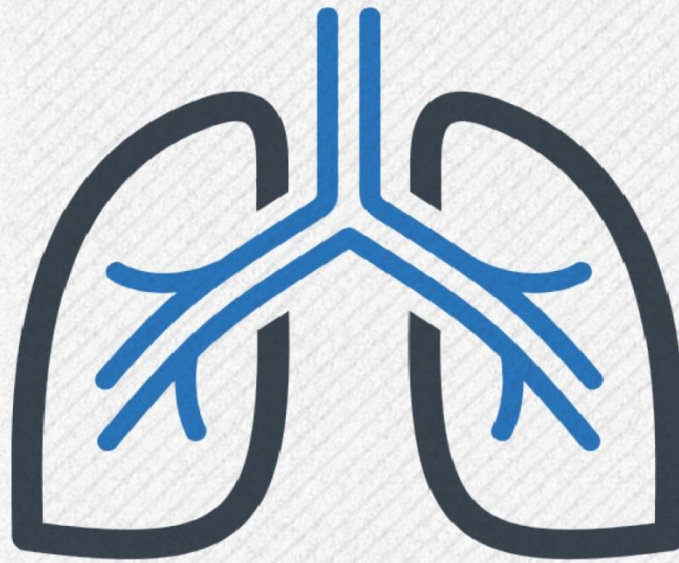
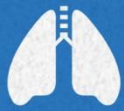


Respiratory system Anatomy



sheet



handout



slides

Number

3

Doctor

Mohammad Al Mohtaseb

Done by

Fahed Al Karmi

corrected by

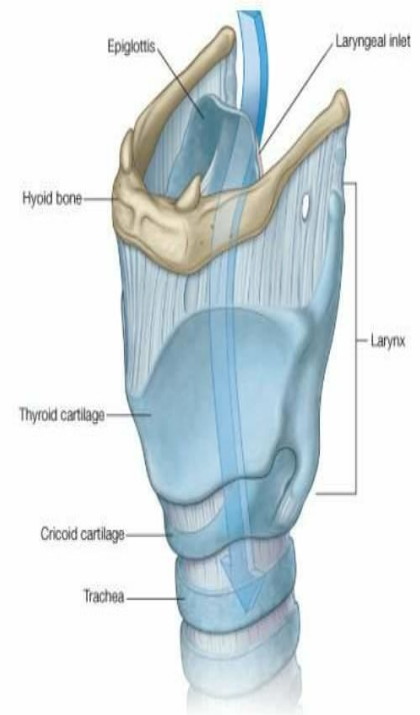
Mohammad Sabateen

The Larynx

- Box of cartilage
- Extends from the middle of C3 vertebra till the level of the lower border of C6 (lower border of cricoid cartilage)
- Continues as Trachea
- Above it opens into the laryngo-pharynx (laryngeal inlet)
- Suspended from the hyoid bone above and attached to the trachea below by membranes and ligaments

Functions

1. acts as an open valve in respiration (passage for air)
2. Acts as a closed valve in deglutition : contraction of epiglottis which goes downward and elevation of larynx so the bolus passes to the esophagus (talking while eating may cause choking which is physical obstruction of the airway, coughing is a protective reflex from choking)
3. Acts as a partially closed valve in the production of voice by vibration (abduction and adduction) of vocal cords during **expiration**, the voice is articulated in the nose (letter N), pharynx and oral cavity (letter L)
4. During cough it is first closed and then open suddenly to release compressed air : adduction of true vocal cords completely closes the airway passage, that increases the pressure below the cords, when they open coughing occurs (protective mechanism)



Parts

1. Cartilage
2. Mucosa lining : it is respiratory mucosa (ciliated pseudostratified columnar) except in:
 - 1- True vocal cords (inside it the vocal ligament): stratified squamous non keratinized, false vocal cords are lined with respiratory epithelium
 - 2- Anterior (upper) surface of the epiglottis (smooth) : oral mucosa which is stratified squamous non keratinized, the lower surface is lined by respiratory mucosa
3. Ligaments and membranes: a membrane is a connective tissue while ligament is a thickening of a membrane in the midline or laterally.
4. Muscles : one external muscles aiding in phonation (the cricothyroid) which causes tension of the true vocal cords to increase the pitch (females have short and thin cords to produce high pitch while males after puberty have thick and long cords for lower

pitch), this muscle is supplied by external laryngeal nerve of the vagus (**the only muscle that is supplied by ext. laryngeal nerve**). Other muscles are internal that abduct or adduct vocal cords, they are supplied by the **recurrent laryngeal nerve** of the vagus (10th cranial nerve) more details in the next lecture

Note: hyoid bone is not part of laryngeal skeleton, it is only the upper border and there are some connections with the larynx through muscles and ligaments (later)

Cartilage

A. Single : Epiglottis, Cricoid and Thyroid

B. Pairs: Arytenoid, Cuneiform and Corniculate

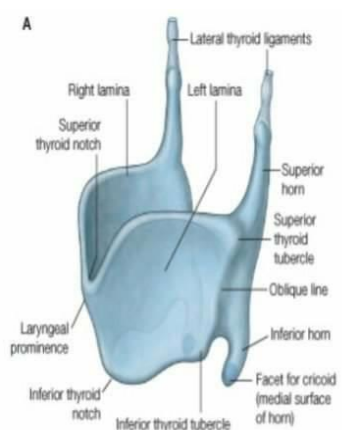
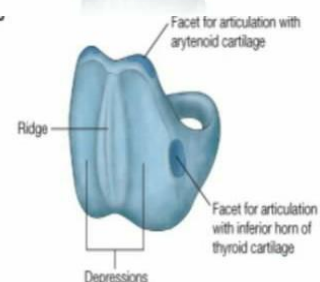
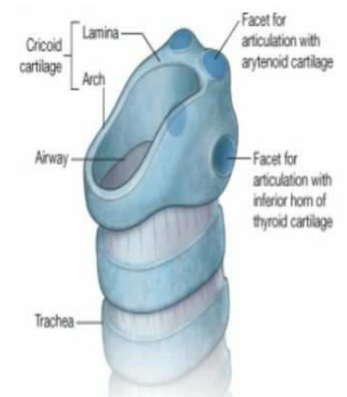
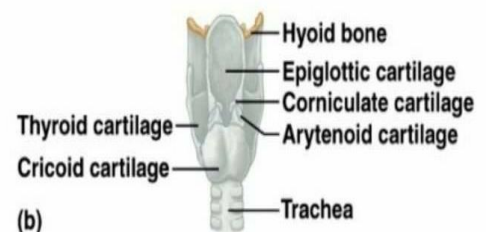
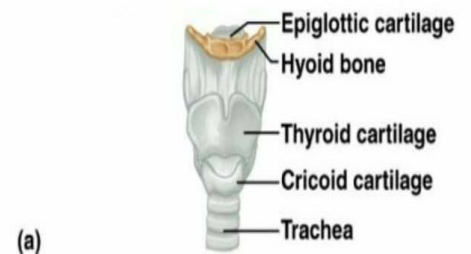
See the picture (a is anterior view, b is posterior)

Cricoid cartilage

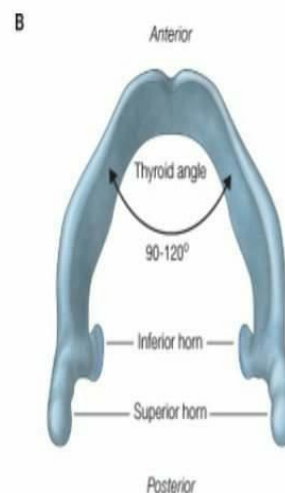
- The most inferior of the laryngeal cartilages
 - Completely encircles the airway (on the other hand, thyroid cartilage is open posteriorly)
 - Shaped like a 'signet ring' : anteriorly the arch and posteriorly the lamina
 - Broad lamina of cricoid cartilage posterior
 - Much narrower arch of cricoid cartilage circling anteriorly.
 - Posterior surface of the lamina has two oval depressions separated by a ridge
 - The esophagus is attached to the ridge
 - Depressions are for attachment of the **posterior crico-arytenoid** muscles(from the depression to the arytenoid cartilage, **abduction** of true vocal cords).
 - Has two articular facets on each side
- 1-One facet is on the **sloping superolateral** surface and articulates with **the base of an arytenoid cartilage**;
 - 2-The other facet is on the **lateral surface** near its base and is for articulation with the **inferior horn of the thyroid cartilage**

Thyroid cartilage

- The **largest** of the laryngeal cartilages
- It is formed by a right and a left lamina
- Widely separated(open) posteriorly, but converge and join anteriorly(anterior midline). (compare with cricoid cartilage)

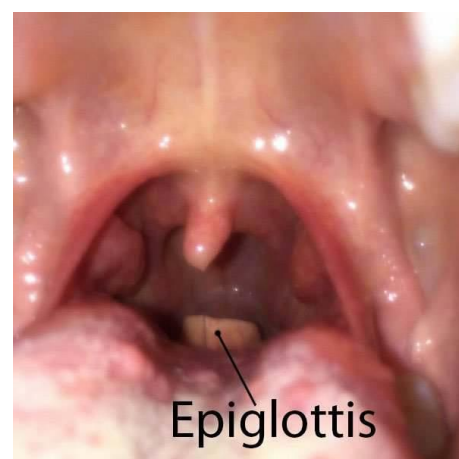


- Posterior margin of each lamina is elongated to form a superior horn and an inferior horn Thyroid cartilage
- Most superior point of the site of fusion between the two laminae is the laryngeal prominence ('Adam's apple')
- Angle between the two laminae is more acute in men (90°) than in women (obtuse, 120°) due to hormonal changes, testosterone makes the angle more acute and the cords longer and thicker so lower pitch, while estrogen and progesterone make the angle obtuse and the cords shorter and thinner so higher pitch (remember cricothyroid muscle above)
- Superior to the laryngeal prominence, the superior thyroid notch separates the two laminae
- Superior thyroid notch and the laryngeal prominence are palpable landmarks in the neck, true vocal cords are deep to this notch.
- Less distinct inferior thyroid notch in the midline along the base of the thyroid cartilage.
- The **medial surface** of the inferior horn has a facet for articulation with the **lateral** facet of cricoid cartilage;
- The superior horn is connected by a ligament to the posterior end of the greater horn of the hyoid bone.
- Lateral surface of lamina is marked by a ridge (the oblique line), which curves anteriorly from the base of the superior horn to the inferior margin of the lamina.
- Ends of the oblique line are expanded to form superior and inferior thyroid tubercles
- The oblique line is a site of attachment for the extrinsic muscles of the larynx (sternothyroid, thyrohyoid, and inferior constrictor of the pharynx).

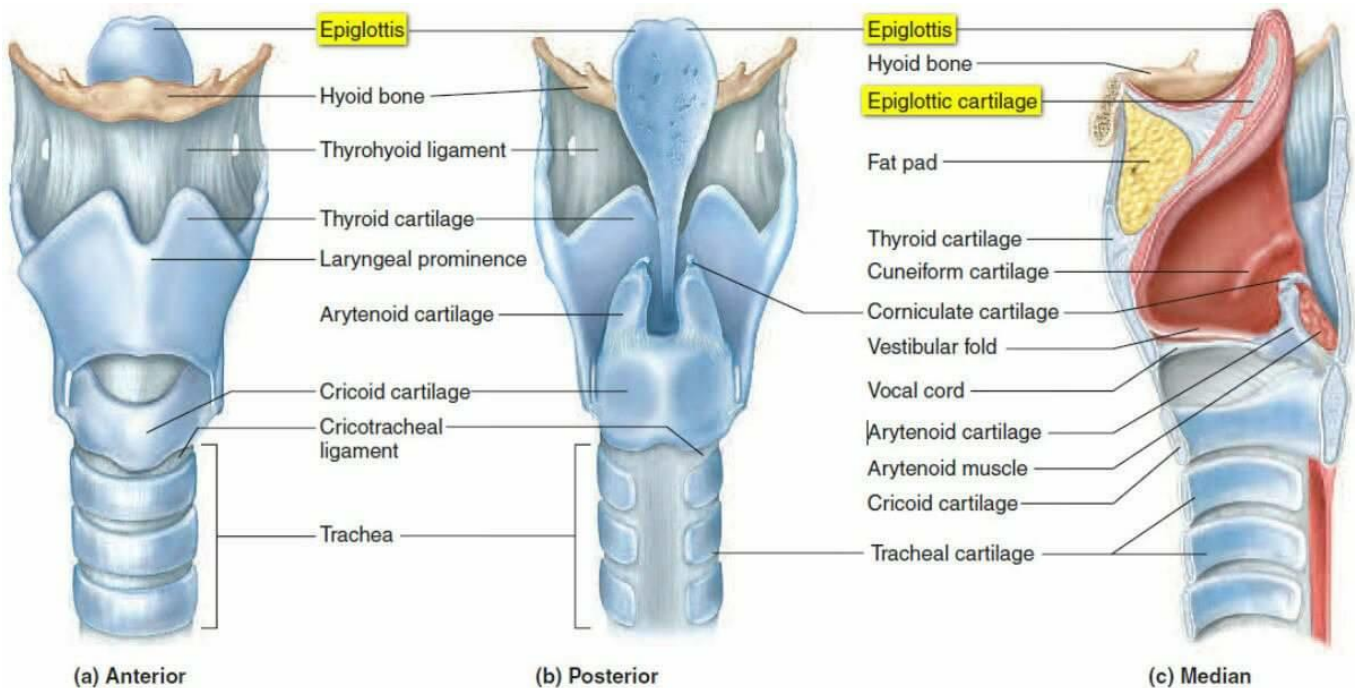


Epiglottis

- Is a 'leaf-shaped' cartilage attached by its stem (apex) to the angle of the thyroid cartilage **internally**. The free edge is superior and the apex is inferior.
- Projects posterosuperiorly from its attachment to the thyroid cartilage.
- The attachment is via the **thyro-epiglottic ligament** in the midline between the **laryngeal prominence and the inferior thyroid notch**
- The upper margin of the epiglottis is behind the pharyngeal part of the tongue.
- The inferior half of the posterior surface of the epiglottis is raised slightly to form an epiglottic tubercle.
- There is a fibroelastic membrane (fold) from the edge of epiglottis to the arytenoid cartilage (The aryepiglottic fold), the aryepiglotticus muscle which runs in this fold contracts to close the inlet, this fold also suspends the cuneiform cartilage. **This fold is the lateral boundary of laryngeal inlet.**

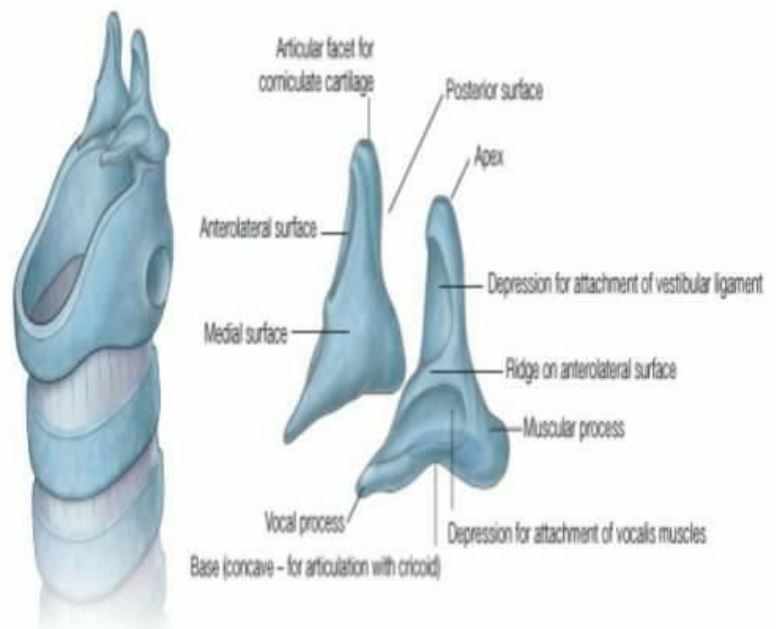


- Superior anterior surface is smooth with oral mucosa, while the posterior inferior surface is rough due to the presence of the ridge and epiglottic tubercle, the lining epithelium is respiratory mucosa



Arytenoid cartilages

- Two arytenoid cartilages are pyramid-shaped cartilages with three surfaces : smooth medial, anterolateral with one ridge and 2 depressions and a posterior surface.
- Base of arytenoid cartilage and an Apex of arytenoid cartilage
- The base of arytenoid cartilage is concave (depression) and articulates with the facet on the superolateral surface of the cricoid cartilage;
- The apex of arytenoid cartilage articulates with a corniculate cartilage;
- The medial surface of each cartilage faces the other;
- The anterolateral surface has two depressions, separated by a ridge, for muscle vocalis (other name is thyroid arytenoid muscle which relaxes the true vocal cords,,,,,and again remember cricothyroid muscle which causes tension) to the **inferior depression** and ligament (vestibular ligament of the false vocal cords) attachment to the **superior**



depression.

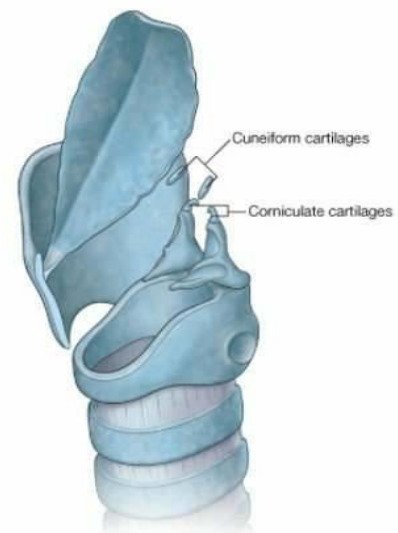
- The base has 2 angles (processes) :

1-The anterior angle (process) of the base of arytenoid cartilage is elongated into a vocal process to which the vocal ligament (see cricothyroid ligament below) is attached

2-The lateral (posterolateral) angle is similarly elongated into a muscular process for attachment of the posterior and lateral crico-arytenoid muscles. Posterior cricoarytenoid muscle abducts (lateral or outside rotation) vocal cords while lateral cricoarytenoid muscle adducts them (medial or inside rotation)

Corniculate and Cuneiform

- The corniculate cartilages are two small conical cartilages
- Bases articulate with the apices of the arytenoid cartilages
- They mark the end of aryepiglottic fold (membrane)
- Their apices project posteromedially towards each other.
- The Cuneiform are two small club- shaped cartilages
- Lie anterior to the corniculate cartilages
- Suspended in the part of the aryepiglottic fold(remember it is a fibroelastic membrane that attaches the arytenoid to the epiglottis).



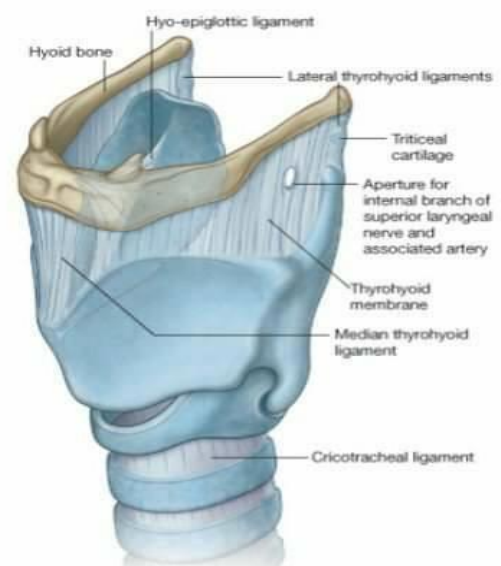
Ligaments

Extrinsic ligaments (remember: thickening of a membrane)

- Thyrohyoid membrane
- Hyo-epiglottic ligament
- Cricotracheal ligament

Thyrohyoid membrane

- Tough fibroelastic ligament that spans between the superior margin of the thyroid cartilage below and the lower border of hyoid bone



- Attached to the thyroid laminae and adjacent anterior margins of the superior horns
- Ascends medial to the greater horns and posterior to the body of the hyoid bone to attach to the superior margins of these structures.
- An aperture in the lateral part of the thyrohyoid membrane on each side is for the superior laryngeal arteries (from superior thyroid artery which is a branch of external carotid), internal laryngeal nerve sensory (sensation above vocal cords) nerve from superior laryngeal branch of the vagus, and lymphatics.

Note: recurrent laryngeal is a mixed nerve (motor for all muscles except the cricothyroid and sensory below vocal cords)

- The posterior borders of the thyrohyoid membrane are thickened to form **the lateral thyrohyoid ligaments**.
- Also thickened anteriorly in the midline to form **the median thyrohyoid ligament**.
- Occasionally, there is a small cartilage (**triticeal cartilage**) in each lateral thyrohyoid ligament to give strength to the ligament.

Cricotracheal ligament

- Runs from the lower border of the cricoid cartilage to the adjacent upper border of the first tracheal cartilage.

The hyo-epiglottic ligament

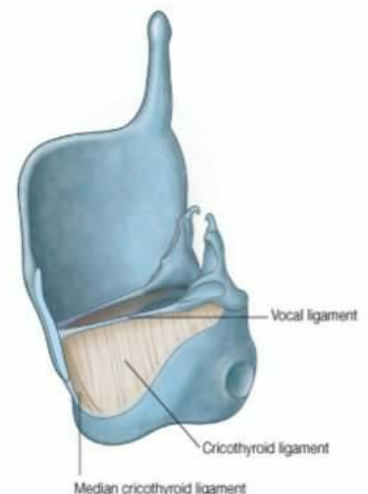
- Extends from the midline of the epiglottis, anterosuperiorly to the body of the hyoid bone.

Intrinsic ligaments

- The fibro-elastic membrane of larynx links together the cartilages and completes the architectural framework of the laryngeal cavity
- It is composed of two parts-a lower cricothyroid ligament and an upper quadrangular membrane.

Cricothyroid ligament

- Cricovocal membrane or cricothyroid membrane. Also called conus elasticus by surgeons.
- Attached to the inside of the arch of cricoid cartilage and extends superiorly (from downwards to upwards)
- End in a free upper margin within the space enclosed by the thyroid cartilage
- Upper free margin (true vocal ligament) attaches:
 - 1-Anteriorly to the thyroid cartilage;
 - 2-Posteriorly to the vocal processes of the arytenoid cartilages.



- The free margin is thickened to form the vocal ligament, which is under the vocal fold (true 'vocal cord') of the larynx.
- The cricothyroid ligament is also thickened anteriorly to form a median cricothyroid ligament
- In emergency situations, the median cricothyroid ligament can be perforated to establish an airway

Quadrangular membrane

- Runs between the lateral margin of the epiglottis and the anterolateral surface of the arytenoid cartilage (superior depression), fibers are from upwards to downwards (compare with cricothyroid ligament)
- Attached to the corniculate cartilage
- Free upper margin and a free lower margin
- Free lower margin is thickened to form the vestibular ligament under the vestibular fold (false 'vocal cord')

Quadrangular membrane

- Vestibular ligament is separated from the vocal ligament below by a gap
- When viewed from above the vestibular ligament is lateral and superior to the vocal ligament

Cartilage and Ligaments

- there is more space between vestibular ligaments, while the space between vocal ligaments is narrower.

Notes:

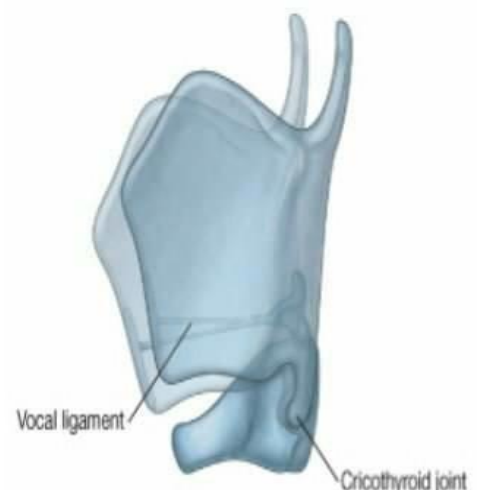
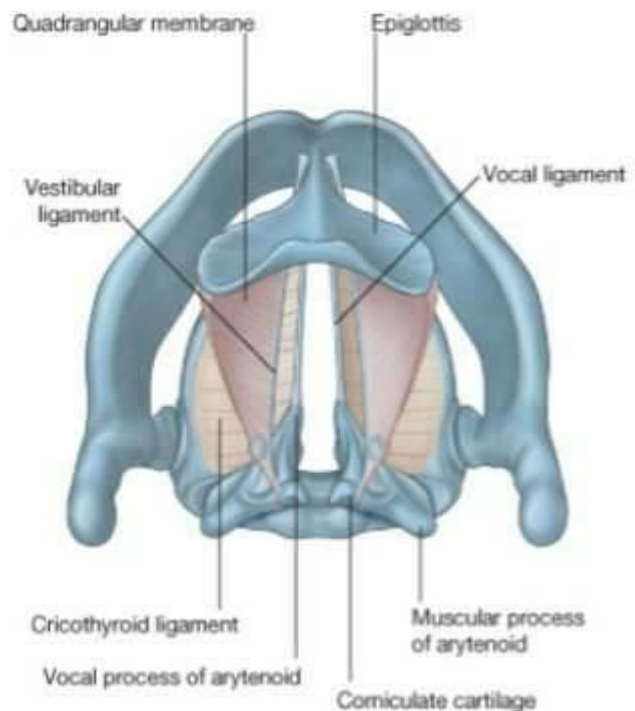
- 1-histological layers from inside to outside: mucosa, ligament, membrane, muscle
- 2-No submucosa in true vocal cords

Laryngeal joints

All are synovial (movement)

Cricothyroid joints

- Between the inferior horns of the thyroid cartilage and the cricoid cartilage, are **synovial**
- Surrounded by a capsule and is reinforced by

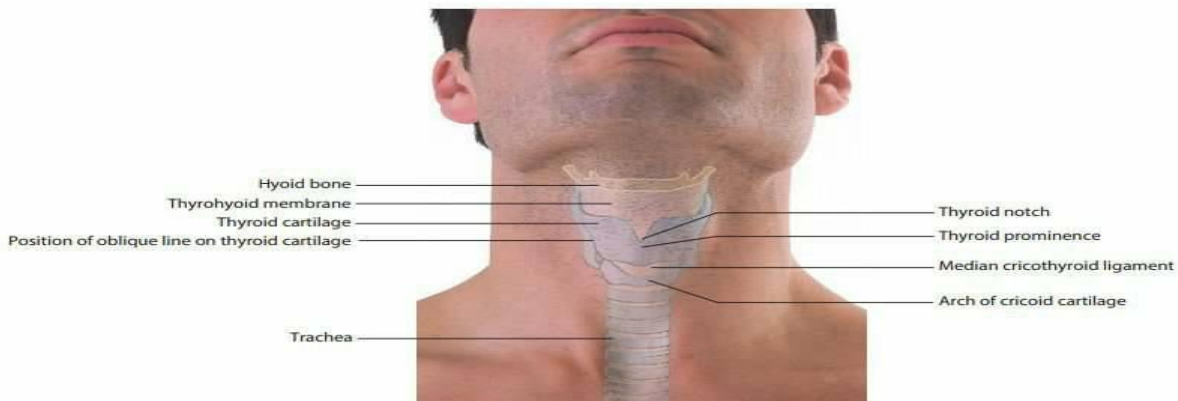
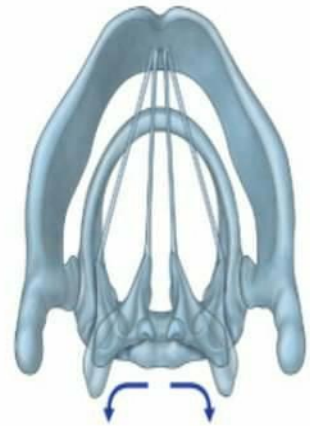


associated ligaments

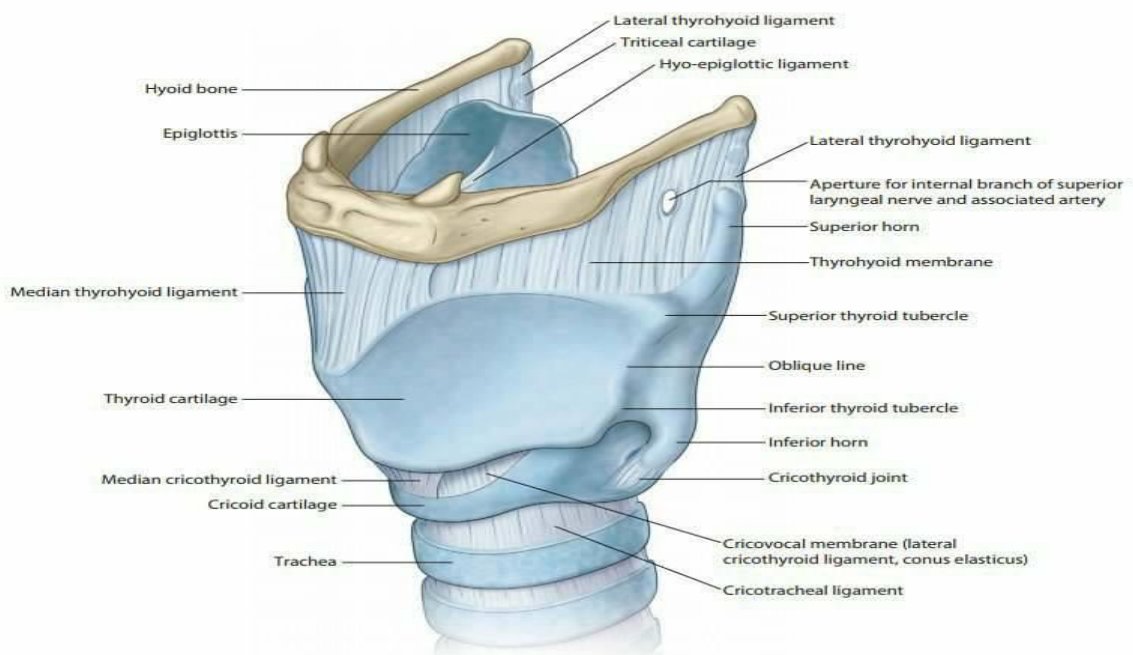
- Enable the thyroid cartilage to move **forward and tilt downwards** on the cricoid cartilage by cricothyroid muscle (increase tension, high pitch)

Crico-arytenoid joints

- Between articular facets on the superolateral surfaces of the cricoid cartilage and the bases of the arytenoid cartilages
- Enable the arytenoid cartilages to slide away or towards each other and to rotate
- The vocal processes pivot either towards or away from the midline.
- These movements abduct and adduct the vocal ligaments
- Posterior cricoarytenoid muscle abducts (lateral or outside rotation) vocal cords while lateral cricoarytenoid muscle adducts them (medial or inside rotation), both muscles are attached to the the lateral (posterolateral) angle (process) in the base of arytenoid cartilage.



Position of larynx in the neck as it relates to the surface



External features of the larynx (anterolateral view)

