

## CASE REPORT

# Milk-Alkali Syndrome a Previously Common but Now Unusual Cause of Hypercalcemia

Shih-Fan Sun MD<sup>1</sup>, Ramy M. Hanna MD<sup>2</sup>

<sup>1</sup>UCLA Health-South Bay Department of Medicine

<sup>2</sup>UCLA Health-Department of Medicine, Division of Nephrology

### Introduction

Milk alkali syndrome is the name for the hyper-absorption of calcium that occurs with ingestion of milk with large quantities of absorbable alkaline calcium tablet.<sup>1</sup> Historical treatment for gastritis included formulations of milk and alkali that brought about initial descriptions of the disease.<sup>2</sup> Inadvertent milk alkali syndrome continued to occur at a steady rate, until the advent of histamine receptor blockers, and proton pump inhibitors significantly reduced the incidence of this disease.<sup>2</sup> The mechanism of milk alkali syndrome involves increased calcium absorption due to factors involving dietary calcium stimulated increases in acid secretion, increased protein breakdown, and increases in available free calcium for absorption.<sup>3</sup> Intestinal calcium absorption is also enhanced by bicarbonate intake via increases in intake of intestinal alkaline phosphatase.<sup>4</sup> Alkali ingestion has been shown to increase calcium reabsorption in murine proximal tubules, but the mechanism is not yet known.<sup>5</sup> It is important to also note that milk alkali syndrome can be directly toxic to the renal tubules and lead to acute tubular necrosis or significant renal damage that can lead to chronic kidney disease.<sup>2</sup>

We presented this case to bring attention to this rare cause of hypercalcemia. Milk alkali syndrome should be considered in hypercalcemic patients where the parathyroid axis is appropriately suppressed, with no evidence of hypervitaminosis D, no evidence of malignancy, and no evidence of rheumatological disease like sarcoidosis.

### Case report

A 68-year-old female with history of hypertension, hyperlipidemia, chronic obstructive pulmonary disease and gout presented to her primary care physician for few weeks of constipation, thirst, intermittent confusion, and body pain. Routine labs were remarkable for calcium of 15.8 mg/dL, potassium of 3.1 mmol/L, bicarbonate of 36 mmol/L, BUN of 35 mg/dL, and creatinine of 2.1 mg/dL. She previously had normal calcium and kidney function. She takes hydrochlorothiazide and atenolol for hypertension, lovastatin for hyperlipidemia, allopurinol for gout, and fluticasone/salmeterol, albuterol and montelukast for chronic

obstructive pulmonary disease. She has a remote history of smoking tobacco 1-2 packs per day for 20 years, but quit in 1983. Family history is remarkable for father with colon cancer at an old age. No other family history of malignancy and patient has never had a colonoscopy. She had no recent travel to coccidiomycosis endemic areas and no tuberculosis exposure.

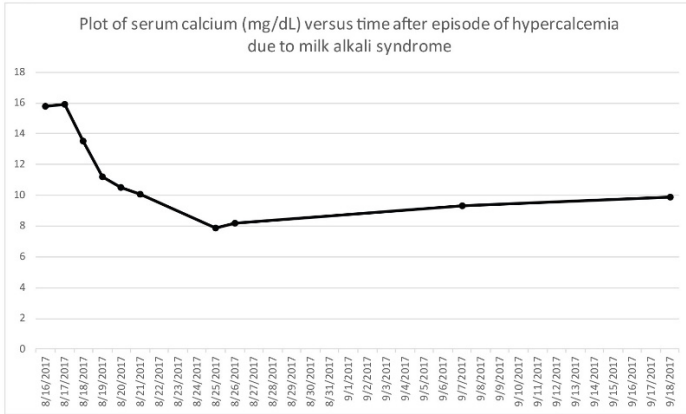
She was sent to the emergency room for further evaluation and management of hypercalcemia and acute kidney injury. Her temperature was 36.3°Celsius, heart rate was 58, respiratory rate was 18, blood pressure was 187/84, and pulse oximetry was 99%. Physical exam was unremarkable. Chest x-ray showed no evidence of acute infiltration or effusion. Abdominal x-ray was nonspecific. Electrocardiogram showed normal sinus rhythm with rate of 61 and left axis deviation. Complete blood count was within normal limits. Albumin was 4.2 g/dL. Total protein was 6.4 g/dL. Ionized calcium was 2.18 mg/dL. Liver function tests were within normal limits. PTH was suppressed at < 2.5 pg/mL. MTB Quantiferon Gold was negative.

She was admitted and treated with intravenous fluids, furosemide, and pamidronate. Hydrochlorothiazide was discontinued. Initial differential diagnoses included malignancy such as myeloma and lung carcinoma and granulomatous diseases such as sarcoidosis. CT chest was repeated given history of sub-centimeter pulmonary nodules noted 5 months ago. The new CT chest appeared to have improved and deemed unlikely the source of hypercalcemia per pulmonology. CT abdomen and pelvis without contrast showed no dominant mass. Calcium normalized to 8.4 mg/dL and creatinine decreased to baseline on discharge.

At follow up the patient recalled that she usually drinks milk with Tums (calcium carbonate). The remainder of the malignancy work ups including SPEP (no monoclonal band), serum Kappa/Lambda light chains (Kappa light chain low at 157 mg/dL, Lambda light chain low at 114 mg/dL, Kappa/Lambda ratio of 1.38), PTHrP (low at < 1.1 pmol/L), and tumor markers (alpha-fetoprotein, CA-125, CA 19-9 and CEA) were all negative. There were no evidence of sarcoidosis based on imaging and labs (ACE level normal at 22 U/L, vitamin D

25-Hydroxy low at 28.7 ng/mL, 1, 25-dihydroxy vitamin D low at < 5.0 pg/mL). Given these unremarkable work ups, patient was diagnosed with milk alkali syndrome and was instructed to stop taking calcium carbonate and stop drinking milk with calcium carbonate. Serial calcium levels have all been normal since stopping this practice. Figure 1 shows trends of serum calcium and Table 1 shows a graphical display of lab values related to calcium homeostasis.

Figure 1



Lab test	value	units	interpretation
PTH	<2.5	pg/ml	supressed
PTHrp	<1.1	pmol/L	supressed
Vit. D2	28.7	mg/mL	low
Vit. D3	<5	pg/ml	very low
ACE level	22	Units/L	normal
SPEP	no m spike	n/a	normal
UPEP	no m spike	n/a	normal
FLC ratio (K/L)	1.377	n/a	normal
Cocci serology	negative	n/a	normal
QFTB gold	negative	n/a	normal

**Table 1 legend:** ACE level=angiotensin converting enzyme level, cocci=coccidiomycosis serology, FLC=free light chains, K=kappa light chain, L=labmda light chain, Mspike= monoclonal spike, QFTB gold=quantiferon mycobacterium tuberculosis serology, dPTH=parathyroid hormone, PTHrp=parathyroid hormone relate peptide, SPEP=serum protein electrophoresis, Vit. D2=25 hydroxy vitamin D, Vit D3=1,25 dihydroxy vitamin D UPEP=urine protein electrophoresis

## Discussion

Milk alkali syndrome is an unusual cause of hypercalcemia in the era of targeted therapies for gastritis and gastric reflux. It illustrates some fairly important points about the need for a thorough review of all over the counter and ingested supplements and notes their potential to cause severe pathology. The interaction of calcium carbonate and hydrochlorothiazide in causing the aforementioned presentation is also notable. In this case cessation of the offending habit resulted in complete resolution of the patient's electrolyte abnormalities, which also included hypokalemia and hypomagnesemia. Ultimately the lack of a clear cause of hypercalcemia including a negative malignancy and infectious workup and a very careful history helped elucidate the pathophysiology of the patient's hypercalcemia. It is important to continue counsel patients who are taking calcium carbonate based medications to avoid excessive doses of these medicines and to avoid concurrent milk intake given the risk of severe sequelae.

## REFERENCES

1. **Medarov BI.** Milk-alkali syndrome. *Mayo Clin Proc.* 2009 Mar;84(3):261-7. doi:10.1016/S0025-6196(11)61144-0. Review. PubMed PMID: 19252114; PubMed Central PMCID: PMC2664604.
2. **Patel AM, Adeseun GA, Goldfarb S.** Calcium-alkali syndrome in the modern era. *Nutrients.* 2013 Nov 27;5(12):4880-93. doi: 10.3390/nu5124880. Review. PubMed PMID: 24288027; PubMed Central PMCID: PMC3875933.
3. **Felsenfeld AJ, Levine BS.** Milk alkali syndrome and the dynamics of calcium homeostasis. *Clin J Am Soc Nephrol.* 2006 Jul;1(4):641-54. Epub 2006 Apr 26. Review. PubMed PMID: 17699269.
4. **Brun LR, Brance ML, Lombarte M, Lupo M, Di Loreto VE, Rigalli A.** Regulation of intestinal calcium absorption by luminal calcium content: role of intestinal alkaline phosphatase. *Mol Nutr Food Res.* 2014 Jul;58(7):1546-51. doi: 10.1002/mnfr.201300686. Epub 2014 Apr 22. PubMed PMID: 24753180.
5. **Bomsztyk K, Calalb MB.** Bicarbonate absorption stimulates active calcium absorption in the rat proximal tubule. *J Clin Invest.* 1988 May;81(5):1455-61. PubMed PMID: 3366902; PubMed Central PMCID: PMC442577.

Submitted October 5, 2017