

The background of the cover is a reproduction of Michelangelo's famous fresco, "The Creation of Adam," from the ceiling of the Sistine Chapel. The central focus is the reclining Adam on the left, whose right arm is extended towards the right, and the bearded God on the right, whose right arm is extended towards Adam. The two hands are just inches apart, creating a sense of tension and divine spark. The fresco shows the intricate musculature of the human body and the dramatic use of light and shadow.

# PLASTIC & RECONSTRUCTIVE SURGERY

FOR THE MEDICAL STUDENT

ALEXANDER C. CASTILLO





Earning a spot in a plastic surgery residency program is a daunting task that is becoming evermore competitive. Every year, I hear residents make the remark that “If I was applying now there’s no way I would get in.” It is important to develop a competitive application as early as possible to allow yourself the best chance of gaining a spot. This guide was made with the medical student in mind that is wanting to shine on his/her away rotation or plastic surgery clerkship. I have compiled concepts and questions that I was “pimped” on during my rotations. Some topics may seem elementary to a few however everyone starts on different levels and hopefully those topics provide help to others.

This guide is by no means sufficient for any discussion in detail but is designed to provide the most high yield questions on certain topics. If on your rotations you receive questions that you feel are important to add to this document please email me and we can expand on it:

[accastil@utmb.edu](mailto:accastil@utmb.edu)

If this document is helpful let me know as I have considered adding a cosmetic chapter as well as hints and tips for leaving an impression during away rotations. The current document is simply what I have been able to put together during my away rotations and my “interview trail”. High yield questions I was asked are denoted by an asterisk (\*) followed by the answer.



*Chapter 1*

GENERAL





## SECTION 2

# Introduction

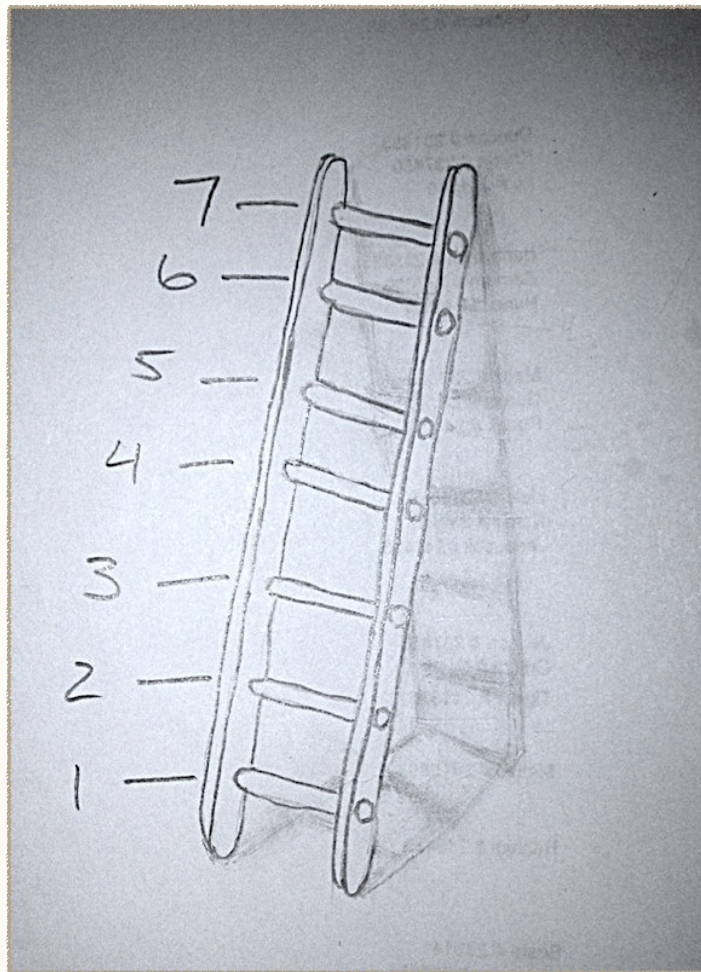


I would like to start off with a chapter that is composed of basic surgery concepts that don't quite fit into the other chapters of the book.



## **PLASTIC SURGERY RECONSTRUCTIVE LADDER**

The reconstructive ladder is a great place to start as it becomes second nature in the way the plastic surgeon undertakes a defect. This concept helps to analyze a wound and come up with possible ways to close the defect starting with the simplest option and progressing up to more complex choices. If an option is chosen that has “rungs” above it then this allows for a back-up plan if needed.



	METHOD OF CLOSURE
7	free tissue transfer
6	Regional tissue transfer
5	Local tissue transfer
4	Skin graft
3	Delayed primary closure
2	Primary closure
1	Secondary closure

## **WOUND HEALING**

Wound healing is an important area of study in the field of plastic surgery. Plastic surgeons have a lot of interaction with the healing process especially when they are consulted for the hard to cover defect or non-healing decubitus ulcer. Wound healing



---

concepts can fill volumes of books up however the basic idea should be understood. The process of wound healing has been divided into three overlapping phases:

- Inflammatory phase (days 1-6) = this phase occurs immediately following injury to the tissue. The main components of this phase are to attain hemostasis, removal of debris and devitalized tissue and to prevent further colonization of pathogens.

\*What is the first cell present following injury to the tissue?

- Platelets are the first cell present followed by:

Neutrophils @ 24-48 hours

Macrophages @ 48-72 hours

Lymphocytes @ 5-7 days

- Proliferating phase (day 4-21) = during this phase granulation tissue is formed and three cells predominate: fibroblast, macrophages and endothelial cells. Vascularization begins to form in this phase as well as an increase in tensile strength begins.

- Remodeling phase (week 3 - year 1) = this is the longest phase of wound healing but also the least understood. The wound begins to contract as well as collagen remodeling occurs. The type III collagen which was laid down during the proliferative phase is replaced with type I collagen during this phase.

\*When is the peak tensile strength reached?

- Between 2-3 months the wound will reach 70-80% strength of unwounded skin.

### **ANESTHETICS:**

Very often plastic surgeons will use local anesthetics at the site of operation. Anesthetics are classified into two categories: amides & esters.

Amides - lidocaine and bupivacaine are included in this group. Amides are metabolized in the liver.

Esters - procaine and cocaine are included in this group. They are metabolized via hydrolysis in the plasma by pseudo-cholinesterase.

*Except for cocaine, all anesthetics cause vasodilation.*

Lidocaine is commonly used and when combined with epinephrine (which frequently occurs) incorporates a two-fold effect. The lidocaine acts rather quickly to produce a local anesthetic and epinephrine causes vasoconstriction which helps to minimize bleeding at the incision and operation site. The vasoconstriction also slows the absorption of anesthetic via the surrounding tissue causing an increased duration of anesthetic locally.

\*How long does it take for epinephrine to work?

- Traditionally textbooks have taught it takes 7 minutes until the epinephrine works. Recently new literature is emerging that reports a 25 minute wait time after injection.



\*What is the most dilute concentration of epinephrine that can be used?

- 1:100,000 - 1:200,00 are common dilutions of epinephrine however 1:1,000,000 has also been reported as an effective concentration.

As well as lidocaine, bupivacaine is also commonly used and serves as a longer duration anesthetic.

\*What should you be cautious about when using bupivacaine?

- Do not accidentally inject into artery or vein as this can cause cardiovascular collapse that is frequently refractory to attempts at resuscitation.

\*What can accidental intravascular injection of epinephrine cause?

- This can cause a dangerous hypertensive response.

### **CANCER:**

In plastic surgery, the most common cancers we encounter are basal cell carcinoma, squamous cell carcinoma and melanoma. Let's briefly highlight these three individually.

### **BASAL CELL CARCINOMA:**

Basal cell carcinoma (BCC) is the most common malignancy being the culprit up to 75% of the time and is frequently found on the head, neck and shoulder regions where patients

have had chronic sun exposure. BCC is a slow growing tumor that can be locally invasive but rarely metastasizes. If left untreated this tumor can cause significant tissue destruction locally and eventually result in a slow death. Risk factors that predispose to BCC include but are not limited to sun exposure, UV radiation and the patient's Fitzpatrick skin type (Fig 1).

Figure 1

SKIN TYPE	COLOR	NOTES
I	Light, pale white	Burns easily and never tans
II	White, fair	Burns easily but tans with difficulty
III	Medium, white to olive	Slow to burn and will tan
IV	Olive to brown	Slow to burn and tans easily
V	Brown to dark brown	May never burn
VI	Black	May never burn

\*What is an inherited form of BCC?

- Nevoid basal cell syndrome (Gorlin's syndrome) is an autosomal dominant disease that causes multiple BCC to form.



---

There are many different subtypes of BCC (20+) however from my experience discussion was centered around 4: Nodular, Superficial spreading, Infiltrating & Morpheaform.

**Nodular** is the most common type of BCC and is the classic form we were introduced to in the beginning of medical school. This type shows the “rolled borders with telangiectasias” and is often referred to as the rodent ulcer.

**Superficial spreading** is reported to have the highest recurrence rate of all BCC because they extend peripherally beyond their clinically apparent borders. Clinically they can look scaly, crusted and erythematous which can be confused as eczema or psoriasis.

**Infiltrating basal cell carcinoma** is poorly marinated and runs an aggressive course. The tumor often runs deep and becomes perpendicular to the skin surface.

**Morpheaform (or sclerosing)** is rare and has minimal elevated skin. The margins in this subtype are clinically impossible to detect and **requires** frozen sections during excision as the tumor has been reported to be up to 7mm from the clinical border. This subtype is the most aggressive of all the types.

### **SQUAMOUS CELL CARCINOMA:**

Squamous cell carcinoma (SCC) is the second most common accounting for 20% of skin malignancies. Risk factors are similar to BCC in addition to HPV exposure and chronic non-healing burns or wounds. SCC are not grouped into subtypes however their grading depends on the degree of cellu-

lar differentiation. The better differentiated the cancer the better the prognosis. SCCs metastasize more often than BCCs do.

\*What is a SCC called that can arise from a wound with chronic inflammation or non healing burn?

- Marjolin ulcers can arise in these wounds and will carry a risk of metastasis up to 50% of the time.

### **MELANOMA:**

This is the third most common skin cancer occurring only 3% of the time but does report for up to 80% of skin cancer related deaths. Risk factors are quite similar to the other two skin cancers discussed. The four most common subtypes we discussed during my rotations were superficial spreading, nodular, lentigo maligna and acral lentiginous.

**Superficial spreading** is the most common melanoma which is the cause 70% of the time. It has been known to arise from preexisting moles.

**Nodular** is the second most common occurring 20% of the time. This type is more aggressive than superficial spreading and usually begins in normal skin (not from preexisting mole).

**Lentigo maligna** presents on skin that has been repeatedly sunburned. These lesions are often hard to distinguish with the naked eye. They rarely are invasive.

**Acral Lentiginous** occurs on the palms, soles and beneath the nail beds of patients. They arise most commonly in darker skinned individuals.



*Chapter 2*

GRAFTS &  
FLAPS





# Introduction



Skin grafts and skin flaps make up a good portion of plastic surgery. For multiple reasons, patients may present with wounds that need to be covered by vitalized tissue. You will encounter the uncontrolled diabetic patient who has a non-healing leg ulcer, the paraplegic patient who has developed a pressure ulcer or the patient who has recently undergone a surgical resection of cancer and all of these cases could benefit from the plastic surgeon. The job of the surgeon is to cover this defect with tissue to allow for appropriate healing underneath and gaining control of the wound. This chapter will begin with a discussion on skin grafts and then will shift the focus to skin flaps.



Grafts can come in all shapes and forms and is defined as a unit of tissue that has disruption of its native blood supply while being transferred from a donor site to recipient site. It must form a new network of blood vessels at the recipient site. Different grafts are used differently and the following will be reviewed.

TYPE	SOURCE
autograft	from self
allograft	from cadaver
xenograft	another organism
synthetic	manufactured matrix

Different grafts have different objectives and will now be discussed individually.

### **AUTOGRAFT**

Autografts are grafts taken from the same patient that is in need of tissue coverage. Autografts can be either a Split Thickness Skin Graft (STSG) or Full Thickness Skin Graft (FTSG).

**STSG:** Harvesting this tissue from the patient can be done by a “dermatome” which uses a blade in order to take a specified depth of skin. This process will leave a donor site which is capable of healing on its own. This is because dermal remnants are left behind such as sweat glands and hair follicles which contain epidermal cells that are capable of repopulating the donor site.

- We facilitate the healing of the donor site by keeping it moist and one way of doing so is by covering the site with a hydrocolloid dressing (aka Duoderm). This dressing has the ability to adhere to the donor site only requiring a surrounding gauze for absorbing excessive exudative drainage that seeps outside of the Duoderm. The hydrocolloid dressing is made of polymers, gelatin and other particles which allow for absorption of the exudate drainage and water from the wound. After absorbing the drainage, the gel forms a moist environment around the wound and promotes wound healing.
- Another way of keeping the donor site moist is by simply wrapping the wound with a plastic dressing. This method is reported by the patients to be less painful than the Duoderm.

STSG can be harvested anywhere from the individual’s body but if given the choice will usually be taken from the lateral aspect of the thigh. The lateral thigh provides for a great surface area of harvested tissue while avoiding the less anesthetic looking scar on the anterior aspect and the more painful interior thigh site.

**FTSG:** Harvesting this tissue from the patient requires removing the epidermis and all of the dermis usually with a scalpel. Since all of the dermis is taken, the donor site will lose the ability to heal on its own. Most times the donor site will be closed primarily.

\* When do you decide if the wound needs a STSG or FTSG?



- This question came up a few times for me during my away rotations and the best way to answer this question is to explore a phenomena known as primary contraction and secondary contracture. These effects happen in both STSG and FTSG but to varying degrees on each. Primary contraction occurs immediately after a skin graft is taken. It is seen when the graft rolls on itself at the edges. Secondary contracture occurs later on in the process of wound healing. It describes how much the graft will distort the surrounding tissue (or contract) during the development of a scar. After reviewing this concept you can see depending on the location of graft placement will warrant the graft used. For instance, if a graft is to be placed on the face the surgeon would desire a graft which has as little secondary contracture as possible. As scar and contracture formation on the face could be very anesthetically displeasing as well as could distort important surrounding structures. Whereas if a graft is needed on the arm or leg due to a large defect, the surgeon would not be as concerned with secondary contracture as this area could be covered with clothing. The surgeon would be more attuned to coverage of the wound as quickly as possible and secondary contracture would be less important. Now which graft has which properties. To remember this concept, I found it easiest to visualize the grafts on a spectrum (Fig. 1).

Figure 1



STSG



FTSG



---

As you can see, increasing the depth of the skin graft increases the amount of dermis included and all components within it. The amount of dermis included will effect both the primary contraction and secondary contracture. As stated, primary contraction occurs after the graft is taken. This is the immediate recoil after being harvested and is caused by the proteins elastin and collagen. FTSG have more of a primary contraction than STSG because of the increased amount of these proteins in the graft. Secondary contracture is the more concerning result of the healing process and occurs later and presumably by myofibroblast (one attending told me a new study suggested otherwise). Having more dermis in place, FTSG are able to hold their shape better than STSG and as a result have less secondary contracture. For a lesion on the face or mobile areas such as overlying a joint, secondary contracture should be avoided if possible.

(At one university, we were placing a FTSG harvested from the neck onto the face and the physician asked )

\*Why did we choose to harvest the graft from this location?

- Facial features of a person are the first aspect noticed on any individual and our goal for any defect of the face should be to make the result as normal-appearing as possible. *FTSGs*, when taken from above the clavicles, have the greatest matching in skin tone to the face that is hard to beat when grafts are taken from anywhere else. Grafts taken from above the clavicles also allows for an appropriate sympathetic response in the patient. For example, when a patient blushes the graft will be able to vasodilate as well. This is in contrast to if the graft is taken elsewhere, the graft won't be able to have the vasodilation to the same extent as the remainder of the face and as result the patient will have a pale spot during an episode of blushing.

### **STSG GRAFT SURVIVAL:**

Once a STSG is placed, it is important for it to remain in contact with the wound bed in order for it to “take”. “A graft can't take on air.” If a seroma or hematoma forms underneath the graft it will compromise the nutrient supply as well as the success rate of the graft. Grafts that will take go through three different phases:

- Plasma imbibition = this occurs up to the first 48 hours and is a time when the graft gains its nutrients by simple diffusion from the wound bed
- Inosculation = occurs from 48 hours to 72 hours and is when the graft is using it's own blood vessels to gain nutrients
- Angiogenesis = after 72 hours the blood vessels in the graft begin to attach to vessels on the wound bed



---

(Full circulation is restored within 4-5 days)

As can be suspected, during this time the graft-wound bed adherence is very fragile. Shear force is a common cause of graft failure which damages the newly forming vessels.

\*What is the leading cause of skin graft loss?

- Hematoma underneath the graft is the most common

### **ALLOGRAFT:**

Allograft is a graft from the same species and in our practice will mostly be from a cadaver. As suspected, a skin graft from another source is prone to eventually fail. However, this graft is not designed for a permanent solution. This graft is used as a temporary means for: 1) coverage and 2) to assess if the wound bed is ready for a permanent graft. In any patient who is recently burned, sick with a non-healing wound or in any other unstable condition one of the first steps is to cover the wound. This will reduce water loss in the burn patient or allow an infection to pass as one stabilizes a patient. Allograft can also be used to see the condition of the wound bed. In a healthy, well prepared wound bed allograft will “take” for the first 2-3 weeks but then will eventually be rejected. If the graft takes for this long it is a good sign the surgeon can proceed with autograft if possible.

\*What part of the graft is responsible for rejection?

- Langerhan cells are the antigen-presenting cells located in the epidermis. The cells are responsible for rejection.

### **XENOGRAFT:**

These grafts come from another species and are used when a donor site is not available such as in a large body surface burn patient.

### **SYNTHETIC:**

Synthetic grafts or dressings can be used to facilitate wound healing when the wound bed is not optimized for a graft quite yet.

Integra dermal regeneration template is a bilayer wound matrix. It is an acellular construct consisting of an epidermal layer made of silicone and a dermal layer consisting of cow and shark cartilage. Once this graft is placed, the collagen on the dermal side is absorbed and act as a template allowing the blood vessels and cells to grow within the graft. They continue to grow along the template forming a dermal layer onto which a future autograft can be placed. After 14-21 days, the silicone (epidermal) layer is removed and the autograft is placed on top of the newly made dermis. This matrix does not have any active cells or release growth factors or matrix proteins in contrast to the next dressing.

Another synthetic dressing used is a bilayer construct of bovine collagen with human keratinocytes and fibroblasts. This dressing has viable cells that release and stimulate growth fac-



---

tors and matrix proteins to encourage wound healing. Apligraf and OrCel are two dressings that work in this way and are used to treat diabetic foot ulcers.



As mentioned previously, the coverage of a wound is an important operation performed by the plastic surgeon. Skin grafts will not always do the trick and as a result skin flaps must be considered. Skin grafts are very unlikely, if not impossible, to “take” on avascular tissue such as exposed tendon, cartilage or bone and skin flaps should be considered at this time. A flap of tissue is defined as a unit of tissue that maintains its own blood supply during and after being transferred from a donor site to recipient site. Flaps can be local (advancement, rotational or transpositional) or axial flaps (in-tact or free flap).

### **LOCAL FLAPS:**

A local flap aka “random” skin flap is appropriate when there is a defect that has skin laxity immediately adjacent to it. These flaps are based off the subdermal plexus for blood supply and are generally limited to a 3:1 length-to-width ratio. Local flaps can be further categorized into an advancement, rotational or transpositional flap. Advancement and rotational flaps rely on “stretching” of the skin to cover a defect. Whereas a transpositional flap covers a defect by “translocating” a piece of tissue to a defect without causing stretching of the skin.

### **ADVANCEMENT FLAP:**

When a unit of skin is moved forward in order to cover a defect. It is not rotated or moved laterally during the advancement. There is many types of advancement flaps in which a

textbook could be devoted to. Here I will show the most basic type to allow for visualization of the advancement flap (Fig. 2).

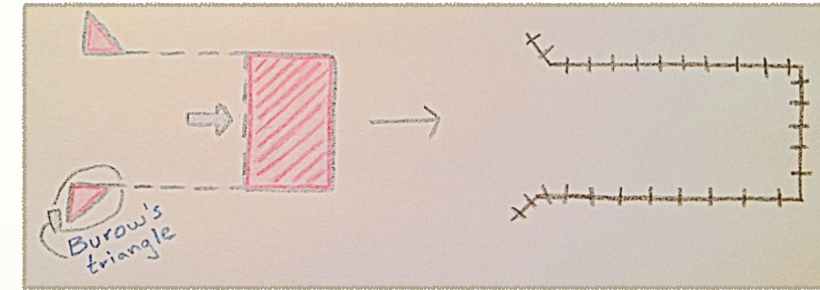


Figure 2

### **ROTATIONAL FLAP:**

These flaps (as the name implies) will rotate amongst a pivot point. As shown (Fig. 3), there are a few additional cuts that can be made to increase the distance of flap coverage. I have shown a backcut and a Burrow's triangle.

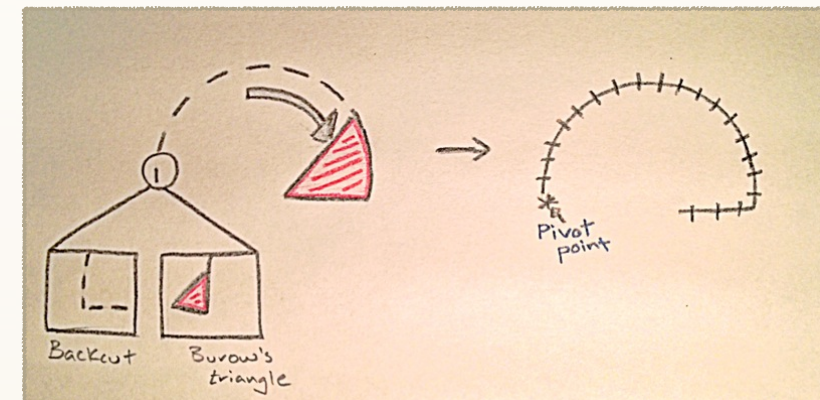


Figure 3

\*What do you have to be cautious about when using a back cut?

- When you make a backcut you are cutting into the base of the flap and its blood supply.



There are many variations of these two flaps and in order to fully appreciate local flaps an outside reference must be sought.

**TRANSPOSITIONAL FLAP:**

These flaps cover a defect without stretching of the skin. Transpositional flaps can be thought of as covering a defect by “transposing” local tissue on top of it. The bilobed flap (Fig. 4) is an example of this flap and uses primary closure at the donor site to relieve any stretching that might accumulate.


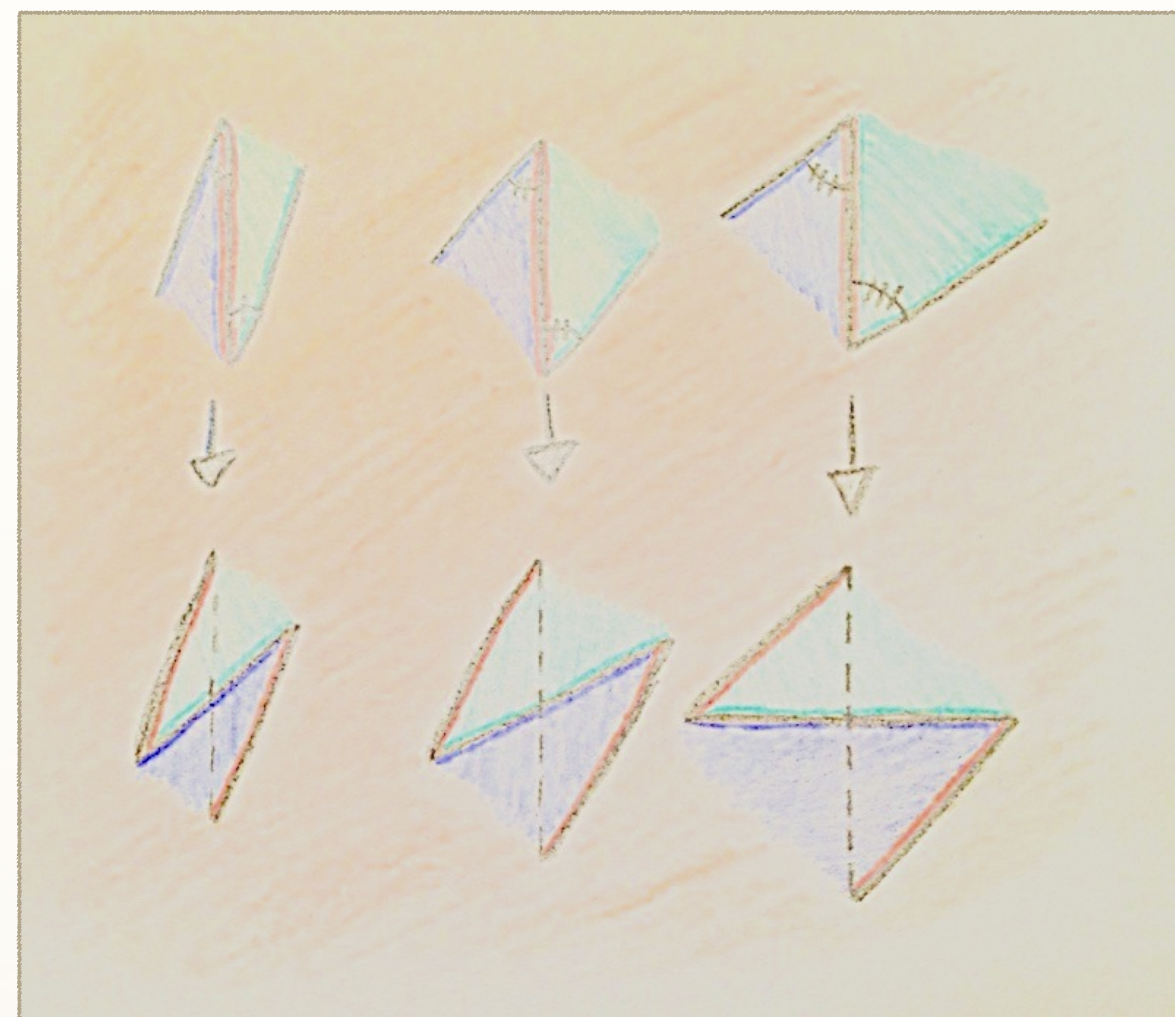


Figure 4

**Z-PLASTY:**

Another form of local flap is a z-plasty. This flap is utilized when revising scars or releasing (or lengthening) a scar contracture. This is because a Z-plasty flap is designed to lengthen the tissue. The central limb is placed on top of the scar or line of tension. Two triangular flaps are raised alongside the central incision and transposed to provide a theoretical gain of length to the central limb. The plastic surgeon can gain different lengths depending on the angle used for the triangular flaps (Fig. 5). Figure 4 is also color coded to help visualize flap placement.

Figure 5



ANGLE	GAIN IN LENGTH (%)
30	25
45	50
60	75
75	100



---

Now we will turn our discussion to pedicle flaps. Pedicle flaps do not solely rely on the subdermal plexus for blood supply as do the random flaps. Pedicle flaps have a direct artery supplying the flap which provides the blood supply. These flaps can consist of different combinations of tissue used such as fasciocutaneous, musculocutaneous, bone or solely muscular flap. We will first review muscular flaps as I feel this knowledge is essential for a thriving medical student then will briefly give mention to a couple more complex flaps. Once again there are books devoted to this subject and should be read in addition to this material. I will end with a quick reference chart to the flaps and blood supply as this is high yield on a rotation. Keep in mind these flaps are capable of being used locally by keeping the pedicle intact or separating the artery and using the flap as a free flap almost anywhere on the body.

### **MUSCULAR FLAPS:**

First let's go over the classification system used for muscle flaps which depends on their circulation pattern.

Mathes and Nahai developed a classification system based on the vascular anatomy.

Type I: Consists of one single vascular pedicle to the muscle. Examples:

- Gastrocnemius
- Tensor fascia lata

Type II: Consists of a single dominant pedicle along with minor pedicles. On dissecting out this type of flap, all or most of the minor pedicles will need to be divided. Examples:

- Gracilis
- Rectus femoris
- Biceps femoris
- Brachioradialis

Type III: Consists of two dominant pedicles, each which can supply the flap. Examples:

- Gluteus maximus
- Pectoralis minor
- Rectus abdominis
- Serratus

Type IV: Consists of a series of segmental pedicles that run along the course of the muscle. Each segment provides circulation to a portion of the flap and as many should stay intact as feasible. Examples:

- External oblique
- Sartorius

Type V: Consist of one dominant pedicle with secondary segmental pedicles. Either blood supply can support the flap. Examples:

- Internal oblique
- Latissimus dorsi



---

- Pectoralis major

### GASTROCNEMIUS (Type I):

This muscle flap has potential as a free flap as well as a local flap. A free flap scenario may include a functional muscle transplant to restore elbow flexion. However, more commonly this flap is used locally to cover defects on the lower extremity. With the increasing number of total knee replacement procedures today and the inherent risk of infection in this area you will likely see this flap. The gastrocnemius muscle is divided into a medial and lateral head. Either head alone can be raised to act as a flap and when only one head is used the functional loss in the patient is negligible. The medial flap is longer and thicker, making it the more common head used. The medial and lateral heads are supplied by the **medial and lateral sural artery**, respectively. The sural arteries arise from the popliteal artery which itself is a continuation of the femoral artery. It is important to give mention to the nerves in this area as they run superficial to the vessels in the popliteal fossa and you could be asked to identify them. As the sciatic nerve courses down the posterior leg it comes to the apex of the popliteal fossa and divides into the tibial nerve and common peroneal (fibular) nerve. The tibial nerve courses down the center of the popliteal fossa and approximately halfway gives off the medial and lateral sural motor branches which are responsible for their respective heads. The tibial nerve will then run underneath the medial and lateral heads. At the beginning of the popliteal fossa

the common peroneal nerve courses laterally along the biceps tendon. It will continue along this direction and overlie the lateral gastrocnemius head where it will run along the lateral aspect.

### GRACILIS FLAP (Type II):

The gracilis is a good muscular flap which can be used locally for wound coverage or perineal reconstruction. It is also readily available to act as a free muscle transfer and is actually the first choice flap for the application of a functioning free muscle transplantation for functional restoration. This free flap has been employed as a functioning muscle in face or limb deficits. This is possible because of the size, length, reliable blood supply and minimal donor site morbidity in function and cosmesis due to the medial thigh donor site. Distally the gracilis has a long tendon which can be used in making a functional muscular flap. The proximal 1/3 of the gracilis can be taken in times of need for facial reanimation or the whole muscle can be taken for arm/forearm muscle replacement. The gracilis muscle's main blood supply is the **terminal branch of the medial femoral circumflex artery**. This branch enters the gracilis muscle belly approximately 8 cm below the pubic tubercle. The medial femoral circumflex originates from the deep femoral artery. As this muscle is a "go-to" for a functional muscle we must point out the motor nerve. The muscle is innervated by the anterior branch of the obturator nerve. This nerve enters the muscle 1-2 cm above the artery.



---

### SERRATUS ANTERIOR FLAP (Type III):

This muscle originates from the lateral scapular and fans out in “slips” attaching to the first 9 ribs. Harvesting the whole muscle is discouraged as the “winged scapula” can present. As a result, the lower three slips are used and can be taken in a combination of all three, just two or a single slip. The superior slips are supplied by the **lateral thoracic artery** and the bottom three are supplied by the **thoracodorsal artery**. We use the bottom three for reconstruction. This flap can also be used for breast reconstruction.

### RECTUS ABDOMINIS (Type III):

The rectus abdominis muscle flap is commonly used for breast reconstruction as well as coverage of defects such as perineum wounds. Being a type III flap it has two dominant pedicles: the **superior epigastric artery** from the top and the deep **inferior epigastric artery** from the bottom. The superior epigastric artery originates from the internal mammary artery and the inferior epigastric artery originates from the external iliac artery. This flap can be rotated up for chest reconstruction when based on the superior pedicle or down for perineum reconstruction based off of the inferior pedicle. Gaining access to this flap is the perfect opportunity for a very popular medical student question.

\*What are the layers of the abdominal wall?

-Skin

-Two layers of fascia

-Camper’s fascia - superficial fatty layer

-Scarpa’s fascia - deep membranous layer

-Rectus sheath

Above arcuate line:

Anterior sheath - Composed of external and internal oblique

Posterior sheath - Composed of internal oblique and transversalis muscle and fascia

Below arcuate line:

Anterior sheath - Composed of external and internal oblique and transversus abdominis

Posterior sheath - transversalis fascia only

### GLUTEUS MAXIMUS (Type III):

The glueus maximus (GM) flap will be a local flap more times than not. This flap relies on a short pedicle causing a difficult dissection. Proving it’s value as a local flap, the GM flap is an ideal choice to cover decubitus ulcers in the sacral or ischial areas of paraplegic patients as well as a few perineal defects. The blood supply of the GM flap comes from both the **superior and inferior gluteal arteries** (Type III - two dominant pedicles however usually the inferior gluteal artery is dominant supplying 2/3 of the muscle). These arteries are terminal branches of the internal iliac artery. After



---

branching off the internal iliac artery, the superior and inferior gluteal arteries pass above and below the piriformis muscle. For completion, the GM is innervated by the inferior gluteal nerve which courses alongside the inferior gluteal artery.

\*What happens if the inferior gluteal nerve is cut?

### PECTORALIS MAJOR FLAP (TYPE V):

The pectoralis major muscle is considered a good option for reconstruction of the head and neck regions. Especially when a patient requires radiation in that region as the pectoralis major is most times located outside the radiation field. Being a type V flap, it has a primary dominant pedicle and secondary segmental pedicles. The primary blood supply is the **pectoral branch coming off of the thoracoacromial trunk**. The pectoral branch pierces the fascia underneath the muscle medial to the pectoralis minor muscle. The secondary pedicles are made up of perforating intercostal branches from the internal mammary artery. For completion, the pectoralis major is innervated by the medial and lateral pectoral nerve branching off of the medial and lateral cords of the brachial plexus.

### LATISSIMUS DORSI FLAP (Type V):

This flap is a great addition to the plastic surgery armamentarium as it is the largest muscle in the body, largest muscular flap on a single pedicle and does not result in a significant donor functional defect. This flap is one of the most commonly

used flaps in plastic surgery being either harvested on a pedicle or as a free flap. The primary dominant pedicle of this flap is the **thoracodorsal artery** which comes off of the subscapular artery. The subscapular artery itself originates from the axillary artery. The thoracodorsal artery divides into a medial and lateral branch within the muscle allowing for the muscle to be taken as a whole or only the superior portion resulting in a partial superior latissimus dorsi flap. The secondary segmental pedicles are posterior intercostal perforators. For completion, the latissimus dorsi is innervated by the long thoracic nerve. This flap is used commonly in breast reconstruction as well as coverage for the upper extremity.

All of the previous flaps have the ability to be harvested with skin paddles intact for reconstruction options and/or flap monitoring of viability. The next flaps do not consist solely of muscle and in fact many times won't contain muscle however these will be seen on your rotations.

### PARAMEDIAN FOREHEAD FLAP:

This flap is used for extensive defects around the nose or upper eyelids. I saw a handful of these on my away rotations after a patient had a basal cell carcinoma removed from the nose tip. This flap is good for reconstruction of the nose because it has a great match in skin tone and texture. The forehead is rich in blood vessels and quite a number of flaps can theoretically be made. For reconstruction of the nose, a verti-

---

cal flap is harvested respecting the **supratrochlear artery** for the blood supply. This procedure occurs in 2-3 phases. During the first phase, the vertical flap is raised and is rotated and transposed down on top of the nose defect. The flap is left intact on the inferior aspect where the pedicle enters the flap. At one university where I saw this procedure, the surgeon left this intact for 2 weeks in non-smokers and 3 weeks in smokers. By leaving the pedicle intact, it creates for a disfiguring look however it is essential for a sufficient collateral blood supply to form between the nose defect and flap. This 2-3 weeks is used to ensure maximum vascularity. During the next phase, the pedicle may safely be divided. Another procedure may be used to thin the flap for a more appropriate cosmetic look. This takes approximately 6 weeks after all phases are accomplished. The donor site on the forehead can be closed primarily in most cases. Healing by secondary intention may be used on larger defects of the distal section.

#### DIEP:

The **Deep Inferior Epigastric Perforator** flap is in contrast to the TRAM flap because it is muscle sparing. Currently, DIEP flaps are a top choice for breast reconstruction in cases where large flaps are needed. This flap consist of skin and fat from the lower abdomen without sacrificing any of the abdominal muscles.

#### ALT:

The Anterolateral Thigh Flap is a fasciocutaneous flap based on the **descending branch of the lateral circumflex femoral artery**. This flap is used as a free flap for larger defects and has the advantage of having the option to tailor the thickness of the flap by altering the amount of vastus lateralis muscles harvested. There are many cases in which an ALT can be used. On one of my away rotations, I saw this flap used to reconstruct a tongue.

#### RADIAL FOREARM:

The radial forearm flap has skin that is thin and pliable enough to be fabricated into many sizes allowing for many uses. On an away rotation, I saw a case where this flap was used to reconstruct a patient's lower jaw. This flap is based off of **branches from the radial artery**. As a result, if this flap is being considered one must ensure complete circulation via the ulnar artery.









*Chapter 3*

BURNS





# Introduction



A burn patient is a serious and challenging task for any physician. Depending on the severity, they require close observation while at the same time possibly being unpredictable. I describe this chapter after the discussion on grafts because skin grafts are a vital part in the recovery of a burn patient. I will describe a quick review on the burn patient and then discuss some of the aspects that are more specific to plastic surgery.



The burn patient needs his ABCs (airway, breathing & circulation) monitored very closely. The peak incident of mortality in a severe burn patient is in a bi-modal distribution with the first peak within 24 hours and the second at approximately a month. There are a number of different methods to predict the mortality in a burn patient. I am most familiar with the APACHE II scoring system and it is still widely used since it has been around since the 1980s and has accumulated much data. There is also the FLAMES scoring system as well as the MOD scoring system. These scoring systems take into account different comorbidities and risk factors.

It is important to review the histology of a burn as well as the classification of burns as this will change the treatment and management of the patient.

A burn is divided into 3 zones (Fig. 1):

**Zone of coagulation** - center of wound consisting of necrotic nonviable tissue that is treated with excision and grafting

**Zone of stasis** - this zone surrounds the zone of coagulation and is initially viable. Adequate hydration is needed to maintain perfusion and to prevent the transformation into nonviable tissue

**Zone of hyperemia** - the outermost zone which is viable and will remain so with adequate hydration

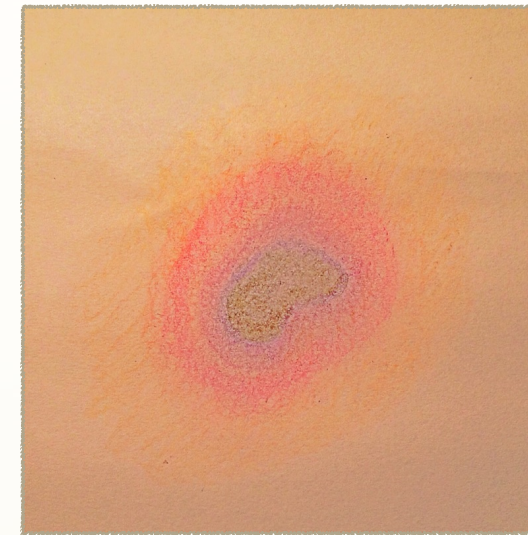


Figure 1

**First degree:** consist of epidermis only and are considered painful. They are caused by flash flame burns or even seen in the common sunburn.

**Second degree** are divided into two categories:

**Superficial:** consist of dermis without involving skin appendages and blanches with pressure

**Deep:** dermis and skin appendages that doesn't blanch with pressure

Blistering occurs in any second degree burn and is a specific sign when this depth of burn has been achieved. Second degree burns are considered very painful. They are caused by liquid burns, chemical burns or even flame burns that have involved the clothes and as a result have been in close contact to the skin for a period of time.

**Third degree:** consist of the entire dermis with underlying structures and is considered painless. This can be caused by chemical burns, liquid burns, prolonged flame burn or electrical burn. There isn't blistering noted in this degree.

As alluded to previously, the degree/depth of burn indicates the treatment required. A first degree superficial burn requires rehydrating lotion to aid in the epithelial repair process. A second and third degree burn requires an agent that provides moisture but also exhibits antibacterial properties.

AGENT	USED FOR	CHARACTERISTICS	SIDE EFFECTS
Silvadene (silver sulfadiazine)	Broad spectrum gram (+) and gram (-)		- Leukopenia - Penetrates eschar poorly
Sulfamylon (mafenide acetate)	Broad spectrum gram (+) and gram (-)	<b>Can penetrate eschar</b> Used commonly on the ears and nose	- Potent carbonic anhydrase inhibitor leading to metabolic acidosis = hyperventilation <b>- Painful</b>
Silver nitrate	Broad spectrum with <b>pseudomonas coverage</b>		- Stains everything black - Hyponatremia - Hypochloremia - Hypokalemia

\* Why do we use sulfamylon on the ears and nose?

- Sulfamylon is used on these areas because of its good eschar penetration. This allows for protection against suppurative chondritis which if occurs usually requires surgical excision.

\* If sulfamylon has good penetration, why not use it everywhere on the body?

- Sulfamylon is too painful to apply over the whole body and also can cause acidosis.



---

We will now turn our attention to the different types of burns.

***THERMAL BURN:***

These are caused by fire or hot liquid and are the most common cause of burn.

\*What is the dreaded tumor that can arise in a chronic burn wound?

- Marjolin's ulcer (typically seen in areas that were not skin grafted)

***CHEMICAL BURN:***

It is important to immediately treat a chemical burn with copious irrigation with water.

\*Why don't we advise neutralization of a chemical burn?

- This will cause an **exothermic** reaction which will superimpose a thermal burn injury on top of the chemical burn

\*Which burn is worse: alkaline or acidic burn? Why?

- Alkaline burns are worse because they cause a liquefaction necrosis which allows the alkaline to penetrate deeper and extend the area of injury.

***ELECTRICAL BURN:***

Any time a patient presents with an electrical burn an entry and exit wound must be identified. As the electricity travels through the body, it can cause damage to internal structures. Hence, electrical burns can be a lot worse than they initially perceive to be. For these patients, ECG must be obtained as

well as assessment of the ABCs. These burns have traditionally been categorized into low-voltage and high-voltage injuries with 1,000-volts being the cut off value. Patients who have suffered low voltage injuries with no loss of consciousness are typically treated conservatively and discharged. Whereas the patient with high-voltage burns needs to be monitored more closely. Cardiac monitoring is done for the first 24 hours, myoglobinuria is watched for, and the assessment for fasciotomy is typically done.

\*How do we treat myoglobinuria?

- Adequate hydration, alkalinization of the urine and mannitol if needed.

\*How do we make sure the patient is hydrated appropriately?

- Urine output is the best indicator of hydration status. A normal goal of urine output is 30 mL/hr. However, if myoglobinuria is suspected a new goal of 100 mL/hr is sustained until the urine has turned from the tea color to clear.

\*How do we alkalinize the urine?

- By giving the patient sodium bicarbonate.

***INHALATION BURN:***

\*What is the only way patient's can be burned below the vocal cords?

- Through steam or inhalation burns (not through direct thermal burns)

---

Inhalation burns should be suspected in any patient who has a history of being trapped in a car or house during the event. Carbon monoxide poisoning is a concern in this setting. Treatment for these patients is usually supportive.

We will review the burn patient in chronological order as they would present.

*INITIAL ENCOUNTER:*

The physician who will treat a burn victim must be familiar with some type of fluid resuscitation protocol. The most widely used is the Parkland formula or some variation of this. This formula calculates the fluid resuscitation required in the first 24 hours after the burn to ensure the patient stays hemodynamically stable. This formula is:

$$4 \text{ mL} \times \text{BSA} (\%) \times \text{weight (kg)}$$

Example: a 70 kg male with 30%TBSA would require

$4 \times 30 \times 70 = 8,400$  mL in the first 24 hours after the burn.

A few important notes:

- half of the fluid needs to be given within the first 8 hours of the event and the second half given over the next 16 hours
- this amount needs to be given within 24 hours after the event. If the patient presents 4 hours after the burn, the total fluid required per formula (ie 8,400 mL) will need to be given over the next 20 hours (and the first half would be given over 4 hours)



In order to calculate Total Body Surface Area (TBSA) you need to be familiar with the rule of 9's (Fig. 2). This provides an assessment of the extent of the burn. Various parts of the body are given percentages in which are added to give the TBSA. In some cases, the total allocated area is not burned and at this time you will use the *patient's hand* to measure the burned area. The *patient's hand* is roughly equivalent to 1%.

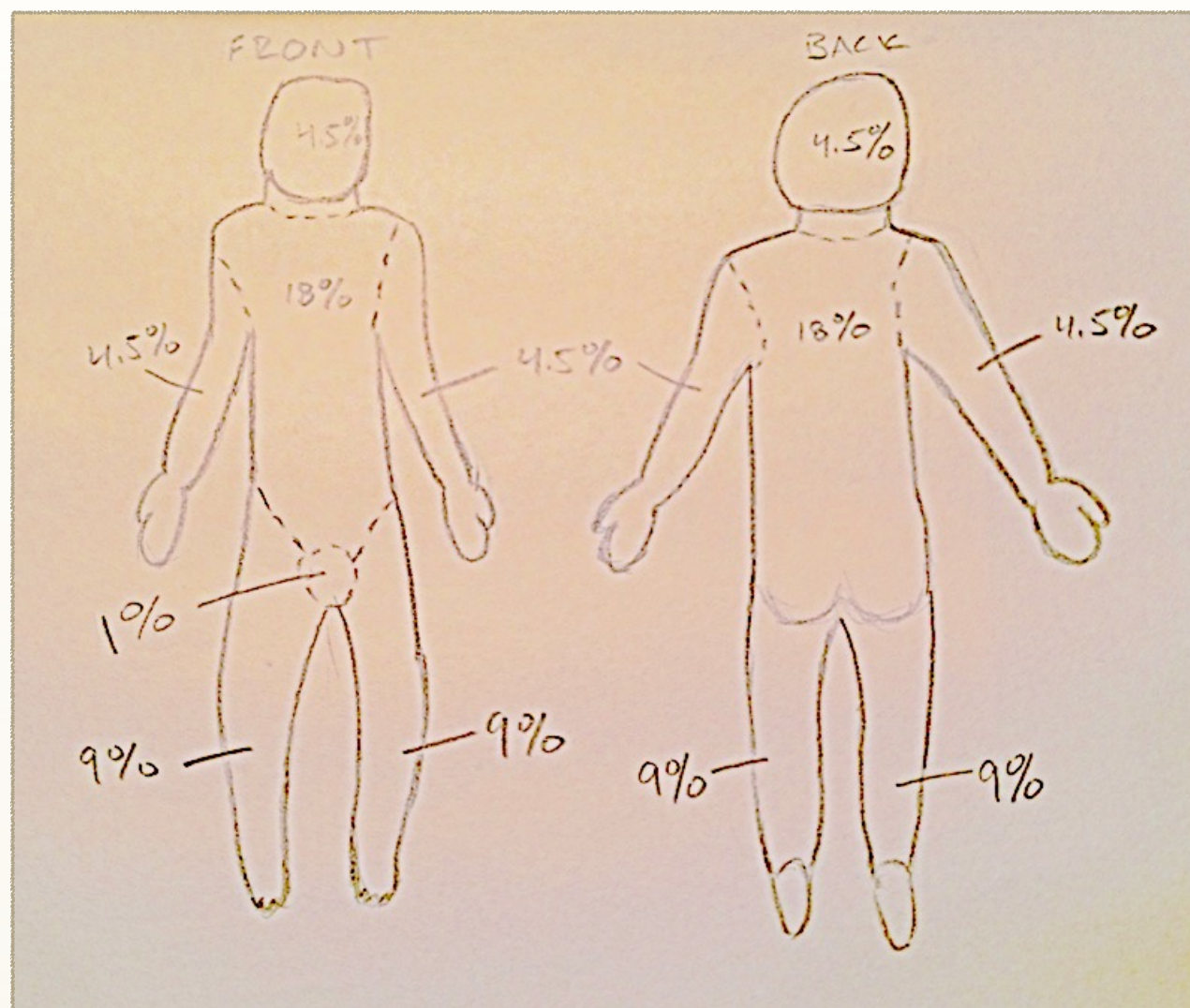


Figure 2

(A different key is used for baby's that are born as their proportions are slightly different)

---

It is also important to be aware of possible circumferential eschar formation during the initial event. Once you have identified an eschar in a patient you will be able to always identify it. Eschar is defined as “dead tissue” and can be formed after a deep extensive burn of the skin. If this eschar forms circumferentially it can restrict any function underneath it. For example, if an eschar forms around the thorax this could compromise respiration. If an eschar forms around an extremity, it could compromise the blood flow to the distal segment resulting in ischemia and possible extremity loss. During one of my away rotations we had a patient with 60% TBSA burns come to the trauma unit. The resident on call identified a circumferential eschar around the thorax and immediately began performing an escharotomy. This is the treatment for the feared circumferential eschar. Using either a scalpel or bovie, you need to cut through the eschar to allow expansion and function of the restricted lungs or vessels.

*STABLE PATIENT:*

Once the patient has become stable, the injured areas need to be addressed. From my experience, this is initially accomplished via allograft coverage. By placing allograft, this reduces the amount of fluid loss through the open wound via evaporation. Allograft placement also allows for observation of the wound and to assess its ability to receive an autograft. If the wound bed is healthy, an allograft will “take” until it is rejected 10-21 days later. At this time it would be appropriate to place autograft on the wounds if there are donor sites available.



*Chapter 4*

**SKELETAL  
RECONSTRUCTION**





# Introduction



The plastic surgeon operates on the whole body and at times will find the need to operate on the face after a trauma event or on the head of a newborn who has premature fusion of a suture line. I developed this chapter for reviewing this region of the body and will also include a section on the hand at the end.



Defects in the head are quite noticeable as they are the most obvious part of the body and should be addressed when needed. I will conduct this review starting from the cranium and will make my way down to the mandible.

### CRANIUM:

The surgeon can use a bicoronal incision to access the frontal sinus region after a trauma event or for visualization of the skull when a newborn has premature fusion of the sutures.

Anytime a surgeon is making an incision through the cranium a favorite question to ask students is:

\*What are the layers I'm cutting through?

- This answer can be easily recalled with the mnemonic

#### SCALP

S - skin

C - connective tissue

A - aponeurosis or galea

\*Underneath the galea (subgaleal) is the desired level for dissection and undermining as it is the least vascular and provides for the easiest and "cleanest" dissection possible.

L - loose connective tissue

P- pericranium

Another question I was asked a few times is:

\* Why do we want to restrict how much we bovie the scalp area?

- You want to damage as few hair follicles as possible so that the scar line will be as least visible as possible.

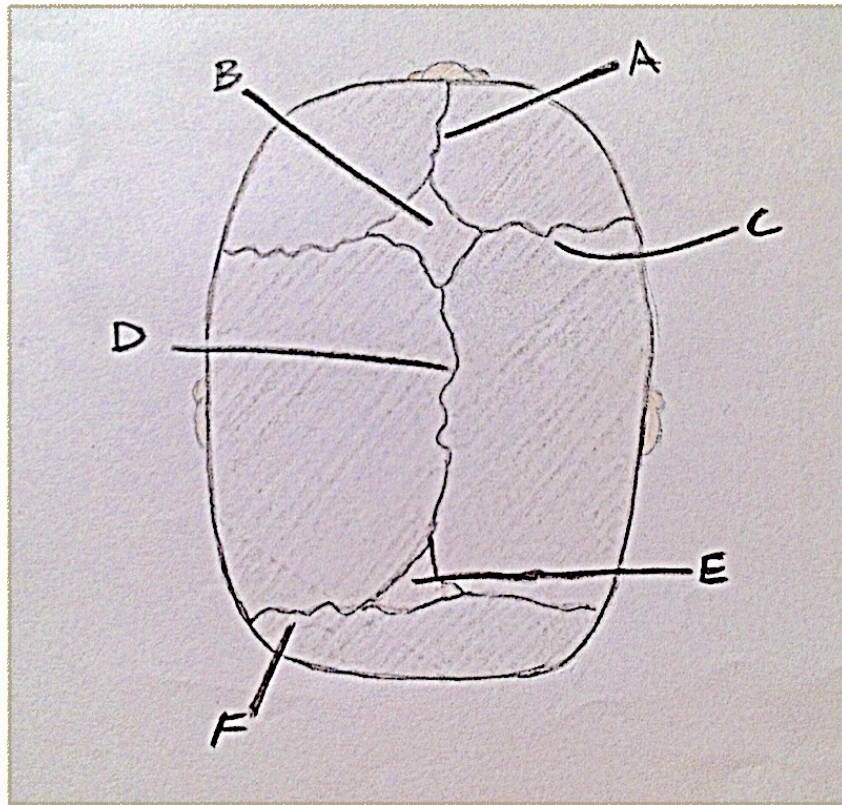
Frontal sinus trauma will be addressed in the next section but let's review craniosynostosis.

In a normally developing newborn, the growing brain causes the skull to expand both parallel and perpendicular to the suture lines (Fig. 1). However, if the suture lines fuse prematurely the skull will only be able to expand **parallel** to the fused suture lines. Premature fusion of sutures is termed craniosynostosis and can involve single or multiple sutures. There are recognized head shapes that form in relation to the sutures involved and we will now review these.

Sutures and normal time of fusion:

SUTURE OR FONTANELLE	TIME
Metopic	2 years
Sagittal	22 years
Coronal	24 years
Lambdoidal	26 years
Posterior fontanelle	3-6 months
Anterior fontanelle	9-12 months

Figure 1



A	Metopic suture
B	Anterior fontanelle
C	Coronal suture
D	Sagittal suture
E	Posterior fontanelle
F	Lambdoidal suture

### **Sagittal synostosis:**

The most commonly seen is sagittal synostosis making up 50% of craniosynostosis cases with a male:female ratio of 4:1. The premature fusion of this suture line makes up a characteristic head shape known as scaphocephaly (“boat-shaped”). The head becomes elongated in the anterior to posterior (AP) direction and shorter in width. These patients will also show frontal bossing with an occipital bulge.

### **Coronal synostosis:**

This is the second most commonly seen with 20% unilateral and 20% bilateral.

- Unilateral: This results a deformity named anterior plagiocephaly (“oblique skull”). On the side of fusion it results in a single frontotemporal bone plate. As one can imagine, this would cause AP shortening and frontal flattening on the fused side. The contralateral side will continue to grow and elongate causing frontal bossing as well as parietal bossing. The supraorbital and lateral rim on the fused side will be elevated and recessed in contrast to the contralateral orbital rim which will show depression.
- Bilateral: Bilateral coronal synostosis occurs with equal frequency and causes the head shape brachycephaly. This head shape is widened laterally and elongated vertically causing a “tower-shaped head”.



---

### **Metopic synostosis:**

This form occurs less than 10% of the time and gives the characteristic trigonocephaly which is triangular in shape. There is frontal flattening with flaring of the parietal bones. There will be a ridge on the forehead as well as an increase in the AP dimension.

### **FRONTAL NASAL SINUS:**

The frontal bone is the strongest bone in the face and requires the greatest force of any facial bone to become fractured. The frontal sinus sits in between the orbits and drains via the nasofrontal ducts in the nasal cavity.

\*Are the frontal sinuses present at birth?

- No, they begin development at age 2 and continue growing up until age 12.

A CT scan is required if there is suspicion for a frontal sinus fracture. The possibility of this fracture is serious as it can lead to a bacteria entry point to the underlying brain matter. The physician needs to evaluate the anterior and posterior tables of the sinus. An assessment should also be sought for nasofrontal duct involvement. Open reduction and internal fixation (ORIF) is acceptable for the patient who doesn't have a duct involvement or CSF leak. However, if the nasofrontal duct is involved without a CSF leak, obliteration of the sinus is warranted. The sinus mucosa is completely removed because if the duct is injured and there is not an outlet for mucous, there will be an accumulation of fluid. If the

patient does present with a CSF leak and/or posterior table comminution the patient will be at constant risk of meningitis as the barriers have been violated. This patient will require removal of the posterior table, removal of duct mucosa and isolation between nasal and cranial cavities with a pericranial flap.

## ORBIT:

Any operation around the eye can be the perfect setup for a question on eyelid anatomy (Fig. 2). This is tough anatomy to identify grossly however a diagram could aid here. Identifying a question correctly would be impressive for any medical student.

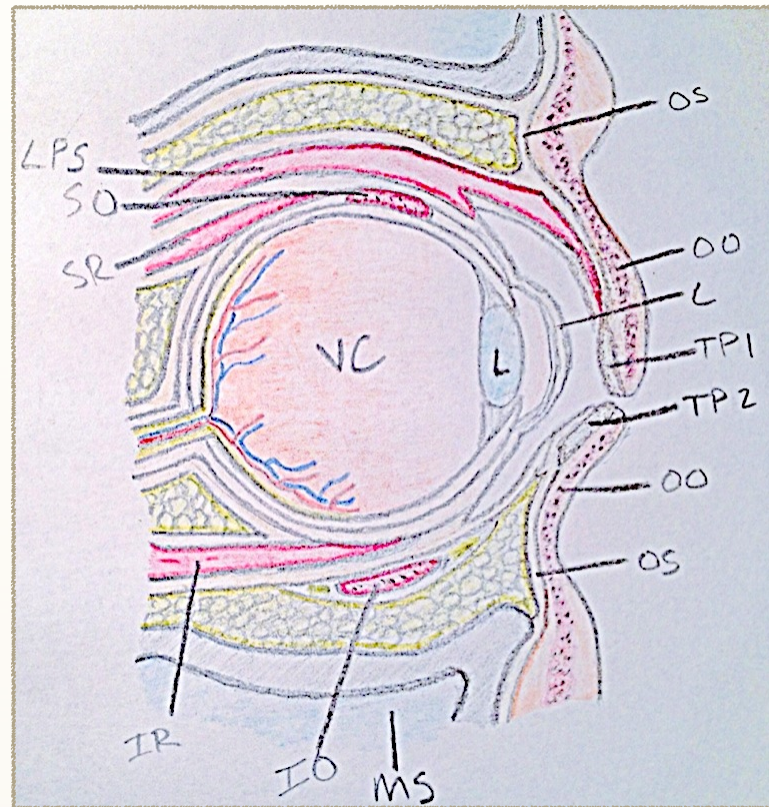


Figure 2

OS	Orbital septum
OO	Orbicularis oculi
TP1	Superior tarsus plate
TP2	Inferior tarsus plate
IO	Inferior oblique
IR	Inferior rectus

SR	Superior rectus
SO	Superior oblique
LPS	Levator palpebrae superioris
VC	Vitreous chamber
L	Lens
MS	Maxillary sinus

This area is prone to fractures as the orbit is surrounded by bone (with the thinnest portion being the lamina papyracea located along the medial wall). This area is also important as incisions made here can provide access to many parts of the facial skeleton. Incisions can be made externally along the lower eyelid (subciliary approach) as well as inside the lower eyelid (transconjunctival approach). These incisions provide visuals to the infraorbital rim and floor of the orbit. One dreaded complication of trauma to the orbit is optic nerve compression.

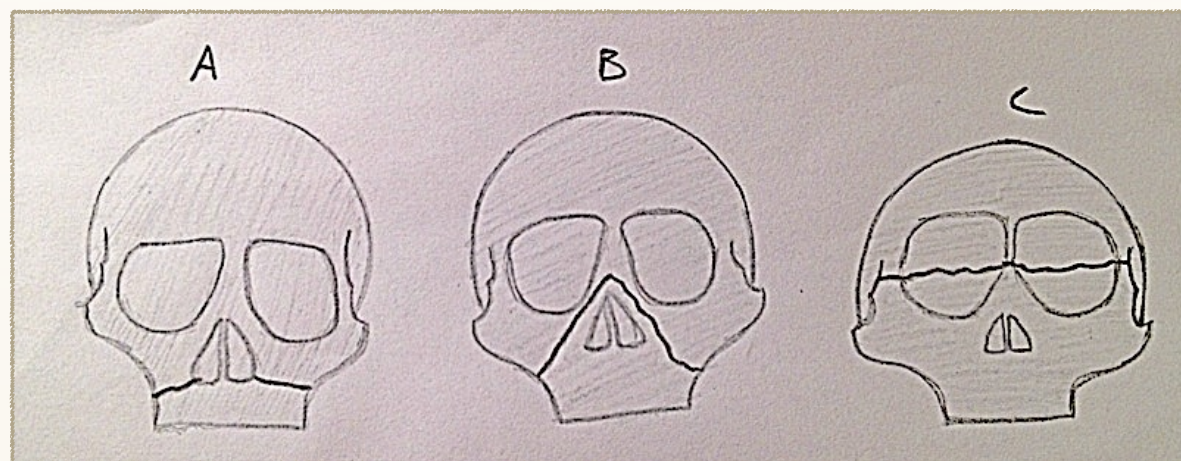
\*What should you be worried about with any change in vision after trauma around the eye?



-Optic nerve compression can be a dreadful complication because if undetected it can lead to blindness. Any change in vision should prompt the physician to investigate this scenario. The first indication of optic nerve compression is red color desaturation. This can be easily tested for with a light source (pen light). Hold the pen to one's finger and the light that passes through the skin will appear red. Ask the patient if there is any change in intensity of the redness with each eye individually.

### **MAXILLARY:**

These fractures have a specific classification system that a prepared medical student will know. The classification system came from Dr. Le Fort who was a French surgeon. By definition, these fractures detach the maxilla from the skull base and must extend through the pterygoid plates to constitute a true Le Fort fracture.



Le Fort I (A) - fracture passes through the maxilla transversely between the tooth roots and infraorbital rim. Clinically - upper jaw is mobile

Le Fort II (B) (pyramidal fracture) - fracture passes through infraorbital rim. Clinically - upper jaw and nasal bones are mobile as unit

Le Fort III (C) - fracture extends along medial orbital wall and out lateral orbital wall

These fractures usually occur in combination and to address the maxillary fracture an upper gingivobuccal sulcus incision can be made. This incision is inside the mouth superior to the upper teeth. It gives great visualization to the maxillary and at the same time concealing a potential scar. When a Le Fort fracture is being repaired a great anatomy question can be asked.

\*What structure warrants meticulous detail when dissecting in the midface region?

-The infraorbital nerve is the largest cutaneous branch of the maxillary division of the trigeminal nerve. The nerve exits the infraorbital foramen 7-10 mm inferior to the infraorbital rim at approximately the medial aspect of the middle thirds of the orbit.

### **MANDIBLE:**

In accessing this type of fracture, a common approach is intraorally. This hides the scar and also gives an excellent visual of the mandible.

\*What structure raises caution when operating in this area?

-The mental nerve is a terminal branch of the mandibular nerve that provides sensory to the skin of the chin and mucosa of the lower lip. This nerve exits the mental foramen that is usually below (or slightly anterior) to the second premolar (bicuspid tooth).

**NASAL:**

These fractures are the most common in facial fractures. This is a great time to review the subunits that compose the nose (Fig. 3).

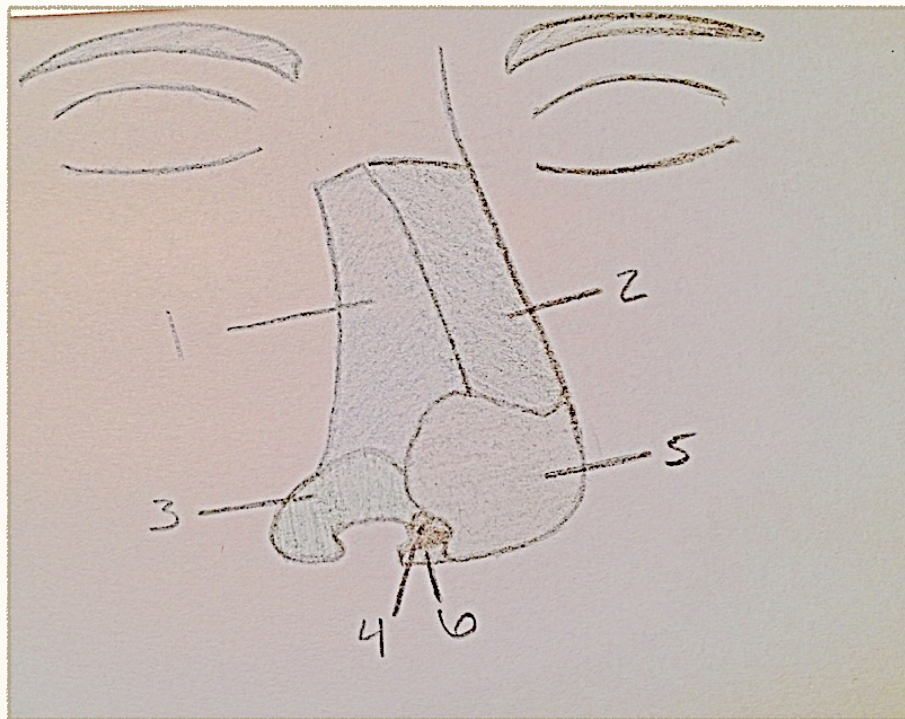


Figure 3

1	lateral sidewall	4	soft triangle
2	dorsum	5	nasal tip
3	alar lobule	6	columella

After trauma, it is important to perform a full physical exam as well as looking inside the nares for the presence of a hematoma.

\*Why is it necessary to identify a septal hematoma if present?

-An undetected hematoma can lead to resorption of the cartilaginous septum and give a saddle nose deformity.

**HAND:**

Any hand procedure can be a daunting task with the complex anatomy and vast functionality humans are capable of. The hand is extraordinarily developed in that we are capable of working on a larger scale such as moving boulders and on a microscopic scale such as the intricate field of microsurgery. It is important to know the nerve paths and routes of the arteries in the hand. Not only for operations that are performed in this region but also for times when a good anesthesia block is needed. In order to block the hand, a physician must recall the distribution of the median, ulnar and radial nerves.

Median block - located medial to the flexor carpi radialis (FCR) and deep to the palmaris longus (PL). A good block can be expected when there is anesthetic injected into the carpal tunnel and in the subcutaneous tissue between the PL and the FCR to block the palmar cutaneous branch of the median nerve.

Radial block - this nerve emerges from beneath the brachioradialis muscle and can be blocked by injecting anesthetic 3 cm



---

proximal to the radial styloid. This block requires an extensive infiltration because of the less predictable anatomic location and multiple cutaneous branches.

Ulnar block - this nerve passes between the flexor carpi ulnaris (FCU) and the ulnar artery. The FCU tendon is superficial to the nerve. It can be blocked by injecting anesthetic deep to the FCU tendon.

Digit blocks are a little more variable and are performed according to the surgeon preference. I've seen blocks on the palmar aspect on top the MCP joint. The surgeon in this instance said to inject directly in to the tendon sheath. I've seen other surgeons inject from a dorsal aspect and go on each side of the digit into the inter-digit webspace.

When injecting digits it has been of debate whether to use 1% epinephrine with lidocaine. Historically, this has been frowned upon as the epinephrine causes vasoconstriction. With the smaller and fewer vessels supplying the fingers this was thought to cause ischemia or reperfusion injury. However, currently this is being challenged with the following argument. During many hand surgeries physician use a tourniquet for up to two hours. If this is acceptable and not causing any lasting damage then the 45 minutes that epinephrine is acting should not be of any harm either.

\*When are times one should not exanguinate the hand?

- When there is an infection and by exanguinating the hand one can theoretically spread the infection. Various tumors can also raise caution on exanguination.

## **SPLINTING**

When a patient needs a splint that covers the hand and fingers there is a specific position one should set it in. This is called the “protective” or “safe” position.

\*What is this position and why is it important?

- This position requires interphalangeal joint extension, metacarpophalangeal joint flexion, and palmar abduction of thumb. This position is important because it keeps all ligaments under maximum stretch preventing any shortening and joint mobility restriction.

## **IMAGING**

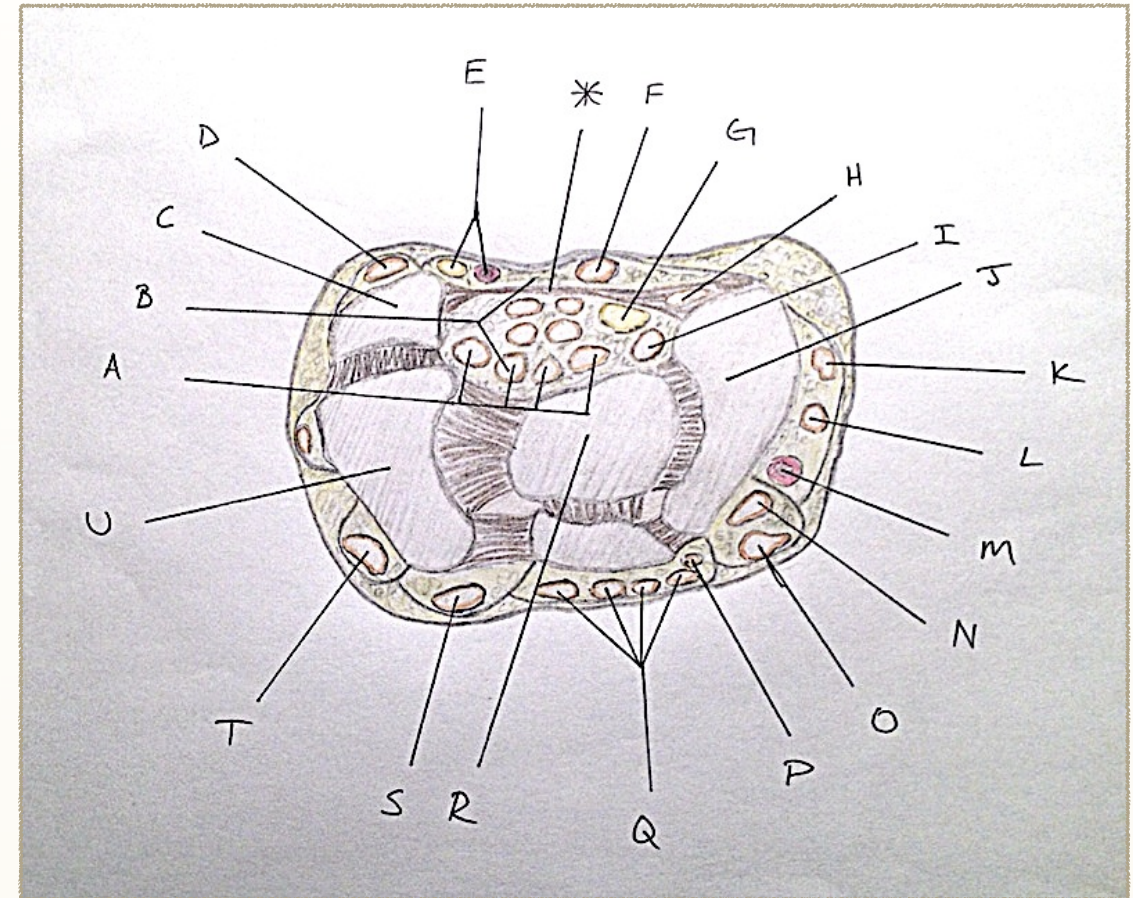
\*When imaging is needed of the hand or wrist, what views do we order?

- X-ray of the wrist include three projections: posteroanterior, lateral and oblique.

I will discuss a few common scenarios that deal with the hand.

You will commonly encounter the patient who has the typical carpal tunnel syndrome symptoms. They are numbness and tingling throughout day and especially at night. The classic sign is the patient who gets up at night and has to shake their hands to “wake” them up.

Figure 4



\*What all is located in the carpal tunnel (Fig. 4)?

- Four tendons of flexor digitorum profundus (FDP), four tendons of flexor digitorum superficialis (FDS), one flexor pollicis longus and the median nerve. (A,B,I,G)

*	Transverse carpal ligament	K	Abd. pollicis longus
A	Flexor digitorum profundus	L	Ext. pollicis brevis
B	Flexor digitorum superficialis	M	Radial artery
C	Piriform	N	Ext. carp. rad. long.
D	Flexor carpi ulnaris	O	Ext. carp. rad. brevis
E	Ulnar artery and nerve	P	Ext. indicis
F	Palmaris longus	Q	Ext. digitorum
G	Median nerve	R	Lunate
H	Flexor carpi radialis	S	Ext. digi. minimi
I	Flexor pollicis longus	T	Ext. carpi. ulnaris
J	Scaphoid	U	Triquetrum



You will see the patient who gets his finger “stuck” in the flexed position. This is called a trigger finger which is commonly associated with diabetes as well as many chronic inflammatory conditions. One professor explained the concept in this manner: picture threading string through the head of a pin. Now pull the string back and forth rather quickly and occasionally you will get a bunch up of the string on one side. This “bunch up” is similar to what is occurring most commonly on the A1 pulley. This helped me to visualize the “catching of a trigger finger”.

A review of the pulley system is appropriate here:

From the metacarpal heads to the distal phalanges, the tendons are held tightly to the bone via the pulley system. There are 5 annular and 3 thinner cruciate pulleys (the thumb has 2 annular and 1 oblique pulley).

Annular pulleys A1-A5:

The odd numbers arise over the joints: MPJ, PIPJ, DIPJ

The even numbers arise over the proximal and middle phalange

\*Which pulleys are the most important?

-The most important pulleys are A2 and A4

## **ZONES OF THE HAND**

Both the palmer and dorsal aspect of the hands are divided into zones for classifying areas of injury.

PALMER VIEW:

Zone I: Distal to FDS

Zone II: Between A1 pulley and FDS

- historically poor results when injury occurs here

Zone III: Carpal tunnel to A1

Zone IV: Carpal tunnel

Zone V: Distal forearm to carpal tunnel

## DORSAL VIEW

(Odd numbers over joints & even numbers over bones)

Zone 1: over DIP

- mallet finger (disruption of terminal tendon) = forced flexion during active extension

Zone 2: between DIP and PIP

Zone 3: over PIP

- boutonniere deformity (disruption of central slip) = flexion of PIP & hyperextension of DIP

Zone 4: between PIP and MCP

Zone 5: over MCP

- area notorious for “human bites”

Zone 6: between MCP and carpal bones

Zone 7: over carpal bones

Zone 8: distal portion of radial/ulnar

Zone 9: middle portion of radial/ulnar