

Acute Respiratory Distress Syndrome after an Exothermic Baralyme®-Sevoflurane Reaction

Randy S. Fatheree, D.O.,* Barbara L. Leighton, M.D.†

ALL modern volatile anesthetics produce carbon monoxide in strongly exothermic reactions with anhydrous carbon dioxide absorbents. Although desflurane produces the most carbon monoxide, the reaction with sevoflurane produces the most heat.¹ Using real anesthesia machines, sevoflurane, and desiccated Baralyme® (Allied Healthcare Products, Inc., St. Louis, MO), peak absorbent canister temperatures of 100–401°C have been documented.¹⁻³ In six clinical cases, sevoflurane reacted with dry soda lime to produce hot canisters and, in two of these cases, 4–9% carboxyhemoglobin.^{4,5} We report a sevoflurane reaction with Baralyme® associated with melted absorbent cartridges, thermochemically-induced acute respiratory distress syndrome, and 29% carboxyhemoglobin.

Case Report

A 40-yr-old, 109-kg man underwent thyroid lobectomy as the first case on a Monday. The patient had smoked one pack of cigarettes daily for 22 yr. He was otherwise healthy except for mild hypertension and hypercholesterolemia. Medications included metoprolol, naproxen, simvastatin, and chlorthalidone. Physical examination was normal. Preoperative hemoglobin was 16.8 g/dl; hematocrit was 49%.

The operating room was equipped with a Datex Ohmeda Modulus II anesthesia machine (Datex-Ohmeda, Inc., Andover, MA). The Baralyme® carbon dioxide absorbent cartridges had been changed the previous Thursday evening. On Friday, the machine was used for five brief, uneventful anesthetics. The anesthesia machine was turned off over the weekend and turned on Monday morning. The sevoflurane vaporizer was filled appropriately. Oxygen then flowed through the machine at 200 ml/min for 4 h.

Initial room air oxygen saturation was 97%. We administered intravenous midazolam 2 mg. Anesthesia was induced intravenously with fentanyl 100 µg, lidocaine 100 mg, and propofol 200 mg. We ventilated the patient with 100% oxygen and 8% sevoflurane. Intravenous succi-

nylcholine 100 mg facilitated tracheal intubation. We instituted controlled ventilation with a minute volume of 9 l/min (750 ml × 12 breaths/min). Anesthetic maintenance consisted of sevoflurane, nitrous oxide 50–70%, and intermittent intravenous doses of fentanyl 50–100 µg. Total fresh gas flow was 3 l/min for 30 min and 2 l/min thereafter. Nondepolarizing muscle relaxants were not used. Because the patient moved after skin incision, 10 min after anesthetic induction, we administered intravenous propofol 50 mg, intravenous fentanyl 50 µg, and briefly increased the sevoflurane vaporizer setting to 8%. The sevoflurane vaporizer setting (8%) did not match the measured inspired sevoflurane concentration (3%). We believed that this was a calibration error and arranged to have the monitor recalibrated as soon as possible. The monitored gas concentration remained lower than the sevoflurane vaporizer setting for the rest of the anesthetic. Fifty min after induction, the airway circuit inadvertently disconnected. The circuit and tube did not feel hot, the only odor was that of sevoflurane, and the gas was colorless. We reconnected the circuit and continued the anesthetic.

When the surgical drapes were removed, 110 min after anesthetic induction, we found that the carbon dioxide container was extremely hot. We immediately disconnected the circuit inspiratory limb from the carbon dioxide canister and saw billowing white gas. We smelled burning plastic. No flames were seen. The inspiratory limb of the circuit tubing contained a small amount of water. The patient was ventilated with 100% oxygen by Ambu bag. The endotracheal tube did not feel hot or look charred. Breath sounds, initially coarse, cleared with suctioning. Fiberoptic bronchoscopy revealed erythema in the trachea and both mainstem bronchi, copious mucus, and a small amount of superficial bleeding. Arterial blood gas analysis showed: pH 7.36, pCO₂ 45 mmHg, pO₂ 208 mmHg, oxyhemoglobin 69%, and carboxyhemoglobin 29%.

The patient was admitted to the intensive care unit and transferred to a tertiary hospital on postoperative day (POD) 1. Fiberoptic bronchoscopy on POD 1 revealed necrotic tracheal mucosa and severe hyperemic bronchitis bilaterally in the proximal airways. Chest radiography showed a moderately extensive left perihilar infiltrate. Hospital-acquired pulmonary infection was diagnosed on POD 4 and treated with antibiotics. The patient met blood gas criteria for acute respiratory distress syndrome (Paco₂/Fio₂ < 200 mmHg without chronic cardiac or pulmonary disease)⁶ from the day of surgery through POD 5. He was extubated on POD 6. The patient did not develop proteinuria or elevated blood creatinine or urea nitrogen levels. Urine output was normal. He did not complain of any visual problems. The patient was discharged home on POD 9. Subsequent recovery has been uneventful.

Immediately after the event, personnel from the Barnes-Jewish St. Peters Hospital biomedical department examined the carbon dioxide canister stack. The Baralyme® granules in the top half of the upper cartridge had turned purple; the rest of the granules were white. The outside plastic canister was almost too hot to touch. A large quantity of water was present in the manifold above the absorbent stack. The plastic mesh on the superior and inferior aspects of the lower Baralyme® cartridge and the inferior aspect of the upper cartridge had melted away (fig. 1). The lower Baralyme® cartridge was partially fused to the outside plastic canister (fig. 2). Personnel from ECRI (formerly the Emergency Care Research Institute, Plymouth Meeting, PA) made the following observations after examining the machine on POD 8. The rubber gasket below the lower canister was burnt over half

This article is accompanied by an Editorial View. Please see: Woehlick HJ: Sleeping with uncertainty: Anesthetics and desiccated absorbent. ANESTHESIOLOGY 2004; 101:276–8.

* Attending Anesthesiologist, Barnes-Jewish St. Peters Hospital; † Professor of Anesthesiology and Professor of Obstetrics and Gynecology, Washington University School of Medicine.

Received from the Department of Anesthesiology, Barnes-Jewish St. Peters Hospital, St. Peters, Missouri, and Washington University School of Medicine, St. Louis, Missouri. Submitted for publication November 18, 2003. Accepted for publication February 24, 2004. Support was provided solely from institutional and/or departmental sources.

Address reprint requests to Dr. Leighton: 660 S. Euclid Avenue, Campus Box 8054, St. Louis, Missouri 63110-1093. Address electronic mail to: bleigh@alumni.princeton.edu. Individual article reprints may be purchased through the Journal Web site, www.anesthesiology.org.




Fig. 1. Inferior aspects of the lower (right) and upper (left) Baralyme® cartridges. Note the extensive melting of the bottom of the upper cartridge and the top and bottom of the lower cartridge. The rubber gasket of the lower cartridge, seen on the right, melted onto the adherent Baralyme® granules.

of its inner circumference and part of its upper surface. The superior mesh of the top cartridge had no apparent heat damage but, in a central, roughly circular area 4 cm in diameter, had many fully and partly occluded openings, which appeared to be from a molding defect. On POD 8, the weight of the affected granules and plastic cartridges was 4.8% less than the weight of two unused Baralyme® cartridges from the same lot.

Discussion

This is the most severe patient lung injury and the highest carboxyhemoglobin level that has been reported after an exothermic sevoflurane-absorbent reaction. Our patient had no renal or retinal problems despite exposure to sevoflurane breakdown products. Six previous exothermic sevoflurane-soda lime cases have been reported in the German literature.^{4,5} One patient developed bronchospasm and required ventilation overnight; the other five patients were extubated immediately after surgery.^{4,5} All patients, including ours, recovered fully.

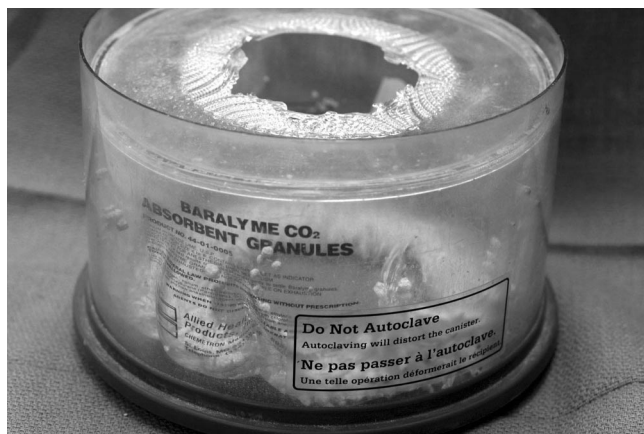

Fig. 2. Side view of the lower Baralyme® canister. The plastic of the Baralyme® cartridge melted onto and deformed the plastic of the outer canister. The top and bottom of this cartridge melted away.

Sevoflurane reacts chemically with desiccated Baralyme® or soda lime to produce carbon monoxide and flammable organic compounds, including methanol and formaldehyde.⁷ The reaction produces heat and heat increases the reaction speed, so the rate of sevoflurane breakdown can accelerate rapidly.^{7,8} Sevoflurane may be so extensively consumed that maintaining anesthesia is difficult.⁷ Compound A is produced but then, to a variable extent, degraded further.⁸ At high temperatures, the flammable metabolites can spontaneously combust.^{2,7} A peak absorbent canister temperature of 120–140°C is generally reached 10–50 min after the start of the reaction, followed by a rapid decrease in canister temperature.^{1–3} However, in four nonhuman trials with real anesthesia machines, the temperature rose rapidly to 330–401°C and parts of the absorbent canister melted.^{2,3,7} The reaction generates water, which can suddenly appear in the circuit.³ Extremely dry absorbent darkens rapidly during this reaction; however, there may be little or no color change in partially desiccated absorbent despite significant sevoflurane degradation.⁷ In our case, fumes from the melted Baralyme® cartridges may have affected the severity of the lung injury.

Under experimental conditions, rapid sevoflurane degradation requires desiccated absorbent; therefore, we assume that our Baralyme® was partially dry. We do not know how this dehydration occurred. Possibilities include initially dry Baralyme®, an undocumented period of high gas flow, regional drying resulting from gas channeling fostered by the partially perforated cartridge mesh, or unauthorized anesthesia machine use. Nitrous oxide abuse and machine sabotage have been reported as causes of unexpected absorbent exhaustion.⁹

Sevoflurane breakdown is a greater problem with Baralyme® than with soda lime. Fresh soda lime contains 14–18% water, and carbon monoxide is only produced in soda lime with <4.7% water.¹⁰ In contrast, fresh Baralyme® contains 13–19% water, and Baralyme® containing <9.7% water can produce carbon monoxide.^{7,10} Higher peak absorbent temperatures are reached with Baralyme® than soda lime when dry absorbent is exposed to sevoflurane.³ All four of the recent sevoflurane-absorbent anesthesia machine fires investigated by ECRI involve Baralyme® (personal written communication on October 30, 2003 between Barbara Leighton and Albert L. de Richemond, MS, PE, Associate Director, Accident and Forensic Investigation Group, ECRI, Plymouth Meeting, PA).

During sevoflurane degradation, carbon monoxide concentrations increase with larger minute ventilation volumes and lower fresh gas flows.⁷ Large minute volumes increase contact between sevoflurane molecules and absorbent granules. Low fresh gas flows allow recirculation of carbon monoxide. Anemia increases the percent carboxyhemoglobin for a given carbon monoxide exposure.⁷ Our patient's relative polycythemia pro-

tected him from an even higher carboxyhemoglobin concentration.

Abbott Laboratories (Abbott Park, IL), the manufacturer of sevoflurane, sent a letter 6 weeks after our case notifying anesthesia providers of revision of the package insert. The package insert now contains the following paragraph.¹¹

Replacement of Desiccated CO₂ Absorbents: When a clinician suspects that the CO₂ absorbent may be desiccated, it should be replaced before administration of sevoflurane. The exothermic reaction that occurs with sevoflurane and CO₂ absorbents is increased when the CO₂ absorbent becomes desiccated, such as after an extended period of dry gas flow through the CO₂ absorbent canisters. Extremely rare cases of spontaneous fire in the respiratory circuit of the anesthesia machine have been reported during sevoflurane use in conjunction with the use of a desiccated CO₂ absorbent. Rapid changes in the color of some CO₂ absorbents or an unusually delayed rise in the delivered (inspired) gas concentration of sevoflurane compared with the vaporizer setting may indicate excessive heating of the CO₂ absorbent canister and chemical breakdown of sevoflurane.

Clinician vigilance and a high index of suspicion will be needed to detect sevoflurane degradation in its early stages. All cases of clinically significant sevoflurane breakdown have involved large discrepancies between the dialed and the monitored agent concentration. Such discrepancies should be investigated. However, running out of agent and monitor dysfunction are more common causes of sevoflurane concentration discrepancy than agent breakdown. In our case, there was no known lengthy period of high flow of dry gas and the absorbent color changed minimally. In the future, consideration should be given to monitoring the temperature of the absorbent canister or to monitoring airway gases for carbon monoxide.

If sevoflurane degradation is suspected, fresh absorbent should be installed quickly. Switching to a different potent agent would decrease potential heat generation but would not eliminate carbon monoxide production. Carboxyhemoglobin concentrations of 8–32% were reported in 29 patients receiving enflurane or isoflurane anesthesia.¹² Fifteen minutes of desflurane anesthesia with desiccated Baralyme® produced 36% carboxyhemoglobin in one patient.¹³ The Baralyme® was then changed and the carboxyhemoglobin level decreased quickly despite continued desflurane anesthesia. Unlike our case, that patient was extubated after 140 min and discharged home 2 h later.¹³ All potent agents react with dry absorbent.¹

Ideally, an absorbent would not react with sevoflurane or would indicate when it was dry. New absorbents that

lack sodium and potassium hydroxide (e.g., Amsorb® (Armstrong Medical, Ltd., Coleraine, Northern Ireland)) react minimally with potent agents and change color when dehydrated.^{14,15} These absorbents are available in Europe but not in the United States.

In summary, we report acute respiratory distress syndrome after an exothermic sevoflurane-absorbent reaction. In response to this case, the authors' departments have switched from Baralyme® to soda lime and now routinely replace absorbent cartridges each Monday morning. Absorbents that react minimally with potent agents are available in Europe but not in the United States. Until this situation changes, clinicians must avoid dry absorbents and be prepared to recognize and respond to the early signs of this reaction.

References

1. Wissing H, Kuhn I, Warnken U, Dudziak R: Carbon monoxide production from desflurane, enflurane, halothane, isoflurane, and sevoflurane with dry soda lime. *ANESTHESIOLOGY* 2001; 95:1205–12
2. Steffey EP, Laster MJ, Ionescu P, Eger EI II, Gong D, Weiskopf RB: Dehydration of Baralyme® increases compound A resulting from sevoflurane degradation in a standard anesthetic circuit used to anesthetize swine. *Anesth Analg* 1997; 85:1382–6
3. Eger EI II, Ionescu P, Laster MJ, Weiskopf RB: Baralyme® dehydration increases and soda lime dehydration decreases the concentration of compound A resulting from sevoflurane degradation in a standard anesthetic circuit. *Anesth Analg* 1997; 85:892–8
4. Janshon GP, Dudziak R: Interactions of dry soda lime with enflurane and sevoflurane: Clinical report on two unusual anesthetics [in German]. *Anaesthesist* 1997; 46:1050–3
5. Baum J, Sitte T, Strauss JM, Forst H, Zimmermann H, Kugler B: Reaction of sevoflurane with dry absorbents: Thoughts based on recent incidents [in German]. *Anaesth Intensivmed* 1998; 39:11–6
6. Bernard GR, Artigas A, Brigham KL, Carlet J, Falke K, Hudson L, Lamy M, Legall JR, Morris A, Spragg R: The American-European Consensus Conference on ARDS. Definitions, mechanisms, relevant outcomes, and clinical trial coordination. *Am J Respir Crit Care Med* 1994; 149:818–24
7. Holak EJ, Mei DA, Dunning MB, Gundamraj R, Noseir R, Zhang L, Woehleck HJ: Carbon monoxide production from sevoflurane breakdown: Modeling of exposures under clinical conditions. *Anesth Analg* 2003; 96:757–64
8. Fang ZX, Kandel L, Laster MJ, Ionescu P, Eger EI II: Factors affecting production of compound A from the interaction of sevoflurane with Baralyme® and soda lime. *Anesth Analg* 1996; 82:775–81
9. Yudenfreund-Sujka SM: Nitrous oxide abuse presenting as premature exhaustion of Sodasorb (letter). *Anesthesiology* 1990; 73:580
10. Fang ZX, Eger EI II, Laster MJ, Chortkoff BS, Kandel L, Ionescu P: Carbon monoxide production from degradation of desflurane, enflurane, isoflurane, halothane, and sevoflurane by soda lime and Baralyme®. *Anesth Analg* 1995; 80:1187–93
11. Ultane® (sevoflurane) package insert, Abbott Laboratories, Abbott Park, IL, revised August, 2003
12. Moon RE: Cause of CO poisoning, relation to halogenated agents still not clear. *Anesthesia Patient Safety Foundation Newsletter* 1994; 9:13–24
13. Berry PD, Sessler DI, Larson MD: Severe carbon monoxide poisoning during desflurane anesthesia. *ANESTHESIOLOGY* 1999; 90:613–6
14. Murray JM, Renfrew CW, Bedi A, McCrystal CB, Jones DS, Fee JPH: Amsorb: A new carbon dioxide absorbent for use in anesthetic breathing systems. *ANESTHESIOLOGY* 1999; 91:1342–8
15. Knolle E, Linert W, Gilly H: The color change in CO₂ absorbents on drying: An *in vitro* study using moisture analysis. *Anesth Analg* 2003; 97:151–5

Spontaneous Ignition, Explosion, and Fire with Sevoflurane and Barium Hydroxide Lime

Junzheng Wu, M.D.,* Joseph P. Previte, M.D.,† Elena Adler, M.D.,‡ Troy Myers,§ John Ball, A.S.,|| Joel B. Gunter, M.D.#

ALL halogenated anesthetics are known to undergo degradation in the presence of strong alkali. Examples of the byproducts of degradation include 2-bromo-2-chloro-1,1-difluoroethene from the haloalkane halothane, carbon monoxide from the difluoromethyl ethers enflurane, isoflurane, and desflurane, and compound A from the monofluoromethyl ether sevoflurane.¹ These degradation reactions are exothermic, with those involving sevoflurane being particularly energetic.²⁻⁷ Under laboratory conditions, degradation reactions involving sevoflurane and barium hydroxide lime have reached temperatures in excess of 350–400°C and melting of plastic components, smoldering, and fire have been reported.^{2,3,5} We wish to report an explosion and fire in a carbon dioxide absorber containing barium hydroxide lime exposed to oxygen and sevoflurane.

Case Report

At the Cincinnati Children's Hospital Medical Center many operating rooms have a small (approximately 12 m²), adjacent induction room with a separate anesthesia machine; most inductions take place in the induction room in the presence of a parent. Inductions are typically performed by inhalation of sevoflurane in nitrous oxide and oxygen at a total fresh gas flow of 10–12 l/min. Once the patient has reached an appropriate level of anesthesia, the parent is escorted to the waiting room and the patient is transferred through a door into the operating room. The anesthesia circuit and bag are removed from the induction room anesthesia machine and transferred to the operating room with the patient. Patients often receive 100% oxygen before transfer, and it is not uncommon for the oxygen flowmeter to be left on between inductions. Total time in the induction room usually approximates 5 min.

During an anesthetic induction being conducted in the operating

room, a loud bang (described as sounding like a gunshot or a firecracker) was heard from the adjacent induction room. On opening the door to the induction room flames were observed within the carbon dioxide absorber canister. While the operating room staff cared for the now-anesthetized child, a nurse entered the induction room and turned off the oxygen flow (set at 1.5 l/min) and disconnected the gas supply lines from the wall source. A visitor to the facility turned off the sevoflurane (Ultane®, Abbott, North Chicago, IL) vaporizer (set at 8%) and a member of the surgical house staff attempted to put out the fire with a fire extinguisher. The still smoldering absorbent canisters were then placed under running water to completely extinguish and cool.

As soon as the brief surgical procedure was completed, the operating room was evacuated. The area was secured upon the arrival of firefighting personnel and remained unused until it had been decontaminated. The Ohmeda Excel 210 anesthesia machine and its two-canister GMS absorber assembly (Datex-Ohmeda, Madison, WI) had neither hoses nor bag attached at the time of the event. Examination of the machine revealed that the clear dome cover of the expiratory valve had fractured all around its rim and the central portion had been blown across the room (fig. 1). Significant charring and soot was noted on and within the absorber assembly. Melting and deformation of the top of the lower absorbent cartridge and the bottom of the upper absorbent cartridge had occurred, suggesting that the explosion and fire had originated in the upper part of the lower cartridge (fig. 2).

The absorber canister had contained two prefilled cartridges of Baralyme® (Allied Healthcare Products, St. Louis, MO), which had last been changed 11 days before the event. The induction room had been used four times the morning of the event; the oxygen flowmeter and sevoflurane vaporizer were known to have been turned off after the first two inductions (performed around 7:30 AM and 8:15 AM) but were certainly left on after the fourth induction (around 10:45 AM) and possibly after the third (around 10:10 AM), induction. As the fire occurred at 11:20 AM, the total time that the absorber was exposed to oxygen and sevoflurane was between 35 and 70 min.

On the basis of the suspicion that the fire was related to a reaction between sevoflurane and desiccated barium hydroxide lime, anesthesia technicians were directed to change the absorbent in all the anesthesia machines in the facility. During this exchange, a second induction room anesthesia machine was discovered with melting and deformation of plastic components in the absorber canister suggesting extreme heat (fig. 3).

This article is accompanied by an Editorial View. Please see: Woehlick HJ: Sleeping with uncertainty: Anesthetics and desiccated absorbent. ANESTHESIOLOGY 2004; 101:276–8.

* Assistant Professor, Clinical Anesthesia and Pediatrics; † Associate Professor, Clinical Anesthesia and Pediatrics; ‡ Adjunct Professor, Clinical Anesthesia and Pediatrics; § Anesthesia Workroom Supervisor, # Professor, Clinical Anesthesia and Pediatrics, Department of Anesthesiology; || Clinical Engineering Specialist, Department of Clinical Bioengineering, Cincinnati Children's Hospital Medical Center.

Received from the Department of Anesthesia, Children's Hospital Medical Center, and the Department of Anesthesiology, University of Cincinnati, Cincinnati, Ohio. Supported by the Department of Anesthesia, Children's Hospital Medical Center, and the Department of Anesthesiology, University of Cincinnati, Cincinnati, Ohio. Received for publication January 16, 2004. Accepted for publication February 11, 2004.

Address reprint requests to Dr. Wu: Department of Anesthesiology, Children's Hospital Medical Center, 3333 Burnet Avenue, Cincinnati, Ohio 45229. Address electronic mail to: junzheng.wu@cchmc.org. Individual article reprints may be purchased through the Journal Web site, www.anesthesiology.org.

Discussion

We were extremely fortunate that the anesthetic induction being conducted at the time of the event was performed in the operating room. Had the induction taken place in the induction room, the explosion and fire combined with a high flow of oxidant (oxygen and nitrous oxide) might have ignited the plastic components of the breathing circuit, resulting in significant injury to patient, parent, and staff.

Degradation reactions leading to the formation of compound A and related compounds from sevoflurane are reasonably well understood.^{1,6,8} However, a report from




Fig. 1. Expiratory valve from the absorber assembly in which the fire occurred; the dome cover was fractured around its rim and blown across the induction room. The white arrow points to the remaining rim of the dome cover. The powder deposited on the valve assembly is from the fire extinguisher.

Germany of five cases of prolonged or failed inhalation induction with sevoflurane suggested that degradation reactions involving sevoflurane might be considerably more complex than previously appreciated.⁴ Because of the architecture of the circuits used in these cases, fresh gas was first directed through the absorber canister, rather than to the patient. The observation that end-tidal sevoflurane concentrations were much less than the vaporizer settings led to the suspicion that the vaporizer had malfunctioned; however, it later became clear that essentially all of the delivered sevoflurane was being degraded by desiccated absorbent. This degradation reaction also produced heat sufficient to make the absorber canisters hot to the touch and produce pungent



Fig. 2. Base of the upper absorbent canister from the absorber assembly in which the fire occurred, showing melting and deformation of the canister seal and the carbon dioxide absorbent cartridge.




Fig. 3. Base of the upper absorbent canister from the second anesthesia machine, showing melting of the carbon dioxide absorbent cartridge.

and irritating gases causing agitation and coughing and rapid absorbent color changes, presumably from acidic by-products. Finally, two of the cases developed significant carboxyhemoglobin levels after the prolonged induction.

In the presence of strong base, sevoflurane can degrade to compound A, through elimination of hydrogen and fluoride to form a double bond, and to hexafluoroisopropanol and formaldehyde.^{1,6,8} Formaldehyde can further react in the presence of strong base to form methanol and formic acid *via* the Cannizzaro disproportionation.⁶ Methanol and formaldehyde are found among the degradation byproducts of sevoflurane.^{3,6} Significant carbon monoxide (CO) production from the degradation of sevoflurane is seen as the reaction temperature exceeds 80°C.^{3,9} It is speculated that there are at least two separate sets of degradation reactions involving sevoflurane: an initial, exothermic reaction which generates compound A, but not CO, and a second reaction which requires higher temperatures and produces CO.⁹

The degradation of sevoflurane is dependent upon the physical characteristics of the carbon dioxide absorbent to which it is exposed. Degradation increases as the water content of the CO₂ absorbent decreases, becoming maximal with complete desiccation.^{2,6,10,11} Anesthetic degradation is also dependent on the strong, monovalent alkali content of the CO₂ absorbent (KOH and NaOH).^{6,8,10,12} Complete desiccation requires several hours in a heated oven¹² or several days of exposure to a constant flow of dry gas at room temperature.^{4,5} Newer absorbents that do not contain KOH or NaOH appear to greatly diminish or eliminate the degradation of anesthetics.^{1,10,12} The absorptive capacity of absorbents without strong alkali is modestly decreased compared with that of conventional absorbents.^{10,12}

Degradation reactions involving sevoflurane are considerably more energetic than those of the other halogenated ethers. Under laboratory conditions, the reaction of sevoflurane with desiccated absorbents containing strong monovalent alkali has routinely reached temperatures well in excess of 100–120°C,^{2-5,7,9} while the reactions of enflurane, isoflurane, and desflurane have been associated with temperatures in the 50–80°C range.^{7,9} Some experiments involving prolonged exposure of sevoflurane to completely desiccated absorbent have resulted in temperatures in excess of 350–400°C associated with smoldering, melting of plastic components, and even explosion and fire.^{2,3,5}

The fire we experienced can therefore be explained by the degradation of sevoflurane in the presence of dry barium hydroxide lime, an absorbent with a high KOH content; this reaction resulted in the generation of extreme heat and volatile, flammable byproducts. Indeed, our event is eerily similar to the experiment reported by Holak *et al.*, in which a two-canister absorber filled with desiccated barium hydroxide lime exploded after 53 min of exposure to 6 l/min of oxygen and 8% sevoflurane.³ It is likely that our absorbent had become completely desiccated; it had not been changed in 11 days, had been used only briefly for induction of anesthesia using high gas flows, and had undoubtedly been exposed on multiple occasions to a continuous flow of fresh gas when operators failed to turn off the flowmeters after induction. In contrast to the case reports from Baum *et al.*,⁴ the fresh gas in our circuit was delivered downstream from the absorber canister; fresh gas could either flow out through the inspiratory valve or retrograde through the absorber canister. Examination of absorbent drying with similar circuit architecture has shown that drying, and reactivity, is greatest at the exit from the canister.⁵ Review of our institutional practice suggests several additional areas where absorbent desiccation may be a concern, including infrequently used machines in off-site locations, limited rehydration of absorbent resulting from the use of high fresh gas flows relative to body size, procedures (e.g., myringotomy and tubes) having short durations that preclude rehydration of absorbent, and the use of high-flow insufflation techniques for endoscopy.

Given these concerns, it is perhaps surprising that we have not experienced additional instances of excessive heat generation or fire. Similarly, not all experiments involving degradation of sevoflurane by completely desiccated absorbents have resulted in fire. There are undoubtedly additional factors that help determine the risk of explosion and fire related to the degradation of sevoflurane. These factors may include a greater absolute mass of absorbent (catalyst),¹¹ a gas flow rate high enough to deliver a sufficient quantity of sevoflurane, but not so high as to wash reactants out of the canister,

and preferential flow (channeling) resulting in localized desiccated absorbent and high reactant concentrations.

Our response to this event has been multifactorial. Anesthetists and technicians have been encouraged to turn off vaporizers and gas flows at the completion of each induction or anesthetic and instructed to change the absorbent if unattended gas delivery is encountered. CO₂ absorbent changes are now performed on a bi-weekly basis (more frequently in high-risk locations), rather than only as needed to avoid exhaustion of absorptive capacity. We initially substituted soda lime for barium hydroxide lime and are currently evaluating Amsorb® (Armstrong Medical, Coleraine, Northern Ireland), a CO₂ absorbent without strong alkali; if it meets our clinical requirements, Amsorb® will be introduced system-wide. Consideration was given to elimination of absorbent from the canisters in the induction rooms; although the clinical impact, given the use of high fresh gas flows and brief exposure to possible rebreathing, was deemed minimal, this intervention has been deferred for the time being.

In conclusion, we have presented an explosion and fire caused by the degradation of sevoflurane in the presence of desiccated CO₂ absorbent containing strong alkali. It is important to emphasize that the conditions that led to our event are identical to those that accentuate the generation of CO from the degradation of enflurane, isoflurane, and desflurane. Thus, even institutions that do not use sevoflurane must attend to the issues of absorbent content, desiccation, and anesthetic degradation. Efforts should be directed to avoiding desiccation of absorbents, combined with a low threshold of suspicion for changing absorbents and consideration of scheduled absorbent changes in high-risk locations. Newer absorbents free of strong, monovalent alkali greatly reduce degradation of anesthetics, and should be considered for high-risk locations or based on institutional practice. The byproducts of anesthetic degradation, whether CO, compound A, or heat and flammable volatiles, are insidious; avoidance of patient harm requires proactive elimination of factors which enhance anesthetic degradation rather than dependence on identification of degradation when it occurs.

The authors wish to thank Andreas Loeckle, M.D., Assistant Professor, Clinical Anesthesia and Pediatrics, Department of Anesthesia, Children's Hospital Medical Center, Cincinnati, Ohio, for his thoughtful translations from German to English.

References

1. Kharasch ED: Putting the brakes on anesthetic breakdown. *ANESTHESIOLOGY* 1999; 91:1192–4
2. Steffey EP, Laster MJ, Ionescu P, Eger EI, Gong D, Weiskopf RB: Dehydration of Baralyme® increases compound A resulting from sevoflurane degradation in a standard anesthetic circuit used to anesthetize swine. *Anesth Analg* 1997; 85: 1382–6
3. Holak EJ, Mei DA, Dunning MB, Gundamraj R, Noseir R, Zhang L, Woehleck HJ: Carbon monoxide production from sevoflurane breakdown: Modeling of exposures under clinical conditions. *Anesth Analg* 2003; 96:757–64

4. Baum J, Sitte T, Strauß JM, Forst H, Zimmermann H, Kugler B: Die reaktion von sevofluran mit trockenem atemkalk-überlegungen anlässlich eines aktuellen zwischenfalls. *Anaesth Intensivmed* 1998; 39:11-6
5. Eger EI II, Ionescu P, Laster MJ, Weiskopf RB: Baralyme® dehydration increases and soda lime dehydration decreases the concentration of compound A resulting from sevoflurane degradation in a standard anesthetic circuit. *Anesth Analg* 1997; 85:892-8
6. Funk W, Gruber M, Wild K, Hobbhahn J: Dry soda lime markedly degrades sevoflurane during simulated inhalation induction. *Br J Anaesth* 1999; 82:193-8
7. Wissing H, Kuhn I, Dudziak R: Zur temperaturentwicklung von inhalationsanästhetika auf trockenem atemkalk. *Anaesthesist* 1997; 46:1064-70
8. Förster H, Warnken UH, Asskali F: Unterschiedliche reaktion von sevofluran mit einzelnen komponenten von atemkalk. *Anaesthesist* 1997; 46:1071-5
9. Wissing H, Kuhn I, Warnken U, Dudziak R: Carbon monoxide production

from desflurane, enflurane, halothane, isoflurane, and sevoflurane with dry soda lime. *ANESTHESIOLOGY* 2001; 95:1205-12

10. Neumann MA, Laster MJ, Weiskopf RB, Gong DH, Dudziak R, Förster H, Eger EI II: The elimination of sodium and potassium hydroxides from desiccated soda lime diminishes degradation of desflurane to carbon monoxide and sevoflurane to compound A but does not compromise carbon dioxide absorption. *Anesth Analg* 1999; 89:768-73

11. Woehlck HJ, Dunning M, Tasleem R, Franklin R, Bolla B, Zink W: Physical factors affecting the production of carbon monoxide from anesthetic breakdown. *ANESTHESIOLOGY* 2001; 94:453-6

12. Stabernack CR, Brown R, Laster MJ, Dudziak R, Eger EI II: Absorbents differ enormously in their capacity to produce compound A and carbon monoxide. *Anesth Analg* 2000; 90:1428-351

Anesthesiology 2004; 101:537-9

© 2004 American Society of Anesthesiologists, Inc. Lippincott Williams & Wilkins, Inc.

Explosion within an Anesthesia Machine: Baralyme®, High Fresh Gas Flows and Sevoflurane Concentration

Barbara A. Castro, M.D.,* L. Allen Freedman, M.D.,† William L. Craig,‡ Carl Lynch III, M.D., Ph.D.§

RECENTLY, warnings have been published by the manufacturer of sevoflurane and in the Anesthesia Patient Safety Foundation Newsletter warning about the potential risks for fires resulting from an exothermic reaction between sevoflurane, oxygen, and a desiccated Baralyme® (Allied Healthcare Products, Inc., St. Louis, MO) carbon dioxide absorbent.¹¹ We report an incident in which the heat and the gases generated resulted in an explosion within an anesthesia machine.

Case Report

A 3-yr-old male with a history of chronic cough, dysphagia, and recurrent pneumonias was scheduled for rigid bronchoscopy, esophagoscopy, and bilateral inguinal hernia repair. A mask induction was performed with a combination of 8% sevoflurane, nitrous oxide (6 l/min), and oxygen (4 l/min). While a peripheral intravenous catheter was inserted the sevoflurane concentration was decreased to 6%, nitrous oxide was discontinued, and oxygen flow was maintained at 6 l/min. Direct laryngoscopy was performed, and the vocal cords were topicalized with 4% lidocaine. The airway was then turned over to the surgeon. The bronchoscope was introduced into the trachea and the anesthesia circuit was connected to the side port of the bronchoscope.

This article is accompanied by an Editorial View. Please see: Woehlck HJ: Sleeping with uncertainty: Anesthetics and desiccated absorbent. *ANESTHESIOLOGY* 2004; 101:276-8.

* Assistant Professor of Anesthesiology and Pediatrics; † Chief Resident in Anesthesiology; ‡ Biomedical Equipment Specialist; § Robert M. Epstein Professor and Chair.

Received from Department of Anesthesiology, University of Virginia Health System, Charlottesville, Virginia. Support was provided solely from institutional and/or departmental sources. Submitted for publication May 18, 2004. Accepted for publication May 19, 2004.

Address reprint requests to Dr. Castro: University of Virginia Health System, Department of Anesthesiology, PO Box 800710, Charlottesville, Virginia 22908-0710. Address electronic mail to: bac3c@virginia.edu. Individual article reprints may be purchased through the Journal Web site, www.anesthesiology.org.

|| Dear Health Care Professional (Letter from Abbott Laboratories, November 17, 2003). Available at: http://www.fda.gov/medwatch/SAFETY/2003/Ultane_deardoc.pdf. Accessed May 19, 2004.

Ventilation was assisted and the inspired sevoflurane concentration was maintained at 8% with an end-tidal concentration of 6-7%. Oxygen flow was maintained at 5-6 l/min.

Approximately 3 min after the introduction of the bronchoscope and 15 min after induction of anesthesia, a loud explosion was heard in the vicinity of the anesthesia machine. A quick inspection revealed that the front and side panel of the ventilator housing was blown out, the expiratory valve was destroyed, the automatic pressure limiting valve was completely dislodged from its seat, and the scavenger tubing was blown off the unit (fig. 1). In addition, the lower canister of carbon dioxide absorbent (Baralyme®) was charred, the drain plug of the canister was bright red, and multiple sparks were seen in the canister (fig. 2). The anesthesia circuit and bag were completely intact and not warm to touch.

The anesthesia circuit was immediately disconnected from the bronchoscope and the patient was ventilated with an anesthesia bag connected to a wall oxygen source. The patient remained hemodynamically stable at this point with saturations of 98-100%. Anesthesia to permit continuation of the bronchoscopy employed a propofol infusion. There was no evidence of thermal injury or barotrauma in the airway. The anesthesia machine was removed from the operating room for further inspection.

The anesthesia machine was subsequently disassembled by technicians of Datex-Ohmeda (Datex-Ohmeda, Inc., Andover, MA) with our Clinical Engineering Department to ascertain the degree and pattern of damage.

Discussion

Recent warnings from both Abbott Laboratories (Abbott Park, IL) and the Anesthesia Patient Safety Foundation have raised awareness of the potential for severe heat buildup in the anesthetic circuit, particularly in the carbon dioxide absorber canister, when sevoflurane is used in association with desiccated carbon dioxide absorbent.^{1,2}

The anesthesia machine in use was a Datex-Ohmeda Aestiva™ Model 5. The procedure was the first case of the day and a complete check of the machine was performed before inducing anesthesia. The machine apparently had not been turned off the day before, but all fresh gas flows and vaporizers were off. The carbon dioxide absorbent in use was Baralyme®. The absorbent




Fig. 1. The explosion in the Datex-Ohmeda Aestiva™ Model 5 gas circuit and ventilator unit resulted in: 1) the splitting of the top of the unit from its base; 2) the expulsion of the APL valve from the unit; 3) blow out of the front flow sensor module of the unit; 4) fracture and destruction of the plastic expiratory valve disc. In addition, the scavenger tubing was blown off the back of the unit.

was not discolored but there was no way to determine if the absorbent was desiccated. High fresh gas flows were used during induction. There was no discrepancy between the sevoflurane vaporizer setting and the inspired sevoflurane concentration, induction of anesthesia was not prolonged, and adequate anesthesia was achieved. There was no warning of the problem before the explosion. Fortunately, there was no apparent patient injury.

For the explosion to occur there must have been combustible vapor present in addition to oxygen. Although sevoflurane may be combustible in oxygen at high concentrations, it is more likely that breakdown products such as methanol and formaldehyde that have been observed under laboratory conditions were responsible.² In addition, the plastic mesh base of the lower canister was completely melted and charred. It is possible that plasticizing agents present in the materials may have been vaporized by the excessive heat and constituted a combustible material. Carbon monoxide is also a breakdown product of this reaction; however, there was nothing to suggest that it was present in this case. Judging by the location of the observed sparks, charring, and




Fig. 2. After the explosion, charred material was noted around the Baralyme® granules in the bottom half of the lower absorbent container (1). In addition, a cherry red glow was noted behind the drain plug of the canister base (2) immediately after the explosion. When dissembled, the plastic base of the lower absorbent container was completely melted and deposited on the bottom of the canister base, occluding gas outflow from the canister.

melting, the primary site of the exothermic reaction was at the base of the canister. In the Aestiva machine, the expiratory gas enters at the top of the absorbent canister. It seems likely that the expiratory carbon dioxide and moisture from the patient may have been sufficient to hydrate the Baralyme® granules in the upper layers sufficiently to prevent reaction with sevoflurane but not in the lower canister.

Perhaps most noteworthy, the melted plastic bottom of the lower plastic canister totally occluded outflow port at the bottom of the canister base. This occlusion may have protected the patient from the explosive pressure wave being propagated down the inspiratory limb of the circuit. Instead, the explosive force proceeded backwards through the canister into the breathing circuit module and the expiratory valve. This was responsible for lifting the circuit module off the base, shattering the expiratory valve disc, dislodging the gas sampling module, and blowing the automatic pressure limiting valve out of its seat. It is unclear if the occlusion of the outflow port of the carbon dioxide contributed to the explosion by restricting

the gas flow at the bottom of the canister such that there was an accumulation of combustible gases.

In retrospect, this may not have been the first incident in which an exothermic reaction was observed in our facility. Approximately 18 months before this incident, the plastic casing of the carbon dioxide absorber of a Dräger 2B anesthesia machine (Dräger Medical, Inc., Telford, PA) was discovered to be melted into a peculiar convex shape, as if the desiccant had become extremely hot and resulted in the expansion of the casing. This particular machine is located in the induction room in our magnetic resonance imaging suite and is infrequently used. In addition, episodes of measured sevoflurane concentrations far lower than set on the vaporizer combined with overheating of an absorbent canister was recently reported in another minimally used machine.

Because of this event, we have elected to change our

carbon dioxide absorbent in our main operating rooms from Baralyme® to soda lime and to use Amsorb® (Armstrong Medical Ltd., Coleraine, Northern Ireland) in our machines that are utilized only intermittently. Amsorb® is an effective carbon dioxide absorbant that remains hydrated and does not contain the strong bases necessary to produce carbon monoxide in clinically significant amounts or react exothermically with sevoflurane.³

References

1. Olympio MA, Morell RC: Canister fires become a hot safety concern. *The Anesthesia Patient Safety Foundation Newsletter* 2003-04; 18:45-64
2. Holak EJ, Mei DA, Dunning MB III, Gundamarj R, Noseir R, Zhang L, Woelck HJ: Carbon monoxide production from sevoflurane breakdown: modeling of exposures under clinical conditions. *Anesth Analg* 2003; 96:757-64
3. Murray JM, Renfrew CW, Bedi A, McCrystal CB, Jones DS, Fee JP, Amsorb A: New carbon dioxide absorbent for use in anesthetic breathing systems. *ANESTHESIOLOGY* 1999; 91:1342-8

Anesthesiology 2004; 101:539-42

© 2004 American Society of Anesthesiologists, Inc. Lippincott Williams & Wilkins, Inc.

Air Embolism during an Aircraft Flight in a Passenger with a Pulmonary Cyst: A Favorable Outcome with Hyperbaric Therapy

Mathieu Closon, M.D.,* Emmanuel Vivier, M.D.,* Charles Breynaert, M.D.,* Serge Duperret, M.D.,* Patricia Branche, M.D.,* Agnès Coulon, M.D.,† Eric De La Roche, M.D.,‡ Bertrand Delafosse, M.D., Ph.D.§

HOWEVER rare, complications likely to occur in patients with pulmonary cysts may be life threatening. Any modification of ambient pressure is likely to induce pulmonary bulla to change in size or, if not possible, to rupture or leak air. We describe a case of severe cerebral air embolism occurring during an aircraft flight in a patient with a pulmonary cyst. A successful treatment with use of hyperbaric therapy was administered at the 48th hour.

Case Report

A 43-yr-old man who smoked and had asthma experienced a sudden loss of consciousness followed by dyspnea and agitation 20 min after take-off of a commercial flight in a Boeing 737. On examination by a medical doctor on the plane, the man was pale and sweating, his blood pressure was 120/80 mmHg, and his heart rate was regular at 80 beats/min. A short-term episode of asthma was first considered, but physical examination did not reveal any wheezing, and the neurologic symptoms could not be explained by an exacerbation of asthma. Therefore,

the flight was diverted toward an airport for emergency care of the patient.

On admission to the intensive care unit, the patient had a Glasgow Coma Score of 7, and was intubated and mechanically ventilated. Further neurologic examination revealed symmetric pupils that were reactive to light; left hemiparesis; and upper motor neuron dysfunction with increased muscle tone, brisk deep tendon reflexes, and Babinski sign. Tendon reflexes were symmetric at the lower limbs. Painful stimuli produced right decorticate posturing. No seizure activity was observed at any time, and the physical examination results were otherwise normal except for a core temperature of 38.5°C. No physician could recollect the presence of signs of air embolism in the skin, such as livedo reticularis, at that time.

A radiograph of the chest and a computed tomography (CT) scan showed a 12 × 8 × 10-cm right lower lobe bulla, with a thin hyperdense wall but no parenchymal infiltration (fig. 1). A cerebral CT image and an electrocardiogram were normal. Electroencephalography showed no focal signs.

Initial (*i.e.*, 8 h after the event) laboratory data showed signs of myocardial injury: The troponin Ic concentration was 9.3 μg/l (normal < 0.4 μg/l). Other laboratory data were within normal ranges.

The patient's fever, neurologic status, and myocardial injury raised several diagnostic hypotheses: herpes meningoencephalitis, venous thrombosis of the cerebral sinus, or coma after heart attack. The results of all of the examinations performed to confirm these diagnoses, including lumbar puncture, herpes polymerase chain reaction, and a new cerebral CT scan with contrast injection, were negative.

Finally, because of the presence of the lower pulmonary lobe bulla, a diagnosis of air embolism involving the brain and the heart was made. The most important criterion to settle the diagnosis of arterial gas embolism was the patient's medical history.¹ The temporal relation between the neurologic symptoms and the pressure variation seemed compatible with a sudden entry of air into the pulmonary vessels. A normal CT scan did not rule out the occurrence of arterial gas embolism. Therefore, a recompression treatment started 48 h after the initial

* Clinical Assistant, † Staff Intensivist, Department of Anesthesia and Intensive Care, ‡ Staff Radiologists, Department of Radiology, Hôpital de la Croix-Rousse, Lyon, France. § Staff Surgeon, Department of Surgery, Hôpital de la Croix-Rousse, Lyon, France. Head of Hyperbaric Center, Hôpital E Herriot, Lyon, France.

Received from Department of Anesthesia and Intensive Care, Hôpital de la Croix Rousse, Lyon, France. Submitted for publication November 3, 2003. Accepted for publication February 19, 2004. Support was provided solely from institutional and/or departmental sources.

Address reprint requests to Dr. Duperret: Department of Anesthesia and Intensive Care, Hôpital de la Croix-Rousse, 69317, Lyon, France. Address electronic mail to: serge.duperret@chu-lyon.fr. Individual article reprints may be purchased through the Journal Web site, www.anesthesiology.org.

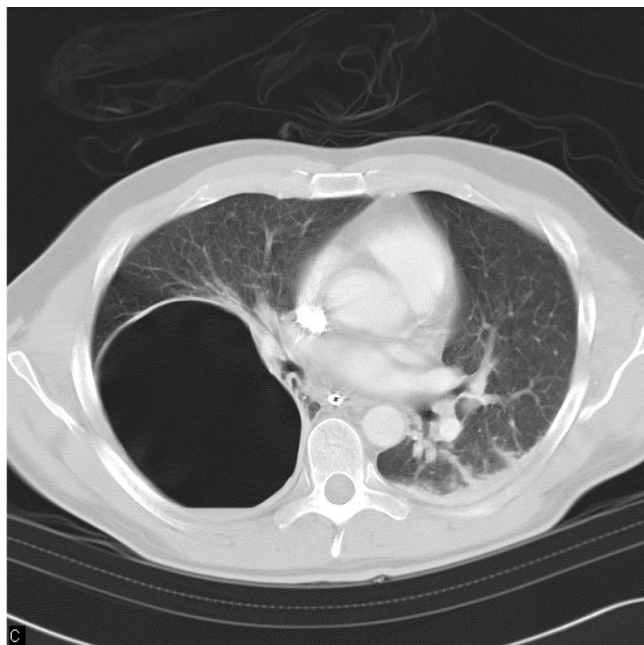

Fig. 1. Computed tomography scan of the chest with a cystic intrapulmonary bulla of the lower inferior right lobe.

accident in a hyperbaric chamber according to a D50 HeO₂ table. This involved immediate compression to 50 m seawater or 6 ATA and lasted 8 h while the patient was ventilated with pure oxygen or a mix of oxygen and helium adjusted to keep the partial pressure of oxygen less than the toxic level of 3.0 ATA (table 1). Before the first dive, a catheter was inserted into the bulla under radiographic guidance to avoid the risk of rupture during decompression. At the end of this first compression, the patient was awakening but still showing clouding of consciousness. However, the motor response elicited by pain was now purposeful. The left hemiparesis had improved, and the muscle tone

Table 1. Dive Profile of the D50 HeO₂-Heliox Table

Pressure, ATA	Time, min	Breathing Media, % Oxygen-Helium	Total Elapsed Time, min
1 to 2.8	4	Oxygen	4
2.8 to 4	2	Heliox 60-40	6
4 to 6	4	Heliox 40-60	10
6	15	Heliox 40-60	25
6 to 4	5	Heliox 40-60	30
4	25	Heliox 60-40	55
4 to 3.4	30	Heliox 60-40	85
3.4	30	Heliox 60-40	115
3.4 to 2.8	30	Heliox 60-40	145
2.8	25	Oxygen	170
2.8	5	Heliox 22-78	175
2.8	25	Oxygen	200
2.8	5	Heliox 22-78	205
2.8	30	Oxygen	235
2.8 to 1.9	30	Oxygen	265
1.9	30	Oxygen	295
1.9	5	Heliox 22-78	300
1.9	55	Oxygen	355
1.9	5	Heliox 22-78	360
1.9	55	Oxygen	415
1.9	5	Heliox 22-78	420
1.9	25	Oxygen	445
1.9 to 1	30	Oxygen	475

ATA = atmospheres absolute.

was normal. One more D50 HeO₂ compression was performed 12 h after the first one, and the patient fully recovered from his neurologic symptoms. Afterward, a thoracotomy with resection of the right lower lobe was performed before a final recompression to 15 m seawater (2.5 ATA) during 2 h with pure oxygen. There were no postoperative complications, and the patient was discharged 10 days later. A month later, magnetic resonance imaging (MRI) was performed, and no abnormalities were found.

Discussion

Although pneumothorax is one of the possible complications in patients with giant intrathoracic bulla,² air embolism is rare.³ However, the mechanisms are similar. Decreasing the ambient pressure leads to an increase in the volume of the bulla or, if not possible, to an increased pressure gradient between the bulla and the pleural space or the surrounding vessels. Such a variation can be observed during an aircraft flight when ambient pressure varies from sea level to an altitude of 2438 m corresponding to the usual cabin altitude pressure of a B737.⁴ This pressure is equal to approximately 0.75 atm. It is reached within 20 min and may be modified during the flight because of traffic or weather.⁵ Whatever the amplitude of variation of pressure, this induces an increase in volume of gas in a noncommunicating space. Therefore, any parenchymal bulla is a classic contraindication of activities leading to sudden variations of ambient pressure⁶ and is a compelling reason to administer surgical treatment. The current patient was aware of the presence of a parenchymal bulla, but no special recommendations regarding air flight had been made.

Pulmonary cysts produce conditions that tend to cause arterial gas embolism in case of pressure variation inside the cyst. Air from the bulla may enter the pulmonary veins, and then bubbles of gas are directly distributed into all organs. Small emboli in muscles or viscera are clinically unnoticed, whereas cerebral or coronary localizations may bring about severe clinical manifestations. This arterial gas embolism is different from the venous gas embolism that may occur during some surgical procedures in which gas enters the systemic venous system. In venous gas embolism, the main clinical manifestations are due to the migration of bubbles to the pulmonary circulation and the subsequent increase of right ventricle afterload. However, even in venous embolism, bubbles may be encountered on the arterial side as a result of a patent foramen ovale or by moving across the pulmonary vascular bed.¹ The consequences are twofold: First, local ischemia and edema due to the absence of blood supply may occur. Second, the interface between the gas bubbles and the endothelium engenders a local inflammatory response, possibly disrupting the blood-brain barrier, worsening edema and further impairing cerebral perfusion.⁷ This physiopathology explains why the main initial clinical manifestations are the neurologic symptoms, whether associated with circulatory disorders or not.

There is no definite nonclinical criterion for air embolism. A CT scan may reveal small air bubbles, but because of the minute size of the bubbles, they may not be well visualized.⁸ Theoretically, only a bubble with a radius exceeding 1 or 2 mm could be detected, provided that the bubble is situated on the tomographic cut.⁹ Previous publications reporting the visualization of cerebral gas on CT scans describe massive arterial embolism occurring during the course of angiography^{8,10} or pulmonary contusion¹¹ or venous gas embolism.¹² However, an initial cerebral CT scan can rule out a cerebral infarct or an intracerebral hemorrhage. Late CT scan changes are nonspecific and could be interpreted as ischemic infarction in case of massive gas embolism.¹³ Other diagnostic methods, such as MRI and single-photon emission CT scanning, are markers of abnormal regional flow. However specific, the finding of gas in the cerebral circulation is uncommon.¹⁴ MRI of the cerebrum has been described in decompression sickness as multiple punctate nonenhancing foci of prolonged relaxation times in subcortical white matter.¹⁵ However, it was unclear whether these MRI findings reflected the acute decompression sickness injuries or the effects of cumulative diving episodes. One study reported a normal MRI scan obtained immediately after the onset of symptoms after gas embolism, and these findings were ascribed to the small dimensions of the injured areas.¹⁶ In the same study, early single-photon emission tomography confirmed the diagnosis. A delayed MRI including diffusion-weighted imaging demonstrated abnormalities consistent with ischemic brain damage.

The primary point of interest in this case is the definitive role of recompression therapy. The mechanism of the beneficial effect of recompression therapy is three-fold. First is the reduction of bubble volume according to the law of Boyle. Second is the increase of the surface of the bubble with respect to its volume and therefore an increase in the exchange gas surface. Finally, when pure oxygen or heliox is breathed, blood nitrogen gas tension is reduced to zero, creating a high gradient for the elimination of nitrogen from the bubble and thus the resolution of the bubble. This last mechanism requires that nitrogen be eliminated from the inspired gas mixture during recompression. This can be achieved with the D50 HeO₂ table or the modified (heliox) Comex 30 table (Comex Inc., Marseille, France). However, this mechanism requires the presence of some blood flow around the bubble. In case of arterial gas embolism, the bubbles fragment and stack longitudinally in small arteries. There is no perfusion around distal bubbles, explaining why they may persist in the cerebral circulation for a long time, 40 h or even longer.¹⁷ This long duration may be enhanced by the platelet aggregation occurring at the gas-blood interface.¹⁸ These changes likely explain why even late recompression therapy can be beneficial. This is also the reason why we used a long and deep table without nitrogen to increase the

nitrogen gradient between bubbles and blood. This nitrogen gradient is 4.70 ATA with the recompression table we used, whereas it is 2.18 ATA with the United States Navy 6 and 3.12 ATA with the modified (heliox) Comex 30. Incidentally, the initial compression using the United States Navy 6A table is performed while the patient breathes air; therefore, the nitrogen gas concentration in the tissues at the end of recompression exceeds that observed at the beginning of hyperbaric therapy. These long and repeated treatment courses are likely to recruit a distal flow by progressively eliminating the stacked bubbles. In addition, a high dissolved oxygen content could increase oxygen delivery to the cerebral zones compromised by a marginal oxygen supply. Our observation proved that this therapy was of value even when performed with a delay beyond the initial embolism accident. Such beneficial effect of delayed treatment has been already reported in venous and arterial gas embolism.¹⁹⁻²¹ In fact, we were unable to find any delay beyond which hyperbaric treatment provided no benefit. Some previous articles reported successful treatment of gas embolism symptoms with hyperbaric oxygen applied 13 days²² and 24 days²³ after the initial injury. Even for patients in extremely poor conditions with coma, hyperbaric therapy in a chamber devoted to the treatment of critically ill patients should be considered.

The authors thank the nursing staff of the Hyperbaric Center of Hôpital E Herriot, Lyon, France, for incomparable expertise and support.

References

- Muth CM, Shank ES: Gas embolism. *N Engl J Med* 2000; 342:476-82
- Ribet ME, Copin MC, Gosselin BH: Bronchogenic cysts of the lung. *Ann Thorac Surg* 1996; 61:1636-40
- Zaugg M, Kaplan V, Widmer U, Baumann PC, Russi EW: Fatal air embolism in an airplane passenger with a giant intrapulmonary bronchogenic cyst. *Am J Respir Crit Care Med* 1998; 157:1686-9
- Blumen IJ, Abernethy MK, Dunne MJ: Flight physiology: Clinical considerations. *Crit Care Clin* 1992; 8:597-618
- Cottrell JJ: Altitude exposures during aircraft flight: Flying higher. *Chest* 1988; 93:81-4
- Medical aspects of transportation aboard commercial aircraft. AMA Commission on Emergency Medical Services. *JAMA* 1982; 247:1007-11
- van Hulst RA, Lameris TW, Hasan D, Klein J, Lachmann B: Effects of cerebral air embolism on brain metabolism in pigs. *Acta Neurol Scand* 2003; 108:118-24
- Soderman M, Bystam J: Cerebral air emboli from angiography in a patient with stroke: A case report. *Acta Radiol* 2001; 42:140-3
- Dexter F, Hindman BJ: Recommendations for hyperbaric oxygen therapy of cerebral air embolism based on a mathematical model of bubble absorption. *Anesth Analg* 1997; 84:1203-7
- Voorhies RM, Fraser RA: Cerebral air embolism occurring at angiography and diagnosed by computerized tomography: Case report. *J Neurosurg* 1984; 60:177-8
- Sakai I, Nishizawa S: Cerebral air embolism after lung contusion: Case illustration. *J Neurosurg* 2001; 95:909
- Valentino R, Hilbert G, Vargas F, Gruson D: Computed tomographic scan of massive cerebral air embolism. *Lancet* 2003; 361:1848
- Heckmann JG, Lang CJ, Kindler K, Huk W, Erbguth FJ, Neundorfer B: Neurologic manifestations of cerebral air embolism as a complication of central venous catheterization. *Crit Care Med* 2000; 28:1621-5
- Moon R: Gas embolism, *Handbook on Hyperbaric Medicine*. Edited by Oriani G, Marroni A, Wattel E. Milan, Italy, Springer, 1996, pp 229-48
- Aksoy FG: MR imaging of subclinical cerebral decompression sickness: A case report. *Acta Radiol* 2003; 44:108-10
- Droghetti L, Giganti M, Memmo A, Zatelli R: Air embolism: Diagnosis with single-photon emission tomography and successful hyperbaric oxygen therapy. *Br J Anaesth* 2002; 89:775-8

17. Layon AJ: Hyperbaric oxygen treatment for cerebral air embolism: Where are the data? *Mayo Clin Proc* 1991; 66:641-6

18. Philp RB, Inwood MJ, Warren BA: Interactions between gas bubbles and components of the blood: Implications in decompression sickness. *Aerosp Med* 1972; 43:946-53

19. Wherrett CG, Mehran RJ, Beaulieu MA: Cerebral arterial gas embolism following diagnostic bronchoscopy: Delayed treatment with hyperbaric oxygen. *Can J Anaesth* 2002; 49:96-9

20. Mader JT, Hulet WH: Delayed hyperbaric treatment of cerebral air embolism: Report of a case. *Arch Neurol* 1979; 36:504-5

21. Bitterman H, Melamed Y: Delayed hyperbaric treatment of cerebral air embolism. *Isr J Med Sci* 1993; 29:22-6

22. Hickey MJ, Zanetti CL: Delayed-onset cerebral arterial gas embolism in a commercial airline mechanic. *Aviat Space Environ Med* 2003; 74:977-80

23. Tirpitz D, Schipke JD: Delayed recompression after SCUBA diving-induced barotrauma: A case report. *Aviat Space Environ Med* 1996; 67:266-7

Anesthesiology 2004; 101:542-3

© 2004 American Society of Anesthesiologists, Inc. Lippincott Williams & Wilkins, Inc.

Presentation and Treatment of Complex Regional Pain Syndrome Type 1 in a 3 Year Old

Yuriy Bukhalo, M.D.,* and Vildan Mullin, M.D.†

COMPLEX Regional Pain Syndrome type 1 (CRPS I), previously known as Reflex Sympathetic Dystrophy, is a heightened response of the sympathetic nervous system to a relatively minor injury. The hallmark of the disease is pain that is out of proportion to the degree of injury. The exact etiology of this disease remains unknown. Typical complaints of a CRPS patient include pain beyond the site of initial injury, allodynia, regional temperature disturbance, edema, sudomotor changes, and inability to use the affected extremity.^{1,2} Unilateral skin color changes, hair and nail growth changes, and changes of skin texture of the affected extremity may be present.^{1,2}

Early diagnosis and treatment may lead to full recovery, whereas a significant delay may result in a prolonged and even lifelong disability. For those unfamiliar with the characteristics of CRPS, diagnosis may be difficult. Because of the infrequency of presentation in a pediatric age group and also the limited communication abilities of children, diagnosis is often delayed.

Although a great deal of literature on CRPS has been published, most of it is geared to the diagnosis and treatment of adolescents and adults. Most published papers are case series of children older than 6 yr.³⁻¹¹ There is one case report of a 3-yr-old child who developed symptoms of CRPS type 2 (causalgia) after a sciatic nerve injury.¹² However, we could not locate any reports on CRPS type 1 diagnosis and treatment of very young children under the age of 5 yr.

We hope to promote awareness of this syndrome in very young children by discussing the presentation and

successful management of a 3-yr-old child with CRPS type 1 who was evaluated and treated in our clinic.

Case Report

A previously healthy 3-yr-old boy was referred to the University of Michigan Health System Multidisciplinary Pain Center for evaluation and treatment of persistent right foot pain presumed by his pediatrician to be secondary to CRPS I. His pain began 3 months earlier after a twist and fall injury to his right ankle. This resulted in mild ankle swelling, and the child complained of pain and difficulty with weight bearing. No fractures were found on radiography. After 3-4 weeks of ineffective conservative treatment consisting of rest, elevation, ice, and ibuprofen elixir, the patient was referred to orthopedic surgery for evaluation. His ankle and foot were placed in a cast for immobilization of the joint for 3 weeks. As a result, his weight bearing improved during this time. After the cast was removed, his ankle was splinted, and the boy reported more pain with weight bearing. On removal of the splint 2 weeks later, it was noted that edema had progressed to involve his ankle, foot, and distal leg. The affected area was extremely tender to touch and with movement. The patient's mother also noted her son's desire to keep the leg uncovered at night. The plain radiographs of the foot showed focal osteopenia, and magnetic resonance imaging revealed an effusion in the tibiotalar joint. In addition, the bone scan revealed soft tissue edema and was reported as "negative for CRPS." Over the next few weeks before being seen in our clinic, the pain, swelling, and unwillingness to bear weight on the extremity persisted. The patient was evaluated by an infectious disease specialist who concluded that there was no evidence of generalized or local infection.

On presentation to our clinic, the patient appeared older than his stated age in size and maturity level. He was extremely anxious to undergo another evaluation. He was unable to describe his pain; however, he began to cry and guard his right leg when approached. He did not let his mother put a sock or shoe on his affected extremity. His right ankle, foot, and distal leg were edematous, warm, and extremely tender to touch. Light touch caused him to cry and pull away. Hair growth, skin color, and skin texture appeared normal. He did have full range of motion at the ankle, but he resisted weight bearing because of pain. His right foot was found to be 8°F warmer than his left. Based on his history and physical examination, the diagnosis of CRPS type 1 was established.

The child was started on naproxen elixir 125 mg orally twice a day. A transcutaneous electrical nerve stimulator unit was prescribed. The child was weary of the apparatus and electrodes at first. The mother had to play a crucial role in the initiation and maintenance of the transcutaneous electrical nerve stimulator treatment. After discussing the treatment plan, preparations were made for a spectacle with the mother playing the role of the patient. The electrodes were placed on

* Pain Medicine Fellow, Department of Anesthesiology, University of Michigan, † Associate Professor, Department of Anesthesiology, Director, Multidisciplinary Pain Center, University of Michigan.

Received from the Department of Anesthesiology, University of Michigan, Ann Arbor, Michigan. Support was provided solely from institutional and/or departmental sources. Submitted for publication February 14, 2003. Accepted for publication June 27, 2003.

Address reprint requests to Dr. Bukhalo: Department of Anesthesiology, Multidisciplinary Pain Center, 1500 East Medical Center Drive, Ann Arbor, Michigan 48109. Address electronic mail to: ybukhalo@yahoo.com. Individual article reprints may be purchased through the Journal Web site, www.anesthesiology.org.

her first, and she expressed extreme satisfaction during the stimulation. After seeing her, the son started asking for electrodes to be placed on him. The patient's mother was instructed on proper electrode placement. She was also instructed on setting the proper stimulation intensity by placing two of the four electrodes on herself simultaneously with her son, and she therefore served as a gauge of stimulation during therapeutic sessions.

The patient also underwent physical therapy three times a week with a therapist interested in pediatric population. The emphasis was on desensitization with varying textures and increased weight-bearing activity. Physical therapy also included massage using lymphedema techniques of skin stretching, along with active and passive range of motion exercises. Two weeks later, his mother reported significant improvement. At 1-month reevaluation, his symptoms had completely resolved.

Discussion

CRPS is a debilitating pain syndrome that appears to have no age boundaries. The theories of pathophysiology of this disease are abounding; nevertheless none can account for the full range of presentations. Most of the literature describing the diagnostic features and treatment is based on case reports on adult and adolescent patients. The diagnosis is uncommon in children, with most literature reporting patients primarily older than 6 yr.³⁻¹¹ We were not able to identify any reports of children younger than 5 yr presenting with CRPS type 1. Many clinicians have never encountered this disease, and when patients (especially children) present with this syndrome, other diagnoses are given and the appropriate treatment is delayed.^{3,5} Early therapeutic intervention may result in complete recovery, whereas immobilization, often offered as an initial treatment, may promote the development of CRPS. Occasionally there is spontaneous resolution of the symptoms without formal treatment. However, for those cases that are progressive, delay in the initiation of treatment equals the worst prognosis.

The physical signs of CRPS in children are similar to those seen in adults. However, there are differences. Children appear to have a much higher incidence of lower extremity involvement as compared with adults.^{3,4} Girls are more frequently affected than boys.^{3,5} Diagnosis in very young children may be difficult because of their limited ability to describe their symptoms. A significant number of children do not report a history of trauma.^{3,6,8} Caregivers should be questioned regarding behaviors such as limited use of the limb, sensitivity to light touch, or guarding of the extremity. Physical characteristics of the extremity since the onset of pain, such as changes of color, sweating, hair and nail growth, should be noted. Radiographic studies are often noncontributory as well. It is important to perform the evaluation of the extremity in a minimally threatening manner in hopes of limiting future anxiety and resistance to

treatment. The examination should be performed with the caregiver present in the room.

Once the diagnosis of CRPS is made an age-appropriate treatment plan that provides adequate pain control along with encouragement of weight-bearing activity is essential. Consideration must be given to the fact that a very young child might not be receptive to traditional modalities of treatment. The approach might require modification according to the child's level of understanding. Transcutaneous electrical nerve stimulator units have been shown to be beneficial in the management of CRPS with very young children.^{4,10,11} In this case, the patient's mother was used to introduce the unit to the child. Management should involve physical therapy, ideally with a pediatric physical therapist trained to treat CRPS. Desensitization, improvement of range of motion, and gradual introduction of age-appropriate weight-bearing activities are essential components for a successful treatment. Unless contraindicated, nonsteroidal antiinflammatory agents should be administered for the treatment of inflammation and pain. Additional medications, such as tricyclic antidepressants or gabapentin, may be added if the nonsteroidal antiinflammatory agents alone are not effective. More invasive procedures, such as sympathetic blockade, should be reserved for those patients who fail conservative management. In conclusion, primary care providers and specialists who treat young children should include CRPS in the differential diagnosis for persistent extremity pain. Early treatment gives children with CRPS the best chance of recovery.

References

1. Merskey H, Bogduk N, eds. *Classification of Chronic Pain: Description of Chronic Pain Syndromes and Definition of Pain Terms*, 2nd ed. Seattle: International Association for the Study of Pain Press, 1994, pp 40-43
2. Harden N, Bruehl S, Galer BS, Saltz A, Bertram M, Backonja M, Gayles R, Rudin N, Bhugra MK, Stanton-Hicks M: Complex regional pain syndrome: Are the International Association for the Study of Pain diagnostic criteria valid and sufficiently comprehensive? *Pain* 1999; 83:211-9
3. Murray CS, Cohen A, Perkins T, Davidson JE, Sills JA: Morbidity in reflex sympathetic dystrophy. *Arch Dis Child* 2000; 82:231-3.
4. Wilder RT, Berde CB, Wolohan M, Vieyra MA, Masek BJ, Micheli LJ: Reflex sympathetic dystrophy in children: Clinical characteristics and follow-up of seventy patients. *J Bone Joint Surg Am* 1992; 74:910-9.
5. Cimaz R, Matucci-Cerinic M, Zulian F, Falcini F: Reflex sympathetic dystrophy in children. *J Child Neurol* 1999; 14:363-7
6. Paice E: Reflex sympathetic dystrophy. *BMJ* 1995; 310:1645-8.
7. Lloyd-Thomas AR, Lauder G: Reflex sympathetic dystrophy in children. *BMJ* 1995; 310:1648-9.
8. Papadopoulos GS, Xenakis TA, Arnaoutoglou E, Tefa L, Kitsoulis PB: The treatment of reflex sympathetic dystrophy in a 9-year-old boy with long standing symptoms. *Minerva Anestesiologica* 2001; 67:659-63.
9. Tong HC, Nelson VS: Recurrent and migratory reflex sympathetic dystrophy in children. *Pediatr Rehabil* 2000; 4:87-9
10. Kesler RW, Saulsbury FT, Miller LT, Rowlingson JC: Reflex sympathetic dystrophy in children: Treatment with transcutaneous electric nerve stimulation. *Pediatrics* 1988; 82:728-32.
11. Richlin DM, Carron H, Rowlingson JC, Sussman MD, Baugher WH, Goldner RD: Reflex sympathetic dystrophy: Successful treatment by transcutaneous nerve stimulation. *J Pediatr* 1978; 93:84-6.
12. Kozin F, Haughton V, Ryan L: The reflex sympathetic dystrophy syndrome in a child. *J Pediatr* 1977; 90:417-9