

# Pituitary Gland in Central Diabetes Insipidus: A Case Report

## INTRODUCTION:

The normal pituitary gland's anterior and posterior parts are distinct on MRI. The anterior part is isointense on both T1 and T2 weighted images. The posterior pituitary has intrinsic high T1 signal, and is of hypointense signal on T2 weighted images. Pituitary stalk shows normal top-to-bottom tapering on sagittal and coronal images.

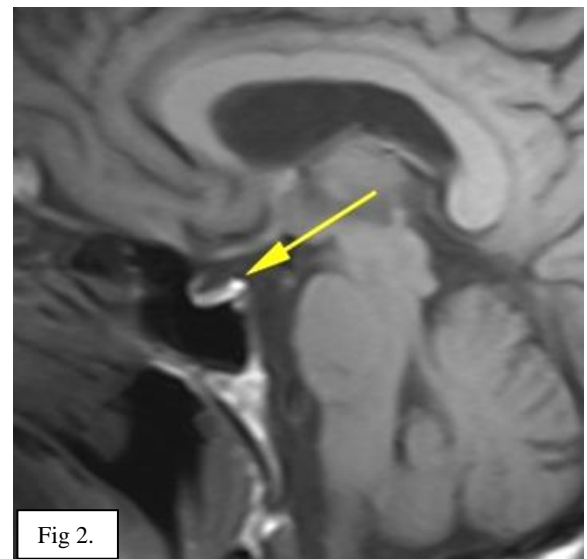
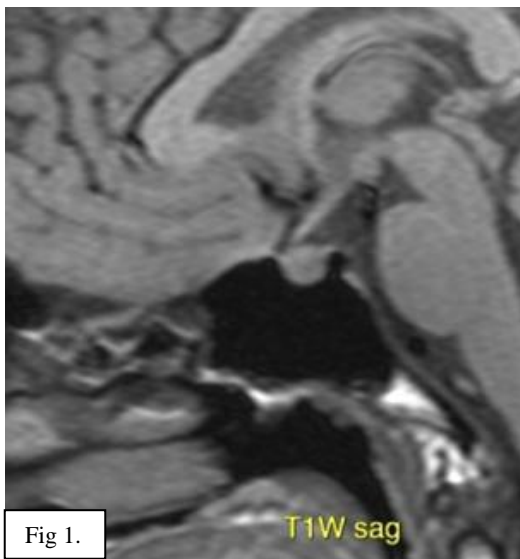We present a case wherein the absence of normal signal of posterior pituitary gland helped us to attain the diagnosis of central diabetes insipidus.

Roughly half the cases of central DI are caused by trauma (surgery or head trauma), tumors (lung cancer, leukemia or lymphoma) or infiltrative diseases (Langerhans cell histiocytosis, sarcoidosis, Wegener's granulomatosis). The other half are due to idiopathic DI, where an autoimmune process is the most common culprit, especially in young adults. Among patients with idiopathic central DI, the most common finding on brain imaging is loss of the posterior pituitary hyperintense signal and pituitary stalk thickening.

## CASE PRESENTATION:

Patient is a 21 year old girl who presented history of polydipsia. There was history of trauma few months back. Patient referred for MRI brain.

## FINDINGS:



- The bright spot of posterior pituitary gland is not well visualised on T1W sagittal images (Fig 1). Note the normal bright posterior pituitary in another patient (Fig 2).

- The infundibular stalk appears thickened and measures 0.6 cm in AP and 0.5 cm in transverse dimension. Enhancement in the stalk is homogeneous. There is loss of normal top to bottom tapering of the stalk (Fig 3).
- Anterior pituitary gland appears mildly bulky and shows superior convexity of its surface (Fig 4). Homogeneous enhancement is seen in the gland with no evidence of focal lesions on dynamic images.

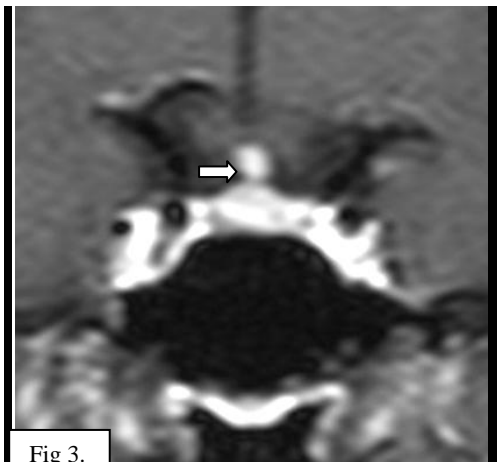


Fig 3.

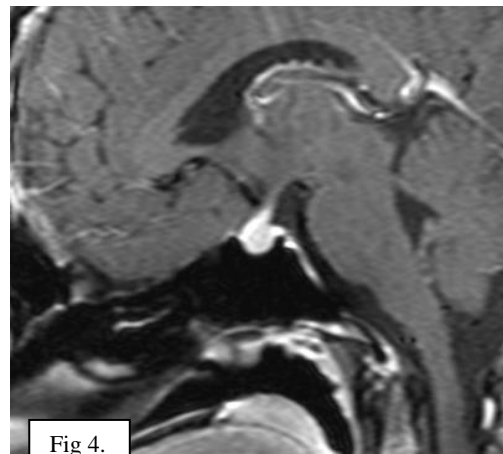


Fig 4.

#### DISCUSSION:

The preferred imaging test in the work-up of patient with symptoms of polydipsia is MRI of the hypothalamus-pituitary. Besides diagnosing central diabetes insipidus, MRI may also help in detecting etio-pathogenesis of central diabetes insipidus. MRI also helps in excluding psychogenic polydipsia because underlying psychiatric problems seen in these patients can be very subtle.

On T1 images absence of bright spot in the posterior pituitary is useful for diagnosis of central DI in majority of the cases. The bright spot is an area of hyperintense signal on T1 images, which corresponds to the portion of the posterior pituitary where neurosecretory granules containing vasopressin are stored. Therefore the intensity varies with the amount of stored vasopressin and will be low in severely dehydrated patients (due to uncontrolled diabetes mellitus or nephrogenic DI) or can be completely absent in patients with central DI as seen in our case. Thickening of pituitary stalk on MRI may result due to various infiltrative diseases, although 50% of cases are idiopathic. AP and transverse diameters of the normal pituitary stalk are  $2.32 \pm 0.39$  mm and  $2.16 \pm 0.37$  mm at the pituitary insertion, respectively, and  $3.25 \pm 0.43$  mm and  $3.35 \pm 0.44$  mm at the level of the optic chiasm. DI may occur before, simultaneously and after the other multisystem manifestations making the diagnosis difficult in initial stages.

**CONCLUSION: Although MR may or may not explain the specific etio-pathogenesis of changes in the pituitary gland, it serves to demonstrate prudent approach to a patient presenting with symptoms of polydipsia or diabetes insipidus.**

Regards,

**Dr. Deepa S. Nadkarni / Dr. Shaikh M. Mazhar**

N.B: This case is authentic and from the archives of Radiance Diagnostics. For any queries/suggestions / feedback write to us at [radiance@radiancediagnostics.in](mailto:radiance@radiancediagnostics.in).

Case of the month can also be accessed anytime online at **VIEW BOX** at [www.radiancediagnostics.in](http://www.radiancediagnostics.in)