



## Scientific Review

# A Review of Breast Pain: Causes, Imaging Recommendations, and Treatment

Rebecca Sivarajah, MD, Janelle Welkie, Julie Mack, MD,  
Rachel S. Casas, MD, EdM, Melody Paulishak, MD,  
Alison L. Chetlen, DO, FSBI\*<sup>Ⓞ</sup>

Penn State Health-Hershey Medical Center, Department of Radiology, Hershey, PA (R.S., J.M., A.L.C.); Penn State College of Medicine, Hershey, PA (J.W.); Penn State Health-Hershey Medical Center, Department of General Internal Medicine, Hershey, PA (R.S.C.); Penn State Health-Hershey Medical Center, Department of Surgery, Hershey, PA (M.P.)

\*Address correspondence to A.L.C. (e-mail: [achetlen@pennstatehealth.psu.edu](mailto:achetlen@pennstatehealth.psu.edu))

## Abstract

Over two-thirds of women will experience breast pain in their lifetime. As one of the leading breast symptoms for which women seek medical attention, breast pain is suspected to be underreported and under-studied. Cyclical breast pain is related to hormonal changes. Noncyclical breast pain is independent of the menstrual cycle and can be idiopathic and related to chronic pain syndromes, infections, ill-fitting bras, musculoskeletal abnormalities, pregnancy, perimenopause, and postsurgical causes. Breast pain can also present in transgender patients and may require additional considerations as to the underlying cause. Imaging of mastalgia depends upon the suspected etiology. Inappropriate imaging for breast pain is associated with significant utilization of health care resources. Cyclical breast pain does not require an imaging work-up. The work-up of focal, noncyclical breast pain includes ultrasound for women aged younger than 40 years, and mammography and ultrasound for women aged 40 years and older. Management of breast pain is often supportive, as most breast pain resolves spontaneously. If pain persists, imaging and management should follow a step-wise approach. If conservative measures fail, second-line therapy is topical nonsteroidal anti-inflammatory drugs. If breast pain is severe and resistant to conservative methods, additional third-line therapies can be added by breast care specialists with specific knowledge of the potential deleterious side effects of these medications. While the causes of mastalgia are overwhelmingly benign, breast pain can significantly impact quality of life, and the breast radiologist should be familiar with causes, management, and treatment recommendations from a multidisciplinary approach.

**Key words:** breast pain; mastalgia; management.

## Introduction

Breast pain, or mastalgia, affects up to 70%–80% of women during their lifetime (1–9). Although it is one of the leading breast symptoms for which women seek medical attention, it is believed that mastalgia may be generally underreported and under-studied (9–14). Complaints of mastalgia are more common in premenopausal women than in those aged older than 60 years, in patients with

larger breast cup size, and in patients with lower fitness and activity levels (15, 16). For men, breast pain is uncommon, although it may occur in the setting of gynecomastia, hormonal imbalance, and other conditions (14, 17, 18). Breast pain can also present in transgender individuals.

For some patients, mastalgia can be a severe and debilitating condition. Many patients with breast pain report that it has negatively

**Key Messages**

- While the causes of breast pain are overwhelmingly benign, mastalgia can significantly impact quality of life, and the breast radiologist should be familiar with causes, management, and treatment recommendations from a multidisciplinary approach.
- When breast pain is associated with other symptoms, such as a palpable mass, skin changes, edema, or nipple discharge, the pain should be considered a secondary symptom, and imaging work-up should be geared toward the primary symptom.
- Breast pain is not usually a sign of breast cancer, and most breast pain resolves spontaneously.

impacted their quality of life. Among women with mastalgia, over 40% report effects on sexual activity; 35% report effects on sleep; and 5% report effects on work activity (15). About one out of four women who experience breast pain report moderate to severe pain and tenderness lasting greater than 5 days (12, 15). In addition to impaired quality of life, those with mastalgia often have increased anxiety, depression, and fatigue (19).

Concern for malignancy is often a source of anxiety in those with mastalgia (20). This has contributed to breast pain becoming the most common breast-related symptom for which a woman will seek consultation from her primary care physician or breast surgeon (13). A large number of patients with breast pain will ultimately be referred to a breast imaging facility for further evaluation and reassurance (21).

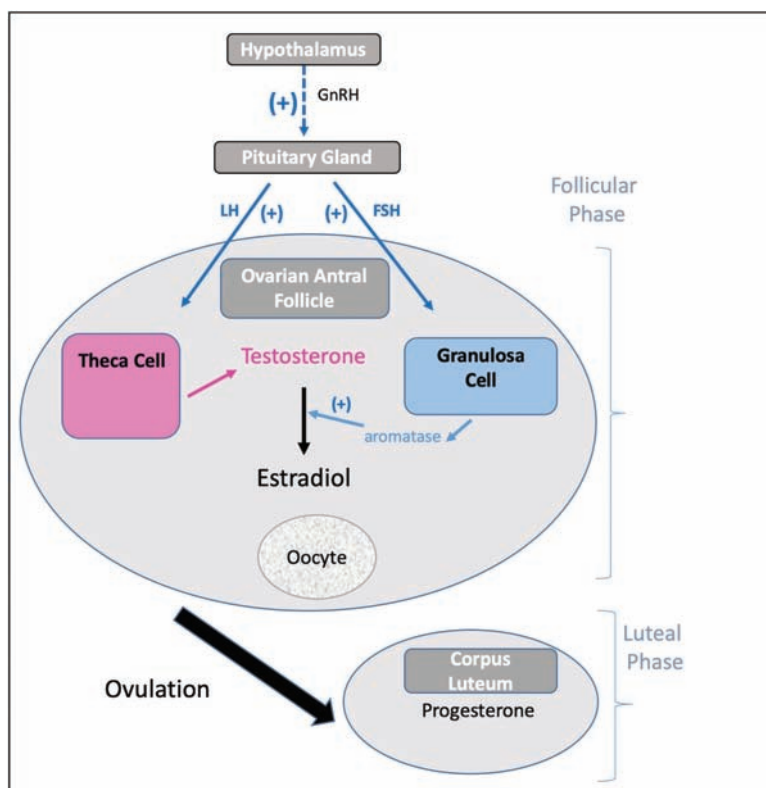
**Common causes of breast pain**

Mastalgia is typically classified into cyclical mastalgia (breast pain that predictably relates to the menstrual cycle) and noncyclical mastalgia (breast pain unrelated to the menstrual cycle). Cyclical is more common than noncyclical mastalgia; about two-thirds of women with mastalgia report cyclical symptoms with pain beginning in the week prior to menstruation (14, 15).

**Cyclical or physiological breast pain**

Cyclical or physiological breast pain is breast pain that is intermittent, recurrent, and related in time to the menstrual cycle. Cyclical breast pain is commonly bilateral and localized in the upper outer quadrants, but it can be unilateral or asymmetric. The breast is a dynamic organ with histologic changes occurring in breast tissue during different phases of the menstrual cycle. The ovulatory menstrual cycle results from a complex interaction of hormones produced by the hypothalamus, pituitary, and ovary (Figure 1) (22).

Physiological breast pain typically occurs in the luteal phase. Coinciding with rising progesterone levels, there are increases in lobule size, terminal ductal units, and basal epithelial cells proliferation. Stromal edema can occur, coinciding with sensation of breast fullness and venous congestion (23). Breast MRI in women during the luteal phase shows increased T2 signal, which likely reflects the increasing stromal edema (24, 25). These morphologic changes and changes in hormonal levels are believed to contribute to the increase in incidence of breast pain in the luteal phase of the cycle (26). The link between breast pain and luteal morphologic and hormonal changes is supported by studies that have shown



**Figure 1.** Endocrine pathways involved in the ovulatory menstrual cycle. (+) indicates stimulation. Abbreviations: GnRH, gonadotropin releasing hormone; FSH, follicle stimulating hormone; LH, luteinizing hormone.

that cyclical morphological breast changes do not occur in the absence of an intact anterior pituitary gland or the ovaries (27). The exact hormonal pathway leading to breast pain is still not completely understood. More recent studies have suggested that sex hormone binding protein (SHBP) may play a role in breast pain (Figure 2). SHBG has been positively associated with percent water in breast tissue which is thought to contribute to breast pain (28, 29).

### Perimenopausal Breast Pain

*Menopause* is defined as the time period that occurs in females following 12 consecutive months of amenorrhea. There is a transitional phase prior to menopause termed *perimenopause*, when women experience physical changes but continue to have menstrual periods. In menopause, estrogen levels are lower than premenopausal levels, and, paradoxically, in perimenopause, estradiol levels are higher than premenopausal levels and are often erratic during this time period (30, 31).

The endocrine basis of the elevated estradiol levels seen in perimenopause is not fully understood. Elevated and erratic estradiol levels likely explain the symptoms women experience during perimenopause (32). Elevated estradiol levels in perimenopause may be related to decreasing levels of a glycoprotein called inhibin B. Inhibin B is normally secreted by the ovaries, and it negatively feedbacks to the pituitary gland to inhibit follicle stimulating hormone (FSH) synthesis and secretion (32). Inhibin B levels have been shown to decrease during perimenopause due to ovarian aging (Figure 3). With less negative feedback, FSH levels increase. Elevated FSH stimulates additional antral follicles in the ovary, which in turn make more estradiol.

Sore and swollen breasts is a common complaint in patients with breast pain associated with perimenopause. Breast tenderness was a symptom for 34% of women in early perimenopause, and the symptoms of breast tenderness decreased in the late perimenopausal and postmenopausal time periods (33). In another study, 26% of perimenopausal women indicated that they experienced extreme breast pain, and this resulted in a negative view of menopause (34).

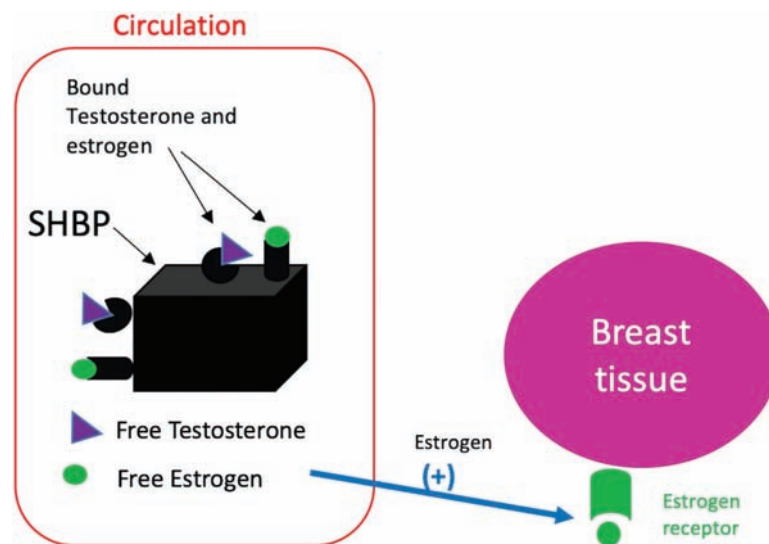
### Pregnancy- and Lactation-Related Breast Pain

Estrogen and progesterone secretion increase substantially during pregnancy (35). Under hormonal stimulation, the breast undergoes a process of growth and development to prepare the breast for milk production after delivery (36). Rising levels of estrogen stimulate ductal arborization and differentiation of epithelial cells into ductal, acinar, and myoepithelial elements (36). Estrogen also stimulates blood vessel growth and the synthesis and release of prolactin from the pituitary gland (which will stimulate secretion of milk after delivery). Rising levels of progesterone stimulate lobulo-alveolar development in the presence of estrogen and prolactin (36, 37). Therefore, there is an overall increase in breast tissue volume and a marked increase in vascular supply to the breast during pregnancy (36). These morphological changes can be accompanied by feelings of breast pain and fullness.

In breastfeeding patients, breast pain is one of the most common complaints that an obstetric care provider will encounter (38), and it may be due to a variety of causes including engorgement, milk stasis, candidiasis, nipple eczema, vasospasm of the nipple, ankyloglossia (commonly known as tongue-tie) of the newborn, trauma, dermatitis, herpes simplex viral outbreaks, or mastitis (38). Nipple and/or breast pain is the second most common factor causing mothers to abandon breastfeeding (38). Engorgement is the result of ineffective or infrequent milk removal from the breast and may be a result of mother–infant separation, a sleepy baby, sore nipples, or improper breastfeeding technique (38). An obstructed duct is a localized blockage of milk resulting from milk status, sometimes due to failure to vary nursing positions or by tight or restrictive clothing (38). Sore nipples are the most common complaint raised by patients in the immediate postpartum period; however, severe nipple pain, the presence of nipple cracks or fissures, pain that persists throughout a feeding, or pain that is not improved by the end of the first week requires evaluation (38).

### Breast Pain in Transgender and Gender-Reassignment Patients

*Transgender* is an adjective used to describe an individual whose gender does not correspond to the one assigned to them at birth.



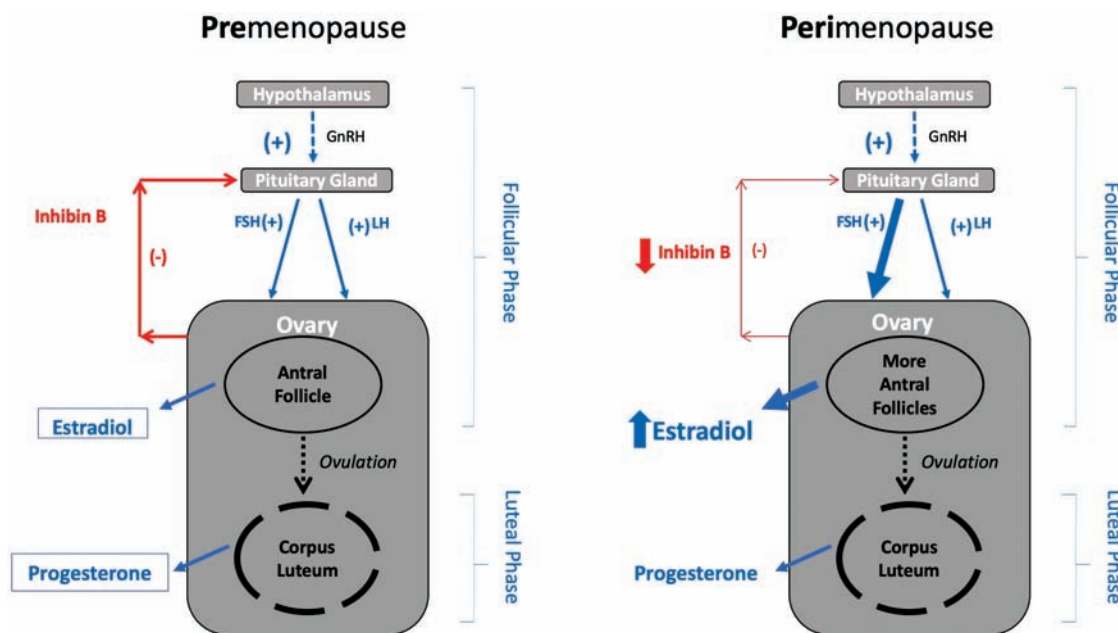
**Figure 2.** Role of sex hormone binding protein (SHBP) in the transport of estrogens. SHBP is a molecule that transports estrogens and testosterone through the blood to other tissues in the body (including breast tissue).

Transgender individuals perceive their breasts as being an important part of their gender identity (39), and respect and consideration of their anatomic and physiologic choices and social vulnerability is essential (40). *Gender reassignment* refers to steps taken to permanently alter persons' phenotype to align with their gender identity, and it is often achieved by hormone treatment and surgery (41). Changes in the breast tissue from hormone therapy, breast binding, mastectomy, or breast augmentation may offer unique challenges to the health care provider when evaluating breast pain (Table 1).

A *transgender woman* is a person who was assigned male sex at birth but identifies as a female (42). When a transgender female transitions from male to female, she is usually treated with estrogen therapies and androgen-lowering medications to promote breast development and feminization. The breast tissue that develops usually includes the development of ducts, lobules, and acini (43). On a mammogram, the breast tissue of a transgender woman has a similar appearance to that of nontransgender women, and transgender women

can have similar breast pathologies to nontransgender women. In review of the literature, breast pain has not been a significant reported side effect in transgender women using hormonal therapy to achieve breast growth (41, 42, 44, 45). However, transgender females often seek breast augmentation with implants to further achieve desired breast size. In transgender females undergoing augmentation, use of free silicone and other particles including mineral oil, liquid paraffin, or petroleum jelly have been associated with palpable lumps as well as breast pain (43, 46).

When a transgender male transitions from female to male, he is often treated with testosterone and may elect to undergo bilateral subcutaneous mastectomy to achieve a masculine chest appearance, termed *top surgery* (43). Prior to or instead of hormonal or invasive therapy, chest binders are often used by transgender males to achieve a male chest appearance (47). Chest binding involves the compression of the chest tissue for masculine gender expression, and for these individuals, chest binding is beneficial mentally and



**Figure 3.** Comparison of the endocrine pathways involved in premenopause and perimenopause. In perimenopause, Inhibin B levels decrease resulting in less negative feedback to the pituitary gland. This results in elevated levels of FSH, which stimulate additional follicles to produce more estradiol. (+) indicates stimulation. (-) indicates inhibition. Abbreviation: FSH, follicle stimulating hormone.

**Table 1.** Summary of Causes Related to Breast Pain in Transgender and Gender-Reassignment Patients and Diagnostic Imaging Recommendations

	Definition	Methods Related to Breasts Used to Achieve Gender for which They Identify	Causes of Breast Pain	Imaging of Breast Pain in Transgender Individuals
Transgender female	Assigned male sex at birth but identifies as a female	<ul style="list-style-type: none"> <li>• Hormonal treatment to develop breast tissue</li> <li>• Breast augmentation</li> <li>• Free silicone injections or other particles into breast</li> </ul>	<ul style="list-style-type: none"> <li>• Injected particles associated with complaints of breast lumps and pain</li> </ul>	<ul style="list-style-type: none"> <li>• For focal pain in transgender women with hormonal-induced breast tissue, diagnostic imaging is the same as in a nontransgender female (43).</li> <li>• Consider MRI to evaluate concerning pain in patients with silicone breast implants or free injection of particles.</li> </ul>
Transgender male	Assigned female sex at birth but identifies as a male	<ul style="list-style-type: none"> <li>• Chest binding</li> <li>• Mastectomy</li> </ul>	<ul style="list-style-type: none"> <li>• Breast pain due to chest binding</li> <li>• Chronic pain following mastectomy</li> </ul>	<ul style="list-style-type: none"> <li>• A patient could have residual breast tissue after mastectomy. Therefore, concerning focal breast pain following mastectomy should be addressed. Consider ultrasound first and then breast MRI if indicated (51).</li> </ul>

emotionally (47). There are many negative health effects associated with chest binding, with 97.2% of participants in one study on breast binding reporting at least one negative outcome attributed to binding, including breast tenderness, which was reported in 34% of participants (47). For those who elect to undergo mastectomy, the technique employed depends on breast size, degree of skin excess, skin elasticity, and nipple size and position (48). Chronic pain following mastectomy has been reported in nontransgender women undergoing mastectomy, with the most common symptoms including aching, throbbing, shooting, stabbing, and sharp pain and pain extending into the arm and shoulder regions (49, 50). There have been no large, well-controlled studies conducted to evaluate the adverse effects of hormone therapy on breast tissue of transgender individuals.

Many of the procedures and practices transgender individuals choose to undergo, such as implantation, injection, binding, and mastectomy, carry serious risks (40) and associated breast pain, and these patients should be treated with attention to both their genetic sex and the sex they are assuming (40).

### Breast Pain Associated with Chronic Pain Syndromes

The association of mastalgia with anxiety, depression, and fatigue (19) has been well established. Other psychological conditions have been associated with mastalgia including posttraumatic stress disorder, panic disorders, eating disorders, alcohol misuse, chronic pelvic pain, irritable bowel syndrome, history of domestic violence, and history of emotional abuse (52, 53). Recently, the relationship between mastalgia and chronic pain syndromes such as fibromyalgia has been examined, and, although not fully understood, studies have shown mastalgia and fibromyalgia are common comorbid conditions (52, 54, 55). It has been estimated that of those patients with fibromyalgia, over 40% will have comorbid mastalgia, and of those with mastalgia, approximately 40% will meet criteria for fibromyalgia (52, 54, 55). Furthermore, it was shown that mastalgia is aggravated by stress, particularly in those with comorbid fibromyalgia. In addition, those patients with comorbid pain conditions tend to experience higher levels of breast pain compared to patients without comorbid conditions and breast pain (54, 55). Although the associations are not fully understood, it is clear that some patients with mastalgia may have associated conditions that complicate and potentiate their breast pain.

### Noncyclical breast pain

The causes of breast pain in those patients who present with noncyclic symptoms are overwhelmingly benign, yet because noncyclical, focal, persistent pain has been associated with cancer, imaging evaluation of these patients is appropriate (56, 57). The incidence of breast cancer found in the setting of focal breast pain (not associated with a palpable lump) ranges from 0%–4.6% (21, 58–60). Many times, the etiology of the noncyclical breast pain will not be elucidated, and the cause is probably best described as idiopathic. Noncyclical breast pain resolves on its own in 50% of women (61). However, sometimes the cause of noncyclical, focal, persistent pain can be determined. Some of the more common specific causes are further discussed below.

### Infection as Cause of Breast Pain

Mastitis and abscess are related infectious processes that often cause pain associated with inflammation. These infections most commonly

occur in the context of lactation but can also occur in patients who are not lactating.

### Inflammatory Causes of Breast Pain

Inflammatory breast cancer can present with pain, but this is reported to occur in less than 20% of patients (62, 63). Idiopathic granulomatous mastitis is an entity that produces inflammation of the breast via an autoimmune process rather than infectious agent (64), and it can be associated with breast pain.

### Masses as a Cause of Breast Pain

Breast pain is an unusual presentation for solid masses in the breasts. However, breast cysts are a frequent cause of breast pain. Benign solid masses that can present with pain include growing fibroadenomas, infarction in a fibroadenoma, or phylloides tumors. Isolated breast pain is associated with cancer in less than 1% of cases (56, 65).

### Structural Causes of Breast Pain

Ill-fitting bras and insufficient breast support can lead to the development of several negative health outcomes such as upper limb neural symptoms and deep bra furrows caused by excessive strap pressure, neck and back pain (66–69), poor posture, and exercise-induced breast discomfort (70–72). Breast pain may be unrelated to the breast and instead be due to musculoskeletal and structural causes including referred pain from arthritis or costochondritis (73). Clinical exam may identify a musculoskeletal cause by reproducing symptoms through localized pressure on the chest wall (73). Macromastia, abnormal enlargement of the breast tissue in excess of the normal proportion, can be caused by glandular hypertrophy, excessive fatty tissue, or a combination of both (74). Macromastia can cause a number of symptoms including back pain, neck pain, shoulder grooves, rashes under the breast, and breast pain (75).

### Postsurgical Causes of Breast Pain

Acute pain following surgery can resolve or develop into a more chronic condition (76). Efforts are ongoing to develop screening tools for the preoperative psychosocial and psychophysical phenotypes as predictors of acute pain outcomes after breast surgery (77). Lymphedema is the abnormal swelling that can develop in the arm, breast, or torso in patients as a side effect of breast cancer surgery (often axillary node dissection) or radiation. The mechanism is felt to be related to the disruption of the primary axillary lymphatic drainage pathway. Breast lymphedema can be accompanied by symptoms of achiness, fullness, and heaviness in the breast and axillary regions (78). Lymphedema of the breast can also occur after surgery particularly with the addition of radiation therapy in the breast cancer patient. Approximately one-quarter of patients may experience breast edema following breast-conserving surgery and radiotherapy, with the highest prevalence 6 months after surgery (79).

### Medication-Related Causes of Breast Pain

Daily combination oral contraceptives (COCs) can cause breast tenderness as a side effect (80). The vaginal ring is a nonoral hormonal contraceptive that delivers a lower dose of estrogen vaginally than COCs, and it is associated with fewer side effects such as breast tenderness. Conversely, the transdermal contraceptive patch has higher total estrogen exposure compared to COCs and slightly higher rates of breast tenderness (81).



Other examples of medications that have been associated with breast pain include antidepressants and antipsychotic medications including SSRIs, amitriptyline, and haloperidol; certain cardiac medications including digoxin and spironolactone; and antimicrobial agents such as metronidazole and ketoconazole, and cimetidine (in males) (14).

## Imaging of breast pain

Breast imaging is not indicated in patients with cyclical breast pain or breast pain that is diffuse and nonfocal. When pain is associated with other symptoms (palpable mass, skin changes, edema, or nipple discharge), the pain should be considered a secondary symptom, and imaging work-up should be tailored to the primary symptom (82).

When breast pain is persistent, focal (less than one quadrant), and noncyclical, imaging studies may provide additional important information. For patients aged younger than 40 years, directed breast sonography is the most appropriate imaging step (82, 83). For patients aged 40 years and older, diagnostic mammography and directed sonography are appropriate (82, 83) (Figure 4). For pregnant patients, ultrasound should be the initial imaging modality utilized in the work-up of concerning breast pain.

Digital breast tomosynthesis (DBT) imaging overcomes some of the limitations of overlapping tissue and decreases lesion masking, and it should be utilized if available and the breast tissue is dense. Although there are no prospective studies comparing DBT to standard 2D imaging in the setting of breast pain, DBT has been shown to increase lesion visualization and characterization in the diagnostic setting (84).

Ultrasound can identify mass lesions, and potentially can find treatable causes of breast pain such as cysts. Ultrasound may be particularly useful in the patient with negative mammogram and dense

breasts. The utility of sonography is less clear after a negative mammogram in a fatty replaced breast. The addition of sonography in these cases may add costs not justified by the outcomes data. Leddy and colleagues found that ultrasound resulted in additional biopsies and recommendations for follow-up exams without detection of additional cancers (58).

For those with breast pain, the negative predictive value of mammography and ultrasound has been demonstrated to be near 100% (21, 57, 85). After initial imaging and reassurance, most women require no follow-up intervention (12, 21). A negative ultrasound may provide important reassurance and relieve the anxiety that breast pain can provoke. Women with high levels of anxiety, perceived stress, and general worry about their health may need further reassurance during the diagnostic consultation, especially if they were only educated to high school level (86).

Additionally, more recent studies have demonstrated that those who received initial breast imaging were significantly more likely to have subsequent imaging, biopsies, follow-up visits, and utilization of other clinical services, compared with those who did not have initial imaging (87, 88). This suggests that for those with mastalgia, imaging may not provide as much reassurance as previously thought, and the value of imaging for mastalgia should be carefully examined.

Imaging of transgender individuals depends on whether they have breast tissue and their risk factors. For a transgender male who still has breasts and has not had top surgery, routine screening should be the same as if he were female. For transgender females who have received hormone treatment with subsequent development of ductal epithelium and lobules, there are no clear recommendations for breast screening. Although not evidence based, screening mammography has been suggested for transgender women with risk factors, including those receiving hormone treatment for greater than 5 years (43). Since transgender women with breast tissue can

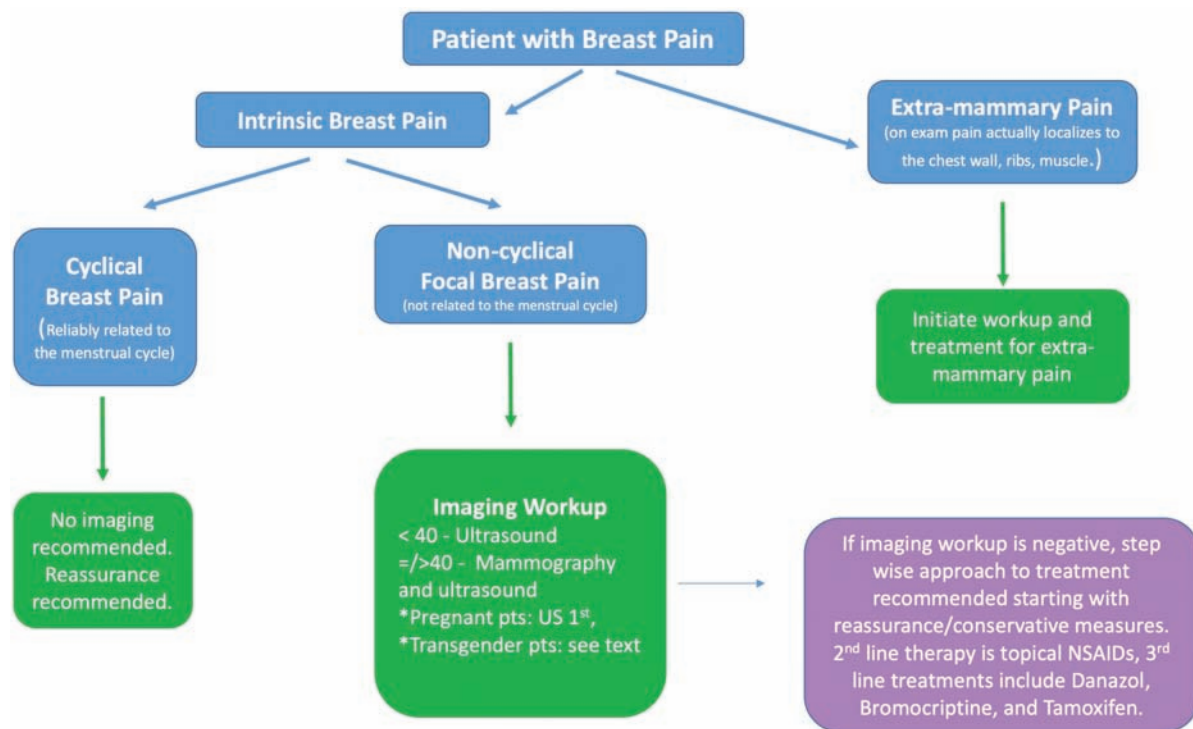


Figure 4. Algorithm for the physician evaluating breast pain.

develop similar breast pathology to that of nontransgender women, diagnostic imaging using mammography, ultrasound, and MRI is the same in these two groups. For transgender females who have undergone augmentation by direct injection of particles, enhanced breast MRI may be more helpful to evaluate clinical findings since mammography is less sensitive in this group (43).

## Management of breast pain

Management of breast pain depends on the underlying etiology and, generally, should be managed by the patient's primary care provider. Therapies that are more advanced for treatment-resistant breast pain may require referral to a specialist. For some women, a clear etiology for their breast pain is evident (mass, cyst, infection, etc.), and management can be tailored to this diagnosis. However, for most women, the etiology of their breast pain is not clearly understood, which makes treatment of most breast pain challenging (Table 2).

## Treatment of Idiopathic Breast Pain

Since breast pain is rarely associated with breast cancer and most breast pain resolves spontaneously, reassurance and education are usually sufficient for many patients (61, 89). Adequate bra support has also been shown to be beneficial in improving mastalgia (90). Exercise is a third conservative measure that may help decrease breast pain, assuming a supportive sports bra is worn when participating (91).

A number of dietary modifications including a low-fat diet, limiting caffeine intake, vitamin consumption, evening primrose oil, and consuming soy have been proposed to relieve breast pain. However, their effectiveness is unclear since they have not been studied using randomized controlled trials (61, 92, 93). If breast pain persists despite conservative measures, the next recommended therapy is a topical nonsteroidal anti-inflammatory drug (NSAID), such as Diclofenac. Topical NSAIDs are nonprescription and have been shown to significantly decrease breast pain without significant side effects (61, 94, 95). Oral NSAIDs have not been shown to have benefit over topical NSAIDs.

**Table 2.** Therapies for Cyclical and Noncyclical Breast Pain

Therapy	Proposed Mechanism	Effect on Breast Pain	Side Effects
<b>Conservative measures</b>			
Reassurance	Relieves anxiety	Cyclical breast pain resolves spontaneously within 3 months in 20%–30% of women; noncyclical breast pain may resolve in about 50% of women (61) Reassurance effectively treated mild, moderate, and severe mastalgia in 86%, 71%, and 52% of patients, respectively (97)	None
Well-fitting bra	Helps support ligamentous structures and reduces amplitude of breast displacement during walking and running	May improve (90)	None
Exercise (91)		May improve, can increase breast pain if the breast is not well supported	None
<b>Dietary &amp; lifestyle</b>			
Fat reducing diet		Likely negligible effect	None
Evening Primrose Oil		Likely negligible effect	None
Vitamin E or D		Likely negligible effect	None
Caffeine Reduction		Likely negligible effect	None
Soy (92)	Isoflavones in soy may bind to estrogen receptors and block effects in breast tissue	May relieve pain in premenopausal women	None
Smoking cessation		No clear link	
<b>Analgesics</b>			
Oral NSAIDs	Anti-inflammatory by inhibiting prostaglandins	No benefit over topical NSAIDs	Gastrointestinal effects
Topical NSAIDs (98)	Anti-inflammatory by inhibiting prostaglandins	Significant decrease in cyclical and noncyclical breast pain	Potential for elevation of LFTs (61)
<b>Hormonal therapies</b>			
Danazol	LH/FSH inhibitor, binds to sex hormone receptors in target tissues resulting in antiestrogen effects	third-line agent; decreases cyclical breast pain	Weight gain, menstrual irregularity, nervousness, deepening of voice, and androgenic effects on fetus
Tamoxifen	Selective estrogen receptor modulator	Third-line agent; reserved for severe breast pain; reduced breast pain by 71%–96% in women with cyclic breast pain and 56% of women with noncyclic breast pain	Venous thrombosis, nausea, and weight gain. Duration of use: 6 months
Gonadorelin analogues	Inhibitor of pituitary gonadotropin secretion decreasing production of estradiol	Reserved for severe refractory breast pain	Vaginal dryness, hot flashes, and irritability Duration of use: 6 months

Abbreviations: FSH, follicle stimulating hormone; LFT, liver function test; LH, luteinizing hormone; NSAID, non-steroidal anti-inflammatory drug.

For severe breast pain and pain that continues despite the use of topical NSAIDs, additional third-line therapies are available. However, due to the side effects of these agents, referral to a specialist in breast care is suggested at this point. A breast specialist may discuss the risks and benefits of additional endocrine or hormonal treatment options, including danazol and tamoxifen (61, 89, 94, 95). Danazol indirectly reduces estrogen production by decreasing pituitary secretion of FSH and LH, and it binds to sex hormone receptors in target tissues, resulting in antiestrogenic effects (61).

Tamoxifen is a selective estrogen receptor modulator that is usually used to prevent and treat breast cancer. Tamoxifen has been shown to be effective in reducing breast pain by 71%–96% in women with cyclic breast pain and 56% of women with noncyclic breast pain (14). However, tamoxifen carries with it some potentially serious side effects including deep venous thrombosis and endometrial cancer. Additional side effects include hot flashes, nausea, and weight gain (61). Duration of treatment should not exceed 6 months (96). Gonadorelin analogue injections can be used to reduce breast pain but should be reserved for severe refractory mastalgia and should be limited to 6 months of treatment (61, 96).

#### Treatment for Breast Pain Related to Macromastia

For women with macromastia, lifestyle-modification counseling for weight loss and referral for surgical intervention should also be considered if appropriate. Treatment of breast pain associated with systemic pain syndromes, such as fibromyalgia, is directed to the underlying condition. Reduction mammoplasty has been shown to reduce symptoms related to macromastia (75). For women with structural pain, correctly fitting, supportive bras have been found to alleviate up to 85% of these pain symptoms, allowing women to exercise in greater comfort and possibly removing the need for breast-reduction surgery (66, 90).

#### Treatment for Breast Pain Related to Inflammation and/or Infection

Idiopathic granulomatous mastitis is often initially treated with surveillance and low-dose prednisolone for up to 6 months; methotrexate and surgery are reserved for refractory cases (64). First-line treatment for fluid collections in the breast is serial aspiration, as this improves cosmesis and decreases healing time. Incision and drainage is recommended for recurrent abscess or if percutaneous drainage is unsuccessful (99, 100). Aspiration may be indicated in patients with symptomatic dominant cysts for pain relief (101).

#### Treatment for Breast Pain Related to Pregnancy and Lactation

For breastfeeding women, topical treatments are often recommended for nipple pain (lanolin, colostrum, and glycerin pads) and breast engorgement (cabbage leaves and cold packs), but there is insufficient evidence for their efficacy (102, 103). In women undergoing treatment for mastitis, pain medication such as NSAIDs should be offered to encourage continued breastfeeding or pumping if not otherwise contraindicated (104).

#### Treatment for Breast Pain Related to Surgical Causes

Acute pain following surgery can be managed in the majority of patients with ibuprofen and acetaminophen, although a minority of patients may require a short course of opioids (76). Some patients

develop a more chronic pain syndrome in which strategies such as pain management consultation may be employed (76). Paravertebral nerve blocks have been shown to be successful in the treatment of postmastectomy-related breast pain (105). Acupuncture and hypnotherapy may also play a role in pain reduction (106). As with lymphedema of the arm, decongestive therapy reduces symptoms including redness, swelling, and pain.

#### Economic impact of breast pain

Given the high prevalence of mastalgia and the associated utilization of diagnostic imaging for breast pain, the economic impact is of interest. In one recent study evaluating the diagnostic work-up and cost of those presenting with the sole complaint of breast pain, nearly 70% of patients received a breast ultrasound exam, and nearly 80% received mammograms with 99.4% of mammograms being negative (88). In the end, the total estimated cost for 1 year of evaluation of breast pain at three community hospital breast imaging centers for 799 patients was \$261 816 (mean cost per patient = \$328) and led to the diagnosis of one incidental cancer in a contralateral breast (88). Importantly, the actual costs were likely much higher given the majority of patients were billed at private insurance rates (88).

Diagnostic imaging is often believed to provide reassurance to patients with mastalgia, and, therefore, may be highly valuable; however, more research is needed to establish the economic impact of mastalgia and evaluate a cost benefit ratio for healthcare utilization in the setting of breast pain. There has been conflicting evidence concerning imaging as a way to reduce anxiety and provide reassurance in patients with mastalgia (12, 20, 107). One recent study investigating the effects of ultrasonography on pain and anxiety in the setting of mastalgia found that severity of pain and anxiety were significantly reduced after ultrasonography (108). However, two studies found that imaging performed to evaluate breast pain did not necessarily result in reassurance and ultimately led to overutilization of health care resources including imaging, biopsies, and additional visits (87, 88). One of the studies found that for those who underwent initial imaging, 75% had normal findings, yet an overwhelming 98% returned for further evaluation (87).

#### Conclusion

While the causes of mastalgia are overwhelmingly benign, breast pain can significantly impact quality of life, and the breast radiologist should be familiar with causes, management, and multidisciplinary treatment recommendations.

#### Conflict of interest statement

R.S. disclosures that her husband, Dr. Suren Sivarajah, is the Medical Director for Cardiovascular Diabetes and Metabolism Section of AstraZeneca; she has no personal financial disclosures. A.L.C. received a consultant fee for BS BARD (\$350); this consulting work is not related to this manuscript topic. For all other authors, none declared.

#### References

1. Olawaiye A, Withiam-Leitch M, Danakas G, Kahn K. Mastalgia: a review of management. *J Reprod Med* 2005;50:933–939.
2. Mansel RE. ABC of breast diseases. Breast pain. *BMJ* 1994;309: 866–868.



3. Maddox PR, Harrison BJ, Mansel RE, Hughes LE. Non-cyclical mastalgia: an improved classification and treatment. *Br J Surg* 1989;76:901–904.
4. Ader DN, Browne MW. Prevalence and impact of cyclic mastalgia in a United States clinic-based sample. *Am J Obstet Gynecol* 1997;177:126–132.
5. Ader DN, Shriver CD. Cyclical mastalgia: prevalence and impact in an outpatient breast clinic sample. *J Am Coll Surg* 1997;185:466–470.
6. Goodwin PJ, DeBoer G, Clark RM, et al. Cyclical mastopathy and premenopausal breast cancer risk. Results of a case-control study. *Breast Cancer Res Treat* 1995;33:63–73.
7. Goodwin PJ, Miller A, Del Giudice ME, Ritchie K. Breast health and associated premenstrual symptoms in women with severe cyclic mastopathy. *Am J Obstet Gynecol* 1997;176:998–1005.
8. Leinster SJ, Whitehouse GH, Walsh PV. Cyclical mastalgia: clinical and mammographic observations in a screened population. *Br J Surg* 1987;74:220–222.
9. Griffith CD, Dowe CS, Hinton CP, Blamey RW. The breast pain clinic: a rational approach to classification and treatment of breast pain. *Postgrad Med J* 1987;63:547–549.
10. Vaidyanathan L, Barnard K, Elnicki DM. Benign breast disease: when to treat, when to reassure, when to refer. *Cleve Clin J Med* 2002;69:425–432.
11. Fentiman IS, Hamed H. Assessment of breast problems. *Int J Clin Pract* 2001;55:458–460.
12. Miller AV, Dirbas FM. Clinical management of breast pain: a review. *Obstet Gynecol Surv* 2002;57:451–461.
13. Morrow M. The evaluation of common breast problems. *Am Fam Physician* 2000;61:2371–8, 2385.
14. Smith RL, Pruthi S, Fitzpatrick LA. Evaluation and management of breast pain. *Mayo Clin Proc* 2004;79:353–372.
15. Scurr J, Hedger W, Morris P, Brown N. The prevalence, severity, and impact of breast pain in the general population. *Breast J* 2014;20:508–513.
16. Brown N, Burnett E, Scurr J. Is breast pain greater in active females compared to the general population in the UK? *Breast J* 2016;22:194–201.
17. Dobs A, Darkes MJ. Incidence and management of gynecomastia in men treated for prostate cancer. *J Urol* 2005;174:1737–1742.
18. Narula HS, Carlson HE. Gynaecomastia—pathophysiology, diagnosis and treatment. *Nat Rev Endocrinol* 2014;10:684–698.
19. Kanat BH, Atmaca M, Girgin M, et al. Effects of mastalgia in young women on quality of life, depression, and anxiety levels. *Indian J Surg* 2016;78:96–99.
20. Leung JW, Kornguth PJ, Gotway MB. Utility of targeted sonography in the evaluation of focal breast pain. *J Ultrasound Med* 2002;21:521–526; quiz 528.
21. Tumyan L, Hoyt AC, Bassett LW. Negative predictive value of sonography and mammography in patients with focal breast pain. *Breast J* 2005;11:333–337.
22. Barbieri RL. The endocrinology of the menstrual cycle. *Methods Mol Biol* 2014;1154:145–169.
23. Vogel PM, Georgiade NG, Fetter BF, Vogel FS, McCarty KS Jr. The correlation of histologic changes in the human breast with the menstrual cycle. *Am J Pathol* 1981;104:23–34.
24. Hussain Z, Roberts N, Whitehouse GH, García-Fiñana M, Percy D. Estimation of breast volume and its variation during the menstrual cycle using MRI and stereology. *Br J Radiol* 1999;72:236–245.
25. Graham SJ, Stanchev PL, Lloyd-Smith JO, Bronskill MJ, Plewes DB. Changes in fibroglandular volume and water content of breast tissue during the menstrual cycle observed by MR imaging at 1.5 T. *J Magn Reson Imaging* 1995;5:695–701.
26. Ramakrishnan R, Khan SA, Badve S. Morphological changes in breast tissue with menstrual cycle. *Mod Pathol* 2002;15:1348–1356.
27. Laidlaw IJ, Clarke RB, Howell A, Owen AW, Potten CS, Anderson E. The proliferation of normal human breast tissue implanted into athymic nude mice is stimulated by estrogen but not progesterone. *Endocrinology* 1995;136:164–171.
28. Linton L, Taylor M, Dunn S, et al. Associations of serum levels of sex hormones in follicular and luteal phases of the menstrual cycle with breast tissue characteristics in young women. *PLoS One* 2016;11:e0163865.
29. Plymate SR, Moore DE, Cheng CY, Bardin CW, Southworth MB, Levinski MJ. Sex hormone-binding globulin changes during the menstrual cycle. *J Clin Endocrinol Metab* 1985;61:993–996.
30. Prior JC. Progesterone for symptomatic perimenopause treatment – progesterone politics, physiology and potential for perimenopause. *Facts Views Vis Obgyn* 2011;3:109–120.
31. Prior JC. Perimenopause: the complex endocrinology of the menopausal transition. *Endocr Rev* 1998;19:397–428.
32. Welt CK, McNicholl DJ, Taylor AE, Hall JE. Female reproductive aging is marked by decreased secretion of dimeric inhibin. *J Clin Endocrinol Metab* 1999;84:105–111.
33. Dennerstein L, Dudley EC, Hopper JL, Guthrie JR, Burger HG. A prospective population-based study of menopausal symptoms. *Obstet Gynecol* 2000;96:351–358.
34. Sood R, Kuhle C, Kapoor E, et al. A negative view of menopause: does the type of symptom matter? *Climacteric* 2016;19:581–587.
35. Tal R, Taylor HS, Burney RO, Mooney SB, Giudice LC. Endocrinology of pregnancy. [Updated 2015 Dec 7]. In: Feingold KR, Anawalt B, Boyce A, et al., eds., *Endotext* [Internet]. South Dartmouth (MA): MDText.com, Inc.; 2000. Available from: <https://www.ncbi.nlm.nih.gov/books/NBK278962/>. Accessed December 5, 2019.
36. Sabate JM, Clotet M, Torrubia S, et al. Radiologic evaluation of breast disorders related to pregnancy and lactation. *Radiographics* 2007;27(Suppl 1):S101–S124.
37. Graham JD, Clarke CL. Physiological action of progesterone in target tissues. *Endocr Rev* 1997;18:502–519.
38. Mass S. Breast pain: engorgement, nipple pain and mastitis. *Clin Obstet Gynecol* 2004;47:676–682.
39. Dutton L, Koenig K, Fennie K. Gynecologic care of the female-to-male transgender man. *J Midwifery Womens Health* 2008;53:331–337.
40. Maycock LB, Kennedy HP. Breast care in the transgender individual. *J Midwifery Womens Health* 2014;59:74–81.
41. T’Sjoen G, Arcelus J, Gooren L, Klink DT, Tangpricha V. Endocrinology of Transgender Medicine. *Endocr Rev* 2019;40:97–117.
42. Hembree WC, Cohen-Kettenis PT, Gooren L, et al. Endocrine treatment of gender-dysphoric/gender-incongruent persons: an Endocrine Society Clinical Practice Guideline. *J Clin Endocrinol Metab* 2017;102:3869–3903.
43. Sonnenblick EB, Shah AD, Goldstein Z, Reisman T. Breast imaging of transgender individuals: a review. *Curr Radiol Rep* 2018;6:1.
44. de Blok CJM, Klaver M, Wiepjes CM, et al. Breast development in transwomen after 1 year of cross-sex hormone therapy: results of a prospective multicenter study. *J Clin Endocrinol Metab* 2018;103:532–538.
45. Seal LJ, Franklin S, Richards C, Shishkareva A, Sinclair C, Barrett J. Predictive markers for mastoplasty and a comparison of side effect profiles in transwomen taking various hormonal regimens. *J Clin Endocrinol Metab* 2012;97:4422–4428.
46. Wilson E, Rapues J, Jin H, Raymond HF. The use and correlates of illicit silicone or “fillers” in a population-based sample of transwomen, San Francisco, 2013. *J Sex Med* 2014;11:1717–1724.
47. Peitzmeier S, Gardner I, Weinand J, Corbet A, Acevedo K. Health impact of chest binding among transgender adults: a community-engaged, cross-sectional study. *Cult Health Sex* 2017;19:64–75.
48. Wang ED KE. Postoperative Care and Common Issues After Masculinizing Chest Surgery. Available at: <https://transcare.ucsf.edu/guidelines/chest-surgery-masculinizing>. Accessed 9 September 2019.
49. Wallace MS, Wallace AM, Lee J, Dobke MK. Pain after breast surgery: a survey of 282 women. *Pain* 1996;66:195–205.
50. Kudel I, Edwards RR, Kozachik S, et al. Predictors and consequences of multiple persistent postmastectomy pains. *J Pain Symptom Manage* 2007;34:619–627.
51. Stowell JT, Grimstad FW, Kirkpatrick DL, et al. Imaging findings in transgender patients after gender-affirming surgery. *Radiographics* 2019;39:1368–1392.

52. Johnson KM, Bradley KA, Bush K, Gardella C, Dobie DJ, Laya MB. Frequency of mastalgia among women veterans. Association with psychiatric conditions and unexplained pain syndromes. *J Gen Intern Med* 2006;21(Suppl 3):S70–S75.
53. Colegrave S, Holcombe C, Salmon P. Psychological characteristics of women presenting with breast pain. *J Psychosom Res* 2001;50:303–307.
54. Genc V, Genc A, Ustuner E, et al. Is there an association between mastalgia and fibromyalgia? Comparing prevalence and symptom severity. *Breast* 2011;20:314–318.
55. Sen M, Kilic MO, Cemeroglu O, Icen D. Can mastalgia be another somatic symptom in fibromyalgia syndrome? *Clinics (Sao Paulo)* 2015;70:733–737.
56. Chetlen AL, Kapoor MM, Watts MR. Mastalgia: imaging work-up appropriateness. *Acad Radiol* 2017;24:345–349.
57. Leddy R, Cluver A. Mammographic and sonographic characteristics of a cavernous hemangioma in a male patient. *J Ultrasound Med* 2010;29:645–649.
58. Leddy R, Irshad A, Zerwas E, et al. Role of breast ultrasound and mammography in evaluating patients presenting with focal breast pain in the absence of a palpable lump. *Breast J* 2013;19:582–589.
59. Loving VA, DeMartini WB, Eby PR, Gutierrez RL, Peacock S, Lehman CD. Targeted ultrasound in women younger than 30 years with focal breast signs or symptoms: outcomes analyses and management implications. *AJR Am J Roentgenol* 2010;195:1472–1477.
60. Holbrook AI, Moy L, Akin EA, et al. ACR Appropriateness Criteria® Breast Pain. *J Am Coll Radiol* 2018;15:S276–S282.
61. Goyal A. Breast pain. *BMJ Clin Evid* 2011;2011:0812. Published 17 January 2011.
62. Menta A, Fouad TM, Lucci A, et al. Inflammatory breast cancer: what to know about this unique, aggressive breast cancer. *Surg Clin North Am* 2018;98:787–800.
63. Matro JM, Li T, Cristofanilli M, et al. Inflammatory breast cancer management in the national comprehensive cancer network: the disease, recurrence pattern, and outcome. *Clin Breast Cancer* 2015;15:1–7.
64. Nair CG, Jacob P, Menon RR. Inflammatory diseases of the non-lactating female breasts. *Int J Surg* 2015;13:8–11.
65. Mohallem Fonseca M, Lamb LR, Verma R, Ogunkinle O, Seely JM. Breast pain and cancer: should we continue to work-up isolated breast pain? *Breast Cancer Res Treat* 2019;177:619–627.
66. Greenbaum AR, Heslop T, Morris J, Dunn KW. An investigation of the suitability of bra fit in women referred for reduction mammoplasty. *Br J Plast Surg* 2003;56:230–236.
67. BeLieu RM. Mastodynia. *Obstet Gynecol Clin North Am* 1994;21:461–477.
68. Ryan EL. Pectoral girdle myalgia in women: a 5-year study in a clinical setting. *Clin J Pain* 2000;16:298–303.
69. KAYE B. Neurologic changes with excessively large breasts. *South Med J* 1972;65:177–80.
70. Gehlsen G, Albohm M. Evaluation of sports bras. *Phys Sportsmed* 1980;8:88–97.
71. Mason BR, Page KA, Fallon K. An analysis of movement and discomfort of the female breast during exercise and the effects of breast support in three cases. *J Sci Med Sport* 1999;2:134–144.
72. Lorentzen D, Lawson L. Selected sports bras: a biomechanical analysis of breast motion while jogging. *Phys Sportsmed* 1987;15:128–139.
73. Amin AL, Purdy AC, Mattingly JD, Kong AL, Termuhlen PM. Benign breast disease. *Surg Clin North Am* 2013;93:299–308.
74. Rahman GA, Adigun IA, Yusuf IF. Macromastia: a review of presentation and management. *Niger Postgrad Med J* 2010;17:45–49.
75. Spector JA, Karp NS. Reduction mammoplasty: a significant improvement at any size. *Plast Reconstr Surg* 2007;120:845–850.
76. Limbach KE, Pommier SJ, Massimino KP, Pommier RE, Naik AM. A prospective study of opioid use for postoperative pain management after breast operation. *Am J Surg* 2019. In press, Available online 25 July 2019. doi:10.1016/j.amjsurg.2019.07.032
77. Schreiber KL, Zinboonyahoon N, Xu X, et al. Preoperative psychosocial and psychophysical phenotypes as predictors of acute pain outcomes after breast surgery. *J Pain* 2019;20:540–556.
78. Degnim AC, Miller J, Hoskin TL, et al. A prospective study of breast lymphedema: frequency, symptoms, and quality of life. *Breast Cancer Res Treat* 2012;134:915–922.
79. Young-Afat DA, Gregorowitsch ML, van den Bongard DH, et al. Breast edema following breast-conserving surgery and radiotherapy: patient-reported prevalence, determinants, and effect on health-related quality of life. *JNCI Cancer Spectr* 2019;3:pkz011.
80. Shulman LP. The state of hormonal contraception today: benefits and risks of hormonal contraceptives: combined estrogen and progestin contraceptives. *Am J Obstet Gynecol* 2011;205:S9–13.
81. Galzote RM, Rafie S, Teal R, Mody SK. Transdermal delivery of combined hormonal contraception: a review of the current literature. *Int J Womens Health* 2017;9:315–321.
82. Holbrook AI, Moy L, Akin E, et al. American College of Radiology ACR Appropriateness Criteria Breast Pain. In: Radiology ACo, ed., 2018;15(11S):S276–S282. doi:10.1016/j.jacr.2018.09.014.
83. Lehman CD, Lee CI, Loving VA, Portillo MS, Peacock S, DeMartini WB. Accuracy and value of breast ultrasound for primary imaging evaluation of symptomatic women 30–39 years of age. *AJR Am J Roentgenol* 2012;199:1169–1177.
84. Gennaro G, Hendrick RE, Toledano A, et al. Combination of one-view digital breast tomosynthesis with one-view digital mammography versus standard two-view digital mammography: per lesion analysis. *Eur Radiol* 2013;23:2087–2094.
85. Masroor I, Afzal S, Sakhawat S, Khan N, Beg MA, Kawal D. Negative predictive value of mammography and sonography in mastalgia with negative physical findings. *J Pak Med Assoc* 2009;59:598–601.
86. Meechan GT, Collins JP, Moss-Morris RE, Petrie KJ. Who is not reassured following benign diagnosis of breast symptoms? *Psychooncology* 2005;14:239–246.
87. Howard MB, Battaglia T, Prout M, Freund K. The effect of imaging on the clinical management of breast pain. *J Gen Intern Med* 2012;27:817–824.
88. Kushwaha AC, Shin K, Kalambo M, et al. Overutilization of health care resources for breast pain. *AJR Am J Roentgenol* 2018;211:217–223.
89. Hafiz SP, Barnes NLP, Kirwan CC. Clinical management of idiopathic mastalgia: a systematic review. *J Prim Health Care* 2018;10:312–323.
90. Hadi MS. Sports Brassiere: is it a solution for mastalgia? *Breast J* 2000;6:407–409.
91. Genç A, Çelebi MM, Çelik SU, et al. The effects of exercise on mastalgia. *Phys Sportsmed* 2017;45:17–21.
92. Ingram DM, Hickling C, West L, Mahe LJ, Dunbar PM. A double-blind randomized controlled trial of isoflavones in the treatment of cyclical mastalgia. *Breast* 2002;11:170–174.
93. Eren T, Aslan A, Ozemir IA, et al. Factors Effecting Mastalgia. *Breast Care (Basel)* 2016;11:188–193.
94. Groen JW, Grosfeld S, Wilschut JA, Bramer WM, Ernst MF, Mullender MM. Cyclic and non-cyclic breast-pain: a systematic review on pain reduction, side effects, and quality of life for various treatments. *Eur J Obstet Gynecol Reprod Biol* 2017;219:74–93.
95. Iddon J, Dixon JM. Mastalgia. *BMJ* 2013;347:f3288.
96. Salzman B, Fleegle S, Tully AS. Common breast problems. *Am Fam Physician* 2012;86:343–349.
97. Barros AC, Mottola J, Ruiz CA, Borges MN, Pinotti JA. Reassurance in the Treatment of Mastalgia. *Breast J* 1999;5:162–165.
98. Colak T, Ipek T, Kanik A, Ogetman Z, Aydin S. Efficacy of topical nonsteroidal antiinflammatory drugs in mastalgia treatment. *J Am Coll Surg* 2003;196:525–530.
99. Lam E, Chan T, Wiseman SM. Breast abscess: evidence based management recommendations. *Expert Rev Anti Infect Ther* 2014;12:753–762.
100. Giess CS, Golshan M, Flaherty K, Birdwell RL. Clinical experience with aspiration of breast abscesses based on size and etiology at an academic medical center. *J Clin Ultrasound* 2014;42:513–521.
101. Rinaldi P, Ierardi C, Costantini M, et al. Cystic breast lesions: sonographic findings and clinical management. *J Ultrasound Med* 2010;29:1617–1626.
102. Dennis CL, Jackson K, Watson J. Interventions for treating painful nipples among breastfeeding women. *Cochrane Database Syst Rev* 2014;(12):CD007366.

103. Mangesi L, Zakarija-Grkovic I. Treatments for breast engorgement during lactation. *Cochrane Database Syst Rev* 2016;(6):CD006946.
104. Berens PD. Breast pain: engorgement, nipple pain, and mastitis. *Clin Obstet Gynecol* 2015;58:902–914.
105. Ilfeld BM, Madison SJ, Suresh PJ, et al. Treatment of postmastectomy pain with ambulatory continuous paravertebral nerve blocks: a randomized, triple-masked, placebo-controlled study. *Reg Anesth Pain Med* 2014;39:89–96.
106. Schnur JB, Bovbjerg DH, David D, et al. Hypnosis decreases presurgical distress in excisional breast biopsy patients. *Anesth Analg* 2008;106:440–444, table of contents.
107. Jokich PM, Bailey L, D’Orsi C, et al. ACR Appropriateness Criteria® breast pain. *J Am Coll Radiol* 2017;14:S25–S33.
108. Zarei F, Pishdad P, Hatami M, Zeinali-Rafsanjani B. Can breast ultrasound reduce patient’s level of anxiety and pain? *Ultrasound* 2017;25:92–97.