



Common neonatal syndromes

Mark H. Lipson*

Department of Genetics, Permanente Medical Group, Sacramento, CA, USA

KEYWORDS

Fluorescence in situ hybridisation (FISH);
Telomere;
Uniparental disomy;
Imprinting

Summary The process of diagnosis of genetic syndromes in the newborn period is carried out in the context of parental anxiety and the grief following an often-unexpected outcome after a long pregnancy. The nursery staffs invariably have a strong interest in giving the family proper information about prognosis. This article is intended to focus on an approach to the diagnosis of genetic syndromes and to discuss specific syndromes that may be seen with some frequency in the nursery.

© 2005 Elsevier Ltd. All rights reserved.

A baby has just been born. The exhausted but jubilant parents are finally able to see the result of the previous 9 months of morning sickness, weight gain and water retention. But instead of unmitigated excitement and happiness, there is fear, uncertainty and disbelief. The reaction of the nurses and doctors has indicated that there is a problem with the baby. What does it mean? Will the baby be OK? What can be done to correct the problem? It is in this context that syndrome identification takes place. It is a very difficult time for both the family and the medical staff. A rapid diagnosis and treatment plan are desired, but this is often not possible.

Although the initial evaluation can be performed by the pediatrician or neonatologist, referral to

a geneticist or genetics centre is essential at some point in the diagnostic process. A diagnosis is not the end of the process but merely the beginning. Genetic counseling is a process whereby a confirmed or possible genetic condition is reviewed with the family, and the etiology, natural history, prognosis, treatment possibilities, risk of recurrence, potential for prenatal diagnosis and the availability of pertinent reading materials and support groups are discussed at length. The emotional and psychological aspects of the situation are also explored.¹ This process usually takes place over the course of several meetings with the family.

This review covers a general approach to making a diagnosis in a newborn with anomalies, and describes some of the common syndromes one encounters in the nursery. Several textbooks are recommended for obtaining more information about these syndromes.^{2–4}

* Tel.: +1 916 614 4785; fax: +1 916 614 4985.
E-mail address: mark.lipson@kp.org

Multiple congenital anomalies

Taking a detailed pregnancy history is essential – it is the starting point of all evaluations of the newborn. A pedigree is also very important. A three-generation pedigree is usually obtained in 10–15 min and can be invaluable. Clues from the type and pattern of anomalies or abnormal pregnancies in family members can point to a certain type of inheritance pattern or chromosome problem. It is easier to identify this type of information from a pedigree than from a series of family history questions.

The physical examination focuses on describing the birth defects and minor anomalies/dysmorphic features. Determining which features are important in syndrome identification is challenging. Examining other family members or looking at family photos can be very helpful in determining whether a dysmorphic feature is a normal family variant or a unique finding that may be part of a syndrome.

Deciding on laboratory testing comes next. If there are birth defects or significant unexplained dysmorphic features, a chromosome study needs to be undertaken. A satisfactory study is one that has a minimum of about 550 bands. If a routine chromosome study is normal, additional studies may be considered necessary looking for submicroscopic abnormalities by a technique called fluorescence in situ hybridisation (FISH).⁵ This technique is based on the hybridisation of a piece of labeled DNA, a probe, to a complementary area on a chromosome. Specific probes are available for each chromosome. Submicroscopic deletions or rearrangements at the ends (telomeres) of the chromosome, performed as a telomeric FISH study, are a recognised cause of malformations.⁶

Obtaining plain X-rays are useful in more precisely evaluating anomalies of the extremities. Certain anomalies are associated with defects in other areas of the body and therefore require evaluation. Examples are heart defects with thumb anomalies (Holt–Oram syndrome) and renal defects and optic nerve coloboma (renal–coloboma syndrome).⁷ Cranial imaging for micro/macrocephaly and hypo/hypertelorism is also recommended.

Where laboratory studies are normal and the diagnosis is unclear, a review of the literature and syndrome textbooks can be useful. Online Mendelian Inheritance in Man (OMIM), an on-line continuously updated catalog of human genes and genetic disorders, is an extremely useful human genetic resource. It is available free of charge. Additionally, there are software dysmorphology databases that can be purchased.

Down syndrome

In the past, this was the most common syndrome identified in the newborn period, despite the availability of chorionic villus sampling and amniocentesis for advanced maternal age. However, with the advent of prenatal screening programs aimed at detecting Down syndrome in the second and more recently the first trimester, the incidence at birth of Down syndrome has decreased. Due to false-negative testing and a significant number of women choosing either not to have screening or not to have amniocentesis after a positive screen, or choosing to continue a pregnancy after amniocentesis makes a definitive diagnosis, Down syndrome continues to still be a condition commonly presenting in the newborn period.

The condition is usually not hard to identify (Fig. 1). However, if the newborn is premature, particularly less than 34 weeks' gestation, Down syndrome may be difficult or nearly impossible to suspect. The typical facial features of up-slanting palpebral fissures, flat facies and small ears (less than 3 cm in vertical length) are well known to clinicians. In addition, the gestalt of the facial expression when the child cries is particularly a useful finding. The hands also give important clues to the diagnosis. Fifth finger clinodactyly, usually bilateral, is very frequent. Simian lines are also common but are present in a significant percentage of the general population. Significant hypotonia may be the initial finding. The best-known characteristic associated birth defects seen

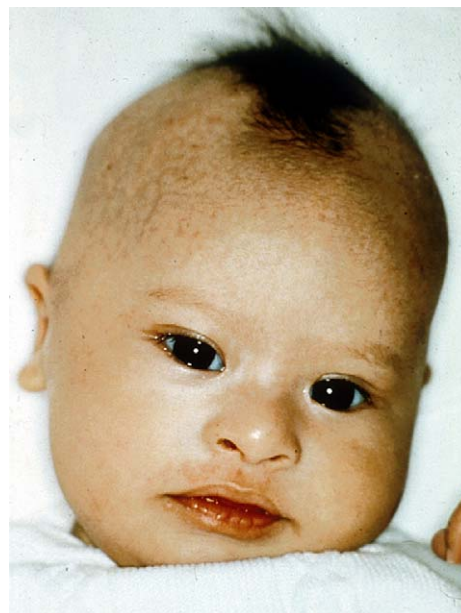

Figure 1 Up-slant to palpebral fissures and low nasal bridge in Down syndrome.

in Down syndrome are duodenal atresia and atrio-ventricular canal defects. Some form of congenital heart defect is by far the most common associated birth defect, with about 40% of patients being affected. Less well-known defects include Hirschsprung disease and congenital hypothyroidism. A prenatal finding of mild dilatation of the cerebral ventricular atria (10–11 mm) without overt hydrocephalus is not infrequent. Special growth charts for Down syndrome patients are available, and the American Academy of Pediatrics has published health supervision guidelines.

The confirmatory diagnosis for Down syndrome is a conventional chromosome study. Even in cases where the diagnosis is obvious, it is important to do the study. In about 95% of the cases (more with an older mother), the Down syndrome baby will have a standard non-dysjunction karyotype (47,+21). Doing chromosome studies on the parents in such cases are not necessary. The risk of recurrence in non-dysjunction Down syndrome is about 1% for younger women and is not increased above the age-related Down syndrome risk for women in their mid-30s and older.

Down syndrome will occasionally be due to a translocation. A family history may be the first clue if there is a history of other Down syndrome offspring in the extended family. The usual situation is a Robertsonian translocation involving a fusion chromosome 14 and 21 (46,t14/21), but other combinations are possible. Chromosome studies on the parents of a translocation Down syndrome baby are very important for proper genetic counseling. The risk of recurrence where one of the parents carries a balanced translocation ranges from less than 1% to as high as 10% based on the type of translocation and the sex of the carrier parent.⁸

A Down syndrome baby will occasionally be born with a 21/21 translocation (46,t21/21). The parents in such a situation usually have normal chromosomes, but rarely one of the parents will have 45 chromosomes and a balanced 21/21 translocation. This is an uncommon situation in which there will be a 100% risk for a child with Down syndrome. The two possibilities at conception are either Down syndrome or monosomy 21, which is typically not compatible with live birth.

Essentially, all babies with trisomy 21 will be mentally retarded, usually in the moderate range. Severe mental retardation is not expected. The chromosome study occasionally shows mosaicism. Parents often ask about this, and if mosaicism is present, they will ask whether the level of cognitive skills will be higher. This is a hard question to answer. If mosaicism is present, it will vary from

tissue to tissue. That is to say, although 30% of the cells in the blood may be normal and 70% may be trisomy 21, it cannot be predicted what the percentage mix will be in the heart, kidney or, most importantly, the brain. Given this uncertainty, it is best to not predict a much better prognosis based on mosaicism. Life expectancy, given access to appropriate medical and surgical interventions, is in the range of 50–60 or more years.

Trisomy 13 and 18

These chromosomal disorders are, like Down syndrome, associated with advanced maternal age. The incidence at birth has fallen over time as second-trimester ultrasound screening in pregnancy has become more routine and affected pregnancies terminated. Expanded alpha fetoprotein screening will detect many cases of trisomy 18 but does not identify trisomy 13. Continuation of pregnancy after confirmation of these trisomies is much rarer than with Down syndrome. Most fetuses with these trisomies do not survive to delivery. Multiple birth defects are common in both the conditions but are much more frequent in trisomy 13 (Figs. 2 and 3). Some babies with trisomy 18 have little in the way of anomalies but may be small for gestational age. The combination of growth retardation and polyhydramnios is especially suggestive of trisomy 18.

Both conditions have facial dysmorphism. The classical trisomy 13 baby will have microcephaly, iris coloboma, abnormally shaped ears and cleft lip

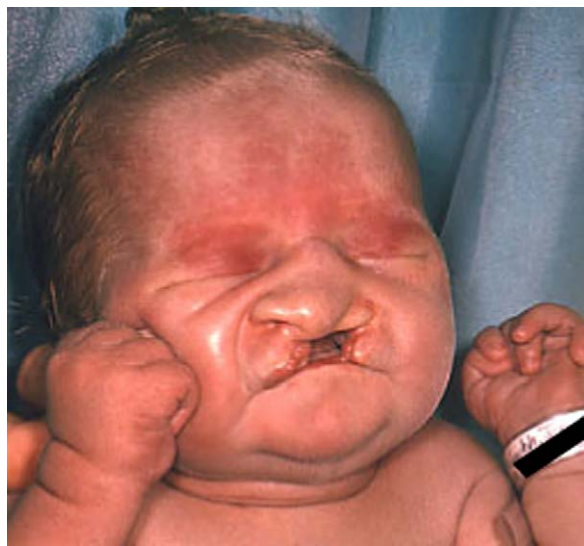

Figure 2 Cleft lip, overlapping fingers, abnormal position of the thumb and polydactyly in trisomy 13.

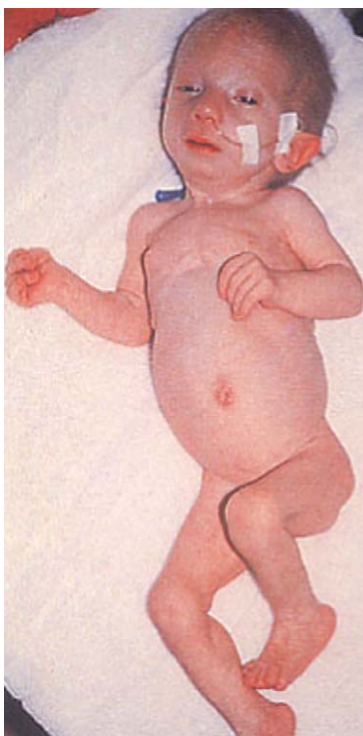

Figure 3 Growth retardation, microcephaly, short palpebral fissures, ptosis, micrognathia, short sternum, clenched hands and rocker-bottom feet in trisomy 18.

with or without cleft palate. The typical baby with trisomy 18 will have microcephaly, malformed ears, a prominent occiput and a small mouth and jaw. Other birth defects in trisomy 13 include heart defects, albeit not usually life-threatening ones, omphalocele, postaxial polydactyly, microphthalmia/anophthalmia, cutis aplasia, cryptorchidism and holoprosencephaly. Trisomy 18 can have many of the same anomalies, but eye and skin malformations are less common, whereas neural tube and limb reduction defects are more common. A very large number of other anomalies have been reported in association with these trisomies. The recurrence risk for non-dysjunction trisomy 13 and 18 is no more than 1%. Families have been described with anomalies suggesting trisomy 13 or trisomy 18 but with normal chromosomes – recurrences in subsequent pregnancies have suggested an autosomal recessive condition. The literature more strongly supports a mendelian phenocopy of trisomy 13.⁹

Profound mental retardation occurs in both the conditions. The mortality rate is equally high for both trisomies, most infants dying in a few months and perhaps 10% surviving to 1 year. Females live longer than males. As with Down syndrome, mosaicism occasionally occurs, but making meaningful predictions based on its presence is perilous.

Turner syndrome

The most common finding in Turner syndrome is a single X chromosome and a missing second sex chromosome (45,X0). The condition is interesting from a biological viewpoint. Its frequency at conception is high, but there is fierce natural selection against it. Approximately 1% of all conceptions have Turner syndrome. In studies of early spontaneous abortions, about 10% are 45,X0.¹⁰ In female fetuses spontaneously aborted in the mid second trimester due to cystic hygroma and generalised edema, most are 45,X0. Of every 100 embryos conceived with 45,X0, only one or two will be liveborn.

At birth, many if not most newborns with Turner syndrome will escape detection. Significant short stature, elbow cubitus valgus and a short fourth metacarpal are not present. Facially, prominent cupped ears can be a clue to the diagnosis. Webbed neck or edema of the hands and feet can be present (Fig. 4). Coarctation of the aorta in a female newborn should raise a suspicion of Turner syndrome. A renal anomaly, particularly horseshoe kidney, is characteristic but certainly not universal. Short stature is usually present by early childhood, and treatment with growth hormone is common.¹¹ Special growth charts for Turner syndrome are available, and the American Academy of Pediatrics has published health supervision guidelines.

The chromosome findings in Turner syndrome vary significantly. In only about half the cases is the karyotype 45,X0. Changes involving the structure of one of the X chromosomes are common, particularly isochromosome of the long arm of X (46,X,i(Xq)). Functionally, this leads to monosomy of the short arm of one of the X chromosomes. A myriad of other chromosome patterns constitute the rest of Turner syndrome cases. Mosaicism is common.^{12,13} Sometimes a Y chromosome is found in a mosaic pattern (45X/46XY). Thus, a careful search for a Y chromosome cell line is essential, since these patients are at increased risk for a malignant tumor at a young age.¹⁴

Noonan syndrome

There are some clinical similarities between this condition and Turner syndrome. In fact, the condition was initially called male Turner syndrome, despite the fact that Noonan syndrome occurs in both the sexes. Nonetheless, the two conditions are quite different. In the newborn period, the

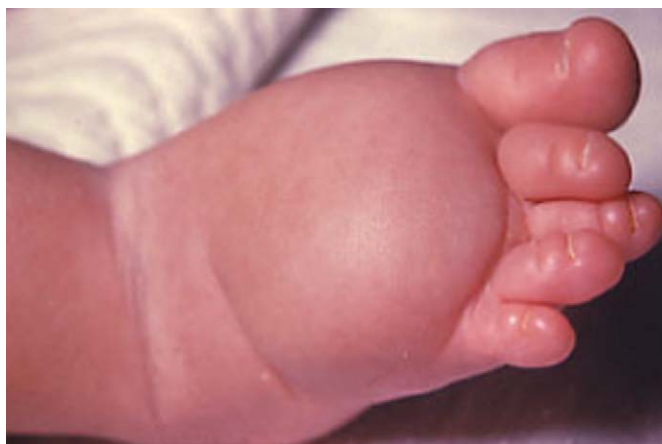

Figure 4 Edema of the foot in Turner syndrome.

facial features and presence of congenital heart defect are the findings that lead most often to the diagnosis. The classical lesion is pulmonary valve stenosis, but hypertrophic cardiomyopathy and a variety of other defects can also occur. Facially, the typical patient has low-set and mildly dysplastic ears, down-slanting palpebral fissures and ptosis. A short or webbed neck and pectus excavatum/carinatum are also typical. Non-life-threatening renal anomalies are seen, and disorders of lymphatic vessels are more common.¹⁵

Growth is usually slow, although normal adult height can occur. Growth hormone treatment has been reported.¹⁶ Cognitive function is usually normal and can be high, although there is an increased chance of needing special education. There is an increased risk of bleeding problems in older patients, most often related to a deficiency of clotting factors XI or XII.¹⁷

A chromosome study should be done and is expected to be normal. The gene for Noonan syndrome, called *PTPN11*, has been identified. DNA analysis is possible in cases where the diagnosis is in doubt, although a DNA mutation is not found in all clearly clinically affected patients.

In nearly all the cases, Noonan syndrome is an autosomal dominant disorder. Many cases are new mutations. If both parent and child are affected, the risk of recurrence to produce another affected child is 50%. Because the facial findings of Noonan syndrome become harder to identify as one ages, careful evaluation of the parents is necessary before concluding that a sporadic case has occurred. A few families have been reported with multiple affected siblings and unaffected consanguineous parents, suggesting the presence of a rare autosomal recessive form of Noonan syndrome.¹⁸ Some caution must therefore be observed in

counseling about a low parental recurrence risk in subsequent pregnancies when a child is born with apparently sporadic Noonan syndrome.

Profound hypotonia

The differential diagnosis of profound hypotonia is large. A detailed history is required to assess prenatal or delivery circumstances such as a teratogen (infection or medication) or perinatal asphyxia that could be the cause of the hypotonia. A family history can be useful in determining whether a condition is autosomal recessive (a similarly affected sibling) or X-linked (similarly affected males related through females). The differential diagnosis once a pregnancy/delivery-related problem has been deemed remote includes myopathies, central nervous system disorders and various genetic conditions. A precise diagnosis is paramount since the risk of recurrence varies from sporadic to 25%, and perhaps higher if mitochondrial DNA mutations are causative (see below). In the past, muscle biopsy was needed to assess many of these conditions. Many can now, however, be diagnosed with DNA or biochemical tests. Several illustrative conditions in the differential of hypotonia will be discussed.

Newborns with Prader–Willi syndrome are typically quite hypotonic and feed poorly. Males usually have undescended testicles. Small hands and feet, and almond-shaped eyes, are not useful diagnostic features in newborns. A specific area on the long arm of chromosome 15 is involved in the etiology of Prader–Willi syndrome. Blood DNA testing can very accurately diagnose Prader–Willi syndrome, with about 95% of the cases having a positive DNA test. Almost all cases are due to the

absence of the paternal copy of the Prader–Willi syndrome critical DNA region on chromosome 15. A chromosome study with FISH is necessary after a positive DNA test in order to determine whether the specific cause is a chromosome deletion. A deletion of the Prader–Willi syndrome critical DNA region is the most common cause of the condition. The second most common cause is inheritance of two copies of chromosome 15 from the mother and none from the father; this is called uniparental disomy. The concept of the biparental inheritance of certain genes being essential for normal development is called imprinting.¹⁹ The risk of recurrence for Prader–Willi syndrome is usually low.

Spinal muscular atrophy (SMA) presents in various ways depending on age and gross motor milestone acquisition. Type 1 SMA presents at birth or very soon after with profound hypotonia and is fatal within a year or two. Treatment is supportive. The diagnosis can be made in nearly all the cases with a blood DNA sample.^{20,21} Early diagnosis allows counseling of the parents about the shortened life expectancy, autosomal recessive inheritance and 25% recurrence risk. Prenatal diagnosis on DNA from chorionic villus sampling or amniocentesis is available.

Zellweger syndrome presents with profound hypotonia. Other findings such as facial features suggestive of Down syndrome, hepatomegaly and calcific stippling of the patella and epiphyses are also present. The condition is caused by the absence of peroxisomes, single-membrane organelles in the cell that contain many essential enzymes. An accumulation of very long-chain fatty acids in plasma due to a deficiency of peroxisomal enzymes is diagnostic. The condition is usually lethal within a few years and has an autosomal recessive inheritance. There is no useful treatment. The disorder is caused by mutations in a number of genes involved in the biogenesis of the peroxisomes. Prenatal diagnosis is available. Zellweger syndrome is the most severe of the numerous inborn errors related to peroxisome structure and function.^{22,23}

Mitochondrial myopathies refer to a group of conditions that affect the energy production in the cell. Despite the name, these disorders can be caused by mutations in either nuclear or mitochondrial DNA. The symptoms caused by mitochondrial myopathies are protean and can involve hypotonia, lactic acidosis, anemia, hearing loss, visual symptoms, gastrointestinal disorders, diabetes mellitus and other organ system dysfunctions. Although a muscle biopsy with histology and biochemical and DNA studies is often required to identify this group of disorders, blood DNA testing alone can

identify some. The prognosis varies, but a neonatal presentation portends a very guarded outlook. When an abnormality is found, there is unfortunately little in the way of useful treatment. Various vitamin and co-factor supplementations can be tried, but success is uncommon. It can be quite difficult to determine whether the condition is due to nuclear or mitochondrial DNA, but trying to do so is important because of the risk of recurrence. Autosomal recessive nuclear DNA mutations have a 25% recurrence risk, whereas some mitochondrial DNA mutations are sporadic with a very low recurrence risk. However, some mutations that cause newborn disease are inherited from the maternal mitochondrial genome. Since there are many mitochondria in each ovum, the risk of recurrence in this situation may be quite high. Women with mitochondrial DNA mutations often carry a lower load of mutated mitochondrial DNA that may not cause symptoms in them or may make the maternal symptoms occur at a later age. Some specific disorders can be diagnosed prenatally via chorionic villus sampling or amniocentesis, but accurate prenatal interpretations of clinical outcome can be difficult.²⁴ Mitochondrial DNA disorders are not considered to be paternally inherited since sperm are generally devoid of mitochondria.

Myotonic dystrophy is an autosomal dominant disorder. When seen in newborns, it typically causes respiratory distress, feeding difficulties and talipes in addition to hypotonia. The mother is nearly always affected, but she is commonly not aware of this. Most congenitally affected babies will be mentally retarded. Diagnosis can be made from a blood DNA test. There are two forms of myotonic dystrophy, with different causation genes. Type 1 is the classic form. Type 2²⁵ differs primarily from Type 1 in that the lower extremity muscle weakness is proximal rather than distal. Myotonic dystrophy is one of several disorders, including Huntington disease and fragile X syndrome, in which the mutation involves an increase in the number of specific groupings (triplet repeats) of nucleic acids.²⁶

There are primary muscle disorders that can present in the newborn period with hypotonia. Examples are myotubular (centronuclear) myopathy, nemaline rod myopathy and central core disease. Myotubular myopathy, an X-linked disorder, can usually be diagnosed with a blood DNA test. Other myopathies can sometimes be identified from a blood DNA test but more often will require a muscle biopsy.²⁷

Genetic causes of hypotonia in the newborn period can also be caused by urea cycle, amino acid and organic acid disorders. Symptoms are

typically not immediately present at birth but usually arise within hours or days.

VATER association

In the early descriptions of the condition, the findings were limited to V (vertebral anomalies), A (anal atresia), TE (tracheo-esophageal fistula) and R (radial dysplasia). Soon after, the V and R came to include vascular and renal anomalies. Later, the acronym VACTERL syndrome was used, in which the C and the L represented cardiac defects and upper limb anomalies other than radial or thumb dysplasia. Other findings can include growth failure and single umbilical artery. Cognitive skills are usually normal. In questionable cases, X-rays should be carried out, looking for vertebral defects and subtle defects of the radial side of the hand and forearm. Chromosomal disorders and mendelian conditions such as Holt–Oram and Townes–Brocks syndromes need to be considered – the risk of recurrence of VATER syndrome is low.

One special caveat: if hydrocephalus is present in a baby whose other findings suggest VATER syndrome, a mendelian syndrome is likely. Families with VATER syndrome and hydrocephalus have been described demonstrating both X-linked and autosomal recessive inheritance.^{28,29}

Goldenhar syndrome

Several additional names are used in the literature to describe conditions with similar findings: hemifacial microsomia, oculoauriculovertebral syndrome and facioauriculovertebral syndrome. There is no consensus on whether all these names refer to the same condition and on what findings distinguish one from another.

The group of disorders is not felt to have a mendelian inheritance basis, although a few families have been described with suspected autosomal dominant inheritance. Core findings include hypoplasia of the bony structures of one side of the face, benign tumors on the external surface of the eye (epibulbar dermoids) and malformed ears (Fig. 5). Many other findings are described, such as oral clefts, heart defects, renal anomalies, vertebral defects and brain malformations. Cognitive function is usually normal unless there is a structurally abnormal brain. The presence of ear malformations and epibulbar dermoids distinguishes this condition from VATER syndrome. Chromosome disorders need to be excluded.

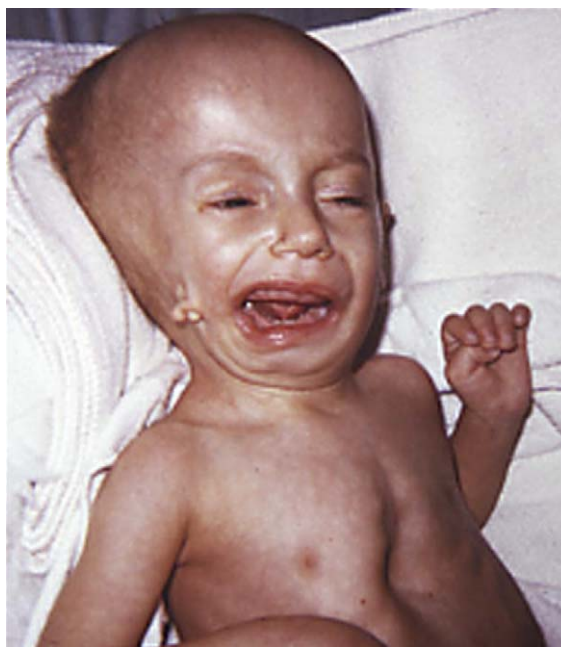

Figure 5 Right-sided microtia and macrostomia in Goldenhar syndrome.

DiGeorge and velocardiofacial syndromes

There is some clinical and etiological overlap of these syndromes, with DiGeorge syndrome typically presenting in the newborn period and velocardiofacial syndrome (VCF) diagnosed later in life, although a neonatal presentation is not rare. Aberrant embryonic development of the third and fourth pharyngeal pouches explains many of the features of DiGeorge syndrome, such as varying degrees of maldevelopment of the thymus, sometimes with resultant cellular immune deficiency, maldevelopment of the parathyroids leading to hypocalcemia and often seizures, and heart defects, particularly conotruncal defects, tetralogy of Fallot and interrupted aortic arch. Mild facial dysmorphic features and mild mental retardation are common. Some cases of DiGeorge syndrome are caused by a small deletion of a specific area on the long arm of chromosome 22 (del22q11.2). This deletion is often not seen with a standard banded karyotype but is readily identified with FISH.

The features of VCF include cleft palate without cleft lip, heart defects such as tetralogy of Fallot and ventricular septal defects, slender hands and learning disabilities. Facial, a squared-off prominent nose, small chin and slightly small head are common. The facial characteristics may not, however, be particularly striking. The heart and cleft

palate may lead to the diagnosis being made in the newborn period. Late-onset hypocalcemia and seizures sometimes occur in this syndrome – another sign of the overlap with DiGeorge syndrome. Microdeletion of 22q11.2 is found in nearly all clearly diagnosed cases.

Deletion of 22q11.2 can also be found in individuals who have what appears to be isolated congenital heart defects, in particular truncus arteriosus, tetralogy of Fallot and pulmonary valve atresia.³⁰ If a deletion is found, parental studies are indicated since the deletion is inherited a small percentage of the time. If a parent also has the deletion, the risk of recurrence is 50%.

CHARGE association

Initially described as choanal atresia associated with other anomalies, the acronym CHARGE association was coined in 1981 to stand for C (coloboma), H (heart disease), A (atresia of the choanae), R (retarded growth and development and/or CNS anomalies), G (genital abnormalities and/or hypogonadism) and E (ear anomalies and/or deafness). At least four of these major findings should be present to confirm the diagnosis.³¹ Other features can include oral clefts and facial palsy. Findings that can cause confusion with VATER syndrome include tracheo-esophageal fistula and renal anomalies, although the face is usually normal in the former condition. Cardiac and ear anomalies may cause confusion with Goldenhar syndrome. The findings are usually specific enough to make a clear clinical diagnosis. Although a few cases show 22q deletion by FISH, most have no recognisable genetic etiology. The risk of recurrence is usually low.

Achondroplasia

This is the most common type of short limb skeletal dysplasia. It can be difficult to make the diagnosis in the newborn period. Most of the time, there will be no clue prenatally. If a mid second-trimester fetal survey ultrasound has been carried out, it is almost always normal. The shortening of the proximal long bones does not usually fall below the 3rd centile until the start of the third trimester. The fetal chest measurement remains in the normal range, and the length is not significantly short at birth. The typical frontal bossing and scooped-out nasal bridge are not striking in newborns. There are shortened long bones,

particularly the proximal long bones, leading to the condition being classified as one of the rhizomelic skeletal dysplasias (Fig. 6). There are many radiographic features of the condition. However, there is one finding, albeit not pathognomonic, that is easily remembered and is seen in all newborns with achondroplasia – absence of widening of the interpedicular distances of the lumbar vertebrae. There is normally an increase in the interpedicular distance from L1 to L4. In achondroplasia, this measurement either stays the same or decreases. Newborns with achondroplasia are healthy at birth. Because of issues related to a small foramen magnum and a narrowed spinal cord, these patients should be followed up by physicians with expertise in this condition. Special growth charts for achondroplasia patients are available, and the American Academy of Pediatrics has published health supervision guidelines.

All the cases of achondroplasia are caused by a mutation in a dominant gene that codes for fibroblast growth factor receptor-3.³² Nearly all affected people, regardless of ethnic group, have an identical mutation in the gene. Interestingly, mutations in other areas of this gene cause a milder skeletal dysplasia (hypochondroplasia), a lethal skeletal dysplasia (thanatophoric dysplasia) and a number of syndromes associated with craniosynostosis.³³ A new mutation in the gene is the cause

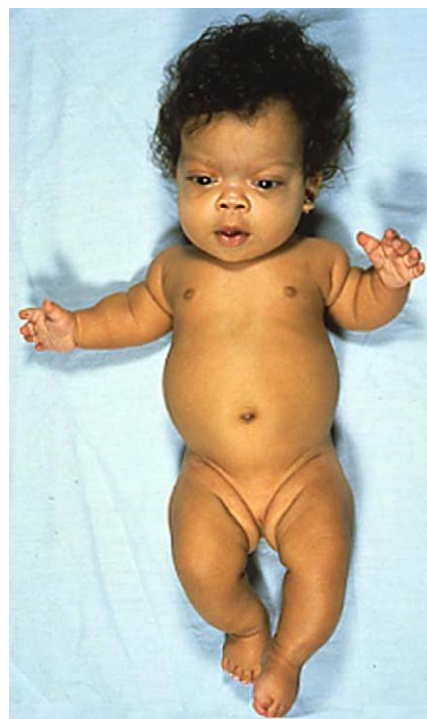


Figure 6 Relative macrocephaly, flat nasal bridge and proximal limb shortening in achondroplasia.

of achondroplasia in about 90% of the cases. The risk of recurrence is 50% if a parent has achondroplasia but quite low if the parents are of normal stature.

Osteogenesis imperfecta

This condition, a disorder of collagen metabolism, is generally classified into four main types.³⁴ Types I and IV osteogenesis imperfecta usually do not present in newborns. Type II osteogenesis imperfecta is the most severe form and is generally lethal at or soon after birth (Figs. 7 and 8). If prenatal ultrasound in the mid second trimester is performed, findings of short extremities, undermineralisation of the bones and fractures will be found. The sclerae are typically blue at birth. Type III osteogenesis imperfecta will present with prenatal fractures and growth deficiency, usually milder than seen in type II osteogenesis imperfecta. Many fractures occur after birth in type III osteogenesis imperfecta, resulting in progressive deformity of the long bones and spine. Severe short stature and spinal deformity are the result, although cognitive function is normal. Varying degrees of deafness and dentinogenesis imperfecta are common postnatal findings.

Although occasional exceptions occur, osteogenesis imperfecta is generally caused by dominant

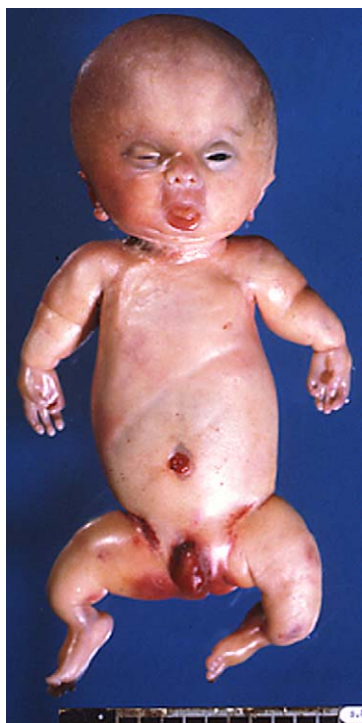

Figure 7 Short limb dwarfism in type II osteogenesis imperfecta.

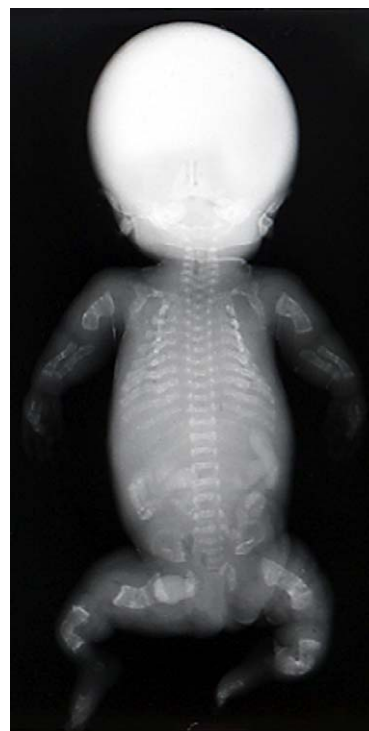

Figure 8 Short, broad long bones and multiple fractures in type II osteogenesis imperfecta.

mutations encoding type I collagen.³⁵ Osteogenesis imperfecta can usually be confidently diagnosed on the basis of the nature of the type I collagen abnormality seen in cultured skin fibroblasts. The more severe types of osteogenesis imperfecta are characterised by qualitative defects of type I collagen. Blood samples for DNA studies of the type I collagen gene are becoming more common.

It should, however, be remembered that the diagnosis of type II osteogenesis imperfecta by a radiologist skilled in the identification of skeletal dysplasias is highly accurate and can eliminate the expense of performing tests from skin biopsy and blood sampling.

Recurrence risk counseling is problematic. Although babies with type II osteogenesis imperfecta typically represent new mutations, there have been reports of recurrences due to parental germ cell mosaicism.³⁶ In an apparently isolated case of type II osteogenesis imperfecta, the risk of recurrence is estimated at 6% because of this possibility.

Individuals with type III osteogenesis imperfecta can reproduce and give each offspring a 50% risk of inheriting the condition. Prenatal testing is possible. Treatment with biphosphonates has been used in surviving patients with more severe manifestations of osteogenesis imperfecta. Long-term outcomes are, however, not yet clear.^{37,38}

Syndrome identification in the nursery takes place in a setting of high emotion and anxiety. If the diagnosis of a genetic condition or malformation syndrome is made or considered, the involvement of a geneticist is essential so that proper genetic counseling can occur. This process is the best way to guide the family along the difficult road leading from what was expected to what is now likely to be.

Practice points

- A three-generation pedigree is superior to asking a series of questions about family history
- If a standard chromosome study is normal and multiple birth defects are present, consider ordering a telomeric FISH study
- Chromosome studies are not needed on the parents of a Down syndrome baby if the baby's chromosome study shows non-dysjunction
- An adequate search for Y chromosomal material in a baby with Turner syndrome is important because of the added risk for gonadal tumors when Y chromosomal material is present
- Always start with blood testing rather than a muscle biopsy in the work-up of a baby with profound hypotonia
- In a baby with congenital myotonic dystrophy, the mother is presumed to be affected until her DNA test is found to be normal
- FISH 22q11.2 deletion is found in nearly all the patients with VCF, some patients with DiGeorge syndrome and a few patients with CHARGE syndrome
- Absence of widening of the lumbar interpedicular distances is seen in all the babies with achondroplasia
- Keep in mind the possibility of parental mosaicism when dealing with cases of lethal osteogenesis imperfecta

Research directions

Research is needed to determine clinical indications for studying telomeric probes when standard chromosome study is normal

References

1. Bernhardt BA, Biesecker BB, Mastromarino CL. Goals, benefits, and outcomes of genetic counseling: client and genetic counselor assessment. *Am J Med Genet* 2000;**94**:189–97.
2. Jones KL. *Smith's recognizable patterns of human malformation*. Philadelphia: WB Saunders; 1997.
3. Gorlin RJ, Cohen MM, Hennekam RCM. *Syndromes of the head and neck*. New York: Oxford University Press; 2001.
4. Cassidy SB, Allanson JE. *Management of genetic syndromes*. New York: Wiley-Liss; 2001.
5. Jalal SM, Law ME. Utility of multicolor fluorescent in situ hybridization in clinical cytogenetics. *Genet Med* 1999;**1**:181–6.
6. De Vries BB, Winter R, Schinzel A, van Ravenswaaij-Arts C. Telomeres: a diagnosis at the end of the chromosomes. *J Med Genet* 2003;**40**:385–98.
7. Ford B, Rupps R, Lirenman D, van Allen M, Farquharsm D, Lyons C, et al. Renal-coloboma syndrome: prenatal detection and clinical spectrum in a large family. *Am J Med Genet* 2001;**99**:137–41.
8. Gardner RJM, Sutherland GR. *Chromosome abnormalities and genetic counseling*. Oxford: Oxford University Press; 2004. p. 132–37.
9. Amor DJ, Woods CG. Pseudotrismy 13 syndrome in sibs. *Clin Dysmorphol* 2000;**9**:115–8.
10. Fritz B, Hallermann C, Olert J, Fuchs B, Bruns M, Aslan M, et al. Cytogenetic analyses of culture failures by comparative genomic hybridisation (CGH) – re-evaluation of chromosome aberration rates in early spontaneous abortions. *Eur J Hum Genet* 2001;**9**:539–47.
11. Sybert VP, McCauley E. Turner's syndrome. *N Engl J Med* 2004;**351**:1227–38.
12. Leppig KA, Disteche CM. Ring X and other structural X chromosome abnormalities: X inactivation and phenotype. *Semin Reprod Med* 2001;**19**:147–57.
13. Fernandez-Garcia R, Garcia-Doval S, Costoya S, Pasaro E. Analysis of sex chromosome aneuploidy in 41 patients with Turner syndrome: a study of 'hidden' mosaicism. *Clin Genet* 2000;**58**:201–8.
14. Troche V, Hernandez E. Neoplasia arising in dysgenetic gonads. *Obstet Gynecol Surv* 1986;**41**:74–9.
15. Chakraborty A. Noonan syndrome: a brief overview. *Hosp Med* 2002;**63**:743–5.
16. Kelnar CJ. Growth hormone therapy in Noonan syndrome. *Horm Res* 2000;**53**(Suppl. 1):77–81.
17. Witt DR, McGillivray BC, Allanson JE, Hughes H, Hathaway W, Zipursky, et al. Bleeding diathesis in Noonan syndrome: a common association. *Am J Med Genet* 1988;**31**:305–17.
18. van Der Burgt I, Brunner H. Genetic heterogeneity in Noonan syndrome: evidence for an autosomal recessive form. *Am J Med Genet* 2000;**94**:46–51.
19. Lalande M. Parental imprinting and human disease. *Annu Rev Genet* 1996;**30**:173–95.
20. Cifuentes-Diaz C, Frugier T, Melki J. Spinal muscular atrophy. *Semin Pediatr Neurol* 2002;**9**:145–50.
21. Ogino S, Wilson RB. Genetic testing and risk assessment for spinal muscular atrophy (SMA). *Hum Genet* 2002;**111**:477–500.
22. Brosius U, Gartner J. Cellular and molecular aspects of Zellweger syndrome and other peroxisome biogenesis disorders. *Cell Mol Life Sci* 2002;**59**:1058–69.
23. Moser H, Moser A. Very long-chain fatty acids in diagnosis, pathogenesis, and therapy of peroxisomal disorders. *Lipids* 1996;**31**(Suppl):S141–4.

24. Vu TH, Hirano M, DiMauro S. Mitochondrial diseases. *Neurol Clin* 2002;**20**:809–39. vii–viii.
25. Day JW, Ricker K, Jacobsen JF, Rasmussen L, Dick K, Kress W, et al. Myotonic dystrophy 2: molecular, diagnostic and clinical spectrum. *Neurology* 2003;**60**:657–64.
26. Gusella JF, MacDonald ME. Trinucleotide instability: a repeating theme in inherited disorders. *Annu Rev Med* 1996;**47**:201–9.
27. Goebel HH. Congenital myopathies at their molecular dawning. *Muscle Nerve* 2003;**27**:527–48.
28. Sujansky E, Leonard B. VACTERL association with hydrocephalus – a new recessive syndrome? *Am J Hum Genet* 1983;**35**:119A.
29. Iafolla AK, McConkie-Rosell A, Chen YT. VATER and hydrocephalus: distinct syndrome? *Am J Med Genet* 1991;**38**:46–51.
30. Emanuel BS, McDonald-McGinn D, Saitte SC, Zackai E. The 22q11.2 deletion syndrome. *Adv Pediatr* 2001;**48**:39–73.
31. Tellier AL, Cormier-Daire V, Abadie V, Amiel J, Sigaudy S, Bonnet D, et al. CHARGE syndrome: report of 47 cases and review. *Am J Med Genet* 1998;**76**:402–9.
32. Rousseau F, Bonaventure J, Legeai-Mallet L, Pelet A, Rozet J, Maroteaux P, et al. Mutations of the fibroblast growth factor receptor-3 gene in achondroplasia. *Horm Res* 1996;**45**:108–10.
33. Vajo Z, Francomano CA, Wilkin DJ. The molecular and genetic basis of fibroblast growth factor receptor 3 disorders: the achondroplasia family of skeletal dysplasias, Muenke craniosynostosis, and Crouzon syndrome with acanthosis nigricans. *Endocr Rev* 2000;**21**:23–39.
34. Sillence DO. Osteogenesis imperfecta nosology and genetics. *Ann N Y Acad Sci* 1988;**543**:1–15.
35. Byers PH, Steiner RD. Osteogenesis imperfecta. *Annu Rev Med* 1992;**43**:269–82.
36. Cohn DH, Starman BJ, Blumberg B, Byers PH. Recurrence of lethal osteogenesis imperfecta due to parental mosaicism for a dominant mutation in a human type I collagen gene (COL1A1). *Am J Hum Genet* 1990;**46**:591–601.
37. Whyte MP, Wenkert D, Clements KL, McAlister WH, Mumm S. Biphosphonate-induced osteopetrosis. *N Engl J Med* 2003;**349**:457–63.
38. Rauch F, Glorieux FH. Osteogenesis imperfecta. *Lancet* 2004;**363**:1377–85.

Available online at www.sciencedirect.com

