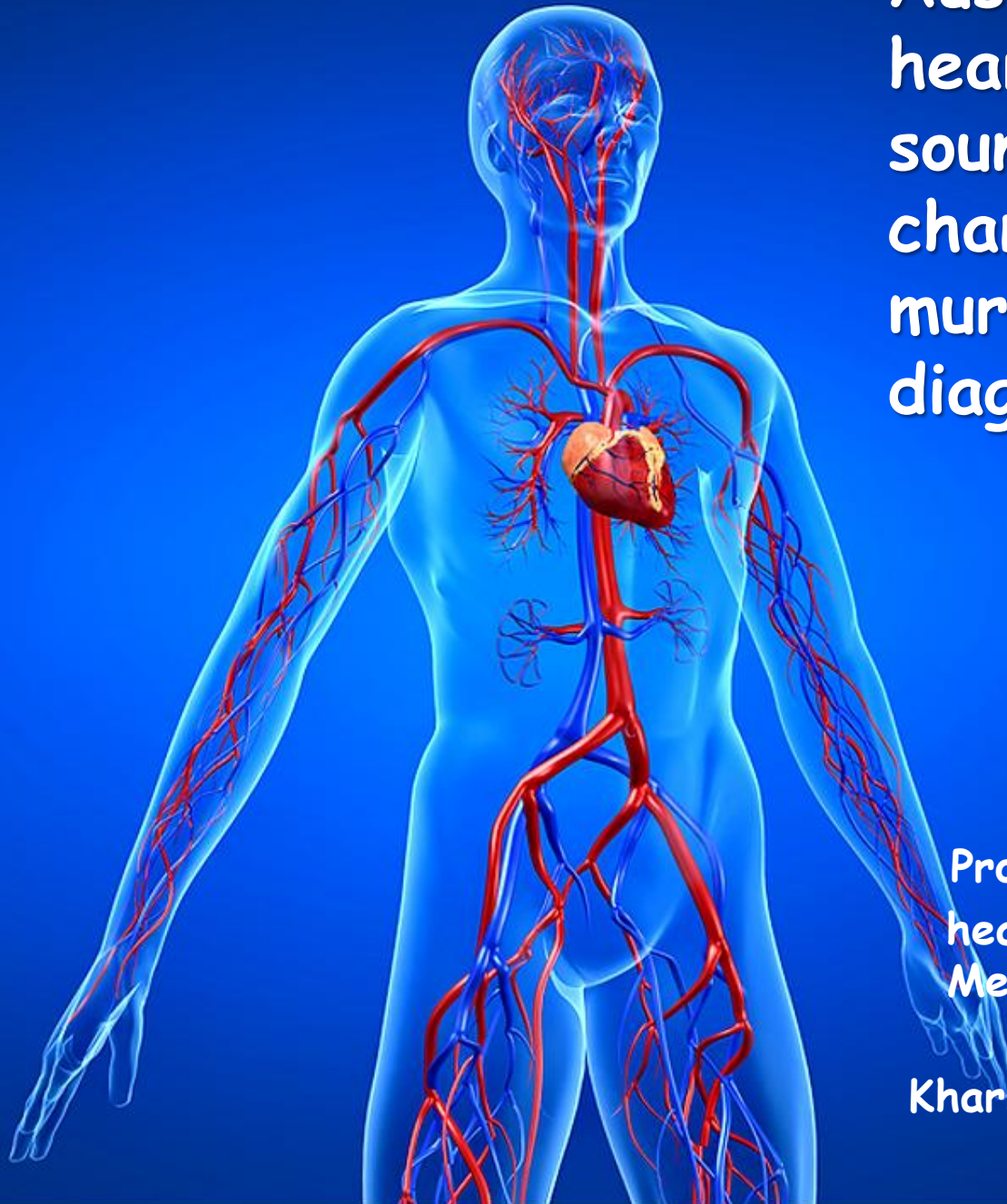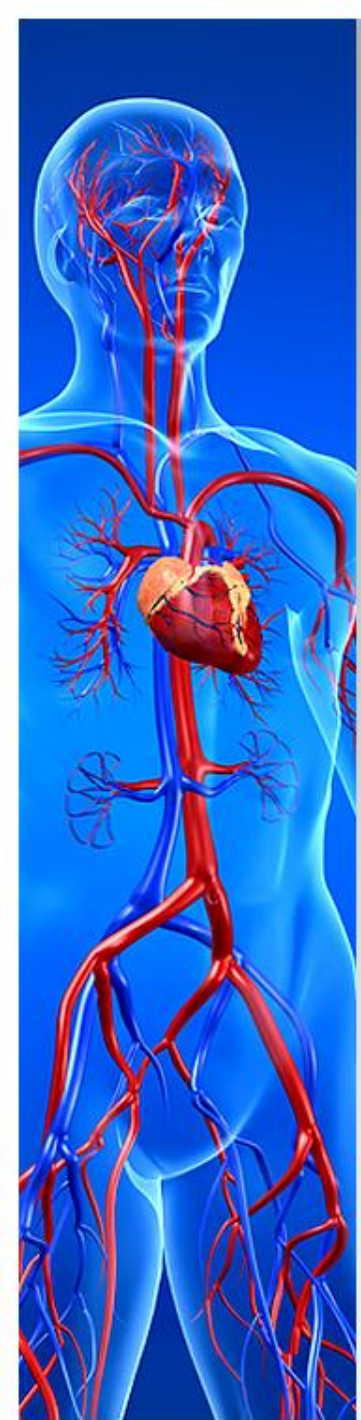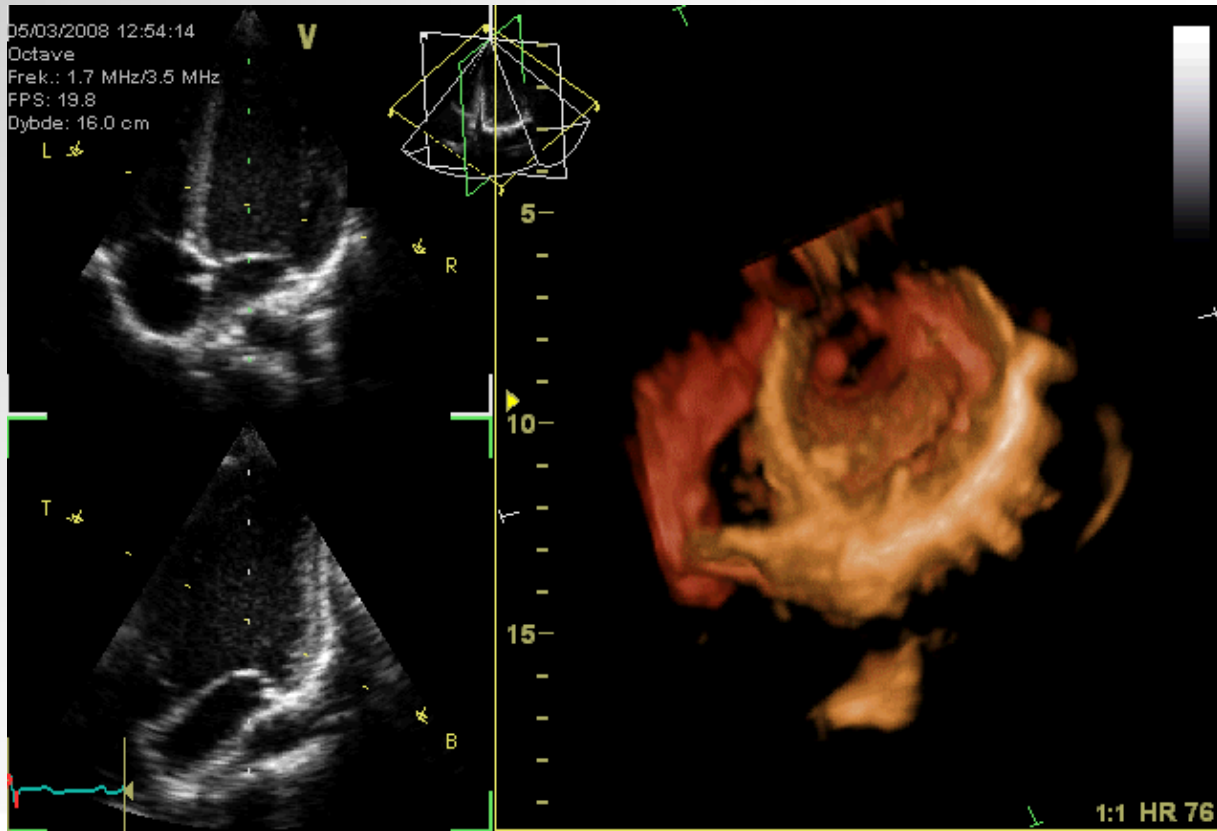


# Auscultation of the heart: normal heart sounds and their changes, heart murmurs and their diagnostic significance

Professor T.V. ASHCHEULOVA  
head of Propedeutics to Internal  
Medicine N1, Basis of Bioethics  
and Biosafety  
Kharkiv National Medical University

# Auscultation of the heart

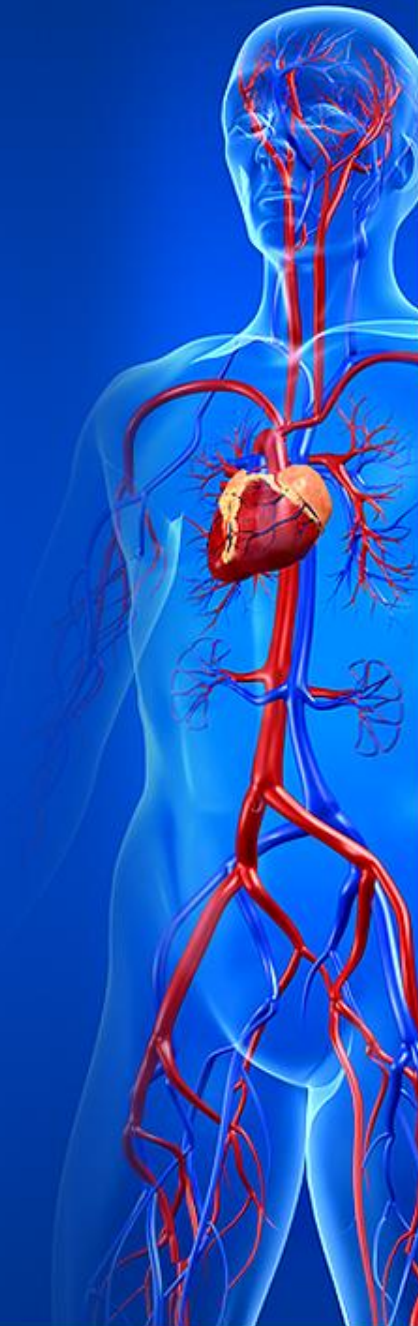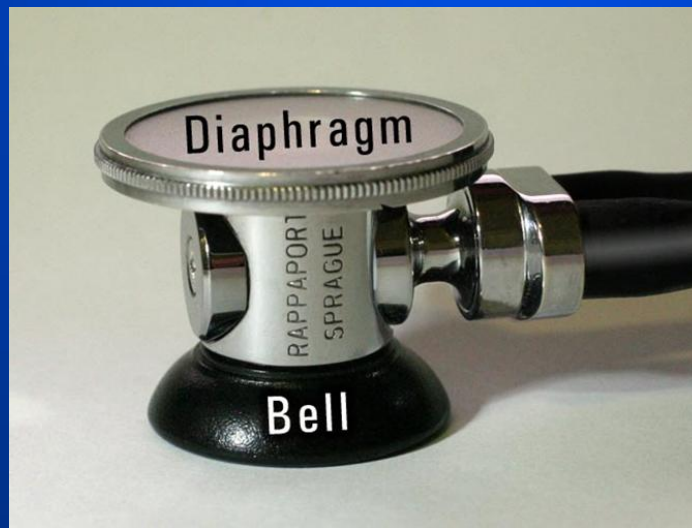- Auscultation of the heart - is objective method based on listening a noise within the heart during cardiac cycle.



# Auscultation of the heart

## Technique

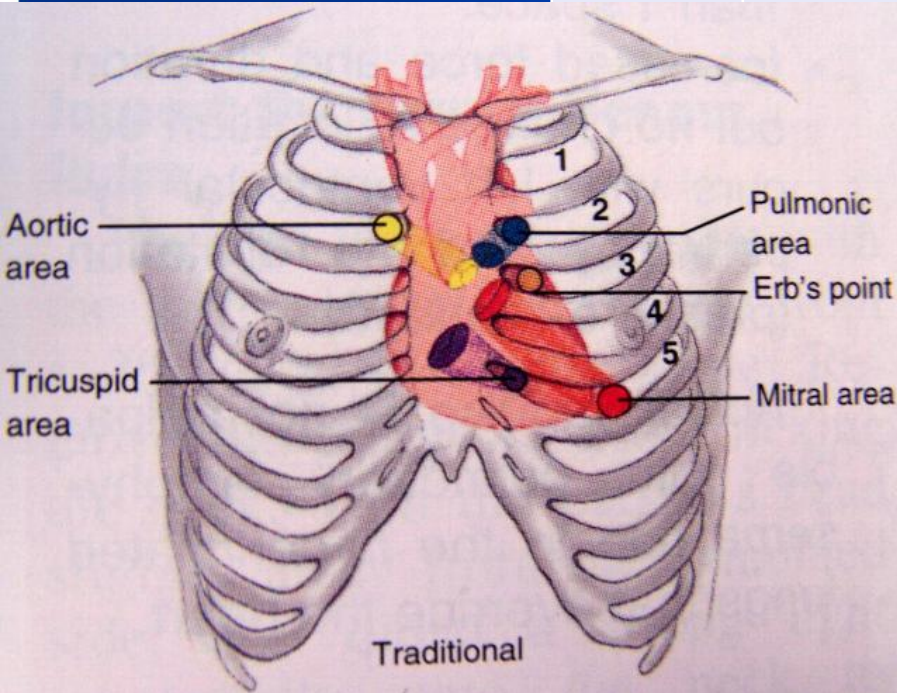
- To obtain the most information from cardiac auscultation and to assess correctly the findings, it is necessary to know the sites of valves projection on the chest wall and listening points of the heart.



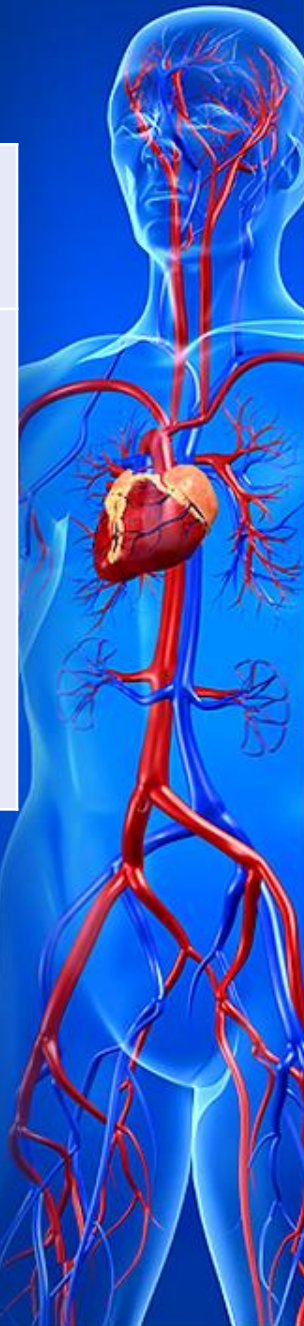# Auscultation of the heart

## Projection of the heart valves on the chest wall

Valve	Mitral	Aortic	Pulmonary	Tricuspid
Site of projection	To the left of the sternum at the level of the 3 <sup>rd</sup> costosternal articulation	In the middle of the sternum at the level of the 3 <sup>rd</sup> costosternal articulation	In the 2 <sup>nd</sup> intercostal space 1-1.5 cm to the left of the sternum	On the sternum midway between 3 <sup>rd</sup> left and 5 <sup>th</sup> right costosternal articulation



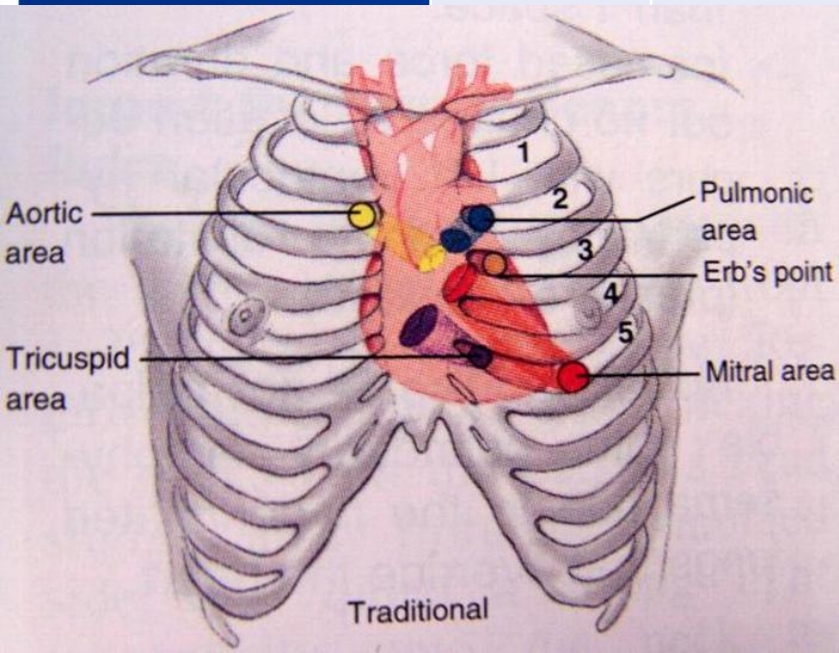
Since the sites of the valves projection on the chest are very close to one another, it is difficult to assess which valve is affected if listen them in the points of their actual projection.



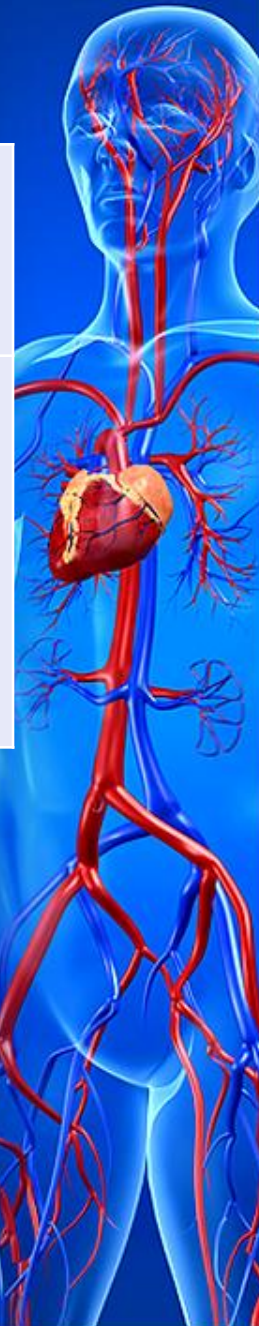# Auscultation of the heart

## Standard listening points of the heart

Valve	Mitral	Aortic	Pulmonary	Tricuspid
Listening point	Heart apex	2 <sup>nd</sup> intercostal space to the right of the sternum	2 <sup>nd</sup> intercostal space to the left of the sternum	Base of the xiphoid process



Therefore the heart sounds are auscultated in the certain listening points where sounds of each valve can be better heard

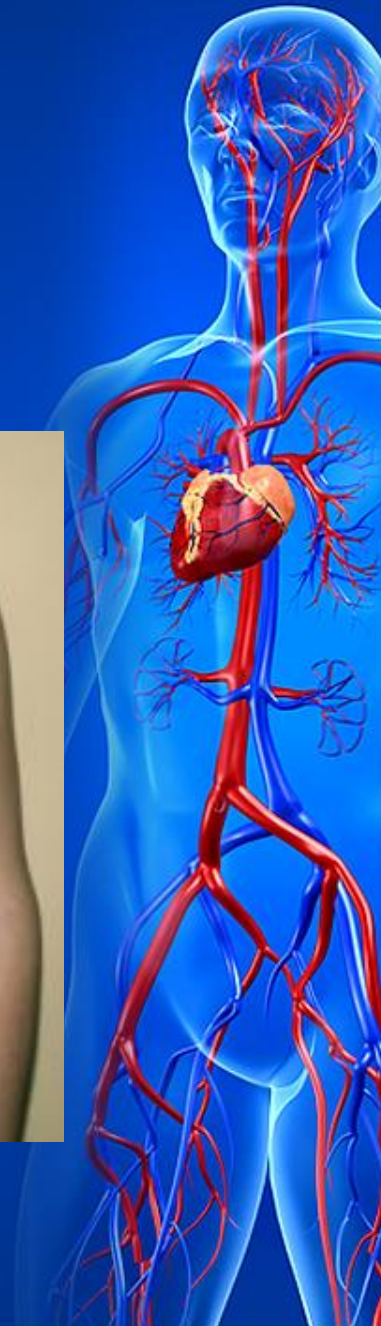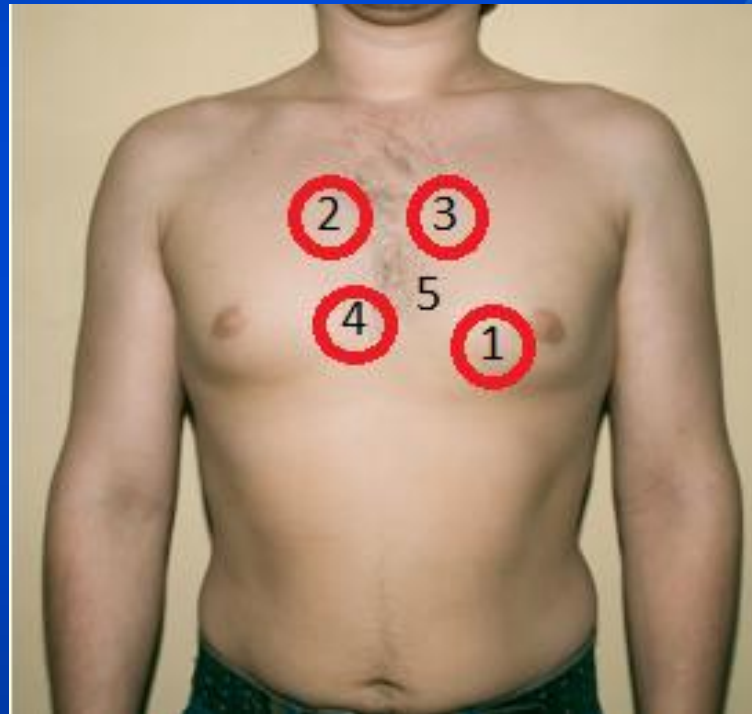


# Auscultation of the heart

## *Technique*

Auscultation should be performed in the order of decreasing frequency of valves affection:


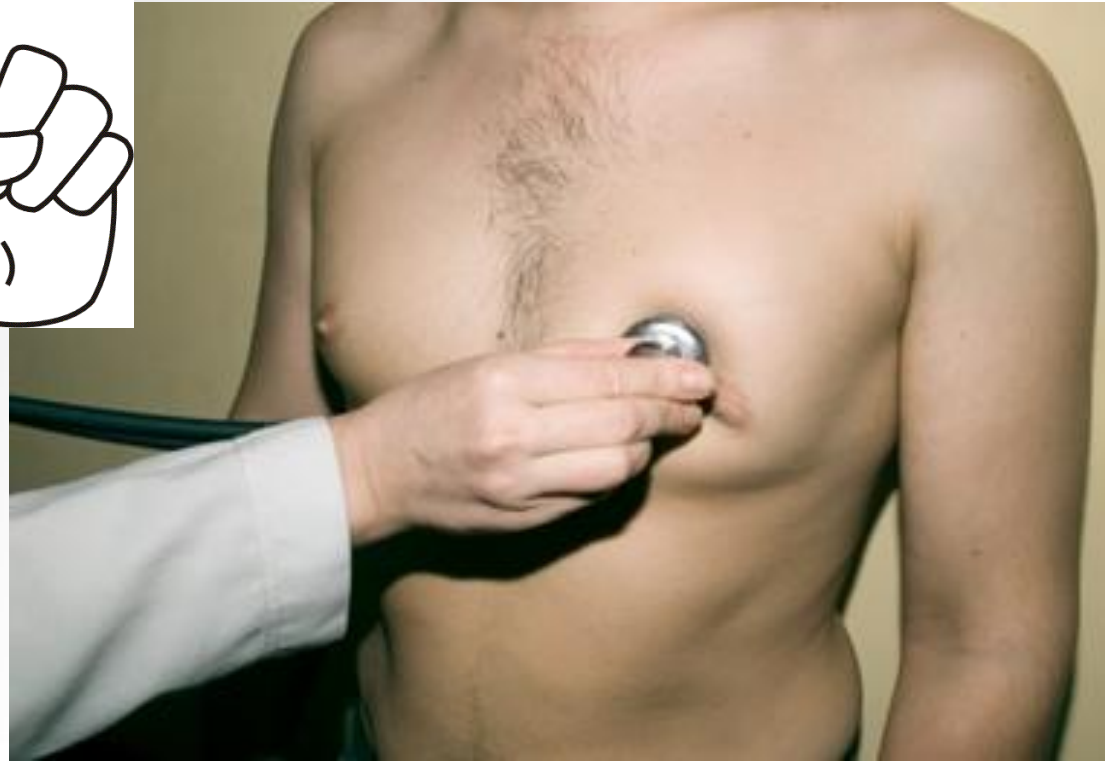- 1 - mitral valve,
- 2 - aortic valve,
- 3 - pulmonary valve,
- 4 - tricuspid valve.
- 5- Botkin-Erb's point (additional for aortic valve)



# Auscultation of the heart

## Mitral valve

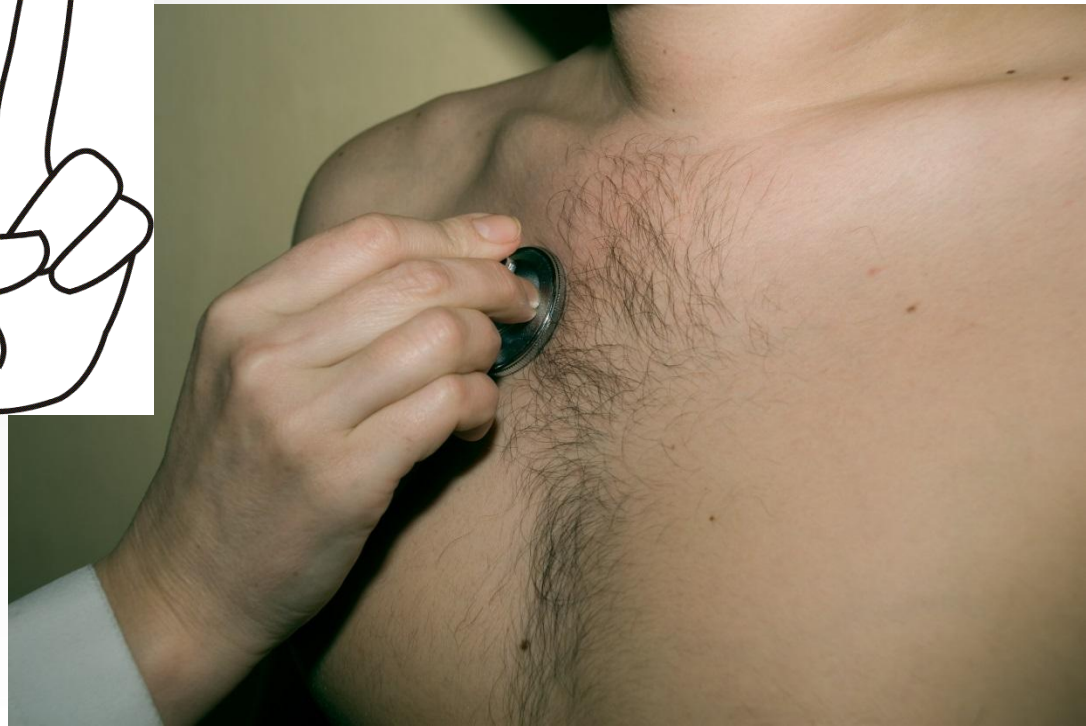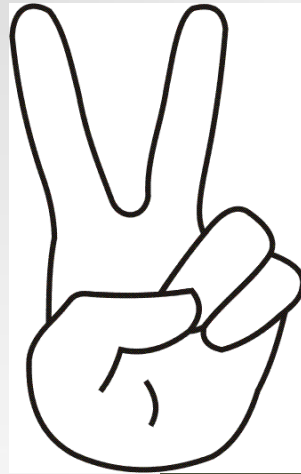
- 1. Standard listening points for mitral valve is heart apex



# Auscultation of the heart

## Aortic Valve

- 2. Standard listening points for aortic valve is 2<sup>nd</sup> interspace to the right of the sternum

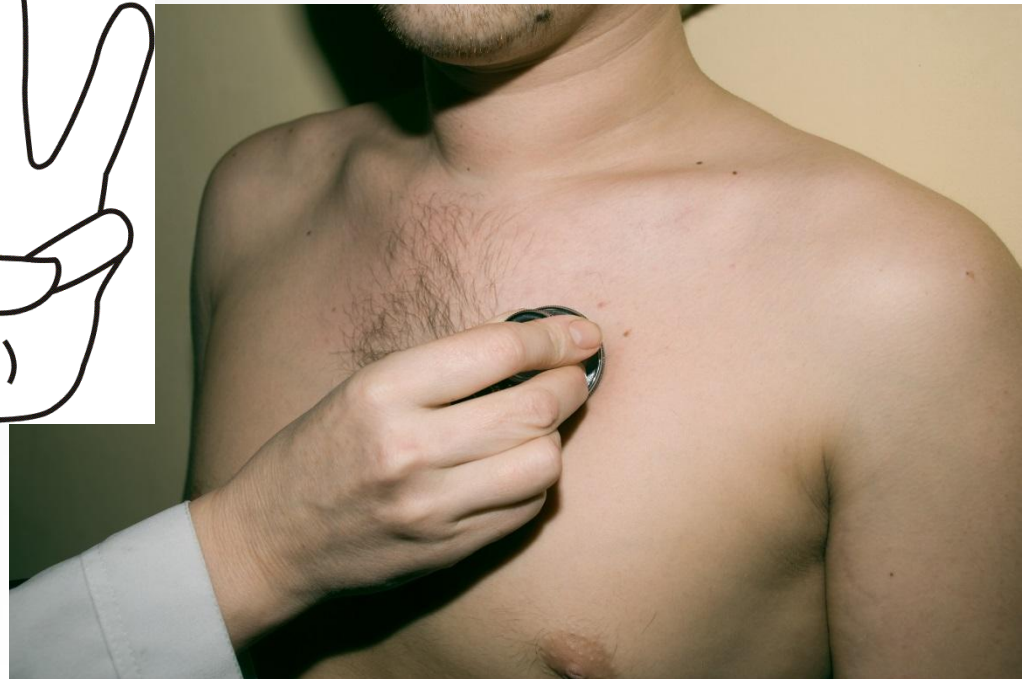




# Auscultation of the heart

## Pulmonary artery valve

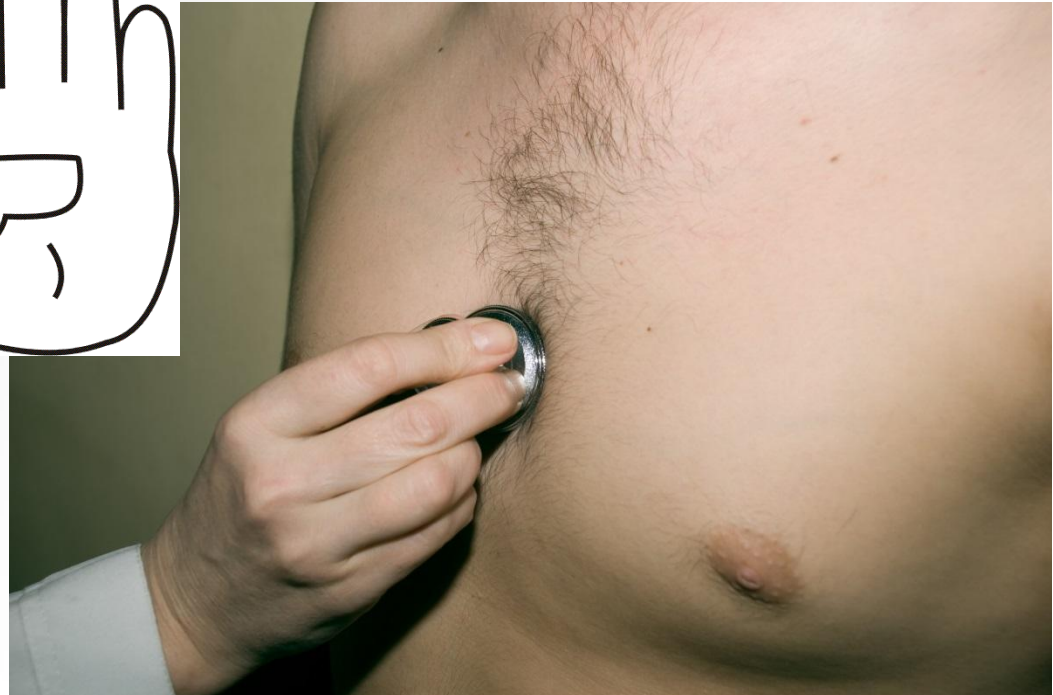- 3. Standard listening points for pulmonary artery valve is 2<sup>nd</sup> interspace to the left of the sternum



# Auscultation of the heart

## Tricuspid valve


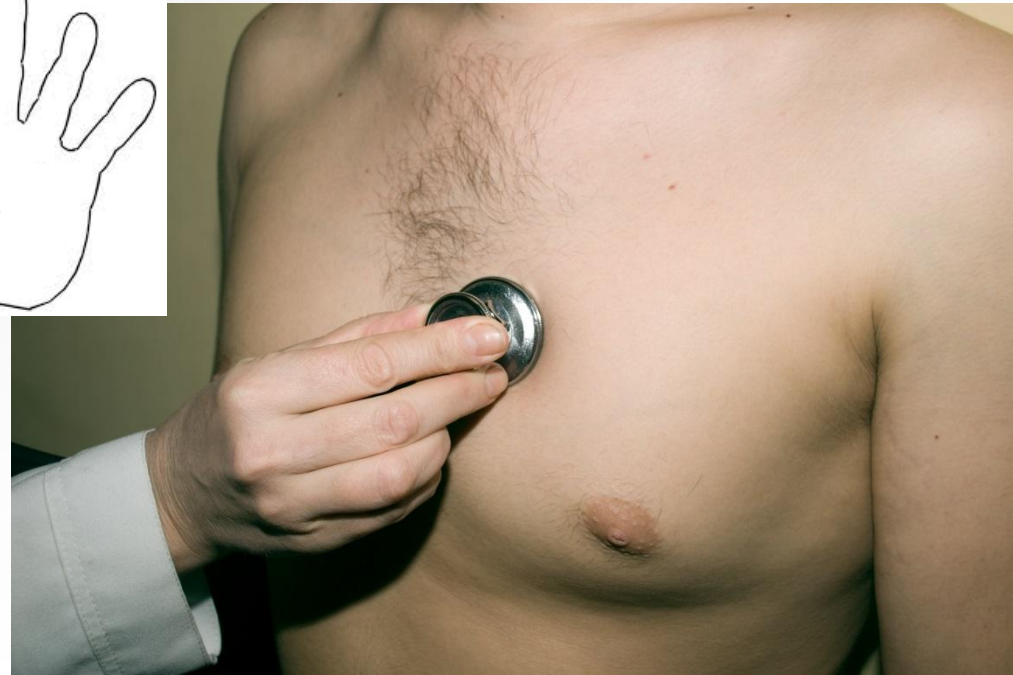- 4. Standard listening points for tricuspid is base of the xiphoid process



# Auscultation of the heart

## Botkin-Erb's point

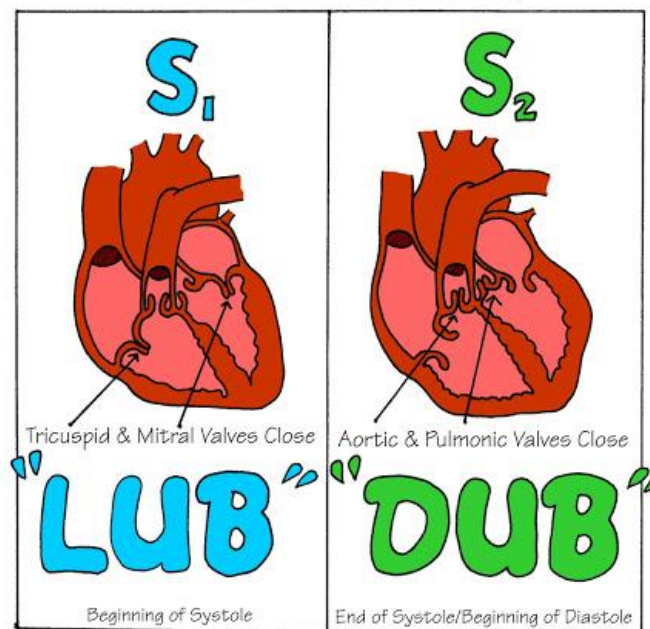
The fifth listening point to the left of the sternum at the 3<sup>rd</sup> and 4<sup>th</sup> costosternal articulation- so-called Botkin-Erb's point, was proposed to assess aortic valve sound.



# Normal heart sound

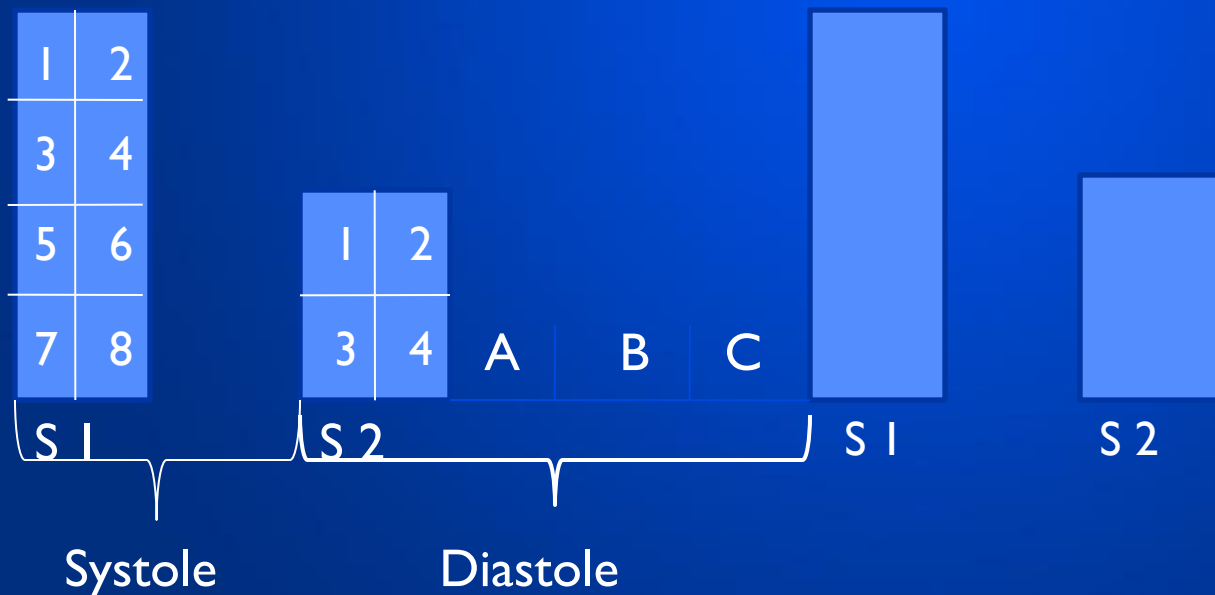
- The noise produced by a working heart is called **heart sounds**.
- In auscultation two sounds can well heard in healthy subjects: the first sound (**S<sub>1</sub>**), which is produced during systole, and the second sound (**S<sub>2</sub>**), which occur during diastole

## HEART SOUNDS



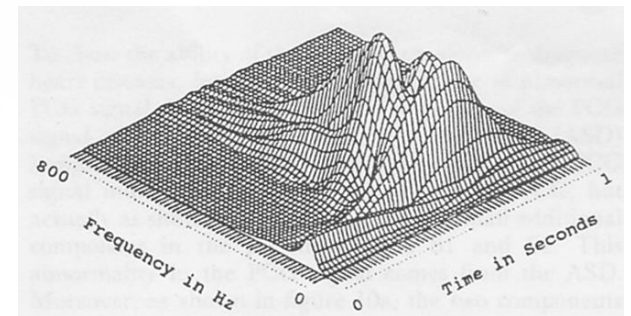
# Normal heart sounds

- $S_1$  components: 1,2 - atrial; 3,4 - valvular; 5,6 - muscular; 7,8 - vascular.
- $S_2$  components: 1,2 - valvular; 3,4 - vascular.
- A - protodiastole, B - mesodiastole, C - presystole.



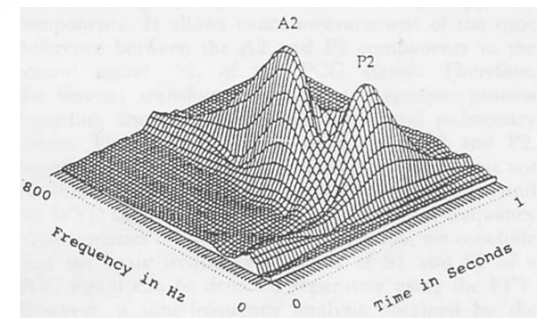
# Normal heart sound: $S_1$

- $S_1$  consists of four pair components:
- **atrial component:**
  - 1 - tension and contraction of the right atrium,
  - 2 - tension and contraction of the left atrium;
- **valvular component:**
  - 3 - closure and vibration of mitral valve cusps,
  - 4 - closure and vibration of tricuspid valve cusps;
- **muscular component:**
  - 5 - isometric tension and contraction of the right ventricle,
  - 6 - isometric tension and contraction of the left ventricle;
- **vascular component:**
  - 7 - vibration of the initial portion of the aorta,
  - 8 - vibration of the initial portion of the pulmonary trunk.

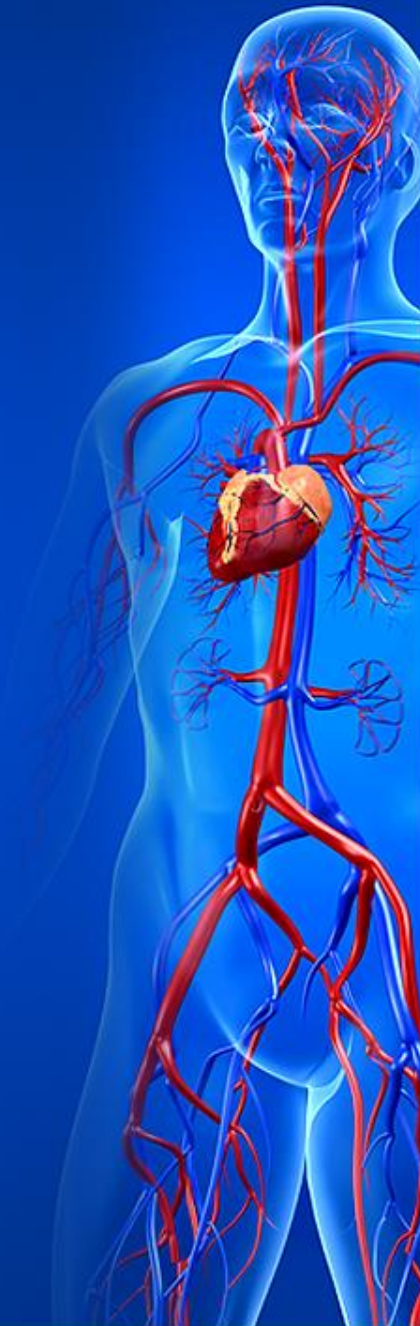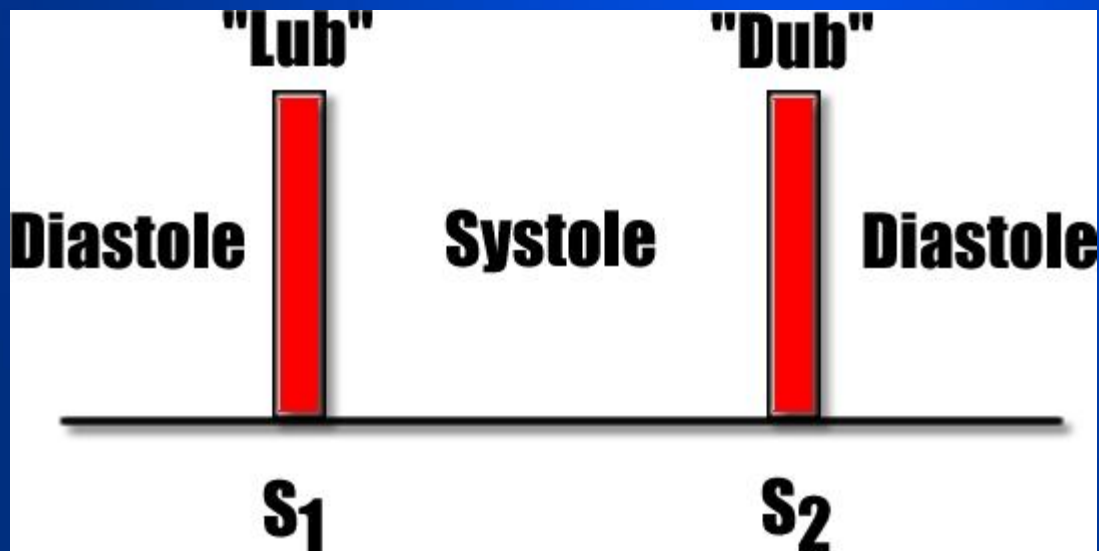


# Normal heart sound: $S_2$

- $S_2$  consists of two pair components:
- **valvular component:**
  - 1 - closure and vibration of the aortic valve cusps,
  - 2 - closure and vibration of the pulmonary valve cusps;
- **vascular component:**
  - 3 - vibration of the aortic walls,
  - 4 - vibration of pulmonary trunk walls.



- ***The first heart sound***, a dull, prolonged 'lub' marks the onset of the ventricular systole.
- ***The second heart sound***, a short, sharp 'dup' occurs at the beginning of ventricular diastole.

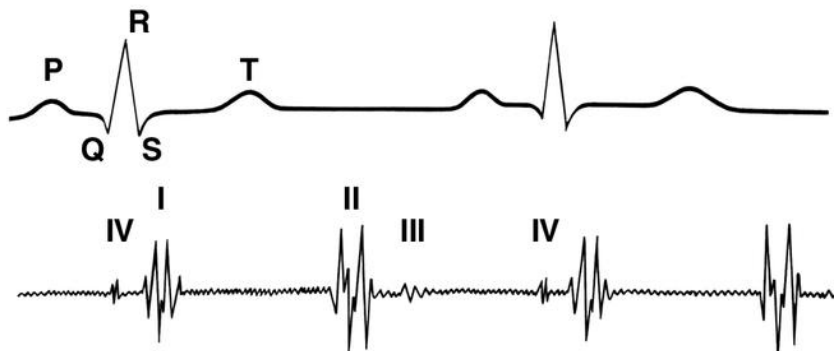




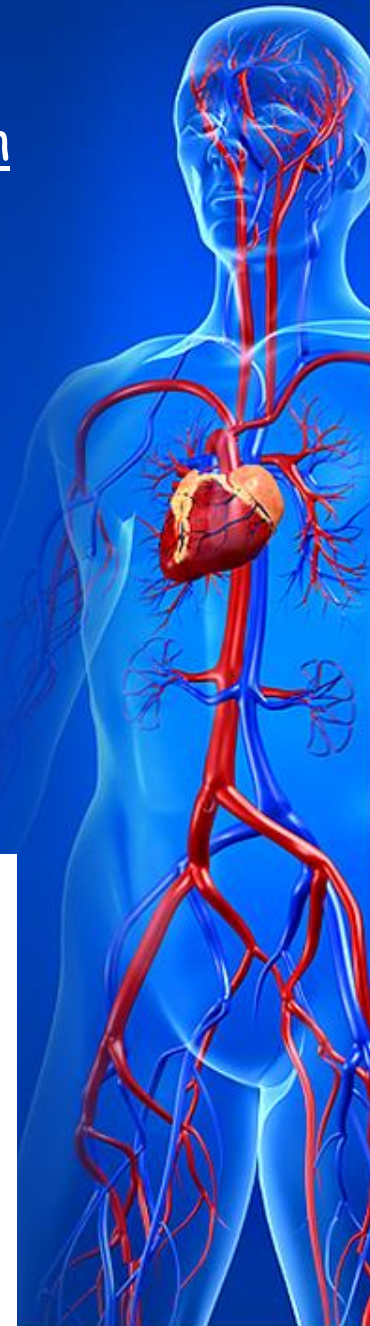
- A weak, low-pitched, dull **third sound ( $S_3$ )** is sometimes heard and is thought to be caused by vibration of the walls of the ventricles when they are suddenly distended by blood from atria (passive rapid filling),

occurs 0,12-0,15 s after the onset of  $S_2$ .

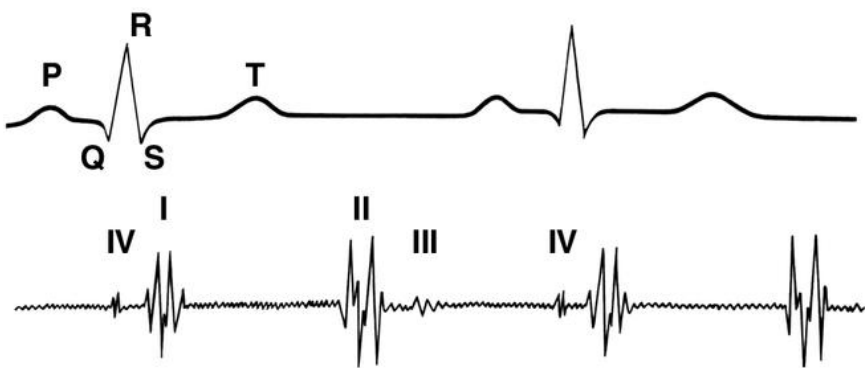
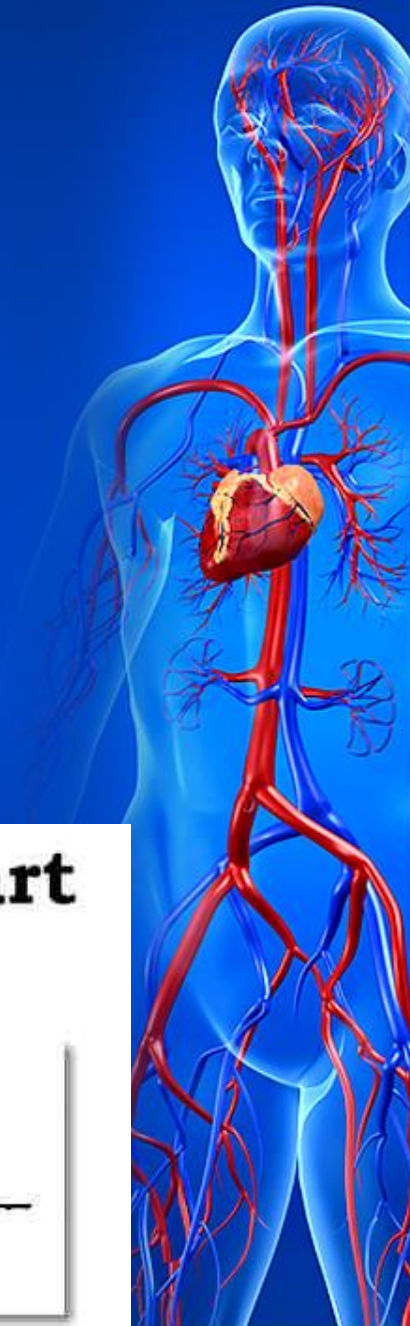- The third sound is heard most clearly at the apex of the heart with the bell of a stethoscope;
- it may be normal in children, adolescents, or very thin adults, or in patients with high cardiac output.



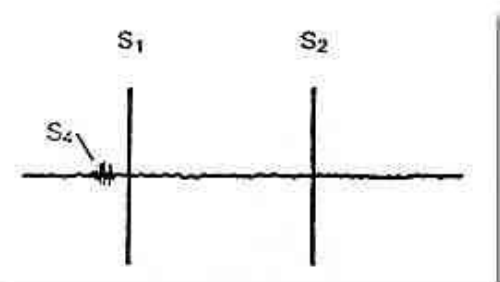
## THIRD HEART SOUND



- The **fourth heart sound** ( $S_4$ ) is a low-pitched, presystolic sound produced in the ventricle during ventricular filling;
- it is associated with an effective atrial contraction and is best heard with the bell piece of the stethoscope.

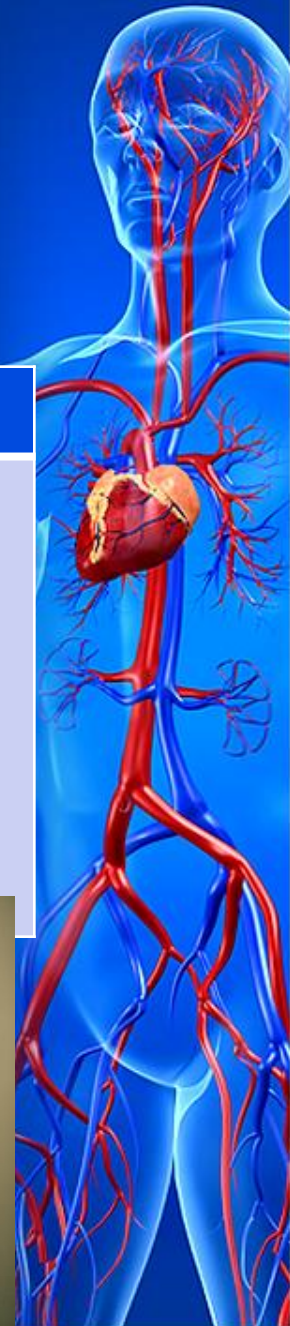

## Fourth Heart Sound

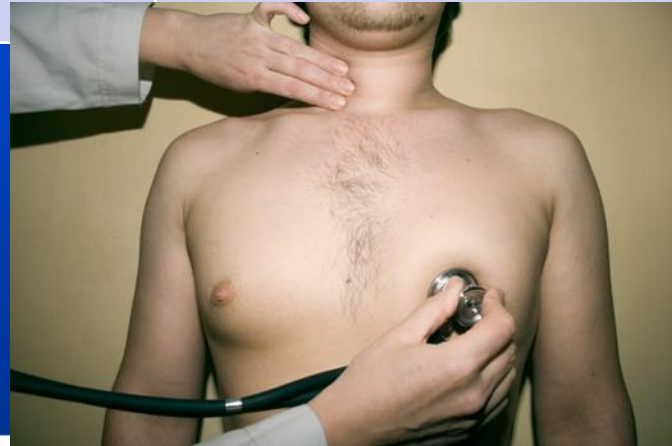
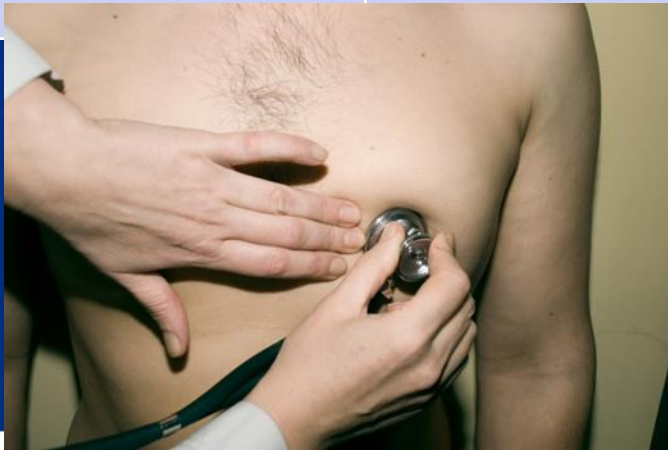
# Differential signs of $S_1$ and $S_2$

- Both heart sounds can be heard over precordium, but their intensity changes depend on nearness of valves that take part in formation of  $S_1$  or  $S_2$ .
- In rhythmic heart activity  $S_1$  and  $S_2$  can be differentiated according to the following signs



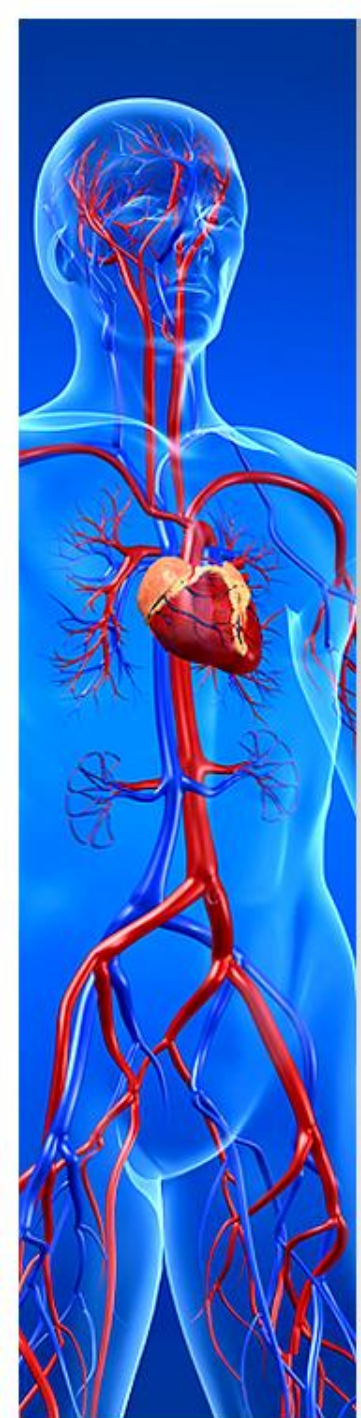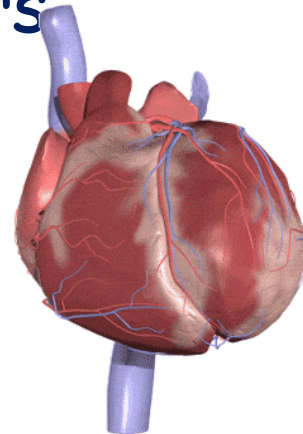
Main sign	First sound	Second sound
Listening point	Heart apex	Heart base
Relation to cardiac pause	Follows the long pause	Follows the short pause
Duration	0,09-0,12 s	0,05-0,07 s
Relation to apex beat	Synchronous	Follows the apex beat
Relation to carotid pulse	Synchronous	Asynchronous



# Auscultation of the heart

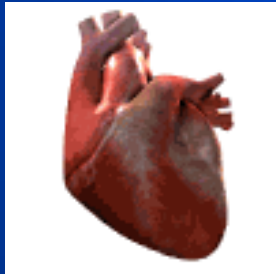## *Examination plan:*

- Heart rhythm;
- Heart rate;
- Heart sounds analysis (loudness, timbre);
- Presence of the splitting and additional sounds;
- Presence of the heart murmurs



# Cardiac rhythm

In healthy subjects  $S_1$  and  $S_2$ ,  $S_2$  and  $S_1$  follow one another at regular intervals:  
the heart activity is said to be rhythmic or regular.



When the cardiac activity is arrhythmic, the heart sounds follow at irregular intervals.



# Heart rate (HR)

**Heart rate (HR)** in normal conditions is 60-80 beats per minute.

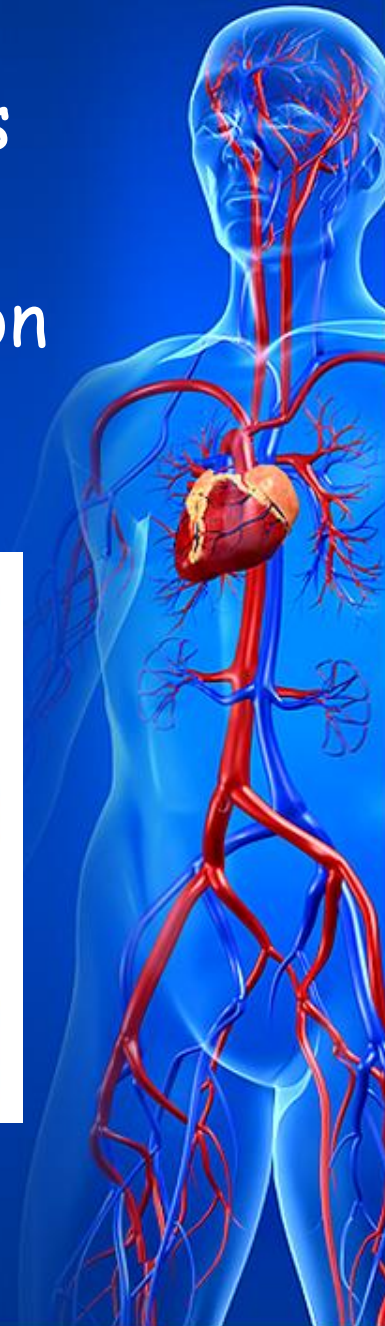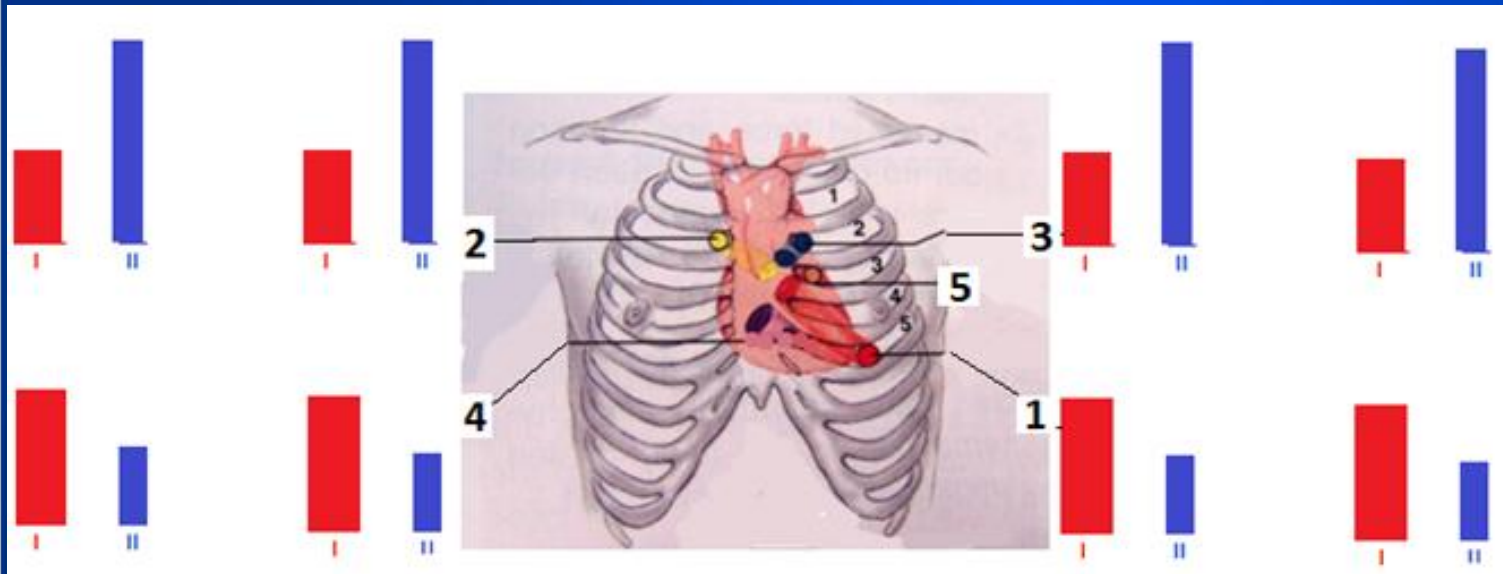
Acceleration of the heart rate to more than 90 beats per minute is called *tachycardia*.

A heart rate less than 60 beat per minute is called *bradycardia*.



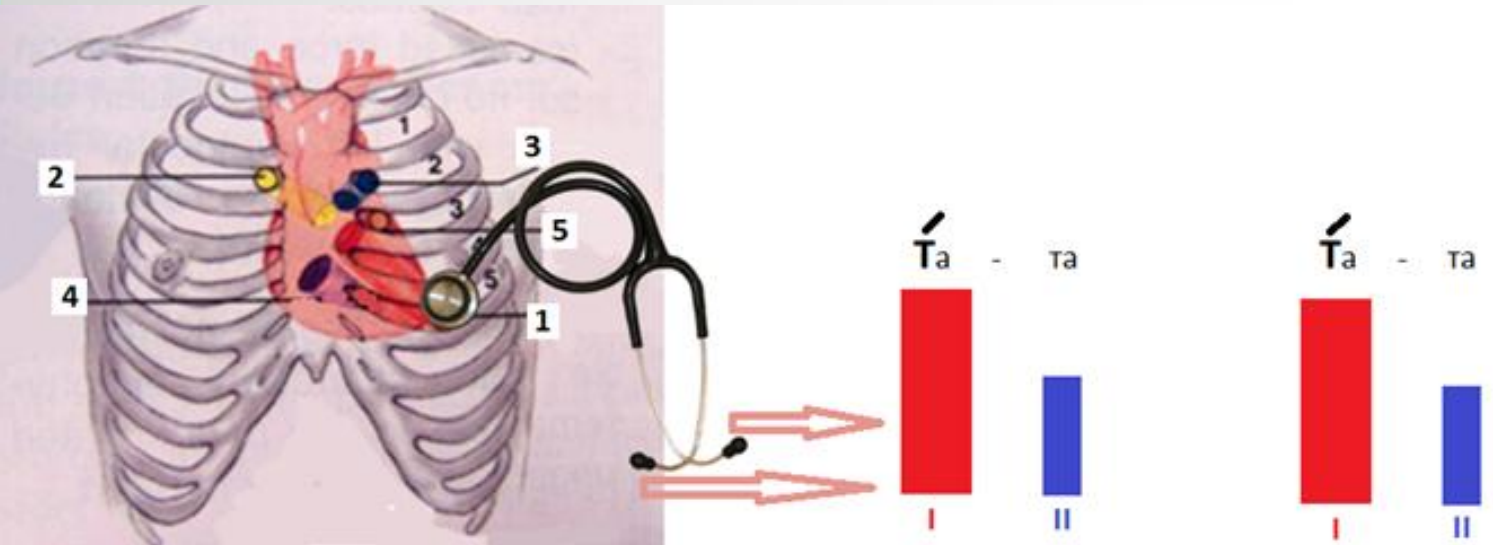
# Heart sounds analysis

- In heart sounds analysis their loudness and timbre should be assessed.
- Loudness of the heart sounds depends on the point of auscultation



# Heart sounds analysis

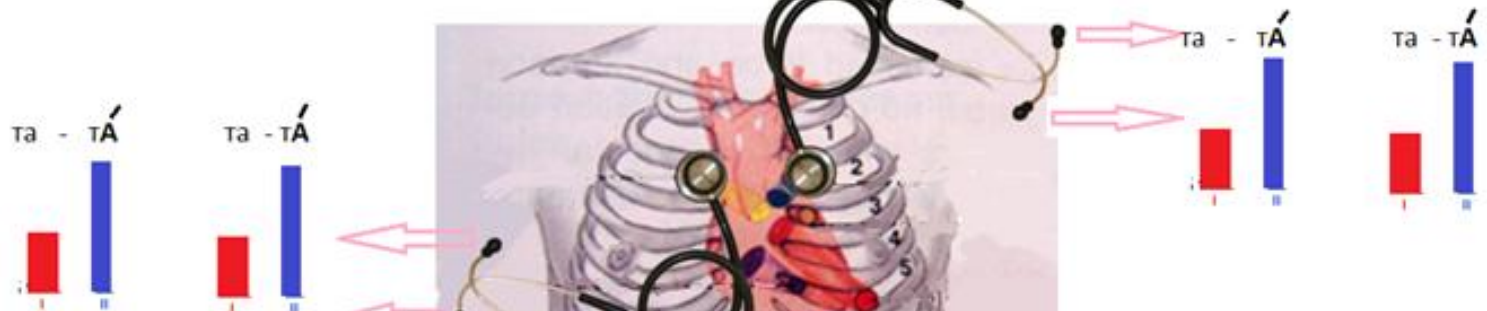Over the heart apex (in the first listening point) and over the base of the sternum (fourth listening point) first heart sound is louder than second one  $S_1 > S_2$ ,





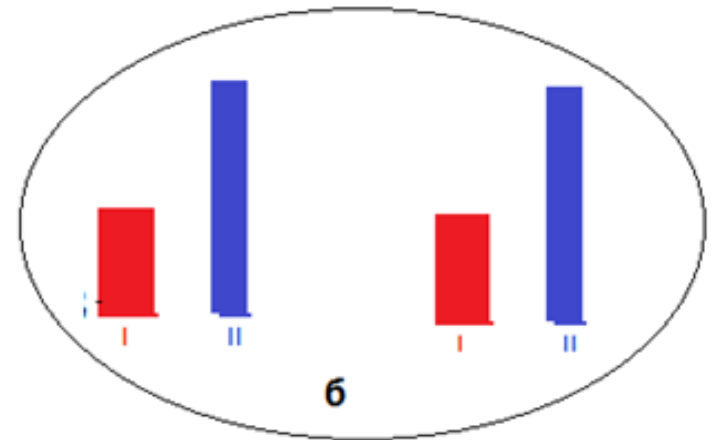
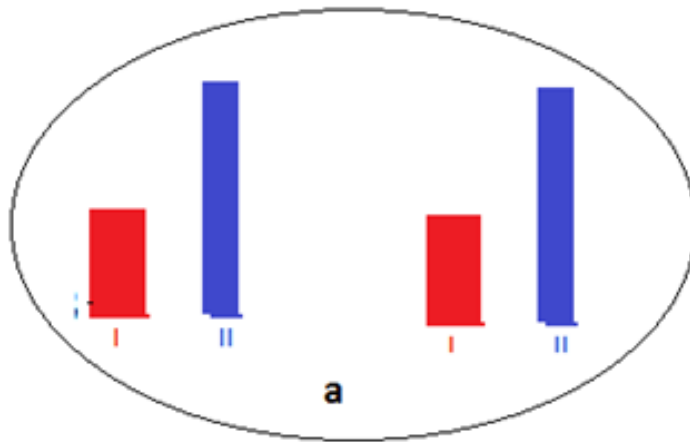
# Heart sounds analysis

Over the heart base (in the second and third listening points) - second heart sound is louder than the first  $S_1 < S_2$ ,



# Heart sounds analysis

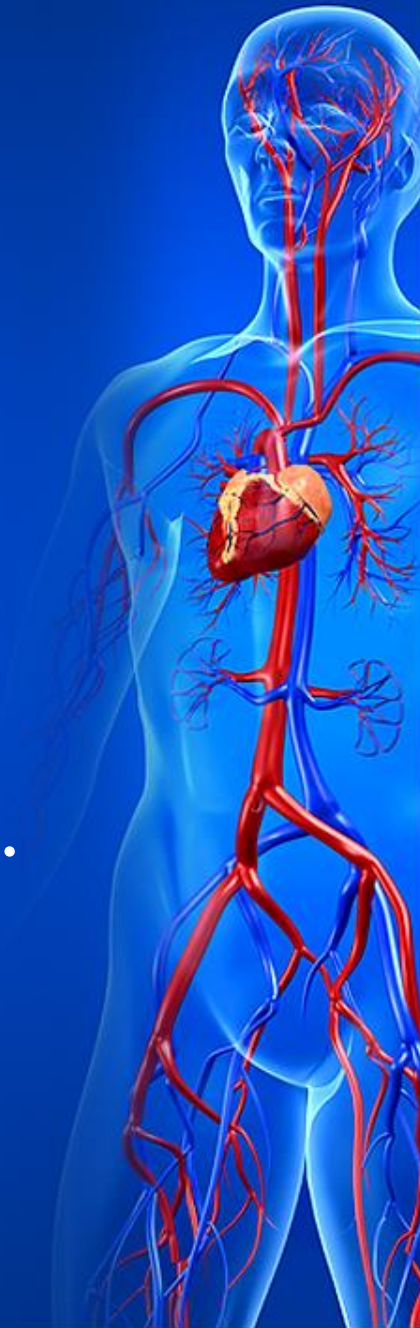The second sound over aorta and pulmonary artery is of the same loudness  $A_2 = P_2$ .



# Heart sounds analysis

The loudness of the heart sounds can be changed in several physiological and pathological conditions.

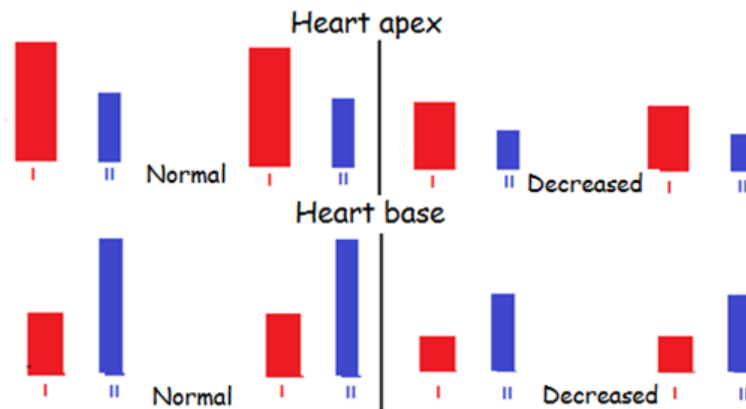
Loudness of one or both heart sounds may increase or decrease.



# Both heart sounds decreasing (in all listening points)

Both heart sounds decreasing (in all listening points).

Extracardiac		Cardiac	
Physiological	Pathological	Primary	Secondary
Excessive muscles development	Obesity Swelling of the chest wall Pulmonary emphysema Effusive pericarditis Effusive left-sided pleurisy	Myocarditis Myocardiosclerosis Myocardial infarction Myocardiopathy	Anemia Collapse Shock



# Both heart sounds increasing (in all listening points)

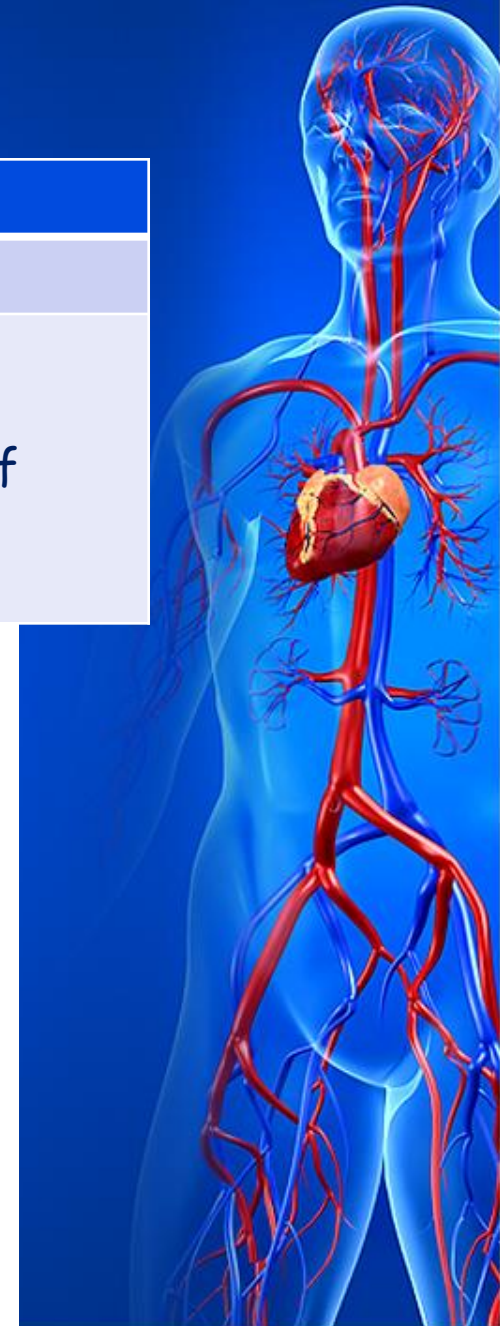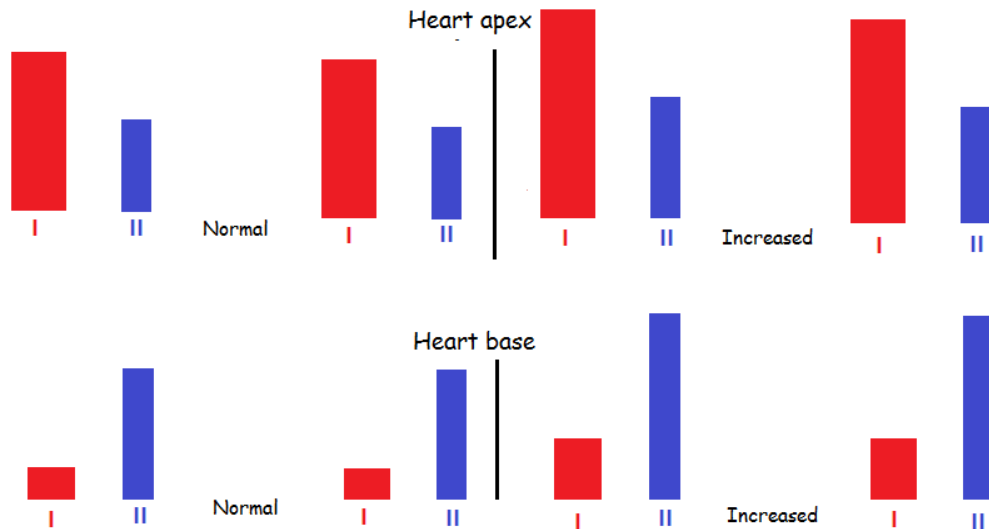
Both heart sounds increasing (in all listening points).

Physiological

Thin chest wall  
Nervous excitement  
Hard physical exertion

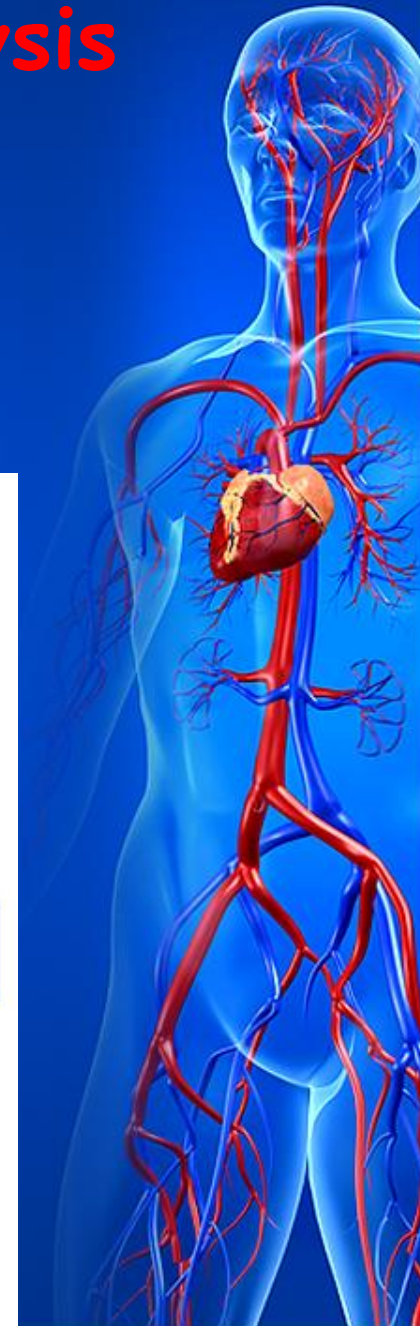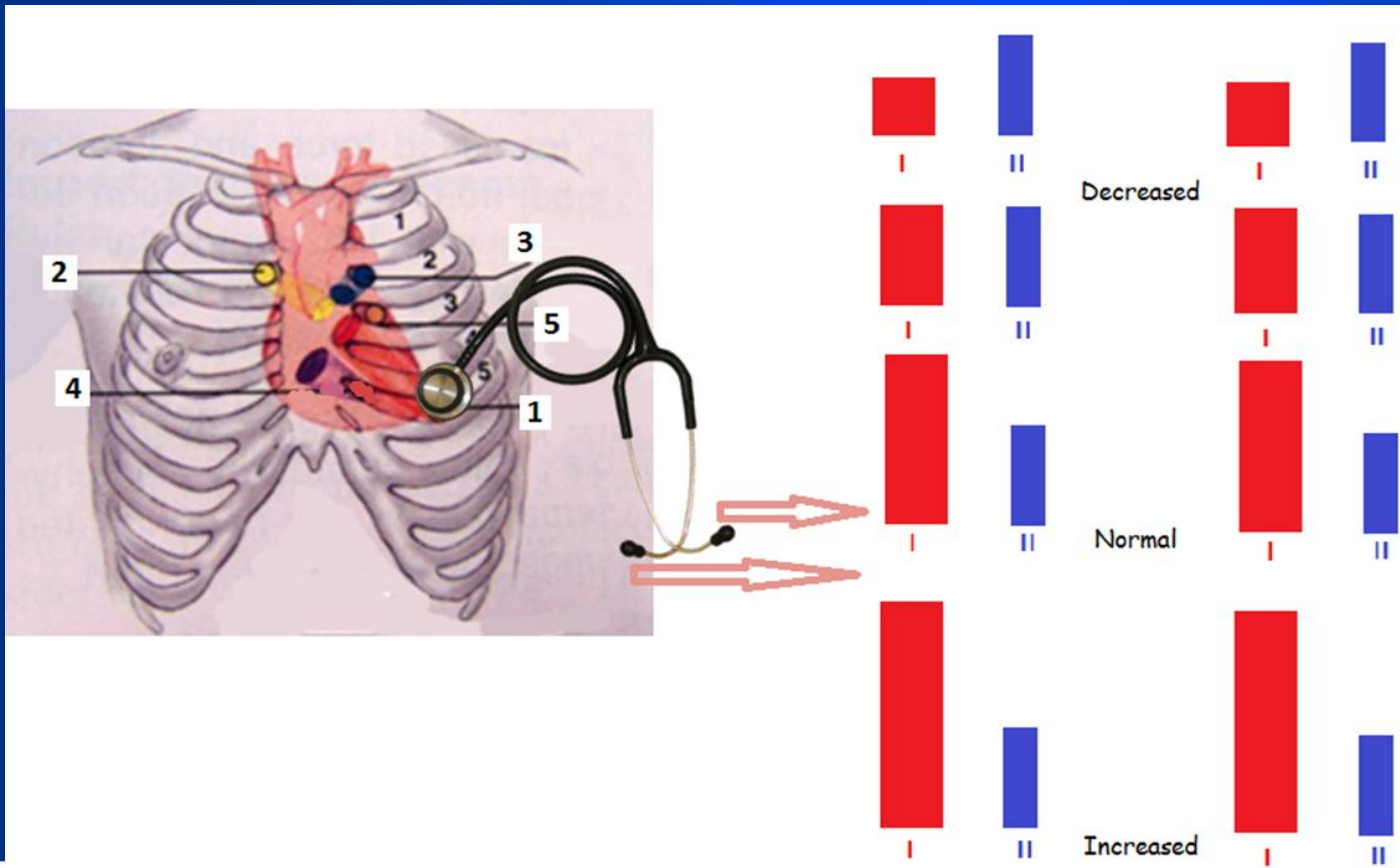
Pathological

Thyrotoxicosis  
Wrinkled pulmonary edges  
Inflammatory consolidation of  
pulmonary edges  
Fever



# Heart sounds analysis

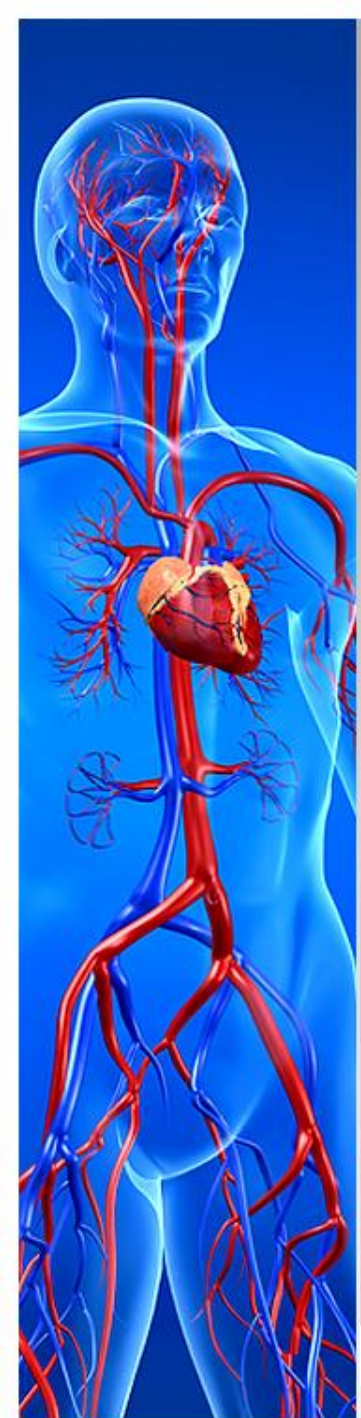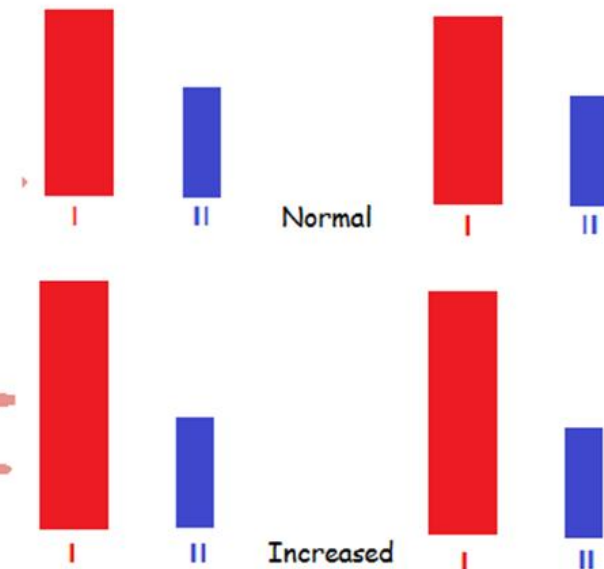
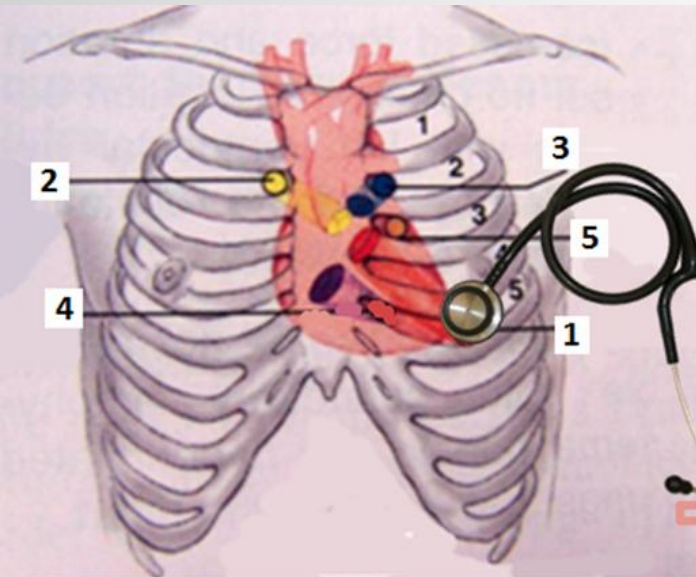
- Changes in only one heart sound are very important diagnostically.



# Increased loudness of $S_1$ at the heart apex

$S_1$  more than 1.5 folds louder than  $S_2$ .

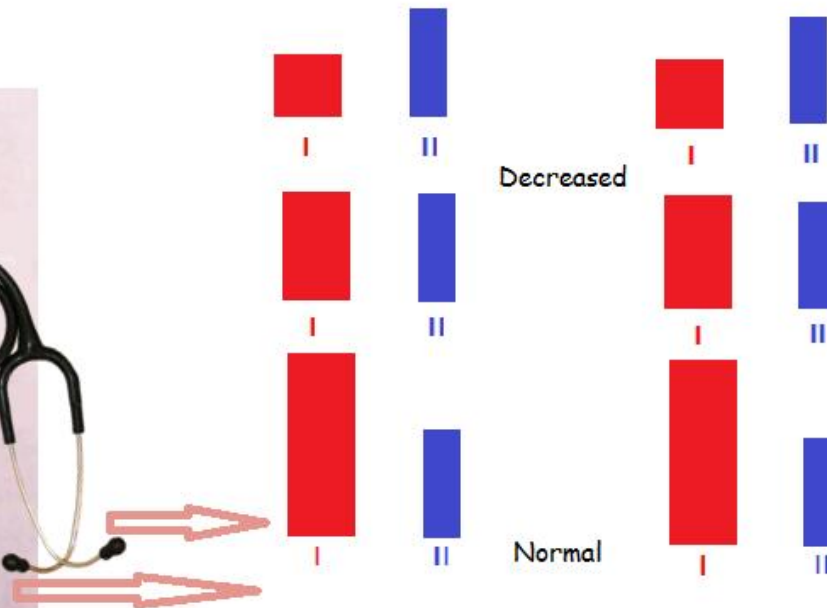
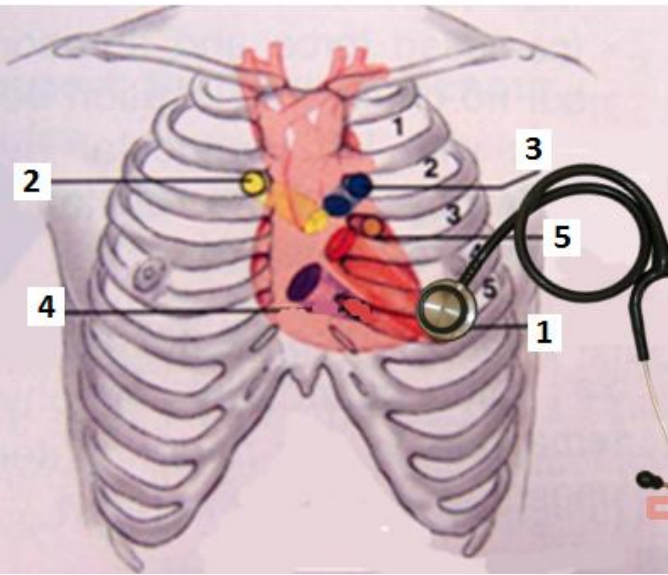
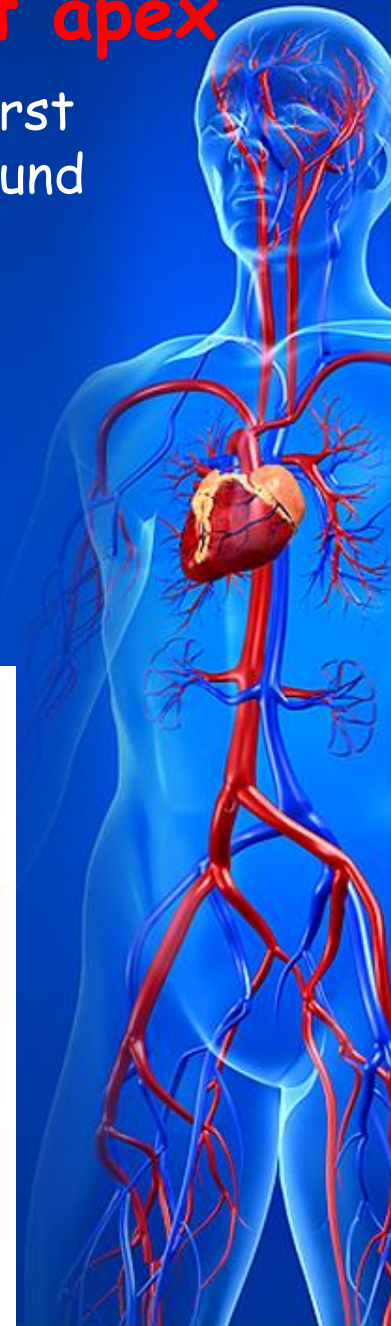Causes	Mechanism
Mitral stenosis Tachycardia Left ventricular extrasystole Complete atrioventricular block in synchronous contraction of atria and ventricles - 'pistol-shot' sound according Strazhesko	Not adequate filling of the left ventricular cavity during diastole, quick and intense contraction of the myocardium



# Decreased loudness of $S_1$ at the heart apex

The first heart sound is less loud than the second or the first heart sound is of the same loudness as the second heart sound

Causes	Mechanism
Mitral regurgitation	Anatomic abnormalities of the valve
Aortic regurgitation	Absence of closed valve period
Aortic stenosis	Overfilling of the left ventricular cavity

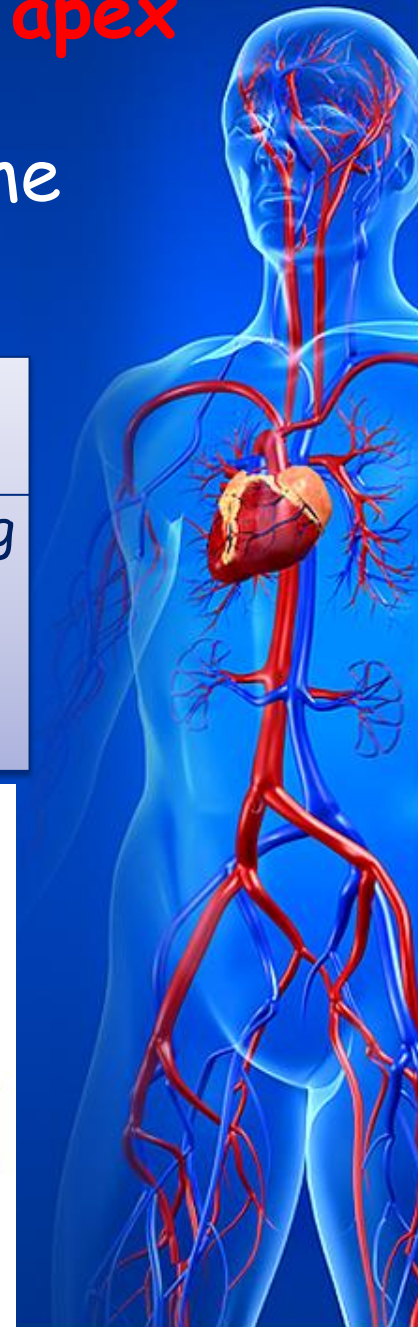
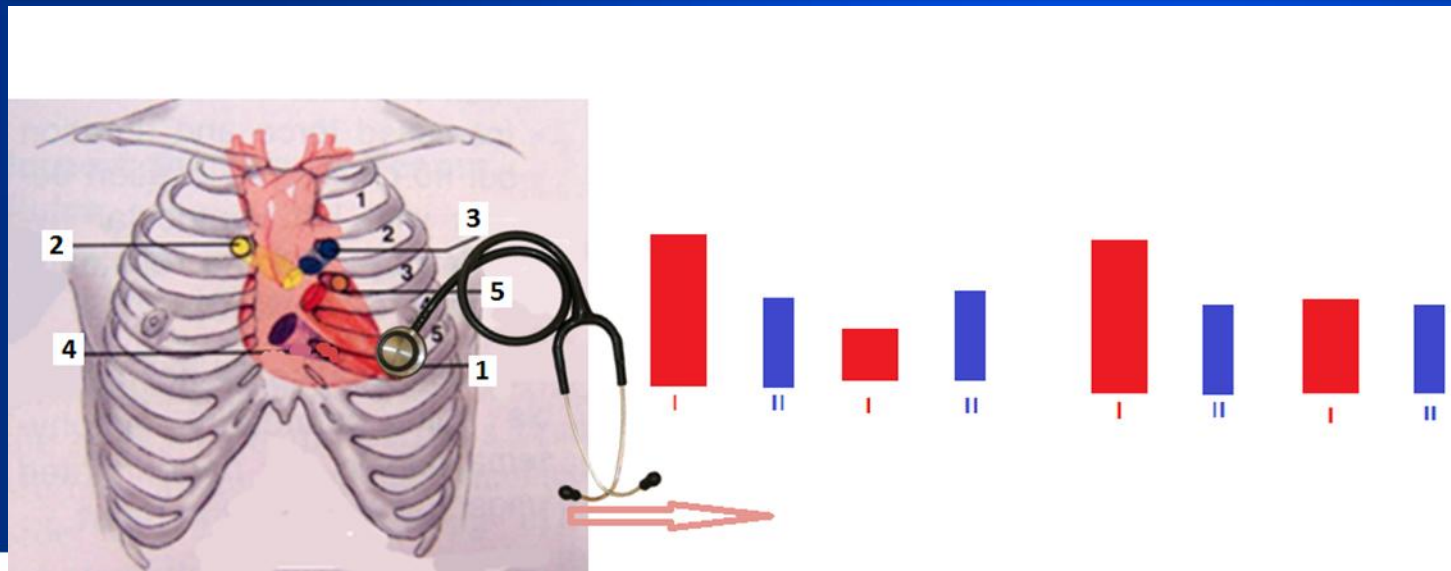




# Different loudness of $S_1$ at the heart apex

- The first heart sound is not of the same intensity in the different cycles

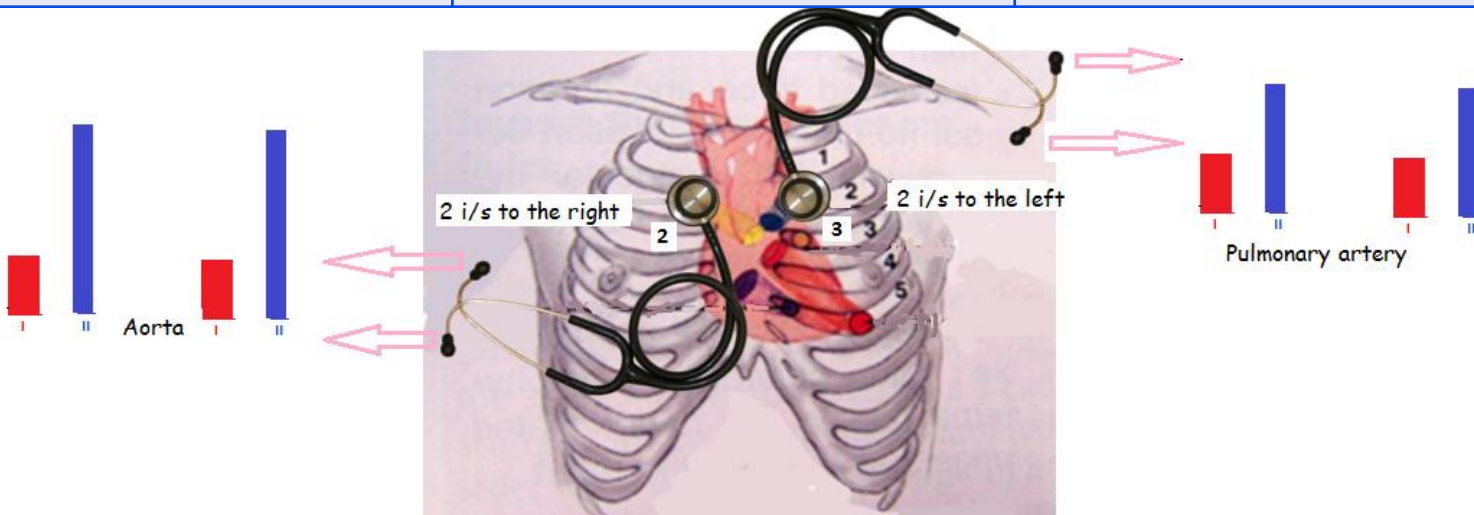
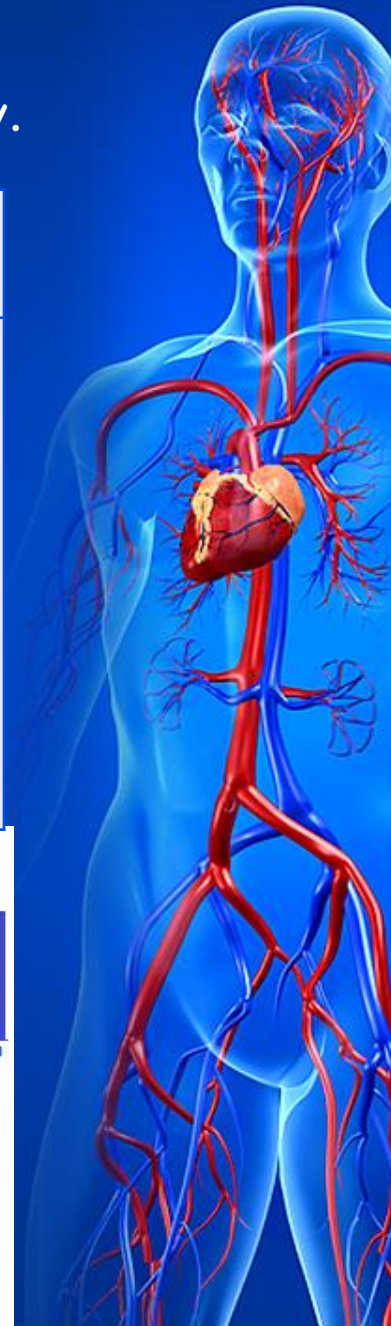Causes	Mechanism
Complete heart block Atrial fibrillation Extrasystolic arrhythmia Ventricular flutter	Different ventricular filling in each cardiac cycle



# Accentuated S<sub>2</sub> over aorta

The second sound over aorta is louder than over pulmonary artery.

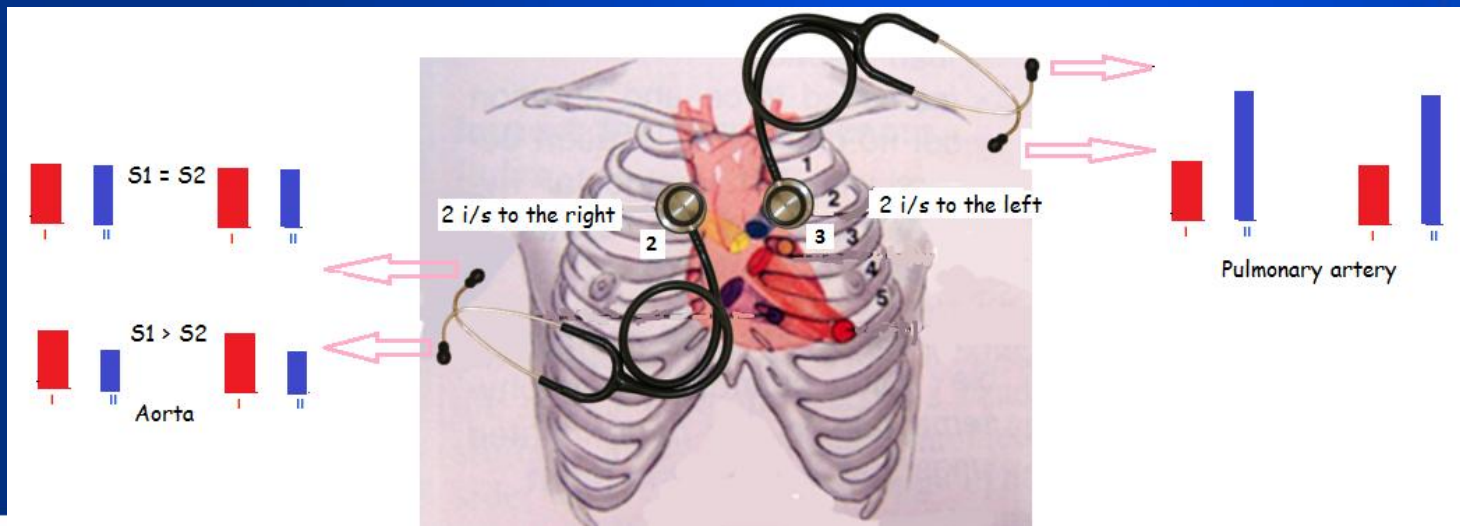
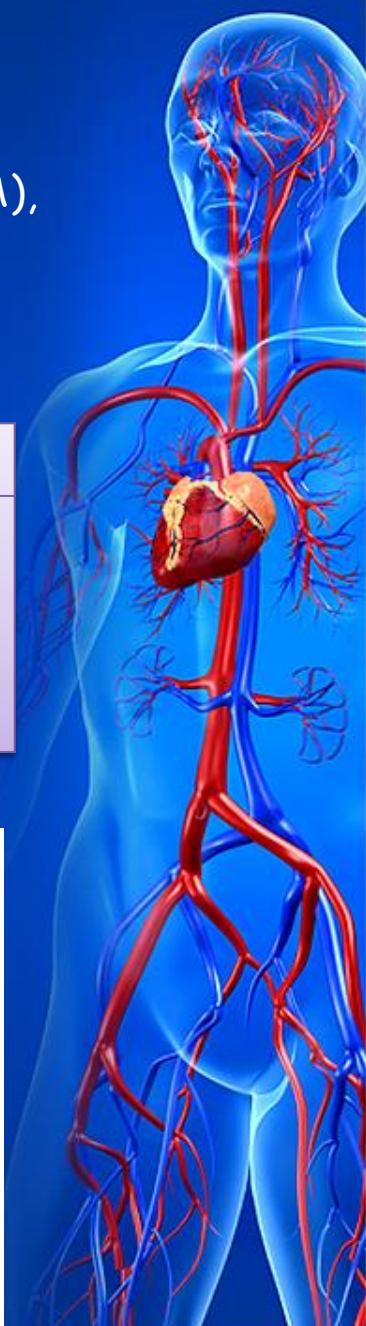Causes		Mechanism
Physiological	Pathological	
Emotional exertion Physical exertion	Essential hypertension Symptomatic hypertension Aortic atherosclerosis Syphilitic mesoaortitis	Pressure elevation in the systemic circulation, decreased elasticity of the aorta



# Decreased $S_2$ over aorta

Second intercostal space to the right of the sternum:  
 Loudness of the second heart sound is the same as the first heart sound (A),  
 the second heart sound loudness is less than the first one (B).

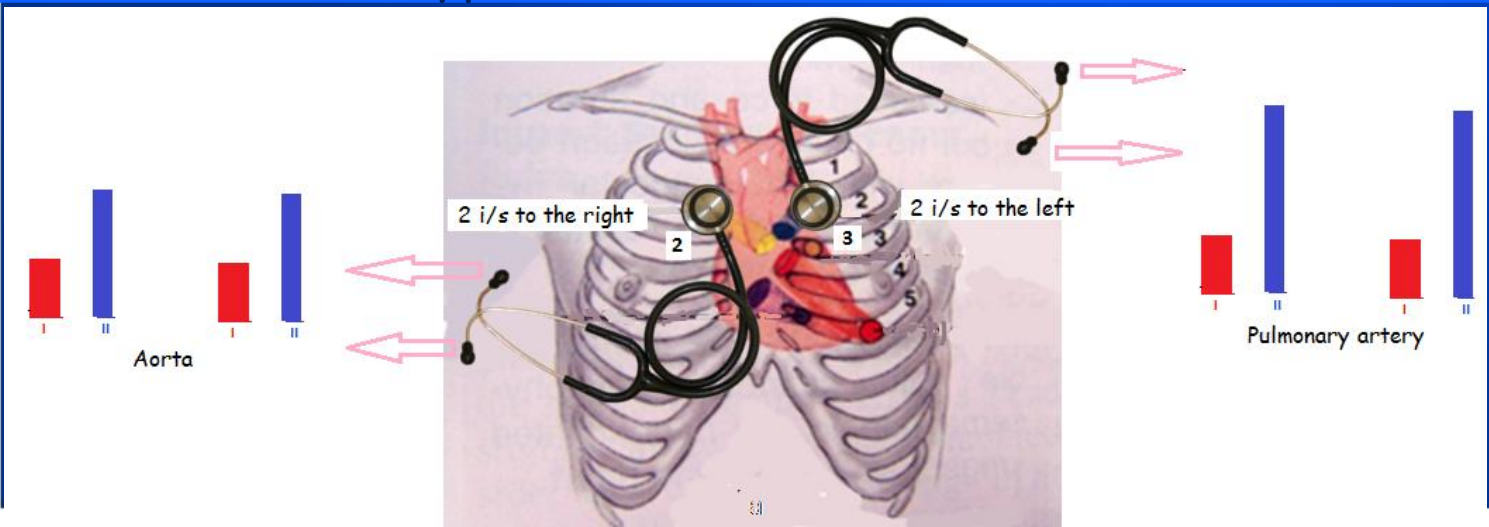
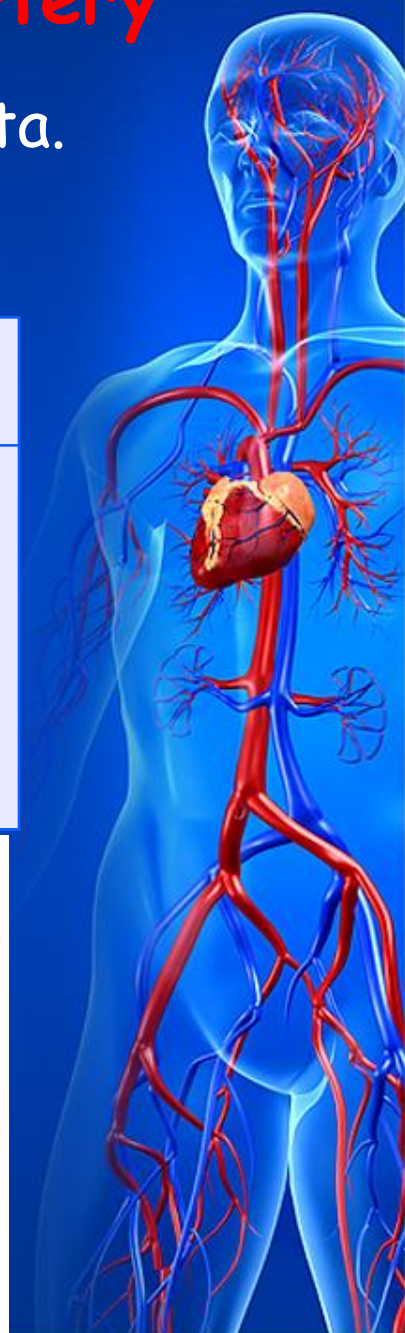Causes	Mechanism
Aortic regurgitation (A) Aortic stenosis (B)	Anatomic changes of valve (A) Low pressure in the aorta at the beginning of the diastole (B)



# Accentuated S<sub>2</sub> over pulmonary artery

S<sub>2</sub> over pulmonary artery is louder than over aorta.

Causes		Mechanism
Physiological	Pathological	
In children	Mitral valvular diseases	Pressure elevation in the pulmonary circulation
Thin chest wall	Diseases of the broncho-pulmonary system	
	Adhesion of the pleural layers	
	Kyphoscoliotic chest	



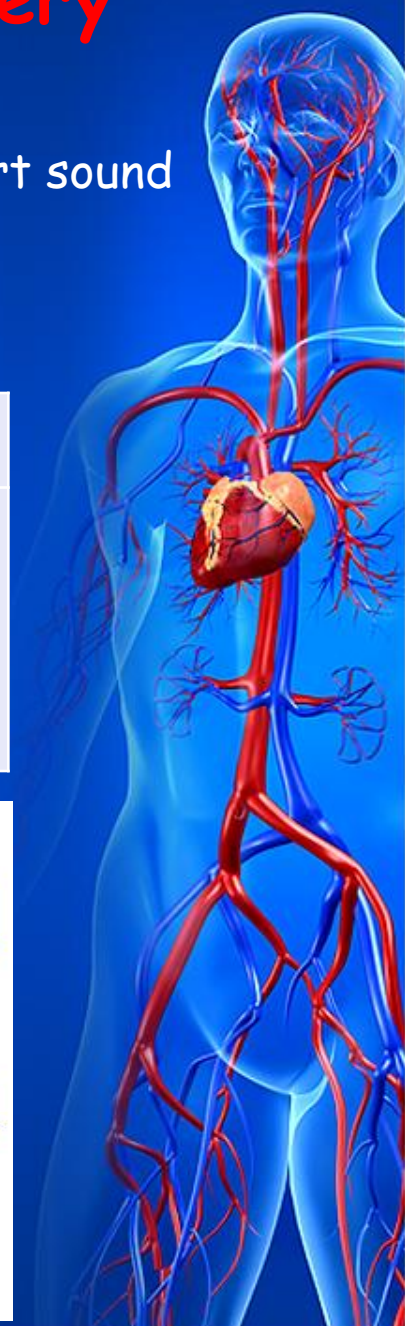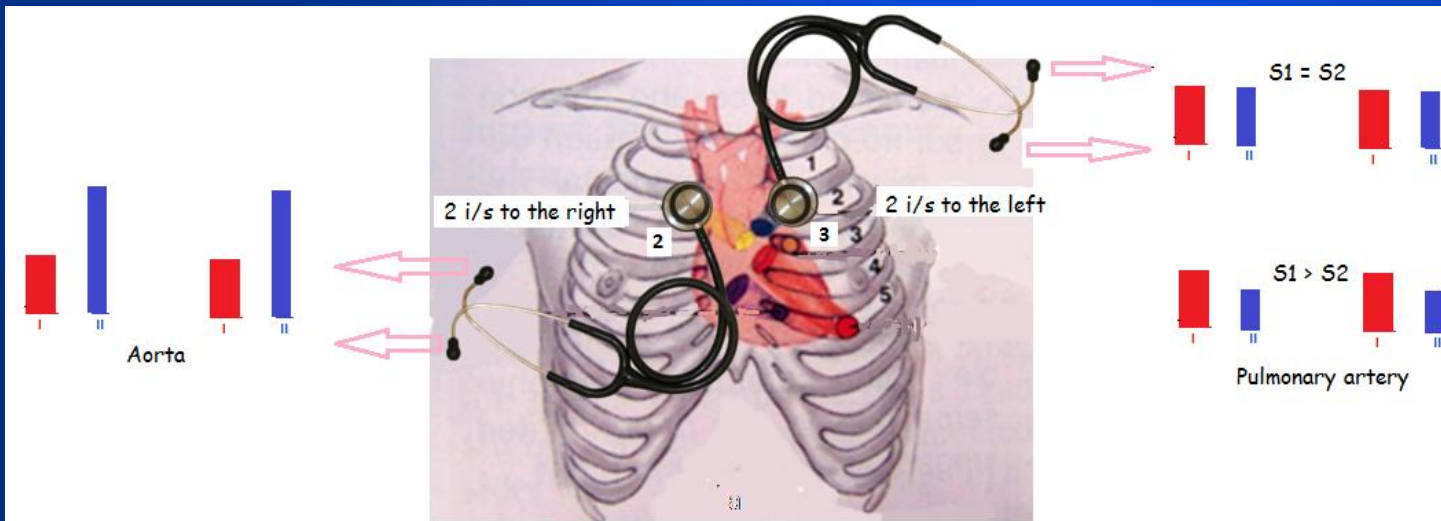
# Decreased $S_2$ over pulmonary artery

Second intercostal space to the left:

Loudness of the second heart sound is the same as the first heart sound (A),

the second heart sound loudness is less than the first one (B).

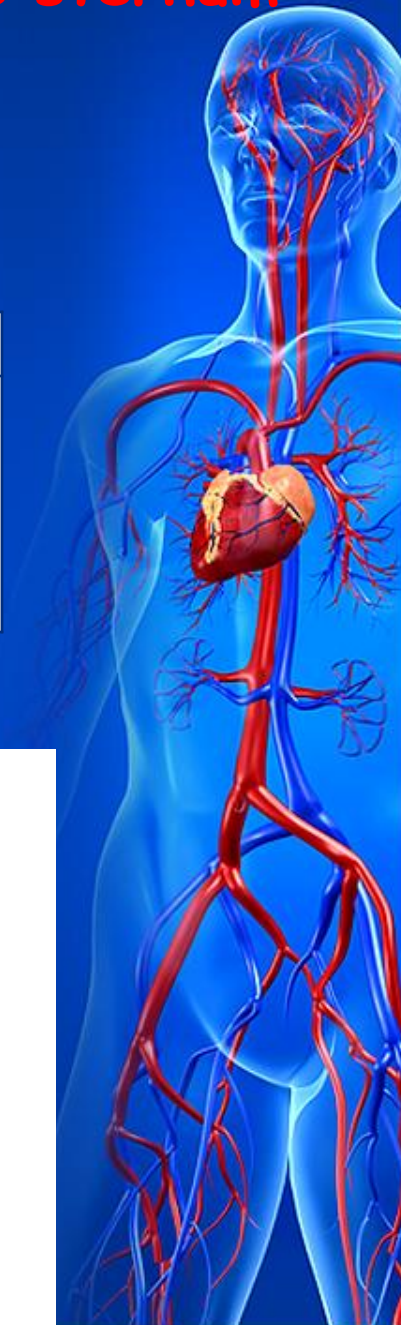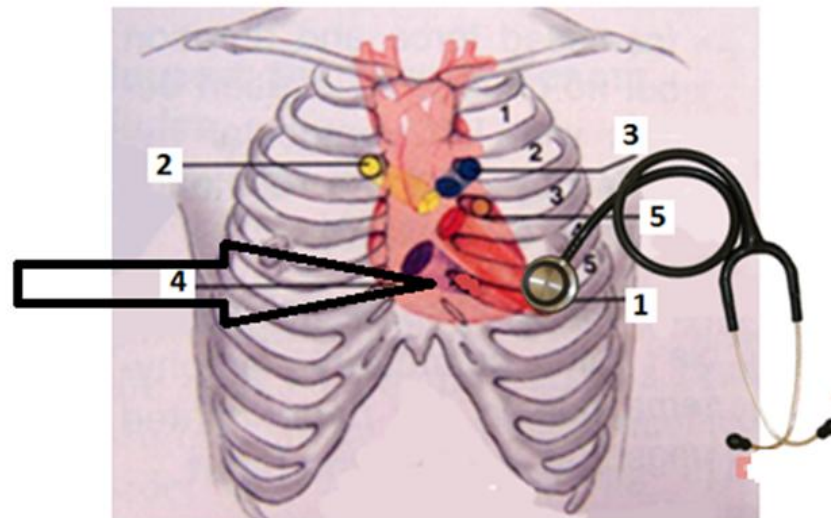
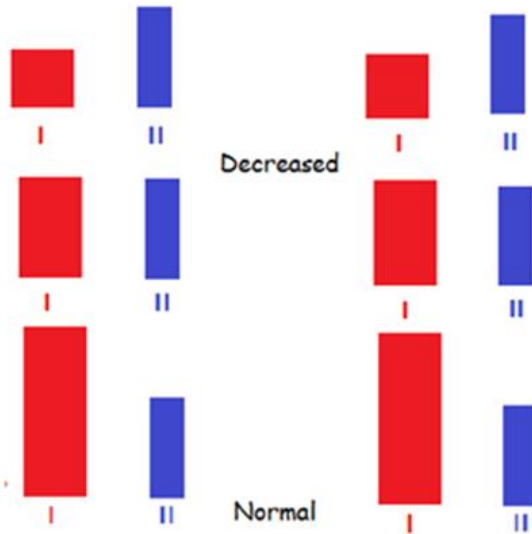
Causes	Mechanism
Pulmonary artery stenosis Pulmonary regurgitation	Anatomical valve changes Low pressure in the pulmonary artery before diastole onset



# Decreased loudness of $S_1$ at the base of the sternum

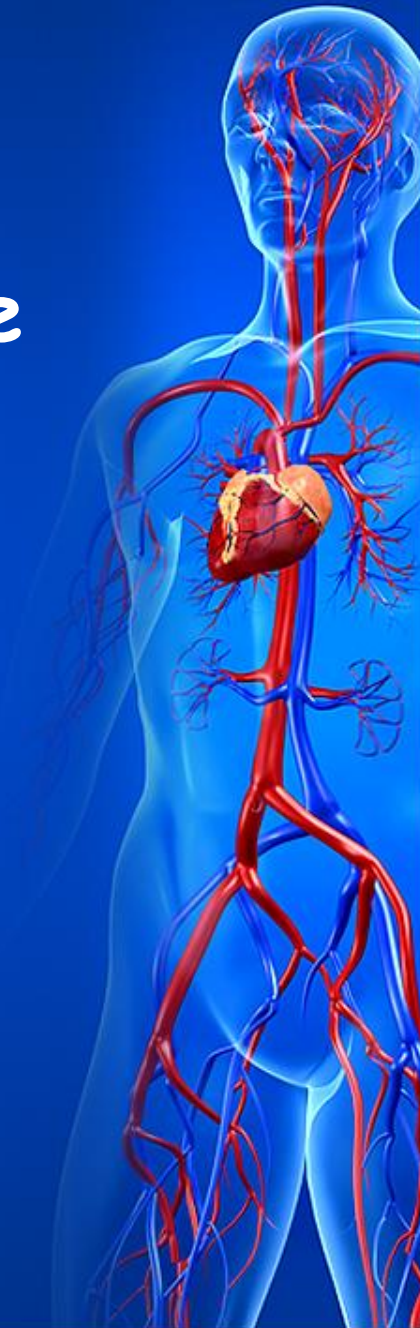- The first heart sound is less loud than the second or the first heart sound is of the same loudness as the second heart sound

Causes	Mechanism
Tricuspid regurgitation	Anatomic changes of the valve Absence of closed valves period Overfilling of the right ventricular cavity



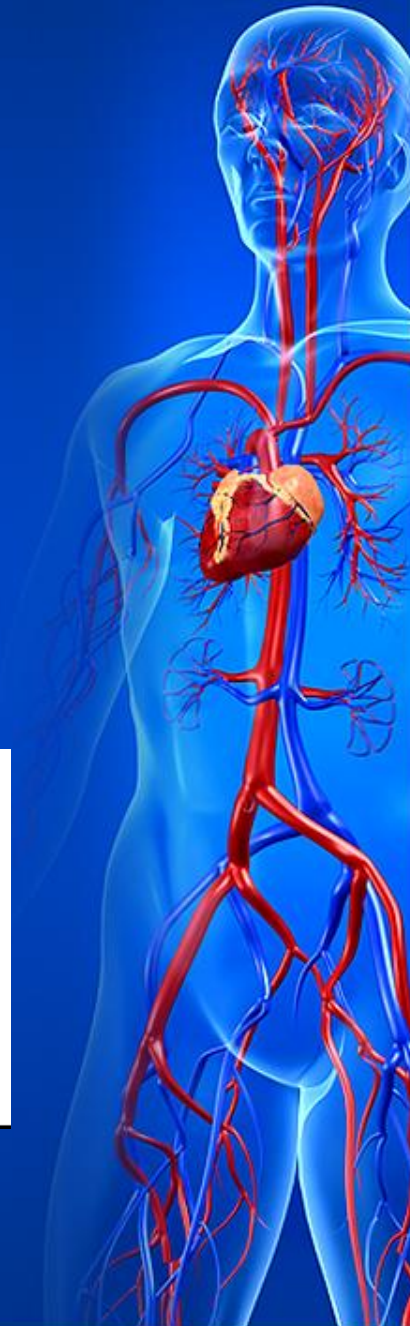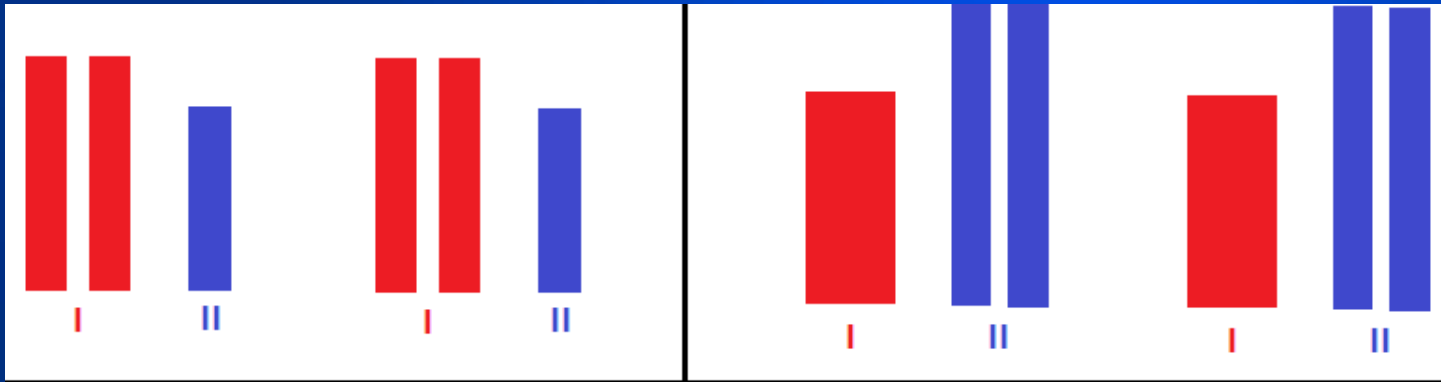
# Reduplication and splitting of the heart sounds

- Reduplication and splitting of the heart sounds may be revealed in auscultation, which are caused by asynchronous work of right and left chambers of the heart.



# Reduplication and splitting of the heart sounds

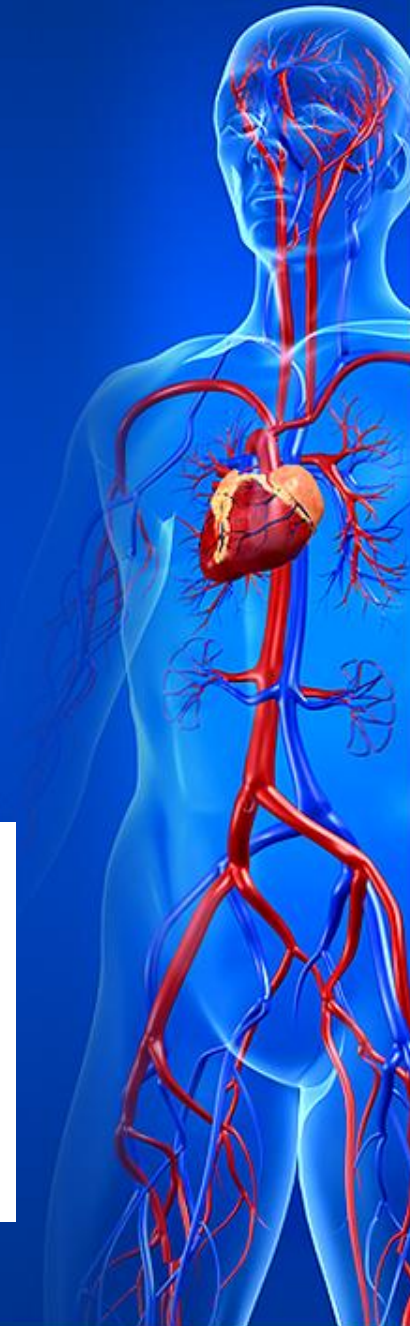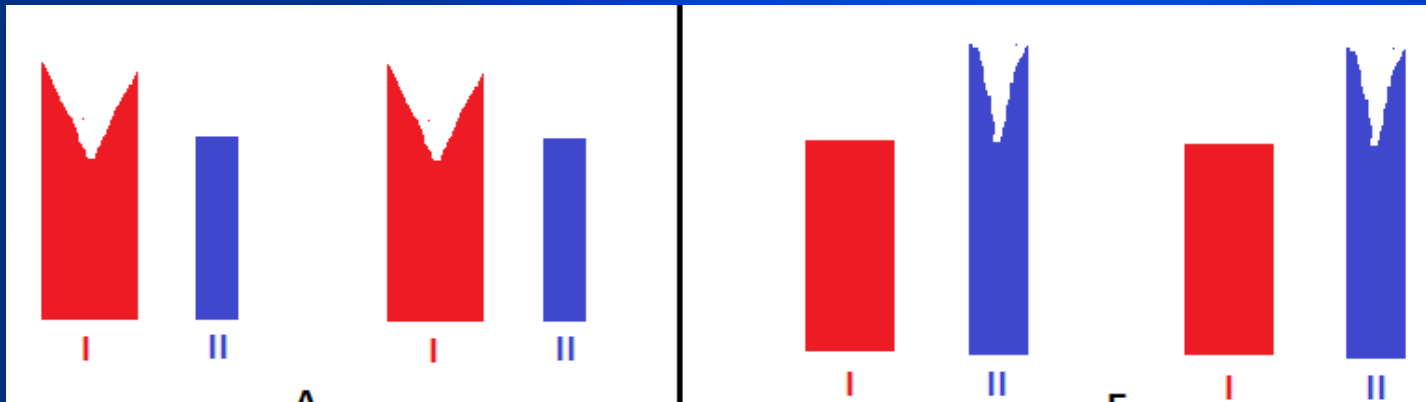
- **Reduplication** - two short sounds follow one another are heard instead  $S_1$  or  $S_2$ .





# Reduplication and splitting of the heart sounds

- ***Splitting*** - two short sounds follow one another at a short interval, and therefore they are not perceived as two separate sounds



# Reduplication and splitting of the heart sounds

- Splitting of the two high-pitched components of  $S_1$  by 10-30 ms is a normal phenomenon, which is recorded by phonocardiography. The third component of  $S_1$  is attributed to mitral valve closure, and the fourth to tricuspid valve closure. Widening of the interval between these two components is heard as  $S_1$  splitting or reduplication at the heart apex or at the base of the xiphoid process.



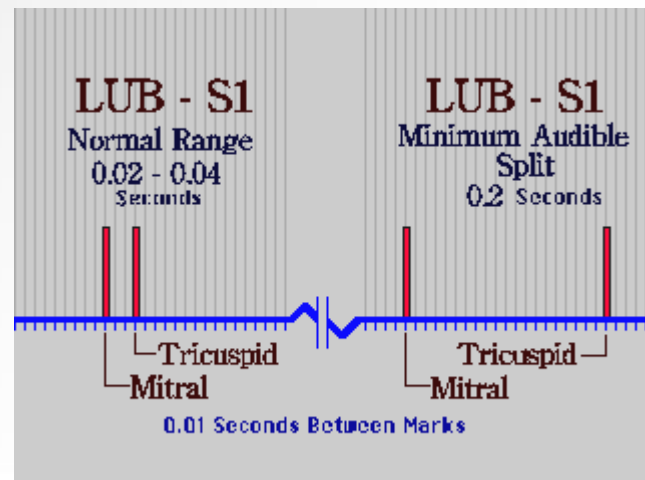
# Reduplication and splitting of the heart sounds

- *Physiological splitting of  $S_1$*  is heard in the upright position of the patient during very deep expiration, when the blood delivers to the left atrium with a greater force to prevent the closure of the mitral valve. The valvular component of the left ventricle is therefore splits and is perceived as a separate sound.



# Reduplication and splitting of the heart sounds

- *Pathological splitting of  $S_1$*  is due to:
  - Sclerosis of the initial part of the aorta;
  - Decreased left ventricular contractility in hypertension, nephritis leads to asynchronous contraction of the ventricles;
  - Aortic regurgitation ("interrupted contraction of the left ventricle - Obratsovs' bisystolia");
  - Complete right bundle branch block and resulting delay in onset of the right ventricular systole.



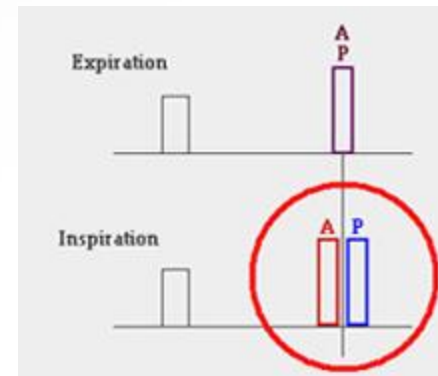
# Reduplication and splitting of the heart sounds

- *Reversed splitting of the  $S_1$*  in which the mitral component follows the tricuspid component, may be present in the patients with left bundle branch block, severe mitral stenosis, and left atrial myxoma.




# Reduplication and splitting of the heart sounds

- Splitting of  $S_2$  occurs more frequently than  $S_1$ .
- ***Physiological splitting of  $S_2$***  into audibly distinct aortic ( $A_2$ ) and pulmonic ( $P_2$ ) components is due to a normal physiological cause: respiration. Normally, the aortic valve closes just before the pulmonary valve, but they are so close together that the sound is a uniform and instantaneous  $S_2$ . When a person takes in a deep breath, the decrease in intrathoracic pressure causes an increase in venous return. This causes the right atrium and ventricle to fill slightly more than normal, and it takes the ventricle slightly longer during systole to eject this extra blood. This delay in ejection forces the pulmonary valve to stay open a bit longer than usual, and the normally small difference between aortic and pulmonary valve closure becomes noticeable as a split  $S_2$  at the heart base.



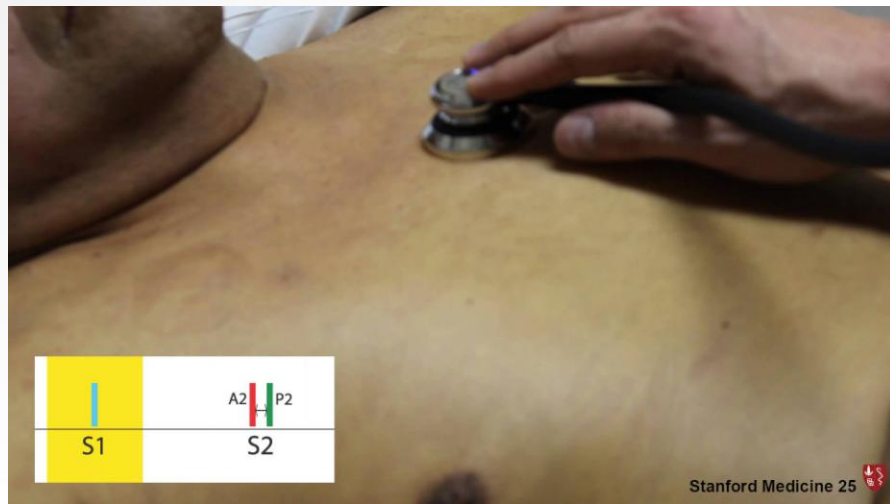# Reduplication and splitting of the heart sounds

- *Pathological splitting of  $S_2$*  may be due to many causes: delayed activation of the right ventricle in right bundle branch block, left ventricular ectopic beats, a left ventricular pacemaker; or delayed pulmonic valve closure because of right ventricular volume overload associated with right ventricular failure.



# Reduplication and splitting of the heart sounds

- Pathological splitting of  $S_2$  occurs in:
- **Mitral stenosis** - delayed pulmonic valve closure because of right ventricular volume overload, and prolongation of the right ventricular ejection;





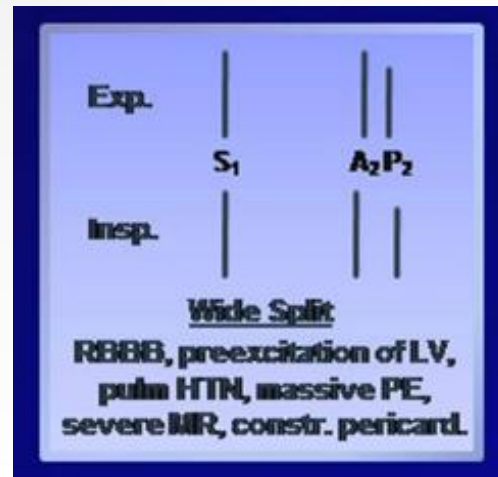
# Reduplication and splitting of the heart sounds

- Pathological splitting of  $S_2$  occurs in:
- Pulmonary stenosis or pulmonary embolism is characterized by prolongation of the right ventricular systolic ejection period and thus delay closure of the pulmonic valve;



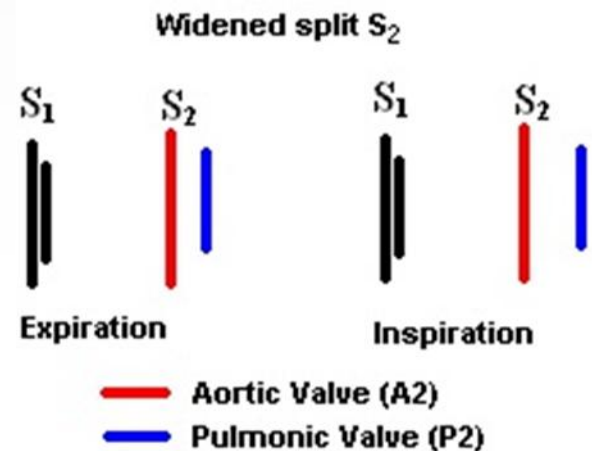
# Reduplication and splitting of the heart sounds

- **Pathological splitting of  $S_2$**  occurs in:
- Shortening of the left ventricular systole and early aortic valve closure occurring with **mitral regurgitation** because blood passes in two direction - into aorta and in the left atrium, also may produce splitting of  $S_2$ ;



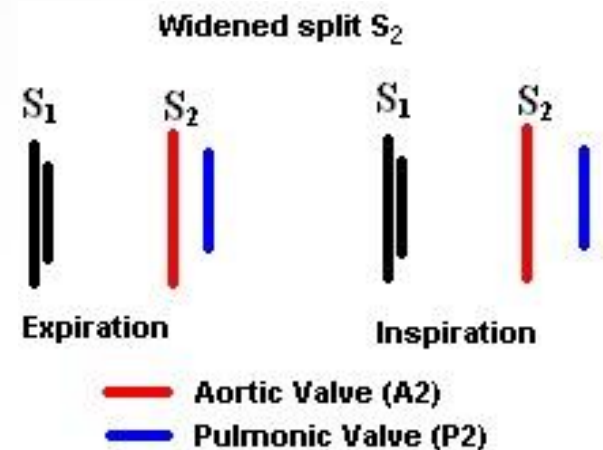
# Reduplication and splitting of the heart sounds

- **Pathological splitting of  $S_2$**  occurs in:
- In the patients with a **ventricular septal defect** blood ejected into aorta and throughout the defect to the right ventricle, left ventricular systole is thus shortened, and occurs splitting of the  $S_2$  a result early aortic component of  $S_2$ .



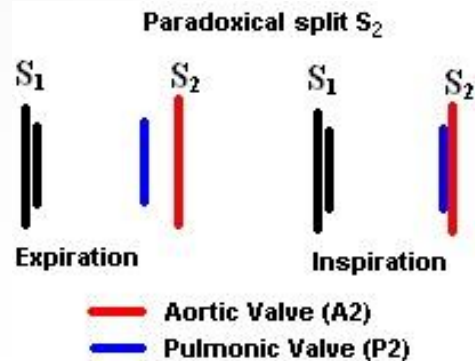
# Reduplication and splitting of the heart sounds

- Pathological splitting of  $S_2$  occurs in:
- An atrial septal defect leads to increased diastolic filling of the right ventricle and early aortic valve closure.



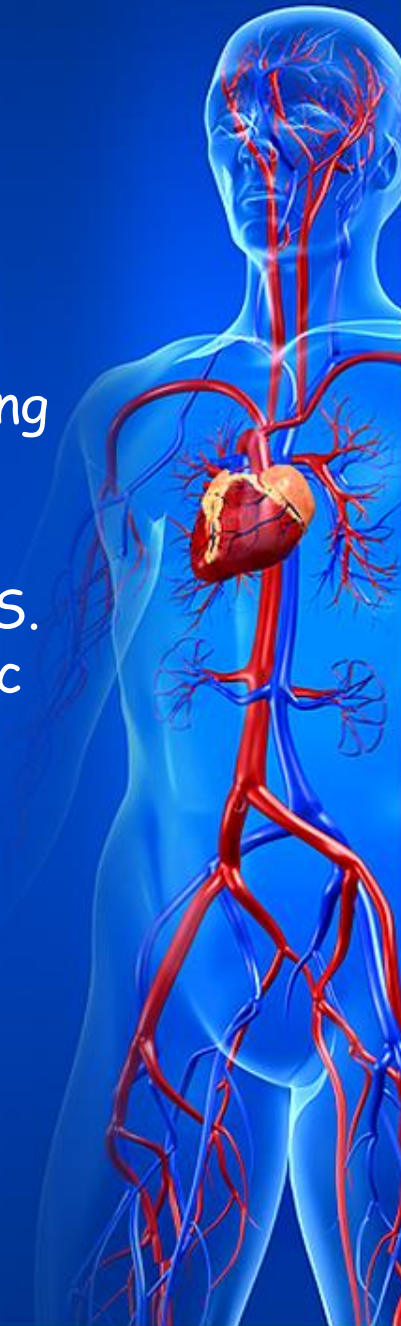
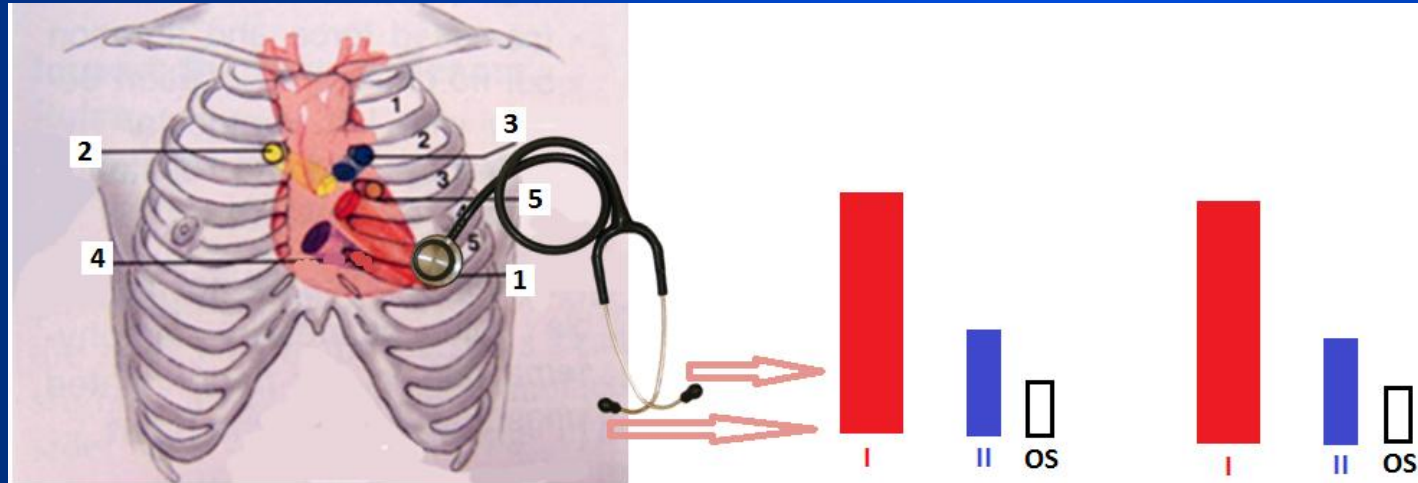
# Reduplication and splitting of the heart sounds

- **Pathological splitting of  $S_2$**
- A delay in aortic valve closure causing  $P_2$  to precede  $A_2$  results in so-called **reversed (paradoxical) splitting of  $S_2$** . The most common causes of reversed splitting of  $S_2$  are left bundle branch block and delayed excitation of the left ventricle from a right ventricle ectopic beat. Mechanical prolongation of the left ventricular systole, resulting in reversed splitting of  $S_2$ , also may be caused by severe aortic outflow obstruction, a large aorta-to-pulmonary artery shunt, systolic hypertension, and coronary heart disease or cardiomyopathy with left ventricular failure.



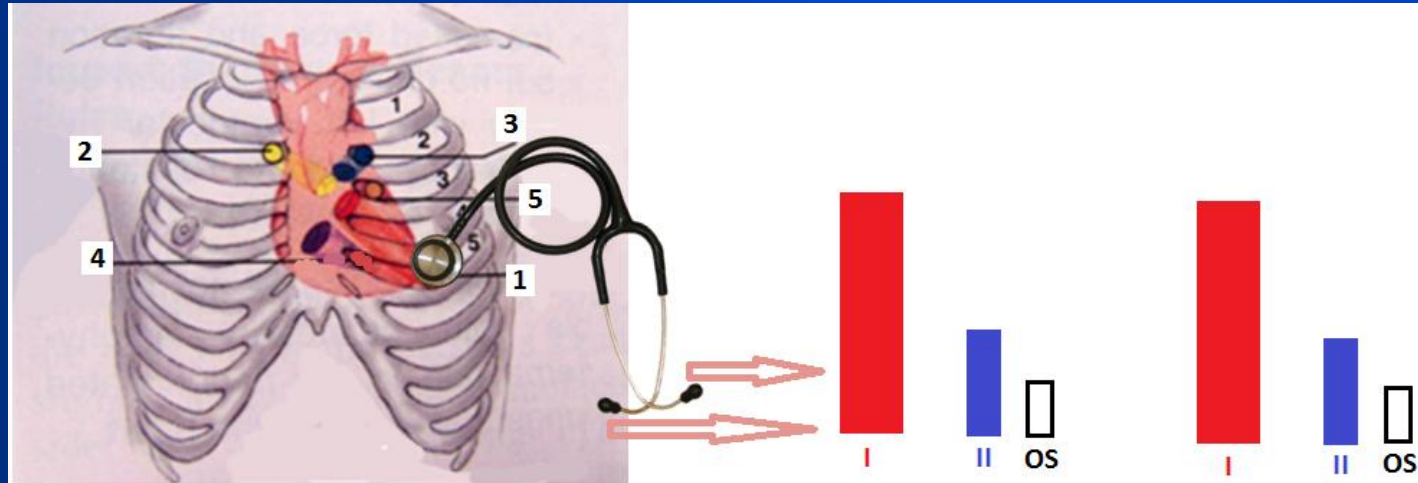
# Three-sound rhythms

- **Triple rhythm** is three-sound rhythm, which is heard at the heart apex in the patient with mitral stenosis.
- Triple rhythm consists of loud (snapping)  $S_1$ , normal  $S_2$  and additional sound, which is heard 0.07-0.13 s following  $S_2$ , and termed OS (opening snap).
- In mitral stenosis blood thrusts against the sclerosed valve, cusps of which cannot freely move, to produce OS. The opening snap is a brief, high-pitched, early diastolic sound.




# Three-sound rhythms

- **Triple rhythm** is three-sound rhythm, which is heard at the heart apex in the patient with mitral stenosis.
- Triple rhythm consists of loud (snapping)  $S_1$ , normal  $S_2$  and additional sound, which is heard 0.07-0.13 s following  $S_2$ , and termed OS (opening snap).
- In mitral stenosis blood thrusts against the sclerosed valve, cusps of which cannot freely move, to produce OS. The opening snap is a brief, high-pitched, early diastolic sound.



# Gallop rhythm

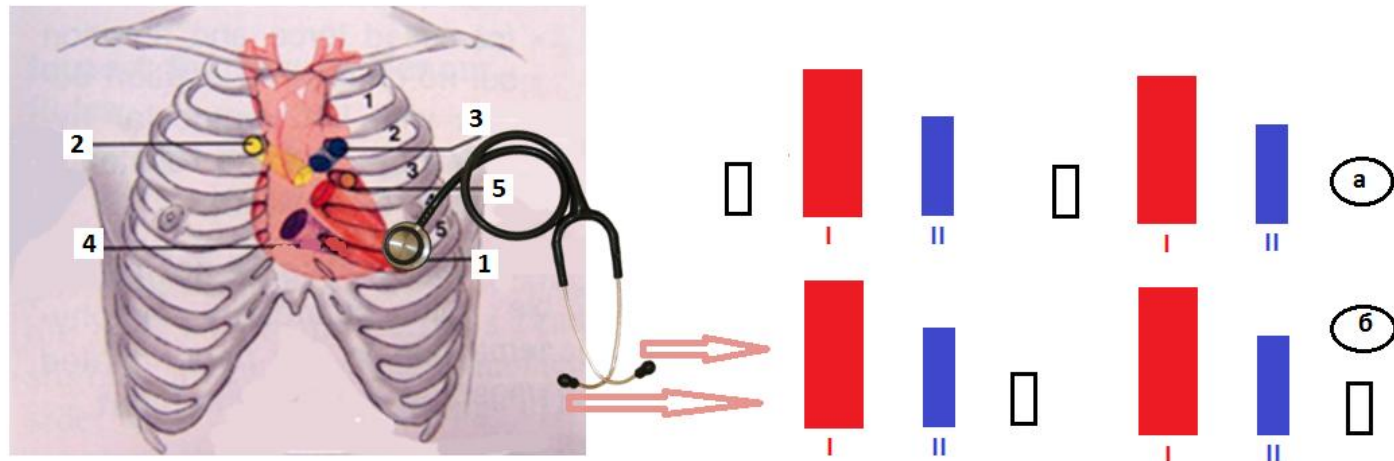
Three-sound rhythm of a peculiar acoustic character, termed gallop rhythm, is also of considerable diagnostic value. The sounds of gallop rhythm are usually soft and low, resemble the galloping of a horse, and are best heard in direct auscultation. Gallop rhythm is heard as three separate audibly distinct sounds in approximately equal intervals.





# Gallop rhythm

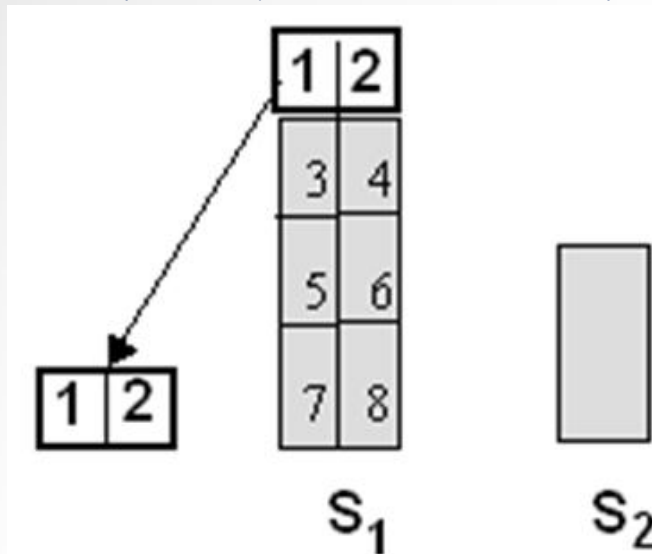
- Gallop rhythm is classified as **presystolic** (at the end of diastole), **protodiastolic** (at the beginning of diastole), and **mesodiastolic** (at the middle of the diastole) depend on the time of appearance of the extra sound in diastole.



# Gallop rhythm

- Presystolic gallop rhythm occurs due to delayed atrioventricular conduction, when atrial systole is separated from the ventricular systole by a longer than normal period, and is heard as separate sound

Three-sound rhythm at the heart apex, in which  $S_1$  is decreased, and the first sound is weakest - is presystolic gallop rhythm.



•

# Presystolic gallop rhythm is heard in the patients with:

- Rheumocarditis;
- Cardiosclerosis;
- Essential hypertension;
- Mitral stenosis;
- Chronic nephritis with  
arterial hypertension  
syndrome;
- Toxic and infectious  
affection of the myocardium.

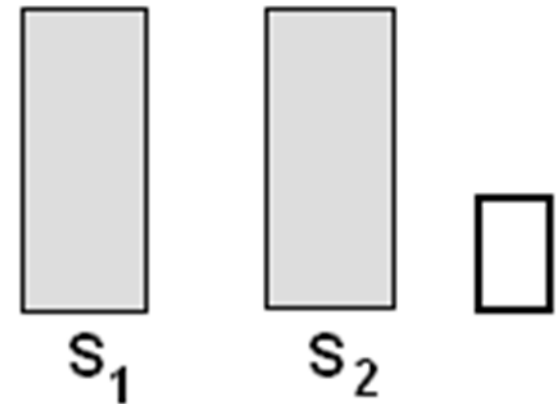


# Gallop rhythm

Protodiastolic gallop rhythm is caused by appearance of pathological additional sound 0.12 - 0.02 s after  $S_2$  as a result of considerably decreased tone of the ventricular myocardium.

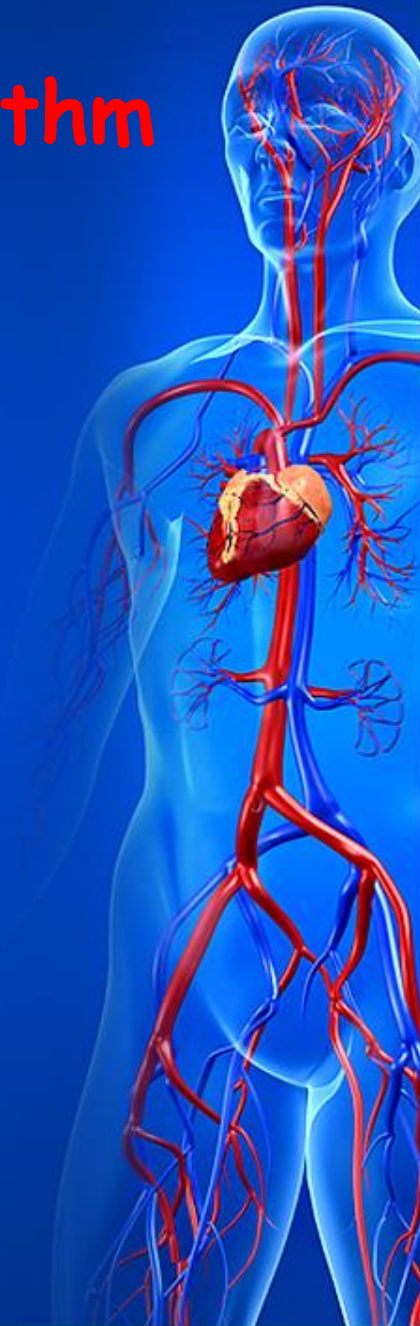Ventricles distended quickly during their filling with blood at the beginning of the diastole and the vibrations thus generated are audible as an extra sound.

- Three-sound rhythm at the heart apex, in which  $S_1$  is decreased, and the third sound is weakest - is protodiastolic gallop rhythm.



# Protodiastolic gallop rhythm

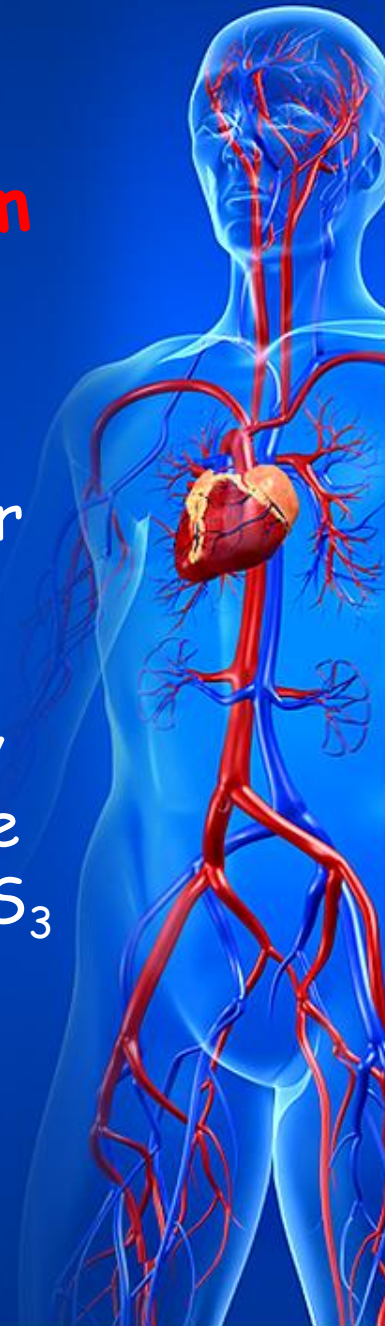
- This auscultation phenomenon is observed in the patients with:
- Acute and chronic myocarditis;
  - Myocardiosclerosis;
  - Heart failure;
  - Toxicosis;
  - Thyrotoxicosis;
  - Anaemias



## Mesodiastolic (summation) gallop rhythm

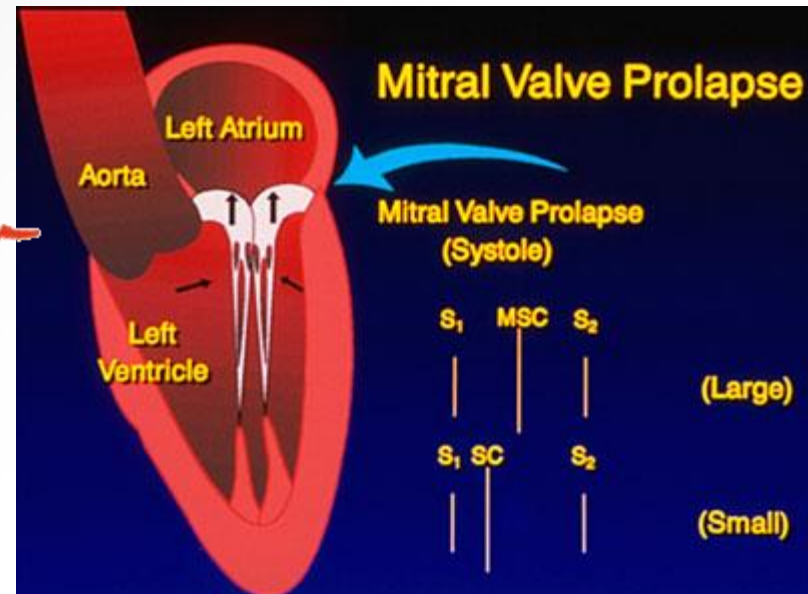
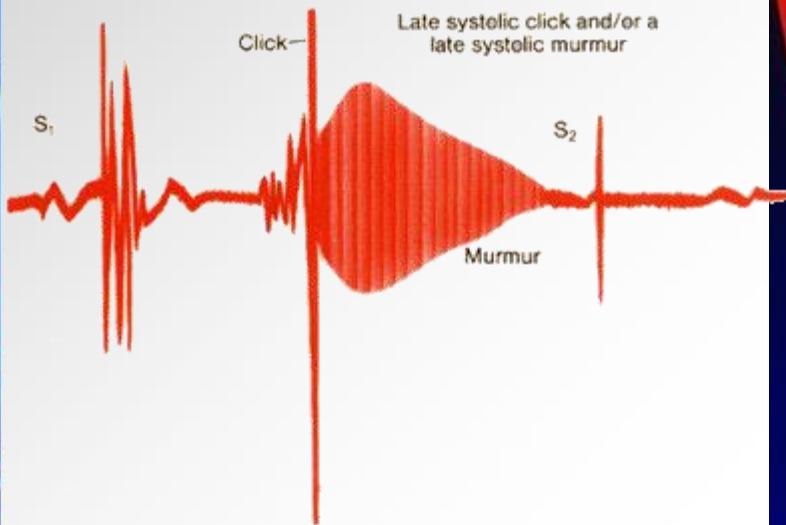
arises in severe dystrophic affection of the myocardium in the patients with myocardial infarction, essential hypertension, heart valvular diseases, myocarditis and chronic nephritis.

Mesodiastolic gallop rhythm is characterized by appearance of the additional sound in the middle of diastole caused by increase intensity of the  $S_3$  and  $S_4$ , which are heard as one gallop sound.



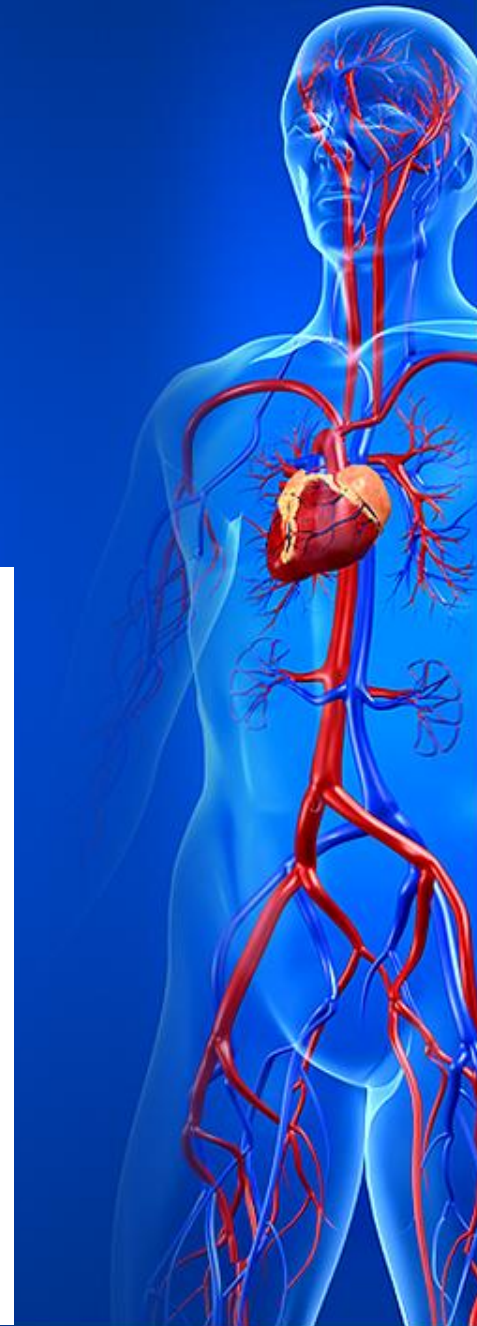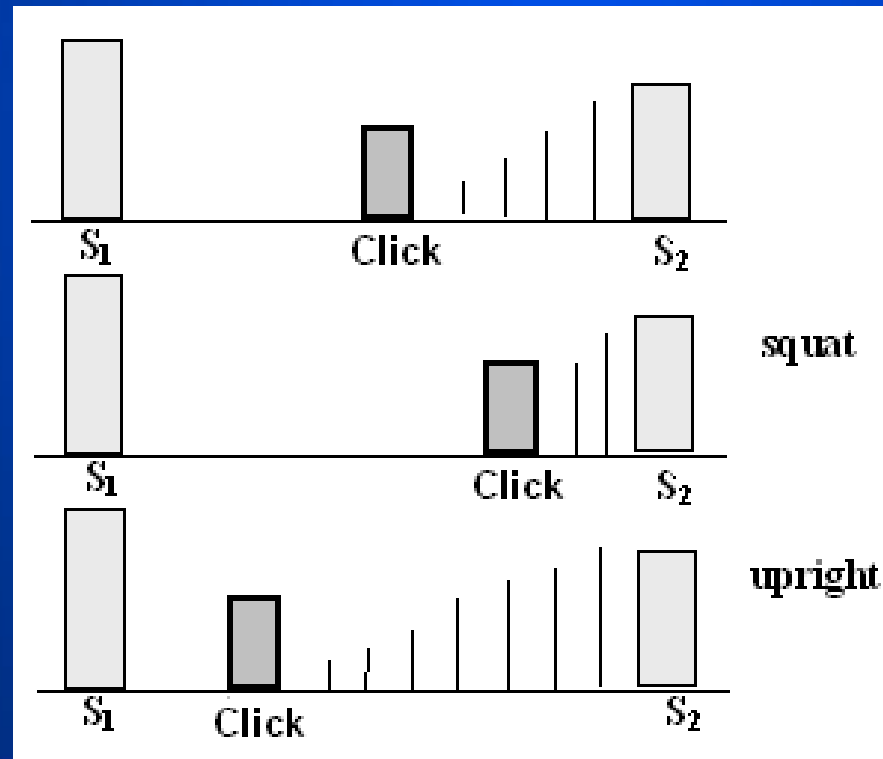
# Systolic clicks

**Systolic clicks** - auscultation phenomenon, which denote prolapse of one or both cusps of the mitral valve. They also may be caused by tricuspid valve prolapse. Auscultation symptomatic may be very different: systolic clicks may be single or multiple, they may occur at any time in systole with or without a late systolic murmur.



# Systolic clicks

- Typical peculiarity - changes of the auscultation data depend on position of the patient and exercise test. If the patient squat click and murmur slightly delayed; in the upright posture click and murmur are closer to  $S_1$

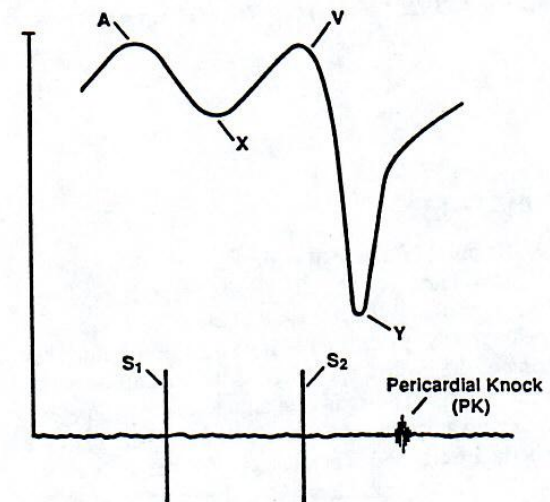




# Pericardial knock

- **Pericardial knock** - high-pitched sound occurs 0.01 - 0.06s after  $S_2$  in the patients with constrictive pericarditis due to vibration of the adherent pericardium in abrupt dilation of the ventricle at the beginning of diastole.
- Pericardial knock is better heard at the heart apex or medially toward to xiphoid.

CONSTRUCTIVE PERICARDITIS



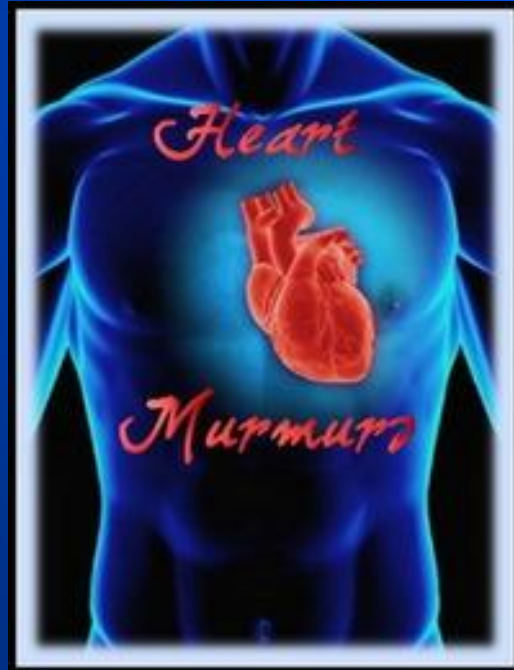
# Embryocardial or pendulum rhythm

- Embryocardial or pendulum rhythm occurs in severe heart failure, attacks of paroxysmal tachycardia, high fever, etc.
- Tachycardia makes diastolic pause almost as short as the systolic one.
- A peculiar auscultative picture, in which heart sounds are similar in intensity, resembles foetal rhythm is termed embryocardia.



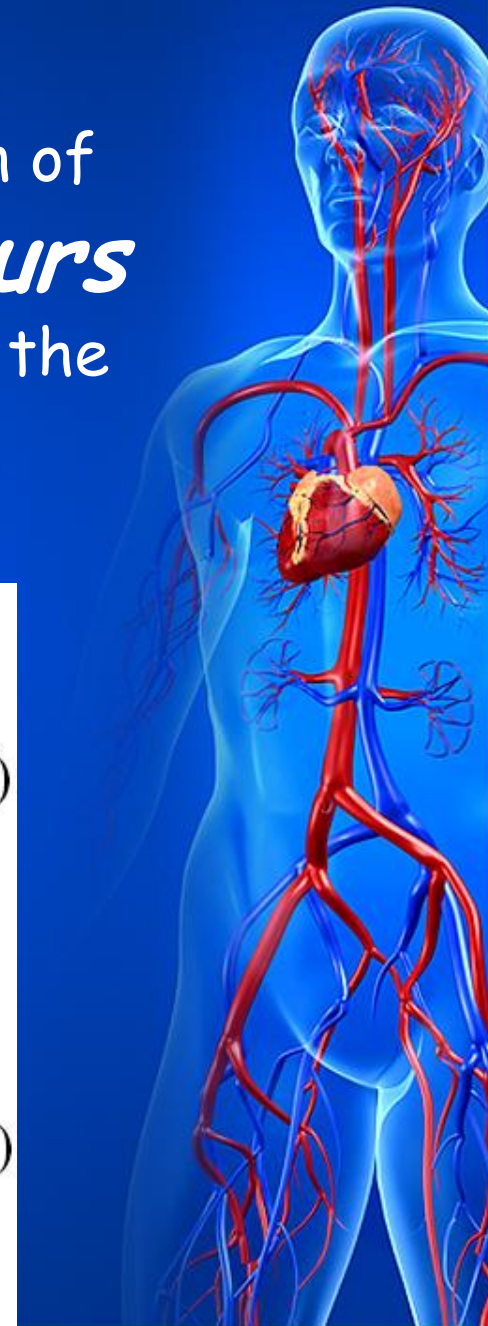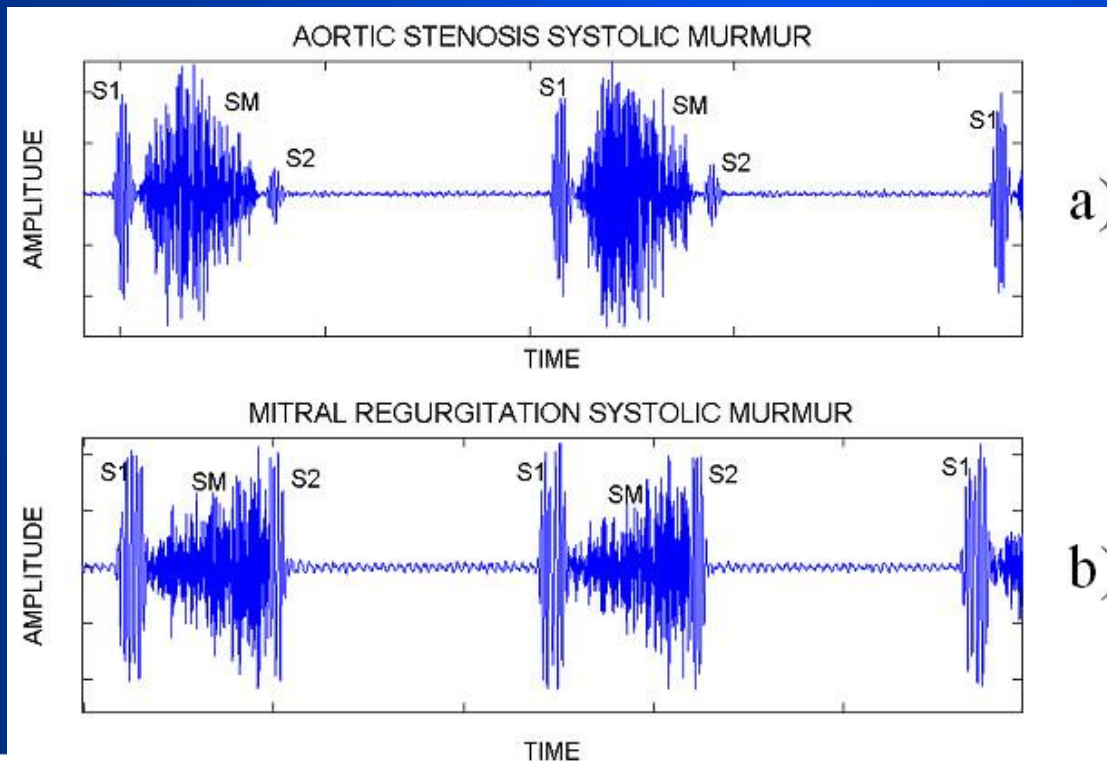
# Cardiac murmurs

- In addition to the normal heart sounds, abnormal sounds known as murmurs may be heard in auscultation. Cardiac murmurs may be both endocardiac and exocardiac.



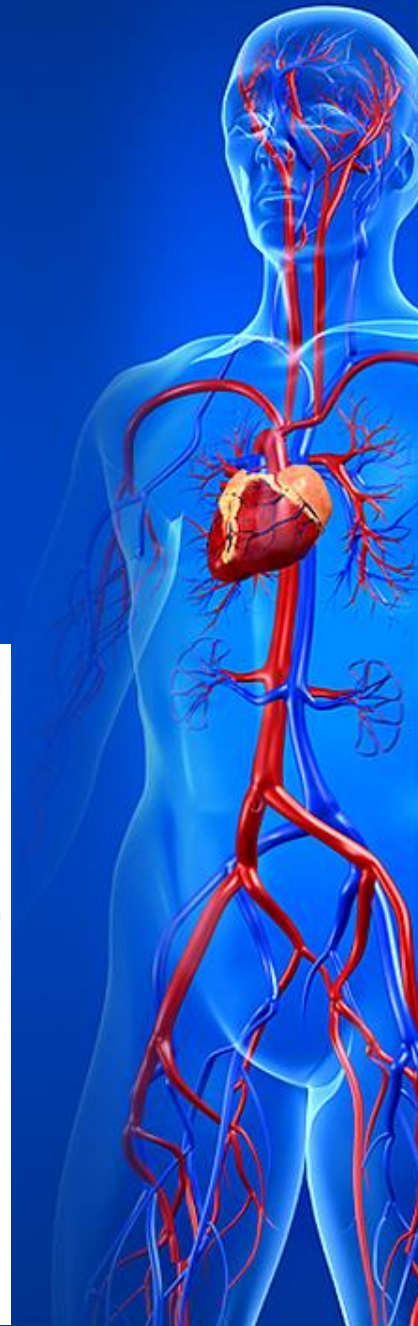
# Cardiac murmurs

- **Endocardiac** murmurs occur in dysfunction of the intact valves - *functional murmurs* or in anatomical changes in the structure of the heart valves - *organic murmurs*.



# Cardiac murmurs

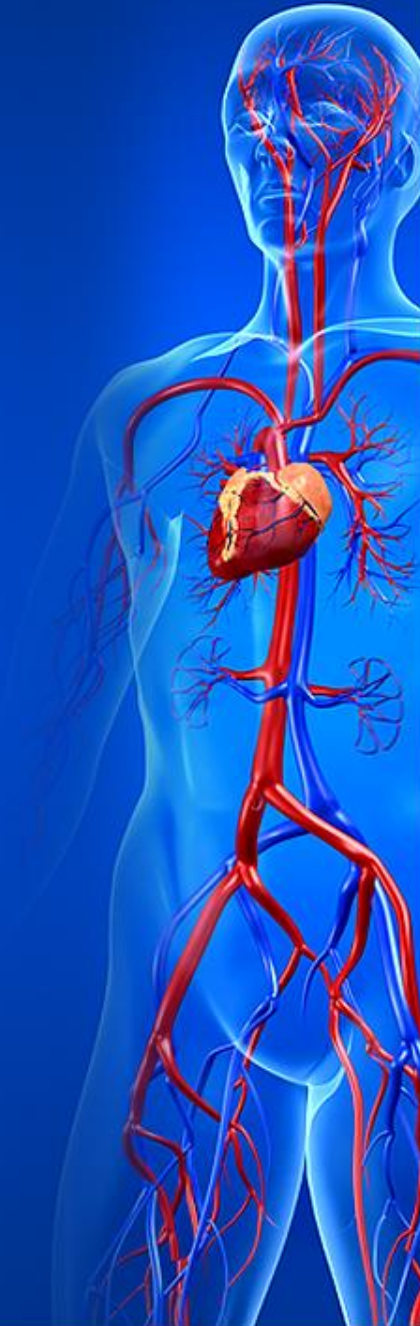- When a valve is stenotic or damaged, the abnormal turbulent flow of blood produces a murmur, which can be heard during the normally quiet times of systole or diastole.



# Cardiac murmurs

Characteristics used to describe cardiac murmurs are:

- timing,
- intensity,
- pitch,
- quality,
- configuration,
- duration,
- location
- radiation

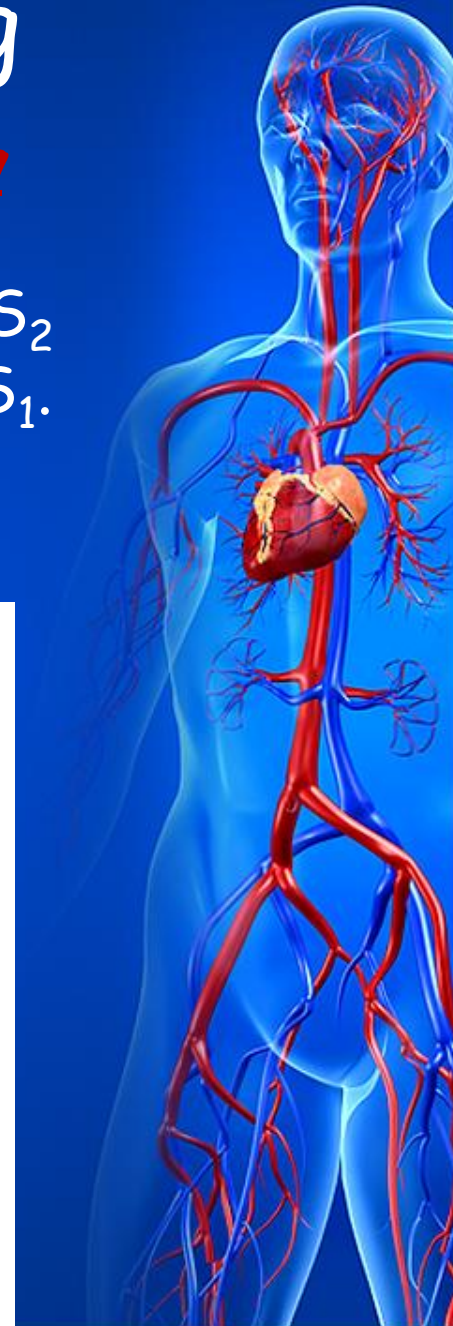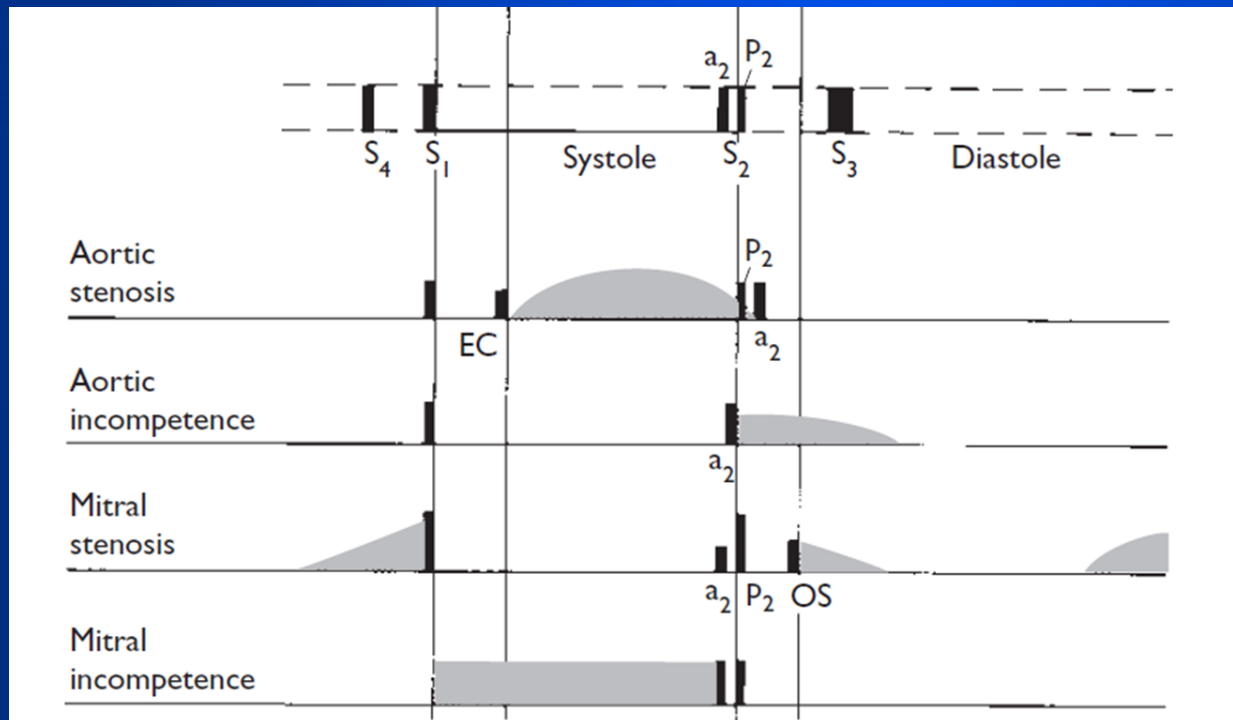


# Cardiac murmurs: Timing

Murmurs are defined in terms of their timing within the cardiac cycle.

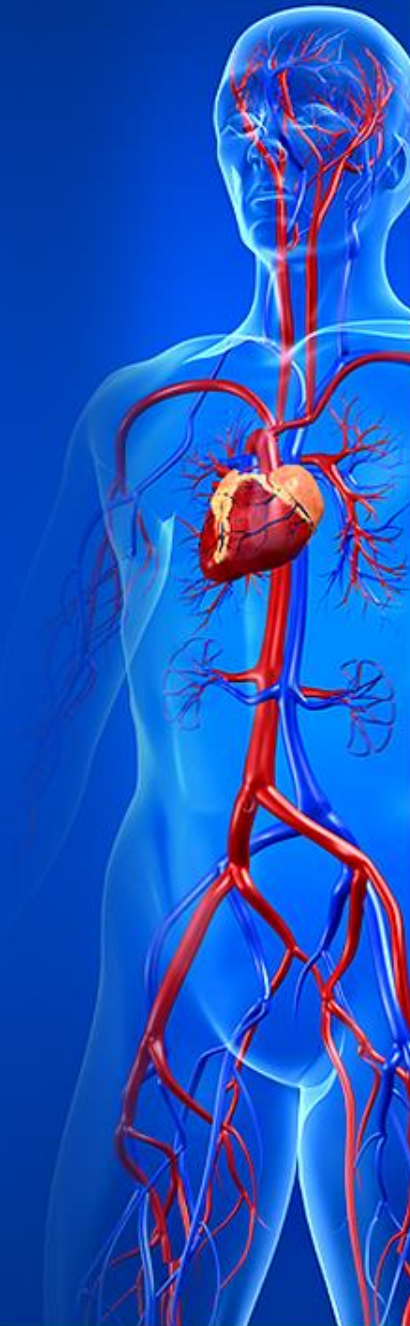*Systolic murmur* terminates between  $S_1$  and  $S_2$  or begins instead of significantly decreased  $S_1$ .

*Diastolic murmur* begins with or after  $S_2$  and terminates at or before the subsequent  $S_1$ .



# Cardiac murmurs: Intensity

- The *intensity* of the murmurs is graded according to the
- **Levine scale**:
- **Grade I** - Lowest intensity, difficult to hear even by expert listeners
- **Grade II** - Low intensity, but usually audible by all listeners
- **Grade III** - Medium intensity, easy to hear even by inexperienced listeners, but without a palpable thrill
- **Grade IV** - Medium intensity with a palpable thrill
- **Grade V** - Loud intensity with a palpable thrill. Audible even with the stethoscope placed on the chest with the edge of the diaphragm
- **Grade VI** - Loudest intensity with a palpable thrill. Audible even with stethoscope raised above the chest.



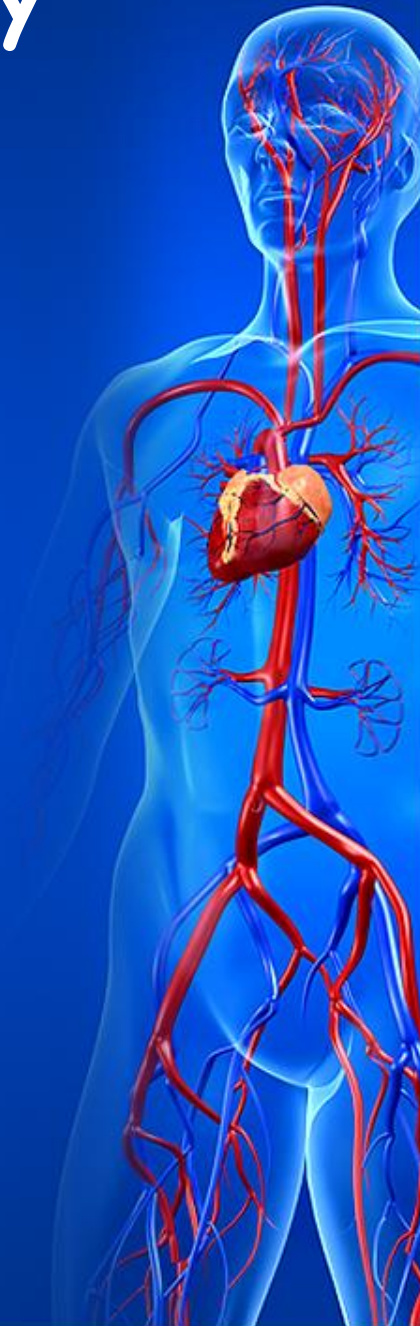

# Cardiac murmurs: Pitch, quality

A cardiac murmur's *pitch* varies from high to low.

Common descriptive terms of a murmur's *quality* include

- rumbling,
- blowing,
- machinery,
- scratchy,
- harsh,
- rough,
- squeaky,
- musical.



# Cardiac murmurs: Configuration

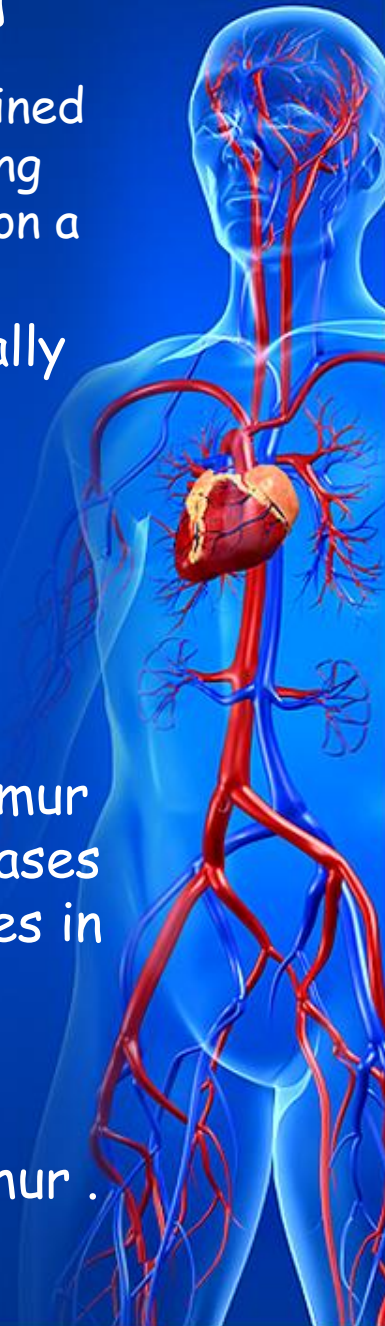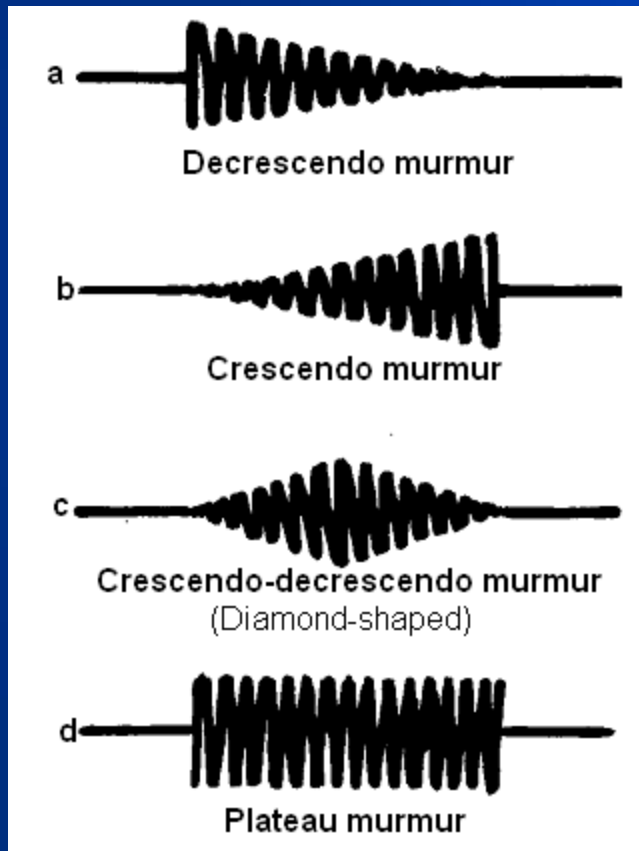
The **configuration of murmur** is defined by changes in their intensity during systole and diastole as recorded on a phonocardiogram .

A **decrescendo** murmur gradually decreases in intensity

a **crescendo** murmur gradually increases in intensity

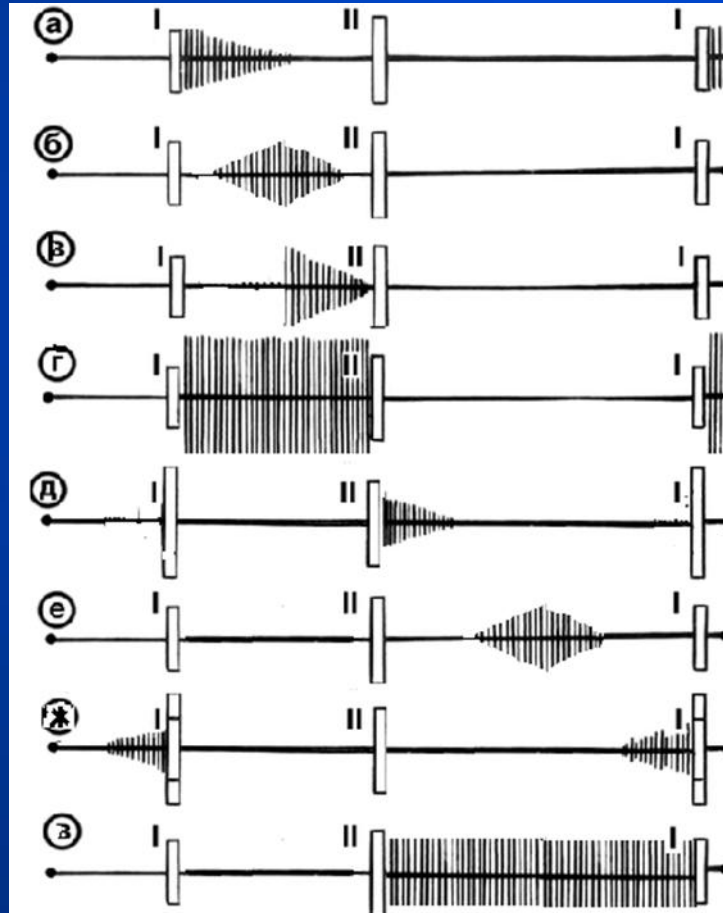
a **crescendo-decrescendo** murmur (a diamond-shaped) first increases in intensity, and then decreases in intensity

a **plateau** murmur is equal in intensity throughout the murmur .

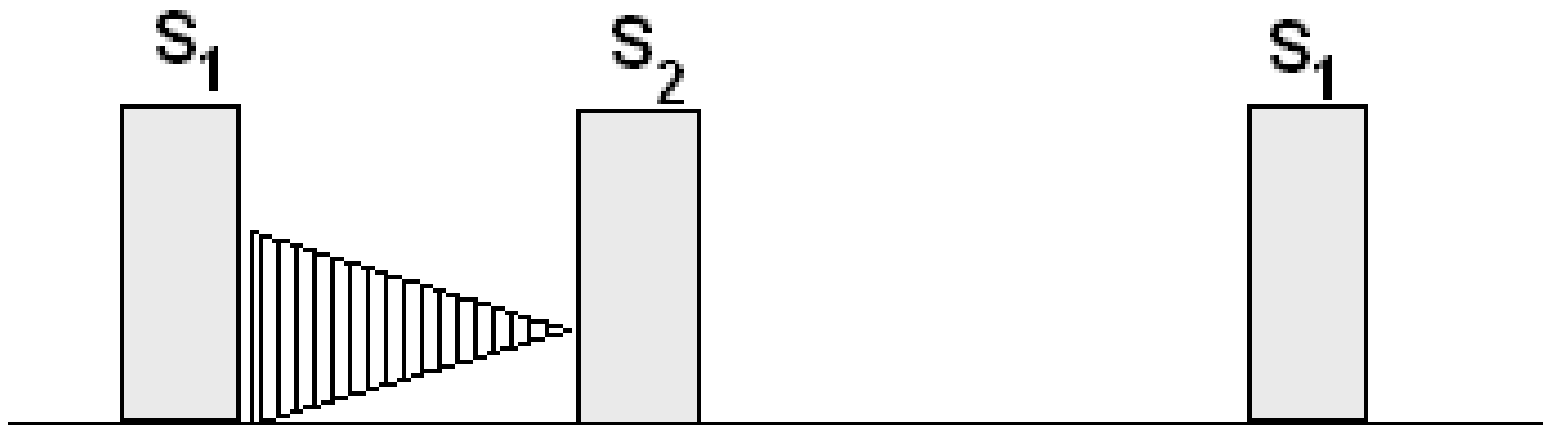


# Cardiac murmurs: Duration

- A murmur's *duration* can be of different length



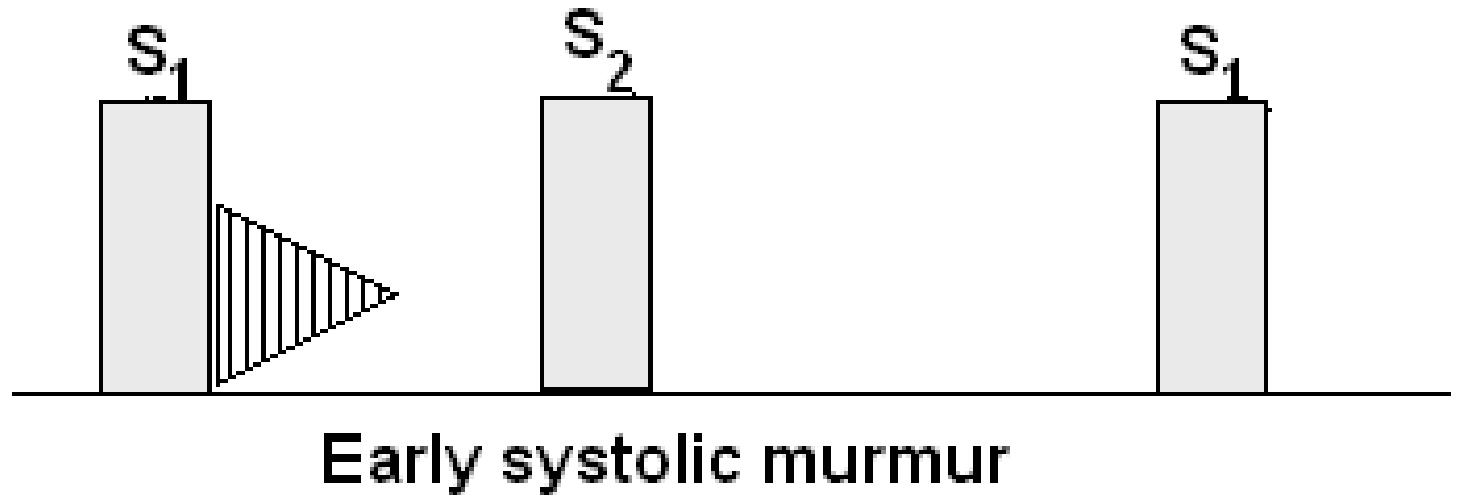
# Systolic murmurs



Holosystolic (pansystolic) murmur

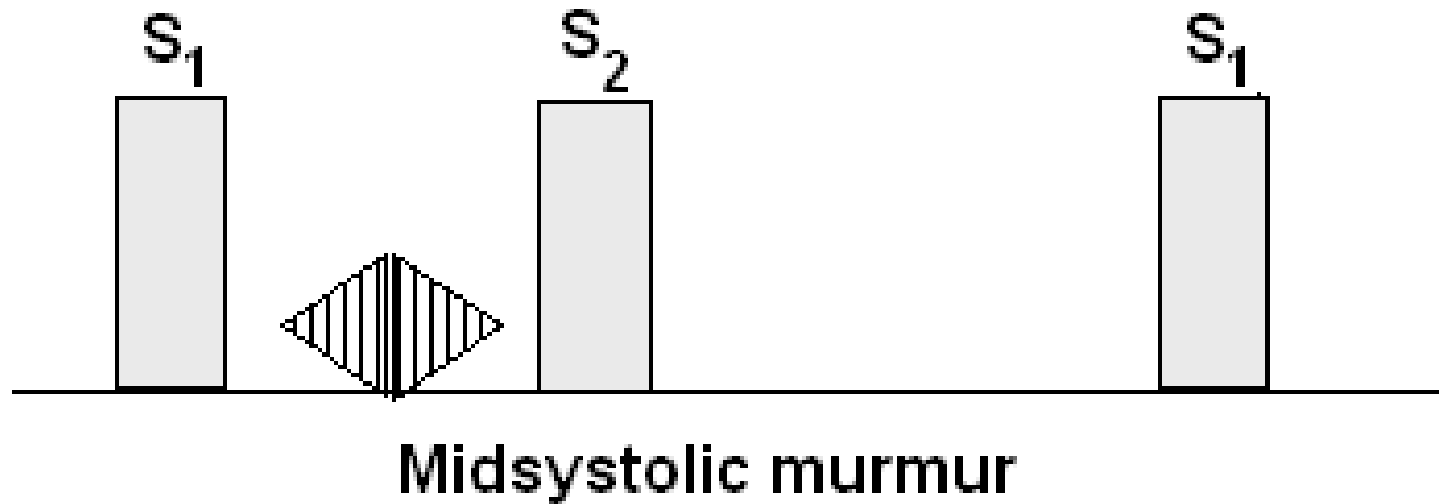
- begin with  $S_1$  and continue through all systole to  $S_2$ .

# Systolic murmurs



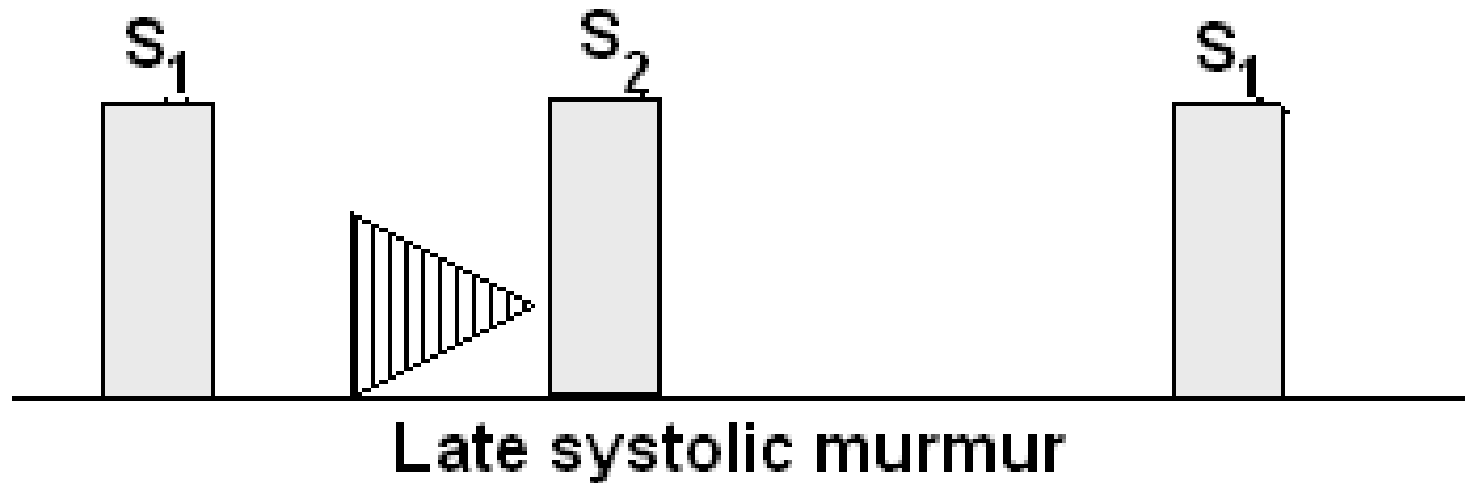
- begins with  $S_1$  and extend for a variable period of time, ending well before  $S_2$ .

# Systolic murmurs



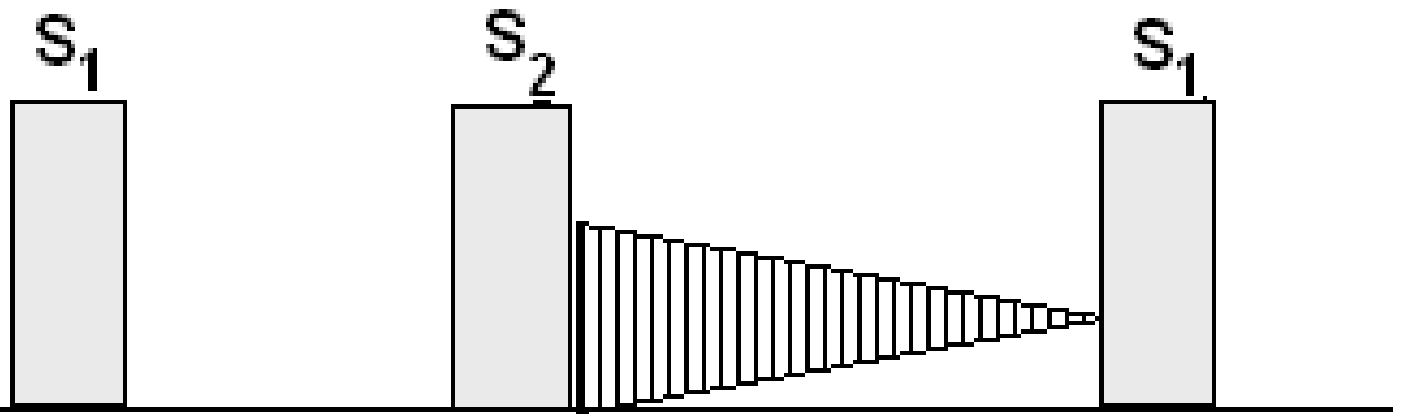
- begins at a short interval following  $S_1$ , end before  $S_2$ , and are usually crescendo-decrescendo in configuration

# Systolic murmurs



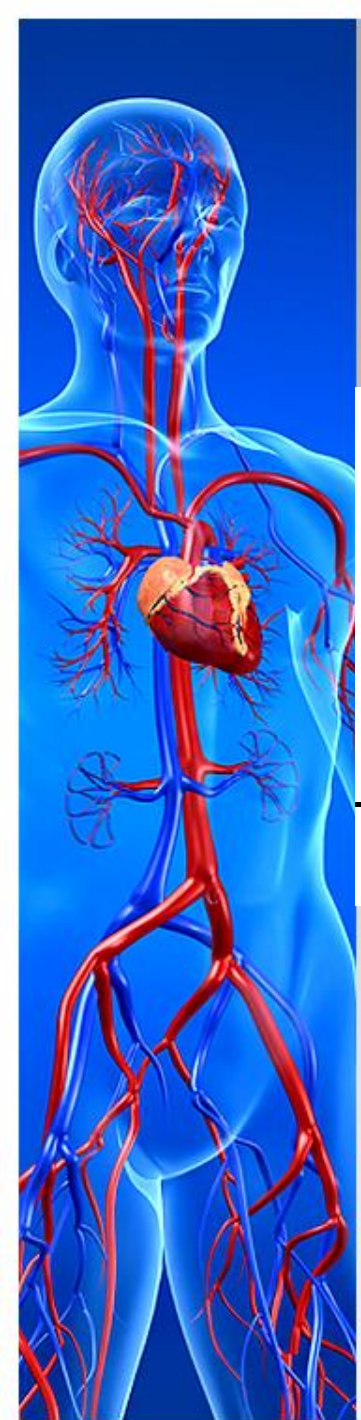- begins well after the onset of ejection that is at the end of systole.

# Diastolic murmurs



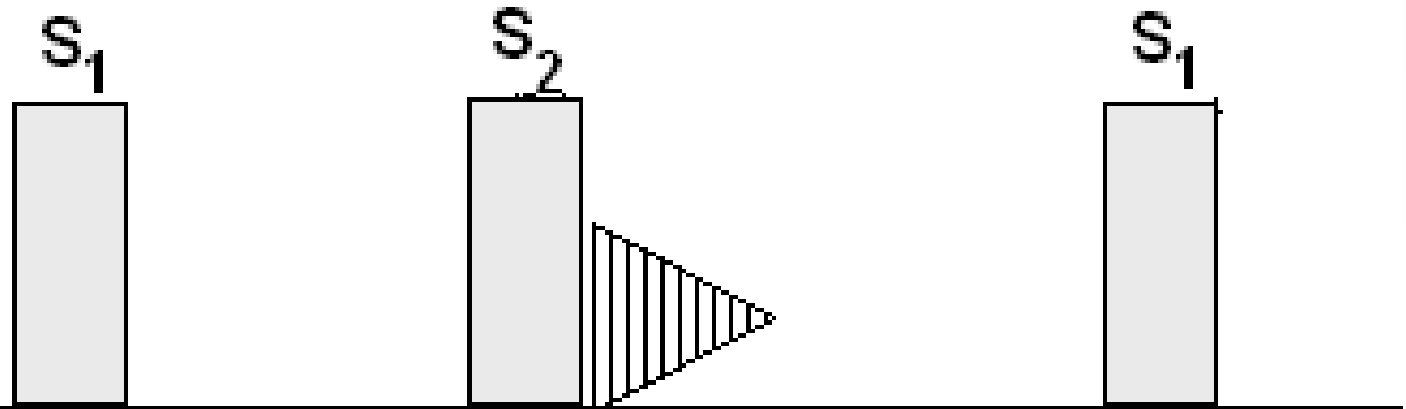
**Holodiastolic (pandiatolic) murmur**

- begins after  $S_2$  and continue through all diastole to  $S_1$ .





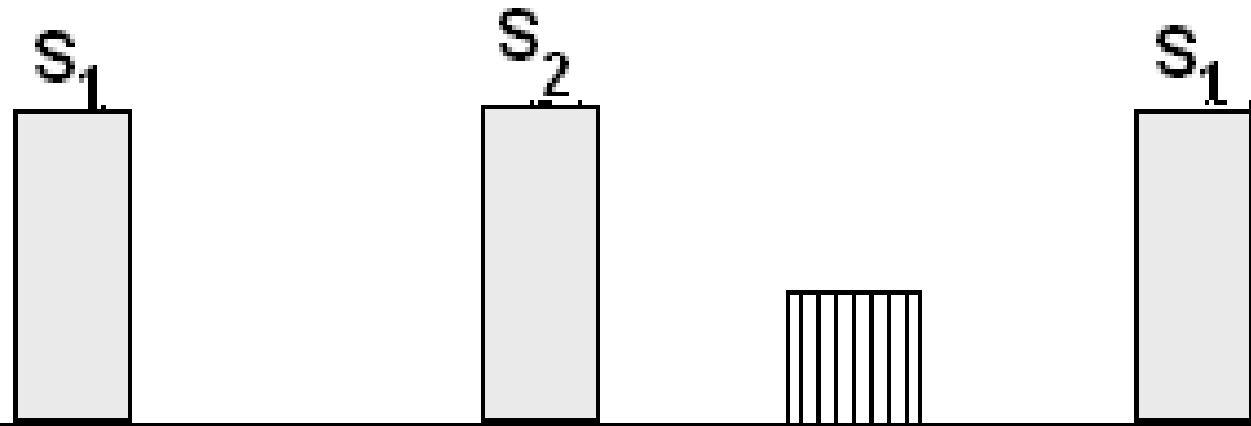
# Diastolic murmurs



Early diastolic (protodiastolic) murmur

- begins with  $S_2$  and ends well before  $S_2$ , usually decrescendo in configuration.

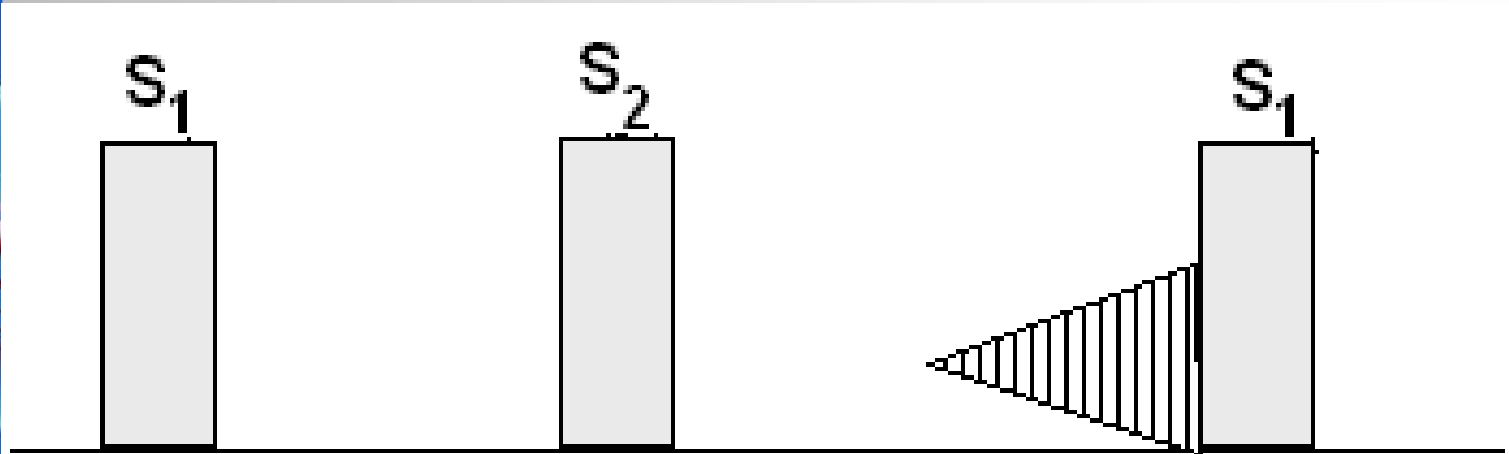
# Diastolic murmurs



Middiastolic (mesodiastolic) murmur

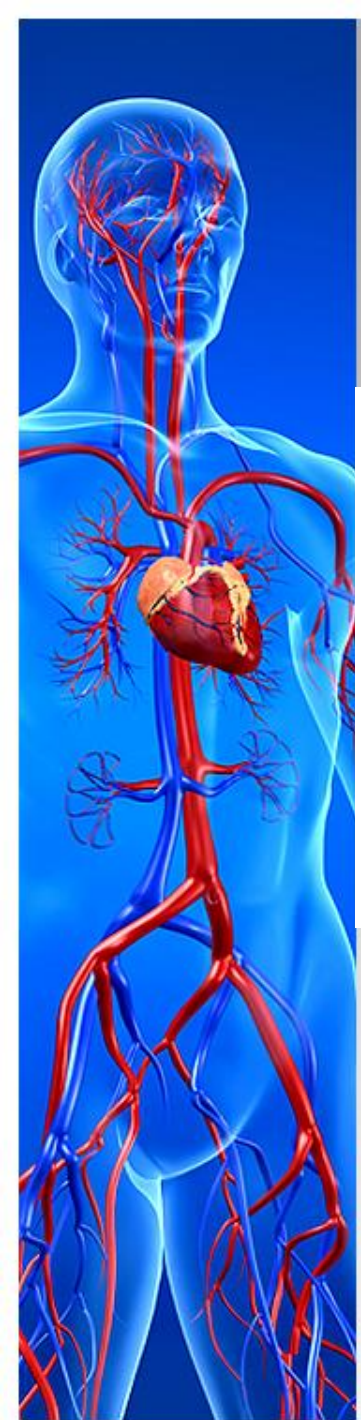- begins at a short interval following  $S_2$ , end before  $S_2$

# Diastolic murmurs



Presystolic murmur

- begins at the end of diastole, usually crescendo in configuration.

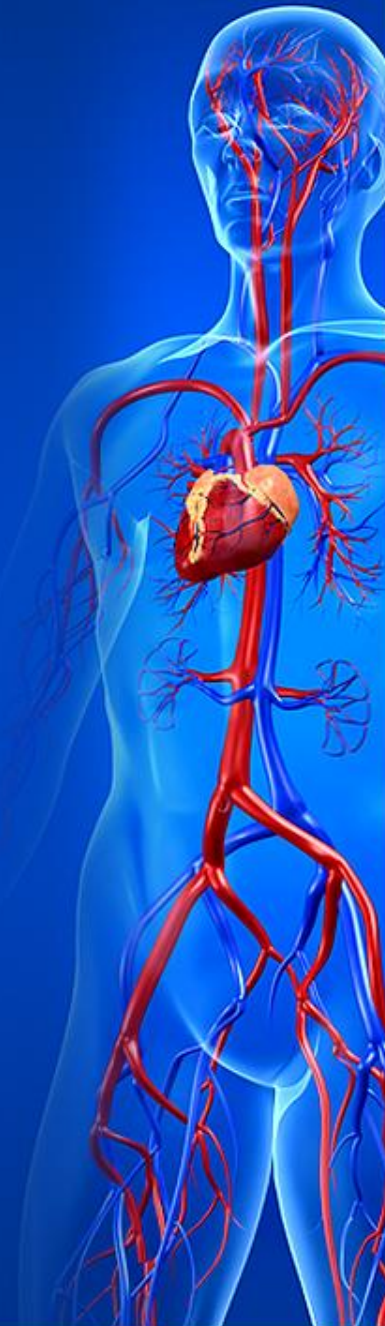

# Cardiac murmurs: Location

Cardiac murmurs may not be audible over all areas of the chest, and it is important to note where it is heard best and where it radiate to.

The location on the chest wall where the murmur is best heard and the areas to which it radiates can be helpful in identifying the cardiac structure from which the murmur originates.

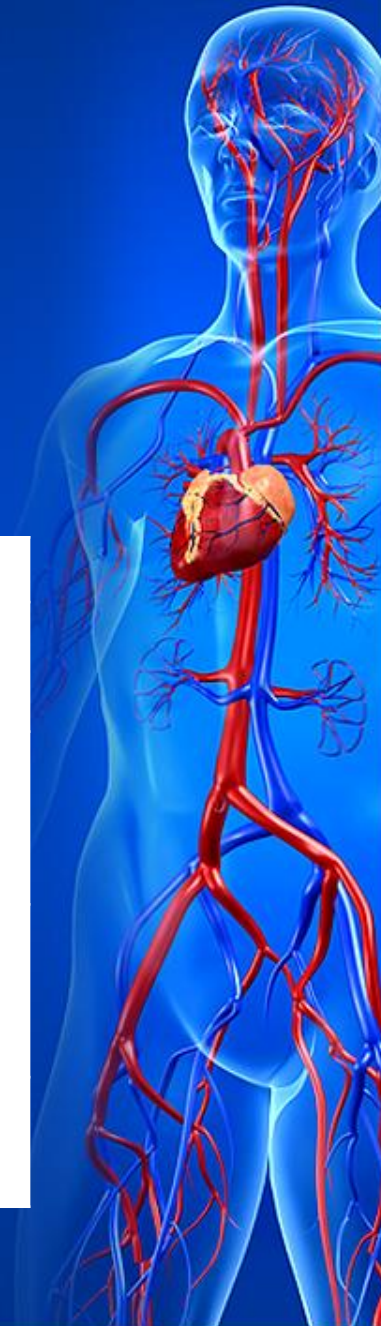Best auscultatory areas of a cardiac murmurs. Topographic classification of murmurs.



# Cardiac murmurs: Location

Best auscultatory areas of a cardiac murmurs. Topographic classification of murmurs.

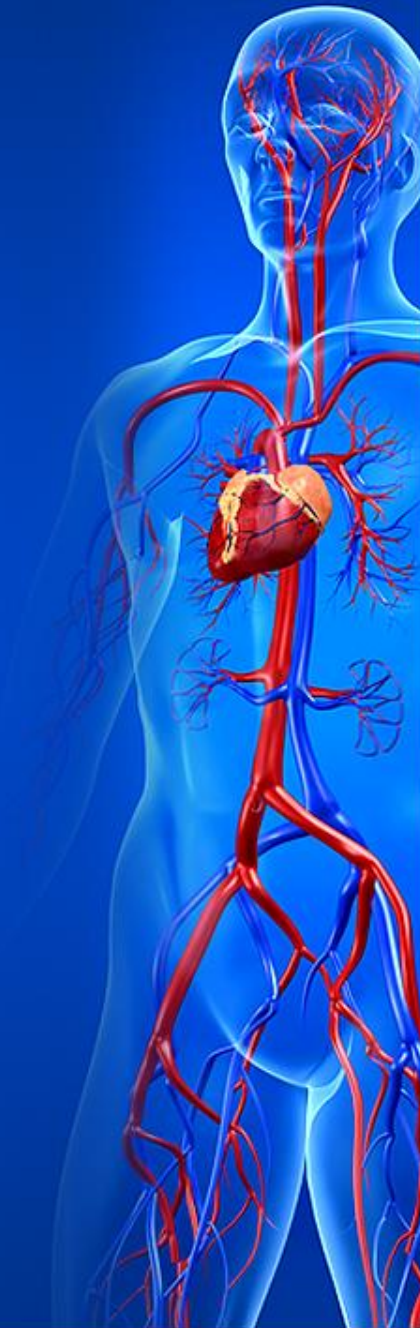Auscultatory areas	Murmur	Heart valvular disease
Heart apex	Systolic Diastolic	Mitral regurgitation Mitral stenosis
Second intercostal space at the right sternal edge	Systolic Diastolic	Aortic stenosis Aortic regurgitation
Second intercostal space at the left sternal edge	Systolic Diastolic	Pulmonary stenosis Pulmonary regurgitation
Base of the ziphoid	Systolic Diastolic	Tricuspid regurgitation Tricuspid stenosis



# Cardiac murmurs: Radiation

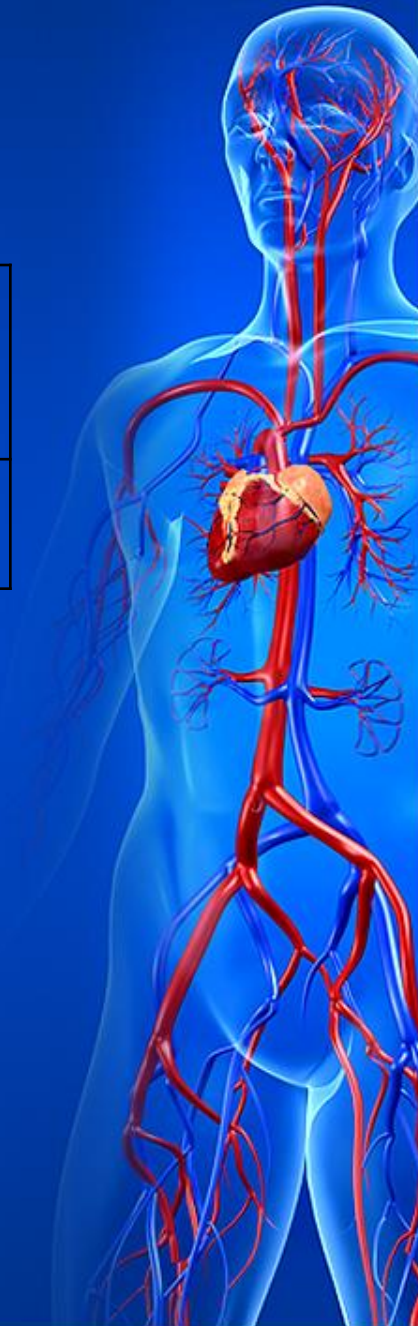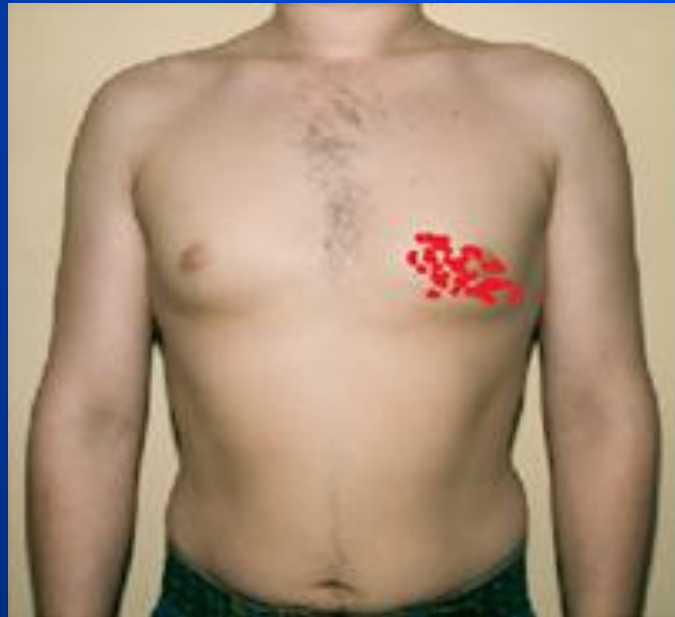Some cardiac murmurs may be heard not only in standard auscultatory areas but also transmitted in the direction of blood flow.

This phenomenon is known as radiation. Murmurs radiate in either a forward (ejection murmurs) or backward direction (regurgitation murmurs).



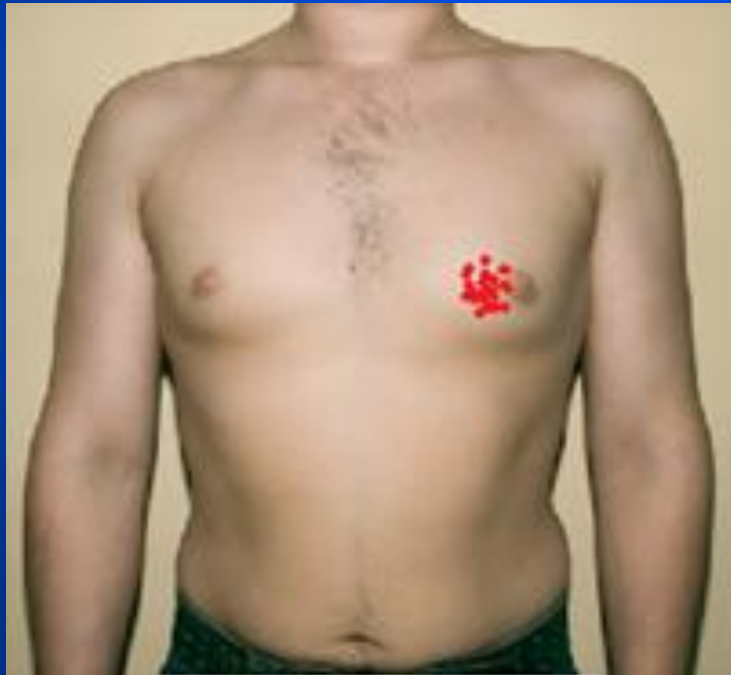# Cardiac murmurs: Radiation

Heart valvular disease	Murmur	Auscultatory areas	Radiation areas
Mitral regurgitation	Systolic	Heart apex	Axillary region



# Cardiac murmurs: Radiation

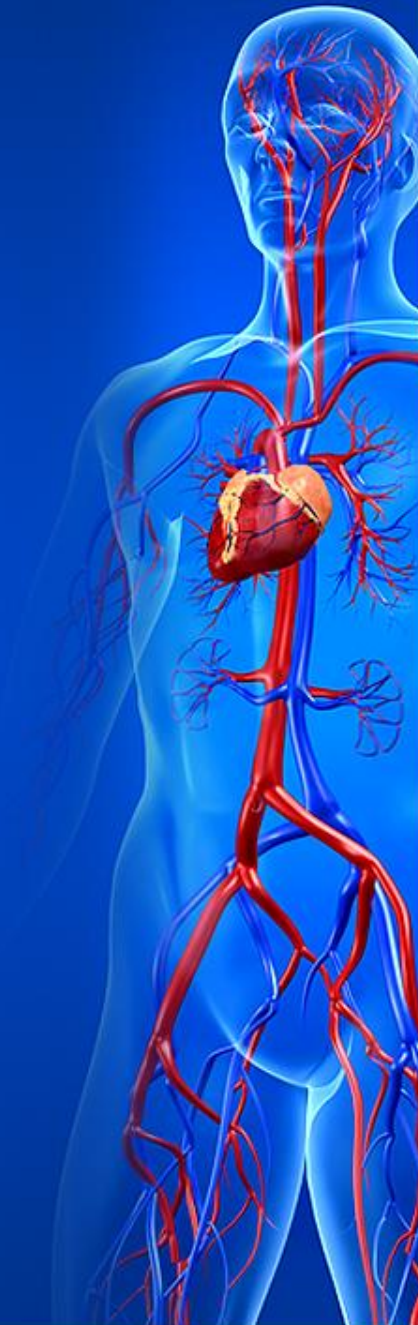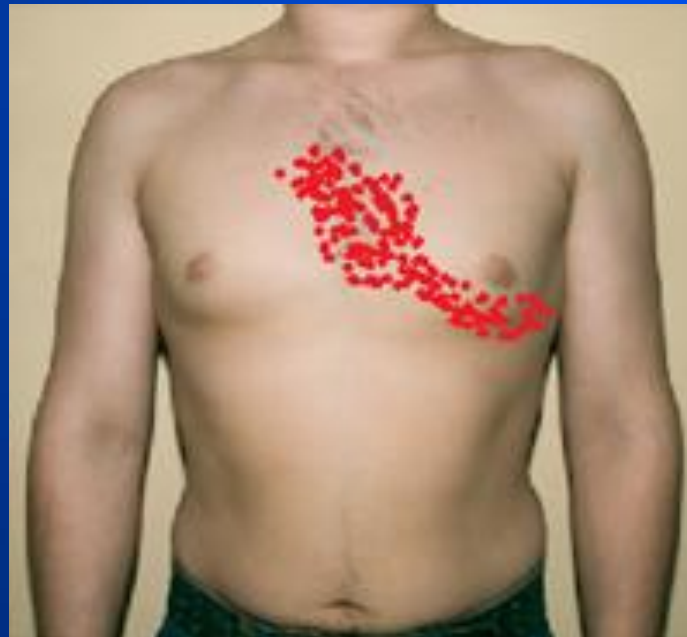Heart valvular disease	Murmur	Auscultatory areas	Radiation areas
Mitral stenosis	Diastolic	Heart apex	No radiation





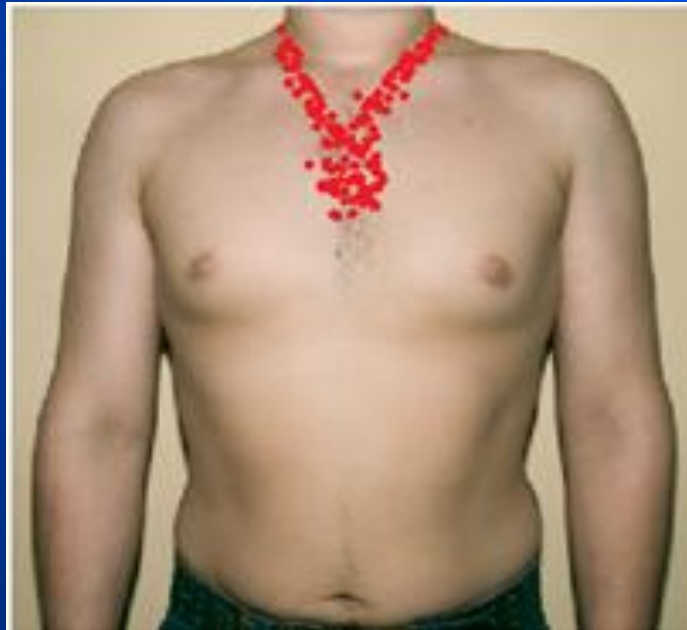# Cardiac murmurs: Radiation

Heart valvular disease	Murmur	Auscultatory areas	Radiation areas
Aortic regurgitation	Diastolic	Second intercostal space at the right sternal edge	Botkin-Erb's point, sometimes heart apex



# Cardiac murmurs: Radiation

Heart valvular disease	Murmur	Auscultatory areas	Radiation areas
Aortic stenosis	Systolic	Second intercostal space at the right sternal edge	Subclavian, carotid arteries, interscapular region

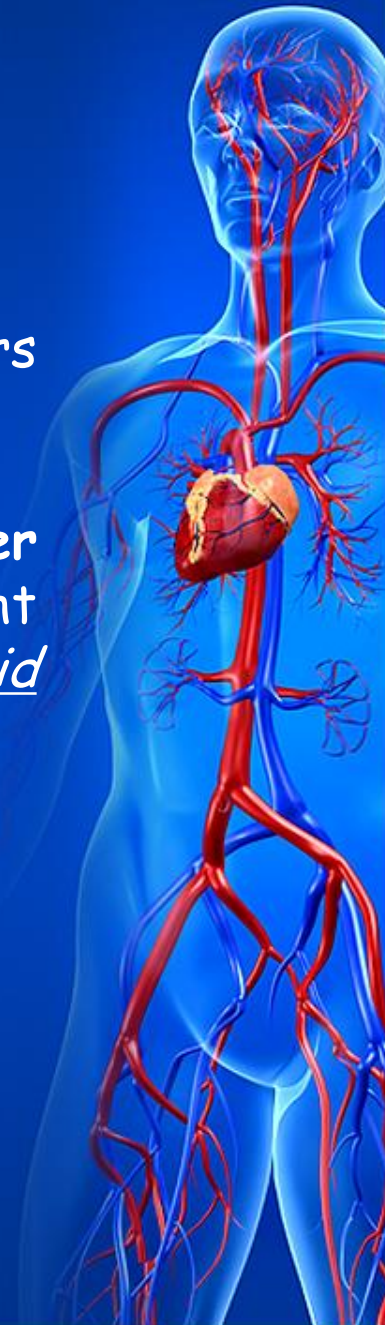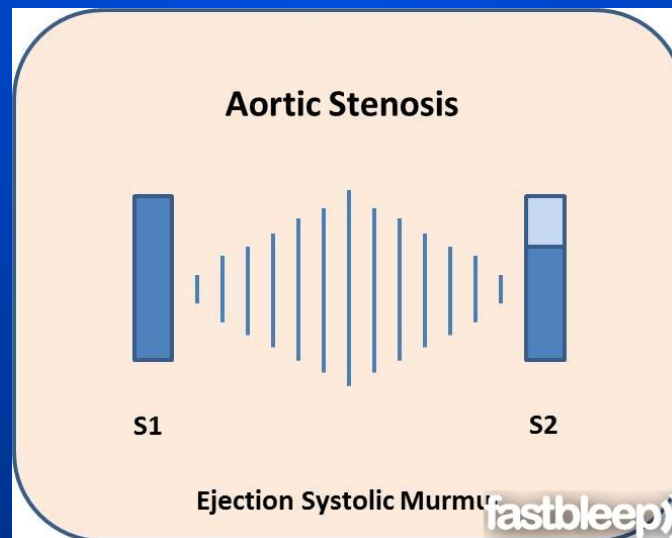
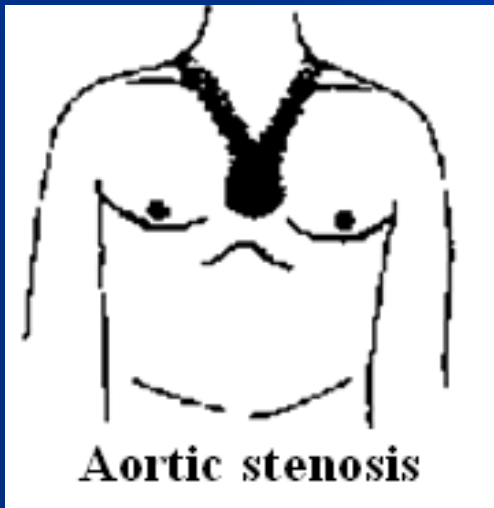


# SYSTOLIC MURMURS

## Aortic stenosis

One of the most frequent pathologic systolic murmurs is due to aortic stenosis.

The murmur of aortic stenosis heard best over "aortic area", second intercostal space along right sternal border, with radiation into the neck, along carotid arteries, into the interscapular region (ejection murmur).



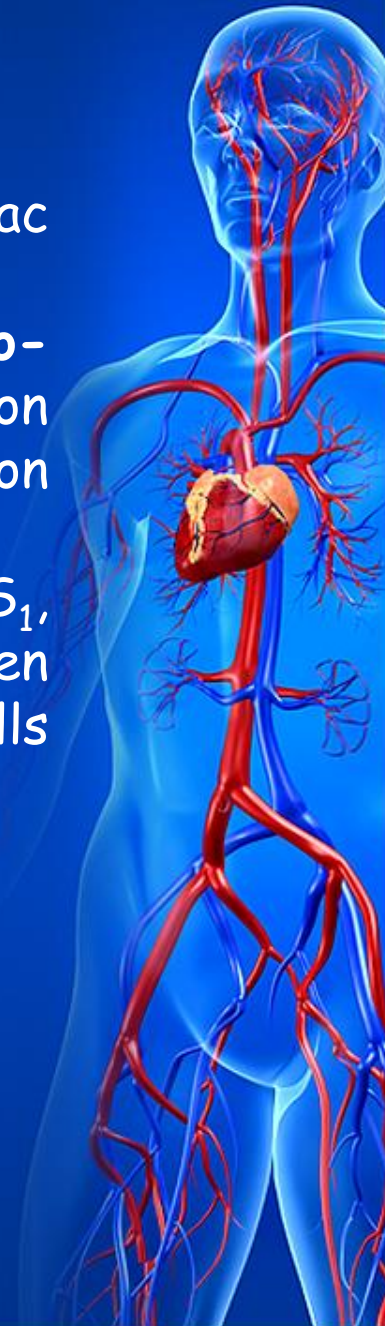
# SYSTOLIC MURMURS

## Aortic stenosis

The intensity of murmur varies directly with the cardiac output.

It has a harsh quality, are usually **crescendo-decrescendo** in configuration (as the velocity of ejection increases, the murmur gets stronger, and as ejection declines, its diminished),

is typically **midsystolic** murmur (starts shortly after  $S_1$ , when the left ventricular pressure becomes enough to open aortic valve; ends before left ventricular pressure falls enough to permit closure of the aortic leaflets).

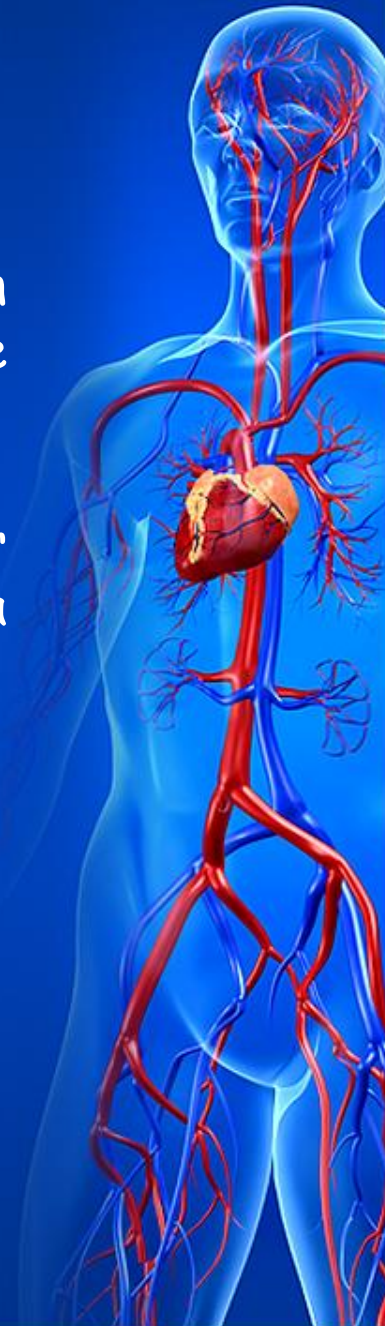


# SYSTOLIC MURMURS

## *Pulmonary stenosis*

The murmur of pulmonary stenosis is heard best in the "pulmonic area", second intercostal space along the left sternal border.

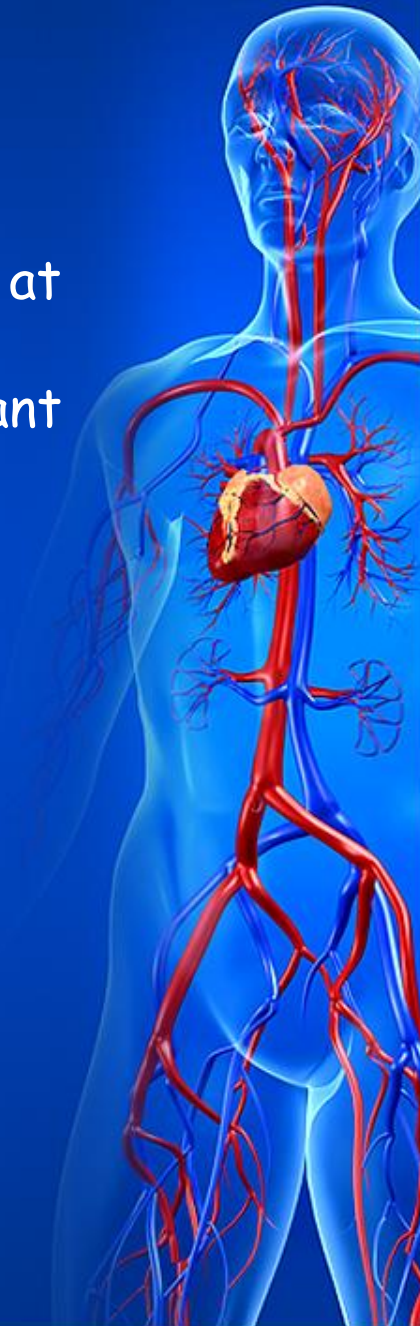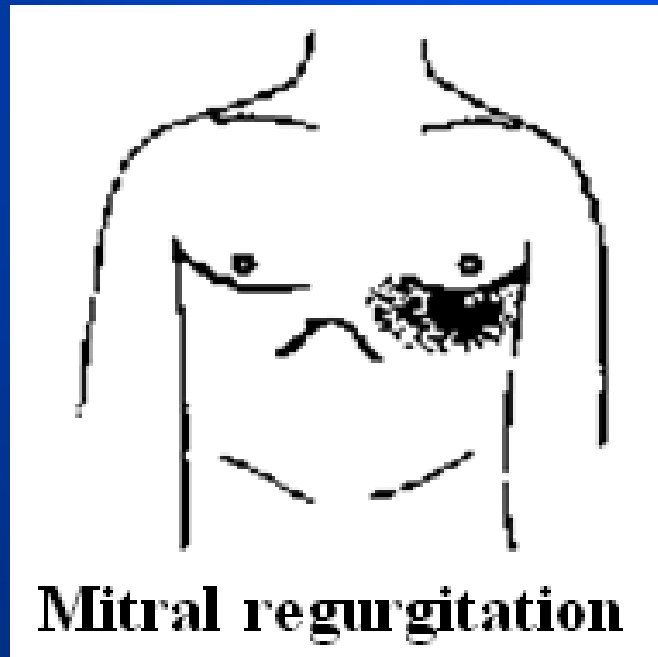
The murmur can be heard radiating into the neck or the back (ejection murmur), has a harsh quality, a crescendo-decrescendo shape, and midsystolic duration.



# SYSTOLIC MURMURS

## *Mitral regurgitation*

Systolic murmur in mitral regurgitation is best heard at the heart apex, with radiation into the axilla (regurgitant murmur).

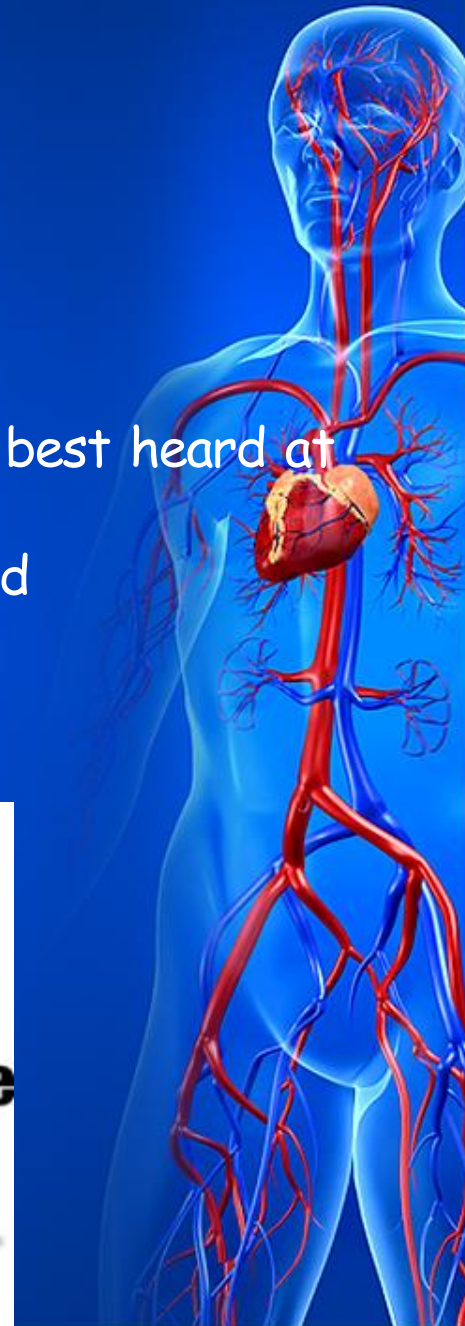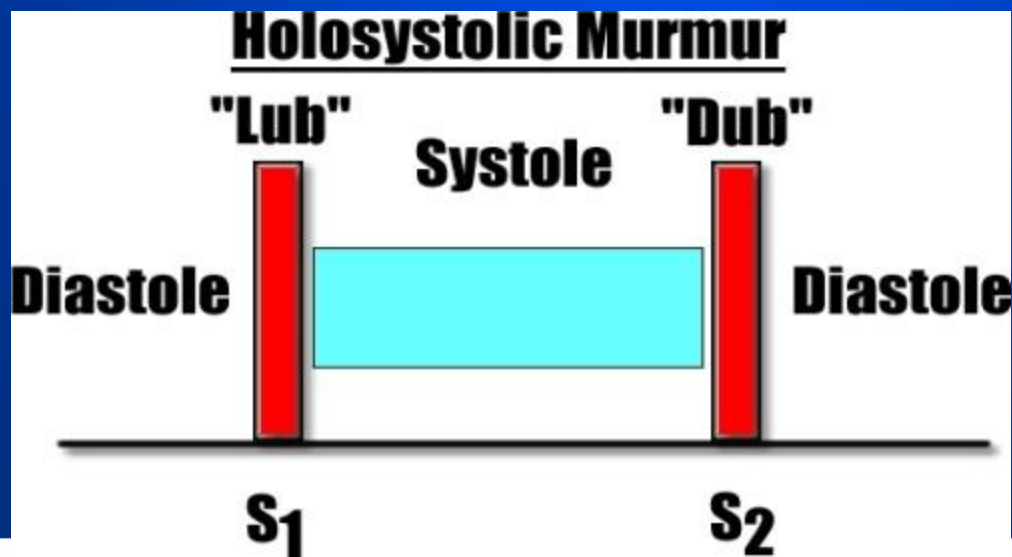




# SYSTOLIC MURMURS

## *Tricuspid regurgitation*

The holosystolic murmur of tricuspid regurgitation is best heard at the base of the sternum, generally softer than that of mitral regurgitation, and frequently increases during inspiration.

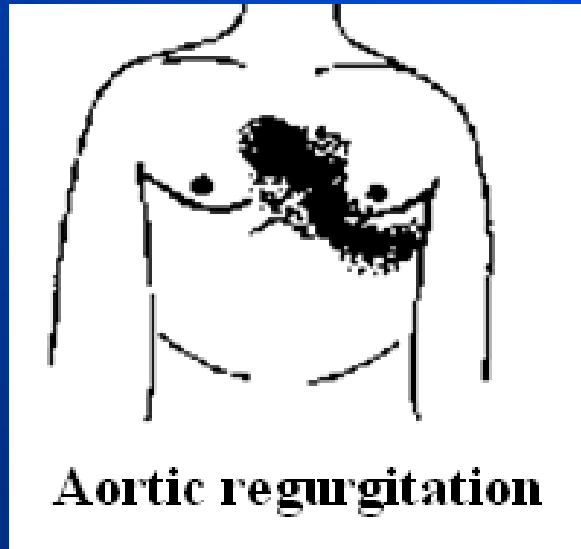




# DIASTOLIC MURMURS

## *Aortic regurgitation*

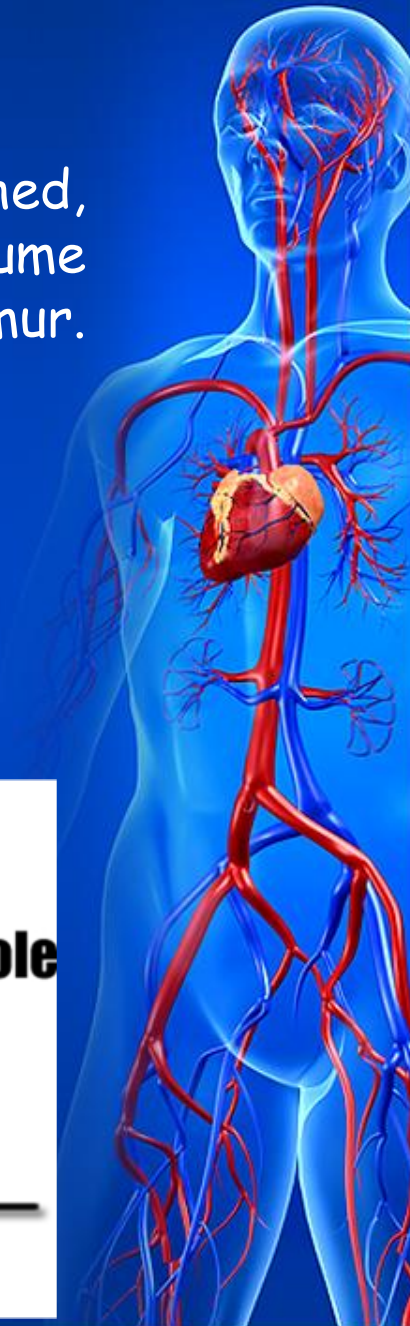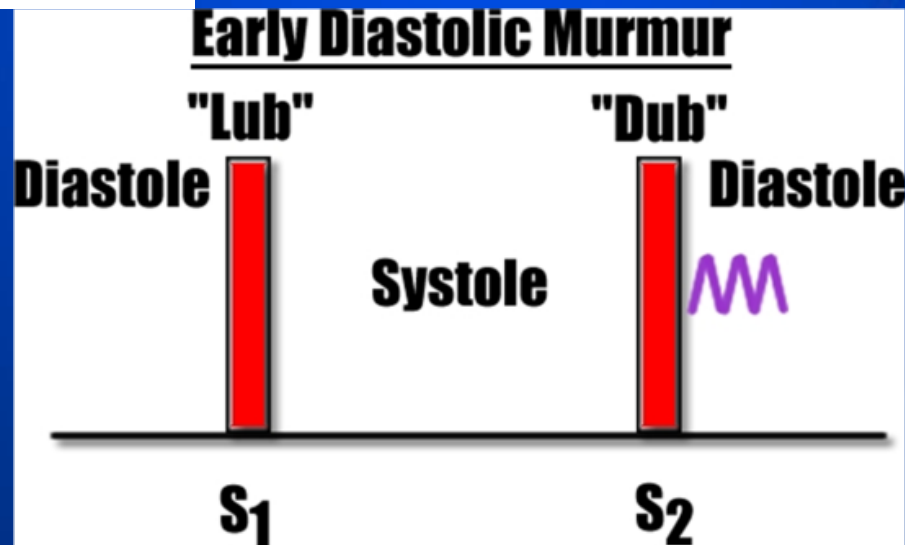
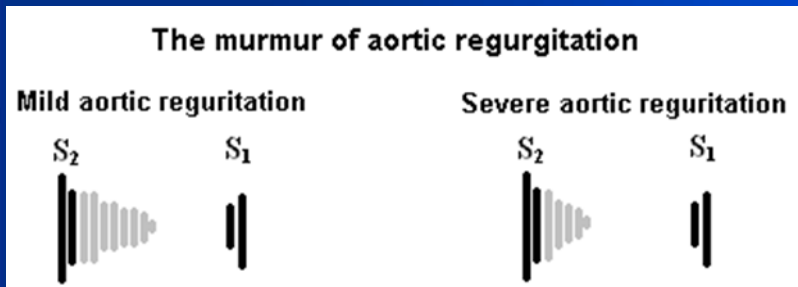
Best heard in the second intercostal space along left sternal edge, it widely radiates along the left sternal border (Botkin-Erb's point) and to be well transmitted to the heart apex (regurgitant murmur).



# DIASTOLIC MURMURS

## *Aortic regurgitation*

Usually characterized as blowing, generally high-pitched, decrescendo (since there is progressive decline in the volume of regurgitation during diastole), and early diastolic murmur. In severe regurgitation, it may be holodiastolic.

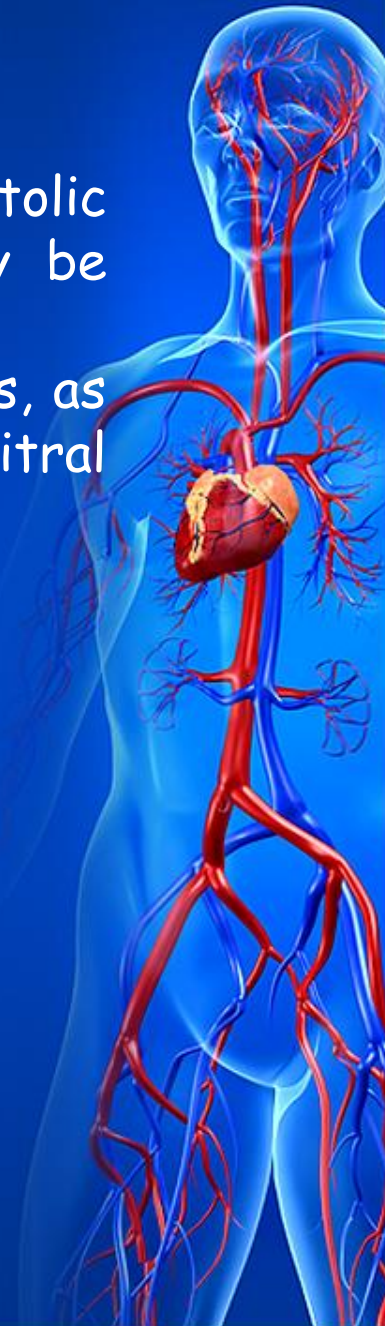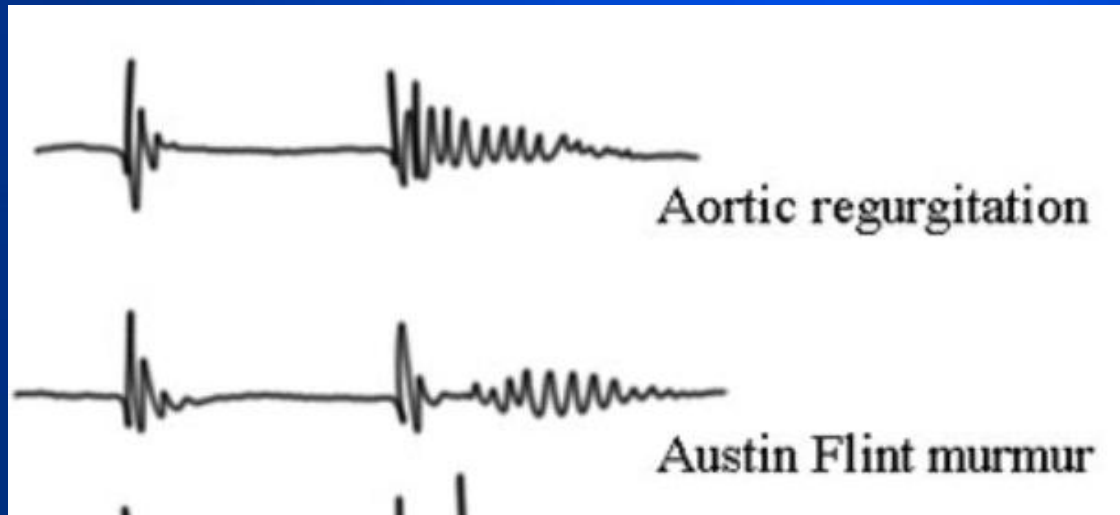


# DIASTOLIC MURMURS

## *Aortic regurgitation*

The soft, rumbling, low-pitched, mid- to late diastolic murmur at the heart apex (*Austin Flint murmur*) may be detected in severe aortic regurgitation.

It is thought to be due to a functional mitral stenosis, as the backflow blood from the aorta presses on the mitral valve, slightly occluding the flow from the left atrium.

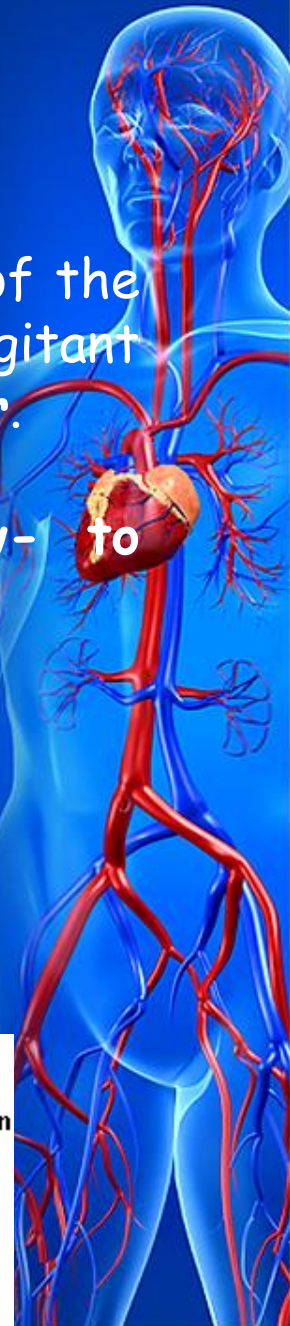


# DIASTOLIC MURMURS


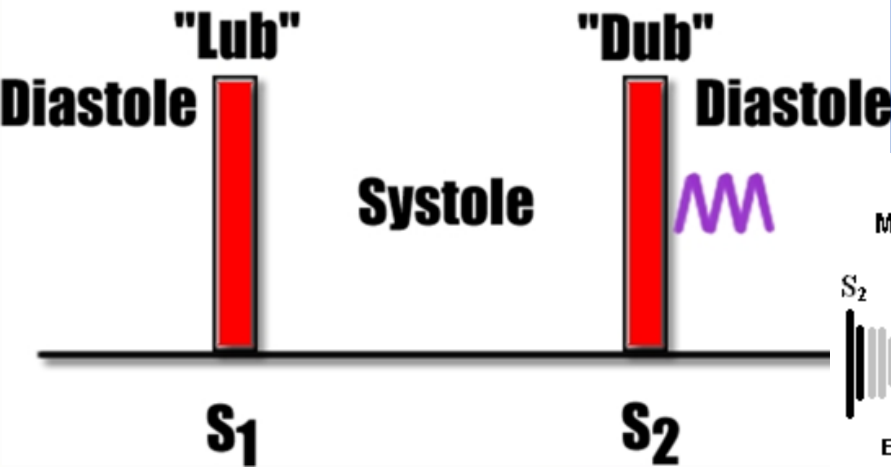
## *Pulmonary regurgitation.*

Best heard in the second intercostal space to the left of the sternum, with radiation along left sternal edge (regurgitant murmur), high-pitched, decrescendo, early diastolic murmur.

The diastolic murmur of pulmonary regurgitation without pulmonary hypertension is softer, and low- to medium-pitched.

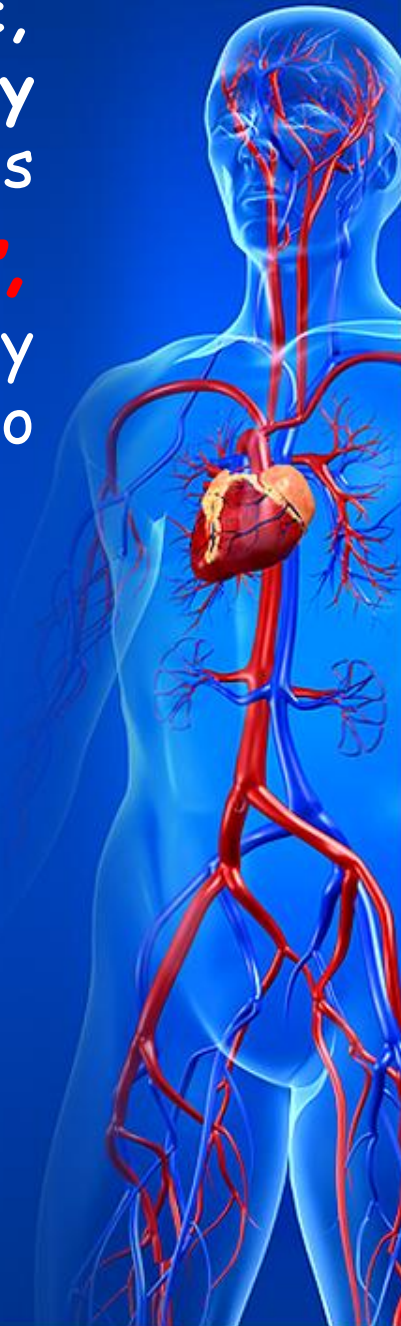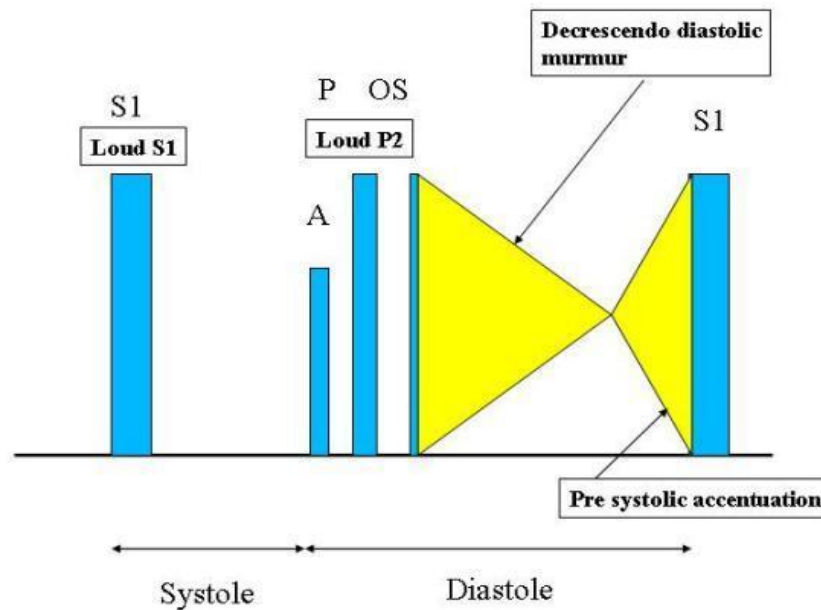


### Early Diastolic Murmur



In mitral stenosis functional early diastolic, high-pitched, with a decrescendo quality murmur is heard over the pulmonic area. This murmur, known as ***Graham Steel murmur***, begins with accentuated  $S_2$ , and is caused by dilation of the pulmonary artery due to significant pulmonary hypertension.

### Heart Sounds (Mitral Stenosis)



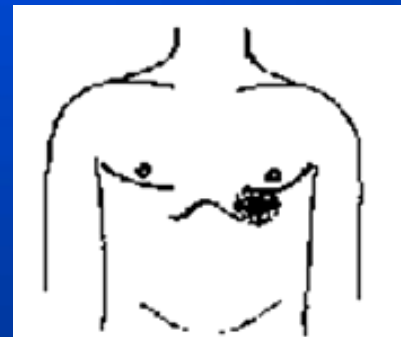
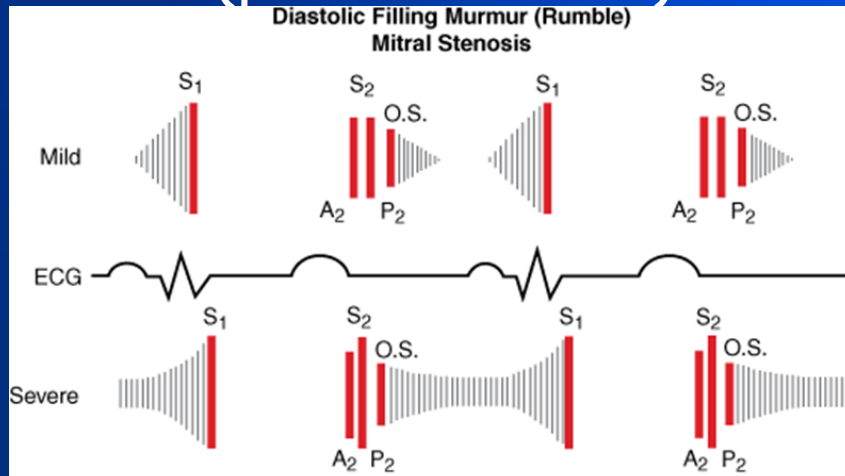
# DIASTOLIC MURMURS

## Mitral stenosis

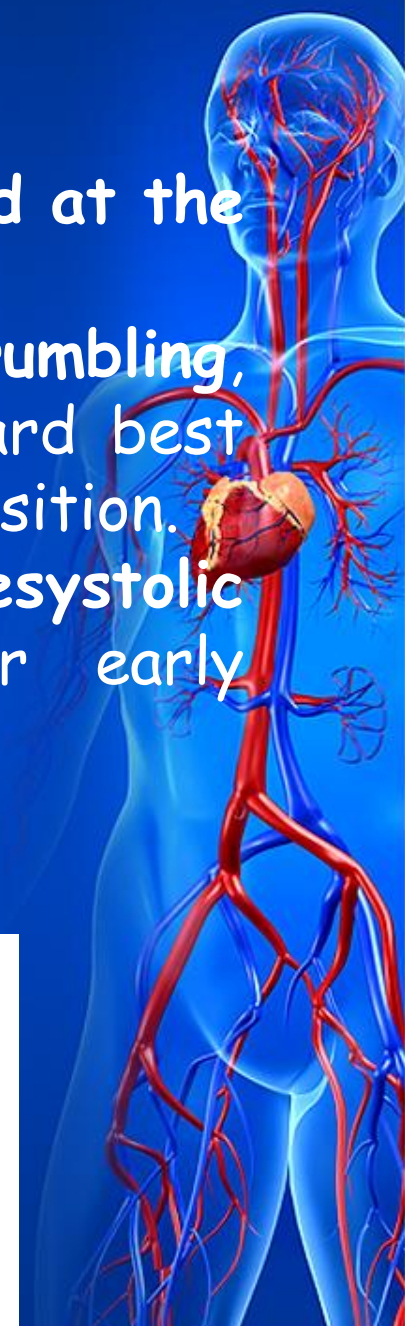The murmur of mitral stenosis is best heard at the heart apex with a little radiation.

It is usually described as low-pitched, rumbling, characteristically follows OS, and can be heard best with the patient in the left lateral decubitus position.

The murmur is nearly holodiastolic with presystolic accentuation, or presystolic crescendo, or early diastolic (protodiastolic) decrescendo.



Mitral stenosis



# DIASTOLIC MURMURS

## *Tricuspid stenosis*

The diastolic murmur associated with tricuspid stenosis is localized to a relatively limited area over the xiphoid, low-pitched, rumbling, and most right-sided events, may be stronger during inspiration.

