

Ministry of Health of Ukraine
Kharkiv National Medical University

PERCUSSION OF THE HEART

Methodical instructions for students

Рекомендовано
Ученым советом ХНМУ
Протокол №__от_____2017 г.

Kharkiv
KhNMU
2017

Percussion of the heart / Authors: T.V. Ashcheulova, O.M. Kovalyova, O.V. Honchar. – Kharkiv: KhNMU, 2016. – 10 c.

Authors: T.V. Ashcheulova
O.M. Kovalyova
O.V. Honchar

PERCUSSION OF THE HEART

Examination plan:

1. Borders of the relative cardiac dullness;
2. Borders of the absolute cardiac dullness;
3. Transverse length of the heart;
4. Borders of the vascular bundle;
5. Configuration of the heart.

Determination of the size, position, and shape of the heart is based on the distinction between percussion sounds. Being the airless organ, the heart gives dull percussion sound. But since it is partly covered by the lungs on its sides, the sound here is intermediate. The heart is surrounded by the lungs, which give clear pulmonary sound in percussion.

Projection of the heart chambers onto the chest: the right contour of the heart is formed by the right atrium at the bottom and by the superior vena cava to the upper edge of the 3rd rib. The left contour is formed by the arch of the aorta, pulmonary trunk, auricle of the left atrium, and downward by the narrow strip of the left ventricle.

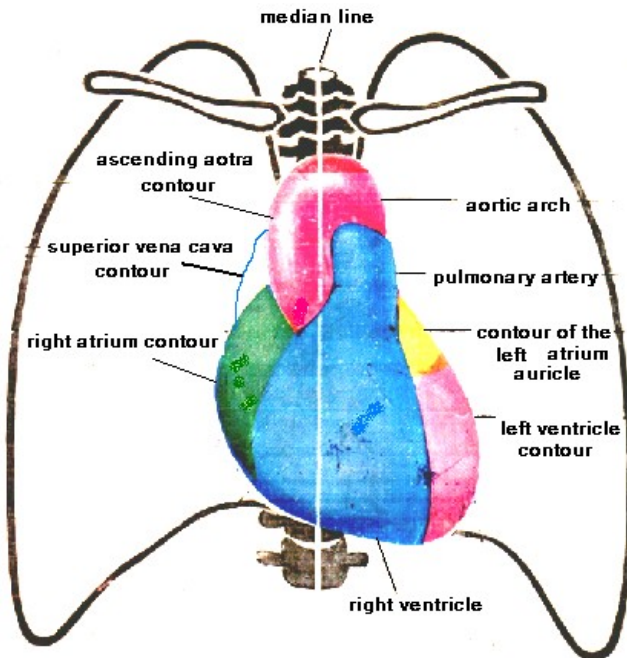


Fig. 1. Projection of the heart chambers onto the chest.

Relative cardiac dullness is the projection of its anterior surface onto the chest. The relative cardiac dullness reflects the true borders of the heart.

In order to determine the borders of the relative cardiac dullness the remotest points of cardiac contour are found on the right, upper, the left.

Technique.

The right border. As it is known, the position of the heart depends on the diaphragm level, which is indicated by the lower border of the lung. The lower border of the right lung by loud percussion is, therefore, first determined in the midclavicular line (normally at the level of the 5th interspace). Then move your pleximeter-finger one interspace above, place it parallel to the sternum and change the percussion technique – medium strength percussion stroke. Continue percussion by moving the pleximeter-finger along the interspace toward the heart until the sound change. The right border of the relative cardiac dullness is marked by the edge of the finger directed to the more clear sound. The normal right border of the relative cardiac dullness is in the 4th intercostal space 1 cm outward from the right edge of the sternum.

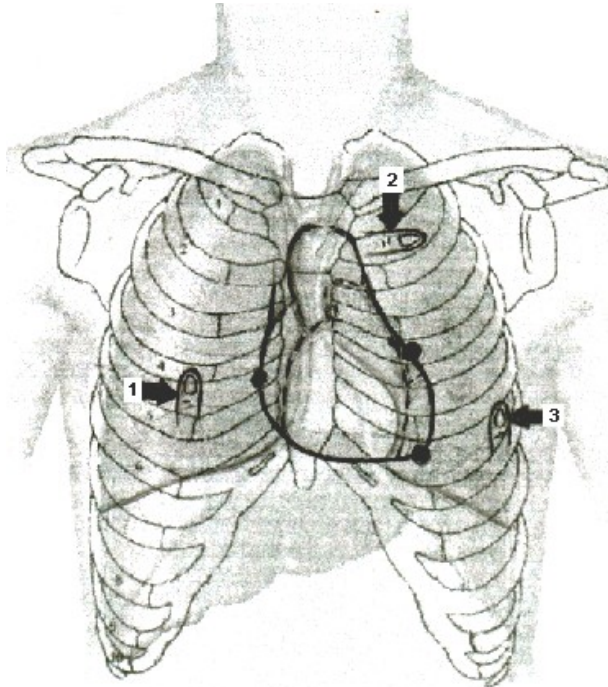


Fig. 2. Position of the pleximeter-finger during outlining the borders of the relative cardiac dullness.

In order to determine the *upper border* of the relative cardiac dullness place pleximeter-finger in the 1st intercostal space in the left parasternal line and move it downward until the percussion sound change. The normal upper border of the relative cardiac dullness is in the 3rd intercostal space in the left parasternal line.

The left border is determined in the interspace, where the apex beat is palpated. Place your pleximeter-finger laterally in this intercostal space parallel to the sought border and move it toward the sternum. If the apex beat is impalpable you should start percussion in the 5th intercostal space from the left anterior axillary line. The left border of the relative cardiac dullness is normally found in the 5th intercostal space 1.5 cm medially of the left midclavicular line.

Displacement of the relative cardiac dullness borders may occur due to dilation of the heart chambers and to a lesser extent due to thickening (hypertrophy) of myocardial wall.

The displacement of the right relative cardiac dullness border to the right is associated with hypertrophy / dilatation of the right atrium (RA) and / or right ventricle (RV). Extracardiac causes: left-sided pneumothorax, left-sided pleural effusion, left-sided hydrothorax, obstructive atelectasis of the right lung. Cardiac Causes: dilatation and hypertrophy of the RA (tricuspid valve insufficiency, atrial septal defect; dilatation and hypertrophy of the RV (pulmonary artery stenosis, tricuspid stenosis, late stages of mitral regurgitation, pulmonary heart in COPD).

The upside displacement of the upper relative cardiac dullness border can be associated with hypertrophy / dilatation of the left atrium and mitral valve diseases (stenosis and regurgitation).

The displacement of the left relative cardiac dullness border to the left is associated with hypertrophy / dilatation of the left ventricle (LV). Extracardiac causes: right-sided pneumothorax, right-sided pleural effusion / hydrothorax, obstructive atelectasis of the left lung. Cardiac causes: hypertrophy and dilatation of the left ventricle (aortic stenosis, aortic regurgitation, hypertension, post-infarction cardiosclerosis).

The displacement of the relative cardiac dullness borders to the left and downside - aortic regurgitation.

The displacement of the relative cardiac dullness borders to the right and upside - mitral stenosis.

The displacement of the relative cardiac dullness borders upside and to the left - mitral insufficiency.

The displacement of the relative cardiac dullness border to the right and to the left - myocarditis, myocardiosclerosis, cardiomyopathy.

The displacement of the relative cardiac dullness borders to all sides - combined congenital and acquired heart diseases, pericardial effusion,

cardiomegaly (cardiomyopathy: hypertrophic and dilated), late stages aortic regurgitation (mitralization).

Transverse length of the heart is the sum of distance from the right border of the relative cardiac dullness to the anterior median line (3-4 cm) and from the left border of the relative cardiac dullness to the median line (8-9 cm). The transverse length is measured by a measuring tape, and normally is 11-13 cm.

Enlargement of the cardiac transverse length is observed in hypertrophy and dilation of the heart chambers (see above).

The borders of the vascular bundle are determined by light percussion in the 2nd intercostal space from midclavicular line to the right and left toward the sternum. The borders of the vascular bundle are normally found along the edges of the sternum. The normal width of the vascular bundle is 4-6 cm.

The width of the vascular bundle can be increased due to dilation of the pulmonary artery due to pulmonary hypertension; aortic aneurysm; syphilitic mesoaortitis; mediastinal tumor.

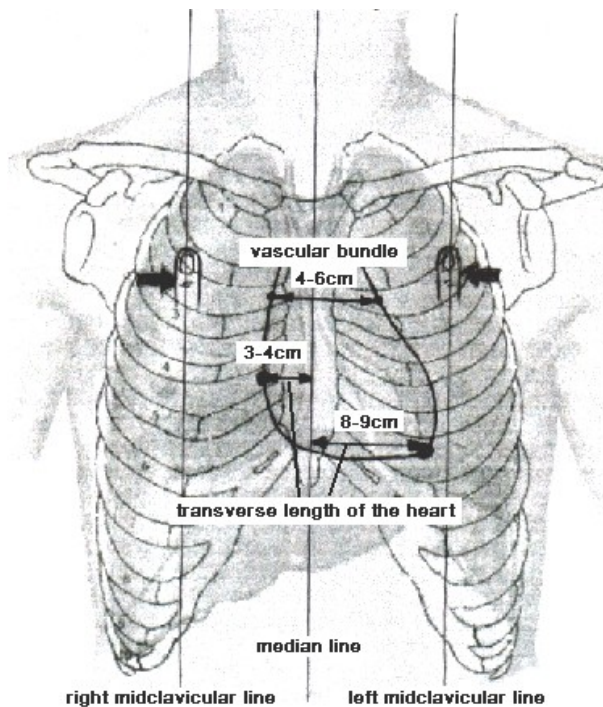


Fig. 3. Transverse length of the heart and the borders of the vascular bundle.

Configuration of the heart can be determined by percussion in the 2nd, 3rd, 4th intercostal spaces on the right and 2nd, 3rd, 4th, 5th intercostal spaces on the left. The pleximeter-finger is moved parallel to the cardiac border. The elicited points are marked on the patient's skin and connected by a line.

Normal configuration of the heart:

Right contour: 2nd intercostal space along right sternal edge,
3rd intercostal space along right sternal edge,
4th intercostal space 1 cm laterally of right sternal edge;
Left contour: 2nd intercostal space along left sternal edge;
3rd intercostal space along left parasternal line;
4th and 5th intercostal spaces 1,5 cm medially of left midclavicular line.

The angle formed by the vascular bundle and left ventricle is called *waist of the heart*. In normal configuration of the heart this angle exceeds 90°.

In pathological conditions, mitral, aortic, and trapezoid configurations of the heart can be observed.

Mitral configuration - protrusion of the upper part of the left contour, indistinct or protruded waist of the heart due to dilation of the left atrium and pulmonary hypertension. Can be observed in mitral heart disease (mitral regurgitation, late stages of mitral stenosis).

Aortic configuration - protrusion of the lower part of the left contour, pronounced waist of the heart due to significant dilation of the left ventricle. Can be observed in aortic defects (stenosis, regurgitation) and hypertension.

Trapezoidal configuration has the shape of a trapeze with a wide base at the bottom with a gradual narrowing upwards. Observed in pericardial effusion, with accumulation of significant amounts of transudate or exudate in the pericardial cavity.

Cor bovinum (bullish heart) - protrusion of all cardiac contours. Observed in myogenic dilatation of both ventricles in cardiomyopathy.

Absolute cardiac dullness is the projection of the anterior surface of the heart, which is not covered by the lungs onto the chest. Absolute cardiac dullness is formed by the right ventricle.

Normal borders of the absolute cardiac dullness:

The right – along the left sternal edge from 4th to 6th rib;

The upper – lower edge of the 4th rib along left parasternal line;

The left – 5th intercostal space 0.5 cm medially of the left border of the relative cardiac dullness.

Changing the boundaries of absolute cardiac dullness:

Decrease: low diaphragm level, pulmonary emphysema, left-sided pneumothorax.

Increase: pregnancy, high diaphragm level, mediastinal tumors, hypertrophy / dilatation of the right ventricle.

The standard description (in healthy individual): On topographic percussion, right border of the heart is determined in the IV intercostal space 1.5 cm outwards from the right edge of the sternum, the upper border is determined in the III intercostal space on the left parasternal line, the left border is determined in the V intercostal space 1- 2 cm medially from the left midclavicular line; vascular bundle width is 6 cm, diameter of the heart is 13 cm, the heart configuration is normal.

TEST CONTROL

1. ***Right border of the relative cardiac dullness is formed by:***
 - A. Right atrium
 - B. Left atrium
 - C. Right ventricle
 - D. Left ventricle
 - E. Aorta
2. ***Right contour of the heart and vessels is formed by:***
 - A. Vena cava superior and right atrium
 - B. Right ventricle and aorta
 - C. Left ventricle and aorta
 - D. Left ventricle and pulmonary artery
 - E. Right atrium and pulmonary artery
3. ***Left contour of the heart and vessels is formed by:***
 - A. Vena cava superior, right atrium, right ventricle
 - B. Aortic arch, pulmonary trunk, left ventricle, left atrium
 - C. Pulmonary trunk, left ventricle, left atrium
 - D. Left ventricle, left atrium
 - E. Vena cava superior, left atrium, left ventricle
4. ***Upper border of the relative cardiac dullness is formed by:***
 - A. Right ventricle
 - B. Pulmonary artery
 - C. Vena cava
 - D. Left atrium
 - E. Right atrium
5. ***Left border of the relative cardiac dullness is formed by:***
 - A. Left atrium
 - B. Right atrium
 - C. Left ventricle

- D. Pulmonary artery
 - E. Aorta
6. ***What is the cause of outward displacement of the right border of the relative cardiac dullness?***
- A. Coronary heart disease
 - B. Mitral stenosis
 - C. Aortic stenosis
 - D. Aortic regurgitation
 - E. Essential hypertension
7. ***In mitral stenosis, outward displacement of ... is observed:***
- A. Upper border of the relative cardiac dullness
 - B. Upper and right borders of the relative cardiac dullness
 - C. Left and right borders of the relative cardiac dullness
 - D. Upper, Left and right borders of the relative cardiac dullness
 - E. Right border of the relative cardiac dullness
8. ***In mitral regurgitation, outward displacement of ... is observed:***
- A. Upper border of the relative cardiac dullness
 - B. Upper and right borders of the relative cardiac dullness
 - C. Left and right borders of the relative cardiac dullness
 - D. Upper and left borders of the relative cardiac dullness
 - E. Right border of the relative cardiac dullness
9. ***In aortic stenosis, outward displacement of ... is observed:***
- A. Left border of the relative cardiac dullness
 - B. Upper and right borders of the relative cardiac dullness
 - C. Left and right borders of the relative cardiac dullness
 - D. Upper, Left, and right borders of the relative cardiac dullness
 - E. Right border of the relative cardiac dullness
10. ***Absolute cardiac dullness is formed by:***
- A. Left atrium
 - B. Right atrium
 - C. Left ventricle
 - D. Right ventricle
 - E. Aorta

Answers: 1A, 2A, 3B, 4D, 5C, 6B, 7B, 8D, 9A, 10D.

Methodical instructions

PERCUSSION OF THE HEART

Methodical instructions for students

Authors: T.V. Ashcheulova
O.M. Kovalyova
O.V. Honchar

Chief Editor Ashcheulova T.V.

Редактор _____
Корректор _____
Компьютерная верстка _____

**г. Харьков, пр. Науки, 4, ХНМУ, 61022
Редакционно-издательский отдел**