

МІНІСТЕРСТВО ОХОРОНИ ЗДОРОВ'Я УКРАЇНИ
Харківський національний медичний університет

DEFORMING ARTHROSIS

***Methodical instructions
for self-study of 5th year students of medical faculties
in discipline "Traumatology and orthopedics"***

ДЕФОРМУЮЧИЙ АРТРОЗ

***Методичні вказівки
до самостійної підготовки студентів 5-го курсу
медичних факультетів
з дисципліни "Травматологія та ортопедія"***

Затверджено
вченою радою ХНМУ.
Протокол № 12 від 20.12.2018

**Харків
ХНМУ
2019**

Deforming arthrosis : methodical instructions for self-study of 5 coursestudents of medical faculties in discipline "Traumatology and orthopedics"/ comp. H. H. Holka, M. A. Harkusha, O. G. Fadeyev et al. – Kharkiv : KhNMU, 2019. – 20 p.

Compilers H. H. Holka,
 M. A. Harkusha,
 O. G. Fadeyev
 A. O. Oliynyk,
 D. A. Istomin,
 V. V. Burlaka

Деформуючий артроз : метод. вказ. до самост. підготовки студентів 5-го курсу мед. фак-тів з дисципліни "Травматологія та ортопедія" / упоряд. Г. Г. Голка, М. А. Гаркуша, О. Г. Фадєєв, та ін. – Харків : ХНМУ, 20 с.

Упорядники Г. Г. Голка
 М. А. Гаркуша
 О. Г. Фадєєв
 А. О. Олійник
 Д.А. Істомін
 В. В. Бурлака

1. Class topic: Osteochondrosis of the spine, osteoarthritis. Clinic, diagnosis, treatment.

The number of hours: 5

2. Material support of the topic

- tables on deforming arthrosis pathogenesis;
- radiographs on studying topic;
- dummies;
- metal structures;
- endoprostheses;
- multimedia accompaniment;
- patients according to the topic of the class.

3. Topic grounding

Deforming arthrosis is one of the most common diseases of the musculoskeletal system. About 5 % of all inhabitants of the globe suffer from it. They make up 1/3 among outpatients with orthopedic profile. In average of 7–10 years from the beginning of the disease deformative arthrosis of large in almost 100 % of cases leads to disability.

4. Topic objective: Based on clinical and radiological data- to learn how to diagnose deforming arthrosis of large joints of various origins and severity, to prescribe appropriate treatment or to send a patient to a specialist for further treatment in time.

To solve this problem, the student must know:

- etiopathogenesis of deforming arthrosis, features of changes in the joints depending on the stage of the disease;
- clinic and X-ray diagnostics of various stages of the disease;
- possible treatment options for pathology, depending on the etiology and stage of the disease;
- indications and principles of surgical treatment.

By the end of the practical class, each student must know how:

- to collect anamnesis and to reveal the clinical symptoms characteristic for deforming arthrosis of large joints;
- identify and describe the radiographic signs of deforming arthrosis and, if possible, establish the etiology of the disease;
- draw up a plan of conservative treatment depending on the etiology and severity, period of the course;
- establish indications for surgical treatment.

5. The main issues of the topic:

- definition of the term “deforming arthrosis”. The prevalence of this disease.
- pathogenesis of primary and secondary arthrosis;
- clinical and radiological characteristics of deforming arthrosis of large joints;

- conservative treatment (medical, PTT, orthopedic) of deforming arthrosis;
- indications and types for surgical treatment.

6. Requirements for the initial level of knowledge

Before studying the topic of the upcoming practical class you need to repeat the following:

In normal anatomy – the normal anatomy of the hip, knee, shoulder and ankle joints (bones, ligaments, periarticular muscles, innervation and blood supply).

In diagnostic radiology – X-ray images of large joints (listed above) in patients of different age groups:

- X-ray signs of deforming arthrosis.

In internal medicine – deforming rheumatoid osteoarthritis. Etiopathogenesis, clinic, diagnosis, treatment.

In phthisiology – pathogenesis and pathological anatomy of the tuberculous process in the joints.

Subject content

Deforming arthrosis is understood as a chronic disease of degenerative joints with primary dystrophy of articular cartilage and subsequent reactive degenerative processes in the epiphysis of the articular bones.

Deforming arthrosis is included in the group of degenerative-dystrophic diseases of the joints and makes up about 80 % in it.

What is the cause of this disease? By its nature, deforming arthrosis is a polyetiological disease. Any process that damages articular cartilage triggers the development of arthrosis.

Uncongenial working and living conditions, dysfunction of the sympathetic nervous system, changes in the neurohumoral nature, genetic, endocrine, enzymatic, immune, vascular factors – all of them can be important in the occurrence of primary arthrosis. Secondary deforming arthrosis develops after injuries, microtraumas, vibrations, inflammatory processes, congenital deficiency of joints, disturbances in static-dynamic function, aseptic necrosis, and other diseases.

For a clearer understanding of the pathogenesis of this disease, we should recall some anatomical and morphological knowledge of the joints. According to modern concepts, the synovial membrane, synovial fluid and articular cartilage make up a complex called the “synovial surrounding of the joint.” One of its main components is hyaline cartilage. Beneath it is the subchondral plate. Exactly in it, the terminal artery zone, there is the richest network of bone tissue capillaries. Nerve fibers also branch out under the base of the articular cartilage and end with varicose thickening.

The cartilage tissue is heterogeneous and resembles a sponge with very thin pores. It consists of chondrocytes and a large amount of dense intercellular

substance called the matrix. The latter contains a fibrous framework of collagen fibers and the main substance, the main components of which are proteoglycans and glycoproteins.

Due to its structure and chemical composition, the cartilage provides strength, elasticity and elasticity of the joint. Through the matrix, chondrocytes are supplied with food, water, oxygen: when moving under the influence of body weight, the articular cartilage of the lower extremities squeezes like a sponge, and unused tissue fluid is squeezed out of it. When unloading pressure in the cartilage drops and the cartilage, like a sponge, freed from pressure, expanding, sucks in a fresh (nutrient-rich) tissue (synovial) fluid. Thus, at each step, the cartilage is powered. From here it becomes clear the meaning of the phrase: "A movement for a joint is life".

However, the synovial fluid cannot deliver oxygen, and the articular cartilage does not have its own vessels, so that it is also powered by the vessels of the subchondral zone. As a result, articular cartilage is the most vulnerable element of the joint and it is also a primary lesion focus at deforming arthrosis.

Thus, at any time, under the influence of an unfavorable external or internal influence, a spasm or thrombosis of the vessels of the subchondral zone of bone or / and the synovial membrane may occur, followed by impaired microcirculation and the development of cartilage hypoxia. In the tissues of the joint elements, accumulation of underoxidized metabolic products (lactic, pyruvic acid), above-threshold accumulation of kinins, prostaglandins, catecholamines will occur.

Disruption of cartilage nutrition leads to its degeneration: the lysosomes of cartilage cells are destroyed, the activation of lysosomal enzymes causes the death of chondrocytes with the release of proteoglycans as a result of their depolymerization.

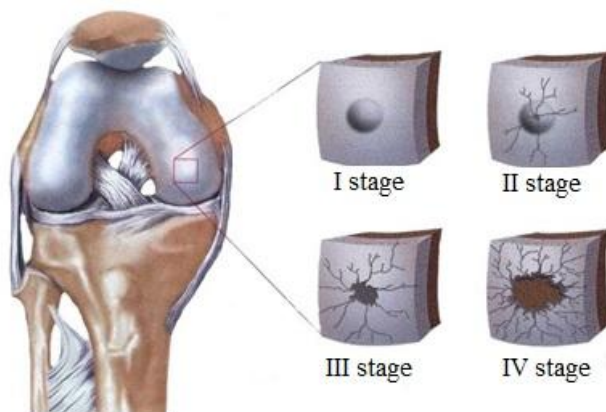
Cell death, depletion of cartilage by proteoglycans lead to a loss of resilience and elasticity of cartilage, breakdown of collagen fibers and the appearance of defects. Disruption of the structure of cartilage is accompanied by ulceration of its surface layers. The development of degenerative changes in the synovial membrane is accompanied by a decrease in the production of synovial fluid and leads to the so-called "dry joint". Along with this, the active substances of cartilage and its particles (detritus from destruction) can cause reactive synovitis, which is accompanied by the release of lysosomal enzymes into the joint. The latter, in its turn, causes lysis of cartilage degeneration.

Thus, pathogenetically, in the first place in the development of primary arthrosis sets the factor of cartilage nutrition. The subsequent changes in cartilage lead to a decrease in its resistance, even to a normal load. Cartilage loss of elasticity and violation of congruence lead to macro- and microtrauma of the subchondral plate, which responds to this by increased production of

bone substance, manifested in the form of osteosclerosis. An excess of bone matter in this area with continued load on the articular surfaces causes it to spread to the places of lowest pressure and accumulation of bone matter, detected radiologically in the form of osteophytes. This contributes to even greater malnutrition of the cartilage.

In secondary arthrosis, the degenerative process develops already in the injured cartilage. Moreover, already at the initial stage of the process, often biomechanical factors in the form of impaired concentration, incongruence and instability of the joint play a dominant role. The development of arthrosis after injuries goes through inflammation, through arthritis and synovitis. In these cases, for the formation of arthrosis 4–5 months are needed.

During the deforming arthrosis there are 4 stages:



I stage is characterized by limb fatigability, moderate limitation of movement in the joint, a slight crunch is possible. At rest and a small load pain is absent. Typically, pain occurs at the beginning of walking – “starting pain” or after prolonged exercise. Radiographically – the narrowing of the joint space due to chondrolysis and mild subchondral sclerosis are revealed.

II stage is characterized by an increase in limitation of movements, which are accompanied by pain, diminishing only after a long rest. There is a deformity of the joint, moderate muscle wasting, contracture of the joint, sparing lameness. Radiographically – the narrowing of the joint space 2 times more in comparison with the norm is revealed; subchondral sclerosis and osteophytes in places of the lowest load are expressed.

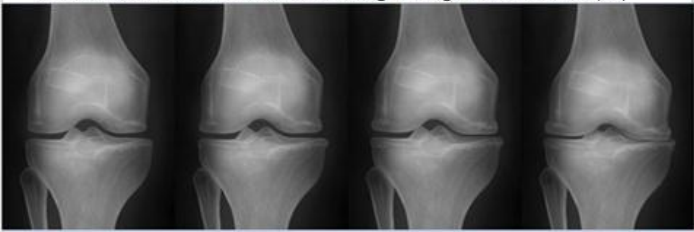
III stage is characterized by a strong restriction of movements, which is accompanied by crepitus, sharply pronounced pain syndrome, which decreases only after a very long rest. Severe deformity of the joint is pronounced.

Radiographically – the narrowing of the joint space 3 times more in comparison with the norm is revealed; subchondral sclerosis and osteophytes in places of the lowest load are expressed.

IV stage is characterized by an almost complete loss of mobility in the joint, only passive swinging movements are maintained, flexion contracture is expressed. The pain persists even at rest; it is not eliminated even after the rest. Possible instability of the joint is present. Radiographically – the joint space is almost completely absent. The articular surface is deformed, marginal growths are expressed. Multiple cysts are identified in the subchondral areas of the articular surfaces.

X-ray examination (radiogram)

Evaluative scale of osteoarthritis according to Kellgren and Lawrence (KL)



	Stage 1	Stage 2	Stage 3	Stage 4	
Classification	Norm	Doubtful	Mild stage	Moderate severity	Severe form
Description	Signs of osteoarthritis are absent	Small osteophytes, presence of osteoarthritis is doubtful	Presence of larger osteophytes, joint space is not narrowed	Moderate narrowing of joint space	Significant narrowing of joint space, subchondral osteosclerosis

Evaluative scale is based on the assessment of osteophytes formation, narrowing of joint space and osteosclerosis progression

Deforming arthrosis of the hip joint (coxarthrosis)

This localization of arthrosis is the most frequent among the other localizations and is makes up about 50 %. The initial stages of coxarthrosis are asymptomatic. Only in some patients there is a decrease in the strength of the thigh muscles, their rapid fatigue during walking and in standing position. Pain may occur at the beginning of walking or after prolonged sitting, while carrying weight. As the process worsens, the intensity of the pain increases. It calms down or disappears completely at rest and grows at the slightest load. In neglected cases, the pain becomes permanent, sometimes worse at night. The pain syndrome is often accompanied by irradiation of the pain to the region of the knee joint (irradiation along the femoral nerve), it also can be localized in the groin, buttocks, lumbar region. A blockage of the hip joint in the form of a sudden painful "jamming" of the joint is possible. Then, the movements are independently restored. Impaired joint function also increases slowly, as the

process gets worse: at first, stiffness and muscle fatigue turns into a pronounced movement disorder with the formation of contractures. There is lameness, shortening of the extremity. The patient hardly puts on socks, sits down in public transport, early loses working capacity. The hypotrophy of muscles of a hip and shin increases. Ultimately, coxarthrosis leads to complete immobility of the joint, pelvic distortion, increased lumbar lordosis, often with lateral curvature of the spine. Bilateral coxarthrosis is accompanied by the syndrome of "bound legs". X-ray examination of the pelvis and hip joints confirms the diagnosis and establishes (confirms) the severity of the existing pathology.

Deforming arthrosis of the knee joint (gonarthrosis)

By frequency, it is in the second place. Among all diseases of the knee it makes up 53 %. Unlike coxarthrosis, gonarthrosis proceeds more easily. IV stage is reached by only 15–17 % of all patients, in half of them the process is delayed at 1,2-st. development. Even in severe cases, it rarely leads to complete disability.

Pathological changes in gonarthrosis do not proceed unnoticed by the patient. The disease develops gradually. Periodically appearing pain in the joint is characterized by low intensity, especially after sleeping and prolonged sitting – “starting pain”. Already at the II stage of the disease, the person begins to experience pain more frequent and a discomfort in the joint is present. The pain syndrome changes somehow: in addition to the “starting pain”, patients are disturbed by the pain after a long stay on their legs, a long walk. These pains calm down or disappear completely after a long night rest. During this period of the disease, patients note a gradually increasing limitation of movement in the joint, a marked muscle hypotrophy as while walking the patient spares the sore leg due to pain. Unpleasant feelings are aggravated while walking (while going down the stairs), morning stiffness in the joint increases, it is difficult for the patient to unbend his leg completely. Pain in the joints especially bothers the patient at the end of the day and makes it difficult to sleep at night. One of the complaints of people suffering from osteoarthritis – crunch and "creak" in the knee. Often the pain intensifies in response to changes in weather conditions - the joints do not respond well to cold and wet weather. Palpation of the knee joint is painful, the pain increases at trying to move the patella. In all patients with gonarthrosis of III stage of the disease a characteristic leg curvature develops (X-shaped or O-shaped). *Figure. 1–2.*

Deformed knee joints swell and bulge. III stage is characterized by persistent pain in the joint, sometimes it becomes acute, and often a blockage of the joint occurs: the leg “stiffens” in some position and active flexion or extension of the tibia is impossible. A moderate flexion contracture, sparing lameness, hypotrophy of the thigh and lower leg muscles are revealed. There are

signs of synovitis: effusion in the joint, deterioration of the general condition, restriction of movements, fever, and accelerated erythrocyte sedimentation rate. Gradually the function of walking is limited. The distance that the patient can walk is reduced. The patient is forced to lean on a cane. In IV stage of development of the disease as a result of contraction and shortening of the muscles, contractures are formed in which the lower leg is bent at the knee joint, depending on more or less damage to the inner or outer part of the joint, the shin can be tucked inwards or outwards and the patient cannot give a normal position to the leg. In the end, movement in the knee joint is severely limited or lost at all.

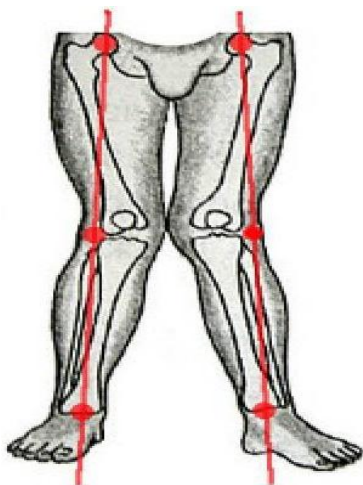


Figure 1

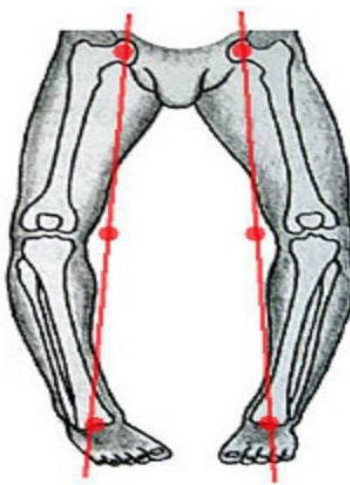


Figure 2

All diseases of the knee joint and periarticular tissues are divided into two large groups – **inflammatory** and **metabolic** (not taking into account the injury of the knee joint). **Gonarthrosis** can be **primary**, that is, initially arising, and **secondary**, arising on the background of any other diseases of the knee joint.

The origin of primary osteoarthritis of the knee joint is not fully understood. It is believed that metabolic disorders in the body, in particular in cartilage tissue, can lead to this disease. The basis of metabolic diseases of the knee joint at arthrosis (osteoarthrosis, gonarthrosis) is a variety of metabolic disorders. As a result of such shifts, biochemical reactions occurring in the tissues of the knee joint change. As a result, the cartilaginous tissue of the knee joint degenerates and is destroyed in some places. All of it changes the surface of the inflamed knee and the structure of its cartilage. In the cavity of the inflamed knee in case of arthrosis (osteoarthrosis, gonarthrosis) effusion (synovitis) can accumulate. **Baker's cyst** may accompany this process.

The basis of the inflammatory processes in the knee joint is an autoimmune reaction that develops in the joint and tissues surrounding the joint. It means that the immunity, which is able to protect our body from infections, tumors and other diseases, behaves inadequately – it “attacks” our own knee joint (the word “autoimmune” can be interpreted as immunity directed against itself). Eastern medicine connects degenerative processes in the joints and spine with the "weak energy" of the kidneys. According to oriental views kidneys are a “mother” of the osteoarticular system and various problems in this energy bed will necessarily affect the condition of bones and joints.

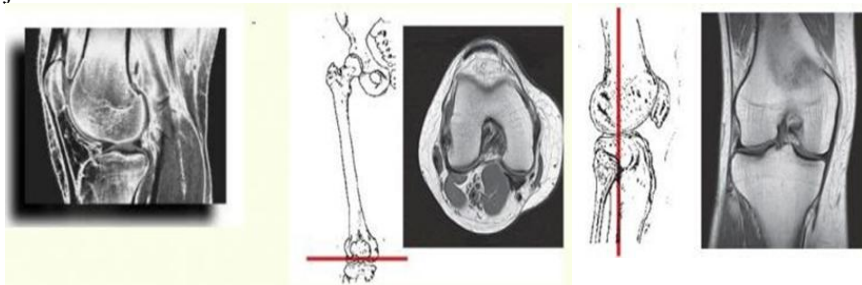
In secondary arthrosis, the degenerative process develops in the injured cartilage so far. Moreover, in the initial stage of the process so far, often biomechanical factors in the form of impaired concentration, congruence of the articular surfaces and instability of the joint play a dominant role. König’s disease also leads to secondary arthrosis of the knee joint. The development of arthrosis after injuries goes through inflammation, through arthritis and synovitis. In these cases, the formation of arthrosis requires only 4–5 months. Secondary gonarthrosis occurs under the influence of several causes, such as: inflammation (having an infectious or autoimmune nature), trauma and dysplasia. Most often, traumatic injuries of the knee meniscus, meniscopathy, lead to gonarthrosis.

The causes of gonarthrosis development are diverse and sometimes require careful differentiation. However, the most frequent are:

- intraarticular fractures of the bones that form the knee joint;
- arthrosis caused by Paget's disease;
- benign and malignant bone tumors;
- ankylosing spondylitis and rheumatoid arthritis.

Diagnosis of arthrosis (coxarthrosis, gonarthrosis) of the joints

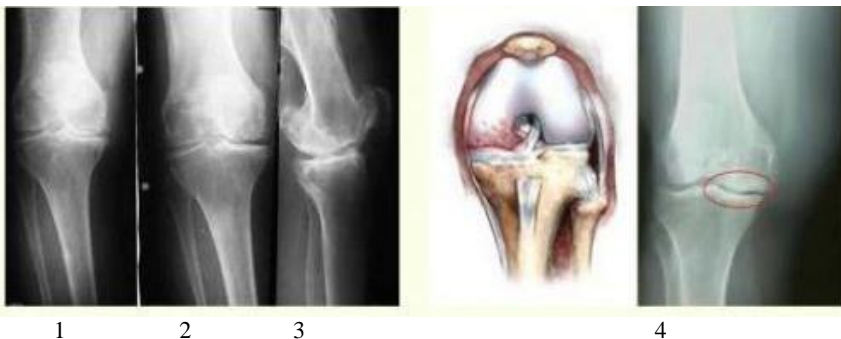Magnetic resonance imaging (MRI) of the joints is one of the most promising and rapidly improving methods of modern diagnostics. While performing magnetic resonance imaging of the joints, the doctor gets the opportunity not only to investigate the structural and pathological changes, but also to evaluate the physicochemical, pathophysiological processes of the entire joint as a whole or its individual structures.



Magnetic resonance imaging (MPT) of the joint allows to get a series of thin sections, to build a three-dimensional reconstruction of the studied area, to identify the vascular network and even individual nerve trunks and vessels, passing in the projection of the joint. Such a reconstruction during magnetic resonance imaging of the joint provides invaluable assistance to the surgeon in planning joint surgery and for subsequent postoperative monitoring of the patient's condition.

Early diagnosis using magnetic resonance imaging of the knee joint, for example, at disrupted ligament of the knee joint or torn meniscus, which occurs when the leg is tucked medially or outwards, often in winter on slippery ice, ice-covered platforms and stairs and at traumas that can occur during sports injury – jumping from a small height, allows you to start treatment of the disease.

Radiography of the knee joint diagnoses fractures with displacement and without displacement, depressions and fragments, free-lying inside and outside the articular body, narrowing of the joint space, subchondral osteosclerosis, osteophytes characteristic of stage III–IV of the disease. Cystic reorganization in the epiphysis of the articular surfaces is not always expressed, even with severe clinical forms of its localization. This diagnostic procedure is carried out in anterior and lateral projections, as well as in various specific styles.



Depending on the preferential localization of the degenerative-dystrophic process, 4 forms of gonarthrosis are distinguished:

1) with a primary lesion of the internal division of the knee joint (the leading symptom complex is the varus deformity of the lower extremity with the apex in the region of the knee joint;

2) with predominant lesion of the external part (valgus deformity);

3) deforming arthrosis of the patellofemoral articulation;

4) gonarthrosis with the affection of all parts of the joint.

Without treatment, gonarthrosis leads to disability and loss of motor activity.

Treatment of coxarthrosis – gonarthrosis

It does not differ from the treatment of osteoarthritis of other localization. It is recommended to limit the physical load on the joint, but physical therapy exercises are obligatory, as the movements performed in the joint allow maintaining its mobility and improving the nutrition of the elements of the joint. If one knee joint is affected, physiotherapy exercises are still assigned to both joints. Patients are recommended self-massage of the knee joint, thigh muscles and shin. It also helps to improve the blood supply to the joint, to maintain the muscles of the extremity in good condition. Nonsteroidal anti-inflammatory drugs, analgesics are prescribed to relieve pain. Various irritating and analgesic ointments are used. To improve the blood supply vasoregulatory drugs and venotonics are prescribed. For a long time, drugs that improve the condition of the articular cartilage – chondroprotectors are prescribed. With non-effectiveness of conservative methods and the progression of the process, surgical treatment and correction of intraarticular disorders are carried out.

The purpose of conservative treatment is the removal of pain, inflammation, swelling in the joint, the restoration of mobility, blood circulation in the tissues of the affected joint. Therapy should be comprehensive and include not only drug treatment, but also physiotherapy, health resort. The following conservative treatment should be comprehensive and consistent with the stage of the disease.

Microcirculation agents are used to restore the microcirculation system. For this purpose, various means are used that are not identical in their mechanism of action: (nicotinic acid, trental, aktovegin, tivortin). They are prescribed in the first stage of the disease in patients without symptoms of synovitis within 2 weeks.

To improve the absorption of oxygen by the tissues of the joint, vitamins of B group are used. Solcoseryl normalizes the metabolic processes in the tissues, especially in severe lesions. Heparin and indirect anticoagulants improve microcirculation indirectly.

Pain relieving and anti-inflammatory therapy. With the development of inflammation in the tissues of the joint, it is better to use means that inactivate the kinin, interleukin (inflammatory enzymes) system - nonsteroidal anti-inflammatory drugs: indomethacin, ibuprofen, diclofenac, xefocam. With the same purpose, the combined drugs with a double action (analgesic and anti-inflammatory) are used - ketonal, diclodev.

Basic antiarthrotic drugs can improve the metabolism of dystrophically modified articular cartilage. These include: chondroprotectors, chondromodulators and collagen medications (chondrosat, glucosat, teraflex, proflex, stromos, etc.), the latter can enhance the regeneration of cartilage and subchondral bone after injuries and dystrophic processes. The main effect of basic drugs is that

they bind the enzymes responsible for cartilage damage and restore its matrix in arthrosis.

Periarticular injection of drugs into the area of periarticular tissues, glucocorticosteroid drugs (depos, phosterone, diprospan, etc.), which reduce the release of lysosomal enzymes and tissue alteration, providing anti-inflammatory, desensitizing suppressive therapy, are injected into the area of the inflamed or partially damaged ligament.

Intraarticular injection of drugs has become widespread, they include hyaluronic acid drugs (ostenil, ostenil plus, arthrum, synovium, etc.) which at proper injection affect all manifestations of arthrosis from stage I to III, but at each stage it is necessary to consider the correct selection of concentration and composition.

Impact on the sympathetic nervous system is achieved by blockages of the nerve trunks, nodes and plexuses, which are aimed to pain elimination and removing muscle spasm with a subsequent increase in the amplitude of movements in the joints.

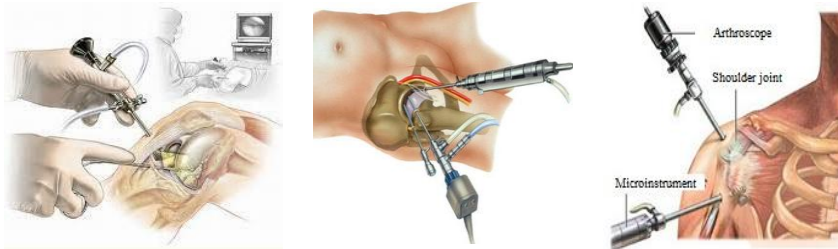
Physiotherapeutic methods of treatment are aimed to stimulate metabolic and trophic processes, restore microcirculation, active recovery processes and reduce dystrophic processes. When prescribing PTT, the disease stage is taken into account. At the initial stages of arthrosis without synovitis, inductothermy, DMW, CMW, SMC, ultrasound therapy, radon, sodium chloride, turpentine baths, mud therapy are prescribed to stimulate metabolic processes. It should be taken into account that in patients with acute exacerbation of synovitis, thermal procedures may intensify the pain syndrome. In these cases, phonophoresis or electrophoresis of lidocaine, hydrocortisone, sodium salicylate is prescribed. UV-irradiation, sinusoidal, diadynamic currents and ultrasound have an analgesic effect. To stimulate metabolic processes in cartilage, electrophoresis is prescribed with chondroprotectors.

Galvanization with the introduction of lytic enzymes ("Karipain-plus") – has been used for more than 15 years. In recent years in Ukraine it has gained wider use. The combination of two factors: galvanic current and the action of enzymes that dissolve non-viable arthritic tissue and fragments of cartilage tissue – gives a pronounced therapeutic effect in many patients.

Locally the compresses with dimexidum and bischofite are used. Physiotherapy and massage stimulate blood circulation, tissue metabolism and contribute to the improvement of joint function. During exacerbation of synovitis, exercise therapy and massage are not indicated. Health resort and spa treatment is started in patients with I–II stages without synovitis in remission. Mud health resorts with sodium chloride and radon waters are prescribed.

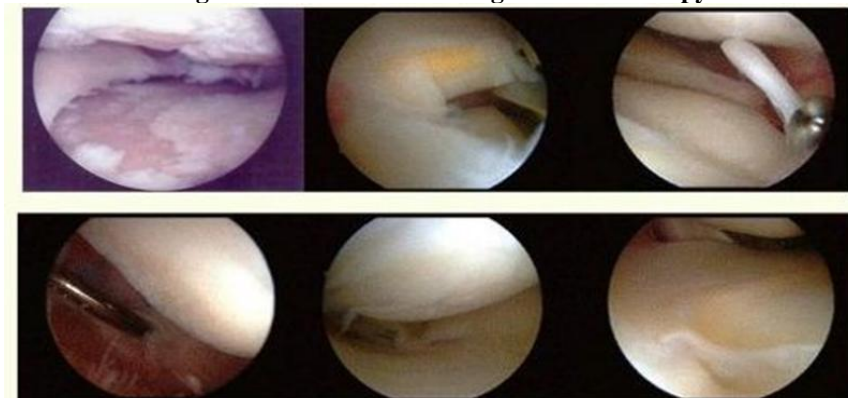
TYPES OF OPERATIONAL TREATMENT OF ARTHROSIS

With the ineffectiveness of conservative therapy a surgical treatment is betaken. Depending on the place of lesion location and its degree, a type of operation is determined that will help the patient to stand up on their feet as quickly as possible, or to improve the function of the joint.



Through small incisions, the camera and instruments are inserted that are manipulated in the articular cavity. Throughout the intervention, physiological fluid is circulated in order to ensure optimal image quality on the video screen.

These images can be observed during knee arthroscopy:



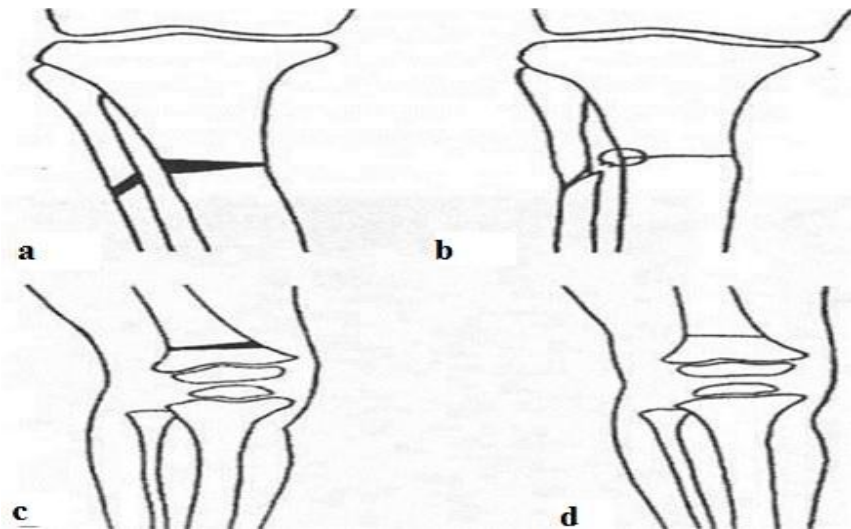
Arthroscopic debridement is an operation that represents the introduction of an arthroscope into a joint and the removal of damaged areas of cartilage tissue. A huge plus of this method is in the rapid removal of pain at II and III stages of arthrosis, as it is not always possible to relieve pain with analgesics. However, the effectiveness of debridement is small: after 1–2 years, the problem of arthrosis returns with all the symptoms and discomfort.

Osteotomy

This method consists in cutting a part of the bone and installing the joint and the adjacent bones at the right angle. If a predominant lesion of the inner or outer part of the joint is found, with small curvatures of the shin, it is possible to perform an operation called corrective tibial subcondylar valgus osteotomy with the lesion of the inner part of the knee joint.

At the lesion of the outer part of the joint, femoral varus supracondylar osteotomy is performed. The implementation of this surgical intervention allows achieving uniformity of the load on the articular surfaces. With a successful operation, good results are achieved in 85 % of patients and the function of the knee joint lasts up to 10 years.

Thus, after surgery and recovery, the load on the affected part of the joint is reduced to the maximum. The effect of such operation is not long-lasting, and the process itself is rather complicated, as is the rehabilitation of the patient after the intervention.

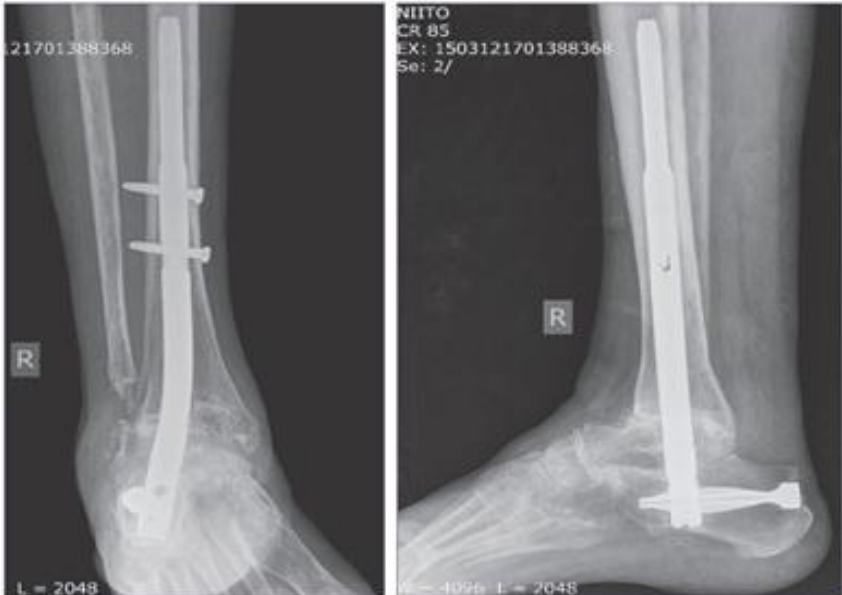

Wedge osteotomy:

- a, b – wedge osteotomy of the tibia and oblique osteotomy at the same level of the fibula (a – before surgery; b – after surgery);
- c, d – wedge-shaped osteotomy of the femur with genu valgum (c – before surgery; d – after surgery)

Arthrodesis

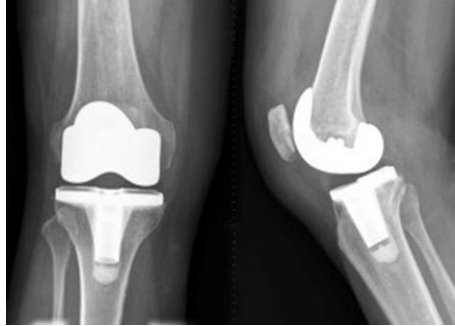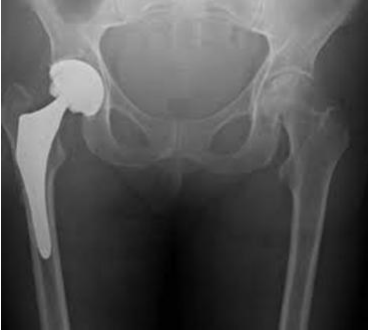Surgical treatment with arthrodesis is one of the most radical methods. It consists of the removal of articular tissue (cartilage and subchondral bone), and fixation by various metal structures (Fig. 2), which leads to the fusion of the articular bones. After the operation, the pain disappears, the possibility of joint damagerecurrence is eliminated, but the limb mobility is severely limited.



Radiograms of ankle joint after arthrodesis with HAN nail (Synthes, Switzerland)

Joint replacement

Artificial replacement of the damaged joint is one of the most effective methods of surgical treatment of coxarthrosis-gonarthrosis. With proper installation of the prosthesis and good rehabilitation, the joint will not disturb the patient for at least next 15–20 years. Rehabilitation measures will allow the patient to fully restore the joint efficiency in a short time, unlike other methods. The only disadvantage of this method of surgical treatment is the cost of the operation. Since arthrosis has been a disease that cannot be cured by 100 %, the decision to replace the joint is optimal, despite the exigency of the method.



7. Questions for self-control

1. Give the definition of "deforming arthrosis".
2. What is included in the concept of "Synovial surrounding of the joint"?
3. What are the nutrition sources of articular cartilage? a), b)
4. Explain the meaning of the phrase: "Movement is life."
5. What process takes the first place in the pathogenesis of deforming arthrosis?
6. Why is there a narrowing of the joint space in case of deforming arthrosis?
7. What is the origin of osteosclerosis of articular surfaces?
8. What is the origin of osteophytes?
9. What is the cause of "starting pains"?
10. How many stages are distinguished in the course of deforming arthrosis?
11. List the forms of gonarthrosis: a), b), c), d).
12. What is the purpose of conservative treatment of primary arthrosis?
13. List drugs with microcirculatory effect.
14. List the groups of anti-inflammatory and analgesic drugs for deforming arthrosis.
15. Objectives of surgical treatment of primary arthrosis of the joints of the lower extremities: a), b).

Reference answers to questions for self-control

1. Deforming arthrosis is a chronic primary degeneration of the articular cartilage, followed by a reactive-degenerative process in the epiphases of the articulating bones of the joint.
2. a) the synovial membrane; b) synovial fluid; c) articular cartilage.
3. a) synovial fluid; b) vessels of the subchondral region of the epiphase.

4. Exchange processes in cartilage occur during movement: loading – removal of waste products from cartilage; unloading - the entrance of nutrients into the cartilage with synovial fluid.

5. Factor of cartilage malnutrition.

6. Due to the loss of elasticity of cartilage and its chondrolysis.

7. Irritation of the epiphyse subchondral plates promotes an increase in the production of bone substance in them.

8. An increase in the amount of bone substance in the subchondral zone with a continuation of the load on the joint promotes the “migration” of the bone substance from the production zone to the places with the least pressure.

9. At the beginning of walking, the load on the articular surface is most of all falls to the place of the greatest thinning and degeneration of the articular cartilage, which irritates the nerve endings of the subchondral plates, causing pain. While moving the pain subsides, because the load while walking also affects other less modified parts of the articular surfaces.

10. Four: I, II, III, IV

11. a) with predominant lesion of the external part of the joint; b) – “– –“ internal – “– – c) arthrosis of the patellofemoral articulation; d) with damage to all parts of the joint;

12. restoration of blood circulation in the tissues of the affected joint;

13. nicotinic acid, actovegin, trental, tivortin;

14. a) ibuprofen; b) diclofenac; c) nonsteroidal anti-inflammatory;

15. a) the elimination of pain, b) restoration of support ability of the extremity.

8. Situational tasks:

1. A 50-year-old patient complains of pain in the knee joint, which occurs after prolonged load. During the examination, an idiopathic deforming arthrosis of the right knee joint of the 1st stage was established. What treatment should be prescribed to the patient?

A. *Non-hormonal anti-inflammatory drugs.*

B. *Group “B” vitamins.*

C. *Hormonal anti-inflammatory drugs.*

D. *Physiotherapy treatment.*

E. *Chondroprotectors.**

2. A 45-year-old patient complains of pain in the knee joint, which increases with a slight load, and restriction of movement in the joint. During the examination, deforming arthrosis of the left knee joint of the III degree was detected against the background of varus deformity of the extremity (genu varum). What treatment is advisable to appoint for a patient?

A. *Non-hormonal anti-inflammatory drugs.*

B. *Hormonal anti-inflammatory drugs.*

*C. Operative treatment (corrective osteotomy).**

D. Health resort treatment.

E. Physiotherapy, chondroprotectors.

3. A 52-year-old patient complains of pain in the ankle joint, which is aggravated after prolonged load. 10 years ago, the patient had a fracture of the inner ankle. During the examination, a post-traumatic deforming arthrosis of the left ankle of 1st degree was revealed against the background of flat-valgus deformity of the foot. What treatment is advisable to appoint for a patient firstly?

A. Non-hormonal anti-inflammatory drugs.

B. Health resort treatment.

C. Physiotherapy treatment.

*D Orthopedic insole (inset) – supinatorfor shoes.**

E. Hormonal anti-inflammatory drugs.

4. A 47-year-old patient complains of pain in the ankle joint, which is exacerbated with a slight load, and a restriction of movement in the joint. During the examination, deforming arthrosis of the ankle joint of the III degree was detected. What treatment is advisable to appoint?

A. Physiotherapeutic treatment.

B. Non-hormonal anti-inflammatory drugs, chondroprotectors.

C. Health resort treatment.

D. Hormonal anti-inflammatory drugs.

*E. Operative (joint arthrodesis).**

References

Main

1. Травматология ортопедия / Г. Г. Голка, А. А. Бурьянов. и др. – Винница : Нова Книга, 2016. – 447 с.

2. Меженина Е.П. Травматология и ортопедия / Е. П. Меженина, Ю. Г. Залозный. – Київ : Вища школа, 1985. – 281 с.

3. Травматология и ортопедия / Х. А. Мусалатов, Г. С. Юмашев и др. – Москва : Медицина, 1995. – 560 с.

4. Олекса А. П. Травматология і ортопедія / А. П. Олекса. – Київ : Вища школа, 1993.

5. Трубников В. Ф. Заболевания и повреждения опорно-двигательного аппарата / В. Ф. Трубников. – Киев : Здоров'я, 1984.

6. Трубников В. Ф. Травматология и ортопедия / В. Ф. Трубников. – Киев : Вища школа, 1984.

7. Юмашев Г. С. Травматология и ортопедия / Г. С. Юмашев. – Москва : Медицина, 1983.

Additional

- 1.– Травматологія та ортопедія, збірник тестових завдань для поза аудиторної підготовки студентів до ліцензійних іспитів / Д. Д. Бітчук, А. Г. Істомін и др. – Харків : 2004.
2. Травматологія : учебник / Г. П. Котельников, А. Ф. Краснов и др. – Москва : 2001.
3. Кондрашин Н. И. Руководство по протезированию / Н. И. Кондрашин. – Москва : Медицина, 1986.
4. Мовшович И. А. Оперативная ортопедия / И. А. Мовшович. – Москва : Медицина, 1994.
5. Прозоровский В. Ф. Курс лекций по ортопедии и травматологии / В. Ф. Прозоровский. – Харьков, 2014.
6. Рейнберг С. А. Рентгенодиагностика заболеваний костей и суставов / С. А. Рейнберг. – Москва : Медицина, 1959.
7. Скляренко Е. Т. Хирургия суставов конечностей / Е. Т. Скляренко. – Киев, 1979.
8. Новые методы лечения дефектов гиалинового хряща коленного сустава у больных гонартрозом / А. А. Стадников и др. // Научно-практическая ревматология. – 2009. – № 3. – С. 1–5.
9. Диагностика и лечение дегенеративно-дистрофических поражений суставов / И. В. Шумада и др. – Киев : Здоров'я, 1990.

Навчальне видання

ДЕФОРМУЮЧИЙ АРТРОЗ

**Методичні вказівки
до самостійної підготовки студентів 5-го курсу
медичних факультетів
з дисципліни "Травматологія та ортопедія"**

Упорядники Голка Григорій Григорович
 Гаркуша Максим Анатолійович
 Фадєєв Олег Валентинович
 Олійник Антон Олександрович
 Істомін Дмитро Андрійович
 Бурлака Віктор Володимирович

Відповідальний за випуск Г. Г.Голка



Комп'ютерна верстка О. Ю. Лавриненко

Формат А5. Ум. друк. арк. 1,3. Зам. № 19-33690.

**Редакційно-видавничий відділ
ХНМУ, пр. Науки, 4, м. Харків, 61022
izdatknmurio@gmail.com**

Свідectво про внесення суб'єкта видавничої справи до Державного реєстру видавництв, виготівників і розповсюджувачів видавничої продукції серії ДК № 3242 від 18.07.2008 р.

DEFORMING ARTHROSIS

*Methodical instructions
for self-study of 5th year students
of medical faculties in discipline
"Traumatology and orthopedics"*