

## PYOGENIC PSOAS MUSCLE ABSCESS: REPORT OF THREE CASES

Seiji Takagi, Taiji Tsukamoto, Yoshiaki Kumamoto,  
Takashi Satoh, Hiroki Horita and Mikio Koroku

*From the Department of Urology, Sapporo Medical University School of Medicine*

We report three cases of primary psoas muscle abscess. Two of these cases were treated by open drainage through a lumbar incision and the other was by ultrasonography (USG)-guided percutaneous aspiration of the abscess. Antibiotic therapy was also instituted in all cases. Post-operatively, the patients recovered well with no sign of recurrence. USG-guided percutaneous drainage combined with appropriate antibiotic therapy appears to be the first choice procedure for treatment of the primary psoas abscess if correct diagnosis is promptly made and the procedure can be performed.

(Acta Urol. Jpn. 40: 699-702, 1994)

**Key words:** Psoas abscess, Ultrasonography-guided drainage

### INTRODUCTION

Diagnosis and treatment of abscesses in the psoas muscle (primary or secondary) still remain a challenge to urologists even in the era of modern antibiotics. This is probably due to the non-specific nature of the symptoms and signs of the disease, and thus eventual delay of the diagnosis.

We herein present three cases of a disease that is relatively uncommon for urologists.

### CASE REPORTS

#### Case 1:

A 35-year-old man was referred to our clinic for urological evaluation of a fever of unknown origin and right hydronephrosis on an excretory urogram. He had been complaining of fever and discomfort of the right hip joint for 2 weeks before the referral despite chemotherapy with third-generation antibiotics. On admission, he was febrile (38°C) and had flexion contracture of the right hip as well as tenderness in the lower quadrant on the same side. A hemogram revealed leukocytosis (13,400/mm<sup>3</sup>) and the erythrocyte sedimentation rate (ESR) was accelerated up to 159 mm/hour. C-reactive protein (CRP) was abnormally elevated. Excretory urography

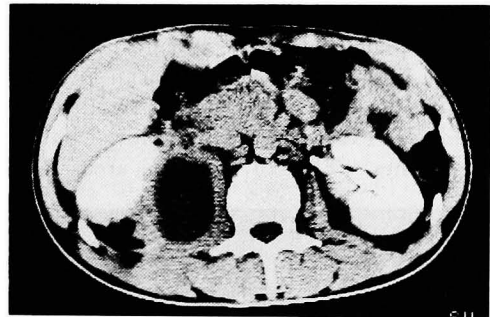


Fig. 1. Low density area in the right psoas muscle of Case 1 shown by CT scan

showed a swollen psoas shadow and mild hydronephrosis on the right side. Urinalysis was normal. Computed tomography (CT) revealed a large, encapsulated low-density area with no enhancement by contrast media in the right psoas muscle (Fig. 1). There were no abnormal radiographic findings in the gastrointestinal series or by barium enema, suggesting no intestinal disease such as Crohn's disease or inflammatory colonic disease. Open drainage through a lumbar incision yielded 320 ml of purulent fluid from the abscess. Antimicrobial chemotherapy with 2 g of cefmetazone, daily was started. He became afebrile on the day after the operation. A culture of the pus produced *Pseudomonas*

*cepa*. On the seventh day, the drainage tube was removed. He is still well 2 years later with no sign of recurrence.

#### Case 2:

The second patient was a 57-year-old man, who had been complaining of fever, appetite loss and right flank dullness that had persisted for more than a week. He was referred for urological evaluation of a retroperitoneal mass that was found on abdominal CT scan in another hospital, where he had received antimicrobial chemotherapy because of persistent fever and acute inflammatory findings in laboratory tests. On admission, he was afebrile and had no sign of flexion contracture of the right hip or tenderness of the right lower back. However, a hemogram showed leukocytosis ( $11,200/\text{mm}^3$ ), and abnormally elevated ESR and CRP, suggesting the presence of a persistent inflammatory focus. Urine was sterile and no pyuria was found. An abdominal CT scan revealed low-density areas in the right swollen psoas muscle extending near the lower pole of the kidney (Fig. 2). These areas were

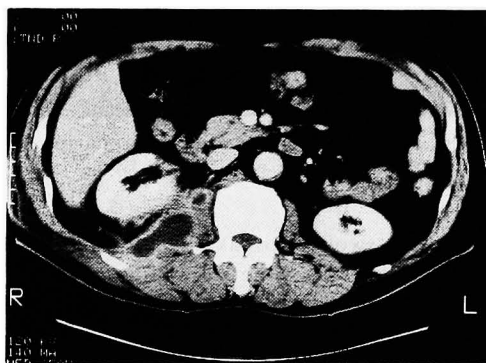


Fig. 2. CT scan of Case 2 demonstrates clearly encapsulated low density areas not enhanced by contrast media.

clearly encapsulated and not enhanced by contrast media. Ultrasonography-guided percutaneous aspiration of the areas produced 35 ml of purulent fluid. Culture did not yield growth of any organisms. Since he was afebrile and had no definite subjective symptoms, only antimicrobial chemotherapy with ofloxacin was continued. A CT scan performed 3 weeks later showed

only small low-density areas remaining. White blood cell (WBC) count and CRP became normal after the chemotherapy. Radiographic and endoscopic examination revealed no inflammatory diseases in the bowel. No recurrence has been found for a year after discharge.

#### Case 3:

A 59-year-old man presented with a one-week history of fever and anorexia. He had suffered from paraplegia and neurogenic bladder due to a cervical cord injury at the age of 52. Since then, he was regularly examined for care of cystostomy at a urology clinic. On admission, no abnormal findings were detected on physical examination other than neurological abnormalities and atrophy of lower extremities. His temperature was 38.4 C and WBC count was elevated to  $13,160/\text{mm}^3$ . Other laboratory tests such as ESR and CRP were abnormal, suggesting the presence of acute inflammation. Urinalysis revealed pyuria (20~30 WBCs/hpf) and urine culture yielded *Serratia marcescens* of  $10^7/\text{ml}$ . Then, antimicrobial chemotherapy with 400 mg of amikacin daily was started under a diagnosis of acute pyelonephritis. However, since fever persisted for more than 5 days in spite of the intensive chemotherapy, radiographic examinations were performed to search for other foci of acute infection. Although the excretory urogram was normal, an abdominal CT scan showed a swollen left psoas muscle containing low density areas (Fig. 3). Open drainage was done, yielding 250 ml

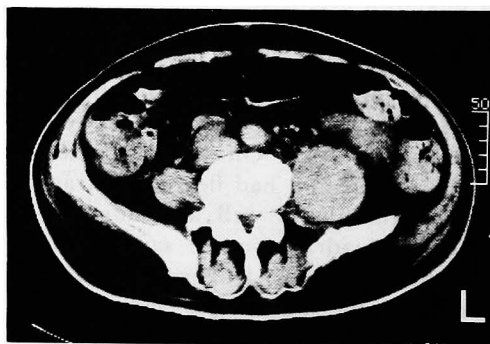


Fig. 3. Precontrast CT scan shows diffuse enlargement of left psoas muscle in Case 3.

of pus discharge. *Bacteroides fragilis* was produced by culture of the pus. Under chemotherapy with 2g of cefmetazone daily, he became afebrile the next day and various abnormal laboratory data became normal within one week. No intestinal abnormalities were identified by radiographic and proctoscopic examination. He is well a year later without recurrence.

### DISCUSSION

Psoas abscesses are classified as primary or secondary depending on their nature. The primary abscess is characterized by hematogenous or lymphatic spread from an occult source that is usually difficult to identify, although a history of trauma often proceeds<sup>1,2)</sup>. The secondary abscess is a result of direct extension from intra-peritoneal, intrapelvic or retroperitoneal infection. Crohn's disease as etiology accounts for more than 50% of the secondary abscesses, appendicitis for 15% and colonic inflammation or neoplastic diseases for 10 %<sup>1)</sup>. Lumbar disc infection and various pelvic inflammations can cause the secondary abscess. The primary abscess is much more frequently found in lesser developed countries where almost all cases are primary, whereas in Europe more than 80% of psoas abscesses are of secondary origin<sup>1 3)</sup>.

Bacteriologically, *Staphylococcus aureus* is most often (more than 88% of the total cases) isolated as a single causative organism in the primary abscess<sup>1)</sup>. On the other hand, gram-negative enteric organisms or anaerobic organisms are more frequently (more than 80% of total cases) isolated in the secondary abscess<sup>1)</sup>. This finding suggests that it is important to rule out occult enteric disease as a cause of abscess whenever culture for pus yields gram-negative enteric or anaerobic organisms. A gram-negative enteric organism was produced in 2 of our 3 cases and an anaerobic organism in the other case. However, no occult enteric diseases were identified by standard examinations. Since the patients had already received intensive chemotherapy when pus was cultured, the original organism (s) may have been eradicated by the chemotherapy.

Irrespective of isolated bacterial species, cases with no apparent etiology are arbitrarily defined as primary. Thus, our three cases can be classified as cases of primary psoas abscess.

Since most symptoms and signs of the disease are of non-specific origin, prompt diagnosis often tends to be difficult. Flexion contracture of the hip is relatively specific if it is present, but urologists may not be familiar with this symptom<sup>4)</sup>. This seems to cause further delay of the diagnosis of this disease. Our third case was very unique in terms of the delay of correct diagnosis. Since the patient had neurological disturbance, he could not be relied on to report subjective symptoms. Moreover, there is always a higher risk of acute pyelonephritis in cystostomy status. These factors influenced the delay in correct diagnosis. Although we regard the third case as a primary abscess, the preceding acute pyelonephritis may have been an etiologic disease because atrophic skeletal muscle has been shown to be attenuated against bacterial infection<sup>5)</sup>.

Treatment for psoas abscess is straightforward if correct diagnosis is made and localization of the abscess is determined by abdominal ultrasonography (USG) or CT<sup>6)</sup>. As in our second case, USG-guided or CT-guided aspiration<sup>3 7 8)</sup> and drainage of the abscess may be a less invasive method with a shorter recovery period than the open drainage used in our other cases. Thus USG-guided or CT-guided aspiration followed by drainage of the abscess is the first choice procedure for isolation of causative organism(s) and treatment of the abscess, if it can be performed.

### REFERENCES

- 1) Ricci MA, Rose FB and Meyar KK: Pyogenic psoas abscess: Worldwide variations in etiology. *World J Surg* 10: 834-843, 1986
- 2) Finnerty RU, Vordermark JS, Modarelli RO, et al.: Primary psoas abscess: Case report and review of literature. *J Urol* 126: 108-109, 1981
- 3) Gruenwald I, Abrahamson J and Cohen O: Psoas abscess: Case report and review of the literature. *J Urol* 147: 1624-1626, 1992

- 4) Lowe BA and Smith AY: Primary psoas abscess. *J Urol* **137**: 485-486, 1987
- 5) Onderdonk AB, Bartlett JG, Louie T, et al.: Microbial synergy in experimental intra-abdominal abscess. *Infect Immunol.* **13**: 22-26, 1976
- 6) Jeffrey RB, Callen PW and Federle MP: Computed tomography of psoas abscess. *J Comput Assist Tomogr* **4**: 639-641, 1980
- 7) Steiner FT, Brem AS and Peter G: Psoas muscle abscess due to *Pasteurella multocida*. *J Urol* **137**: 487-488, 1987
- 8) Kahn FW, Glasser JE and Agger WA: Psoas muscle abscess due to *Yersinia enterocolitica*. *Am J Med* **76**: 947-949, 1983

(Received on October 29, 1993)  
(Accepted on April 21, 1994)

## 和文抄録

### 腸腰筋膿瘍の3例

札幌医科大学泌尿器科学教室 (主任: 熊本悦明教授)

高木 誠次, 塚本 泰司, 熊本 悦明  
佐藤 隆志, 堀田 浩貴, 小六 幹雄

原発性腹腰筋膿瘍の3例を経験した。3例中2例に腰部斜切開による切開排膿術を施行した。他の1例に対しては、超音波ガイド下に穿刺吸引を行った。3例ともに術後経過は良好で再発は認めなかった。原発性

腸腰筋膿瘍の治療法として正しい診断がつき次第、超音波ガイド下に経皮的ドレナージを行い、適切な抗菌薬投与を行うことが重要と考えられた。

(泌尿紀要 **40**: 699-702, 1994)