

# **Anatomy of abdominal anterior cutaneous intercostal nerves with respect to the pathophysiology of anterior cutaneous nerve entrapment syndrome (ACNES): A case study.**

Frédérique M.U. Mol

Arno Lataster

Marc R.M. Scheltinga

Rudi M.H. Roumen

*Translational Research in Anatomy* 2017; 8-9: 6-10.  
[doi.org/10.1016/j.tria.2017.10.001](https://doi.org/10.1016/j.tria.2017.10.001)

## ABSTRACT

**Introduction:** Anterior Cutaneous Nerve Entrapment Syndrome is allegedly caused by entrapment of an intercostal nerve in a fibrous ring in the rectus abdominis muscle leading to neuropathic pain. Surgical release of the strained nerve (neurectomy) obtains adequate pain relief in 70% of patients. Standard anatomy texts and previous research however might underestimate the complex network of nerve branches in the abdominal wall, leading to suboptimal treatment results and misguided pathophysiology.

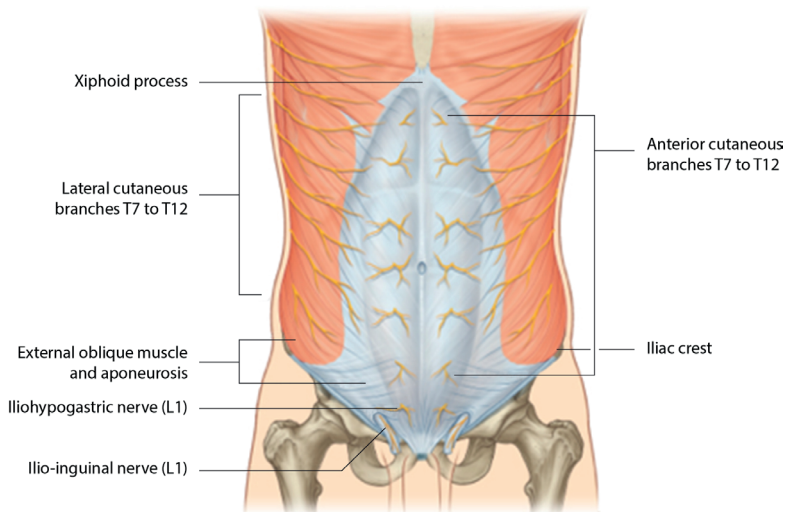
**Material and methods:** One fresh frozen cadaver with no gross previous pathology was dissected to map the course of intercostal nerves from the lateral abdominal wall to their nerve terminals in the subcutis of the anterior abdominal wall. Histology was performed to differentiate between nerve tissue and fascia. Special attention was paid to fibrous ring like structures.

**Results:** Five major neurovascular bundles were identified (T8-T12). Fibrous rings were not found intramuscularly but in the posterior rectus sheath, if present. Multiple neural interconnections at the lateral border of the posterior rectus sheath were found. Per dermatome several small branches perforated the rectus abdominis muscle.

**Conclusions:** The trajectory of nerves in the abdominal wall appears to be more complex than previously suggested, which should be addressed when for instance a neurectomy is performed.

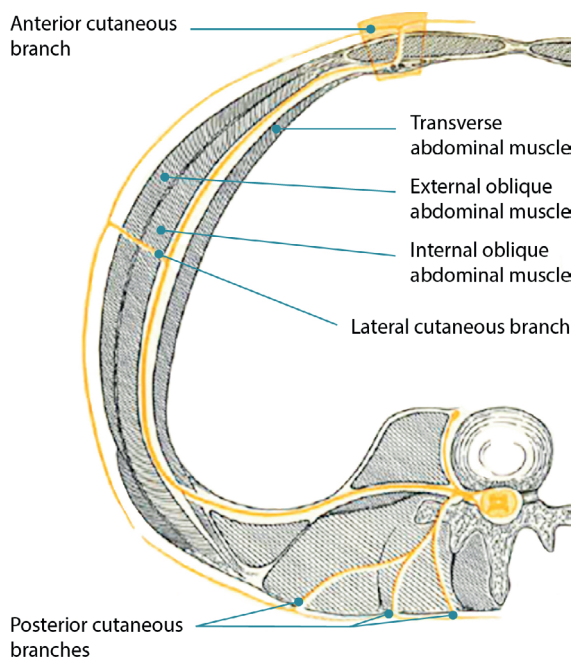
## INTRODUCTION

A frequently overlooked cause of chronic abdominal wall pain is the anterior cutaneous nerve entrapment syndrome (ACNES). This syndrome is characterized by an exceedingly painful peripheral neuropathy, allegedly caused by entrapped sensory cutaneous terminal branches of abdominal intercostal nerves innervating the skin of the lateral and anterior abdominal wall.<sup>1,2</sup> Entrapment may occur at various anatomic sites, for instance where the nerve passes through fibrous or osseofibrous structures or penetrates muscles as also observed in carpal tunnel syndrome and sciatic nerve entrapment.<sup>3,4</sup> In the case of ACNES this concerns the 6 lowest intercostal nerves (T7 –T12) which are anchored (1) to the spinal cord, (2) to the dorsal branch of the spinal nerve, (3) at the level where the lateral cutaneous branch originates, (4) at the entering point of the anterior cutaneous branch into the posterior rectus sheath and (5) to the skin. (fig. 1).



**Fig. 1:** Lateral and anterior cutaneous nerve branches of the abdominal wall. Source: Drake et al: Gray's Anatomy for Students, 2<sup>nd</sup> edition Copyright 2009 by Churchill Livingstone, an imprint of Elsevier, Inc., chapter 44; The Abdomen, page 259.

According to one previous microanatomy study the most likely anatomical site of entrapment is the point where the neurovascular bundle enters the posterior rectus abdominis sheath it makes a nearly 90° turn, piercing through the rectus muscle, eventually reaching the skin (Fig 2). The author of this study claimed that the neurovascular bundle is encircled at this level by a fibrous ring, located intramuscular just anterior from the posterior rectus sheath (Fig. 3). He suggested that connective fat tissue is able to herniate within this ring once changes in intraabdominal pressure occur. This chain of events would result in neural ischemia causing pain.<sup>5,6</sup>

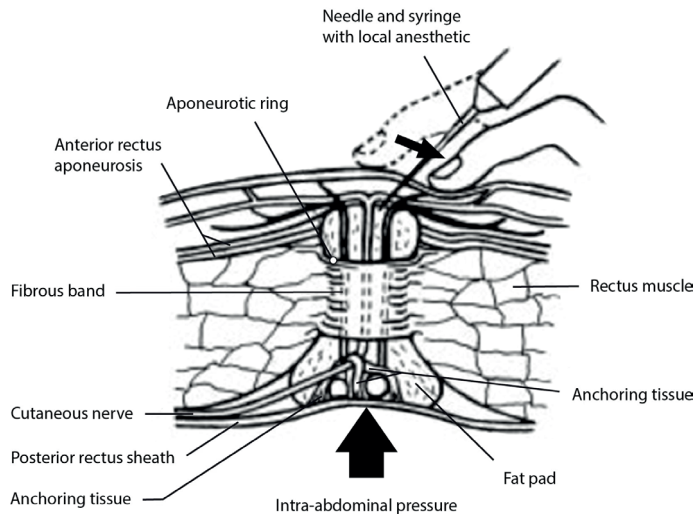


**Fig. 2:** Anchoring points of the intercostal nerve from back to abdominal wall. The anterior branch makes a sharp 90 degree turn through the rectus muscle. Illustration from Applegate WV, Abdominal cutaneous nerve entrapment syndrome. *Am Fam Physician.* 1973 Sep;8(3):132-3.

ACNES can therefore occur in each dermatome of the trunk that is innervated by the lower six intercostal nerves. Patients typically complain of abdominal pain at a one-finger-tip specific point projecting over the rectus abdominis muscle. Pain is often severe requiring selective nerve blocks or even a surgical intervention.<sup>7</sup> A neurectomy appeared to be an effective treatment modality as demonstrated in a double blind randomized setting.<sup>8</sup> The rationale of this procedure is to remove the pain generating nerve terminals and to release the entrapped nerve. Two types of procedures are performed. The first approach focuses on the nerve terminals at the site of the *anterior* fascia of the rectus abdominis muscle and obtains adequate pain relief in some 70% of operated patients.<sup>9</sup> Patients who experience insufficient pain relief after this procedure are eligible for a second operation. During this procedure, the neurovascular bundle is identified and removed at the posterolateral border of the muscle. The success rate of this secondary procedure is between 50-60%.<sup>10</sup>

Observations based on approximately 150 secondary neurectomy procedures performed by the two senior authors (RR and MS) indicate that the anatomy of these intercostal nerve terminals is more variable and complex than suggested in standard anatomy texts. The aim of the present study was to take a first step in exploring and delineating the topography of the intercostal nerves at the level of the rectus muscle

through cadaveric dissection and to relate the observed anatomical patterns to clinical aspects of ACNES.



**Fig. 3:** Detail of fibrous ring as described by W. Applegate. Source: Abdominal Cutaneous Nerve Entrapment Syndrome (ACNES): A commonly overlooked cause of abdominal pain. The Permanente Journal/ Summer 2002 / Volume 6 No. 3.

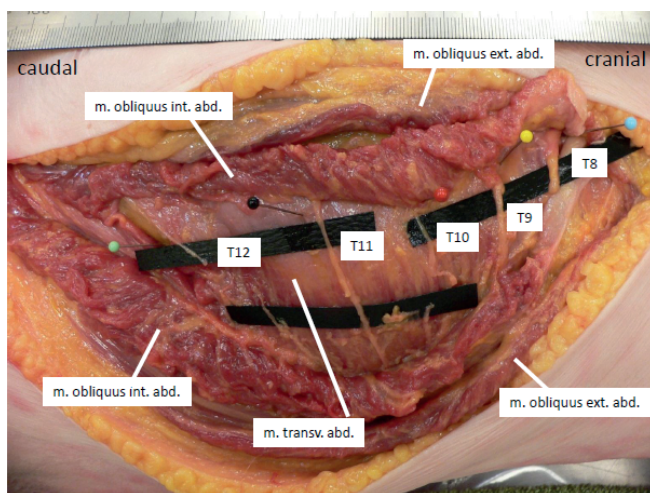
## MATERIALS AND METHODS

A fresh frozen cadaver was dissected at the Department of Anatomy and Embryology, Faculty of Health, Medicine Life Sciences of Maastricht University, Maastricht, the Netherlands by two experienced surgeons (RR and MS) who also perform neurectomy procedures. The cadaver was of an 84-year old female without gross pathology, previous surgical procedures or traumatic lesions to the abdomen or pelvis. The dissection procedure started with a 20 cm longitudinal incision some 15cm lateral to the midline xyphoid process-umbilicus-symphysis. The left external and internal oblique abdominal muscles were dissected, exposing the left transverse abdominal muscle and the fascia transversalis. Five major neurovascular bundles (T8-T12) were identified within this plane and were followed proximally and distally. Tissue samples were collected and processed for histology at the Department of Anatomy and Embryology using standard Hematoxylin & Eosin (HE) staining to differentiate nerve tissue from fascia connections and blood vessels and confirm the presence of neural tissue and Osmium Tetroxide ( $\text{OsO}_4$ ) staining more specifically for myelin.

During dissection, images were recorded with a Panasonic Lumix digital camera (model: DMC-FZ3). Specific attention was paid to nerve interconnections, plane of penetration and branches that penetrated the fascia of the anterior rectus sheath.

## RESULTS

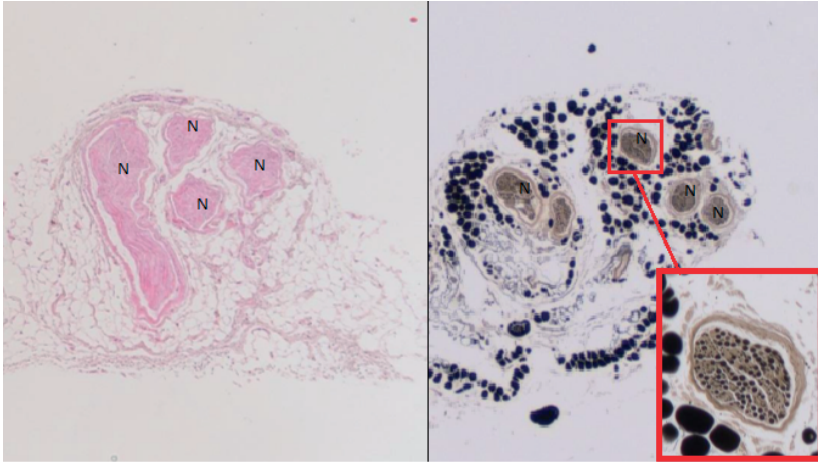
Five major neurovascular bundles were exposed using a latero-medial approach (Fig. 4). Histology confirmed the presence of multiple separate nerve fibers in all bundles (Fig. 5), (Table 1). T11 (black) and T10 (red) were traced distally to where they enter the posterior rectus muscle sheath. At this point, a network of interconnections was observed before the remaining anterior bundles branched into several minor perforators disappearing into the rectus muscle (Fig.6). A fibrous ring could not be identified at these T10-T11 branches as they appeared to run over the fascia transversalis without any strong relation to other fascial layers.



**Fig. 4:** Overview as seen from the left side of the abdomen. Right is cranial and left is caudal. Five neurovascular bundles T8-T12 are identified in the transverse abdominal plane and indicated by colored pins. Oblique abdominal muscles are folded away. T12 was damaged during dissection.

A deeper located branch of T9, however, appeared to travel beneath the internal oblique abdominal muscle and ran within the posterior rectus sheath through a resistant fibrous foramen (Fig. 6, Fig. 7). At this level, the posterior rectus sheath is a fusion of the deep internal oblique abdominal aponeurosis and the transverse abdominal aponeurosis. In our opinion, this structure might correspond with the description of a fibrous ring. However, we did not observe any structure resembling a fibrous ring at every level of T8 to T12.

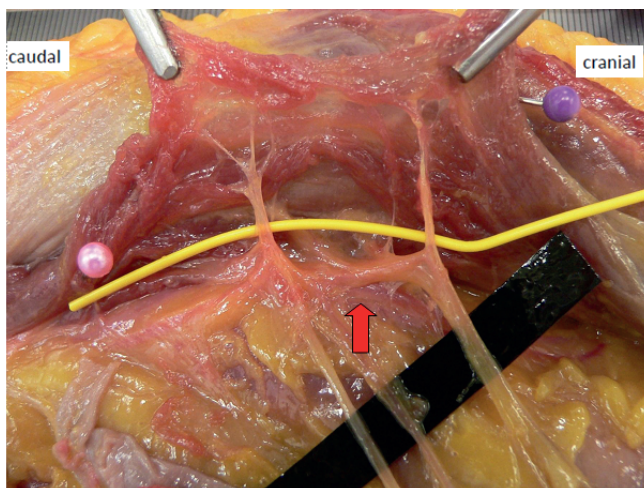
The right side of the abdominal wall was then opened 1 cm from the umbilical midline. This approach may to a certain extent be regarded as the approach used for an anterior neurectomy. The subcutis was dissected and folded away from the anterior rectus sheath, exposing anterior terminal branches of the minor perforating neurovascular



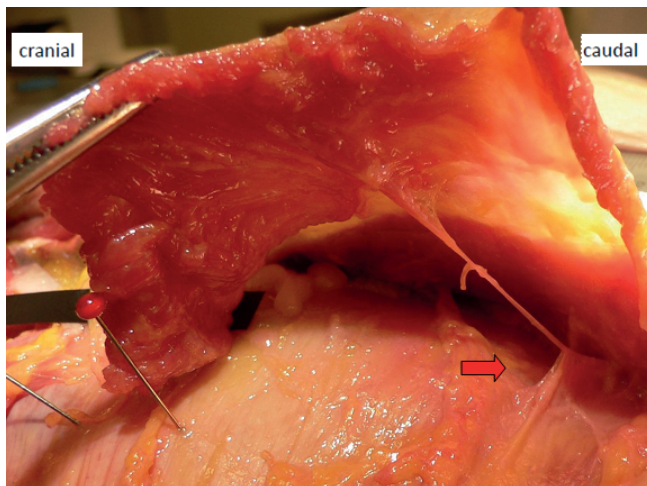
**Fig. 5:** An example of the histological findings in the tissue sample of T8 using hematoxylin & eosin (HE) and osmium tetroxide ( $\text{OsO}_4$ ) staining at 5x magnification. 'N' signifies nerve tissue. The inlay shows one nerve strand at 10x magnification.

**Table 1.** Number of nerve strands per histology sample in Fig. 4.

Nerve ID	Histology Count
T8	4
T9	2
T10	3
T11	2
T12	2

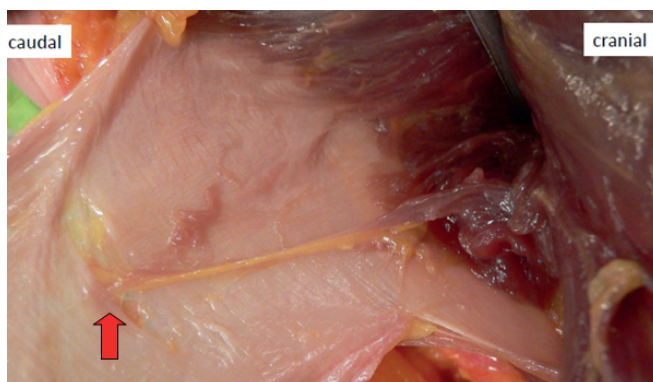

**Fig. 6:** Similar orientation as figure 4. The lateral border of the rectus abdominis muscle is lifted exposing a network of interconnecting branches (red arrow) between T10 and T11.



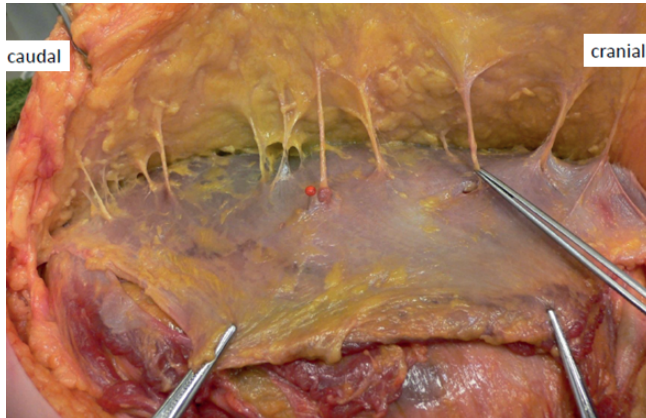
**Fig. 7:** The red arrow indicates where a nerve branch, most probably from T9, tunnels through a fibrous structure consisting of posteriorly located rectus fascia: a ‘fibrous ring’ ?

bundles piercing the rectus muscle. More than 10 nerve-like structures were identified (Fig. 8), although it was exceedingly difficult to distinguish between fibrous strands and nerve tissue at this level. Focusing on T10 (red pin) it may be obvious that two other, albeit smaller bundles, were present within its direct vicinity (Fig. 9) piercing the rectus. All three bundles contained nerve tissue as demonstrated by final histology. In contrast to suggestions as made in Gray’s Anatomy for Students (2<sup>nd</sup> edition, Copyright 2009 by Churchill Livingstone, an imprint of Elsevier, Inc., chapter 44; The Abdomen, page 259) for instance, numerous small perforators and anterior nerve branches may be present at each of the 5 dermatomes comprising the abdominal wall.

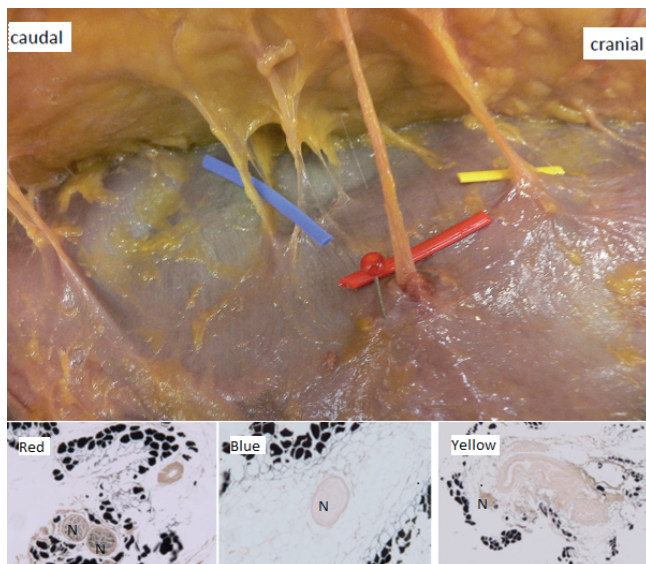


**Fig. 8:** Another example of a nerve structure perforating the posterior rectus sheath that could be identified as a possible Applegate’s fibrous ring (red arrow).





**Fig. 9:** Neurovascular bundles piercing through the anterior rectus sheath. There are evidently more than 5 piercing bundles in total suggesting multiple nerves per each of the 5 dermatomes T8-T10.



**Fig. 10:** Similar orientation as figure 9. T10 (red pin and label) and two smaller bundles (blue and yellow labels) pierce the rectus. Histology in the lower display with osmium tetroxide ( $\text{OsO}_4$ ) staining at 10x magnification demonstrates myelin in all bundles, although less visible in blue and yellow.

In conclusion, various plexiform interconnections between anterior branches of intercostal nerves can be observed at the lateral border of the rectus muscle, possibly extending over multiple dermatomal zones. Second, some nerve branches were found to travel within the posterior rectus sheath, which may potentially be seen as a fibrous ring. Other neurovascular bundles, however, appeared to travel freely in or between

planes whereas fibrous ring like structures could not be identified. Finally, various main and small terminal branches were found per dermatome to perforate the anterior rectus sheath.

## DISCUSSION

This single cadaver study was performed to identify the course of anterior cutaneous branches of intercostal nerves in the abdominal wall. The study suggests that their anatomy is far more complex than suggested and illustrated in standard anatomy texts and previous literature on the pathophysiological mechanisms on ACNES. The present observations may have several consequences for the surgical practice of performing a neurectomy for ACNES.

Using the anterior approach, the surgeon's aim is to identify various branches that perforate the anterior rectus sheath. This is also the conviction of the senior authors who have performed several successful re-explorations in patients with persistent symptoms. The observed neural interconnections at the lateral rectus border are of importance when performing a secondary neurectomy using a posterior approach. The surgeon should be aware of these possible anatomic variations and try to find and resect these small branches at the level of the posterior rectus sheath.

This rather complicated anatomy of intercostal nerves possibly explains why success rates of surgical procedures such as an anterior neurectomy are not beyond 70%. Suboptimal responses to surgery are possibly explained by aberrant intercostal nerve anatomy or by an etiology that differs from an entrapment mechanism.

To attain normative data on topography of abdominal anterior cutaneous branches of intercostal nerves, a number of dissections should be performed and a graded system for variations should be initiated as previously performed for example for inguinal nerves.<sup>11-13</sup>

Concerning the entrapment hypothesis as the main pathophysiological mechanism for ACNES the present study suggests neurovascular bundles of interest travel rather freely through the transverse abdominal plane and through the rectus sheath. Referred pain mechanisms and visceral-parietal metameres could be a potential different pathophysiological pathway contributing to ACNES and of interest in other present studies.

14, 15

## REFERENCES

1. Applegate WV. Abdominal cutaneous nerve entrapment syndrome (ACNES): a commonly overlooked cause of abdominal pain. *Perm J* 2002;6:20-7.
2. Carnett JB. Intercostal neuralgia as a cause of abdominal pain and tenderness. *Surg Gyn Obstet* 1926;42:625-632
3. Kopell HP, Thompson WA. *Peripheral entrapment neuropathies*. Malabar (FL): Robert E. Kreiger Publishing; 1976. P1-7, 85-8.
4. Chamas M, Boretto J, Burmann LM. Carpal tunnel syndrome – Part I (anatomy, physiology, etiology and diagnosis). *Rev Bras Ortop*. 2014 Aug 20;49(5):429-36.
5. Applegate WV. Abdominal cutaneous nerve entrapment syndrome. *Surgery* 1972;7:118-24.
6. Applegate WV, Buckwalter NR. Microanatomy of the structures contributing to abdominal cutaneous nerve entrapment syndrome. *J Am Board Fam Pract*. 1997 Sep-Oct;10(5):329-32.
7. Boelens OB, Scheltinga MR, Houterman S, Roumen RM. Management of anterior cutaneous nerve entrapment syndrome in a cohort of 139 patients. *Ann Surg* 2011;254:1054-8
8. Boelens OB, van Assen T, Houterman S, Scheltinga MR, Roumen RM. A double-blind, randomized controlled trial on surgery for chronic abdominal pain due to anterior cutaneous nerve entrapment syndrome. *Ann Surg* 2013;257:845-9.
9. Van Assen T, Boelens OB, van Eerten PV, Scheltinga MR, Roumen RM. Surgical options after a failed neurectomy in anterior cutaneous nerve entrapment syndrome. *World J Surg*. 2014 Dec;38(12):3105-11.
10. Van Assen T, Boelens OB, van Eerten PV, Perquin C, Scheltinga MR, Roumen RM. Long-term success rates after an anterior neurectomy in patients with an abdominal cutaneous nerve entrapment syndrome. *Surgery*. 2015 Jan;157(1):137-43.
11. Klaassen Z, Marshall E, Tubbs RS, Louis RG Jr, Wartmann CT, Loukas M. Anatomy of the ilioinguinal and iliohypogastric nerves with observations of their spinal nerve contributions. *Clin Anat*. 2011 24:454-4618.
12. Rozen WM, Tran TM, Ashton MW, Barrington MJ, Ivanusic JJ, Taylor GI. Refining the course of the thoracolumbar nerves: a new understanding of the innervation of the anterior abdominal wall. *Clin Anat*. 2008;21(4):325–333.
13. Bachul PK, Tomaszewski A, Kmiotek EK, Kratochwil M, Solecki R, Walocha JA. Piotr Anatomic variability of groin innervation. *Folia Morphol*. 2013 : Vol. 72, nr 3, s. 267-270
14. Dommerholt J, Grieve R, Hooks T, Layton M. A critical overview of the current myofascial pain literature – October 2015. *J Bodyw Mov Ther*. 2015 Oct;19(4):736-46
15. Giamberardino MA, Vecchiet L. Pathophysiology of visceral pain. *Curr Pain Headache Rep*. 1997; 1:23-33