

II. Osteology

THE GENERAL framework of the body is built up mainly of a series of bones, supplemented, however, in certain regions by pieces of cartilage; the bony part of the framework constitutes the **skeleton**. 1

In the skeleton of the adult there are 206 distinct bones, as follows:— 2

	Vertebral column	26
Axial	Skull	22
Skeleton	Hyoid bone	1
	Ribs and sternum	25
		— 74
Appendicular	Upper extremities	64
Skeleton	Lower extremities	62
		— 126
Auditory ossicles		6
		—
	Total	206

The patellæ are included in this enumeration, but the smaller sesamoid bones are not reckoned. 3

Bones are divisible into four classes: *Long, Short, Flat, and Irregular*. 4

Long Bones.—The long bones are found in the limbs, and each consists of a body or shaft and two extremities. The **body**, or **diaphysis** is cylindrical, with a central cavity termed the **medullary canal**; the wall consists of dense, compact tissue of considerable thickness in the middle part of the body, but becoming thinner toward the extremities; within the medullary canal is some cancellous tissue, scanty in the middle of the body but greater in amount toward the ends. The *extremities* are generally expanded, for the purposes of articulation and to afford broad surfaces for muscular attachment. They are usually developed from separate centers of ossification termed **epiphyses**, and consist of cancellous tissue surrounded by thin compact bone. The medullary canal and the spaces in the cancellous tissue are filled with marrow. The long bones are not straight, but curved, the curve generally taking place in two planes, thus affording greater strength to the bone. The bones belonging to this class are: the **clavicle, humerus, radius, ulna, femur, tibia, fibula, metacarpals, metatarsals, and phalanges**. 5

Short Bones.—Where a part of the skeleton is intended for strength and compactness combined with limited movement, it is constructed of a 6

number of short bones, as in the **carpus** and **tarsus**. These consist of cancellous tissue covered by a thin crust of compact substance. The **patellæ**, together with the other sesamoid bones, are by some regarded as short bones.

Flat Bones.—Where the principal requirement is either extensive protection or the provision of broad surfaces for muscular attachment, the bones are expanded into broad, flat plates, as in the **skull** and the **scapula**. These bones are composed of two thin layers of compact tissue enclosing between them a variable quantity of cancellous tissue. In the cranial bones, the layers of compact tissue are familiarly known as the **tables of the skull**; the outer one is thick and tough; the inner is thin, dense, and brittle, and hence is termed the **vitreous table**. The intervening cancellous tissue is called the **diploë**, and this, in certain regions of the skull, becomes absorbed so as to leave spaces filled with air (*air-sinuses*) between the two tables. The flat bones are: the **occipital, parietal, frontal, nasal, lacrimal, vomer, scapula, os coxæ** (*hip bone*), **sternum, ribs**, and, according to some, the **patella**. 7

Irregular Bones.—The irregular bones are such as, from their peculiar form, cannot be grouped under the preceding heads. They consist of cancellous tissue enclosed within a thin layer of compact bone. The irregular bones are: the **vertebræ, sacrum, coccyx, temporal, sphenoid, ethmoid, zygomatic, maxilla, mandible, palatine, inferior nasal concha**, and **hyoid**. 8

Surfaces of Bones.—If the surface of a bone be examined, certain eminences and depressions are seen. These eminences and depressions are of two kinds: articular and non-articular. Well-marked examples of **articular eminences** are found in the heads of the humerus and femur; and of **articular depressions** in the glenoid cavity of the scapula, and the acetabulum of the hip bone. **Non-articular eminences** are designated according to their form. Thus, a broad, rough, uneven elevation is called a **tuberosity, protuberance, or process**, a small, rough prominence, a **tubercle**; a sharp, slender pointed eminence, **aspine**; a narrow, rough elevation, running some way along the surface, a **ridge, crest, or line**. *Non-articular depressions* are also of variable form, and are described as **fossæ, pits, depressions, grooves, furrows, fissures, notches**, etc. These non-articular eminences and depressions serve to increase the extent of surface for the attachment of ligaments and muscles, and are usually well-marked in proportion to the muscularity of the subject. A short perforation is called a **foramen**, a longer passage a **canal**. 9

1. Development of the Skeleton

The Skeleton.—The skeleton is of mesodermal origin, and may be divided into (*a*) that of the trunk (**axial skeleton**), comprising the vertebral column, skull, ribs, and sternum, and (*b*) that of the limbs (**appendicular skeleton**). 10

The Vertebral Column.—The notochord ([Fig. 19](#)) is a temporary structure and forms a central axis, around which the segments of the vertebral column are developed. [11](#) It is derived from the entoderm, and consists of a rod of cells, which lies on the ventral aspect of the neural tube and reaches from the anterior end of the mid-brain to the extremity of the tail. On either side of it is a column of paraxial mesoderm which becomes subdivided into a number of more or less cubical segments, the **primitive segments** ([Figs. 19](#) and [20](#)). These are separated from one another 11

by **intersegmental septa** and are arranged symmetrically on either side of the neural tube and notochord: to every segment a spinal nerve is distributed. At first each segment contains a central cavity, the **myocœl**, but this is soon filled with a core of angular and spindle-shaped cells. The cells of the segment become differentiated into three groups, which form respectively the cutis-plate or dermatome, the muscle-plate or myotome, and the sclerotome ([Fig. 64](#)). The **cutis-plate** is placed on the lateral and dorsal aspect of the myocœl, and from it the true skin of the corresponding segment is derived; the **muscle-plate** is situated on the medial side of the cutis-plate and furnishes the muscles of the segment. The cells of the **sclerotome** are largely derived from those forming the core of the myocœl, and lie next the notochord. Fusion of the individual sclerotomes in an antero-posterior direction soon takes place, and thus a continuous strand of cells, the **sclerotogenous layer**, is formed along the ventro-lateral aspects of the neural tube. The cells of this layer proliferate rapidly, and extending medialward surround the notochord; at the same time they grow backward on the lateral aspects of the neural tube and eventually surround it, and thus the notochord and neural tube are enveloped by a continuous sheath of mesoderm, which is termed the **membranous vertebral column**. In this mesoderm the original segments are still distinguishable, but each is now differentiated into two portions, an anterior, consisting of loosely arranged cells, and a posterior, of more condensed tissue ([Fig. 65, A and B](#)). Between the two portions the rudiment of the intervertebral fibrocartilage is laid down ([Fig. 65, C](#)). Cells from the posterior mass grow into the intervals between the myotomes ([Fig. 65, B and C](#)) of the corresponding and succeeding segments, and extend both dorsally and ventrally; the dorsal extensions surround the neural tube and represent the future vertebral arch, while the ventral extend into the body-wall as the costal processes. The hinder part of the posterior mass joins the anterior mass of the succeeding segment to form the vertebral body. Each vertebral body is therefore a composite of two segments, being formed from the posterior portion of one segment and the anterior part of that immediately behind it. The vertebral and costal arches are derivatives of the posterior part of the segment in front of the intersegmental septum with which they are associated.

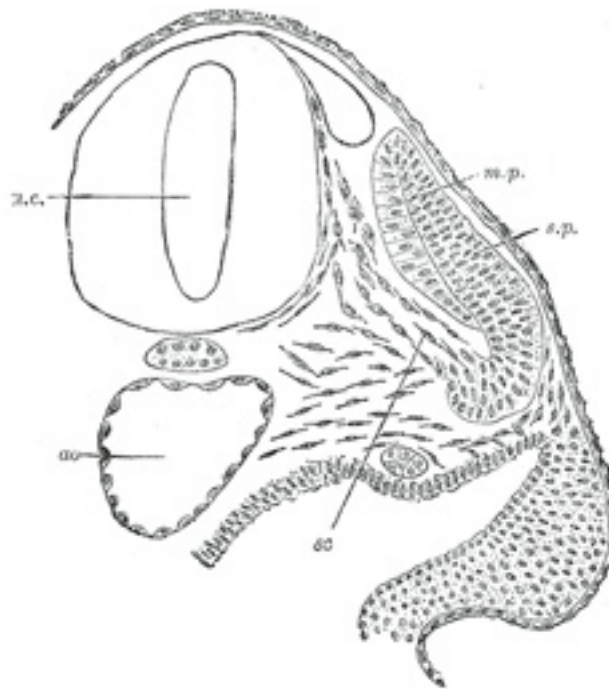


FIG. 64— Transverse section of a human embryo of the third week to show the differentiation of the primitive segment. (Kollmann.) *ao.* Aorta. *m.p.* Muscle-plate. *n.c.* Neural canal. *sc.* Sclerotome. *s.p.* cutis-plate. ([See enlarged image](#))

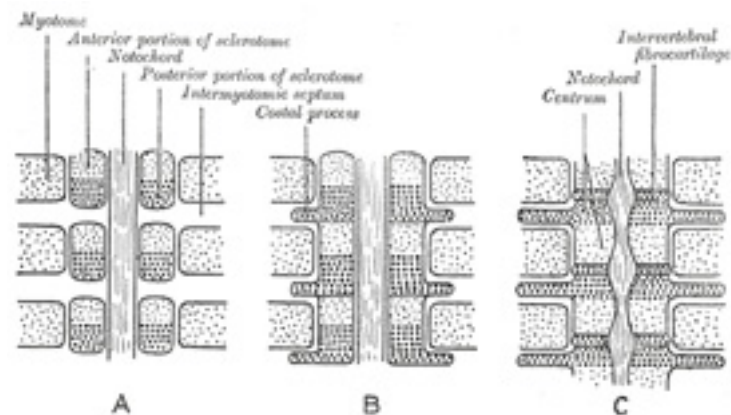


FIG. 65– Scheme showing the manner in which each vertebral centrum is developed from portions of two adjacent segments. ([See enlarged image](#))

This stage is succeeded by that of the **cartilaginous vertebral column**. In the fourth week two cartilaginous centers make their appearance, one ¹² on either side of the notochord; these extend around the notochord and form the body of the cartilaginous vertebra. A second pair of cartilaginous foci appear in the lateral parts of the vertebral bow, and grow backward on either side of the neural tube to form the cartilaginous vertebral arch, and a separate cartilaginous center appears for each costal process. By the eighth week the cartilaginous arch has fused with the body, and in the fourth month the two halves of the arch are joined on the dorsal aspect of the neural tube. The spinous process is developed from the junction of the two halves of the vertebral arch. The transverse process grows out from the vertebral arch behind the costal process.

In the upper cervical vertebræ a band of mesodermal tissue connects the ends of the vertebral arches across the ventral surfaces of the ¹³ intervertebral fibrocartilages. This is termed the **hypochordal bar** or **brace**; in all except the first it is transitory and disappears by fusing with the fibrocartilages. In the atlas, however, the entire bow persists and undergoes chondrification; it develops into the anterior arch of the bone, while the cartilage representing the body of the atlas forms the dens or odontoid process which fuses with the body of the second cervical vertebra.

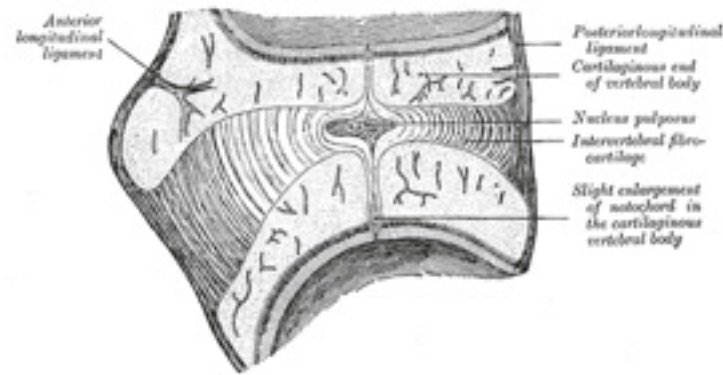


FIG. 66—Sagittal section through an intervertebral fibrocartilage and adjacent parts of two vertebræ of an advanced sheep's embryo. (Kölliker.)
([See enlarged image](#))

The portions of the notochord which are surrounded by the bodies of the vertebræ atrophy, and ultimately disappear, while those which lie in the centers of the intervertebral fibrocartilages undergo enlargement, and persist throughout life as the central **nucleus pulposus** of the fibrocartilages ([Fig. 66](#)).

14

The Ribs.—The ribs are formed from the ventral or costal processes of the primitive vertebral bows, the processes extending between the muscle-plates. In the *thoracic region* of the vertebral column the costal processes grow lateralward to form a series of arches, the **primitive costal arches**. As already described, the transverse process grows out behind the vertebral end of each arch. It is at first connected to the costal process by continuous mesoderm, but this becomes differentiated later to form the costotransverse ligament; between the costal process and the tip of the transverse process the costotransverse joint is formed by absorption. The costal process becomes separated from the vertebral bow by the development of the costocentral joint. In the *cervical vertebræ* ([Fig. 67](#)) the transverse process forms the posterior boundary of the foramen transversarium, while the costal process corresponding to the head and neck of the rib fuses with the body of the vertebra, and forms the antero-lateral boundary of the foramen. The distal portions of the primitive costal arches remain undeveloped; occasionally the arch of the seventh cervical vertebra undergoes greater development, and by the formation of costovertebral joints is separated off as a rib. In the *lumbar region* the distal portions of the primitive costal arches fail; the proximal portions fuse with the transverse processes to form the transverse processes of descriptive anatomy. Occasionally a movable rib is developed in connection with the first lumbar vertebra. In the *sacral region* costal processes are developed only in connection with the upper three, or it may be four, vertebræ the processes of adjacent segments fuse with one another to form the lateral parts of the sacrum. The *coccygeal vertebræ* are devoid of costal processes.

15

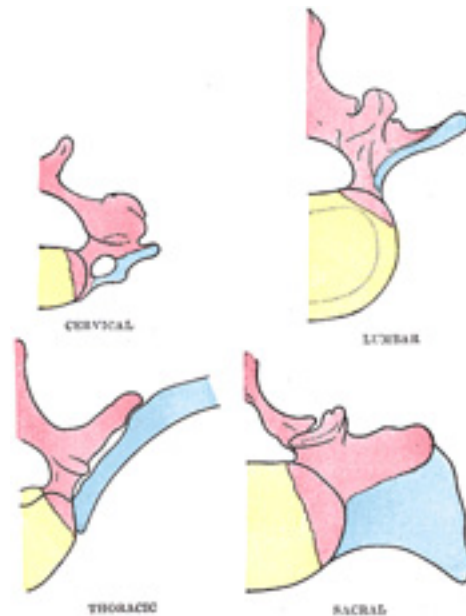


FIG. 67—Diagrams showing the portions of the adult vertebræ derived respectively from the bodies, vertebral arches, and costal processes of the embryonic vertebræ. The bodies are represented in yellow, the vertebral arches in red, and the costal processes in blue. ([See enlarged image](#))

The Sternum.—The ventral ends of the ribs become united to one another by a longitudinal bar termed the **sternal plate**, and opposite the first seven pairs of ribs these sternal plates fuse in the middle line to form the manubrium and body of the sternum. The xiphoid process is formed by a backward extension of the sternal plates. 16

The Skull.—Up to a certain stage the development of the skull corresponds with that of the vertebral column; but it is modified later in association with the expansion of the brain-vesicles, the formation of the organs of smell, sight, and hearing, and the development of the mouth and pharynx. 17

The notochord extends as far forward as the anterior end of the mid-brain, and becomes partly surrounded by mesoderm ([Fig. 68](#)). The posterior part of this mesodermal investment corresponds with the basilar part of the occipital bone, and shows a subdivision into four segments, which are separated by the roots of the hypoglossal nerve. The mesoderm then extends over the brain-vesicles, and thus the entire brain is enclosed by a 18

mesodermal investment, which is termed the **membranous cranium**. From the inner layer of this the bones of the skull and the membranes of the brain are developed; from the outer layer the muscles, bloodvessels, true skin, and subcutaneous tissues of the scalp. In the shark and dogfish this membranous cranium undergoes complete chondrification, and forms the cartilaginous skull or **chondrocranium** of these animals. In mammals, on the other hand, the process of chondrification is limited to the base of the skull—the roof and sides being covered in by membrane. Thus the bones of the base of the skull are preceded by cartilage, those of the roof and sides by membrane. The posterior part of the base of the skull is developed around the notochord, and exhibits a segmented condition analogous to that of the vertebral column, while the anterior part arises in front of the notochord and shows no regular segmentation. The base of the skull may therefore be divided into (a) a **chordal or vertebral**, and (b) a **prechordal or prevertebral portion**.

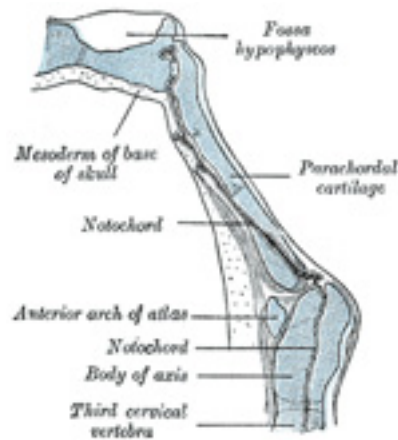


FIG. 68— Sagittal section of cephalic end of notochord. (Keibel.) ([See enlarged image](#))

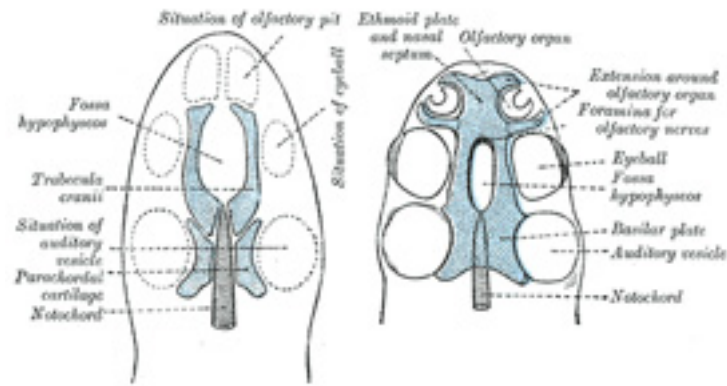


FIG. 69– Diagrams of the cartilaginous cranium. (Wiedersheim.) ([See enlarged image](#))

In the lower vertebrates two pairs of cartilages are developed, viz., a pair of parachordal cartilages, one on either side of the notochord; and a pair of prechordal cartilages, the **trabeculae cranii**, in front of the notochord (Fig. 66). The **parachordal cartilages** (Fig. 69) unite to form a basilar plate, from which the cartilaginous part of the occipital bone and the basi-sphenoid are developed. On the lateral aspects of the parachordal cartilages the auditory vesicles are situated, and the mesoderm enclosing them is soon converted into cartilage, forming the **cartilaginous ear-capsules**. These cartilaginous ear-capsules, which are of an oval shape, fuse with the sides of the basilar plate, and from them arise the petrous and mastoid portions of the temporal bones. The **trabeculae cranii** (Fig. 69) are two curved bars of cartilage which embrace the hypophysis cerebri; their posterior ends soon unite with the basilar plate, while their anterior ends join to form the **ethmoidal plate**, which extends forward between the fore-brain and the olfactory pits. Later the trabeculae meet and fuse below the hypophysis, forming the floor of the fossa hypophyseos and so cutting off the anterior lobe of the hypophysis from the stomodeum. The median part of the ethmoidal plate forms the bony and cartilaginous parts of the nasal septum. From the lateral margins of the trabeculae cranii three processes grow out on either side. The anterior forms the ethmoidal labyrinth and the lateral and alar cartilages of the nose; the middle gives rise to the small wing of the sphenoid, while from the posterior the great wing and lateral pterygoid plate of the sphenoid are developed (Figs. 70, 71). The bones of the vault are of membranous formation, and are termed **dermal** or **covering bones**. They are partly developed from the mesoderm of the membranous cranium, and partly from that which lies outside the entoderm of the foregut. They comprise the upper part of the occipital squama (interparietal), the squamæ and tympanic parts of the temporals, the parietals, the frontal, the vomer, the medial pterygoid plates, and the bones of the face. Some of them remain distinct throughout life, e.g., parietal and frontal, while others join with the bones of the chondrocranium, e.g., interparietal, squamæ of temporals, and medial pterygoid plates.

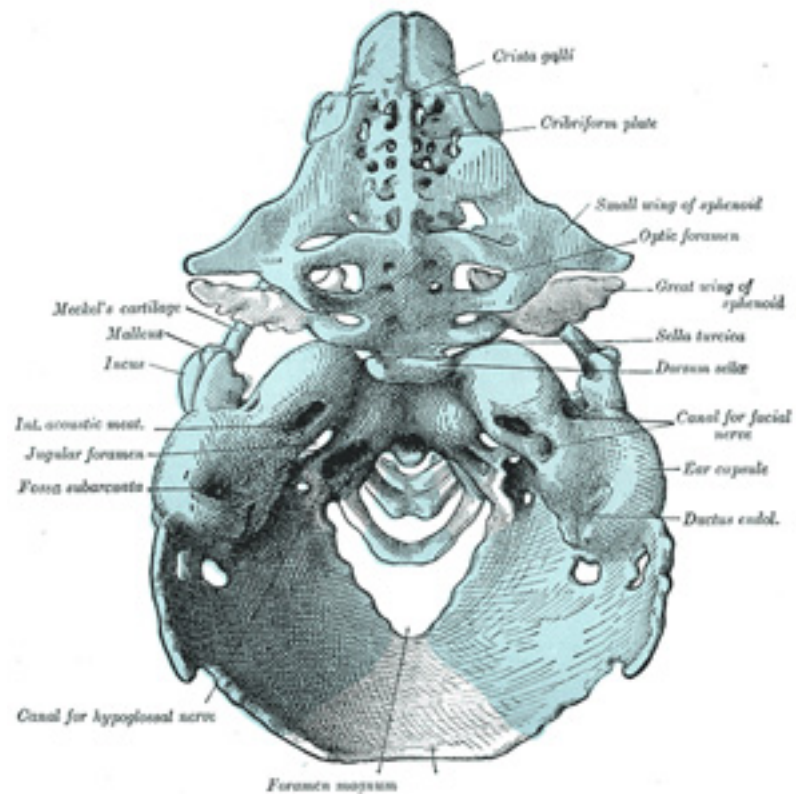


FIG. 70— Model of the chondrocranium of a human embryo, 8 cm. long. (Hertwig.) The membrane bones are not represented. ([See enlarged image](#))

Recent observations have shown that, in mammals, the basi-cranial cartilage, both in the chordal and prechordal regions of the base of the skull, ²⁰ is developed as a single plate which extends from behind forward. In man, however, its posterior part shows an indication of being developed from two chondrifying centers which fuse rapidly in front and below. The anterior and posterior thirds of the cartilage surround the notochord, but its middle third lies on the dorsal aspect of the notochord, which in this region is placed between the cartilage and the wall of the pharynx.

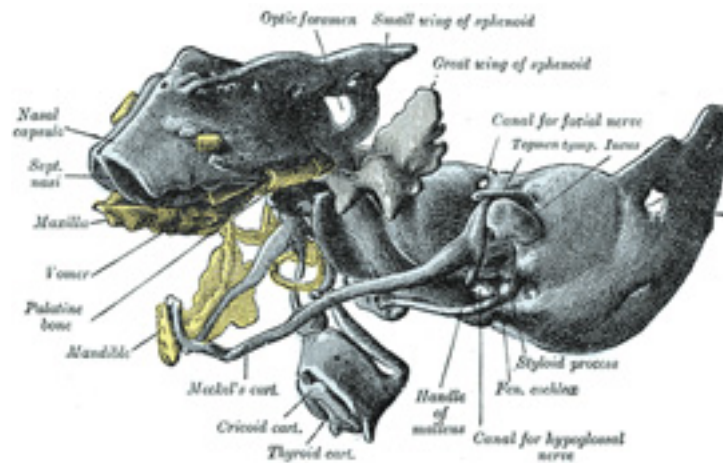


FIG. 71— The same model as shown in [Fig. 70](#) from the left side. Certain of the membrane bones of the right side are represented in yellow. (Hertwig.) ([See enlarged image](#))

Note 11. In the amphioxus the notochord persists and forms the only representative of a skeleton in that animal. [\[back\]](#)

2. Bone

Structure and Physical Properties.—Bone is one of the hardest structures of the animal body; it possesses also a certain degree of toughness and elasticity. Its color, in a fresh state, is pinkish-white externally, and deep red within. On examining a section of any bone, it is seen to be composed of two kinds of tissue, one of which is dense in texture, like ivory, and is termed **compact tissue**; the other consists of slender fibers and lamellæ, which join to form a reticular structure; this, from its resemblance to lattice-work, is called **cancellous tissue**. The compact tissue is always placed on the exterior of the bone, the cancellous in the interior. The relative quantity of these two kinds of tissue varies in different bones, and in different parts of the same bone, according as strength or lightness is requisite. Close examination of the compact tissue shows it to be extremely porous, so that the difference in structure between it and the cancellous tissue depends merely upon the different amount of solid matter, and the size and number of spaces in each; the cavities are small in the compact tissue and the solid matter between them abundant, while in the cancellous tissue the spaces are large and the solid matter is in smaller quantity.

Bone during life is permeated by vessels, and is enclosed, except where it is coated with articular cartilage, in a fibrous membrane,

the **periosteum**, by means of which many of these vessels reach the hard tissue. If the periosteum be stripped from the surface of the living bone, small bleeding points are seen which mark the entrance of the periosteal vessels; and on section during life every part of the bone exudes blood from the minute vessels which ramify in it. The interior of each of the long bones of the limbs presents a cylindrical cavity filled with marrow and lined by a highly vascular areolar structure, called the **medullary membrane**.

THE STRENGTH OF BONE COMPARED WITH OTHER MATERIALS

Substance.	Weight in pounds per cubic foot.	Ultimate strength. Pounds per square inch.		
		Tension.	Compression.	Shear.
Medium steel	490	65,000	60,000	40,000
Granite	170	1,500	15,000	2,000
Oak, white	46	12,500 12	7,000	4,000 13
Compact bone (low)	119	13,200	18,000	11,800
Compact bone (high)	17,700	24,000	7,150

Periosteum.—The periosteum adheres to the surface of each of the bones in nearly every part, but not to cartilaginous extremities. When strong tendons or ligaments are attached to a bone, the periosteum is incorporated with them. It consists of two layers closely united together, the outer one formed chiefly of connective tissue, containing occasionally a few fat cells; the inner one, of elastic fibers of the finer kind, forming dense membranous networks, which again can be separated into several layers. In young bones the periosteum is thick and very vascular, and is intimately connected at either end of the bone with the epiphysial cartilage, but less closely with the body of the bone, from which it is separated by a layer of soft tissue, containing a number of **granular corpuscles** or **osteoblasts**, by which ossification proceeds on the exterior of the young bone. Later in life the periosteum is thinner and less vascular, and the osteoblasts are converted into an epithelioid layer on the deep surface of the periosteum. The periosteum serves as a nidus for the ramification of the vessels previous to their distribution in the bone; hence the liability of bone to exfoliation or necrosis when denuded of this membrane by injury or disease. Fine nerves and lymphatics, which generally accompany the arteries, may also be demonstrated in the periosteum. 3

Marrow.—The marrow not only fills up the cylindrical cavities in the bodies of the long bones, but also occupies the spaces of the cancellous tissue and extends into the larger bony canals (Haversian canals) which contain the bloodvessels. It differs in composition in different bones. In the bodies of the long bones the marrow is of a *yellow* color, and contains, in 100 parts, 96 of fat, 1 of areolar tissue and vessels, and 3 of fluid with extractive matter; it consists of a basis of connective tissue supporting numerous bloodvessels and cells, most of which are fat cells but some are “marrow cells,” such as occur in the red marrow to be immediately described. In the flat and short bones, in the articular ends of the long bones, in the bodies of the vertebræ, in the cranial diploë, and in the sternum and ribs the marrow is of a *red* color, and contains, in 100 4

parts, 75 of water, and 25 of solid matter consisting of cell-globulin, nucleoprotein, extractives, salts, and only a small proportion of fat. The red marrow consists of a small quantity of connective tissue, bloodvessels, and numerous cells (Fig. 72), some few of which are fat cells, but the great majority are roundish nucleated cells, the true “marrow cells” of Kölliker. These marrow cells proper, or **myelocytes**, resemble in appearance lymphoid corpuscles, and like them are ameboid; they generally have a hyaline protoplasm, though some show granules either oxyphil or basophil in reaction. A number of eosinophil cells are also present. Among the marrow cells may be seen smaller cells, which possess a slightly pinkish hue; these are the **erythroblasts** or **normoblasts**, from which the red corpuscles of the adult are derived, and which may be regarded as descendants of the nucleated colored corpuscles of the embryo. **Giant cells** (*myeloplaxes*, *osteoclasts*), large, multinucleated, protoplasmic masses, are also to be found in both sorts of adult marrow, but more particularly in red marrow. They were believed by Kölliker to be concerned in the absorption of bone matrix, and hence the name which he gave to them—*osteoclasts*. They excavate in the bone small shallow pits or cavities, which are named **Howship’s foveolæ**, and in these they are found lying.

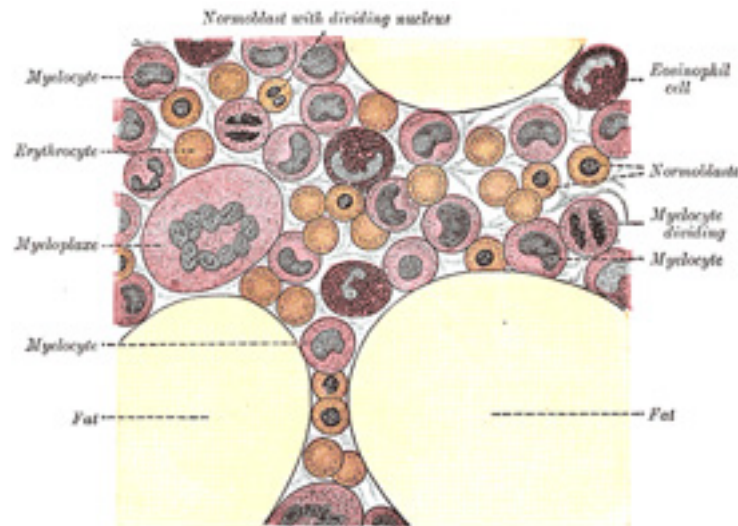

FIG. 72— Human bone marrow. Highly magnified. ([See enlarged image](#))

Vessels and Nerves of Bone.—The **bloodvessels** of bone are very numerous. Those of the compact tissue are derived from a close and dense network of vessels ramifying in the periosteum. From this membrane vessels pass into the minute orifices in the compact tissue, and run through the canals which traverse its substance. The cancellous tissue is supplied in a similar way, but by less numerous and larger vessels, which, perforating the outer compact tissue, are distributed to the cavities of the spongy portion of the bone. In the long bones, numerous apertures may

be seen at the ends near the articular surfaces; some of these give passage to the arteries of the larger set of vessels referred to; but the most numerous and largest apertures are for some of the veins of the cancellous tissue, which emerge apart from the arteries. The marrow in the body of a long bone is supplied by one large artery (or sometimes more), which enters the bone at the nutrient foramen (situated in most cases near the center of the body), and perforates obliquely the compact structure. The *medullary* or *nutrient* artery, usually accompanied by one or two veins, sends branches upward and downward, which ramify in the medullary membrane, and give twigs to the adjoining canals. The ramifications of this vessel anastomose with the arteries of the cancellous and compact tissues. In most of the flat, and in many of the short spongy bones, one or more large apertures are observed, which transmit to the central parts of the bone vessels corresponding to the nutrient arteries and veins. The **veins** emerge from the long bones in three places (Kölliker): (1) one or two large veins accompany the artery; (2) numerous large and small veins emerge at the articular extremities; (3) many small veins pass out of the compact substance. In the flat cranial bones the veins are large, very numerous, and run in tortuous canals in the diploic tissue, the sides of the canals being formed by thin lamellæ of bone, perforated here and there for the passage of branches from the adjacent cancelli. The same condition is also found in all cancellous tissue, the veins being enclosed and supported by osseous material, and having exceedingly thin coats. When a bone is divided, the vessels remain patulous, and do not contract in the canals in which they are contained. **Lymphatic vessels**, in addition to those found in the periosteum, have been traced by Cruikshank into the substance of bone, and Klein describes them as running in the Haversian canals. **Nerves** are distributed freely to the periosteum, and accompany the nutrient arteries into the interior of the bone. They are said by Kölliker to be most numerous in the articular extremities of the long bones, in the vertebræ, and in the larger flat bones.

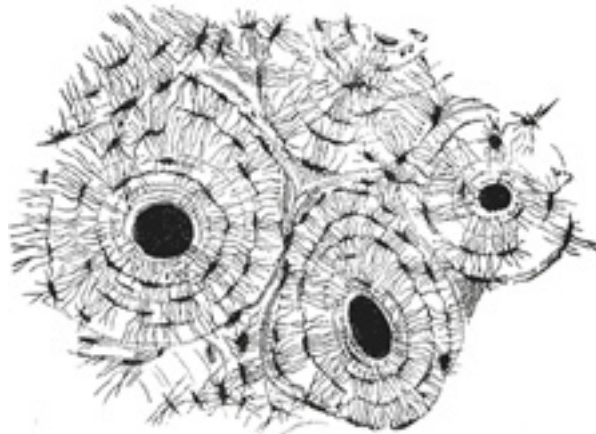


FIG. 73— Transverse section of compact tissue bone. Magnified. (Sharpey.) ([See enlarged image](#))

Minute Anatomy.—A transverse section of dense bone may be cut with a saw and ground down until it is sufficiently thin. 6

If this be examined with a rather low power the bone will be seen to be mapped out into a number of circular districts each consisting of a central hole surrounded by a number of concentric rings. These districts are termed **Haversian systems**; the central hole is an **Haversian canal**, and the rings are layers of bony tissue arranged concentrically around the central canal, and termed **lamellæ**. Moreover, on closer examination it will be found that between these lamellæ, and therefore also arranged concentrically around the central canal, are a number of little dark spots, the **lacunæ**, and that these lacunæ are connected with each other and with the central Haversian canal by a number of fine dark lines, which radiate like the spokes of a wheel and are called **canaliculi**. Filling in the irregular intervals which are left between these circular systems are other lamellæ, with their lacunæ and canaliculi running in various directions, but more or less curved ([Fig. 73](#)); they are termed **interstitial lamellæ**. Again, other lamellæ, found on the surface of the bone, are arranged parallel to its circumference; they are termed **circumferential**, or by some authors **primary** or **fundamental lamellæ**, to distinguish them from those laid down around the axes of the Haversian canals, which are then termed **secondary** or **special lamellæ**. 7

The **Haversian canals**, seen in a transverse section of bone as round holes at or about the center of each Haversian system, may be demonstrated to be true canals if a longitudinal section be made ([Fig. 74](#)). It will then be seen that the canals run parallel with the longitudinal axis of the bone for a short distance and then branch and communicate. They vary considerably in size, some being as much as 0.12 mm. in diameter; the average size is, however, about 0.05 mm. Near the medullary cavity the canals are larger than those near the surface of the bone. Each canal contains one or two bloodvessels, with a small quantity of delicate connective tissue and some nerve filaments. In the larger ones there are also lymphatic vessels, and cells with branching processes which communicate, through the canaliculi, with the branched processes of certain bone cells in the substance of the bone. Those canals near the surface of the bone open upon it by minute orifices, and those near the medullary cavity open in the same way into this space, so that the whole of the bone is permeated by a system of bloodvessels running through the bony canals in the centers of the Haversian systems. 8

The **lamellæ** are thin plates of bony tissue encircling the central canal, and may be compared, for the sake of illustration, to a number of sheets of paper pasted one over another around a central hollow cylinder. After macerating a piece of bone in dilute mineral acid, these lamellæ may be stripped off in a longitudinal direction as thin films. If one of these be examined with a high power of the microscope, it will be found to be composed of a finely reticular structure, made up of very slender transparent fibers, decussating obliquely; and coalescing at the points of intersection; these fibers are composed of fine fibrils identical with those of white connective tissue. The intercellular matrix between the fibers is impregnated by calcareous deposit which the acid dissolves. In many places the various lamellæ may be seen to be held together by tapering fibers, which run obliquely through them, pinning or bolting them together; they were first described by Sharpey, and were named by him **perforating fibers** ([Fig. 75](#)). 9

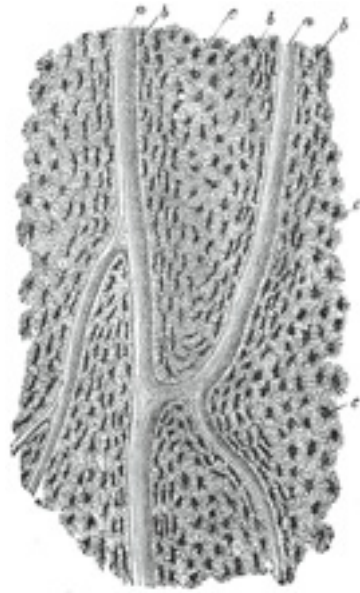


FIG. 74— Section parallel to the surface from the body of the femur. X 100. *a*, Haversian canals; *b*, lacunæ seen from the side; *c*, others seen from the surface in lamellæ, which are cut horizontally. ([See enlarged image](#))

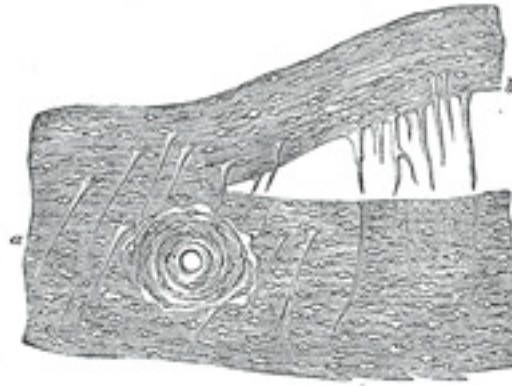


FIG. 75— Perforating fibers, human parietal bone, decalcified. (H. Müller.) *a*, perforating fibers *in situ*; *b*, fibres drawn out of their sockets; *c*, sockets. ([See enlarged image](#))

The **Lacunæ** are situated between the lamellæ, and consist of a number of oblong spaces. In an ordinary microscopic section, viewed by transmitted light, they appear as fusiform opaque spots. Each lacuna is occupied during life by a branched cell, termed a **bone-cell** or **bone-corporuscle**, the processes from which extend into the canaliculi ([Fig. 76](#)). 10

The **Canaliculi** are exceedingly minute channels, crossing the lamellæ and connecting the lacunæ with neighboring lacunæ and also with the Haversian canal. From the Haversian canal a number of canaliculi are given off, which radiate from it, and open into the first set of lacunæ between the first and second lamellæ. From these lacunæ a second set of canaliculi is given off; these run outward to the next series of lacunæ, and so on until the periphery of the Haversian system is reached; here the canaliculi given off from the last series of lacunæ do not communicate with the lacunæ of neighboring Haversian systems, but after passing outward for a short distance form loops and return to their own lacunæ. Thus every part of an Haversian system is supplied with nutrient fluids derived from the vessels in the Haversian canal and distributed through the canaliculi and lacunæ. 11

The **bone cells** are contained in the lacunæ, which, however, they do not completely fill. They are flattened nucleated branched cells, homologous with those of connective tissue; the branches, especially in young bones, pass into the canaliculi from the lacunæ. 12

In thin plates of bone (as in the walls of the spaces of cancellous tissue) the Haversian canals are absent, and the canaliculi open into the spaces of the cancellous tissue (medullary spaces), which thus have the same function as the Haversian canals. 13

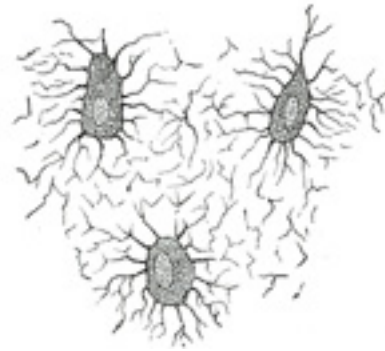


FIG. 76— Nucleated bone cells and their processes, contained in the bone lacunæ and their canaliculi respectively. From a section through the vertebra of an adult mouse. (Klein and Noble Smith.) ([See enlarged image](#))

Chemical Composition.—Bone consists of an animal and an earthy part intimately combined together. 14

The animal part may be obtained by immersing a bone for a considerable time in dilute mineral acid, after which process the bone comes out exactly the same shape as before, but perfectly flexible, so that a long bone (one of the ribs, for example) can easily be tied in a knot. If now a transverse section is made ([Fig. 77](#)) the same general arrangement of the Haversian canals, lamellæ, lacunæ, and canaliculi is seen. 15

The earthy part may be separately obtained by calcination, by which the animal matter is completely burnt out. The bone will still retain its original form, but it will be white and brittle, will have lost about one-third of its original weight, and will crumble down with the slightest force. The earthy matter is composed chiefly of calcium phosphate, about 58 per cent. of the weight of the bone, calcium carbonate about 7 per cent., calcium fluoride and magnesium phosphate from 1 to 2 per cent. each and sodium chloride less than 1 per cent.; they confer on bone its hardness and rigidity, while the animal matter (*osseïn*) determines its tenacity. 16

Ossification.—Some bones are preceded by membrane, such as those forming the roof and sides of the skull; others, such as the bones of the limbs, are preceded by rods of cartilage. Hence two kinds of ossification are described: the **intramembranous** and the **intracartilaginous**. 17

INTRAMEMBRANOUS OSSIFICATION.—In the case of bones which are developed in membrane, no cartilaginous mould precedes the appearance of the bony tissue. The membrane which occupies the place of the future bone is of the nature of connective tissue, and ultimately forms the periosteum; it is composed of fibers and granular cells in a matrix. The peripheral portion is more fibrous, while, in the interior the cells or *osteoblasts* predominate; the whole tissue is richly supplied with blood vessels. At the outset of the process of bone formation a little network of spicules is noticed radiating from the point or center of ossification. These rays consist at their growing points of a network of fine clear fibers and granular corpuscles with an intervening ground substance ([Fig. 78](#)). The fibers are termed **osteogenetic fibers**, and are made up of fine fibrils differing little from those of white fibrous tissue. The membrane soon assumes a dark and granular appearance from the deposition 18

of calcareous granules in the fibers and in the intervening matrix, and in the calcified material some of the granular corpuscles or osteoblasts are enclosed. By the fusion of the calcareous granules the tissue again assumes a more transparent appearance, but the fibers are no longer so distinctly seen. The involved osteoblasts from the corpuscles of the future bone, the spaces in which they are enclosed constituting the lacunæ. As the osteogenetic fibers grow out to the periphery they continue to calcify, and give rise to fresh bone spicules. Thus a network of bone is formed, the meshes of which contain the bloodvessels and a delicate connective tissue crowded with osteoblasts. The bony trabeculæ thicken by the addition of fresh layers of bone formed by the osteoblasts on their surface, and the meshes are correspondingly encroached upon. Subsequently successive layers of bony tissue are deposited under the periosteum and around the larger vascular channels which become the Haversian canals, so that the bone increases much in thickness.

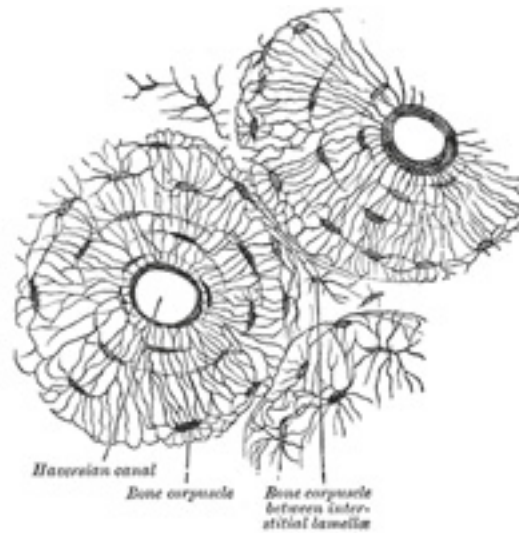


FIG. 77– Transverse section of body of human fibula, decalcified. X 250. ([See enlarged image](#))

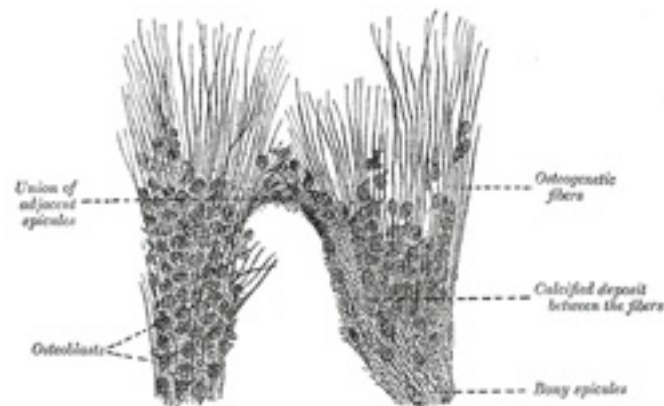


FIG. 78— Part of the growing edge of the developing parietal bone of a fetal cat. (After J. Lawrence.) ([See enlarged image](#))

INTERCARTILAGINOUS OSSIFICATION.—Just before ossification begins the mass is entirely cartilaginous, and in a long bone, which may be taken as an example, the process commences in the center and proceeds toward the extremities, which for some time remain cartilaginous. Subsequently a similar process commences in one or more places in those extremities and gradually extends through them. The extremities do not, however, become joined to the body of the bone by bony tissue until growth has ceased; between the body and either extremity a layer of cartilaginous tissue termed the **epiphysial cartilage** persists for a definite period. 19

The first step in the ossification of the cartilage is that the cartilage cells, at the point where ossification is commencing and which is termed a **center of ossification**, enlarge and arrange themselves in rows ([Fig. 79](#)). The matrix in which they are imbedded increases in quantity, so that the cells become further separated from each other. A deposit of calcareous material now takes place in this matrix, between the rows of cells, so that they become separated from each other by longitudinal columns of calcified matrix, presenting a granular and opaque appearance. Here and there the matrix between two cells of the same row also becomes calcified, and transverse bars of calcified substance stretch across from one calcareous column to another. Thus there are longitudinal groups of the cartilage cells enclosed in oblong cavities, the walls of which are formed of calcified matrix which cuts off all nutrition from the cells; the cells, in consequence, atrophy, leaving spaces called the **primary areolæ**. 20

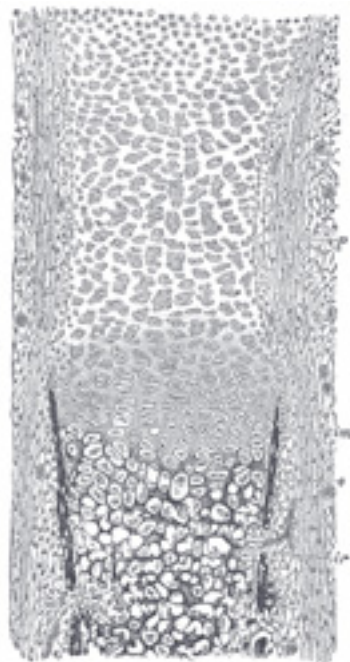


FIG. 79— Section of fetal bone of cat. *ir*. Irruption of the subperiosteal tissue. *p*. Fibrous layer of the periosteum. *o*. Layer of osteoblasts. *im*. Subperiosteal bony deposit. (From Quain's "Anatomy," E. A. Schäfer.) ([See enlarged image](#))

At the same time that this process is going on in the center of the solid bar of cartilage, certain changes are taking place on its surface. This is covered by a very vascular membrane, the **perichondrium**, entirely similar to the embryonic connective tissue already described as constituting the basis of membrane bone; on the inner surface of this—that is to say, on the surface in contact with the cartilage—are gathered the formative cells, the **osteoblasts**. By the agency of these cells a thin layer of bony tissue is formed between the perichondrium and the cartilage, by the *intramembranous* mode of ossification just described. There are then, in this first stage of ossification, two processes going on simultaneously: in the center of the cartilage the formation of a number of oblong spaces, formed of calcified matrix and containing the withered cartilage cells, and on the surface of the cartilage the formation of a layer of true membrane bone. The second stage consists in the prolongation into the cartilage of processes of the deeper or osteogenetic layer of the perichondrium, which has now become periosteum ([Fig. 79, *ir*](#)). The processes consist of bloodvessels and cells—**osteoblasts**, or **bone-formers**, and **osteoclasts**, or **bone-destroyers**. The latter are similar to the giant cells (myeloplaxes) found in marrow, and they excavate passages through the new-formed bony layer by absorption, and pass through it into the calcified matrix ([Fig. 80](#)). Wherever these processes come in contact with the calcified walls of the primary areolæ they absorb them,

and thus cause a fusion of the original cavities and the formation of larger spaces, which are termed the **secondary areolæ** or **medullary spaces**. These secondary spaces become filled with embryonic marrow, consisting of osteoblasts and vessels, derived, in the manner described above, from the osteogenetic layer of the periosteum (Fig. 80).

Thus far there has been traced the formation of enlarged spaces (secondary areolæ), the perforated walls of which are still formed by calcified cartilage matrix, containing an embryonic marrow derived from the processes sent in from the osteogenetic layer of the periosteum, and consisting of bloodvessels and osteoblasts. The walls of these secondary areolæ are at this time of only inconsiderable thickness, but they become thickened by the deposition of layers of true bone on their surface. This process takes place in the following manner: Some of the osteoblasts of the embryonic marrow, after undergoing rapid division, arrange themselves as an epithelioid layer on the surface of the wall of the space (Fig. 81). This layer of osteoblasts forms a bony stratum, and thus the wall of the space becomes gradually covered with a layer of true osseous substance in which some of the bone-forming cells are included as bone corpuscles. The next stage in the process consists in the removal of these primary bone spicules by the osteoclasts. One of these giant cells may be found lying in a Howship's foveola at the free end of each spicule. The removal of the primary spicules goes on *pari passu* with the formation of permanent bone by the periosteum, and in this way the medullary cavity of the body of the bone is formed.

22

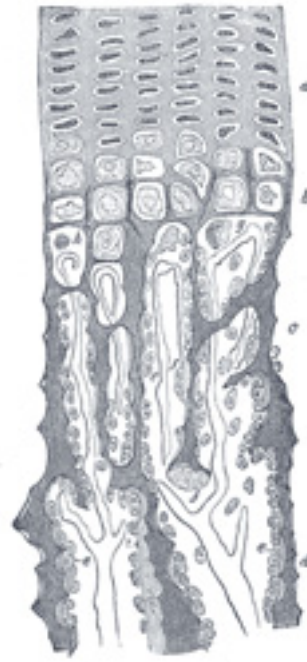

FIG. 80— Part of a longitudinal section of the developing femur of a rabbit. *a.* Flattened cartilage cells. *b.* Enlarged cartilage cells. *c, d.* Newly formed bone. *e.* Osteoblasts. *f.* Giant cells or osteoclasts. *g, h.* Shrunken cartilage cells. (From “Atlas of Histology,” Klein and Noble Smith.)
[\(See enlarged image\)](#)

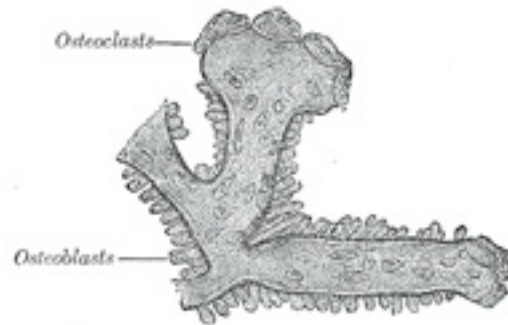


FIG. 81— Osteoblasts and osteoclasts on trabecula of lower jaw of calf embryo. (Kölliker.) [\(See enlarged image\)](#)

This series of changes has been gradually proceeding toward the end of the body of the bone, so that in the ossifying bone all the changes described above may be seen in different parts, from the true bone at the center of the body to the hyaline cartilage at the extremities. 23

While the ossification of the cartilaginous body is extending toward the articular ends, the cartilage immediately in advance of the osseous tissue continues to grow until the length of the adult bone is reached. 24

During the period of growth the articular end, or epiphysis, remains for some time entirely cartilaginous, then a bony center appears, and initiates in it the process of intracartilaginous ossification; but this process never extends to any great distance. The epiphysis remains separated from the body by a narrow cartilaginous layer for a definite time. This layer ultimately ossifies, the distinction between body and epiphysis is obliterated, and the bone assumes its completed form and shape. The same remarks also apply to such processes of bone as are separately ossified, *e.g.*, the trochanters of the femur. The bones therefore continue to grow until the body has acquired its full stature. They increase in length by ossification continuing to extend behind the epiphysial cartilage, which goes on growing in advance of the ossifying process. They increase in circumference by deposition of new bone, from the deeper layer of the periosteum, on their external surface, and at the same time an absorption takes place from within, by which the medullary cavities are increased. 25

The permanent bone formed by the periosteum when first laid down is cancellous in structure. Later the osteoblasts contained in its spaces become arranged in the concentric layers characteristic of the Haversian systems, and are included as bone corpuscles. 26

The number of ossific centers varies in different bones. In most of the short bones ossification commences at a single point near the center, and proceeds toward the surface. In the long bones there is a central point of ossification for the body or diaphysis: and one or more for each 27

extremity, the epiphysis. That for the body is the first to appear. The times of union of the epiphyses with the body vary inversely with the dates at which their ossifications began (with the exception of the fibula) and regulate the direction of the nutrient arteries of the bones. Thus, the nutrient arteries of the bones of the arm and forearm are directed toward the elbow, since the epiphyses at this joint become united to the bodies before those at the opposite extremities. In the lower limb, on the other hand, the nutrient arteries are directed away from the knee: that is, upward in the femur, downward in the tibia and fibula; and in them it is observed that the upper epiphysis of the femur, and the lower epiphyses of the tibia and fibula, unite first with the bodies. Where there is only one epiphysis, the nutrient artery is directed toward the other end of the bone; as toward the acromial end of the clavicle, toward the distal ends of the metacarpal bone of the thumb and the metatarsal bone of the great toe, and toward the proximal ends of the other metacarpal and metatarsal bones.

Parsons [14](#) groups epiphyses under three headings, viz.: (1) **pressure epiphyses**, appearing at the articular ends of the bones and transmitting “the weight of the body from bone to bone;” (2) **traction epiphyses**, associated with the insertion of muscles and “originally sesamoid structures though not necessarily sesamoid bones;” and (3) **atavistic epiphyses**, representing parts of the skeleton, which at one time formed separate bones, but which have lost their function, “and only appear as separate ossifications in early life.” 28

Note 12. Indicates stresses with the grain, *i.e.*, when the load is parallel to the long axis of the material, or parallel to the direction of the fibers of the material. [[back](#)]

Note 13. Indicates unit-stresses across the grain, *i.e.*, at right angles to the direction of the fibers of the material. [[back](#)]

Note 14. Jour. of Anat. and Phys., vols. xxxviii, xxxix, and xlii. [[back](#)]

3. The Vertebral Column

(Columna Vertebralis; Spinal Column). 1

The **vertebral column** is a flexuous and flexible column, formed of a series of bones called **vertebræ**.

The vertebræ are thirty-three in number, and are grouped under the names **cervical**, **thoracic**, **lumbar**, **sacral**, and **coccygeal**, according to the regions they occupy; there are seven in the cervical region, twelve in the thoracic, five in the lumbar, five in the sacral, and four in the coccygeal. 2

This number is sometimes increased by an additional vertebra in one region, or it may be diminished in one region, the deficiency often being supplied by an additional vertebra in another. The number of cervical vertebræ is, however, very rarely increased or diminished. 3

The vertebræ in the upper three regions of the column remain distinct throughout life, and are known as **true** or **movable** vertebræ; those of the sacral and coccygeal regions, on the other hand, are termed **false** or **fixed** vertebræ, because they are united with one another in the adult to form two bones—five forming the upper bone or **sacrum**, and four the terminal bone or **coccyx**. 4

With the exception of the first and second cervical, the true or movable vertebræ present certain common characteristics which are best studied by examining one from the middle of the thoracic region.

3a. General Characteristics of a Vertebra

A **typical vertebra** consists of two essential parts—viz., an anterior segment, the **body**, and a posterior part, the **vertebral** or **neural arch**; these enclose a foramen, the **vertebral foramen**. The vertebral arch consists of a pair of **pedicles** and a pair of **laminae**, and supports **seven processes**—viz., four **articular**, two **transverse**, and one **spinous**. ¹

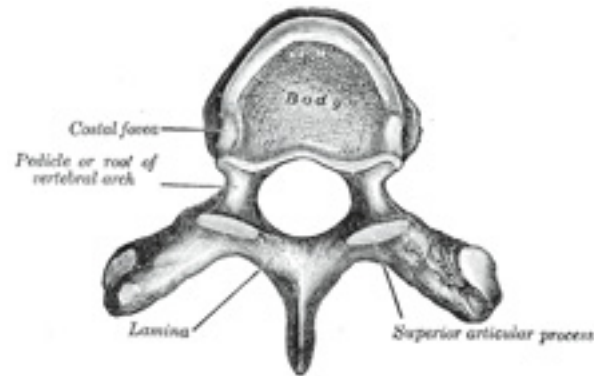


FIG. 82— A typical thoracic vertebra, viewed from above. ([See enlarged image](#))

When the vertebræ are articulated with each other the bodies form a strong pillar for the support of the head and trunk, and the vertebral foramina constitute a canal for the protection of the medulla spinalis (*spinal cord*), while between every pair of vertebræ are two apertures, the **intervertebral foramina**, one on either side, for the transmission of the spinal nerves and vessels. ²

Body (*corpus vertebræ*).—The body is the largest part of a vertebra, and is more or less cylindrical in shape. Its upper and lower surfaces are flattened and rough, and give attachment to the intervertebral fibrocartilages, and each presents a rim around its circumference. In front, the body is convex from side to side and concave from above downward. Behind, it is flat from above downward and slightly concave from side to side. Its anterior surface presents a few small apertures, for the passage of nutrient vessels; on the posterior surface is a single large, irregular aperture, or occasionally more than one, for the exit of the basi-vertebral veins from the body of the vertebra. ³

Pedicles (*radices arci vertebræ*).—The pedicles are two short, thick processes, which project backward, one on either side, from the upper part of the body, at the junction of its posterior and lateral surfaces. The concavities above and below the pedicles are named the **vertebral notches**; and when the vertebræ are articulated, the notches of each contiguous pair of bones form the intervertebral foramina, already referred to. ⁴

Laminae.—The laminae are two broad plates directed backward and medialward from the pedicles. They fuse in the middle line posteriorly, and so complete the posterior boundary of the vertebral foramen. Their upper borders and the lower parts of their anterior surfaces are rough for the attachment of the ligamenta flava. 5

Processes.—Spinous Process (*processus spinosus*).—The spinous process is directed backward and downward from the junction of the laminae, and serves for the attachment of muscles and ligaments. 6

Articular Processes.—The articular processes, two superior and two inferior, spring from the junctions of the pedicles and laminae. The superior project upward, and their articular surfaces are directed more or less backward; the inferior project downward, and their surfaces look more or less forward. The articular surfaces are coated with hyaline cartilage. 7

Transverse Processes (*processus transversi*).—The transverse processes, two in number, project one at either side from the point where the lamina joins the pedicle, between the superior and inferior articular processes. They serve for the attachment of muscles and ligaments. 8

Structure of a Vertebra (Fig. 83).—The body is composed of cancellous tissue, covered by a thin coating of compact bone; the latter is perforated by numerous orifices, some of large size for the passage of vessels; the interior of the bone is traversed by one or two large canals, for the reception of veins, which converge toward a single large, irregular aperture, or several small apertures, at the posterior part of the body. The thin bony lamellae of the cancellous tissue are more pronounced in lines perpendicular to the upper and lower surfaces and are developed in response to greater pressure in this direction (Fig. 83). The arch and processes projecting from it have thick coverings of compact tissue. 9

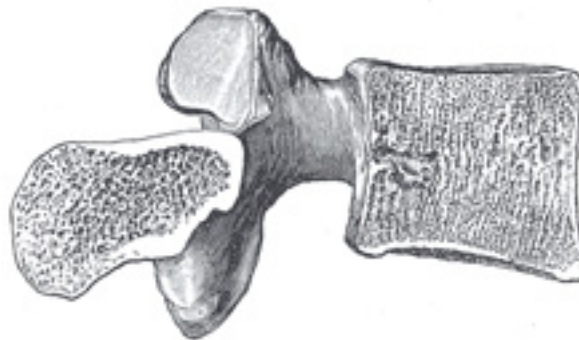


FIG. 83— Sagittal section of a lumbar vertebra. ([See enlarged image](#))

3a. 1. The Cervical Vertebrae

(Vertebrae Cervicales).

1

cervical vertebrae (Fig. 84) are the smallest of the true vertebrae, and can be readily distinguished from those of the thoracic or lumbar regions by the presence of a foramen in each transverse process. The first, second, and seventh present exceptional features and must be separately described; the following characteristics are common to the remaining four.

The **body** is small, and broader from side to side than from before backward. The **anterior and posterior surfaces** are flattened and of equal depth; the former is placed on a lower level than the latter, and its inferior border is prolonged downward, so as to overlap the upper and forepart of the vertebra below. The **upper surface** is concave transversely, and presents a projecting lip on either side; the **lower surface** is concave from before backward, convex from side to side, and presents laterally shallow concavities which receive the corresponding projecting lips of the subjacent vertebra. The **pedicles** are directed lateralward and backward, and are attached to the body midway between its upper and lower borders, so that the superior vertebral notch is as deep as the inferior, but it is, at the same time, narrower. The **laminæ** are narrow, and thinner above than below; the **vertebral foramen** is large, and of a triangular form. The **spinous process** is short and bifid, the two divisions being often of unequal size. The **superior and inferior articular processes** on either side are fused to form an articular pillar, which projects lateralward from the junction of the pedicle and lamina. The articular facets are flat and of an oval form: the superior look backward, upward, and slightly medialward: the inferior forward, downward, and slightly lateralward. The **transverse processes** are each pierced by the **foramen transversarium**, which, in the upper six vertebrae, gives passage to the vertebral artery and vein and a plexus of sympathetic nerves. Each process consists of an anterior and a posterior part. The **anterior** portion is the homologue of the rib in the thoracic region, and is therefore named the **costal process** or **costal element**: it arises from the side of the body, is directed lateralward in front of the foramen, and ends in a tubercle, the **anterior tubercle**. The **posterior** part, the true transverse process, springs from the vertebral arch behind the foramen, and is directed forward and lateralward; it ends in a flattened vertical tubercle, the **posterior tubercle**. These two parts are joined, outside the foramen, by a bar of bone which exhibits a deep sulcus on its upper surface for the passage of the corresponding spinal nerve. [15](#)

2

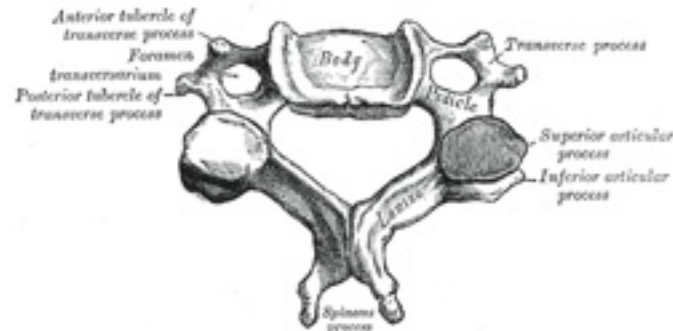


FIG. 84— A cervical vertebra. ([See enlarged image](#))

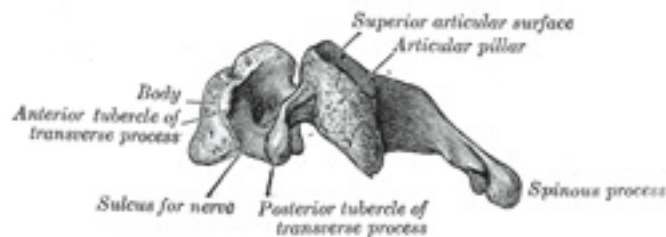


FIG. 85— Side view of a typical cervical vertebra. ([See enlarged image](#))

First Cervical Vertebra.—The first cervical vertebra ([Fig. 86](#)) is named the **atlas** because it supports the globe of the head. Its chief peculiarity is that it has no body, and this is due to the fact that the body of the atlas has fused with that of the next vertebra. Its other peculiarities are that it has no spinous process, is ring-like, and consists of an anterior and a posterior arch and two lateral masses. The **anterior arch** forms about one-fifth of the ring: its anterior surface is convex, and presents at its center the **anterior tubercle** for the attachment of the Longus colli muscles; posteriorly it is concave, and marked by a smooth, oval or circular facet (*fovea dentis*), for articulation with the odontoid process (*dens*) of the axis. The upper and lower borders respectively give attachment to the anterior atlantooccipital membrane and the anterior atlantoaxial ligament; the former connects it with the occipital bone above, and the latter with the axis below. The **posterior arch** forms about two-fifths of the circumference of the ring: it ends behind in the **posterior tubercle**, which is the rudiment of a spinous process and gives origin to the Recti capitis posteriores minores. The diminutive size of this process prevents any interference with the movements between the atlas and the skull. The posterior part of the arch presents above and behind a rounded edge for the attachment of the posterior atlantoöccipital membrane, while immediately behind each superior articular process is a groove (*sulcus arteriae vertebralis*), sometimes converted into a foramen by a delicate bony spiculum which arches backward from the posterior end of the superior articular process. This groove represents the superior vertebral notch, and serves for the transmission of the vertebral artery, which, after ascending through the foramen in the transverse process, winds around the lateral mass in a direction backward and medialward; it also transmits the suboccipital (first spinal) nerve. On the under surface of the posterior arch, behind the articular facets, are two shallow grooves, the **inferior vertebral notches**. The lower border gives attachment to the posterior atlantoaxial ligament, which connects it with the axis. The **lateral masses** are the most bulky and solid parts of the atlas, in order to support the weight of the head. Each carries two articular facets, a superior and an inferior. The **superior facets** are of large size, oval, concave, and approach each other in front, but diverge behind: they are directed upward, medialward, and a little backward, each forming a cup for the corresponding condyle of the occipital bone, and are admirably adapted to the nodding movements of the head. Not infrequently they are partially

subdivided by indentations which encroach upon their margins. The **inferior articular facets** are circular in form, flattened or slightly convex and directed downward and medialward, articulating with the axis, and permitting the rotatory movements of the head. Just below the medial margin of each superior facet is a small tubercle, for the attachment of the transverse atlantal ligament which stretches across the ring of the atlas and divides the vertebral foramen into two unequal parts—the anterior or smaller receiving the odontoid process of the axis, the posterior transmitting the medulla spinalis and its membranes. This part of the vertebral canal is of considerable size, much greater than is required for the accommodation of the medulla spinalis, and hence lateral displacement of the atlas may occur without compression of this structure. The **transverse processes** are large; they project lateralward and downward from the lateral masses, and serve for the attachment of muscles which assist in rotating the head. They are long, and their anterior and posterior tubercles are fused into one mass; the foramen transversarium is directed from below, upward and backward.

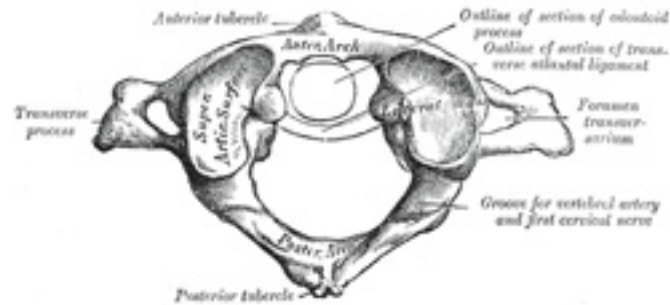


FIG. 86— First cervical vertebra, or atlas. ([See enlarged image](#))

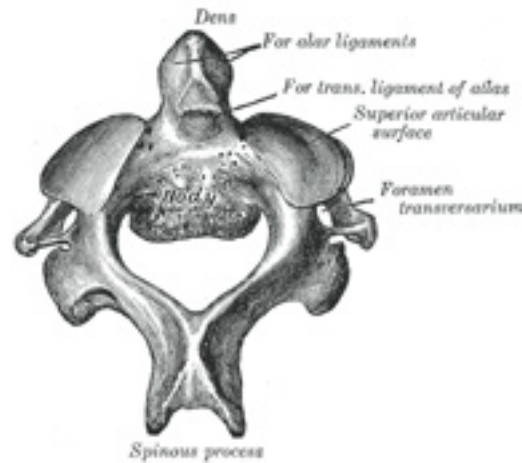


FIG. 87— Second cervical vertebra, or epistropheus, from above. ([See enlarged image](#))

Second Cervical Vertebra.—The second cervical vertebra ([Fig. 87](#) and [88](#)) is named the **epistropheus** or **axis** because it forms the pivot upon which the first vertebra, carrying the head, rotates. The most distinctive characteristic of this bone is the strong odontoid process which rises perpendicularly from the upper surface of the body. The **body** is deeper in front than behind, and prolonged downward anteriorly so as to overlap the upper and fore part of the third vertebra. It presents in front a median longitudinal ridge, separating two lateral depressions for the attachment of the Longus colli muscles. Its under surface is concave from before backward and convex from side to side. The **dens** or **odontoid process** exhibits a slight constriction or neck, where it joins the body. On its anterior surface is an oval or nearly circular facet for articulation with that on the anterior arch of the atlas. On the back of the neck, and frequently extending on to its lateral surfaces, is a shallow groove for the transverse atlantal ligament which retains the process in position. The **apex** is pointed, and gives attachment to the apical odontoid ligament; below the apex the process is somewhat enlarged, and presents on either side a rough impression for the attachment of the alar ligament; these ligaments connect the process to the occipital bone. The internal structure of the odontoid process is more compact than that of the body. The **pedicles** are broad and strong, especially in front, where they coalesce with the sides of the body and the root of the odontoid process. They are covered above by the superior articular surfaces. The **laminæ** are thick and strong, and the vertebral foramen large, but smaller than that of the atlas. The **transverse processes** are very small, and each ends in a single tubercle; each is perforated by the foramen transversarium, which is directed obliquely upward and lateralward. The **superior articular surfaces** are round, slightly convex, directed upward and lateralward, and are supported on the body, pedicles, and transverse processes. The **inferior articular surfaces** have the same direction as those of the other cervical vertebræ. The **superior vertebral notches** are very shallow, and lie behind the articular processes; the **inferior** lie in front of the articular processes, as in the other cervical vertebræ. The **spinous process** is large, very strong, deeply channelled on its under surface, and presents a

bifid, tuberculated extremity.

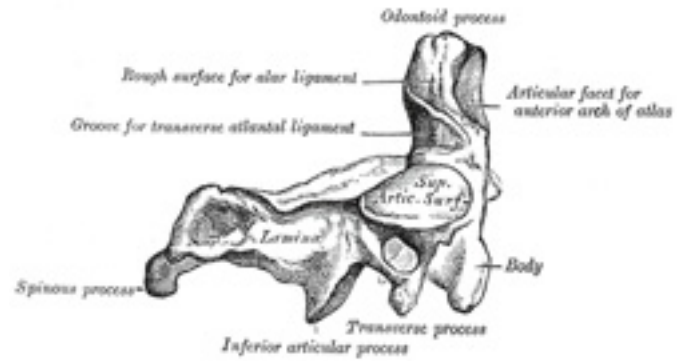


FIG. 88– Second cervical vertebra, epistropheus, or axis, from the side. ([See enlarged image](#))

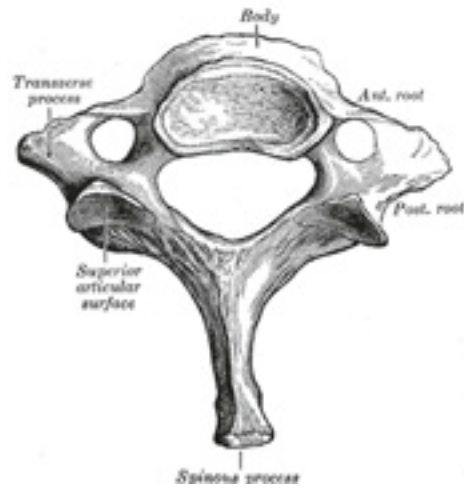


FIG. 89– Seventh cervical vertebra. ([See enlarged image](#))

The Seventh Cervical Vertebra (Fig. 89).—The most distinctive characteristic of this vertebra is the existence of a long and prominent spinous process, hence the name **vertebra prominens**. This process is thick, nearly horizontal in direction, not bifurcated, but terminating in a tubercle to which the lower end of the ligamentum nuchæ is attached. The **transverse processes** are of considerable size, their posterior roots are large and prominent, while the anterior are small and faintly marked; the upper surface of each has usually a shallow sulcus for the eighth spinal nerve, and its extremity seldom presents more than a trace of bifurcation. The foramen transversarium may be as large as that in the other cervical vertebræ, but is generally smaller on one or both sides; occasionally it is double, sometimes it is absent. On the left side it occasionally gives passage to the vertebral artery; more frequently the vertebral vein traverses it on both sides; but the usual arrangement is for both artery and vein to pass in front of the transverse process, and not through the foramen. Sometimes the anterior root of the transverse process attains a large size and exists as a separate bone, which is known as a **cervical rib**.

Note 15. The *costal element* of a cervical vertebra not only includes the portion which springs from the side of the body, but the anterior and posterior tubercles and the bar of bone which connects them (Fig. 67). [[back](#)]

3a. 2. The Thoracic Vertebræ

(Vertebræ Thoracales).

The **thoracic vertebræ (Fig. 90)** are intermediate in size between those of the cervical and lumbar regions; they increase in size from above downward, the upper vertebræ being much smaller than those in the lower part of the region. They are distinguished by the presence of facets on the sides of the bodies for articulation with the heads of the ribs, and facets on the transverse processes of all, except the eleventh and twelfth, for articulation with the tubercles of the ribs.

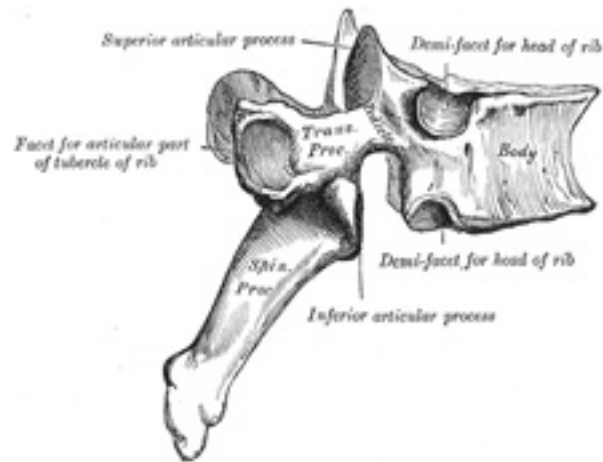


FIG. 90— A thoracic vertebra. ([See enlarged image](#))

The **bodies** in the middle of the thoracic region are heart-shaped, and as broad in the antero-posterior as in the transverse direction. At the ends of the thoracic region they resemble respectively those of the cervical and lumbar vertebræ. They are slightly thicker behind than in front, flat above and below, convex from side to side in front, deeply concave behind, and slightly constricted laterally and in front. They present, on either side, two costal demi-facets, one above, near the root of the pedicle, the other below, in front of the inferior vertebral notch; these are covered with cartilage in the fresh state, and, when the vertebræ are articulated with one another, form, with the intervening intervertebral fibrocartilages, oval surfaces for the reception of the heads of the ribs. The **pedicles** are directed backward and slightly upward, and the inferior vertebral notches are of large size, and deeper than in any other region of the vertebral column. The **laminæ** are broad, thick, and imbricated—that is to say, they overlap those of subjacent vertebræ like tiles on a roof. The **vertebral foramen** is small, and of a circular form. The **spinous process** is long, triangular on coronal section, directed obliquely downward, and ends in a tuberculated extremity. These processes overlap from the fifth to the eighth, but are less oblique in direction above and below. The **superior articular processes** are thin plates of bone projecting upward from the junctions of the pedicles and laminæ; their articular facets are practically flat, and are directed backward and a little lateralward and upward. The **inferior articular processes** are fused to a considerable extent with the laminæ, and project but slightly beyond their lower borders; their facets are directed forward and a little medialward and downward. The **transverse processes** arise from the arch behind the superior articular processes and pedicles; they are thick, strong, and of considerable length, directed obliquely backward and lateralward, and each ends in a clubbed extremity, on the front of which is a small, concave surface, for articulation with the tubercle of a rib. The *first, ninth, tenth, eleventh, and twelfth* thoracic vertebræ present certain peculiarities, and must be specially considered ([Fig. 91](#)).

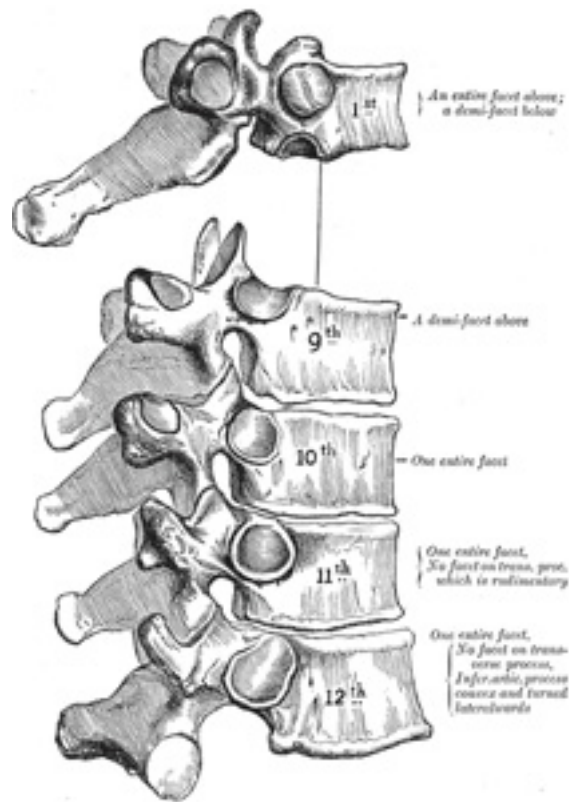


FIG. 91— Peculiar thoracic vertebræ. ([See enlarged image](#))

The **First Thoracic Vertebra** has, on either side of the **body**, an entire articular facet for the head of the first rib, and a demi-facet for the upper half of the head of the second rib. The body is like that of a cervical vertebra, being broad transversely; its upper surface is concave, and lipped on either side. The **superior articular surfaces** are directed upward and backward; the **spinous process** is thick, long, and almost horizontal. The **transverse processes** are long, and the upper vertebral notches are deeper than those of the other thoracic vertebræ. 3

The **Ninth Thoracic Vertebra** may have no demi-facets below. In some subjects however, it has two demi-facets on either side; when this occurs the tenth has only demi-facets at the upper part. 4

The **Tenth Thoracic Vertebra** has (except in the cases just mentioned) an entire articular facet on either side, which is placed partly on the 5

lateral surface of the pedicle.

In the **Eleventh Thoracic Vertebra** the **body** approaches in its form and size to that of the lumbar vertebræ. The articular facets for the heads of the ribs are of large size, and placed chiefly on the pedicles, which are thicker and stronger in this and the next vertebra than in any other part of the thoracic region. The **spinous process** is short, and nearly horizontal in direction. The **transverse processes** are very short, tuberculated at their extremities, and have no articular facets. 6

The **Twelfth Thoracic Vertebra** has the same general characteristics as the eleventh, but may be distinguished from it by its inferior articular surfaces being convex and directed lateralward, like those of the lumbar vertebræ; by the general form of the body, laminæ, and spinous process, in which it resembles the lumbar vertebræ; and by each transverse process being subdivided into three elevations, the superior, inferior, and lateral tubercles: the superior and inferior correspond to the mammillary and accessory processes of the lumbar vertebræ. Traces of similar elevations are found on the transverse processes of the tenth and eleventh thoracic vertebræ. 7

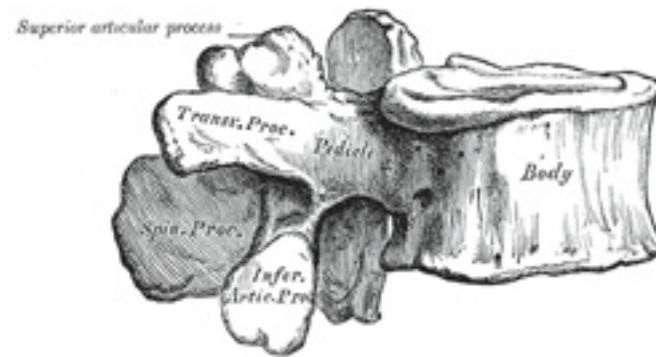


FIG. 92– A lumbar vertebra seen from the side. ([See enlarged image](#))

3a. 3. The Lumbar Vertebræ

(Vertebræ Lumbales).

1

The **lumbar vertebræ** ([Figs. 92](#) and [93](#)) are the largest segments of the movable part of the vertebral column, and can be distinguished by the absence of a foramen in the transverse process, and by the absence of facets on the sides of the body.

The **body** is large, wider from side to side than from before backward, and a little thicker in front than behind. It is flattened or slightly concave above and below, concave behind, and deeply constricted in front and at the sides. The **pedicles** are very strong, directed backward from the 2

upper part of the body; consequently, the inferior vertebral notches are of considerable depth. The **laminae** are broad, short, and strong; the **vertebral foramen** is triangular, larger than in the thoracic, but smaller than in the cervical region. The **spinous process** is thick, broad, and somewhat quadrilateral; it projects backward and ends in a rough, uneven border, thickest below where it is occasionally notched. The **superior and inferior articular processes** are well-defined, projecting respectively upward and downward from the junctions of pedicles and laminae. The facets on the superior processes are concave, and look backward and medialward; those on the inferior are convex, and are directed forward and lateralward. The former are wider apart than the latter, since in the articulated column the inferior articular processes are embraced by the superior processes of the subjacent vertebra. The **transverse processes** are long, slender, and horizontal in the upper three lumbar vertebrae; they incline a little upward in the lower two. In the upper three vertebrae they arise from the junctions of the pedicles and laminae, but in the lower two they are set farther forward and spring from the pedicles and posterior parts of the bodies. They are situated in front of the articular processes instead of behind them as in the thoracic vertebrae, and are homologous with the ribs. Of the three tubercles noticed in connection with the transverse processes of the lower thoracic vertebrae, the superior one is connected in the lumbar region with the back part of the superior articular process, and is named the **mammillary process**; the inferior is situated at the back part of the base of the transverse process, and is called the **accessory process** ([Fig. 93](#)).

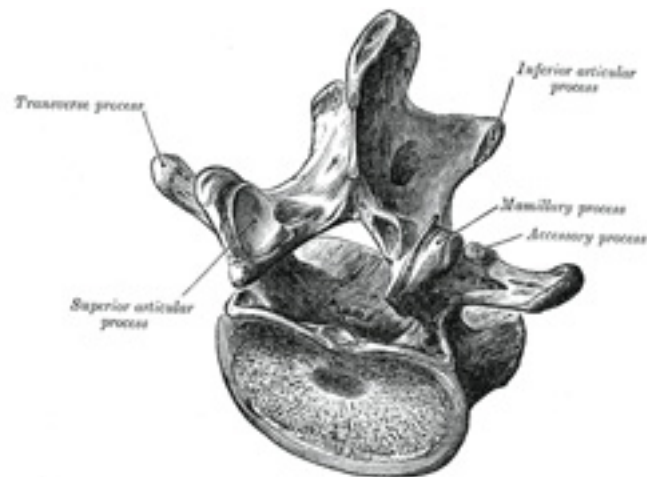


FIG. 93— A lumbar vertebra from above and behind. ([See enlarged image](#))

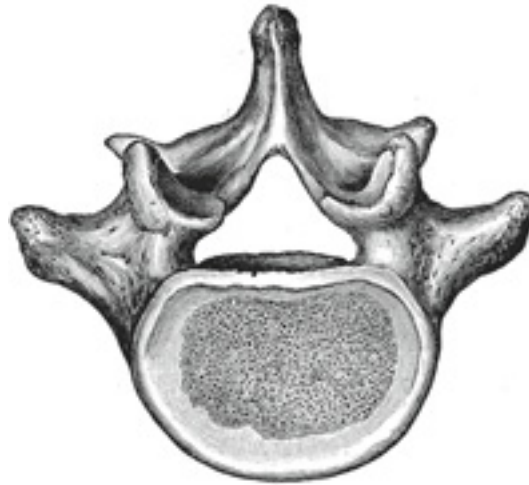

FIG. 94— Fifth lumbar vertebra, from above. ([See enlarged image](#))

The **Fifth Lumbar Vertebra** ([Fig. 94](#)) is characterized by its body being much deeper in front than behind, which accords with the prominence of the sacrovertebral articulation; by the smaller size of its spinous process; by the wide interval between the inferior articular processes; and by the thickness of its transverse processes, which spring from the body as well as from the pedicles.

3a. 4. The Sacral and Coccygeal Vertebræ

The **sacral** and **coccygeal vertebræ** consist at an early period of life of nine separate segments which are united in the adult, so as to form two bones, five entering into the formation of the sacrum, four into that of the coccyx. Sometimes the coccyx consists of five bones; occasionally the number is reduced to three. 1

The Sacrum (*os sacrum*).—The sacrum is a large, triangular bone, situated in the lower part of the vertebral column and at the upper and back part of the pelvic cavity, where it is inserted like a wedge between the two hip bones; its upper part or base articulates with the last lumbar vertebra, its apex with the coccyx. It is curved upon itself and placed very obliquely, its base projecting forward and forming the **prominent sacrovertebral angle** when articulated with the last lumbar vertebra; its central part is projected backward, so as to give increased capacity to the 2

pelvic cavity.

Pelvic Surface (*facies pelvina*).—The pelvic surface ([Fig. 95](#)) is concave from above downward, and slightly so from side to side. Its middle part is crossed by four **transverse ridges**, the positions of which correspond with the original planes of separation between the five segments of the bone. The portions of bone intervening between the ridges are the bodies of the sacral vertebræ. The body of the first segment is of large size, and in form resembles that of a lumbar vertebra; the succeeding ones diminish from above downward, are flattened from before backward, and curved so as to accommodate themselves to the form of the sacrum, being concave in front, convex behind. At the ends of the ridges are seen the **anterior sacral foramina**, four in number on either side, somewhat rounded in form, diminishing in size from above downward, and directed lateralward and forward; they give exit to the anterior divisions of the sacral nerves and entrance to the lateral sacral arteries. Lateral to these foramina are the **lateral parts of the sacrum**, each consisting of five separate segments at an early period of life; in the adult, these are blended with the bodies and with each other. Each lateral part is traversed by four broad, shallow grooves, which lodge the anterior divisions of the sacral nerves, and are separated by prominent ridges of bone which give origin to the Piriformis muscle.

If a sagittal section be made through the center of the sacrum ([Fig. 99](#)), the bodies are seen to be united at their circumferences by bone, wide intervals being left centrally, which, in the fresh state, are filled by the intervertebral fibrocartilages. In some bones this union is more complete between the lower than the upper segments.

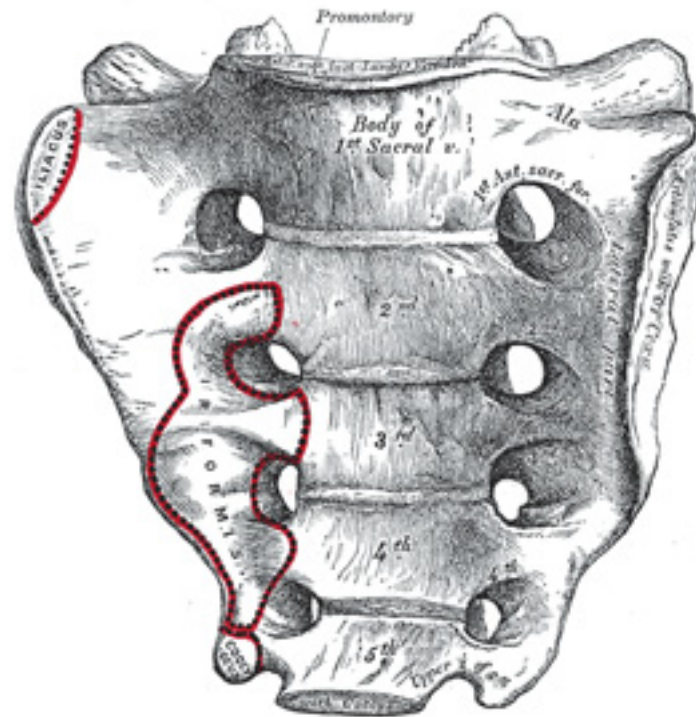


FIG. 95— Sacrum, pelvic surface. ([See enlarged image](#))

Dorsal Surface (*facies dorsalis*).—The dorsal surface ([Fig. 96](#)) is convex and narrower than the pelvic. In the middle line it displays a crest, the **middle sacral crest**, surmounted by three or four tubercles, the rudimentary spinous processes of the upper three or four sacral vertebræ. On either side of the middle sacral crest is a shallow groove, the **sacral groove**, which gives origin to the Multifidus, the floor of the groove being formed by the united laminæ of the corresponding vertebræ. The laminæ of the fifth sacral vertebra, and sometimes those of the fourth, fail to meet behind, and thus a hiatus or deficiency occurs in the posterior wall of the sacral canal. On the lateral aspect of the sacral groove is a linear series of tubercles produced by the fusion of the articular processes which together form the indistinct **sacral articular crests**. The articular processes of the first sacral vertebra are large and oval in shape; their facets are concave from side to side, look backward and medialward, and articulate with the facets on the inferior processes of the fifth lumbar vertebra. The tubercles which represent the inferior articular processes of

the fifth sacral vertebra are prolonged downward as rounded processes, which are named the **sacral cornua**, and are connected to the cornua of the coccyx. Lateral to the articular processes are the four **posterior sacral foramina**; they are smaller in size and less regular in form than the anterior, and transmit the posterior divisions of the sacral nerves. On the lateral side of the posterior sacral foramina is a series of tubercles, which represent the transverse processes of the sacral vertebræ, and form the **lateral crests** of the sacrum. The transverse tubercles of the first sacral vertebra are large and very distinct; they, together with the transverse tubercles of the second vertebra, give attachment to the horizontal parts of the posterior sacroiliac ligaments; those of the third vertebra give attachment to the oblique fasciculi of the posterior sacroiliac ligaments; and those of the fourth and fifth to the sacrotuberous ligaments.

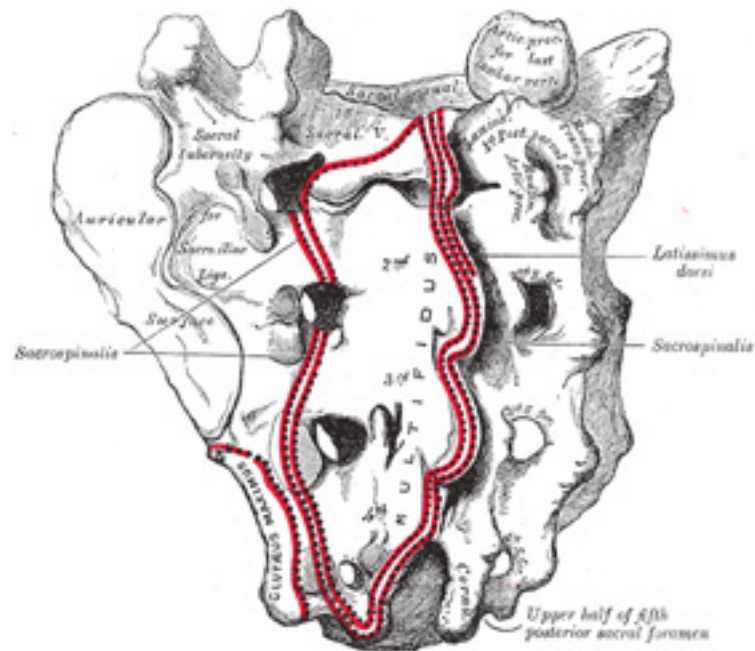


FIG. 96— Sacrum, dorsal surface. ([See enlarged image](#))

Lateral Surface.—The lateral surface is broad above, but narrowed into a thin edge below. The upper half presents in front an ear-shaped surface, the **auricular surface**, covered with cartilage in the fresh state, for articulation with the ilium. Behind it is a rough surface, the **sacral**

tuberosity, on which are three deep and uneven impressions, for the attachment of the posterior sacroiliac ligament. The lower half is thin, and ends in a projection called the **inferior lateral angle**; medial to this angle is a notch, which is converted into a foramen by the transverse process of the first piece of the coccyx, and transmits the anterior division of the fifth sacral nerve. The thin lower half of the lateral surface gives attachment to the sacrotuberous and sacrospinous ligaments, to some fibers of the Glutæus maximus behind, and to the Coccygeus in front.

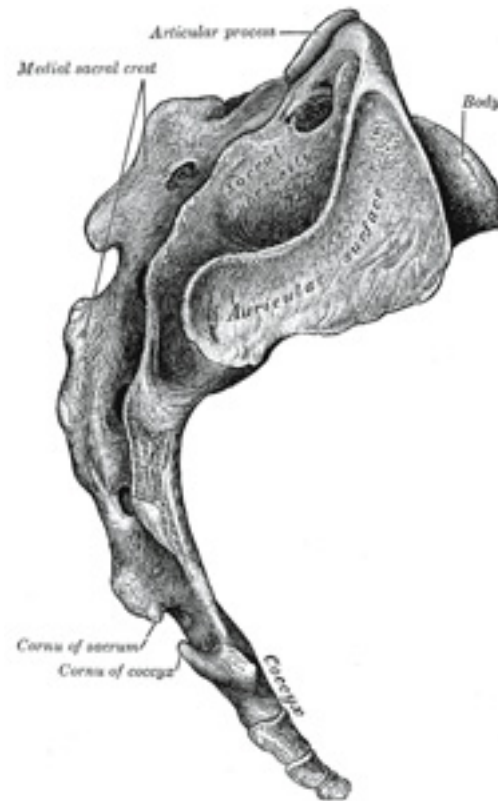

FIG. 97— Lateral surfaces of sacrum and coccyx. ([See enlarged image](#))

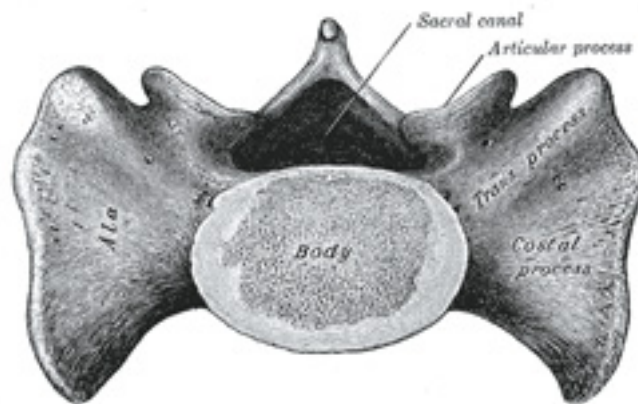


FIG. 98— Base of sacrum. ([See enlarged image](#))

Base (*basis oss. sacri*).—The base of the sacrum, which is broad and expanded, is directed upward and forward. In the middle is a large oval articular surface, the upper surface of the body of the first sacral vertebra, which is connected with the under surface of the body of the last lumbar vertebra by an intervertebral fibrocartilage. Behind this is the large triangular orifice of the sacral canal, which is completed by the laminæ and spinous process of the first sacral vertebra. The superior articular processes project from it on either side; they are oval, concave, directed backward and medialward, like the superior articular processes of a lumbar vertebra. They are attached to the body of the first sacral vertebra and to the alæ by short thick pedicles; on the upper surface of each pedicle is a vertebral notch, which forms the lower part of the foramen between the last lumbar and first sacral vertebræ. On either side of the body is a large triangular surface, which supports the Psoas major and the lumbosacral trunk, and in the articulated pelvis is continuous with the iliac fossa. This is called the **ala**; it is slightly concave from side to side, convex from before backward, and gives attachment to a few of the fibers of the Iliacus. The posterior fourth of the ala represents the transverse process, and its anterior three-fourths the costal process of the first sacral segment.

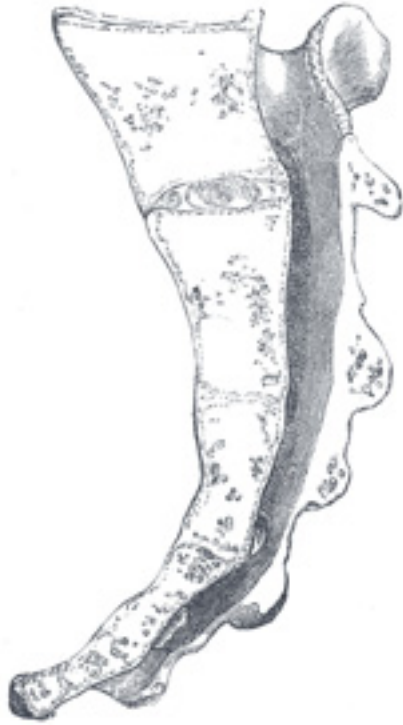

FIG. 99– Median sagittal section of the sacrum. ([See enlarged image](#))

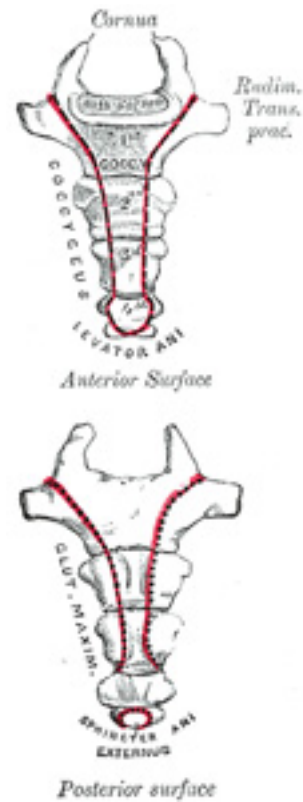

FIG. 100—Coccyx. ([See enlarged image](#))

Apex (*apex oss. sacri*).—The apex is directed downward, and presents an oval facet for articulation with the coccyx.

8

Vertebral Canal (*canalis sacralis; sacral canal*).—The vertebral canal ([Fig. 99](#)) runs throughout the greater part of the bone; above, it is triangular in form; below, its posterior wall is incomplete, from the non-development of the laminæ and spinous processes. It lodges the sacral nerves, and its walls are perforated by the anterior and posterior sacral foramina through which these nerves pass out.

9

Structure.—The sacrum consists of cancellous tissue enveloped by a thin layer of compact bone. 10

Articulations.—The sacrum articulates with *four* bones; the last lumbar vertebra above, the coccyx below, and the hip bone on either side. 11

Differences in the Sacrum of the Male and Female.—In the female the sacrum is shorter and wider than in the male; the lower half forms a greater angle with the upper; the upper half is nearly straight, the lower half presenting the greatest amount of curvature. The bone is also directed more obliquely backward; this increases the size of the pelvic cavity and renders the sacrovertebral angle more prominent. In the male the curvature is more evenly distributed over the whole length of the bone, and is altogether greater than in the female. 12

Variations.—The sacrum, in some cases, consists of six pieces; occasionally the number is reduced to four. The bodies of the first and second vertebræ may fail to unite. Sometimes the uppermost transverse tubercles are not joined to the rest of the ala on one or both sides, or the sacral canal may be open throughout a considerable part of its length, in consequence of the imperfect development of the laminæ and spinous processes. The sacrum, also, varies considerably with respect to its degree of curvature. 13

The Coccyx (*os coccygis*).—The coccyx ([Fig. 100](#)) is usually formed of four rudimentary vertebræ; the number may however be increased to five or diminished to three. In each of the first three segments may be traced a rudimentary body and articular and transverse processes; the last piece (sometimes the third) is a mere nodule of bone. All the segments are destitute of pedicles, laminæ, and spinous processes. The first is the largest; it resembles the lowest sacral vertebra, and often exists as a separate piece; the last three diminish in size from above downward, and are usually fused with one another. 14

Surfaces.—The **anterior surface** is slightly concave, and marked with three transverse grooves which indicate the junctions of the different segments. It gives attachment to the anterior sacrococcygeal ligament and the Levatores ani, and supports part of the rectum. The **posterior surface** is convex, marked by transverse grooves similar to those on the anterior surface, and presents on either side a linear row of tubercles, the rudimentary articular processes of the coccygeal vertebræ. Of these, the superior pair are large, and are called the **coccygeal cornua**; they project upward, and articulate with the cornua of the sacrum, and on either side complete the foramen for the transmission of the posterior division of the fifth sacral nerve. 15

Borders.—The **lateral borders** are thin, and exhibit a series of small eminences, which represent the transverse processes of the coccygeal vertebræ. Of these, the first is the largest; it is flattened from before backward, and often ascends to join the lower part of the thin lateral edge of the sacrum, thus completing the foramen for the transmission of the anterior division of the fifth sacral nerve; the others diminish in size from above downward, and are often wanting. The borders of the coccyx are narrow, and give attachment on either side to the sacrotuberous and sacrospinous ligaments, to the Coccygeus in front of the ligaments, and to the Glutæus maximus behind them. 16

Base.—The base presents an oval surface for articulation with the sacrum. 17

Apex.—The apex is rounded, and has attached to it the tendon of the Sphincter ani externus. It may be bifid, and is sometimes deflected to one or other side. 18

Ossification of the Vertebral Column.—Each cartilaginous vertebra is ossified from three primary centers ([Fig. 101](#)), two for the vertebral arch and one for the body. ¹⁹ Ossification of the vertebral arches begins in the upper cervical vertebræ about the seventh or eighth week of fetal life, and gradually extends down the column. The ossific granules first appear in the situations where the transverse processes afterward project, and spread backward to the spinous process forward into the pedicles, and lateralward into the transverse and articular processes. Ossification of the bodies begins about the eighth week in the lower thoracic region, and subsequently extends upward and downward along the column. The center for the body does not give rise to the whole of the body of the adult vertebra, the postero-lateral portions of which are ossified by extensions from the vertebral arch centers. The body of the vertebra during the first few years of life shows, therefore, two synchondroses, **neurocentral synchondroses**, traversing it along the planes of junction of the three centers ([Fig. 102](#)). In the thoracic region, the facets for the heads of the ribs lie behind the neurocentral synchondroses and are ossified from the centers for the vertebral arch. At birth the vertebra consists of three pieces, the body and the halves of the vertebral arch. During the first year the halves of the arch unite behind, union taking place first in the lumbar region and then extending upward through the thoracic and cervical regions. About the third year the bodies of the upper cervical vertebræ are joined to the arches on either side; in the lower lumbar vertebræ the union is not completed until the sixth year. Before puberty, no other changes occur, excepting a gradual increase of these primary centers, the upper and under surfaces of the bodies and the ends of the transverse and spinous processes being cartilaginous. About the sixteenth year ([Fig. 102](#)), five secondary centers appear, one for the tip of each transverse process, one for the extremity of the spinous process, one for the upper and one for the lower surface of the body ([Fig. 103](#)). These fuse with the rest of the bone about the age of twenty-five.

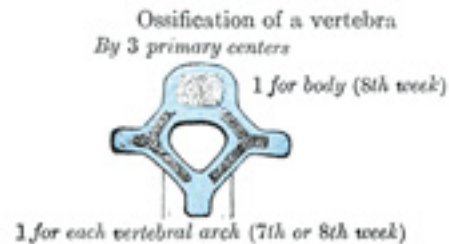

FIG. 101—Ossification of a vertebra ([See enlarged image](#))

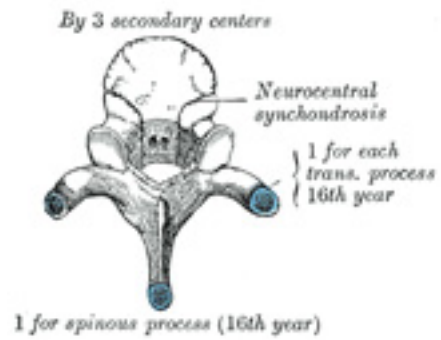


FIG. 102– No caption. ([See enlarged image](#))

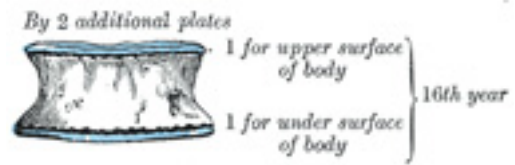

FIG. 103– No caption. ([See enlarged image](#))

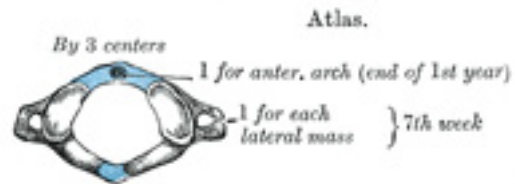


FIG. 104– Atlas. ([See enlarged image](#))

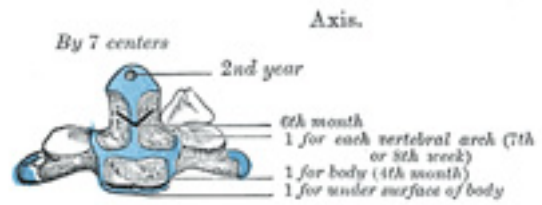


FIG. 105- Axis. ([See enlarged image](#))

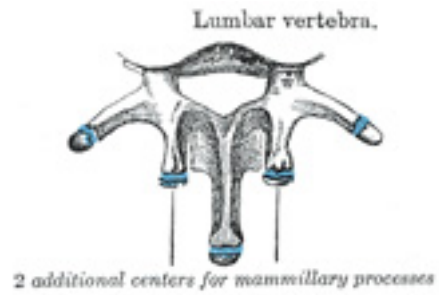


FIG. 106- Lumbar vertebra. ([See enlarged image](#))

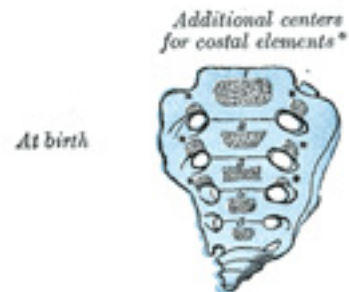

FIG. 107– No caption. ([See enlarged image](#))

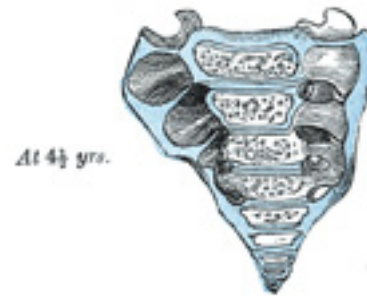

FIG. 108– No caption. ([See enlarged image](#))

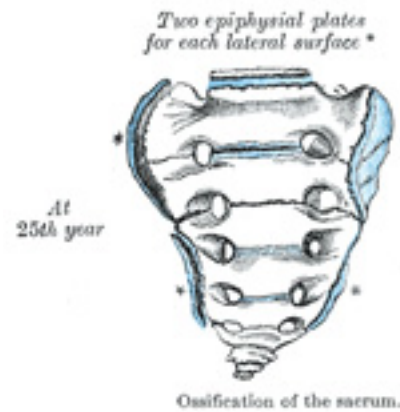


FIG. 109– Ossification of the sacrum. ([See enlarged image](#))

Exceptions to this mode of development occur in the first, second, and seventh cervical vertebræ, and in the lumbar vertebræ.

Atlas.—The atlas is usually ossified from *three* centers ([Fig. 104](#)). Of these, one appears in each lateral mass about the seventh week of fetal life, and extends backward; at birth, these portions of bone are separated from one another behind by a narrow interval filled with cartilage. Between the third and fourth years they unite either directly or through the medium of a separate center developed in the cartilage. At birth, the anterior arch consists of cartilage; in this a separate center appears about the end of the first year after birth, and joins the lateral masses from the sixth to the eighth year—the lines of union extending across the anterior portions of the superior articular facets. Occasionally there is no separate center, the anterior arch being formed by the forward extension and ultimate junction of the two lateral masses; sometimes this arch is ossified from two centers, one on either side of the middle line. 21

Epistrophæus or Axis.—The axis is ossified from *five* primary and *two* secondary centers ([Fig. 105](#)). The body and vertebral arch are ossified in the same manner as the corresponding parts in the other vertebræ, viz., one center for the body, and two for the vertebral arch. The centers for the arch appear about the seventh or eighth week of fetal life, that for the body about the fourth or fifth month. The dens or odontoid process consists originally of a continuation upward of the cartilaginous mass, in which the lower part of the body is formed. About the sixth month of fetal life, two centers make their appearance in the base of this process: they are placed laterally, and join before birth to form a conical bilobed mass deeply cleft above; the interval between the sides of the cleft and the summit of the process is formed by a wedge-shaped piece of cartilage. The base of the process is separated from the body by a cartilaginous disk, which gradually becomes ossified at its circumference, but remains cartilaginous in its center until advanced age. In this cartilage, rudiments of the lower epiphysial lamella of the atlas and the upper epiphysial lamella of the axis may sometimes be found. The apex of the odontoid process has a separate center which appears in the second and joins about the twelfth year; this is the upper epiphysial lamella of the atlas. In addition to these there is a secondary center for a thin epiphysial plate on the under surface of the body of the bone. 22

The Seventh Cervical Vertebra.—The anterior or costal part of the transverse process of this vertebra is sometimes ossified from a separate center which appears about the sixth month of fetal life, and joins the body and posterior part of the transverse process between the fifth and sixth years. Occasionally the costal part persists as a separate piece, and, becoming lengthened lateralward and forward, constitutes what is known as a *cervical rib*. Separate ossific centers have also been found in the costal processes of the fourth, fifth, and sixth cervical vertebræ. 23

Lumbar Vertebræ.—The lumbar vertebræ ([Fig. 106](#)) have each *two* additional centers, for the mammillary processes. The transverse process of the first lumbar is sometimes developed as a separate piece, which may remain permanently ununited with the rest of the bone, thus forming a lumbar rib—a peculiarity, however, rarely met with. 24

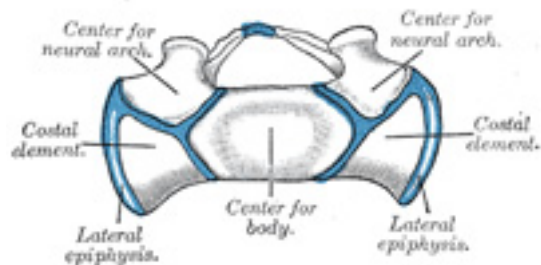


FIG. 110— Base of young sacrum. ([See enlarged image](#))

Sacrum ([Figs. 107 to 110](#)).—The *body* of each sacral vertebra is ossified from a primary center and *two* epiphysial plates, one for its upper and another for its under surface, while each vertebral arch is ossified from two centers. 25

The anterior portions of the *lateral parts* have *six* additional centers, two for each of the first three vertebræ; these represent the costal elements, and make their appearance above and lateral to the anterior sacral foramina ([Figs. 107, 108](#)). 26

On each *lateral surface* two epiphysial plates are developed ([Figs. 109, 110](#)): one for the auricular surface, and another for the remaining part of the thin lateral edge of the bone. 17 27

PERIODS OF OSSIFICATION.—About the eighth or ninth week of fetal life, ossification of the central part of the body of the first sacral vertebra commences, and is rapidly followed by deposit of ossific matter in the second and third; ossification does not commence in the bodies of the lower two segments until between the fifth and eighth months of fetal life. Between the sixth and eighth months ossification of the vertebral arches takes place; and about the same time the costal centers for the lateral parts make their appearance. The junctions of the vertebral arches with the bodies take place in the lower vertebræ as early as the second year, but are not effected in the uppermost until the fifth or sixth year. About the sixteenth year the epiphysial plates for the upper and under surfaces of the bodies are formed; and between the eighteenth and twentieth years, those for the lateral surfaces make their appearance. The bodies of the sacral vertebræ are, during early life, separated from each other by intervertebral fibrocartilages, but about the eighteenth year the two lowest segments become united by bone, and the process of bony union gradually extends upward, with the result that between the twenty-fifth and thirtieth years of life all the segments are united. On examining a sagittal section of the sacrum, the situations of the intervertebral fibrocartilages are indicated by a series of oval cavities ([Fig. 99](#)). 28

Coccyx.—The coccyx is ossified from *four* centers, one for each segment. The ossific nuclei make their appearance in the following order: in the first segment between the first and fourth years; in the second between the fifth and tenth years; in the third between the tenth and fifteenth years; in the fourth between the fourteenth and twentieth years. As age advances, the segments unite with one another, the union between the first and second segments being frequently delayed until after the age of twenty-five or thirty. At a late period of life, especially in females, the coccyx often fuses with the sacrum. 29

Note 16. A vertebra is occasionally found in which the body consists of two lateral portions—a condition which proves that the body is sometimes ossified from *two* primary centers, one on either side of the middle line. [\[back\]](#)

Note 17. The ends of the spinous processes of the upper three sacral vertebræ are sometimes developed from separate epiphyses, and Fawcett (*Anatomischer Anzeiger*, 1907, Band xxx) states that a number of epiphysial nodules may be seen in the sacrum at the age of eighteen years. These are distributed as follows: One for each of the mammillary processes of the first sacral vertebra; twelve—six on either side—in connection with the costal elements (two each for the first and second and one each for the third and fourth) and eight for the transverse processes—four on either side—one each for the first, third, fourth, and fifth. He is further of opinion that the lower part of each lateral surface of the sacrum is formed by the extension and union of the third and fourth “costal” and fourth and fifth “transverse” epiphyses. [\[back\]](#)

3b. The Vertebral Column as a Whole

The vertebral column is situated in the median line, as the posterior part of the trunk; its average length in the male is about 71 cm. Of this length the cervical part measures 12.5 cm., the thoracic about 28 cm., the lumbar 18 cm., and the sacrum and coccyx 12.5 cm. The female column is about 61 cm. in length. ¹

Curves.—Viewed laterally ([Fig. 111](#)), the vertebral column presents several curves, which correspond to the different regions of the column, and are called cervical, thoracic, lumbar, and pelvic. The **cervical** curve, convex forward, begins at the apex of the odontoid process, and ends at the middle of the second thoracic vertebra; it is the least marked of all the curves. The **thoracic** curve, concave forward, begins at the middle of the second and ends at the middle of the twelfth thoracic vertebra. Its most prominent point behind corresponds to the spinous process of the seventh thoracic vertebra. The **lumbar** curve is more marked in the female than in the male; it begins at the middle of the last thoracic vertebra, and ends at the sacrovertebral angle. It is convex anteriorly, the convexity of the lower three vertebræ being much greater than that of the upper two. The **pelvic** curve begins at the sacrovertebral articulation, and ends at the point of the coccyx; its concavity is directed downward and forward. The thoracic and pelvic curves are termed primary curves, because they alone are present during fetal life. The cervical and lumbar curves are compensatory or secondary, and are developed after birth, the former when the child is able to hold up its head (at three or four months), and to sit upright (at nine months), the latter at twelve or eighteen months, when the child begins to walk. ²

The vertebral column has also a slight **lateral** curvature, the convexity of which is directed toward the right side. This may be produced by muscular action, most persons using the right arm in preference to the left, especially in making long-continued efforts, when the body is curved to the right side. In support of this explanation it has been found that in one or two individuals who were left-handed, the convexity was to the left side. By others this curvature is regarded as being produced by the aortic arch and upper part of the descending thoracic aorta—a view which is supported by the fact that in cases where the viscera are transposed and the aorta is on the right side, the convexity of the curve is directed to the left side. ³

Surfaces.—Anterior Surface.—When viewed from in front, the width of the bodies of the vertebræ is seen to increase from the second cervical ⁴

to the first thoracic; there is then a slight diminution in the next three vertebræ; below this there is again a gradual and progressive increase in width as low as the sacrovertebral angle. From this point there is a rapid diminution, to the apex of the coccyx.

Posterior Surface.—The posterior surface of the vertebral column presents in the median line the spinous processes. In the cervical region (with the exception of the second and seventh vertebræ) these are short and horizontal, with bifid extremities. In the upper part of the thoracic region they are directed obliquely downward; in the middle they are almost vertical, and in the lower part they are nearly horizontal. In the lumbar region they are nearly horizontal. The spinous processes are separated by considerable intervals in the lumbar region, by narrower intervals in the neck, and are closely approximated in the middle of the thoracic region. Occasionally one of these processes deviates a little from the median line—a fact to be remembered in practice, as irregularities of this sort are attendant also on fractures or displacements of the vertebral column. On either side of the spinous processes is the **vertebral groove** formed by the laminae in the cervical and lumbar regions, where it is shallow, and by the laminae and transverse processes in the thoracic region, where it is deep and broad; these grooves lodge the deep muscles of the back. Lateral to the vertebral grooves are the articular processes, and still more laterally the transverse processes. In the thoracic region, the transverse processes stand backward, on a plane considerably behind that of the same processes in the cervical and lumbar regions. In the cervical region, the transverse processes are placed in front of the articular processes, lateral to the pedicles and between the intervertebral foramina. In the thoracic region they are posterior to the pedicles, intervertebral foramina, and articular processes. In the lumbar region they are in front of the articular processes, but behind the intervertebral foramina. ⁵

Lateral Surfaces.—The lateral surfaces are separated from the posterior surface by the articular processes in the cervical and lumbar regions, and by the transverse processes in the thoracic region. They present, in front, the sides of the bodies of the vertebræ, marked in the thoracic region by the facets for articulation with the heads of the ribs. More posteriorly are the intervertebral foramina, formed by the juxtaposition of the vertebral notches, oval in shape, smallest in the cervical and upper part of the thoracic regions, and gradually increasing in size to the last lumbar. They transmit the spinal nerves and are situated between the transverse processes in the cervical region, and in front of them in the thoracic and lumbar regions. ⁶

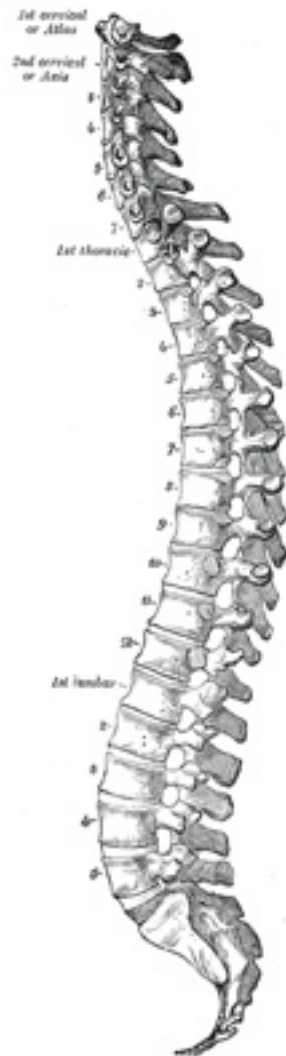

FIG. 111— Lateral view of the vertebral column. ([See enlarged image](#))

Vertebral Canal.—The vertebral canal follows the different curves of the column; it is large and triangular in those parts of the column which enjoy the greatest freedom of movement, viz., the cervical and lumbar regions; and is small and rounded in the thoracic region, where motion is more limited. 7

Abnormalities.—Occasionally the coalescence of the laminæ is not completed, and consequently a cleft is left in the arches of the vertebræ, through which a protrusion of the spinal membranes (dura mater and arachnoid), and generally of the medulla spinalis itself, takes place, constituting the malformation known as *spina bifida*. This condition is most common in the lumbosacral region, but it may occur in the thoracic or cervical region, or the arches throughout the whole length of the canal may remain incomplete. 8

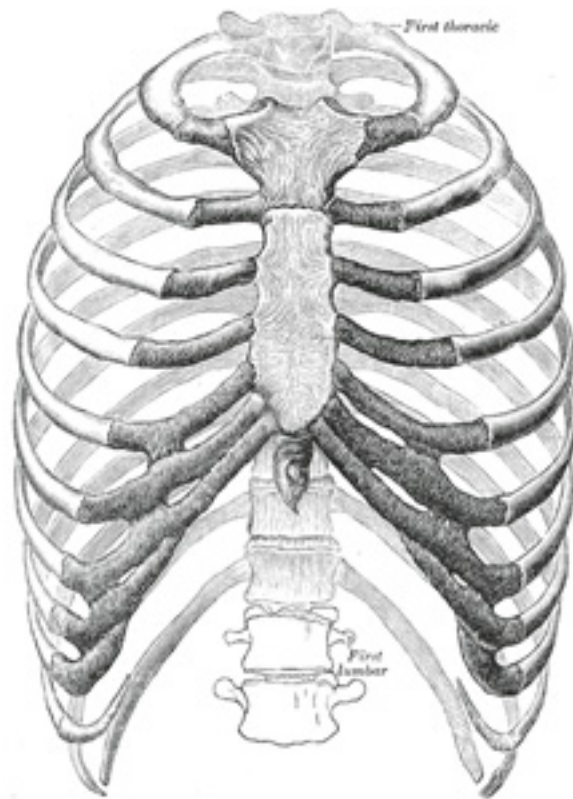


FIG. 112– The thorax from in front. (Spalteholz.) ([See enlarged image](#))

4. The Thorax

The skeleton of the **thorax** or **chest** ([Figs. 112, 113, 114](#)) is an osseo-cartilaginous cage, containing and protecting the principal organs of respiration and circulation. It is conical in shape, being narrow above and broad below, flattened from before backward, and longer behind than in front. It is somewhat reniform on transverse section on account of the projection of the vertebral bodies into the cavity.

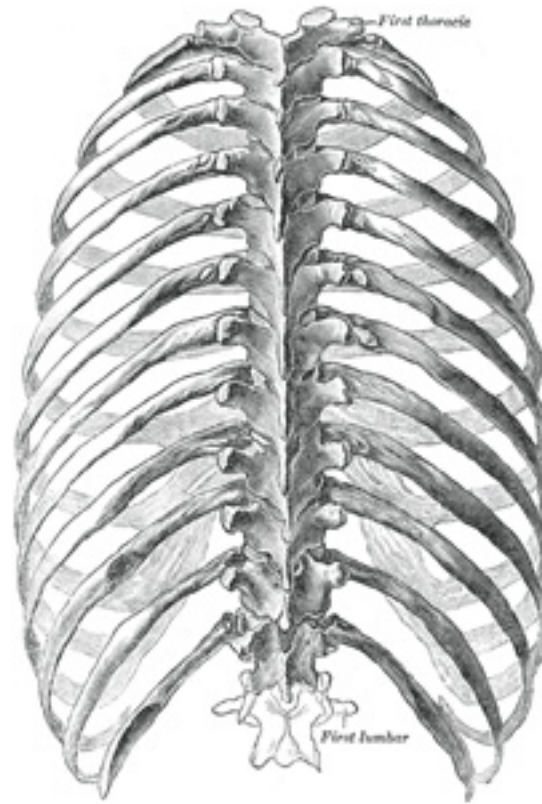


FIG. 113— The thorax from behind. (Spalteholz.) ([See enlarged image](#))

Boundaries.—The **posterior surface** is formed by the twelve thoracic vertebræ and the posterior parts of the ribs. It is convex from above downward, and presents on either side of the middle line a deep groove, in consequence of the lateral and backward direction which the ribs take from their vertebral extremities to their angles. The **anterior surface**, formed by the sternum and costal cartilages, is flattened or slightly convex, and inclined from above downward and forward. The **lateral surfaces** are convex; they are formed by the ribs, separated from each other by the intercostal spaces, eleven in number, which are occupied by the Intercostal muscles and membranes.

2

The **upper opening** of the thorax is reniform in shape, being broader from side to side than from before backward. It is formed by the first

3

thoracic vertebra behind, the upper margin of the sternum in front, and the first rib on either side. It slopes downward and forward, so that the anterior part of the opening is on a lower level than the posterior. Its antero-posterior diameter is about 5 cm., and its transverse diameter about 10 cm. The **lower opening** is formed by the twelfth thoracic vertebra behind, by the eleventh and twelfth ribs at the sides, and in front by the cartilages of the tenth, ninth, eighth, and seventh ribs, which ascend on either side and form an angle, the **subcostal angle**, into the apex of which the xiphoid process projects. The lower opening is wider transversely than from before backward, and slopes obliquely downward and backward, it is closed by the diaphragm which forms the floor of the thorax.

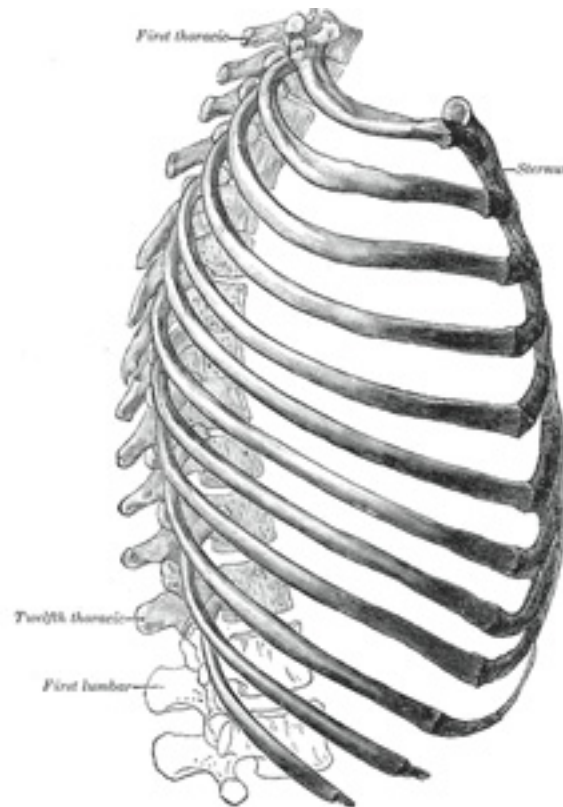


FIG. 114– The thorax from the right. (Spalteholz.) ([See enlarged image](#))

The thorax of the female differs from that of the male as follows: 1. Its capacity is less. 2. The sternum is shorter. 3. The upper margin of the sternum is on a level with the lower part of the body of the third thoracic vertebra, whereas in the male it is on a level with the lower part of the body of the second. 4. The upper ribs are more movable, and so allow a greater enlargement of the upper part of the thorax.

4a. The Sternum

(Breast Bone)

1

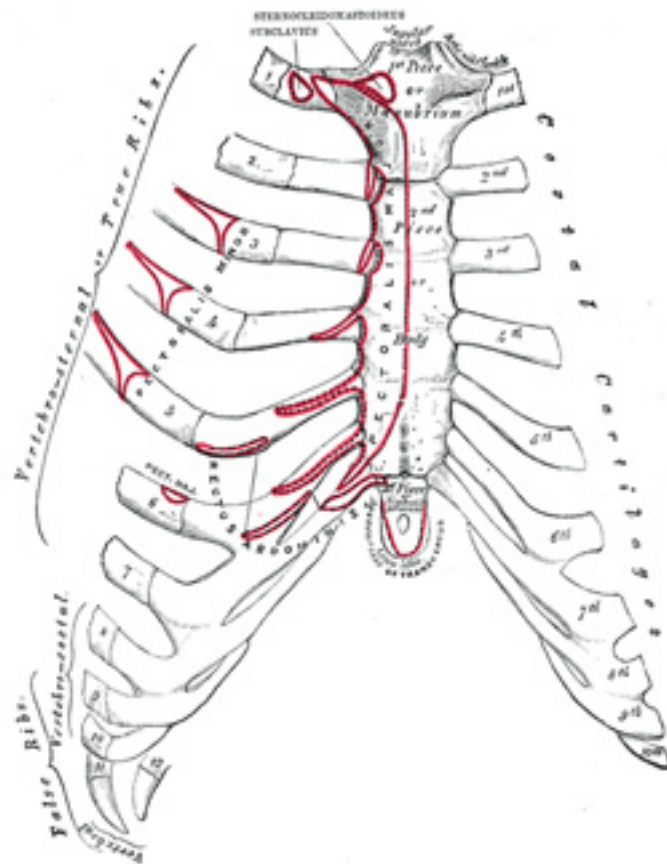


FIG. 115– Anterior surface of sternum and costa cartilages. ([See enlarged image](#))

The **sternum** ([Figs. 115 to 117](#)) is an elongated, flattened bone, forming the middle portion of the anterior wall of the thorax. Its upper end supports the clavicles, and its margins articulate with the cartilages of the first seven **pairs** of ribs. It consists of three parts, named from above downward, the **manubrium**, the **body** or **gladiolus**, and the **xiphoid process**; in early life the body consists of four segments or *sternebrae*. In its natural position the inclination of the bone is oblique from above, downward and forward. It is slightly convex in front and concave behind; broad above, becoming narrowed at the point where the manubrium joins the body, after which it again widens a little to below the middle of the

body, and then narrows to its lower extremity. Its average length in the adult is about 17 cm., and is rather greater in the male than in the female.

Manubrium (*manubrium sterni*).—The manubrium is of a somewhat quadrangular form, broad and thick above, narrow below at its junction with the body. 3

Surfaces.—Its **anterior surface**, convex from side to side, concave from above downward, is smooth, and affords attachment on either side to the sternal origins of the Pectoralis major and Sternocleidomastoideus. Sometimes the ridges limiting the attachments of these muscles are very distinct. Its **posterior surface**, concave and smooth, affords attachment on either side to the Sternohyoideus and Sternothyroideus. 4

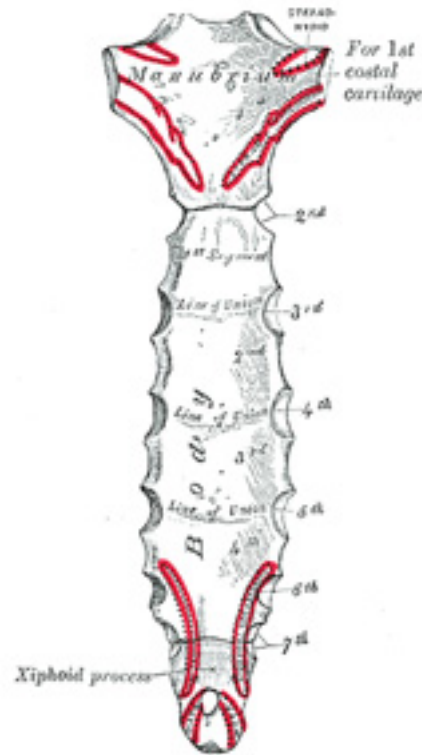


FIG. 116— Posterior surface of sternum. ([See enlarged image](#))

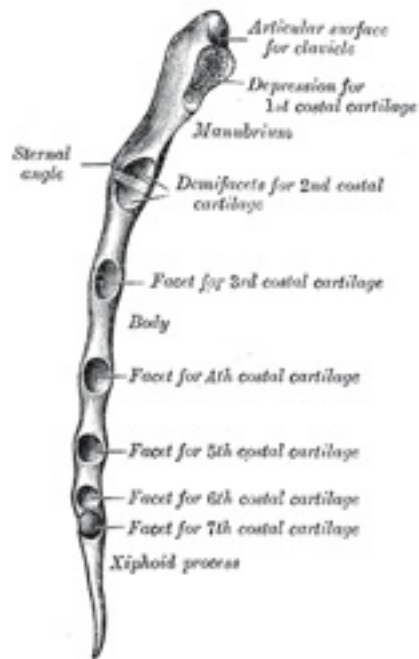


FIG. 117– Lateral border of sternum. ([See enlarged image](#))

Borders.—The **superior border** is the thickest and presents at its center the **jugular or presternal notch**; on either side of the notch is an oval articular surface, directed upward, backward, and lateralward, for articulation with the sternal end of the clavicle. The **inferior border**, oval and rough, is covered in a fresh state with a thin layer of cartilage, for articulation with the body. The **lateral borders** are each marked above by a depression for the first costal cartilage, and below by a small facet, which, with a similar facet on the upper angle of the body, forms a notch for the reception of the costal cartilage of the second rib. Between the depression for the first costal cartilage and the demi-facet for the second is a narrow, curved edge, which slopes from above downward and medialward. 5

Body (*corpus sterni; gladiolus*).—The body, considerably longer, narrower, and thinner than the manubrium, attains its greatest breadth close to 6

the lower end.

Surfaces.—Its **anterior surface** is nearly flat, directed upward and forward, and marked by three transverse ridges which cross the bone opposite the third, fourth, and fifth articular depressions. [18](#) It affords attachment on either side to the sternal origin of the Pectoralis major. At the junction of the third and fourth pieces of the body is occasionally seen an orifice, the **sternal foramen**, of varying size and form. The **posterior surface**, slightly concave, is also marked by three transverse lines, less distinct, however, than those in front; from its lower part, on either side, the Transversus thoracis takes origin. 7

Borders.—The **superior border** is oval and articulates with the manubrium, the junction of the two forming the **sternal angle** (*angulus Ludovici* [19](#)). The **inferior border** is narrow, and articulates with the xiphoid process. Each **lateral border** ([Fig. 117](#)), at its superior angle, has a small facet, which with a similar facet on the manubrium, forms a cavity for the cartilage of the second rib; below this are four angular depressions which receive the cartilages of the third, fourth, fifth, and sixth ribs, while the inferior angle has a small facet, which, with a corresponding one on the xiphoid process, forms a notch for the cartilage of the seventh rib. These articular depressions are separated by a series of curved interarticular intervals, which diminish in length from above downward, and correspond to the intercostal spaces. Most of the cartilages belonging to the true ribs, as will be seen from the foregoing description, articulate with the sternum at the lines of junction of its primitive component segments. This is well seen in many of the lower animals, where the parts of the bone remain ununited longer than in man. 8

Xiphoid Process (*processus xiphoideus; ensiform or xiphoid appendix*).—The xiphoid process is the smallest of the three pieces: it is thin and elongated, cartilaginous in structure in youth, but more or less ossified at its upper part in the adult. 9

Surfaces.—Its **anterior surface** affords attachment on either side to the anterior costoxiphoid ligament and a small part of the Rectus abdominis; its **posterior surface**, to the posterior costoxiphoid ligament and to some of the fibers of the diaphragm and Transversus thoracis, its **lateral borders**, to the aponeuroses of the abdominal muscles. Above, it articulates with the lower end of the body, and on the front of each superior angle presents a facet for part of the cartilage of the seventh rib; below, by its pointed extremity, it gives attachment to the linea alba. The xiphoid process varies much in form; it may be broad and thin, pointed, bifid, perforated, curved, or deflected considerably to one or other side. 10

Structure.—The sternum is composed of highly vascular cancellous tissue, covered by a thin layer of compact bone which is thickest in the manubrium between the articular facets for the clavicles. 11

Ossification.—The sternum originally consists of two cartilaginous bars, situated one on either side of the median plane and connected with the cartilages of the upper nine ribs of its own side. These two bars fuse with each other along the middle line to form the cartilaginous sternum which is ossified from *six* centers: one for the manubrium, four for the body, and one for the xiphoid process ([Fig. 118](#)). The ossific centers appear in the intervals between the articular depressions for the costal cartilages, in the following order: in the manubrium and first piece of the body, during the sixth month; in the second and third pieces of the body, during the seventh month of fetal life; in its fourth piece, during the first 12

year after birth; and in the xiphoid process, between the fifth and eighteenth years. The centers make their appearance at the upper parts of the segments, and proceed gradually downward. ²⁰ To these may be added the occasional existence of two small episternal centers, which make their appearance one on either side of the jugular notch; they are probably vestiges of the episternal bone of the monotremata and lizards. Occasionally some of the segments are formed from more than one center, the number and position of which vary (Fig. 120). Thus, the first piece may have two, three, or even six centers. When two are present, they are generally situated one above the other, the upper being the larger; the second piece has seldom more than one; the third, fourth, and fifth pieces are often formed from two centers placed laterally, the irregular union of which explains the rare occurrence of the sternal foramen (Fig. 121), or of the vertical fissure which occasionally intersects this part of the bone constituting the malformation known as *asfissura sterni*; these conditions are further explained by the manner in which the cartilaginous sternum is formed. More rarely still the upper end of the sternum may be divided by a fissure. Union of the various centers of the body begins about puberty, and proceeds from below upward (Fig. 119); by the age of twenty-five they are all united. The xiphoid process may become joined to the body before the age of thirty, but this occurs more frequently after forty; on the other hand, it sometimes remains ununited in old age. In advanced life the manubrium is occasionally joined to the body by bone. When this takes place, however, the bony tissue is generally only superficial, the central portion of the intervening cartilage remaining unossified.

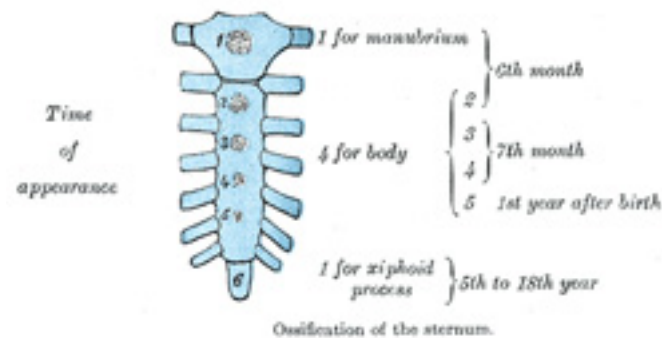


FIG. 118—Ossification of the sternum. (See enlarged image)

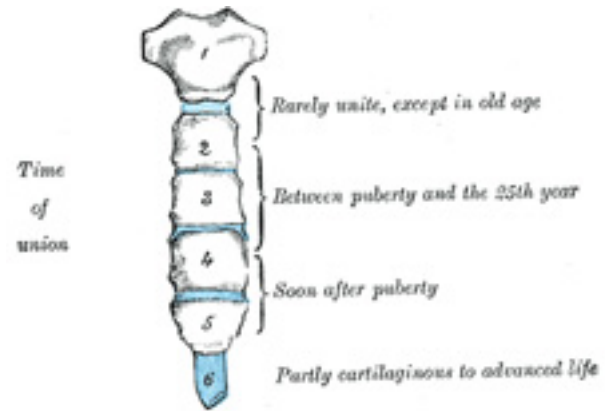


FIG. 119— No caption. ([See enlarged image](#))

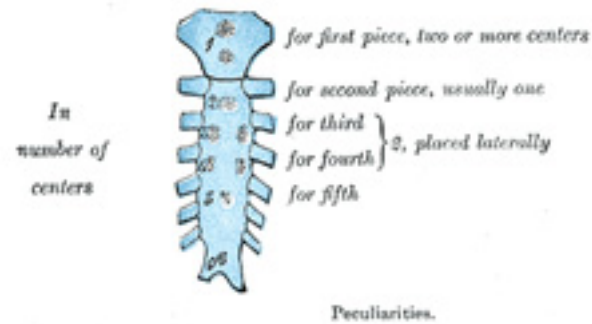

FIG. 120— Peculiarities. ([See enlarged image](#))

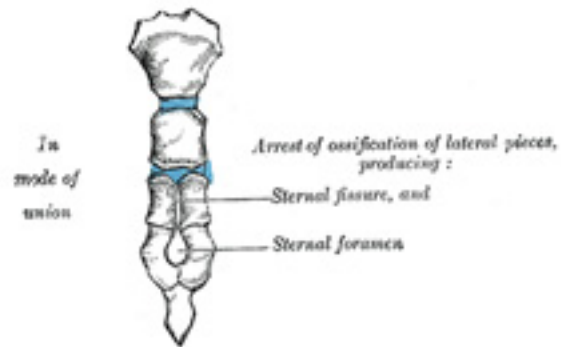


FIG. 121— No caption. ([See enlarged image](#))

Articulations.—The sternum articulates on either side with the clavicle and upper seven costal cartilages.

13

Note 18. Paterson (*The Human Sternum*, 1904), who examined 524 specimens, points out that these ridges are altogether absent in 26.7 per cent.; that in 69 per cent. a ridge exists opposite the third costal attachment; in 39 per cent. opposite the fourth; and in 4 per cent. only, opposite the fifth. [[back](#)]

Note 19. Named after the French surgeon Antoine Louis, 1723–1792. The Latin name *angulus Ludovici* is not infrequently mistranslated into English as “the angle of Ludwig.” [[back](#)]

Note 20. Out of 141 sterna between the time of birth and the age of sixteen years, Paterson (*op. cit.*) found the fourth or lowest center for the body present only in thirty-eight cases—*i. e.*, 26.9 per cent. [[back](#)]

4b. The Ribs

(*Costæ*)

1

The **ribs** are elastic arches of bone, which form a large part of the thoracic skeleton. They are twelve in number on either side; but this number may be increased by the development of a cervical or lumbar rib, or may be diminished to eleven. The first seven are connected behind with the vertebral column, and in front, through the intervention of the costal cartilages, with the sternum ([Fig. 115](#)); they are called **true** or **vertebro-**

sternal ribs. [21](#)The remaining five are **false ribs**; of these, the first three have their cartilages attached to the cartilage of the rib above (**vertebro-chondral**): the last two are free at their anterior extremities and are termed **floating** or **vertebral ribs**. The ribs vary in their direction, the upper ones being less oblique than the lower; the obliquity reaches its maximum at the ninth rib, and gradually decreases from that rib to the twelfth. The ribs are situated one below the other in such a manner that spaces called **intercostal spaces** are left between them. The length of each space corresponds to that of the adjacent ribs and their cartilages; the breadth is greater in front than behind, and between the upper than the lower ribs. The ribs increase in length from the first to the seventh, below which they diminish to the twelfth. In breadth they decrease from above downward; in the upper ten the greatest breadth is at the sternal extremity.

Common Characteristics of the Ribs ([Figs. 122, 123](#)).—A rib from the middle of the series should be taken in order to study the common characteristics of these bones. 2

Each rib has two extremities, a **posterior** or **vertebral**, and an **anterior** or **sternal**, and an intervening portion—the **body** or **shaft**. 3

Posterior Extremity.—The **posterior** or **vertebral extremity** presents for examination a head, neck, and tubercle. 4

The **head** is marked by a kidney-shaped articular surface, divided by a horizontal crest into two facets for articulation with the depression formed on the bodies of two adjacent thoracic vertebræ; the upper facet is the smaller; to the crest is attached the interarticular ligament. 5

The **neck** is the flattened portion which extends lateralward from the head; it is about 2.5 cm. long, and is placed in front of the transverse process of the lower of the two vertebræ with which the head articulates. Its **anterior surface** is flat and smooth, its **posterior** rough for the attachment of the ligament of the neck, and perforated by numerous foramina. Of its two borders the **superior** presents a rough crest (*crista colli costæ*) for the attachment of the anterior costotransverse ligament; its **inferior border** is rounded. On the posterior surface at the junction of the neck and body, and nearer the lower than the upper border, is an eminence—the **tubercle**; it consists of an articular and a non-articular portion. The *articular portion*, the lower and more medial of the two, presents a small, oval surface for articulation with the end of the transverse process of the lower of the two vertebræ to which the head is connected. The *non-articular portion* is a rough elevation, and affords attachment to the ligament of the tubercle. The tubercle is much more prominent in the upper than in the lower ribs. 6

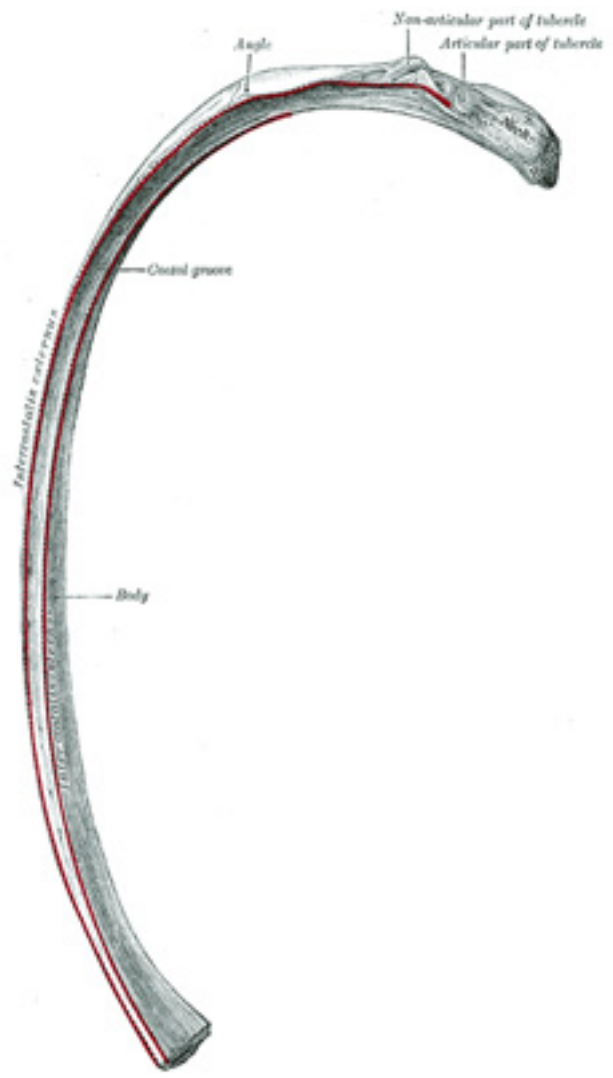


FIG. 122– A central rib of the left side. Inferior aspect. ([See enlarged image](#))

Body.—The **body** or **shaft** is thin and flat, with two surfaces, an external and an internal; and two borders, a superior and an inferior. 7
The **external surface** is convex, smooth, and marked, a little in front of the tubercle, by a prominent line, directed downward and lateralward; this gives attachment to a tendon of the Iliocostalis, and is called the **angle**. At this point the rib is bent in two directions, and at the same time twisted on its long axis. If the rib be laid upon its lower border, the portion of the body in front of the angle rests upon this border, while the portion behind the angle is bent medialward and at the same time tilted upward; as the result of the twisting, the external surface, behind the angle, looks downward, and in front of the angle, slightly upward. The distance between the angle and the tubercle is progressively greater from the second to the tenth ribs. The portion between the angle and the tubercle is rounded, rough, and irregular, and serves for the attachment of the Longissimus dorsi. The **internal surface** is concave, smooth, directed a little upward behind the angle, a little downward in front of it, and is marked by a ridge which commences at the lower extremity of the head; this ridge is strongly marked as far as the angle, and gradually becomes lost at the junction of the anterior and middle thirds of the bone. Between it and the inferior border is a groove, the **costal groove**, for the intercostal vessels and nerve. At the back part of the bone, this groove belongs to the inferior border, but just in front of the angle, where it is deepest and broadest, it is on the internal surface. The superior edge of the groove is rounded and serves for the attachment of an Intercostalis internus; the inferior edge corresponds to the lower margin of the rib, and gives attachment to an Intercostalis externus. Within the groove are seen the orifices of numerous small foramina for nutrient vessels which traverse the shaft obliquely from before backward. The **superior border**, thick and rounded, is marked by an external and an internal lip, more distinct behind than in front, which serve for the attachment of Intercostales externus and internus. The **inferior border** is thin, and has attached to it an Intercostalis externus.

Anterior Extremity.—The **anterior** or **sternal extremity** is flattened, and presents a porous, oval, concave depression, into which the costal cartilage is received. 8

Peculiar Ribs.—The first, second, tenth, eleventh, and twelfth ribs present certain variations from the common characteristics described above, and require special consideration. 9

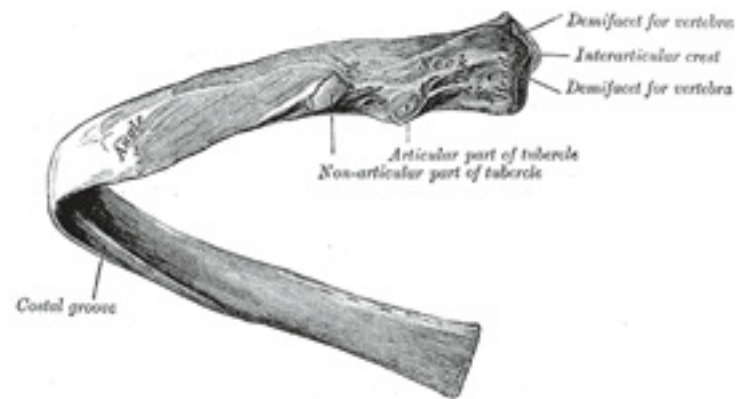


FIG. 123— A central rib of the left side, viewed from behind. ([See enlarged image](#))

First Rib.—The first rib ([Fig. 124](#)) is the most curved and usually the shortest of all the ribs; it is broad and flat, its surfaces looking upward and downward, and its borders inward and outward. The **head** is small, rounded, and possesses only a single articular facet, for articulation with the body of the first thoracic vertebra. The **neck** is narrow and rounded. The **tubercle**, thick and prominent, is placed on the outer border. There is *no angle*, but at the tubercle the rib is slightly bent, with the convexity upward, so that the head of the bone is directed downward. The **upper surface** of the body is marked by two shallow grooves, separated from each other by a slight ridge prolonged internally into a tubercle, the **scalene tubercle**, for the attachment of the Scalenus anterior; the anterior groove transmits the subclavian vein, the posterior the subclavian artery and the lowest trunk of the brachial plexus. ²² Behind the posterior groove is a rough area for the attachment of the Scalenus medius. The **under surface** is smooth, and destitute of a costal groove. The **outer border** is convex, thick, and rounded, and at its posterior part gives attachment to the first digitation of the Serratus anterior; the **inner border** is concave, thin, and sharp, and marked about its center by the scalene tubercle. The **anterior extremity** is larger and thicker than that of any of the other ribs. ¹⁰

Second Rib.—The second rib ([Fig. 125](#)) is much longer than the first, but has a very similar curvature. The non-articular portion of the **tubercle** is occasionally only feebly marked. The **angle** is slight, and situated close to the tubercle. The **body** is not twisted, so that both ends touch any plane surface upon which it may be laid; but there is a bend, with its convexity upward, similar to, though smaller than that found in the first rib. The body is not flattened horizontally like that of the first rib. Its **external surface** is convex, and looks upward and a little outward; near the middle of it is a rough eminence for the origin of the lower part of the first and the whole of the second digitation of the Serratus anterior; behind and above this is attached the Scalenus posterior. The **internal surface**, smooth, and concave, is directed downward and a little inward: on its posterior part there is a short costal groove. ¹¹

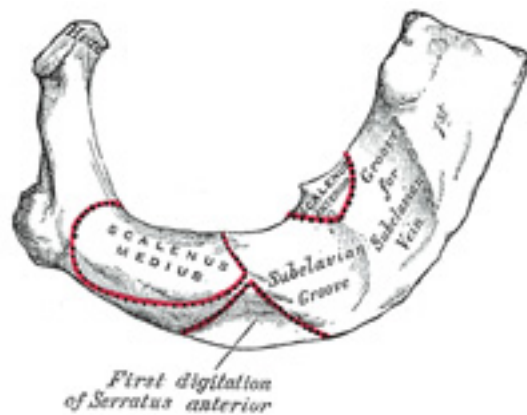


FIG. 124— Peculiar ribs. ([See enlarged image](#))

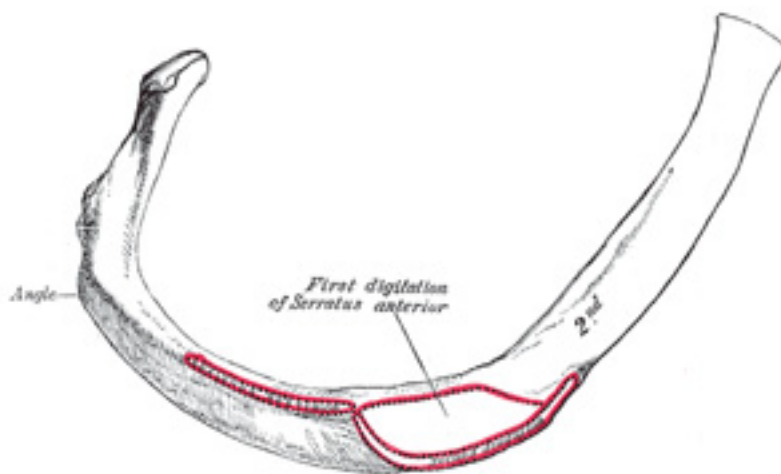


FIG. 125— Peculiar ribs. ([See enlarged image](#))

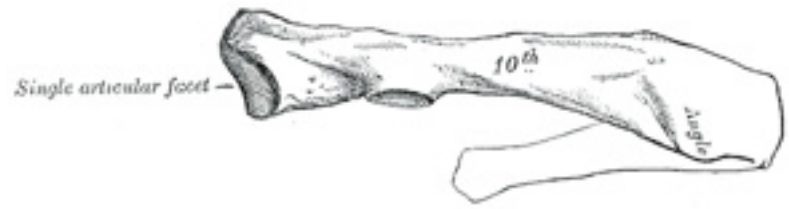

FIG. 126— Peculiar ribs. ([See enlarged image](#))

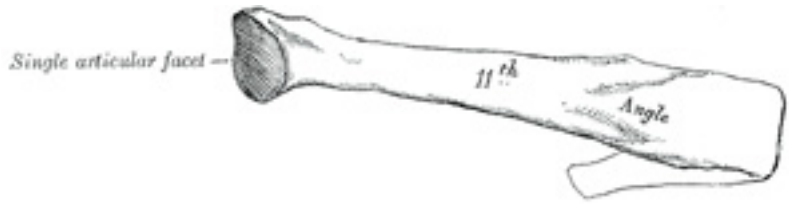

FIG. 127— Peculiar ribs. ([See enlarged image](#))

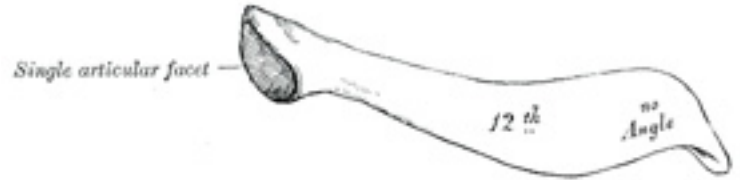

FIG. 128— Peculiar ribs. ([See enlarged image](#))

Tenth Rib.—The tenth rib ([Fig. 126](#)) has only a single articular facet on its head.

Eleventh and Twelfth Ribs.—The eleventh and twelfth ribs ([Figs. 127](#) and [128](#)) have each a single articular facet on the head, which is of rather large size; they have *no necks or tubercles*, and are pointed at their anterior ends. The eleventh has a slight angle and a shallow costal groove. The twelfth has neither; it is much shorter than the eleventh, and its head is inclined slightly downward. Sometimes the twelfth rib is even shorter than the first. 13

Structure.—The ribs consist of highly vascular cancellous tissue, enclosed in a thin layer of compact bone. 14

Ossification.—Each rib, with the exception of the last two, is ossified from *four* centers; a primary center for the body, and three epiphysial centers, one for the head and one each for the articular and non-articular parts of the tubercle. The eleventh and twelfth ribs have each only *two* centers, those for the tubercles being wanting. Ossification begins near the angle toward the end of the second month of fetal life, and is seen first in the sixth and seventh ribs. The epiphyses for the head and tubercle make their appearance between the sixteenth and twentieth years, and are united to the body about the twenty-fifth year. Fawcett [23](#) states that “in all probability there is usually no epiphysis on the non-articular part of the tuberosity below the sixth or seventh rib. 15

Note 21. Sometimes the eighth rib cartilage articulates with the sternum; this condition occurs more frequently on the right than on the left side. [\[back\]](#)

Note 22. Anat. Anzeiger, 1910, Band xxxvi. [\[back\]](#)

Note 23. Journal of Anatomy and Physiology. vol. xlv. [\[back\]](#)

4c. The Costal Cartilages

(Cartilagine Costales)

1

The **costal cartilages** ([Fig. 115](#)) are bars of hyaline cartilage which serve to prolong the ribs forward and contribute very materially to the elasticity of the walls of the thorax. The first seven pairs are connected with the sternum; the next three are each articulated with the lower border of the cartilage of the preceding rib; the last two have pointed extremities, which end in the wall of the abdomen. Like the ribs, the costal cartilages vary in their length, breadth, and direction. They increase in length from the first to the seventh, then gradually decrease to the twelfth. Their breadth, as well as that of the intervals between them, diminishes from the first to the last. They are broad at their attachments to the ribs, and taper toward their sternal extremities, excepting the first two, which are of the same breadth throughout, and the sixth, seventh, and eighth, which are enlarged where their margins are in contact. They also vary in direction: the first descends a little, the second is horizontal, the third ascends slightly, while the others are angular, following the course of the ribs for a short distance, and then ascending to the sternum or preceding cartilage. Each costal cartilage presents two surfaces, two borders, and two extremities.

Surfaces.—The **anterior surface** is convex, and looks forward and upward: that of the first gives attachment to the costoclavicular ligament and the Subclavius muscle; those of the first six or seven at their sternal ends, to the Pectoralis major. The others are covered by, and give partial attachment to, some of the flat muscles of the abdomen. The **posterior surface** is concave, and directed backward and downward; that of the first gives attachment to the Sternothyroideus, those of the third to the sixth inclusive to the Transversus thoracis, and the six or seven inferior ones to the Transversus abdominis and the diaphragm. 2

Borders.—Of the two borders the **superior** is concave, the **inferior** convex; they afford attachment to the Intercostales interni: the upper border of the sixth gives attachment also to the Pectoralis major. The inferior borders of the sixth, seventh, eighth, and ninth cartilages present heel-like projections at the points of greatest convexity. These projections carry smooth oblong facets which articulate respectively with facets on slight projections from the upper borders of the seventh, eighth, ninth, and tenth cartilages. 3

Extremities.—The **lateral end** of each cartilage is continuous with the osseous tissue of the rib to which it belongs. The **medial end** of the first is continuous with the sternum; the medial ends of the six succeeding ones are rounded and are received into shallow concavities on the lateral margins of the sternum. The medial ends of the eighth, ninth, and tenth costal cartilages are pointed, and are connected each with the cartilage immediately above. Those of the eleventh and twelfth are pointed and free. In old age the costal cartilages are prone to undergo superficial ossification. 4

Cervical ribs derived from the seventh cervical vertebra (page 83) are of not infrequent occurrence, and are important clinically because they may give rise to obscure nervous or vascular symptoms. The cervical rib may be a mere epiphysis articulating only with the transverse process of the vertebra, but more commonly it consists of a defined head, neck, and tubercle, with or without a body. It extends lateralward, or forward and lateralward, into the posterior triangle of the neck, where it may terminate in a free end or may join the first thoracic rib, the first costal cartilage, or the sternum. [24](#) It varies much in shape, size, direction, and mobility. If it reach far enough forward, part of the brachial plexus and the subclavian artery and vein cross over it, and are apt to suffer compression in so doing. Pressure on the artery may obstruct the circulation so much that arterial thrombosis results, causing gangrene of the finger tips. Pressure on the nerves is commoner, and affects the eighth cervical and first thoracic nerves, causing paralysis of the muscles they supply, and neuralgic pains and paresthesia in the area of skin to which they are distributed: no oculo-pupillary changes are to be found. 5

The *thorax* is frequently found to be altered in shape in certain diseases. 6

In *rickets*, the ends of the ribs, where they join the costal cartilages, become enlarged, giving rise to the so-called “rickety rosary,” which in mild cases is only found on the internal surface of the thorax. Lateral to these enlargements the softened ribs sink in, so as to present a groove passing downward and lateralward on either side of the sternum. This bone is forced forward by the bending of the ribs, and the antero-posterior diameter of the chest is increased. The ribs affected are the second to the eighth, the lower ones being prevented from falling in by the presence of the liver, stomach, and spleen; and when the abdomen is distended, as it often is in rickets, the lower ribs may be pushed outward, causing a transverse groove (Harrison’s sulcus) just above the costal arch. This deformity or forward projection of the sternum, often asymmetrical, is known as *pigeon breast*, and may be taken as evidence of active or old rickets except in cases of primary spinal curvature. In many instances it is associated in children with obstruction in the upper air passages, due to enlarged tonsils or adenoid growths. In some rickety children or adults, 7

and also in others who give no history or further evidence of having had rickets, an opposite condition obtains. The lower part of the sternum and often the xiphoid process as well are deeply depressed backward, producing an oval hollow in the lower sternal and upper epigastric regions. This is known as *funnel breast* (German, *Trichterbrust*); it never appears to produce the least disturbance of any of the vital functions. The *phthisical chest* is often long and narrow, and with great obliquity of the ribs and projection of the scapulæ. In *pulmonary emphysema* the chest is enlarged in all its diameters, and presents on section an almost circular outline. It has received the name of the *barrel-shaped chest*. In severe cases of *lateral curvature of the vertebral column* the thorax becomes much distorted. In consequence of the rotation of the bodies of the vertebræ which takes place in this disease, the ribs opposite the convexity of the dorsal curve become extremely convex behind, being thrown out and bulging, and at the same time flattened in front, so that the two ends of the same rib are almost parallel. Coincidentally with this the ribs on the opposite side, on the concavity of the curve, are sunk and depressed behind, and bulging and convex in front.

Note 24. W. Thorburn, *The Medical Chronicle*, Manchester, 1907, 4th series, xiv, No. 3 [[back](#)]

5. The Skull

The **skull** is supported on the summit of the vertebral column, and is of an oval shape, wider behind than in front. It is composed of a series of flattened or irregular bones which, with one exception (the mandible), are immovably jointed together. It is divisible into two parts: (1) the **cranium**, which lodges and protects the brain, consists of eight bones, and (2) the **skelton of the face**, of fourteen, as follows:

	Occipital.
	Two Parietals.
	Frontal.
<i>Cranium</i> , 8 bones	Two Temporals.
	Sphenoidal.
	Ethmoidal.
	Two Nasals.
<i>Skull</i> , 22 bones	Two Maxillæ.
	Two Lacrimals.
	Two Zygomatics.
<i>Face</i> , 14 bones	Two Palatines.
	Two Inferior Nasal Conchæ.
	Vomer.
	Mandible.

FIG. 129— Occipital bone. Outer surface. ([See enlarged image](#))

The curved, expanded plate behind the foramen magnum is named the **squama**; the thick, somewhat quadrilateral piece in front of the foramen is called the **basilar part**, whilst on either side of the foramen is the **lateral portion**. 2

The Squama (*squama occipitalis*).—The squama, situated above and behind the foramen magnum, is curved from above downward and from side to side. 3

Surfaces.—The **external surface** is convex and presents midway between the summit of the bone and the foramen magnum a prominence, the **external occipital protuberance**. Extending lateralward from this on either side are two curved lines, one a little above the other. The upper, often faintly marked, is named the **highest nuchal line**, and to it the galea aponeurotica is attached. The lower is termed the **superior nuchal line**. That part of the squama which lies above the highest nuchal lines is named the **planum occipitale**, and is covered by the Occipitalis muscle; that below, termed the **planum nuchale**, is rough and irregular for the attachment of several muscles. From the external occipital protuberance a ridge or crest, the **median nuchal line**, often faintly marked, descends to the foramen magnum, and affords attachment to the ligamentum nuchæ; running from the middle of this line across either half of the nuchal plane is the **inferior nuchal line**. Several muscles are attached to the outer surface of the squama, thus: the superior nuchal line gives origin to the Occipitalis and Trapezius, and insertion to the Sternocleidomastoideus and Splenius capitis: into the surface between the superior and inferior nuchal lines the Semispinalis capitis and the Obliquus capitis superior are inserted, while the inferior nuchal line and the area below it receive the insertions of the Recti capitis posteriores major and minor. The posterior atlantooccipital membrane is attached around the postero-lateral part of the foramen magnum, just outside the margin of the foramen. 4

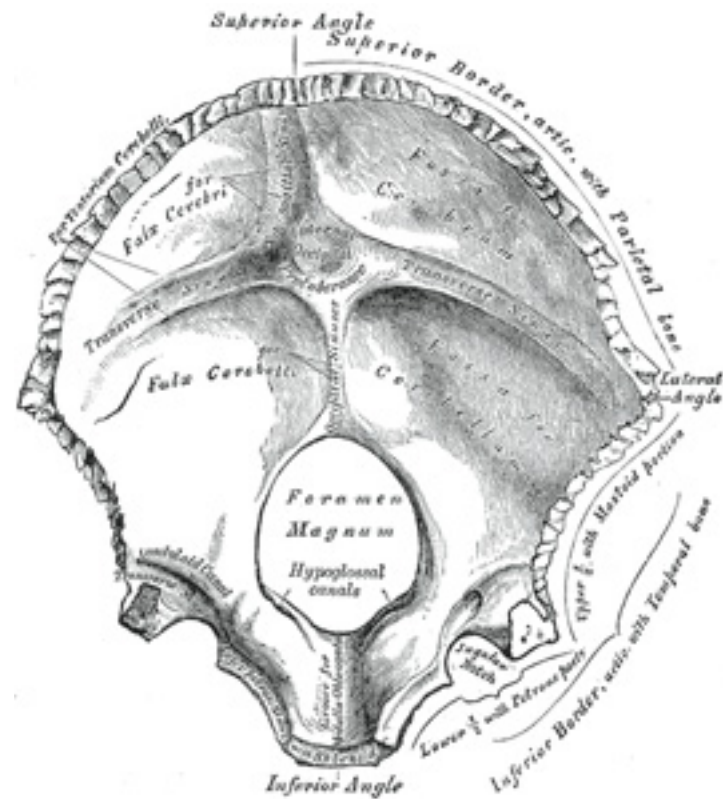


FIG. 130– Occipita bone. Inner surface. ([See enlarged image](#))

The **internal surface** is deeply concave and divided into four fossæ by a **cruciate eminence**. The upper two fossæ are triangular and lodge the occipital lobes of the cerebrum; the lower two are quadrilateral and accommodate the hemispheres of the cerebellum. At the point of intersection of the four divisions of the cruciate eminence is the **internal occipital protuberance**. From this protuberance the upper division of the cruciate eminence runs to the superior angle of the bone, and on one side of it (generally the right) is a deep groove, the **sagittal sulcus**, which lodges the hinder part of the superior sagittal sinus; to the margins of this sulcus the falx cerebri is attached. The lower division of the cruciate eminence is prominent, and is named the **internal occipital crest**; it bifurcates near the foramen magnum and gives attachment to the falx cerebelli; in the attached margin of this falx is the occipital sinus, which is sometimes duplicated. In the upper part of the internal occipital crest, a small

depression is sometimes distinguishable; it is termed the **vermian fossa** since it is occupied by part of the vermis of the cerebellum. Transverse grooves, one on either side, extend from the internal occipital protuberance to the lateral angles of the bone; those grooves accommodate the transverse sinuses, and their prominent margins give attachment to the tentorium cerebelli. The groove on the right side is usually larger than that on the left, and is continuous with that for the superior sagittal sinus. Exceptions to this condition are, however, not infrequent; the left may be larger than the right or the two may be almost equal in size. The angle of union of the superior sagittal and transverse sinuses is named the **confluence of the sinuses** (*torcular Herophili* [25](#)), and its position is indicated by a depression situated on one or other side of the protuberance.

Lateral Parts (*pars lateralis*).—The lateral parts are situated at the sides of the foramen magnum; on their under surfaces are the **condyles** for articulation with the superior facets of the atlas. The condyles are oval or reniform in shape, and their anterior extremities, directed forward and medialward, are closer together than their posterior, and encroach on the basilar portion of the bone; the posterior extremities extend back to the level of the middle of the foramen magnum. The articular surfaces of the condyles are convex from before backward and from side to side, and look downward and lateralward. To their margins are attached the capsules of the atlantoöccipital articulations, and on the medial side of each is a rough impression or tubercle for the alar ligament. At the base of either condyle the bone is tunnelled by a short canal, the **hypoglossal canal** (*anterior condyloid foramen*). This begins on the cranial surface of the bone immediately above the foramen magnum, and is directed lateralward and forward above the condyle. It may be partially or completely divided into two by a spicule of bone; it gives exit to the hypoglossal and twelfth cerebral nerve, and entrance to a meningeal branch of the ascending pharyngeal artery. Behind either condyle is a depression, the **condyloid fossa**, which receives the posterior margin of the superior facet of the atlas when the head is bent backward; the floor of this fossa is sometimes perforated by the **condyloid canal**, through which an emissary vein passes from the transverse sinus. Extending lateralward from the posterior half of the condyle is a quadrilateral plate of bone, the **jugular process**, excavated in front by the **jugular notch**, which, in the articulated skull, forms the posterior part of the jugular foramen. The jugular notch may be divided into two by a bony spicule, the **intrajugular process**, which projects lateralward above the hypoglossal canal. The under surface of the jugular process is rough, and gives attachment to the Rectus capitis lateralis muscle and the lateral atlantoöccipital ligament; from this surface an eminence, the **paramastoid process**, sometimes projects downward, and may be of sufficient length to reach, and articulate with, the transverse process of the atlas. Laterally the jugular process presents a rough quadrilateral or triangular area which is joined to the jugular surface of the temporal bone by a plate of cartilage; after the age of twenty-five this plate tends to ossify.

The **upper surface** of the lateral part presents an oval eminence, the **jugular tubercle**, which overlies the hypoglossal canal and is sometimes crossed by an oblique groove for the glossopharyngeal, vagus, and accessory nerves. On the upper surface of the jugular process is a deep groove which curves medialward and forward and is continuous with the jugular notch. This groove lodges the terminal part of the transverse sinus, and opening into it, close to its medial margin, is the orifice of the condyloid canal.

Basilar Part (*pars basilaris*).—The basilar part extends forward and upward from the foramen magnum, and presents *in front* an area more or less quadrilateral in outline. In the young skull this area is rough and uneven, and is joined to the body of the sphenoid by a plate of cartilage. By the twenty-fifth year this cartilaginous plate is ossified, and the occipital and sphenoid form a continuous bone.

Surfaces.—On its **lower surface**, about 1 cm. in front of the foramen magnum, is the **pharyngeal tubercle** which gives attachment to the fibrous

raphé of the pharynx. On either side of the middle line the Longus capitis and Rectus capitis anterior are inserted, and immediately in front of the foramen magnum the anterior atlantoöccipital membrane is attached.

The **upper surface** presents a broad, shallow groove which inclines upward and forward from the foramen magnum; it supports the medulla oblongata, and near the margin of the foramen magnum gives attachment to the membrana tectoria. On the lateral margins of this surface are faint grooves for the inferior petrosal sinuses. 10

Foramen Magnum.—The foramen magnum is a large oval aperture with its long diameter antero-posterior; it is wider behind than in front where it is encroached upon by the condyles. It transmits the medulla oblongata and its membranes, the accessory nerves, the vertebral arteries, the anterior and posterior spinal arteries, and the membrana tectoria and alar ligaments. 11

Angles.—The **superior angle** of the occipital bone articulates with the occipital angles of the parietal bones and, in the fetal skull, corresponds in position with the **posterior fontanelle**. The **inferior angle** is fused with the body of the sphenoid. The **lateral angles** are situated at the extremities of the grooves for the transverse sinuses: each is received into the interval between the mastoid angle of the parietal and the mastoid part of the temporal. 12

Borders.—The **superior borders** extend from the superior to the lateral angles: they are deeply serrated for articulation with the occipital borders of the parietals, and form by this union the **lambdoidal suture**. The **inferior borders** extend from the lateral angles to the inferior angle; the upper half of each articulates with the mastoid portion of the corresponding temporal, the lower half with the petrous part of the same bone. These two portions of the inferior border are separated from one another by the jugular process, the notch on the anterior surface of which forms the posterior part of the jugular foramen. 13

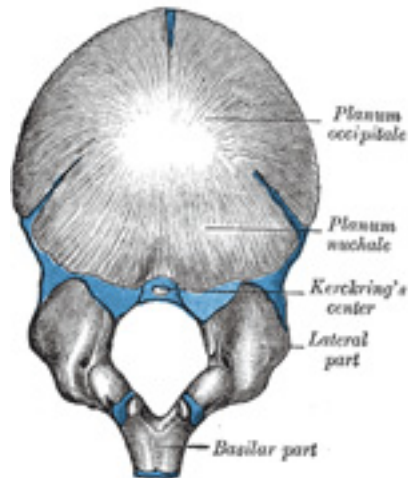


FIG. 131— Occipital bone at birth. ([See enlarged image](#))

Structure.—The occipital, like the other cranial the *outer* and *inner tables*, between which is the cancellous tissue or diploë; the bone is especially thick at the ridges, protuberances, condyles, and anterior part of the basilar part; in the inferior fossæ it is thin, semitransparent, and destitute of diploë.

14

Ossification (Fig. 131).—The planum occipitale of the squama is developed in membrane, and may remain separate throughout life when it constitutes the *interparietal* bone; the rest of the bone is developed in cartilage. The number of nuclei for the planum occipitale is usually given as four, two appearing near the middle line about the second month, and two some little distance from the middle line about the third month of fetal life. The planum nuchale of the squama is ossified from two centers, which appear about the seventh week of fetal life and soon unite to form a single piece. Union of the upper and lower portions of the squama takes place in the third month of fetal life. An occasional center (Kerckring) appears in the posterior margin of the foramen magnum during the fifth month; this forms a separate ossicle (sometimes double) which unites with the rest of the squama before birth. Each of the lateral parts begins to ossify from a single center during the eighth week of fetal life. The basilar portion is ossified from two centers, one in front of the other; these appear about the sixth week of fetal life and rapidly coalesce. Mall [26](#) states that the planum occipitale is ossified from two centers and the basilar portion from one. About the fourth year the squama and the two lateral portions unite, and about the sixth year the bone consists of a single piece. Between the eighteenth and twenty-fifth years the occipital and sphenoid become united, forming a single bone.

15

Articulations.—The occipital articulates with *six* bones: the two parietals, the two temporals, the sphenoid, and the atlas.

16

Note 25. The columns of blood coming in different directions were supposed to be pressed together at this point (*torcular*, a wine press). [[back](#)]

Note 26. American Journal of Anatomy, 1906, vol. v. [[back](#)]

5a. 2. The Parietal Bone

(Os Parietale)

1

The **parietal bones** form, by their union, the sides and roof of the cranium. Each bone is irregularly quadrilateral in form, and has two surfaces, four borders, and four angles.

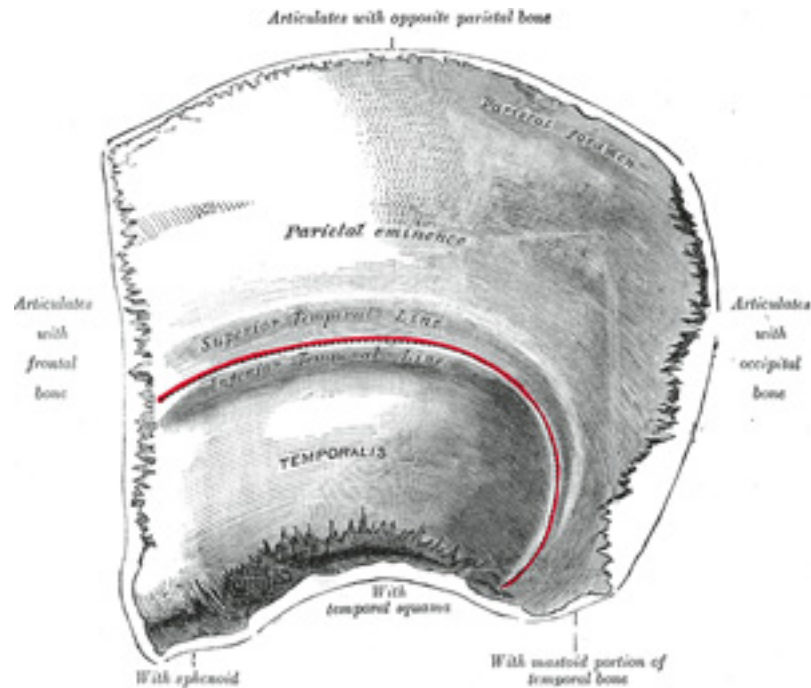


FIG. 132— Left parietal bone. Outer surface. ([See enlarged image](#))

Surfaces.—The **external surface** ([Fig. 132](#)) is convex, smooth, and marked near the center by an eminence, the **parietal eminence** (*tuber parietale*), which indicates the point where ossification commenced. Crossing the middle of the bone in an arched direction are two curved lines, the **superior** and **inferior temporal lines**; the former gives attachment to the temporal fascia, and the latter indicates the upper limit of the muscular origin of the Temporalis. Above these lines the bone is covered by the galea aponeurotica; below them it forms part of the temporal fossa, and affords attachment to the Temporalis muscle. At the back part and close to the upper or sagittal border is the **parietal foramen**, which transmits a vein to the superior sagittal sinus, and sometimes a small branch of the occipital artery; it is not constantly present, and its size varies considerably.

The **internal surface** ([Fig. 133](#)) is concave; it presents depressions corresponding to the cerebral convolutions, and numerous furrows for the ramifications of the middle meningeal vessel; [27](#) the latter run upward and backward from the sphenoidal angle, and from the central and posterior part of the squamous border. Along the upper margin is a shallow groove, which, together with that on the opposite parietal, forms a

2

3

channel, the **sagittal sulcus**, for the superior sagittal sinus; the edges of the sulcus afford attachment to the falx cerebri. Near the groove are several depressions, best marked in the skulls of old persons, for the **arachnoid granulations** (*Pacchionian bodies*). In the groove is the internal opening of the parietal foramen when that aperture exists.

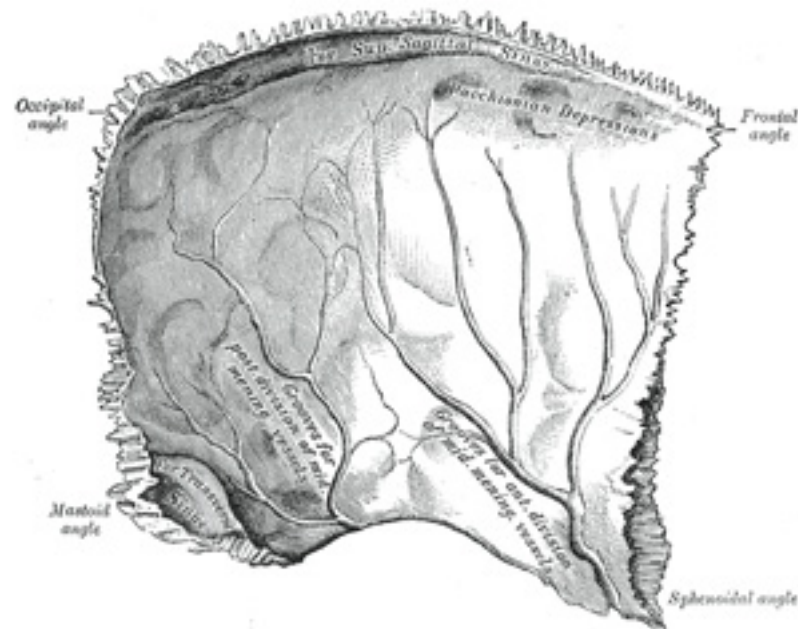


FIG. 133— Left parietal bone. Inner surface. ([See enlarged image](#))

Borders.—The **sagittal border**, the longest and thickest, is dentated and articulates with its fellow of the opposite side, forming the sagittal suture. The **squamous border** is divided into three parts: of these, the anterior is thin and pointed, bevelled at the expense of the outer surface, and overlapped by the tip of the great wing of the sphenoid; the middle portion is arched, bevelled at the expense of the outer surface, and overlapped by the squama of the temporal; the posterior part is thick and serrated for articulation with the mastoid portion of the temporal. The **frontal border** is deeply serrated, and bevelled at the expense of the outer surface above and of the inner below; it articulates with the frontal bone, forming one-half of the **coronal suture**. The **occipital border**, deeply denticulated, articulates with the occipital, forming one-half of the **lambdoidal suture**.

Angles.—The **frontal angle** is practically a right angle, and corresponds with the point of meeting of the sagittal and coronal sutures; this point is named the **bregma**; in the fetal skull and for about a year and a half after birth this region is membranous, and is called the **anterior fontanelle**. The **sphenoidal angle**, thin and acute, is received into the interval between the frontal bone and the great wing of the sphenoid. Its inner surface is marked by a deep groove, sometimes a canal, for the anterior divisions of the middle meningeal artery. The **occipital angle** is rounded and corresponds with the point of meeting of the sagittal and lambdoidal sutures—a point which is termed the **lambda**; in the fetus this part of the skull is membranous, and is called the **posterior fontanelle**. The **mastoid angle** is truncated; it articulates with the occipital bone and with the mastoid portion of the temporal, and presents on its inner surface a broad, shallow groove which lodges part of the transverse sinus. The point of meeting of this angle with the occipital and the mastoid part of the temporal is named the **asterion**. 5

Ossification.—The parietal bone is ossified in membrane from a single center, which appears at the parietal eminence about the eighth week of fetal life. Ossification gradually extends in a radial manner from the center toward the margins of the bone; the angles are consequently the parts last formed, and it is here that the fontanelles exist. Occasionally the parietal bone is divided into two parts, upper and lower, by an antero-posterior suture. 6

Articulations.—The parietal articulates with *five* bones: the opposite parietal, the occipital, frontal, temporal, and sphenoid. 7

Note 27. Journal of Anatomy and Physiology, 1912, vol. xlvi. [[back](#)]

5a. 3. The Frontal Bone

(Os Frontale) 1

The **frontal bone** resembles a cockle-shell in form, and consists of two portions—**avertical** portion, the **squama**, corresponding with the region of the forehead; and **anorbital** or **horizontal** portion, which enters into the formation of the roofs of the orbital and nasal cavities.

Squama (*squama frontalis*).—**Surfaces.**—The **external surface** ([Fig. 134](#)) of this portion is convex and usually exhibits, in the lower part of the middle line, the remains of the **frontal** or **metopic suture**; in infancy this suture divides the bone into two, a condition which may persist throughout life. On either side of this suture, about 3 cm. above the supraorbital margin, is a rounded elevation, the **frontal eminence** (*tuber frontale*). These eminences vary in size in different individuals, are occasionally unsymmetrical, and are especially prominent in young skulls; the surface of the bone above them is smooth, and covered by the galea aponeurotica. Below the frontal eminences, and separated from them by a shallow groove, are two arched elevations, the **superciliary arches**; these are prominent medially, and are joined to one another by a smooth elevation named the **glabella**. They are larger in the male than in the female, and their degree of prominence depends to some extent on the size 2

of the frontal air sinuses; [28](#) prominent ridges are, however, occasionally associated with small air sinuses. Beneath each superciliary arch is a curved and prominent margin, the **supraorbital margin**, which forms the upper boundary of the base of the orbit, and separates the squama from the orbital portion of the bone. The lateral part of this margin is sharp and prominent, affording to the eye, in that situation, considerable protection from injury; the medial part is rounded. At the junction of its medial and intermediate thirds is a notch, sometimes converted into a foramen, the **supraorbital notch or foramen**, which transmits the supraorbital vessels and nerve. A small aperture in the upper part of the notch transmits a vein from the diploë to join the supraorbital vein. The supraorbital margin ends laterally in the **zygomatic process**, which is strong and prominent, and articulates with the zygomatic bone. Running upward and backward from this process is a well-marked line, the **temporal line**, which divides into the **upper and lower temporal lines**, continuous, in the articulated skull, with the corresponding lines on the parietal bone. The area below and behind the temporal line forms the anterior part of the temporal fossa, and gives origin to the Temporalis muscle. Between the supraorbital margins the squama projects downward to a level below that of the zygomatic processes; this portion is known as the **nasal part** and presents a rough, uneven interval, the **nasal notch**, which articulates on either side of the middle line with the nasal bone, and laterally with the frontal process of the maxilla and with the lacrimal. The term **nasion** is applied to the middle of the frontonasal suture. From the center of the notch the **nasal process** projects downward and forward beneath the nasal bones and frontal processes of the maxillæ, and supports the bridge of the nose. The nasal process ends below in a sharp **spine**, and on either side of this is a small grooved surface which enters into the formation of the roof of the corresponding nasal cavity. The spine forms part of the septum of the nose, articulating in front with the crest of the nasal bones and behind with the perpendicular plate of the ethmoid.

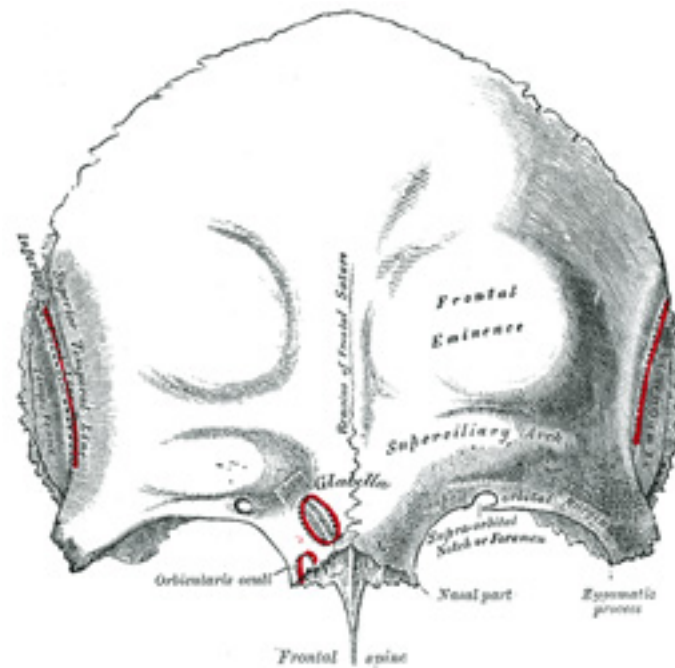


FIG. 134— Frontal bone. Outer surface. ([See enlarged image](#))

The **internal surface** ([Fig. 135](#)) of the squama is concave and presents in the upper part of the middle line a vertical groove, the **sagittal sulcus**, the edges of which unite below to form a ridge, the **frontal crest**; the sulcus lodges the superior sagittal sinus, while its margins and the crest afford attachment to the falx cerebri. The crest ends below in a small notch which is converted into a foramen, the **foramen cecum**, by articulation with the ethmoid. This foramen varies in size in different subjects, and is frequently impervious; when open, it transmits a vein from the nose to the superior sagittal sinus. On either side of the middle line the bone presents depressions for the convolutions of the brain, and numerous small furrows for the anterior branches of the middle meningeal vessels. Several small, irregular fossæ may also be seen on either side of the sagittal sulcus, for the reception of the arachnoid granulations.

3

Orbital or Horizontal Part (*pars orbitalis*).—This portion consists of two thin triangular plates, the **orbital plates**, which form the vaults of the orbits, and are separated from one another by a median gap, the **ethmoidal notch**.

4

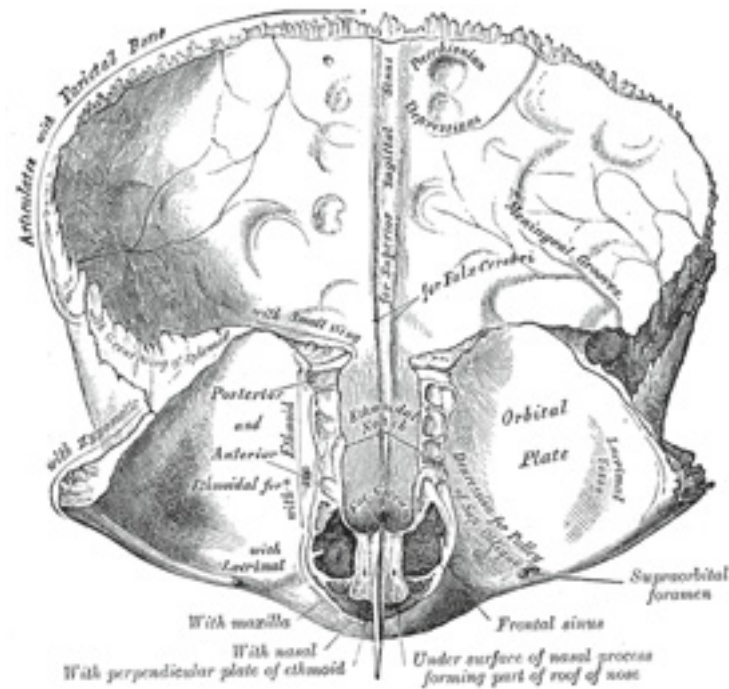


FIG. 135— Frontal bone. Inner surface. ([See enlarged image](#))

Surfaces.—The **inferior surface** ([Fig. 135](#)) of each orbital plate is smooth and concave, and presents, laterally, under cover of the zygomatic process, a shallow depression, the **lacrima fossa**, for the lacrimal gland; near the nasal part is a depression, the **fovea trochlearis**, or occasionally a small **trochlear spine**, for the attachment of the cartilaginous pulley of the Obliquus oculi superior. The **superior surface** is convex, and marked by depressions for the convolutions of the frontal lobes of the brain, and faint grooves for the meningeal branches of the ethmoidal vessels.

The **ethmoidal notch** separates the two orbital plates; it is quadrilateral, and filled, in the articulated skull, by the cribriform plate of the ethmoid. The margins of the notch present several half-cells which, when united with corresponding half-cells on the upper surface of the ethmoid, complete the ethmoidal air cells. Two grooves cross these edges transversely; they are converted into the **anterior** and **posterior ethmoidal canals** by the ethmoid, and open on the medial wall of the orbit. The anterior canal transmits the nasociliary nerve and anterior

5

6

ethmoidal vessels, the posterior, the posterior ethmoidal nerve and vessels. In front of the ethmoidal notch, on either side of the frontal spine, are the openings of the **frontal air sinuses**. These are two irregular cavities, which extend backward, upward, and lateralward for a variable distance between the two tables of the skull; they are separated from one another by a thin bony septum, which often deviates to one or other side, with the result that the sinuses are rarely symmetrical. Absent at birth, they are usually fairly well-developed between the seventh and eighth years, but only reach their full size after puberty. They vary in size in different persons, and are larger in men than in women. ²⁹ They are lined by mucous membrane, and each communicates with the corresponding nasal cavity by means of a passage called the **frontonasal duct**.

Borders.—The **border of the squama** is thick, strongly serrated, bevelled at the expense of the inner table above, where it rests upon the parietal bones, and at the expense of the outer table on either side, where it receives the lateral pressure of those bones; this border is continued below into a triangular, rough surface, which articulates with the great wing of the sphenoid. The **posterior borders of the orbital plates** are thin and serrated, and articulate with the small wings of the sphenoid. 7

Structure.—The squama and the zygomatic processes are very thick, consisting of diploic tissue contained between two compact laminæ; the diploic tissue is absent in the regions occupied by the frontal air sinuses. The orbital portion is thin, translucent, and composed entirely of compact bone; hence the facility with which instruments can penetrate the cranium through this part of the orbit; when the frontal sinuses are exceptionally large they may extend backward for a considerable distance into the orbital portion, which in such cases also consists of only two tables. 8

Ossification (Fig. 136).—The frontal bone is ossified in membrane from *two primary* centers, one for each half, which appear toward the end of the second month of fetal life, one above each supraorbital margin. From each of these centers ossification extends upward to form the corresponding half of the squama, and backward to form the orbital plate. The spine is ossified from a pair of *secondary* centers, on either side of the middle line; similar centers appear in the nasal part and zygomatic processes. At birth the bone consists of two pieces, separated by the frontal suture, which is usually obliterated, except at its lower part, by the eighth year, but occasionally persists throughout life. It is generally maintained that the development of the frontal sinuses begins at the end of the first or beginning of the second year, but Onodi's researches indicate that development begins at birth. The sinuses are of considerable size by the seventh or eighth year, but do not attain their full proportions until after puberty. 9

Articulations.—The frontal articulates with *twelve* bones: the sphenoid, the ethmoid, the two parietals, the two nasals, the two maxillæ, the two lacrimals, and the two zygomatics. 10

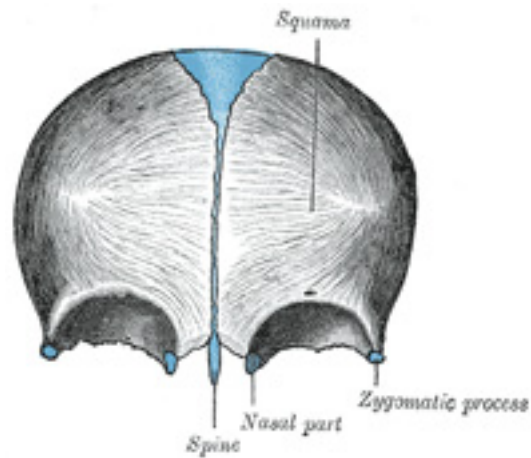


FIG. 136– Frontal bone at birth. ([See enlarged image](#))

Note 28. Some confusion is occasioned to students commencing the study of anatomy by the name “sinus” having been given to two different kinds of space connected with the skull. It may be as well, therefore, to state here that the “sinuses” in the interior of the cranium which produce the grooves on the inner surfaces of the bones are venous channels which convey the blood from the brain, while the “sinuses” external to the cranial cavity (the frontal, sphenoidal, ethmoidal, and maxillary) are hollow spaces in the bones themselves; they communicate with the nasal cavities and contain air. [\[back\]](#)

Note 29. Aldren Turner (The Accessory Sinuses of the Nose, 1901) gives the following measurements for a sinus of average size: height, 1 1/4 inches; breadth, 1 inch; depth from before backward, 1 inch. [\[back\]](#)

5a. 4. The Temporal Bone

(Os Temporale)

1

The **temporal bones** are situated at the sides and base of the skull. Each consists of five parts, viz., the **squama**, the **petrous**, **mastoid**, and **tympanic parts**, and the **styloid process**.

The Squama (*squama temporalis*).—The squama forms the anterior and upper part of the bone, and is scale-like, thin, and translucent.

2

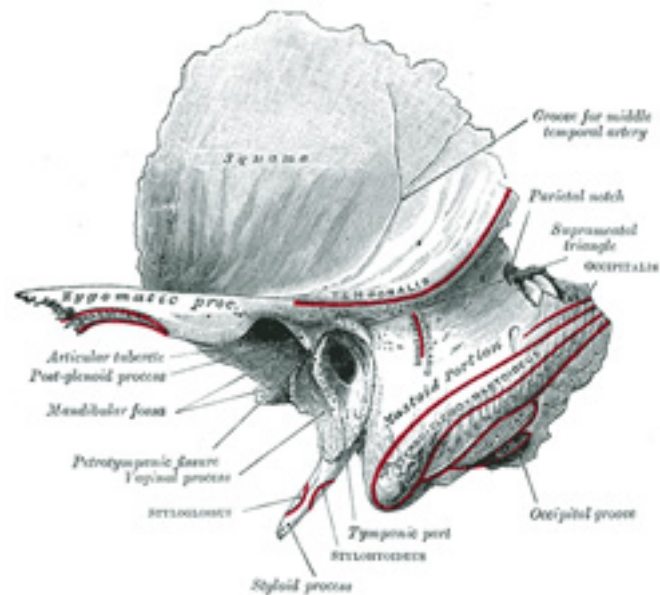


FIG. 137— Left temporal bone. Outer surface. ([See enlarged image](#))

Surfaces.—Its **outer surface** ([Fig. 137](#)) is smooth and convex; it affords attachment to the Temporalis muscle, and forms part of the temporal fossa; on its hinder part is a vertical groove for the middle temporal artery. A curved line, the **temporal line**, or **supramastoid crest**, runs backward and upward across its posterior part; it serves for the attachment of the temporal fascia, and limits the origin of the Temporalis muscle. The boundary between the squama and the mastoid portion of the bone, as indicated by traces of the original suture, lies about 1 cm. below this line. Projecting from the lower part of the squama is a long, arched process, the **zygomatic process**. This process is at first directed lateralward, its two surfaces looking upward and downward; it then appears as if twisted inward upon itself, and runs forward, its surfaces now looking medialward and lateralward. The superior border is long, thin, and sharp, and serves for the attachment of the temporal fascia; the inferior, short, thick, and arched, has attached to it some fibers of the Masseter. The lateral surface is convex and subcutaneous; the medial is concave, and affords attachment to the Masseter. The anterior end is deeply serrated and articulates with the zygomatic bone. The posterior end is connected to the squama by two roots, the **anterior** and **posterior roots**. The posterior root, a prolongation of the upper border, is strongly marked; it runs backward above the external acoustic meatus, and is continuous with the temporal line. The anterior root, continuous with the lower border, is short but broad and strong; it is directed medialward and ends in a rounded eminence, the **articular tubercle** (*eminencia articularis*). This

tubercle forms the front boundary of the mandibular fossa, and in the fresh state is covered with cartilage. In front of the articular tubercle is a small triangular area which assists in forming the infratemporal fossa; this area is separated from the outer surface of the squama by a ridge which is continuous behind with the anterior root of the zygomatic process, and in front, in the articulated skull, with the infratemporal crest on the great wing of the sphenoid. Between the posterior wall of the external acoustic meatus and the posterior root of the zygomatic process is the area called the **suprameatal triangle**(Macewen), or **mastoid fossa**, through which an instrument may be pushed into the tympanic antrum. At the junction of the anterior root with the zygomatic process is a projection for the attachment of the temporomandibular ligament; and behind the anterior root is an oval depression, forming part of the mandibular fossa, for the reception of the condyle of the mandible. The **mandibular fossa** (*glenoid fossa*) is bounded, in front, by the articular tubercle; behind, by the tympanic part of the bone, which separates it from the external acoustic meatus; it is divided into two parts by a narrow slit, the **petrotympanic fissure** (*Glaserian fissure*). The anterior part, formed by the squama, is smooth, covered in the fresh state with cartilage, and articulates with the condyle of the mandible. Behind this part of the fossa is a small conical eminence; this is the representative of a prominent tubercle which, in some mammals, descends behind the condyle of the mandible, and prevents its backward displacement. The posterior part of the mandibular fossa, formed by the tympanic part of the bone, is non-articular, and sometimes lodges a portion of the parotid gland. The petrotympanic fissure leads into the middle ear or tympanic cavity; it lodges the anterior process of the malleus, and transmits the tympanic branch of the internal maxillary artery. The chorda tympani nerve passes through a canal (*canal of Huguier*), separated from the anterior edge of the petrotympanic fissure by a thin scale of bone and situated on the lateral side of the auditory tube, in the retiring angle between the squama and the petrous portion of the temporal.

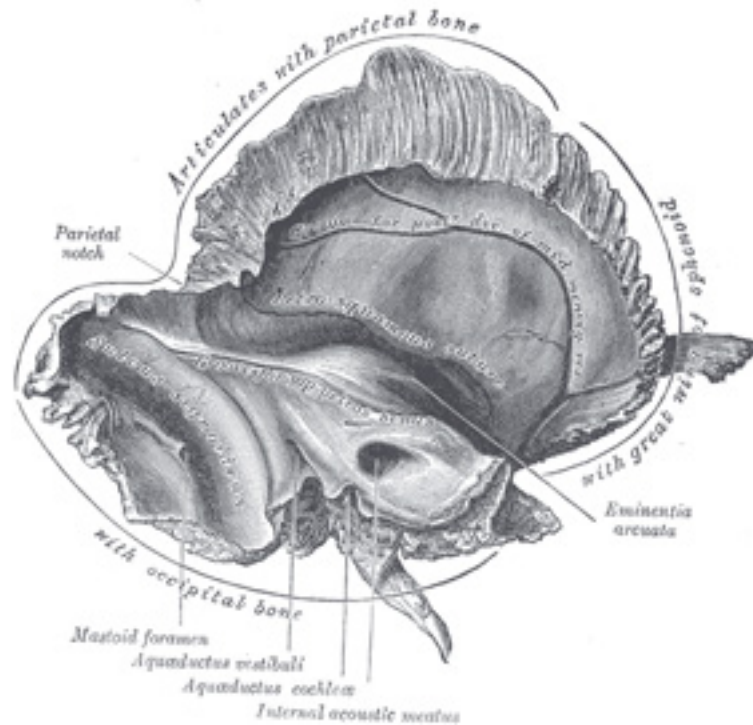


FIG. 138— Left temporal bone. Inner surface. ([See enlarged image](#))

The **internal surface** of the squama ([Fig. 138](#)) is concave; it presents depressions corresponding to the convolutions of the temporal lobe of the brain, and grooves for the branches of the middle meningeal vessels. 4

Borders.—The **superior border** is thin, and bevelled at the expense of the internal table, so as to overlap the squamous border of the parietal bone, forming with it the squamosal suture. Posteriorly, the superior border forms an angle, the **parietal notch**, with the mastoid portion of the bone. The **antero-inferior border** is thick, serrated, and bevelled at the expense of the inner table above and of the outer below, for articulation with the great wing of the sphenoid. 5

Mastoid Portion (*pars mastoidea*).—The mastoid portion forms the posterior part of the bone. 6

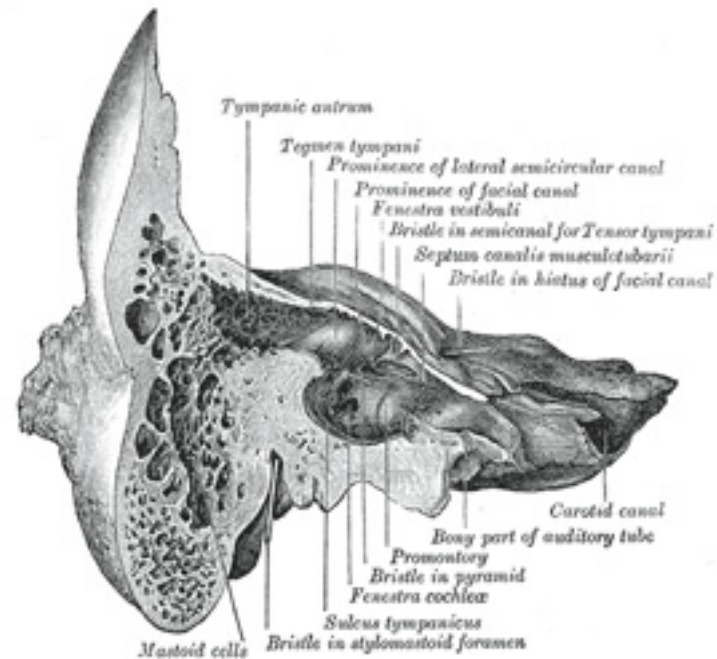


FIG. 139— Coronal section of right temporal bone. ([See enlarged image](#))

Surfaces.—Its **outer surface** ([Fig. 137](#)) is rough, and gives attachment to the Occipitalis and Auricularis posterior. It is perforated by numerous foramina; one of these, of large size, situated near the posterior border, is termed the **mastoid foramen**; it transmits a vein to the transverse sinus and a small branch of the occipital artery to the dura mater. The position and size of this foramen are very variable; it is not always present; sometimes it is situated in the occipital bone, or in the suture between the temporal and the occipital. The mastoid portion is continued below into a conical projection, the **mastoid process**, the size and form of which vary somewhat; it is larger in the male than in the female. This process serves for the attachment of the Sternocleidomastoideus, Splenius capitis, and Longissimus capitis. On the medial side of the process is a deep groove, the **mastoid notch** (*digastric fossa*), for the attachment of the Digastricus; medial to this is a shallow furrow, the **occipital groove**, which lodges the occipital artery.

The **inner surface** of the mastoid portion presents a deep, curved groove, the **sigmoid sulcus**, which lodges part of the transverse sinus; in it

7

8

may be seen the opening of the mastoid foramen. The groove for the transverse sinus is separated from the innermost of the mastoid air cells by a very thin lamina of bone, and even this may be partly deficient.

Borders.—The **superior border** of the mastoid portion is broad and serrated, for articulation with the mastoid angle of the parietal. 9
The **posterior border**, also serrated, articulates with the inferior border of the occipital between the lateral angle and jugular process. Anteriorly the mastoid portion is fused with the descending process of the squama above; below it enters into the formation of the external acoustic meatus and the tympanic cavity.

A section of the mastoid process ([Fig. 139](#)) shows it to be hollowed out into a number of spaces, the **mastoid cells**, which exhibit the greatest possible variety as to their size and number. At the upper and front part of the process they are large and irregular and contain air, but toward the lower part they diminish in size, while those at the apex of the process are frequently quite small and contain marrow; occasionally they are entirely absent, and the mastoid is then solid throughout. In addition to these a large irregular cavity is situated at the upper and front part of the bone. It is called the **tympanic antrum**, and must be distinguished from the mastoid cells, though it communicates with them. Like the mastoid cells it is filled with air and lined by a prolongation of the mucous membrane of the tympanic cavity, with which it communicates. The tympanic antrum is bounded above by a thin plate of bone, the **tegmen tympani**, which separates it from the middle fossa of the base of the skull; below by the mastoid process; laterally by the squama just below the temporal line, and medially by the lateral semicircular canal of the internal ear which projects into its cavity. It opens in front into that portion of the tympanic cavity which is known as the **attic** or **epitympanic recess**. The tympanic antrum is a cavity of some considerable size at the time of birth; the mastoid air cells may be regarded as diverticula from the antrum, and begin to appear at or before birth; by the fifth year they are well-marked, but their development is not completed until toward puberty. 10

Petrous Portion (*pars petrosa [pyramis]*).—The petrous portion or **pyramid** is pyramidal and is wedged in at the base of the skull between the sphenoid and occipital. Directed medialward, forward, and a little upward, it presents for examination a base, an apex, three surfaces, and three angles, and contains, in its interior, the essential parts of the organ of hearing. 11

Base.—The base is fused with the internal surfaces of the squama and mastoid portion. 12

Apex.—The apex, rough and uneven, is received into the angular interval between the posterior border of the great wing of the sphenoid and the basilar part of the occipital; it presents the anterior or internal orifice of the carotid canal, and forms the postero-lateral boundary of the foramen lacerum. 13

Surfaces.—The **anterior surface** forms the posterior part of the middle fossa of the base of the skull, and is continuous with the inner surface of the squamous portion, to which it is united by the **petrosquamous suture**, remains of which are distinct even at a late period of life. It is marked by depressions for the convolutions of the brain, and presents six points for examination: (1) near the center, an **eminence** (*eminentia arcuata*) which indicates the situation of the superior semicircular canal; (2) in front of and a little lateral to this eminence, a depression indicating the position of the tympanic cavity: here the layer of bone which separates the tympanic from the cranial cavity is extremely thin, and is known as the **tegmen tympani**; (3) a shallow groove, sometimes double, leading lateralward and backward to an oblique opening, the **hiatus of the facial** 14

canal, for the passage of the greater superficial petrosal nerve and the petrosal branch of the middle meningeal artery; (4) lateral to the hiatus, a smaller opening, occasionally seen, for the passage of the lesser superficial petrosal nerve; (5) near the apex of the bone, the termination of the carotid canal, the wall of which in this situation is deficient in front; (6) above this canal the shallow **trigeminal impression** for the reception of the semilunar ganglion.

The **posterior surface** (Fig. 138) forms the front part of the posterior fossa of the base of the skull, and is continuous with the inner surface of the mastoid portion. Near the center is a large orifice, the **internal acoustic meatus**, the size of which varies considerably; its margins are smooth and rounded, and it leads into a short canal, about 1 cm. in length, which runs lateralward. It transmits the facial and acoustic nerves and the internal auditory branch of the basilar artery. The lateral end of the canal is closed by a vertical plate, which is divided by a horizontal crest, the **crista falciformis**, into two unequal portions (Fig. 140). Each portion is further subdivided by a vertical ridge into an anterior and a posterior part. In the portion beneath the crista falciformis are three sets of foramina; one group, just below the posterior part of the crest, situated in the **area cribrosa media**, consists of several small openings for the nerves to the sacculæ; below and behind this area is the **foramen singulare**, or opening for the nerve to the posterior semicircular duct; in front of and below the first is the **tractus spiralis foraminosus**, consisting of a number of small spirally arranged openings, which encircle the **canalis centralis cochleæ**; these openings together with this central canal transmit the nerves to the cochlea. The portion above the crista falciformis presents behind, the **area cribrosa superior**, pierced by a series of small openings, for the passage of the nerves to the utricle and the superior and lateral semicircular ducts, and, in front, the **area facialis**, with one large opening, the commencement of the canal for the facial nerve (**aquæductus Fallopii**). Behind the internal acoustic meatus is a small slit almost hidden by a thin plate of bone, leading to a canal, the **aquæductus vestibuli**, which transmits the ductus endolymphaticus together with a small artery and vein. Above and between these two openings is an irregular depression which lodges a process of the dura mater and transmits a small vein; in the infant this depression is represented by a large fossa, the **subarcuate fossa**, which extends backward as a blind tunnel under the superior semicircular canal.

15

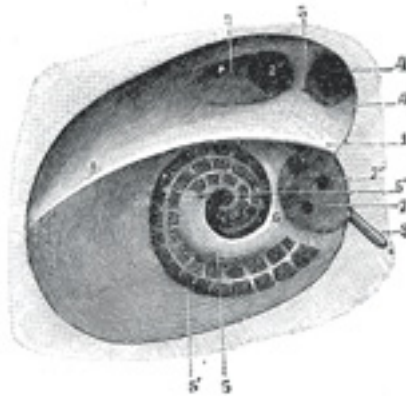


FIG. 140— Diagrammatic view of the fundus of the right internal acoustic meatus. (Testut.) 1. Crista falciformis. 2. Area facialis, with (2') internal

opening of the facial canal. 3. Ridge separating the area facialis from the area cribrosa superior. 4. Area cribrosa superior, with (4') openings for nerve filaments. 5. Anterior inferior cribriform area, with (5') the tractus spiralis foraminosus, and (5'') the canalis centralis of the cochlea. 6. Ridge separating the tractus spiralis foraminosus from the area cribrosa media. 7. Area cribrosa media, with (7') orifices for nerves to sacculæ. 8. Foramen singulare. ([See enlarged image](#))

The **inferior surface** ([Fig. 141](#)) is rough and irregular, and forms part of the exterior of the base of the skull. It presents eleven points for examination: (1) near the apex is a rough surface, quadrilateral in form, which serves partly for the attachment of the Levator veli palatini and the cartilaginous portion of the auditory tube, and partly for connection with the basilar part of the occipital bone through the intervention of some dense fibrous tissue; (2) behind this is the large circular aperture of the **carotid canal**, which ascends at first vertically, and then, making a bend, runs horizontally forward and medialward; it transmits into the cranium the internal carotid artery, and the carotid plexus of nerves; (3) medial to the opening for the carotid canal and close to its posterior border, in front of the jugular fossa, is a triangular depression; at the apex of this is a small opening, the **aquæductus cochleæ**, which lodges a tubular prolongation of the dura mater establishing a communication between the perilymphatic space and the subarachnoid space, and transmits a vein from the cochlea to join the internal jugular; (4) behind these openings is a deep depression, the **jugular fossa**, of variable depth and size in different skulls; it lodges the bulb of the internal jugular vein; (5) in the bony ridge dividing the carotid canal from the jugular fossa is the small **inferior tympanic canaliculus** for the passage of the tympanic branch of the glossopharyngeal nerve; (6) in the lateral part of the jugular fossa is the **mastoid canaliculus** for the entrance of the auricular branch of the vagus nerve; (7) behind the jugular fossa is a quadrilateral area, the **jugular surface**, covered with cartilage in the fresh state, and articulating with the jugular process of the occipital bone; (8) extending backward from the carotid canal is the **vaginal process**, a sheath-like plate of bone, which divides behind into two laminæ; the lateral lamina is continuous with the tympanic part of the bone, the medial with the lateral margin of the jugular surface; (9) between these laminæ is the **styloid process**, a sharp spine, about 2.5 cm. in length; (10) between the styloid and mastoid processes is the **stylomastoid foramen**; it is the termination of the facial canal, and transmits the facial nerve and stylomastoid artery; (11) situated between the tympanic portion and the mastoid process is the tympanomastoid fissure, for the exit of the auricular branch of the vagus nerve.

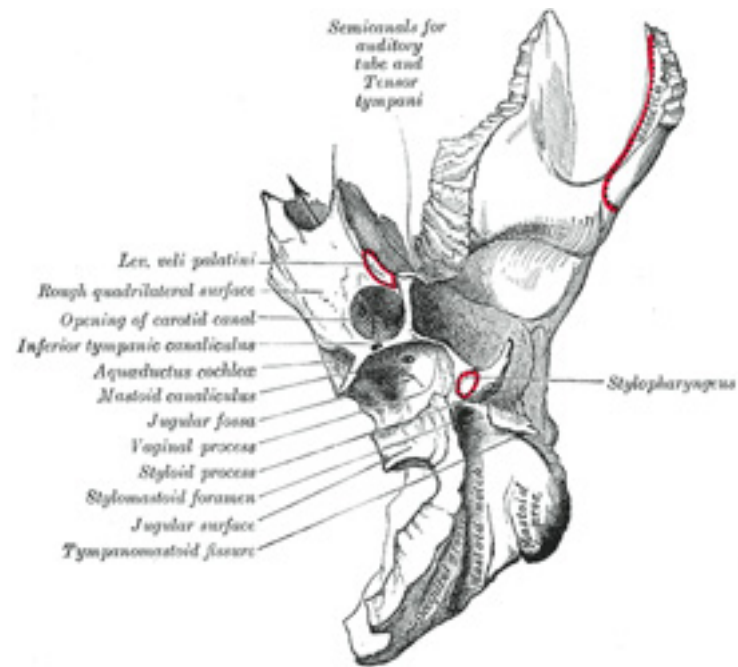


FIG. 141— Left temporal bone. Inferior surface. ([See enlarged image](#))

Angles.—The **superior angle**, the longest, is grooved for the superior petrosal sinus, and gives attachment to the tentorium cerebelli; at its medial extremity is a notch, in which the trigeminal nerve lies. The **posterior angle** is intermediate in length between the superior and the anterior. Its medial half is marked by a sulcus, which forms, with a corresponding sulcus on the occipital bone, the channel for the inferior petrosal sinus. Its lateral half presents an excavation—the **jugular fossa**—which, with the jugular notch on the occipital, forms the **jugular foramen**; an eminence occasionally projects from the center of the fossa, and divides the foramen into two. The **anterior angle** is divided into two parts—a lateral joined to the squama by a suture (*petrosquamous*), the remains of which are more or less distinct; a medial, free, which articulates with the spinous process of the sphenoid.

17

At the angle of junction of the petrous part and the squama are two canals, one above the other, and separated by a thin plate of bone, the **septum canalis musculotubarii**(*processus cochleariformis*); both canals lead into the tympanic cavity. The upper one (*semicanalis m. tensoris tympani*) transmits the Tensor tympani, the lower one (*semicanalis tubæ auditivæ*) forms the bony part of the auditory tube.

18

The tympanic cavity, auditory ossicles, and internal ear, are described with the organ of hearing. 19

Tympanic Part (*pars tympanica*).—The tympanic part is a curved plate of bone lying below the squama and in front of the mastoid process. 20

Surfaces.—Its **postero-superior surface** is concave, and forms the anterior wall, the floor, and part of the posterior wall of the bony external acoustic meatus. Medially, it presents a narrow furrow, the **tympanic sulcus**, for the attachment of the tympanic membrane. Its **antero-inferior surface** is quadrilateral and slightly concave; it constitutes the posterior boundary of the mandibular fossa, and is in contact with the retromandibular part of the parotid gland. 21

Borders.—Its **lateral border** is free and rough, and gives attachment to the cartilaginous part of the external acoustic meatus. Internally, the tympanic part is fused with the petrous portion, and appears in the retreating angle between it and the squama, where it lies below and lateral to the orifice of the auditory tube. Posteriorly, it blends with the squama and mastoid part, and forms the anterior boundary of the tympanomastoid fissure. Its **upper border** fuses laterally with the back of the postglenoid process, while medially it bounds the petrotympanic fissure. The medial part of the **lower border** is thin and sharp; its lateral part splits to enclose the root of the styloid process, and is therefore named the **vaginal process**. The central portion of the tympanic part is thin, and in a considerable percentage of skulls is perforated by a hole, the **foramen of Huschke**. 22

The **external acoustic meatus** is nearly 2 cm. long and is directed inward and slightly forward: at the same time it forms a slight curve, so that the floor of the canal is convex upward. In sagittal section it presents an oval or elliptical shape with the long axis directed downward and slightly backward. Its anterior wall and floor and the lower part of its posterior wall are formed by the tympanic part; the roof and upper part of the posterior wall by the squama. Its inner end is closed, in the recent state, by the tympanic membrane; the upper limit of its outer orifice is formed by the posterior root of the zygomatic process, immediately below which there is sometimes seen a small spine, the **suprameatal spine**, situated at the upper and posterior part of the orifice. 23

Styloid Process (*processus styloideus*).—The styloid process is slender, pointed, and of varying length; it projects downward and forward, from the under surface of the temporal bone. Its proximal part (*tympanohyal*) is ensheathed by the vaginal process of the tympanic portion, while its distal part (*stylohyal*) gives attachment to the stylohyoid and stylomandibular ligaments, and to the Styloglossus, Stylohyoideus, and Stylopharyngeus muscles. The stylohyoid ligament extends from the apex of the process to the lesser cornu of the hyoid bone, and in some instances is partially, in others completely, ossified. 24

Structure.—The structure of the squama is like that of the other cranial bones: the mastoid portion is spongy, and the petrous portion dense and hard. 25

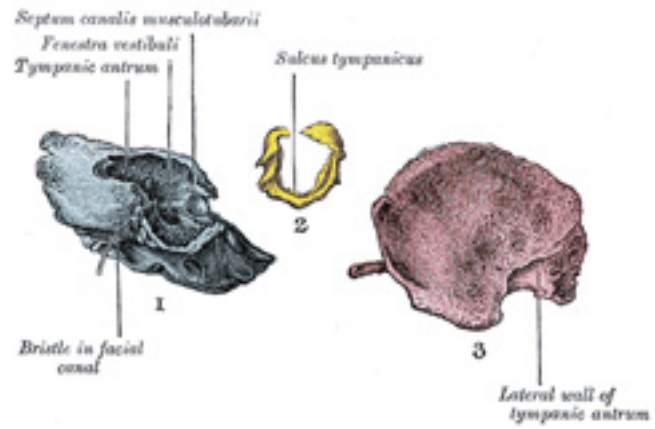


FIG. 142— The three principal parts of the temporal bone at birth. 1. Outer surface of petromastoid part. 2. Outer surface of tympanic ring. 3. Inner surface of squama. ([See enlarged image](#))

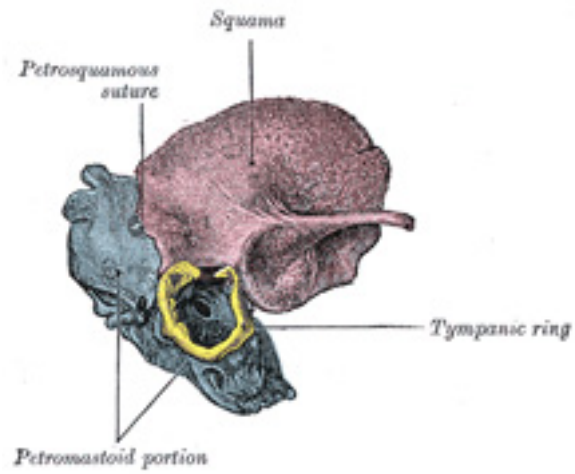


FIG. 143— Temporal bone at birth. Outer aspect. ([See enlarged image](#))

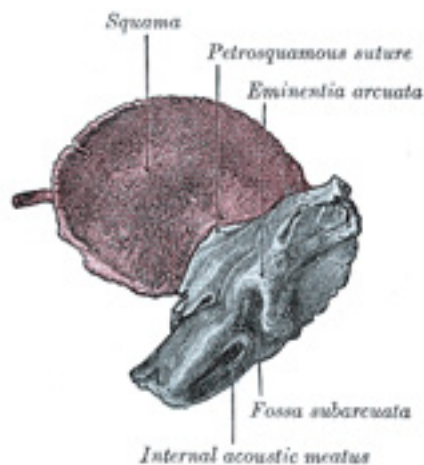


FIG. 144— Temporal bone at birth. Inner aspect. ([See enlarged image](#))

Ossification.—The temporal bone is ossified from *eight* centers, exclusive of those for the internal ear and the tympanic ossicles, viz., one for the squama including the zygomatic process, one for the tympanic part, four for the petrous and mastoid parts, and two for the styloid process. Just before the close of fetal life ([Fig. 142](#)) the temporal bone consists of three principal parts: 1. The *squama* is ossified in membrane from a single nucleus, which appears near the root of the zygomatic process about the second month. 2. The *petromastoid* part is developed from four centers, which make their appearance in the cartilaginous ear capsule about the fifth or sixth month. One (*proötic*) appears in the neighborhood of the eminentia arcuata, spreads in front and above the internal acoustic meatus and extends to the apex of the bone; it forms part of the cochlea, vestibule, superior semicircular canal, and medial wall of the tympanic cavity. A second (*opisthotic*) appears at the promontory on the medial wall of the tympanic cavity and surrounds the fenestra cochleæ; it forms the floor of the tympanic cavity and vestibule, surrounds the carotid canal, invests the lateral and lower part of the cochlea, and spreads medially below the internal acoustic meatus. A third (*pterotic*) roofs in the tympanic cavity and antrum; while the fourth (*epiotic*) appears near the posterior semicircular canal and extends to form the mastoid process (Vrolik). 3. The *tympanic ring* is an incomplete circle, in the concavity of which is a groove, the tympanic sulcus, for the attachment of the circumference of the tympanic membrane. This ring expands to form the tympanic part, and is ossified in membrane from a single center which appears about the third month. The *styloid process* is developed from the proximal part of the cartilage of the second branchial or hyoid arch by

two centers: one for the proximal part, the *tympanohyal*, appears before birth; the other, comprising the rest of the process, is named the *stylohyal*, and does not appear until after birth. The tympanic ring unites with the squama shortly before birth; the petromastoid part and squama join during the first year, and the tympanohyal portion of the styloid process about the same time (Figs. 143, 144). The stylohyal does not unite with the rest of the bone until after puberty, and in some skulls never at all.

The chief subsequent changes in the temporal bone apart from increase in size are: (1) The tympanic ring extends outward and backward to form the tympanic part. This extension does not, however, take place at an equal rate all around the circumference of the ring, but occurs most rapidly on its anterior and posterior portions, and these outgrowths meet and blend, and thus, for a time, there exists in the floor of the meatus a foramen, the *foramen of Huschke*; this foramen is usually closed about the fifth year, but may persist throughout life. (2) The mandibular fossa is at first extremely shallow, and looks lateralward as well as downward; it becomes deeper and is ultimately directed downward. Its change in direction is accounted for as follows. The part of the squama which forms the fossa lies at first below the level of the zygomatic process. As, however, the base of the skull increases in width, this lower part of the squama is directed horizontally inward to contribute to the middle fossa of the skull, and its surfaces therefore come to look upward and downward; the attached portion of the zygomatic process also becomes everted, and projects like a shelf at right angles to the squama. (3) The mastoid portion is at first quite flat, and the stylomastoid foramen and rudimentary styloid process lie immediately behind the tympanic ring. With the development of the air cells the outer part of the mastoid portion grows downward and forward to form the mastoid process, and the styloid process and stylomastoid foramen now come to lie on the under surface. The descent of the foramen is necessarily accompanied by a corresponding lengthening of the facial canal. (4) The downward and forward growth of the mastoid process also pushes forward the tympanic part, so that the portion of it which formed the original floor of the meatus and contained the foramen of Huschke is ultimately found in the anterior wall. (5) The fossa subarcuata becomes filled up and almost obliterated.

Articulations.—The temporal articulates with *five* bones: occipital, parietal, sphenoid, mandible and zygomatic.

5a. 5. The Sphenoid Bone

(Os Sphenoidale)

The **sphenoid bone** is situated at the base of the skull in front of the temporals and basilar part of the occipital. It somewhat resembles a bat with its wings extended, and is divided into a median portion or body, two great and two small wings extending outward from the sides of the body, and two pterygoid processes which project from it below.

Body (*corpus sphenoidale*).—The body, more or less cubical in shape, is hollowed out in its interior to form two large cavities, the **sphenoidal air sinuses**, which are separated from each other by a septum.

Surfaces.—The **superior surface** of the body (Fig. 145) presents in front a prominent spine, the **ethmoidal spine**, for articulation with the

cribriform plate of the ethmoid; behind this is a smooth surface slightly raised in the middle line, and grooved on either side for the olfactory lobes of the brain. This surface is bounded behind by a ridge, which forms the anterior border of a narrow, transverse groove, the **chiasmatic groove** (*optic groove*), above and behind which lies the optic chiasma; the groove ends on either side in the **optic foramen**, which transmits the optic nerve and ophthalmic artery into the orbital cavity. Behind the chiasmatic groove is an elevation, the **tuberculum sellæ**; and still more posteriorly, a deep depression, the **sella turcica**, the deepest part of which lodges the hypophysis cerebri and is known as the **fossa hypophyseos**. The anterior boundary of the sella turcica is completed by two small eminences, one on either side, called the **middle clinoid processes**, while the posterior boundary is formed by a square-shaped plate of bone, the **dorsum sellæ**, ending at its superior angles in two tubercles, the **posterior clinoid processes**, the size and form of which vary considerably in different individuals. The posterior clinoid processes deepen the sella turcica, and give attachment to the tentorium cerebelli. On either side of the dorsum sellæ is a notch for the passage of the abducent nerve, and below the notch a sharp process, the **petrosal process**, which articulates with the apex of the petrous portion of the temporal bone, and forms the medial boundary of the foramen lacerum. Behind the dorsum sellæ is a shallow depression, the **clivus**, which slopes obliquely backward, and is continuous with the groove on the basilar portion of the occipital bone; it supports the upper part of the pons.

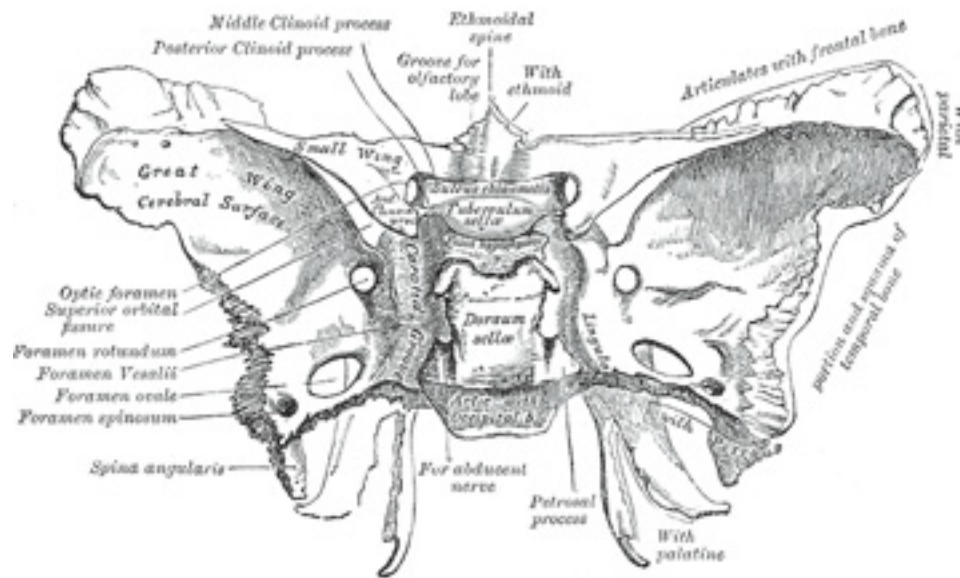


FIG. 145– Sphenoid bone. Upper surface. ([See enlarged image](#))

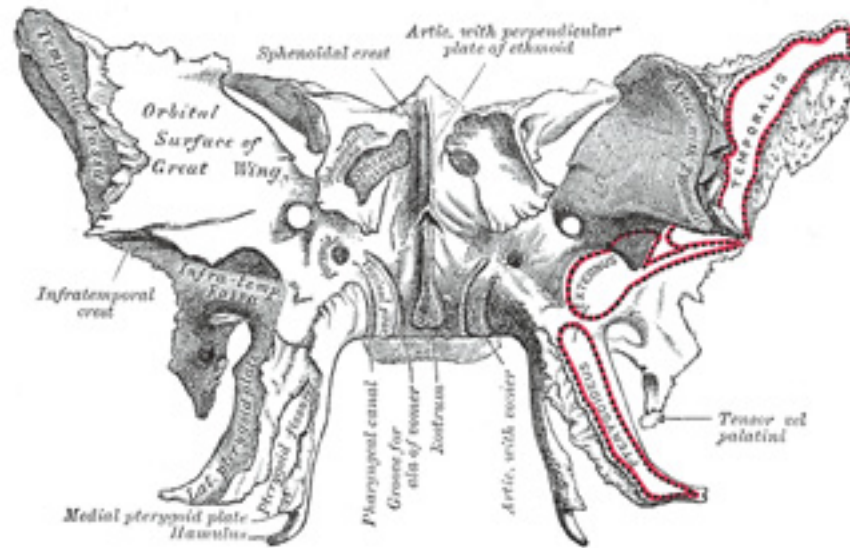


FIG. 146– Sphenoid bone. Anterior and inferior surfaces. ([See enlarged image](#))

The **lateral surfaces** of the body are united with the great wings and the medial pterygoid plates. Above the attachment of each great wing is a broad groove, curved something like the italic letter *f*; it lodges the internal carotid artery and the cavernous sinus, and is named the **carotid groove**. Along the posterior part of the lateral margin of this groove, in the angle between the body and great wing, is a ridge of bone, called the **lingula**. 4

The **posterior surface**, quadrilateral in form ([Fig. 147](#)), is joined, during infancy and adolescence, to the basilar part of the occipital bone by a plate of cartilage. Between the eighteenth and twenty-fifth years this becomes ossified, ossification commencing above and extending downward. 5

The **anterior surface** of the body ([Fig. 146](#)) presents, in the middle line, a vertical crest, the **sphenoidal crest**, which articulates with the perpendicular plate of the ethmoid, and forms part of the septum of the nose. On either side of the crest is an irregular opening leading into the corresponding **sphenoidal air sinus**. These sinuses are two large, irregular cavities hollowed out of the interior of the body of the bone, and separated from one another by a bony septum, which is commonly bent to one or the other side. They vary considerably in form and size, [30](#) are seldom symmetrical, and are often partially subdivided by irregular bony laminæ. Occasionally, they extend into the basilar part of the occipital nearly as far as the foramen magnum. They begin to be developed before birth, and are of a considerable size by the age of six. They are partially closed, in front and below, by two thin, curved plates of bone, the **sphenoidal conchæ** (see page 152), leaving in the articulated skull a round 6

opening at the upper part of each sinus by which it communicates with the upper and back part of the nasal cavity and occasionally with the posterior ethmoidal air cells. The lateral margin of the anterior surface is serrated, and articulates with the lamina papyracea of the ethmoid, completing the posterior ethmoidal cells; the lower margin articulates with the orbital process of the palatine bone, and the upper with the orbital plate of the frontal bone.

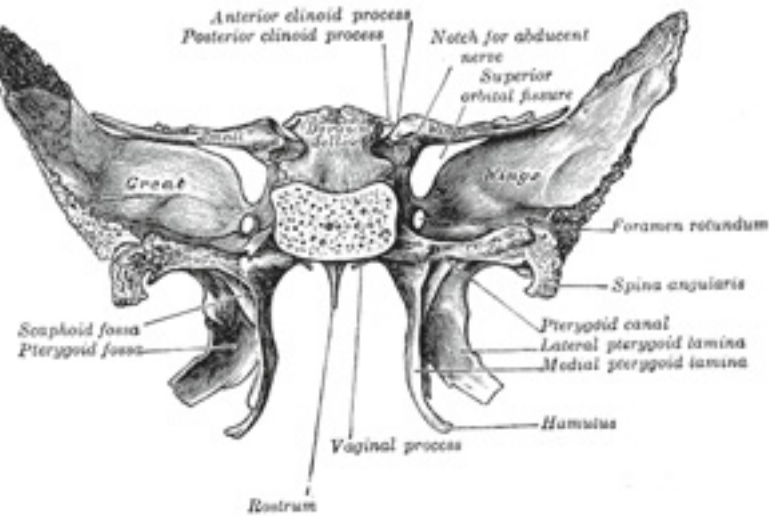


FIG. 147— Sphenoid bone. Upper and posterior surfaces. ([See enlarged image](#))

The **inferior surface** presents, in the middle line, a triangular spine, the **sphenoidal rostrum**, which is continuous with the sphenoidal crest on the anterior surface, and is received in a deep fissure between the alæ of the vomer. On either side of the rostrum is a projecting lamina, the **vaginal process**, directed medialward from the base of the medial pterygoid plate, with which it will be described. 7

The Great Wings (*alæ magnæ*).—The great wings, or **ali-sphenoids**, are two strong processes of bone, which arise from the sides of the body, and are curved upward, lateralward, and backward; the posterior part of each projects as a triangular process which fits into the angle between the squama and the petrous portion of the temporal and presents at its apex a downwardly directed process, the **spina angularis** (*sphenoidal spine*). 8

Surfaces.—The **superior** or **cerebral surface** of each great wing ([Fig. 145](#)) forms part of the middle fossa of the skull; it is deeply concave, and 9

presents depressions for the convolutions of the temporal lobe of the brain. At its anterior and medial part is a circular aperture, the **foramen rotundum**, for the transmission of the maxillary nerve. Behind and lateral to this is the **foramen ovale**, for the transmission of the mandibular nerve, the accessory meningeal artery, and sometimes the lesser superficial petrosal nerve. ³¹ Medial to the foramen ovale, a small aperture, the **foramen Vesalii**, may occasionally be seen opposite the root of the pterygoid process; it opens below near the scaphoid fossa, and transmits a small vein from the cavernous sinus. Lastly, in the posterior angle, near to and in front of the spine, is a short canal, sometimes double, the **foramen spinosum**, which transmits the middle meningeal vessels and a recurrent branch from the mandibular nerve.

The **lateral surface** (Fig. 146) is convex, and divided by a transverse ridge, the **infratemporal crest**, into two portions. The superior or temporal portion, convex from above downward, concave from before backward, forms a part of the temporal fossa, and gives attachment to the Temporalis; the inferior or infratemporal, smaller in size and concave, enters into the formation of the infratemporal fossa, and, together with the infratemporal crest, affords attachment to the Pterygoideus externus. It is pierced by the foramen ovale and foramen spinosum, and at its posterior part is the spina angularis, which is frequently grooved on its medial surface for the chorda tympani nerve. To the spina angularis are attached the sphenomandibular ligament and the Tensor veli palatini. Medial to the anterior extremity of the infratemporal crest is a triangular process which serves to increase the attachment of the Pterygoideus externus; extending downward and medialward from this process on to the front part of the lateral pterygoid plate is a ridge which forms the anterior limit of the infratemporal surface, and, in the articulated skull, the posterior boundary of the pterygomaxillary fissure. 10

The **orbital surface** of the great wing (Fig. 146), smooth, and quadrilateral in shape, is directed forward and medialward and forms the posterior part of the lateral wall of the orbit. Its upper serrated edge articulates with the orbital plate of the frontal. Its inferior rounded border forms the postero-lateral boundary of the inferior orbital fissure. Its medial sharp margin forms the lower boundary of the superior orbital fissure and has projecting from about its center a little tubercle which gives attachment to the inferior head of the Rectus lateralis oculi; at the upper part of this margin is a notch for the transmission of a recurrent branch of the lacrimal artery. Its lateral margin is serrated and articulates with the zygomatic bone. Below the medial end of the superior orbital fissure is a grooved surface, which forms the posterior wall of the pterygopalatine fossa, and is pierced by the foramen rotundum. 11

Margin (Fig. 145).—Commencing from behind, that portion of the circumference of the great wing which extends from the body to the spine is irregular. Its medial half forms the anterior boundary of the foramen lacerum, and presents the posterior aperture of the pterygoid canal for the passage of the corresponding nerve and artery. Its lateral half articulates, by means of a synchondrosis, with the petrous portion of the temporal, and between the two bones on the under surface of the skull, is a furrow, the **sulcus tubæ**, for the lodgement of the cartilaginous part of the auditory tube. In front of the spine the circumference presents a concave, serrated edge, bevelled at the expense of the inner table below, and of the outer table above, for articulation with the temporal squama. At the tip of the great wing is a triangular portion, bevelled at the expense of the internal surface, for articulation with the sphenoidal angle of the parietal bone; this region is named the **pterion**. Medial to this is a triangular, serrated surface, for articulation with the frontal bone; this surface is continuous medially with the sharp edge, which forms the lower boundary of the superior orbital fissure, and laterally with the serrated margin for articulation with the zygomatic bone. 12

The Small Wings (*alæ parvæ*).—The small wings or **orbito-sphenoids** are two thin triangular plates, which arise from the upper and anterior parts of the body, and, projecting lateralward, end in sharp points (Fig. 145). 13

Surfaces.—The **superior surface** of each is flat, and supports part of the frontal lobe of the brain. The **inferior surface** forms the back part of the roof of the orbit, and the upper boundary of the **superior orbital fissure**. This fissure is of a triangular form, and leads from the cavity of the cranium into that of the orbit: it is bounded *medially* by the body; *above*, by the small wing; *below*, by the medial margin of the orbital surface of the great wing; and is completed *laterally* by the frontal bone. It transmits the oculomotor, trochlear, and abducent nerves, the three branches of the ophthalmic division of the trigeminal nerve, some filaments from the cavernous plexus of the sympathetic, the orbital branch of the middle meningeal artery, a recurrent branch from the lacrimal artery to the dura mater, and the ophthalmic vein. 14

Borders.—The **anterior border** is serrated for articulation with the frontal bone. The **posterior border**, smooth and rounded, is received into the lateral fissure of the brain; the medial end of this border forms the **anterior clinoid process**, which gives attachment to the tentorium cerebelli; it is sometimes joined to the middle clinoid process by a spicule of bone, and when this occurs the termination of the groove for the internal carotid artery is converted into a foramen (*carotico-clinoid*). The small wing is connected to the body by two roots, the upper thin and flat, the lower thick and triangular; between the two roots is the **optic foramen**, for the transmission of the optic nerve and ophthalmic artery. 15

Pterygoid Processes (*processus pterygoidei*).—The pterygoid processes, one on either side, descend perpendicularly from the regions where the body and great wings unite. Each process consists of a medial and a lateral plate, the upper parts of which are fused anteriorly; a vertical sulcus, the **pterygopalatine groove**, descends on the front of the line of fusion. The plates are separated below by an angular cleft, the **pterygoid fissure**, the margins of which are rough for articulation with the pyramidal process of the palatine bone. The two plates diverge behind and enclose between them a V-shaped fossa, the **pterygoid fossa**, which contains the Pterygoideus internus and Tensor veli palatini. Above this fossa is a small, oval, shallow depression, the **scaphoid fossa**, which gives origin to the Tensor veli palatini. The anterior surface of the pterygoid process is broad and triangular near its root, where it forms the posterior wall of the pterygopalatine fossa and presents the anterior orifice of the pterygoid canal. 16

Lateral Pterygoid Plate.—The **lateral pterygoid plate** is broad, thin, and everted; its **lateral surface** forms part of the medial wall of the infratemporal fossa, and gives attachment to the Pterygoideus externus; its **medial surface** forms part of the pterygoid fossa, and gives attachment to the Pterygoideus internus. 17

Medial Pterygoid Plate.—The medial pterygoid plate is narrower and longer than the lateral; it curves lateralward at its lower extremity into a hook-like process, the **pterygoid hamulus**, around which the tendon of the Tensor veli palatini glides. The **lateral surface** of this plate forms part of the pterygoid fossa, the **medial surface** constitutes the lateral boundary of the choana or posterior aperture of the corresponding nasal cavity. Superiorly the medial plate is prolonged on to the under surface of the body as a thin lamina, named the **vaginal process**, which articulates in front with the sphenoidal process of the palatine and behind this with the ala of the vomer. The angular prominence between the posterior margin of the vaginal process and the medial border of the scaphoid fossa is named the **pterygoid tubercle**, and immediately above this is the posterior opening of the pterygoid canal. On the under surface of the vaginal process is a furrow, which is converted into a canal by the sphenoidal process of the palatine bone, for the transmission of the pharyngeal branch of the internal maxillary artery and the pharyngeal nerve from the sphenopalatine ganglion. The pharyngeal aponeurosis is attached to the entire length of the posterior edge of the medial plate, and the 18

Constrictor pharyngis superior takes origin from its lower third. Projecting backward from near the middle of the posterior edge of this plate is an angular process, the **processus tubarius**, which supports the pharyngeal end of the auditory tube. The anterior margin of the plate articulates with the posterior border of the vertical part of the palatine bone.

The Sphenoidal Conchæ (*conchæ sphenoidales; sphenoidal turbinated processes*).—The sphenoidal conchæ are two thin, curved plates, situated at the anterior and lower part of the body of the sphenoid. An aperture of variable size exists in the anterior wall of each, and through this the sphenoidal sinus opens into the nasal cavity. Each is irregular in form, and tapers to a point behind, being broader and thinner in front. Its upper surface is concave, and looks toward the cavity of the sinus; its under surface is convex, and forms part of the roof of the corresponding nasal cavity. Each bone articulates in front with the ethmoid, laterally with the palatine; its pointed posterior extremity is placed above the vomer, and is received between the root of the pterygoid process laterally and the rostrum of the sphenoid medially. A small portion of the sphenoidal concha sometimes enters into the formation of the medial wall of the orbit, between the lamina papyracea of the ethmoid in front, the orbital plate of the palatine below, and the frontal bone above.

19

Ossification.—Until the seventh or eighth month of fetal life the body of the sphenoid consists of two parts, viz., one in front of the tuberculum sellæ, the *presphenoid*, with which the small wings are continuous; the other, comprising the sella turcica and dorsum sellæ, the *postsphenoid*, with which are associated the great wings, and pterygoid processes. The greater part of the bone is ossified in cartilage. There are fourteen centers in all, *six* for the presphenoid and *eight* for the postsphenoid.

20

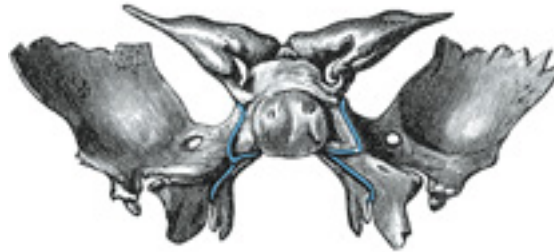


FIG. 148— Sphenoid bone at birth. Posterior aspect. ([See enlarged image](#))

Presphenoid.—About the ninth week of fetal life an ossific center appears for each of the small wings (orbitosphenoids) just lateral to the optic foramen; shortly afterward two nuclei appear in the presphenoid part of the body. The sphenoidal conchæ are each developed from a center which makes its appearance about the fifth month; [32](#) at birth they consist of small triangular laminae, and it is not until the third year that they become hollowed out and coneshaped; about the fourth year they fuse with the labyrinths of the ethmoid, and between the ninth and twelfth years they unite with the sphenoid.

21

Postspenoid.—The first ossific nuclei are those for the great wings (ali-sphenoids) [33](#). One makes its appearance in each wing between the foramen rotundum and foramen ovale about the eighth week. The orbital plate and that part of the sphenoid which is found in the temporal fossa, as well as the lateral pterygoid plate, are ossified in membrane (Fawcett) [34](#). Soon after, the centers for the postspenoid part of the body appear, one on either side of the sella turcica, and become blended together about the middle of fetal life. Each medial pterygoid plate (with the exception of its hamulus) is ossified in membrane, and its center probably appears about the ninth or tenth week; the hamulus becomes chondrified during the third month, and almost at once undergoes ossification (Fawcett). [35](#) The medial joins the lateral pterygoid plate about the sixth month. About the fourth month a center appears for each lingula and speedily joins the rest of the bone. 22

The presphenoid is united to the postspenoid about the eighth month, and at birth the bone is in three pieces ([Fig. 148](#)): a central, consisting of the body and small wings, and two lateral, each comprising a great wing and pterygoid process. In the first year after birth the great wings and body unite, and the small wings extend inward above the anterior part of the body, and, meeting with each other in the middle line, form an elevated smooth surface, termed the *jugum sphenoidale*. By the twenty-fifth year the sphenoid and occipital are completely fused. Between the pre- and postspenoid there are occasionally seen the remains of a canal, the *canalis cranio-pharyngeus*, through which, in early fetal life, the hypophyseal diverticulum of the buccal ectoderm is transmitted. 23

The sphenoidal sinuses are present as minute cavities at the time of birth (Onodi), but do not attain their full size until after puberty. 24

Intrinsic Ligaments of the Sphenoid.—The more important of these are: the *pterygospinous*, stretching between the spina angularis and the lateral pterygoid plate (*seecervical fascia*); the *interclinoid*, a fibrous process joining the anterior to the posterior clinoid process; and the *caroticoclinoid*, connecting the anterior to the middle clinoid process. These ligaments occasionally ossify. 25

Articulations.—The sphenoid articulates with *twelve* bones: four single, the vomer, ethmoid, frontal, and occipital; and four paired, the parietal, temporal, zygomatic, and palatine. [36](#) 26

Note 30. Aldren Turner (*op. cit.*) gives the following as their average measurements: vertical height, 7/8 inch; antero-posterior depth, 7/8 inch; transverse breadth, 3/4 inch. [\[back\]](#)

Note 31. The lesser superficial petrosal nerve sometimes passes through a special canal (*canaliculus innominatus* of Arnold) situated medial to the foramen spinosum. [\[back\]](#)

Note 32. According to Cleland, each sphenoidal concha is ossified from four centers. [\[back\]](#)

Note 33. Mall, *Am. Jour. Anat.*, 1906, states that the pterygoid center appears first in an embryo fifty-seven days old. [\[back\]](#)

Note 34. *Journal of Anatomy and Physiology*, 1910, vol. xlv. [\[back\]](#)

Note 35. *Anatomischer Anzeiger*, March, 1905. [\[back\]](#)

Note 36. It also sometimes articulates with the tuberosity of the maxilla (see page 159). [\[back\]](#)

5a. 6. Ethmoid bone

(Os Ethmoidale)

1

The **ethmoid bone** is exceedingly light and spongy, and cubical in shape; it is situated at the anterior part of the base of the cranium, between the two orbits, at the roof of the nose, and contributes to each of these cavities. It consists of four parts: a **horizontal or cribriform plate**, forming part of the base of the cranium; a **perpendicular plate**, constituting part of the nasal septum; and two **lateral masses** or labyrinths.

Cribriform Plate (*lamina cribrosa; horizontal lamina*).—The cribriform plate ([Fig. 149](#)) is received into the ethmoidal notch of the frontal bone and roofs in the nasal cavities. Projecting upward from the middle line of this plate is a thick, smooth, triangular process, the **crista galli**, so called from its resemblance to a cock's comb. The long thin posterior border of the crista galli serves for the attachment of the falx cerebri. Its anterior border, short and thick, articulates with the frontal bone, and presents two small projecting **alæ**, which are received into corresponding depressions in the frontal bone and complete the foramen cecum. Its sides are smooth, and sometimes bulging from the presence of a small air sinus in the interior. On either side of the crista galli, the cribriform plate is narrow and deeply grooved; it supports the olfactory bulb and is perforated by foramina for the passage of the olfactory nerves. The foramina in the middle of the groove are small and transmit the nerves to the roof of the nasal cavity; those at the medial and lateral parts of the groove are larger—the former transmit the nerves to the upper part of the nasal septum, the latter those to the superior nasal concha. At the front part of the cribriform plate, on either side of the crista galli, is a small fissure which is occupied by a process of dura mater. Lateral to this fissure is a notch or foramen which transmits the nasociliary nerve; from this notch a groove extends backward to the anterior ethmoidal foramen.

2

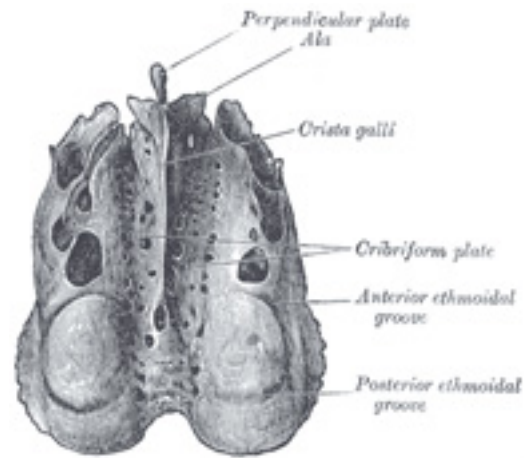


FIG. 149– Ethmoid bone from above. ([See enlarged image](#))

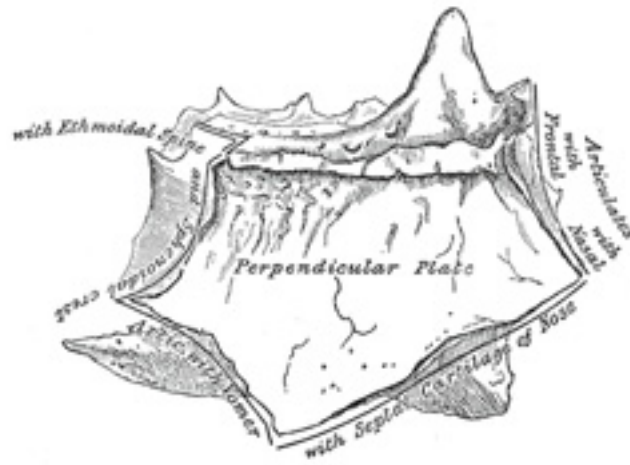


FIG. 150– Perpendicular plate of ethmoid. Shown by removing the right labyrinth. ([See enlarged image](#))

Perpendicular Plate (*lamina perpendicularis*; *vertical plate*).—The perpendicular plate (Figs. 150, 151) is a thin, flattened lamina, polygonal in form, which descends from the under surface of the cribriform plate, and assists in forming the septum of the nose; it is generally deflected a little to one or other side. The **anterior border** articulates with the spine of the frontal bone and the crest of the nasal bones. The **posterior border** articulates by its upper half with the sphenoidal crest, by its lower with the vomer. The **inferior border** is thicker than the posterior, and serves for the attachment of the septal cartilage of the nose. The surfaces of the plate are smooth, except above, where numerous grooves and canals are seen; these lead from the medial foramina on the cribriform plate and lodge filaments of the olfactory nerves.

3

The **Labyrinth** or **Lateral Mass** (*labyrinthus ethmoidalis*) consists of a number of thin-walled cellular cavities, the **ethmoidal cells**, arranged in three groups, *anterior*, *middle*, and *posterior*, and interposed between two vertical plates of bone; the lateral plate forms part of the orbit, the medial, part of the corresponding nasal cavity. In the disarticulated bone many of these cells are opened into, but when the bones are articulated, they are closed in at every part, except where they open into the nasal cavity.

4

Surfaces.—The **upper surface** of the labyrinth (Fig. 149) presents a number of half-broken cells, the walls of which are completed, in the articulated skull, by the edges of the ethmoidal notch of the frontal bone. Crossing this surface are two grooves, converted into canals by articulation with the frontal; they are the **anterior** and **posterior ethmoidal canals**, and open on the inner wall of the orbit. The **posterior surface** presents large irregular cellular cavities, which are closed in by articulation with the sphenoidal concha and orbital process of the palatine. The **lateral surface** (Fig. 152) is formed of a thin, smooth, oblong plate, the **lamina papyracea** (*os planum*), which covers in the middle and posterior ethmoidal cells and forms a large part of the medial wall of the orbit; it articulates above with the orbital plate of the frontal bone, below with the maxilla and orbital process of the palatine, in front with the lacrimal, and behind with the sphenoid.

5

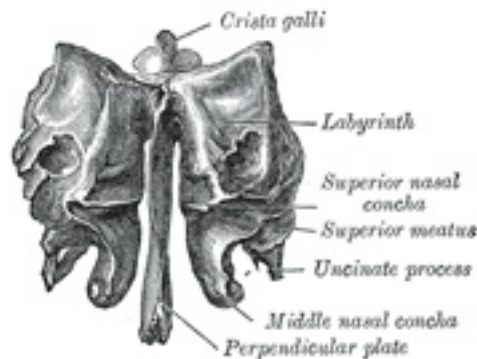


FIG. 151—Ethmoid bone from behind. ([See enlarged image](#))

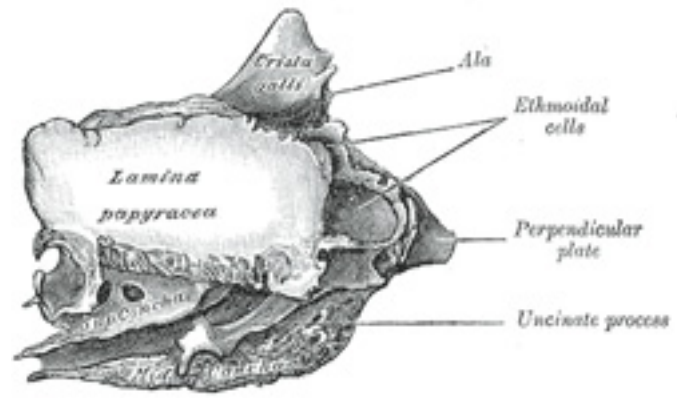


FIG. 152– Ethmoid bone from the right side. ([See enlarged image](#))

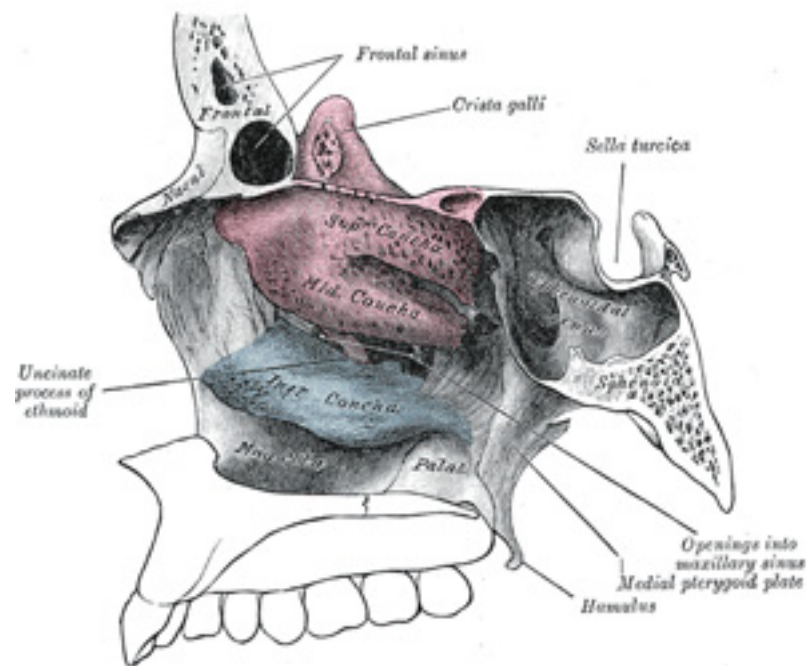


FIG. 153– Lateral wall of nasal cavity, showing ethmoid bone in position. ([See enlarged image](#))

In front of the lamina papyracea are some broken air cells which are overlapped and completed by the lacrimal bone and the frontal process of the maxilla. A curved lamina, the **uncinate process**, projects downward and backward from this part of the labyrinth; it forms a small part of the medial wall of the maxillary sinus, and articulates with the ethmoidal process of the inferior nasal concha. 6

The **medial surface** of the labyrinth ([Fig. 153](#)) forms part of the lateral wall of the corresponding nasal cavity. It consists of a thin lamella, which descends from the under surface of the cribriform plate, and ends below in a free, convoluted margin, the **middle nasal concha**. It is rough, and marked above by numerous grooves, directed nearly vertically downward from the cribriform plate; they lodge branches of the olfactory nerves, which are distributed to the mucous membrane covering the superior nasal concha. The back part of the surface is subdivided by a narrow oblique fissure, the **superior meatus** of the nose, bounded above by a thin, curved plate, the **superior nasal concha**; the posterior ethmoidal cells open into this meatus. Below, and in front of the superior meatus, is the convex surface of the middle nasal concha; it extends along the whole length of the medial surface of the labyrinth, and its lower margin is free and thick. The lateral surface of the middle concha is concave, and assists in forming the **middle meatus** of the nose. The middle ethmoidal cells open into the central part of this meatus, and a 7

sinuous passage, termed the **infundibulum**, extends upward and forward through the labyrinth and communicates with the anterior ethmoidal cells, and in about 50 per cent. of skulls is continued upward as the frontonasal duct into the frontal sinus.

Ossification.—The ethmoid is ossified in the cartilage of the nasal capsule by *three* centers: one for the perpendicular plate, and one for each labyrinth. 8

The labyrinths are first developed, ossific granules making their appearance in the region of the lamina papyracea between the fourth and fifth months of fetal life, and extending into the conchæ. At birth, the bone consists of the two labyrinths, which are small and ill-developed. During the first year after birth, the perpendicular plate and crista galli begin to ossify from a single center, and are joined to the labyrinths about the beginning of the second year. The cribriform plate is ossified partly from the perpendicular plate and partly from the labyrinths. The development of the ethmoidal cells begins during fetal life. 9

Articulations.—The ethmoid articulates with *fifteen* bones: four of the cranium—the frontal, the sphenoid, and the two sphenoidal conchæ; and eleven of the face—the two nasals, two maxillæ, two lacrimals, two palatines, two inferior nasal conchæ, and the vomer. 10

Sutural or Wormian 37 Bones.—In addition to the usual centers of ossification of the cranium, others may occur in the course of the sutures, giving rise to irregular, isolated bones, termed *sutural* or *Wormian bones*. They occur most frequently in the course of the lambdoidal suture, but are occasionally seen at the fontanelles, especially the posterior. One, the *pterion ossicle*, sometimes exists between the sphenoidal angle of the parietal and the great wing of the sphenoid. They have a tendency to be more or less symmetrical on the two sides of the skull, and vary much in size. Their number is generally limited to two or three; but more than a hundred have been found in the skull of an adult hydrocephalic subject. 11

Note 37. Ole Worm, Professor of Anatomy at Copenhagen, 1624–1639, was erroneously supposed to have given the first detailed description of these bones. [[back](#)]

5b. The Facial Bones. 1. The Nasal Bones

(Ossa Faciei) & (Ossa Nasalia) 1

The **nasal bones** are two small oblong bones, varying in size and form in different individuals; they are placed side by side at the middle and upper part of the face, and form, by their junction, “the bridge” of the nose ([Fig. 190](#)). Each has two surfaces and four borders.

Surfaces.—The **outer surface** ([Fig. 155](#)) is concavoconvex from above downward, convex from side to side; it is covered by the Procerus and Compressor naris, and perforated about its center by a foramen, for the transmission of a small vein. The **inner surface** ([Fig. 156](#)) is concave from side to side, and is traversed from above downward, by a groove for the passage of a branch of the nasociliary nerve. 2

Borders.—The **superior border** is narrow, thick, and serrated for articulation with the nasal notch of the frontal bone. The **inferior border** is thin, and gives attachment to the lateral cartilage of the nose; near its middle is a notch which marks the end of the groove just referred to. The **lateral border** is serrated, bevelled at the expense of the inner surface above, and of the outer below, to articulate with the frontal process of the maxilla. The **medial border**, thicker above than below, articulates with its fellow of the opposite side, and is prolonged behind into a vertical crest, which forms part of the nasal septum: this crest articulates, from above downward, with the spine of the frontal, the perpendicular plate of the ethmoid, and the septal cartilage of the nose.

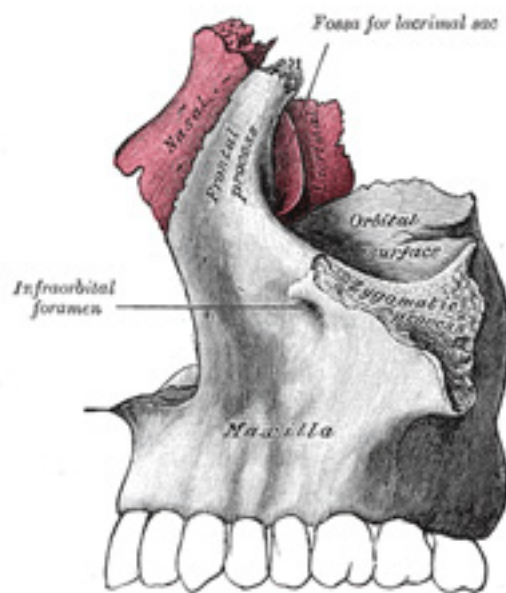


FIG. 154— Articulation of nasal and lacrimal bones with maxilla. ([See enlarged image](#))

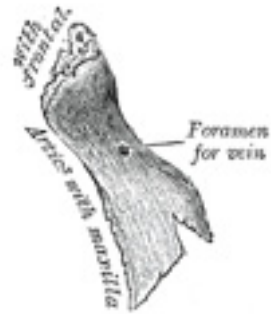


FIG. 155— Right nasal bone. Outer surface. ([See enlarged image](#))

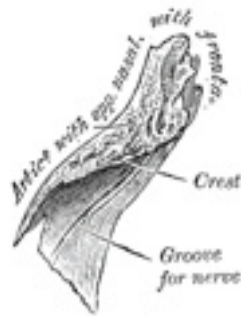

FIG. 156— Right nasal bone. Inner surface. ([See enlarged image](#))

Ossification.—Each bone is ossified from *one* center, which appears at the beginning of the third month of fetal life in the membrane overlying the front part of the cartilaginous nasal capsule. 4

Articulations.—The nasal articulates with four bones: two of the cranium, the frontal and ethmoid, and two of the face, the opposite nasal and the maxilla.

5b. 2. The Maxillæ (Upper Jaw)

The **maxillæ** are the largest bones of the face, excepting the mandible, and form, by their union, the whole of the upper jaw. Each assists in forming the boundaries of three cavities, viz., the roof of the mouth, the floor and lateral wall of the nose and the floor of the orbit; it also enters into the formation of two fossæ, the infratemporal and pterygopalatine, and two fissures, the inferior orbital and pterygomaxillary.

Each bone consists of a body and four processes—zygomatic, frontal, alveolar, and palatine.

The Body (*corpus maxillæ*).—The body is somewhat pyramidal in shape, and contains a large cavity, the **maxillary sinus** (*antrum of Highmore*). It has four surfaces—an anterior, a posterior or infratemporal, a superior or orbital, and a medial or nasal.

Surfaces.—The **anterior surface** ([Fig. 157](#)) is directed forward and lateralward. It presents at its lower part a series of eminences corresponding to the positions of the roots of the teeth. Just above those of the incisor teeth is a depression, the **incisive fossa**, which gives origin to the Depressor alæ nasi; to the alveolar border below the fossa is attached a slip of the Orbicularis oris; above and a little lateral to it, the Nasalis arises. Lateral to the incisive fossa is another depression, the **canine fossa**; it is larger and deeper than the incisive fossa, and is separated from it by a vertical ridge, the **canine eminence**, corresponding to the socket of the canine tooth; the canine fossa gives origin to the Caninus. Above the fossa is the **infraorbital foramen**, the end of the infraorbital canal; it transmits the infraorbital vessels and nerve. Above the foramen is the margin of the orbit, which affords attachment to part of the Quadratus labii superioris. Medially, the anterior surface is limited by a deep concavity, the **nasal notch**, the margin of which gives attachment to the Dilator naris posterior and ends below in a pointed process, which with its fellow of the opposite side forms the **anterior nasal spine**.

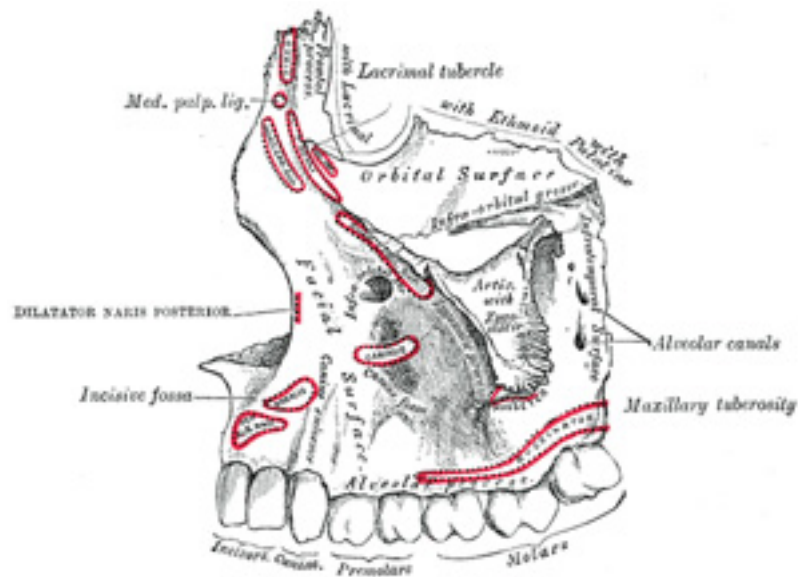


FIG. 157– Left maxilla. Outer surface. ([See enlarged image](#))

The **infratemporal surface** ([Fig. 157](#)) is convex, directed backward and lateralward, and forms part of the infratemporal fossa. It is separated from the anterior surface by the zygomatic process and by a strong ridge, extending upward from the socket of the first molar tooth. It is pierced about its center by the apertures of the **alveolar canals**, which transmit the posterior superior alveolar vessels and nerves. At the lower part of this surface is a rounded eminence, the **maxillary tuberosity**, especially prominent after the growth of the wisdom tooth; it is rough on its lateral side for articulation with the pyramidal process of the palatine bone and in some cases articulates with the lateral pterygoid plate of the sphenoid. It gives origin to a few fibers of the Pterygoideus internus. Immediately above this is a smooth surface, which forms the anterior boundary of the pterygopalatine fossa, and presents a groove, for the maxillary nerve; this groove is directed lateralward and slightly upward, and is continuous with the infraorbital groove on the orbital surface.

5

The **orbital surface** ([Fig. 157](#)) is smooth and triangular, and forms the greater part of the floor of the orbit. It is bounded *medially* by an irregular margin which in front presents a notch, the **lacrimal notch**; behind this notch the margin articulates with the lacrimal, the lamina papyracea of the ethmoid and the orbital process of the palatine. It is bounded *behind* by a smooth rounded edge which forms the anterior margin of the inferior orbital fissure, and sometimes articulates at its lateral extremity with the orbital surface of the great wing of the sphenoid.

6

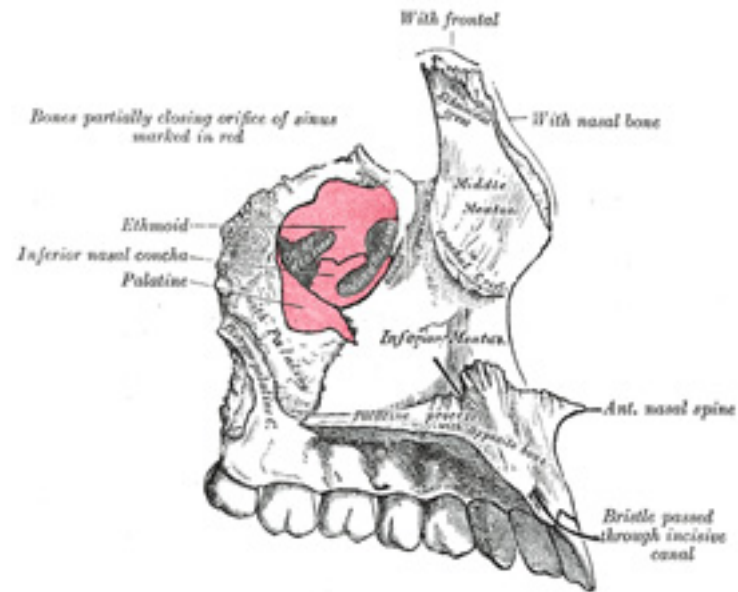


FIG. 158– Left maxilla. Nasal surface. ([See enlarged image](#))

It is limited *in front* by part of the circumference of the orbit, which is continuous medially with the frontal process, and laterally with the zygomatic process. Near the middle of the posterior part of the orbital surface is the **infraorbital groove**, for the passage of the infraorbital vessels and nerve. The groove begins at the middle of the posterior border, where it is continuous with that near the upper edge of the infratemporal surface, and, passing forward, ends in a canal, which subdivides into two branches. One of the canals, the **infraorbital canal**, opens just below the margin of the orbit; the other, which is smaller, runs downward in the substance of the anterior wall of the maxillary sinus, and transmits the anterior superior alveolar vessels and nerve to the front teeth of the maxilla. From the back part of the infraorbital canal, a second small canal is sometimes given off; it runs downward in the lateral wall of the sinus, and conveys the middle alveolar nerve to the premolar teeth. At the medial and forepart of the orbital surface just lateral to the lacrimal groove, is a depression, which gives origin to the *Obliquus oculi inferior*.

The **nasal surface** ([Fig. 158](#)) presents a large, irregular opening leading into the maxillary sinus. At the upper border of this aperture are some broken air cells, which, in the articulated skull, are closed in by the ethmoid and lacrimal bones. Below the aperture is a smooth concavity which forms part of the inferior meatus of the nasal cavity, and behind it is a rough surface for articulation with the perpendicular part of the palatine bone; this surface is traversed by a groove, commencing near the middle of the posterior border and running obliquely downward and forward;

7

8

the groove is converted into a canal, the **pterygopalatine canal**, by the palatine bone. In front of the opening of the sinus is a deep groove, the **lacrima groove**, which is converted into the nasolacrimal canal, by the lacrimal bone and inferior nasal concha; this canal opens into the inferior meatus of the nose and transmits the nasolacrimal duct. More anteriorly is an oblique ridge, the **conchal crest**, for articulation with the inferior nasal concha. The shallow concavity above this ridge forms part of the atrium of the middle meatus of the nose, and that below it, part of the inferior meatus.

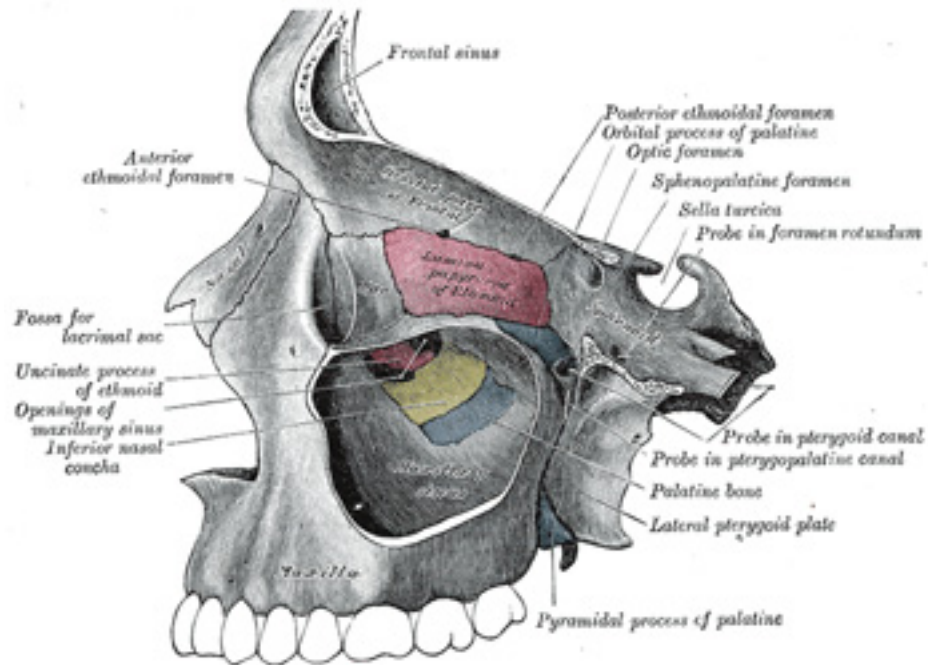


FIG. 159— Left maxillary sinus opened from the exterior. ([See enlarged image](#))

The Maxillary Sinus or Antrum of Highmore (*sinus maxillaris*).—The maxillary sinus is a large pyramidal cavity, within the body of the maxilla: its **apex**, directed lateralward, is formed by the zygomatic process; its **base**, directed medialward, by the lateral wall of the nose. Its walls are everywhere exceedingly thin, and correspond to the nasal orbital, anterior, and infratemporal surfaces of the body of the bone. Its **nasal wall**, or **base**, presents, in the disarticulated bone, a large, irregular aperture, communicating with the nasal cavity. In the articulated skull this

aperture is much reduced in size by the following bones: the uncinat process of the ethmoid above, the ethmoidal process of the inferior nasal concha below, the vertical part of the palatine behind, and a small part of the lacrimal above and in front ([Figs. 158, 159](#)); the sinus communicates with the middle meatus of the nose, generally by two small apertures left between the above-mentioned bones. In the fresh state, usually only one small opening exists, near the upper part of the cavity; the other is closed by mucous membrane. On the **posterior wall** are the **alveolar canals**, transmitting the posterior superior alveolar vessels and nerves to the molar teeth. The **floor** is formed by the alveolar process of the maxilla, and, if the sinus be of an average size, is on a level with the floor of the nose; if the sinus be large it reaches below this level.

Projecting into the floor of the antrum are several conical processes, corresponding to the roots of the first and second molar teeth; [38](#) in some cases the floor is perforated by the fangs of the teeth. The infraorbital canal usually projects into the cavity as a well-marked ridge extending from the roof to the anterior wall; additional ridges are sometimes seen in the posterior wall of the cavity, and are caused by the alveolar canals. The size of the cavity varies in different skulls, and even on the two sides of the same skull. [39](#)

The Zygomatic Process (*processus zygomaticus; malar process*).—The zygomatic process is a rough triangular eminence, situated at the angle of separation of the anterior, zygomatic, and orbital surfaces. *In front* it forms part of the anterior surface; *behind*, it is concave, and forms part of the infratemporal fossa; *above*, it is rough and serrated for articulation with the zygomatic bone; while *below*, it presents the prominent arched border which marks the division between the anterior and infratemporal surfaces.

The Frontal Process (*processus frontalis; nasal process*).—The frontal process is a strong plate, which projects upward, medialward, and backward, by the side of the nose, forming part of its lateral boundary. Its *lateral surface* is smooth, continuous with the anterior surface of the body, and gives attachment to the Quadratus labii superioris, the Orbicularis oculi, and the medial palpebral ligament. Its *medial surface* forms part of the lateral wall of the nasal cavity; at its upper part is a rough, uneven area, which articulates with the ethmoid, closing in the anterior ethmoidal cells; below this is an oblique ridge, the **ethmoidal crest**, the posterior end of which articulates with the middle nasal concha, while the anterior part is termed the **agger nasi**; the crest forms the upper limit of the atrium of the middle meatus. The *upper border* articulates with the frontal bone and the *anterior* with the nasal; the *posterior border* is thick, and hollowed into a groove, which is continuous below with the lacrimal groove on the nasal surface of the body: by the articulation of the medial margin of the groove with the anterior border of the lacrimal a corresponding groove on the lacrimal is brought into continuity, and together they form the **lacrimal fossa** for the lodgement of the lacrimal sac. The lateral margin of the groove is named the **anterior lacrimal crest**, and is continuous below with the orbital margin; at its junction with the orbital surface is a small tubercle, the **lacrimal tubercle**, which serves as a guide to the position of the lacrimal sac.

The Alveolar Process (*processus alveolaris*).—The alveolar process is the thickest and most spongy part of the bone. It is broader behind than in front, and excavated into deep cavities for the reception of the teeth. These cavities are eight in number, and vary in size and depth according to the teeth they contain. That for the canine tooth is the deepest; those for the molars are the widest, and are subdivided into minor cavities by septa; those for the incisors are single, but deep and narrow. The Buccinator arises from the outer surface of this process, as far forward as the first molar tooth. When the maxillæ are articulated with each other, their alveolar processes together form the **alveolar arch**; the center of the anterior margin of this arch is named the **alveolar point**.

The Palatine Process (*processus palatinus; palatal process*).—The palatine process, thick and strong, is horizontal and projects medialward from the nasal surface of the bone. It forms a considerable part of the floor of the nose and the roof of the mouth and is much thicker in front than behind. Its *inferior surface* (Fig. 160) is concave, rough and uneven, and forms, with the palatine process of the opposite bone, the anterior three-fourths of the hard plate. It is perforated by numerous foramina for the passage of the nutrient vessels; is channelled at the back part of its lateral border by a groove, sometimes a canal, for the transmission of the descending palatine vessels and the anterior palatine nerve from the sphenopalatine ganglion; and presents little depressions for the lodgement of the palatine glands. When the two maxillæ are articulated, a funnel-shaped opening, the **incisive foramen**, is seen in the middle line, immediately behind the incisor teeth. In this opening the orifices of two lateral canals are visible; they are named the **incisive canals** or **foramina of Stenson**; through each of them passes the terminal branch of the descending palatine artery and the nasopalatine nerve. Occasionally two additional canals are present in the middle line; they are termed the **foramina of Scarpa**, and when present transmit the nasopalatine nerves, the left passing through the anterior, and the right through the posterior canal. On the under surface of the palatine process, a delicate linear suture, well seen in young skulls, may sometimes be noticed extending lateralward and forward on either side from the incisive foramen to the interval between the lateral incisor and the canine tooth. The small part in front of this suture constitutes the **premaxilla** (*os incisivum*), which in most vertebrates forms an independent bone; it includes the whole thickness of the alveolus, the corresponding part of the floor of the nose and the anterior nasal spine, and contains the sockets of the incisor teeth. The *upper surface* of the palatine process is concave from side to side, smooth, and forms the greater part of the floor of the nasal cavity. It presents, close to its medial margin, the upper orifice of the incisive canal. The *lateral border* of the process is incorporated with the rest of the bone. The *medial border* is thicker in front than behind, and is raised above into a ridge, the **nasal crest**, which, with the corresponding ridge of the opposite bone, forms a groove for the reception of the vomer. The front part of this ridge rises to a considerable height, and is named the **incisor crest**; it is prolonged forward into a sharp process, which forms, together with a similar process of the opposite bone, the **anterior nasal spine**. The *posterior border* is serrated for articulation with the horizontal part of the palatine bone.

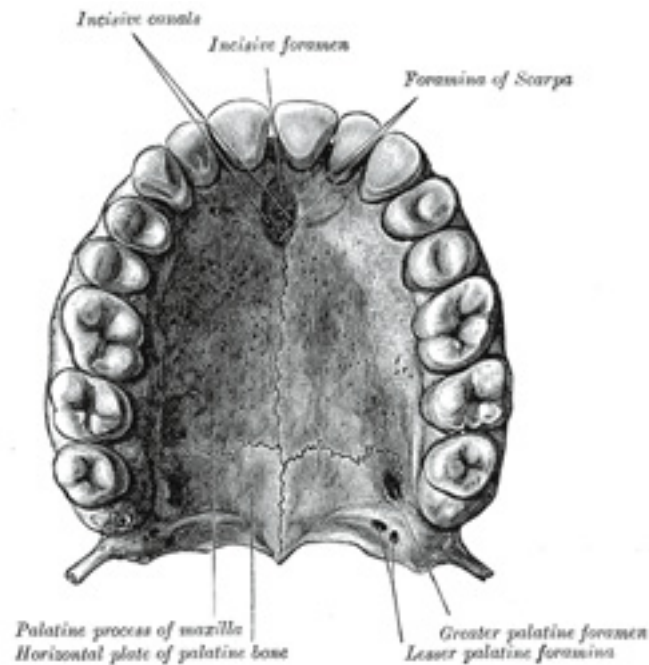


FIG. 160— The bony palate and alveolar arch. ([See enlarged image](#))

Ossification.—The maxilla is ossified in membrane. Mall [40](#) and Fawcett [41](#) maintain that it is ossified from *two* centers only, one for the maxilla proper and one for the premaxilla. These centers appear during the sixth week of fetal life and unite in the beginning of the third month, but the suture between the two portions persists on the palate until nearly middle life. Mall states that the frontal process is developed from both centers. The maxillary sinus appears as a shallow groove on the nasal surface of the bone about the fourth month of fetal life, but does not reach its full size until after the second dentition. The maxilla was formerly described as ossifying from six centers, viz., one, the *orbitonasal*, forms that portion of the body of the bone which lies medial to the infraorbital canal, including the medial part of the floor of the orbit and the lateral wall of the nasal cavity; a second, the *zygomatic*, gives origin to the portion which lies lateral to the infraorbital canal, including the zygomatic process; from a third, the *palatine*, is developed the palatine process posterior to the incisive canal together with the adjoining part of the nasal wall; a fourth, the *premaxillary*, forms the incisive bone which carries the incisor teeth and corresponds to the premaxilla of the lower vertebrates; [42](#) a fifth, the *nasal*, gives rise to the frontal process and the portion above the canine tooth; and a sixth, the *infravomerine*, lies

between the palatine and premaxillary centers and beneath the vomer; this center, together with the corresponding center of the opposite bone, separates the incisive canals from each other.

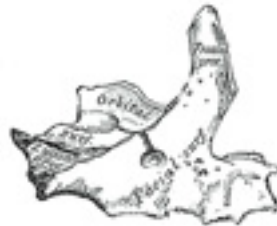

FIG. 161— Anterior surface of maxilla at birth. ([See enlarged image](#))



FIG. 162— Inferior surface of maxilla at birth. ([See enlarged image](#))

Articulations.—The maxilla articulates with *nine* bones: two of the cranium, the frontal and ethmoid, and seven of the face, viz., the nasal, zygomatic, lacrimal, inferior nasal concha, palatine, vomer, and its fellow of the opposite side. Sometimes it articulates with the orbital surface, and sometimes with the lateral pterygoid plate of the sphenoid.

16

Changes Produced in the Maxilla by AgeAt birth the transverse and antero-posterior diameters of the bone are each greater than the vertical. The frontal process is well-marked and the body of the bone consists of little more than the alveolar process, the teeth sockets reaching almost to the floor of the orbit. The maxillary sinus presents the appearance of a furrow on the lateral wall of the nose. In the adult the vertical diameter is the greatest, owing to the development of the alveolar process and the increase in size of the sinus. In old age the bone reverts in some measure

17

to the infantile condition; its height is diminished, and after the loss of the teeth the alveolar process is absorbed, and the lower part of the bone contracted and reduced in thickness.

Note 38. The number of teeth whose roots are in relation with the floor of the antrum is variable. The sinus “may extend so as to be in relation to all the teeth of the true maxilla, from the canine to the *dens sapientia*.” (Salter.) [\[back\]](#)

Note 39. Aldren Turner (*op. cit.*) gives the following measurements as those of an average sized sinus: vertical height opposite first molar tooth, 1 1/2 inch; transverse breadth, 1 inch; and antero-posterior depth, 1 1/4 inch. [\[back\]](#)

Note 40. American Journal of Anatomy, 1906, vol. v. [\[back\]](#)

Note 41. Journal of Anatomy and Physiology, 1911, vol. xlv. [\[back\]](#)

Note 42. Some anatomists believe that the premaxillary bone is ossified by two centers (see page 299). [\[back\]](#)

5b. 3. The Lacrimal Bone

(Os Lacrimale)

1

The **lacrimal bone**, the smallest and most fragile bone of the face, is situated at the front part of the medial wall of the orbit ([Fig. 164](#)). It has two surfaces and four borders.

Surfaces.—The **lateral** or **orbital surface** ([Fig. 163](#)) is divided by a vertical ridge, the **posterior lacrimal crest**, into two parts. In front of this crest is a longitudinal groove, the **lacrimal sulcus** (*sulcus lacrimonalis*), the inner margin of which unites with the frontal process of the maxilla, and the lacrimal fossa is thus completed. The upper part of this fossa lodges the lacrimal sac, the lower part, the naso-lacrimal duct. The portion behind the crest is smooth, and forms part of the medial wall of the orbit. The crest, with a part of the orbital surface immediately behind it, gives origin to the lacrimal part of the Orbicularis oculi and ends below in a small, hook-like projection, the **lacrimal hamulus**, which articulates with the lacrimal tubercle of the maxilla, and completes the upper orifice of the lacrimal canal; it sometimes exists as a separate piece, and is then called the **lesser lacrimal bone**. 2

The **medial** or **nasal surface** presents a longitudinal furrow, corresponding to the crest on the lateral surface. The area in front of this furrow forms part of the middle meatus of the nose; that behind it articulates with the ethmoid, and completes some of the anterior ethmoidal cells. 3

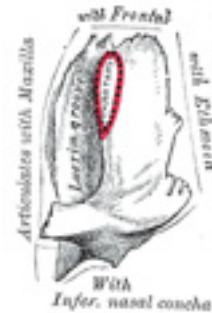


FIG. 163– Left lacrimal bone. Orbital surface. Enlarged. ([See enlarged image](#))

Borders.—Of the *four borders* the **anterior** articulates with the frontal process of the maxilla; the **posterior** with the lamina papyracea of the ethmoid; the **superior** with the frontal bone. The **inferior** is divided by the lower edge of the posterior lacrimal crest into two parts: the posterior part articulates with the orbital plate of the maxilla; the anterior is prolonged downward as the **descending process**, which articulates with the lacrimal process of the inferior nasal concha, and assists in forming the canal for the nasolacrimal duct. 4

Ossification.—The lacrimal is ossified from a single center, which appears about the twelfth week in the membrane covering the cartilaginous nasal capsule. 5

Articulations.—The lacrimal articulates with *four* bones: two of the cranium, the frontal and ethmoid, and two of the face, the maxilla and the inferior nasal concha.

5b. 4. The Zygomatic Bone

(Os Zygomaticum; Malar Bone)

1

The **zygomatic bone** is small and quadrangular, and is situated at the upper and lateral part of the face: it forms the prominence of the cheek, part of the lateral wall and floor of the orbit, and parts of the temporal and infratemporal fossæ ([Fig. 164](#)). It presents a malar and a temporal surface; four processes, the frontosphenoidal, orbital, maxillary, and temporal; and four borders.

Surfaces.—The **malar surface** ([Fig. 165](#)) is convex and perforated near its center by a small aperture, the **zygomaticofacial foramen**, for the passage of the zygomaticofacial nerve and vessels; below this foramen is a slight elevation, which gives origin to the Zygomaticus. 2

The **temporal surface** ([Fig. 166](#)), directed backward and medialward, is concave, presenting medially a rough, triangular area, for articulation with the maxilla, and laterally a smooth, concave surface, the upper part of which forms the anterior boundary of the temporal fossa, the lower a part of the infratemporal fossa. Near the center of this surface is the **zygomaticotemporal foramen** for the transmission of the zygomaticotemporal nerve. 3

Processes.—The **frontosphenoidal process** is thick and serrated, and articulates with the zygomatic process of the frontal bone. On its orbital surface, just within the orbital margin and about 11 mm. below the zygomaticofrontal suture is a tubercle of varying size and form, but present in 95 per cent. of skulls ([Whitnall 43](#)). The **orbital process** is a thick, strong plate, projecting backward and medialward from the orbital margin. Its *antero-medial surface* forms, by its junction with the orbital surface of the maxilla and with the great wing of the sphenoid, part of the floor and lateral wall of the orbit. On it are seen the orifices of two canals, the **zygomaticoörbital foramina**; one of these canals opens into the temporal fossa, the other on the malar surface of the bone; the former transmits the zygomaticotemporal, the latter the zygomaticofacial nerve. Its *postero-lateral surface*, smooth and convex, forms parts of the temporal and infratemporal fossæ. Its *anterior margin*, smooth and rounded, is part of the circumference of the orbit. Its *superior margin*, rough, and directed horizontally, articulates with the frontal bone behind the zygomatic process. Its *posterior margin* is serrated for articulation, with the great wing of the sphenoid and the orbital surface of the maxilla. At the angle of junction of the sphenoidal and maxillary portions, a short, concave, non-articular part is generally seen; this forms the anterior boundary of the inferior orbital fissure: occasionally, this non-articular part is absent, the fissure then being completed by the junction of the maxilla and sphenoid, or by the interposition of a small sutural bone in the angular interval between them. The **maxillary process** presents a rough, triangular surface which articulates with the maxilla. The **temporal process**, long, narrow, and serrated, articulates with the zygomatic process of the temporal. 4

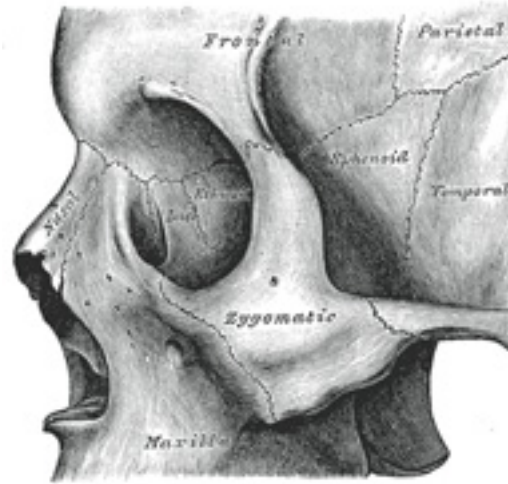


FIG. 164— Left zygomatic bone *in situ*. ([See enlarged image](#))

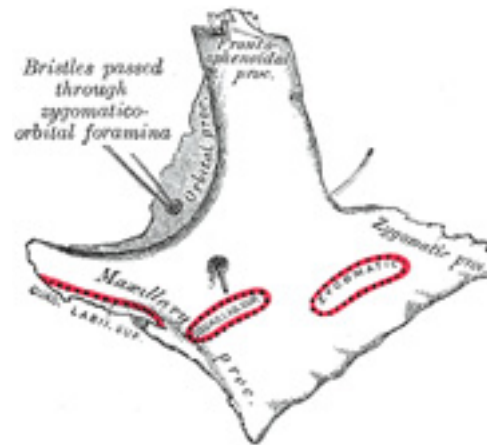


FIG. 165– Left zygomatic bone. Malar surface. ([See enlarged image](#))

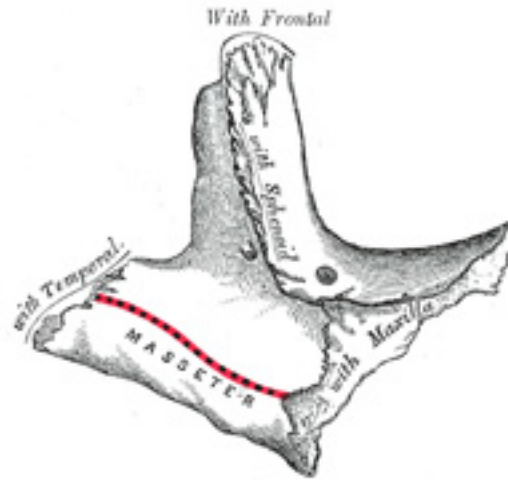


FIG. 166– Left zygomatic bone. Temporal surface. ([See enlarged image](#))

Borders.—The **antero-superior** or **orbital border** is smooth, concave, and forms a considerable part of the circumference of the orbit. 5
The **antero-inferior** or **maxillary border** is rough, and bevelled at the expense of its inner table, to articulate with the maxilla; near the orbital margin it gives origin to the *Quadratus labii superioris*. The **postero-superior** or **temporal border**, curved like an italic letter *f*, is continuous above with the commencement of the temporal line, and below with the upper border of the zygomatic arch; the temporal fascia is attached to it. The **postero-inferior** or **zygomatic border** affords attachment by its rough edge to the *Masseter*.

Ossification.

—The zygomatic bone is generally described as ossifying from three centers—one for the malar and two for the orbital portion; these appear about the eighth week and fuse about the fifth month of fetal life. Mall describes it as being ossified from one center which appears just beneath and to the lateral side of the orbit. After birth, the bone is sometimes divided by a horizontal suture into an upper larger, and a lower smaller division. In some quadrumana the zygomatic bone consists of two parts, an orbital and a malar. 6

Articulations.—The zygomatic articulates with *four* bones: the frontal, sphenoidal, temporal, and maxilla.

7

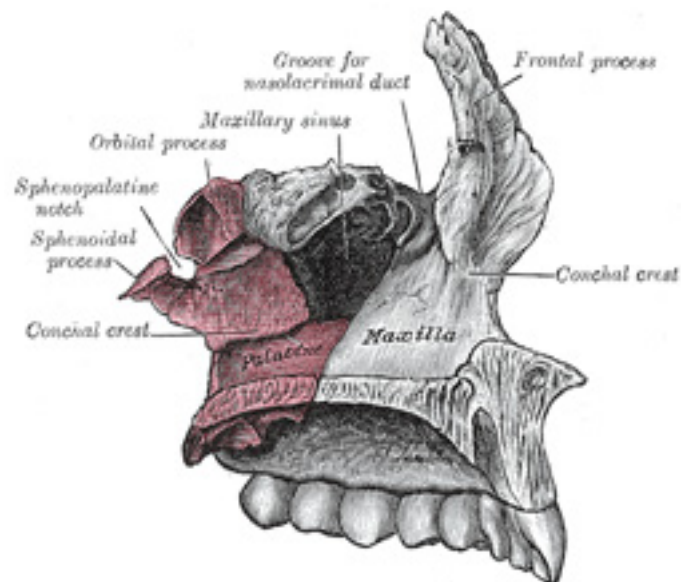


FIG. 167— Articulation of left palatine bone with maxilla. ([See enlarged image](#))

Note 43. Journal of Anatomy and Physiology, vol. xlv. The structures attached to this tubercle are: (1) the check ligament of the Rectus lateralis; (2) the lateral end of the aponeurosis of the Levator palpebræ superioris; (3) the suspensory ligament of the eye (Lockwood); and (4) the lateral extremities of the superior and inferior tarsi. [[back](#)]

5b. 5. The Palatine Bone

(Os Palatinum; Palate Bone)

1

The **palatine bone** is situated at the back part of the nasal cavity between the maxilla and the pterygoid process of the sphenoid ([Fig. 167](#)). It contributes to the walls of three cavities: the floor and lateral wall of the nasal cavity, the roof of the mouth, and the floor of the orbit; it enters into the formation of two fossæ, the **pterygopalatine** and **pterygoid fossæ**; and one fissure, the **inferior orbital fissure**. The palatine bone somewhat resembles the letter L, and consists of a horizontal and a vertical part and three outstanding processes—viz., the pyramidal process, which is directed backward and lateralward from the junction of the two parts, and the orbital and sphenoidal processes, which surmount the vertical part, and are separated by a deep notch, the sphenopalatine notch.

The Horizontal Part (*pars horizontalis*; *horizontal plate*) ([Figs. 168, 169](#)).—The horizontal part is quadrilateral, and has two surfaces and four borders. 2

Surfaces.—The **superior surface**, concave from side to side, forms the back part of the floor of the nasal cavity. The **inferior surface**, slightly concave and rough, forms, with the corresponding surface of the opposite bone, the posterior fourth of the hard palate. Near its posterior margin may be seen a more or less marked transverse ridge for the attachment of part of the aponeurosis of the Tensor veli palatini. 3

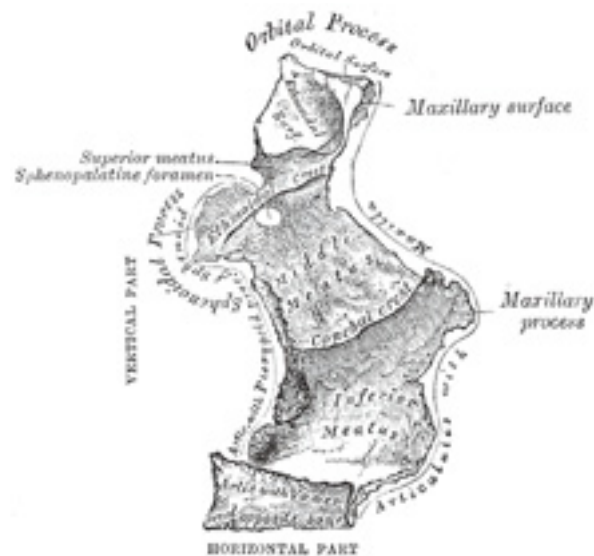

FIG. 168— Left palatine bone. Nasal aspect. Enlarged. ([See enlarged image](#))

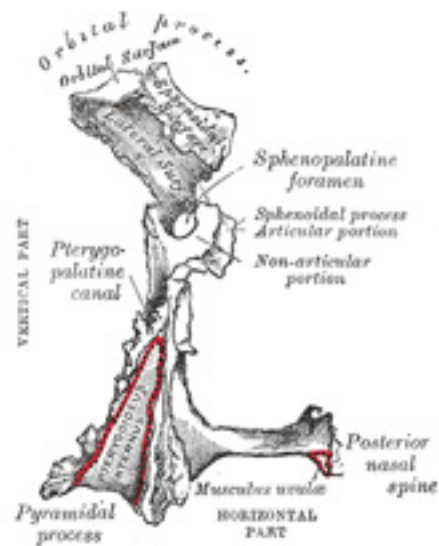


FIG. 169— Left palatine bone. Posterior aspect. Enlarged. ([See enlarged image](#))

Borders.—The **anterior border** is serrated, and articulates with the palatine process of the maxilla. The **posterior border** is concave, free, and serves for the attachment of the soft palate. Its medial end is sharp and pointed, and, when united with that of the opposite bone, forms a projecting process, the **posterior nasal spine** for the attachment of the Musculus uvulæ. The **lateral border** is united with the lower margin of the perpendicular part, and is grooved by the lower end of the pterygopalatine canal. The **medial border**, the thickest, is serrated for articulation with its fellow of the opposite side; its superior edge is raised into a ridge, which, united with the ridge of the opposite bone, forms the **nasal crest** for articulation with the posterior part of the lower edge of the vomer. 4

The Vertical Part (*pars perpendicularis; perpendicular plate*) ([Figs. 168, 169](#)).—The vertical part is thin, of an oblong form, and presents two surfaces and four borders. 5

Surfaces.—The **nasal surface** exhibits at its lower part a broad, shallow depression, which forms part of the inferior meatus of the nose. 6

Immediately above this is a well-marked horizontal ridge, the **conchal crest**, for articulation with the inferior nasal concha; still higher is a second broad, shallow depression, which forms part of the middle meatus, and is limited above by a horizontal crest less prominent than the inferior, the **ethmoidal crest**, for articulation with the middle nasal concha. Above the ethmoidal crest is a narrow, horizontal groove, which forms part of the superior meatus.

The **maxillary surface** is rough and irregular throughout the greater part of its extent, for articulation with the nasal surface of the maxilla; its upper and back part is smooth where it enters into the formation of the pterygopalatine fossa; it is also smooth in front, where it forms the posterior part of the medial wall of the maxillary sinus. On the posterior part of this surface is a deep vertical groove, converted into the **pterygopalatine canal**, by articulation with the maxilla; this canal transmits the descending palatine vessels, and the anterior palatine nerve. 7

Borders.—The **anterior border** is thin and irregular; opposite the conchal crest is a pointed, projecting lamina, the **maxillary process**, which is directed forward, and closes in the lower and back part of the opening of the maxillary sinus. The **posterior border** ([Fig. 169](#)) presents a deep groove, the edges of which are serrated for articulation with the medial pterygoid plate of the sphenoid. This border is continuous above with the sphenoidal process; below it expands into the pyramidal process. The **superior border** supports the orbital process in front and the sphenoidal process behind. These processes are separated by the **sphenopalatine notch**, which is converted into the **sphenopalatine foramen** by the under surface of the body of the sphenoid. In the articulated skull this foramen leads from the pterygopalatine fossa into the posterior part of the superior meatus of the nose, and transmits the sphenopalatine vessels and the superior nasal and nasopalatine nerves. The **inferior border** is fused with the lateral edge of the horizontal part, and immediately in front of the pyramidal process is grooved by the lower end of the pterygopalatine canal. 8

The Pyramidal Process or Tuberosity (*processus pyramidalis*).—The pyramidal process projects backward and lateralward from the junction of the horizontal and vertical parts, and is received into the angular interval between the lower extremities of the pterygoid plates. On its **posterior surface** is a smooth, grooved, triangular area, limited on either side by a rough articular furrow. The furrows articulate with the pterygoid plates, while the grooved intermediate area completes the lower part of the pterygoid fossa and gives origin to a few fibers of the Pterygoideus internus. The anterior part of the **lateral surface** is rough, for articulation with the tuberosity of the maxilla; its posterior part consists of a smooth triangular area which appears, in the articulated skull, between the tuberosity of the maxilla and the lower part of the lateral pterygoid plate, and completes the lower part of the infratemporal fossa. On the **base** of the pyramidal process, close to its union with the horizontal part, are the lesser palatine foramina for the transmission of the posterior and middle palatine nerves. 9

The Orbital Process (*processus orbitalis*).—The orbital process is placed on a higher level than the sphenoidal, and is directed upward and lateralward from the front of the vertical part, to which it is connected by a constricted neck. It presents five surfaces, which enclose an air cell. Of these surfaces, three are articular and two non-articular. The articular surfaces are: (1) the **anterior or maxillary**, directed forward, lateralward, and downward, of an oblong form, and rough for articulation with the maxilla; (2) the **posterior or sphenoidal**, directed backward, upward, and medialward; it presents the opening of the air cell, which usually communicates with the sphenoidal sinus; the margins of the opening are serrated for articulation with the sphenoidal concha; (3) the **medial or ethmoidal**, directed forward, articulates with the labyrinth of the ethmoid. In some cases the air cell opens on this surface of the bone and then communicates with the posterior ethmoidal cells. More rarely it opens on both surfaces, and then communicates with the posterior ethmoidal cells and the sphenoidal sinus. The non-articular surfaces are: (1) 10

the **superior** or **orbital**, directed upward and lateralward; it is triangular in shape, and forms the back part of the floor of the orbit; and (2) the **lateral**, of an oblong form, directed toward the pterygopalatine fossa; it is separated from the orbital surface by a rounded border, which enters into the formation of the inferior orbital fissure.

The Sphenoidal Process (*processus sphenoidalis*).—The sphenoidal process is a thin, compressed plate, much smaller than the orbital, and directed upward and medialward. It presents three surfaces and two borders. The **superior surface** articulates with the root of the pterygoid process and the under surface of the sphenoidal concha, its medial border reaching as far as the ala of the vomer; it presents a groove which contributes to the formation of the pharyngeal canal. The **medial surface** is concave, and forms part of the lateral wall of the nasal cavity. The **lateral surface** is divided into an articular and a non-articular portion: the former is rough, for articulation with the medial pterygoid plate; the latter is smooth, and forms part of the pterygopalatine fossa. The **anterior border** forms the posterior boundary of the sphenopalatine notch. The **posterior border**, serrated at the expense of the outer table, articulates with the medial pterygoid plate. 11

The orbital and sphenoidal processes are separated from one another by the **sphenopalatine notch**. Sometimes the two processes are united above, and form between them a complete foramen ([Fig. 168](#)), or the notch may be crossed by one or more spicules of bone, giving rise to two or more foramina. 12

Ossification.—The palatine bone is ossified in membrane from a single center, which makes its appearance about the sixth or eighth week of fetal life at the angle of junction of the two parts of the bone. From this point ossification spreads medialward to the horizontal part, downward into the pyramidal process, and upward into the vertical part. Some authorities describe the bone as ossifying from four centers: one for the pyramidal process and portion of the vertical part behind the pterygopalatine groove; a second for the rest of the vertical and the horizontal parts; a third for the orbital, and a fourth for the sphenoidal process. At the time of birth the height of the vertical part is about equal to the transverse width of the horizontal part, whereas in the adult the former measures about twice as much as the latter. 13

Articulations.—The palatine articulates with *six* bones: the sphenoid, ethmoid, maxilla, inferior nasal concha, vomer, and opposite palatine.

5b. 6. The Inferior Nasal Concha

(Concha Nasalis Inferior; Inferior Turbinated Bone)

The **inferior nasal concha** extends horizontally along the lateral wall of the nasal cavity ([Fig. 170](#)) and consists of a lamina of spongy bone, curled upon itself like a scroll. It has two surfaces, two borders, and two extremities. 1

The **medial surface** ([Fig. 171](#)) is convex, perforated by numerous apertures, and traversed by longitudinal grooves for the lodgement of vessels. The **lateral surface** is concave ([Fig. 172](#)), and forms part of the inferior meatus. Its **upper border** is thin, irregular, and connected to various bones along the lateral wall of the nasal cavity. It may be divided into three portions: of these, the anterior articulates with the conchal crest of the 2

maxilla; the posterior with the conchal crest of the palatine; the middle portion presents three well-marked processes, which vary much in their size and form. Of these, the anterior or **lacrimal process** is small and pointed and is situated at the junction of the anterior fourth with the posterior three-fourths of the bone: it articulates, by its apex, with the descending process of the lacrimal bone, and, by its margins, with the groove on the back of the frontal process of the maxilla, and thus assists in forming the canal for the nasolacrimal duct. Behind this process a broad, thin plate, the **ethmoidal process**, ascends to join the uncinat process of the ethmoid; from its lower border a thin lamina, the **maxillary process**, curves downward and lateralward; it articulates with the maxilla and forms a part of the medial wall of the maxillary sinus. The **inferior border** is free, thick, and cellular in structure, more especially in the middle of the bone. Both **extremities** are more or less pointed, the posterior being the more tapering.

Ossification.—The inferior nasal concha is ossified from a single center, which appears about the fifth month of fetal life in the lateral wall of the cartilaginous nasal capsule. ³

Articulations.—The inferior nasal concha articulates with *four* bones: the ethmoid, maxilla, lacrimal, and palatine. ⁴

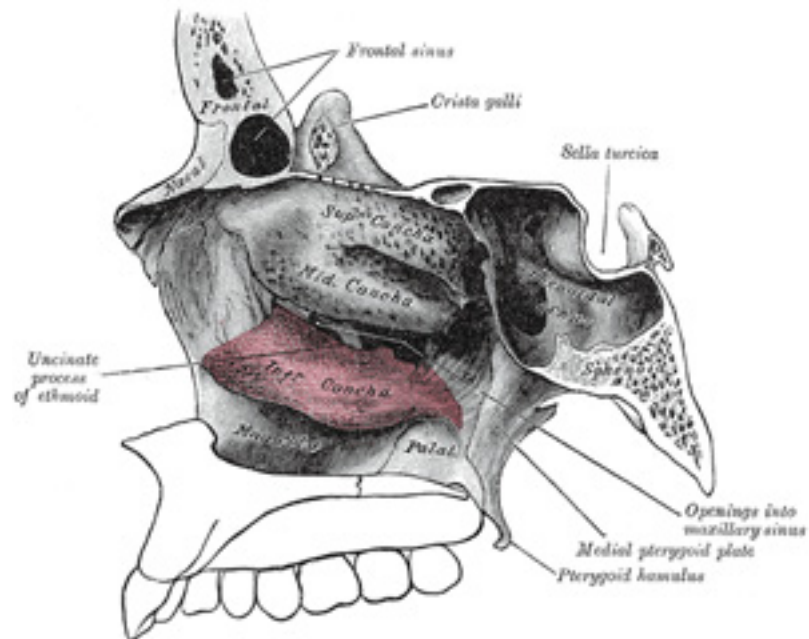


FIG. 170– Lateral wall of right nasal cavity showing inferior concha *in situ*. ([See enlarged image](#))

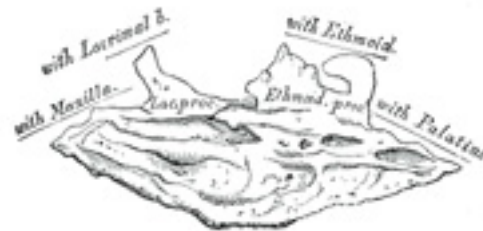

FIG. 171– Right inferior nasal concha. Medial surface. ([See enlarged image](#))

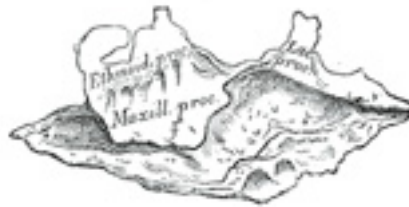

FIG. 172– Right inferior nasal concha. Lateral surface. ([See enlarged image](#))

5b. 7. The Vomer

The **vomer** is situated in the median plane, but its anterior portion is frequently bent to one or other side. It is thin, somewhat quadrilateral in shape, and forms the hinder and lower part of the nasal septum ([Fig. 173](#)); it has two surfaces and four borders. The **surfaces** ([Fig. 174](#)) are marked by small furrows for blood-vessels, and on each is the **nasopalatine groove**, which runs obliquely downward and forward, and lodges the nasopalatine nerve and vessels. The **superior border**, the thickest, presents a deep furrow, bounded on either side by a horizontal projecting ala of bone; the furrow receives the rostrum of the sphenoid, while the margins of the alæ articulate with the vaginal processes of the medial pterygoid plates of the sphenoid behind, and with the sphenoidal processes of the palatine bones in front. The **inferior border** articulates with the crest formed by the maxillæ and palatine bones. The **anterior border** is the longest and slopes downward and forward. Its upper half is fused

with the perpendicular plate of the ethmoid; its lower half is grooved for the inferior margin of the septal cartilage of the nose. The **posterior border** is free, concave, and separates the choanæ. It is thick and bifid above, thin below.

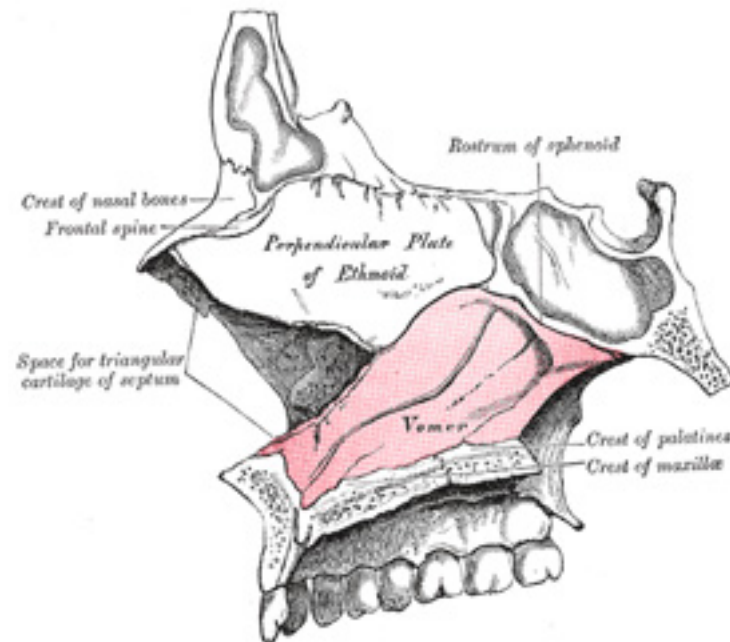


FIG. 173— Median wall of left nasal cavity showing vomer *in situ*. ([See enlarged image](#))

Ossification.—At an early period the septum of the nose consists of a plate of cartilage, the *ethmovomerine cartilage*. The postero-superior part of this cartilage is ossified to form the perpendicular plate of the ethmoid; its antero-inferior portion persists as the septal cartilage, while the vomer is ossified in the membrane covering its postero-inferior part. Two ossific centers, one on either side of the middle line, appear about the eighth week of fetal life in this part of the membrane, and hence the vomer consists primarily of two lamellæ. About the third month these unite below, and thus a deep groove is formed in which the cartilage is lodged. As growth proceeds, the union of the lamellæ extends upward and forward, and at the same time the intervening plate of cartilage undergoes absorption. By the age of puberty the lamellæ are almost completely united to form a median plate, but evidence of the bilaminar origin of the bone is seen in the everted alæ of its upper border and the groove on its anterior margin.

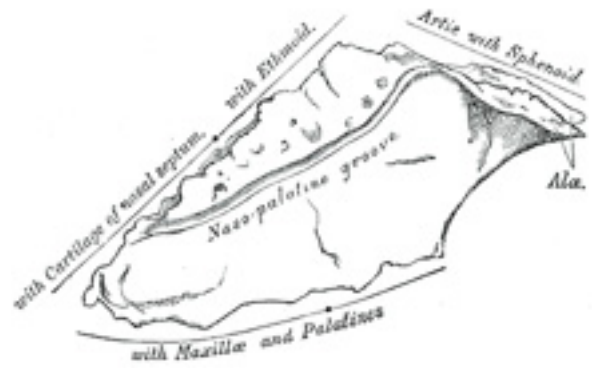

FIG. 174— The vomer. ([See enlarged image](#))



FIG. 175— Vomer of infant. ([See enlarged image](#))

Articulations.—The vomer articulates with *six* bones: two of the cranium, the sphenoid and ethmoid; and four of the face, the two maxillæ and the two palatine bones; it also articulates with the septal cartilage of the nose.

5b. 8. The Mandible (Lower Jaw)

(Inferior Maxillary Bone)

The **mandible**, the largest and strongest bone of the face, serves for the reception of the lower teeth. It consists of a curved, horizontal portion, the **body**, and two perpendicular portions, the **rami**, which unite with the ends of the body nearly at right angles.

The Body (*corpus mandibulæ*).—The body is curved somewhat like a horseshoe and has two surfaces and two borders.

Surfaces.—The **external surface** (Fig. 176) is marked in the median line by a faint ridge, indicating the **symphysis** or line of junction of the two pieces of which the bone is composed at an early period of life. This ridge divides below and encloses a triangular eminence, the **mental protuberance**, the base of which is depressed in the center but raised on either side to form the **mental tubercle**. On either side of the symphysis, just below the incisor teeth, is a depression, the **incisive fossa**, which gives origin to the Mentalis and a small portion of the Orbicularis oris. Below the second premolar tooth, on either side, midway between the upper and lower borders of the body, is the **mental foramen**, for the passage of the mental vessels and nerve. Running backward and upward from each mental tubercle is a faint ridge, the **oblique line**, which is continuous with the anterior border of the ramus; it affords attachment to the Quadratus labii inferioris and Triangularis; the Platysma is attached below it.

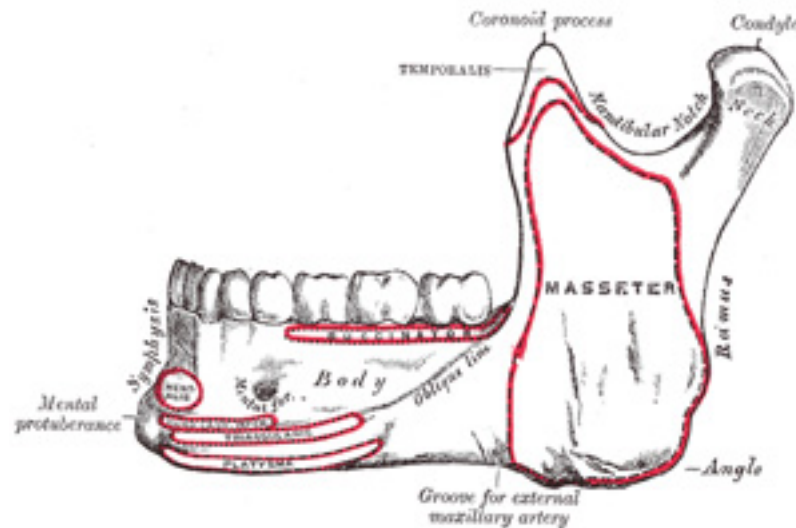


FIG. 176—Mandible. Outer surface. Side view. ([See enlarged image](#))

The **internal surface** (Fig. 177) is concave from side to side. Near the lower part of the symphysis is a pair of laterally placed spines, termed the **mental spines**, which give origin to the Genioglossi. Immediately below these is a second pair of spines, or more frequently a median ridge or impression, for the origin of the Geniohyoidei. In some cases the mental spines are fused to form a single eminence, in others they are absent and their position is indicated merely by an irregularity of the surface. Above the mental spines a median foramen and furrow are sometimes seen; they mark the line of union of the halves of the bone. Below the mental spines, on either side of the middle line, is an oval depression for the attachment of the anterior belly of the Digastricus. Extending upward and backward on either side from the lower part of the symphysis is the **mylohyoid line**, which gives origin to the Mylohyoideus; the posterior part of this line, near the alveolar margin, gives attachment to a small part of the Constrictor pharyngis superior, and to the pterygomandibular raphé. Above the anterior part of this line is a smooth triangular area against which the sublingual gland rests, and below the hinder part, an oval fossa for the submaxillary gland.

4

Borders.—The **superior or alveolar border**, wider behind than in front, is hollowed into cavities, for the reception of the teeth; these cavities are sixteen in number, and vary in depth and size according to the teeth which they contain. To the outer lip of the superior border, on either side, the Buccinator is attached as far forward as the first molar tooth. The **inferior border** is rounded, longer than the superior, and thicker in front than behind; at the point where it joins the lower border of the ramus a shallow groove; for the external maxillary artery, may be present.

5

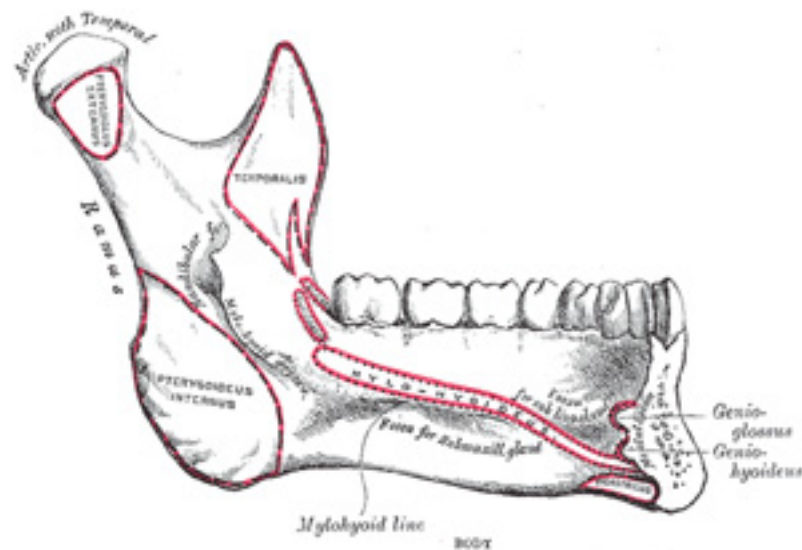


FIG. 177—Mandible. Inner surface. Side view. ([See enlarged image](#))

The Ramus (*ramus mandibulæ; perpendicular portion*).—The ramus is quadrilateral in shape, and has two surfaces, four borders, and two processes. 6

Surfaces.—The **lateral surface** (Fig. 176) is flat and marked by oblique ridges at its lower part; it gives attachment throughout nearly the whole of its extent to the Masseter. The **medial surface** (Fig. 177) presents about its center the oblique **mandibular foramen**, for the entrance of the inferior alveolar vessels and nerve. The margin of this opening is irregular; it presents in front a prominent ridge, surmounted by a sharp spine, the **lingula mandibulæ**, which gives attachment to the sphenomandibular ligament; at its lower and back part is a notch from which the **mylohyoid groove** runs obliquely downward and forward, and lodges the mylohyoid vessels and nerve. Behind this groove is a rough surface, for the insertion of the Pterygoideus internus. The **mandibular canal** runs obliquely downward and forward in the ramus, and then horizontally forward in the body, where it is placed under the alveoli and communicates with them by small openings. On arriving at the incisor teeth, it turns back to communicate with the mental foramen, giving off two small canals which run to the cavities containing the incisor teeth. In the posterior two-thirds of the bone the canal is situated nearer the internal surface of the mandible; and in the anterior third, nearer its external surface. It contains the inferior alveolar vessels and nerve, from which branches are distributed to the teeth. The **lower border** of the ramus is thick, straight, and continuous with the inferior border of the body of the bone. At its junction with the posterior border is the **angle of the mandible**, which may be either inverted or everted and is marked by rough, oblique ridges on each side, for the attachment of the Masseter laterally, and the Pterygoideus internus medially; the stylomandibular ligament is attached to the angle between these muscles. The **anterior border** is thin above, thicker below, and continuous with the oblique line. The **posterior border** is thick, smooth, rounded, and covered by the parotid gland. The **upper border** is thin, and is surmounted by two processes, the **coronoid** in front and the **condyloid** behind, separated by a deep concavity, the **mandibular notch**. 7

The **Coronoid Process** (*processus coronoideus*) is a thin, triangular eminence, which is flattened from side to side and varies in shape and size. 8 Its *anterior border* is convex and is continuous below with the anterior border of the ramus; its *posterior border* is concave and forms the anterior boundary of the mandibular notch. Its *lateral surface* is smooth, and affords insertion to the Temporalis and Masseter. Its *medial surface* gives insertion to the Temporalis, and presents a ridge which begins near the apex of the process and runs downward and forward to the inner side of the last molar tooth. Between this ridge and the anterior border is a grooved triangular area, the upper part of which gives attachment to the Temporalis, the lower part to some fibers of the Buccinator.

The **Condyloid Process** (*processus condyloideus*) is thicker than the coronoid, and consists of two portions: the **condyle**, and the constricted portion which supports it, the **neck**. The **condyle** presents an articular surface for articulation with the articular disk of the temporomandibular joint; it is convex from before backward and from side to side, and extends farther on the posterior than on the anterior surface. Its long axis is directed medialward and slightly backward, and if prolonged to the middle line will meet that of the opposite condyle near the anterior margin of the foramen magnum. At the lateral extremity of the condyle is a small tubercle for the attachment of the temporomandibular ligament. The **neck** is flattened from before backward, and strengthened by ridges which descend from the forepart and sides of the condyle. Its posterior surface is convex; its anterior presents a depression for the attachment of the Pterygoideus externus. 9

The **mandibular notch**, separating the two processes, is a deep semilunar depression, and is crossed by the masseteric vessels and nerve. 10

Ossification.—The mandible is ossified in the fibrous membrane covering the outer surfaces of Meckel's cartilages. These cartilages form the cartilaginous bar of the mandibular arch (see p. 66), and are two in number, a right and a left. Their proximal or cranial ends are connected with the ear capsules, and their distal extremities are joined to one another at the symphysis by mesodermal tissue. They run forward immediately below the condyles and then, bending downward, lie in a groove near the lower border of the bone; in front of the canine tooth they incline upward to the symphysis. From the proximal end of each cartilage the malleus and incus, two of the bones of the middle ear, are developed; the next succeeding portion, as far as the lingula, is replaced by fibrous tissue, which persists to form the sphenomandibular ligament. Between the lingula and the canine tooth the cartilage disappears, while the portion of it below and behind the incisor teeth becomes ossified and incorporated with this part of the mandible. 11

Ossification takes place in the membrane covering the outer surface of the ventral end of Meckel's cartilage (Figs. 178 to 181), and each half of the bone is formed from a single center which appears, near the mental foramen, about the sixth week of fetal life. By the tenth week the portion of Meckel's cartilage which lies below and behind the incisor teeth is surrounded and invaded by the membrane bone. Somewhat later, accessory nuclei of cartilage make their appearance, viz., a wedge-shaped nucleus in the condyloid process and extending downward through the ramus; a small strip along the anterior border of the coronoid process; and smaller nuclei in the front part of both alveolar walls and along the front of the lower border of the bone. These accessory nuclei possess no separate ossific centers, but are invaded by the surrounding membrane bone and undergo absorption. The inner alveolar border, usually described as arising from a separate ossific center (*splenic center*), is formed in the human mandible by an ingrowth from the main mass of the bone. At birth the bone consists of two parts, united by a fibrous symphysis, in which ossification takes place during the first year. 12

The foregoing description of the ossification of the mandible is based on the researches of Low [44](#) and Fawcett, [45](#) and differs somewhat from that usually given. 13

Articulations.—The mandible articulates with the *two* temporal bones. 14

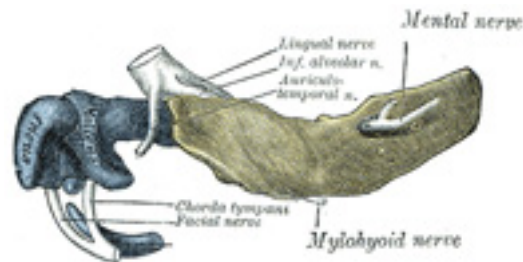


FIG. 178—Mandible of human embryo 24 mm. long. Outer aspect. (From model by Low.) ([See enlarged image](#))

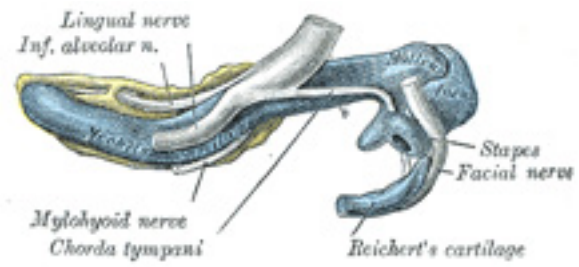


FIG. 179– Mandible of human embryo 24 mm. long. Inner aspect. (From model by Low.) ([See enlarged image](#))

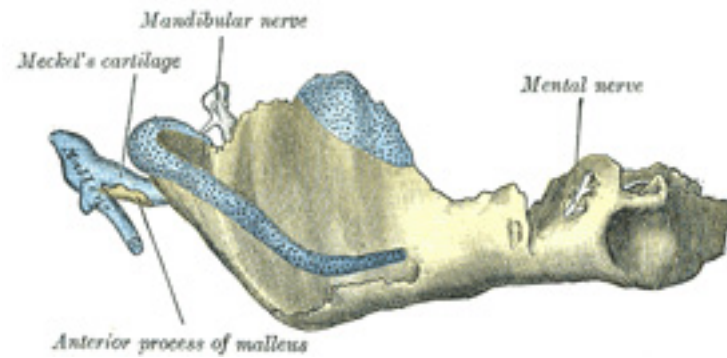


FIG. 180– Mandible of human embryo 95 mm. long. Outer aspect. Nuclei of cartilage stippled. (From model by Low.) ([See enlarged image](#))

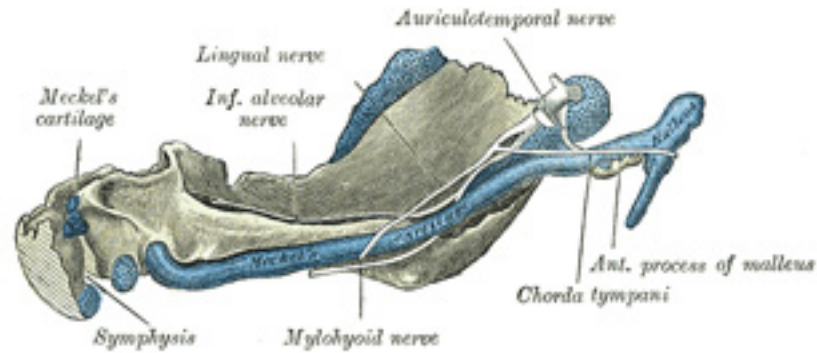


FIG. 181– Mandible of human embryo 95 mm. long. Inner aspect. Nuclei of cartilage stippled. (From model by Low.) ([See enlarged image](#))

Changes Produced in the Mandible by Age At birth (Fig. 182) the body of the bone is a mere shell, containing the sockets of the two incisor, the canine, and the two deciduous molar teeth, imperfectly partitioned off from one another. The mandibular canal is of large size, and runs near the lower border of the bone; the mental foramen opens beneath the socket of the first deciduous molar tooth. The angle is obtuse (175°), and the condyloid portion is nearly in line with the body. The coronoid process is of comparatively large size, and projects above the level of the condyle.

15

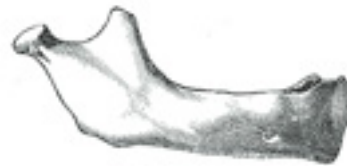

FIG. 182– At birth. ([See enlarged image](#))

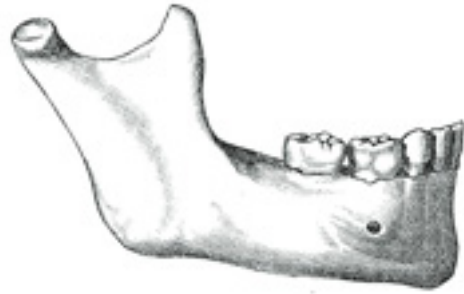


FIG. 183– In childhood. ([See enlarged image](#))

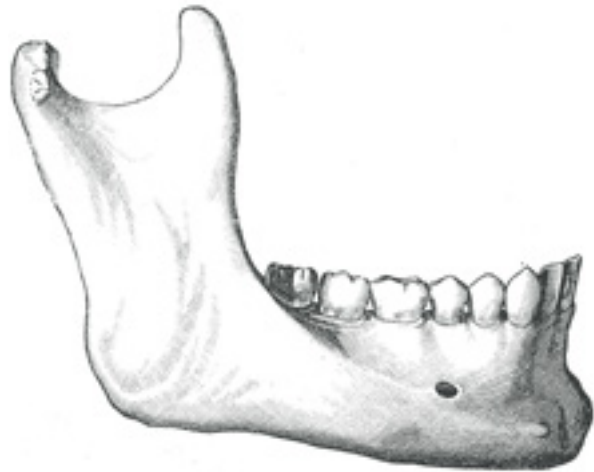


FIG. 184– In the adult. ([See enlarged image](#))

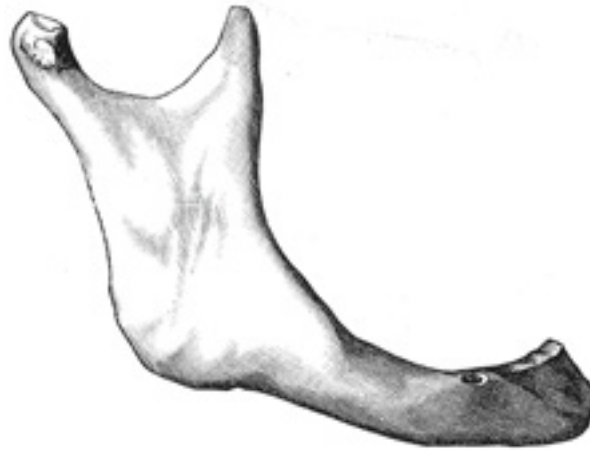

FIG. 185– In old age. Side view of the mandible at different periods of life. ([See enlarged image](#))

After birth ([Fig. 183](#)) the two segments of the bone become joined at the symphysis, from below upward, in the first year; but a trace of separation may be visible in the beginning of the second year, near the alveolar margin. The body becomes elongated in its whole length, but more especially behind the mental foramen, to provide space for the three additional teeth developed in this part. The depth of the body increases owing to increased growth of the alveolar part, to afford room for the roots of the teeth, and by thickening of the subdental portion which enables the jaw to withstand the powerful action of the masticatory muscles; but the alveolar portion is the deeper of the two, and, consequently, the chief part of the body lies above the oblique line. The mandibular canal, after the second dentition, is situated just above the level of the mylohyoid line; and the mental foramen occupies the position usual to it in the adult. The angle becomes less obtuse, owing to the separation of the jaws by the teeth; about the fourth year it is 140° . 16

In the adult ([Fig. 184](#)) the alveolar and subdental portions of the body are usually of equal depth. The mental foramen opens midway between the upper and lower borders of the bone, and the mandibular canal runs nearly parallel with the mylohyoid line. The ramus is almost vertical in direction, the angle measuring from 110° to 120° . 17

In old age ([Fig. 185](#)) the bone becomes greatly reduced in size, for with the loss of the teeth the alveolar process is absorbed, and, consequently, the chief part of the bone is below the oblique line. The mandibular canal, with the mental foramen opening from it, is close to the alveolar border. The ramus is oblique in direction, the angle measures about 140° , and the neck of the condyle is more or less bent backward. 18

Note 44. Proceedings of the Anatomical and Anthropological Society of the University of Aberdeen, 1905, and Journal of Anatomy and Physiology, vol. xlv. [[back](#)]

Note 45. Journal of the American Medical Association, September 2, 1905. [[back](#)]

5b. 9. The Hyoid Bone

(Os Hyoideum; Lingual Bone)

1

The **hyoid bone** is shaped like a horseshoe, and is suspended from the tips of the styloid processes of the temporal bones by the stylohyoid ligaments. It consists of five segments, viz., a **body**, two **greater cornua**, and two **lesser cornua**.

The Body or Basihyal (*corpus oss. hyoidei*).—The body or central part is of a quadrilateral form. Its **anterior surface** (Fig. 186) is convex and directed forward and upward. It is crossed in its upper half by a well-marked transverse ridge with a slight downward convexity, and in many cases a vertical median ridge divides it into two lateral halves. The portion of the vertical ridge above the transverse line is present in a majority of specimens, but the lower portion is evident only in rare cases. The anterior surface gives insertion to the Geniohyoideus in the greater part of its extent both above and below the transverse ridge; a portion of the origin of the Hyoglossus notches the lateral margin of the Geniohyoideus attachment. Below the transverse ridge the Mylohyoideus, Sternohyoideus, and Omohyoideus are inserted. The **posterior surface** is smooth, concave, directed backward and downward, and separated from the epiglottis by the hyothyroid membrane and a quantity of loose areolar tissue; a bursa intervenes between it and the hyothyroid membrane. The **superior border** is rounded, and gives attachment to the hyothyroid membrane and some aponeurotic fibers of the Genioglossus. The **inferior border** affords insertion medially to the Sternohyoideus and laterally to the Omohyoideus and occasionally a portion of the Thyreohyoideus. It also gives attachment to the Levator glandulæ thyreoideæ, when this muscle is present. In early life the **lateral borders** are connected to the greater cornua by synchondroses; after middle life usually by bony union.

2

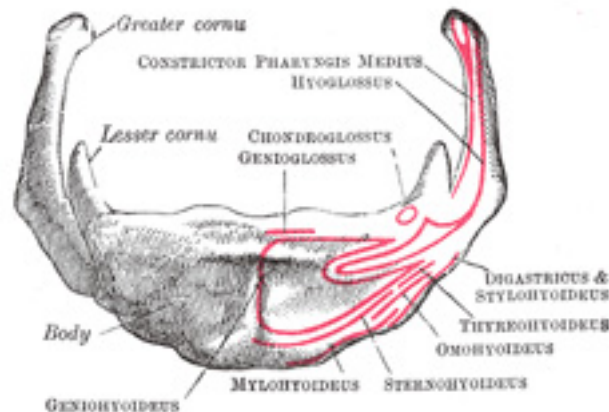


FIG. 186— Hyoid bone. Anterior surface. Enlarged. ([See enlarged image](#))

The Greater Cornua or Thyrohyals (*cornua majora*).—The greater cornua project backward from the lateral borders of the body; they are flattened from above downward and diminish in size from before backward; each ends in a tubercle to which is fixed the lateral hyothyroid ligament. The **upper surface** is rough close to its lateral border, for muscular attachments: the largest of these are the origins of the Hyoglossus and Constrictor pharyngis medius which extend along the whole length of the cornu; the Digastricus and Stylohyoideus have small insertions in front of these near the junction of the body with the cornu. To the **medial border** the hyothyroid membrane is attached, while the anterior half of the **lateral border** gives insertion to the Thyreohyoideus. 3

The Lesser Cornua or Ceratohyals (*cornua minora*).—The lesser cornua are two small, conical eminences, attached by their bases to the angles of junction between the body and greater cornua. They are connected to the body of the bone by fibrous tissue, and occasionally to the greater cornua by distinct diarthrodial joints, which usually persist throughout life, but occasionally become ankylosed. 4

The lesser cornua are situated in the line of the transverse ridge on the body and appear to be morphological continuations of it (Parsons [46](#)). The apex of each cornu gives attachment to the stylohyoid ligament; [47](#) the Chondroglossus rises from the medial side of the base. 5

Ossification.—The hyoid is ossified from *six* centers: two for the body, and one for each cornu. Ossification commences in the greater cornua toward the end of fetal life, in the body shortly afterward, and in the lesser cornua during the first or second year after birth. 6

Note 46. See article on “The Topography and Morphology of the Human Hyoid Bone,” by F. G. Parsons, Journal of Anatomy and Physiology, vol. xliii. [[back](#)]

Note 47. These ligaments in many animals are distinct bones, and in man may undergo partial ossification. [[back](#)]

5c. The Exterior of the Skull

The skull as a whole may be viewed from different points, and the views so obtained are termed the **normæ** of the skull; thus, it may be examined from above (**norma verticalis**), from below (**norma basalis**), from the side (**norma lateralis**), from behind (**norma occipitalis**), or from the front (**norma frontalis**). 1

Norma Verticalis.—When viewed from above the outline presented varies greatly in different skulls; in some it is more or less oval, in others more nearly circular. The surface is traversed by three sutures, viz.: (1) the **coronal sutures**, nearly transverse in direction, between the frontal and parietals; (2) the **sagittal sutures**, medially placed, between the parietal bones, and deeply serrated in its anterior two-thirds; and (3) the upper part of the **lambdoidal suture**, between the parietals and the occipital. The point of junction of the sagittal and coronal suture is named 2

the **bregma**, that of the sagittal and lambdoid sutures, the **lambda**; they indicate respectively the positions of the anterior and posterior fontanelles in the fetal skull. On either side of the sagittal suture are the **parietal eminence** and **parietal foramen**—the latter, however, is frequently absent on one or both sides. The skull is often somewhat flattened in the neighborhood of the parietal foramina, and the term **obelion** is applied to that point of the sagittal suture which is on a level with the foramina. In front is the **glabella**, and on its lateral aspects are the **superciliary arches**, and above these the **frontal eminences**. Immediately above the glabella may be seen the remains of the **frontal suture**; in a small percentage of skulls this suture persists and extends along the middle line to the bregma. Passing backward and upward from the zygomatic processes of the frontal bone are the **temporal lines**, which mark the upper limits of the temporal fossæ. The zygomatic arches may or may not be seen projecting beyond the anterior portions of these lines.

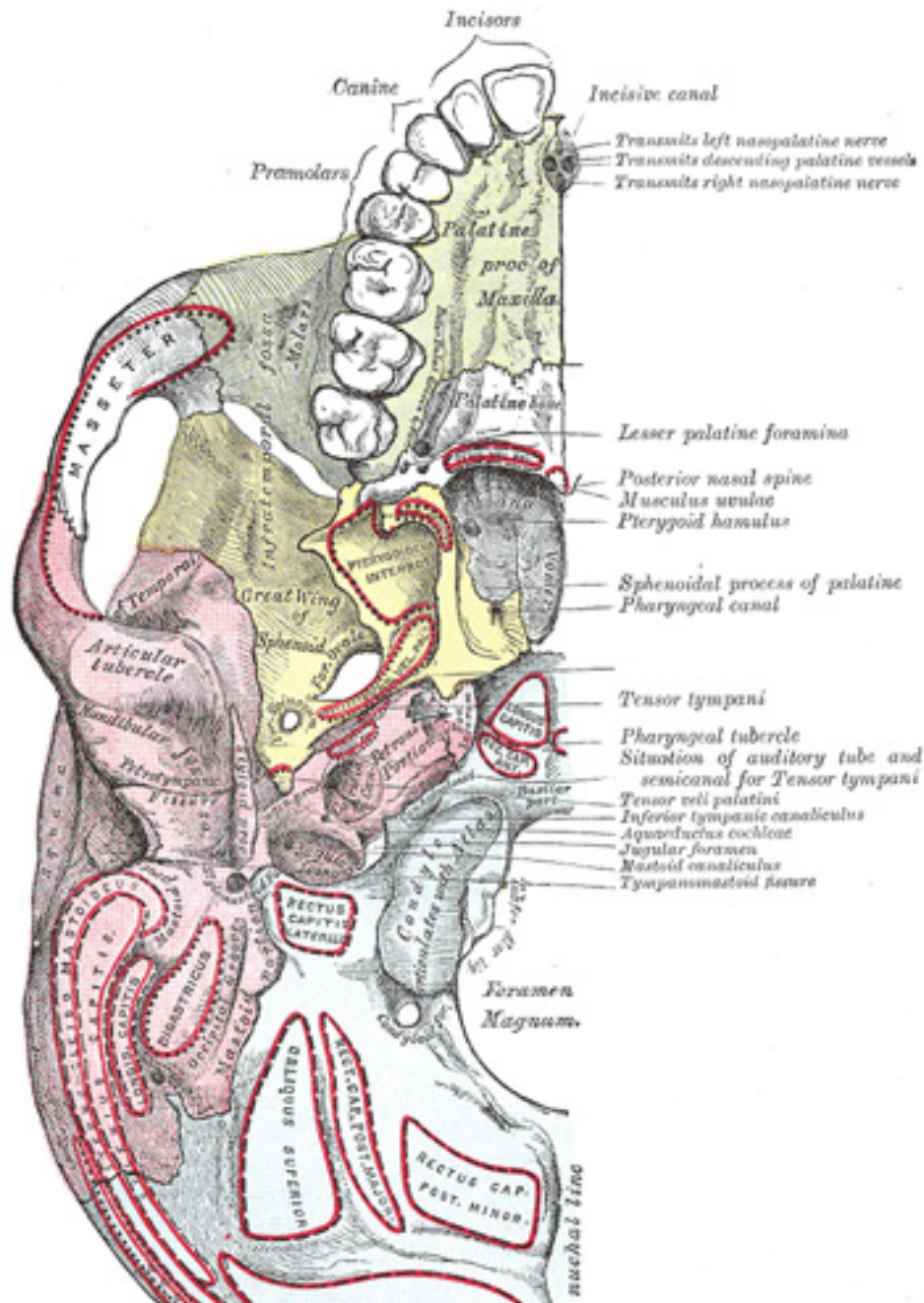


FIG. 187— Base of skull. Inferior surface. ([See enlarged image](#))

Norma Basalis (Fig. 187).—The inferior surface of the base of the skull, exclusive of the mandible, is bounded in front by the incisor teeth in the maxillæ; behind, by the superior nuchal lines of the occipital; and laterally by the alveolar arch, the lower border of the zygomatic bone, the zygomatic arch and an imaginary line extending from it to the mastoid process and extremity of the superior nuchal line of the occipital. It is formed by the palatine processes of the maxillæ and palatine bones, the vomer, the pterygoid processes, the under surfaces of the great wings, spinous processes, and part of the body of the sphenoid, the under surfaces of the squamæ and mastoid and petrous portions of the temporals, and the under surface of the occipital bone. The anterior part or hard palate projects below the level of the rest of the surface, and is bounded in front and laterally by the alveolar arch containing the sixteen teeth of the maxillæ. Immediately behind the incisor teeth is the **incisive foramen**. In this foramen are two lateral apertures, the openings of the **incisive canals** (*foramina of Stenson*) which transmit the anterior branches of the descending palatine vessels, and the nasopalatine nerves. Occasionally two additional canals are present in the incisive foramen; they are termed the **foramina of Scarpa** and are situated in the middle line; when present they transmit the nasopalatine nerves. The vault of the hard palate is concave, uneven, perforated by numerous foramina, marked by depressions for the palatine glands, and traversed by a crucial suture formed by the junction of the four bones of which it is composed. In the young skull a suture may be seen extending on either side from the incisive foramen to the interval between the lateral incisor and canine teeth, and marking off the os incisivum or premaxillary bone. At either posterior angle of the hard palate is the **greater palatine foramen**, for the transmission of the descending palatine vessels and anterior palatine nerve; and running forward and medialward from it a groove, for the same vessels and nerve. Behind the posterior palatine foramen is the **pyramidal process of the palatine bone**, perforated by one or more **lesser palatine foramina**, and marked by the commencement of a transverse ridge, for the attachment of the tendinous expansion of the Tensor veli palatini. Projecting backward from the center of the posterior border of the hard palate is the **posterior nasal spine**, for the attachment of the Musculus uvulæ. Behind and above the hard palate are the **choanæ**, measuring about 2.5 cm. in their vertical and 1.25 cm. in their transverse diameters. They are separated from one another by the vomer, and each is bounded above by the body of the sphenoid, below by the horizontal part of the palatine bone, and laterally by the medial pterygoid plate of the sphenoid. At the superior border of the vomer may be seen the expanded alæ of this bone, receiving between them the rostrum of the sphenoid. Near the lateral margins of the alæ of the vomer, at the roots of the pterygoid processes, are the **pharyngeal canals**. The pterygoid process presents near its base the **pterygoid canal**, for the transmission of a nerve and artery. The medial pterygoid plate is long and narrow; on the lateral side of its base is the **scaphoid fossa**, for the origin of the Tensor veli palatini, and at its lower extremity the **hamulus**, around which the tendon of this muscle turns. The lateral pterygoid plate is broad; its lateral surface forms the medial boundary of the infratemporal fossa, and affords attachment to the Pterygoideus externus.

Behind the nasal cavities is the basilar portion of the occipital bone, presenting near its center the **pharyngeal tubercle** for the attachment of the fibrous raphé of the pharynx, with depressions on either side for the insertions of the Rectus capitis anterior and Longus capitis. At the base of the lateral pterygoid plate is the **foramen ovale**, for the transmission of the mandibular nerve, the accessory meningeal artery, and sometimes the lesser superficial petrosal nerve; behind this are the **foramen spinosum** which transmits the middle meningeal vessels, and the prominent **spina angularis** (*sphenoidal spine*), which gives attachment to the sphenomandibular ligament and the Tensor veli palatini. Lateral to the spina angularis is the **mandibular fossa**, divided into two parts by the **petrotympanic fissure**; the anterior portion, concave, smooth

bounded in front by the **articular tubercle**, serves for the articulation of the condyle of the mandible; the posterior portion, rough and bounded behind by the tympanic part of the temporal, is sometimes occupied by a part of the parotid gland. Emerging from between the laminae of the vaginal process of the tympanic part is the **styloid process**; and at the base of this process is the **stylomastoid foramen**, for the exit of the facial nerve, and entrance of the stylomastoid artery. Lateral to the stylomastoid foramen, between the tympanic part and the mastoid process, is the **tympanomastoid fissure**, for the auricular branch of the vagus. Upon the medial side of the mastoid process is the **mastoid notch** for the posterior belly of the Digastricus, and medial to the notch, the **occipital groove** for the occipital artery. At the base of the medial pterygoid plate is a large and somewhat triangular aperture, the **foramen lacerum**, bounded in front by the great wing of the sphenoid, behind by the apex of the petrous portion of the temporal bone, and medially by the body of the sphenoid and basilar portion of the occipital bone; it presents in front the posterior orifice of the **pterygoid canal**; behind, the aperture of the **carotid canal**. The lower part of this opening is filled up in the fresh state by a fibrocartilaginous plate, across the upper or cerebral surface of which the internal carotid artery passes. Lateral to this aperture is a groove, the **sulcus tubæ auditivæ**, between the petrous part of the temporal and the great wing of the sphenoid. This sulcus is directed lateralward and backward from the root of the medial pterygoid plate and lodges the cartilaginous part of the auditory tube; it is continuous behind with the canal in the temporal bone which forms the bony part of the same tube. At the bottom of this sulcus is a narrow cleft, the **petrosphenoidal fissure**, which is occupied, in the fresh condition, by a plate of cartilage. Behind this fissure is the under surface of the petrous portion of the temporal bone, presenting, near its apex, the quadrilateral rough surface, part of which affords attachment to the Levator veli palatini; lateral to this surface is the orifice of the **carotid canal**, and medial to it, the depression leading to the **aquæductus cochleæ**, the former transmitting the internal carotid artery and the carotid plexus of the sympathetic, the latter serving for the passage of a vein from the cochlea. Behind the carotid canal is the **jugular foramen**, a large aperture, formed in front by the petrous portion of the temporal, and behind by the occipital; it is generally larger on the right than on the left side, and may be subdivided into three compartments. The anterior compartment transmits the inferior petrosal sinus; the intermediate, the glossopharyngeal, vagus, and accessory nerves; the posterior, the transverse sinus and some meningeal branches from the occipital and ascending pharyngeal arteries. On the ridge of bone dividing the carotid canal from the jugular foramen is the **inferior tympanic canaliculus** for the transmission of the tympanic branch of the glossopharyngeal nerve; and on the wall of the jugular foramen, near the root of the styloid process, is the **mastoid canaliculus** for the passage of the auricular branch of the vagus nerve. Extending forward from the jugular foramen to the foramen lacerum is the **petrooccipital fissure** occupied, in the fresh state, by a plate of cartilage. Behind the basilar portion of the occipital bone is the **foramen magnum**, bounded laterally by the occipital condyles, the medial sides of which are rough for the attachment of the alar ligaments. Lateral to each condyle is the **jugular process** which gives attachment to the Rectus capitis lateralis muscle and the lateral atlantooccipital ligament. The foramen magnum transmits the medulla oblongata and its membranes, the accessory nerves, the vertebral arteries, the anterior and posterior spinal arteries, and the ligaments connecting the occipital bone with the axis. The mid-points on the anterior and posterior margins of the foramen magnum are respectively termed the **basion** and the **opisthion**. In front of each condyle is the canal for the passage of the hypoglossal nerve and a meningeal artery. Behind each condyle is the **condyloid fossa**, perforated on one or both sides by the condyloid canal, for the transmission of a vein from the transverse sinus. Behind the foramen magnum is the **median nuchal line** ending above at the **external occipital protuberance**, while on either side are the **superior** and **inferior nuchal lines**; these, as well as the surfaces of bone between them, are rough for the attachment of the muscles which are enumerated on pages 129 and 130.

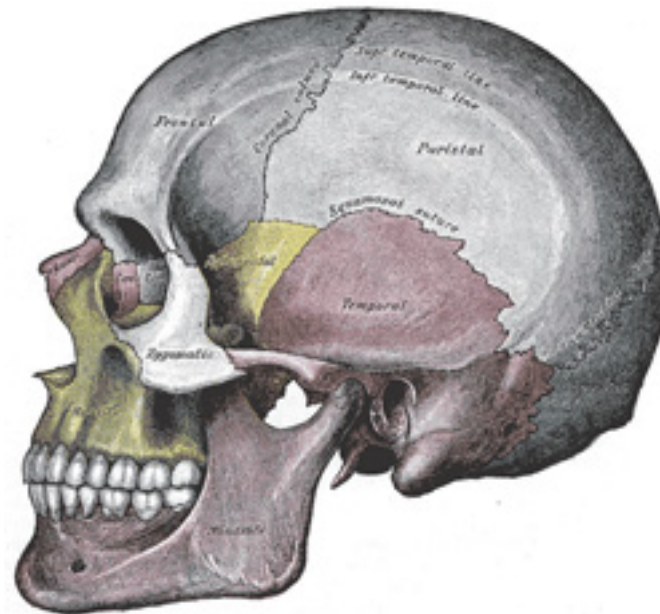


FIG. 188— Side view of the skull. ([See enlarged image](#))

Norma Lateralis (Fig. 188).—When viewed from the side the skull is seen to consist of the cranium above and behind, and of the face below and in front. The cranium is somewhat ovoid in shape, but its contour varies in different cases and depends largely on the length and height of the skull and on the degree of prominence of the superciliary arches and frontal eminences. Entering into its formation are the frontal, the parietal, the occipital, the temporal, and the great wing of the sphenoid. These bones are joined to one another and to the zygomatic by the following **sutures**: the **zygomaticotemporal** between the zygomatic process of the temporal and the temporal process of the zygomatic; the **zygomaticofrontal** uniting the zygomatic bone with the zygomatic process of the frontal; the sutures surrounding the great wing of the sphenoid, viz., the **sphenozygomatic** in front, the **sphenofrontal** and **sphenoparietal** above, and the **sphenosquamosal** behind. The sphenoparietal suture varies in length in different skulls, and is absent in those cases where the frontal articulates with the temporal squama. The point corresponding with the posterior end of the sphenoparietal suture is named the **pterion**; it is situated about 3 cm. behind, and a little above the level of the zygomatic process of the frontal bone.

The **squamosal suture** arches backward from the pterion and connects the temporal squama with the lower border of the parietal: this suture is continuous behind with the short, nearly horizontal **parietomastoid suture**, which unites the mastoid process of the temporal with the region of

the mastoid angle of the parietal. Extending from above downward and forward across the cranium are the **coronal** and **lambdoidal sutures**; the former connects the parietals with the frontal, the latter, the parietals with the occipital. The lambdoidal suture is continuous below with the **occipitomastoid suture** between the occipital and the mastoid portion of the temporal. In or near the last suture is the **mastoid foramen**, for the transmission of an emissary vein. The point of meeting of the parietomastoid, occipitomastoid, and lambdoidal sutures is known as the **asterion**. Immediately above the orbital margin is the **superciliary arch**, and, at a higher level, the **frontal eminence**. Near the center of the parietal bone is the **parietal eminence**. Posteriorly is the **external occipital protuberance**, from which the superior nuchal line may be followed forward to the mastoid process. Arching across the side of the cranium are the **temporal lines**, which mark the upper limit of the temporal fossa.

The Temporal Fossa (*fossa temporalis*).—The temporal fossa is bounded above and behind by the temporal lines, which extend from the zygomatic process of the frontal bone upward and backward across the frontal and parietal bones, and then curve downward and forward to become continuous with the supramastoid crest and the posterior root of the zygomatic arch. The point where the upper temporal line cuts the coronal suture is named the **stephanion**. The temporal fossa is bounded in *front* by the frontal and zygomatic bones, and opening on the back of the latter is the **zygomaticotemporal foramen**. *Laterally* the fossa is limited by the zygomatic arch, formed by the zygomatic and temporal bones; *below*, it is separated from the infratemporal fossa by the **infratemporal crest** on the great wing of the sphenoid, and by a ridge, continuous with this crest, which is carried backward across the temporal squama to the anterior root of the zygomatic process. In front and below, the fossa communicates with the orbital cavity through the **inferior orbital or sphenomaxillary fissure**. The floor of the fossa is deeply concave in front and convex behind, and is formed by the zygomatic, frontal, parietal, sphenoid, and temporal bones. It is traversed by vascular furrows; one, usually well-marked, runs upward above and in front of the external acoustic meatus, and lodges the middle temporal artery. Two others, frequently indistinct, may be observed on the anterior part of the floor, and are for the anterior and posterior deep temporal arteries. The temporal fossa contains the Temporalis muscle and its vessels and nerves, together with the zygomaticotemporal nerve.

The **zygomatic arch** is formed by the zygomatic process of the temporal and the temporal process of the zygomatic, the two being united by an oblique suture; the tendon of the Temporalis passes medial to the arch to gain insertion into the coronoid process of the mandible. The zygomatic process of the temporal arises by two roots, an anterior, directed inward in front of the mandibular fossa, where it expands to form the articular tubercle, and a posterior, which runs backward above the external acoustic meatus and is continuous with the supramastoid crest. The upper border of the arch gives attachment to the temporal fascia; the lower border and medial surface give origin to the Masseter.

Below the posterior root of the zygomatic arch is the elliptical orifice of the **external acoustic meatus**, bounded in front, below, and behind by the tympanic part of the temporal bone; to its outer margin the cartilaginous segment of the external acoustic meatus is attached. The small triangular area between the posterior root of the zygomatic arch and the postero-superior part of the orifice is termed the **suprameatal triangle**, on the anterior border of which a small spinous process, the **suprameatal spine**, is sometimes seen. Between the tympanic part and the articular tubercle is the **mandibular fossa**, divided into two parts by the petrotympanic fissure. The anterior and larger part of the fossa articulates with the condyle of the mandible and is limited behind by the external acoustic meatus: the posterior part sometimes lodges a portion of the parotid gland. The styloid process extends downward and forward for a variable distance from the lower part of the tympanic part, and gives attachment to the Styloglossus, Stylohyoideus, and Stylopharyngeus, and to the stylohyoid and stylomandibular ligaments. Projecting downward behind the external acoustic meatus is the mastoid process, to the outer surface of which the Sternocleidomastoideus, Splenius capitis, and Longissimus capitis are attached.

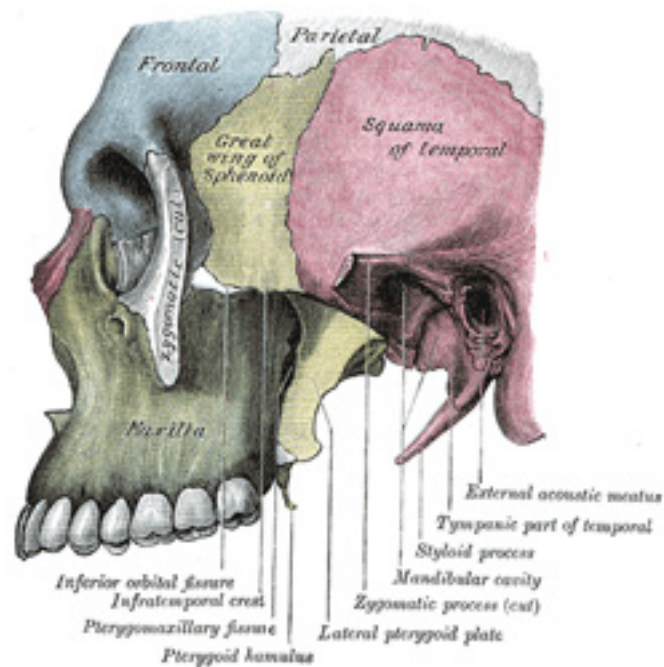


FIG. 189— Left infratemporal fossa. ([See enlarged image](#))

The Infratemporal Fossa (*fossa infratemporalis*; *zygomatic fossa*) ([Fig. 189](#)).—The infratemporal fossa is an irregularly shaped cavity, situated below and medial to the **zygomatic arch**. It is bounded, in *front*, by the infratemporal surface of the maxilla and the ridge which descends from its zygomatic process; *behind*, by the articular tubercle of the temporal and the spinal angularis of the sphenoid; *above*, by the great wing of the sphenoid below the infratemporal crest, and by the under surface of the temporal squama; *below*, by the alveolar border of the maxilla; *medially*, by the lateral pterygoid plate. It contains the lower part of the Temporalis, the Pterygoidei internus and externus, the internal maxillary vessels, and the mandibular and maxillary nerves. The **foramen ovale** and **foramen spinosum** open on its roof, and the **alveolar canals** on its anterior wall. At its upper and medial part are two fissures, which together form a T-shaped fissure, the horizontal limb being named the inferior orbital, and the vertical one the pterygomaxillary.

The **inferior orbital fissure** (*fissura orbitalis inferior*; *sphenomaxillary fissure*), horizontal in direction, opens into the lateral and back part of the orbit. It is bounded *above* by the lower border of the orbital surface of the great wing of the sphenoid; *below*, by the lateral border of the

10

11

orbital surface of the maxilla and the orbital process of the palatine bone; *laterally*, by a small part of the zygomatic bone: [48](#) *medially*, it joins at right angles with the pterygomaxillary fissure. Through the inferior orbital fissure the orbit communicates with the temporal, infratemporal, and pterygopalatine fossæ; the fissure transmits the maxillary nerve and its zygomatic branch, the infraorbital vessels, the ascending branches from the sphenopalatine ganglion, and a vein which connects the inferior ophthalmic vein with the pterygoid venous plexus.

The **pterygomaxillary fissure** is vertical, and descends at right angles from the medial end of the preceding; it is a triangular interval, formed by the divergence of the maxilla from the pterygoid process of the sphenoid. It connects the infratemporal with the pterygopalatine fossa, and transmits the terminal part of the internal maxillary artery. 12

The Pterygopalatine Fossa (*fossa pterygopalatina; sphenomaxillary fossa*).—The pterygopalatine fossa is a small, triangular space at the angle of junction of the inferior orbital and pterygomaxillary fissures, and placed beneath the apex of the orbit. It is bounded *above* by the under surface of the body of the sphenoid and by the orbital process of the palatine bone; *in front*, by the infratemporal surface of the maxilla; *behind*, by the base of the pterygoid process and lower part of the anterior surface of the great wing of the sphenoid; *medially*, by the vertical part of the palatine bone with its orbital and sphenoidal processes. This fossa communicates with the orbit by the inferior orbital fissure, with the nasal cavity by the sphenopalatine foramen, and with the infratemporal fossa by the pterygomaxillary fissure. Five foramina open into it. Of these, three are on the posterior wall, viz., the **foramen rotundum**, the **pterygoid canal**, and the **pharyngeal canal**, in this order downward and medialward. On the medial wall is the **sphenopalatine foramen**, and below is the superior orifice of the **pterygopalatine canal**. The fossa contains the maxillary nerve, the sphenopalatine ganglion, and the terminal part of the internal maxillary artery. 13

Norma Occipitalis.—When viewed from behind the cranium presents a more or less circular outline. In the middle line is the posterior part of the **sagittal suture** connecting the parietal bones; extending downward and lateralward from the hinder end of the sagittal suture is the deeply serrated **lambdoidal suture** joining the parietals to the occipital and continuous below with the **parietomastoid** and **occipitomastoid sutures**; it frequently contains one or more sutural bones. Near the middle of the occipital squama is the **external occipital protuberance** or **inion**, and extending lateralward from it on either side is the superior nuchal line, and above this the faintly marked highest nuchal line. The part of the squama above the inion and highest lines is named the **planum occipitale**, and is covered by the Occipitalis muscle; the part below is termed the **planum nuchale**, and is divided by the median nuchal line which runs downward and forward from the inion to the foramen magnum; this ridge gives attachment to the ligamentum nuchæ. The muscles attached to the planum nuchale are enumerated on p. 130. Below and in front are the mastoid processes, convex laterally and grooved medially by the mastoid notches. In or near the occipitomastoid suture is the **mastoid foramen** for the passage of the mastoid emissary vein. 14

Norma Frontalis (Fig. 190).—When viewed from the front the skull exhibits a somewhat oval outline, limited *above* by the frontal bone, *below* by the body of the mandible, and *laterally* by the zygomatic bones and the mandibular rami. The upper part, formed by the frontal squama, is smooth and convex. The lower part, made up of the bones of the face, is irregular; it is excavated laterally by the orbital cavities, and presents in the middle line the **anterior nasal aperture** leading to the nasal cavities, and below this the transverse slit between the upper and lower dental arcades. *Above*, the **frontal eminences** stand out more or less prominently, and beneath these are the **superciliary arches**, joined to one another in the middle by the **glabella**. On and above the glabella a trace of the **frontal sutures** sometimes persists; beneath it is the frontonasal suture, the mid-point of which is termed the **nasion**. Behind and below the frontonasal suture the frontal articulates with the frontal process of the 15

maxilla and with the lacrimal. Arching transversely below the superciliary arches is the upper part of the margin of the orbit, thin and prominent in its lateral two-thirds, rounded in its medial third, and presenting, at the junction of these two portions, the **supraorbital notch** or **foramen** for the supraorbital nerve and vessels. The supraorbital margin ends laterally in the zygomatic process which articulates with the zygomatic bone, and from it the temporal line extends upward and backward. Below the frontonasal suture is the bridge of the nose, convex from side to side, concavo-convex from above downward, and formed by the two nasal bones supported in the middle line by the perpendicular plate of the ethmoid, and laterally by the frontal processes of the maxillæ which are prolonged upward between the nasal and lacrimal bones and form the lower and medial part of the circumference of each orbit. Below the nasal bones and between the maxillæ is the anterior aperture of the nose, pyriform in shape, with the narrow end directed upward. Laterally this opening is bounded by sharp margins, to which the lateral and alar cartilages of the nose are attached; *below*, the margins are thicker and curve medialward and forward to end in the **anterior nasal spine**. On looking into the nasal cavity, the bony septum which separates the nasal cavities presents, in front, a large triangular deficiency; this, in the fresh state, is filled up by the cartilage of the nasal septum; on the lateral wall of each nasal cavity the anterior part of the inferior nasal concha is visible. Below and lateral to the anterior nasal aperture are the anterior surfaces of the maxillæ, each perforated, near the lower margin of the orbit, by the **infraorbital foramen** for the passage of the infraorbital nerve and vessels. Below and medial to this foramen is the canine eminence separating the incisive from the canine fossa. Beneath these fossæ are the alveolar processes of the maxillæ containing the upper teeth, which overlap the teeth of the mandible in front. The zygomatic bone on either side forms the prominence of the cheek, the lower and lateral portion of the orbital cavity, and the anterior part of the zygomatic arch. It articulates medially with the maxilla, behind with the zygomatic process of the temporal, and above with the great wing of the sphenoid and the zygomatic process of the frontal; it is perforated by the **zygomaticofacial foramen** for the passage of the zygomaticofacial nerve. On the body of the mandible is a median ridge, indicating the position of the symphysis; this ridge divides below to enclose the mental protuberance, the lateral angles of which constitute the mental tubercles. Below the incisor teeth is the **incisive fossa**, and beneath the second premolar tooth the **mental foramen** which transmits the mental nerve and vessels. The oblique line runs upward from the mental tubercle and is continuous behind with the anterior border of the ramus. The posterior border of the ramus runs downward and forward from the condyle to the angle, which is frequently more or less everted.

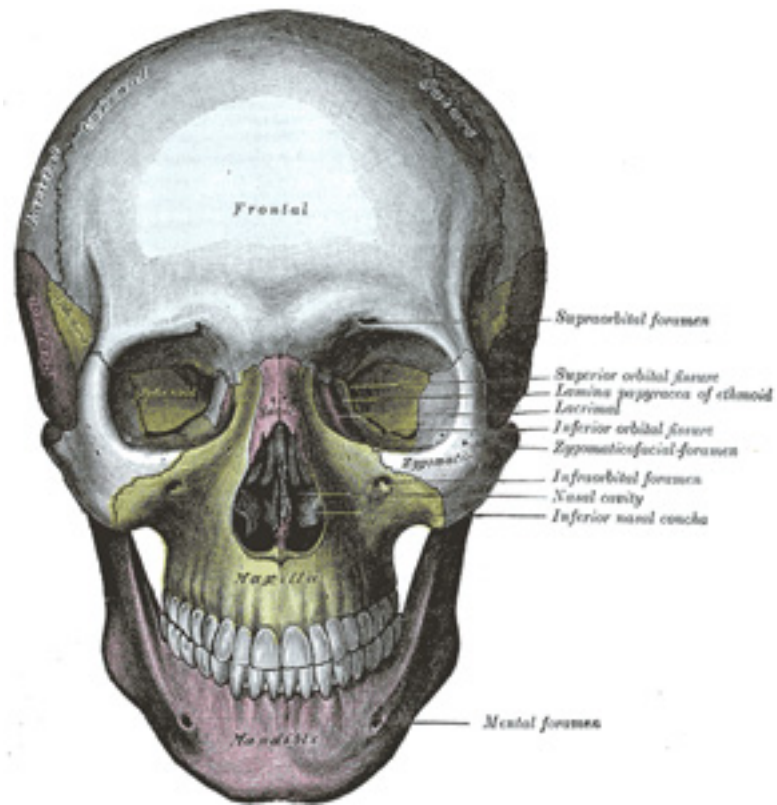


FIG. 190— The skull from the front. ([See enlarged image](#))

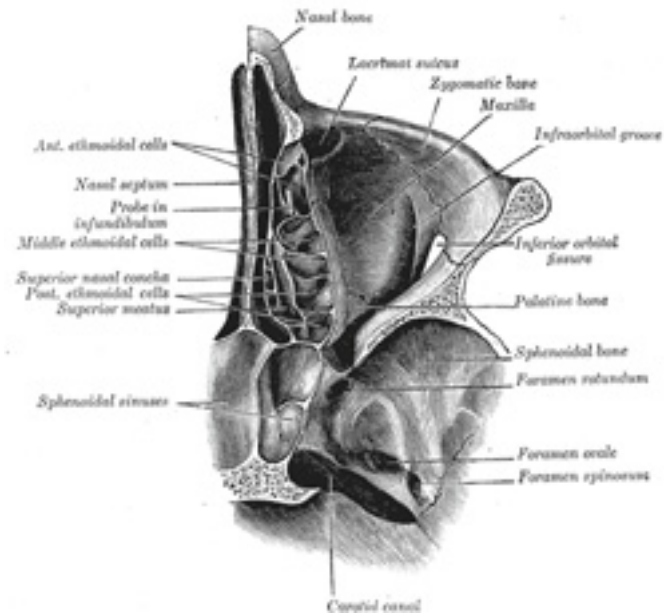


FIG. 191— Horizontal section of nasal and orbital cavities. ([See enlarged image](#))

The Orbits (*orbitæ*) (Fig. 190).—The orbits are two quadrilateral pyramidal cavities, situated at the upper and anterior part of the face, their bases being directed forward and lateralward, and their apices backward and medialward, so that their long axes, if continued backward, would meet over the body of the sphenoid. Each presents for examination **roof**, a **floor**, a **medial** and a **lateral wall**, a **base**, and an **apex**.

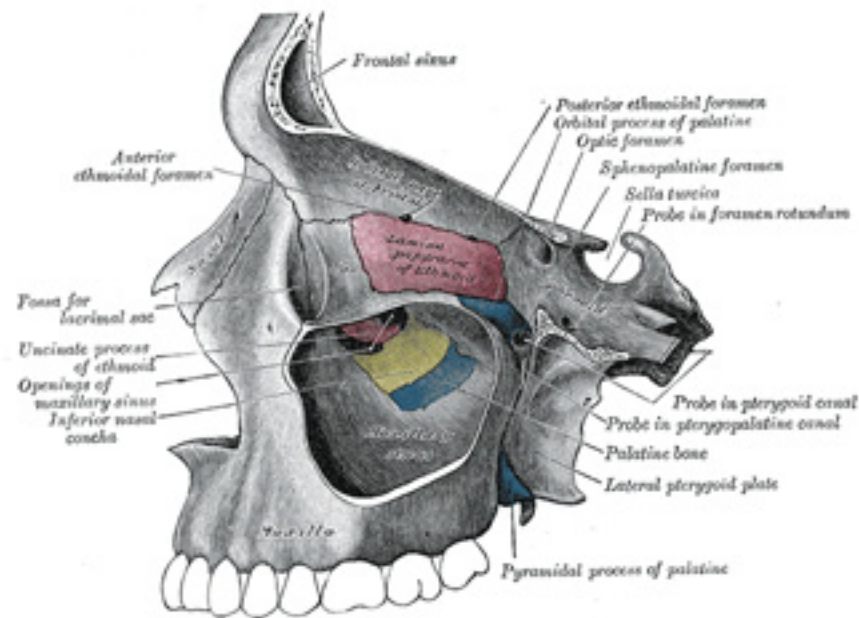


FIG. 192– Medial wall of left orbit. ([See enlarged image](#))

The **roof** is concave, directed downward, and slightly forward, and formed in *front* by the orbital plate of the frontal; *behind* by the small wing of the sphenoid. It presents *medially* the **trochlear fovea** for the attachment of the cartilaginous pulley of the Obliquus oculi superior; *laterally*, the **lacrimal fossa** for the lacrimal gland; and *posteriorly*, the suture between the frontal bone and the small wing of the sphenoid. 17

The **floor** is directed upward and lateralward, and is of less extent than the roof; it is formed chiefly by the orbital surface of the maxilla; in *front* and *laterally*, by the orbital process of the zygomatic bone, and *behind* and *medially*, to a small extent, by the orbital process of the palatine. At its medial angle is the upper opening of the nasolacrimal canal, immediately to the lateral side of which is a depression for the origin of the Obliquus oculi inferior. On its lateral part is the suture between the maxilla and zygomatic bone, and at its posterior part that between the maxilla and the orbital process of the palatine. Running forward near the middle of the floor is the **infraorbital groove**, ending in front in the infraorbital canal and transmitting the infraorbital nerve and vessels. 18

The **medial wall** ([Fig. 192](#)) is nearly vertical, and is formed from before backward by the frontal process of the maxilla, the lacrimal, the lamina papyracea of the ethmoid, and a small part of the body of the sphenoid in front of the optic foramen. Sometimes the sphenoidal concha forms a small part of this wall (see page 152). It exhibits three vertical sutures, viz., the lacrimomaxillary, lacrimoethmoidal, and sphenoeethmoidal. In 19

front is seen the **lacrimal groove**, which lodges the lacrimal sac, and behind the groove is the **posterior lacrimal crest**, from which the lacrimal part of the Orbicularis oculi arises. At the junction of the medial wall and the roof are the frontomaxillary, frontolacrimal, frontoethmoidal, and sphenofrontal sutures. The point of junction of the anterior border of the lacrimal with the frontal is named the **dacryon**. In the frontoethmoidal suture are the **anterior** and **posterior ethmoidal foramina**, the former transmitting the nasociliary nerve and anterior ethmoidal vessels, the latter the posterior ethmoidal nerve and vessels.

The **lateral wall**, directed medialward and forward, is formed by the orbital process of the zygomatic and the orbital surface of the great wing of the sphenoid; these are united by the sphenozygomatic suture which terminates below at the front end of the inferior orbital fissure. On the orbital process of the zygomatic bone are the orbital tubercle (Whitnall) and the orifices of one or two canals which transmit the branches of the zygomatic nerve. Between the roof and the lateral wall, near the apex of the orbit, is the **superior orbital fissure**. Through this fissure the oculomotor, the trochlear, the ophthalmic division of the trigeminal, and the abducent nerves enter the orbital cavity, also some filaments from the cavernous plexus of the sympathetic and the orbital branches of the middle meningeal artery. Passing backward through the fissure are the ophthalmic vein and the recurrent branch from the lacrimal artery to the dura mater. The lateral wall and the floor are separated posteriorly by the **inferior orbital fissure** which transmits the maxillary nerve and its zygomatic branch, the infraorbital vessels, and the ascending branches from the sphenopalatine ganglion. 20

The **base** of the orbit, quadrilateral in shape, is formed *above* by the supraorbital arch of the frontal bone, in which is the **supraorbital notch** or **foramen** for the passage of the supraorbital vessels and nerve; *below* by the zygomatic bone and maxilla, united by the zygomaticomaxillary suture; laterally by the zygomatic bone and the zygomatic process of the frontal joined by the zygomaticofrontal suture; medially by the frontal bone and the frontal process of the maxilla united by the frontomaxillary suture. 21

The **apex**, situated at the back of the orbit, corresponds to the optic foramen [49](#) a short, cylindrical canal, which transmits the optic nerve and ophthalmic artery. 22

It will thus be seen that there are nine openings communicating with each orbit, viz., the optic foramen, superior and inferior orbital fissures, supraorbital foramen, infraorbital canal, anterior and posterior ethmoidal foramina, zygomatic foramen, and the canal for the nasolacrimal duct. 23

Note 48. Occasionally the maxilla and the sphenoid articulate with each other at the anterior extremity of this fissure; the zygomatic is then excluded from it. [[back](#)]

Note 49. Some anatomists describe the apex of the orbit as corresponding with the medial end of the superior orbital fissure. It seems better, however, to adopt the statement in the text, since the ocular muscles take origin around the optic foramen, and diverge from it to the bulb of the eye. [[back](#)]

5d. The Interior of the Skull

Inner Surface of the Skull-cap.—The inner surface of the skull-cap is concave and presents depressions for the convolutions of the cerebrum, together with numerous furrows for the lodgement of branches of the meningeal vessels. Along the middle line is a longitudinal groove, narrow in 1

front, where it commences at the frontal crest, but broader behind; it lodges the superior sagittal sinus, and its margins afford attachment to the falx cerebri. On either side of it are several depressions for the arachnoid granulations, and at its back part, the openings of the **parietal foramina** when these are present. It is crossed, in front, by the **coronal suture**, and behind by the **lambdoidal**, while the **sagittal** lies in the medial plane between the parietal bones.

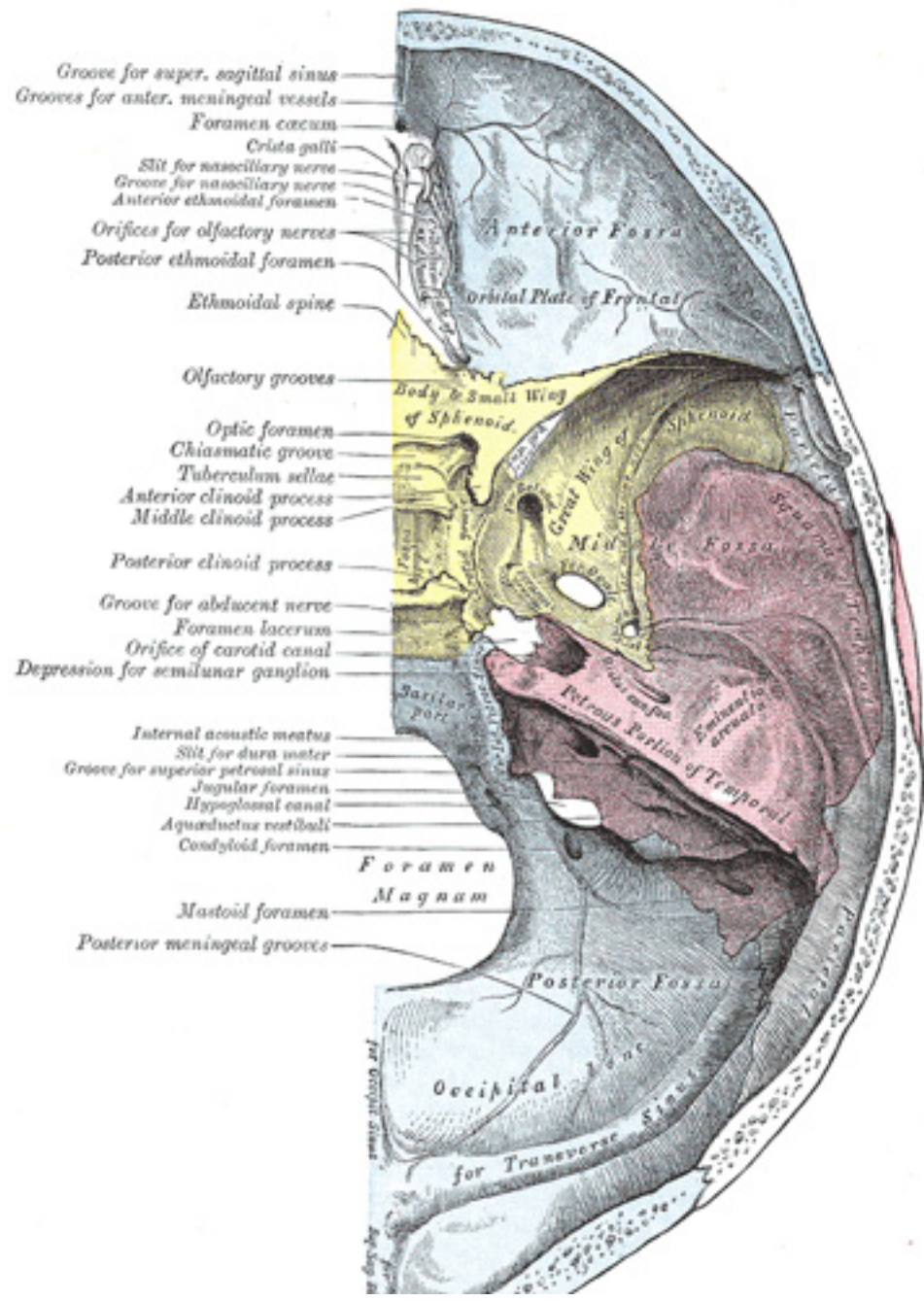
Upper Surface of the Base of the Skull (Fig. 193).—The upper surface of the base of the skull or floor of the cranial cavity presents three fossæ, ² called the **anterior, middle, and posterior cranial fossæ**.

Anterior Fossa (*fossa cranii anterior*).—The floor of the anterior fossa is formed by the orbital plates of the frontal, the cribriform plate of the ethmoid, and the small wings and front part of the body of the sphenoid; it is limited behind by the posterior borders of the small wings of the sphenoid and by the anterior margin of the chiasmatic groove. It is traversed by the **frontoethmoidal, sphenoethmoidal, and sphenofrontal sutures**. Its lateral portions roof in the orbital cavities and support the frontal lobes of the cerebrum; they are convex and marked by depressions for the brain convolutions, and grooves for branches of the meningeal vessels. The central portion corresponds with the roof of the nasal cavity, and is markedly depressed on either side of the crista galli. It presents, in and near the median line, from before backward, the commencement of the **frontal crest** for the attachment of the falx cerebri; the **foramen cecum**, between the frontal bone and the crista galli of the ethmoid, which usually transmits a small vein from the nasal cavity to the superior sagittal sinus; behind the foramen cecum, the **crista galli**, the free margin of which affords attachment to the falx cerebri; on either side of the crista galli, the **olfactory groove** formed by the cribriform plate, which supports the olfactory bulb and presents foramina for the transmission of the olfactory nerves, and in front a slit-like opening for the nasociliary nerve. Lateral to either olfactory groove are the internal openings of the **anterior and posterior ethmoidal foramina**; the anterior, situated about the middle of the lateral margin of the olfactory groove, transmits the anterior ethmoidal vessels and the nasociliary nerve; the nerve runs in a groove along the lateral edge of the cribriform plate to the slit-like opening above mentioned; the posterior ethmoidal foramen opens at the back part of this margin under cover of the projecting lamina of the sphenoid, and transmits the posterior ethmoidal vessels and nerve. Farther back in the middle line is the **ethmoidal spine**, bounded behind by a slight elevation separating two shallow longitudinal grooves which support the olfactory lobes. Behind this is the anterior margin of the chiasmatic groove, running lateralward on either side to the upper margin of the optic foramen. ³

The Middle Fossa (*fossa cranii media*).—The middle fossa, deeper than the preceding, is narrow in the middle, and wide at the sides of the skull. It is bounded in *front* by the posterior margins of the small wings of the sphenoid, the anterior clinoid processes, and the ridge forming the anterior margin of the chiasmatic groove; *behind*, by the superior angles of the petrous portions of the temporals and the dorsum sellæ; *laterally* by the temporal squamæ, sphenoidal angles of the parietals, and great wings of the sphenoid. It is traversed by the **squamosal, sphenoparietal, sphenosquamosal, and sphenopetrosal sutures**. ⁴

The middle part of the fossa presents, in *front*, the **chiasmatic groove** and **tuberculum sellæ**; the chiasmatic groove ends on either side at the **optic foramen**, which transmits the optic nerve and ophthalmic artery to the orbital cavity. Behind the optic foramen the **anterior clinoid process** is directed backward and medialward and gives attachment to the tentorium cerebelli. Behind the tuberculum sellæ is a deep depression, the **sella turcica**, containing the **fossa hypophyseos**, which lodges the hypophysis, and presents on its anterior wall the **middle clinoid processes**. The sella turcica is bounded posteriorly by a quadrilateral plate of bone, the **dorsum sellæ**, the upper angles of which are surmounted ⁵

by the **posterior clinoid processes**: these afford attachment to the tentorium cerebelli, and below each is a notch for the abducent nerve. On either side of the sella turcica is the **carotid groove**, which is broad, shallow, and curved somewhat like the italic letter *f*. It begins behind at the foramen lacerum, and ends on the medial side of the anterior clinoid process, where it is sometimes converted into a foramen (*carotico-clinoid*) by the union of the anterior with the middle clinoid process; posteriorly, it is bounded laterally by the **lingula**. This groove lodges the cavernous sinus and the internal carotid artery, the latter being surrounded by a plexus of sympathetic nerves.



- Groove for super. sagittal sinus
- Grooves for anter. meningeal vessels
- Foramen cecum
- Crista galli
- Slit for nasociliary nerve
- Groove for nasociliary nerve
- Anterior ethmoidal foramen
- Orifices for olfactory nerves
- Posterior ethmoidal foramen
- Ethmoidal spine
- Olfactory grooves
- Optic foramen
- Chiasmatic groove
- Tuberculum sellae
- Anterior clinoid process
- Middle clinoid process
- Posterior clinoid process
- Groove for abducent nerve
- Foramen lacerum
- Orifice of carotid canal
- Depression for semilunar ganglion
- Internal acoustic meatus
- Slit for dura mater
- Groove for superior petrosal sinus
- Jugular foramen
- Hypoglossal canal
- Aqueductus vestibuli
- Condyloid foramen
- Mastoid foramen
- Posterior meningeal grooves

Anterior Fossa

Oriental Plate of Frontal

Body & Small Wing of Sphenoid

Great Wing of Sphenoid

Middle Fossa

Petrous Part of Temporal

Posterior Fossa

Occipital Condyle

for Transverse Sinus

for Sigmoid Sinus

Foramen Magnum

Saxillary part

Orifice of carotid canal

Internal acoustic meatus

Slit for dura mater

Groove for superior petrosal sinus

Jugular foramen

Hypoglossal canal

Aqueductus vestibuli

Condyloid foramen

Foramen Magnum

Mastoid foramen

Posterior meningeal grooves

Occipital Condyle

for Transverse Sinus

for Sigmoid Sinus

FIG. 193— Base of the skull. Upper surface. ([See enlarged image](#))

The lateral parts of the middle fossa are of considerable depth, and support the temporal lobes of the brain. They are marked by depressions for the brain convolutions and traversed by furrows for the anterior and posterior branches of the middle meningeal vessels. These furrows begin near the foramen spinosum, and the anterior runs forward and upward to the sphenoidal angle of the parietal, where it is sometimes converted into a bony canal; the posterior runs lateralward and backward across the temporal squama and passes on to the parietal near the middle of its lower border. The following apertures are also to be seen. In front is the **superior orbital fissure**, bounded above by the small wing, below, by the great wing, and medially, by the body of the sphenoid; it is usually completed laterally by the orbital plate of the frontal bone. It transmits to the orbital cavity the oculomotor, the trochlear, the ophthalmic division of the trigeminal, and the abducent nerves, some filaments from the cavernous plexus of the sympathetic, and the orbital branch of the middle meningeal artery; and from the orbital cavity a recurrent branch from the lacrimal artery to the dura mater, and the ophthalmic veins. Behind the medial end of the superior orbital fissure is the **foramen rotundum**, for the passage of the maxillary nerve. Behind and lateral to the foramen rotundum is the **foramen ovale**, which transmits the mandibular nerve, the accessory meningeal artery, and the lesser superficial petrosal nerve. ⁵⁰ Medial to the foramen ovale is the **foramen Vesalii**, which varies in size in different individuals, and is often absent; when present, it opens below at the lateral side of the scaphoid fossa, and transmits a small vein. Lateral to the foramen ovale is the **foramen spinosum**, for the passage of the middle meningeal vessels, and a recurrent branch from the mandibular nerve. Medial to the foramen ovale is the **foramen lacerum**; in the fresh state the lower part of this aperture is filled up by a layer of fibrocartilage, while its upper and inner parts transmit the internal carotid artery surrounded by a plexus of sympathetic nerves. The nerve of the pterygoid canal and a meningeal branch from the ascending pharyngeal artery pierce the layer of fibrocartilage. On the anterior surface of the petrous portion of the temporal bone are seen the eminence caused by the projection of the superior semicircular canal; in front of and a little lateral to this a depression corresponding to the roof of the tympanic cavity; the groove leading to the **hiatus of the facial canal**, for the transmission of the greater superficial petrosal nerve and the petrosal branch of the middle meningeal artery; beneath it, the smaller groove, for the passage of the lesser superficial petrosal nerve; and, near the apex of the bone, the depression for the semilunar ganglion and the orifice of the carotid canal.

The Posterior Fossa (*fossa cranii posterior*).—The posterior fossa is the largest and deepest of the three. It is formed by the dorsum sellæ and clivus of the sphenoid, the occipital, the petrous and mastoid portions of the temporals, and the mastoid angles of the parietal bones; it is crossed by the **occipitomastoid** and the **parietomastoid sutures**, and lodges the cerebellum, pons, and medulla oblongata. It is separated from the middle fossa in and near the median line by the dorsum sellæ of the sphenoid and on either side by the superior angle of the petrous portion of the temporal bone. This angle gives attachment to the tentorium cerebelli, is grooved for the superior petrosal sinus, and presents at its medial end a notch upon which the trigeminal nerve rests. The fossa is limited behind by the grooves for the transverse sinuses. In its center is the **foramen magnum**, on either side of which is a rough tubercle for the attachment of the alar ligaments; a little above this tubercle is the canal, which transmits the hypoglossal nerve and a meningeal branch from the ascending pharyngeal artery. In front of the foramen magnum the basilar portion of the occipital and the posterior part of the body of the sphenoid form a grooved surface which supports the medulla oblongata and pons; in the young skull these bones are joined by a synchondrosis. This grooved surface is separated on either side from the petrous portion of the temporal by the **petro-occipital fissure**, which is occupied in the fresh state by a plate of cartilage; the fissure is continuous behind with the

jugular foramen, and its margins are grooved for the inferior petrosal sinus. The **jugular foramen** is situated between the lateral part of the occipital and the petrous part of the temporal. The anterior portion of this foramen transmits the inferior petrosal sinus; the posterior portion, the transverse sinus and some meningeal branches from the occipital and ascending pharyngeal arteries; and the intermediate portion, the glossopharyngeal, vagus, and accessory nerves. Above the jugular foramen is the **internal acoustic meatus**, for the facial and acoustic nerves and internal auditory artery; behind and lateral to this is the slit-like opening leading into the aquæductus vestibuli, which lodges the ductus endolymphaticus; while between these, and near the superior angle of the petrous portion, is a small triangular depression, the remains of the fossa subarcuata, which lodges a process of the dura mater and occasionally transmits a small vein. Behind the foramen magnum are the **inferior occipital fossæ**, which support the hemispheres of the cerebellum, separated from one another by the **internal occipital crest**, which serves for the attachment of the falx cerebelli, and lodges the occipital sinus. The posterior fossæ are surmounted by the deep grooves for the **transverse sinuses**. Each of these channels, in its passage to the jugular foramen, grooves the occipital, the mastoid angle of the parietal, the mastoid portion of the temporal, and the jugular process of the occipital, and ends at the back part of the jugular foramen. Where this sinus grooves the mastoid portion of the temporal, the orifice of the **mastoid foramen** may be seen; and, just previous to its termination, the **condyloid canal** opens into it; neither opening is constant.

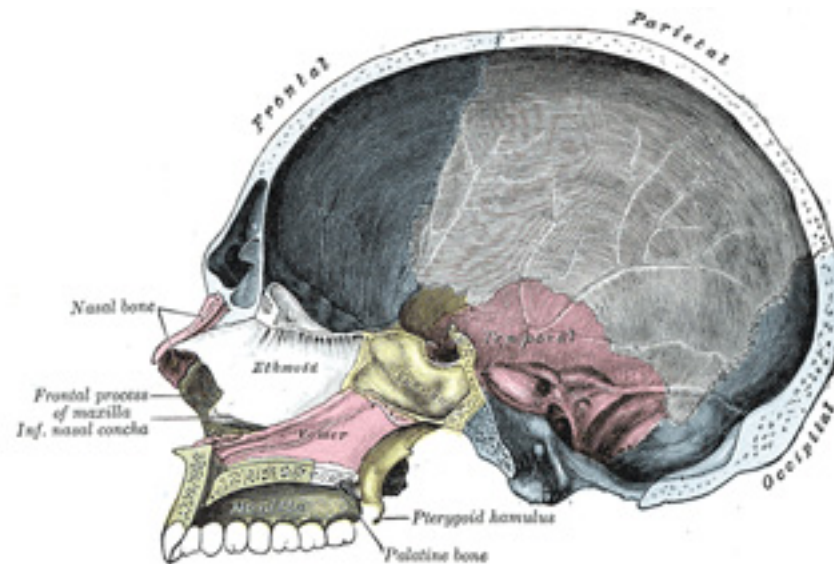


FIG. 194— Sagittal section of skull. ([See enlarged image](#))

The Nasal Cavity (*cavum nasi*; *nasal fossa*).—The nasal cavities are two irregular spaces, situated one on either side of the middle line of the face, extending from the base of the cranium to the roof of the mouth, and separated from each other by a thin vertical septum. They open on the face through the pear-shaped **anterior nasal aperture**, and their posterior openings or **choanae** communicate, in the fresh state, with the nasal part of the pharynx. They are much narrower above than below, and in the middle than at their anterior or posterior openings: their depth, which is considerable, is greatest in the middle. They communicate with the frontal, ethmoidal, sphenoidal, and maxillary sinuses. Each cavity is bounded by a **roof**, a **floor**, a **medial** and a **lateral wall**.

8

The **roof** (Figs. 195, 196) is horizontal in its central part, but slopes downward in front and behind; it is formed in *front* by the nasal bone and the spine of the frontal; in the *middle*, by the cribriform plate of the ethmoid; and *behind*, by the body of the sphenoid, the sphenoidal concha, the ala of the vomer and the sphenoidal process of the palatine bone. In the cribriform plate of the ethmoid are the foramina for the olfactory nerves, and on the posterior part of the roof is the opening into the sphenoidal sinus.

9

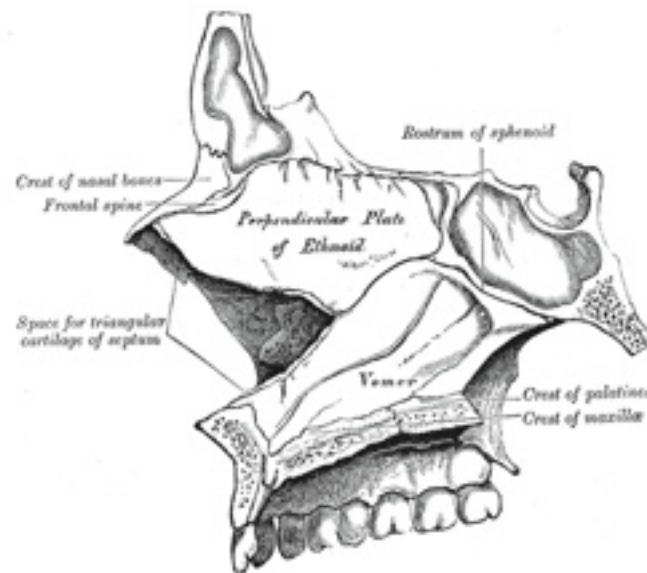


FIG. 195— Medial wall of left nasal fossa. ([See enlarged image](#))

The **floor** is flattened from before backward and concave from side to side. It is formed by the palatine process of the maxilla and the horizontal part of the palatine bone; near its anterior end is the opening of the incisive canal.

10

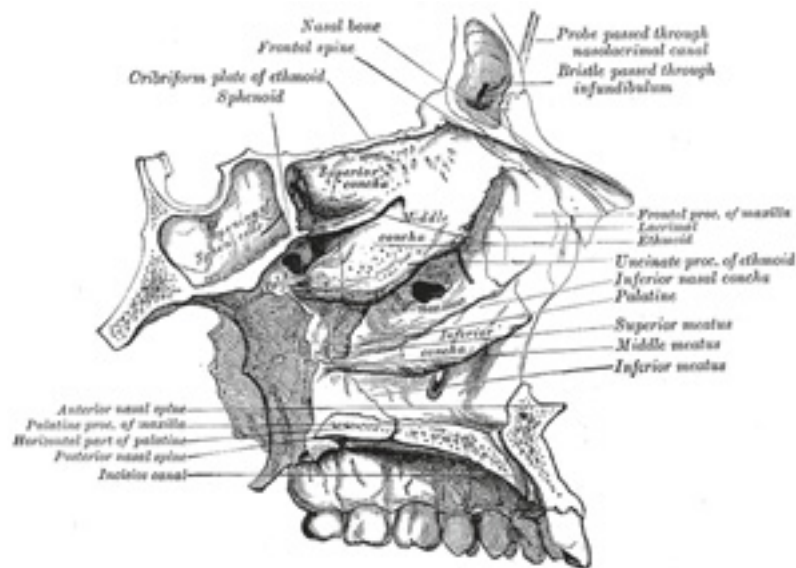


FIG. 196– Roof, floor, and lateral wall of left nasal cavity. ([See enlarged image](#))

The **medial wall** (*septum nasi*) ([Fig. 195](#)), is frequently deflected to one or other side, more often to the left than to the right. It is formed, in *front*, by the crest of the nasal bones and frontal spine; in the *middle*, by the perpendicular plate of the ethmoid; *behind*, by the vomer and the rostrum of the sphenoid; *below*, by the crest of the maxillæ and palatine bones. It presents, in front, a large, triangular notch, which receives the cartilage of the septum; and behind, the free edge of the vomer. Its surface is marked by numerous furrows for vessels and nerves and by the grooves for the nasopalatine nerve, and is traversed by sutures connecting the bones of which it is formed.

11

The **lateral wall** ([Fig. 196](#)) is formed, in front, by the frontal process of the maxilla and by the lacrimal bone; in the middle, by the ethmoid, maxilla, and inferior nasal concha; behind, by the vertical plate of the palatine bone, and the medial pterygoid plate of the sphenoid. On this wall are three irregular anteroposterior passages, termed the superior, middle, and inferior meatuses of the nose. The **superior meatus**, the smallest of the three, occupies the middle third of the lateral wall. It lies between the superior and middle nasal conchæ; the **sphenopalatine foramen** opens into it behind, and the **posterior ethmoidal cells** in front. The sphenoidal sinus opens into a recess, the **sphenoethmoidal recess**, which is placed above and behind the superior concha. The **middle meatus** is situated between the middle and inferior conchæ, and extends from the anterior to the posterior end of the latter. The lateral wall of this meatus can be satisfactorily studied only after the removal of the middle concha. On it is a curved fissure, the **hiatus semilunaris**, limited below by the edge of the uncinæ process of the ethmoid and above by an elevation named the **bullæ ethmoidalis**; the middle ethmoidal cells are contained within this bulla and open on or near to it. Through the hiatus semilunaris the meatus communicates with a curved passage termed the **infundibulum**, which communicates in front with the anterior ethmoidal cells and in

12

rather more than fifty per cent. of skulls is continued upward as the **frontonasal duct** into the frontal air-sinus; when this continuity fails, the frontonasal duct opens directly into the anterior part of the meatus. Below the bulla ethmoidalis and hidden by the uncinat process of the ethmoid is the opening of the maxillary sinus (**ostium maxillare**); an accessory opening is frequently present above the posterior part of the inferior nasal concha. The **inferior meatus**, the largest of the three, is the space between the inferior concha and the floor of the nasal cavity. It extends almost the entire length of the lateral wall of the nose, is broader in front than behind, and presents anteriorly the lower **orifice of the nasolacrimal canal**.

The **Anterior Nasal Aperture** (Fig. 181) is a heart-shaped or pyriform opening, whose long axis is vertical, and narrow end upward; in the recent state it is much contracted by the lateral and alar cartilages of the nose. It is bounded *above* by the inferior borders of the nasal bones; *laterally* by the thin, sharp margins which separate the anterior from the nasal surfaces of the maxillæ; and *below* by the same borders, where they curve medialward to join each other at the anterior nasal spine. 13

The **choanæ** are each bounded *above* by the under surface of the body of the sphenoid and ala of the vomer; *below*, by the posterior border of the horizontal part of the palatine bone; *laterally*, by the medial pterygoid plate; they are separated from each other by the posterior border of the vomer. 14

Differences in the Skull Due to Age
At birth the skull is large in proportion to the other parts of the skeleton, but its facial portion is small, and equals only about one-eighth of the bulk of the cranium as compared with one-half in the adult. The frontal and parietal eminences are prominent, and the greatest width of the skull is at the level of the latter; on the other hand, the glabella, superciliary arches, and mastoid processes are not developed. Ossification of the skull bones is not completed, and many of them, *e. g.*, the occipital, temporals, sphenoid, frontal, and mandible, consist of more than one piece. Unossified membranous intervals, termed *fontanelles*, are seen at the angles of the parietal bones; these fontanelles are six in number: two, an anterior and a posterior, are situated in the middle line, and two, an antero-lateral and a postero-lateral, on either side. 15

The *anterior* or *bregmatic fontanelle* (Fig. 197) is the largest, and is placed at the junction of the sagittal, coronal, and frontal sutures; it is lozenge-shaped, and measures about 4 cm. in its antero-posterior and 2.5 cm. in its transverse diameter. The *posterior fontanelle* is triangular in form and is situated at the junction of the sagittal and lambdoidal sutures. The *lateral fontanelles* (Fig. 198) are small, irregular in shape, and correspond respectively with the sphenoidal and mastoid angles of the parietal bones. An additional fontanelle is sometimes seen in the sagittal suture at the region of the obelion. The fontanelles are usually closed by the growth and extension of the bones which surround them, but sometimes they are the sites of separate ossific centers which develop into sutural bones. The posterior and lateral fontanelles are obliterated within a month or two after birth, but the anterior is not completely closed until about the middle of the second year. 16

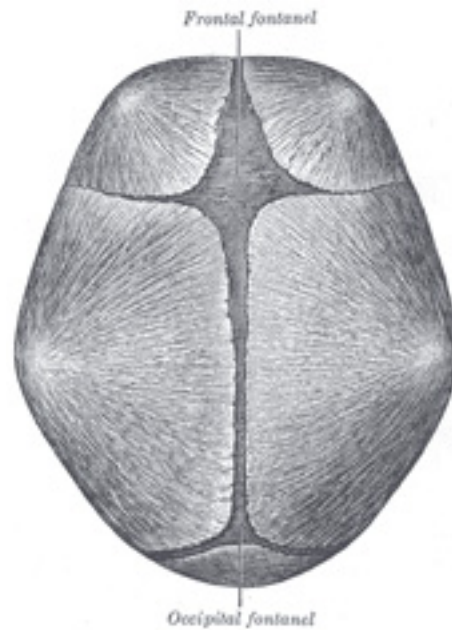


FIG. 197– Skull at birth, showing frontal and occipital fonticuli. ([See enlarged image](#))

The smallness of the face at birth is mainly accounted for by the rudimentary condition of the maxillæ and mandible, the non-eruption of the teeth, and the small size of the maxillary air sinuses and nasal cavities. At birth the nasal cavities lie almost entirely between the orbits, and the lower border of the anterior nasal aperture is only a little below the level of the orbital floor. With the eruption of the deciduous teeth there is an enlargement of the face and jaws, and these changes are still more marked after the second dentition. 17

The skull grows rapidly from birth to the seventh year, by which time the foramen magnum and petrous parts of the temporals have reached their full size and the orbital cavities are only a little smaller than those of the adult. Growth is slow from the seventh year until the approach of puberty, when a second period of activity occurs: this results in an increase in all directions, but it is especially marked in the frontal and facial regions, where it is associated with the development of the air sinuses. 18

Obliteration of the sutures of the vault of the skull takes place as age advances. This process may commence between the ages of thirty and forty, and is first seen on the inner surface, and some ten years later on the outer surface of the skull. The dates given are, however, only approximate, as it is impossible to state with anything like accuracy the time at which the sutures are closed. Obliteration usually occurs first in the posterior part of the sagittal suture, next in the coronal, and then in the lambdoidal. 19

In old age the skull generally becomes thinner and lighter, but in a small proportion of cases it increases in thickness and weight, owing to an hypertrophy of the inner table. The most striking feature of the old skull is the diminution in the size of the maxillæ and mandible consequent on the loss of the teeth and the absorption of the alveolar processes. This is associated with a marked reduction in the vertical measurement of the face and with an alteration in the angles of the mandible.

20

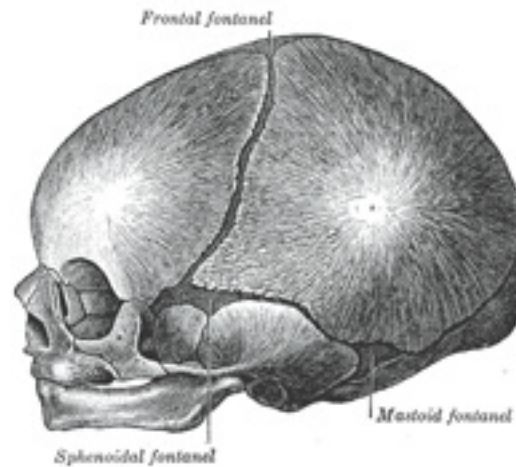


FIG. 198– Skull at birth, showing sphenoidal and mastoid fonticuli. ([See enlarged image](#))

Sexual Differences in the Skull Until the age of puberty there is little difference between the skull of the female and that of the male. The skull of an adult female is, as a rule, lighter and smaller, and its cranial capacity about 10 per cent. less, than that of the male. Its walls are thinner and its muscular ridges less strongly marked; the glabella, superciliary arches, and mastoid processes are less prominent, and the corresponding air sinuses are small or rudimentary. The upper margin of the orbit is sharp, the forehead vertical, the frontal and parietal eminences prominent, and the vault somewhat flattened. The contour of the face is more rounded, the facial bones are smoother, and the maxillæ and mandible and their contained teeth smaller. From what has been said it will be seen that more of the infantile characteristics are retained in the skull of the adult female than in that of the adult male. A well-marked male or female skull can easily be recognized as such, but in some cases the respective characteristics are so indistinct that the determination of the sex may be difficult or impossible.

21

Craniology Skulls vary in size and shape, and the term craniology is applied to the study of these variations. The capacity of the cranial cavity constitutes a good index of the size of the brain which it contained, and is most conveniently arrived at by filling the cavity with shot and

22

measuring the contents in a graduated vessel. Skulls may be classified according to their capacities as follows:

1. *Microcephalic*, with a capacity of less than 1350 c.cm.—*e.g.*, those of native Australians and Andaman Islanders. 23
2. *Mesocephalic*, with a capacity of from 1350 c.cm. to 1450 c.cm.—*e.g.*, those of African negroes and Chinese. 24
3. *Megacephalic*, with a capacity of over 1450 c.cm.—*e.g.*, those of Europeans, Japanese, and Eskimos. 25

In comparing the shape of one skull with that of another it is necessary to adopt some definite position in which the skulls should be placed during the process of examination. They should be so placed that a line carried through the lower margin of the orbit and upper margin of the external acoustic meatus is in the horizontal plane. The normæ of one skull can then be compared with those of another, and the differences in contour and surface form noted. Further, it is necessary that the various linear measurements used to determine the shape of the skull should be made between definite and easily localized points on its surface. The principal points may be divided into two groups: (1) those in the median plane, and (2) those on either side of it. 26

The Points in the Median Plane are the: 27

Mental Point. The most prominent point of the chin. 28

Alveolar Point or *Prosthion*. The central point of the anterior margin of the upper alveolar arch. 29

Subnasal Point. The middle of the lower border of the anterior nasal aperture, at the base of the anterior nasal spine. 30

Nasion. The central point of the frontonasal suture. 31

Glabella. The point in the middle line at the level of the superciliary arches. 32

Ophryon. The point in the middle line of the forehead at the level where the temporal lines most nearly approach each other. 33

Bregma. The meeting point of the coronal and sagittal sutures. 34

Obelion. A point in the sagittal suture on a level with the parietal foramina. 35

Lambda. The point of junction of the sagittal and lambdoidal sutures. 36

Occipital Point. The point in the middle line of the occipital bone farthest from the glabella. 37

Inion. The external occipital protuberance. 38

Opisthion. The mid-point of the posterior margin of the foramen magnum. 39

Basion. The mid-point of the anterior margin of the foramen magnum. 40

The Points on Either Side of the Median Plane are the: 41

Gonion. The outer margin of the angle of the mandible. 42

Dacryon. The point of union of the antero-superior angle of the lacrimal with the frontal bone and the frontal process of the maxilla. 43

Stephanion. The point where the temporal line intersects the coronal suture. 44

Pterion. The point where the great wing of the sphenoid joins the sphenoidal angle of the parietal. 45

Auricular Point. The center of the orifice of the external acoustic meatus. 46

Asterion. The point of meeting of the lambdoidal, mastoöccipital, and mastoparietal sutures. 47

The *horizontal circumference* of the cranium is measured in a plane passing through the glabella (Turner) or the ophryon (Flower) in front, and 48

the occipital point behind; it averages about 50 cm. in the female and 52.5 cm. in the male.

The *occipitofrontal* or *longitudinal arc* is measured from the nasion over the middle line of the vertex to the opisthion: while the *basinasal length* is the distance between the basion and the nasion. These two measurements, plus the antero-posterior diameter of the foramen magnum, represent the *vertical circumference* of the cranium. 49

The *length* is measured from the glabella to the occipital point, while the *breadth* or greatest transverse diameter is usually found near the external acoustic meatus. The proportion of breadth to length (breadth X 100)/length is termed the *cephalic index* or *index of breadth*. 50

The *height* is usually measured from the basion to the bregma, and the proportion of height to length (height X 100)/length constitutes the *vertical* or *height index*. 51

In studying the face the principal points to be noticed are the proportion of its length and breadth, the shape of the orbits and of the anterior nasal aperture, and the degree of projection of the jaws. 52

The *length of the face* may be measured from the ophryon or nasion to the chin, or, if the mandible be wanting, to the alveolar point; while its *width* is represented by the distance between the zygomatic arches. By comparing the length with the width of the face, skulls may be divided into two groups; *dolichofacial* or *leptoprosope* (long faced) and *brachyfacial* or *chemoprosope* (short faced). 53

The *orbital index* signifies the proportion which the orbital height bears to the orbital width, thus: 54

$$\text{orbital height X 100/orbital width}$$

The *nasal index* expresses the proportion which the width of the anterior nasal aperture bears to the height of the nose, the latter being measured from the nasion to the lower margin of the nasal aperture, thus: 55

$$\text{nasal width X 100/nasal height}$$

The degree of projection of the jaws is determined by the *gnathic* or *alveolar index*, which represents the proportion between the basialveolar and basinasal lengths, thus: 56

$$\text{basialveolar length X 100/basinasal length}$$

The following table, modified from that given by Duckworth, 51 illustrates how these different indices may be utilized in the classification of skulls: 57

Index.	Classification.	Nomenclature.	Examples.
1. Cephalic	Below 75	Dolichocephalic	Kaffirs and Native Australians.
	Between 75 and 80	Mesaticephalic	Europeans and Chinese.
	Above 80	Brachycephalic	Mongolians and Andamans.
2. Orbital	Below 84	Microseme	Tasmanians and Native Australians.
	Between 84 and 89	Mesoseme	Europeans.
	Above 89	Megaseme	Chinese and Polynesians.

3. Nasal	Below 48	Leptorhine	Europeans.
	Between 48 and 53	Mesorhine	Japanese and Chinese.
	Above 53	Platyrrhine	Negroes and Native Australians.
4. Gnathic	Below 98	Orthognathous	Europeans.
	Between 98 and 103	Mesognathous	Chinese and Japanese.
	Above 103	Prognathous	Native Australians.

The chief function of the skull is to protect the brain, and therefore those portions of the skull which are most exposed to external violence are thicker than those which are shielded from injury by overlying muscles. Thus, the skull-cap is thick and dense, whereas the temporal squamæ being protected by the temporales muscles, and the inferior occipital fossæ, being shielded by the muscles at the back of the neck, are thin and fragile. Fracture of the skull is further prevented by its elasticity, its rounded shape, and its construction of a number of secondary elastic arches, each made up of a single bone. The manner in which vibrations are transmitted through the bones of the skull is also of importance as regards its protective mechanism, at all events as far as the base is concerned. In the vault, the bones being of a fairly equal thickness and density, vibrations are transmitted in a uniform manner in all directions, but in the base, owing to the varying thickness and density of the bones, this is not so; and therefore in this situation there are special buttresses which serve to carry the vibrations in certain definite directions. At the front of the skull, on either side, is the ridge which separates the anterior from the middle fossa of the base; and behind, the ridge or buttress which separates the middle from the posterior fossa; and if any violence is applied to the vault, the vibrations would be carried along these buttresses to the sella turcica, where they meet. This part has been termed the “center of resistance,” and here there is a special protective mechanism to guard the brain. The subarachnoid cavity at the base of the brain is dilated, and the cerebrospinal fluid which fills it acts as a water cushion to shield the brain from injury. In like manner, when violence is applied to the base of the skull, as in falls upon the feet, the vibrations are carried backward through the occipital crest, and forward through the basilar part of the occipital and body of the sphenoid to the vault of the skull. 58

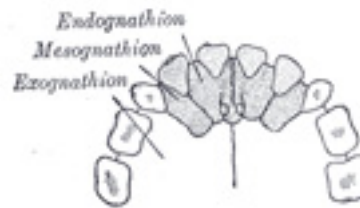


FIG. 199– The premaxilla and its sutures. (After Albrecht.) ([See enlarged image](#))

In connection with the bones of the face a common malformation is *cleft palate*. The cleft usually starts posteriorly, and its most elementary 59

form is a bifid uvula; or the cleft may extend through the soft palate; or the posterior part of the whole of the hard palate may be involved, the cleft extending as far forward as the incisive foramen. In the severest forms, the cleft extends through the alveolus and passes between the incisive or premaxillary bone and the rest of the maxilla; that is to say, between the lateral incisor and canine teeth. In some instances, the cleft runs between the central and lateral incisor teeth; and this has induced some anatomists to believe that the premaxillary bone is developed from two centers ([Fig. 199](#)) and not from one, as was stated on p. 163. The medial segment, bearing a central incisor, is called an *endognathion*; the lateral segment, bearing the lateral incisor, is called a *mesognathion*. The cleft may affect one or both sides; if the latter, the central part is frequently displaced forward and remains united to the septum of the nose, the deficiency in the alveolus being complicated with a cleft in the lip (hare-lip). On examining a cleft palate in which the alveolus is not implicated, the cleft will generally appear to be in the median line, but occasionally is unilateral and in some cases bilateral. To understand this it must be borne in mind that three processes are concerned in the formation of the palate—the palatine processes of the two maxillæ, which grow in horizontally and unite in the middle line, and the ethmovomerine process, which grows downward from the base of the skull and frontonasal process to unite with the palatine processes in the middle line. In those cases where the palatine processes fail to unite with each other and with the medial process, the cleft of the palate is median; where one palatine process unites with the medial septum, the other failing to do so, the cleft in the palate is unilateral. In some cases where the palatine processes fail to meet in the middle, the ethmovomerine process grows downward between them and thus produces a bilateral cleft. Occasionally there may be a hole in the middle line of the hard palate, the anterior part of the hard and the soft palate being perfect; this is rare, because, as a rule, the union of the various processes progresses from before backward, and therefore the posterior part of the palate is more frequently defective than the anterior.

Note 50. See footnote, page 150. [[back](#)]

Note 51. Morphology and Anthropology, by W. L. H. Duckworth, M.A., Cambridge University Press. [[back](#)]

6. The Extremities

The bones by which the upper and lower limbs are attached to the trunk constitute respectively the shoulder and pelvic girdles. The **shoulder girdle** or **girdle of the superior extremity** is formed by the scapulæ and clavicles, and is imperfect in front and behind. In front, however, it is completed by the upper end of the sternum, with which the medial ends of the clavicles articulate. Behind, it is widely imperfect, the scapulæ being connected to the trunk by muscles only. The **pelvic girdle** or **girdle of the inferior extremity** is formed by the hip bones, which articulate with each other in front, at the symphysis pubis. It is imperfect behind, but the gap is filled in by the upper part of the sacrum. The pelvic girdle, with the sacrum, is a complete ring, massive and comparatively rigid, in marked contrast to the lightness and mobility of the shoulder girdle.

6a. The Bones of the Upper Extremity. 1. [The Clavicle](#)

(*Ossa Extremitatis Superioris*) & (*Clavicula*; Collar Bone)

The **clavicle** (Figs. 200, 201) forms the anterior portion of the shoulder girdle. It is a long bone, curved somewhat like the italic letter *f*, and placed nearly horizontally at the upper and anterior part of the thorax, immediately above the first rib. It articulates medially with the manubrium sterni, and laterally with the acromion of the scapula. ⁵² It presents a double curvature, the convexity being directed forward at the sternal end, and the concavity at the scapular end. Its lateral third is flattened from above downward, while its medial two-thirds is of a rounded or prismatic form.

Lateral Third.—The lateral third has two surfaces, an upper and a lower; and two borders, an anterior and a posterior. 2

Surface.—The **upper surface** is flat, rough, and marked by impressions for the attachments of the Deltoideus in front, and the Trapezius behind; between these impressions a small portion of the bone is subcutaneous. The **under surface** is flat. At its posterior border, near the point where the prismatic joins with the flattened portion, is a rough eminence, the **coracoid tuberosity** (*conoid tubercle*); this, in the natural position of the bone, surmounts the coracoid process of the scapula, and gives attachment to the conoid ligament. From this tuberosity an oblique ridge, the **oblique** or **trapezoid ridge**, runs forward and lateralward, and afford attachment to the trapezoid ligament. 3

Borders.—The **anterior border** is concave, thin, and rough, and gives attachment to the Deltoideus. The **posterior border** is convex, rough, thicker than the anterior, and gives attachment to the Trapezius. 4

Medial Two-thirds.—The medial two-thirds constitute the prismatic portion of the bone, which is curved so as to be convex in front, concave behind, and is marked by three borders, separating three surfaces. 5

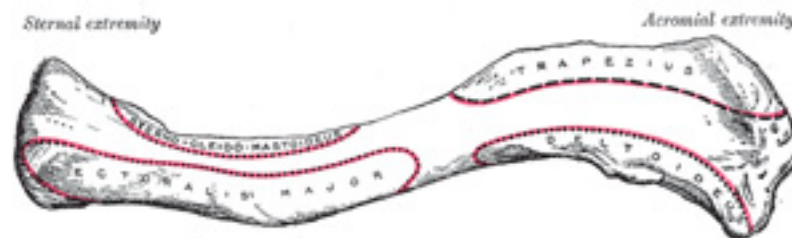


FIG. 200— Left clavicle. Superior surface. ([See enlarged image](#))

Borders.—The **anterior border** is continuous with the anterior margin of the flat portion. Its lateral part is smooth, and corresponds to the interval between the attachments of the Pectoralis major and Deltoideus; its medial part forms the lower boundary of an elliptical surface for the attachment of the clavicular portion of the Pectoralis major, and approaches the posterior border of the bone. The **superior border** is continuous with the posterior margin of the flat portion, and separates the anterior from the posterior surface. Smooth and rounded laterally, it becomes rough toward the medial third for the attachment of the Sternocleidomastoideus, and ends at the upper angle of the sternal extremity. The **posterior or subclavian border** separates the posterior from the inferior surface, and extends from the coracoid tuberosity to the costal tuberosity; it forms the posterior boundary of the groove for the Subclavius, and gives attachment to a layer of cervical fascia which envelops the Omohyoideus.

6

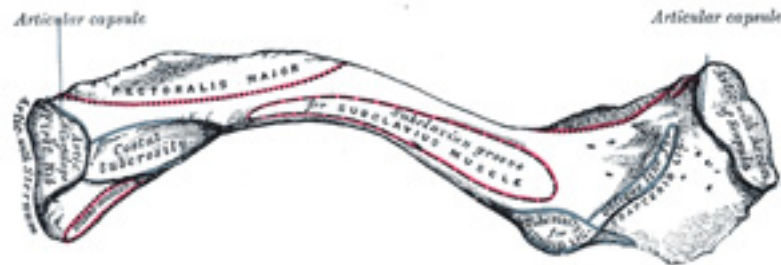


FIG. 201— Left clavicle. Inferior surface. ([See enlarged image](#))

Surfaces.—The **anterior surface** is included between the superior and anterior borders. Its lateral part looks upward, and is continuous with the superior surface of the flattened portion; it is smooth, convex, and nearly subcutaneous, being covered only by the Platysma. Medially it is divided by a narrow subcutaneous area into two parts: a lower, elliptical in form, and directed forward, for the attachment of the Pectoralis major; and an upper for the attachment of the Sternocleidomastoideus. The **posterior or cervical surface** is smooth, and looks backward toward the root of the neck. It is limited, above, by the superior border; below, by the subclavian border; medially, by the margin of the sternal extremity; and laterally, by the coracoid tuberosity. It is concave medio-laterally, and is in relation, by its lower part, with the transverse scapular vessels. This surface, at the junction of the curves of the bone, is also in relation with the brachial plexus of nerves and the subclavian vessels. It gives attachment, near the sternal extremity, to part of the Sternohyoideus; and presents, near the middle, an oblique foramen directed lateralward, which transmits the chief nutrient artery of the bone. Sometimes there are two foramina on the posterior surface, or one on the posterior and another on the inferior surface. The **inferior or subclavian surface** is bounded, in front, by the anterior border; behind, by the subclavian border. It is narrowed medially, but gradually increases in width laterally, and is continuous with the under surface of the flat portion. On its medial part is a broad rough surface, the **costal tuberosity (rhomboid impression)**, rather more than 2 cm. in length, for the attachment of the costoclavicular ligament. The rest of this surface is occupied by a groove, which gives attachment to the Subclavius; the coracoclavicular fascia, which splits to enclose the muscle, is attached to the margins of the groove. Not infrequently this groove is subdivided longitudinally by a

7

line which gives attachment to the intermuscular septum of the Subclavius.

The Sternal Extremity (*extremitas sternalis; internal extremity*).—The sternal extremity of the clavicle is triangular in form, directed medialward, and a little downward and forward; it presents an articular facet, concave from before backward, convex from above downward, which articulates with the manubrium sterni through the intervention of an articular disk. The lower part of the facet is continued on to the inferior surface of the bone as a small semi-oval area for articulation with the cartilage of the first rib. The circumference of the articular surface is rough, for the attachment of numerous ligaments; the upper angle gives attachment to the articular disk. 8

The Acromial Extremity (*extremitas acromialis; outer extremity*).—The acromial extremity presents a small, flattened, oval surface directed obliquely downward, for articulation with the acromion of the scapula. The circumference of the articular facet is rough, especially above, for the attachment of the acromioclavicular ligaments. 9

In the female, the clavicle is generally shorter, thinner, less curved, and smoother than in the male. In those persons who perform considerable manual labor it becomes thicker and more curved, and its ridges for muscular attachment are prominently marked. 10

Structure.—The clavicle consists of cancellous tissue, enveloped by a compact layer, which is much thicker in the intermediate part than at the extremities of the bone. 11

Ossification.—The clavicle begins to ossify before any other bone in the body; it is ossified from *three* centers—viz., two primary centers, a medial and a lateral, for the body, 53 which appear during the fifth or sixth week of fetal life; and a secondary center for the sternal end, which appears about the eighteenth or twentieth year, and unites with the rest of the bone about the twenty-fifth year. 12

Note 52. The clavicle acts especially as a fulcrum to enable the muscles to give lateral motion to the arm. It is accordingly absent in those animals whose fore-limbs are used only for progression, but is present for the most part in animals whose anterior extremities are clawed and used for prehension, though in some of them—as, for instance, in a large number of the carnivora—it is merely a rudimentary bone suspended among the muscles, and not articulating with either the scapula or sternum. [[back](#)]

Note 53. Mall, American Journal of Anatomy, vol. v; Fawcett, Journal of Anatomy and Physiology, vol. xlvii. [[back](#)]

6a. 2. The Scapula (Shoulder Blade)

(Shoulder Blade)

1

The **scapula** forms the posterior part of the shoulder girdle. It is a flat, triangular bone, with two surfaces, three borders, and three angles.

Surfaces.—The **costal** or **ventral surface** (Fig. 202) presents a broad concavity, the **subscapular fossa**. The medial two-thirds of the fossa are marked by several oblique ridges, which run lateralward and upward. The ridges give attachment to the tendinous insertions, and the surfaces between them to the fleshy fibers, of the Subscapularis. The lateral third of the fossa is smooth and covered by the fibers of this muscle. The fossa is separated from the vertebral border by smooth triangular areas at the medial and inferior angles, and in the interval between these by a narrow ridge which is often deficient. These triangular areas and the intervening ridge afford attachment to the Serratus anterior. At the upper part of the fossa is a transverse depression, where the bone appears to be bent on itself along a line at right angles to and passing through the center of the glenoid cavity, forming a considerable angle, called the **subscapular angle**; this gives greater strength to the body of the bone by its arched form, while the summit of the arch serves to support the spine and acromion.

The **dorsal surface** (Fig. 203) is arched from above downward, and is subdivided into two unequal parts by the spine; the portion above the spine is called the **supraspinatous fossa**, and that below it the **infraspinatous fossa**.

The **supraspinatous fossa**, the smaller of the two, is concave, smooth, and broader at its vertebral than at its humeral end; its medial two-thirds give origin to the Supraspinatus.

The **infraspinatous fossa** is much larger than the preceding; toward its vertebral margin a shallow concavity is seen at its upper part; its center presents a prominent convexity, while near the axillary border is a deep groove which runs from the upper toward the lower part. The medial two-thirds of the fossa give origin to the Infraspinatus; the lateral third is covered by this muscle.

The dorsal surface is marked near the axillary border by an elevated ridge, which runs from the lower part of the glenoid cavity, downward and backward to the vertebral border, about 2.5 cm. above the inferior angle. The ridge serves for the attachment of a fibrous septum, which separates the Infraspinatus from the Teres major and Teres minor. The surface between the ridge and the axillary border is narrow in the upper two-thirds of its extent, and is crossed near its center by a groove for the passage of the scapular circumflex vessels; it affords attachment to the Teres minor. Its lower third presents a broader, somewhat triangular surface, which gives origin to the Teres major, and over which the Latissimus dorsi glides; frequently the latter muscle takes origin by a few fibers from this part. The broad and narrow portions above alluded to are separated by an oblique line, which runs from the axillary border, downward and backward, to meet the elevated ridge: to it is attached a fibrous septum which separates the Teres muscles from each other.

The Spine (*spina scapulae*).—The spine is a prominent plate of bone, which crosses obliquely the medial four-fifths of the dorsal surface of the scapula at its upper part, and separates the supra- from the infraspinatous fossa. It begins at the vertical border by a smooth, triangular area over which the tendon of insertion of the lower part of the Trapezius glides, and, gradually becoming more elevated, ends in the acromion, which overhangs the shoulder-joint. The spine is triangular, and flattened from above downward, its apex being directed toward the vertebral border. It presents two surfaces and three borders. Its **superior surface** is concave; it assists in forming the supraspinatous fossa, and gives origin to part of the Supraspinatus. Its **inferior surface** forms part of the infraspinatous fossa, gives origin to a portion of the Infraspinatus, and presents near its center the orifice of a nutrient canal. Of the three borders, the **anterior** is attached to the dorsal surface of the bone; the **posterior, or crest of the spine**, is broad, and presents two lips and an intervening rough interval. The Trapezius is attached to the superior lip, and a rough tubercle is generally seen on that portion of the spine which receives the tendon of insertion of the lower part of this muscle. The Deltoideus is attached to the whole length of the inferior lip. The interval between the lips is subcutaneous and partly covered by the tendinous fibers of these muscles. The **lateral border, or base**, the shortest of the three, is slightly concave; its edge, thick and round, is continuous above with the under surface of

the acromion, below with the neck of the scapula. It forms the medial boundary of the **great scapular notch**, which serves to connect the supra- and infraspinatus fossæ.

The Acromion.—The acromion forms the summit of the shoulder, and is a large, somewhat triangular or oblong process, flattened from behind forward, projecting at first lateralward, and then curving forward and upward, so as to overhang the glenoid cavity. Its **superior surface**, directed upward, backward, and lateralward, is convex, rough, and gives attachment to some fibers of the Deltoides, and in the rest of its extent is subcutaneous. Its **inferior surface** is smooth and concave. Its **lateral border** is thick and irregular, and presents three or four tubercles for the tendinous origins of the Deltoides. Its **medial border**, shorter than the lateral, is concave, gives attachment to a portion of the Trapezius, and presents about its center a small, oval surface for articulation with the acromial end of the clavicle. 8

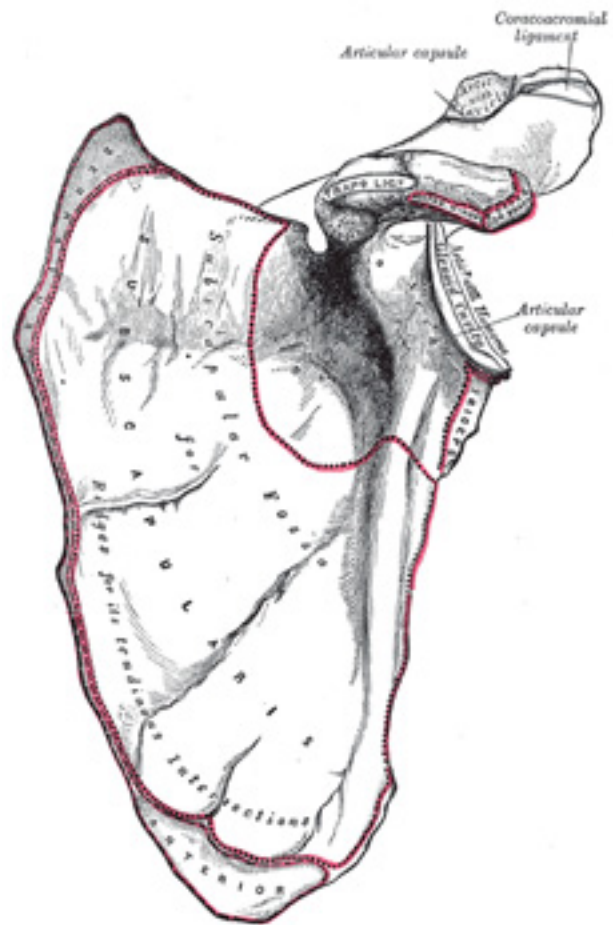


FIG. 202– Left scapula. Costal surface. ([See enlarged image](#))

Its **apex**, which corresponds to the point of meeting of these two borders in front, is thin, and has attached to it the coracoacromial ligament.

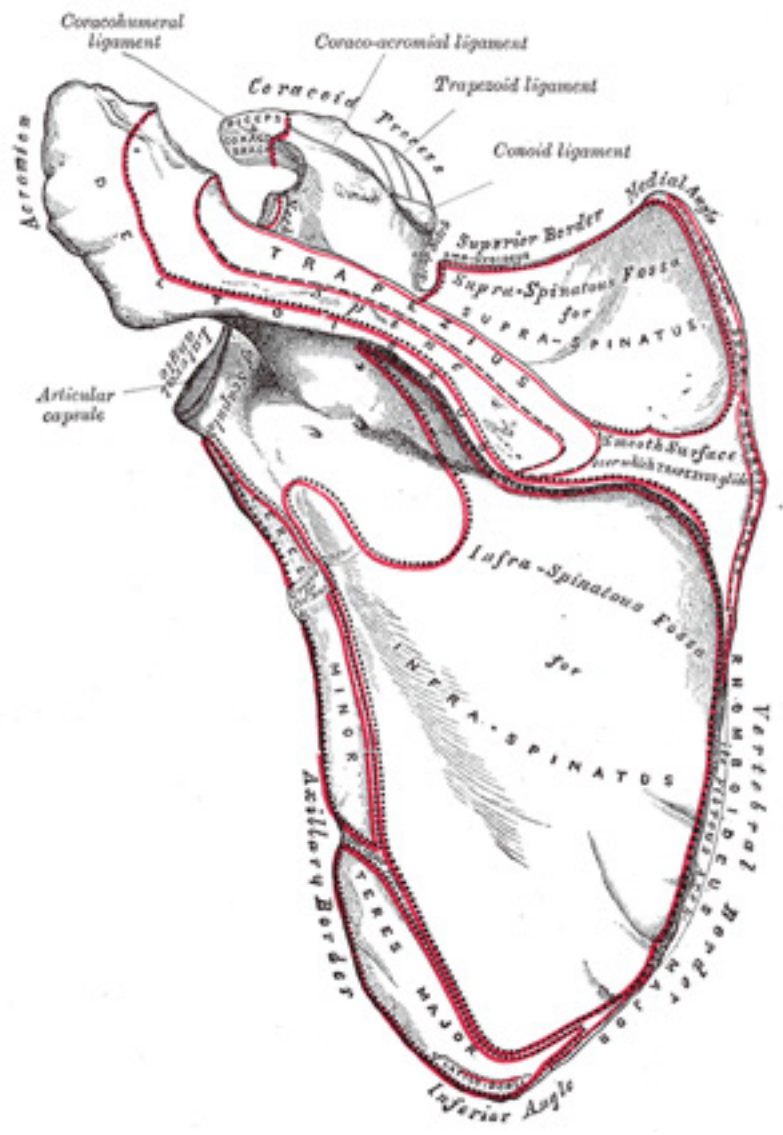


FIG. 203— Left scapula. Dorsal surface. ([See enlarged image](#))

Borders.—Of the *three* borders of the scapula, the **superior** is the shortest and thinnest; it is concave, and extends from the medial angle to the base of the coracoid process. At its lateral part is a deep, semicircular notch, the **scapular notch**, formed partly by the base of the coracoid process. This notch is converted into a foramen by the superior transverse ligament, and serves for the passage of the suprascapular nerve; sometimes the ligament is ossified. The adjacent part of the superior border affords attachment to the Omohyoideus. The **axillary border** is the thickest of the three. It begins above at the lower margin of the glenoid cavity, and inclines obliquely downward and backward to the inferior angle. Immediately below the glenoid cavity is a rough impression, the **infraglenoid tuberosity**, about 2.5 cm. in length, which gives origin to the long head of the Triceps brachii; in front of this is a longitudinal groove, which extends as far as the lower third of this border, and affords origin to part of the Subscapularis. The inferior third is thin and sharp, and serves for the attachment of a few fibers of the Teres major behind, and of the Subscapularis in front. The **vertebral border** is the longest of the three, and extends from the medial to the inferior angle. It is arched, intermediate in thickness between the superior and the axillary borders, and the portion of it above the spine forms an obtuse angle with the part below. This border presents an anterior and a posterior lip, and an intermediate narrow area. The anterior lip affords attachment to the Serratus anterior; the posterior lip, to the Supraspinatus above the spine, the Infraspinatus below; the area between the two lips, to the Levator scapulæ above the triangular surface at the commencement of the spine, to the Rhomboideus minor on the edge of that surface, and to the Rhomboideus major below it; this last is attached by means of a fibrous arch, connected above to the lower part of the triangular surface at the base of the spine, and below to the lower part of the border. 10

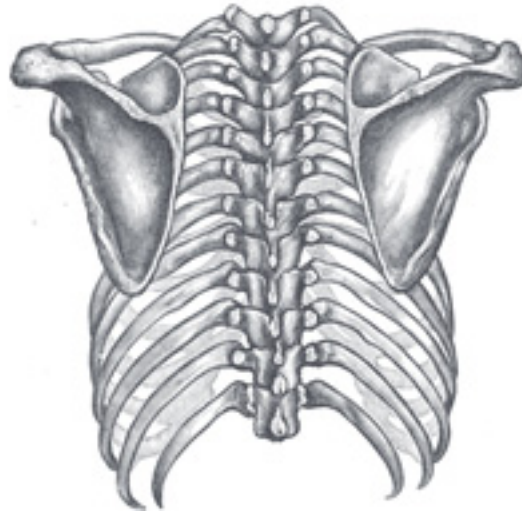


FIG. 204— Posterior view of the thorax and shoulder girdle. (Morris.) ([See enlarged image](#))

Angles.—Of the *three* angles, the **medial**, formed by the junction of the superior and vertebral borders, is thin, smooth, rounded, inclined somewhat lateralward, and gives attachment to a few fibers of the Levator scapulæ. The **inferior angle**, thick and rough, is formed by the union of the vertebral and axillary borders; its dorsal surface affords attachment to the Teres major and frequently to a few fibers of the Latissimus dorsi. The **lateral angle** is the thickest part of the bone, and is sometimes called the head of the scapula. On it is a shallow pyriform, articular surface, the **glenoid cavity**, which is directed lateralward and forward and articulates with the head of the humerus; it is broader below than above and its vertical diameter is the longest. The surface is covered with cartilage in the fresh state; and its margins, slightly raised, give attachment to a fibrocartilaginous structure, the **glenoidal labrum**, which deepens the cavity. At its apex is a slight elevation, the **supraglenoid tuberosity**, to which the long head of the Biceps brachii is attached. The **neck** of the scapula is the slightly constricted portion which surrounds the head; it is more distinct below and behind than above and in front. 11

The Coracoid Process (*processus coracoideus*).—The coracoid process is a thick curved process attached by a broad base to the upper part of the neck of the scapula; it runs at first upward and medialward; then, becoming smaller, it changes its direction, and projects forward and lateralward. The ascending portion, flattened from before backward, presents in front a smooth concave surface, across which the Subscapularis passes. The horizontal portion is flattened from above downward; its upper surface is convex and irregular, and gives attachment to the Pectoralis minor; its under surface is smooth; its medial and lateral borders are rough; the former gives attachment to the Pectoralis minor and 12

the latter to the coracoacromial ligament; the apex is embraced by the conjoined tendon of origin of the Coracobrachialis and short head of the Biceps brachii and gives attachment to the coracoclavicular fascia. On the medial part of the root of the coracoid process is a rough impression for the attachment of the conoid ligament; and running from it obliquely forward and lateralward, on to the upper surface of the horizontal portion, is an elevated ridge for the attachment of the trapezoid ligament.

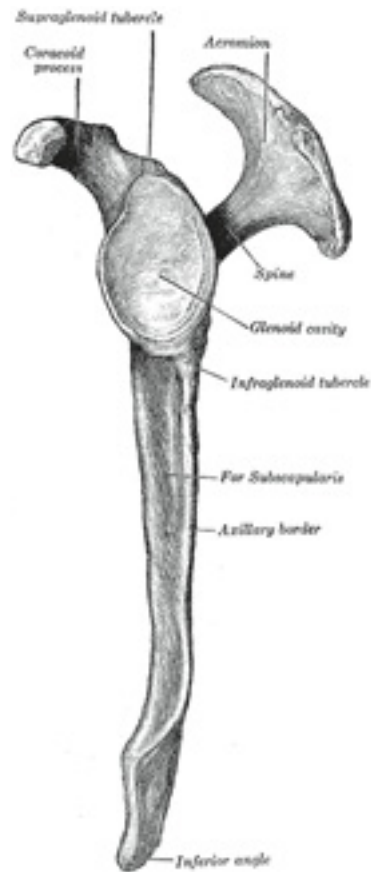

FIG. 205– Left scapula. Lateral view. ([See enlarged image](#))

Structure.—The head, processes, and the thickened parts of the bone, contain cancellous tissue; the rest consists of a thin layer of compact tissue. The central part of the supraspinatous fossa and the upper part of the infraspinatous fossa, but especially the former, are usually so thin as to be semitransparent; occasionally the bone is found wanting in this situation, and the adjacent muscles are separated only by fibrous tissue.

13

Ossification (Fig. 206).—The scapula is ossified from *seven* or more centers: one for the body, two for the coracoid process, two for the acromion, one for the vertebral border, and one for the inferior angle.

14

Ossification of the body begins about the second month of fetal life, by the formation of an irregular quadrilateral plate of bone, immediately behind the glenoid cavity. This plate extends so as to form the chief part of the bone, the spine growing up from its dorsal surface about the third month. At birth, a large part of the scapula is osseous, but the glenoid cavity, the coracoid process, the acromion, the vertebral border, and the inferior angle are cartilaginous. From the fifteenth to the eighteenth month after birth, ossification takes place in the middle of the coracoid process, which as a rule becomes joined with the rest of the bone about the fifteenth year. Between the fourteenth and twentieth years, ossification of the remaining parts takes place in quick succession, and usually in the following order; first, in the root of the coracoid process, in the form of a broad scale; secondly, near the base of the acromion; thirdly, in the inferior angle and contiguous part of the vertebral border; fourthly, near the extremity of the acromion; fifthly, in the vertebral border. The base of the acromion is formed by an extension from the spine; the two separate nuclei of the acromion unite, and then join with the extension from the spine. The upper third of the glenoid cavity is ossified from a separate center (subcoracoid), which makes its appearance between the tenth and eleventh years and joins between the sixteenth and the eighteenth. Further, an epiphysical plate appears for the lower part of the glenoid cavity, while the tip of the coracoid process frequently presents a separate nucleus. These various epiphyses are joined to the bone by the twenty-fifth year. Failure of bony union between the acromion and spine sometimes occurs, the junction being effected by fibrous tissue, or by an imperfect articulation; in some cases of supposed fracture of the acromion with ligamentous union, it is probable that the detached segment was never united to the rest of the bone.

15

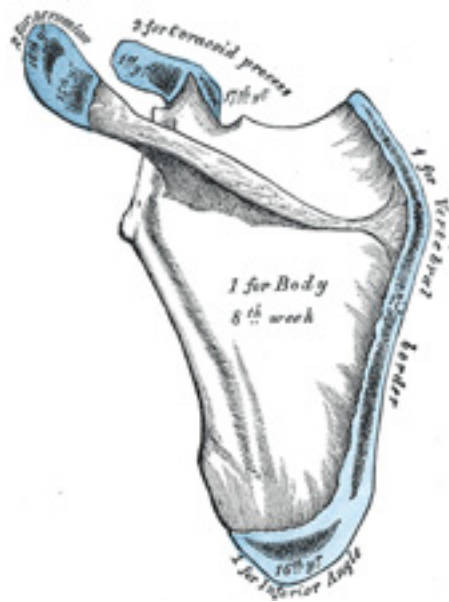


FIG. 206— Plan of ossification of the scapula. From seven centers. ([See enlarged image](#))

6a. 3. The Humerus

(Arm Bone)

1

The **humerus** ([Figs. 207, 208](#)) is the longest and largest bone of the upper extremity; it is divisible into a **body** and **two extremities**.

Upper Extremity.—The upper extremity consists of a large rounded *head* joined to the body by a constricted portion called the **neck**, and two eminences, the **greater** and **lesser tubercles**.

2

The Head (*caput humeri*).—The head, nearly hemispherical in form, [54](#) is directed upward, medialward, and a little backward, and articulates with the glenoid cavity of the scapula. The circumference of its articular surface is slightly constricted and is termed the **anatomical neck**, in

3

contradistinction to a constriction below the tubercles called the **surgical neck** which is frequently the seat of fracture. Fracture of the anatomical neck rarely occurs.

The **Anatomical Neck** (*collum anatomicum*) is obliquely directed, forming an obtuse angle with the body. It is best marked in the lower half of its circumference; in the upper half it is represented by a narrow groove separating the head from the tubercles. It affords attachment to the articular capsule of the shoulder-joint, and is perforated by numerous vascular foramina. 4

The Greater Tubercle (*tuberculum majus; greater tuberosity*).—The greater tubercle is situated lateral to the head and lesser tubercle. Its upper surface is rounded and marked by three flat impressions: the highest of these gives insertion to the Supraspinatus; the middle to the Infraspinatus; the lowest one, and the body of the bone for about 2.5 cm. below it, to the Teres minor. The lateral surface of the greater tubercle is convex, rough, and continuous with the lateral surface of the body. 5

The Lesser Tubercle (*tuberculum minus; lesser tuberosity*).—The lesser tubercle, although smaller, is more prominent than the greater: it is situated in front, and is directed medialward and forward. Above and in front it presents an impression for the insertion of the tendon of the Subscapularis. 6

The tubercles are separated from each other by a deep groove, the **intertubercular groove** (*bicipital groove*), which lodges the long tendon of the Biceps brachii and transmits a branch of the anterior humeral circumflex artery to the shoulder-joint. It runs obliquely downward, and ends near the junction of the upper with the middle third of the bone. In the fresh state its upper part is covered with a thin layer of cartilage, lined by a prolongation of the synovial membrane of the shoulder-joint; its lower portion gives insertion to the tendon of the Latissimus dorsi. It is deep and narrow above, and becomes shallow and a little broader as it descends. Its lips are called, respectively, the **crests of the greater and lesser tubercles** (*bicipital ridges*), and form the upper parts of the anterior and medial borders of the body of the bone. 7

The Body or Shaft (*corpus humeri*).—The body is almost cylindrical in the upper half of its extent, prismatic and flattened below, and has three borders and three surfaces. 8

Borders.—The **anterior border** runs from the front of the greater tubercle above to the coronoid fossa below, separating the antero-medial from the antero-lateral surface. Its upper part is a prominent ridge, the crest of the greater tubercle; it serves for the insertion of the tendon of the Pectoralis major. About its center it forms the anterior boundary of the deltoid tuberosity; below, it is smooth and rounded, affording attachment to the Brachialis. 9

The **lateral border** runs from the back part of the greater tubercle to the lateral epicondyle, and separates the anterolateral from the posterior surface. Its upper half is rounded and indistinctly marked, serving for the attachment of the lower part of the insertion of the Teres minor, and below this giving origin to the lateral head of the Triceps brachii; its center is traversed by a broad but shallow oblique depression, the **radial sulcus** (*musculospiral groove*). Its lower part forms a prominent, rough margin, a little curved from behind forward, the **lateral supracondylar ridge**, which presents an anterior lip for the origin of the Brachioradialis above, and Extensor carpi radialis longus below, a posterior lip for the Triceps brachii, and an intermediate ridge for the attachment of the lateral intermuscular septum. 10

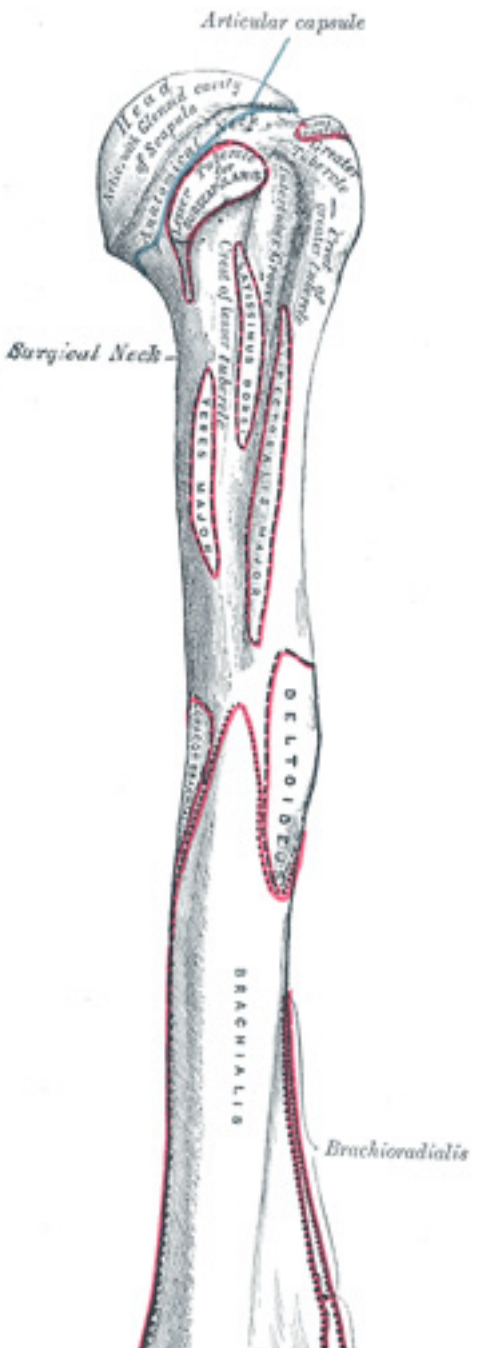


FIG. 207– Left humerus. Anterior view. ([See enlarged image](#))

The **medial border** extends from the lesser tubercle to the medial epicondyle. Its upper third consists of a prominent ridge, the **crest of the lesser tubercle**, which gives insertion to the tendon of the Teres major. About its center is a slight impression for the insertion of the Coracobrachialis, and just below this is the entrance of the nutrient canal, directed downward; sometimes there is a second nutrient canal at the commencement of the radial sulcus. The inferior third of this border is raised into a slight ridge, the **medial supracondylar ridge**, which becomes very prominent below; it presents an anterior lip for the origins of the Brachialis and Pronator teres, a posterior lip for the medial head of the Triceps brachii, and an intermediate ridge for the attachment of the medial intermuscular septum. 11

Surfaces.—The **antero-lateral surface** is directed lateralward above, where it is smooth, rounded, and covered by the Deltoideus; forward and lateralward below, where it is slightly concave from above downward, and gives origin to part of the Brachialis. About the middle of this surface is a rough, triangular elevation, the **deltoid tuberosity** for the insertion of the Deltoideus; below this is the **radial sulcus**, directed obliquely from behind, forward, and downward, and transmitting the radial nerve and profunda artery. 12

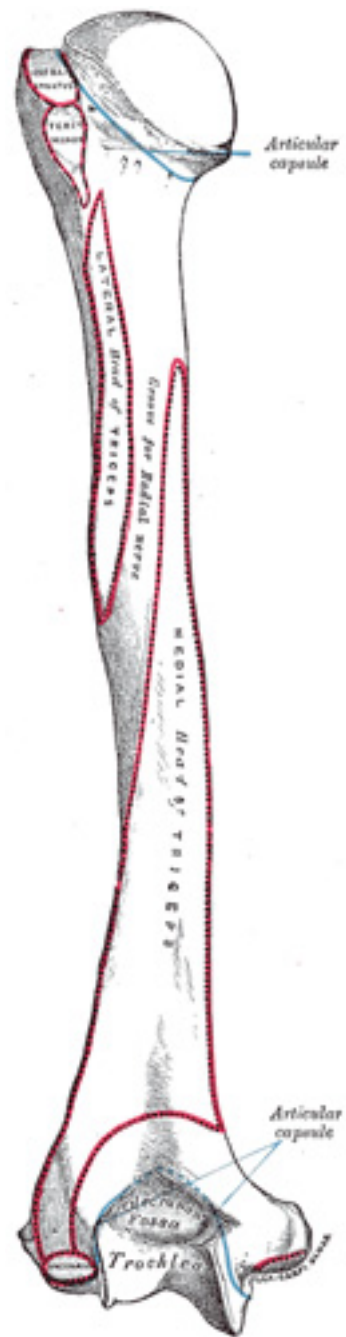


FIG. 208– Left humerus. Posterior view. ([See enlarged image](#))

The **antero-medial surface**, less extensive than the antero-lateral, is directed medialward above, forward and medialward below; its upper part is narrow, and forms the floor of the intertubercular groove which gives insertion to the tendon of the Latissimus dorsi; its middle part is slightly rough for the attachment of some of the fibers of the tendon of insertion of the Coracobrachialis; its lower part is smooth, concave from above downward, and gives origin to the Brachialis. [55](#) 13

The **posterior surface** appears somewhat twisted, so that its upper part is directed a little medialward, its lower part backward and a little lateralward. Nearly the whole of this surface is covered by the lateral and medial heads of the Triceps brachii, the former arising above, the latter below the radial sulcus. 14

The Lower Extremity.—The lower extremity is flattened from before backward, and curved slightly forward; it ends below in a broad, articular surface, which is divided into two parts by a slight ridge. Projecting on either side are the lateral and medial epicondyles. The **articular surface** extends a little lower than the epicondyles, and is curved slightly forward; its medial extremity occupies a lower level than the lateral. The lateral portion of this surface consists of a smooth, rounded eminence, named the **capitulum of the humerus**; it articulates with the cupshaped depression on the head of the radius, and is limited to the front and lower part of the bone. On the medial side of this eminence is a shallow groove, in which is received the medial margin of the head of the radius. Above the front part of the capitulum is a slight depression, the **radial fossa**, which receives the anterior border of the head of the radius, when the forearm is flexed. The medial portion of the articular surface is named the **trochlea**, and presents a deep depression between two well-marked borders; it is convex from before backward, concave from side to side, and occupies the anterior, lower, and posterior parts of the extremity. The lateral border separates it from the groove which articulates with the margin of the head of the radius. The medial border is thicker, of greater length, and consequently more prominent, than the lateral. The grooved portion of the articular surface fits accurately within the semilunar notch of the ulna; it is broader and deeper on the posterior than on the anterior aspect of the bone, and is inclined obliquely downward and forward toward the medial side. Above the front part of the trochlea is a small depression, the **coronoid fossa**, which receives the coronoid process of the ulna during flexion of the forearm. Above the back part of the trochlea is a deep triangular depression, the **olecranon fossa**, in which the summit of the olecranon is received in extension of the forearm. These fossæ are separated from one another by a thin, transparent lamina of bone, which is sometimes perforated by **asupratrochlear foramen**; they are lined in the fresh state by the synovial membrane of the elbow-joint, and their margins afford attachment to the anterior and posterior ligaments of this articulation. The **lateral epicondyle** is a small, tuberculated eminence, curved a little forward, and giving attachment to the radial collateral ligament of the elbow-joint, and to a tendon common to the origin of the Supinator and some of the Extensor muscles. The **medial epicondyle**, larger and more prominent than the lateral, is directed a little backward; it gives attachment to the ulnar collateral ligament of the elbow-joint, to the Pronator teres, and to a common tendon of origin of some of the Flexor muscles of the forearm; the ulnar nerve runs in a groove on the back of this epicondyle. The epicondyles are continuous above with the supracondylar ridges. 15

Structure.—The extremities consist of cancellous tissue, covered with a thin, compact layer ([Fig. 209](#)); the body is composed of a cylinder of compact tissue, thicker at the center than toward the extremities, and contains a large medullary canal which extends along its whole length. 16

Ossification (Figs. 210, 211).—The humerus is ossified from *eight* centers, one for each of the following parts: the body, the head, the greater tubercle, the lesser tubercle, the capitulum, the trochlea, and one for each epicondyle. The center for the body appears near the middle of the bone in the eighth week of fetal life, and soon extends toward the extremities. At birth the humerus is ossified in nearly its whole length, only the extremities remaining cartilaginous. During the first year, sometimes before birth, ossification commences in the head of the bone, and during the third year the center for the greater tubercle, and during the fifth that for the lesser tubercle, make their appearance. By the sixth year the centers for the head and tubercles have joined, so as to form a single large epiphysis, which fuses with the body about the twentieth year. The lower end of the humerus is ossified as follows. At the end of the second year ossification begins in the capitulum, and extends medialward, to form the chief part of the articular end of the bone; the center for the medial part of the trochlea appears about the age of twelve. Ossification begins in the medial epicondyle about the fifth year, and in the lateral about the thirteenth or fourteenth year. About the sixteenth or seventeenth year, the lateral epicondyle and both portions of the articulating surface, having already joined, unite with the body, and at the eighteenth year the medial epicondyle becomes joined to it.

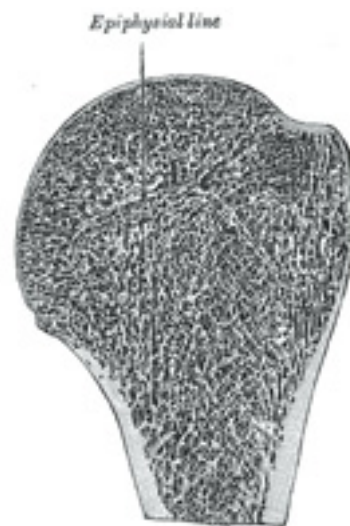

FIG. 209— Longitudinal section of head of left humerus. ([See enlarged image](#))

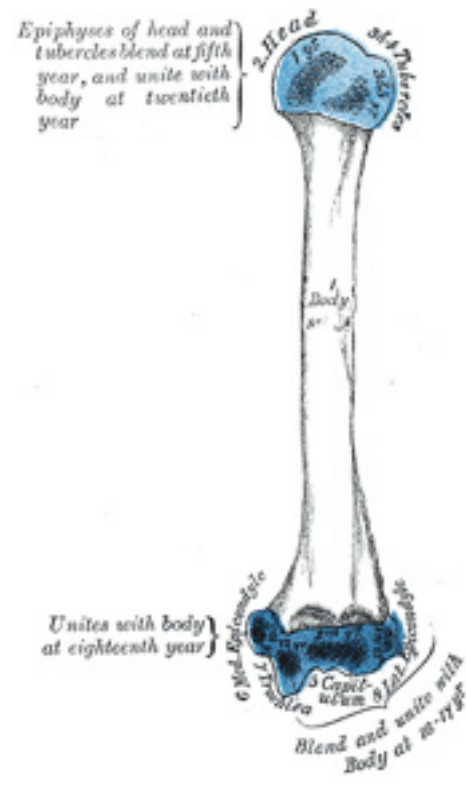


FIG. 210— Plan of ossification of the humerus. ([See enlarged image](#))

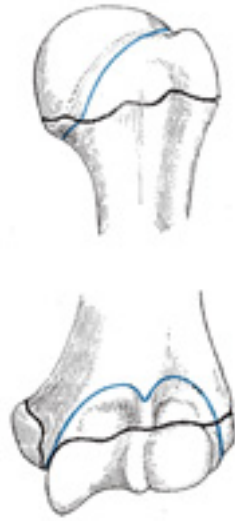

FIG. 211– Epiphysial lines of humerus in a young adult. Anterior aspect. The lines of attachment of the articular capsules are in blue. ([See enlarged image](#))

Note 54. Though the head is nearly hemispherical in form, its margin, as Humphry has shown, is by no means a true circle. Its greatest diameter is, from the top of the intertubercular groove in a direction downward, medialward, and backward. Hence it follows that the greatest elevation of the arm can be obtained by rolling the articular surface in this direction—that is to say, obliquely upward, lateralward, and forward. [[back](#)]

Note 55. A small, hook-shaped process of bone, the *supracondylar process*, varying from 2 to 20 mm. in length, is not infrequently found projecting from the antero-medial surface of the body of the humerus 5 cm. above the medial epicondyle. It is curved downward and forward, and its pointed end is connected to the medial border, just above the medial epicondyle, by a fibrous band, which gives origin to a portion of the Pronator teres; through the arch completed by this fibrous band the median nerve and brachial artery pass, when these structures deviate from their usual course. Sometimes the nerve alone is transmitted through it, or the nerve may be accompanied by the ulnar artery, in cases of high division of the brachial. A well-marked groove is usually found behind the process, in which the nerve and artery are lodged. This arch is the homologue of the supracondyloid foramen found in many animals, and probably serves in them to protect the nerve and artery from compression during the contraction of the muscles in this region. [[back](#)]

6a. 4. The Ulna

(Elbow Bone) [56](#)

1

The **ulna** ([Figs. 212, 213](#)) is a long bone, prismatic in form, placed at the medial side of the forearm, parallel with the radius. It is divisible into a **body** and **two extremities**. Its upper extremity, of great thickness and strength, forms a large part of the elbow-joint; the bone diminishes in size from above downward, its lower extremity being very small, and excluded from the wrist-joint by the interposition of an articular disk.

The Upper Extremity (proximal extremity) ([Fig. 212](#)).—The upper extremity presents two curved processes, the **olecranon** and the **coronoid process**; and two concave, articular cavities, the **semilunar** and **radial notches**.

2

The Olecranon (olecranon process).—The olecranon is a large, thick, curved eminence, situated at the upper and back part of the ulna. It is bent forward at the summit so as to present a prominent lip which is received into the olecranon fossa of the humerus in extension of the forearm. Its **base** is contracted where it joins the body and the narrowest part of the upper end of the ulna. Its **posterior surface**, directed backward, is triangular, smooth, subcutaneous, and covered by a bursa. Its **superior surface** is of quadrilateral form, marked behind by a rough impression for the insertion of the Triceps brachii; and in front, near the margin, by a slight transverse groove for the attachment of part of the posterior ligament of the elbow-joint. Its **anterior surface** is smooth, concave, and forms the upper part of the semilunar notch. Its **borders** present continuations of the groove on the margin of the superior surface; they serve for the attachment of ligaments, viz., the back part of the ulnar collateral ligament medially, and the posterior ligament laterally. From the medial border a part of the Flexor carpi ulnaris arises; while to the lateral border the Anconæus is attached.

3

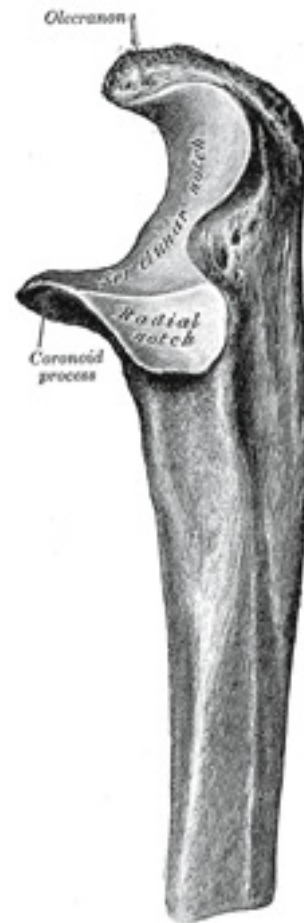

FIG. 212— Upper extremity of left ulna. Lateral aspect. ([See enlarged image](#))

The Coronoid Process (*processus coronoideus*).—The coronoid process is a triangular eminence projecting forward from the upper and front part of the ulna. Its **base** is continuous with the body of the bone, and of considerable strength. Its **apex** is pointed, slightly curved upward, and

in flexion of the forearm is received into the coronoid fossa of the humerus. Its **upper surface** is smooth, concave, and forms the lower part of the semilunar notch. Its **antero-inferior surface** is concave, and marked by a rough impression for the insertion of the Brachialis. At the junction of this surface with the front of the body is a rough eminence, the **tuberosity of the ulna**, which gives insertion to a part of the Brachialis; to the lateral border of this tuberosity the oblique cord is attached. Its **lateral surface** presents a narrow, oblong, articular depression, the **radial notch**. Its **medial surface**, by its prominent, free margin, serves for the attachment of part of the ulnar collateral ligament. At the front part of this surface is a small rounded eminence for the origin of one head of the Flexor digitorum sublimis; behind the eminence is a depression for part of the origin of the Flexor digitorum profundus; descending from the eminence is a ridge which gives origin to one head of the Pronator teres. Frequently, the Flexor pollicis longus arises from the lower part of the coronoid process by a rounded bundle of muscular fibers.

The Semilunar Notch (*incisura semilunaris; greater sigmoid cavity*).—The semilunar notch is a large depression, formed by the olecranon and the coronoid process, and serving for articulation with the trochlea of the humerus. About the middle of either side of this notch is an indentation, which contracts it somewhat, and indicates the junction of the olecranon and the coronoid process. The notch is concave from above downward, and divided into a medial and a lateral portion by a smooth ridge running from the summit of the olecranon to the tip of the coronoid process. The medial portion is the larger, and is slightly concave transversely; the lateral is convex above, slightly concave below. 5

The Radial Notch (*incisura radialis; lesser sigmoid cavity*).—The radial notch is a narrow, oblong, articular depression on the lateral side of the coronoid process; it receives the circumferential articular surface of the head of the radius. It is concave from before backward, and its prominent extremities serve for the attachment of the annular ligament. 6

The Body or Shaft (*corpus ulnæ*).—The body at its upper part is prismatic in form, and curved so as to be convex behind and lateralward; its central part is straight; its lower part is rounded, smooth, and bent a little lateralward. It tapers gradually from above downward, and has three borders and three surfaces. 7

Borders.—The **volar border** (*margo volaris; anterior border*) begins above at the prominent medial angle of the coronoid process, and ends below in front of the styloid process. Its upper part, well-defined, and its middle portion, smooth and rounded, give origin to the Flexor digitorum profundus; its lower fourth serves for the origin of the Pronator quadratus. This border separates the volar from the medial surface. 8

The **dorsal border** (*margo dorsalis; posterior border*) begins above at the apex of the triangular subcutaneous surface at the back part of the olecranon, and ends below at the back of the styloid process; it is well-marked in the upper three-fourths, and gives attachment to an aponeurosis which affords a common origin to the Flexor carpi ulnaris, the Extensor carpi ulnaris, and the Flexor digitorum profundus; its lower fourth is smooth and rounded. This border separates the medial from the dorsal surface. 9

The **interosseous crest** (*crista interossea; external or interosseous border*) begins above by the union of two lines, which converge from the extremities of the radial notch and enclose between them a triangular space for the origin of part of the Supinator; it ends below at the head of the ulna. Its upper part is sharp, its lower fourth smooth and rounded. This crest gives attachment to the interosseous membrane, and separates the volar from the dorsal surface. 10

Surfaces.—The **volar surface** (*facies volaris; anterior surface*), much broader above than below, is concave in its upper three-fourths, and gives origin to the Flexor digitorum profundus; its lower fourth, also concave, is covered by the Pronator quadratus. The lower fourth is separated from the remaining portion by a ridge, directed obliquely downward and medialward, which marks the extent of origin of the Pronator quadratus. At the junction of the upper with the middle third of the bone is the nutrient canal, directed obliquely upward. ¹¹

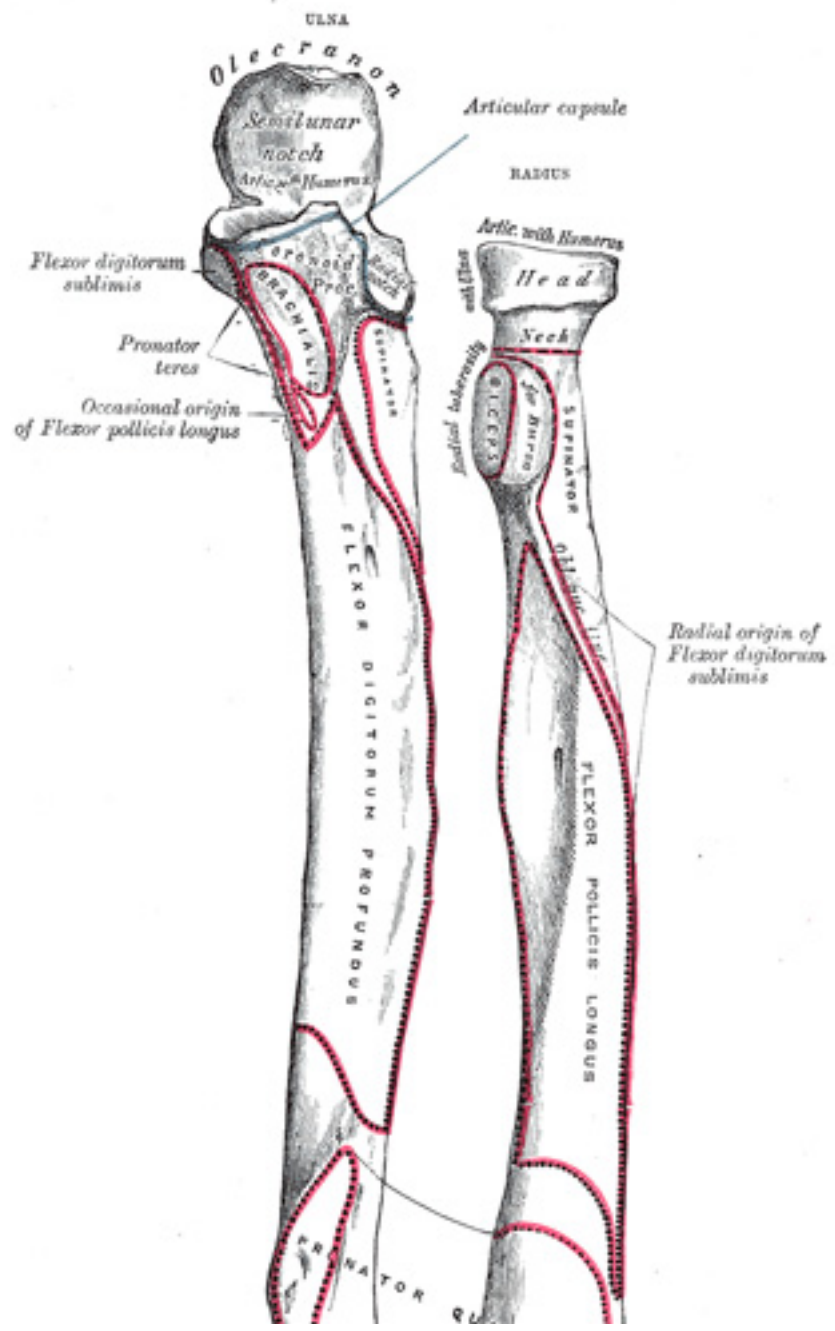


FIG. 213– Bones of left forearm. Anterior aspect. ([See enlarged image](#))

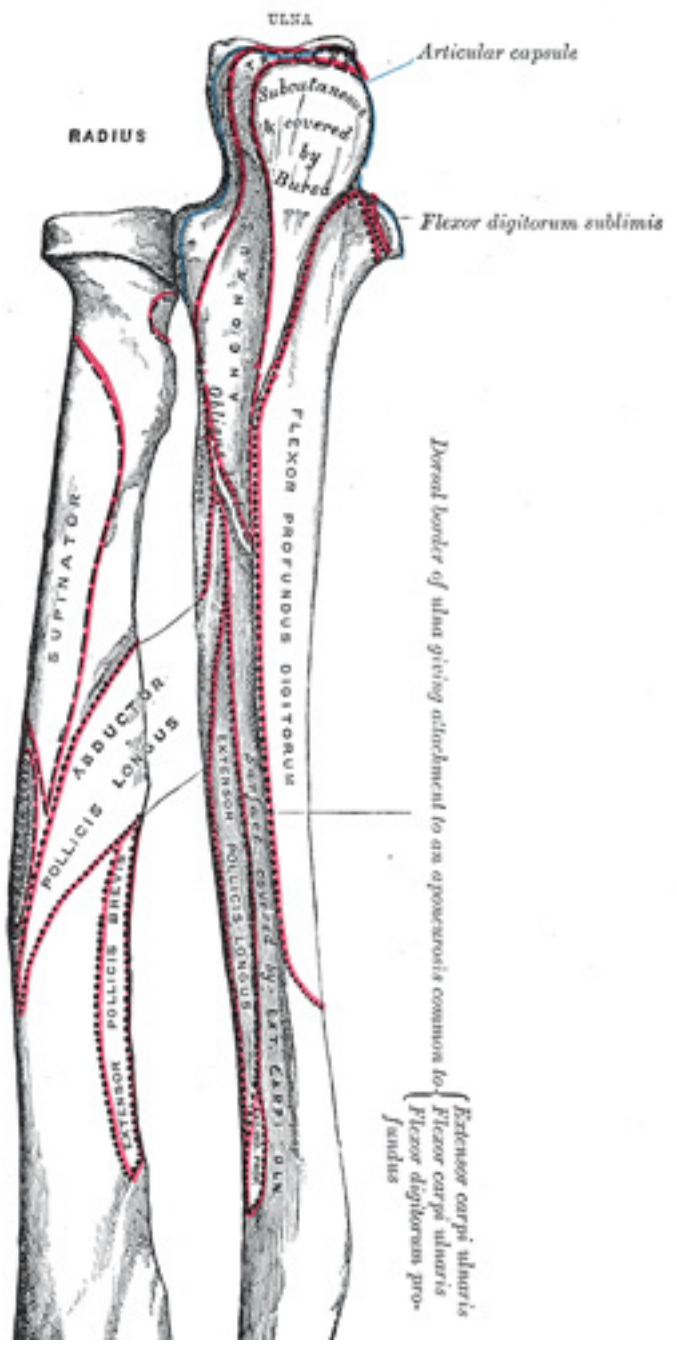


FIG. 214– Bones of left forearm. Posterior aspect. ([See enlarged image](#))

The **dorsal surface** (*facies dorsalis; posterior surface*) directed backward and lateralward, is broad and concave above; convex and somewhat narrower in the middle; narrow, smooth, and rounded below. On its upper part is an oblique ridge, which runs from the dorsal end of the radial notch, downward to the dorsal border; the triangular surface above this ridge receives the insertion of the Anconæus, while the upper part of the ridge affords attachment to the Supinator. Below this the surface is subdivided by a longitudinal ridge, sometimes called the **perpendicular line**, into two parts: the medial part is smooth, and covered by the Extensor carpi ulnaris; the lateral portion, wider and rougher, gives origin from above downward to the Supinator, the Abductor pollicis longus, the Extensor pollicis longus, and the Extensor indicis proprius.

12

The **medial surface** (*facies medialis; internal surface*) is broad and concave above, narrow and convex below. Its upper three-fourths give origin to the Flexor digitorum profundus; its lower fourth is subcutaneous.

13

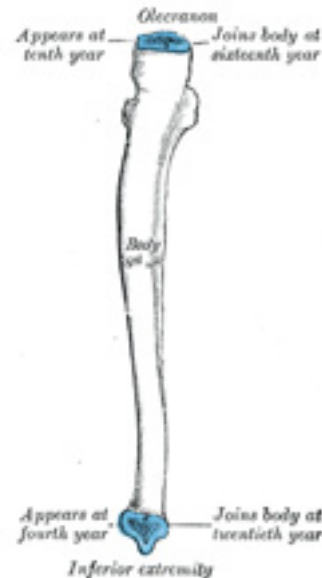


FIG. 215– Plan of ossification of the ulna. From three centers. ([See enlarged image](#))

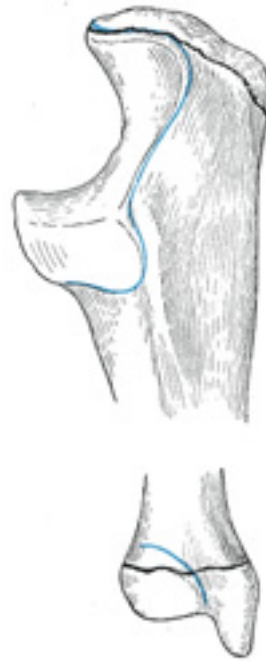

FIG. 216– Epiphysial lines of ulna in a young adult. Lateral aspect. The lines of attachment of the articular capsules are in blue. ([See enlarged image](#))

The Lower Extremity (*distal extremity*).—The lower extremity of the ulna is small, and presents two eminences; the lateral and larger is a rounded, articular eminence, termed the head of the ulna; the medial, narrower and more projecting, is a non-articular eminence, the styloid process. The **head** presents an articular surface, part of which, of an oval or semilunar form, is directed downward, and articulates with the upper surface of the triangular articular disk which separates it from the wrist-joint; the remaining portion, directed lateralward, is narrow, convex, and received into the ulnar notch of the radius. The **styloid process** projects from the medial and back part of the bone; it descends a little lower than the head, and its rounded end affords attachment to the ulnar collateral ligament of the wrist-joint. The head is separated from the styloid process by a depression for the attachment of the apex of the triangular articular disk, and behind, by a shallow groove for the tendon of the Extensor carpi ulnaris.

Structure.—The long, narrow medullary cavity is enclosed in a strong wall of compact tissue which is thickest along the interosseous border and dorsal surface. At the extremities the compact layer thins. The compact layer is continued onto the back of the olecranon as a plate of close spongy bone with lamellæ parallel. From the inner surface of this plate and the compact layer below it trabeculæ arch forward toward the olecranon and coronoid and cross other trabeculæ, passing backward over the medullary cavity from the upper part of the shaft below the coronoid. Below the coronoid process there is a small area of compact bone from which trabeculæ curve upward to end obliquely to the surface of the semilunar notch which is coated with a thin layer of compact bone. The trabeculæ at the lower end have a more longitudinal direction. 15

Ossification (Figs. 215, 216).—The ulna is ossified from *three* centers: one each for the body, the inferior extremity, and the top of the olecranon. Ossification begins near the middle of the body, about the eighth week of fetal life, and soon extends through the greater part of the bone. At birth the ends are cartilaginous. About the fourth year, a center appears in the middle of the head, and soon extends into the styloid process. About the tenth year, a center appears in the olecranon near its extremity, the chief part of this process being formed by an upward extension of the body. The upper epiphysis joins the body about the sixteenth, the lower about the twentieth year. 16

Articulations.—The ulna articulates with the humerus and radius. 17

Note 56. In the anatomical position, the forearm is placed in extension and supination with the palm looking forward and the thumb on the outer side. [[back](#)]

6a. 5. The Radius

The **radius** (Figs. 213, 214) is situated on the lateral side of the ulna, which exceeds it in length and size. Its upper end is small, and forms only a small part of the elbow-joint; but its lower end is large, and forms the chief part of the wrist-joint. It is a long bone, prismatic in form and slightly curved longitudinally. It has a body and two extremities. 1

The Upper Extremity (proximal extremity).—The upper extremity presents a head, neck, and tuberosity. The **head** is of a cylindrical form, and on its upper surface is a shallow cup or fovea for articulation with the capitulum of the humerus. The circumference of the head is smooth; it is broad medially where it articulates with the radial notch of the ulna, narrow in the rest of its extent, which is embraced by the annular ligament. The head is supported on a round, smooth, and constricted portion called the **neck**, on the back of which is a slight ridge for the insertion of part of the Supinator. Beneath the neck, on the medial side, is an eminence, the **radial tuberosity**; its surface is divided into a posterior, rough portion, for the insertion of the tendon of the Biceps brachii, and an anterior, smooth portion, on which a bursa is interposed between the tendon and the bone. 2

The Body or Shaft (corpus radii).—The body is prismoid in form, narrower above than below, and slightly curved, so as to be convex lateralward. It presents three borders and three surfaces. 3

Borders.—The **volar border** (*margo volaris; anterior border*) extends from the lower part of the tuberosity above to the anterior part of the base of the styloid process below, and separates the volar from the lateral surface. Its upper third is prominent, and from its oblique direction has received the name of the **oblique line of the radius**; it gives origin to the Flexor digitorum sublimis and Flexor pollicis longus; the surface above the line gives insertion to part of the Supinator. The middle third of the volar border is indistinct and rounded. The lower fourth is prominent, and gives insertion to the Pronator quadratus, and attachment to the dorsal carpal ligament; it ends in a small tubercle, into which the tendon of the Brachioradialis is inserted. 4

The **dorsal border** (*margo dorsalis; posterior border*) begins above at the back of the neck, and ends below at the posterior part of the base of the styloid process; it separates the posterior from the lateral surface. It is indistinct above and below, but well-marked in the middle third of the bone. 5

The **interosseous crest** (*crista interossea; internal or interosseous border*) begins above, at the back part of the tuberosity, and its upper part is rounded and indistinct; it becomes sharp and prominent as it descends, and at its lower part divides into two ridges which are continued to the anterior and posterior margins of the ulnar notch. To the posterior of the two ridges the lower part of the interosseous membrane is attached, while the triangular surface between the ridges gives insertion to part of the Pronator quadratus. This crest separates the volar from the dorsal surface, and gives attachment to the interosseous membrane. 6

Surface.—The **volar surface** (*facies volaris; anterior surface*) is concave in its upper three-fourths, and gives origin to the Flexor pollicis longus; it is broad and flat in its lower fourth, and affords insertion to the Pronator quadratus. A prominent ridge limits the insertion of the Pronator quadratus below, and between this and the inferior border is a triangular rough surface for the attachment of the volar radiocarpal ligament. At the junction of the upper and middle thirds of the volar surface is the nutrient foramen, which is directed obliquely upward. 7

The **dorsal surface** (*facies dorsalis; posterior surface*) is convex, and smooth in the upper third of its extent, and covered by the Supinator. Its middle third is broad, slightly concave, and gives origin to the Abductor pollicis longus above, and the Extensor pollicis brevis below. Its lower third is broad, convex, and covered by the tendons of the muscles which subsequently run in the grooves on the lower end of the bone. 8

The **lateral surface** (*facies lateralis; external surface*) is convex throughout its entire extent. Its upper third gives insertion to the Supinator. About its center is a rough ridge, for the insertion of the Pronator teres. Its lower part is narrow, and covered by the tendons of the Abductor pollicis longus and Extensor pollicis brevis. 9

The Lower Extremity.—The lower extremity is large, of quadrilateral form, and provided with two articular surfaces—one below, for the carpus, and another at the medial side, for the ulna. The carpal articular surface is triangular, concave, smooth, and divided by a slight antero-posterior ridge into two parts. Of these, the lateral, triangular, articulates with the navicular bone; the medial, quadrilateral, with the lunate bone. The articular surface for the ulna is called the **ulnar notch (sigmoid cavity) of the radius**; it is narrow, concave, smooth, and articulates with the head of the ulna. These two articular surfaces are separated by a prominent ridge, to which the base of the triangular articular disk is attached; this disk separates the wrist-joint from the distal radioulnar articulation. This end of the bone has three non-articular surfaces—volar, dorsal, and lateral. The **volar surface**, rough and irregular, affords attachment to the volar radiocarpal ligament. The **dorsal surface** is convex, affords attachment to the dorsal radiocarpal ligament, and is marked by three grooves. Enumerated from the lateral side, the first groove is broad, but 10

shallow, and subdivided into two by a slight ridge; the lateral of these two transmits the tendon of the Extensor carpi radialis longus, the medial the tendon of the Extensor carpi radialis brevis. The second is deep but narrow, and bounded laterally by a sharply defined ridge; it is directed obliquely from above downward and lateralward, and transmits the tendon of the Extensor pollicis longus. The third is broad, for the passage of the tendons of the Extensor indicis proprius and Extensor digitorum communis. The **lateral surface** is prolonged obliquely downward into a strong, conical projection, the **styloid process**, which gives attachment by its base to the tendon of the Brachioradialis, and by its apex to the radial collateral ligament of the wrist-joint. The lateral surface of this process is marked by a flat groove, for the tendons of the Abductor pollicis longus and Extensor pollicis brevis.

Structure.—The long narrow medullary cavity is enclosed in a strong wall of compact tissue which is thickest along the interosseous border and thinnest at the extremities except over the cup-shaped articular surface (fovea) of the head where it is thickened. The trabeculae of the spongy tissue are somewhat arched at the upper end and pass upward from the compact layer of the shaft to the fovea capituli; they are crossed by others parallel to the surface of the fovea. The arrangement at the lower end is somewhat similar. ¹¹

Ossification (Figs. 217, 218).—The radius is ossified from *three* centers: one for the body, and one for either extremity. That for the body makes its appearance near the center of the bone, during the eighth week of fetal life. About the end of the second year, ossification commences in the lower end; and at the fifth year, in the upper end. The upper epiphysis fuses with the body at the age of seventeen or eighteen years, the lower about the age of twenty. An additional center sometimes found in the radial tuberosity, appears about the fourteenth or fifteenth year. ¹²

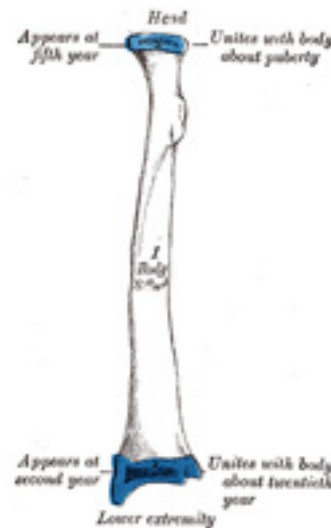

FIG. 217– Plan of ossification of the radius. From three centers. ([See enlarged image](#))



FIG. 218– Epiphysial lines of radius in a young adult. Anterior aspect. The line of attachment of the articular capsule of the wrist-joint is in blue. ([See enlarged image](#))

6b. The Hand. 1. The Carpus

The skeleton of the hand ([Figs. 219, 220](#)) is subdivided into three segments: the **carpus** or **wrist bones**; the **metacarpus** or **bones of the palm**; and the **phalanges** or **bones of the digits**.

1

2

The Carpus (Ossa Carpi)

The **carpal bones**, eight in number, are arranged in two rows. Those of the proximal row, from the radial to the ulnar side, are named the **navicular, lunate, triangular, and pisiform**; those of the distal row, in the same order, are named the **greater multangular, lesser multangular, capitate, and hamate**.

Common Characteristics of the Carpal Bones.—Each bone (excepting the pisiform) presents six surfaces. Of these the *volar* or *anterior* and the *dorsal* or *posterior surfaces* are rough, for ligamentous attachment; the dorsal surfaces being the broader, except in the navicular and lunate. The *superior* or *proximal*, and *inferior* or *distal surfaces* are articular, the superior generally convex, the inferior concave; the *medial* and *lateral surfaces* are also articular where they are in contact with contiguous bones, otherwise they are rough and tuberculated. The structure in all is similar, viz., cancellous tissue enclosed in a layer of compact bone. ³

Bones of the Proximal Row (upper row).—**The Navicular Bone** (*os naviculare manus; scaphoid bone*) (Fig. 221).—The navicular bone is the largest bone of the proximal row, and has received its name from its fancied resemblance to a boat. It is situated at the radial side of the carpus, its long axis being from above downward, lateralward, and forward. The **superior surface** is convex, smooth, of triangular shape, and articulates with the lower end of the radius. The **inferior surface**, directed downward, lateralward, and backward, is also smooth, convex, and triangular, and is divided by a slight ridge into two parts, the lateral articulating with the greater multangular, the medial with the lesser multangular. On the **dorsal surface** is a narrow, rough groove, which runs the entire length of the bone, and serves for the attachment of ligaments. The **volar surface** is concave above, and elevated at its lower and lateral part into a rounded projection, the **tubercle**, which is directed forward and gives attachment to the transverse carpal ligament and sometimes origin to a few fibers of the Abductor pollicis brevis. The **lateral surface** is rough and narrow, and gives attachment to the radial collateral ligament of the wrist. The **medial surface** presents two articular facets; of these, the superior or smaller is flattened of semilunar form, and articulates with the lunate bone; the inferior or larger is concave, forming with the lunate a concavity for the head of the capitate bone. ⁴

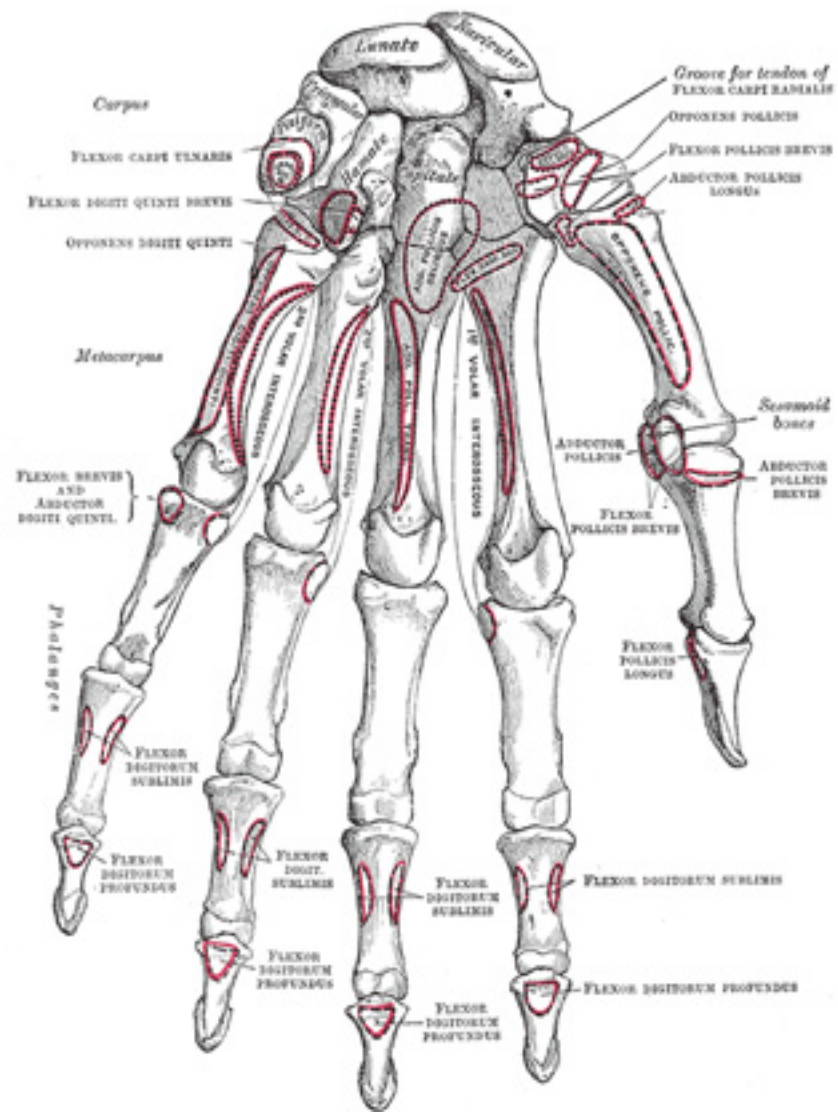


FIG. 219– Bones of the left hand. Volar surface. ([See enlarged image](#))

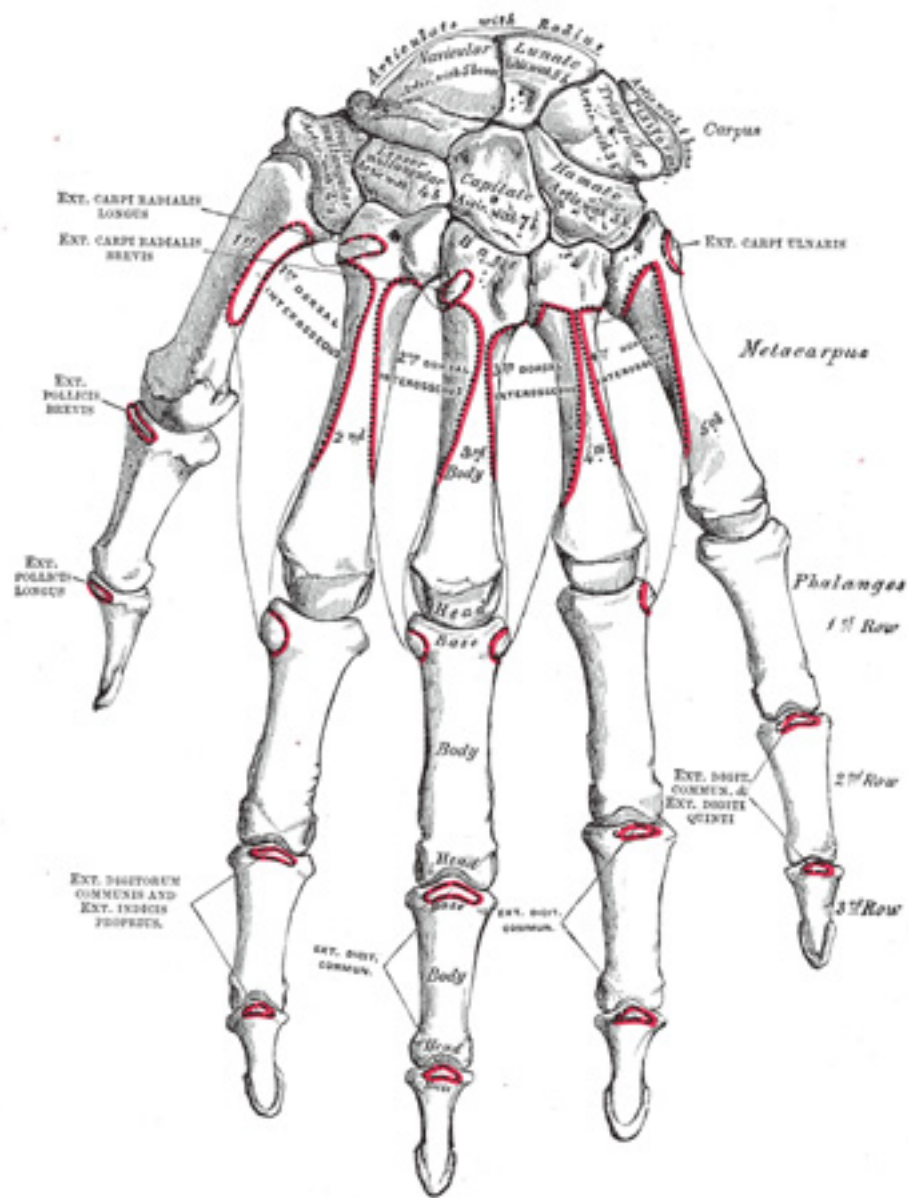


FIG. 220– Bones of the left hand. Dorsal surface. ([See enlarged image](#))

Articulations.—The navicular articulates with *five* bones: the radius proximally, greater and lesser multanguls distally, and capitate and lunate medially. 5

The Lunate Bone (*os lunatum; semilunar bone*) ([Fig. 222](#)).—The lunate bone may be distinguished by its deep concavity and crescentic outline. It is situated in the center of the proximal row of the carpus, between the navicular and triangular. The **superior surface**, convex and smooth, articulates with the radius. The **inferior surface** is deeply concave, and of greater extent from before backward than transversely: it articulates with the head of the capitate, and, by a long, narrow facet (separated by a ridge from the general surface), with the hamate. The **dorsal** and **volar surfaces** are rough, for the attachment of ligaments, the former being the broader, and of a somewhat rounded form. The **lateral surface** presents a narrow, flattened, semilunar facet for articulation with the navicular. The **medial surface** is marked by a smooth, quadrilateral facet, for articulation with the triangular. 6

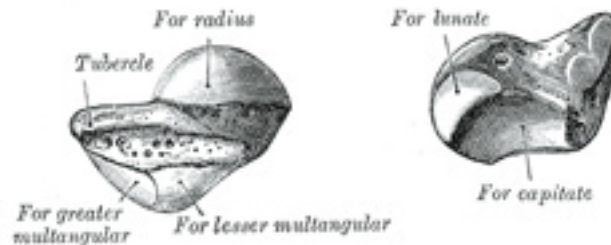


FIG. 221– The left navicular bone. ([See enlarged image](#))

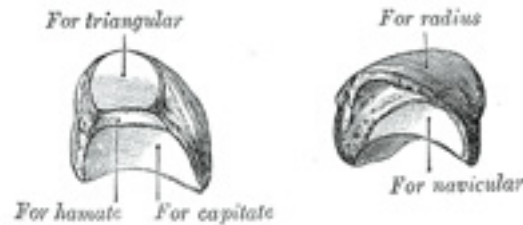


FIG. 222— The left lunate bone. ([See enlarged image](#))

Articulations.—The lunate articulates with *five* bones: the radius proximally, capitate and hamate distally, navicular laterally, and triangular medially.

7

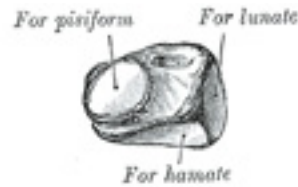

FIG. 223— The left triangular bone. ([See enlarged image](#))



FIG. 224— The left pisiform bone. ([See enlarged image](#))

The Triangular Bone (*os triquetum; cuneiform bone*) ([Fig. 223](#)).—The triangular bone may be distinguished by its pyramidal shape, and by an oval isolated facet for articulation with the pisiform bone. It is situated at the upper and ulnar side of the carpus. The **superior surface** presents a medial, rough, non-articular portion, and a lateral convex articular portion which articulates with the triangular articular disk of the wrist. The **inferior surface**, directed lateralward, is concave, sinuously curved, and smooth for articulation with the hamate. The **dorsal surface** is rough for the attachment of ligaments. The **volar surface** presents, on its medial part, an oval facet, for articulation with the pisiform; its lateral part is rough for ligamentous attachment. The **lateral surface**, the base of the pyramid, is marked by a flat, quadrilateral facet, for articulation with the lunate. The **medial surface**, the summit of the pyramid, is pointed and roughened, for the attachment of the ulnar collateral ligament of the wrist.

8

Articulations.—The triangular articulates with *three* bones: the lunate laterally, the pisiform in front, the hamate distally; and with the triangular articular disk which separates it from the lower end of the ulna. 9

The Pisiform Bone (*os pisiforme*) (Fig. 224).—The pisiform bone may be known by its small size, and by its presenting a single articular facet. 10
It is situated on a plane anterior to the other carpal bones and is spheroidal in form. Its **dorsal surface** presents a smooth, oval facet, for articulation with the triangular: this facet approaches the superior, but not the inferior border of the bone. The **volar surface** is rounded and rough, and gives attachment to the transverse carpal ligament, and to the Flexor carpi ulnaris and Abductor digiti quinti. The **lateral** and **medial surfaces** are also rough, the former being concave, the latter usually convex.

Articulation.—The pisiform articulates with *one* bone, the triangular. 11

Bones of the Distal Row (*lower row*).—**The Greater Multangular Bone (*os multangulum majus; trapezium*) (Fig. 225).**—The greater multangular bone may be distinguished by a deep groove on its volar surface. It is situated at the radial side of the carpus, between the navicular and the first metacarpal bone. The **superior surface** is directed upward and medialward; medially it is smooth, and articulates with the navicular; laterally it is rough and continuous with the lateral surface. The **inferior surface** is oval, concave from side to side, convex from before backward, so as to form a saddle-shaped surface for articulation with the base of the first metacarpal bone. The **dorsal surface** is rough. The **volar surface** is narrow and rough. At its upper part is a deep groove, running from above obliquely downward and medialward; it transmits the tendon of the Flexor carpi radialis, and is bounded laterally by an oblique ridge. This surface gives origin to the Opponens pollicis and to the Abductor and Flexor pollicis brevis; it also affords attachment to the transverse carpal ligament. The **lateral surface** is broad and rough, for the attachment of ligaments. The **medial surface** presents two facets; the upper, large and concave, articulates with the lesser multangular; the lower, small and oval, with the base of the second metacarpal. 12

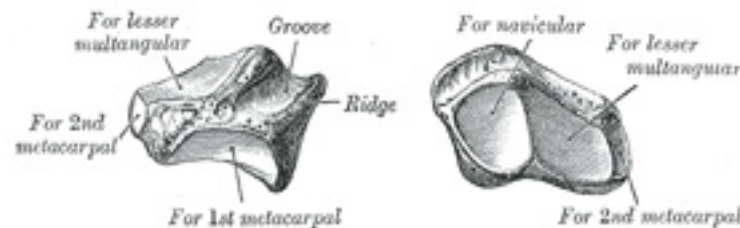


FIG. 225— The left greater multangular bone. ([See enlarged image](#))

Articulations.—The greater multangular articulates with *four* bones: the navicular proximally, the first metacarpal distally, and the lesser 13

multangular and second metacarpal medially.

The Lesser Multangular Bone (*os multangulum minus; trapezoid bone*) (Fig. 226).—The lesser multangular is the smallest bone in the distal row. It may be known by its wedge-shaped form, the broad end of the wedge constituting the dorsal, the narrow end the volar surface; and by its having four articular facets touching each other, and separated by sharp edges. The **superior surface**, quadrilateral, smooth, and slightly concave, articulates with the navicular. The **inferior surface** articulates with the proximal end of the second metacarpal bone; it is convex from side to side, concave from before backward and subdivided by an elevated ridge into two unequal facets. The **dorsal** and **volar surfaces** are rough for the attachment of ligaments, the former being the larger of the two. The **lateral surface**, convex and smooth, articulates with the greater multangular. The **medial surface** is concave and smooth in front, for articulation with the capitate; rough behind, for the attachment of an interosseous ligament. 14

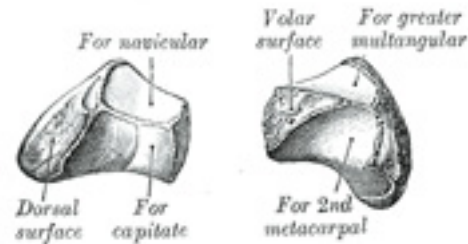


FIG. 226—The left lesser multangular bone. ([See enlarged image](#))

Articulations.—The lesser multangular articulates with *four* bones: the navicular proximally, second metacarpal distally, greater multangular laterally, and capitate medially. 15

The Capitate Bone (*os capitatum; os magnum*) (Fig. 227).—The capitate bone is the largest of the carpal bones, and occupies the center of the wrist. It presents, above, a rounded portion or head, which is received into the concavity formed by the navicular and lunate; a constricted portion or neck; and below this, the body. The **superior surface** is round, smooth, and articulates with the lunate. The **inferior surface** is divided by two ridges into three facets, for articulation with the second, third, and fourth metacarpal bones, that for the third being the largest. The **dorsal surface** is broad and rough. The **volar surface** is narrow, rounded, and rough, for the attachment of ligaments and a part of the Adductor pollicis obliquus. 16

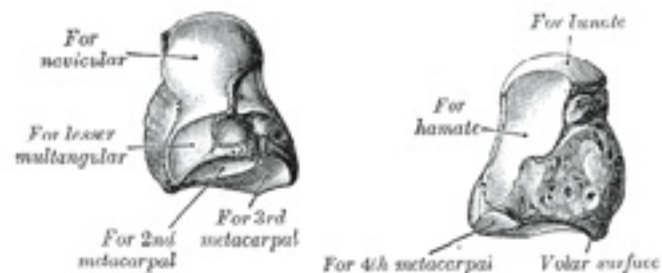


FIG. 227— The left capitate bone. ([See enlarged image](#))

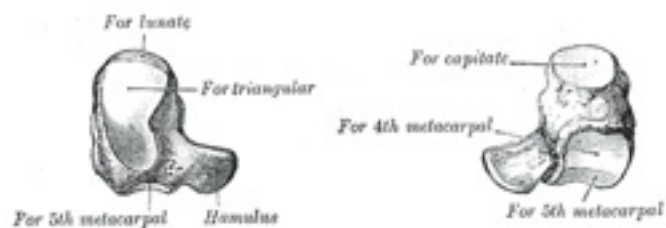

FIG. 228— The left hamate bone. ([See enlarged image](#))

The **lateral surface** articulates with the lesser multangular by a small facet at its anterior inferior angle, behind which is a rough depression for the attachment of an interosseous ligament. Above this is a deep, rough groove, forming part of the neck, and serving for the attachment of ligaments; it is bounded superiorly by a smooth, convex surface, for articulation with the navicular. The **medial surface** articulates with the hamate by a smooth, concave, oblong facet, which occupies its posterior and superior parts; it is rough in front, for the attachment of an interosseous ligament. 17

Articulations.—The capitate articulates with *seven* bones: the navicular and lunate proximally, the second, third, and fourth metacarpals distally, the lesser multangular on the radial side, and the hamate on the ulnar side. 18

The Hamate Bone (*os hamatum; unciform bone*) ([Fig. 228](#)).—The hamate bone may be readily distinguished by its wedge-shaped form, and the hook-like process which projects from its volar surface. It is situated at the medial and lower angle of the carpus, with its base downward, 19

resting on the fourth and fifth metacarpal bones, and its apex directed upward and lateralward. The **superior surface**, the apex of the wedge, is narrow, convex, smooth, and articulates with the lunate. The **inferior surface** articulates with the fourth and fifth metacarpal bones, by concave facets which are separated by a ridge. The **dorsal surface** is triangular and rough for ligamentous attachment. The **volar surface** presents, at its lower and ulnar side, a curved, hook-like process, the **hamulus**, directed forward and lateralward. This process gives attachment, by its apex, to the transverse carpal ligament and the Flexor carpi ulnaris; by its medial surface to the Flexor brevis and Opponens digiti quinti; its lateral side is grooved for the passage of the Flexor tendons into the palm of the hand. It is one of the four eminences on the front of the carpus to which the transverse carpal ligament of the wrist is attached; the others being the pisiform medially, the oblique ridge of the greater multangular and the tubercle of the navicular laterally. The **medial surface** articulates with the triangular bone by an oblong facet, cut obliquely from above, downward and medialward. The *lateral surface* articulates with the capitate by its upper and posterior part, the remaining portion being rough, for the attachment of ligaments.

Articulations.—The hamate articulates with *five* bones: the lunate proximally, the fourth and fifth metacarpals distally, the triangular medially, the capitate laterally. 20

6b. 2. The Metacarpus

The **metacarpus** consists of five cylindrical bones which are numbered from the lateral side (*ossa metacarpalia I-V*); each consists of a body and two extremities. 1

Common Characteristics of the Metacarpal Bones.—The Body (*corpus; shaft*).—The body is prismoid in form, and curved, so as to be convex in the longitudinal direction behind, concave in front. It presents three surfaces: medial, lateral, and dorsal. The **medial and lateral surfaces** are concave, for the attachment of the Interossei, and separated from one another by a prominent anterior ridge. The **dorsal surface** presents in its distal two-thirds a smooth, triangular, flattened area which is covered in the fresh state, by the tendons of the Extensor muscles. This surface is bounded by two lines, which commence in small tubercles situated on either side of the digital extremity, and, passing upward, converge and meet some distance above the center of the bone and form a ridge which runs along the rest of the dorsal surface to the carpal extremity. This ridge separates two sloping surfaces for the attachment of the Interossei dorsales. To the tubercles on the digital extremities are attached the collateral ligaments of the metacarpophalangeal joints. 2

The **Base or Carpal Extremity (*basis*)** is of a cuboidal form, and broader behind than in front: it articulates with the carpus, and with the adjoining metacarpal bones; its **dorsal and volar surfaces** are rough, for the attachment of ligaments. 3

The **Head or Digital Extremity (*capitulum*)** presents an oblong surface markedly convex from before backward, less so transversely, and flattened from side to side; it articulates with the proximal phalanx. It is broader, and extends farther upward, on the volar than on the dorsal aspect, and is longer in the antero-posterior than in the transverse diameter. On either side of the head is a tubercle for the attachment of the collateral ligament of the metacarpophalangeal joint. The **dorsal surface**, broad and flat, supports the Extensor tendons; the **volar surface** is grooved in the middle line for the passage of the Flexor tendons, and marked on either side by an articular eminence continuous with the terminal 4

articular surface.

Characteristics of the Individual Metacarpal Bones.—The First Metacarpal Bone (*os metacarpale I; metacarpal bone of the thumb*) (Fig. 229) is shorter and stouter than the others, diverges to a greater degree from the carpus, and its volar surface is directed toward the palm. The **body** is flattened and broad on its dorsal surface, and does not present the ridge which is found on the other metacarpal bones; its volar surface is concave from above downward. On its radial border is inserted the Opponens pollicis; its ulnar border gives origin to the lateral head of the first Interosseus dorsalis. The **base** presents a concavo-convex surface, for articulation with the greater multangular; it has no facets on its sides, but on its radial side is a tubercle for the insertion of the Abductor pollicis longus. The **head** is less convex than those of the other metacarpal bones, and is broader from side to side than from before backward. On its volar surface are two articular eminences, of which the lateral is the larger, for the two sesamoid bones in the tendons of the Flexor pollicis brevis.

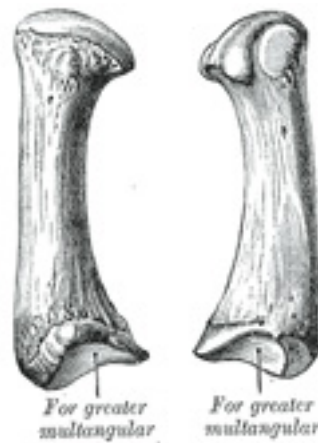

FIG. 229— The first metacarpal. (Left.) (See enlarged image)

The Second Metacarpal Bone (*os metacarpale II; metacarpal bone of the index finger*) (Fig. 230) is the longest, and its base the largest, of the four remaining bones. Its **base** is prolonged upward and medialward, forming a prominent ridge. It presents four articular facets: three on the upper surface and one on the ulnar side. Of the facets on the upper surface the intermediate is the largest and is concave from side to side, convex from before backward for articulation with the lesser multangular; the lateral is small, flat and oval for articulation with the greater multangular; the medial, on the summit of the ridge, is long and narrow for articulation with the capitate. The facet on the ulnar side articulates with the third metacarpal. The Extensor carpi radialis longus is inserted on the dorsal surface and the Flexor carpi radialis on the volar surface of the base.

The Third Metacarpal Bone (*os metacarpale III; metacarpal bone of the middle finger*) (Fig. 231) is a little smaller than the second. The dorsal

aspect of its **base** presents on its radial side a pyramidal eminence, the **styloid process**, which extends upward behind the capitate; immediately distal to this is a rough surface for the attachment of the Extensor carpi radialis brevis. The carpal articular facet is concave behind, flat in front, and articulates with the capitate. On the radial side is a smooth, concave facet for articulation with the second metacarpal, and on the ulnar side two small oval facets for the fourth metacarpal.

The Fourth Metacarpal Bone (*os metacarpale IV; metacarpal bone of the ring finger*)(Fig. 232) is shorter and smaller than the third. The **base** is small and quadrilateral; its superior surface presents two facets, a large one medially for articulation with the hamate, and a small one laterally for the capitate. On the radial side are two oval facets, for articulation with the third metacarpal; and on the ulnar side a single concave facet, for the fifth metacarpal.

The Fifth Metacarpal Bone (*os metacarpale V; metacarpal bone of the little finger*)(Fig. 233) presents on its **base** one facet on its superior surface, which is concavo-convex and articulates with the hamate, and one on its radial side, which articulates with the fourth metacarpal. On its ulnar side is a prominent tubercle for the insertion of the tendon of the Extensor carpi ulnaris. The dorsal surface of the body is divided by an oblique ridge, which extends from near the ulnar side of the base to the radial side of the head. The lateral part of this surface serves for the attachment of the fourth Interosseus dorsalis; the medial part is smooth, triangular, and covered by the Extensor tendons of the little finger.

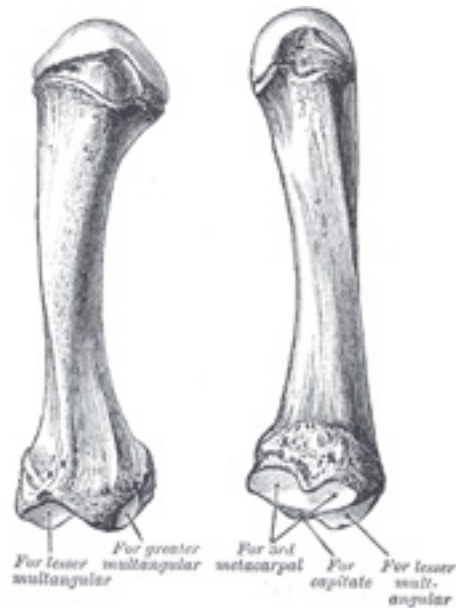


FIG. 230– The second metacarpal. (Left.) ([See enlarged image](#))

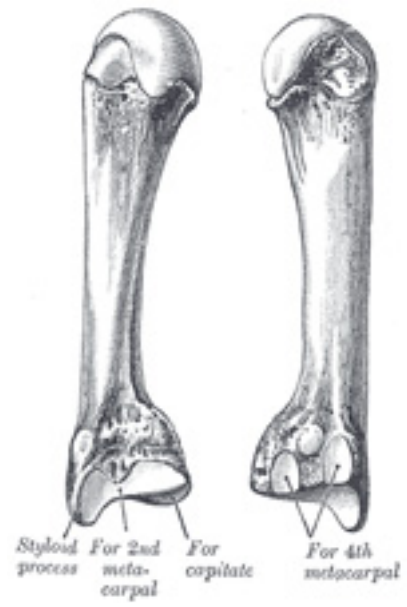

FIG. 231— The third metacarpal. (Left.) ([See enlarged image](#))

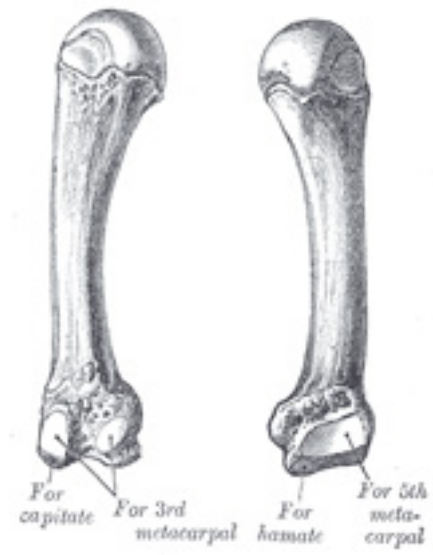


FIG. 232– The fourth metacarpal. (Left.) ([See enlarged image](#))

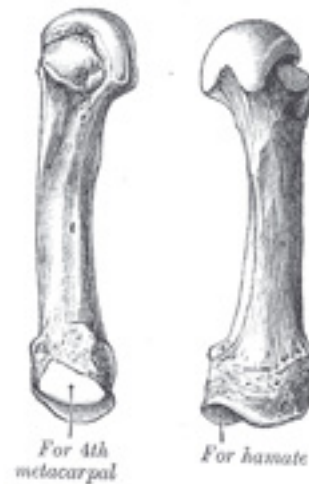

FIG. 233— The fifth metacarpal. (Left.) ([See enlarged image](#))

Articulations.—Besides their phalangeal articulations, the metacarpal bones articulate as follows: the first with the greater multangular; the second with the greater multangular, lesser multangular, capitate and third metacarpal; the third with the capitate and second and fourth metacarpals; the fourth with the capitate, hamate, and third and fifth metacarpals; and the fifth with the hamate and fourth metacarpal.

6b. 3. The Phalanges of the Hand

(Phalanges Digitorum Manus)

1

The **phalanges** are fourteen in number, three for each finger, and two for the thumb. Each consists of a body and two extremities. The **body** tapers from above downward, is convex posteriorly, concave in front from above downward, flat from side to side; its sides are marked by rough which give attachment to the fibrous sheaths of the Flexor tendons. The **proximal extremities** of the bones of the first row present oval, concave articular surfaces, broader from side to side than from before backward. The **proximal extremity** of each of the bones of the second and third rows presents a double concavity separated by a median ridge. The **distal extremities** are smaller than the proximal, and each ends in two condyles separated by a shallow groove; the articular surface extends farther on the volar than on the dorsal surface, a condition best marked in the bones of the first row.

The **ungual phalanges** are convex on their dorsal and flat on their volar surfaces; they are recognized by their small size, and by a roughened, elevated surface of a horseshoe form on the volar surface of the distal extremity of each which serves to support the sensitive pulp of the finger.

2

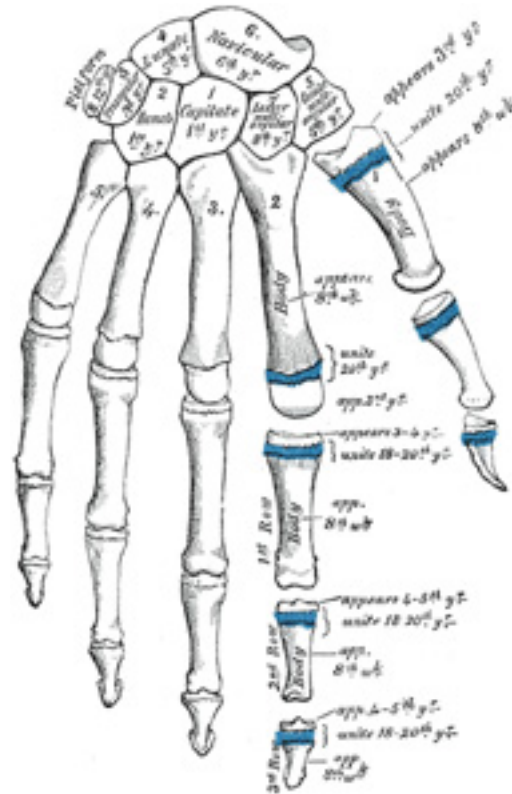


FIG. 234— Plan of ossification of the hand. ([See enlarged image](#))

Articulations.—In the four fingers the phalanges of the first row articulate with those of the second row and with the metacarpals; the phalanges of the second row with those of the first and third rows, and the unguis phalanges with those of the second row. In the thumb, which has only two phalanges, the first phalanx articulates by its proximal extremity with the metacarpal bone and by its distal with the unguis phalanx.

3

Ossification of the Bones of the Hand.—The **carpal bones** are each ossified from a single center, and ossification proceeds in the following order ([Fig. 234](#)): in the capitate and hamate, during the first year, the former preceding the latter; in the triangular, during the third year; in the lunate and greater multangular, during the fifth year, the former preceding the latter; in the navicular, during the sixth year; in the lesser multangular, during the eighth year; and in the pisiform, about the twelfth year

4

Occasionally an additional bone, the *os centrale*, is found on the back of the carpus, lying between the navicular, lesser multangular, and capitate. During the second month of fetal life it is represented by a small cartilaginous nodule, which usually fuses with the cartilaginous navicular. Sometimes the styloid process of the third metacarpal is detached and forms an additional ossicle.

5

The **metacarpal bones** are each ossified from *two* centers: one for the body and one for the distal extremity of each of the second, third, fourth, and fifth bones; one for the body and one for the base of the first metacarpal bone. [57](#) The first metacarpal bone is therefore ossified in the same manner as the phalanges, and this has led some anatomists to regard the thumb as being made up of three phalanges, and not of a metacarpal bone and two phalanges. Ossification commences in the middle of the body about the eighth or ninth week of fetal life, the centers for the second and third metacarpals being the first, and that for the first metacarpal, the last, to appear; about the third year the distal extremities of the metacarpals of the fingers, and the base of the metacarpal of the thumb, begin to ossify; they unite with the bodies about the twentieth year.

6

The **phalanges** are each ossified from *two* centers: one for the body, and one for the proximal extremity. Ossification begins in the body, about the eighth week of fetal life. Ossification of the proximal extremity commences in the bones of the first row between the third and fourth years, and a year later in those of the second and third rows. The two centers become united in each row between the eighteenth and twentieth years.

7

In the ungual phalanges the centers for the bodies appear at the distal extremities of the phalanges, instead of at the middle of the bodies, as in the other phalanges. Moreover, of all the bones of the hand, the ungual phalanges are the first to ossify.

8

Note 57. Allen Thomson demonstrated the fact that the first metacarpal bone is often developed from three centers: that is to say, there is a separate nucleus for the distal end, forming a distinct epiphysis visible at the age of seven or eight years. He also stated that there are traces of a proximal epiphysis in the second metacarpal bone, *Journal of Anatomy and Physiology*, 1869. [\[back\]](#)

6c. The Bones of the Lower Extremity. 1. The Hip Bone

(*Ossa Extremitatis Inferioris*) & (*Os Coxæ; Innominate Bone*)

1

The **hip bone** is a large, flattened, irregularly shaped bone, constricted in the center and expanded above and below. It meets its fellow on the opposite side in the middle line in front, and together they form the sides and anterior wall of the pelvic cavity. It consists of three parts, the **ilium**, **ischium**, and **pubis**, which are distinct from each other in the young subject, but are fused in the adult; the union of the three parts takes place in and around a large cup-shaped articular cavity, the **acetabulum**, which is situated near the middle of the outer surface of the bone. The **ilium**, so-called because it supports the flank, is the superior broad and expanded portion which extends upward from the acetabulum. The **ischium** is the lowest and strongest portion of the bone; it proceeds downward from the acetabulum, expands into a large tuberosity, and then, curving forward, forms, with the pubis, a large aperture, the **obturator foramen**. The **pubis** extends medialward and downward from the

acetabulum and articulates in the middle line with the bone of the opposite side: it forms the front of the pelvis and supports the external organs of generation.

The Ilium (*os ilii*).—The ilium is divisible into two parts, the **body** and the **ala**; the separation is indicated on the internal surface by a curved line, the **arcuate line**, and on the external surface by the margin of the acetabulum. 2

The Body (*corpus oss. ilii*).—The body enters into the formation of the acetabulum, of which it forms rather less than two-fifths. Its **external surface** is partly articular, partly non-articular; the articular segment forms part of the lunate surface of the acetabulum, the non-articular portion contributes to the acetabular fossa. The **internal surface** of the body is part of the wall of the lesser pelvis and gives origin to some fibers of the Obturator internus. Below, it is continuous with the pelvic surfaces of the ischium and pubis, only a faint line indicating the place of union. 3

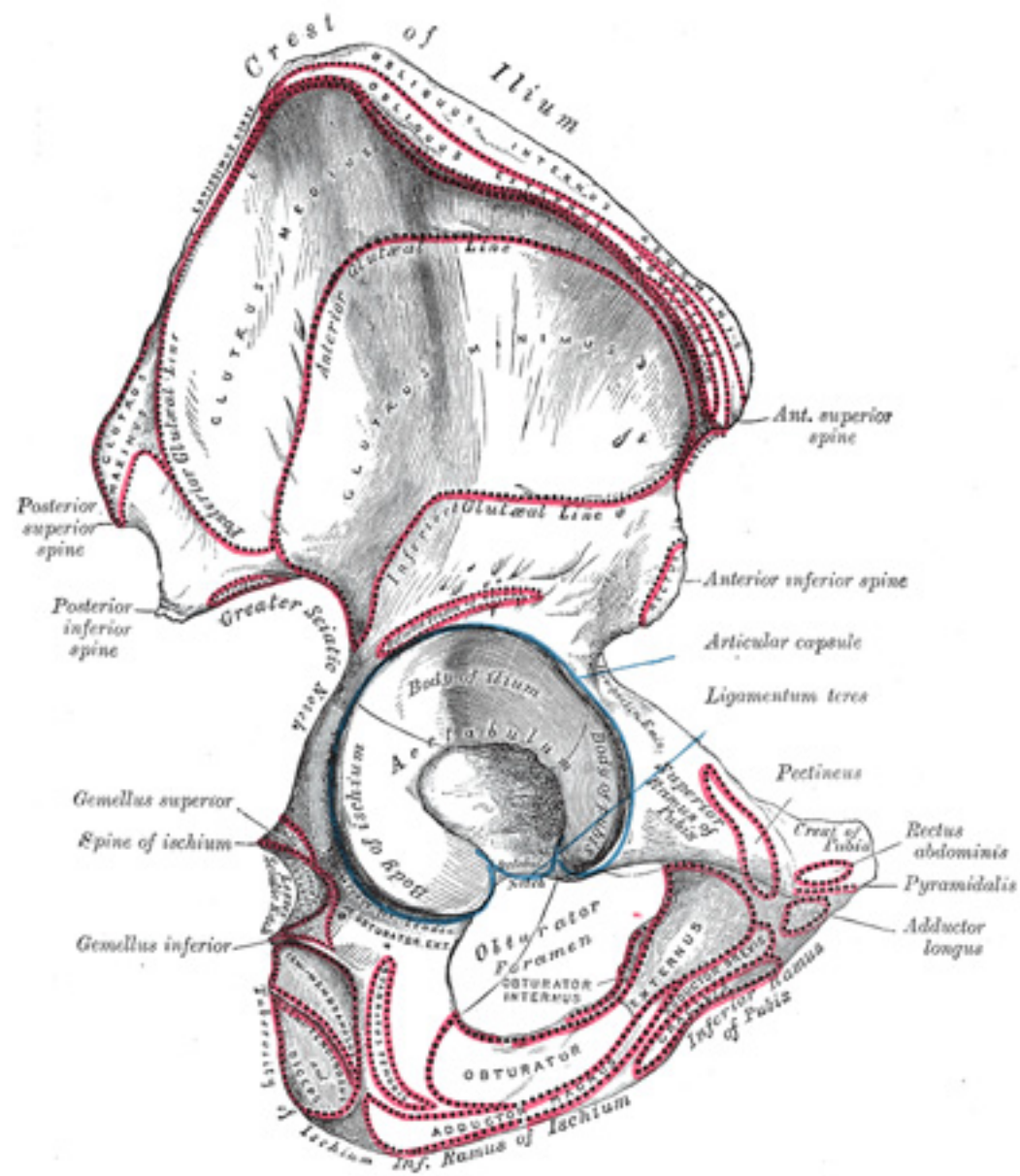


FIG. 235— Right hip bone. External surface. ([See enlarged image](#))

The Ala (*ala oss. ilii*).—The ala is the large expanded portion which bounds the greater pelvis laterally. It presents for examination two surfaces—an external and an internal—a crest, and two borders—an anterior and a posterior. The **external surface** ([Fig. 235](#)), known as the **dorsum ilii**, is directed backward and lateralward behind, and downward and lateralward in front. It is smooth, convex in front, deeply concave behind; bounded above by the crest, below by the upper border of the acetabulum, in front and behind by the anterior and posterior borders. This surface is crossed in an arched direction by three lines—the posterior, anterior, and inferior gluteal lines. The **posterior gluteal line** (*superior curved line*), the shortest of the three, begins at the crest, about 5 cm. in front of its posterior extremity; it is at first distinctly marked, but as it passes downward to the upper part of the greater sciatic notch, where it ends, it becomes less distinct, and is often altogether lost. Behind this line is a narrow semilunar surface, the upper part of which is rough and gives origin to a portion of the *Glutæus maximus*; the lower part is smooth and has no muscular fibers attached to it. The **anterior gluteal line** (*middle curved line*), the longest of the three, begins at the crest, about 4 cm. behind its anterior extremity, and, taking a curved direction downward and backward, ends at the upper part of the greater sciatic notch. The space between the anterior and posterior gluteal lines and the crest is concave, and gives origin to the *Glutæus medius*. Near the middle of this line a nutrient foramen is often seen. The **inferior gluteal line** (*inferior curved line*), the least distinct of the three, begins in front at the notch on the anterior border, and, curving backward and downward, ends near the middle of the greater sciatic notch. The surface of bone included between the anterior and inferior gluteal lines is concave from above downward, convex from before backward, and gives origin to the *Glutæus minimus*. Between the inferior gluteal line and the upper part of the acetabulum is a rough, shallow groove, from which the reflected tendon of the *Rectus femoris* arises.

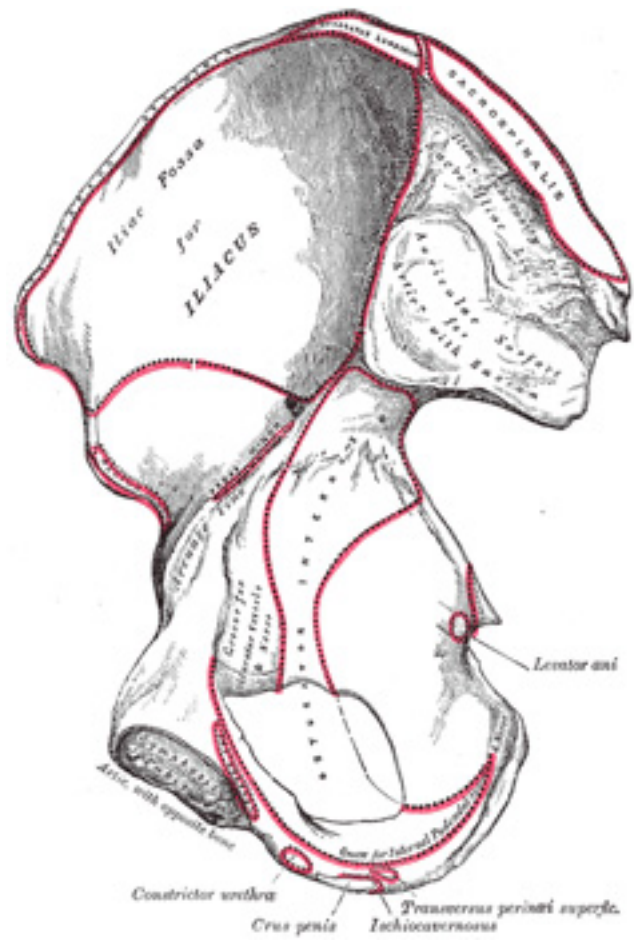


FIG. 236– Right hip bone. Internal surface. ([See enlarged image](#))

The **internal surface** ([Fig. 236](#)) of the ala is bounded above by the crest, below, by the arcuate line; in front and behind, by the anterior and posterior borders. It presents a large, smooth, concave surface, called the **iliac fossa**, which gives origin to the Iliacus and is perforated at its inner part by a nutrient canal; and below this a smooth, rounded border, the **arcuate line**, which runs downward, forward, and medialward.

Behind the iliac fossa is a rough surface, divided into two portions, an anterior and a posterior. The **anterior surface** (*auricular surface*), so called from its resemblance in shape to the ear, is coated with cartilage in the fresh state, and articulates with a similar surface on the side of the sacrum. The posterior portion, known as the **iliac tuberosity**, is elevated and rough, for the attachment of the posterior sacroiliac ligaments and for the origins of the Sacrospinalis and Multifidus. Below and in front of the auricular surface is the **preauricular sulcus**, more commonly present and better marked in the female than in the male; to it is attached the pelvic portion of the anterior sacroiliac ligament.

The **crest** of the ilium is convex in its general outline but is sinuously curved, being concave inward in front, concave outward behind. It is thinner at the center than at the extremities, and ends in the **anterior** and **posterior superior iliac spines**. The surface of the crest is broad, and divided into external and internal lips, and an intermediate line. About 5 cm. behind the anterior superior iliac spine there is a prominent tubercle on the outer lip. To the external lip are attached the Tensor fasciæ latæ, Obliquus externus abdominis, and Latissimus dorsi, and along its whole length the fascia lata; to the intermediate line the Obliquus internus abdominis; to the internal lip, the fascia iliaca, the Transversus abdominis, Quadratus lumborum, Sacrospinalis, and Iliacus. 6

The **anterior border** of the ala is concave. It presents two projections, separated by a notch. Of these, the uppermost, situated at the junction of the crest and anterior border, is called the **anterior superior iliac spine**; its outer border gives attachment to the fascia lata, and the Tensor fasciæ latæ, its inner border, to the Iliacus; while its extremity affords attachment to the inguinal ligament and gives origin to the Sartorius. Beneath this eminence is a notch from which the Sartorius takes origin and across which the lateral femoral cutaneous nerve passes. Below the notch is the **anterior inferior iliac spine**, which ends in the upper lip of the acetabulum; it gives attachment to the straight tendon of the Rectus femoris and to the iliofemoral ligament of the hip-joint. Medial to the anterior inferior spine is a broad, shallow groove, over which the Iliacus and Psoas major pass. This groove is bounded medially by an eminence, the **iliopectineal eminence**, which marks the point of union of the ilium and pubis. 7

The **posterior border** of the ala, shorter than the anterior, also presents two projections separated by a notch, the **posterior superior iliac spine** and the **posterior inferior iliac spine**. The former serves for the attachment of the oblique portion of the posterior sacroiliac ligaments and the Multifidus; the latter corresponds with the posterior extremity of the auricular surface. Below the posterior inferior spine is a deep notch, the **greater sciatic notch**. 8

The Ischium (*os ischii*).—The ischium forms the lower and back part of the hip bone. It is divisible into three portions—a **body** and **two rami**. 9

The Body (*corpus oss. ischii*).—The body enters into and constitutes a little more than two-fifths of the acetabulum. Its **external surface** forms part of the lunate surface of the acetabulum and a portion of the acetabular fossa. Its **internal surface** is part of the wall of the lesser pelvis; it gives origin to some fibers of the Obturator internus. Its anterior border projects as the **posterior obturator tubercle**; from its posterior border there extends backward a thin and pointed triangular eminence, the **ischial spine**, more or less elongated in different subjects. The external surface of the spine gives attachment to the Gemellus superior, its internal surface to the Coccygeus, Levator ani, and the pelvic fascia; while to the pointed extremity the sacrospinous ligament is attached. Above the spine is a large notch, the **greater sciatic notch**, converted into a foramen by the sacrospinous ligament; it transmits the Piriformis, the superior and inferior gluteal vessels and nerves, the sciatic and posterior femoral cutaneous nerves, the internal pudendal vessels, and nerve, and the nerves to the Obturator internus and Quadratus femoris. Of these, the superior gluteal vessels and nerve pass out above the Piriformis, the other structures below it. Below the spine is a smaller notch, the **lesser sciatic notch**; it is smooth, coated in the recent state with cartilage, the surface of which presents two or three ridges corresponding to the subdivisions 10

of the tendon of the Obturator internus, which winds over it. It is converted into a foramen by the sacrotuberous and sacrospinous ligaments, and transmits the tendon of the Obturator internus, the nerve which supplies that muscle, and the internal pudendal vessels and nerve.

The Superior Ramus (*ramus superior oss. ischii; descending ramus*).—The superior ramus projects downward and backward from the body and presents for examination three surfaces: external, internal, and posterior. The **external surface** is quadrilateral in shape. It is bounded *above* by a groove which lodges the tendon of the Obturator externus; *below*, it is continuous with the inferior ramus; in *front* it is limited by the posterior margin of the obturator foramen; *behind*, a prominent margin separates it from the posterior surface. In front of this margin the surface gives origin to the Quadratus femoris, and anterior to this to some of the fibers of origin of the Obturator externus; the lower part of the surface gives origin to part of the Adductor magnus. The **internal surface** forms part of the bony wall of the lesser pelvis. In *front* it is limited by the posterior margin of the obturator foramen. *Below*, it is bounded by a sharp ridge which gives attachment to a falciform prolongation of the sacrotuberous ligament, and, more anteriorly, gives origin to the Transversus perinæi and Ischiocavernosus. *Posteriorly* the ramus forms a large swelling, the **tuberosity of the ischium**, which is divided into two portions: a lower, rough, somewhat triangular part, and an upper, smooth, quadrilateral portion. The lower portion is subdivided by a prominent longitudinal ridge, passing from base to apex, into two parts; the outer gives attachment to the Adductor magnus, the inner to the sacrotuberous ligament. The upper portion is subdivided into two areas by an oblique ridge, which runs downward and outward; from the upper and outer area the Semimembranosus arises; from the lower and inner, the long head of the Biceps femoris and the Semitendinosus. 11

The Inferior Ramus (*ramus inferior oss. ischii; ascending ramus*).—The inferior ramus is the thin, flattened part of the ischium, which ascends from the superior ramus, and joins the inferior ramus of the pubis—the junction being indicated in the adult by a raised line. The **outer surface** is uneven for the origin of the Obturator externus and some of the fibers of the Adductor magnus; its **inner surface** forms part of the anterior wall of the pelvis. Its **medial border** is thick, rough, slightly everted, forms part of the outlet of the pelvis, and presents two ridges and an intervening space. The ridges are continuous with similar ones on the inferior ramus of the pubis: to the outer is attached the deep layer of the superficial perineal fascia (*fascia of Colles*), and to the inner the inferior fascia of the urogenital diaphragm. If these two ridges be traced downward, they will be found to join with each other just behind the point of origin of the Transversus perinæi; here the two layers of fascia are continuous behind the posterior border of the muscle. To the intervening space, just in front of the point of junction of the ridges, the Transversus perinæi is attached, and in front of this a portion of the crus penis vel clitoridis and the Ischiocavernosus. Its **lateral border** is thin and sharp, and forms part of the medial margin of the obturator foramen. 12

The Pubis (*os pubis*).—The pubis, the anterior part of the hip bone, is divisible into **abody**, a **superior** and an **inferior ramus**. 13

The Body (*corpus oss. pubis*).—The body forms one-fifth of the acetabulum, contributing by its **external surface** both to the lunate surface and the acetabular fossa. Its **internal surface** enters into the formation of the wall of the lesser pelvis and gives origin to a portion of the Obturator internus. 14

The Superior Ramus (*ramus superior oss. pubis; ascending ramus*).—The superior ramus extends from the body to the median plane where it 15

articulates with its fellow of the opposite side. It is conveniently described in two portions, viz., a medial flattened part and a narrow lateral prismatic portion.

The **Medial Portion** of the superior ramus, formerly described as the body of the pubis, is somewhat quadrilateral in shape, and presents for examination two surfaces and three borders. The **anterior surface** is rough, directed downward and outward, and serves for the origin of various muscles. The Adductor longus arises from the upper and medial angle, immediately below the crest; lower down, the Obturator externus, the Adductor brevis, and the upper part of the Gracilis take origin. The **posterior surface**, convex from above downward, concave from side to side, is smooth, and forms part of the anterior wall of the pelvis. It gives origin to the Levator ani and Obturator internus, and attachment to the puboprosthetic ligaments and to a few muscular fibers prolonged from the bladder. The **upper border** presents a prominent tubercle, the **pubic tubercle** (*pubic spine*), which projects forward; the inferior crus of the **subcutaneous inguinal ring** (*external abdominal ring*), and the **inguinal ligament** (*Poupart's ligament*) are attached to it. Passing upward and lateralward from the pubic tubercle is a well-defined ridge, forming a part of the pectineal line which marks the brim of the lesser pelvis: to it are attached a portion of the **inguinal falx** (*conjoined tendon of Obliquus internus and Transversus*), the **lacunar ligament** (*Gimbernat's ligament*), and the **reflected inguinal ligament** (*triangular fascia*). Medial to the pubic tubercle is the **crest**, which extends from this process to the medial end of the bone. It affords attachment to the inguinal falx, and to the Rectus abdominis and Pyramidalis. The point of junction of the crest with the medial border of the bone is called the **angle**; to it, as well as to the symphysis, the superior crus of the subcutaneous inguinal ring is attached. The **medial border** is articular; it is oval, and is marked by eight or nine transverse ridges, or a series of nipple-like processes arranged in rows, separated by grooves; they serve for the attachment of a thin layer of cartilage, which intervenes between it and the interpubic fibrocartilaginous lamina. The **lateral border** presents a sharp margin, the **obturator crest**, which forms part of the circumference of the obturator foramen and affords attachment to the obturator membrane.

The **Lateral Portion** of the ascending ramus has three surfaces: superior, inferior, and posterior. The **superior surface** presents a continuation of the pectineal line, already mentioned as commencing at the pubic tubercle. In front of this line, the surface of bone is triangular in form, wider laterally than medially, and is covered by the Pectineus. The surface is bounded, laterally, by a rough eminence, the **iliopectineal eminence**, which serves to indicate the point of junction of the ilium and pubis, and below by a prominent ridge which extends from the acetabular notch to the pubic tubercle. The **inferior surface** forms the upper boundary of the obturator foramen, and presents, laterally, a broad and deep, oblique groove, for the passage of the obturator vessels and nerve; and medially, a sharp margin, the **obturator crest**, forming part of the circumference of the obturator foramen, and giving attachment to the obturator membrane. The **posterior surface** constitutes part of the anterior boundary of the lesser pelvis. It is smooth, convex from above downward, and affords origin to some fibers of the Obturator internus.

The Inferior Ramus (*ramus inferior oss. pubis; descending ramus*).—The inferior ramus is thin and flattened. It passes lateralward and downward from the medial end of the superior ramus; it becomes narrower as it descends and joins with the inferior ramus of the ischium below the obturator foramen. Its **anterior surface** is rough, for the origin of muscles—the Gracilis along its medial border, a portion of the Obturator externus where it enters into the formation of the obturator foramen, and between these two, the Adductores brevis and magnus, the former being the more medial. The **posterior surface** is smooth, and gives origin to the Obturator internus, and, close to the medial margin, to the Constrictor urethræ. The **medial border** is thick, rough, and everted, especially in females. It presents two ridges, separated by an intervening space. The ridges extend downward, and are continuous with similar ridges on the inferior ramus of the ischium; to the external is attached the fascia of Colles, and to the internal the inferior fascia of the urogenital diaphragm. The **lateral border** is thin and sharp, forms part of the circumference of the obturator foramen, and gives attachment to the obturator membrane.

The Acetabulum (*cotyloid cavity*).—The acetabulum is a deep, cup-shaped, hemispherical depression, directed downward, lateralward, and forward. It is formed medially by the pubis, above by the ilium, laterally and below by the ischium; a little less than two-fifths is contributed by the ilium, a little more than two-fifths by the ischium, and the remaining fifth by the pubis. It is bounded by a prominent uneven rim, which is thick and strong above, and serves for the attachment of the **glenoidal labrum (*cotyloid ligament*)**, which contracts its orifice, and deepens the surface for articulation. It presents below a deep notch, the **acetabular notch**, which is continuous with a circular non-articular depression, the **acetabular fossa**, at the bottom of the cavity: this depression is perforated by numerous apertures, and lodges a mass of fat. The notch is converted into a foramen by the transverse ligament; through the foramen nutrient vessels and nerves enter the joint; the margins of the notch serve for the attachment of the ligamentum teres. The rest of the acetabulum is formed by a curved articular surface, the **lunate surface**, for articulation with the head of the femur.

19

The Obturator Foramen (*foramen obturatum; thyroid foramen*).—The obturator foramen is a large aperture, situated between the ischium and pubis. In the male it is large and of an oval form, its longest diameter slanting obliquely from before backward; in the female it is smaller, and more triangular. It is bounded by a thin, uneven margin, to which a strong membrane is attached, and presents, superiorly, a deep groove, the **obturator groove**, which runs from the pelvis obliquely medialward and downward. This groove is converted into a canal by a ligamentous band, a specialized part of the obturator membrane, attached to two tubercles: one, the **posterior obturator tubercle**, on the medial border of the ischium, just in front of the acetabular notch; the other, the **anterior obturator tubercle**, on the obturator crest of the superior ramus of the pubis. Through the canal the obturator vessels and nerve pass out of the pelvis.

20

Structure.—The thicker parts of the bone consist of cancellous tissue, enclosed between two layers of compact tissue; the thinner parts, as at the bottom of the acetabulum and center of the iliac fossa, are usually semitransparent, and composed entirely of compact tissue.

21

Ossification (Fig. 237).—The hip bone is ossified from *eight* centers: *three* primary—one each for the ilium, ischium, and pubis; and *five* secondary—one each for the crest of the ilium, the anterior inferior spine (said to occur more frequently in the male than in the female), the tuberosity of the ischium, the pubic symphysis (more frequent in the female than in the male), and one or more for the Y-shaped piece at the bottom of the acetabulum. The centers appear in the following order: in the lower part of the ilium, immediately above the greater sciatic notch, about the eighth or ninth week of fetal life; in the superior ramus of the ischium, about the third month; in the superior ramus of the pubis, between the fourth and fifth months. At birth, the three primary centers are quite separate, the crest, the bottom of the acetabulum, the ischial tuberosity, and the inferior rami of the ischium and pubis being still cartilaginous. By the seventh or eighth year, the inferior rami of the pubis and ischium are almost completely united by bone. About the thirteenth or fourteenth year, the three primary centers have extended their growth into the bottom of the acetabulum, and are there separated from each other by a Y-shaped portion of cartilage, which now presents traces of ossification, often by two or more centers. One of these, the *os acetabuli*, appears about the age of twelve, between the ilium and pubis, and fuses with them about the age of eighteen; it forms the pubic part of the acetabulum. The ilium and ischium then become joined, and lastly the pubis and ischium, through the intervention of this Y-shaped portion. At about the age of puberty, ossification takes place in each of the remaining portions, and they join with the rest of the bone between the twentieth and twenty-fifth years. Separate centers are frequently found for the pubic tubercle and the ischial spine, and for the crest and angle of the pubis.

22

Articulations.—The hip bone articulates with its fellow of the opposite side, and with the sacrum and femur.

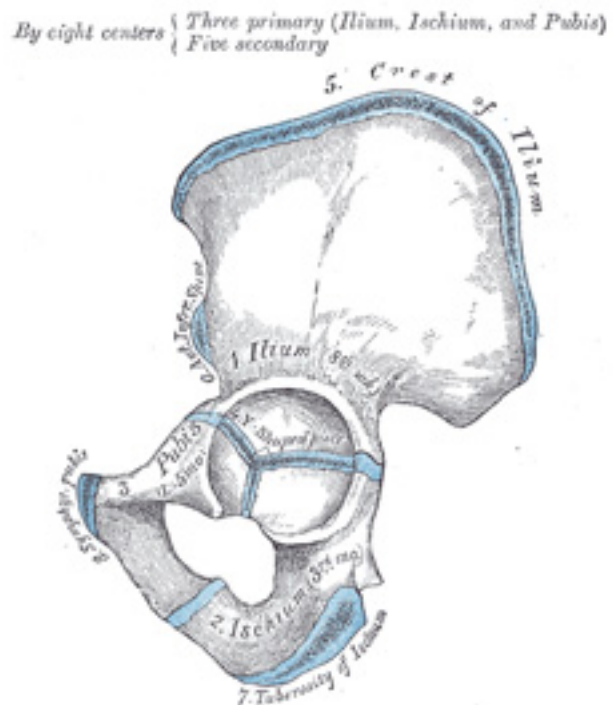


FIG. 237— Plan of ossification of the hip bone. The three primary centers unite through a Y-shaped piece about puberty. Epiphyses appear about puberty, and unite about twenty-fifth year. ([See enlarged image](#))

6c. 2. The Pelvis

The **pelvis**, so called from its resemblance to a basin, is a bony ring, interposed between the movable vertebræ of the vertebral column which it supports, and the lower limbs upon which it rests; it is stronger and more massively constructed than the wall of the cranial or thoracic cavities, and is composed of four bones: the two **hip bones** laterally and in front and the **sacrum** and **coccyx** behind. 1

The pelvis is divided by an oblique plane passing through the prominence of the sacrum, the arcuate and pectineal lines, and the upper margin of the symphysis pubis, into the greater and the lesser pelvis. The circumference of this plane is termed the **linea terminalisor pelvic brim**. 2

The Greater or False Pelvis (*pelvis major*).—The greater pelvis is the expanded portion of the cavity situated above and in front of the pelvic brim. It is bounded on either side by the ilium; in *front* it is incomplete, presenting a wide interval between the anterior borders of the ilia, which is filled up in the fresh state by the parietes of the abdomen; behind is a deep notch on either side between the ilium and the base of the sacrum. It supports the intestines, and transmits part of their weight to the anterior wall of the abdomen. 3

The Lesser or True Pelvis (*pelvis minor*).—The lesser pelvis is that part of the pelvic cavity which is situated below and behind the pelvic brim. Its bony walls are more complete than those of the greater pelvis. For convenience of description, it is divided into an **inlet** bounded by the superior circumference, and **outlet** bounded by the inferior circumference, and a **cavity**. 4

The Superior Circumference.—The superior circumference forms the brim of the pelvis, the included space being called the **superior aperture** or **inlet** (*apertura pelvis [minoris]superior*) ([Fig. 238](#)). It is formed laterally by the pectineal and arcuate lines, in front by the crests of the pubes, and behind by the anterior margin of the base of the sacrum and sacrovertebral angle. The superior aperture is somewhat heart-shaped, obtusely pointed in front, diverging on either side, and encroached upon behind by the projection forward of the promontory of the sacrum. It has three principal diameters: antero-posterior, transverse, and oblique. The **anteroposterior** or **conjugate diameter** extends from the sacrovertebral angle to the symphysis pubis; its average measurement is about 110 mm. in the female. The **transverse diameter** extends across the greatest width of the superior aperture, from the middle of the brim on one side to the same point on the opposite; its average measurement is about 135 mm. in the female. The **oblique diameter** extends from the iliopectineal eminence of one side to the sacroiliac articulation of the opposite side; its average measurement is about 125 mm. in the female. 5

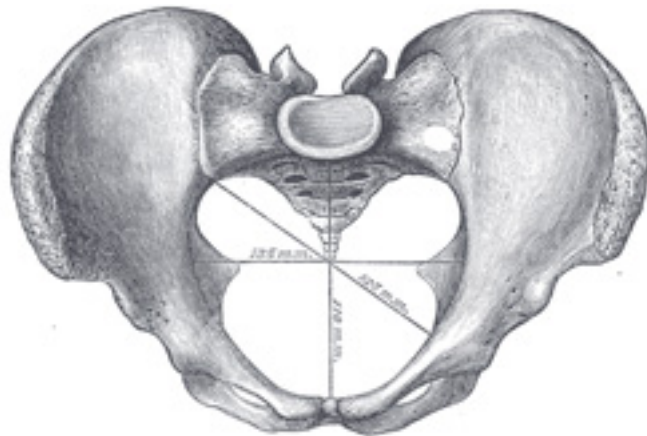


FIG. 238— Diameters of superior aperture of lesser pelvis (female). ([See enlarged image](#))

The **cavity** of the lesser pelvis is bounded in front and below by the pubic symphysis and the superior rami of the pubes; above and behind, by the pelvic surfaces of the sacrum and coccyx, which, curving forward above and below, contract the superior and inferior apertures of the cavity; laterally, by a broad, smooth, quadrangular area of bone, corresponding to the inner surfaces of the body and superior ramus of the ischium and that part of the ilium which is below the arcuate line. From this description it will be seen that the cavity of the lesser pelvis is a short, curved canal, considerably deeper on its posterior than on its anterior wall. It contains, in the fresh subject, the pelvic colon, rectum, bladder, and some of the organs of generation. The rectum is placed at the back of the pelvis, in the curve of the sacrum and coccyx; the bladder is in front, behind the pubic symphysis. In the female the uterus and vagina occupy the interval between these viscera.

6

The Lower Circumference.—The lower circumference of the pelvis is very irregular; the space enclosed by it is named the **inferior aperture** or **outlet** (*apertura pelvis [minoris] inferior*) ([Fig. 239](#)), and is bounded behind by the point of the coccyx, and laterally by the ischial tuberosities. These eminences are separated by three notches: one in front, the **pubic arch**, formed by the convergence of the inferior rami of the ischium and pubis on either side. The other notches, one on either side, are formed by the sacrum and coccyx behind, the ischium in front, and the ilium above; they are called the **sciatic notches**; in the natural state they are converted into foramina by the sacrotuberous and sacrospinous ligaments. When the ligaments are *in situ*, the inferior aperture of the pelvis is lozenge-shaped, bounded, in front, by the pubic arcuate ligament and the inferior rami of the pubes and ischia; laterally, by the ischial tuberosities; and behind, by the sacrotuberous ligaments and the tip of the coccyx.

7

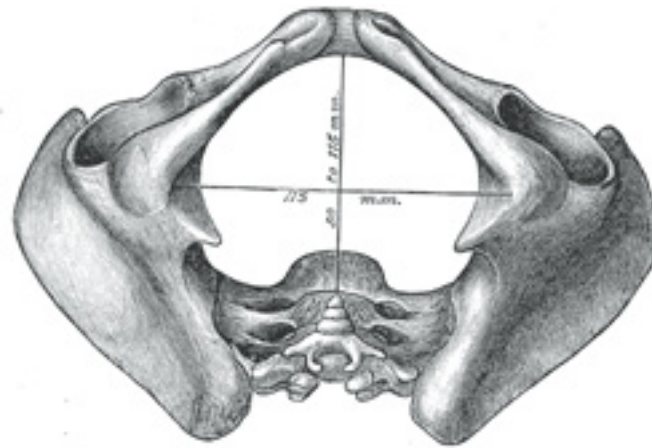


FIG. 239– Diameters of inferior aperture of lesser pelvis (female). ([See enlarged image](#))

The diameters of the outlet of the pelvis are two, antero-posterior and transverse. The **antero-posterior diameter** extends from the tip of the coccyx to the lower part of the pubic symphysis; its measurement is from 90 to 115 mm. in the female. It varies with the length of the coccyx, and is capable of increase or diminution, on account of the mobility of that bone. The **transverse diameter**, measured between the posterior parts of the ischial tuberosities, is about 115 mm. in the female. [58](#)

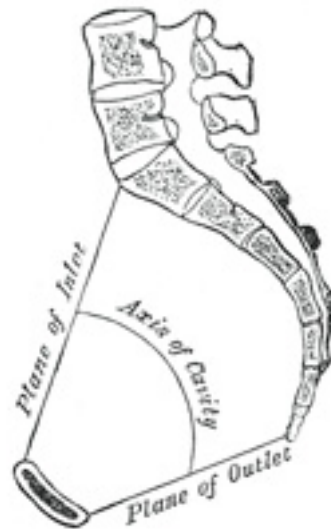

FIG. 240— Median sagittal section of pelvis. ([See enlarged image](#))

Axes (Fig. 240).—A line at right angles to the plane of the superior aperture at its center would, if prolonged, pass through the umbilicus above and the middle of the coccyx below; the axis of the superior aperture is therefore directed downward and backward. The axis of the inferior aperture, produced upward, would touch the base of the sacrum, and is also directed downward, and slightly backward. The axis of the cavity—*i. e.*, an axis at right angles to a series of planes between those of the superior and inferior apertures—is curved like the cavity itself: this curve corresponds to the concavity of the sacrum and coccyx, the extremities being indicated by the central points of the superior and inferior apertures. A knowledge of the direction of these axes serves to explain the course of the fetus in its passage through the pelvis during parturition. ⁹

Position of the Pelvis (Fig. 240).—In the erect posture, the pelvis is placed obliquely with regard to the trunk: the plane of the superior aperture forms an angle of from 50° to 60° , and that of the inferior aperture one of about 15° with the horizontal plane. The pelvic surface of the symphysis pubis looks upward and backward, the concavity of the sacrum and coccyx downward and forward. The position of the pelvis in the erect posture may be indicated by holding it so that the anterior superior iliac spines and the front of the top of the symphysis pubis are in the same vertical plane. ¹⁰

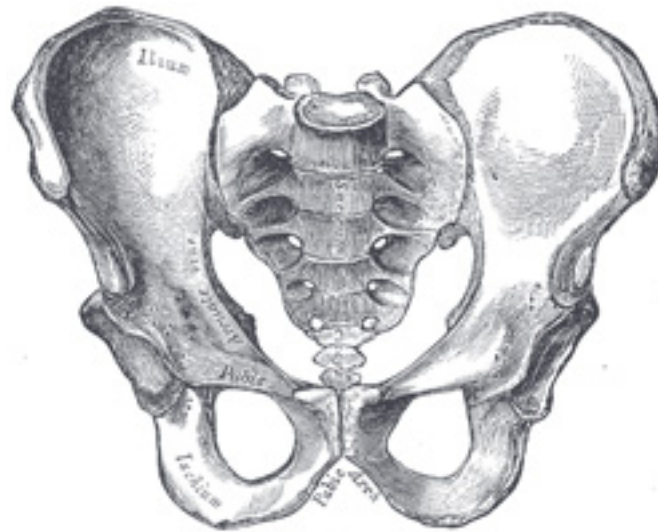


FIG. 241— Male pelvis. ([See enlarged image](#))

Differences between the Male and Female Pelves.—The *female* pelvis ([Fig. 242](#)) is distinguished from that of the *male* ([Fig. 241](#)) by its bones being more delicate and its depth less. The whole pelvis is less massive, and its muscular impressions are slightly marked. The ilia are less sloped, and the anterior iliac spines more widely separated; hence the greater lateral prominence of the hips. The preauricular sulcus is more commonly present and better marked. The superior aperture of the lesser pelvis is larger in the female than in the male; it is more nearly circular, and its obliquity is greater. The cavity is shallower and wider; the sacrum is shorter wider, and its upper part is less curved; the obturator foramina are triangular in shape and smaller in size than in the male. The inferior aperture is larger and the coccyx more movable. The sciatic notches are wider and shallower, and the spines of the ischia project less inward. The acetabula are smaller and look more distinctly forward (Derry [59](#)). The ischial tuberosities and the acetabula are wider apart, and the former are more everted. The pubic symphysis is less deep, and the pubic arch is wider and more rounded than in the male, where it is an angle rather than an arch. 11

The size of the pelvis varies not only in the two sexes, but also in different members of the same sex, and does not appear to be influenced in any way by the height of the individual. Women of short stature, as a rule, have broad pelves. Occasionally the pelvis is equally contracted in all its dimensions, so much so that all its diameters measure 12.5 mm. less than the average, and this even in well-formed women of average height. The principal divergences, however, are found at the superior aperture, and affect the relation of the antero-posterior to the transverse diameter. Thus the superior aperture may be elliptical either in a transverse or an antero-posterior direction, the transverse diameter in the former, and the 12

antero-posterior in the latter, greatly exceeding the other diameters; in other instances it is almost circular.

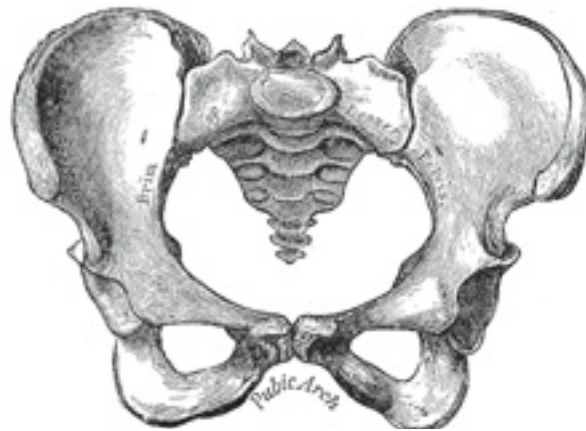


FIG. 242— Female pelvis. ([See enlarged image](#))

In the fetus, and for several years after birth, the pelvis is smaller in proportion than in the adult, and the projection of the sacrovertebral angle ¹³ less marked. The characteristic differences between the male and female pelvis are distinctly indicated as early as the fourth month of fetal life.

Abnormalities.—There is arrest of development in the bones of the pelvis in cases of extroversion of the bladder; the anterior part of the pelvic ¹⁴ girdle is deficient, the superior rami of the pubes are imperfectly developed, and the symphysis is absent. “The pubic bones are separated to the extent of from two to four inches, the superior rami shortened and directed forward, and the obturator foramen diminished in size, narrowed, and turned outward. The iliac bones are straightened out more than normal. The sacrum is very peculiar. The lateral curve, instead of being concave, is flattened out or even convex, with the iliosacral facets turned more outward than normal, while the vertical curve is straightened.” [60](#)

Note 58. The measurements of the pelvis given above are fairly accurate, but different figures are given by various authors no doubt due mainly to differences in the physique and stature of the population from whom the measurements have been taken. [[back](#)]

Note 59. Journal of Anatomy and Physiology, vol. xliii. [[back](#)]

Note 60. Wood, Heath’s Dictionary of Practical Surgery, i, 426. [[back](#)]

6c. 3. The Femur

(Thigh Bone)

1

The **femur** (Figs. 244, 245), the longest and strongest bone in the skeleton, is almost perfectly cylindrical in the greater part of its extent. In the erect posture it is not vertical, being separated above from its fellow by a considerable interval, which corresponds to the breadth of the pelvis, but inclining gradually downward and medialward, so as to approach its fellow toward its lower part, for the purpose of bringing the knee-joint near the line of gravity of the body. The degree of this inclination varies in different persons, and is greater in the female than in the male, on account of the greater breadth of the pelvis. The femur, like other long bones, is divisible into a **body** and **two extremities**.

The Upper Extremity (*proximal extremity*, Fig. 243).—The upper extremity presents for examination a **head**, a **neck**, a **greater** and a **lesser trochanter**.

2

The Head (*caput femoris*).—The head which is globular and forms rather more than a hemisphere, is directed upward, medialward, and a little forward, the greater part of its convexity being above and in front. Its surface is smooth, coated with cartilage in the fresh state, except over an ovoid depression, the **fovea capitis femoris**, which is situated a little below and behind the center of the head, and gives attachment to the ligamentum teres.

3

The Neck (*collum femoris*).—The neck is a flattened pyramidal process of bone, connecting the head with the body, and forming with the latter a wide angle opening medialward. The angle is widest in infancy, and becomes lessened during growth, so that at puberty it forms a gentle curve from the axis of the body of the bone. In the adult, the neck forms an angle of about 125° with the body, but this varies in inverse proportion to the development of the pelvis and the stature. In the female, in consequence of the increased width of the pelvis, the neck of the femur forms more nearly a right angle with the body than it does in the male. The angle decreases during the period of growth, but after full growth has been attained it does not usually undergo any change, even in old age; it varies considerably in different persons of the same age. It is smaller in short than in long bones, and when the pelvis is wide. In addition to projecting upward and medialward from the body of the femur, the neck also projects somewhat forward; the amount of this forward projection is extremely variable, but on an average is from 12° to 14°.

4

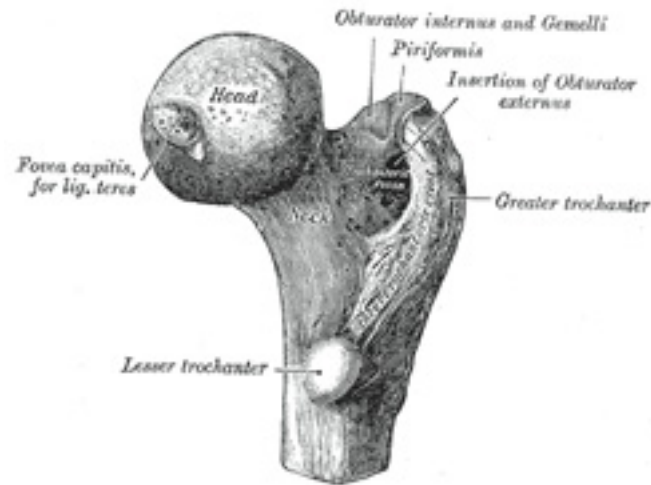


FIG. 243— Upper extremity of right femur viewed from behind and above. ([See enlarged image](#))

The neck is flattened from before backward, contracted in the middle, and broader laterally than medially. The vertical diameter of the lateral half is increased by the obliquity of the lower edge, which slopes downward to join the body at the level of the lesser trochanter, so that it measures one-third more than the antero-posterior diameter. The medial half is smaller and of a more circular shape. The **anterior surface** of the neck is perforated by numerous vascular foramina. Along the upper part of the line of junction of the anterior surface with the head is a shallow groove, best marked in elderly subjects; this groove lodges the orbicular fibers of the capsule of the hip-joint. The **posterior surface** is smooth, and is broader and more concave than the anterior: the posterior part of the capsule of the hip-joint is attached to it about 1 cm. above the intertrochanteric crest. The **superior border** is short and thick, and ends laterally at the greater trochanter; its surface is perforated by large foramina. The **inferior border**, long and narrow, curves a little backward, to end at the lesser trochanter.

5

The Trochanters.—The trochanters are prominent processes which afford leverage to the muscles that rotate the thigh on its axis. They are two in number, the greater and the lesser.

6

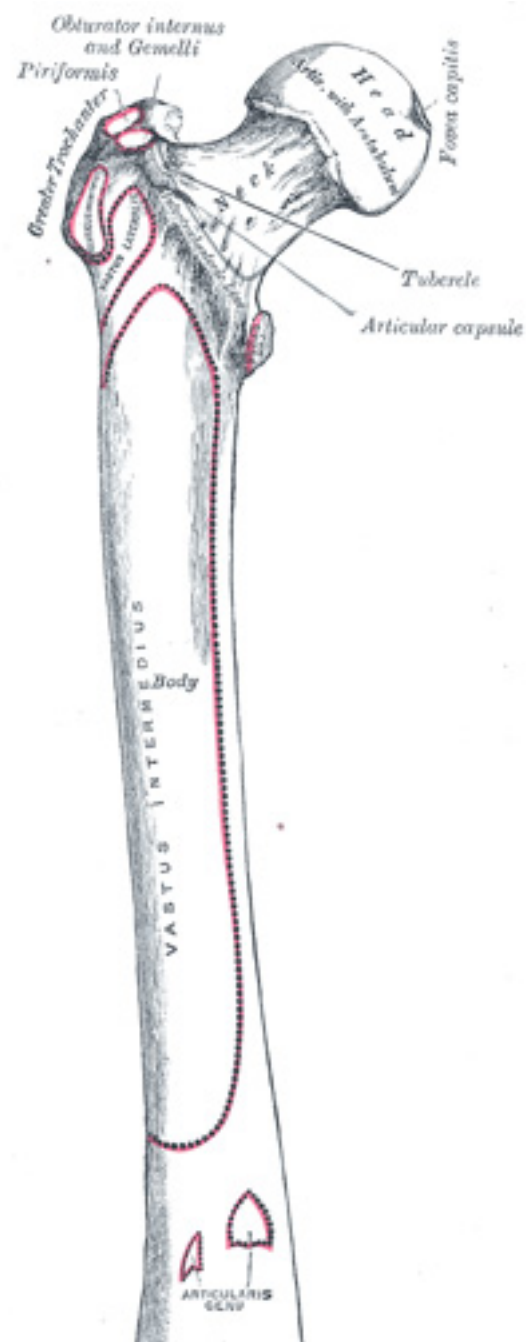


FIG. 244— Right femur. Anterior surface. ([See enlarged image](#))

The **Greater Trochanter** (*trochanter major; great trochanter*) is a large, irregular, quadrilateral eminence, situated at the junction of the neck with the upper part of the body. It is directed a little lateralward and backward, and, in the adult, is about 1 cm. lower than the head. It has two surfaces and four borders. The **lateral surface**, quadrilateral in form, is broad, rough, convex, and marked by a diagonal impression, which extends from the postero-superior to the antero-inferior angle, and serves for the insertion of the tendon of the Glutæus medius. Above the impression is a triangular surface, sometimes rough for part of the tendon of the same muscle, sometimes smooth for the interposition of a bursa between the tendon and the bone. Below and behind the diagonal impression is a smooth, triangular surface, over which the tendon of the Glutæus maximus plays, a bursa being interposed. The **medial surface**, of much less extent than the lateral, presents at its base a deep depression, the **trochanteric fossa** (*digital fossa*), for the insertion of the tendon of the Obturator externus, and above and in front of this an impression for the insertion of the Obturator internus and Gemelli. The **superior border** is free; it is thick and irregular, and marked near the center by an impression for the insertion of the Piriformis. The **inferior border** corresponds to the line of junction of the base of the trochanter with the lateral surface of the body; it is marked by a rough, prominent, slightly curved ridge, which gives origin to the upper part of the Vastus lateralis. The **anterior border** is prominent and somewhat irregular; it affords insertion at its lateral part to the Glutæus minimus. The **posterior border** is very prominent and appears as a free, rounded edge, which bounds the back part of the trochanteric fossa. 7

The **Lesser Trochanter** (*trochanter minor; small trochanter*) is a conical eminence, which varies in size in different subjects; it projects from the lower and back part of the base of the neck. From its apex three well-marked borders extend; two of these are above—a **medial** continuous with the lower border of the neck, a **lateral** with the intertrochanteric crest; the **inferior border** is continuous with the middle division of the linea aspera. The **summit** of the trochanter is rough, and gives insertion to the tendon of the Psoas major. 8

A prominence, of variable size, occurs at the junction of the upper part of the neck with the greater trochanter, and is called the **tubercle of the femur**; it is the point of meeting of five muscles: the Glutæus minimus laterally, the Vastus lateralis below, and the tendon of the Obturator internus and two Gemelli above. Running obliquely downward and medialward from the tubercle is the **intertrochanteric line** (*spiral line of the femur*); it winds around the medial side of the body of the bone, below the lesser trochanter, and ends about 5 cm. below this eminence in the linea aspera. Its upper half is rough, and affords attachment to the iliofemoral ligament of the hip-joint; its lower half is less prominent, and gives origin to the upper part of the Vastus medialis. Running obliquely downward and medialward from the summit of the greater trochanter on the posterior surface of the neck is a prominent ridge, the **intertrochanteric crest**. Its upper half forms the posterior border of the greater trochanter, and its lower half runs downward and medialward to the lesser trochanter. A slight ridge is sometimes seen commencing about the middle of the intertrochanteric crest, and reaching vertically downward for about 5 cm. along the back part of the body: it is called the **linea quadrata**, and gives attachment to the Quadratus femoris and a few fibers of the Adductor magnus. Generally there is merely a slight thickening about the middle of the intertrochanteric crest, marking the attachment of the upper part of the Quadratus femoris. 9

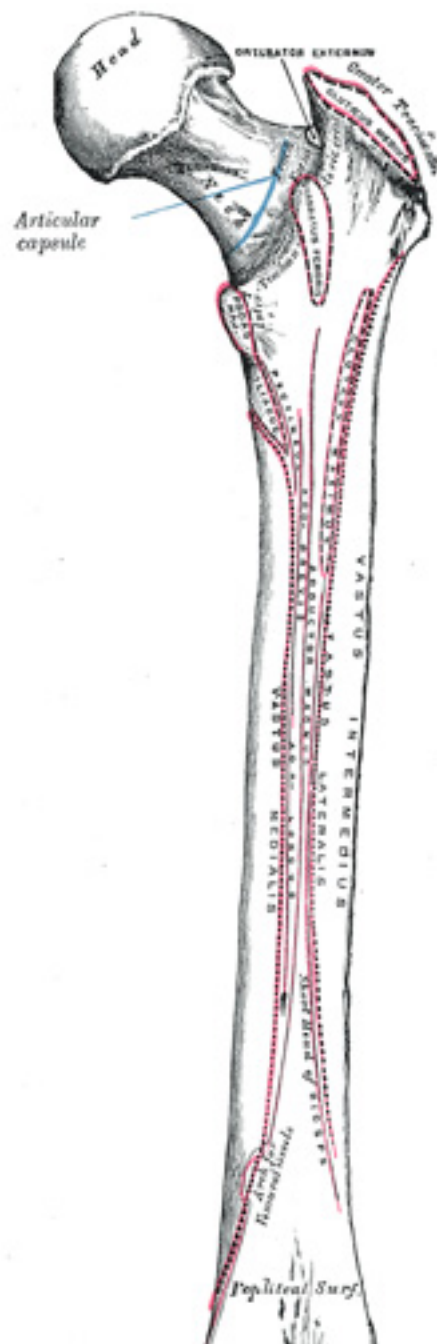


FIG. 245– Right femur. Posterior surface. ([See enlarged image](#))

The Body or Shaft (*corpus femoris*).—The body, almost cylindrical in form, is a little broader above than in the center, broadest and somewhat flattened from before backward below. It is slightly arched, so as to be convex in front, and concave behind, where it is strengthened by a prominent longitudinal ridge, the **linea aspera**. It presents for examination three borders, separating three surfaces. Of the borders, one, the linea aspera, is posterior, one is medial, and the other, lateral. 10

The **linea aspera** ([Fig. 245](#)) is a prominent longitudinal ridge or crest, on the middle third of the bone, presenting a medial and a lateral lip, and a narrow rough, intermediate line. Above, the linea aspera is prolonged by three ridges. The lateral ridge is very rough, and runs almost vertically upward to the base of the greater trochanter. It is termed the **gluteal tuberosity**, and gives attachment to part of the *Glutæus maximus*: its upper part is often elongated into a roughened crest, on which a more or less well-marked, rounded tubercle, the **third trochanter**, is occasionally developed. The intermediate ridge or **pectineal line** is continued to the base of the lesser trochanter and gives attachment to the *Pectineus*; the medial ridge is lost in the intertrochanteric line; between these two a portion of the *Iliacus* is inserted. Below, the linea aspera is prolonged into two ridges, enclosing between them a triangular area, the **popliteal surface**, upon which the popliteal artery rests. Of these two ridges, the lateral is the more prominent, and descends to the summit of the lateral condyle. The medial is less marked, especially at its upper part, where it is crossed by the femoral artery. It ends below at the summit of the medial condyle, in a small tubercle, the **adductor tubercle**, which affords insertion to the tendon of the *Adductor magnus*. 11

From the **medial lip** of the linea aspera and its prolongations above and below, the *Vastus medialis* arises; and from the **lateral lip** and its upward prolongation, the *Vastus lateralis* takes origin. The *Adductor magnus* is inserted into the linea aspera, and to its lateral prolongation above, and its medial prolongation below. Between the *Vastus lateralis* and the *Adductor magnus* two muscles are attached—viz., the *Glutæus maximus* inserted above, and the short head of the *Biceps femoris* arising below. Between the *Adductor magnus* and the *Vastus medialis* four muscles are inserted: the *Iliacus* and *Pectineus* above; the *Adductor brevis* and *Adductor longus* below. The linea aspera is perforated a little below its center by the nutrient canal, which is directed obliquely upward. 12

The other two *borders* of the femur are only slightly marked: the **lateral border** extends from the antero-inferior angle of the greater trochanter to the anterior extremity of the lateral condyle; the **medial border** from the intertrochanteric line, at a point opposite the lesser trochanter, to the anterior extremity of the medial condyle. 13

The **anterior surface** includes that portion of the shaft which is situated between the lateral and medial borders. It is smooth, convex, broader above and below than in the center. From the upper three-fourths of this surface the *Vastus intermedius* arises; the lower fourth is separated from the muscle by the intervention of the synovial membrane of the knee-joint and a bursa; from the upper part of it the *Articularis genu* takes origin. The **lateral surface** includes the portion between the lateral border and the linea aspera; it is continuous above with the corresponding surface of the greater trochanter, below with that of the lateral condyle: from its upper three-fourths the *Vastus intermedius* takes origin. The **medial surface** includes the portion between the medial border and the linea aspera; it is continuous above with the lower border of the neck, below with the medial side of the medial condyle: it is covered by the *Vastus medialis*. 14

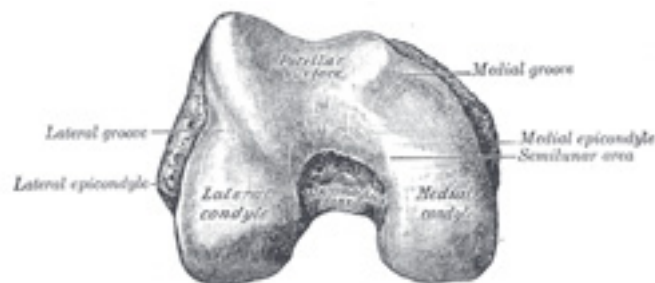


FIG. 246— Lower extremity of right femur viewed from below. ([See enlarged image](#))

The Lower Extremity (distal extremity), (Fig. 246).—The lower extremity, larger than the upper, is somewhat cuboid in form, but its transverse diameter is greater than its antero-posterior; it consists of two oblong eminences known as the **condyles**. In front, the condyles are but slightly prominent, and are separated from one another by a smooth shallow articular depression called the **patellar surface**; behind, they project considerably, and the interval between them forms a deep notch, the **intercondyloid fossa**. The **lateral condyle** is the more prominent and is the broader both in its antero-posterior and transverse diameters, the **medial condyle** is the longer and, when the femur is held with its body perpendicular, projects to a lower level. When, however, the femur is in its natural oblique position the lower surfaces of the two condyles lie practically in the same horizontal plane. The condyles are not quite parallel with one another; the long axis of the lateral is almost directly antero-posterior, but that of the medial runs backward and medialward. Their opposed surfaces are small, rough, and concave, and form the walls of the intercondyloid fossa. This fossa is limited above by a ridge, the **intercondyloid line**, and below by the central part of the posterior margin of the patellar surface. The posterior cruciate ligament of the knee-joint is attached to the lower and front part of the medial wall of the fossa and the anterior cruciate ligament to an impression on the upper and back part of its lateral wall. Each condyle is surmounted by an elevation, the epicondyle. The **medial epicondyle** is a large convex eminence to which the tibial collateral ligament of the knee-joint is attached. At its upper part is the adductor tubercle, already referred to, and behind it is a rough impression which gives origin to the medial head of the Gastrocnemius. The **lateral epicondyle**, smaller and less prominent than the medial, gives attachment to the fibular collateral ligament of the knee-joint. Directly below it is a small depression from which a smooth well-marked groove curves obliquely upward and backward to the posterior extremity of the condyle. This groove is separated from the articular surface of the condyle by a prominent lip across which a second, shallower groove runs vertically downward from the depression. In the fresh state these grooves are covered with cartilage. The Popliteus arises from the depression; its tendon lies in the oblique groove when the knee is flexed and in the vertical groove when the knee is extended. Above and behind the lateral epicondyle is an area for the origin of the lateral head of the Gastrocnemius, above and to the medial side of which the Plantaris arises.

15

The **articular surface** of the lower end of the femur occupies the anterior, inferior, and posterior surfaces of the condyles. Its front part is named the **patellar surface** and articulates with the patella; it presents a median groove which extends downward to the intercondyloid fossa and two convexities, the lateral of which is broader, more prominent, and extends farther upward than the medial. The lower and posterior parts of the articular surface constitute the **tibial surfaces** for articulation with the corresponding condyles of the tibia and menisci. These surfaces are

16

separated from one another by the intercondyloid fossa and from the patellar surface by faint grooves which extend obliquely across the condyles. The lateral groove is the better marked; it runs lateralward and forward from the front part of the intercondyloid fossa, and expands to form a triangular depression. When the knee-joint is fully extended, the triangular depression rests upon the anterior portion of the lateral meniscus, and the medial part of the groove comes into contact with the medial margin of the lateral articular surface of the tibia in front of the lateral tubercle of the tibial intercondyloid eminence. The medial groove is less distinct than the lateral. It does not reach as far as the intercondyloid fossa and therefore exists only on the medial part of the condyle; it receives the anterior edge of the medial meniscus when the knee-joint is extended. Where the groove ceases laterally the patellar surface is seen to be continued backward as a semilunar area close to the anterior part of the intercondyloid fossa; this semilunar area articulates with the medial vertical facet of the patella in forced flexion of the knee-joint. The tibial surfaces of the condyles are convex from side to side and from before backward. Each presents a double curve, its posterior segment being an arc of a circle, its anterior, part of a cycloid. [61](#)

The Architecture of the Femur.—Koch [62](#) by mathematical analysis has “shown that in every part of the femur there is a remarkable adaptation of the inner structure of the bone to the mechanical requirements due to the load on the femur-head. The various parts of the femur taken together form a single mechanical structure wonderfully well-adapted for the efficient, economical transmission of the loads from the acetabulum to the tibia; a structure in which every element contributes its modicum of strength in the manner required by theoretical mechanics for maximum efficiency.” “The internal structure is everywhere so formed as to provide in an efficient manner for all the internal stresses which occur due to the load on the femur-head. Throughout the femur, with the load on the femur-head, the bony material is arranged in the paths of the maximum internal stresses, which are thereby resisted with the greatest efficiency, and hence with maximum economy of material.” “The conclusion is inevitable that the inner structure and outer form of the femur are governed by the conditions of maximum stress to which the bone is subjected normally by the preponderant load on the femur-head; that is, by the body weight transmitted to the femur-head through the acetabulum.” “The femur obeys the mechanical laws that govern other elastic bodies under stress; the relation between the computed internal stresses due to the load on the femur-head, and the internal structure of the different portions of the femur is in very close agreement with the theoretical relations that should exist between stress and structure for maximum economy and efficiency; and, therefore, it is believed that the following laws of bone structure have been demonstrated for the femur: 17

“1. The inner structure and external form of human bone are closely adapted to the mechanical conditions existing at every point in the bone. 18

“2. The inner architecture of normal bone is determined by definite and exact requirements of mathematical and mechanical laws to produce a maximum of strength with a minimum of material.” 19

The Inner Architecture of the Upper Femur.—“The spongy bone of the upper femur (to the lower limit of the lesser trochanter) is composed of two distinct systems of trabeculae arranged in curved paths: one, which has its origin in the medial (inner) side of the shaft and curving upward in a fan-like radiation to the opposite side of the bone; the other, having origin in the lateral (outer) portion of the shaft and arching upward and medially to end in the upper surface of the greater trochanter, neck and head. These two systems intersect each other at right angles. 20

“A. *Medial (Compressive) System of Trabeculae.*—As the compact bone of the medial (inner) part of the shaft nears the head of the femur it gradually becomes thinner and finally reaches the articular surface of the head as a very thin layer. From a point at about the lower level of the lesser trochanter, 2 1/2 to 3 inches from the lower limit of the articular surface of the head, the trabeculae branch off from the shaft in smooth curves, spreading radially to cross to the opposite side in two well-defined groups: a lower, or secondary group, and an upper, or principal group. 21

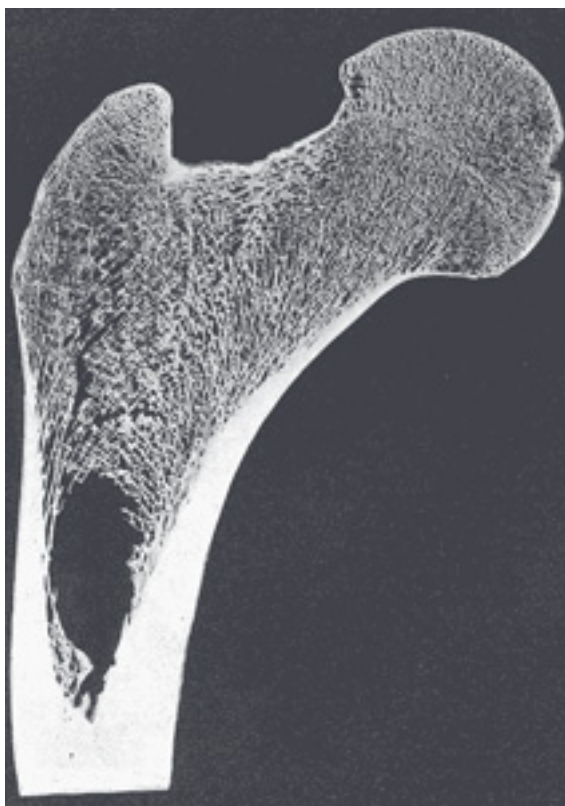


FIG. 247— Frontal longitudinal midsection of upper femur. ([See enlarged image](#))

a. The Secondary Compressive Group.—This group of trabeculae leaves the inner border of the shaft beginning at about the level of the lesser trochanter, and for a distance of almost 2 inches along the curving shaft, with which the separate trabeculae make an angle of about 45 degrees. They curve outwardly and upwardly to cross in radiating smooth curves to the opposite side. The lower filaments end in the region of the greater trochanter: the adjacent filaments above these pursue a more nearly vertical course and end in the upper portion of the neck of the femur. The trabeculae of this group are thin and with wide spaces between them. As they traverse the space between the medial and lateral surfaces of the bone they cross at right angles the system of curved trabeculae which arise from the lateral (outer) portion of the shaft. ([Figs.](#)

[247](#) and [249](#).)

“*b. The Principal Compressive Group.*—This group of trabeculæ ([Figs. 247](#) and [249](#).) springs from the medial portion of the shaft just above the group above-described, and spreads upward and in slightly radial smooth curved lines to reach the upper portion of the articular surface of the head of the femur. These trabeculæ are placed very closely together and are the thickest ones seen in the upper femur. They are a prolongation of the shaft from which they spring in straight lines which gradually curve to meet at right-angles the articular surface. There is no change as they cross the epiphyseal line. They also intersect at right-angles the system of lines which rise from the lateral side of the femur.

23

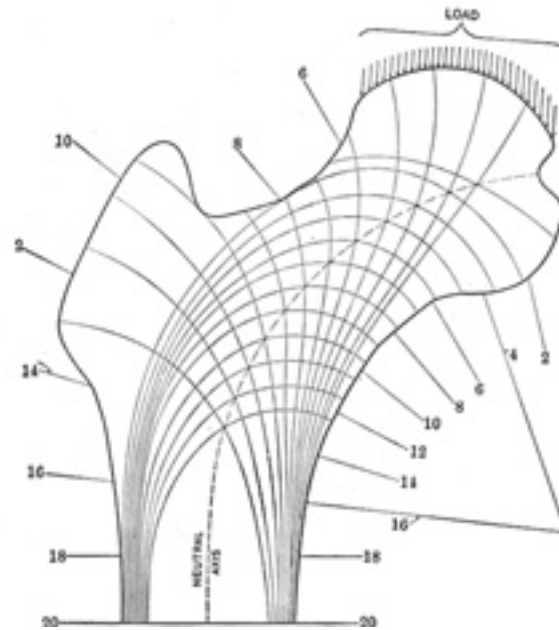


FIG. 248— Diagram of the lines of stress in the upper femur, based upon the mathematical analysis of the right femur. These result from the combination of the different kinds of stresses at each point in the femur. (After Koch.) ([See enlarged image](#))

“This system of principal and secondary compressive trabeculæ corresponds in position and in curvature with the lines of maximum compressive stress, which were traced out in the mathematical analysis of this portion of the femur. ([Figs. 247](#) and [250](#).)

24

“*B. Lateral (Tensile) System of Trabeculæ.*—As the compact bone of the outer portion of the shaft approaches the greater trochanter it gradually decreases in thickness. Beginning at a point about 1 inch below the level of the lower border of the greater trochanter, numerous thin trabeculæ

25

are given off from the outer portion of the shaft. These trabeculæ lie in three distinct groups.

“*c. The Greater Trochanter Group.*—These trabeculæ rise from the outer part of the shaft just below the greater trochanter and rise in thin, curving lines to cross the region of the greater trochanter and end in its upper surface. Some of these filaments are poorly defined. This group intersects the trabeculæ of group (*a*) which rise from the opposite side. The trabeculæ of this group evidently carry small stresses, as is shown by their slenderness.

26



FIG. 249— Frontal longitudinal midsection of left femur. Taken from the same subject as the one that was analyzed and shown in [Figs. 248](#) and [250](#). 4/9 of natural size. (After Koch.) ([See enlarged image](#))




FIG. 250— Diagram of the computed lines of maximum stress in the normal femur. The section numbers 2, 4, 6, 8, etc., show the positions of the transverse sections analyzed. The amounts of the maximum tensile and compressive stress at the various sections are given for a load of 100 pounds on the femur-head. For the standing position (“at attention”) these stresses are multiplied by 0.6, for walking by 1.6 and for running by 3.2. (After Koch.) ([See enlarged image](#))

“*d. The Principal Tensile Group.*—This group springs from the outer part of the shaft immediately below group *c*, and curves convexly upward and inward in nearly parallel lines across the neck of the femur and ends in the inferior portion of the head. These trabeculae are somewhat thinner and more, widely spaced than those of the principal compressive group (*b*). All the trabeculae of this group cross those of groups (*a*) and (*b*) at right angles. This group is the most important of the lateral system (tensile) and, as will be shown later, the greatest tensile stresses of the upper femur are carried by the trabeculae of this group.

“*e. The Secondary Tensile Group.*—This group consists of the trabeculae which spring from the outer side of the shaft and lie below those of the preceding group. They curve upward and medially across the axis of the femur and end more or less irregularly after crossing the midline, but a number of these filaments end in the medial portion of the shaft and neck. They cross at right angles the trabeculae of group (*a*).

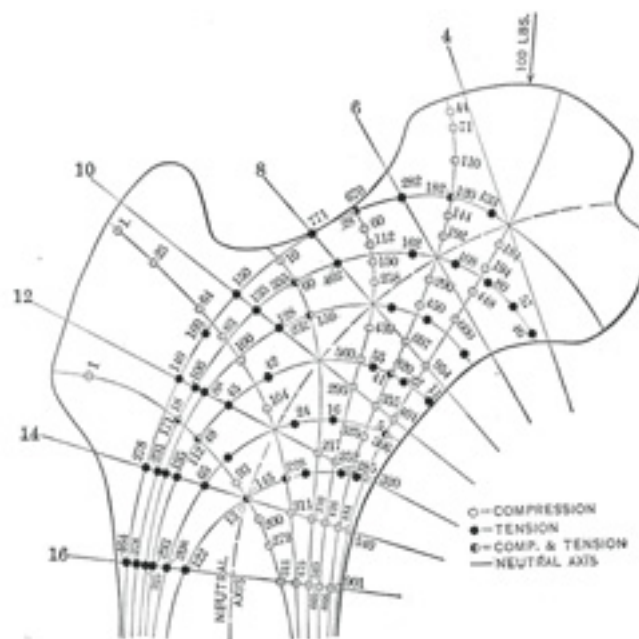


FIG. 251— Intensity of the maximum tensile and compressive stresses in the upper femur. Computed for the load of 100 pounds on the right femur. Corresponds to the upper part of Fig. 250. (After Koch.) ([See enlarged image](#))

“In general, the trabeculæ of the tensile system are lighter in structure than those of the compressive system in corresponding positions. The significance of the difference in thickness of these two systems is that the thickness of the trabeculæ varies with the intensity of the stresses at any given point. Comparison of [Fig. 247](#) with [Fig. 251](#) will show that the trabeculæ of the compressive system carry heavier stresses than those of the tensile system in corresponding positions. For example, the maximum tensile stress at section 8 ([Fig. 251](#)) in the outermost fiber is 771 pounds per square inch, and at the corresponding point on the compressive side the compressive stress is 954 pounds per square inch. Similar comparisons may be made at other points, which confirm the conclusion that the thickness and closeness of spacing of the trabeculæ varies in proportion to the intensity of the stresses carried by them. 29

“It will be seen that the trabeculæ lie exactly in the paths of the maximum tensile and compressive stresses (compare [Figs. 247, 248](#) and [251](#)), and hence these trabeculæ carry these stresses in the most economical manner. This is in accordance with the well-recognized principle of mechanics that the most direct manner of transmitting stress is in the direction in which the stress acts. 30

“[Fig. 249](#) shows a longitudinal frontal section through the left femur, which is the mate of the right femur on which the mathematical analysis was made. In this midsection the system of tensile trabeculæ, which rises from the lateral (outer) part of the shaft and crosses over the central area to end in the medial portion of the shaft, neck and head, is clearly shown. This figure also shows the compressive system of trabeculæ which rises on the medial portion of the shaft and crosses the central area to end in the head, neck and greater trochanter. By comparing the position of these two systems of trabeculæ shown in [Fig. 249](#) with the lines of maximum and minimum stresses shown in [Figs. 248](#) and [250](#) it is seen that the tensile system of trabeculæ corresponds exactly with the position of the lines of maximum and minimum tensile stresses which were determined by mathematical analysis. In a similar manner, the compressive system of trabeculæ in [Fig. 249](#) corresponds exactly with the lines of maximum and minimum compressive stresses computed by mathematical analysis. 31

“The amount of vertical shear varies almost uniformly from a maximum of 90 pounds (90 percent. of the load on the femur-head) midway between sections 4 and 6, to a minimum of —5.7 pounds at section 18” ([Fig. 251](#)). There is a gradual diminution of the spongy bone from section 6 to section 18 parallel with the diminished intensities of the vertical shear. 32

1. The trabeculæ of the upper femur, as shown in frontal sections, are arranged in two general systems, compressive and tensile, which correspond in position with the lines of maximum and minimum stresses in the femur determined by the mathematical analysis of the femur as a mechanical structure. 33

2. The thickness and spacing of the trabeculæ vary with the intensity of the maximum stresses at various points in the upper femur, being thickest and most closely spaced in the regions where the greatest stresses occur. 34

3. The amount of bony material in the spongy bone of the upper femur varies in proportion to the intensity of the shearing force at the various sections. 35

4. The arrangement of the trabeculæ in the positions of maximum stresses is such that the greatest strength is secured with a minimum of material. 36

Significance of the Inner Architecture of the Shaft.—1. Economy for resisting shear. The shearing stresses are at a minimum in the shaft. “It is clear that a minimum amount of material will be required to resist the shearing stresses.” As horizontal and vertical shearing stresses are most 37

efficiently resisted by material placed near the neutral plane, in this region a minimum amount of material will be needed near the neutral axis. In the shaft there is very little if any material in the central space, practically the only material near the neutral plane being in the compact bone, but lying at a distance from the neutral axis. This conforms to the requirement of mechanics for economy, as a minimum of material is provided for resisting shearing stresses where these stresses are a minimum.

2. Economy for resisting bending moment. “The bending moment increases from a minimum at section 4 to a maximum between sections 16 and 18, then gradually decreases almost uniformly to 0 near section 75.” “To resist bending moment stresses most effectively the material should be as far from the neutral axis as possible.” It is evident that the hollow shaft of the femur is an efficient structure for resisting bending moment stresses, all of the material in the shaft being relatively at a considerable distance from the neutral axis. It is evident that the hollow shaft provides efficiently for resisting bending moment not only due to the load on the femur-head, but from any other loads tending to produce bending in other planes.

3. Economy for resisting axial stress.

The inner architecture of the shaft is adapted to resist in the most efficient manner the combined action of the minimal shearing forces and the axial and maximum bending stresses.

The structure of the shaft is such as to secure great strength with a relatively small amount of material.

The Distal Portion of the Femur.—In frontal section (Fig. 249) in the distal 6 inches of the femur “there are to be seen two main systems of trabeculæ, a longitudinal and a transverse system. The trabeculæ of the former rise from the inner wall of the shaft and continue in perfectly straight lines parallel to the axis of the shaft and proceed to the epiphyseal line, whence they continue in more or less curved lines to meet the articular surface of the knee-joint at right angles at every point. Near the center there are a few thin, delicate, longitudinal trabeculæ which spring from the longitudinal trabeculæ just described, to which they are joined by fine transverse filaments that lie in planes parallel to the sagittal plane.

“The trabeculæ of the transverse system are somewhat lighter in structure than those of the longitudinal system, and consist of numerous trabeculæ at right angles to the latter.

“As the distal end of the femur is approached the shaft gradually becomes thinner until the articular surface is reached, where there remains only a thin shell of compact bone. With the gradual thinning of the compact bone of the shaft, there is a simultaneous increase in the amount of the spongy bone, and a gradual flaring of the femur which gives this portion of the bone a gradually increasing gross area of cross-section.

“There is a marked thickening of the shell of bone in the region of the intercondyloid fossa where the anterior and posterior crucial ligaments are attached. This thickened area is about 0.4 inch in diameter and consists of compact bone from which a number of thick trabeculæ pass at right angles to the main longitudinal system. The inner structure of the bone is here evidently adapted to the efficient distribution of the stresses arising from this ligamentary attachment.

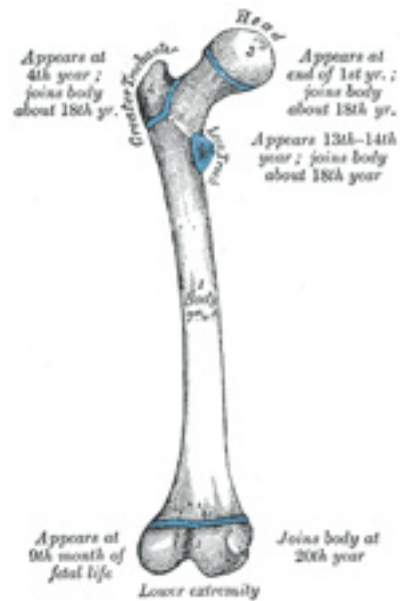


FIG. 252– Plan of ossification of the femur. From five centers. ([See enlarged image](#))

“Near the distal end of the femur the longitudinal trabeculae gradually assume curved paths and end perpendicularly to the articular surface at every point. Such a structure is in accordance with the principles of mechanics, as stresses can be communicated through a frictionless joint only in a direction perpendicular to the joint surface at every point. 46

“With practically no increase in the amount of bony material used, there is a greatly increased stability produced by the expansion of the lower femur from a hollow shaft of compact bone to a structure of much larger cross-section almost entirely composed of spongy bone. 47

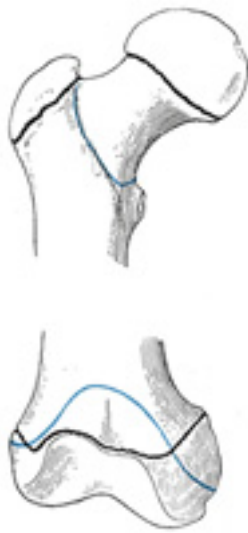

FIG. 253– Epiphysal lines of femur in a young adult. Anterior aspect. The lines of attachment of the articular capsules are in blue. ([See enlarged image](#))

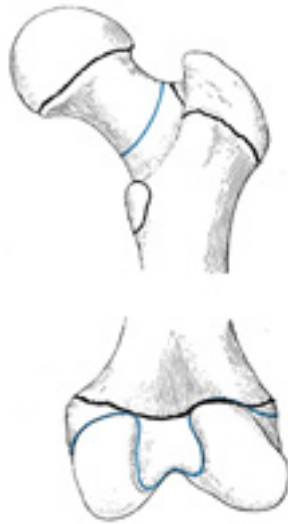


FIG. 254— Epiphysial lines of femur in a young adult. Posterior aspect. The lines of attachment of the articular capsules are in blue. ([See enlarged image](#))

“*Significance of the Inner Architecture of the Distal Part of the Femur.*—The function of the lower end of the femur is to transmit through a hinged joint the loads carried by the femur. For stability the width of the bearing on which the hinge action occurs should be relatively large. For economy of material the expansion of the end bearing should be as lightly constructed as is consistent with proper strength. In accordance with the principles of mechanics... . . . , the most efficient manner in which stresses are transmitted is by the arrangement of the resisting material in lines parallel to the direction in which the stresses occur and in the paths taken by the stresses. Theoretically the most efficient manner to attain these objects would be to prolong the innermost filaments of the bone as straight lines parallel to the longitudinal axis of the bone, and gradually to flare the outer shell of compact bone outward, and continuing to give off filaments of bone parallel to the longitudinal axis as the distal end of the femur is approached. These filaments should be well-braced transversely and each should carry its proportionate part of the total load, parallel to the longitudinal axis, transmitting it eventually to the articular surface, and in a direction perpendicular to that surface.” 48

Referring to [Fig. 249](#), it is seen that the large expansion of the bone is produced by the gradual transition of the hollow shaft of compact bone to cancellated bone, resulting in the production of a much larger volume. The trabeculæ are given off from the shaft in lines parallel to the longitudinal axis, and are braced transversely by two series of trabeculæ at right angles to each other, in the same manner as required theoretically for economy. 49

Although the action of the muscles exerts an appreciable effect on the stresses in the femur, it is relatively small and very complex to analyze and has not been considered in the above analysis. 50

Ossification (Figs. 252, 253, 254).—The femur is ossified from *five* centers: one for the body, one for the head, one for each trochanter, and one for the lower extremity. Of all the long bones, except the clavicle, it is the first to show traces of ossification; this commences in the middle of the body, at about the seventh week of fetal life, and rapidly extends upward and downward. The centers in the epiphyses appear in the following order: in the lower end of the bone, at the ninth month of fetal life (from this center the condyles and epicondyles are formed); in the head, at the end of the first year after birth; in the greater trochanter, during the fourth year; and in the lesser trochanter, between the thirteenth and fourteenth years. The order in which the epiphyses are joined to the body is the reverse of that of their appearance; they are not united until after puberty, the lesser trochanter being first joined, then the greater, then the head, and, lastly, the inferior extremity, which is not united until the twentieth year.

Note 61. A *cycloid* is a curve traced by a point in the circumference of a wheel when the wheel is rolled along in a straight line. [\[back\]](#)

Note 62. The Laws of Bone Architecture. Am. Jour. of Anat., 21, 1917. The following paragraphs are taken almost verbatim from Koch's article in which we have the first correct mathematical analysis of the femur in support of the theory of the functional form of bone proposed by Wolff and also by Roux. [\[back\]](#)

6c. 4. The Patella

(Knee Cap)

The **patella** (Figs. 255, 256) is a flat, triangular bone, situated on the front of the knee-joint. It is usually regarded as a sesamoid bone, developed in the tendon of the Quadriceps femoris, and resembles these bones (1) in being developed in a tendon; (2) in its center of ossification presenting a knotty or tuberculated outline; (3) in being composed mainly of dense cancellous tissue. It serves to protect the front of the joint, and increases the leverage of the Quadriceps femoris by making it act at a greater angle. It has an anterior and a posterior surface three borders, and an apex.



FIG. 255– Right patella. Anterior surface. ([See enlarged image](#))



FIG. 256– Right patella. Posterior surface. ([See enlarged image](#))

Surfaces.—The **anterior surface** is convex, perforated by small apertures for the passage of nutrient vessels, and marked by numerous rough, longitudinal striæ. This surface is covered, in the recent state, by an expansion from the tendon of the Quadriceps femoris, which is continuous below with the superficial fibers of the ligamentum patellæ. It is separated from the integument by a bursa. The **posterior surface** presents above a smooth, oval, articular area, divided into two facets by a vertical ridge; the ridge corresponds to the groove on the patellar surface of the femur, and the facets to the medial and lateral parts of the same surface; the lateral facet is the broader and deeper. Below the articular surface is a rough, convex, non-articular area, the lower half of which gives attachment to the ligamentum patellæ; the upper half is separated from the head of the tibia by adipose tissue. 2

Borders.—The **base** or **superior border** is thick, and sloped from behind, downward, and forward: it gives attachment to that portion of the Quadriceps femoris which is derived from the Rectus femoris and Vastus intermedius. The **medial** and **lateral borders** are thinner and converge below: they give attachment to those portions of the Quadriceps femoris which are derived from the Vasti lateralis and medialis. 3

Apex.—The apex is pointed, and gives attachment to the ligamentum patellæ. 4

Structure.—The patella consists of a nearly uniform dense cancellous tissue, covered by a thin compact lamina. The cancelli immediately beneath the anterior surface are arranged parallel with it. In the rest of the bone they radiate from the articular surface toward the other parts of the bone. 5

Ossification.—The patella is ossified from a single center, which usually makes its appearance in the second or third year, but may be delayed 6

until the sixth year. More rarely, the bone is developed by two centers, placed side by side. Ossification is completed about the age of puberty.

Articulation.—The patella articulates with the femur.

7

6c. 5. The Tibia

(Shin Bone)

1

The **tibia** ([Figs. 258, 259](#)) is situated at the medial side of the leg, and, excepting the femur, is the longest bone of the skeleton. It is prismoid in form, expanded above, where it enters into the knee-joint, contracted in the lower third, and again enlarged but to a lesser extent below. In the male, its direction is vertical, and parallel with the bone of the opposite side; but in the female it has a slightly oblique direction downward and lateralward, to compensate for the greater obliquity of the femur. It has a **body** and **two extremities**.

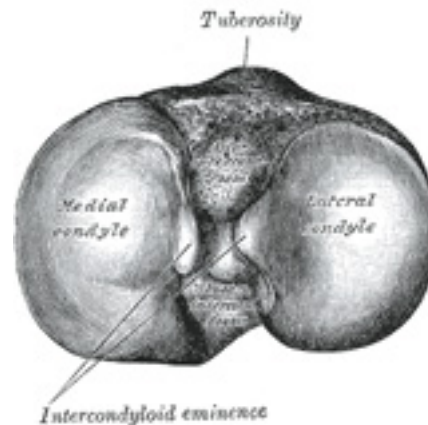


FIG. 257— Upper surface of right tibia. ([See enlarged image](#))

The Upper Extremity (*proximal extremity*).—The upper extremity is large, and expanded into two eminences, the **medial** and **lateral condyles**. The **superior articular surface** presents two smooth articular facets ([Fig. 257](#)). The medial facet, oval in shape, is slightly concave

2

from side to side, and from before backward. The lateral, nearly circular, is concave from side to side, but slightly convex from before backward, especially at its posterior part, where it is prolonged on to the posterior surface for a short distance. The central portions of these facets articulate with the condyles of the femur, while their peripheral portions support the menisci of the knee-joint, which here intervene between the two bones. Between the articular facets, but nearer the posterior than the anterior aspect of the bone, is the **intercondyloid eminence** (*spine of tibia*), surmounted on either side by a prominent tubercle, on to the sides of which the articular facets are prolonged; in front of and behind the intercondyloid eminence are rough depressions for the attachment of the anterior and posterior cruciate ligaments and the menisci. The **anterior surfaces** of the condyles are continuous with one another, forming a large somewhat flattened area; this area is triangular, broad above, and perforated by large vascular foramina; narrow below where it ends in a large oblong elevation, the **tuberosity of the tibia**, which gives attachment to the ligamentum patellæ; a bursa intervenes between the deep surface of the ligament and the part of the bone immediately above the tuberosity. *Posteriorly*, the condyles are separated from each other by a shallow depression, the **posterior intercondyloid fossa**, which gives attachment to part of the posterior cruciate ligament of the knee-joint. The **medial condyle** presents posteriorly a deep transverse groove, for the insertion of the tendon of the Semimembranosus. Its *medial surface* is convex, rough, and prominent; it gives attachment to the tibial collateral ligament. The **lateral condyle** presents posteriorly a flat articular facet, nearly circular in form, directed downward, backward, and lateralward, for articulation with the head of the fibula. Its *lateral surface* is convex, rough, and prominent in front: on it is an eminence, situated on a level with the upper border of the tuberosity and at the junction of its anterior and lateral surfaces, for the attachment of the iliotibial band. Just below this a part of the Extensor digitorum longus takes origin and a slip from the tendon of the Biceps femoris is inserted.

The Body or Shaft (*corpus tibiæ*).—The body has three borders and three surfaces.

3

Borders.—The **anterior crest or border**, the most prominent of the three, commences above at the tuberosity, and ends below at the anterior margin of the medial malleolus. It is sinuous and prominent in the upper two-thirds of its extent, but smooth and rounded below; it gives attachment to the deep fascia of the leg.

4

The **medial border** is smooth and rounded above and below, but more prominent in the center; it begins at the back part of the medial condyle, and ends at the posterior border of the medial malleolus; its upper part gives attachment to the tibial collateral ligament of the knee-joint to the extent of about 5 cm., and insertion to some fibers of the Popliteus; from its middle third some fibers of the Soleus and Flexor digitorum longus take origin.

5

The **interosseous crest or lateral border** is thin and prominent, especially its central part, and gives attachment to the interosseous membrane; it commences above in front of the fibular articular facet, and bifurcates below, to form the boundaries of a triangular rough surface, for the attachment of the interosseous ligament connecting the tibia and fibula.

6

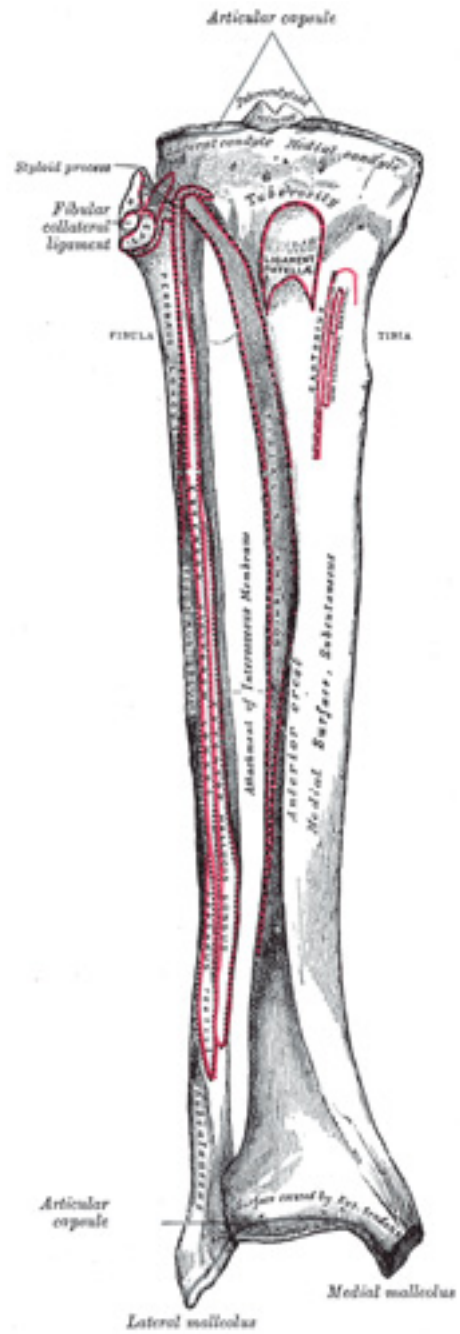


FIG. 258—Bones of the right leg. Anterior surface. ([See enlarged image](#))

Surfaces.—The **medial surface** is smooth, convex, and broader above than below; its upper third, directed forward and medialward, is covered by the aponeurosis derived from the tendon of the Sartorius, and by the tendons of the Gracilis and Semitendinosus, all of which are inserted nearly as far forward as the anterior crest; in the rest of its extent it is subcutaneous. 7

The **lateral surface** is narrower than the medial; its upper two-thirds present a shallow groove for the origin of the Tibialis anterior; its lower third is smooth, convex, curves gradually forward to the anterior aspect of the bone, and is covered by the tendons of the Tibialis anterior, Extensor hallucis longus, and Extensor digitorum longus, arranged in this order from the medial side. 8

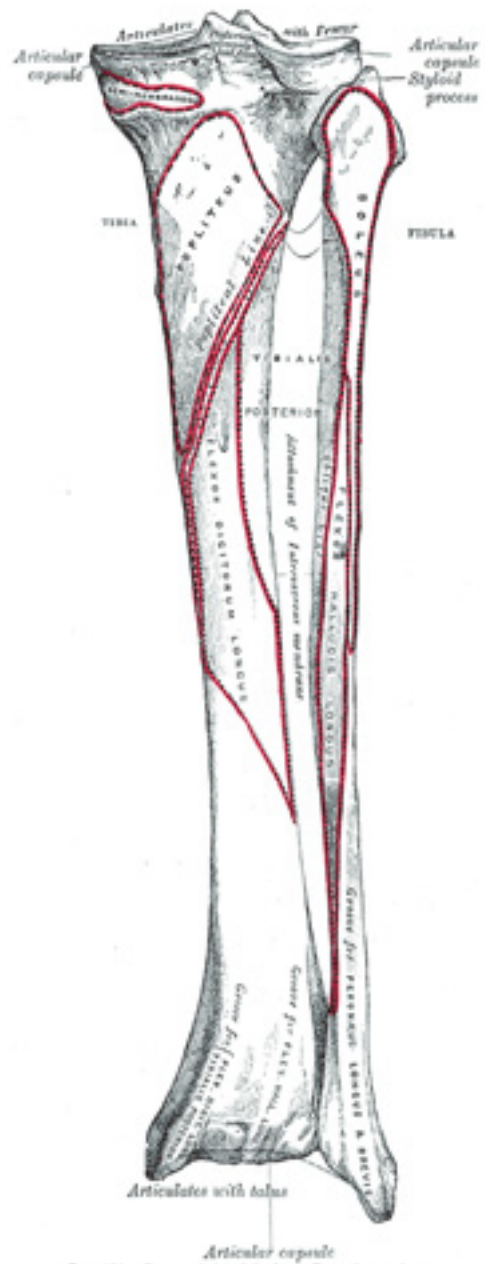


FIG. 259.—Bones of the right leg. Posterior surface.

FIG. 259– Bones of the right leg. Posterior surface. ([See enlarged image](#))

The **posterior surface** ([Fig. 259](#)) presents, at its upper part, a prominent ridge, the **popliteal line**, which extends obliquely downward from the back part of the articular facet for the fibula to the medial border, at the junction of its upper and middle thirds; it marks the lower limit of the insertion of the Popliteus, serves for the attachment of the fascia covering this muscle, and gives origin to part of the Soleus, Flexor digitorum longus, and Tibialis posterior. The triangular area, above this line, gives insertion to the Popliteus. The middle third of the posterior surface is divided by a vertical ridge into two parts; the ridge begins at the popliteal line and is well-marked above, but indistinct below; the medial and broader portion gives origin to the Flexor digitorum longus, the lateral and narrower to part of the Tibialis posterior. The remaining part of the posterior surface is smooth and covered by the Tibialis posterior, Flexor digitorum longus, and Flexor hallucis longus. Immediately below the popliteal line is the **nutrient foramen**, which is large and directed obliquely downward. 9

The Lower Extremity (*distal extremity*).—The lower extremity, much smaller than the upper, presents five surfaces; it is prolonged downward on its medial side as a strong process, the **medial malleolus**. 10

Surfaces.—The **inferior articular surface** is quadrilateral, and smooth for articulation with the talus. It is concave from before backward, broader in front than behind, and traversed from before backward by a slight elevation, separating two depressions. It is continuous with that on the medial malleolus. 11

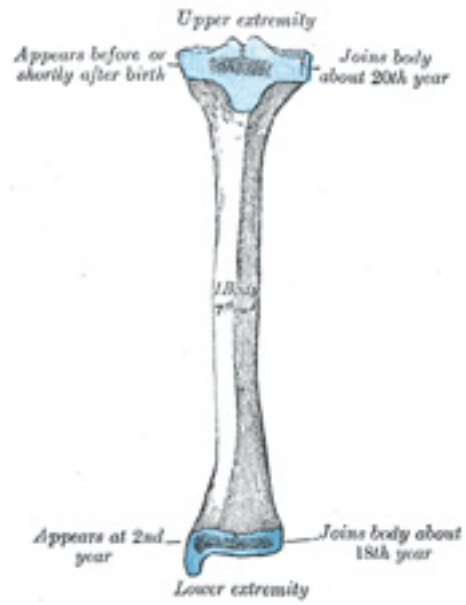


FIG. 260— Plan of ossification of the tibia. From three centers. ([See enlarged image](#))

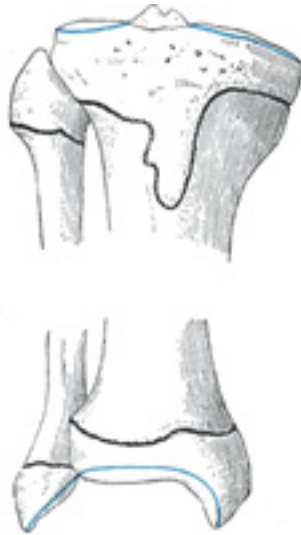

FIG. 261— Epiphysial lines of tibia and fibula in a young adult. Anterior aspect. ([See enlarged image](#))

The **anterior surface** of the lower extremity is smooth and rounded above, and covered by the tendons of the Extensor muscles; its lower margin presents a rough transverse depression for the attachment of the articular capsule of the ankle-joint. 12

The **posterior surface** is traversed by a shallow groove directed obliquely downward and medialward, continuous with a similar groove on the posterior surface of the talus and serving for the passage of the tendon of the Flexor hallucis longus. 13

The **lateral surface** presents a triangular rough depression for the attachment of the inferior interosseous ligament connecting it with the fibula; the lower part of this depression is smooth, covered with cartilage in the fresh state, and articulates with the fibula. The surface is bounded by two prominent borders, continuous above with the interosseous crest; they afford attachment to the anterior and posterior ligaments of the lateral malleolus. 14

The **medial surface** is prolonged downward to form a strong pyramidal process, flattened from without inward—the **medial malleolus**. The *medial surface* of this process is convex and subcutaneous; its *lateral or articular surface* is smooth and slightly concave, and articulates with the talus; its *anterior border* is rough, for the attachment of the anterior fibers of the deltoid ligament of the ankle-joint; its *posterior border* presents a broad groove, the **malleolar sulcus**, directed obliquely downward and medialward, and occasionally double; this sulcus lodges the tendons of the Tibialis posterior and Flexor digitorum longus. The *summit* of the medial malleolus is marked by a rough depression behind, for the attachment of the deltoid ligament. 15

Structure.—The structure of the tibia is like that of the other long bones. The compact wall of the body is thickest at the junction of the middle and lower thirds of the bone. 16

Ossification.—The tibia is ossified from *three* centers (Figs. 260, 261): one for the body and one for either extremity. Ossification begins in the center of the body, about the seventh week of fetal life, and gradually extends toward the extremities. The center for the upper epiphysis appears before or shortly after birth; it is flattened in form, and has a thin tongue-shaped process in front, which forms the tuberosity (Fig. 260); that for the lower epiphysis appears in the second year. The lower epiphysis joins the body at about the eighteenth, and the upper one joins about the twentieth year. Two additional centers occasionally exist, one for the tongue-shaped process of the upper epiphysis, which forms the tuberosity, and one for the medial malleolus. 17

6c. 6. The Fibula

(Calf Bone) 1

The **fibula** (Figs. 258, 259) is placed on the lateral side of the tibia, with which it is connected above and below. It is the smaller of the two bones, and, in proportion to its length, the most slender of all the long bones. Its upper extremity is small, placed toward the back of the head of the tibia, below the level of the knee-joint, and excluded from the formation of this joint. Its lower extremity inclines a little forward, so as to be on a plane anterior to that of the upper end; it projects below the tibia, and forms the lateral part of the ankle-joint. The bone has a **body** and **two extremities**.

The Upper Extremity or Head (*capitulum fibulae*; *proximal extremity*).—The upper extremity is of an irregular quadrate form, presenting above a flattened articular surface, directed upward, forward, and medialward, for articulation with a corresponding surface on the lateral condyle of the tibia. On the lateral side is a thick and rough prominence continued behind into a pointed eminence, the **apex** (*styloid process*), which projects upward from the posterior part of the head. The prominence, at its upper and lateral part, gives attachment to the tendon of the Biceps femoris and to the fibular collateral ligament of the knee-joint, the ligament dividing the tendon into two parts. The remaining part of the circumference of the head is rough, for the attachment of muscles and ligaments. It presents in front a tubercle for the origin of the upper and anterior fibers of the Peronæus longus, and a surface for the attachment of the anterior ligament of the head; and behind, another tubercle, for the attachment of the posterior ligament of the head and the origin of the upper fibers of the Soleus. 2

The Body or Shaft (*corpus fibulae*).—The body presents four borders—the antero-lateral, the antero-medial, the postero-lateral, and the postero-medial; and four surfaces— anterior, posterior, medial, and lateral. 3

Borders.—The **antero-lateral border** begins above in front of the head, runs vertically downward to a little below the middle of the bone, and 4

then curving somewhat lateralward, bifurcates so as to embrace a triangular subcutaneous surface immediately above the lateral malleolus. This border gives attachment to an intermuscular septum, which separates the Extensor muscles on the anterior surface of the leg from the Peronæi longus and brevis on the lateral surface.

The **antero-medial border**, or **interosseous crest**, is situated close to the medial side of the preceding, and runs nearly parallel with it in the upper third of its extent, but diverges from it in the lower two-thirds. It begins above just beneath the head of the bone (sometimes it is quite indistinct for about 2.5 cm. below the head), and ends at the apex of a rough triangular surface immediately above the articular facet of the lateral malleolus. It serves for the attachment of the interosseous membrane, which separates the Extensor muscles in front from the Flexor muscles behind.

The **postero-lateral border** is prominent; it begins above at the apex, and ends below in the posterior border of the lateral malleolus. It is directed lateralward above, backward in the middle of its course, backward, and a little medialward below, and gives attachment to an aponeurosis which separates the Peronæi on the lateral surface from the Flexor muscles on the posterior surface.

The **postero-medial border**, sometimes called the **oblique line**, begins above at the medial side of the head, and ends by becoming continuous with the interosseous crest at the lower fourth of the bone. It is well-marked and prominent at the upper and middle parts of the bone. It gives attachment to an aponeurosis which separates the Tibialis posterior from the Soleus and Flexor hallucis longus.

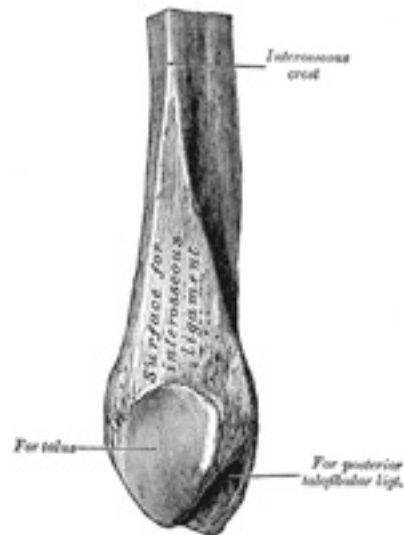


FIG. 262– Lower extremity of right fibula. Medial aspect. ([See enlarged image](#))



FIG. 263— Plan of ossification of the fibula. From three centers. ([See enlarged image](#))

Surfaces.—The **anterior surface** is the interval between the antero-lateral and antero-medial borders. It is extremely narrow and flat in the upper third of its extent; broader and grooved longitudinally in its lower third; it serves for the origin of three muscles: the Extensor digitorum longus, Extensor hallucis longus, and Peronæus tertius. 8

The **posterior surface** is the space included between the postero-lateral and the postero-medial borders; it is continuous below with the triangular area above the articular surface of the lateral malleolus; it is directed backward above, backward and medialward at its middle, directly medialward below. Its upper third is rough, for the origin of the Soleus; its lower part presents a triangular surface, connected to the tibia by a strong interosseous ligament; the intervening part of the surface is covered by the fibers of origin of the Flexor hallucis longus. Near the middle of this surface is the nutrient foramen, which is directed downward. 9

The **medial surface** is the interval included between the antero-medial and the postero-medial borders. It is grooved for the origin of the Tibialis posterior. 10

The **lateral surface** is the space between the antero-lateral and postero-lateral borders. It is broad, and often deeply grooved; it is directed 11

lateralward in the upper two-thirds of its course, backward in the lower third, where it is continuous with the posterior border of the lateral malleolus. This surface gives origin to the Peronæi longus and brevis.

The Lower Extremity or Lateral Malleolus (*malleolus lateralis; distal extremity; external malleolus*).—The lower extremity is of a pyramidal form, and somewhat flattened from side to side; it descends to a lower level than the medial malleolus. The **lateral surface** is convex, subcutaneous, and continuous with the triangular, subcutaneous surface on the lateral side of the body. The **medial surface** ([Fig. 262](#)) presents in front a smooth triangular surface, convex from above downward, which articulates with a corresponding surface on the lateral side of the talus. Behind and beneath the articular surface is a rough depression, which gives attachment to the posterior talofibular ligament. The **anterior border** is thick and rough, and marked below by a depression for the attachment of the anterior talofibular ligament. The **posterior border** is broad and presents the shallow **malleolar sulcus**, for the passage of the tendons of the Peronæi longus and brevis. The **summit** is rounded, and give attachment to the calcaneofibular ligament. 12

Ossification.—The fibula is ossified from *three* centers ([Fig. 263](#)): one for the body, and one for either end. Ossification begins in the body about the eighth week of fetal life, and extends toward the extremities. At birth the ends are cartilaginous. Ossification commences in the lower end in the second year, and in the upper about the fourth year. The lower epiphysis, the first to ossify, unites with the body about the twentieth year; the upper epiphysis joins about the twenty-fifth year. 13

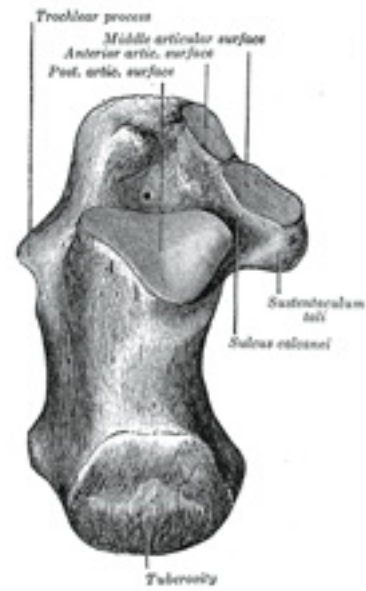

FIG. 264– Left calcaneus, superior surface. ([See enlarged image](#))

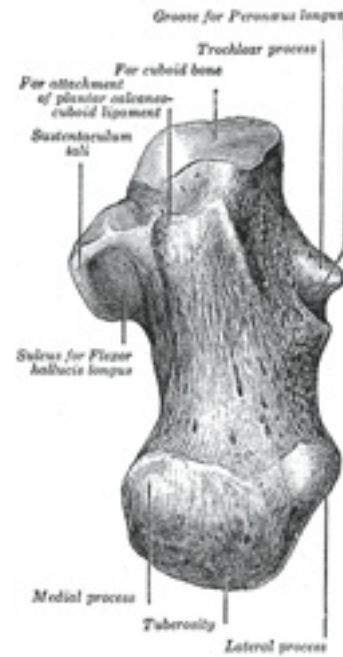

FIG. 265— Left calcaneus, inferior surface. ([See enlarged image](#))

6d. The Foot. 1. The Tarsus

The skeleton of the foot ([Figs. 268](#) and [269](#)) consists of three parts: the **tarsus**, **metatarsus**, and **phalanges**.

1
2

The Tarsus (Ossa Tarsi)

The **tarsal bones** are seven in number, viz., the **calcaneus**, **talus**, **cuboid**, **navicular**, and the **first**, **second**, and **third cuneiforms**.

The Calcaneus (*os calcis*) ([Figs. 264 to 267](#)).—The calcaneus is the largest of the tarsal bones. It is situated at the lower and back part of the

3

foot, serving to transmit the weight of the body to the ground, and forming a strong lever for the muscles of the calf. It is irregularly cuboidal in form, having its long axis directed forward and lateralward; it presents for examination six surfaces.

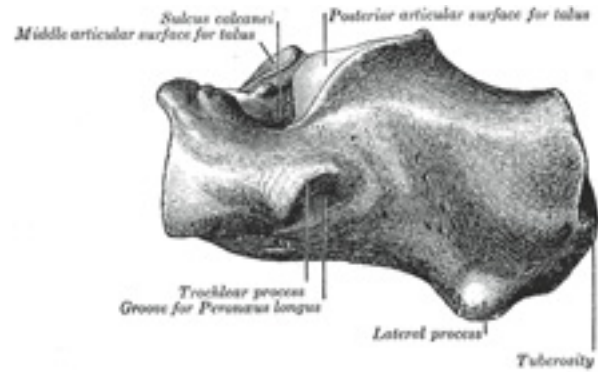


FIG. 266– Left calcaneus, lateral surface. ([See enlarged image](#))

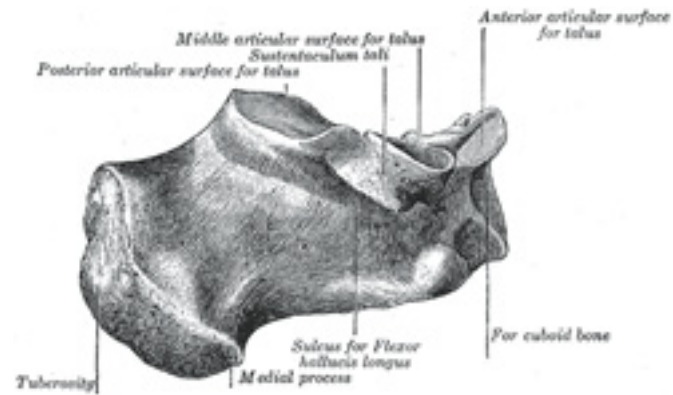


FIG. 267– Left calcaneus, medial surface. ([See enlarged image](#))

Surfaces.—The **superior surface** extends behind on to that part of the bone which projects backward to form the heel. This varies in length in different individuals, is convex from side to side, concave from before backward, and supports a mass of fat placed in front of the tendo calcaneus. In front of this area is a large usually somewhat oval-shaped facet, the **posterior articular surface**, which looks upward and forward; it is convex from behind forward, and articulates with the posterior calcaneal facet on the under surface of the talus. It is bounded anteriorly by a deep depression which is continued backward and medialward in the form of a groove, the **calcaneal sulcus**. In the articulated foot this sulcus lies below a similar one on the under surface of the talus, and the two form a canal (**sinus tarsi**) for the lodgement of the interosseous talocalcaneal ligament. In front and to the medial side of this groove is an elongated facet, concave from behind forward, and with its long axis directed forward and lateralward. This facet is frequently divided into two by a notch: of the two, the posterior, and larger is termed the **middle articular surface**; it is supported on a projecting process of bone, the **sustentaculum tali**, and articulates with the middle calcaneal facet on the under surface of the talus; the **anterior articular surface** is placed on the anterior part of the body, and articulates with the anterior calcaneal facet on the talus. The upper surface, anterior and lateral to the facets, is rough for the attachment of ligaments and for the origin of the Extensor digitorum brevis.

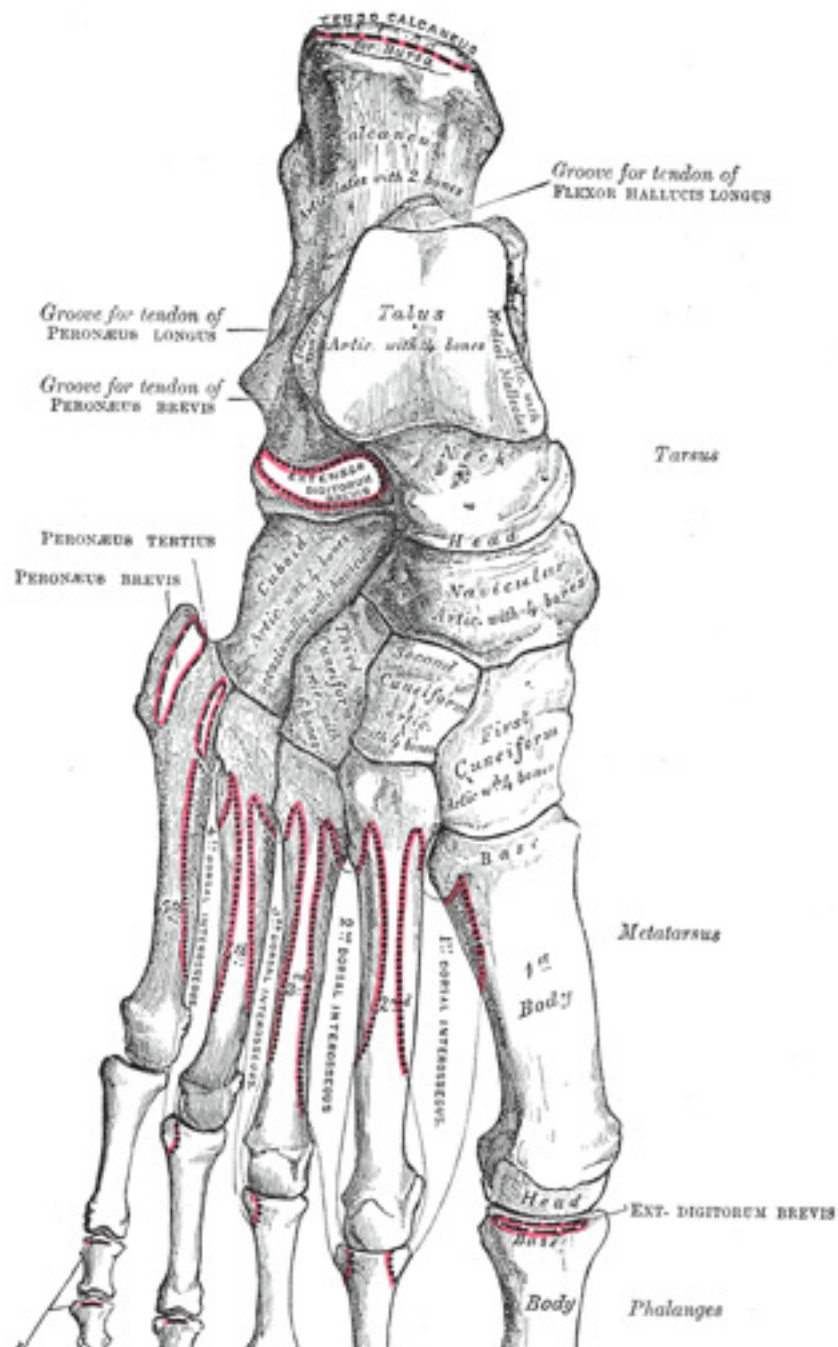


FIG. 268– Bones of the right foot. Dorsal surface. ([See enlarged image](#))

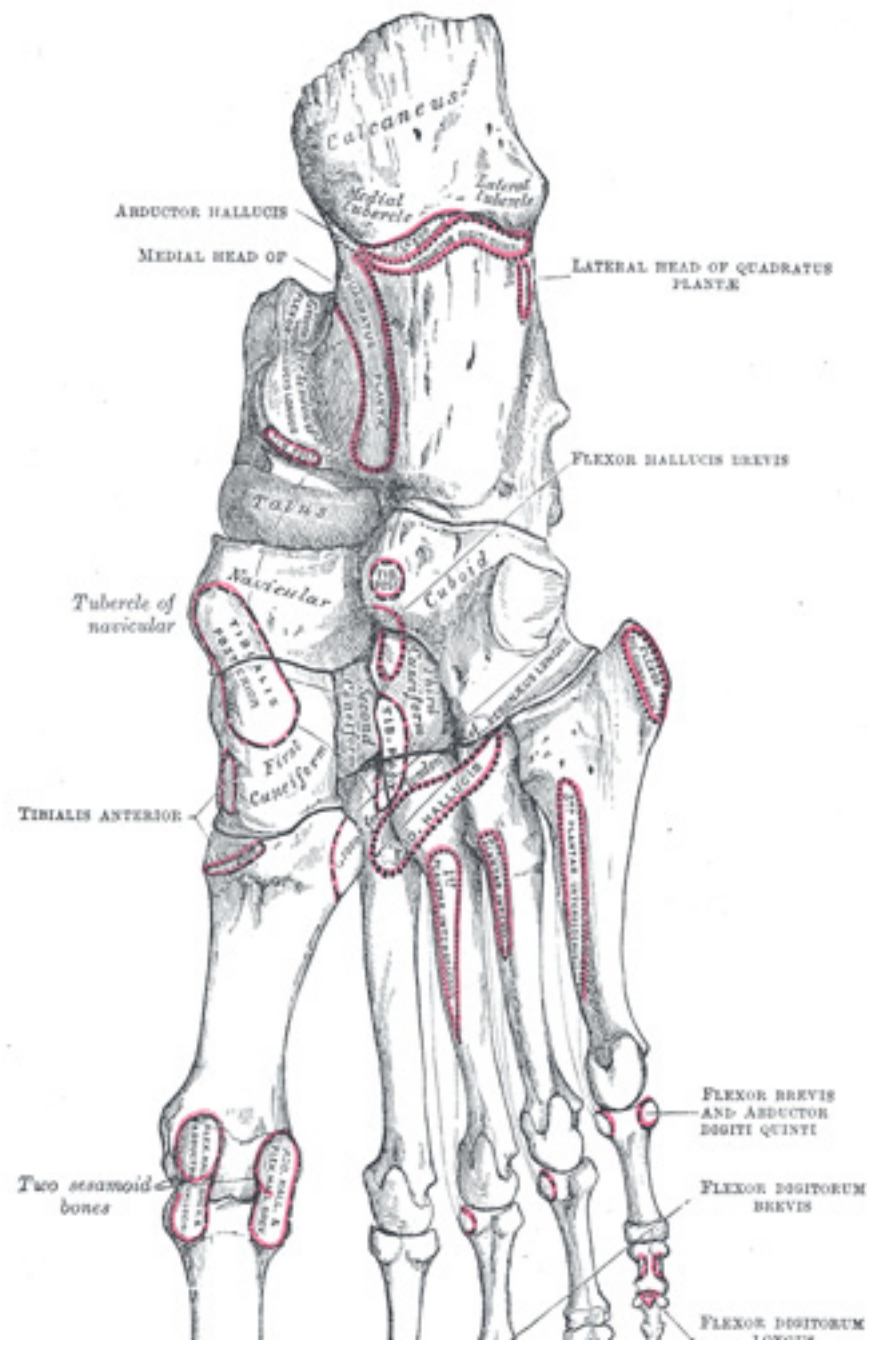


FIG. 269— Bones of the right foot. Plantar surface. ([See enlarged image](#))

The **inferior** or **plantar surface** is uneven, wider behind than in front, and convex from side to side; it is bounded posteriorly by a transverse elevation, the **calcaneal tuberosity**, which is depressed in the middle and prolonged at either end into a process; the **lateral process**, small, prominent, and rounded, gives origin to part of the Abductor digiti quinti; the **medial process**, broader and larger, gives attachment, by its prominent medial margin, to the Abductor hallucis, and in front to the Flexor digitorum brevis and the plantar aponeurosis; the depression between the processes gives origin to the Abductor digiti quinti. The rough surface in front of the processes gives attachment to the long plantar ligament, and to the lateral head of the Quadratus plantæ while to a prominent tubercle nearer the anterior part of this surface, as well as to a transverse groove in front of the tubercle, is attached the plantar calcaneocuboid ligament. 5

The **lateral surface** is broad behind and narrow in front, flat and almost subcutaneous; near its center is a tubercle, for the attachment of the calcaneofibular ligament. At its upper and anterior part, this surface gives attachment to the lateral talocalcaneal ligament; and in front of the tubercle it presents a narrow surface marked by two oblique grooves. The grooves are separated by an elevated ridge, or tubercle, the **trochlear process** (*peroneal tubercle*), which varies much in size in different bones. The **superior groove** transmits the tendon of the Peronæus brevis; the **inferior groove**, that of the Peronæus longus. 6

The **medial surface** is deeply concave; it is directed obliquely downward and forward, and serves for the transmission of the plantar vessels and nerves into the sole of the foot; it affords origin to part of the Quadratus plantæ. At its upper and forepart is a horizontal eminence, the **sustentaculum tali**, which gives attachment to a slip of the tendon of the Tibialis posterior. This eminence is concave above, and articulates with the middle calcaneal articular surface of the talus; below, it is grooved for the tendon of the Flexor hallucis longus; its anterior margin gives attachment to the plantar calcaneonavicular ligament, and its medial, to a part of the deltoid ligament of the ankle-joint. 7

The **anterior** or **cuboid articular surface** is of a somewhat triangular form. It is concave from above downward and lateralward, and convex in a direction at right angles to this. Its medial border gives attachment to the plantar calcaneonavicular ligament. 8

The **posterior surface** is prominent, convex, wider below than above, and divisible into three areas. The lowest of these is rough, and covered by the fatty and fibrous tissue of the heel; the middle, also rough, gives insertion to the tendo calcaneus and Plantaris; while the highest is smooth, and is covered by a bursa which intervenes between it and the tendo calcaneus. 9

Articulations.—The calcaneus articulates with two bones: the talus and cuboid. 10

The Talus (*astragalus; ankle bone*) ([Figs. 270 to 273](#)).—The talus is the second largest of the tarsal bones. It occupies the middle and upper part of the tarsus, supporting the tibia above, resting upon the calcaneus below, articulating on either side with the malleoli, and in front with the navicular. It consists of a **body**, a **neck**, and a **head** 11

The Body (*corpus tali*).—The **superior surface** of the body presents, behind, a smooth trochlear surface, the **trochlea**, for articulation with the tibia. The trochlea is broader in front than behind, convex from before backward, slightly concave from side to side: in front it is continuous with the upper surface of the neck of the bone. 12

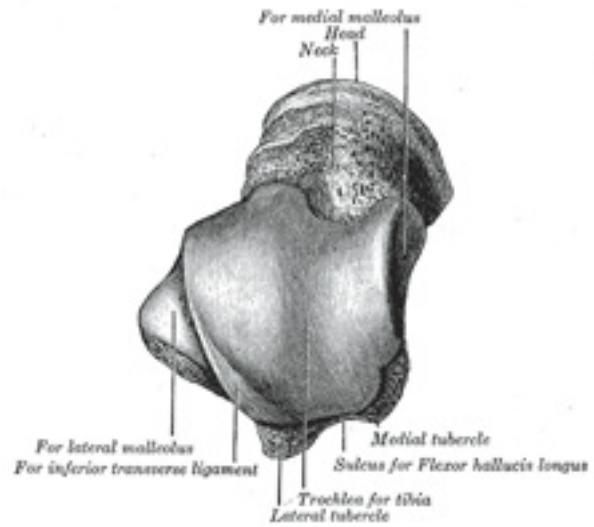


FIG. 270– Left talus, from above. ([See enlarged image](#))

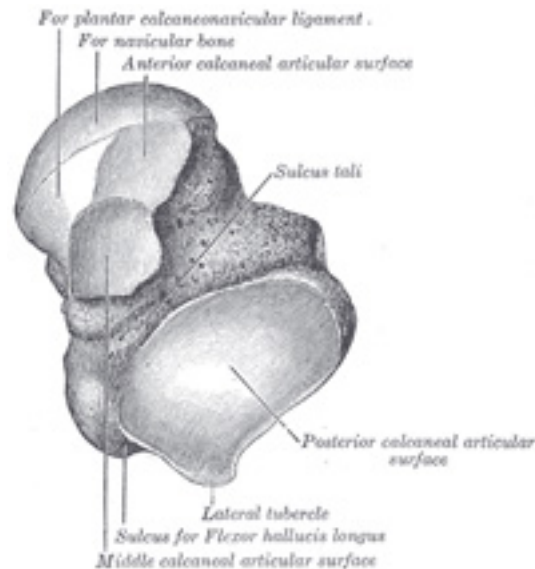


FIG. 271– Left talus, from below. ([See enlarged image](#))

The **inferior surface** presents two articular areas, the posterior and middle calcaneal surfaces, separated from one another by a deep groove, the **sulcus tali**. The groove runs obliquely forward and lateralward, becoming gradually broader and deeper in front: in the articulated foot it lies above a similar groove upon the upper surface of the calcaneus, and forms, with it, a canal (**sinus tarsi**) filled up in the fresh state by the interosseous talocalcaneal ligament. The **posterior calcaneal articular surface** is large and of an oval or oblong form. It articulates with the corresponding facet on the upper surface of the calcaneus, [63](#) and is deeply concave in the direction of its long axis which runs forward and lateralward at an angle of about 45° with the median plane of the body. The **middle calcaneal articular surface** is small, oval in form and slightly convex; it articulates with the upper surface of the sustentaculum tali of the calcaneus.

13

The **medial surface** presents at its upper part a pear-shaped articular facet for the medial malleolus, continuous above with the trochlea; below the articular surface is a rough depression for the attachment of the deep portion of the deltoid ligament of the ankle-joint.

14

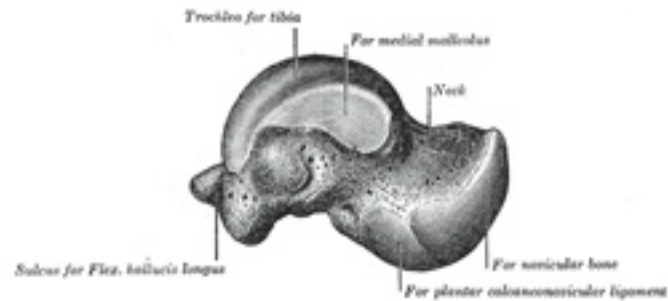


FIG. 272– Left talus, medial surface. ([See enlarged image](#))

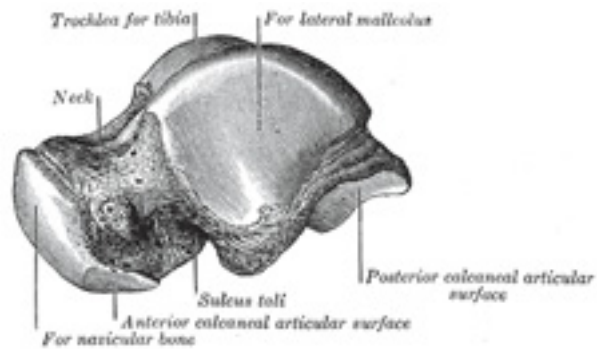


FIG. 273– Left talus, lateral surface. ([See enlarged image](#))

The **lateral surface** carries a large triangular facet, concave from above downward, for articulation with the lateral malleolus; its anterior half is continuous above with the trochlea; and in front of it is a rough depression for the attachment of the anterior talofibular ligament. Between the posterior half of the lateral border of the trochlea and the posterior part of the base of the fibular articular surface is a triangular facet (Fawcett [64](#)) which comes into contact with the transverse inferior tibiofibular ligament during flexion of the ankle-joint; below the base of this facet is a groove which affords attachment to the posterior talofibular ligament. 15

The **posterior surface** is narrow, and traversed by a groove running obliquely downward and medialward, and transmitting the tendon of the Flexor hallucis longus. Lateral to the groove is a prominent tubercle, the **posterior process**, to which the posterior talofibular ligament is 16

attached; this process is sometimes separated from the rest of the talus, and is then known as the **os trigonum**. Medial to the groove is a second smaller tubercle.

The Neck (*collum tali*).—The neck is directed forward and medialward, and comprises the constricted portion of the bone between the body and the oval head. Its **upper** and **medial surfaces** are rough, for the attachment of ligaments; its **lateral surface** is concave and is continuous below with the deep groove for the interosseous talocalcaneal ligament. 17

The Head (*caput tali*).—The head looks forward and medialward; its **anterior articular or navicular surface** is large, oval, and convex. 18
Its **inferior surface** has two facets, which are best seen in the fresh condition. The medial, situated in front of the middle calcaneal facet, is convex, triangular, or semi-oval in shape, and rests on the plantar calcaneonavicular ligament; the lateral, named the **anterior calcaneal articular surface**, is somewhat flattened, and articulates with the facet on the upper surface of the anterior part of the calcaneus.

Articulations.—The talus articulates with *four* bones: tibia, fibula, calcaneus, and navicular. 19

The Cuboid Bone (*os cuboideum*) (Figs. 274, 275).—The cuboid bone is placed on the lateral side of the foot, in front of the calcaneus, and behind the fourth and fifth metatarsal bones. It is of a pyramidal shape, its base being directed medialward. 20

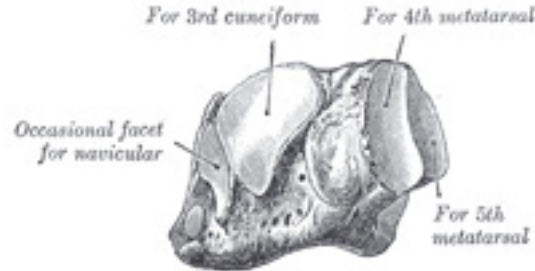


FIG. 274— The left cuboid. Antero-medial view. ([See enlarged image](#))

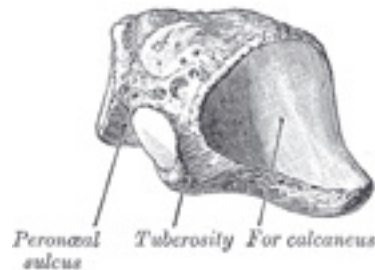


FIG. 275— The left cuboid. Postero-lateral view. ([See enlarged image](#))

Surfaces.—The **dorsal surface**, directed upward and lateralward, is rough, for the attachment of ligaments. The **plantar surface** presents in front a deep groove, the **peroneal sulcus**, which runs obliquely forward and medialward; it lodges the tendon of the Peronæus longus, and is bounded behind by a prominent ridge, to which the long plantar ligament is attached. The ridge ends laterally in an eminence, the **tuberosity**, the surface of which presents an oval facet; on this facet glides the sesamoid bone or cartilage frequently found in the tendon of the Peronæus longus. The surface of bone behind the groove is rough, for the attachment of the plantar calcaneocuboid ligament, a few fibers of the Flexor hallucis brevis, and a fasciculus from the tendon of the Tibialis posterior. The **lateral surface** presents a deep notch formed by the commencement of the peroneal sulcus. The **posterior surface** is smooth, triangular, and concavo-convex, for articulation with the anterior surface of the calcaneus; its infero-medial angle projects backward as a process which underlies and supports the anterior end of the calcaneus. The **anterior surface**, of smaller size, but also irregularly triangular, is divided by a vertical ridge into two facets: the medial, quadrilateral in form, articulates with the fourth metatarsal; the lateral, larger and more triangular, articulates with the fifth. The **medial surface** is broad, irregularly quadrilateral, and presents at its middle and upper part a smooth oval facet, for articulation with the third cuneiform; and behind this (occasionally) a smaller facet, for articulation with the navicular; it is rough in the rest of its extent, for the attachment of strong interosseous ligaments. 21

Articulations.—The cuboid articulates with *four* bones: the calcaneus, third cuneiform, and fourth and fifth metatarsals; occasionally with a fifth, the navicular. 22

The Navicular Bone (*os naviculare pedis*; *scaphoid bone*) ([Figs. 276, 277](#)).—The navicular bone is situated at the medial side of the tarsus, between the talus behind and the cuneiform bones in front. 23

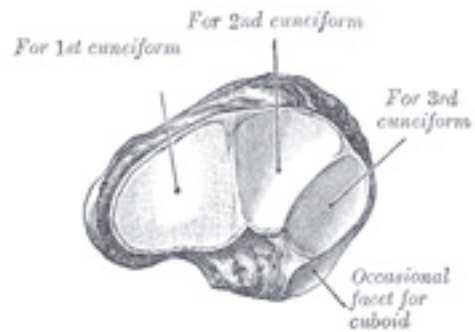


FIG. 276— The left navicular. Antero-lateral view. ([See enlarged image](#))

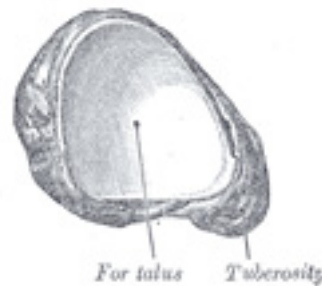


FIG. 277— The left navicular. Postero-medial view. ([See enlarged image](#))

Surfaces.—The **anterior surface** is convex from side to side, and subdivided by two ridges into three facets, for articulation with the three cuneiform bones. The **posterior surface** is oval, concave, broader laterally than medially, and articulates with the rounded head of the talus. The **dorsal surface** is convex from side to side, and rough for the attachment of ligaments. The **plantar surface** is irregular, and also rough for the attachment of ligaments. The **medial surface** presents a rounded **tuberosity**, the lower part of which gives attachment to part of the tendon of the Tibialis posterior. The **lateral surface** is rough and irregular for the attachment of ligaments, and occasionally presents a small facet for articulation with the cuboid bone.

Articulations.—The navicular articulates with *four* bones: the talus and the three cuneiforms; occasionally with a fifth, the cuboid.

25

The First Cuneiform Bone (*os cuneiform primum; internalcuneiform*) (Figs. 278,279).—The first cuneiform bone is the largest of the three cuneiforms. It is situated at the medial side of the foot, between the navicular behind and the base of the first metatarsal in front.

26

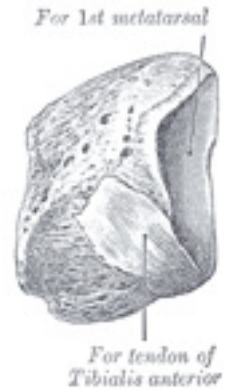

FIG. 278— The left first cuneiform. Antero-medial view. ([See enlarged image](#))

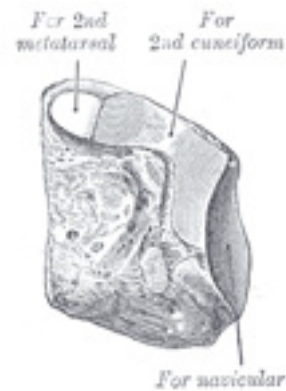

FIG. 279— The left first cuneiform. Postero-lateral view. ([See enlarged image](#))

Surfaces.—The **medial surface** is subcutaneous, broad, and quadrilateral; at its anterior plantar angle is a smooth oval impression, into which part of the tendon of the Tibialis anterior is inserted; in the rest of its extent it is rough for the attachment of ligaments. The **lateral surface** is concave, presenting, along its superior and posterior borders a narrow L-shaped surface, the vertical limb and posterior part of the horizontal limb of which articulate with the second cuneiform, while the anterior part of the horizontal limb articulates with the second metatarsal bone: the rest of this surface is rough for the attachment of ligaments and part of the tendon of the Peronæus longus. The **anterior surface**, kidney-shaped and much larger than the posterior, articulates with the first metatarsal bone. The **posterior surface** is triangular, concave, and articulates with the most medial and largest of the three facets on the anterior surface of the navicular. The **plantar surface** is rough, and forms the base of the wedge; at its back part is a tuberosity for the insertion of part of the tendon of the Tibialis posterior. It also gives insertion in front to part of the tendon of the Tibialis anterior. The **dorsal surface** is the narrow end of the wedge, and is directed upward and lateralward; it is rough for the attachment of ligaments. 27

Articulations.—The first cuneiform articulates with *four* bones: the navicular, second cuneiform, and first and second metatarsals. 28

The Second Cuneiform Bone (*os cuneiforme secundum; middle cuneiform*) ([Figs. 280,281](#)).—The second cuneiform bone, the smallest of the three, is of very regular wedge-like form, the thin end being directed downward. It is situated between the other two cuneiforms, and articulates with the navicular behind, and the second metatarsal in front. 29

Surfaces.—The **anterior surface**, triangular in form, and narrower than the posterior, articulates with the base of the second metatarsal bone. The **posterior surface**, also triangular, articulates with the intermediate facet on the anterior surface of the navicular. The **medial surface** carries an L-shaped articular facet, running along the superior and posterior borders, for articulation with the first cuneiform, and is rough in the rest of its extent for the attachment of ligaments. The **lateral surface** presents posteriorly a smooth facet for articulation with the third cuneiform bone. The **dorsal surface** forms the base of the wedge; it is quadrilateral and rough for the attachment of ligaments. The **plantar surface**, sharp and tuberculated, is also rough for the attachment of ligaments, and for the insertion of a slip from the tendon of the Tibialis posterior. 30

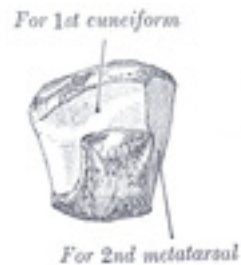

FIG. 280— The left second cuneiform. Antero-medial view. ([See enlarged image](#))

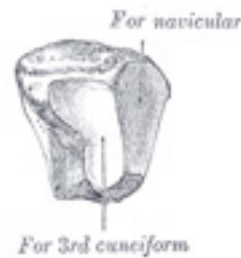

FIG. 281— The left second cuneiform. Postero-lateral view. ([See enlarged image](#))

Articulations.—The second cuneiform articulates with *four* bones: the navicular, first and third cuneiforms, and second metatarsal. 31

The Third Cuneiform Bone (*os cuneiforme tertium; external cuneiform*) ([Figs. 282,283](#)).—The third cuneiform bone, intermediate in size 32
between the two preceding, is wedge-shaped, the base being uppermost. It occupies the center of the front row of the tarsal bones, between the second cuneiform medially, the cuboid laterally, the navicular behind, and the third metatarsal in front.

Surfaces.—The **anterior surface**, triangular in form, articulates with the third metatarsal bone. The **posterior surface** articulates with the lateral 33
facet on the anterior surface of the navicular, and is rough below for the attachment of ligamentous fibers. The **medial surface** presents an anterior and a posterior articular facet, separated by a rough depression: the anterior, sometimes divided, articulates with the lateral side of the base of the second metatarsal bone; the posterior skirts the posterior border, and articulates with the second cuneiform; the rough depression

gives attachment to an interosseous ligament. The **lateral surface** also presents two articular facets, separated by a rough non-articular area; the anterior facet, situated at the superior angle of the bone, is small and semi-oval in shape, and articulates with the medial side of the base of the fourth metatarsal bone; the posterior and larger one is triangular or oval, and articulates with the cuboid; the rough, non-articular area serves for the attachment of an interosseous ligament. The three facets for articulation with the three metatarsal bones are continuous with one another; those for articulation with the second cuneiform and navicular are also continuous, but that for articulation with the cuboid is usually separate. The **dorsal surface** is of an oblong form, its postero-lateral angle being prolonged backward. The **plantar surface** is a rounded margin, and serves for the attachment of part of the tendon of the Tibialis posterior, part of the Flexor hallucis brevis, and ligaments.

Articulations.—The third cuneiform articulates with *six* bones: the navicular, second cuneiform, cuboid, and second, third, and fourth metatarsals.

34

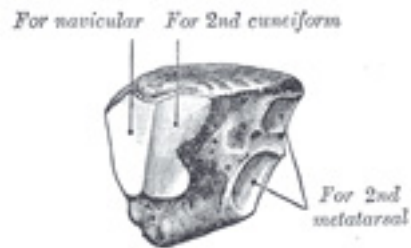


FIG. 282— The left third cuneiform. Postero-medial view. ([See enlarged image](#))

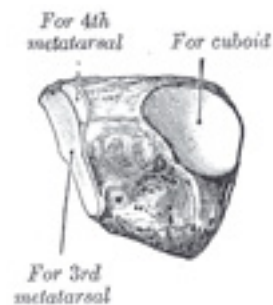


FIG. 283— The third left cuneiform. Antero-lateral view. ([See enlarged image](#))

Note 63. Sewell (Journal of Anatomy and Physiology, vol. xxxviii) pointed out that in about 10 per cent. of bones a small triangular facet, continuous with the posterior calcaneal facet, is present at the junction of the lateral surface of the body with the posterior wall of the sulcus tali. [[back](#)]

Note 64. Edinburgh Medical Journal, 1895. [[back](#)]

6d. 2. The Metatarsus

The **metatarsus** consists of five bones which are numbered from the medial side (*ossa metatarsalia* I.-V.); each presents for examination a **body** and **two extremities**. 1

Common Characteristics of the Metatarsal Bones.—The body is prismoid in form, tapers gradually from the tarsal to the phalangeal extremity, and is curved longitudinally, so as to be concave below, slightly convex above. The **base** or **posterior extremity** is wedge-shaped, articulating proximally with the tarsal bones, and by its sides with the contiguous metatarsal bones: its dorsal and plantar surfaces are rough for the attachment of ligaments. The **head** or **anterior extremity** presents a convex articular surface, oblong from above downward, and extending farther backward below than above. Its sides are flattened, and on each is a depression, surmounted by a tubercle, for ligamentous attachment. Its plantar surface is grooved antero-posteriorly for the passage of the Flexor tendons, and marked on either side by an articular eminence continuous with the terminal articular surface. 2

Characteristics of the Individual Metatarsal Bones. — The First Metatarsal Bone (*os metatarsale I; metatarsal bone of the great toe*) [[Fig. 284](#)].—The first metatarsal bone is remarkable for its great thickness, and is the shortest of the metatarsal bones. The **body** is strong, and of well-marked prismoid form. The **base** presents, as a rule, no articular facets on its sides, but occasionally on the lateral side there is an oval facet, by which it articulates with the second metatarsal. Its proximal articular surface is of large size and kidney-shaped; its circumference is grooved, for the tarsometatarsal ligaments, and medially gives insertion to part of the tendon of the Tibialis anterior; its plantar angle presents a rough oval prominence for the insertion of the tendon of the Peronæus longus. The **head** is large; on its plantar surface are two grooved facets, on which glide sesamoid bones; the facets are separated by a smooth elevation. 3

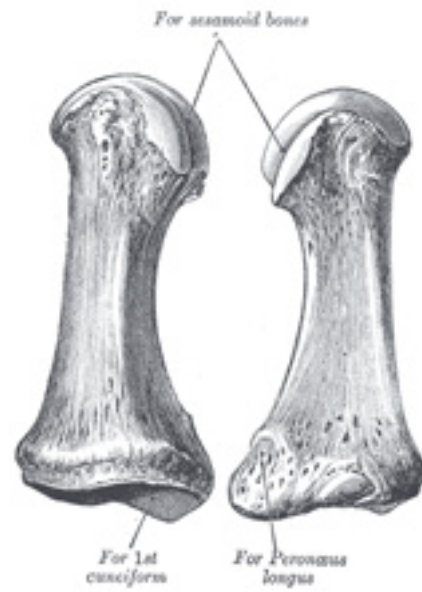

FIG. 284— The first metatarsal. (Left.) ([See enlarged image](#))

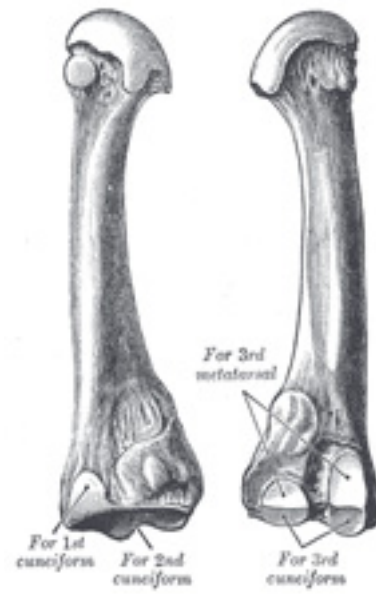


FIG. 285– The second metatarsal. (Left.) ([See enlarged image](#))

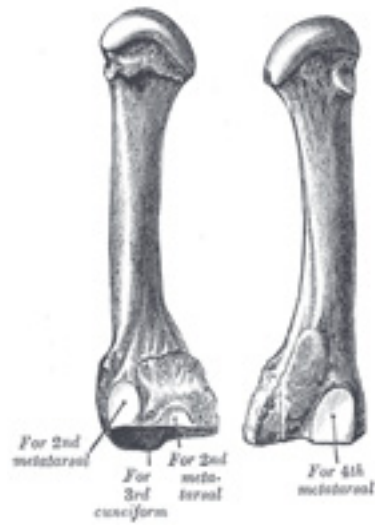


FIG. 286— The third metatarsal. (Left.) ([See enlarged image](#))

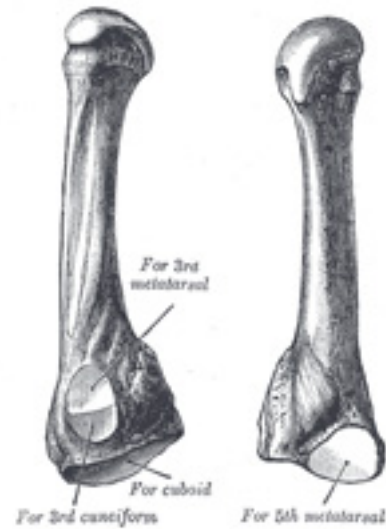


FIG. 287— The fourth metatarsal. (Left.) ([See enlarged image](#))

The Second Metatarsal Bone (*os metatarsale II*) (Fig. 285).—The second metatarsal bone is the longest of the metatarsal bones, being prolonged backward into the recess formed by the three cuneiform bones. Its **base** is broad above, narrow and rough below. It presents four articular surfaces: one behind, of a triangular form, for articulation with the second cuneiform; one at the upper part of its medial surface, for articulation with the first cuneiform; and two on its lateral surface, an upper and lower, separated by a rough non-articular interval. Each of these lateral articular surfaces is divided into two by a vertical ridge; the two anterior facets articulate with the third metatarsal; the two posterior (sometimes continuous) with the third cuneiform. A fifth facet is occasionally present for articulation with the first metatarsal; it is oval in shape, and is situated on the medial side of the body near the base. 4

The Third Metatarsal Bone (*os metatarsale III*) (Fig. 286).—The third metatarsal bone articulates proximally, by means of a triangular smooth surface, with the third cuneiform; medially, by two facets, with the second metatarsal; and laterally, by a single facet, with the fourth metatarsal. This last facet is situated at the dorsal angle of the base. 5

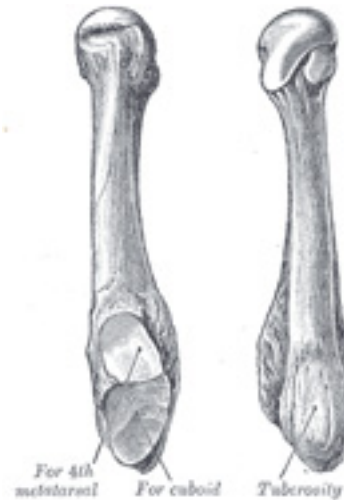

FIG. 288— The fifth metatarsal. (Left.) ([See enlarged image](#))

The Fourth Metatarsal Bone (*os metatarsale IV*) ([Fig. 287](#)).—The fourth metatarsal bone is smaller in size than the preceding; its **base** presents an oblique quadrilateral surface for articulation with the cuboid; a smooth facet on the medial side, divided by a ridge into an anterior portion for articulation with the third metatarsal, and a posterior portion for articulation with the third cuneiform; on the lateral side a single facet, for articulation with the fifth metatarsal. 6

The Fifth Metatarsal Bone (*os metatarsale V*) ([Fig. 288](#)).—The fifth metatarsal bone is recognized by a rough eminence, the **tuberosity**, on the lateral side of its base. The **base** articulates behind, by a triangular surface cut obliquely in a transverse direction, with the cuboid; and medially, with the fourth metatarsal. On the medial part of its dorsal surface is inserted the tendon of the Peronæus tertius and on the dorsal surface of the tuberosity that of the Peronæus brevis. A strong band of the plantar aponeurosis connects the projecting part of the tuberosity with the lateral process of the tuberosity of the calcaneus. The plantar surface of the base is grooved for the tendon of the Abductor digiti quinti, and gives origin to the Flexor digiti quinti brevis. 7

Articulations.—The base of each metatarsal bone articulates with one or more of the tarsal bones, and the head with one of the first row of phalanges. The first metatarsal articulates with the first cuneiform, the second with all three cuneiforms, the third with the third cuneiform, the fourth with the third cuneiform and the cuboid, and the fifth with the cuboid. 8

6d. 3. The Phalanges of the Foot

(Phalanges Digitorum Pedis)

1

The **phalanges** of the foot correspond, in number and general arrangement, with those of the hand; there are two in the great toe, and three in each of the other toes. They differ from them, however, in their size, the bodies being much reduced in length, and, especially in the first row, laterally compressed.

First Row.—The **body** of each is compressed from side to side, convex above, concave below. The **base** is concave; and the **head** presents a trochlear surface for articulation with the second phalanx.

2

Second Row.—The phalanges of the second row are remarkably small and short, but rather broader than those of the first row.

3

The **ungual phalanges**, in form, resemble those of the fingers; but they are smaller and are flattened from above downward; each presents a broad base for articulation with the corresponding bone of the second row, and an expanded distal extremity for the support of the nail and end of the toe.

4

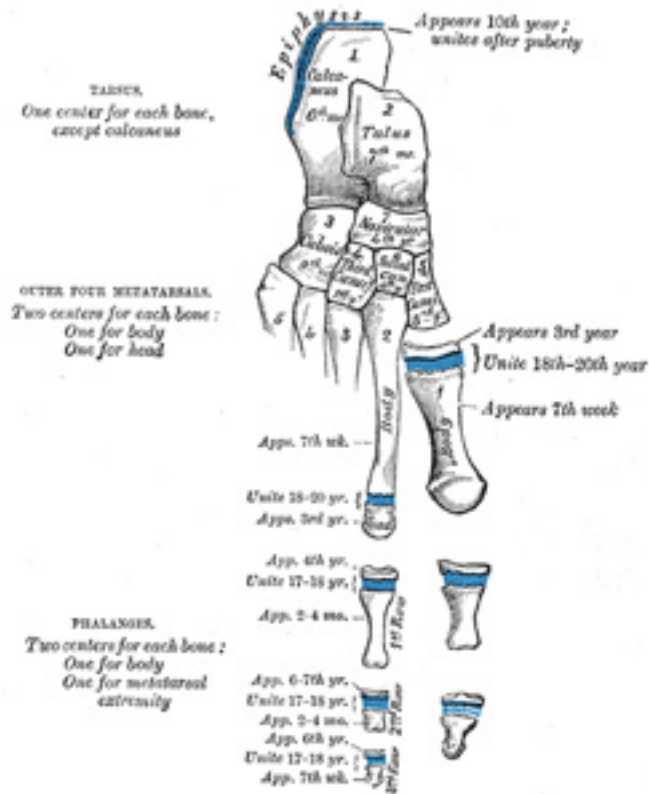


FIG. 289— Plan of ossification of the foot. ([See enlarged image](#))

Articulations.—In the second, third, fourth, and fifth toes the phalanges of the first row articulate behind with the metatarsal bones, and in front with the second phalanges, which in their turn articulate with the first and third; the unguis phalanges articulate with the second. ⁵

Ossification of the Bones of the Foot (Fig. 289).—The **tarsal bones** are each ossified from a *single* center, excepting the calcaneus, which has an epiphysis for its posterior extremity. The centers make their appearance in the following order: calcaneus at the sixth month of fetal life; talus, about the seventh month; cuboid, at the ninth month; third cuneiform, during the first year; first cuneiform, in the third year; second cuneiform ⁶

and navicular, in the fourth year. The epiphysis for the posterior extremity of the calcaneus appears at the tenth year, and unites with the rest of the bone soon after puberty. The posterior process of the talus is sometimes ossified from a separate center, and may remain distinct from the main mass of the bone, when it is named the *os trigonum*.

The **metatarsal bones** are each ossified from *two* centers: one for the body, and one for the head, of the second, third, fourth, and fifth metatarsals; one for the body, and one for the base, of the first metatarsal. ⁷ **65** Ossification commences in the center of the body about the ninth week, and extends toward either extremity. The center for the base of the first metatarsal appears about the third year; the centers for the heads of the other bones between the fifth and eighth years; they join the bodies between the eighteenth and twentieth years.

The **phalanges** are each ossified from *two* centers: one for the body, and one for the base. The center for the body appears about the tenth week, ⁸ that for the base between the fourth and tenth years; it joins the body about the eighteenth year.

Note 65. As was noted in the first metacarpal (see footnote, page 231), so in the first metatarsal, there is often a second epiphysis for its head. [[back](#)]

6d. 4. Comparison of the Bones of the Hand and Foot

The hand and foot are constructed on somewhat similar principles, each consisting of a proximal part, the carpus or the tarsus, a middle portion, the metacarpus, or the metatarsus, and a terminal portion, the phalanges. ¹ The proximal part consists of a series of more or less cubical bones which allow a slight amount of gliding on one another and are chiefly concerned in distributing forces transmitted to or from the bones of the arm or leg. The middle part is made up of slightly movable long bones which assist the carpus or tarsus in distributing forces and also give greater breadth for the reception of such forces. The separation of the individual bones from one another allows of the attachments of the Interossei and protects the dorsi-palmar and dorsi-plantar vascular anastomoses. The terminal portion is the most movable, and its separate elements enjoy a varied range of movements, the chief of which are flexion and extension.

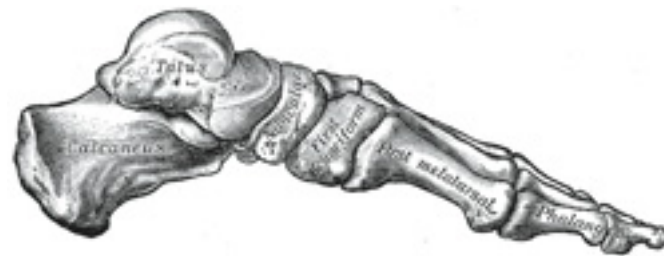

FIG. 290— Skeleton of foot. Medial aspect. ([See enlarged image](#))

The function of the hand and foot are, however, very different, and the general similarity between them is greatly modified to meet these requirements. Thus the foot forms a firm basis of support for the body in the erect posture, and is therefore more solidly built up and its component parts are less movable on each other than those of the hand. In the case of the phalanges the difference is readily noticeable; those of the foot are smaller and their movements are more limited than those of the hand. Very much more marked is the difference between the metacarpal bone of the thumb and the metatarsal bone of the great toe. The metacarpal bone of the thumb is constructed to permit of great mobility, is directed at an acute angle from that of the index finger, and is capable of a considerable range of movements at its articulation with the carpus. The metatarsal bone of the great toe assists in supporting the weight of the body, is constructed with great solidity, lies parallel with the other metatarsals, and has a very limited degree of mobility. The carpus is small in proportion to the rest of the hand, is placed in line with the forearm, and forms a transverse arch, the concavity of which constitutes a bed for the Flexor tendons and the palmar vessels and nerves. The tarsus forms a considerable part of the foot, and is placed at right angles to the leg, a position which is almost peculiar to man, and has relation to his erect posture. In order to allow of their supporting the weight of the body with the least expenditure of material the tarsus and a part of the metatarsus are constructed in a series of arches (Figs. 290, 291), the disposition of which will be considered after the articulations of the foot have been described.

2

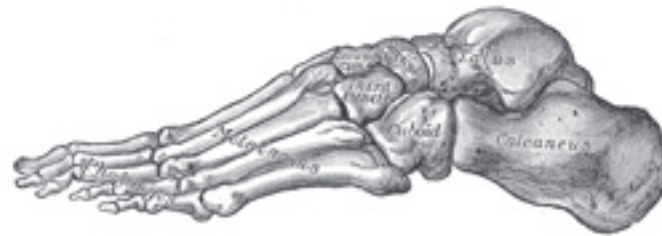

FIG. 291– Skeleton of foot. Lateral aspect. ([See enlarged image](#))

6d. 5. The Sesamoid Bones

(Ossa Sesamoidea)

1

Sesamoid bones are small more or less rounded masses embedded in certain tendons and usually related to joint surfaces. Their functions probably are to modify pressure, to diminish friction, and occasionally to alter the direction of a muscle pull. That they are not developed to meet certain physical requirements in the adult is evidenced by the fact that they are present as cartilaginous nodules in the fetus, and in greater numbers than in the adult. They must be regarded, according to Thilenius, as integral parts of the skeleton phylogenetically inherited. [66](#) Physical necessities probably come into play in selecting and in regulating the degree of development of the original cartilaginous nodules. Nevertheless,

irregular nodules of bone may appear as the result of intermittent pressure in certain regions, *e.g.*, the “rider’s bone,” which is occasionally developed in the Adductor muscles of the thigh.

Sesamoid bones are invested by the fibrous tissue of the tendons, except on the surfaces in contact with the parts over which they glide, where they present smooth articular facets. 2

In the upper extremity the sesamoid bones of the joints are found only on the palmar surface of the hand. Two, of which the medial is the the larger, are constant at the metacarpophalangeal joint of the thumb; one is frequently present in the corresponding joint of the little finger, and one (or two) in the same joint of the index finger. Sesamoid bones are also found occasionally at the metacarpophalangeal joints of the middle and ring fingers, at the interphalangeal joint of the thumb and at the distal interphalangeal joint of the index finger. 3

In the lower extremity the largest sesamoid bone of the joints is the patella, developed in the tendon of the Quadriceps femoris. On the plantar aspect of the foot, two, of which the medial is the larger, are always present at the metatarsophalangeal joint of the great toe; one sometimes at the metatarsophalangeal joints of the second and fifth toes, one occasionally at the corresponding joint of the third and fourth toes, and one at the interphalangeal joint of the great toe. 4

Sesamoid bones apart from joints are seldom found in the tendons of the upper limb; one is sometimes seen in the tendon of the Biceps brachii opposite the radial tuberosity. They are, however, present in several of the tendons of the lower limb, *viz.*, one in the tendon of the Peronæus longus, where it glides on the cuboid; one, appearing late in life, in the tendon of the Tibialis anterior, opposite the smooth facet of the first cuneiform bone; one in the tendon of the Tibialis posterior, opposite the medial side of the head of the talus; one in the lateral head of the Gastrocnemius, behind the lateral condyle of the femur; and one in the tendon of the Psoas major, where it glides over the pubis. Sesamoid bones are found occasionally in the tendon of the Glutæus maximus, as it passes over the greater trochanter, and in the tendons which wind around the medial and lateral malleoli. 5

Note 66. Morpholog. Arbeiten, 1906, v, 309. [[back](#)]