

Pagetoid reticulosis Woringer–Kolopp type, a particular variant of mycosis fungoides: a case report

SILVIU HORIA MORARIU¹⁾, MARIA ROTARU²⁾, MIHAI DORIN VARTOLOMEI³⁾, MIHAI TURCU⁴⁾,
 ANDREEA-LUCIANA CHIOTOROIU⁵⁾, MIRCEA SUCIU⁶⁾, OVIDIU SIMION COTOI⁷⁾

¹⁾Department of Dermatology, University of Medicine and Pharmacy of Tirgu Mures, Romania

²⁾Department of Dermatology, "Victor Papilian" Faculty of Medicine, "Lucian Blaga" University of Sibiu, Romania

³⁾Department of Cell and Molecular Biology, University of Medicine and Pharmacy of Tirgu Mures, Romania

⁴⁾Department of Pathology, University of Medicine and Pharmacy of Tirgu Mures, Romania

⁵⁾Student, Faculty of Medicine, University of Medicine and Pharmacy of Tirgu Mures, Romania

⁶⁾Department of Oral Rehabilitation and Occlusology, University of Medicine and Pharmacy of Tirgu Mures, Romania

⁷⁾Department of Pathophysiology, University of Medicine and Pharmacy of Tirgu Mures, Romania

Abstract

According to the definition of WHO, pagetoid reticulosis (PR) is characterized by the presence of unique skin lesion in the shape of patches or plaques caused by the proliferation of atypical T-cells in epidermis. We report the case of a 50-year-old female, presenting a 50×65 mm erythematous scaly patch, well-defined, slightly infiltrated, discrete polycyclic, on the right buttock, which appeared and developed in about 6–8 months. The clinical and dermatoscopic aspects suggested a Bowen's disease. A skin biopsy was performed. The histological examination of the pieces confirmed the presence of monoclonal lymphoid infiltrate with obvious phenomena of epidermotropism. Immunophenotypically the tumoral cells express intensively CD3 and CD8 and focally CD4. Surgical excision was performed without radiotherapy and chemotherapy. The patient was followed-up for 42 months without local relapses, distant lymph nodes or visceral metastases. Microscopic aspect of the lesion corresponds to stage I–II of mycosis fungoides (MF) (patches or plaques); the diagnosis was PR Woringer–Kolopp type. The most recent classification of skin lymphomas (WHO, 2008) confirms that the immunohistochemical profile of T-cells can be CD4+ and CD8- or CD4- and CD8+, and frequently CD30+, in contrast to the classical versions of MF. Pagetoid reticulosis type Woringer–Kolopp, a rare particular variant of mycosis fungoides, is suspected in cases with unique, distinctive lesion and confirmed only by histological immunohistochemistry. Treatment consists of surgical excision of the lesion with long follow-up.

Keywords: pagetoid reticulosis, Woringer–Kolopp, Ketron–Goodman, immunohistochemistry.

Introduction

The first description of the pagetoid reticulosis (PR) disease belongs to Frédéric Woringer and Pierre Kolopp. They present in *Annales de Dermatologie et Vénérologie* [1], in 1939, the case of a 13-year-old boy with a single lesion scaly erythematous, polycyclic on the forearm that started six years ago. From the beginning, it was considered a subtype or a particular variant of mycosis fungoides (MF). The term of Woringer–Kolopp PR was introduced 44 years later, in 1973, by Braun-Falco *et al.* in honor of the two dermatologists [2]. A disseminated variant of PR was described by Ketron–Goodman, this disease is with a reserved prognosis because of high recurrence rates [3].

Currently, according to 2001 and 2008 WHO (*World Health Organization*) Classifications and to EORTC (*European Organization for Research and The Treatment of Cancer*) from 1997 [4–6], the term PR is used only for single lesions, localized, without systemic spread. While disseminated form Ketron–Goodman is not considered PR, but a classic form of MF, a primary cutaneous lymphoma with T-cell cytotoxic CD8-positive or gamma/delta positive – CTCL (primary cutaneous aggressive CD8+ cytotoxic T-cell lymphoma, or γ/δ positive CTCL) [7].

In this paper is presented a very rare case, a particular variant of mycosis fungoides, the pagetoid reticulosis type Woringer–Kolopp.

Patient, Methods and Results

We report the case of a 50-year-old Caucasian female, from urban area, presenting with a 50×65 mm erythematous scaly patch, asymptomatic, well-defined margins, slightly infiltrated, discrete polycyclic, on the right buttock, which appeared and developed in about 6–8 months, with slow and progressive growth.

We initiated the treatment with a local corticosteroid. We proposed her to perform a skin biopsy, but the patient refused. After eight months, the patient presented for a check up that showed no significant changes in the lesion. We perform dermatoscopy, and photodynamic examination of the lesion.

On dermatoscopic examination, we observed a discrete homogeneous pink background erythema and dotted glomerular vessels and white areas corresponding scales. At the periphery, we found a Bowen disease characteristic (the negative network). Photodynamic diagnosis after local application of delta-aminolevulinic acid showed no fluorescence characteristic to Bowen disease or other skin tumors.

Laboratory examination did not highlight any significant changes. Clinical examination and local dermatoscopy suggested a Bowen's disease, for that reason punch biopsy was indicated under local anesthesia, the patient sign an informed consent. Microscopic examination excluded Bowen disease, but revealed the presence of a

lymphoid infiltrate with epidermotropism phenomena, therefore was indicated wide surgical excision of the whole lesion, with subsequent restoration of cutaneous defect with skin graft. CT scan was performed and revealed no presence of growth lymph node or visceral lesions (Figures 1–3).

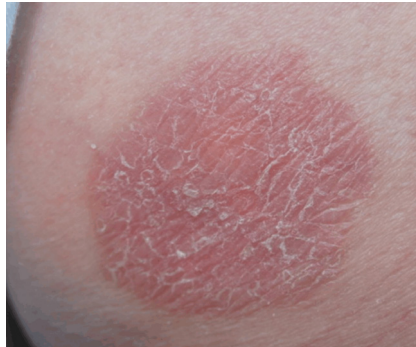


Figure 1 – Clinical aspects.

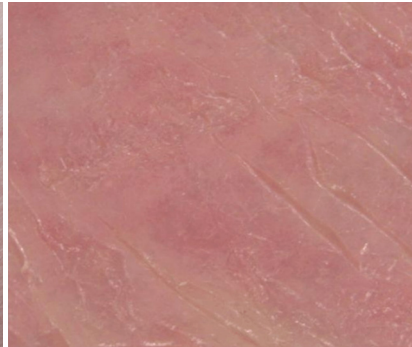

Figure 2 – Dermatoscopic aspects.

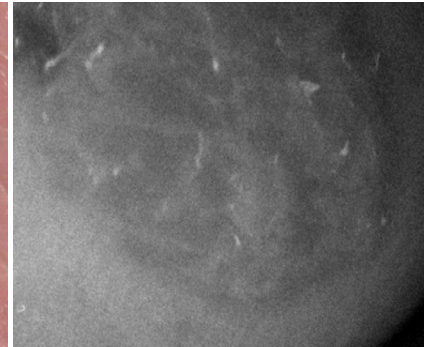


Figure 3 – Photodynamic diagnosis.

Tissue fragments collected by punch biopsy and surgical excision were processed by standard histological methods: fixing in 10% formalin, pH 7.2 for 24 hours, paraffin embedding, sectioning at 4–5 μm thickness, staining with Hematoxylin–Eosin (HE).

Microscopic examination reveals a lymphoid infiltrate mainly localized in the epidermis consisting in atypical mononuclear cells. The cells were medium or large-sized, with abundant cytoplasm, vacuolar and present a charac-

teristic perinuclear halo. Atypical cells were arranged singly or in small nests (Pautrier abscess-like). The epidermis was infiltrated especially in the basal third. Surface epithelium shows mild hyperkeratosis orthokeratosis or parakeratosis type associated with acanthosis and elongation of rete ridges, psoriasiform type. Papillary dermis shows dilated small blood vessels, with perivascular lymphocytic inflammatory infiltrate. Tumoral cells are rare or absent in the dermis (Figure 4).

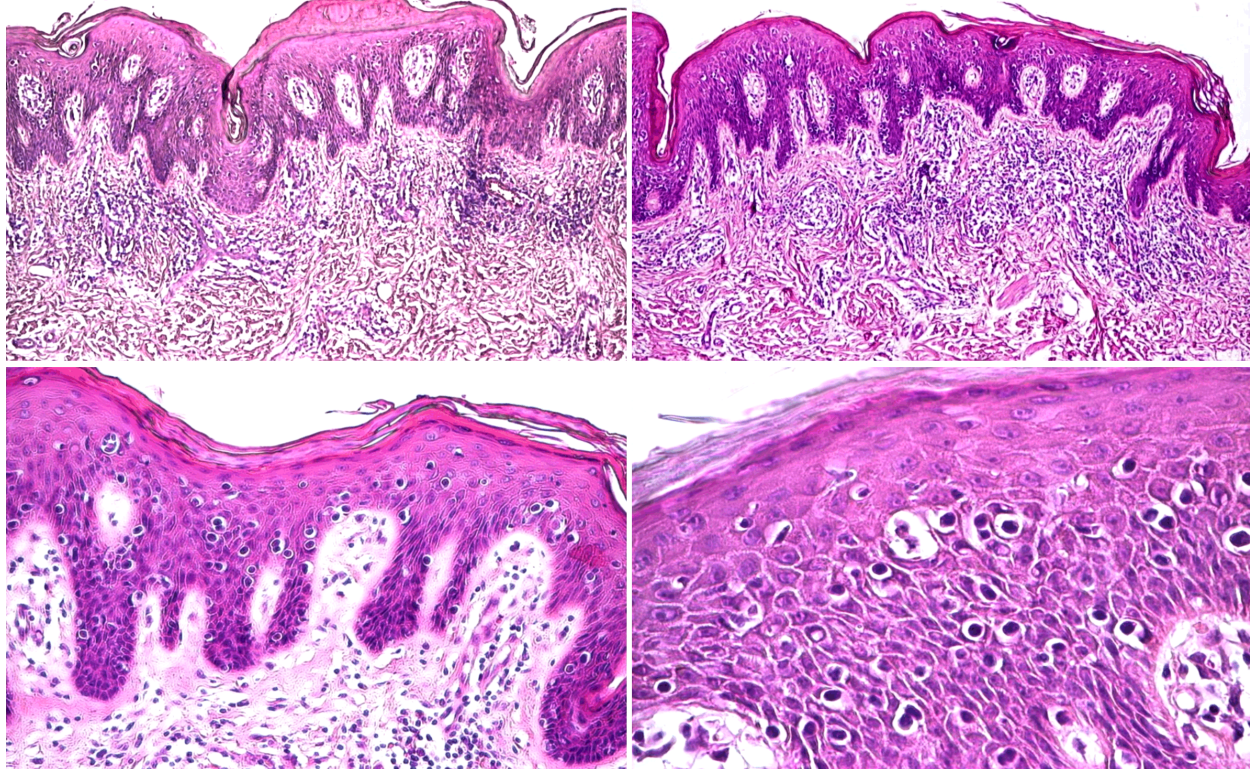


Figure 4 – Microscopic aspects, excisional skin biopsy. HE staining, 40 \times , 100 \times , and 200 \times .

For immunohistochemical examination were selected the most representative paraffin blocks. After dewaxing and hydration, endogenous peroxidase blocking was performed with 3% hydrogen peroxide. Incubation with the primary antigen was done for 30 minutes. Working method used was Streptavidin–Biotin complex system,

the final result was revealed with DAB (3,3'-Diaminobenzidine) in brown color. Primary antibody panel included: CD3 (clone SP-7, 1:200 dilution, Lab Vision), CD4 (clone 4B12, 1:80 dilution, Dako), CD8 (mouse monoclonal clone NCL-L-CD8-295, 1:40 dilution, Novocastra), CD20 (clone Ab-1, 1:250 dilution, Lab

Vision) and CD68 (clone KP-1, 1:600 dilution, Dako).

Immunohistochemical profile highlighted atypical lymphocytes which express intense and diffuse CD3, CD8 and focal CD4. Also, we observe CD68-positive macrophages, without B-lymphocytes CD20-positive (T-cell lymphoid infiltrates only) (Figure 5).

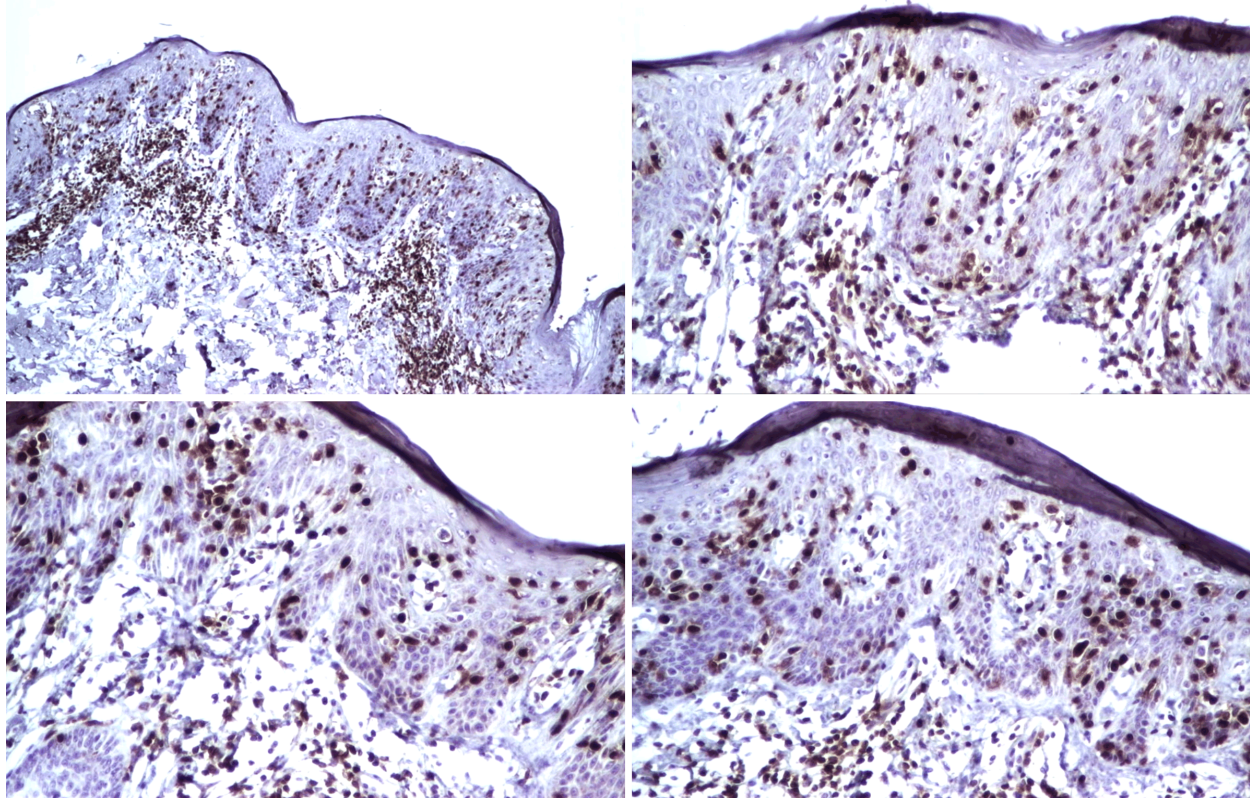


Figure 5 – Immunohistochemical profile, excisional skin biopsy. T-cells CD3 and CD8 positive, 40 \times and 100 \times .

Discussion

Pagetoid reticulosis Woringer–Kolopp type can begin at any age; several cases were described with beginning at a few months after birth [8]. Initially, P. Kolopp diagnosed clinically PR as skin tuberculosis [1], which nevertheless requires histopathology, requested by Fr. Woringer who made the first diagnosis of extramammary Paget's disease [1], a condition that requires today making a differential diagnosis [9, 10].

The clinical appearance of lesion in practice compels the differential diagnosis with psoriasis in single lesion, which is rare and chronic eczema with pruritus. In our case, clinical and dermatoscopic appearance – with dotted glomerular vessels in homogeneity pinkish background and whitish scaly areas, imposed initially the diagnosis of Bowen's disease. However, unlike Suzaki *et al.* [11] we had not highlighted peripheral negative network specific to Bowen's disease.

Some authors have described cases with different localizations: palms and soles or foot [12–14].

Immunophenotype: atypical cells express all T-cells markers (pan-T-cell antigens): CD2, CD3 and CD5. There were described different phenotypes: CD4-positive (T-helper) and CD8-positive (T-suppressor/cytotoxic) or CD4-positive and CD8-negative or CD4-negative and CD8-positive. Usually, CD7 is negative. Is noted a CD30 positivity in over 50% of cases, and a Ki-67 (proliferative index) increased in 50–60% of cases [15–17].

Surgical resection margins were negative. Clinical and imaging control (CT scan) performed at 6, 12, 24 and 42 months after surgical excision detected no local recurrence or appearance of new lesions and no lymph node or visceral metastases. In present, patient health status is very good, with excellent quality of life.

Cytogenetics: keratinocytes express HLA-DR and clonal TCR gene rearrangement in atypical T-cells. It may be a α/β TCR gene rearrangement type, or very rarely γ/δ TCR gene rearrangement type.

Histological differential diagnosis consists of several lesions, tumoral and non-tumoral, invasive or *in situ* type. The most important differential diagnosis is with primary cutaneous T-cell lymphoma (CTCL) with suppressor/cytotoxic T-lymphocytes (CD8+), marked by epidermotropism phenomena. Usually differentiation is based on clinical aspects and progression. In CTCL, prognosis is reserved.

Microscopically, PR differs from other types of injuries with epidermotropism: lymphomatoid papulosis, lymphomatoid drug reactions, classic mycosis fungoides or epithelial neoplasia with pagetoid appearance or melanoma *in situ*.

Although different types of treatments are cited according to various authors that use skin-directed therapies including local steroids, local nitrogen, psoralen plus ultraviolet A, narrow-band ultraviolet B and radiation therapy [18]. We used as first stage, for eight months, local corticoid but it did not influence the evolution and appearance of the initial lesion. We preferred the wide surgical excision of the entire lesion with cutaneous skin graft in two steps. In this type of lymphoma, the treatment is controversial. It is recommended clinical monitoring, but in literature there are cases treated by narrowband ultraviolet B (NB-UVB) with interferon, radiotherapy, Imiquimod or Alitretinoid [19–23].

PR evolution is generally slow with many years of stagnation. The lesion is asymptomatic, that is the reason why patients are coming late at the doctor. There are cited cases of spontaneous regression without recurrence at five years [24].

Prognosis is good, with no relapses and no dissemination or metastasis after initial treatment. Burns *et al.* were following eight cases of PR Woringer–Kolopp type between 18 months and 17 years and did not find any recurrence, metastasis or dissemination of lesions [25]. In our case, the follow up at 42 months showed no clinical or CT scan evidence of relapses, other skin lesions occurrence, lymph node enlargement or visceral metastases.

In disseminated Ketron–Goodman disease, where the prognosis is reserved by relatively high recurrence rate after many years, if skin lesions vanish does not mean healing [26]. This is one of the reasons why separate approach of this disease is mandatory and framed it in a primary cutaneous T-cell cytotoxic CD8-positive lymphoma (CTCL).

✉ Conclusions

In this case, clinical, histological and phenotypical findings suggested a rare particular variant of mycosis fungoides. The atypical T-cells express intense and diffuse CD3, CD8 and focal CD4. Accurate diagnosis was based on histology and immunochemistry because of the resembles of the clinical findings with other skin lesions: Bowen's disease, extramammary Paget's disease, psoriasis with single lesion, and chronic eczema. The target treatment is surgical excision with long follow up. In cases with a short history, long-term follow-up is mandatory to make the differential diagnosis with disseminated Ketron–Goodman type that has a reserved prognosis.

References

- [1] Woringer F, Kolopp P, *Lésion érythémato-squameuse polycyclique de l'avant-bras évoluant depuis 6 ans chez un garçonnet de 13 ans: histologiquement infiltrat intraépidermique d'apparence tumorale*, Ann Dermatol Venereol, 1939, 10:945–948.
- [2] Braun-Falco O, Marghescu S, Wolf HH, *Pagetoid reticulosis (Morbus Woringer–Kolopp)*, Hautarzt, 1973, 24(1):11–21.
- [3] Luther H, Bacharach-Buhles M, Schultz-Ehrenburg U, Altmeyer P, *Pagetoid reticulosis of the Ketron–Goodman type*, Hautarzt, 1989, 40(8):530–535.
- [4] Jaffe ES, Lee Harris N, Stein H, Vardiman JW (eds), *Pathology and genetics of tumours of haematopoietic and lymphoid tissues*, World Health Organization (WHO) Classification of Tumours, IARC Press, Lyon, 2001.
- [5] Swerdlow SH, Campo E, Lee Harris N, Jaffe ES, Pileri SA, Stein H, Thiele J, Vardiman JW (eds), *Pathology and genetics of tumours of haematopoietic and lymphoid tissues*, World Health Organization (WHO) Classification of Tumours, IARC Press, Lyon, 2008.
- [6] Willemze R, Kerl H, Sterry W, Berti E, Cerroni L, Chimenti S, Diaz-Peréz JL, Geerts ML, Goos M, Knobler R, Ralfkiaer E, Santucci M, Smith N, Wechsler J, van Vloten WA, Meijer CJ, *EORTC classification for primary cutaneous lymphomas: a proposal from the Cutaneous Lymphoma Study Group of the European Organization for Research and Treatment of Cancer*, Blood, 1997, 90(1):354–371.
- [7] Bologna JL, Jorizzo JL, Schaffer JV, *Dermatology*, vol. II, 3rd edition, 2012, Elsevier–Saunders, 1973–1974.
- [8] Matsuzaki Y, Kimura K, Nakano H, Hanada K, Sawamura D, *Localized pagetoid reticulosis (Woringer–Kolopp disease) in early childhood*, J Am Acad Dermatol, 2009, 61(1):120–123.
- [9] Ahn CS, ALSayyah A, Sangüeza OP, *Mycosis fungoides: an updated review of clinicopathologic variants*, Am J Dermatopathol, 2014, 36(12):933–951.
- [10] Fernandez-Flores A, *Cutaneous MALT-lymphoma: from cutaneous immunocytoma and pseudolymphoma to the current (and future) conceptions*, Rom J Morphol Embryol, 2013, 54(1):7–12.
- [11] Suzaki R, Kobayashi K, Ishizaki S, Fujibayashi M, Tanaka M, *Dermoscopic features of CD8-positive solitary pagetoid reticulosis on the left leg*, Dermatol Res Pract, 2010, 2010:850416.
- [12] Yao Y, Mark LA, *Woringer–Kolopp disease mimicking foot dermatitis*, Cutis, 2012, 90(6):307–309, 316.
- [13] Martin SJ, Cohen PR, Cho-Vega JH, Tschen JA, *CD8+ pagetoid reticulosis presenting as a solitary foot plaque in a young woman*, J Clin Aesthet Dermatol, 2010, 3(10):46–49.
- [14] Grubb B, Henderson DB, Pandya AG, *Adult T-cell lymphoma/leukemia presenting as pagetoid reticulosis of the palms and soles*, J Am Acad Dermatol, 2011, 65(5):1063–1064.
- [15] Cho-Vega JH, Tschen JA, Duvic M, Vega F, *Early-stage mycosis fungoides variants: case-based review*, Ann Diagn Pathol, 2010, 14(5):369–385.
- [16] Jacyk WK, Grayson W, Dinkel JE, Requena L, *Pagetoid reticulosis with CD30 positivity and cytotoxic/suppressor cells*, J Cutan Pathol, 2007, 34(8):644–647.
- [17] Mourtzinou N, Puri PK, Wang G, Liu ML, *CD4/CD8 double negative pagetoid reticulosis: a case report and literature review*, J Cutan Pathol, 2010, 37(4):491–496.
- [18] Lee J, Viakhireva N, Cesca C, Lee P, Kohler S, Hoppe RT, Kim YH, *Clinicopathologic features and treatment outcomes in Woringer–Kolopp disease*, J Am Acad Dermatol, 2008, 59(4):706–712.
- [19] Wang T, Liu YH, Zheng HY, *Localized pagetoid reticulosis (Woringer–Kolopp disease) completely response to NB-UVB combined with IFN*, Dermatol Ther, 2014, 27(4):227–229.
- [20] Mendese GW, Beckford A, Krejci N, Mahalingam M, Goldberg L, Gilchrist BA, *Pagetoid reticulosis in a prepubescent boy successfully treated with photodynamic therapy*, Clin Exp Dermatol, 2012, 37(7):759–761.
- [21] Mount C, Ferraro D, Gru A, Bradbury M, Cornelius L, Gay H, *Treatment of pagetoid reticulosis with intensity modulated radiation therapy*, Dermatol Online J, 2014, 20(10).
- [22] Su O, Dizman D, Onsun N, Bahali AG, Biyik Ozkaya D, Tosuner Z, Demirkesen C, *Treatment of localized pagetoid reticulosis with imiquimod: a case report and literature review*, J Eur Acad Dermatol Venereol, 2014, Sep 26.
- [23] Schmitz L, Bierhoff E, Dirschka T, *Alitretinoin: an effective treatment option for pagetoid reticulosis*, J Dtsch Dermatol Ges, 2013, 11(12):1194–1195.
- [24] Skiljevic D, Bogdanovic Z, Vesic S, Vukicevic-Sretenovic J, Gajic-Veljcic M, Medenica L, *Pagetoid reticulosis of Woringer–Kolopp*, Dermatol Online J, 2008, 14(1):18.
- [25] Burns MK, Chan LS, Cooper KD, *Woringer–Kolopp disease (localized pagetoid reticulosis) or unilesional mycosis fungoides? An analysis of eight cases with benign disease*, Arch Dermatol, 1995, 131(3):325–329.
- [26] Nakada T, Sueki H, Iijima M, *Disseminated pagetoid reticulosis (Ketron–Goodman disease): six-year follow-up*, J Am Acad Dermatol, 2002, 47(2 Suppl):S183–S186.

Corresponding author

Maria Rotaru, Associate Professor, MD, PhD, Chief of the Department of Dermatology, “Victor Papilian” Faculty of Medicine, “Lucian Blaga” University of Sibiu, 2–4 Corneliu Coposu Avenue, 550245 Sibiu, Romania; Phone +40724–307 495, Fax +40269–235 336, e-mail: mrotaru07@gmail.com