

# Preauricular lymphadenopathy in a pediatric patient: A diagnostic pitfall

Doina Anca Plesca<sup>1,2</sup>, Teodora Jescu<sup>1</sup>, Andrei Zamfirescu<sup>1,2</sup>, Cristian Soreanu<sup>3</sup>,  
Carmen Ardeleanu<sup>4</sup>, Codruta Comsa<sup>5</sup>, Iulia Tincu<sup>1,2</sup>

<sup>1</sup>Department of Pediatrics, Faculty of Medicine, "Carol Davila" University of Medicine and Pharmacy, Bucharest, Romania

<sup>2</sup>Department of Pediatrics, "Victor Gomoiu" Clinical Children's Hospital, Bucharest, Romania

<sup>3</sup>Otolaryngology Department, "Victor Gomoiu" Clinical Children's Hospital, Bucharest, Romania

<sup>4</sup>Onco Team Diagnostic, Bucharest, Romania

<sup>5</sup>Department of Pediatric Oncology, Oncological Institute Bucharest, Romania

## ABSTRACT

The authors present the case of a 1 year and 7 months old girl, with no medical history, initially diagnosed with left preauricular adenopathy, which increased in volume progressively, despite 12 days of antibiotic therapy. This report presents the causes of laterocervical adenopathy and the main tumor etiologies with preauricular and parotid localization. The clinical case presented a challenge in clarifying the final diagnosis – high-risk embryonal rhabdomyosarcoma.

**Keywords:** adenopathy, rhabdomyosarcoma, child

## Abbreviations

RMS – rhabdomyosarcoma

ERMS – embryonal rhabdomyosarcoma

CT – computer tomography

MRI – magnetic resonance imaging

## GENERAL DATA

Swollen lymph nodes are usually due to lymphocyte proliferation either in response to infection, lymphoproliferative disorders or as consequence of malignant cell infiltration. Infections are the most common cause of swollen lymph nodes in children (1). Generalized adenopathy involves swollen of at least 2 lymph nodes in different anatomical regions and is caused by different etiologies: infectious diseases (viral, bacterial, fungal infections, tuberculosis etc.), neoplastic diseases (leukemias, lymphomas etc.), connective tissue diseases (juvenile chronic arthritis – systemic form). Localized adenopathy is the result of a limited infection involving one lymph node and/or its drainage area. In acute infection ad-

enopathy may be painful and accompanied by Celsian signs (hyperemia, local warmth in the overlying tegument). These signs are absent in case of chronic infection. The presence of fixed, firm adenopathy should raise the suspicion of neoplastic infiltration, regardless of other changes on clinical examination. Neoplastic lymphadenopathy lasts more than 14 days and may be accompanied by symptoms caused by local extension (dysphagia/dysphonia) or systemic signs (weight loss, fever, night sweats) (2). Ultrasonography is an important imaging method to determine the number, character and size of affected lymph nodes and is helpful for all stages of patient assessment: diagnosis, therapy monitoring and post-therapy follow-up (3).

Corresponding author:

Doina Anca Plesca

E-mail: doina.plesca@umfcd.ro

Article History:

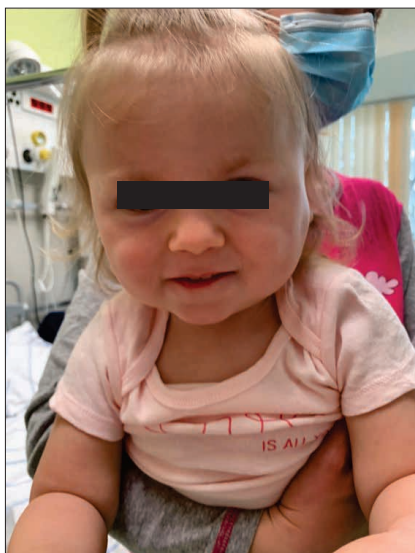Received: 25 November 2021

Accepted: 6 December 2021

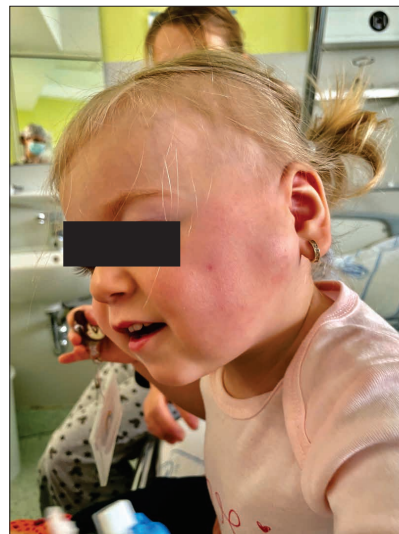## CASE PRESENTATION

S.T. is a 1 year and 7 months old preschool girl, admitted to our clinic for investigation of a left preauricular adenopathy. Patient's mother noticed the appearance of left preauricular swelling 2 weeks prior admission, at that time it was approximately 0.5 cm. The patient was evaluated as an outpatient, had a complete blood count (normal) and otolaryngology evaluation and was diagnosed with acute pharyngitis and left preauricular adenopathy and received oral antibiotic (Azithromycin) for 5 days. The tumor grew despite antibiotic treatment. She underwent an outpatient otolaryngology consultation, and the tumor was found to be progressively increasing in size and it was decided to continue the antibiotic therapy for 7 days, with Cefuroxime per os. She received another recommendation of Amoxicillin + Clavulanic acid for another 7 days, but after 2 days of treatment, the girl was brought to the Emergency Room of the Children's Clinical Hospital "Dr. Victor Gomoiu", and the oncall pediatrician decided to admit her to the Paediatric Department 1 for further investigations.

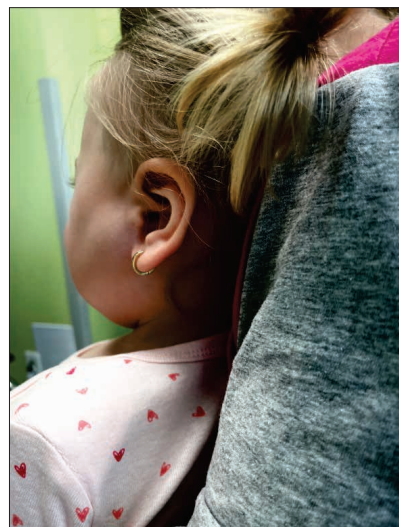On admission, the girl was in a satisfactory general condition, afebrile, with pale skin, left preauricular swelling, round-oval, of increased consistency, adherent to the deeper tissues, without local signs of hyperemia, apparently tender on palpation, approximately 4/4 cm in diameter, which caused an asymmetrical appearance of the facies (Fig. 1, 2, 3). In addition, the clinical examination also unveiled the presence of bilaterally localized latero-cervical micro adenopathy, minimal pharyngeal hyperemia, apparently the left tonsil was larger than the right one. Otherwise, clinical examination was unremarkable. Family medical history revealed that our patient paternal uncle was diagnosed with unspecific thoracic tumor (without medical documents) and paternal grandmother died because of a neoplasia.



**FIGURE 1.** Left preauricular formation that determines the asymmetry of the facies (face)



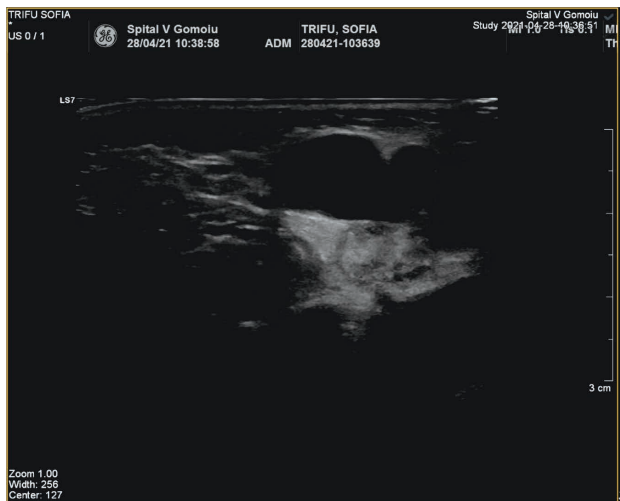
**FIGURE 2.** Left preauricular formation with approximate dimensions of 4/4 cm (profile)



**FIGURE 3.** Left preauricular formation, photographed latero-posteriorly

CBC, reticulocytes, coagulation tests, liver and kidney function, LDH, serum amylase were normal, negative inflammatory markers, heterophile antibodies, cytomegalovirus IgM and IgG antibodies, Epstein-Barr virus IgM and IgG antibodies, HIV antibodies, QuantiFERON TB test was negative and some imaging investigations (abdominal and lung ultrasound) were within normal limits. Soft tissue ultrasonography identified a polylobular, non-homogeneous, relatively well defined, ~40/45 mm sized, tumor mass in the left parotid lobe with necrotic tissue and several small vascular tracts; associated with a ~20/15 mm retroangulomandibular adenopathic block (Fig. 4).

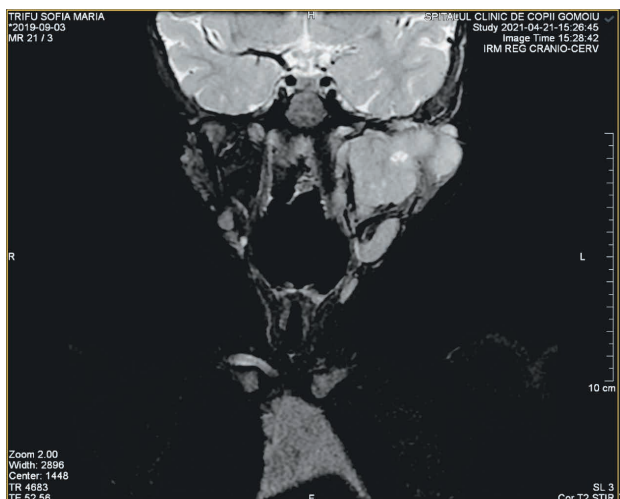
MRI describes a 53/41/30 mm space-occupying, polylobed tumor, with nonhomogeneous signal, developed in the left parotid gland, extending towards the base of the skull, reaching the left parapharyngeal space, with slight pharyngeal impression (Fig. 5). After contrast administration, the formation shows nonhomogeneous contrast uptake, more intense in the anterobasal and deep marginal portion. In the



**FIGURE 4.** Ultrasonography of soft parts: at the level of the left parotid lodge, the presence of a tumor mass with dimensions of ~ 40/45 mm is identified

posterior part of the gland there were identified patches of nonhomogeneous glandular tissue. The lesion had posterior contact with the internal carotid artery on the same side and anterior with the facial branch. There also described adenopathy in the mid cervical compartment, ellipsoid, infracentimetric in short axis, with gadolinium enhancement, of homogeneous aspect and with tendency to conflate, descending below the sternocleidomastoid muscle to C4 level. On the right side there were infracentimetric lymph nodes with the same disposition.

An incisional biopsy of the left parotid formation was performed to complete the diagnosis. The anatomopathological examination identified fibroconnective tissue with undifferentiated malignant tumor infiltration with small hyperchromatic cells and diffuse pattern of proliferation. Marginal serous salivary gland tissue and small lymph node



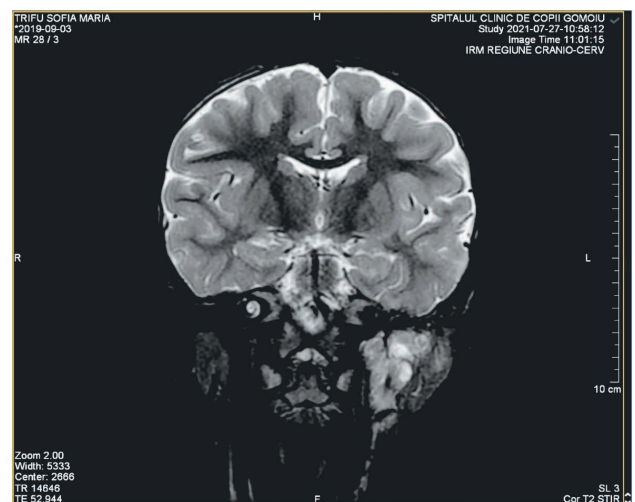
**FIGURE 5.** Magnetic resonance imaging of the head: at the level of the left parotid gland - polylobed formation, with dimensions 53/41/30 mm

with reactive appearance. IHC: VIM positive in tumor cells, membranous and golgian, AE1-AE3 negative, CD99 negative, CD3 positive in vessels, negative in tumor cells, CD45 positive in lymphoid elements in lymph node, positive in scattered lymphocytes, S100 negative in tumor cells, desmin diffusely positive, predominantly with golgian pattern MyoD1 nuclear positive in tumor cells, Ki67 positive 80-90%. Finally, the diagnosis of embryonal rhabdomyosarcoma was affirmed.

The patient was transferred to the Pediatric Oncology Clinic – Bucharest Oncology Institute. To complete the diagnosis and establish the therapeutic management, the patient underwent a chest CT (no secondary pulmonary determinations were identified), bone marrow biopsy (no atypical cells with neoplastic characters on the fields examined), bone scintigraphy (normal radiotracer uptake) and 18FDG PET-CT - whole body PET (basal skull lesion - left parapharyngeal space - and bilateral cervical adenopathy with increased metabolic activity), thus giving the diagnosis of high-risk non-metastatic embryonal rhabdomyosarcoma.

The therapeutic protocol included 3 courses of chemotherapy (Vincristine, Isophosphamide, Adriamycin, Mesna, Actinomycin) and Filgrastim administered prophylactically, which resulted in significant clinical remission of the tumor in the left parotid. 3 months after the final diagnosis and initiation of chemotherapy, the patient is MRI re-evaluated: same space-occupying, hypercellular tumor developed in the left parotid gland, with extension to the base of the skull, in slight dimensional regression – 45/32/30 mm, left latero-cervical adenopathy in numerical regression (Fig. 6).

After five months from diagnosis, the excision of the left parapharyngeal tumor and of the lymph node (from both sides) was performed. The anatom-



**FIGURE 6.** Magnetic resonance imaging of the head at an interval of 3 months: the same formation developed at the level of the left parotid, in slight dimensional regression - 45/32/30 mm

ical specimens were sent for a new pathology examination.

## DISCUSSIONS

Enlarged lymph nodes are frequently found mainly due to local inflammatory process caused by reactive hyperplasia of the lymphatic tissue. In children, compared to the adult population, the differential diagnosis of persistent cervical localized lymphadenopathy is different due to the increased incidence of malformations that can be identified at this age or infectious (acute tonsillitis, acute otitis media, tuberculosis, rubella, mononucleosis, epidemic parotitis etc.) extremely common in the pediatric population. It should be noted that malignant tumors with preauricular, cervical location in this age group are extremely rare (3). Preauricular adenopathy is common in the following circumstances: ocular infections (e.g. conjunctivitis), acute otitis media, facial cellulitis, salivary gland infection, but also in viral infections (e.g. rubella, parvovirus) (2).

Given the anatomical location of the parotid gland, tumors at this level can lead to confusion between gland injury and inflammatory preauricular adenopathy. Parotid lesions can be divided into benign or malignant. The age of the patient helps to guide the differential diagnosis towards vascular and/or congenital lesions, the latter being more common in the first year of life, and solid tumors are more common in older children. An inflammatory condition usually has an acute onset compared to neoplastic processes or congenital malformations, which have a slowly progressive course. Imaging techniques such as soft tissue ultrasound, computer tomography and MRI are used to investigate the parotid region. Ultrasound is used as the first line to identify the morphology and vascularity of these lesions. To evaluate a parotid abscess or duct lithiasis, CT is used and MRI is useful to investigate the type and extension of the lesion (4).

Differential diagnosis of a parotid tumor includes exophytic tumor of the mandible, odontogenic cysts, giant cell granulomas. Less common differential diagnoses are ossifying fibromas, Paget's disease, fibrous dysplasia and other benign and malignant neoplasms (5).

Studies over the years have shown that approximately 50% of children diagnosed with soft tissue sarcoma had rhabdomyosarcoma (RMS). This is a high-grade malignant tumour with a tendency to myogenic differentiation. There are two major subtypes of RMS (,alveolar' RMS and ,embryonal' RMS), which have different mechanisms of occurrence. Both subtypes present evolutionary challenges. Curative treatment involves control of the primary tumour by surgical resection and/or ionising radia-

tion and eradication of systemic metastatic disease using intensive chemotherapy (6).

Most cases of soft-tissue sarcoma occur sporadically, but up to 30% may have a risk factor such as: Hep53 suppressor gene end line mutations (there is an association between early onset breast cancer, sarcomas, brain tumours and adrenal cortical tumours in family members), ionizing radiation, neurofibromatosis type 1 (these patients have up to 15% lifetime risk of developing peripheral nerve sheath neoplasm), DICER1 gene mutation (associated with familial pleuropulmonary blastoma, increases risk of other tumors in children including ERMS), parental substance abuse such as marijuana and cocaine and also prenatal radiation exposure in the first trimester are considered environmental risk factors for ERMS (7), ERMS may associate Li-Fraumeni syndrome and p53 gene mutation, which is characterized by high incidence of soft tissue sarcoma, bone sarcoma, leukemia, brain tumors, adrenal gland tumors and breast cancer in perimenopause (8).

RMS can occur in any anatomical region of the body which consists in skeletal muscle tissue, but also in the urinary bladder and common biliary duct. In pediatric patients under 10 years old, RMS is most frequent in head and neck region and also in genitourinary system. RMS localization in teenage pediatric patients involves commonly limbs, torso and paratesticular region.

In 40% of cases, primary localization on RMS involves head and neck region. In 25% of cases, they are parameningeal rhabdomyosarcomas (localized in nasopharynx, middle ear, paranasal sinuses, infratemporal and pterygopalatine fossae), 8% are orbital rhabdomyosarcoma and 7% have non-orbital localization (oropharynx, larynx, parotid salivary gland, scalp or cheek). In 29 percent of cases RMS has genitourinary localization: paratesticular, urinary bladder, prostate, vagina or uterus.

Clinical manifestations vary depending on tumor localization and local invasion. In most cases, initial manifestation soft tissue sarcoma is non-painful lump. In table 1 we enlist the signs and symptoms which may uncover RMS.

RMS diagnosis is based upon clinical history, clinical examination, lab results, imaging and biopsy and pathology exam of the biopsy tissue. During admission we performed CBC, chemistry panel for renal and hepatic function, LDH (this enzyme has increased values in most types of cancer and may be useful to evaluate treatment response or disease progression), soft tissue ultrasound and MRI scan (to evaluate the tumor), CT scan of the thoracic cavity (in order to identify metastatic cancer, especially in the lung), FDG-PET-CT scan (to assess the primary disease and presumed metastasis; it also can evalu-

**TABLE 1.** Signs and symptoms in rhabdomyosarcoma according to anatomical location – adapted after (7)

Location	Signs and symptoms
<i>Head and neck</i>	
Neck	Soft tissue tumour formation, dysphagia
Nasopharynx	Sinusitis, local oedema/pain, epistaxis
Orbit	Proptosis, ocular paralysis, conjunctival mass
Middle ear/ Mastoid	Peripheral facial nerve palsy, Chronic otitis media with purulent otitis or otorrhea
Paranasal sinuses	Sinusitis, sinus obstruction, epistaxis
<i>Genito-urinary</i>	
Vagina and uterus	Vaginal bleeding
Prostate	Haematuria, constipation, urinary tract obstruction
Urinary bladder	Urinary tract obstruction, haematuria, tumour torsion, recurrent urinary tract infections

ate post-treatment response), bilateral bone marrow biopsy (unnecessary in non-invading tumors, no lymph node involvement or in invasive ERMS with no signs of cancer extension in thoracic CT scan). Biopsy and pathology exam were the key elements for the final diagnosis. One can practice excisional, incisional or even percutaneous parotid gland biopsy, but the gold standard consists in incisional biopsy. Clinicians can also practice biopsy of suspicious lymph nodes. RMS staging is essential in order to establish elective treatment: systemic or/and local therapy (7).

Invasive RMS usually affects close range lymph nodes, lungs, cortical bone and bone marrow. Therefore, initial staging of RMS includes thoracic CT scan in order to identify lung involvement, bone scintigraphy to detect bone metastasis and also bone marrow biopsy. RMS usually has a reduced incidence of metastasis. The therapy of RMS is individualized according to the stage, considering that lymph node invasion, tumor local invasion and histologic category are the most important predictors for metastatic cancer.

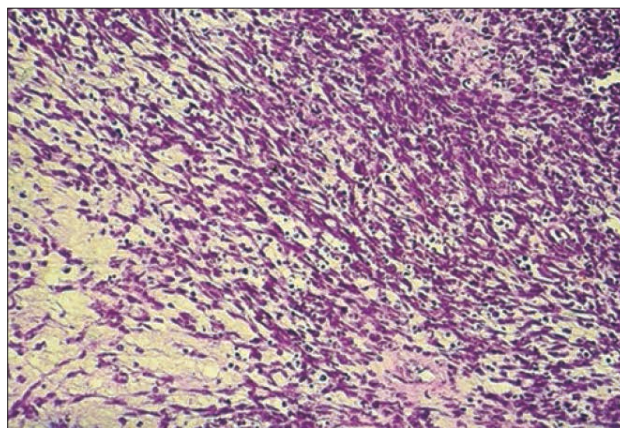
Intergroup Rhabdomyosarcoma Study Group and Children's Oncology Group published in 2013 a retrospective study form 13 years of data collection (1991-1997, 1999-2004), of 1,687 patients: 5.7% had lung metastatic cancer, 4.8% had secondary bone cancer and 6% had secondary bone marrow invasion. T1 ERMS without local invasion had low metastasis rate (no cases of invasion of bone or bone marrow). However, T2 ERMS had 9% incidence of pulmonary metastasis (9).

Microscopically, ESMR shows heterogeneous-appearing rhabdomyoblasts (Fig. 7) (10). In regions of low cell density are common round, undeveloped cells, with a hyperchromatic nucleus and basophilic cytoplasm, in a myxoid submucosa. Regions of high

cell concentration are present around vessels and are organized in characteristic perivascular thickenings. In association with poorly differentiated cells, better differentiated rhabdomyomas are frequently observed showing acidophilic cytoplasm, sometimes with cross-striation. In most cases, the histology of ESMR resembles a combination of the stages of striated muscle embryonic development: from small, round, undifferentiated cells, to elongated, ribbon-shaped striated cells, to fully differentiated rhabdomyoblasts (11).

The treatment of rhabdomyosarcoma is based on determining the specific risk of each patient according to histological classification, pre-surgical stage and post-surgical evolution. Therapeutic steps include: surgical ablation, chemotherapy and radiotherapy. Local treatment is a decisive part of the management of rhabdomyosarcoma; however, the advantages and disadvantages of radical surgery and/or radiotherapy should be considered. In the last decade there has been an improvement in patient outcomes as a result of multimodal therapeutic protocols.

There are two main chemotherapy regimens used in the treatment of rhabdomyosarcoma: the VAC regimen (Vincristine, Actinomycin D and Cyclophosphamide) and the IVA regimen (Ifosfamide, Vincristine and Actinomycin D). These regimens are given in up to 15 cycles, depending on the stage of the disease. Ionizing radiation therapy has proven to be an important tool in lowering disease recurrence rates and is mainly used to complement patient management, especially when complete resection is not possible. Treatment of patients with rhabdomyosarcoma is continually evolving as new evidence-based results emerge from clinical trials (9). Overall, patients with RMS have a 5-year survival rate of approximately 70%. Local treatment

**FIGURE 7.** Anatomic-pathological examination: microscopic appearance of embryonic rhabdomyosarcoma – fibroconjunctival tissue with undifferentiated malignant tumor infiltration, with small hyperchromatic cells and diffuse proliferation pattern (10)

failure in patients with non-metastatic ESMR is frequently reported (7).

Complete local control has been defined as complete remission or stationary residual mass for more than 6 months after completing therapy. Relapse corresponded to local, regional or metastatic disease recurrence after complete local control. Because no specific treatment guidelines have been defined for relapsed RMS, the usual recommendations included a complete new radiological, clinical and laboratory evaluation similar to that performed at diagnosis.

## CONCLUSIONS

In unilateral preauricular adenopathy that is progressively increasing in size, the differential diagnosis should include a possible tumor. ESMR is a

solid neoplasm, frequently localized in the head, neck, orbit and genitourinary tract. It can occur in pediatric patients, most often at ages between 3 to 12 years. It may appear as a solid, hard, palpable, painless mass.

One particularity of the case diagnosed in our clinic is that the patient was only 1 year and 7 months old by the time we established the diagnosis of parotid gland ESMR. Furthermore, the patient presented minimal symptomatology and maintained a very good general condition, in spite of a severe life-threatening condition.

The evolution of the case will depend on the efficiency of a multidisciplinary team (consisting of pediatrician, pediatric oncologist, surgeon, radiologist, radiotherapist), which will ensure continuous monitoring and effective therapeutic intervention.

*Conflict of interest:* none declared

*Financial support:* none declared

## REFERENCES

1. Nield LS, Kamat D. Lymphadenopathy in children: when and how to evaluate. *Clin Pediatr (Phila)*. 2004 Jan-Feb;43(1):25-33.
2. Richard L, Tower II, Bruce M, Camitta, Lymphadenopathy. In: Kliegman R, Geme J, Blum N, et al. *Nelson's textbook of pediatrics* 21st ed. Philadelphia, Elsevier, 2020:10336-10338.
3. Niedzielska G, Kotowski M, Niedzielski A, Dybiec E, Wiczorek P. Cervical lymphadenopathy in children--incidence and diagnostic management. *Int J Pediatr Otorhinolaryngol*. 2007 Jan;71(1):51-6.
4. Inarejos Clemente EJ, Navallas M, Tolend M, Suñol Capella M, Rubio-Palau J, Albert Cazalla A, Rebollo Polo M. Imaging Evaluation of Pediatric Parotid Gland Abnormalities. *Radiographics*. 2018 Sep-Oct; 38(5):1552-1575.
5. Ihbe J, Stoll C, Liede A, et al. Tumor der Regio parotidea bei einem Kind. *Laryngo-Rhino-Otologie*. 2015;94(9):611-612.
6. Skapek SX, Ferrari A, Gupta AA, Lupo PJ, Butler E, Shipley J, Barr FG, Hawkins DS. Rhabdomyosarcoma. *Nat Rev Dis Primers*. 2019 Jan 7; 5(1):1.
7. Levy CF, Wexler LH. Rhabdomyosarcoma and Other Soft-Tissue Sarcomas. In: Lanzkowsky P, Lipton J, Fish J. *Lanzkowsky's manual of pediatric hematology and oncology*, 6th ed. Academic Press – Elsevier, 2016:505-523.
8. Magnusson S, Gisselsson D, Wiebe T, Kristofferson U, Borg Å, Olsson H. Prevalence of germline TP53 mutations and history of Li-Fraumeni syndrome in families with childhood adrenocortical tumors, choroid plexus tumors, and rhabdomyosarcoma: a population-based survey. *Pediatr Blood Cancer*. 2012 Nov;59(5):846-53.
9. Weiss AR, Lyden ER, Anderson JR, Hawkins DS, Spunt SL, et al. Histologic and clinical characteristics can guide staging evaluations for children and adolescents with rhabdomyosarcoma: a report from the Children's Oncology Group Soft Tissue Sarcoma Committee. *J Clin Oncol*. 2013 Sep 10;31(26):3226-32.
10. Parham DM. Pathologic classification of rhabdomyosarcomas and correlations with molecular studies. *Mod Pathol*. 2001 May; 14(5):506-14.
11. Dziuba I, Kurzawa P, Dopierata M, Larque AB, Januszkiewicz-Lewandowska D. Rhabdomyosarcoma in children - current pathologic and molecular classification. *Pol J Pathol*. 2018;69(1):20-32.