

# Equine Laparoscopy: Gonadectomy

John P. Caron, DVM  
Michigan State University

**For more information, please see the companion articles: "Equine Laparoscopy: Equipment and Basic Principles" (March 2012), "Equine Laparoscopy: Abdominal Access Techniques" (November 2012), and "Equine Laparoscopy: Hemostasis" (December 2012).**

Laparoscopic removal of the gonads from male and female horses is regularly performed for a variety of reasons. In female horses, common indications for ovariectomy include behavioral problems and signs of abdominal pain that are linked to estrus. Another indication is an abnormal, enlarged ovary, typically due to ovarian neoplasia, the most common being granulosa thecal cell tumor. Ovariectomy is also a treatment option for ovarian hematomas and other abnormalities. In addition, ovariectomy is used to sterilize mares intended for artificial insemination or embryo transfer programs.

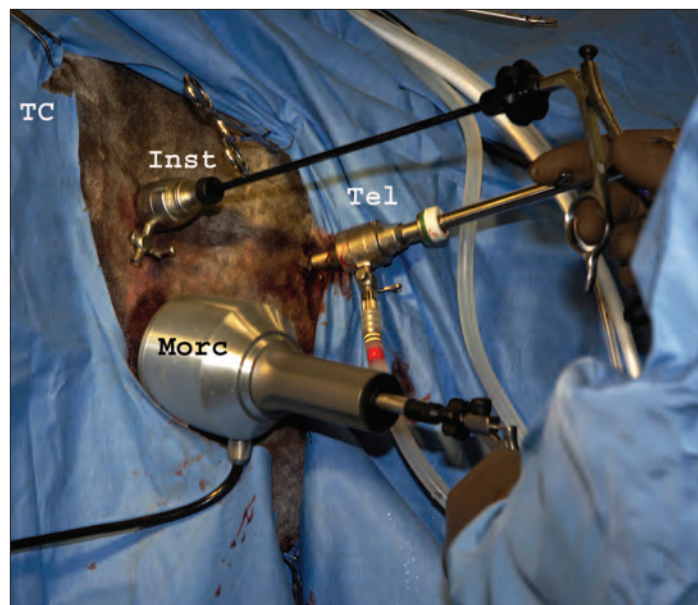
The main reason for laparoscopic gonadectomy in male horses is the removal of cryptorchid testicles. Cryptorchidism is often considered a heritable trait, although this is not universally acknowledged.<sup>1</sup> Authors have suggested dominant and recessive patterns of inheritance, although the supportive evidence is limited. Regardless of the specific etiology, cryptorchid horses are generally considered genetically unsound and are, therefore, usually castrated.

In the past, cryptorchidectomy and ovariectomy were performed using various surgical approaches. The principles, general techniques, and benefits of laparoscopic gonadectomy in male and female horses are very similar. The advantages of laparoscopic techniques for gonadectomy are also comparable, generally paralleling those for any laparoscopic surgery. The advantages over traditional surgery include more thorough inspection of the surgical field, smaller incisions (which usually have a superior cosmetic result), tension-free hemostasis ensured by direct observation, and shorter convalescence.

## Patient Preparation

The basic considerations for patient evaluation and preoperative preparation are similar for laparoscopic ovariectomy and cryptorchidectomy. Preoperative evaluation includes assessing the patient's general condition and suitability for sedation or anesthesia and surgery in addition to ruling out concomitant conditions. Although not a strict requirement, obtaining a complete blood count and a chemistry panel before surgery is common. Preoperative fasting to reduce intestinal content is recommended regardless of whether

the patient will be standing, sedated, or anesthetized during the procedure. The duration of preoperative fasting depends on the clinician's preference; I consider 15 hours adequate in most cases. Longer periods of feed restriction for standing ovariectomy/cryptorchidectomy and recumbent cryptorchidectomy (e.g., 24 to 36 hours) are common; however, longer periods are often not necessary and the associated stress can have deleterious effects. A rare exception is when a mare requires general anesthesia for bilateral ovariectomy: a fasting period of 36 to 48 hours is necessary to sufficiently reduce colonic content in order to access the ovaries. While these are technically clean procedures, many clinicians administer perioperative antimicrobials, often limited to a single preoperative dose. Perioperative analgesia using NSAIDs often suffices, with the first dose frequently given orally 12 hours preoperatively. For ovariectomy, I supplement NSAID administration with a preoperative epidural using morphine (0.2 mg/kg) and detomidine (10 µg/kg).

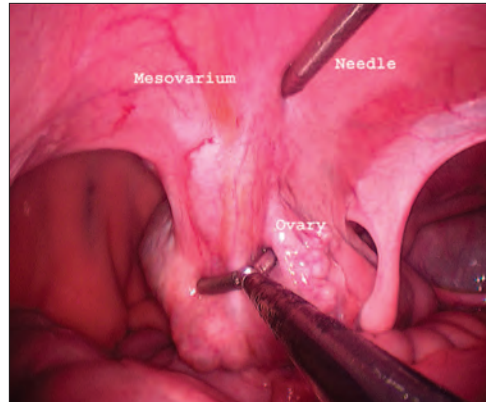


**Figure 1.** Typical portal arrangement for laparoscopic gonadectomy in standing, sedated horses. For this ovariectomy, the approach is from the right side. The telescope portal (*Tel*) is in the 17th intercostal space, below the level of the ventral limit of the tuber coxa (*TC*). Paired instrument portals for a grasping instrument (*Inst*) and a morcellator (*Morc*) are located in the paralumbar fossa.

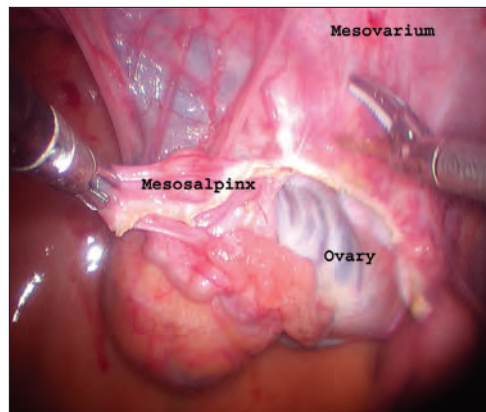
**Ovariectomy**

While removal of normal or pathologic ovaries has been described in anesthetized, dorsally recumbent mares, this practice has been largely superseded by techniques performed on standing, sedated mares. Mares are confined in treatment stocks with cross-ties. A convenient protocol for sedation is an intravenous loading dose of 3 µg/kg of detomidine followed by a continuous intravenous infusion (12 mg of detomidine diluted in 250 mL of sterile polyionic fluid) given to effect. Sedation using this protocol is considerable; the use of a well-padded halter minimizes the risk of facial neuropathy. One or both flanks are clipped and prepared (depending on whether one or both ovaries will be removed) in a conventional fashion. Local anesthesia delivered by injections at the intended portal sites is convenient and effective.

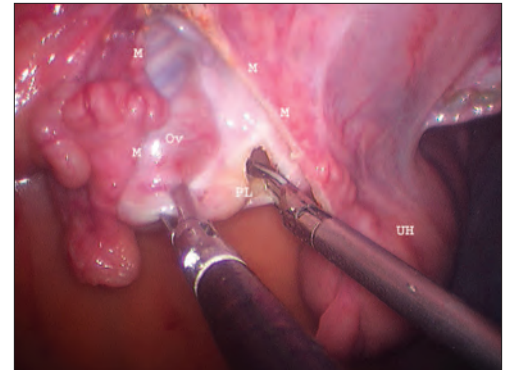
Typically, ovariectomy is performed using a three-portal technique (one telescope and two instrument portals), which is duplicated on the opposite side of the mare to remove the other ovary. Several different topographic arrangements of the portals have been described in the literature.<sup>2</sup> One popular array is a telescope portal located in the center of the paralumbar fossa, immediately dorsal to the crus of the internal abdominal oblique muscle, with instrument portals flanking it. I prefer to use the 17th intercostal space for the telescope portal with a pair of instrument portals in the paralumbar fossa, located to optimize triangulation (FIGURE 1). This is usually accomplished by separating the portals by 6 to 8 cm in the dorsoventral and craniocaudal directions. When bilateral ovariectomy is performed, access is usually obtained on the left side first because inadvertent damage to the spleen is usually of minimal consequence; in contrast, an error during right-sided access could result in damage/perforation of the cecal base. While somewhat less than ideal ergonomically, placing a second instrument portal immediately below the first—separated by a distance that corresponds to the approximate size of the ovary (or ovaries)—is useful, as the two portals can be connected for tissue removal. This portal arrangement is generally necessary only on the right side of the mare when both ovaries will be removed because the left ovary can be passed from one side of the abdomen to the other between the uterine body and urinary bladder. Ulti-



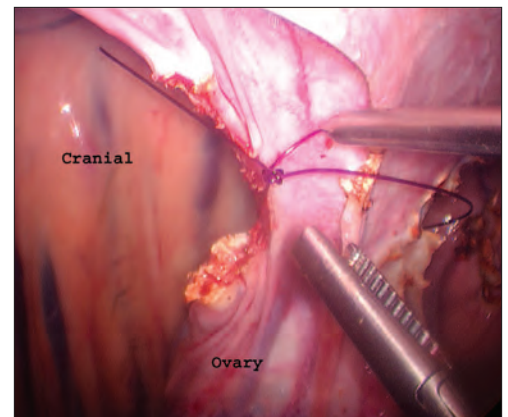
**Figure 2.** The ovary is locally anesthetized by infiltrating the mesovarium at several locations using an endoscopic needle via a portal.



**Figure 3.** The mesosalpinx is dissected from the lateral surface of the ovary to expose the ligament connecting the ovary to the tip of the uterine horn.



**Figure 4.** The proper ligament (PL) is transected, and dissection of the mesovarium (M) continues cranial to create a small pedicle. Ov = ovary; UH = uterine horn.



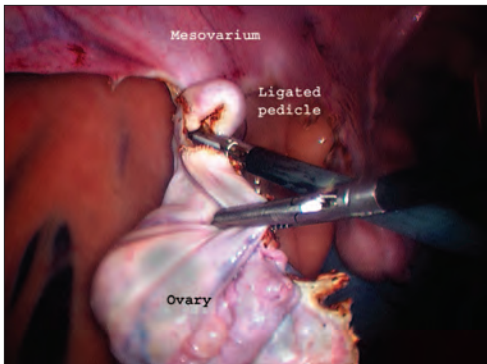
**Figure 5.** A ligating loop is placed around the vascular pedicle of the mesovarium and is tightened. The notch in the cranial mesovarium minimizes the tendency of the loop to slip distally toward the ovary.

mately, portal arrangement is largely a matter of personal preference. (Principles and practices of abdominal access and portal placement were discussed in “Equine Laparoscopy: Equipment and Basic Principles” [March 2012] and “Equine Laparoscopy: Abdominal Access Techniques” [November 2012]).

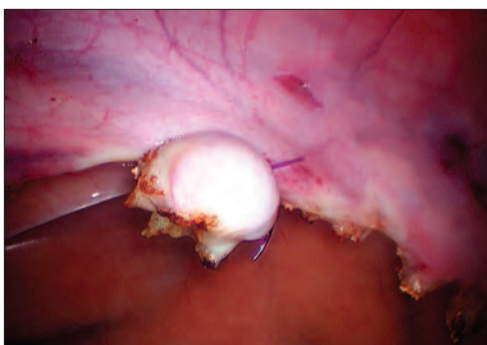
Once access to the abdominal cavity is safely achieved, insufflation with carbon dioxide can be used to augment working space. Pressures of 6 to 10 mm Hg are usually sufficient; however, if the area around the ovary is obscured by other viscera, incremental increases in insufflation pressure (to a maximum of 15 mm Hg) can be helpful.

The mesovarium can be desensitized by using an endoscopic needle to inject 20 to 30 mL of local anesthetic at three to five locations dorsal to the ovary and the tip of the uterine horn (FIGURE 2). Thoroughly desensitizing this area can help when manipulating the ovary and adnexa and can prevent undesired movement by the mare during mesovarial dissection.

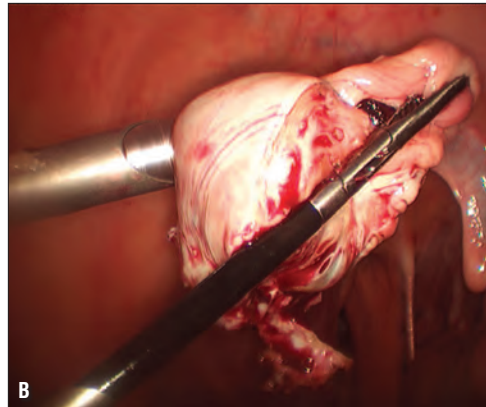
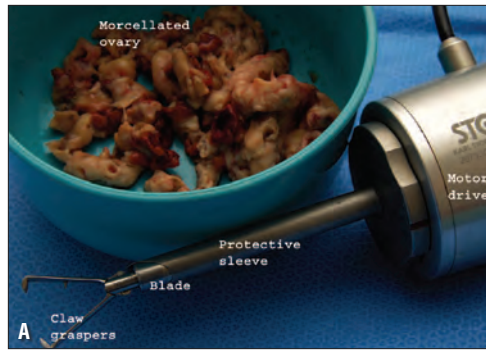
There are several physical and electrosurgical options for simultaneously dissecting an ovary from its mesenteric attachments and controlling hemorrhage (see “Equine Laparoscopy: Hemostasis”).



**Figure 6.** Transection of the ovarian pedicle distal to a previously placed ligature loop.



**Figure 7.** Close-up of the transected vascular pedicle showing excellent hemorrhage control.



**Figure 8.** (A) A morcellator. (B) Use of a morcellator to remove an ovary. The helping instrument is used to position the specimen against the rotating blade of the morcellator.

Mechanical devices such as ligature loops and polyamide ties, combined with cold scissor dissection, are relatively economical. A second, relatively inexpensive method is the combination of scissor dissection and bipolar electrocautery. A more expensive alternative is the use of scissor dissection and endoscopic staples. Currently, the most popular technique involves the use of an advanced bipolar cautery system (LigaSure [Covidien], Enseal [Ethicon]) or electro-mechanical shears (e.g., SonoSurg [Olympus]) for dissection and hemostasis. These two technologies were recently combined in one device (Thunderbeat [Olympus]). Although expensive, these alternatives are convenient because they reduce dissection time and can often be used without supplementary hemostasis. I typically use an ultrasonic dissector with a ligature loop.

Regardless of the method of dissection, the principles are the same. In my opinion, dissection is most easily performed by proceeding from the caudal pole of the ovary and progressing cranially. This approach preserves the normal anatomic position of the ovary throughout dissection. Specifically, the mesosalpinx is elevated from the lateral side of the ovary and dissected cranially to the point at which it fuses with the mesovarium (FIGURE 3). Subsequently, the proper ligament is severed, separating the ovary from the tip of the uterine horn (FIGURE 4). This dissection is continued cranially until a relatively narrow pedicle of mesovarium remains. A small notch created with the dissector in the cranial portion of the mesovarium provides a site for placing a hand-tied ligating loop. The

loop is introduced, placed on the previously dissected mesovarian pedicle, and tightened (FIGURE 5). The remaining mesovarium, containing the principal vasculature of the ovary, can then be transected between the ovary and the ligature while preserving a virtually bloodless field (FIGURE 6). The stump of the mesovarium should be inspected to ensure hemorrhage control (FIGURE 7). For bilateral ovariectomies, the left ovary is typically removed first (because abdominal access is safer on the left side) and passed to the right side of the abdomen using a grasping forceps such as an endoscopic Babcock. The grasping forceps are left in place while the right ovary is amputated in an identical manner. Subsequently, both ovaries are removed from the right side.

Options for removing amputated ovaries are diverse and may depend on the size of the specimens. Although leaving normal ovaries in the abdomen is not common, the associated compli-

cations appear to be minimal.<sup>3</sup> The simplest option for removing one or both ovaries is to connect instrument portal incisions through the skin and the external abdominal oblique fasciae and to complete the small laparotomy using a conventional muscle-splitting, or “grid,” approach. Aggressive grasping forceps (e.g., Ochsner forceps) can be introduced into the abdomen, and the ovary can be grasped and removed through the laparotomy. The size of the incision should be commensurate to the size of the ovary: specimens of up to 40 cm have been removed using a flank approach.<sup>4</sup> The size of the flank incision can be reduced if the resected tissue is placed in a plastic retrieval bag, the open end of which is exteriorized through a small laparotomy incision, and the ovary is cut into small pieces with scissors and/or a scalpel within the bag.<sup>5</sup> A short-term general anesthetic and a ventral midline approach has also been used for removing large neoplastic ovaries. Another elegant, though expensive, alternative is the use of a mechanical morcellator<sup>6</sup> (FIGURE 8A; FIGURE 8B).

## Cryptorchidectomy

Laparoscopic cryptorchidectomy can be performed (1) in horses with a single, normally descended testicle and no external evidence of the presence of a second one, (2) in geldings with stallion-like behavior, and (3) as an exploratory procedure in horses in which surgical exploration could not locate a retained testicle. Laparoscopic cryptorchidectomy can be performed in standing, sedated

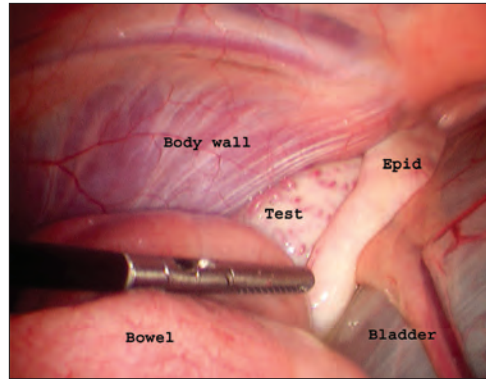
horses using a surgical procedure that very closely parallels the one described above for ovariectomy.<sup>7,8</sup> An alternative is to perform the procedure with the patient under general anesthesia.

## Cryptorchidectomy Using General Anesthesia

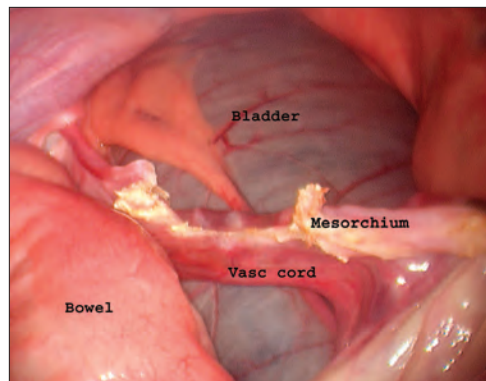
For cryptorchidectomy with the patient under general anesthesia, the horse is anesthetized and placed in dorsal recumbency, and the scrotum and inguinal region are carefully palpated to rule out a small inguinally retained or subcutaneously situated testicle. If a testicle is located, routine castration with or without primary closure can be performed. The ventral abdomen of the horse is clipped and prepared in a routine fashion, and an initial telescope portal can be made immediately cranial to the umbilical scar. (I prefer to use a modified open technique, as outlined in “Equine Laparoscopy: Abdominal Access Techniques” [November 2012].) Once the cannula is safely placed in the abdominal cavity, which can generally be confirmed by direct observation of the abdominal viscera using the telescope, the horse can be repositioned in a 20° to 25° Trendelenburg position while the abdomen is insufflated. Both inguinal ring areas must be inspected to confirm that there are no abnormalities other than the retained testicle. Typically, the testicle is adjacent to the inguinal ring on the side on which it is retained (FIGURE 9). The testicle can often be located without the placement of an instrument portal. Conversely, sometimes the testicle is beneath part of the abdominal viscera in the pelvic area, and an instrument can be introduced to resituate viscera to permit its identification and presentation. With experience, the location of the portals is not critical; for clinicians with less experience, triangulation can be facilitated by placing an instrument portal on either side of the ventral midline approximately 15 cm cranial to the palpable cranial edge of the external inguinal ring and approximately 10 to 15 cm lateral to the ventral midline. Hemostasis of the spermatic cord can be achieved before transection using a two-portal or three-portal technique, as described below.

### The Two-portal Technique

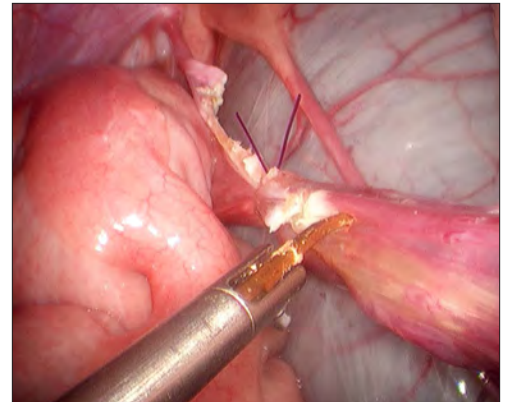
The two-portal technique is essentially cryptorchidectomy using a laparoscopic-assisted, open technique. Once insufflation is



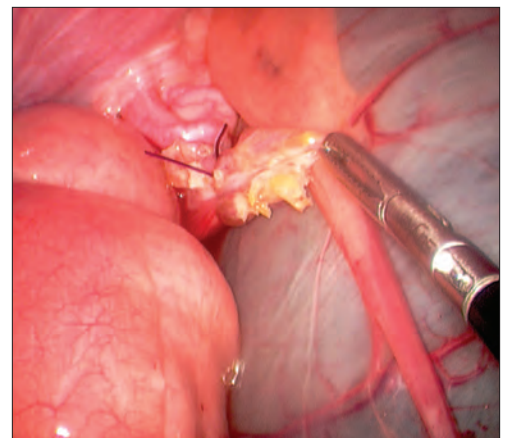
**Figure 9.** Left side of the pelvic canal in a dorsally recumbent cryptorchid horse. A portion of the retained testicle (*Test*) and epididymis (*Epid*) can be seen next to the urinary bladder. This is a relatively common location for retained testicles.



**Figure 10.** Completed dissection of relatively avascular elements of the testicular attachments showing the cut edge of the mesorchium and the intact vascular cord containing the spermatic artery and the pampiniform plexus.



**Figure 11.** Transection of the vascular portion of the spermatic cord, distal to a ligating loop, using ultrasonic shears.



**Figure 12.** A grasping instrument holding a spermatic cord stump to verify adequacy of hemostasis.

satisfactory and the patient is in the Trendelenburg position, the abdominal testicle is identified in the vicinity of the internal inguinal ring. A small parainguinal incision is made, typically craniomedial to the external inguinal ring. Then a laparoscopic grasping forceps is introduced into the abdomen to grasp the testicle and advance it toward the ventral body wall. The incision is enlarged to accommodate the testicle, which is subsequently exteriorized. The spermatic cord is emasculated or ligated and transected extraabdominally. Once hemostasis is ensured, the spermatic cord stump can be returned to the abdomen, the pneumoperitoneum evacuated, the patient returned to a level position, and the incisions closed using conventional means. This method is rapid, requires minimal specialized equipment, and leaves the inguinal ring structures intact.

### The Three-portal Technique

The three-portal technique is incrementally more demanding and time-consuming, involving intraabdominal dissection and hemostasis and typically requiring a second instrument portal. For this technique, the telescope portal is supplemented with two instrument portals positioned to ensure efficient triangulation.

I prefer to place both instrument portals on the side opposite the retained testis, which optimizes ergonomics, and the angle of approach of the instruments facilitates rapid dissection of the spermatic cord structures.

Several options exist for intracorporeal dissection and for hemostasis when three-portal cryptorchidectomy is performed. Hemorrhage control of the spermatic/testicular artery is a strict requirement, and hemostasis of the accompanying capacitance vessels is desired to maintain a clean, visible surgical field. I prefer transection of the nonvascular portion of the spermatic cord (ductus deferens, mesoductus, and mesorchium) using ultrasonic shears (FIGURE 10), followed by placement of a ligating loop on the vascular cord and subsequent distal transection (FIGURE 11). A popular alternative is the exclusive use of conventional laparoscopic monopolar or bipolar electro-surgical instruments or advanced bipolar instruments such as LigaSure. If an electro-surgical generator is not available, an acceptable alternative is to place a ligature loop around the spermatic cord, mesorchium, and ductus deferens and then use endoscopic scissors to sharply transect distal to the ligature. The adequacy of hemostasis should be monitored throughout dissection and transection because, once released, the spermatic cord stump can retract into a pool of peritoneal fluid in the inguinal ring area, complicating control of subsequent hemorrhage (FIGURE 12).

Regardless of the technique employed, it is important to verify that hemostasis is adequate. In bilateral testicular retention, the testicle that has been dissected is placed in the vesicogenital pouch or is left with a forceps attached so that it will not be lost within the abdominal viscera. Once a testicle has been dissected, it can be removed through the ventral midline portal by slightly extending the length of the incision in the linea alba. The small incisions are closed in a routine manner.

### Postoperative Management and Potential Complications

Postoperative care for laparoscopic gonadectomy in horses is usually relatively uncomplicated. The patient is confined to a box stall for 1 or 2 days, during which systemic health and the surgical sites are monitored; afterward, the patient is gradually returned to normal activities. If an unusually large testicle or an intraabdominal teratoma was removed, exercise restriction is extended commensurate with the size and location of the incision for specimen removal to allow adequate healing of the body wall; for very large

gonads removed through the ventral midline, exercise may be restricted for up to 60 days. Continued antimicrobial therapy is seldom required, and NSAIDs can be used at standard dosages for 1 to 3 days at the clinician's discretion. Potential complications are associated with anesthesia and surgery, in general, and laparoscopic procedures, in particular. Inadvertent injury to intraabdominal structures during abdominal access is exceedingly rare with the use of the modified open technique for placing the first portal on the ventral midline. When practicable, left flank access and insufflation is unlikely to result in serious complications, although shallow lacerations to the splenic capsule can occur. If they do, additional treatment is seldom required. Accidental thermal injury to nearby viscera when electrocautery or electromechanical instruments are used can be avoided by careful attention to the position of the mesovarium/spermatic cord structures relative to nearby viscera and by avoiding activation of the instrument when its jaws are not clearly in view. Persistent masculine or estrus behavior is occasionally a problem after cryptorchidectomy or bilateral ovariectomy, respectively. The presence of residual ovarian tissue is highly unlikely when appropriate technique is used. If the presence of residual testicular tissue is suspected, a serum sample can be obtained to assess the testosterone level soon after surgery. If no testicular tissue remains, the serum testosterone level will be negligible 12 to 24 hours after the procedure; this is due to the short half-life of testosterone in circulation.

### References

1. Bishop MWH. Genetically determined abnormalities of the reproductive system. *J Reprod Fertil (Suppl)* 1972;15:51-78.
2. Boure L, Marcoux M, Lavery S. Paralumbar fossa laparoscopic ovariectomy in horses with use of endoloop ligatures. *Vet Surg* 1997;26(6):478-483.
3. Shoemaker RW, Read EK, Duke T, Wilson DG. In situ coagulation and transection of the ovarian pedicle: an alternative to laparoscopic ovariectomy in juvenile horses. *Can J Vet Res* 2004;68(1):27-32.
4. Goodin JT, Rodgerson DH, Gomez JH. Standing hand-assisted laparoscopic ovariectomy in 65 mares. *Vet Surg* 2010;40(1):90-92.
5. De Bont MP, Wilderjans H, Simon O. Standing laparoscopic ovariectomy technique with intraabdominal dissection for removal of large pathologic ovaries in mares. *Vet Surg* 2010;39(6):737-741.
6. Kummer M, Theiss F, Jackson M, Fürst A. Evaluation of a motorized morcellator for laparoscopic removal of granulosa-theca cell tumors in standing mares. *Vet Surg* 2010;39(5):649-653.
7. Trumble TN, Hendrickson DA. Standing male equine urogenital surgery. *Vet Clin North Am Equine* 2000;16(2):269-284.
8. Joyce J. A review of laparoscopic cryptorchidectomy. *J Equine Vet Sci* 2008;28(2):112-117.