

---

---

# Appropriate Use Criteria for Ventilation–Perfusion Imaging in Pulmonary Embolism

Alan D. Waxman<sup>1</sup>, Marika Bajc<sup>2</sup>, Michael Brown<sup>3</sup>, Frederic H. Fahey<sup>1</sup>, Leonard M. Freeman<sup>1</sup>, Linda B. Haramati<sup>4</sup>, Peter Julien<sup>4</sup>, Grégoire Le Gal<sup>5</sup>, Brian Neilly<sup>2</sup>, Joseph Rabin<sup>6</sup>, Gabriel Soudry<sup>1</sup>, Victor Tapson<sup>7</sup>, Sam Torbati<sup>3</sup>, Julie Kauffman<sup>1</sup>, Sukhjeet Ahuja<sup>1</sup>, and Kevin Donohoe<sup>1</sup>

<sup>1</sup>*Society of Nuclear Medicine and Molecular Imaging*; <sup>2</sup>*European Association of Nuclear Medicine*; <sup>3</sup>*American College of Emergency Physicians*; <sup>4</sup>*American College of Radiology*; <sup>5</sup>*American Society of Hematology*; <sup>6</sup>*Society of Thoracic Surgeons*; and <sup>7</sup>*American College of Chest Physicians*

## EXECUTIVE SUMMARY

Perfusion lung imaging for diagnosing pulmonary embolism (PE) was introduced 50 y ago (1). At that time, it offered a noninvasive alternative to pulmonary angiography in patients with a clinical suspicion of PE. Because there are many causes of diminished regional blood flow in the lungs, particularly redistribution of blood flow away from regions with lung disease, the subsequent introduction of radionuclide ventilation studies added greater specificity to findings on radionuclide perfusion imaging. When appropriately used and interpreted, ventilation–perfusion (V/Q) scintigraphy is an important examination for the evaluation of patients suspected of having regional compromise of lung perfusion and ventilation.

The purpose of this document is to describe the appropriate use of V/Q scintigraphy in patients suspected of having acute PE. It is hoped that through these recommendations, V/Q scintigraphy will be appropriately applied to benefit patients.

Representatives from the Society of Nuclear Medicine and Molecular Imaging (SNMMI), the European Association of Nuclear Medicine (EANM), the American Society of Hematology (ASH), the Society of Thoracic Surgeons (STS), and the American College of Emergency Physicians (ACEP), as well as chest radiologists, emergency department physicians, pulmonary critical care physicians, and physician experts in thromboembolic disease, assembled as an autonomous workgroup to develop the following appropriate use criteria (AUC). This process was performed in accordance with the Protecting Access to Medicare Act of 2014 (2). This legislation requires that all referring physicians consult AUC using a clinical decision support mechanism before ordering any advanced diagnostic imaging service. Such services are defined as diagnostic MRI, CT, nuclear medicine procedures (including PET), and others as specified by the secretary of Health and Human Services in consultation with physician specialty organizations and other stakeholders (2). These AUC are intended to aid referring medical practitioners in the appropriate use of V/Q scans in patients suspected of having PE (3).

## INTRODUCTION

The following document describes the appropriate use of V/Q scans in patients suspected of having PE. The authors have tried to

cover the most common clinical scenarios for this use. However, the reader is reminded that a patient may present with variations of the scenarios covered here, or with signs or symptoms not described, for which V/Q scanning may still be indicated. This document is presented to assist health-care practitioners considering V/Q scanning in patients suspected of having PE; however, each patient is unique, as is each patient's clinical presentation, and therefore this document cannot replace clinical judgement. V/Q scanning can also be used for other conditions. These other scenarios are beyond the scope of this document.

Over the past half century, V/Q lung scintigraphy has been a sensitive and useful tool to detect the presence of PE. CT pulmonary angiography (CTPA) was introduced in the mid-1990s, and subsequently this technology demonstrated the ability to detect peripheral or subsegmental PE (4). CT scans are more commonly available 24 h a day, 7 d per week, as compared with nuclear medicine studies. In addition, CTPA diagnostic algorithms are simpler and able to depict pulmonary, pleural, mediastinal, and chest wall lesions that may cause symptoms similar to those of PE. With these attributes, CTPA has become the most common procedure for the diagnosis of PE. On the other hand, CTPA may be contraindicated in some patients, such as those with intravenous radiographic contrast reactions or renal failure. Therefore, in many patients, V/Q scintigraphy may be warranted as the primary imaging procedure when PE is suspected.

The exquisite anatomic detail of CTPA has raised concerns about the overdiagnosis and overtreatment of small, clinically insignificant PEs and the frequent reporting of new incidental findings that require further work-up (5,6). A third and even greater concern is the patient's CTPA radiation exposure, particularly to the radiosensitive breast tissue of young women.

To protect the systemic circulation, the pulmonary arteries and capillary beds uniquely possess properties that both trap and lyse small subsegmental clots, suggesting that small PEs are common physiologic phenomena (3,7). It is not, however, uncommon for radiologists viewing an abdominal CT examination to see incidental PEs at the lung bases. Physicians in the United States tend to treat these small PEs, although the wisdom for treating small, incidentally discovered PEs has been questioned. A recent policy statement from the American College of Chest Physicians (ACCP) (8) says that for subsegmental PEs and no proximal deep vein thrombosis (DVT), clinical surveillance is suggested over anticoagulation when there is a low risk of recurrent venous PE (venous thromboembolism [VTE]) and anticoagulation is suggested over clinical surveillance when there

---

For correspondence or reprints contact: Alan Waxman, Cedars-Sinai Medical Center, 8700 Beverly Blvd., Room A042, Los Angeles, CA 90048.  
E-mail: waxmana@cshs.org.  
COPYRIGHT © 2017 by the Society of Nuclear Medicine and Molecular Imaging.

is a high risk of recurrent venous PE. As stated by Goodman (3), the only 3 reasons to treat small PEs are inadequate cardiopulmonary reserve, coexisting acute DVT, and prevention of chronic PEs and pulmonary artery hypertension in patients with thrombophilia.

With an increasing clinical consensus that not all PEs should be treated, it is clear that PE imaging is best evaluated on the basis of outcomes rather than accuracy. In a prospective study comparing V/Q and CTPA, Anderson et al. (9) showed that the outcomes (based on a 3-mo follow-up of negative cases) were similar (false-negative rate,  $\leq 1\%$ ) despite the fact that more PEs were detected with CTPA than with V/Q scans (17.7% for CTPA and 11.7% for V/Q). Similar outcome data have also been described in a large retrospective analysis (10).

Many of the referrals for patients with suspected PE are for the presence of shortness of breath or hypoxemia. Both V/Q scans and CTPA can assist in diagnosing the cause of hypoxemia or shortness of breath. This document is therefore written to assist all medical practitioners in the appropriate use of V/Q scintigraphy in all patients that present with signs or symptoms of PE.

The two basic methods used to perform V/Q studies are planar imaging and SPECT. SPECT combined with low-dose CT has gained some popularity as well. Both methods have excellent performance characteristics in the diagnosis of clinically significant PE. SPECT, similar to CTPA, may demonstrate the presence of small, subsegmental emboli, which, if uncomplicated, may not require treatment. There is regional variation in the choice of V/Q methodology, with V/Q planar imaging being the preferred study in the United States (11) whereas V/Q SPECT is favored by the EANM and preferred in Europe, Australia, and some countries in Asia (11,12).

### V/Q Planar Imaging

The standard planar examination consists of 8 ventilation views and 8 perfusion views (anterior, posterior, both lateral, both anterior oblique, and both posterior oblique) obtained in the same orientation. The ventilation study generally precedes the perfusion examination. Several different radiopharmaceuticals have been used for ventilation imaging.  $^{133}\text{Xe}$  gas was commonly used in the past; however, in many centers xenon has been supplanted by aerosols. Presently, the most commonly used aerosol is  $^{99\text{m}}\text{Tc}$ -diethylenetriaminepentaacetic acid.  $^{99\text{m}}\text{Tc}$ -pyrophosphate and  $^{99\text{m}}\text{Tc}$ -sulfur colloid aerosols are also in use with similar success. Some centers are using krypton gas. Several different kits are commercially available to administer these aerosols. A promising new agent not yet approved for use in the United States is an Australian product, Technegas (Cyclomedica), which produces a fine carbonized particle suspension with deep alveolar penetration (13).

The perfusion study is performed with  $^{99\text{m}}\text{Tc}$ -macroaggregated albumin. These albumin particles average 20–70  $\mu\text{m}$  in size, which effectively allows them to lodge in the pulmonary capillaries and distal arteriolar tree. A typical 111- to 185-MBq (3–5 mCi) dose will contain 200,000–700,000 particles, which will embolize less than 1% of the pulmonary capillary bed (14). The package insert from the manufacturer (Jubilant DraxImage) cautions against use in patients with severe pulmonary arterial hypertension; alternatively, some investigators choose to reduce the number of administered particles in these patients (15).

In centers with mobile  $\gamma$ -cameras available, bedside V/Q studies may be performed even in severely ill and hemodynamically unstable patients.

In pregnant patients suspected of having PE, the use of a perfusion-only study using a reduced administered activity of 18.5–37 MBq (0.5–1 mCi) of  $^{99\text{m}}\text{Tc}$ -macroaggregated albumin is suggested.

### V/Q SPECT

Characteristics of V/Q SPECT include a high diagnostic sensitivity. V/Q SPECT allows identification of segmental and subsegmental perfusion defects typical of PE, particularly in the middle lobe and lingula (11,16). It also allows quantification of PE, valuable for therapeutic decision making, follow-up, and research (11,17). In patients with suspected PE who have complex situations including comorbidities such as COPD, left heart failure, pneumonia, and tumor, V/Q SPECT retains its diagnostic utility (11,18).

## METHODOLOGY

### Workgroup Selection

The experts of the AUC workgroup were convened by SNMMI to represent a multidisciplinary panel of health-care providers with substantive knowledge of the use of V/Q scans in PE. In addition to SNMMI member representation, 2 international representatives from the EANM, 1 representative and 1 other member of the American College of Emergency Physicians (ACEP), and a representative each from the American College of Radiology (ACR), ASH, Society of Thoracic Surgeons (STS), and ACCP were also included in the workgroup. Thirteen physician members were ultimately selected to participate and contribute to the resulting AUC. A complete list of workgroup participants and external reviewers can be found in Appendix B.

### AUC Development

The process for AUC development was modeled after the RAND/UCLA appropriateness method (19,20) and included the development of a list of common clinical scenarios encountered in the management of patients with PE, a systematic review of evidence related to these scenarios, and development of AUC for each scenario using a modified Delphi process. This process strove to adhere to the standards of the Institute of Medicine for developing trustworthy clinical guidance (21). The process included identification of relevant scenarios, a systematic synthesis of available evidence, individual and group ratings of the scenarios using a formal consensus process, and document drafting based on final group ratings and discussions.

### Scope and Development of Clinical Scenarios

To begin this process, the workgroup discussed various potential clinical indications or scenarios for which use of V/Q scans might be considered (including possible contraindications). The scope of this workgroup was to focus on the appropriate use of V/Q scans specifically for the diagnosis and management of acute PE, although chronic and recurrent PEs were also considered. For all scenarios, the relevant population was patients suspected of having acute PE (male or female, pregnant or nonpregnant, inpatient or outpatient) aged 14 y or older and of any race or geographic location (rural, urban, etc.).

The workgroup identified 21 scenarios for the use of V/Q scans in patients suspected of having PE. The clinical indications are intended to be as representative of the relevant patient population as possible.

The resulting AUC are based on evidence regarding diagnostic accuracy and effects on clinical outcomes and clinical decision making as applied to each scenario. Other factors affecting the AUC recommendations were potential harm—including long-term harm that may be difficult to capture—costs, availability, and patient preferences.

### Systematic Review

To inform the workgroup, a systematic review of the relevant evidence was commissioned by an independent group, the Pacific

Northwest Evidence-Based Practice Center of Oregon Health and Science University (22). The primary purpose of the systematic review was to assess the diagnostic accuracy and comparative effectiveness of V/Q scans on clinical decision making and clinical outcomes for acute PE.

The key research questions used to guide the systematic review were as follows. How does the diagnostic accuracy of V/Q imaging compare with that of pulmonary angiography or CTPA for evaluation of acute PE in adults (and secondarily, how does V/Q with SPECT compare with V/Q without SPECT, and how does V/Q vary according to patient characteristics such as body habitus and underlying lung disease)? How does V/Q imaging compare with SPECT or CTPA regarding their effect on clinical decision making (and secondarily, how do patient characteristics comparatively affect decision making for each of these techniques)? How does V/Q imaging compare with SPECT or CTPA regarding their effect on clinical outcomes (and secondarily, how do patient characteristics comparatively affect the outcomes for each of these techniques).

The inclusion and exclusion criteria for this review were based on the study parameters established by the workgroup using the PICOTS (population, intervention, comparisons, outcomes, timing, and setting) approach. Searches were conducted on the following databases: the Cochrane Central Registry of Controlled Trials, the Cochrane Database of Systematic Reviews, and OVID Medline (from 1946 through May 2015). These searches were supplemented by reviewing the reference lists of relevant publications.

Two reviewers independently assessed abstracts and full-text articles for inclusion and rated study quality as defined by the established PICOTS parameters. The quality (based on the risk of bias) for each study was categorized as “good,” “fair,” or “poor” using the U.S. Preventive Services Task Force criteria (for randomized trials and cohort studies) (23), QUADAS-2 (for diagnostic accuracy studies) (24), and AMSTAR (for systematic reviews) (25). The strength of overall evidence was graded as high, moderate, low, or very low using methods based on the quality of evidence, consistency, directness, precision, and reporting bias.

Literature searches resulted in 880 potentially relevant articles. After dual review of abstracts and titles, 144 articles were selected for full-text review and 16 publications were determined to meet inclusion criteria and were included in this review.

### Rating and Scoring

In developing these AUC for V/Q scans, the workgroup members used the following definition of appropriateness to guide their considerations and group discussions (26): “The concept of appropriateness, as applied to health care, balances risk and benefit of a treatment, test, or procedure in the context of available resources for an individual patient with specific characteristics.”

On evaluating the evidence summary of the systematic review, the workgroup further refined its draft clinical scenarios to ensure their accuracy and facilitate consistent interpretation when scoring each indication for appropriateness. Using the evidence summary, workgroup members were first asked individually to assess the benefits and risks of V/Q scans for each of the identified scenarios and provide an appropriateness score for each scenario. Workgroup members then convened in a group setting via webinar to discuss each indication and associated scores from the first round of individual scoring. After deliberate discussion, each member independently provided a second round of scores for each scenario. For each indication, the mode numeric score was

determined and then assigned to the associated appropriate use category. For this scoring round, the members were asked to include their expert opinion. All members contributed to the final discussion, and no one was forced into consensus. Once the rating process was completed, the final appropriate use ratings were summarized in a format similar to that outlined by the RAND/UCLA appropriateness method.

The workgroup scored each scenario as “appropriate,” “may be appropriate,” or “rarely appropriate” on a scale from 1 to 9. Scores 7–9 indicate that the use of the procedure is appropriate for the specific scenario and is generally considered acceptable. Scores 4–6 indicate that the use of the procedure may be appropriate for the specific scenario, implying that more research is needed to classify the scenario definitively. Scores 1–3 indicate that the use of the procedure is rarely appropriate for the specific scenario and generally is not considered acceptable.

As stated by other societies that develop AUC, the division of these scores into 3 general levels of appropriateness is partially arbitrary, and the numeric designations should be viewed as a continuum. Additionally, if there was a difference in clinical opinion for a particular scenario such that workgroup members could not agree on a common score, that scenario was given a score of 5 to indicate a lack of agreement on appropriateness based on the available literature and the members’ collective clinical opinion, indicating the need for additional research.

### Clinical Scenarios and AUC Scores

Clinical scenarios for the use of V/Q imaging in PE and final AUC scores are presented in Table 1.

*Scenario 1: PE Unlikely, D-Dimer Negative (Score 1—Rarely Appropriate).* The reasoning behind the rarely appropriate rating is that a patient with a low clinical suspicion for PE (“PE unlikely”) in combination with a negative D-dimer result is at very low risk for PE. Such patients do not routinely require further diagnostic testing for venous thromboembolism (VTE), and alternative diagnoses should be considered. This approach is also supported by other clinical practice guidelines.

*Scenario 2: PE Likely, D-Dimer Negative (Score 8—Appropriate).* A D-dimer test is not typically ordered for patients who have a high pretest probability of PE given that a negative D-dimer result cannot move the posttest probability to a level below the test threshold (e.g., 2%). However, if the initial clinical suspicion for PE is low and a D-dimer test is ordered, but then suspicion increases into the “PE likely” range as more information becomes available (e.g., patient had recent surgery that was not initially disclosed), further diagnostic evaluation with a V/Q scan would be appropriate even if the D-dimer result is negative (despite its sensitivity). A significant number of patients (as many as 9% in one study) with a normal D-dimer result and high clinical probability may be diagnosed with acute VTE, although this situation is unusual (27). Thus, it is recommended that physicians proceed with further testing in the setting of a normal D-dimer result and high clinical probability of VTE.

*Scenario 3: PE Unlikely, D-Dimer Positive (Score 8—Appropriate).* Given a situation in which the initial suspicion for PE is low and the D-dimer result is positive, further diagnostic evaluation is indicated (28). In the systematic literature review, 2 small good-quality studies (28,29) and 1 large fair-quality study (30) indicated that the likelihood ratio associated with a normal or low-probability V/Q result was approximately 0.2. Therefore, for a patient with a low clinical suspicion (e.g., pretest probability of

**TABLE 1**  
Clinical Scenarios for PE in Adults

Scenario no.	Description	Appropriateness	Score
1	PE unlikely, D-dimer negative	Rarely appropriate	1
2	PE likely, D-dimer negative	Appropriate	8
3	PE unlikely, D-dimer positive	Appropriate	8
4	PE likely, male or nonpregnant female with normal chest radiograph	Appropriate	9
5	PE likely, male or nonpregnant female with mild abnormal chest radiograph	Appropriate	9
6	Suspected PE, male or nonpregnant female with significant abnormal chest radiograph	May be appropriate	5
7	PE likely, patient with abnormal renal function	Appropriate	9
8	PE likely, patient at risk for contrast complication	Appropriate	9
9	PE likely, patient who cannot cooperate for ventilation imaging, perfusion only	May be appropriate	5
10	PE likely, CTPA inconclusive or discordant with clinical probability	Appropriate	9
11	PE likely, hemodynamically unstable patient, portable V/Q equipment available	Appropriate	7
12	PE likely, hemodynamically unstable patient, portable V/Q equipment unavailable	Rarely appropriate	1
13	PE likely, ultrasound of lower extremity with clot	Appropriate	9
14	PE (clinically) unlikely, ultrasound of lower extremity with clot	May be appropriate	5
15	PE likely, pregnant patient with normal/mild abnormal chest radiograph, low-dose perfusion only	Appropriate	9
16	PE likely, pregnant patient with severe abnormal chest radiograph, perfusion only	Rarely appropriate	3
17	PE likely, patient ventilator-dependent	May be appropriate	5
18	Recent/prior documentation of PE with CTPA, suspected new PE	Rarely appropriate	2
19	Recent/prior documentation of PE with V/Q scan, suspected new PE	Appropriate	9
20	Recent documentation of PE by CTPA, patient now on anticoagulation; imaging to document disease status when clinically indicated	Rarely appropriate	2
21	Recent documentation of PE by V/Q scan, patient now on anticoagulation; imaging to document disease status when clinically indicated	Appropriate	9

PE likely or unlikely is determined by the referring clinician.

10%) and a normal or low-probability V/Q result (likelihood ratio of 0.2), the posttest probability for PE is below the test threshold (e.g., posttest probability of 2%) for which alternative diagnoses should be considered. A high-probability V/Q result would warrant treatment for PE. It has been suggested that clinicians use age-adjusted D-dimer thresholds (age  $\times$  10 ng/mL) rather than the same lower limit of normal in patients older than 50 y to determine whether imaging is warranted (7).

*Scenario 4: PE Likely, Male or Nonpregnant Female with Normal Chest Radiograph (Score 9—Appropriate).* There was strong agreement among the workgroup members to rank this indication as appropriate based on the high sensitivity and specificity of V/Q imaging in patients with normal chest radiography results. Most importantly, 2 large outcome analyses (9,11) have shown that the rate of symptomatic VTE over a 3-mo follow-up period was extremely low (<1.5%) among patients in whom PE is ruled out. Other general considerations such as the lower patient radiation exposure from V/Q than from CTPA, as well as the avoidance of overdiagnosis of clinically insignificant PEs, is also relevant. The recent policy statement from the ACCP applies in this situation: “[For] subsegmental pulmonary embolism and no proximal DVT, we suggest clinical surveillance over anticoagulation with a low risk of recurrent VTE. . .and [we suggest]

anticoagulation over clinical surveillance with a high risk [of recurrent VTE]” (8).

*Scenario 5: PE Likely, Male or Nonpregnant Female with Mildly Abnormal Chest Radiograph (Score 9—Appropriate).* Examples of abnormalities with a spectrum that includes mild disease on chest radiography are cardiomegaly, diaphragmatic elevation, fibrotic changes, congestive heart failure, and diffuse emphysema. Mismatches between ventilation and perfusion that reflect PE should still be recognizable when only mild radiographic abnormalities exist, resulting in a diagnostic V/Q scan (31).

*Scenario 6: Suspected PE, Male or Nonpregnant Female with Significant Abnormal Chest Radiograph (Score 5—May Be Appropriate).* In general, the presence of dense consolidations on chest radiography could result in a triple match, triggering an indeterminate (nondiagnostic) V/Q result, with the main concern being a pulmonary infarction. In patients with significant chest radiographic abnormalities, CTPA is more specific for the diagnosis of PE. The V/Q scan can be helpful when CTPA is contraindicated, such as in patients with renal insufficiency or patients unable to receive premedication even though they had a prior intravenous radiographic contrast reaction. Scenario 6 may be true when the V/Q scan demonstrates certain findings: The first of these findings is a triple-matched-defect imaging

pattern (32) in the upper or mid lung zones; in this case, the likelihood of PE is considerably much lower (11%–12%) than when the pattern occurs in the lower lung zones (33%).

The second finding is the reverse-mismatch defect (33), which refers to studies in which the ventilation defect is greater than the perfusion defect; this type of defect is a very good negative predictor of PE. When a significant ventilation abnormality exists without a large concordant perfusion defect, a nonembolic pulmonary source, such as airway disease, is likely. A reverse mismatch may indicate hypoxia with good perfusion and poor ventilation, which allows poorly oxygenated blood to return to the systemic circulation. This finding may be seen in subjects with a mucous plug or a primarily pulmonary parenchymal process with nonpatent bronchi and intact perfusion.

The third finding is the stripe sign (34), which refers to the presence of a band of normal parenchymal activity separating the perfusion defect from the lung periphery (pleural surface). This is a strong negative indicator for PE that had 93% accuracy on analysis of the original Prospective Investigation of Pulmonary Embolism Diagnosis (PIOPED) study.

The last finding is the pulmonary infarct sign. On occasion, a perfusion defect without a ventilation defect (i.e., a pulmonary infarct sign (35)) may be seen despite the presence of a radiographic opacity in the same area. When this occurs, the finding is more suggestive of PE, depending on the size and number of perfusion defects without ventilation abnormalities. Several other useful ancillary findings are described in a review article by Freeman et al. (32)

*Scenario 7: PE Likely, Patient with Abnormal Renal Function (Score 9—Appropriate).* In patients with acute or chronic kidney disease who have a high clinical pretest probability of PE, the V/Q scan is a particularly appropriate imaging modality. The alternative modality, CTPA, requires the use of intravenous contrast. It is prudent for patients with acute kidney injury to avoid exposure to intravascular contrast, when feasible, because they are particularly susceptible to the ill effects of nephrotoxin exposure. A patient's individual risk–benefit should be carefully weighed when intravenous contrast administration is considered in the setting of acute kidney injury because no particular threshold laboratory measure of kidney function has been established as safe. In chronic kidney disease, contrast administration is considered safe for patients with an estimated glomerular filtration rate of 30 mL/min/1.73 m<sup>2</sup> or more; individual risk–benefit should be carefully evaluated when intravenous contrast administration is considered for an estimated glomerular filtration rate of less than 30 mL/min/1.73 m<sup>2</sup> in chronic kidney disease. Dialysis patients may receive intravenous contrast without additional risk of kidney injury (36).

*Scenario 8: PE Likely, Patient at Risk for Contrast Complication (Score 9—Appropriate).* The consensus of the workgroup is that if the risk of contrast reaction is elevated above that of the normal population, a V/Q scan is an appropriate alternative to CTPA. In patients with an elevated risk of reaction to iodinated contrast medium and who have a high clinical pretest probability of PE, the V/Q scan is a particularly appropriate imaging modality. The alternative modality, CTPA, requires the use of intravenous contrast, with its attendant risks. In the general population, the risk of a contrast reaction is low: 0.6% for any reaction, 0.04% for a serious reaction, and 0.0002% for a fatal reaction (36). The risk of a contrast reaction is elevated in patients who have had a prior contrast reaction and patients who are atopic and probably asthmatic. People who have had an anaphylactic reaction to any substance or a previous anaphylactoid reaction to intravenous contrast

are at an elevated risk of a severe contrast reaction, even when premedication is administered. Other uncommon risks of contrast administration include iodine-provoked delayed hyperthyroidism in patients with preexisting thyroid disease and, occasionally, respiratory distress in patients with myasthenia gravis.

*Scenario 9: PE Likely, Patient Who Cannot Cooperate for Ventilation Imaging, Perfusion Only (Score 5—May Be Appropriate).* Cooperation from the patient is essential to perform a ventilation scan. When there is a high clinical likelihood of PE and normal results on chest radiography, a perfusion-only nuclear scan is reasonable but not the preferred test. The workgroup feels that if neither the ventilation nor the perfusion portion of the V/Q can be performed and there are no contraindications to CTPA, it is the preferred test (32–35).

*Scenario 10: PE Likely, CTPA Inconclusive or Discordant with Clinical Probability (Score 9—Appropriate).* This scenario refers to several situations: the contrast bolus timing for the CTPA is early or late, leading to inadequate opacification of the pulmonary arteries; the patient is unable to stay still or hold the breath, resulting in motion artifacts; or the large body habitus of a patient results in excessive photon attenuation and degradation of image quality (image noise). Other causes for indeterminate CTPA include parenchymal lung disease (increase in vascular resistance), increased unopacified blood flow from the inferior vena cava (transient interruption of contrast, particularly common in pregnant patients), and streak artifacts from dense contrast in the superior vena cava. In the PIOPED II study (30), when the CTPA results were inconsistent with the clinical probability, the positive predictive value and negative predictive value were reported at 58% and 60%, respectively. Additional imaging was recommended in this setting.

*Scenario 11: PE Likely, Hemodynamically Unstable Patient, Portable V/Q Equipment Available (Score 7—Appropriate).* A portable V/Q scanner is useful in patients who are critically ill and too unstable to move. Patients in shock requiring vasopressors represent one of the more common such scenarios. Similarly, those with extreme ventilator or oxygen requirements may not be stable for transport to radiology. The portable V/Q scanner is most useful when there is no substantial parenchymal lung disease or other diffuse radiographic abnormalities. However, even when there are such abnormalities, it is still possible that one or more large perfusion defects may be diagnostic or at least strongly suggest that risk–benefit favors PE therapy. Stable ICU patients, including those on mechanical ventilation with suspected PE, however, may undergo CTPA because CT is more useful in these patients (37). A portable perfusion scan may be used for patients in extremis who are too unstable to be moved (38). A portable V/Q scanner may be used as deemed appropriate by the clinician (37).

*Scenario 12: PE Likely, Hemodynamically Unstable Patient, Portable V/Q Equipment Unavailable (Score 1—Rarely Appropriate).* In scenario 12, the approach to PE diagnosis requires compiling other clinical data and determining whether risk–benefit favors initiation of therapy for acute PE. Leg or upper-extremity ultrasound, for example, may document venous thrombosis and preclude an urgent need for PE diagnosis. Echocardiography may reveal the McConnell sign, which, although not diagnostic for PE, suggests the diagnosis (39).

PE with shock or hypotension, defined as a systolic blood pressure of less than 90 mm Hg or a sustained drop in systolic blood pressure of more than 40 mm Hg not due to rhythm disturbance, is associated with a high risk of PE-related or in-hospital mortality. In this high-risk setting, the 2014 European Society of Cardiology guidelines (40) recommend CTPA as the test of choice if immediately available

or echocardiography if not. The absence of signs of right ventricular overload or right ventricular dysfunction on echocardiography practically excludes PE as the cause of hemodynamic instability and may provide information about other causes of shock, including pericardial tamponade, acute valvular or left ventricular dysfunction, or hypovolemia.

*Scenario 13: PE Likely, Ultrasound of Lower Extremity with Clot (Score 9—Appropriate).* The presence of DVT generally documented by a positive Doppler sonographic study is a definitive indication for anticoagulant therapy. The incidence of PE in patients with DVT has been estimated to be 38%–50% (41,42). Moreover, in a study in which patients with suspected PE underwent both leg ultrasound and CTPA, the positive predictive value of the presence of a DVT on leg ultrasound for the diagnosis of PE was 96% (43).

*Scenario 14: PE (Clinically) Unlikely, Ultrasound of Lower Extremity with Clot (Score 5—May Be Appropriate).* Some workgroup members argued that the incidence of PE in patients with documented DVT was very significant and varied between 38% and 50%. Many of these PEs may be clinically silent. If the patient were to subsequently develop symptoms of PE on anticoagulation, and a V/Q scan is obtained at that time, it may be helpful to have a baseline study for comparison to distinguish between prior embolization (before treatment) and new pulmonary emboli despite anticoagulation. However, from a resource-use perspective, because most patients with treated DVTs will not develop subsequent clinically significant PE, too many patients may undergo an unnecessary baseline study.

*Scenario 15: PE Likely, Pregnant Patient with Normal/Mild Abnormal Chest Radiograph, Low-Dose Perfusion Only (Score 9—Appropriate).* The clinical diagnosis of PE in pregnancy is sometimes confusing because symptoms and signs such as dyspnea and tachycardia may resemble normal physiologic findings frequently seen in pregnancy. It is, however, important to note that PE occurs 5 times more frequently in pregnant women than in nonpregnant women of the same age (44). The radiation dose to both the fetus and the mother, particularly the breast, are of concern in the pregnant patient. These considerations are emphasized in the National Council on Radiation Protection and Measurements report (45). The effective dose to the woman from CTPA is in the range of about 5–20 mSv, depending on the protocol, as compared with 1.0–3.1 mSv for the radionuclide V/Q scan (46–48). The radiation dose to the breast from CTPA is estimated to be in the range of 10–70 mGy whereas for the V/Q scan it is in the range of 0.9–1.4 mGy (46,47). The fetal dose is estimated to be 0.01–0.66 and 0.5–1.1 mGy for CTPA and the V/Q study, respectively (46,49).

Low-dose perfusion imaging is being used increasingly in many centers. It is estimated to deliver a dose of 0.6 mGy to the maternal breast and 0.1–0.2 mGy to the fetus (46,49). The fetal dose for both the V/Q and the low-dose perfusion studies are comparable to that for CTPA; however, all of the fetal doses are considerably lower than the 100-mSv threshold for concern about teratogenic effects discussed in the National Council on Radiation Protection and Measurements report (47). Newer CT scanners may be able to significantly reduce radiation dose. However, the above estimates are reasonable for most scanners in current use.

Another factor is that the mean pulmonary arterial enhancement on CTPA in pregnant patients is significantly lower than that in nonpregnant patients.

A recent joint recommendation of the Society of Thoracic Radiology and the American Thoracic Society (also endorsed by the American College of Obstetrics and Gynecology) proposed the

initial use of a Doppler leg study, which, if negative, is followed by chest radiography and a V/Q study (50). Several reports have indicated that the low-dose, perfusion-only study will be sufficient to obtain a diagnostic study in almost all cases (51,52).

*Scenario 16: PE Likely, Pregnant Patient with Severe Abnormal Chest Radiograph, Perfusion Only (Score 3—Rarely Appropriate).* The presence of a severe abnormality on the chest radiograph will almost certainly be accompanied by a matched perfusion abnormality, resulting in a nondiagnostic (intermediate) interpretation. A perfusion-only lung scan will not be diagnostic, and it is likely that chest CTPA will be necessary for diagnosis in this scenario. If a contraindication to CTPA exists, such as severe renal insufficiency or contrast medium allergy, a full V/Q scan may sometimes be helpful, particularly when ventilation is significantly poorer than perfusion.

*Scenario 17: PE Likely, Patient Ventilator-Dependent (Score 5—May Be Appropriate).* This discussion is essentially the same as for scenarios 11 and 12. The portable scan may prove to be extremely important and useful especially since an aerosol ventilation study may be done with perfusion at the bedside or in the intensive care unit.

*Scenario 18: Recent/Prior Documentation of PE with CTPA, Suspected New PE (Score 2—Rarely Appropriate).* V/Q would not be recommended in this scenario. If the prior study documenting the presence of PE was a CTPA, it would be best to repeat the same modality to achieve the most meaningful comparison.

The diagnosis of recurrent PEs poses specific diagnostic challenges. First, patients with PE often complain of persistent or recurrent symptoms. In a cohort study of patients with a first unprovoked PE and in whom anticoagulant therapy was discontinued 5–7 mo after their index episode, half the patients were investigated for a suspected recurrent episode over the following 18 mo. Second, patients with previous VTE are more likely to have a positive D-dimer test result and are more likely to be classified as having a high pretest probability (points attributed to previous VTE in pretest probability scoring systems). Imaging tests are requested in many of these patients. Third, thrombus resolution can be a slow process. In a systematic review of studies of patients in whom repeated imaging was systematically performed during follow-up, 87% of patients had residual pulmonary thrombi 8 d after diagnosis, 68% after 3 mo, 57% after 6 mo, and 52% at 1 y (53,54).

V/Q and CTPA results differ by modality. The location and extent of a perfusion defect on a V/Q scan do not allow one to predict with certainty the location and extent of the corresponding filling defect on CT, and vice versa. Using the same imaging modality as that used for initial PE diagnosis allows a comparison of the distribution and extent of the thrombotic burden. Diagnostic cohort studies suggest that a clinically suspected PE might be ruled out on the basis of unchanged or improved yet abnormal V/Q results. For follow-up imaging, the V/Q study also helps to identify the extent of any residual or possibly new perfusion abnormality. Similarly, cohort studies have shown the safety of ruling out PE using CTPA in patients with a prior PE.

*Scenario 19: Recent/Prior Documentation of PE with V/Q Scan, Suspected New PE (Score 9—Appropriate).* V/Q scanning should be performed to achieve the most meaningful comparison with the prior V/Q study for reasons similar to those discussed in scenario 18. However, when comparing findings on follow-up imaging, it should be recalled that a significant proportion of patients with PE will have residual abnormalities evident on imaging tests in excess of 6 mo after the event (53).

*Scenario 20: Recent Documentation of PE by CTPA, Patient Now on Anticoagulation; Imaging to Document Disease Status When Clinically Indicated (Score 2—Rarely Appropriate).* In general, there is no definite supporting evidence for obtaining a V/Q scan after PE is diagnosed by CTPA and is being treated.

*Scenario 21: Recent Documentation of PE by V/Q Scan, Patient Now on Anticoagulation; Imaging to Document Disease Status When Clinically Indicated (Score 9—Appropriate).* Surprisingly little hard evidence exists on the rate of resolution of PE after diagnosis and treatment. Anecdotal accounts have documented resolution of pulmonary emboli within 24 h of development, providing the rationale for PE imaging to be undertaken within 24 h of the onset of symptoms. One study (55) revealed partial or full resolution of the clot in a significant proportion of patients within a few weeks of diagnosis of PE after the initiation of treatment. It is suggested that an echocardiogram be performed 3–6 mo after PE to assess the presence or absence of pulmonary arterial hypertension (56). When chronic thromboembolic pulmonary hypertension is suspected, a confirmatory V/Q study is the preferred test (57). The more important consideration at an interval of 3–6 mo after PE is to assess the presence or absence of pulmonary arterial hypertension using echocardiography (58). When chronic thromboembolic pulmonary hypertension is suspected, a V/Q scan can be helpful in making the diagnosis. If a prior study documenting the presence of PE was a V/Q, it would be best to repeat the same modality to achieve the most meaningful comparison.

## **BENEFITS AND HARMS OF IMPLEMENTING THE AUC GUIDANCE**

These AUC include the critical evaluation of the available literature on V/Q scintigraphic imaging in PE and draw on the clinical experience of a range of experts skilled in the diagnosis and treatment of patients with suspected acute PE. In selecting the specific scenarios for inclusion, the workgroup attempted to choose those that were most clinically relevant and of broad interest. The AUC address the use of V/Q scans in several common clinical settings, including pregnancy, renal failure, contrast allergy, hemodynamic instability, and abnormal chest radiography results. As such, the AUC are a distillation of the knowledge and experience of experts applied to common clinical scenarios involving V/Q in suspected PE.

The benefit of the AUC, if implemented, is the standardization of an evidence- and expert-based approach to the diagnosis of patients with suspected PE. This opens the opportunity for auditing of outcomes and for collaborative research between centers.

However, in the development of these AUC, the workgroup considered that the use of imaging tests in PE diagnosis varies at different centers, often dictated by previous practice patterns, availability of equipment at different times of the day, and local expertise for interpretation and reporting of imaging studies. For these reasons, local resources and expertise should be considered in making decisions on incorporating these AUC recommendations. The workgroup also acknowledges that there are likely additional scenarios not covered by these AUC in which V/Q imaging may be completely justified. This document is therefore not intended or able to include all scenarios in which V/Q scans should be used.

The ventilation portion of the V/Q scan provides crucial information in most scenarios. More than 50% of symptomatic patients suspected of having PE show ventilation and perfusion

defects typical of other acute or chronic pulmonary disorders that cannot be diagnosed otherwise (18). Consideration and assessment of the ventilation and perfusion defects together allows qualitative consideration of the relative contribution of PE and other pulmonary diseases to the clinical presentation.

## **IMPLEMENTATION OF THE AUC GUIDANCE**

To develop broad-based multidisciplinary clinical guidance documents, SNMMI has been working with several other medical specialty societies. This collaboration will foster the acceptance and adoption of this guidance by other specialties.

SNMMI has developed a multipronged approach to disseminate the AUC for V/Q scans in PE to all relevant stakeholders—referring physicians, nuclear medicine physicians, and patients. The dissemination and implementation tactics will be a mix of outreach and educational activities and will be targeted to each of these audiences.

SNMMI will create detailed case studies for its members as well as for referring physicians and make them available via online modules and webinars. These cases will cover the appropriate clinical indications for the use of V/Q scans in PE, as well as some cases in which the results of this study are equivocal.

Related resources such as the systematic review supporting the development of these AUC, a list of upcoming education events on the AUC, factsheets, and other didactic materials will be made available on the SNMMI webpage dedicated to V/Q AUC. Live sessions will be held at the SNMMI annual and midwinter meetings, as well as at the relevant societal meetings of referring physicians, to highlight the importance of these AUC.

SNMMI also aims to create a mobile application for the V/Q AUC for both Apple and Android platforms. Mobile applications are becoming increasingly popular in the health-care industry and can be used to push updates to all users.

In addition to the above activities, SNMMI will also undertake patient-focused outreach to provide education on how AUC can play an invaluable role in the cost-effective and efficient attainment of an accurate diagnosis.

## **APPENDIX A: CEDARS-SINAI MEDICAL CENTER ALGORITHM**

The Cedars-Sinai Medical Center algorithm for evaluating patients with suspected PE is presented in Figures 1A and 2A.

## **APPENDIX B: WORKGROUP MEMBERS AND EXTERNAL REVIEWERS**

### **Workgroup**

The members of the workgroup are Alan D. Waxman, MD (chair), Cedars-Sinai Medical Center, Los Angeles, CA (SNMMI); Marika Bajc, MD, PhD, Lund University, Sweden (EANM); Michael Brown, MD, MSc, Michigan State University, Grand Rapids, MI (ACEP); Frederick H. Fahey, DSc, Boston Children's Hospital, Boston, MA (SNMMI); Leonard M. Freeman, MD, Montefiore Medical Center, Bronx, NY (SNMMI); Linda B. Haramati, MD, MS, Montefiore Medical Center, Bronx, NY (ACR); Peter Julien, MD, Cedars-Sinai Medical Center, West Hollywood, CA (ACR); Grégoire Le Gal, MD, PhD, Ottawa Hospital Research Institute, Ottawa, Ontario, Canada (ASH); Brian Neilly, MD, FRCP, FRCR, Glasgow Royal Infirmary, Glasgow, United Kingdom (EANM); Joseph Rabin, MD, University of Maryland Medical Center, Baltimore, MD (STS); Gabriel Soudry, MD, Franklin Square Medical Center, Baltimore, MD (SNMMI); Victor Tapon, MD, Cedars-Sinai

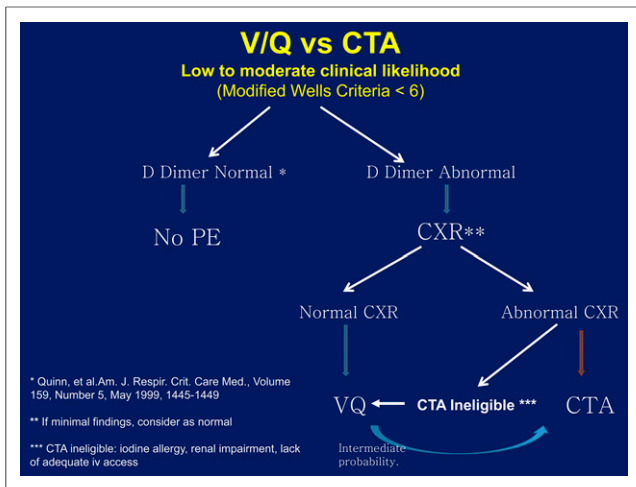


FIGURE 1A.

Medical Center, Los Angeles, CA (ACCP); and Sam Torbati, MD, Cedars-Sinai Medical Center, West Hollywood, CA (ACEP).

**SNMMI**

The staff support from SNMMI is Sukhjeet Ahuja, MD, MPH, director, Evidence & Quality Department; and Julie Kauffman, associate program manager, Evidence & Quality Department.

**APPENDIX C: DEFINITION OF TERMS AND ACRONYMS**

ACCP: American College of Chest Physicians.  
 ACEP: American College of Emergency Physicians.

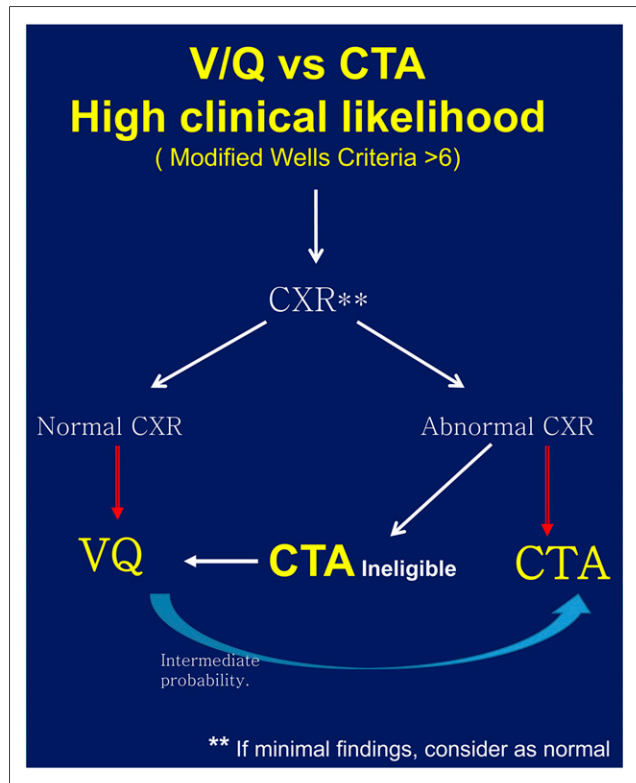


FIGURE 2A.

**TABLE 1D**

Reported Relationships with Industry and Other Entities

Workgroup member	Reported relationships
Waxman, Alan	None
Bajc, Marika	None
Brown, Michael	None
Fahey, Frederic	None
Freeman, Leonard	Jubilant DraxImage (advisory committee member)
Haramati, Linda	None
Julien, Peter	None
Le Gal, Grégoire	None
Neilly, Brian	None
Rabin, Joseph	None
Soudry, Gabriel	None
Tapson, Victor	Bayer (clinical research consulting—VTE)
	Janssen (clinical research consulting—VTE)
	Actelion (consulting—pulmonary hypertension)
	Ekos (clinical research consulting—VTE)
	United Therapeutics (clinical research/consulting—pulmonary hypertension)
Torbati, Sam	None

ACR: American College of Radiology.

AMSTAR: Assessing the Methodological Quality of Systematic Reviews.

Anticoagulants: medications that significantly limit or prevent blood clotting.

ASH: American Society of Hematology.

AUC: appropriate use criteria.

Contrast-induced nephropathy (56): a widely recognized and clinically significant problem in patients undergoing an increasing number of minimally invasive procedures that require contrast administration. Contrast-induced nephropathy is the third most common cause of hospital-acquired renal failure and has significant prognostic implications on patient outcomes. Interventional practitioners are faced with challenging decisions regarding prophylaxis and patient management. The major risk factor for developing contrast-induced nephropathy is preexisting renal dysfunction, particularly in association with diabetes. Patients are considered to be at risk when estimated glomerular filtration rate or estimated creatinine clearance is less than 60 mL/min. The cornerstone of prevention of contrast-induced nephropathy is appropriate risk stratification, intravenous hydration with normal saline or sodium bicarbonate, appropriate withholding of nephrotoxic medications, use of low-osmolar or isoosmolar contrast medium, and various intraprocedural methods for iodinated contrast dose reduction. Although N-acetylcysteine administration is popular, it remains unproven.



Practitioners must be familiar with prevention strategies and diagnosis of contrast-induced nephropathy to minimize its clinical impact.

CT: computed tomography (59), an imaging method that uses x-rays to create pictures of cross-sections of the body.

CTPA: CT pulmonary angiography.

D-dimer test (59): a test used to check for blood-clotting problems. Blood clots can cause health problems, such as deep vein thrombosis, pulmonary embolism, stroke, and disseminated intravascular coagulation.

Diagnostic imaging: chest x-rays, CT, CT with contrast (CT angiography), ventilation lung scanning (aerosol, xenon, Technegas).

DVT: deep vein thrombosis.

EANM: European Association of Nuclear Medicine.

Nephropathy (56): damage, disease, or other problems with the kidney. IgA nephropathy is a kidney disorder in which antibodies called IgA build up in kidney tissue. It is also called Berger disease.

PE: pulmonary embolism.

PICOTS: population, intervention, comparisons, outcomes, timing, and setting. This is an approach to evaluating the diagnostic value of clinical suspicion and VQ scan in pulmonary PE (PTE).

PIOPED and PISA-PED (30,60): Prospective Investigation of Pulmonary Embolism Diagnosis and Prospective Investigative Study of Acute Pulmonary Embolism Diagnosis, respectively, two studies assessing the value of perfusion lung scanning in the diagnosis of PE.

QUADAS-2: Quality Assessment of Diagnostic Accuracy Studies, version 2.

Radiography: chest x-rays, CT, CT angiography.

Renal function tests (59): laboratory tests to evaluate how well the kidneys are working. Such tests include blood urea nitrogen, blood creatinine, creatinine clearance, and urine creatinine.

SNMMI: Society of Nuclear Medicine and Molecular Imaging.

SPECT: single-photon emission tomography.

Stress perfusion study (4): A type of study in which images of a patient's heart at rest are compared with images immediately after exercise to determine the effect of physical stress on coronary blood flow. The stress perfusion study assesses heart function and whether the heart is receiving enough blood and oxygen. The test is performed with either SPECT or PET, which produce 3-dimensional images that show the flow of blood through the coronary arteries and the heart itself.

STS: Society of Thoracic Surgeons.

Ultrasound (61), an anatomic imaging technology that uses soundwaves to create images of tissue within the body. Ultrasound can be a molecular imaging technique when used in conjunction with targeted microbubbles.

V/Q (59): ventilation/perfusion scan, a combination of 2 nuclear scans to measure breathing (ventilation) and circulation (perfusion) in all areas of the lungs.

VTE: venous thromboembolism.

#### APPENDIX D: DISCLOSURES AND CONFLICTS OF INTEREST (COIs)

SNMMI rigorously attempted to avoid any actual, perceived, or potential COIs that might have arisen as a result of an outside relationship or personal interest on the part of the workgroup members or external reviewers. Workgroup members were required to provide disclosure statements of all relationships that might be perceived as real or potential COIs. These statements were reviewed and discussed by the workgroup chair and SNMMI

staff at the beginning of every workgroup meeting or teleconference. The disclosures for the workgroup members can be found in Table 1D. To adjudicate the COIs, the SNMMI leadership used a template developed for the amyloid AUC. A COI was defined as a relationship with industry—including consulting, speaking, research, and nonresearch activities—that exceeds \$5,000 in funding over the previous or upcoming 12-mo period. In addition, if an external reviewer was either the principle investigator of a study or another key member of the study personnel, that person's participation in the review was considered likely to present a COI. All reviewers were asked about any potential COI. The authors of studies chosen for the systematic literature review were cross-checked against reviewers' financial and intellectual COIs.

#### APPENDIX E: PUBLIC COMMENTARY

The workgroup solicited information from all communities through the SNMMI website and through direct solicitation of SNMMI members. The comments and input helped to shape the development of these AUC and consensus recommendations on the appropriate use of V/Q imaging in the detection of pulmonary embolism.

#### ACKNOWLEDGMENTS

The workgroup acknowledges staff support from Avalere Health (Kristi Mitchell, MPP, senior vice president; Hillary Kleiner, MPH, director; and Michelle Bruno, MPH, manager) and from the Pacific Northwest Evidence-Based Practice Center of Oregon Health and Science University (Roger Chou, MD, FACP, director; Christina Bougatsos, MPH, research associate; Ian Blazina, MPH, research associate; and Miranda Pappas, MA, project manager, research associate).

#### REFERENCES

1. Wagner HN, Sabiston DC, Iio M, McAfee JG, Meyer JK, Langan JK. Regional pulmonary blood flow in man by radioisotope scanning. *JAMA*. 1964;187:601–603.
2. Protecting Access to Medicare Act of 2014. Congress.gov website. <https://www.congress.gov/113/plaws/pub193/PLAW-113pub193.pdf>. Accessed March 7, 2017.
3. Goodman LR. Small pulmonary emboli: what do we know? *Radiology*. 2005;234:654–658.
4. Remy-Jardin M, Remy J, Wattinne L, Giraud F. Central pulmonary thromboembolism: diagnosis with spiral volumetric CT with the single-breath-hold technique—comparison with pulmonary angiography. *Radiology*. 1992;185:381–387.
5. Hall WB, Truitt SG, Scheunemann LP, et al. The prevalence of clinically relevant incidental findings on chest computed tomographic angiograms ordered to diagnose pulmonary embolism. *Arch Intern Med*. 2009;169:1961–1965.
6. Schattner A. Computed tomographic pulmonary angiography to diagnose acute pulmonary embolism: the good, the bad, and the ugly—comment on “The prevalence of clinically relevant incidental findings on chest computed tomographic angiograms ordered to diagnose pulmonary embolism.” *Arch Intern Med*. 2009;169:1966–1968.
7. Gurney JW. No fooling around: direct visualization of pulmonary embolism. *Radiology*. 1993;188:618–619.
8. Kearon C, Akl EA, Ornelas J, et al. Antithrombotic therapy for VTE disease: CHEST guideline and expert panel report. *Chest*. 2016;149:315–352.
9. Anderson DR, Kahn SR, Rodger MA, et al. Computed tomographic pulmonary angiography vs ventilation-perfusion lung scanning in patients with suspected pulmonary embolism: a randomized controlled trial. *JAMA*. 2007;298:2743–2753.
10. da Silva R, Shah M, Freeman LM. Ventilation-perfusion (V/Q) lung scintigraphy: a long journey to a renewed position of prominence in diagnosing pulmonary embolism. *Clin Transl Imaging*. 2014;2:369–378.
11. Bajc M, Neilly JB, Miniati M, et al. EANM guidelines for ventilation/perfusion scintigraphy: part 1—pulmonary imaging with ventilation/perfusion single photon emission tomography. *Eur J Nucl Med Mol Imaging*. 2009;36:1356–1370.

12. Le Roux PY, Pelletier-Galarneau M, De Laroche R, et al. Pulmonary scintigraphy for the diagnosis of acute pulmonary embolism: a survey of current practices in Australia, Canada, and France. *J Nucl Med*. 2015;56:1212–1217.
13. Freeman LM, Blaufox MD. SPECT V/Q imaging of the lungs. *Semin Nucl Med*. 2010;40:393–394.
14. Weibel ER. *Morphometry of the Human Lung*. Berlin, Germany: Springer-Verlag; 1963.
15. DRAXIMAGE MAA [package insert]. Kirkland, Québec, Canada: Jubilant DraxImage Inc.
16. Grüning T, Drake BE, Farrell SL, Nokes T. Three-year clinical experience with VQ SPECT for diagnosing pulmonary embolism: diagnostic performance. *Clin Imaging*. 2014;38:831–835.
17. Elf JE, Jogi J, Bajc M. Home treatment of patients with small to medium sized acute pulmonary embolism. *J Thromb Thrombolysis*. 2015;39:166–172.
18. Begic A, Opankovic E, Cucik V, Lindqvist A, Miniati M, Bajc M. Ancillary findings assessed by ventilation/perfusion tomography: impact and clinical outcome in patients with suspected pulmonary embolism. *Nuklearmedizin*. 2015;54:223–230.
19. Hendel RC, Patel MR, Allen JM, et al. Appropriate use of cardiovascular technology: 2013 ACCF appropriate use criteria methodology update: a report of the American College of Cardiology Foundation appropriate use criteria task force. *J Am Coll Cardiol*. 2013;61:1305–1317.
20. Fitch K, Bernstein SJ, Aguilar MD, et al. The RAND/UCLS appropriateness method user's manual. RAND Corporation website. [http://www.rand.org/pubs/monograph\\_reports/MR1269.html](http://www.rand.org/pubs/monograph_reports/MR1269.html). Published 2001. Accessed March 3, 2017.
21. Institute of Medicine of the National Academies. *Clinical Practice Guidelines We Can Trust*. Washington, DC: The National Academies Press; 2011.
22. Pacific Northwest Evidence-Based Practice Center. *Systematic Review: Diagnostic Accuracy of Bone Scintigraphy for Malignant Disease*. Portland, Oregon: Oregon Health and Science University; September 2015.
23. *U.S. Preventive Services Task Force Procedure Manual*. Rockville, MD: Agency for Healthcare Research and Quality; July 2008; AHRQ publication no. 08-05118-EF.
24. Whiting PF, Rutjes AW, Westwood ME, et al. QUADAS-2: a revised tool for the quality assessment of diagnostic accuracy studies. *Ann Intern Med*. 2011;155:529–536.
25. Shea BJ, Bouter LM, Peterson J, et al. External validation of a measurement tool to assess systematic reviews (AMSTAR). *PLoS One*. 2007;2:e1350.
26. AQA Principles for Appropriateness Criteria. London, U.K.: Assessment and Qualifications Alliance; 2009.
27. Gibson NS, Sohne M, Gerdes VE, Nijkeuter M, Buller HR. The importance of clinical probability assessment in interpreting a normal d-dimer in patients with suspected pulmonary embolism. *Chest*. 2008;134:789–793.
28. Lechleitner P, Riedl B, Raneburger W, Gamper G, Theurl A, Lederer A. Chest sonography in the diagnosis of pulmonary embolism: a comparison with MRI angiography and ventilation perfusion scintigraphy. *Ultraschall Med*. 2002;23:373–378.
29. McEwan L, Gandhi M, Andersen J, Manthey K. Can CT pulmonary angiography replace ventilation-perfusion scans as a first line investigation for pulmonary emboli? *Australas Radiol*. 1999;43:311–314.
30. Sostman HD, Stein PD, Gottschalk A, Matta F, Hull R, Goodman L. Acute pulmonary embolism: sensitivity and specificity of ventilation-perfusion scintigraphy in PLOPED II study. *Radiology*. 2008;246:941–946.
31. Robin P, Le Roux PY, Tissot V, et al. Interest of chest x-ray in tailoring the diagnostic strategy in patients with suspected pulmonary embolism. *Blood Coagul Fibrinolysis*. 2015;26:643–648.
32. Freeman LM, Krynycki B, Zuckier LS. Enhanced lung scan diagnosis of pulmonary embolism with the use of ancillary scintigraphic findings and clinical correlation. *Semin Nucl Med*. 2001;31:143–157.
33. Carvalho P, Lavender JP. The incidence and etiology of the ventilation/perfusion reverse mismatch defect. *Clin Nucl Med*. 1989;14:571–576.
34. Sostman HD, Gottschalk A. Prospective validation of the stripe sign in ventilation-perfusion scintigraphy. *Radiology*. 1992;184:455–459.
35. Strauss EB, Sostman HD, Gottschalk A. Radiographic parenchymal opacity, matching perfusion defect, and normal ventilation: a sign of pulmonary embolism? Work in progress. *Radiology*. 1987;163:505–506.
36. ACR manual on contrast media. American College of Radiology website. <https://www.acr.org/~media/37D84428BF1D4E1B9A3A2918DA9E27A3.pdf>. 2016. Accessed February 10, 2017.
37. Righini M, Van Es J, Den Exter PL, et al. Age-adjusted D-dimer cutoff levels to rule out pulmonary embolism: the ADJUST-PE study. *JAMA*. 2014;311:1117–1124.
38. Stein PD, Woodard PK, Weg JG, et al. Diagnostic pathways in acute pulmonary embolism: recommendations of the PLOPED II investigators. *Am J Med*. 2006;119:1048–1055.
39. McConnell MV, Solomon SD, Rayan ME, Come PC, Goldhaber SZ, Lee RT. Regional right ventricular dysfunction detected by echocardiography in acute pulmonary embolism. *Am J Cardiol*. 1996;78:469–473.
40. Konstantinides SV, Torbicki A, Agnelli G, et al. 2014 ESC guidelines on the diagnosis and management of acute pulmonary embolism. *Eur Heart J*. 2014;35:3033–3069.
41. Monreal M. Deep venous thrombosis and the risk of pulmonary embolism: a systematic study. *Chest*. 1992;102:677–681.
42. Moser KM. Frequent asymptomatic pulmonary embolism in patients with deep venous thrombosis. *JAMA*. 1994;271:223–225.
43. Le Gal G, Righini M, Sanchez O, et al. A positive compression ultrasonography of the lower limb veins is highly predictive of pulmonary embolism on computed tomography in suspected patients. *Thromb Haemost*. 2006;95:963–966.
44. Matthews S. Short communication: imaging pulmonary embolism in pregnancy—what is the most appropriate imaging protocol? *Br J Radiol*. 2006;79:441–444.
45. *Preconception and Prenatal Radiation Exposure: Health Effects and Protective Guidance*. Bethesda, MD: National Council on Radiation Protection and Measurements; 2013. NCRP report no. 174.
46. Astani SA, Davis LC, Harkness BA, Supanich MP, Dalal I. Detection of pulmonary embolism during pregnancy: comparing radiation doses of CTPA and pulmonary scintigraphy. *Nucl Med Commun*. 2014;35:704–711.
47. Pahade JK, Litmanovich D, Pedrosa I, Romero J, Bankier AA, Boiselle PM. Quality initiatives: imaging pregnant patients with suspected pulmonary embolism—what the radiologist needs to know. *Radiographics*. 2009;29:639–654.
48. Revel MP, Cohen S, Sanchez O, et al. Pulmonary embolism during pregnancy: diagnosis with lung scintigraphy or CT angiography? *Radiology*. 2011;258:590–598.
49. International Commission on Radiological Protection (ICRP). Radiation dose to patients from radiopharmaceuticals: a compendium of current information related to frequently used substances—ICRP publication 128. *Ann ICRP*. 2015;44(2S).
50. Leung AN, Bull TM, Jaeschke R, et al. An official American Thoracic Society/Society of Thoracic Radiology clinical practice guideline: evaluation of suspected pulmonary embolism in pregnancy. *Am J Respir Crit Care Med*. 2011;184:1200–1208.
51. Cutts BA, Dasgupta D, Hunt BJ. New directions in the diagnosis and treatment of pulmonary embolism in pregnancy. *Am J Obstet Gynecol*. 2013;208:102–108.
52. da Silva R, Shah M, Freeman LM. Ventilation-perfusion (V/Q) lung scintigraphy: a long journey to a renewed position of prominence in diagnosing pulmonary embolism. *Clin Transl Imaging*. 2014;2:369–378.
53. Nijkeuter M, Hovens MM, Davidson BL, Huisman MV. Resolution of thromboemboli in patients with acute pulmonary embolism: a systematic review. *Chest*. 2006;129:192–197.
54. Olsson CG, Bitzén U, Olsson B, et al. Outpatient tinzaparin therapy in pulmonary embolism quantified with ventilation/perfusion scintigraphy. *Med Sci Monit*. 2006;12:9–13.
55. van Es J, Douma RA, Kamphuisen PW, et al. Clot resolution after 3 weeks of anticoagulant treatment for pulmonary embolism: comparison of computed tomography and perfusion scintigraphy. *J Thromb Haemost*. 2013;11:679–685.
56. Stacul F, van der Molen AJ, Reimer P, et al. Contrast induced nephropathy: updated ESUR Contrast Media Safety Committee guidelines. *Eur Radiol*. 2011;21:2527–2541.
57. Kim NH, Delcroix M, Jenkins DP, et al. Chronic thromboembolic pulmonary hypertension. *J Am Coll Cardiol*. 2013; 62(25, suppl):D92–D99.
58. Kline JA, Steuerwald MT, Marchick MR, Hernandez-Nino J, Rose GA. Prospective evaluation of right ventricular function and functional status 6 months after acute submassive pulmonary embolism: frequency of persistent or subsequent elevation in estimated pulmonary artery pressure. *Chest*. 2009;136:1202–1210.
59. Medical Encyclopedia. MedlinePlus website. <https://medlineplus.gov/encyclopedia.html>. Accessed February 10, 2017.
60. Sostman HD, Miniati M, Gottschalk A, Matta F, Stein PD, Pistolesi M. Sensitivity and specificity of perfusion scintigraphy combined with chest radiography for acute pulmonary embolism in PLOPED II. *J Nucl Med*. 2008;49:1741–1748.
61. Glossary of molecular imaging terms. SNMMI website. <http://www.snmmi.org/AboutSNMMI/Content.aspx?ItemNumber=5646>. Accessed February 10, 2017.