

## Hereditary Opalescent Dentin – A Case Report

Dr. M. Chandra Sekhar, MDS<sup>1</sup>, Dr. D. Ayesha Thabusum, MDS<sup>2</sup>, Dr. M. Charitha, MDS<sup>2</sup>, Dr. G. Chandrasekhar, BDS<sup>2</sup>, Dr. K. Sai Dharani<sup>3</sup>

<sup>1</sup>Professor & HOD, Department of Oral medicine and Radiology, Government Dental College and Hospital, Kadapa

<sup>2</sup>Department of Oral medicine and Radiology, Government Dental College and Hospital, Kadapa

<sup>3</sup>Post Graduate Student, Department of Oral medicine and Radiology, Government Dental College and Hospital, Kadapa

\*Corresponding author: Dr. M. Chandra Sekhar

| Received: 14.03.2019 | Accepted: 22.03.2019 | Published: 31.03.2019

DOI: [10.36348/sjm.2019.v04i03.023](https://doi.org/10.36348/sjm.2019.v04i03.023)

### Abstract

Dentinogenesis imperfecta is an autosomal dominant disorder of tooth development characterized by the presence of opalescent dentin, resulting in a dusky blue to brownish discoloration of the teeth. This condition is genetically and clinically heterogeneous. Both deciduous and permanent dentitions are affected. This report describes a case of 19 year old female patient with characteristic dental features of dentinogenesis imperfecta type II.

**Keywords:** Dentinogenesis imperfecta, Autosomal dominant, Opalescent dentin.

**Copyright © 2019:** This is an open-access article distributed under the terms of the Creative Commons Attribution license which permits unrestricted use, distribution, and reproduction in any medium for non-commercial use (Non-Commercial, or CC-BY-NC) provided the original author and source are credited.

### INTRODUCTION

Dentinogenesis imperfecta is one of the most common hereditary disorders of dentin formation. It follows an autosomal dominant pattern of transmission affecting both the formation and mineralisation of dentin. Synonyms are “Hereditary opalescent dentin, Capdeponts teeth” [1]. It is localised form of mesodermal dysplasia of the dentin affecting both primary and permanent dentitions. It was first documented by Barret in year 1882. The term Dentinogenesis imperfecta was coined by Robert and Schour in 1939. The term Hereditary opalescent dentin was first used by Finn [2], Skiller [3], Hodges [4] to describe brown translucent teeth which are opalescent lacking pulp chambers. This trait has very low incidence (1 in 8000 people) with a high degree of penetrance [5]. Dentinogenesis imperfecta classified by Shields and co-workers into three types:-

**Type 1:-** DGI associated with Osteogenesis imperfecta.

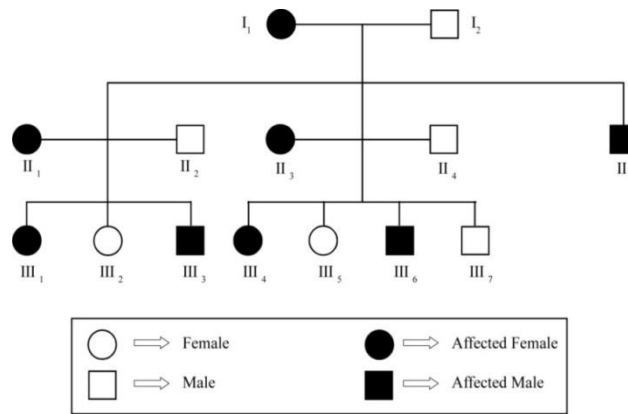
**Type 2:-** DGI without OI (Corresponds to type 1 of revised classification).

**Type 3:-** Brandywine type, rare variety characterized by shell teeth, with very little dentin, multiple pulp exposures in primary teeth (corresponds to type 2 of revised classification).

Clinically DGI affected teeth show gray to brownish blue discoloration (amber). Tooth shape is also affected. Crowns are bulbous and pulp chambers are narrow by excess production of defectively mineralised dentin matrix.<sup>4</sup> Here we present a case of DGI in 19 year old female.

### CASE REPORT

A 19 year old female patient reported to the department of oral medicine and radiology with a complaint of brown colored teeth that were continuously wearing out. She gives history of poor aesthetics due to brown discoloration, wearing away of teeth since many years. She gives history of similar coloured milk teeth which were exfoliated and permanent also resulted in same. She gives no history of any unusual bone brittleness or any other unexplained hearing loss, no systemic illness, no drug usage in present or past. She had no relevant medical history. On further questioning she reported that her mother and her maternal grandmother, one sibling had affected teeth with same brownish discoloration. Her father and all her paternal relations are normal.



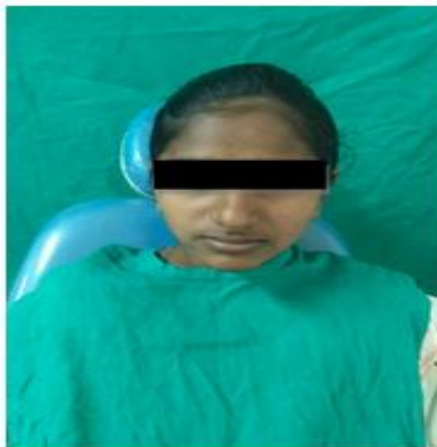On intraoral examination generalised opalescent teeth with brownish blue discoloration, generalised chipping of enamel present, fractured cusps present in multiple teeth. Coronal height of teeth reduced to 1/3<sup>rd</sup> of normal height. Loss of tooth structure till the gingival level was seen in relation to 31, 32, and 36,41,42,46. Pulp exposures were seen in 11, 12,21,22,33 which were non tender on vertical percussion.

An Intraoral periapical radiograph reveals loss of coronal structure involving the pulp in relation to 11,12,21,22 and typical tulip tooth appearance in

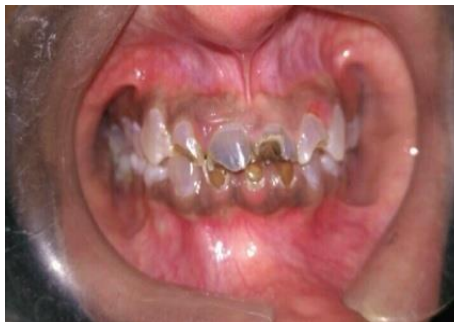relation to 16, 17, 18. Obliteration of root canals, spike like roots with no periapical pathology.

A Panoramic radiograph reveals loss of coronal structures without periapical pathology in relation to 11,12,13,14,21,22,23,31,32,41,42,43 and marked cervical constrictions of most of teeth, partial or complete obliteration of root canals.

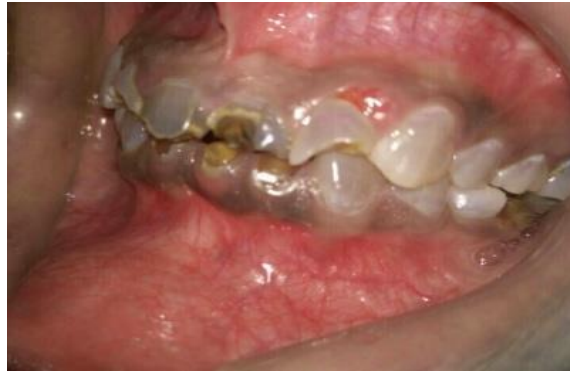Based on the history, clinical examination, radiographic findings and autosomal dominant Inheritance pattern in the family over three generations a diagnosis of Dentinogenesis imperfecta type 2 (Shields classification) was made.



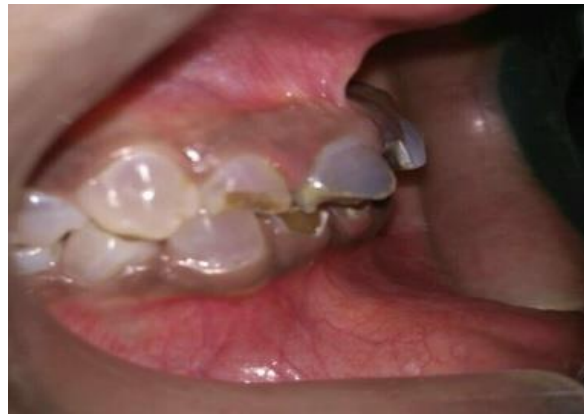**Fig-1: Patients extra oral Frontal profile**



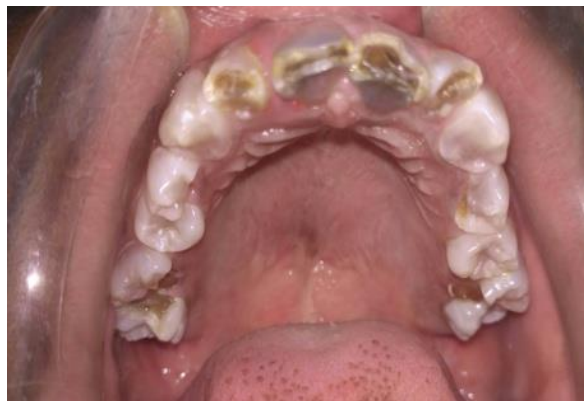**Fig-2: Showing generalised Opalescent teeth with brownish blue discoloration**



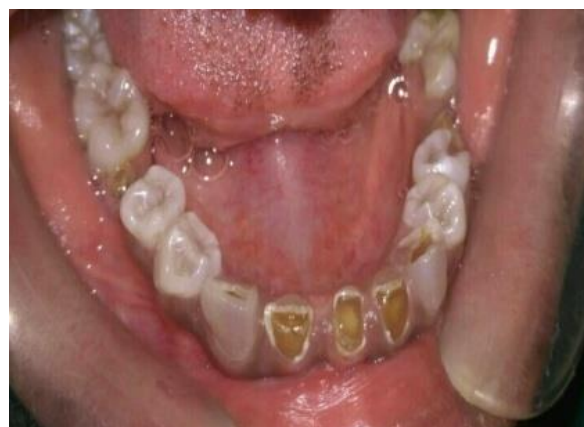**Fig-3: Showing loss of enamel**



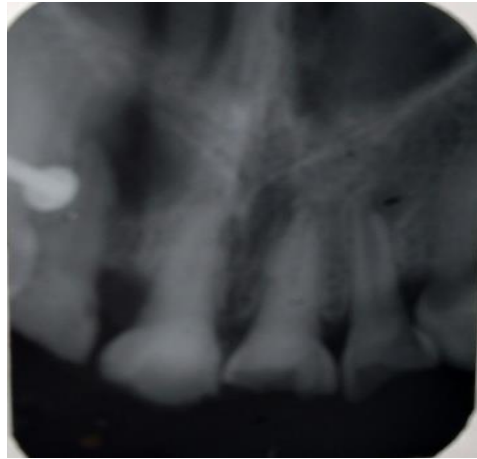**Fig-4: Showing decreased vertical dimension**



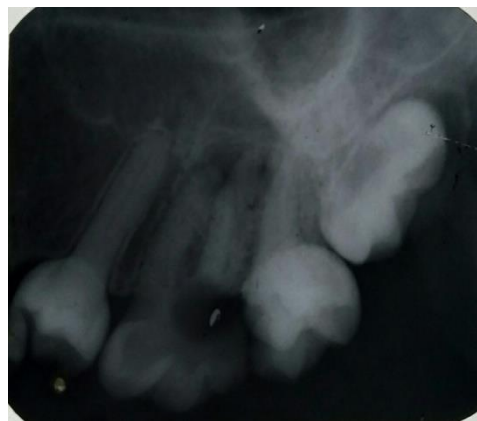**Fig-5: Maxillary arch showing fracture of cusps in multiple teeth**



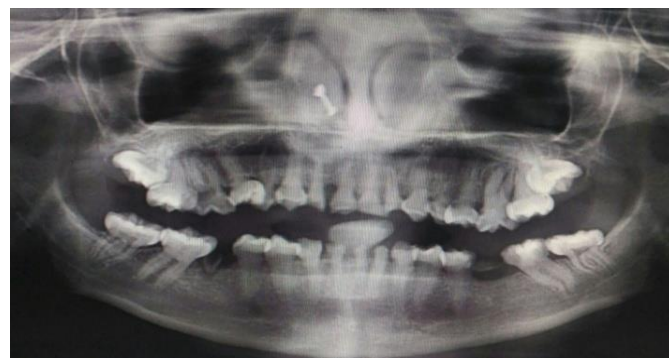**Fig-6: Mandibular arch showing generalised chipping of enamel**



**Fig-7: Intraoral periapical Radiograph of maxillary Anteriors showing pulp Exposures seen irt 21, 22**



**Fig-8: Radiograph of maxillary posterior teeth showing bulbous crowns**



**Fig-9: Orthopantomograph showing obliteration of Pulp spaces, bulbous crowns with cervical constrictions, Short and malformed roots, typical tulip tooth appearance**

## DISCUSSION

Dentinogenesis Imperfecta is thought to have been first recognised by W. C. Barret [6]. It is a hereditary disorder of dentin in the absence of any other systemic disorder [7]. It is a localised mesodermal defect which may affect both primary and permanent dentitions [8, 9, 1].

Shields and co-workers classified dentinogenesis imperfecta based on phenotypic variability into type I -DGI with Osteogenesis imperfecta, Type II -DGI without Osteogenesis imperfecta, Type III is Brandywine type was found in

Brandywine triracial isolate in southern Maryland [10]. Genetic research has confirmed that Osteogenesis imperfecta with opalescent teeth is a separate disease from DGI. Osteopontin a bone glycoprotein is also expressed in dentin. However there is no association between a type of polymorphism at the osteopontin locus and DGI .Hence revised classification is proposed DGI 1 – without Osteogenesis imperfecta, DGI2 – Brandywine type [5].

Most hereditary dentin defects are secondary to mutation in the genes encoding major protein constitute of dentin. Killely *et al.*, Reported DGI to be

due to an autosomal dominant mutation in DentinSialoPhosphoProtein (DSPP) gene mapping to a locus of 4q 12 - 4q21 which encodes for two dentin specific non collagenous acidic matrix proteins Dentin Sialophosphoprotein (DSP), Dentinphosphoprotein (DPP) which together constitute 50% of non collagenous proteins of dentin. Mac Dougall *et al.*, Found that DPP and DSP are cleavage products expressed from a single transcript coded by a gene on human chromosome 4 [11].

Clinically appearance of teeth with DGI is characteristic showing a higher degree of amber like translucency and color ranging from yellowish to blue gray. Broad crowns with cervical constrictions which give teeth a typical tulip appearance [12]. The enamel easily fractures from the teeth and crowns wear readily. Dental tissues in DGI will have low hardness, elasticity and stiffness leading to a phenomenon of micro environment results in failure of restorations [13].

Radiographically the teeth appear solid lacking pulp chambers and root canals, marked attrition of occlusal surfaces, short and slender roots with constrictions of cervical portions of the tooth giving the crown a bulbous appearances [14].

Histopathologically The peculiar shade of enamel though normal is the manifestation of defective dentin with large areas of uncalcified matrix, composed of irregular dentinal tubules, larger in diameter, readily degenerating odontoblasts which gets entrapped in dentin matrix is common [15].

Dentinogenesis imperfecta should be differentiated from amelogenesis imperfecta, Fluorosis, Dentin dysplasia, Tetracycline staining, congenital erythropoietic porphyria. Amelogenesis imperfecta like DGI is also a hereditary disorder. In this teeth are usually sensitive and on radiographs enamel is less radio dense and thinner than dentin pulp chambers and root canals are not usually sclerosed [1].

Both DGI and dentin dysplasia can produce crowns with altered color and occluded pulp chamber. Thistle tube shaped pulp chamber in single rooted tooth strengthens the possibility of dentin dysplasia

Mild to moderate fluorosis ranges clinically from white enamel spots to mottled brown and white discolorations. Severe fluorosis appears as pitted, irregular and discoloured enamel. No pitting is seen in DGI. Teeth affected with tetracycline staining have a bright yellow band appearance that fluoresces under ultraviolet light. On exposure to sunlight color gradually changes to grey or red brown. In congenital erythropoietic porphyria abnormally high levels of porphyrin pigments are incorporated into teeth during their formation due to inborn error of porphyrin

metabolism. The entire primary or permanent dentitions are pink or reddish brown [5].

## CONCLUSION

Dentinogenesis imperfecta causes aesthetic as well as functional problems to the patients. Where diagnosis occurs early in the life of the patient, good aesthetics and function can be obtained thereby minimising nutritional deficits and psychological distress.

## REFERENCES

1. Bhandari, S., & Pannu, K. (2008). Dentinogenesis imperfecta: a review and case report of a family over four generations. *Indian Journal of Dental Research*, 19(4), 357-361.
2. Finn, D. B. (1933). The denaturation of fish muscle proteins by freezing. *Contributions to Canadian Biology and Fisheries*, 8(1), 311-320.
3. Skilling, H. H., & Dykes, P. D. K. (1937). Distortion of traveling waves by corona. *Electrical Engineering*, 56(7), 850-857.
4. Hodges, P. C., Phemister, D. B., & Brunschwig, A. (1938). *The Roentgen-Ray Diagnosis of Diseases of the Bones and Joints*. Thomas Nelson & Sons.
5. Subramaniam, P., Mathew, S., & Sugnani, S. N. (2008). Dentinogenesis imperfecta: a case report. *Journal of Indian Society of Pedodontics and Preventive Dentistry*, 26(2), 85-87.
6. Round, J. H. (1882). Notes on Dignities in the Peerage of Scotland which are Dormant or which have been Forfcited. *The Academy and literature*, 1914-1916, (541), 197-198.
7. Neville, A. J. (2009). Problem-based learning and medical education forty years on. *Medical Principles and Practice*, 18(1), 1-9.
8. Sing, M., & Singh, S. (2004). Hereditary opalescent dentin-a case report. *J Indian Soc Ped Prev Dent*, 22(3), 144-147.
9. Sinha, R., & Khaitan, T. (2016). Dentinogenesis imperfecta: a case report and review of literature. *Journal of oral medicine, oral surgery, oral pathology, oral radiology*, 2:156-58.
10. Singhal, P., & Priya S. (2014). Dentinogenesis imperfecta type II: A case report with review of literature. *Global journal of medical research*, 14.
11. Thotakura, S. R., Mah, T., Srinivasan, R., Takagi, Y., Veis, A., & George, A. (2000). The non-collagenous dentin matrix proteins are involved in dentinogenesis imperfecta type II (DGI-II). *Journal of dental research*, 79(3), 835-839.
12. Kamboj, M., & Chandra A. (2007). Dentinogenesis imperfecta type II. *Journal of oral sciences*, 49:241-44.
13. MacDougall, M., Jeffords, L. G., Gu, T. T., Knight, C. B., Frei, G., Reus, B. E., ... & Leach, R. J. (1999). Genetic linkage of the dentinogenesis imperfecta type III locus to chromosome 4q. *Journal of dental research*, 78(6), 1277-1282.
14. Kerebel, B., Daculsi, G., Menanteau, J., & Kerebel,

- L. M. (1981). The inorganic phase in dentinogenesis imperfecta. *Journal of dental research*, 60(9), 1655-1660.
15. Barron, M. J., McDonnell, S. T., MacKie, I., & Dixon, M. J. (2008). Hereditary dentine disorders: dentinogenesis imperfecta and dentine dysplasia. *Orphanet journal of rare diseases*, 3(1), 31.