

## Effectiveness of Different Fixatives in Body Fluid Analysis

Dr. Sonti Sulochana<sup>1</sup>, Miss. Sudha<sup>2</sup>, Kolappan<sup>3</sup>, Vinodh<sup>4</sup>

<sup>1</sup>Professor, Department of Pathology, Saveetha Medical College and Hospital, Saveetha Institute of Medical and Technical Sciences, Thandalam

<sup>2</sup>B. Sc. Medical Laboratory Technologist Internship Student

<sup>3</sup>Laboratory Manager

<sup>4</sup>Cytology Laboratory Technologist

DOI: [10.36348/SJPM.2019.v04i09.010](https://doi.org/10.36348/SJPM.2019.v04i09.010)

Received: 21.09.2019 | Accepted: 28.09.2019 | Published: 30.09.2019

\*Corresponding author: Dr. Sonti Sulochana

### Abstract

**Background:** Body fluid samples are routinely received for cytological examination to diagnose inflammatory, benign or malignancy. Diagnostic efficiency depending on the type of fixatives used. Therefore these fluid samples are processed with six different fixatives to study the cytomorphological changes. **Aim and objectives:** 1. The aim of the study was to study as closely as possible the cytomorphological characteristics of body fluids by different fixatives. 2. To compare and analyse the most effective fixative. **Materials and method:** In present study, the body fluid samples were received from various out-patient and inpatient departments of saveetha medical college and hospital (from Jan 2019 to March 2019). About 50 body fluid samples of various patients is collected for morphological examination. The moderate amount of fluid (10ml to 15ml) were processed by centrifugation, then smeared and stained. **Results:** Schaudins and carnoys fixatives are the best among the other six different fixatives which had an excellent nuclear and cytoplasmic features and clear background. **Conclusion:** Isopropyl alcohol using as an ideal fixative in cytology laboratory. But Schaudins and carnoys are also as best fixative as that of isopropyl alcohol in body fluid cytology

**Keywords:** fixative, body fluids, hematoxylin and eosin, centrifuge.

**Copyright © 2019:** This is an open-access article distributed under the terms of the Creative Commons Attribution license which permits unrestricted use, distribution, and reproduction in any medium for non-commercial use (NonCommercial, or CC-BY-NC) provided the original author and sources are credited.

### INTRODUCTION

The cytologic study of body fluids is one of the oldest applications of cytologic techniques first investigated in the latter half of the 19<sup>th</sup> century. For many years efforts have been made to develop methods that would enhance the sensitivity and specificity of the smear. Preservation of cellular morphology until the sample can be processed is essential to accurate cytologic interpretation. "prefixation" refers to the collection of a fluid specimen in a medium that will preserve morphology up to the time of slide preparation. A fresh sample is one to which fixative has been added. The accurate diagnosis of cytological smears are based on how fluid samples are fixed. The purpose of cytologic fixatives is to maintain the cytomorphologic characteristics of the cell [1].

An appropriate fixative for cytodiagnosis of fluids should perform the following functions.

- Penetrate cells rapidly
- Minimize cell shrinkage
- Maintain morphologic integrity
- Deactivate autolytic enzymes
- Replace cellular water.

- Facilitate diffusion of dyes across cell boundaries
- Helps cell adherence to a glass surface
- Provide consistent results over time
- Produce a permanent cell record
- Stop cellular and microbial growth (anti -microbial).

Body fluids samples are collected from pleural, peritoneal, pericardial cavities and joint spaces. This is divided into intracellular and extracellular in a two to one ratio, 28-32 liters are inside the cells and 14-15 liters outside the cells. These body fluid samples may contain blood, mucus, inflammatory cells, microbial agents, crystals, proteinaceous material or other debris limiting specimen adequacy. Gross appearance of effusions gives indication about its causes and nature of cellular contents. Haemorrhagic effusions are common findings, these may be pathological (malignancy, tuberculosis, etc). Proper fixation of body fluids is essential when it comes to laboratory for analysing cytological changes. If smears are allowed to dry prior to fixation, marked distortion of cells occurs [2]. So rapid fixation of smears is necessary to preserve cytologic detail of cells. The smears are spreading on a glass slide and stained by H& E staining. This study has been undertaken to improve the

quality of morphology of cells and their background. And to identify cytomorphological details of smears and also to find out the most effective fixative by using various (6different) fixatives (carnoys, schaudinns, ether alcohol, gender, formalol, isopropyl alcohol).

## MATERIALS AND METHODS

This study includes pleural fluid ,synovial fluid, cerebrospinal fluid, asciticfluid, pericardial fluid from various wards and departments of SMCH (Saveetha Medical College and Hospital) over a period from January 2019 to march 2019 (50 body fluid samples). Fluids with quantity less than 2ml were excluded from the study. This study was approved by Institutional Review Board.

Received samples were examined under following headings:

Physical examination (volume, colour, cobweb formation)

Processing, smearing and fixation

Staining of smear samples

Cytological examination. The received sample after physical examination (table 2) is collected for fixationand processing. Specimens without preservative are facilitate for immediate processing, the length of time between collection and preparation of the sample before cellular damages occur depends on the pH protein content, enzymatic activity, and the presence or absence of bacteria [1, 3].

## METHODOLOGY

Put the sample in clean air tight centrifuged tube. Rotate the tube at 1500 rounds per minute (RPM) for 5 minutes in Cyto centrifugation (REMI R-8C) (10) (Fig 1). Discard the supernatant fluid. Make multiple smears from the sediments on a clean glass slide. If RPM is more than 1500 /10 minutes may cause morphological distortion of cells, so carefull attention should be given in this aspect. The smears are then fixed immediately in six different fixatives and stained by H&E method and then mounted[8]. (Fig 2). IfSpecimens consisting of small amount of sediment material that adhere well to glass slides can be smeared directly on the slide using a steady motion. The smears were made to the respective labelling slide. (e.g: the samples are smeared based on the labelling of the slide either with patients name or patient identification number).



Fig-1: Cyto centrifuge



Fig-2: Fixation of smears in different fixatives

## FIXATIVES

Cytological fixatives are very much important to preserve intracellular structures or inclusion [4, 7].

**In this study, the fixative prepared is**

### CARNOYS FIXATIVE (alcohol containing fixative)

95% Ethanol60ml

Chloroform 30ml

Glacial acetic acid 10ml

This fixative must be prepared fresh when needed and discarded after each use. This fixative will hemolyze red blood cells and therefore is useful for bloody specimens. Nuclear chromatin will be lost if the cell samples remains in carnoy's fixative for longer than 15 minutes. It penetrates rapidly and is excellent nuclear fixative [4, 7].

### ETHER ALCOHOL (cytoplasmic fixative)

Ether 25ml

Alcohol 25ml

Ideal fixative, good dehydrating agent and it causes desired amount of cell contraction. This also yields optimal chromatin detail characteristics. The fixation time is 15 minutes, can be prolonged, several days or even fewer weeks. If smears are to be preserved over a long period of time in alcohol, it is better to store them in captured containers in the refrigerator.

### SCHAUDINNS FIXATIVE

Mercuric chloride, saturated aqueous solution 2 parts, Absolute alcohol 1part. This fixative has been popular for many reasons as a cytoplasmic fixative for wet smears. Wet smears are well fixed in 10-20 minutes unless too thick rarely becomes subsequently detached from the slide. This fixative should be prepared immediately.

### GENDERS FIXATIVE

Picric acid saturated in aqueous solution 75ml

Formalin (40% formaldehyde) 25 ml

Glacial acetic acid 5 ml

This fluid is said to give good fixation of glycogen, after 3-4 hours at room temperature.

### FORMAL ALCOHOL

Formalin 10 ml

70-95 per cent alcohol 90 ml

If desired, 0.5 g of calcium acetate can be added to ensure neutrality.

6.80% ISO PROPYL ALCOHOL:

90% ISO PROPYL ALCOHOL

#### WATER 10%

Naturally colorless may contain color additives. This fixative can be used for about 7 days and it does not involve immediate preparation. It is the most commonly used fixative of choice.

After fixation the smears are then stained with routine haematoxylin and eosin stain.

Haematoxylin 5g

Absolute alcohol 50 ml

Alum 100 g

Distilled water 1000ml

Mercuric oxide 2.5 g

EOSIN:

Eosin Y 16 g

Potassium dichromate 8g

Picric acid 160 ml

95% alcohol 160 ml

Distilled water 1280 ml

The smears are placed in haematoxylin for 3-5 minutes, then washed in running tap water for 2 seconds which then undergoes differentiation in alcohol followed by washing in tap water (bluing) and are then placed in eosin for 2 sec. The slides are then mounted and kept ready to pathologists for observation or analysis.

### OBSERVATION AND RESULTS

A total of 50 body fluid samples were taken in this study, in which maximum number were pleural fluid 52% of cases followed by ascitic fluid 32% cases, synovial fluid 12% of cases followed by CSF, pericardial and peritoneal fluid 2% of each cases (Table 1). In present study, maximum number of cases were males and ratio of male to female 1:8:1 (Table-2) the smears were observed for morphology of nucleus and cytoplasm and background by semiquantitative scoring system. The cytomorphological details were observed in carnoys fixative followed by ether alcohol, 80% iso propyl alcohol, gendens fixative, schaudins, and formal alcohol (Table 3).

**Table-1: Total number and the percentage of the fluids analysed**

S.No	Body fluids	No of cases	percentage
1	Pleural fluid	26	52%
2	Ascitic fluid	16	32%
3	Synovial fluid	6	12%
4	CSF	1	2%
5	Pericardial fluid	1	2%
6	Peritoneal fluid	1	2%

**Table-2: (Age and Sex and physical characteristics of various body fluids)**

S.N O	UHID	Type of specimen	VOLUME	COLOUR	AGE/SEX	DIAGNOSIS
1	1901030120	Ascitic fluid	10 ml	PALE YELLOW	13/F	CAD/T2DM
2	1701050217	Pleural fluid	8.2ml	REDDISH	70/F	LRRT
3	1712110201	Synovial fluid	9.6ml	PALE YELLOW	54/M	STS/GOUT
4	1901070243	Peritoneal fluid	5.4ml	REDDISH	41/F	ACUTE APPENICITIS
5	1901070156	Synovial fluid	4.1ml	PALE YELLOW	51/M	R-LL CELLULITIS
6	1812300421	Pleural fluid	6.9ml	YELLOW	63/F	CKD
7	1803280832	Ascitic fluid	10.3ml	TURBID YELLOW	83/F	DCLD
8	1812190312	Pleural fluid	8.8ml	REDDISH	58/F	RIGHT PL. EF
9	1901100038	Pleural fluid	6.9ml	GREYISH WHITE	75/M	L SIDED EMPHYMA
10	1812310283	Ascitic fluid	5.8ml	YELLOW	25/M	CKD
11	1703210052	Ascitic fluid	4.8ml	PALE YELLOW	29/M	INTESTIAL TB
12	1901210002	Ascitic fluid	9ml	YELLOW	53/M	DCLD
13	1901210281	Pleural fluid	8.3ml	YELLOW	62/M	RPL.EF
14	1901210153	Pleural fluid	6.5ml	PALE YELLOW	32/M	PLEURAL EFFUSION
15	1901210177	Pleural fluid	8.2ml	REDDISH	31/M	CKD/SHTN
16	1901210228	Pleural fluid	7.9ml	YELLOW	30/F	LUNG ABSCESS
17	1902250434	Pericardial fluid	8ml	YELLOW	38/F	PERICARDIAL EFFUSION
18	1902110096	Pleural fluid	6.2ml	TURBID YELLOW	59/M	EMPHYMA
19	1902129004	Pleural fluid	8.3ml	YELLOW	51/M	HEAD INJURY
20	1606230001	Ascitic fluid	9.3ml	YELLOW	42/M	GASTRITIS
21	1902090278	Ascitic fluid	5.6ml	PALE YELLOW	47/M	ANAEMIA
22	1612310044	CSF	3.2ml	PALE YELLOW	62/M	AGA/SEPSIS

23	1902022524	Ascitic fluid	6.3ml	YELLOW	76/M	ASCITIS
24	1901170008	Ascitic fluid	9.8ml	YELLOW	28/M	DCLD
25	1808100374	Pleural fluid	8.3ml	YELLOW	35/M	TB EFFUSION
26	1808140011	Pleural fluid	7.4ml	PALE YELLOW	44/M	HYDROPNEUMO THORAX
27	1803120301	Pleural fluid	8.3ml	PALE YELLOW	55/F	B/L PL.EFF
28	1902260119	Pleural fluid	5.4ml	REDDISH	28/M	COPD
29	1902240398	Pleural fluid	5.6ml	YELLOW	39/M	LOBULAR PNEUMONIA
30	1905264310	Pleural fluid	9.3ml	YELLOW	54/M	COPD/T2DM/CKD
31	1905260410	Plueral fluid	8.6ml	REDDISH	37/F	HEMATO THROAX
31	1802560143	Pleural fluid	6.2ml	YELLOW	45/F	TB
32	1905060425	Pleural fluid	7.8ml	YELLOW	35/F	PLEURAL EMPYMA
33	1905060210	Ascitic fluid	6.5ml	PALE YELLOW	51/M	GASTRITIS
34	1905062315	Synovial fluid	7.3ml	PALE YELLOW	32/M	RHEUMATIC ATHRITI
35	1708045012	Ascitic fluid	7.8ml	YELLOW	26/M	NEPHROTIC SYNDROME
36	1905062310	Pleural fluid	8.6ml	YELLOW	54/M	LEFT LUNG EFFUSION
37	1506020375	Ascitic fluid	8.9ml	REDDISH	37/F	PANCTOPENIA
38	1502304120	Pleural fluid	7.3ml	PALE YELLOW	36/F	BRONCHITITIS
39	1701236589	Pleural fluid	8.6ml	YELLOW	35/M	PLEURAL EMPHYMA
40	1906031205	Synovial fluid	4.3ml	YELLOW	26/F	CKD/SHTN
41	1905678941	Ascitic fluid	8.1ml	YELLOW	29/F	L L DIABETIC FOOT ULCER
42	1924654130	Pleural fluid	10ml	PALE YELLOW	41/M	PNEMONIA
43	1459876655	Synovial fluid	5.3ml	YELLOW	54/F	ARTHRITIS
44	1542011545	Pleural fluid	7.4ml	YELLOW	61/F	CA LUNG
45	1545460056	Pleural fluid	6.2ml	BRIGHT YELLOW	36/M	PLEURAL EFFUSION
46	1402456121	Ascitic fluid	8.5ml	REDDISH	34/F	NEPHROTIC SYNDROME
47	1905062045	Pleural fluid	5.9ml	YELLOW	39/F	CKD/SHTN
48	1904563220	Ascitic fluid	9.3ml	PALE YELLOW	29/M	ANAEMIA
49	1906556222	Ascitic fluid	6.5ml	YELLOW	46/M	HTN/GASTRITIS
50	5465461146	Synovial fluid	8.2ml	REDDISH	45/F	PRE PETTALAR EFFUSION

## DISCUSSION

The body cavities in human are lined by the two layers of mesothelium –visceral and parietal. There are three important cavities which includes – the pleural covering the lungs, the peritoneal enclosing gastrointestinal tract organs and pericardial covering the heart. In the absence of disease the two layers of these cavities are separated by a thin layer of lubricating fluid to facilitate the movements of the membranes against one another [5].

In disease conditions, excess fluid accumulates within these cavities constituting effusion which may be either a transudate or exudate [9].

Investigations of the effusions by cytologic examination are of much importance in the diagnosis of disease as well as for exclusion of neoplasia. A cytologic examination of the fluid performed on the smears of centrifuged specimens helps in the planning of treatment. It eliminates the need for invasive procedures and unnecessary surgical intervention, thus

making the pathologist contribute positively to the clinical diagnosis and management of patients.

Different body fluids were used in the study. They include pleural fluid, peritoneal fluid, cerebrospinal fluid, synovial fluid, pericardial and ascitic fluid.

Volume and gross appearance of the fluid specimen should be documented as soon as the fluid specimen is received, since gross examination of fluid will aid in the diagnosis.

Features like volume, color, clarity, opalescence, odour, and viscosity should be assessed.

1) Volume will give an idea about the cytopreparatory technique. 2. Colour of the fluid will guide diagnosis. Most of the malignant effusions are grossly blood stained but only proportions of them are positive for malignant cells. Cyto centrifugation helps in concentrating the cells and the fluid to be centrifuged at 2000 rpm for 10 minutes. The supernatant fluid

discarding and the sediment is placed on slide and making as smears. Direct smears are prepared from fresh unfixed thick or turbid fluids. It is done by placing a drop of fluid directly on the slide and smearing it.

Cytological examination of body fluids is of distinct value in confirming or disapproving malignant metastatic tumours to the cavities [6]. Since mesothelial and synovial tumors are rare, this method is useful to detect malignant cells to the body cavities. In other studies the primary site of malignancy was mainly the breast and lung and hence the pleural cavity was more frequently involved. In our experience the immediately processed samples showed cells that retained their morphology to a considerable extent. Fresh samples offer several important advantages compared to samples collected in preservatives. If the fluids were fixed in various fixatives, they are easier to handle, cells are sticker and can adhere well to the glass slides and it is also our choice to use different fixative. All these features have been noted in our study. The smears were made and reported by pathologist. The smear showed good morphological characters of nucleus and cytoplasm in certain fixatives. In our study we had 50 cases of body fluids collected from various body cavities. 52% of pleural, 32% of ascitic fluid, 12% of synovial fluid and 2% of CSF, pericardial fluid,

peritoneal. It is interesting to note that smears fixed in Carnoy's and Schaudinns showed better nuclear and cytoplasmic details with a clear background. This is explained by the fact that Schaudinns and Carnoy's are good fixatives for body fluids (Fig 5, 8). In ether, the background shows vaculation around the nucleus although the staining of nucleus was good, but showed shrinkage of nucleus because of the fact that it causes desired amount of cell contraction (Fig 6). The advantage of ether fixative is the fixation time can be prolonged several days or even fewer weeks, if smears are to be preserved over a long period of time, it is better to store them in captured containers in the refrigerator. In formal alcohol there is no clear background and it showed shrunken cells of RBC'S, staining of other cells was pale. If desired 0.5g of calcium acetate can be added to ensure neutrality (Fig-3) In Gender's fixative there is a reduced size of cells and background clarity was not clear, chromatin details were not clear, cytoplasm of the cells are not good compared to other fixatives. The smears were unsatisfactory when fixed and examined using Gender's fixative (Fig-4). Isopropyl alcohol shows mild pale staining of cells and sometimes chromatin details are not clear. However, it is most commonly used fixative because of its easy availability and cost effective (fig7).

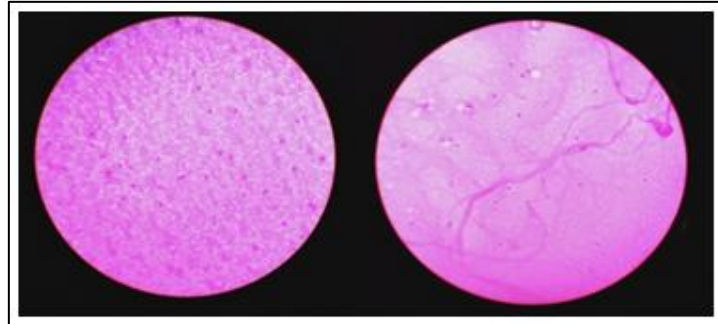
**Table-3: Comparison of cytomorphological features of body fluids using various fixatives by semiquantitative scoring system**

<b>Nuclear features</b>	<b>Score 0</b>	<b>Score 1</b>	<b>Score 2</b>	<b>Score 3</b>
Ether			√	
Isopropyl			√	
Formalol			√	
Carnoys				√
Genders		√		
Schaudinns				√
<b>CYTOPLASMIC FEATURES</b>	<b>Score 0</b>	<b>Score 1</b>	<b>Score 2</b>	<b>Score 3</b>
Ether			√	
Formalol			√	
Carnoys				√
Genders		√		
Schaudinns				√
Isopropyl			√	
<b>Background features</b>	<b>Score 0</b>	<b>Score 1</b>	<b>Score 2</b>	<b>Score 3</b>
Ether				√
Isopropyl				√
Formalol				√
Carnoys				√
Genders				√
Schaudinns				√
<b>Quality of cells</b>	<b>Score 0</b>	<b>Score 1</b>	<b>Score 2</b>	<b>Score 3</b>
Ether				√
Isopropyl				√
Formalol				√
Carnoys				√
Genders			√	
Schaudinns				√

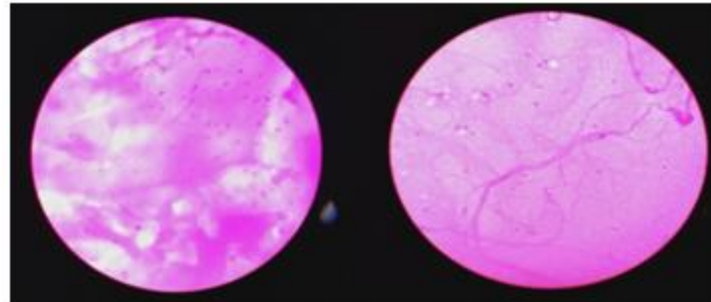
Score 0- Unsatisfactory. Score 1- Satisfactory Score 2 – Good Score 3 - Excellent.

**Table-4: Total score of each fixative**

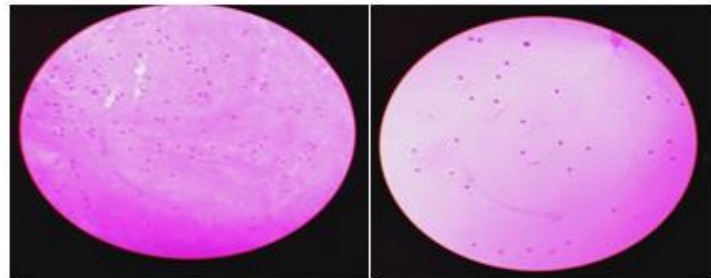
Sno	Name of the fixative	Overall score	Percentage (%)
1	Ether	08	66%
2	Isopropyl	10	83%
3	Formalol	09	75%
4	Carnoys	12	100%
5	Genders	07	58%
6	Schaudinns	12	100%



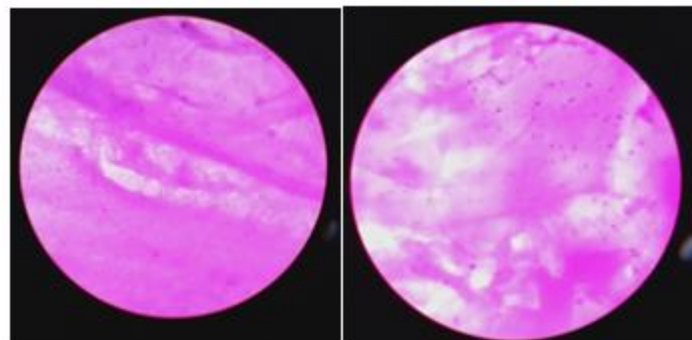
**Fig-3: a, b formal alcohol fixative (40x) poor morphology of cells and background**



**Fig-4: a, b Gender's fixative (40x)-poor morphology of cells and background**



**Fig-5a, b.carnoy's fixative (40X)Good nuclear and cytoplasmic staining in clear background**



**Fig-6: Ether alcohol fixative- nuclear, cytoplasmic and background vacuolation**

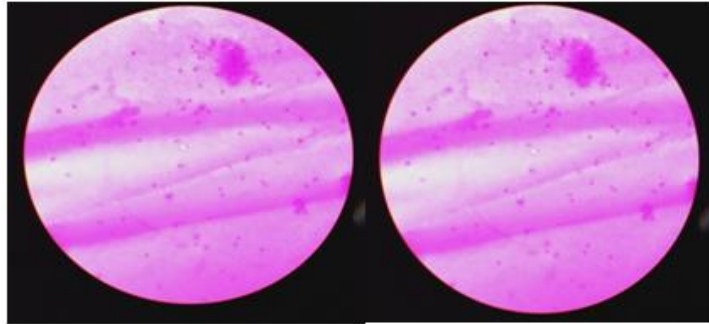


Fig-7: Isopropyl alcohol- mild pale staining of cells in an eosinophilic ground

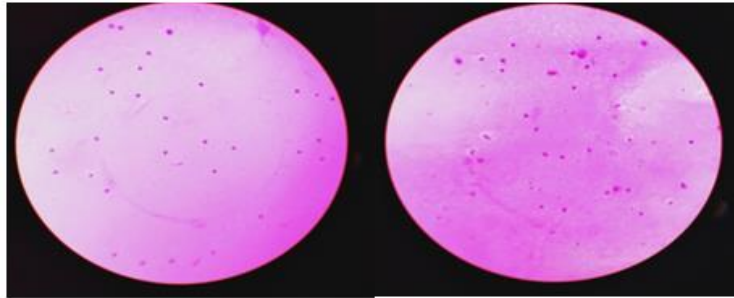


Fig-8: Schaudinn's Fixative- good nuclear, cytoplasm and clear background

## CONCLUSION

It has been concluded that Schaudinn's and Carnoy's fixative are best for processing body fluids. Carnoy's penetrates very rapidly and gives excellent nuclear fixation. Quiet faster in their action, fixation completes within 15-20 minutes, useful in cytology to clear heavily blood stained smear, no shrinkage of cells, it gives clear cytoplasmic membrane and nuclear staining with a clear background. Schaudinn's has been popular for many reasons as a cytoplasmic fixative it gives a good staining quality with a clear background and even the lobes of the neutrophil and other cells are very clear including the cytoplasmic borders. As a mercuric chloride based fixative used to preserve the integrity of sample specimen in preparation and analysis. Ether was also good cytological fixative. Isopropyl alcohol was a common cytological fixative used in almost all the labs. According to our study formal alcohol and Gender fixatives are not suitable for the study of body fluids, because of poor morphology of cells and background. According to our study the suitable fixatives in body fluid analysis was showed in the descending order are Carnoy's, Schaudinn's, Ether, Isopropyl alcohol, formal alcohol and Gender fixative.

## ACKNOWLEDGEMENT

Am thankful to our technician vinodh, and Labmanager kolappan, who are helped and supported in this project

## REFERENCE

1. Koss -A book of diagnostic cytology and its histopathology basis volume 2, 5<sup>th</sup> edition chapter 31, cytopreparatory techniques.
2. Benjammin, Cummings – introduction to body fluids.
3. Pranavdev – introduction to histopathology and cyto techniques, chapter 13, cytology sample processing.
4. Ramdassnayak – Histopathology techniques and its management, chapter 2- fixatives and fixation.
5. Jyotisinghrajput – a comparative study of processing of haemorrhagic body fluids by different hemolysing techniques.
6. Swathy, P.U. – dissertation on comparison between liquid based cytology a conventional preparatory methods in body fluid cavity.
7. Culling C.F.A. – handbook of histopathological and histochemical techniques.
8. Leicabiosystems – fixation and staining echniques.
9. Gia – Khanhnguyen – essentials of fluid cytology.
10. Ashok kumardeshpande – comparative study of body fluid cytology using cytospin 2 and ordinary centrifuge.