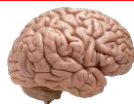

# Central Nervous System Tumors

## General



~1% of tumors in adults, but ~25% of malignancies in children (only 2<sup>nd</sup> to leukemia).  
 Significant increase in incidence in primary brain tumors in elderly.  
 Metastases to the brain far outnumber primary CNS tumors → multiple cerebral tumors.

**One can develop a very good DDX by just location, age, and imaging.**

### Differential Diagnosis by clinical information:

Location	Pediatric/Young Adult	Older Adult
<b>Cerebral/ Supratentorial</b>	Ganglioglioma, DNET, PXA, Ependymoma, AT/RT CNS Embryonal Neoplasms	Glioblastoma Multiforme (GBM) Infiltrating Astrocytoma (grades II-III), Oligodendroglioma, Metastases, Lymphoma, Infection
<b>Cerebellar/ Infratentorial/ Fourth ventricle</b>	PA, Medulloblastoma, Ependymoma, Choroid plexus papilloma, AT/RT	Metastases, Hemangioblastoma, Choroid plexus papilloma, Subependymoma
<b>Brainstem</b>	PA, DMG	Astrocytoma, Glioblastoma, DMG, Metastases
<b>Spinal cord (intramedullary)</b>	Ependymoma, PA, DMG, MPE, Drop metastases	Ependymoma, Astrocytoma, DMG, MPE (filum), Paranglioma (filum),
<b>Spinal cord (extramedullary)</b>	Meningioma, Schwannoma, Metastases, Melanocytoma/melanoma	Schwannoma, Meningioma, Melanocytoma/melanoma, MPNST
<b>Spinal cord (extradural)</b>	Bone tumor, Meningioma, Abscess, Vascular malformation,	Herniated disk, Lymphoma, Abscess, Metastases,
<b>Extra-axial/Dural/ Leptomeningeal</b>	Leukemia/lymphoma, Ewing Sarcoma, Rhabdomyosarcoma, Disseminated medulloblastoma, DLGNT,	Meningioma, SFT, Metastases, Lymphoma,
<b>Sellar/infundibular</b>	Pituitary adenoma, Craniopharyngioma, Rathke cleft cyst, Pituicytoma, LCH, Germ cell tumors	Pituitary adenoma, Craniopharyngioma, Rathke cleft cyst, Pituicytoma, Meningioma, Metastases, Chordoma
<b>Suprasellar/ Hypothalamic/ Optic pathway/ Third ventricle</b>	Germ cell tumors, Craniopharyngioma, PA/optic glioma, LCH	Colloid cyst, Craniopharyngioma, Chordoid glioma,
<b>Pineal</b>	Germ cell tumors, Pineocytoma, Pineoblastoma, Pineal cyst,	Pineocytoma, Pineal cyst, PPTID
<b>Thalamus</b>	PA, DMG,	DMG, GBM, Lymphoma,
<b>Lateral ventricle</b>	Central neurocytoma, SEGA, Choroid plexus papilloma/carcinoma, meningioma	Central neurocytoma, SEGA, Choroid plexus papilloma, Subependymoma, meningioma
<b>Nerve root/ Paraspinal</b>	Neurofibroma, Schwannoma, MPNST,	Neurofibroma, Schwannoma, MPNST, Lymphoma, Meningioma
<b>Cerebellopontine angle</b>	Schwannoma, Choroid plexus papilloma, AT/RT	Schwannoma, Meningioma, Epidermoid cyst, Choroid plexus papilloma, Endolymphatic sac tumor

## Common Abbreviations

**PA** → Pilocytic Astrocytoma

**PXA** → Pleomorphic Xanthoastrocytoma

**DNET** → Dysembryoplastic Neuroepithelial Tumor

**GBM** → Glioblastoma (Multiforme)

**AT/RT** → Atypical Teratoid/Rhabdoid Tumor

**DMG** → Diffuse Midline Glioma (H3 K27M mutant)

**SEGA** → Subependymal Giant Cell Astrocytoma

**MPE** → Myxopapillary Ependymoma

**DIPG** → Diffuse Intrinsic Pontine Glioma

**MPNST** → Malignant Peripheral Nerve Sheath Tumor

**SFT** → Solitary Fibrous Tumor

**LCH** → Langerhans Cell Histiocytosis

**PPTID** → Pineal Parenchymal Tumor of Intermediate Differentiation

**DLGNT** → Diffuse Leptomeningeal Glioneuronal Tumor

## Classic Locations/Correlations

### Imaging findings:

**Metastases** → Multiple enhancing/rim-enhancing nodules at grey-white junctions in cerebrum

**Lymphoma** → Periventricular enhancing lesion

**Glioblastoma Multiforme** → Rim enhancing, “Butterfly” mass

**Myxopapillary ependymoma** → Filium terminale mass

**Meningioma** → Dural lesion with a “dural tail” (enhancing)

**Pilocytic astrocytoma** → Circumscribed, cystic brain mass in the cerebellum of a child

**Ganglioglioma** → Child with epilepsy and a temporal lobe cystic mass

### Classic clinical associations:

**Metastases** → Common sites of origin: lung, breast, and kidney

→ Strong prediction: melanoma and choriocarcinoma

## A Note on Grading

Grade is part of a **continuum** and **estimates malignancy/aggressiveness**.

Brain tumors are pathologically graded, but not staged (as often not resected en bloc).

With increasingly small biopsies, IHC, molecular, and cytogenetics are now critical for Dx and grading!

Some tumors have inherent grades, while others have criteria for grading often depending on mitoses, necrosis/microvascular proliferation, and atypia.

### Generally:

**Grade 1** → Low proliferation potential and possibility of cure after surgical resection alone.

**Grade 2** → Usually infiltrative in nature and often recur, despite having low levels of proliferation. Some may progress to higher levels of malignancy. Often survive >5 years.

**Grade 3** → Clear histologic evidence of malignancy, including nuclear atypia and sometimes brisk mitotic activity. Patients with these tumors often receive chemotherapy and/or radiation. Often survive 2-3 years.

**Grade 4** → Cytologically malignant, mitotically active, necrosis-prone neoplasms that are often associated with rapid progression and fatal outcome. Includes GBM (survival < 1 year) and most embryonal neoplasms (survival depends on treatment and can be long).

# Glomas

Tumors derived from **glial cells** that support for neurons in the CNS, including **astrocytes** (form blood-brain barrier) and **oligodendrocytes** (coat axons forming myelin sheath).

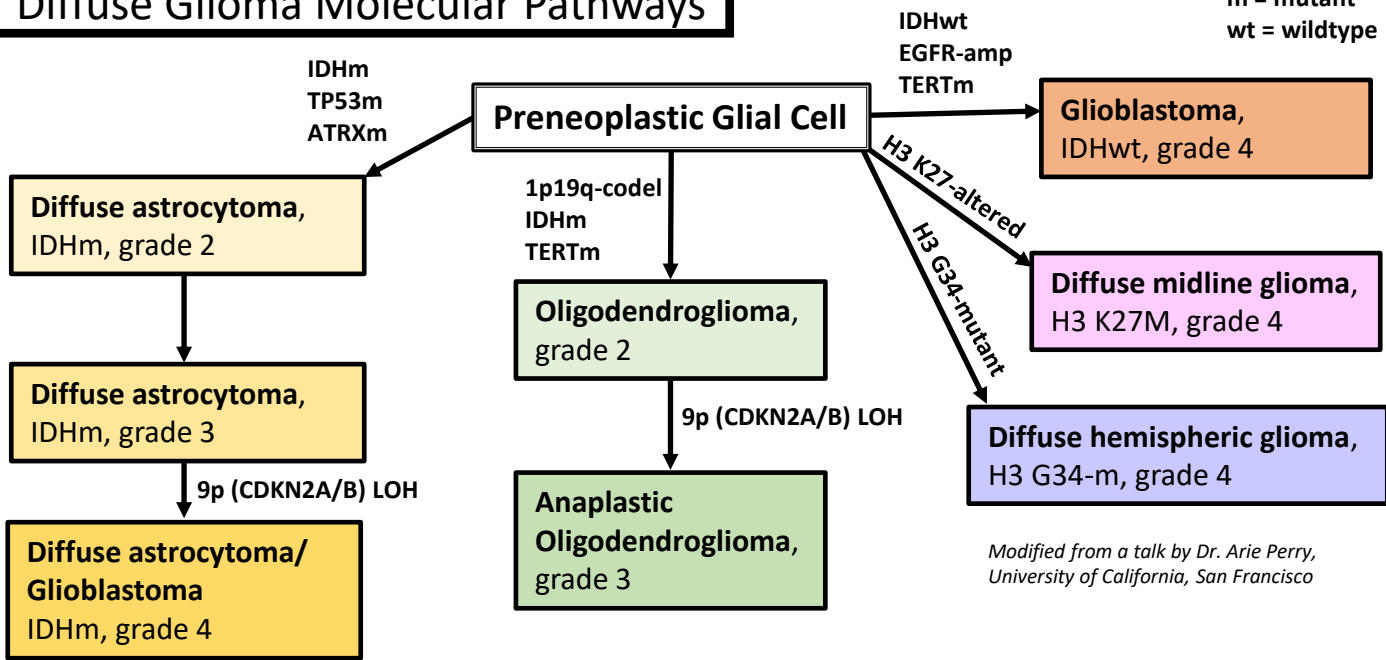
## General

Most common primary tumors of CNS parenchyma.

**Diffuse gliomas** ("infiltrative gliomas," including astrocytomas) → widely invasive into brain parenchyma → often not resectable → often naturally progress to higher grade lesions → often resistant to therapy.

Other astrocytomas (like pilocytic astrocytoma, PXA, and SEGA) are better circumscribed and have different molecular pathways.

## Diffuse Glioma Molecular Pathways



Modified from a talk by Dr. Arie Perry, University of California, San Francisco

## Is this tumor *Glial*?

As opposed to metastases, and other non-glial tumors, glial tumors often have:

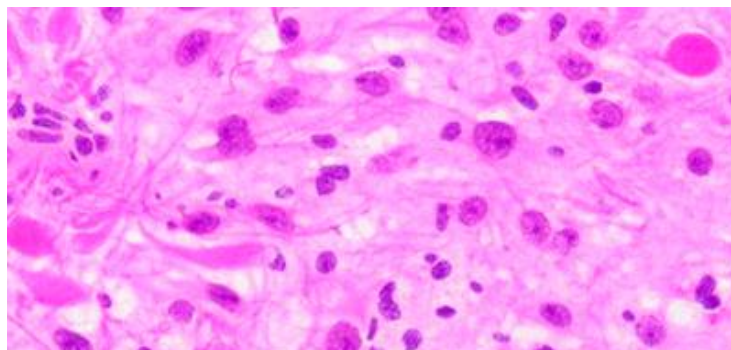
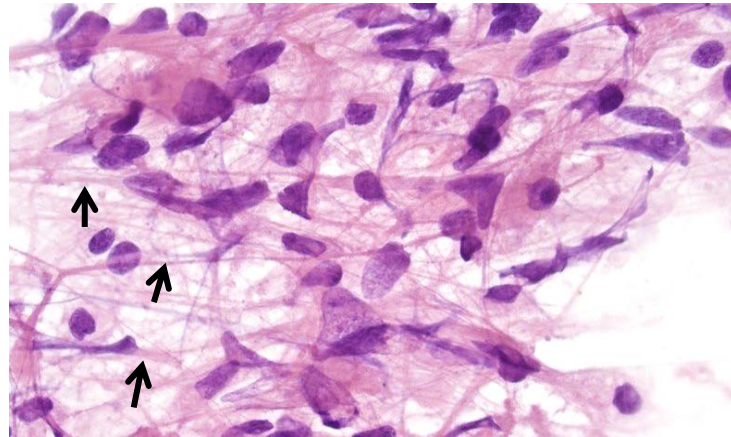
**Fibrillary processes** (→), often also naked nuclei. Best appreciated on cytology like squash prep.

**Infiltrative growth** into brain parenchyma with intra tumoral axons (neurofilament +; primarily seen with astrocytomas and oligodendroglioma). (vs non-glial tumors, which are usually well-demarcated)

Secondary structures, such as **perineuronal satellitosis**, subpial density, perivascular collections.

Eosinophilic cytoplasm with nuclear hyperchromasia/pleomorphism

**IHC: GFAP** and/or **OLIG2** positive (Warning: broad spectrum cytokeratins may stain glial filaments as they are both intermediate filaments!).



## Are these glial cells **neoplastic**? (or is it a mimic??!)

**Gliosis** = **reactive changes of glial cells in response to injury**. Includes both proliferation and hypertrophy.

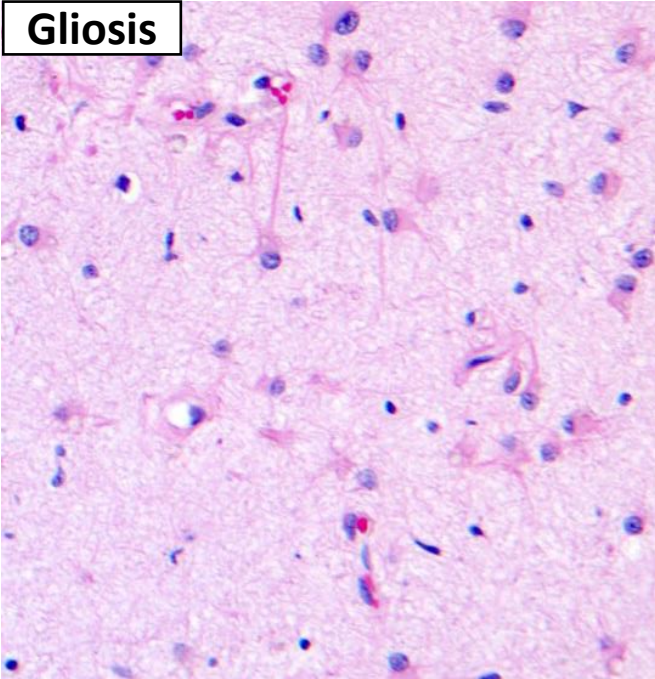
This can histologically mimic a tumor and pose a diagnostic dilemma, especially intraoperatively. This is particularly troublesome as gliosis can be found adjacent to tumors or as part of reactive process that can mimic tumors radiographically.

Early reactive astrocytosis → hypertrophy with enlarged cytoplasm/processes and open chromatin with prominent nucleoli (abundant astrocyte cytoplasm is almost always pathologic!)

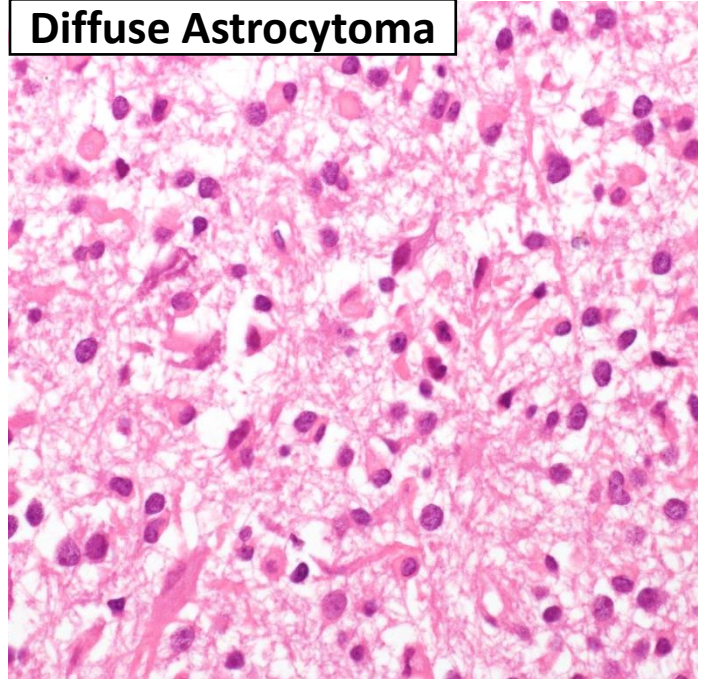
Longer term reactive astrocytosis → astrocytes become **gemistocytic** (large amounts of brightly eosinophilic eccentric cytoplasm) Warning: some tumors can appear gemistocytic too!!

Chronic reactive astrocytosis → often seen around slow-growing lesions → more fibrillar with long astrocytic processes and Rosenthal fibers → "*piloid gliosis*"

**Gliosis**



**Diffuse Astrocytoma**



### Gliosis

Euchromatic, round/ovoid nuclei

Evenly spaced astrocytes

Abundant eosinophilic cytoplasm

Astrocytes with variable atypia

No mitotic activity

Radially oriented fibrillary processes

Other reactive changes, such as inflammation, macrophages, etc...

### Glioma

Large, hyperchromatic, irregular (astrocytoma) to round nuclei (oligodendroglioma)

Clustering of astrocytes, Hypercellular, Satellitosis

"Naked" nuclei

Uniform atypia

Possible mitoses

Necrosis and/or microvascular proliferation (usually in high grades)

Demonstratable mutation (e.g., IDH1, ATRX, etc...)



# Astrocytic Tumors

## Classic Organization/Grading

See more discussion later for evolving/new changes!

WHO Grade	Tumor	Histologic criteria	Prognosis
I	Pilocytic astrocytoma		Excellent
II	Diffuse astrocytoma	One: Nuclear atypia	>5 years
III	Anaplastic astrocytoma	Two: Atypia + Mitoses	2-5 years
IV	Glioblastoma multiforme	Three: Above + Vascular proliferation and/or Necrosis	1 year

**Diffuse Gliomas**

Modified from a presentation by Dr. Hannes Vogel, Stanford University Medical Center.

**Atypia** → Variation in nuclear size and shape with hyperchromasia

**Mitoses** → Must be unequivocal. No strict cut-offs, but a single mitotic figure in a large specimen is insufficient to upgrade to Grade III.

**Microvascular proliferation** → Apparent multilayering of endothelium or glomeruloid microvasculature.

**Necrosis** → Can be any type (does not need to be pseudopalisading).

Order of appearance: Atypia → Mitoses → Increased cellularity → Necrosis and/or microvascular proliferation

## Diffuse Astrocytoma WHO grade II

aka "Diffuse astrocytoma, IDH-mutant"

A **diffusely infiltrating astrocytoma** with a mutation in either the **IDH1 or IDH2 gene** (in adults).

**NO** CDKN2A/B homozygous deletions

Most common in **young adults** (mid-30s), most commonly in **frontal lobes** (but can get anywhere in CNS). Commonly present with seizures.

**Well-differentiated fibrillary astrocytes.**

Cellularity is moderately increased.

**Moderate nuclear atypia.**

Often loose microcystic background.

Mitotic activity is generally absent (A single mitotic figure in a large specimen is acceptable, but not a Bx)

**Molecular/IHC: IDH1 or IDH2 mutations**

Most common mutation (~90%) is **IDH1 R132H**

→ can detect with mutation-specific IHC

**ATRX mutation** → loss of ATRX IHC staining

**TP53 mutation** → strong nuclear p53 IHC staining

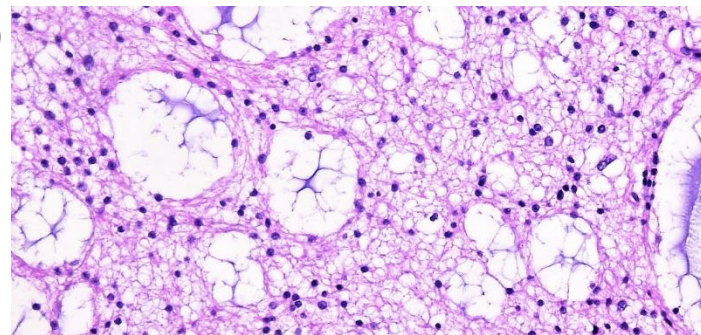
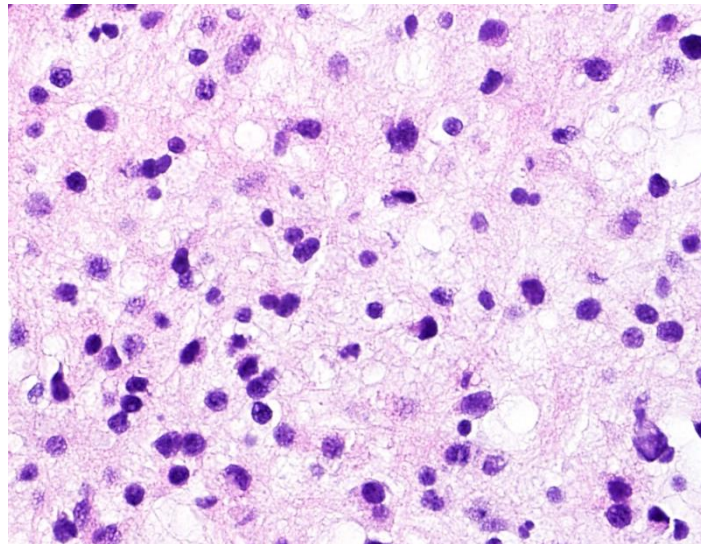
Ki67 usually <4%. Express GFAP.

**Slow growth. Survival >5yrs** (now often >10 yrs!).

**Intrinsic capacity for malignant progression** →

Anaplastic astrocytoma → GBM.

**Gemistocytic Astrocytoma:** A variant of IDH-mutated astrocytoma with prominent gemistocytic neoplastic astrocytes (>20%). Historically thought to progress faster, but may not be true.



**Pediatric Diffuse Astrocytoma:** Same histology. Much less common. Most common in cerebrum, but also thalamus. Rare progression. MYB and BRAF alterations. **ABSENT** IDH1&2, ATRX, mutations!

# Anaplastic Astrocytoma

## WHO grade III

Diffusely infiltrating astrocytoma with focal or diffuse **anaplasia**, **significant proliferative activity**, and a **mutation in either IDH1 or IDH2**.

**NO CDKN2A/B homozygous deletions**

Can arise from grade II diffuse astrocytoma, but most of the time no precursor lesion is identified.

Most commonly in the **cerebrum** (although can get anywhere in CNS) of **young adults** (often 30s).

Similar appearance to diffuse astrocytoma, often with **more nuclear atypia** and **higher cellularity**.

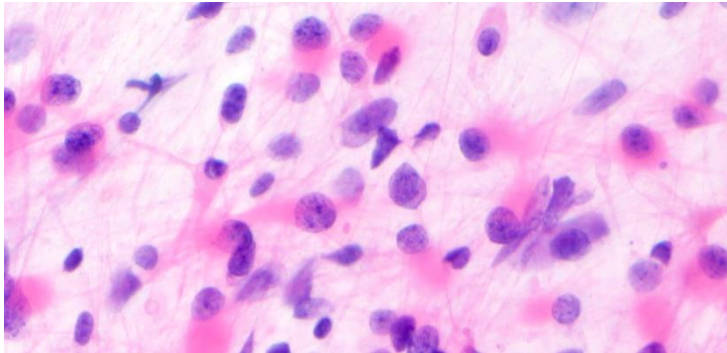
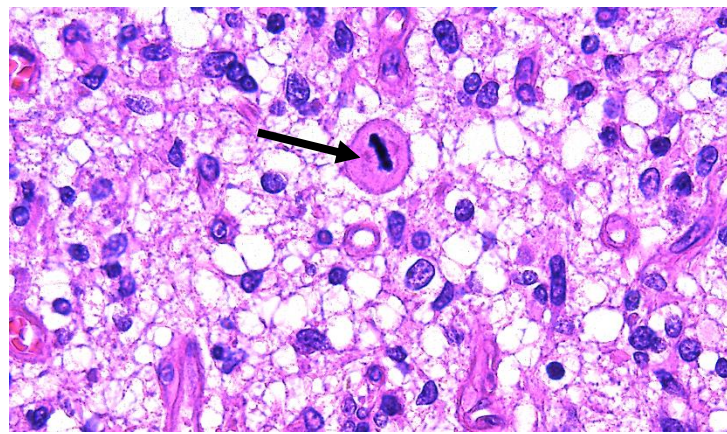
→ Increased pleomorphism, coarse chromatin, prominent nucleoli, multinucleation, atypical mitoses.

**Increased mitotic activity** → must evaluate in context of sample size. A single mitotic figure on a biopsy is enough. In resections, need to see “significant” mitotic activity (often  $\geq 2$ ).

By definition: NO necrosis and NO microvascular proliferation (otherwise would be a GBM!)

**Intrinsic tendency to progress to GBM.**

Historic survival: 3-5 years (but is increasing!)



**Molecular/IHC: IDH1 or IDH2 mutations**

Most common mutation (~90%) is **IDH1 R132H**

→ can detect with mutation-specific IHC

**ATRX mutation** → loss of ATRX IHC staining

**TP53 mutation** → strong nuclear p53 IHC staining

Ki67 usually 5-10%. Express GFAP.

# Glioblastoma

## WHO grade IV

*Old name: Glioblastoma Multiforme (GBM)*

A **high-grade glioma** with predominantly astrocytic differentiation with **nuclear atypia**, **mitotic activity**, **AND microvascular proliferation**, and/or **necrosis**. Often diffuse growth.

**Most common malignant primary brain tumor in adults.**

Often **diffusely infiltrates** adjacent and distant brain structures.

On imaging → **irregularly shaped with ring-shaped enhancement** around central dark necrosis.

→ Can grow along corpus callosum into other hemisphere → “butterfly glioma”

Often present with seizure or neurological deficits.

There are **two major molecular pathways** with **dramatically different prognoses**:

**IDH-wildtype** (primary) → much more common → **old patients** with no precursor → TERT promoter mutations → **rapid progression and death**, often within 1 year.

**IDH-mutant** (secondary) → less common → **younger** patients with precursor astrocytoma → 9p (CDKN2A/B) deletions → **slower** progression → **prolonged survival**, up to several years.

To distinguish between the two, perform IHC for IDH1 R132H first, if positive → IDH-mutant. If negative → proceed to IDH1&2 sequencing to exclude other mutation. However, this may be unnecessary in older patients with classic histology.



## Glioblastoma (*continued*)

**Variable histology** (hence “multiforme”):

**Highly cellular** with poorly differentiated, sometimes very pleomorphic tumor cells.

**Brisk mitotic activity.**

**Either necrosis or microvascular proliferation.**

→ glomeruloid tufts of multilayered mitotically active endothelium with smooth muscle and pericytes. Often near necrosis.

Often **regional heterogeneity.**

Tumor cells will often migrate/invade around existing structures, e.g., around neurons (satellitosis), in subpial zone, etc..

Specific morphologic patterns:

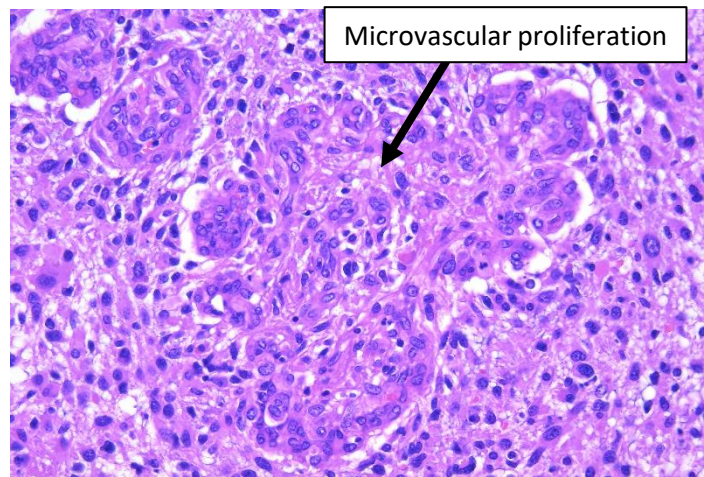
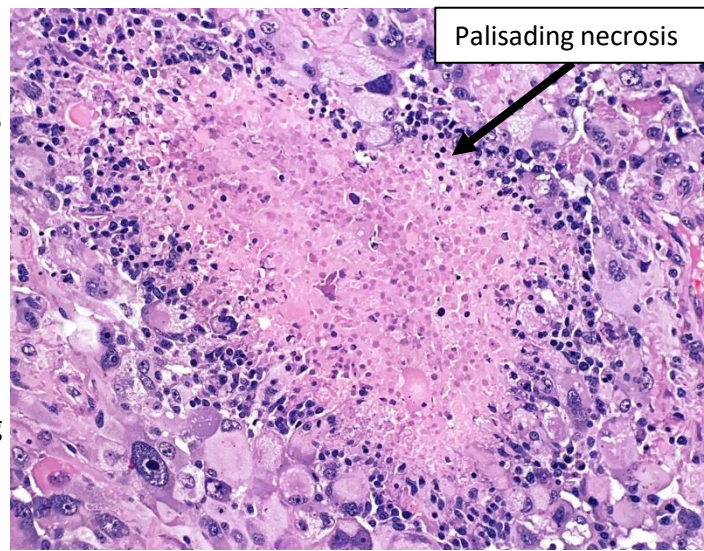
- Small cell glioblastoma
- Glioblastoma with a primitive neuronal component
- Gemistocytic glioblastoma
- Lipidized glioblastoma
- Granular cell glioblastoma
- Adenoid glioblastoma

IHC: Typically (+) GFAP, S100, OLIG2

Ki67 typically ~15-20%, but can be much more

Can grow into multiple lobes/hemispheres → “gliomatosis cerebri”

Metastases are very uncommon.



	IDH- <u>wildtype</u> Glioblastoma	IDH- <u>mutant</u> Glioblastoma (Astrocytoma, IDH-mutant, grade 4)
Synonym	Primary glioblastoma	Secondary glioblastoma
Precursor lesion	None	Anaplastic astrocytoma
Proportion of GBMs	~90%	~10%
Mean age at Dx	~60 years	~45 years
Mean length of clinical Hx	4 months (short)	15 months (long)
Survival with treatment	< 1 year (short)	2 years (long)
Location	Supratentorial	Frontal lobe specifically
Necrosis	Extensive	Limited
TERT promoter mutations	70%	25%
ATRX mutations	Rare	70%
EGFR amplifications	35%	Rare
PTEN mutations	25%	Rare
MGMT promoter methylation status predicts response to alkylating chemotherapy agents		



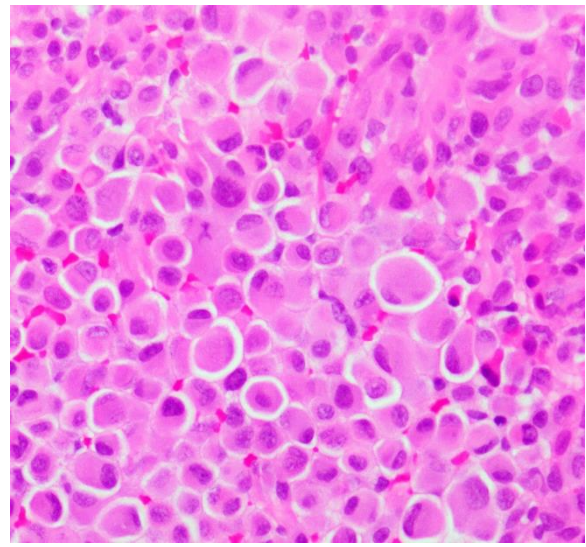
## Epithelioid Glioblastoma

High-grade diffuse astrocytic tumor with a **dominant population of closely packed epithelioid cells**, some rhabdoid cells, mitotic activity, microvascular proliferation, and necrosis.

Predominantly in **young adults and children**.

IHC/Molecular: (+)GFAP, S100, Vimentin  
Frequent expression of CK AE1/AE3 or EMA  
Frequent **BRAF V600E mutations**  
**IDH-wildtype**

**Aggressive** with short survival (~6 months).



## Giant Cell Glioblastoma

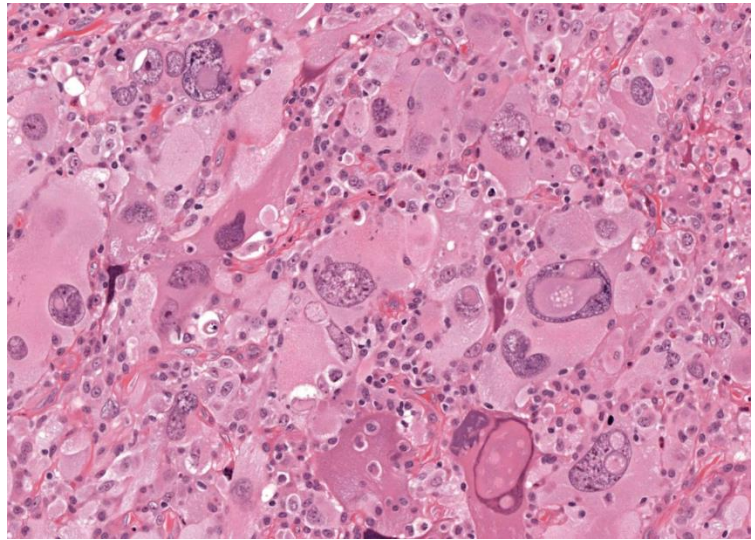
Rare variant of **IDH-wildtype** glioblastoma.

**Bizarre, multinucleated giant cells**.  
Occasionally abundant reticulin network.

Often more **circumscribed** → Somewhat **better prognosis**

High rate of **TP53 mutations** (rare EGFR amplifications)

*Consider PXA in differential diagnosis*



## Gliosarcoma

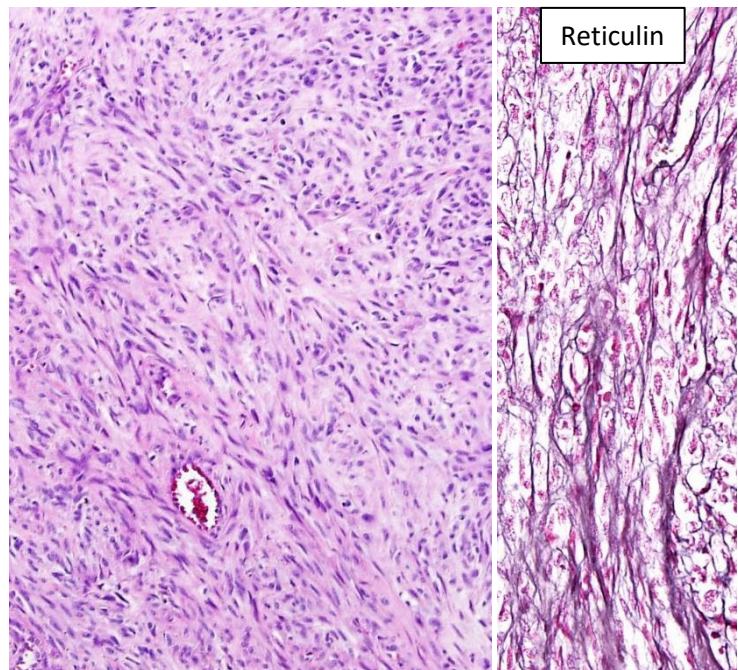
Variant of **IDH-wild-type glioblastoma** with **biphasic growth displaying glial and mesenchymal differentiation**  
→ analogous to epithelial-to-mesenchymal transition in carcinomas

Sarcomatous component often has a **spindle cell pattern** with densely packed long bundles of spindle cells with **abundant reticulin** framework. Also mitoses, necrosis, and atypia.

IHC: Sarcoma component often **lacks** GFAP

Can have heterologous differentiation (e.g, cartilage, rhabdomyoblasts, etc...).

**Similar prognosis** and clinical characteristics to IDH-wildtype glioblastoma





# New Molecular Grading Changes

## Diffuse astrocytic glioma, IDH-wildtype, with molecular features of glioblastoma, WHO grade IV

Genetic changes that indicate an **IDH-wild type astrocytoma** will behave aggressively and should be graded as **Glioblastoma, grade IV** (even if traditional morphologic findings of glioblastoma aren't present): 1) EGFR amplification, or 2) Combined whole chromosome 7 gain and whole chromosome 10 loss (+7/-10), or 3) TERT promoter mutation

## Astrocytoma, IDH-mutant, WHO grade IV

Given that IDH-mutant glioblastomas have a better prognosis than IDH-wildtype glioblastomas, there is a shift to now classify them as grade 4 "astrocytomas" instead. For IDH-mutant tumors, CDKN2A/B homozygous deletion can also count similar to necrosis and microvascular proliferation for upgrading.

**Table 6.** Suggested definitions and grading of Astrocytomas, IDH-mutant.

### *Astrocytoma, IDH-mutant, WHO grade 2*

A diffusely infiltrative astrocytic glioma with an *IDH1* or *IDH2* mutation that is well differentiated and lacks histologic features of anaplasia. Mitotic activity is not detected or low. Microvascular proliferation, necrosis and *CDKN2A/B* homozygous deletions are absent

### *Astrocytoma, IDH-mutant, WHO grade 3*

A diffusely infiltrative astrocytic glioma with an *IDH1* or *IDH2* mutation that exhibits focal or dispersed anaplasia and displays significant mitotic activity. Microvascular proliferation, necrosis and *CDKN2A/B* homozygous deletions are absent

### *Astrocytoma, IDH-mutant, WHO grade 4*

A diffusely infiltrative astrocytic glioma with an *IDH1* or *IDH2* mutation that exhibits microvascular proliferation or necrosis or *CDKN2A/B* homozygous deletion or any combination of these features

**Table 5.** Suggested criteria for Glioblastoma, IDH-wildtype.

An IDH-wildtype diffuse astrocytic glioma with:

- Microvascular proliferation, or
- Necrosis, or
- One or more of the following molecular features of glioblastoma:
  - *TERT* promoter mutation, or
  - *EGFR* gene amplification, or
  - +7/-10 chromosome copy number changes

*Figures from: Louis DN, et al. cIMPACT-NOW update 6: new entity and diagnostic principle recommendations of the cIMPACT-Utrecht meeting on future CNS tumor classification and grading. Brain Pathol. 2020 Jul;30(4):844-856.*

## Diffuse Glioma, H3.3 G34-mutant

## WHO grade IV

A **diffuse glioma** of the **cerebral hemispheres** with a **missense mutation** exchanging glycine for arginine or valine at position 34 of the **mature histone H3.3 protein**. IDH-wildtype.

**Pediatric and young adult patients.**

**Cerebral hemispheres.**

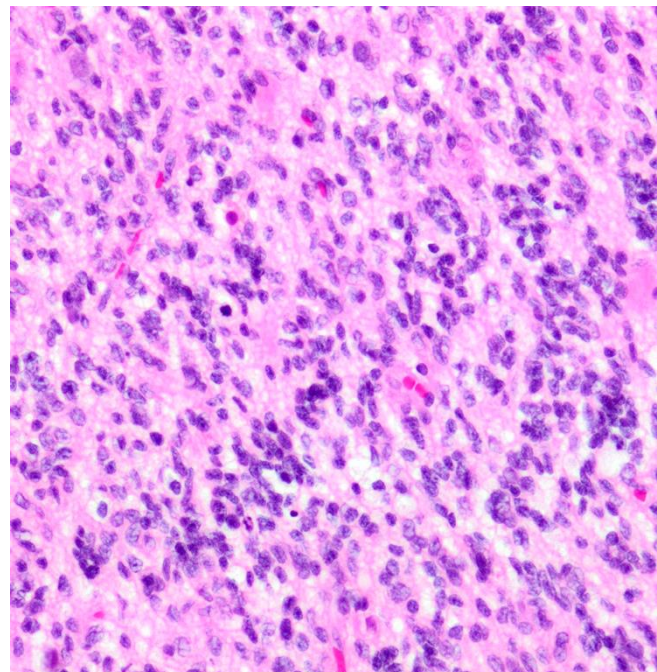
Diffusely infiltrating atypical astrocytes with features of anaplasia, including mitotic activity, microvascular proliferation and/or necrosis.

Sometimes may resemble Embryonal tumor (high N:C ratio)

Molecular/IHC: **(+) H3.3 G34-mutant specific IHC**, p53 overexpression. Loss of ATRX.

(-) IDH, OLIG2.

**Poor prognosis.**





## Diffuse Midline Glioma, H3 K27M-mutant

WHO grade IV

Older name: *Diffuse Intrinsic Pontine Glioma (DIPG)*

An **infiltrative high-grade midline glioma** with predominantly astrocytic differentiation and a **K27M mutation in the histone coding genes H3F3A or HIST1H3B/C**.

**Predominates in children**, but can see in adults.

Common locations: **Brainstem/Pons**, Thalamus, spinal cord.

Tumor cells usually small and monomorphic, sometimes can be pleomorphic

**Diffusely infiltrates adjacent and distant brain structures.**

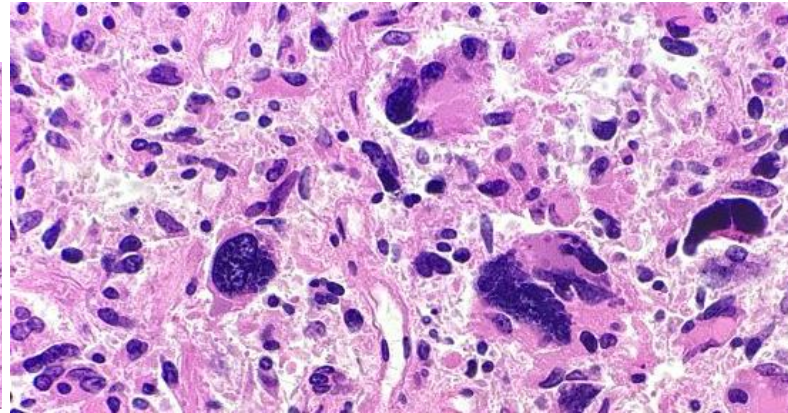
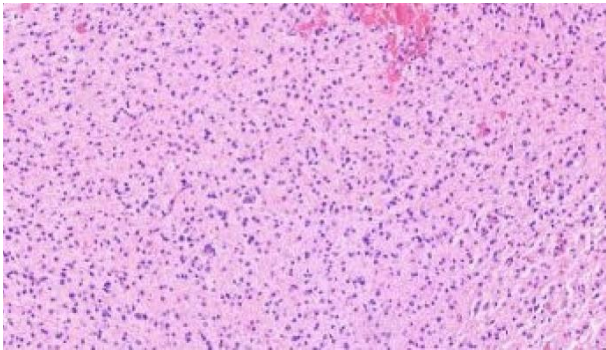
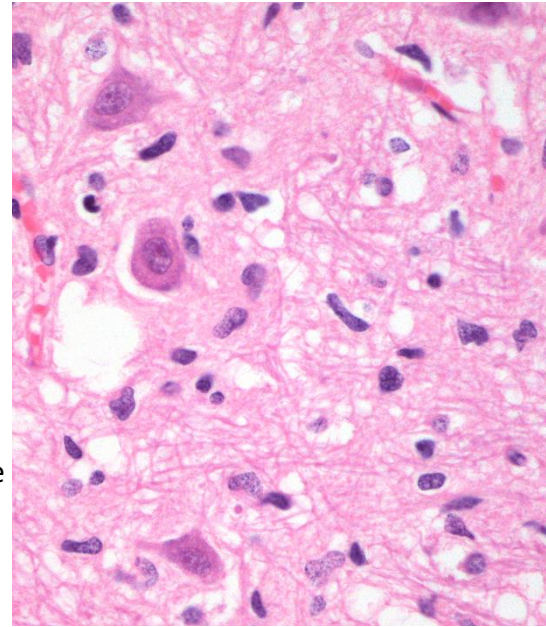
Mitotic activity is often present.

Necrosis and microvascular proliferation may be present, but are not necessary for Dx.

IHC: (+) S100, OLIG2; (+/-) GFAP, MAP2

**(+) Mutation-specific antibody for H3 K27M**

**Poor prognosis (<2 years)**



## Subependymal Giant Cell Astrocytoma (SEGA)

WHO grade I

Benign, slow-growing tumor

**SEGA**<sup>®</sup>

**Well-circumscribed.** Often calcifications  
Composed of **large, plump gemistocytic astrocytes** with **abundant pink glassy cytoplasm**.

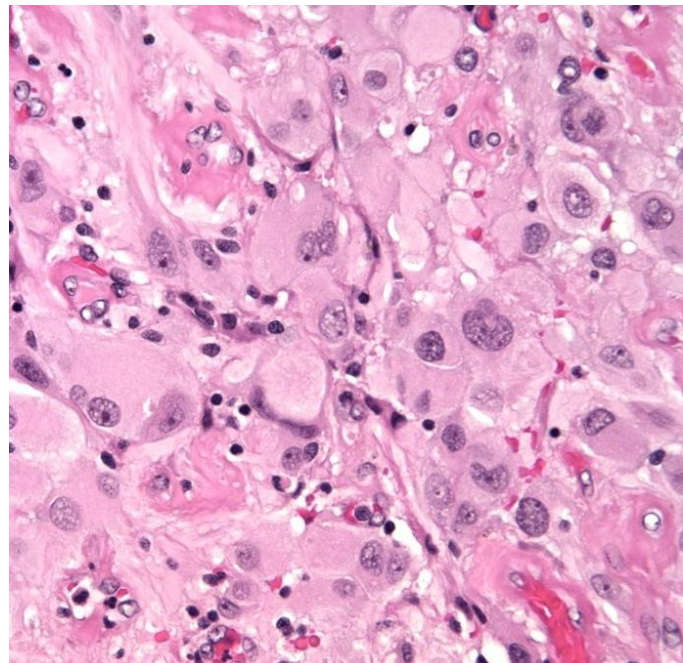
Arranged in fascicles, sheets, and nests.  
Some areas may have smaller, spindled cells.  
Frequently giant **ganglion-like cells with prominent nucleoli**. Considerable nuclear pleomorphism.

Typically arises in the **wall of the lateral ventricles**.  
Usually present before age 20, often with seizures.

Very strong association with **Tuberous sclerosis**.

→ One of the major diagnostic criteria

Good prognosis with totally resected.





# Pilocytic astrocytoma ("PA")

## WHO grade I

An **astrocytoma** with a biphasic pattern with varying proportions of 1) **compact bipolar cells with Rosenthal fibers** and 2) **loose, textured multipolar cells with microcysts and eosinophilic granular bodies**.

Nuclei typically elongate and relatively bland, may be round (Oligo-like)

Still allowed: Rare mitoses, Hyperchromatic pleomorphic nuclei, microvascular proliferation, necrosis, and infiltration of meninges

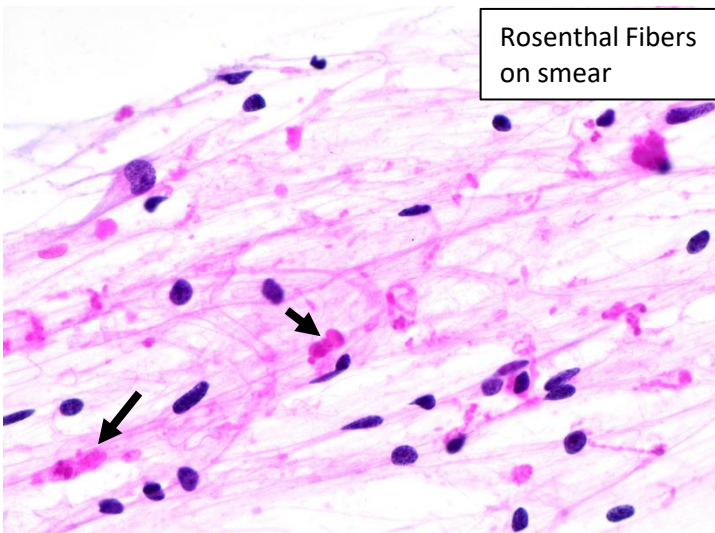
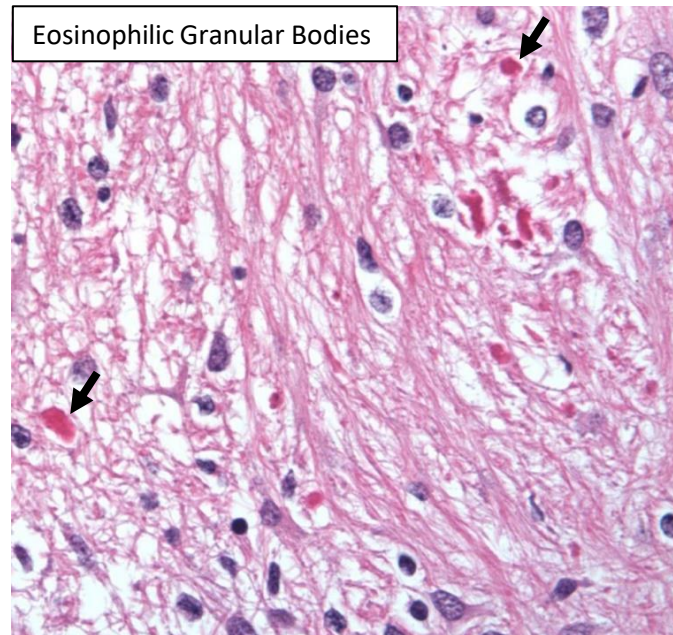
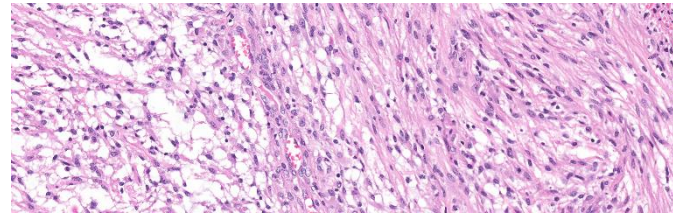
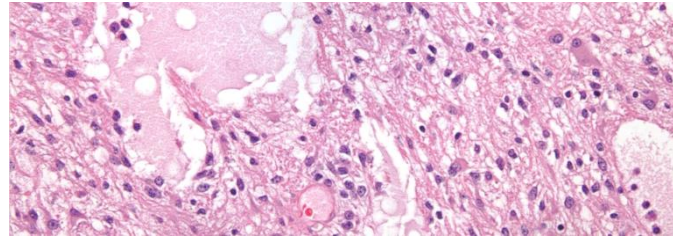
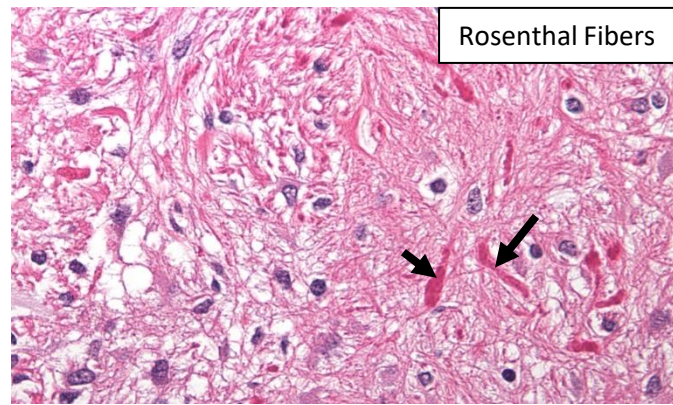
**Most common glioma in children and adolescents.** Preferentially infratentorial, located in the **cerebellum** and cerebral **midline structures** (e.g., optic pathways, brainstem, etc..).

Often present with neurologic deficits.

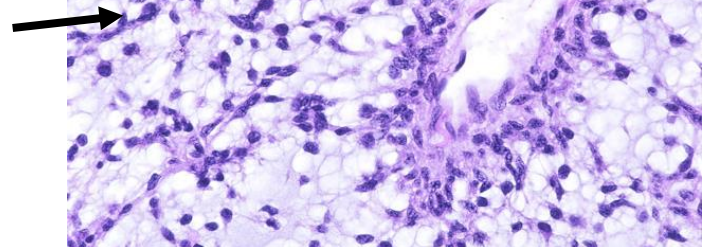
Generally **circumscribed** and **slow growing**. Sometimes **cystic**.

Mutations in MAPK pathway, most commonly **BRAF** fusion proteins.

**Slow-growing**, low-grade with **favorable prognosis**. Can be **cured with surgical excision** (if possible).



**Pilomyxoid astrocytoma**—variant with angiocentric arrangement of monomorphous, bipolar cells in a prominent myxoid background. May grow more rapidly and have worse prognosis. Not currently graded.





## Pleomorphic Xanthoastrocytoma ("PXA")

WHO grade II

Astrocytic tumor with **large, pleomorphic, and frequently multinucleated spindled and lipidized cells.**

Frequent intranuclear inclusions and prominent nucleoli.

Dense reticulin network.

Numerous eosinophilic granular bodies.

Often neuronal differentiation.

**Low mitotic activity** (<5 mitoses/10 HPF)

IHC/Molecular: Frequent **BRAF V600E**

(No IDH mutations!)

Majority have combo of BRAFV600E

AND CDKN2A/B homozygous deletion

(+) GFAP, S100

(+/-) Neuronal markers (e.g., MAP2), CD34

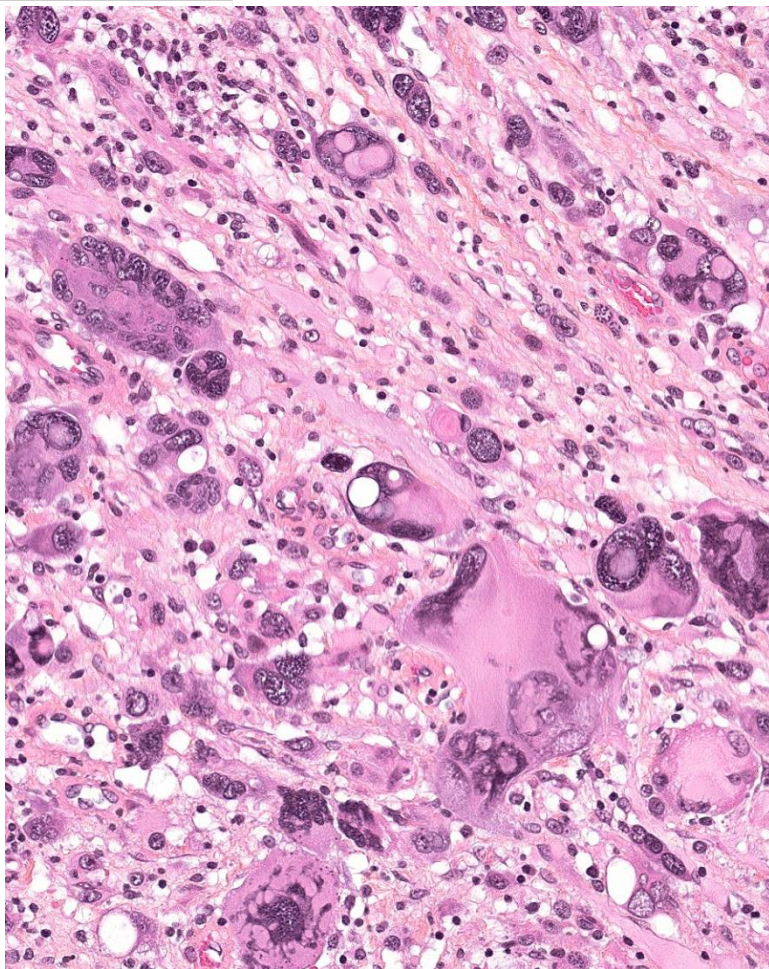
Ki67 generally <1%.

Relatively rare.

Most common in **children and young adults.**

Often superficially located in cerebral hemispheres (esp. temporal lobe) with involvement of leptomeninges.

**Good prognosis** with long survival.



## Anaplastic Pleomorphic Xanthoastrocytoma

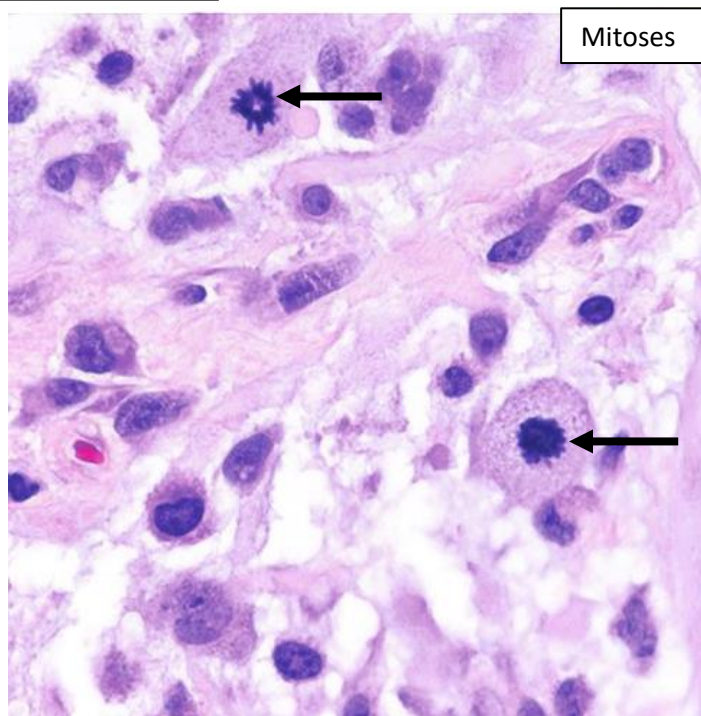
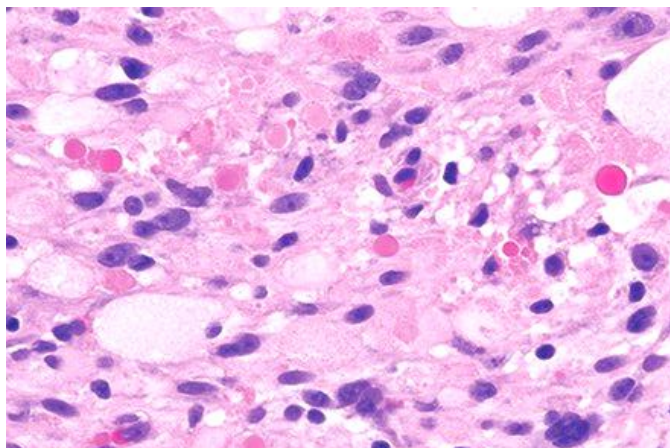
WHO grade III

Same as above, but **≥5 mitoses/10 HPF**

May have necrosis, but not necessary for Dx.


Lower frequency of BRAF V600E mutation.

**Significantly worse prognosis than PXA** (but still better than many high-grade gliomas)





# Oligodendrocyte Tumors



Diffusely infiltrating gliomas morphologically resembling *oligodendrocytes*.

\*\*\***Defining genetics: IDH1 or IDH2 mutations AND 1p/19q-codeletions.**\*\*\*

- An unbalanced translocation between chromosomes 1 and 19 results in loss of the der(1;19) chromosome, causing codeletion of whole arms of 1p and 19q
- it's acceptable if some cells show astrocytic differentiation if these genetic changes are present.
- IDH1 R132H mutations (present in >90%) can be detected by IHC.
- 1p/19q-codeletions are usually identified by FISH.
- Frequent TERT promoter mutations. Unlike in astrocytomas, there is no ATRX loss or p53 mutations

Usually adult patients in the cerebral hemispheres (esp. frontal lobe). Rare in children.  
Often present with seizures.

IHC: (+)MAP2, S100, SOX10, OLIG2, ; Usually (+) IDH1 R132H, Intact ATRX, wild-type p53.

## Oligodendroglioma WHO grade II

Moderately cellular, diffusely infiltrating.

**Monomorphic round nuclei with artifactual perinuclear halos** → “fried egg” or “honeycomb” appearance (only seen on formalin-fixed sections)

“Salt and pepper” chromatin

**Microcalcifications** and cystic degeneration common.

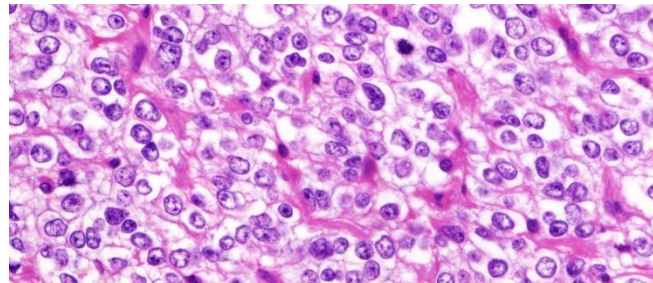
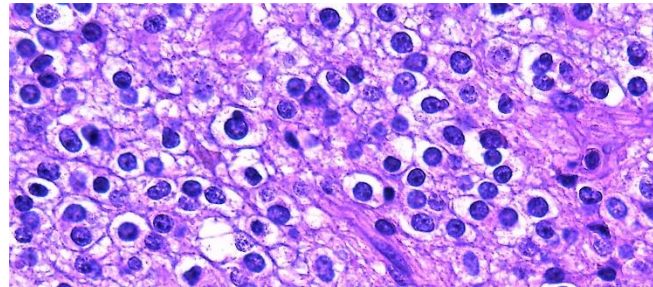
**Delicate branching capillary network.**

Low mitotic activity (rare mitoses acceptable)

Ki67 proliferation index usually < 5%

**Prolonged survival** → can be >11 years!

Generally recur. Malignant progression common (but much slower than astrocytomas).



## Anaplastic Oligodendroglioma

### WHO grade III

Similar to above, but with focal or diffuse histologic features of **anaplasia** (usually shows multiple):

- **Brisk mitotic activity** (often >6 per 10HPF)
- **Microvascular proliferation**
- **Spontaneous necrosis**

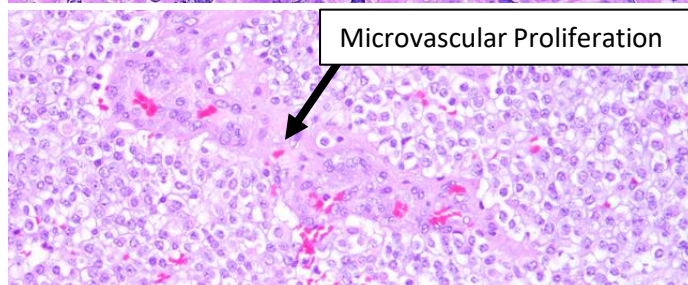
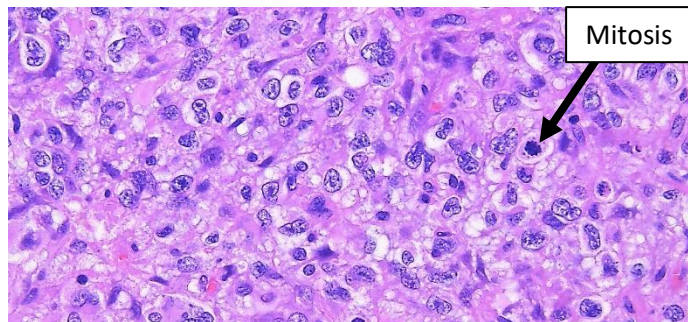
(Although some of these findings are also seen in GBM's, as long as the defining genetic alterations are present, you can still make this Dx).

Can sometimes see marked atypia.

Ki67 often >5%

Progression from grade II → grade III takes ~6 years, so patients often slightly older (middle-aged)

Shorter survival: ~3.5 years



# Ependymal Tumors

## Ependymoma

WHO grade II or III

**Circumscribed glioma**, composed of **uniform small cells with round nuclei and speckled chromatin in a fibrillary matrix**

Characteristic **pseudorosettes** (perivascular anucleate zones) found in practically every case.

True ependymal **rosettes** (bland cuboidal cells arranged around a central lumen) found in ~1/3 of cases.

Variable cellularity. Can hyalinize or have “canals.”

Mainly **intracranial**, can get in **spinal cord**.

Can occur in both children and adults.

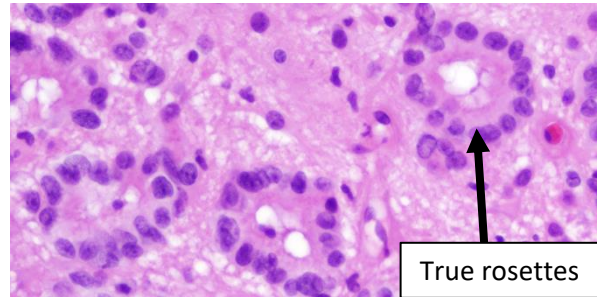
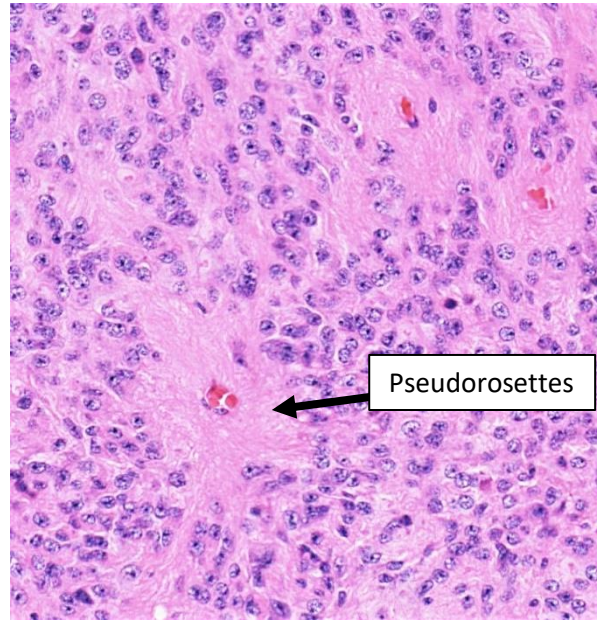
**In children** → usually **posterior fossa** (often 4<sup>th</sup> ventricle)

Generally low cell density and mitotic index.

Electron microscopy: shows cilia and microvilli.

IHC: **(+) EMA** (along lumina surface of rosettes or dot-like perinuclear), GFAP in pseudorosettes, S100.

Variable outcome depending on resection, therapy, and molecular group.



Pseudorosettes

True rosettes

**Current recommendation is to classify based on Location** (e.g., “Supratentorial ependymoma”) and **molecular changes** (see below). If there are no molecular changes, say “Not Elsewhere Classified” (NEC).

If can’t do molecular testing, say “Not Otherwise Specified” (NOS)

Can grade as 2 or 3 morphologically (default = 2; brisk mitotic activity and dense cellularity → grade 3)

Morphologic subtypes of ependymoma exist (tancytic, clear cell, papillary), but do not impact prognosis. Subependymoma and myxopapillary ependymoma are identified morphologically.

## Unique Molecular Subgroups by Location:

Location	Molecular Subgroup	Age	Prognosis	Comments
Supratentorial (ST)	YAP1-fusion	Infants and kids	Good	
	RELA-fusion ( <i>c11orf95</i> )	Infants to adults	Poor	IHC: Positive for cyclinD1 and L1CAM
Posterior Fossa (PF)	Methylation group A (PFA)	Infants	Poor	IHC: Loss of H3K27me3
	Methylation group B (PFB)	Older children and adults	Good	IHC: Retained H3K27me3
Spinal Cord (SC)	MYCN amplified	Older children and adults	Poor	Frequent dissemination



## Subependymoma WHO grade I

Slow-growing, exophytic, and intraventricular.

Clusters of mostly bland cells embedded in abundant fibrillary matrix.

No significant mitotic activity.

Frequent microcystic change. Sometimes calcified.

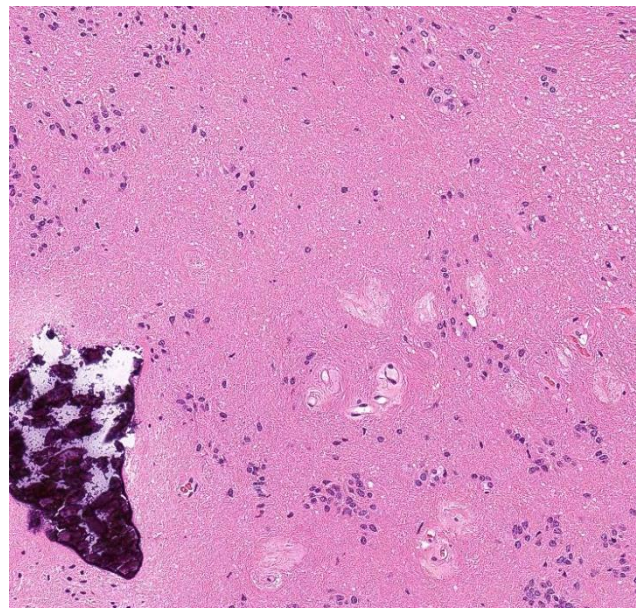
Rare pseudorosettes.

Often detected incidentally → often asymptomatic.

All ages. Sharply demarcated grossly.

IHC: (+) GFAP; (-) EMA (unlike ependymoma); Ki67 <1%

Excellent prognosis



## Myxopapillary Ependymoma

**WHO grade II**

Arises almost exclusively in region of conus medullaris, cauda equina, and filum terminale.

Elongated to cuboidal cells arranged in radial patterns around vascularized, mucoid, fibrovascular cores

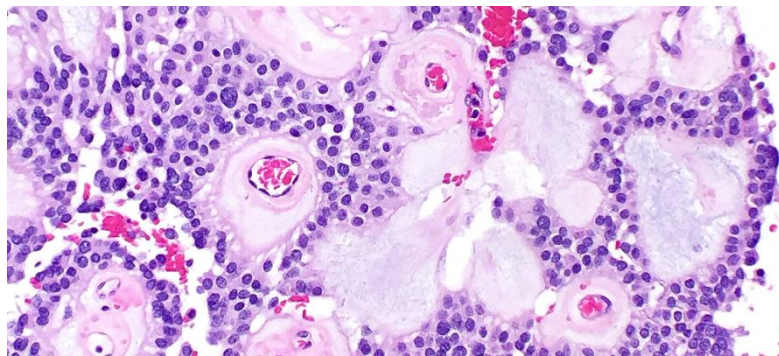
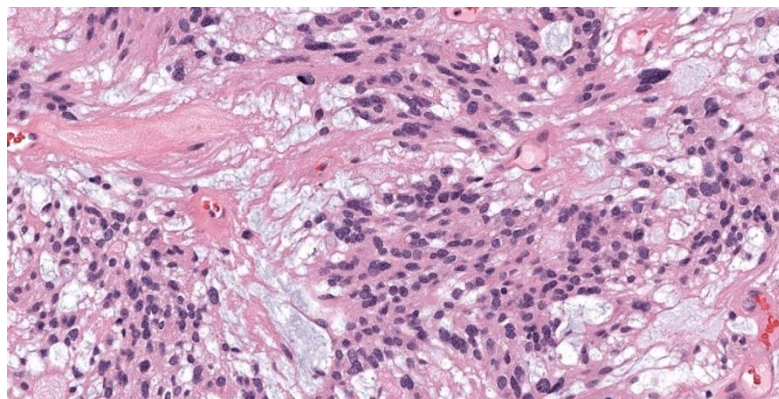
Slow-growing.

Typically occurs in young adults.

Stains: Mucin is highlighted by alcian blue  
(+) GFAP, S100, CD99, CK AE1/AE3

Thought to have a **favorable prognosis**, but sometimes hard to resect with recurrences.

Was previously WHO grade I, but current data suggests actually grade II.



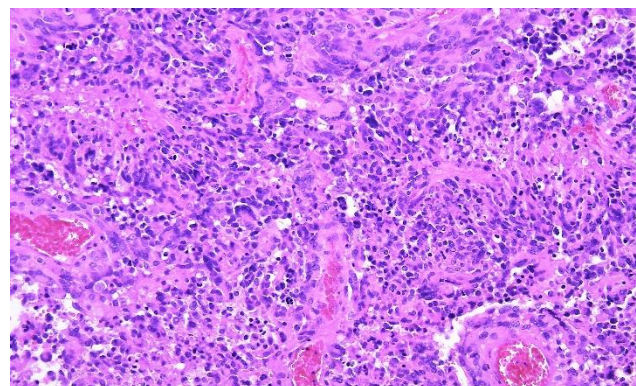
## Anaplastic Ependymoma

**WHO grade III**

Was a category in the 2016 WHO, but will no longer be with next edition as WHO grade doesn't seem to significantly impact prognosis in ependymomas.

Defined by high cell density and elevated mitotic count.

Also may see widespread microvascular proliferation and necrosis.





## Other Gliomas

### Chordoid Glioma (of the Third Ventricle)

#### WHO grade II

Slow-growing, non-invasive, glial tumor. Very rare.  
Located in 3<sup>rd</sup> ventricle → obstructive hydrocephalus

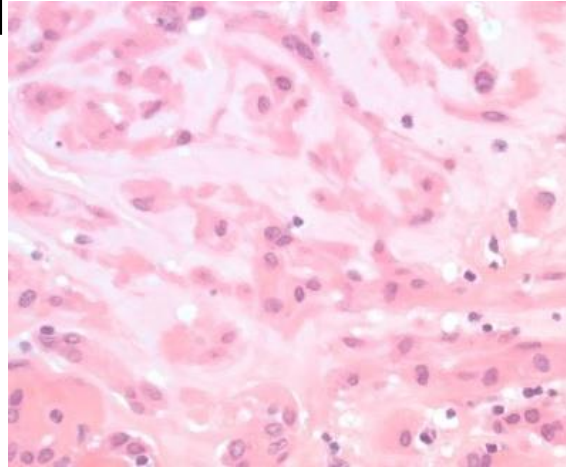
Clusters and cords of epithelioid tumor cells within variably **mucinous stroma**.

Typically has associated lymphoplasmacytic infiltrate.

IHC: (+) **GFAP** (strong, diffuse), TTF-1, CD34; (+/-) S100, CK

Usually Adults.

Good prognosis if resected.



### Angiocentric Glioma WHO grade I

Stable or **slow-growing**. **Well-circumscribed**.

Primarily impacts **children** and young adults.

Presents with **epilepsy**.

Superficial cerebrocortical location.

**Angiocentric growth pattern**.

**Monomorphous bipolar cells**, oriented around cortical blood vessels.

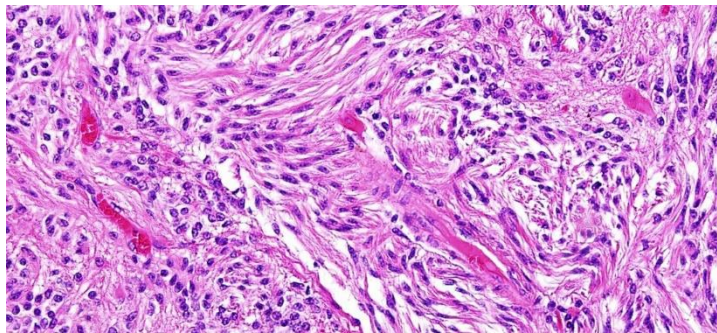
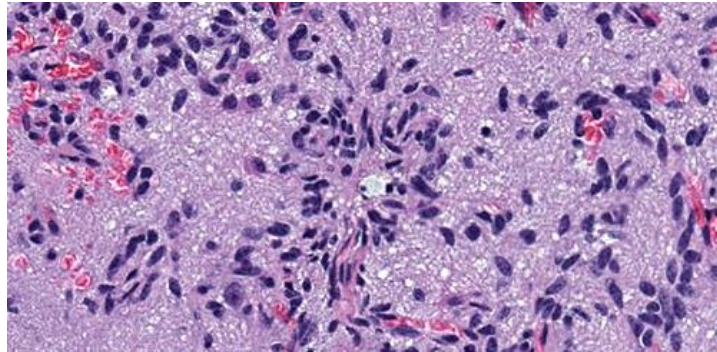
Can resemble pseudorosettes of ependymomas.

Other areas can resemble schwannoma with fibrillary areas.

IHC: (+) GFAP, EMA (like ependymoma)

Molecular: **MYB fusions** (usually **MYB-QKI**)

**Excellent prognosis** → usually cured by excision



### Astroblastoma

**Rare**. Mainly children and adolescents.  
Well-demarcated. Within cerebral hemispheres.

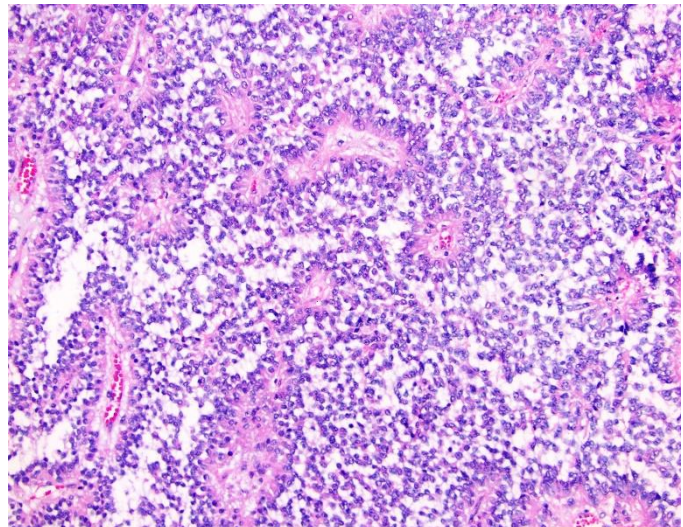
Cells with broad processes radiating towards central blood vessels (astroblastic pseudorosettes).

Frequent vascular hyalinization.

IHC: (+) GFAP, S100

Molecular: Commonly with **MN1-alterations**

Biologic behavior varies → not currently graded.





# Choroid Plexus Tumors

Derived from **choroid plexus epithelium**; Found in **Ventricles**.  
IHC: (+) KIR7.1, CK AE1/AE3, Vimentin, CK7. (+/-) S100. (-) EMA,

## Choroid Plexus Papilloma

### WHO grade I

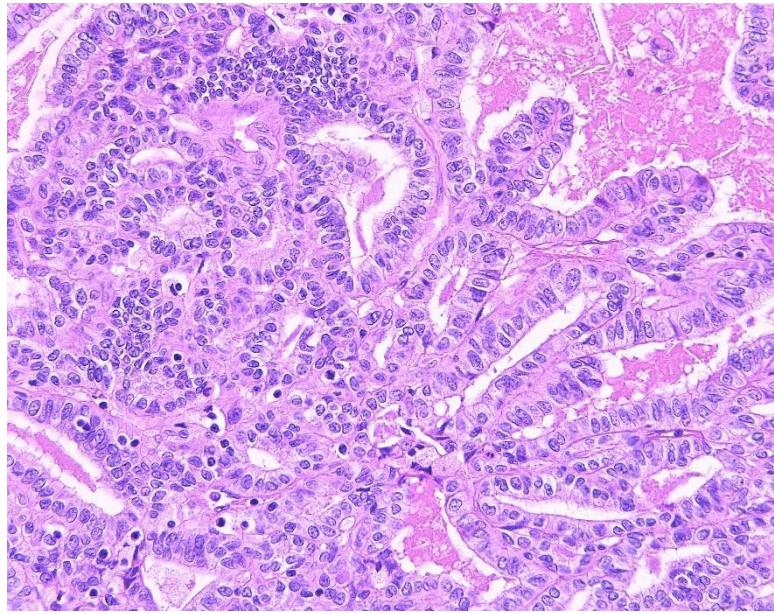
#### **Benign ventricular papillary neoplasm.**

Most common in lateral ventricle  
~2/3 of choroid plexus tumors.  
All ages, but more common in kids.  
Can present with hydrocephalus.

Delicate fibrovascular fronds covered by a single layer of cuboidal to columnar epithelium.

Round to oval, basal, **monomorphic nuclei**.  
**Very low/absent mitotic activity** (<2/10 HPF)  
Ki67 usually <2%

Patients usually cured by surgical resection.



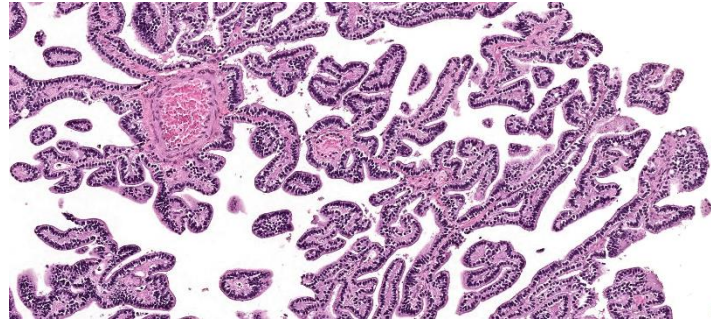
## Atypical Choroid Plexus Papilloma

### WHO grade II

A choroid plexus papilloma that has **increased mitotic activity** ( $\geq 2$  mitoses/10 HPF), but does not fulfill the criteria of choroid plexus carcinoma.

Often present, but not required: increased cellularity, nuclear pleomorphism, solid growth, necrosis.

**More likely to recur**, but still relatively good prognosis.



## Choroid Plexus Carcinoma

### WHO grade III

#### **Frankly malignant epithelial neoplasm.**

Most commonly in the **lateral ventricles** of **children**

#### **At least 4 of the following:**

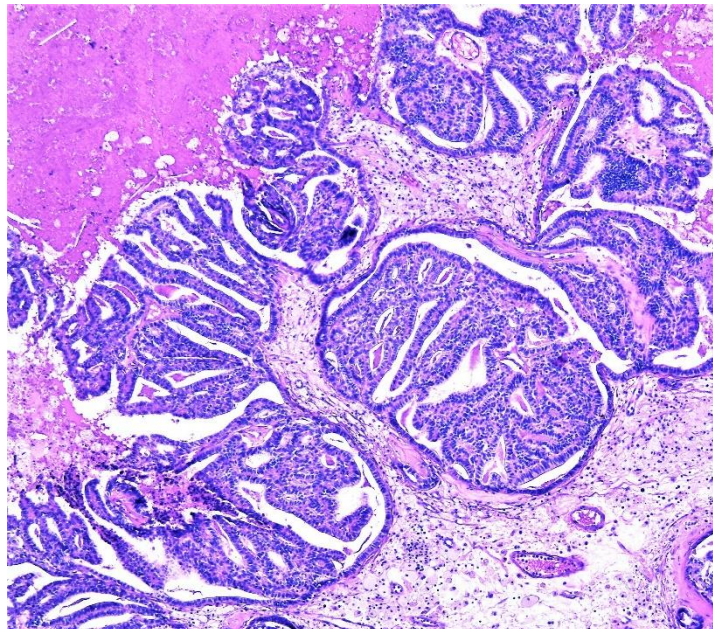
- 1) Frequent mitoses ( $>5/10$  HPF)
- 2) Increased cellular density
- 3) Nuclear pleomorphism
- 4) Blurring of the papillary pattern with poorly-formed sheets of tumor cells
- 5) Necrosis

**Frequently invades neighboring brain and metastasizes via CSF.**

Ki67 often  $>10\%$

~1/2 have TP53 mutations

Intermediate prognosis/survival





# Neuronal and Mixed Neuronal-Glial Tumors

## Dysembryoplastic Neuroepithelial Tumor (“DNET”)

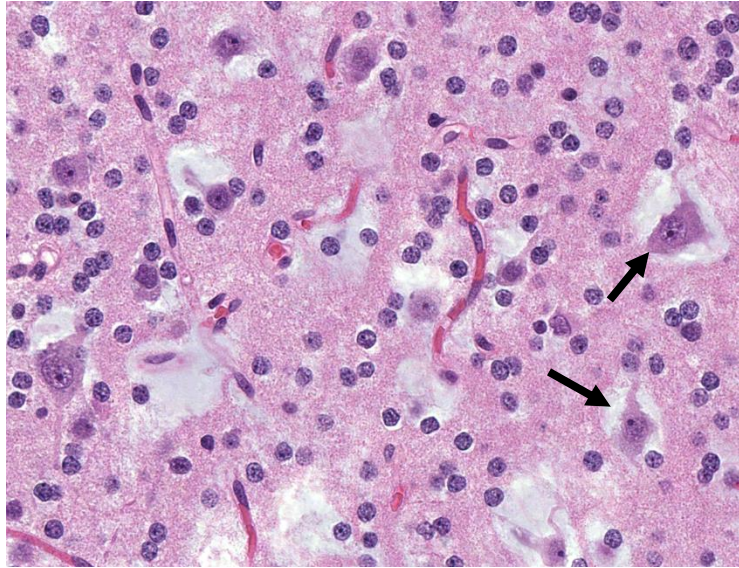
WHO grade I

Benign glioneuronal neoplasm.  
Usually **Children** or young adults.  
Typically **temporal lobe**. Often cortical.  
Present with early onset **epilepsy**.

Columns of **small round monotonous cells** (oligodendroglioma-like) oriented perpendicular to the cortical surface formed by axon bundles.  
Normal **neurons “floating” in mucin pools** (→).  
Multinodular architecture.  
May be associated with cortical dysplasia.

Molecular: Presence of an IDH mutation or Codeletion of 1p/19q **excludes** this Dx.

**Excellent outcomes**



## Ganglioglioma WHO grade I

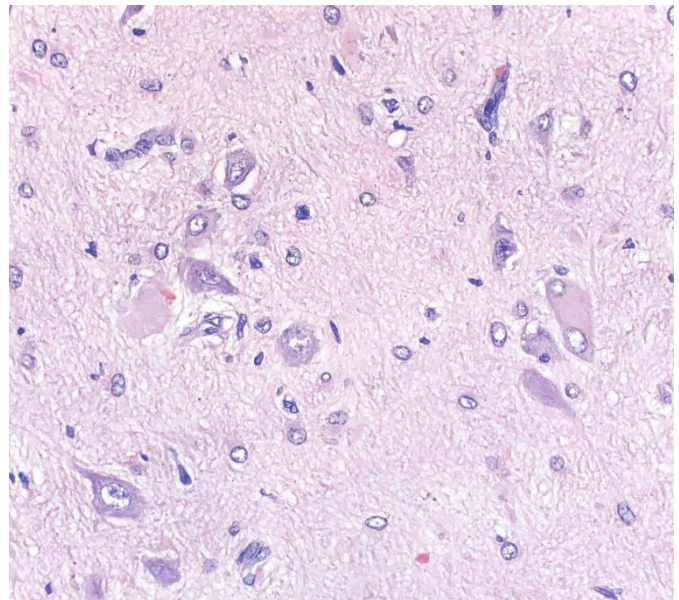
Well-differentiated, slow-growing.  
Often in the **temporal lobe** of **young children**.  
Intracortical, circumscribed, and **cystic**  
Frequently present with early-onset focal **epilepsy**.

**Dysplastic ganglion cells** (dysmorphic neuronal features, without the architectural arrangement or cytological characteristics of cortical neurons) with **neoplastic glial cells** (may resemble astrocytoma, oligodendroglioma, or pilocytic astrocytoma)  
Can be **heterogenous** within tumor.

Molecular/IHC: BRAF V600E mutation in about ¼  
Presence of an IDH mutation or Codeletion of 1p/19q **excludes** this Dx.

**Excellent outcomes**

If increased cellularity, pleomorphism, mitotic figures, microvascular proliferation, and/or necrosis within glial component, consider “**Anaplastic Ganglioglioma**” (WHO grade III). Uncertain outcomes.

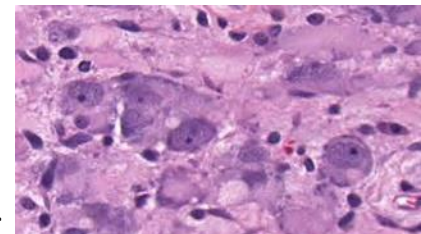


## Gangliocytoma WHO grade I

Rare. Slow-growing. Usually Children with epilepsy  
Composed of **irregular clusters of mature neoplastic ganglion cells**, often with dysplastic features. **Stroma of non-neoplastic glial elements**.

**May be hard to distinguish from Ganglioglioma** in some cases (spectrum).

**Dysplastic cerebellar gangliocytoma** (Lhermitte-Duclos Disease)—Rare, benign, cerebellar tumor.  
Dysplastic ganglion cells that conform to existing cortical architecture. Major manifestation of **Cowden’s Syndrome** (PTEN hamartoma syndrome).





## Papillary Glioneuronal Tumor

### WHO grade I

Low-grade biphasic neoplasm with:

**1) Prominent pseudopapillary architecture** with a uboidal glial cells with round nuclear and scant cytoplasm around hyalinized blood vessels.

**2) Intervening collections of neurocytes** with medium-sized **ganglion cells** with neuropil.

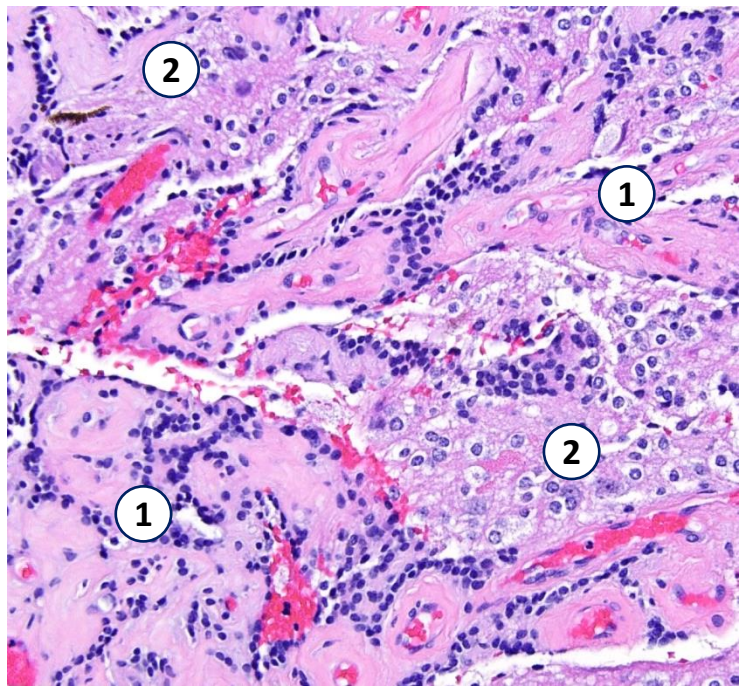
Can be have fibrillary or microcystic background.

Often in the **cerebral hemispheres near the ventricles**.

Often **young adults**. Circumscribed.

Molecular: Frequent **SLC44A1-PRKCA** fusions

**Good prognosis.**



## Desmoplastic Infantile Astrocytoma (DIA) and Ganglioglioma (DIG)

### WHO grade I

Rare neoplasms of **early childhood**.

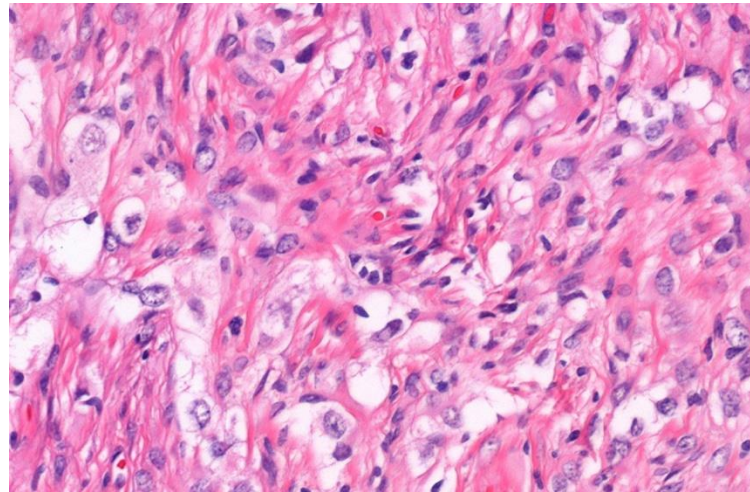
Always supratentorial. Often large and cystic.

Leptomeningeal component.

**Prominent desmoplastic stroma with a neuroepithelial population of astrocytes (DIA) possibly with a mature neuronal component (DIG).**

Abundant connective tissue → Prominent reticulin → may mimic a mesenchymal tumor!

**Good prognosis.**



## Rosette-forming Glioneuronal Tumor

### WHO grade I

Two distinct components:

**1) Uniform neurocytes forming rosettes**

and/or perivascular pseudorosettes

**2) An astrocytic component** resembling a pilocytic astrocytoma

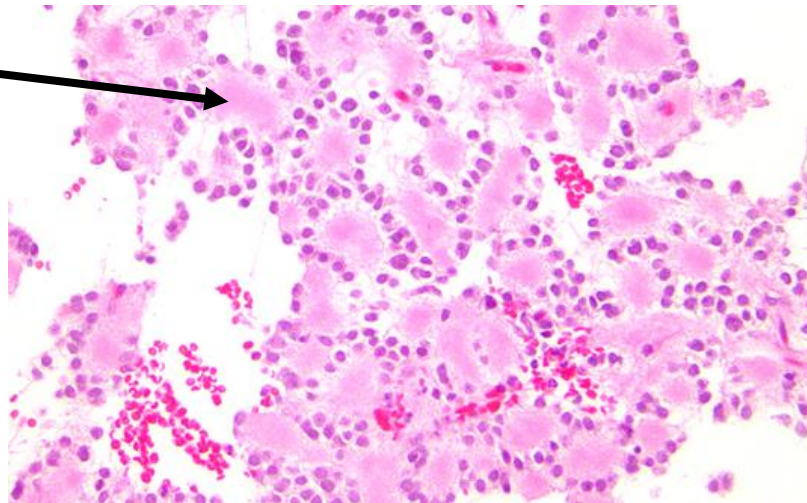
Slow-growing. Relatively well-circumscribed.

Most common in the **4<sup>th</sup> ventricle**.

Typically **children or young adults**.

Molecular: **PIK3CA** and **FGFR1** mutations

**Relatively good prognosis.**





## Diffuse Leptomeningeal Glioneuronal Tumor

Rare. Usually young children. Spine or Intracranial.

**Predominant and Widespread leptomeningeal growth.**

**Oligodendroglioma-like morphology,**

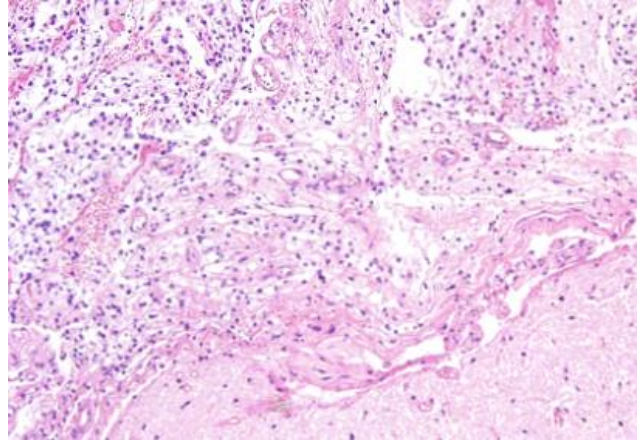
Neuronal differentiation in a subset of cases.

Usually low-grade appearing. Occasional anaplasia.

Molecular: **Frequent KIAA1549-BRAF fusions and either 1p deletion or 1p/19q codeletion in the absence of an IDH mutation.**

Not currently graded (too rare).

**Slow progression** over many years.



## Central Neurocytoma

### WHO grade II

Uncommon. **Intraventricular**, often lateral.

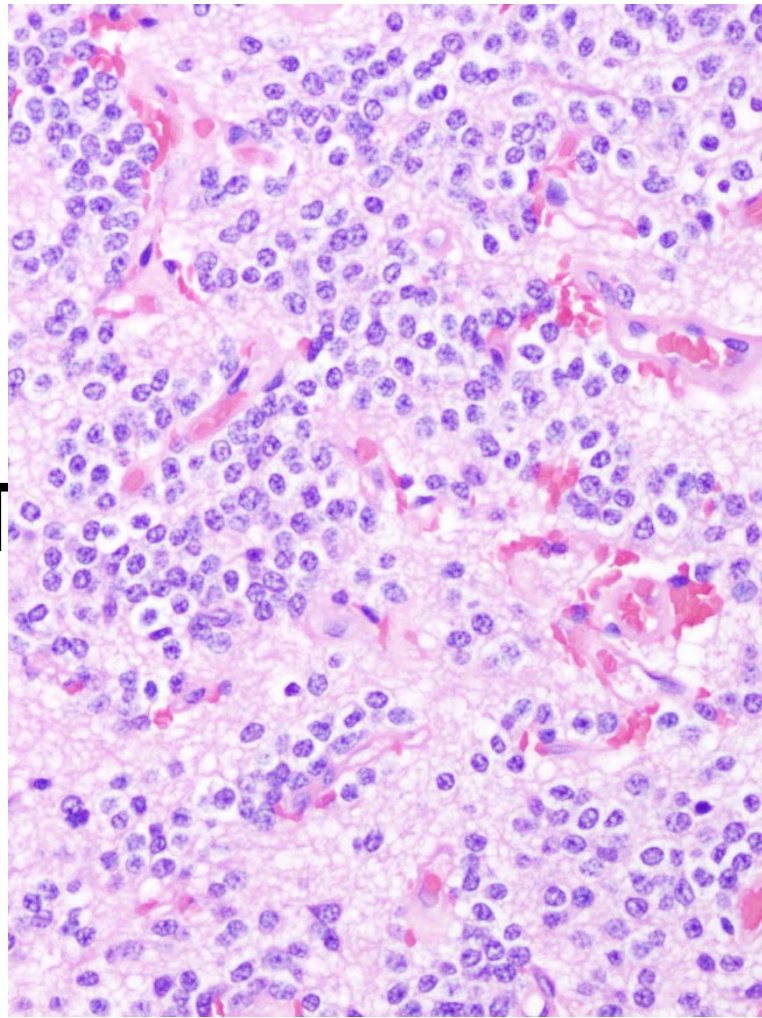
Usually young adults.

**Uniform round cells with speckled chromatin and a neuronal immunophenotype**

(+Synaptophysin, - GFAP)

Fibrillary areas may mimic neuropil or ependymal pseudorosettes.

**Favorable prognosis.**



## Extraventricular Neurocytoma

### WHO grade II

Present throughout CNS, often cerebrum,

without ventricular association.

Well-circumscribed. Slow-growing.

Histologically similar to central neurocytoma, but more varied in appearance.

Wide age range, often middle-age.

Must rule out a diffuse glioma → make sure no IDH mutations.

Favorable prognosis.

## Other

**Cerebellar Liponeurocytoma** (WHO grade II)—a rare **cerebellar** tumor with a mixture of small **neurocytic cells with regular round nuclei and focal lipoma-like changes** (just lipid in tumor cells, not actual adipocytes). Adults. Favorable prognosis.

**Paranglioma** (WHO grade I)—like elsewhere, “Zellballen” nests of cells surrounded by a delicate sustentacular network. Most common in cauda equina and jugulotympanic regions.



# Embryonal Tumors

## Medulloblastoma WHO grade IV

Most common *malignant* brain tumor of **childhood**.  
 Arise in **cerebellum** or dorsal brainstem.  
 Block CSF flow → increased ICP → short history of headaches, nausea, ataxia.  
 Propensity to spread through CSF.

Embryonal neuroepithelial tumor consisting of densely packed **small round undifferentiated cells**.  
**High N:C ratios**. Variable **rosettes** (Homer-Wright)  
 Usually mild to moderate pleomorphism.  
**High mitotic rate**.

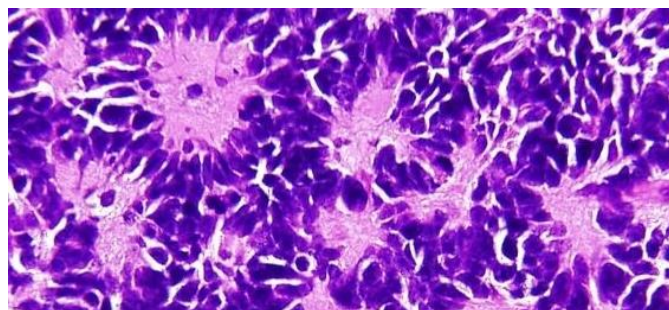
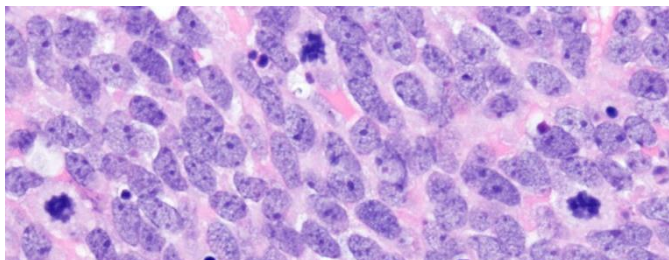
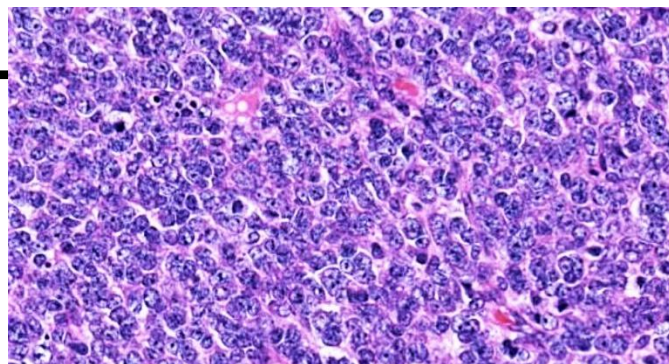
IHC: Diffuse synaptophysin. Focal NeuN

Currently, can be classified by molecular or histologic findings (or, ideally, both!).

Commonly altered pathways:

**SHH Pathway** = “Sonic Hedge Hog”

**WNT Pathway**—often through CTNNB1 (β-catenin )



	WNT-activated	SHH-activated		Non-WNT/Non-SHH		
		TP53-Wildtype	TP53-Mutant	Group 3	Group 4	
<b>Age</b>	Childhood	Infancy or Adult	Childhood	Infancy/ Childhood	All	
<b>Proportion</b>	~10%	~20%	~10%	~20%	~40%	
<b>Usual Histology</b>	<b>Classic</b>	<b>Desmoplastic/ Nodular</b>	<b>Large cell/ Anaplastic</b>	<b>Classic, Large cell/Anaplastic</b>	<b>Classic</b>	
<b>Genetic Changes</b>	<b>CTNNB1 mutations</b>  Monosomy 6	<b>PTCH1 mutation/loss</b>	<b>TP53 mutation</b>	<b>MYC amplification</b> PVT1-MYC fusions often	<b>KDM6A, SNCAIP</b> among others	
<b>Prognosis</b>	<b>Excellent</b>	<b>Low-risk</b> (Standard if classic histology)	<b>Poor</b>	<b>High-risk</b> (Standard if classic histology)	<b>Standard</b>	
<b>Immunohistochemistry</b>	<b>β-catenin</b> (WNT pathway)	Nuclear + Cytoplasmic	Cytoplasmic	Cytoplasmic	Cytoplasmic	Cytoplasmic
	<b>GAB1</b>	Negative	Cytoplasmic	Cytoplasmic	Negative	Negative
	<b>FilaminA</b>	Cytoplasmic	Cytoplasmic	Cytoplasmic	Negative	Negative
	<b>YAP1</b>	Nuclear + Cytoplasmic	Nuclear + Cytoplasmic	Nuclear + Cytoplasmic	Negative	Negative



## **Medulloblastoma Histologic Subtypes:**

**Classic**—see prior page (lack features below). Most common histology.

**Desmoplastic/Nodular**—nodular reticulin-free zones (“pale islands”) with intervening densely packed, poorly differentiated cells that produce an intercellular network of reticulin fibers.

↕ *Significant overlap. Both SHH-pathway, TP53-wt.*  
↕ *Good prognosis. Often considered together.*

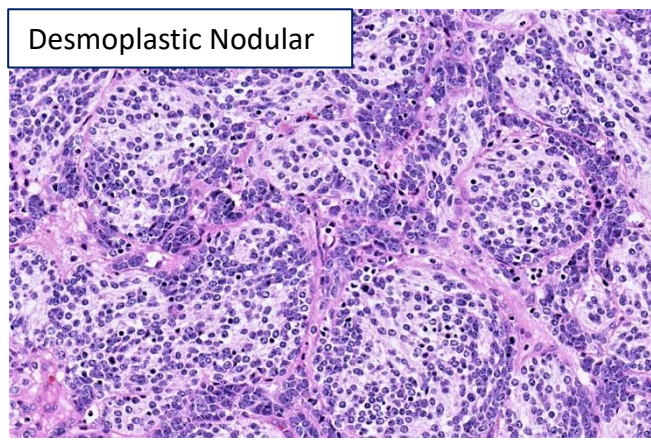
**Extensive Nodularity**—many, large, reticulin-free nodules of neurocytic cells against a neuropil-like matrix. Narrow internodular strands.

**Anaplastic**—marked nuclear pleomorphism with particularly numerous mitoses and apoptoses. Frequent nuclear molding and cell wrapping.

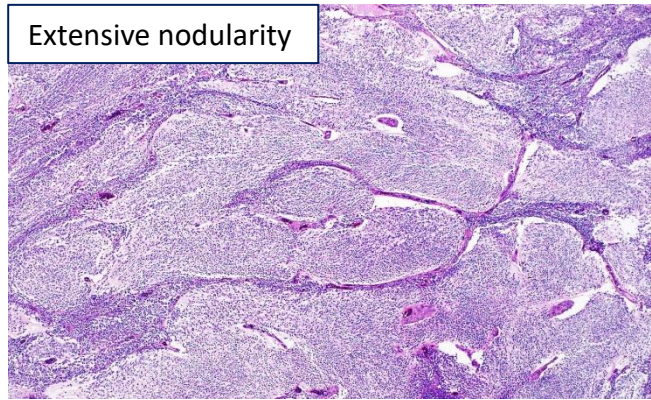
↕ *Significant overlap. Often group 3 or SHH, TP53-mutant. High risk. Often considered together.*

**Large Cell**—Large, monomorphic cells with prominent nucleoli.

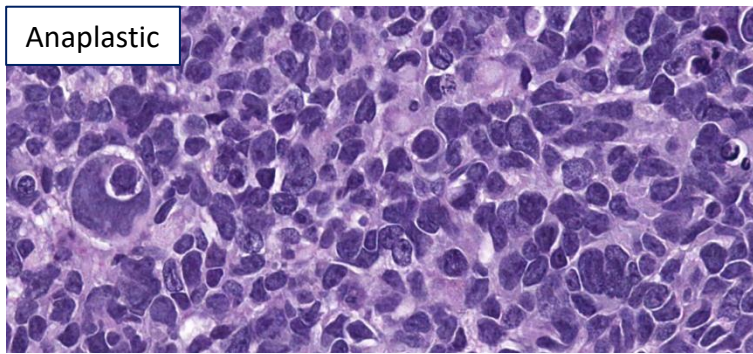
Desmoplastic Nodular



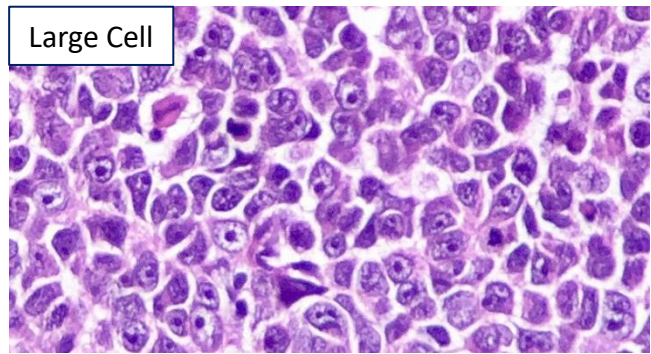
Extensive nodularity



Anaplastic



Large Cell



## **Embryonal Tumor with Multilayered Rosettes, C19MC-altered**

### **WHO grade IV**

*Includes previous entities of: Medulloepithelioma, Ependyoblastoma, and Embryonal tumor with abundant neuropil and true rosettes.*

**Defining molecular alteration: C19MC (microRNA) upregulation** via amplifications and fusions

Variable morphology, often including:

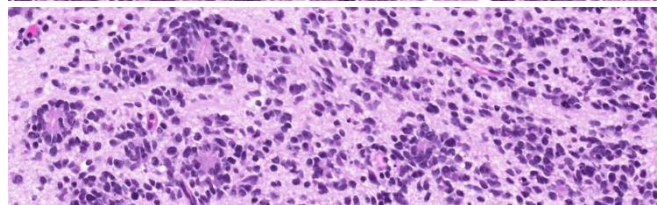
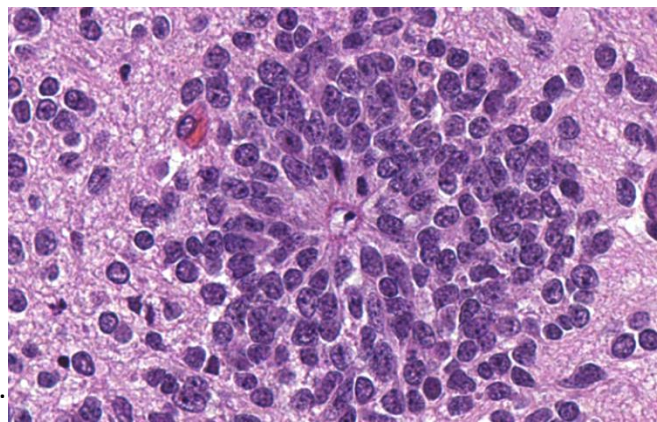
**Multilayered rosettes** consisting of pseudostratified neuroepithelium with a central, round or slit-like lumen.

Numerous mitotic figures.

Fibrillary neuropil-like areas.

Often **young children**. Most often cerebral.

**Aggressive** course.





## Atypical Teratoid/Rhabdoid Tumor (“AT/RT”)

WHO grade IV

Most often in **young children**. Variable location.

**Rhabdoid cells** with eccentric nuclei with vesicular chromatin and prominent nucleoli.

**Abundant eosinophilic cytoplasm.**

**Abundant mitoses. Geographic necrosis.**

Most tumors contain *other* poorly-differentiated elements with neuroectodermal, epithelial, and/or mesenchymal differentiation, including a small cell embryonal component, spindle cell component, or even gland-like areas.

**Molecular/IHC (required for Dx): Loss of SMARCB1**

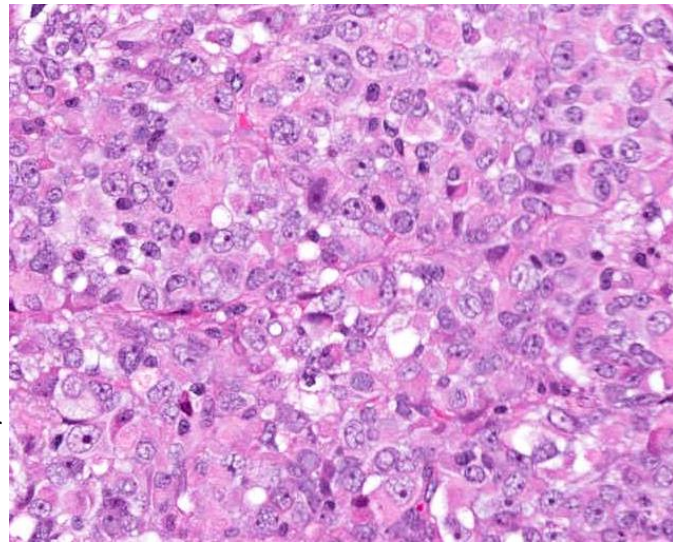
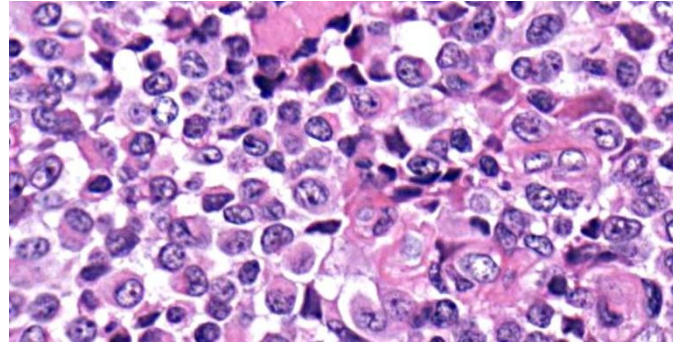
**(INI1)** [rarely loss of SMARCA4 (BRG1)]—part of SWI/SNF chromatin remodeling complex.

(+)EMA, SMA, (+/-)GFAP, CK, Synaptophysin.

Ki67 usually >50%

**Aggressive** course.

If INI1 and BRG1 are intact (or you are unable to test for these)→ “*CNS embryonal tumor with rhabdoid features*”



## CNS Embryonal Tumor, NOS

WHO grade IV

Poorly-differentiated embryonal tumors of neuroectodermal origin that do not have the histopathologic/molecular alterations of the tumors listed above.

High-grade with aggressive clinical courses.

### ***Biomarkers that might help in the classification of small cell, embryonal-appearing tumors:***

Biomarker	Associated Tumor
C19MC amplification or LIN28A expression	Embryonal tumor with multilayered rosettes
SMARCB1 or SMARCA4 loss	Atypical Teratoid/Rhabdoid Tumor
H3 K27 mutations	Diffuse Midline Glioma, H3 K27M-mutant
C11orf95-RELA fusion gene or L1CAM expression	Supratentorial ependymoma
IDH1 or IDH2	Adult-type diffuse gliomas
CTNNB1 mutations (nuclear $\beta$ -catenin)	Medulloblastoma, WNT-activated
GAB1 or YAP1 staining	Medulloblastoma, SHH-activated



## Pineal Tumors

Often block aqueduct → increased intracranial pressure → Headache, papilledema, brainstem/cerebellar dysfunction (ataxia), nausea, etc..

### Pineocytoma WHO grade I

**Uniform, small, mature cells** (resembling normal pineal cells) that **grow primarily in sheets and often form large pineocytomatous rosettes** (not in normal pineal gland) and/or pleomorphic cells showing gangliocytic differentiation.

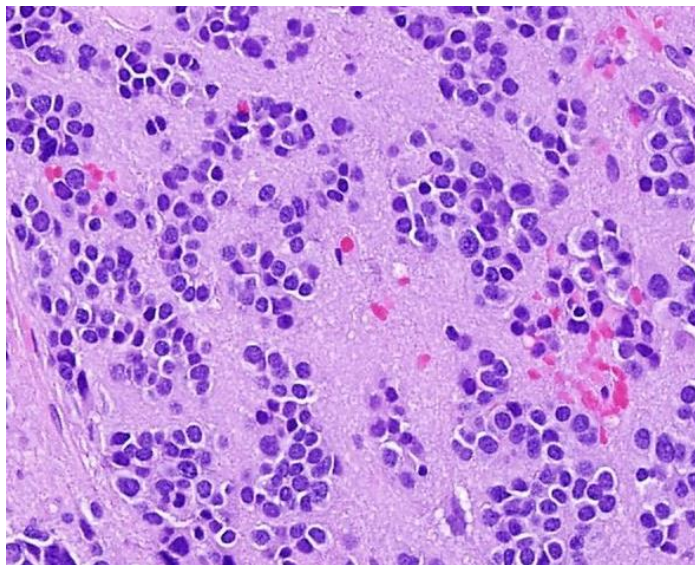
Round nuclei with fine chromatin. Lots of processes.  
**No mitotic activity** (<1 per 10 HPF). Ki67 usually <1%.

Rare. Usually **adults**.

Exclusive localization in **pineal region**

**Well-demarcated, solid mass without infiltration or dissemination.**

**Good prognosis.**



### Pineoblastoma WHO grade IV

*Resembles other primitive neuroectodermal tumors (e.g., medulloblastoma)*

Poorly-differentiated, highly cellular embryonal tumor.

**Patternless sheets of small immature neuroepithelial cells.**

High N:C ratio. Hyperchromatic.

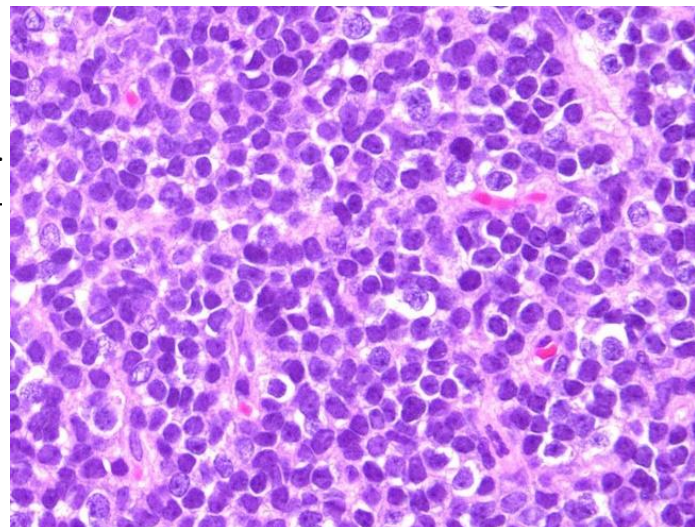
**Frequent mitoses.** Ki67 >20%. Necrosis common.

No pineocytomatous rosettes, but may see Homer-Wright rosettes

Most often young adults/adolescents.

Invasively spread via CSF.

**Aggressive** clinical course.



### Pineal Parenchymal Tumor of Intermediate Differentiation ("PPTID")

**Intermediate malignancy between Pineoblastoma and Pineocytoma.**

Diffuse sheets or large lobules of monomorphic round cells that appear more differentiated than in pineoblastoma.

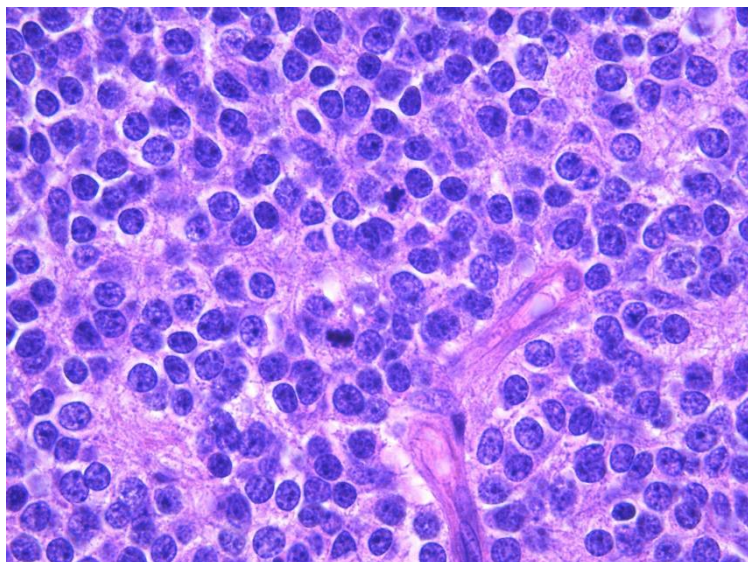
Pleomorphic cells may be present.

**Mitotic activity low to moderate.**

**Ki67 elevated (often >5%)**

Mainly adults.

**Variable outcome, currently without grading criteria**





## Papillary Tumor of the Pineal Region

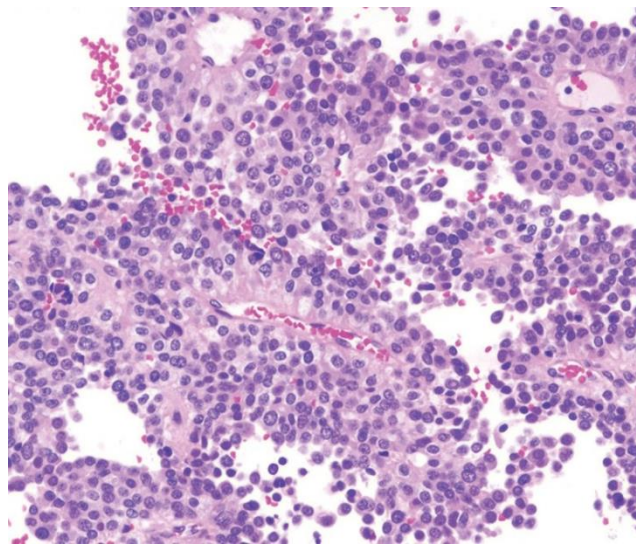
**Papillary tumor of the pineal region with densely cellular areas exhibiting ependymal-like differentiation** (with true rosettes and tubes). May have solid areas. Nuclei mostly round and stippled.

**Moderate mitoses with moderate Ki67** (median ~7%)

**IHC: React with cytokeratins** (unique), S100, NSE, (-)EMA. (+/-) GFAP

No grading criteria (too rare).

**Frequent local recurrences.**



## Dural Tumors

### Meningioma

**Dural, mostly benign, slow-growing.**

Derived from Meningothelial cells of arachnoid layer.

*General classic findings:*

**Oval nuclei** with delicate chromatin.

Frequent **intranuclear pseudoinclusions**.

**Syncytial tumor cells with abundant eosinophilic cytoplasm.**

Numerous **whorls**. Occasional **psammoma bodies**.

Most frequent brain tumor in USA.

Often **older adults** (risk increases with age).

More common in females.

On imaging have characteristic **“dural tail”**

**Grossly rubbery/firm.**

**IHC: (+) Somatostatin Receptor 2A (SSTR2A)** is likely the most sensitive/specific. Also, **(+) EMA, Vimentin, PR.** (+/-) S100.

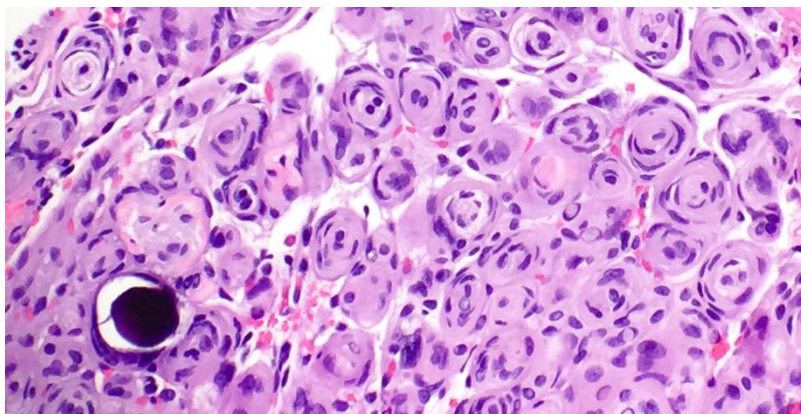
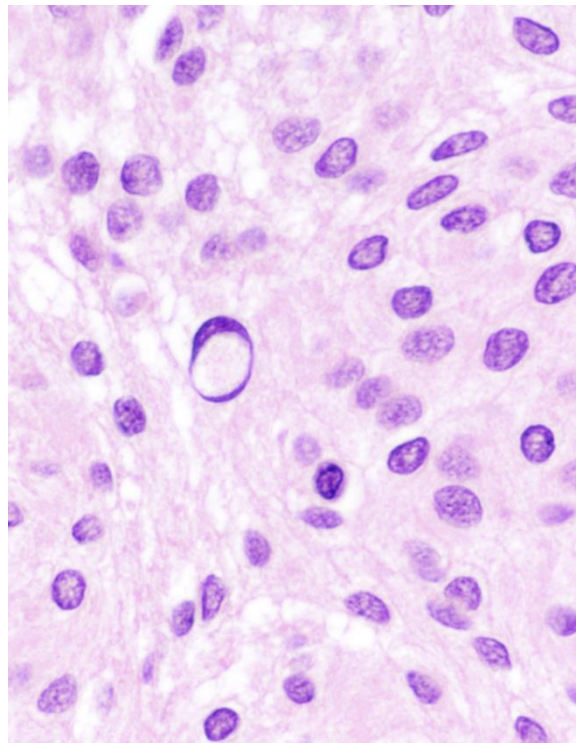
Ki67 varies often with grade.

Molecular: **NF2 mutations common.** Cytogenetic alterations.

Variable histologic findings with specific grades (see next page). The criteria to diagnose atypical and anaplastic meningiomas are assigned regardless of subtype.

**Outcome is associated with grade.**

Higher grade = more likely to recur/progress





**Grades regardless of subtype:** Sometimes only focal changes.

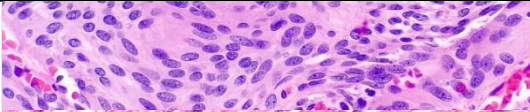
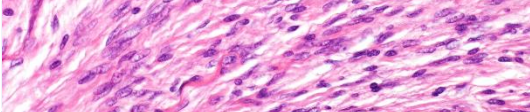
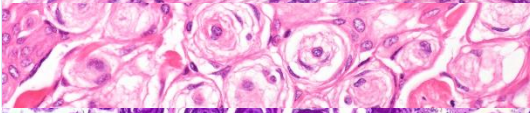
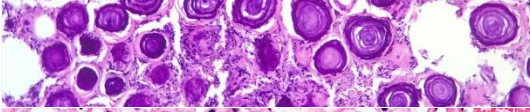
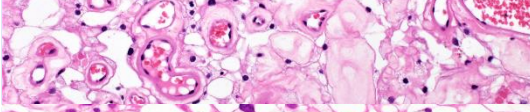
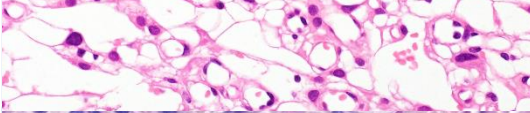
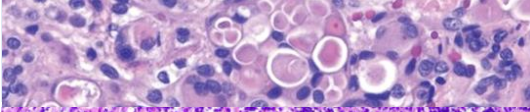
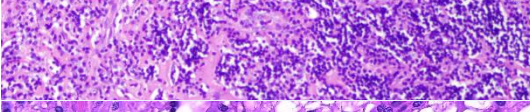
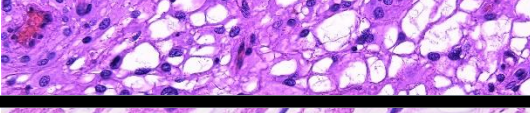
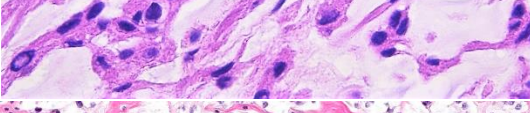
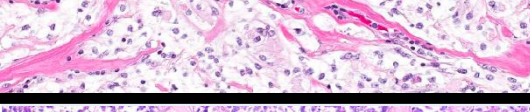
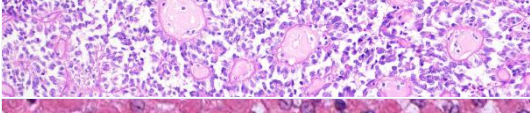
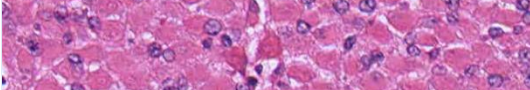
**Atypical Meningioma (WHO grade II)** (Need either 1 of major criteria or 3/5 minor criteria)

A meningioma with either: **increased mitotic activity** ( $\geq 4$  per 10 HPF), **brain invasion** (tongue-like protrusions), or at least 3 of the following: 1) Increased cellularity, 2) Small cells with high N:C ratios, 3) Sheet-like growth (patternless, uninterrupted), 4) Spontaneous tumor-type necrosis, 5) Macronucleoli.

**Anaplastic Meningioma (WHO grade III)**

**Overtly malignant** cytology (resembling carcinoma, melanoma, or sarcoma) and/or **markedly elevated mitotic rate** ( $\geq 20$  per 10 HPF). Often contain necrosis and have Ki67  $>20\%$ .

**Common Subtypes:** Usually want  $>50\%$  of tumor to have this morphology.

Type	Grade	Description	
<b>Meningothelial</b>	1	Classic (typical) morphology as described on previous page. Most common. Lobulated architecture.	
<b>Fibrous</b>	1	Spindled cells forming parallel to storiform bundles with abundant collagen matrix.	
<b>Transitional (mixed)</b>	1	Meningothelial + Fibrous with conspicuous whorls and psammoma bodies.	
<b>Psammomatous</b>	1	Predominance of psammoma bodies over tumor cells. Often thoracic.	
<b>Angiomatous</b>	1	Numerous blood vessels (often more endothelial than meningothelial cells!)	
<b>Microcystic</b>	1	Cells with thin, elongated processes and creating a cobweb-like background.	
<b>Secretory</b>	1	Focal epithelial differentiation $\rightarrow$ intracellular lumina with PAS-positive secretions ("pseudopsammoma bodies").	
<b>Lymphoplasmacyte-rich</b>	1	Extensive chronic inflammatory infiltrates, often overshadowing meningothelial cells.	
<b>Metaplastic</b>	1	Has a mesenchymal component (osseous, cartilaginous, myoid, lipomatous, or xanthomatous)	
<b>Chordoid</b>	2	Cords or trabeculae of eosinophilic, often vacuolated cells, set in mucoid matrix (like chordoma).	
<b>Clear cell</b>	2	Polygonal cells with clear, glycogen-rich cytoplasm and prominent perivascular and interstitial collagen. Sheet-like.	
<b>Papillary</b>	3	Perivascular pseudopapillary pattern. Loss of cell cohesion. Resembles pseudorosettes.	
<b>Rhabdoid</b>	3	Rhabdoid cells (plump cells with eccentric nuclei, open chromatin, prominent nucleoli, and eosinophilic cytoplasm)	



# Solitary Fibrous Tumor/Hemangiopericytoma

Fibroblastic tumor with a histologic spectrum (previously considered 2 entities, but united by genetics).

Usually **Dural** and **supratentorial**.

**Solitary Fibrous Tumor (SFT):** "Patternless pattern" of short fascicles with alternating hyper and hypocellular areas with thick collagen bands.

**Hemangiopericytoma:** High cellularity and rich network of reticulin fibers.

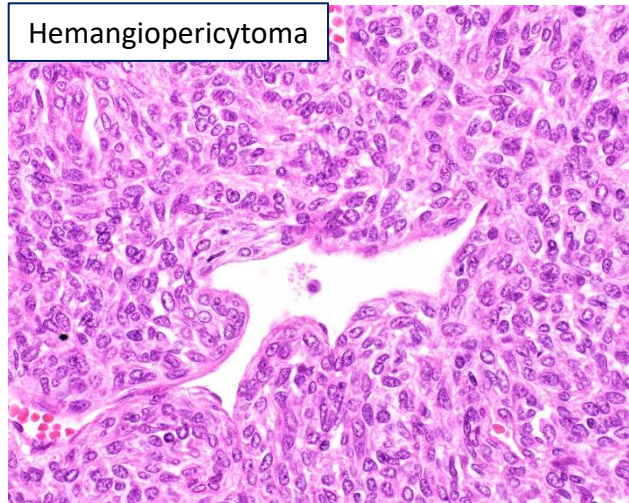
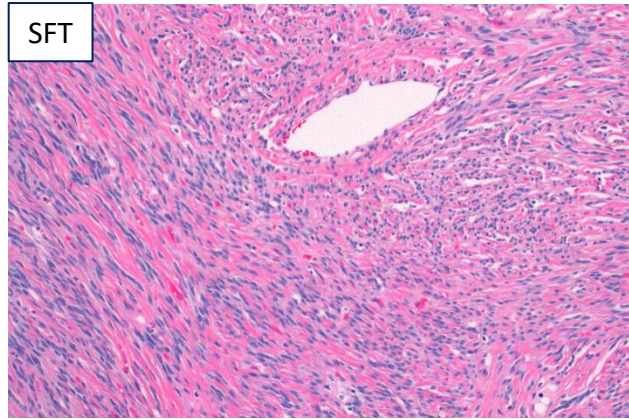
**BOTH** have large, open, branching "Staghorn" vessels.

Molecular/IHC: NAB2-STAT6 fusion, best identified with **STAT6 IHC**. Also, (+) CD34, CD99

**Grade based on morphology/mitoses:**

Grade I: Solitary Fibrous Tumor → considered benign → Treat with surgery only

Grade II: Hemangiopericytoma with <5 mitoses per 10 HPF  
Grade III: Hemangiopericytoma with ≥5 mitoses per 10 HPF  
→ Considered malignant → Treat with surgery and radiation



## Unique Mesenchymal Tumors

Pretty much any mesenchymal tumor can involve the CNS, so also refer to separate Soft Tissue/Bone Guides

### Hemangioblastoma WHO grade I

Two characteristic components:

1) Large stromal cells that are vacuolated with often clear cytoplasm.

2) Abundant vascularity

Most common in **Adults**.

Most common in **cerebellum**. Can get anywhere.

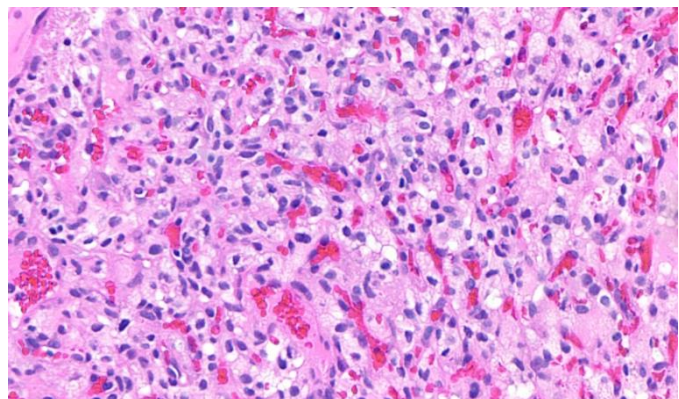
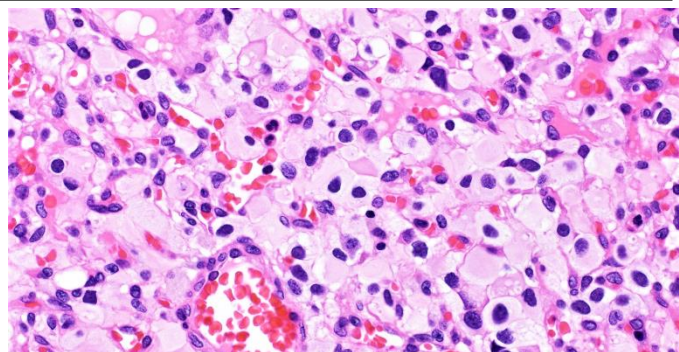
Associated with **Von Hippel-Lindau disease**.

Molecular: VHL tumor suppressor inactivated in both sporadic and VHL-associated cases

IHC: **Stromal cells (+) Inhibin, Brachyury**. Endothelial cells express vascular markers (+ CD31, CD34, ERG...)

**Important to differentiate from metastatic clear cell**

**RCC**, especially if in setting of VHL disease! In contrast, RCC stains with: PAX8, AE1/AE3, CD10, EMA





# Germ Cell Tumors

Note: For more info, refer to the Testicle and Ovary guides

Morphologically identical to gonadal counterparts!

Usually children/adolescents.

Usually in the midline, most commonly **pineal gland**.

Symptoms depend on location. Can be "Mixed" GCT.

## Germinoma

Large **polygonal cells** with clear to eosinophilic cytoplasm, distinct cell membranes, vesicular chromatin, and prominent nucleoli. Fibrous septae and **nested architecture**

**Lymphocytic infiltrate**; Sometimes granulomas

## Yolk Sac Tumor

**Many patterns/architecture**. Often hypocellular myxoid areas

Most common = reticular/microcystic. Hyaline globules.

Classic: Schiller-Duval Bodies; Variable architecture.

Hyaline globules. **Elevated Serum AFP**

## Embryonal Carcinoma

Large "Primitive" cells

**Vesicular nuclei with prominent nucleoli**

Coarse, basophilic chromatin. Amphophilic cytoplasm

Variable architecture (nests, sheets, glands). Aggressive.

## Choriocarcinoma

**Malignant cytotrophoblasts (mononuclear) and syncytiotrophoblasts (multinucleated)**

Abundant **Hemorrhage**. Elevated serum or CSF hCG.

## Teratoma

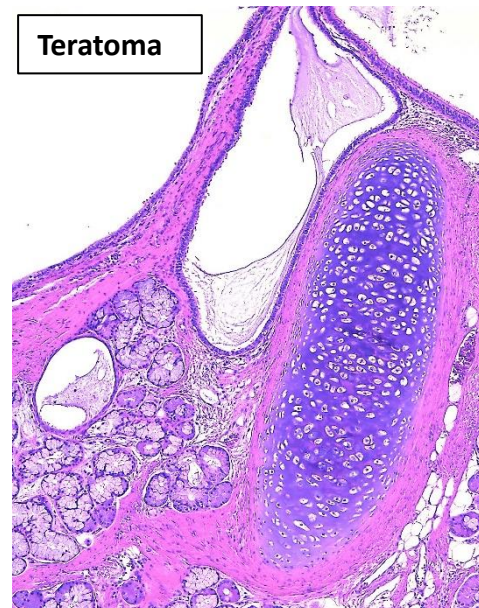
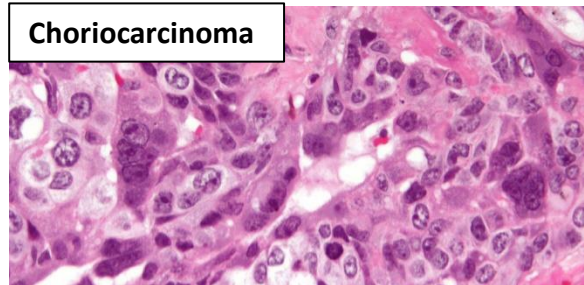
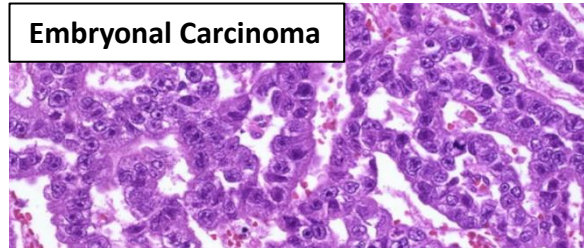
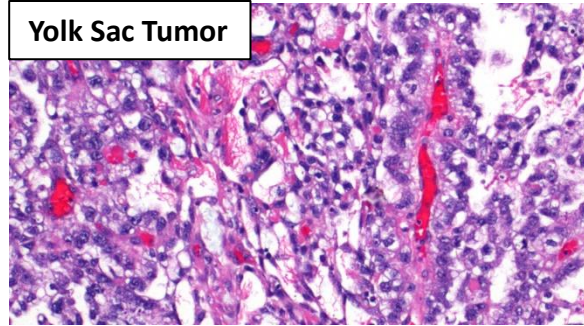
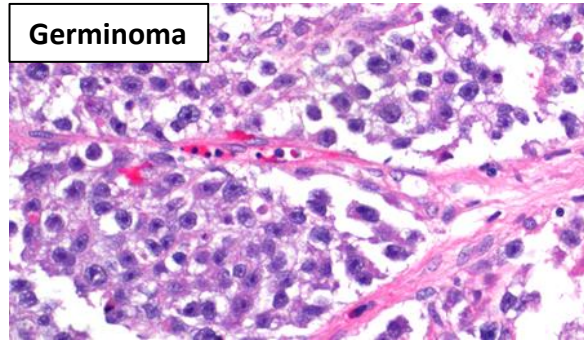
Composed of tissues from 2-3 germ layers.

Common elements: Skin (with adnexal structures), Cartilage, GI, Brain, etc...

*Mature* → exclusively mature (adult-type) tissues

*Immature* → has immature fetal/embryonic tissue

...with *Malignant Transformation* → somatic malignancy developing in a teratoma



## Germ Cell Tumor Immunohistochemistry:

IHC Stain	Seminoma	Embryonal Carcinoma	Yolk Sac Tumor	ChorioCA
SALL4	+	+	+	+
OCT 3/4	+	+	-	-
D2-40	+	+/-	-	-
CD117	+	-	-	-
CD30	-	+	-/+	-
Glypican 3	-	-	+	+/-



# Lymphomas

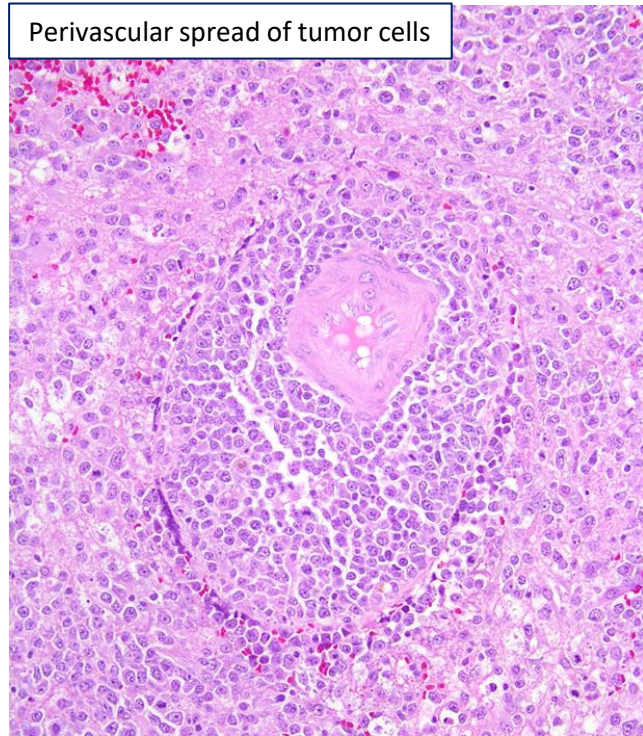
**Discohesive cells with scant cytoplasm.**  
**Frequent perivascular infiltration**

**Diffuse Large B-cell Lymphoma of the CNS:** DLBCL confined to the CNS at presentation. Often older patients with cognitive dysfunction and a single supratentorial mass. Need tissue to Dx → important to not give steroids before surgery as may cause tumor waning making it harder to Dx. Highly cellular, diffuse, patternless growth. Often necrosis with viable perivascular islands. Perivascular infiltration of nearby brain. IHC: (+) PAX5, CD20, CD19. NOT virus related.

**Immunodeficiency-associated CNS lymphomas:** Most common in AIDS. EBV-associated. Often multifocal.

**Other Lymphomas:** Lymphomatoid granulomatosis, Intravascular Large B cell lymphoma, Extranodal marginal lymphoma of mucosa-associated lymphoid tissue (MALT) lymphoma of the dura.

Perivascular spread of tumor cells



# Miscellaneous Other Tumors

## **Melanocytic tumors:**

Presumably arise from leptomeningeal melanocytes. Often contain melanin.

*Must consider/exclude metastatic melanoma!*

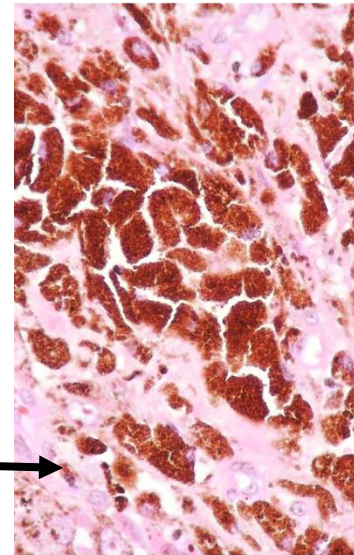
IHC: (+)S100, MelanA, HMB45, MITF; Ki67 usually <2% in melanocytomas

**Meningeal Melanocytosis**—Diffuse/multifocal benign proliferation of cytologically bland melanocytes in subarachnoid space. Don't frankly invade brain.

**Meningeal Melanomatosis**—Primary CNS melanoma with diffuse spread throughout subarachnoid space. Often CNS invasion.

**Meningeal Melanocytoma**—Well-differentiated, solid, non-infiltrative melanocytic neoplasm

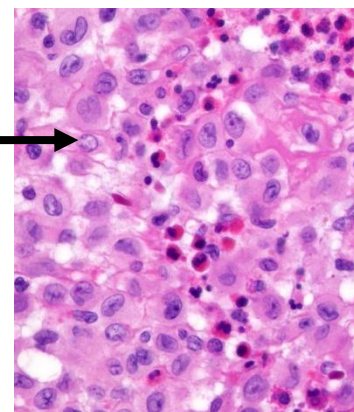
**Meningeal Melanoma**—Primary CNS melanoma. Solitary mass with aggressive growth.



## **Histiocytic tumors:**

**Langerhans's Cell Histiocytosis**—Clonal proliferation of Langerhans cells.

IHC: (+)S100, CD1a, Langerin. May involve CNS secondarily via extension from bone or primarily. Usually children. Cells have pale cytoplasm with reniform nuclei. Classically associated eosinophils. Frequent BRAF V600E mutations.



**Erdheim-Chester disease, Rosai-Dorfman disease, Juvenile Xanthogranuloma, Histiocytic sarcoma**



# Sellar Tumors

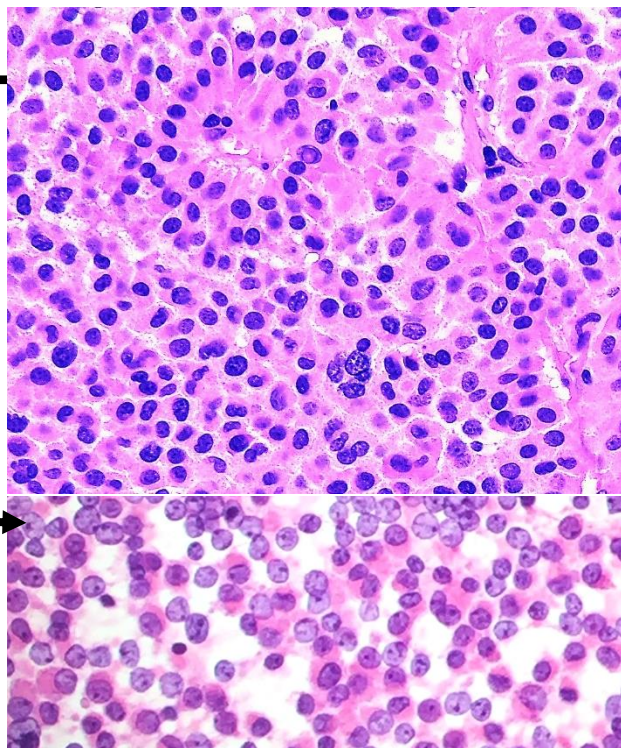
## Pituitary Adenoma

**Most common** tumor of sella turcica. Usually **Adults**.  
Neoplasm of **anterior pituitary hormone-producing cells**.  
**Benign**, but can invade adjacent structures.

**Monomorphic Neuroendocrine cells**. Round nuclei.  
Variety of histologic growth patterns, including diffuse, papillary, and trabecular (like other NE tumors)  
May have eosinophilic or basophilic cytoplasm  
May have perivascular orientation.

**On touch prep see cellular, discohesive, homogeneous neuroendocrine proliferation**

Stains: (+) Synaptophysin, chromogranin; (-) S100  
**Reticulin shows dissolution of normal network**.  
(disruption of small normal micro-acini → larger nests)



**Subclassify by hormone secretion**, use IHC panel: Growth Hormone (GH), prolactin, TSH-β, ACTH, FSH-β, LH-β, Alpha subunit (α-SU)

**“Functioning” adenomas → secrete hormone → often present early with symptoms/tumor syndrome.**  
“Silent” adenomas do not secrete hormone, but still stain with hormone IHC.

Non-functional ones often present with mass effect. **Press on optic chiasm → bitemporal hemianopsia, diplopia, headache.**

Usually sporadic, but can occur in MEN1, DICER1 syndrome, etc...

Treatment: Usually Transsphenoidal **resection is #1**; may also consider pharmacotherapy or radiation

Type	Hormone Secreted	IHC	
<b>Lactotroph</b>	Prolactin	Prolactin, PIT1,	<b>Most common</b> (up to 1/2 of all adenomas). Presentation depends on sex: females present with <b>galactorrhea &amp; amenorrhea</b> , men present with sexual dysfunction and mass effect.
<b>Corticotroph</b>	ACTH	ACTH, TPIT	Excess glucocorticoid → <b>Cushing’s Disease</b> .
<b>Gonadotroph</b>	FSH-β, LH-β, and/or α-SU,	FSH-β, LH-β, α-SU, SF1	Most are non-functioning and present with mass effect. Can result in menstrual disturbances in women and sexual dysfunction in men.
<b>Somatotroph</b>	Growth Hormone	GH, PIT1,	Present with <b>gigantism</b> and/or <b>acromegaly</b> . Eosinophilic.
<b>Thyrotroph</b>	TSH	TSH-β, α-SU, PIT1,	Rare. Present with <b>hyperthyroidism</b> .
<b>Null Cell</b>	None	None	Present due to mass effect
<b>Plurihormonal</b>	Multiple	Multiple, PIT1	Some established adenoma subtypes excrete 2 hormones, like <b>mammotrophs</b> (GH and prolactin) and are not considered in this group. Presentation depends on hormones.



# Pituitary Carcinoma

**Defined by metastasis** (independent of any histologic finding!)

Very rare. Must have proven primary tumor. Metastases are usually in craniospinal axis.

Resemble pituitary adenoma with histology and IHC.

Often have more abnormal cells and proliferation (e.g., more mitoses, higher Ki67)

Relatively poor prognosis.

# Pituitary Blastoma

Rare developmental tumor seen in neonatal period.

Three components:

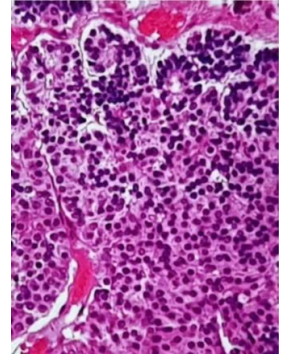
- 1) Small chromophobic and undifferentiated blastema-like cells,
- 2) Larger patternless secretory cells with round nuclei and abundant cytoplasm,
- 3) Cuboidal to columnar cells forming glandular-like structures.

IHC: (+) ACTH (-)Prolactin, TSH, FSH, LH

Associated with Cushing disease.

Molecular: **DICER1 mutations**

Relatively poor prognosis.



# Craniopharyngioma WHO grade I

**Benign, epithelial tumors derived from embryonic remnants of Rathke's pouch.**

Usually present with mass effect (visual disturbance, headache, or endocrine changes).

Nearby gliosis and Rosenthal fibers.

## Adamantinomatous craniopharyngioma

Bimodal age distribution (1<sup>st</sup> and 5<sup>th</sup> decades)

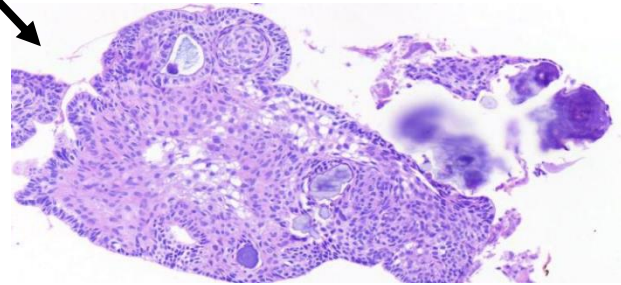
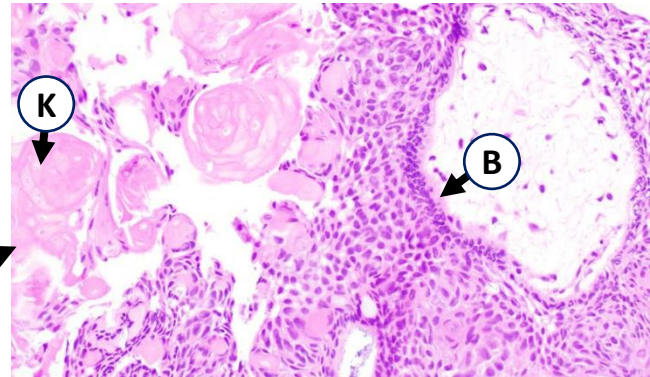
**Basal layer with basal palisading (B)**

**Stellate reticulum** (loose background), whorls, "Wet keratin" (K), Calcifications, Cholesterol clefts.

**Multi-Cystic** areas.

IHC/Molecular: **Nuclear expression of  $\beta$ -catenin**

Tumors with frank anaplasia, necrosis, and numerous mitoses are considered malignant.



## Papillary craniopharyngioma

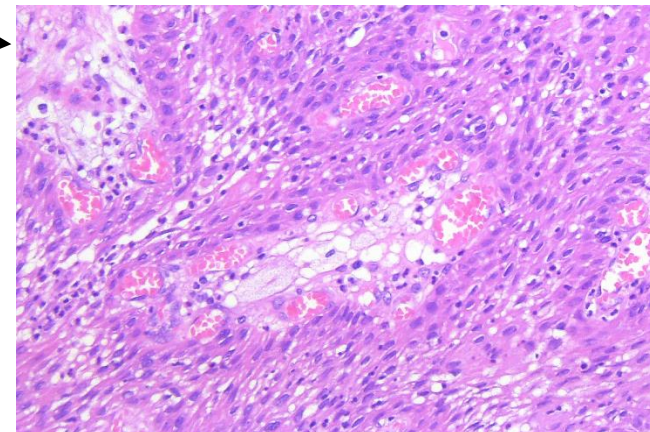
Exclusively in adults

**Resembles a squamous papilloma:** Non-keratinizing epithelium and fibrovascular cores. **Solid.**

NO stellate reticulum, wet keratin, or calcifications

IHC/Molecular: **BRAF V600E mutations, (+)p63, CK5/6**

**Generally favorable prognosis.** Treated with surgery. Nevertheless, can be infiltrative and hard to manage.





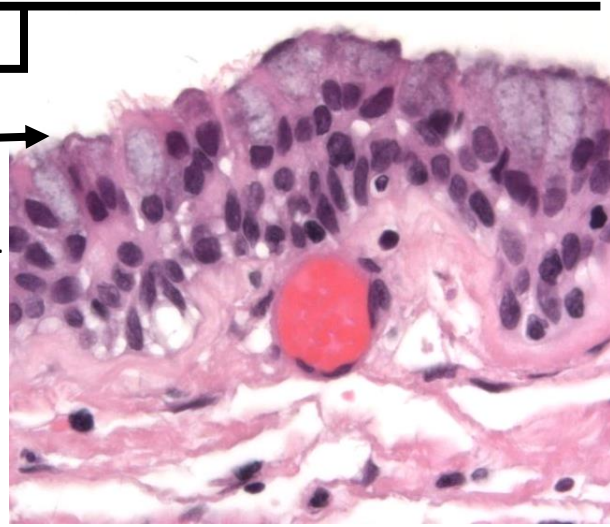
## Non-neoplastic lesions of Rathke's Cleft

**No nuclear  $\beta$ -catenin or BRAF V600E staining.**

**Rathke's Cleft Cyst:** Cyst wall lined by columnar or cuboidal epithelium, which is often ciliated with mucinous and goblet cells. May rupture inducing a xanthogranulomatous reaction.

**Xanthogranuloma:** Cholesterol clefts, foamy macrophages, multinucleated giant cells, chronic inflammation, necrotic debris, and hemosiderin. May see scant epithelium from Rathke's cleft cyst remnants.

**Epidermoid cyst:** Unilocular cavity lined by squamous epithelium and filled with dry, flaky keratin (like elsewhere)



## Granular Cell Tumor of the Sellar Region

WHO grade I

**Epithelioid to spindled cells with abundant granular eosinophilic cytoplasm** (full of lysosomes).

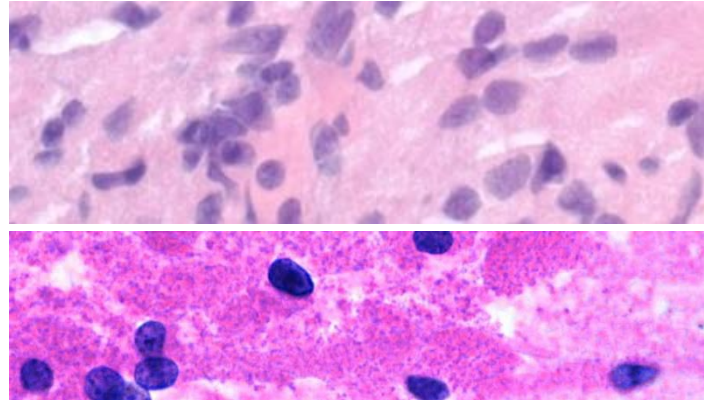
IHC: (+) Diffuse TTF1; (+/-) CD68, S100

**Possibly on a spectrum with the two entities below**

Arises in **posterior pituitary (neurohypophysis) or infundibulum**. Circumscribed.

Usually adults. Rare.

Slow progression and **benign** clinical course.



## Pituicytoma WHO grade I

Low-grade glial tumor composed of bipolar spindled cells arranged in a fascicular or storiform pattern.

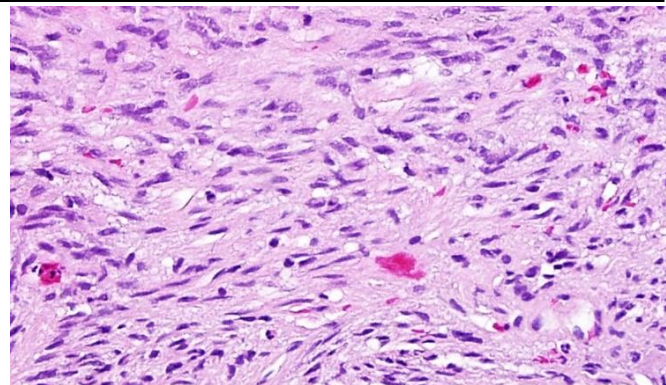
IHC: (+) TTF1, S100; (+/-) GFAP; (-) Synpto

**Possibly on a spectrum with the above & below DXs**

Circumscribed, Solid. Rare.

In **posterior pituitary/infundibulum**.

Good prognosis.



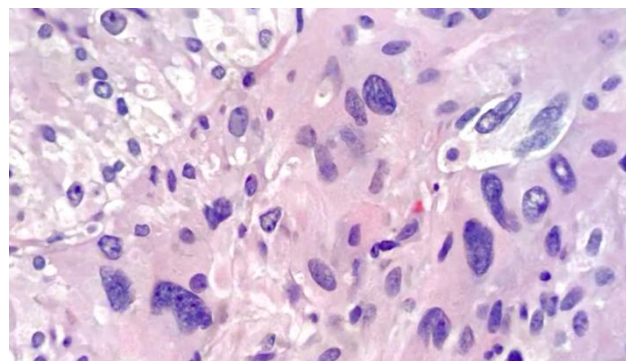
## Spindle Cell Oncocytoma WHO grade I

**Spindled to epithelioid oncocytic non-neuroendocrine neoplasm of posterior pituitary gland.** Variable pleomorphism.

IHC: (+) TTF1, S100, EMA; (-) Synpto

**Possibly on a spectrum with the above two DXs**

Good prognosis.





## Metastatic Tumors

Metastases are the most common CNS tumors in Adults!

Usually **multiple** lesions. Usually **well-circumscribed** (as opposed to an infiltrative diffuse glioma)  
80% of metastases are to **cerebral hemispheres**, particularly in arterial border zones and at the grey-white junction. Often present with signs of increased intracranial pressure (headache, altered mental status, ataxia, etc..)

*Most common sites of origin:*

Men → 1) Lung, 2)GI, 3)Melanoma, 4)Kidney

Women → 1) Lung, 2)Breast, 3)GI, 4)Melanoma

## Tumor Syndromes

AD= Autosomal Dominant

Syndrome	Gene	Nervous System Tumor(s)	Other manifestations
<b>Neurofibromatosis Type 1 (NF1)</b>	NF1 (AD)	Optic tract pilocytic astrocytomas, Astrocytomas, Neurofibromas, MPNST's	Café-au-lait spots, axillary freckles, osseous lesions, Lisch nodules, GIST etc..
<b>Neurofibromatosis Type 2 (NF2)</b>	NF2 (AD)	Bilateral vestibular schwannomas (and elsewhere), Meningiomas, Gliomas, and developmental lesions	Ocular abnormalities.
<b>Schwannomatosis</b>	SMARCB1 or LZTR1 (Sporadic)	Multiple Schwannomas and Meningiomas	Rare.
<b>Von Hippel—Lindau Disease (VHL)</b>	VHL (AD)	Hemangioblastoma	Clear cell renal cell carcinoma, Pheochromocytoma, Pancreas NET, Ear and epididymis tumors.
<b>Tuberous sclerosis</b>	TSC1 or TSC2 (AD)	SEGAs, Cortical hamartomas, Subependymal glial nodules	Cutaneous angiofibroma, Cardiac rhabdomyomas, Renal angiomyolipoma, Lung LAM
<b>Li-Fraumeni Syndrome</b>	TP53 (AD)	Astrocytoma, Glioblastoma, Medulloblastoma, Choroid plexus tumors	Multiple primary tumors in children and young adults including: Breast cancer, Soft tissue sarcomas, Adrenal cortical carcinoma, and Osteosarcoma.
<b>Cowden Syndrome</b>	PTEN (AD)	Dysplastic cerebellar gangliocytoma (Lhermitte-Duclos disease),	Breast, Endometrium, and Thyroid cancer. Multiple hamartomas including skin and GI
<b>Turcot Syndrome</b>	APC (AD)	Medulloblastoma	Colon Cancer, Osteomas, Fibromatosis,
	Mismatch repair enzymes (AD)	Gliomas	Café-au-lait macules, Lymphoma
<b>Nevoid Basal Cell Carcinoma (Gorlin) Syndrome</b>	PTCH1 or PTCH2 (AD)	Medulloblastoma (desmoplastic/nodular)	Skin basal cell carcinoma, Odontogenic keratocytes
<b>Rhabdoid Tumor Predisposition Syndrome</b>	SMARCB1 or SMARCA4	AT/RT	Kidney malignant rhabdoid tumor



## Pattern-Based Approach

Modified from: "Practical Surgical Neuropathology"  
by Arie Perry and Daniel Brat

**General Comments:** Although a pattern-based approach is very useful, in many cases you might have a good idea of the Dx via "instant pattern recognition." Nevertheless, it can be helpful to judiciously consider mimickers and other diagnoses based on a pattern-based approach.

## Parenchymal Infiltrate with Hypercellularity

*Intact architecture, but with a hypercellular infiltrate*

Diffuse gliomas	Histiocytic disorders (e.g., Erdheim-Chester disease)
Diffuse large B cell lymphoma of the CNS	Infarcts
Angiocentric glioma	Metabolic/toxic diseases
Encephalitis (inflammatory/infectious processes)	Reactive gliosis
Active demyelinating diseases	

## Solid Mass

*A sharply demarcated lesion*

Metastases	Choroid plexus tumors
Ependymoma	Hemangioblastoma
Subependymoma	Paranglioma
SEGA	Pituitary adenomas
Neurocytomas	Astroblastoma
Pineal parenchymal tumors	Chordoid glioma of the 3 <sup>rd</sup> ventricle
Embryonal neoplasms	

## Solid and Infiltrative Process

*A lesion that is mostly solid, but with an ill-defined (infiltrative) margin with the adjacent brain tissue.*

Pilocytic astrocytoma	Craniopharyngioma
Pilocytic xanthoastrocytoma	Diffuse large B-cell Lymphoma
Glioblastoma/gliosarcoma	Sarcomas
Ganglioglioma	Histiocytic tumors
Disembryoplastic neuroepithelial tumor	Abscesses/infection
Embryonal neoplasms (e.g., Medulloblastoma)	
Choroid plexus carcinoma	
Germ cell tumors	

## Destructive/Necrotic Process

*Extensive necrosis and destruction of normal tissue*

Infarcts	Vasculitis
Glioblastoma	Lymphoma
Radiation necrosis/treatment effect	Severe demyelinating disease
Infection	Metabolic/toxic disease

## Vasculocentric

*A disease process centered around blood vessels*

Diffuse large B-cell lymphoma  
Intravascular lymphoma  
Angiocentric glioma  
Ependymoma  
Vasculitis  
Demyelinating diseases

Amyloid angiopathy  
Arteriosclerosis  
Vascular malformations  
Infections  
Sarcoidosis  
Thromboembolic disease

## Extra-Axial Mass

*External to the brain*

Meningioma  
SFT/Hemangiopericytoma  
Hemangioblastoma  
Peripheral nerve sheath tumors  
Metastasis  
Melanocytoma/melanoma  
Paranglioma

Pituitary adenoma  
Sarcoidosis  
Infection  
Bone tumors  
Histiocytic tumors  
Leukemia/lymphoma

## Almost Normal Tissue

*Very subtle changes*

Nonrepresentative biopsy ("they missed")  
Subtle diffuse glioma  
Cortical dysplasia and other malformations  
Mesial temporal sclerosis  
Intravascular lymphoma  
Encephalitis  
Cerebral malaria  
Microembolic disease

Neurodegenerative diseases  
Metabolic/toxic disorders  
Reactive gliosis  
Cerebral edema  
Spongiotic/vacuolar changes  
Ischemic changes

## Meningeal/CSF Infiltrate

*An expanded subarachnoid space filled with a cellular infiltrate*

Meningeal carcinomatosis  
Meningeal gliomatosis  
Meningeal melanocytosis/melanomatosis  
Diffuse leptomeningeal glioneuronal tumor  
Metastatic medulloblastoma  
Leukemia/lymphoma

Histiocytic disorders  
Meningitis  
Sarcoidosis  
Infection  
Collagen vascular disease