

## Letters to the Editor

### Hemobilia related to cystic artery pseudoaneurysm as a cause of acute pancreatitis

*Key words:* Hemobilia. Pseudoaneurysm. Cystic. Pancreatitis.

DOI: 10.17235/reed.2017.4532/2016

Dear Editor,

Hemobilia is a rare cause of upper gastrointestinal bleeding (UGIB). It is commonly iatrogenic, and is more rarely caused by tumors, lithiasis, and inflammatory or vascular disease. We describe a case of cystic artery pseudoaneurysm, which caused acute pancreatitis as an unusual complication.

#### Case report

An 85-year-old woman with a history of gallstones presented with abdominal pain located in the right upper quadrant radiating to the back, vomiting and hematochezia. Laboratory findings showed leukocytosis (14,300, neutrophils 84.5%), hemoglobin 7 g/dl, elevation of reactive C protein 179 mg/l, amylase 648 U/l, lipase 1,417 U/l and cholestatic pattern. A gallbladder wall thickening with gallstones and an inflammatory process in the pancreatic tail was observed on an abdominal computed tomography (CT) scan. As UGIB and anemia continued an angio-CT was performed, showing a lobed contour structure within the gallbladder which was hyperdense in the arterial phase, did not change its morphology in the venous study, and was compatible with a cystic artery pseudoaneurysm (Fig. 1). The final diagnosis

was acute pancreatitis by hemobilia secondary to a cystic artery pseudoaneurysm bleed. Bleeding point embolization was performed with a successful recovery of the patient.

#### Discussion

Hemobilia is a rare cause of UGIB and is commonly iatrogenic. Tumors, gallstones and vascular or inflammatory diseases may also cause hemobilia (1,2). Hemobilia classically presents with the Quinke triad (abdominal pain, obstructive jaundice and UGIB) (1,3,4). If bile duct obstruction by hemobilia occurs, it may cause pancreatitis. Gold standard treatment is selective transarterial embolization (3,5). In conclusion, we

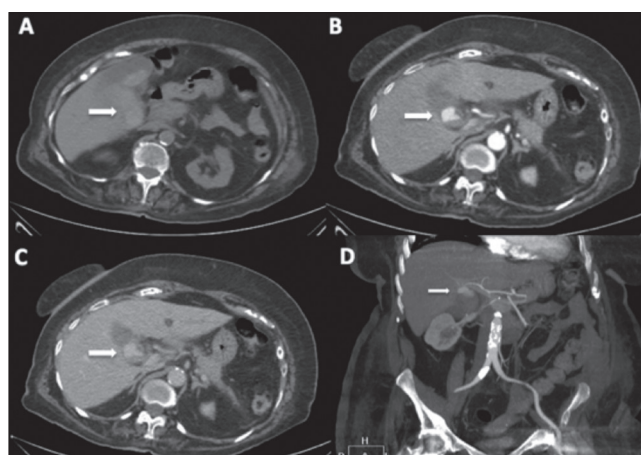


Fig. 1. A. Axial section of an abdominal CT which showed a hyperdense content within the gallbladder (arrow). B. A rounded structure which is enhanced like the vessels (arrow) was observed in the arterial phase of the study. C. The venous phase continued showing the rounded structure (arrow). D. Coronal section of a MIP (maximum intensity projection) reconstruction where a rounded structure (arrow) could be observed, in relation with hemobilia related to the right hepatic artery branch, probably the cystic artery.

would like to emphasize that acute biliary symptoms combined with UGIB should strongly suggest the possibility of hemobilia, which involves high mortality rates without specific treatment.

Patricia Lozano-Cruz<sup>1</sup>, Percy Arenas<sup>2</sup> and Ignacio Moral<sup>3</sup>

*Departments of <sup>1</sup>Internal Medicine, <sup>2</sup>Radiology, and <sup>3</sup>Digestive Diseases. Hospital Universitario Príncipe de Asturias. Alcalá de Henares, Madrid. Spain*

## References

1. Arroja B, Canhoto M, Barata P, et al. Hemobilia por pseudoaneurisma de una rama de la arteria hepática derecha. *Rev Esp Enferm Dig* 2010;102(6):386-7.
2. Feinman M, Haut E. Upper gastrointestinal bleeding. *Surg Clin North Am* 2014;94(1):43-53. DOI: 10.1016/j.suc.2013.10.004
3. Marynissen T, Maleux G, Heye S, et al. Transcatheter arterial embolization for iatrogenic hemobilia is a safe and effective procedure: Case series and review of the literature. *Eur J Gastroenterol Hepatol* 2012;24(8):905-9. DOI: 10.1097/MEG.0b013e328354ae1b
4. Huang CW, Hsu PI, Chan HH. Acute pancreatitis and cholangitis caused by hemobilia secondary to hepatocellular carcinoma: A case report. *J Intern Med Taiwan* 2013;24:500-4.
5. Lorente-Hence JM, Diéguez-Rascón F, Núñez G, et al. Tratamiento endovascular de hemobilia iatrogénica. *Rev Esp Enferm Dig* 2012;104(2):102-3. DOI: 10.4321/S1130-01082012000200015