

Topographical anatomy of the upper limb. Axillary fossa

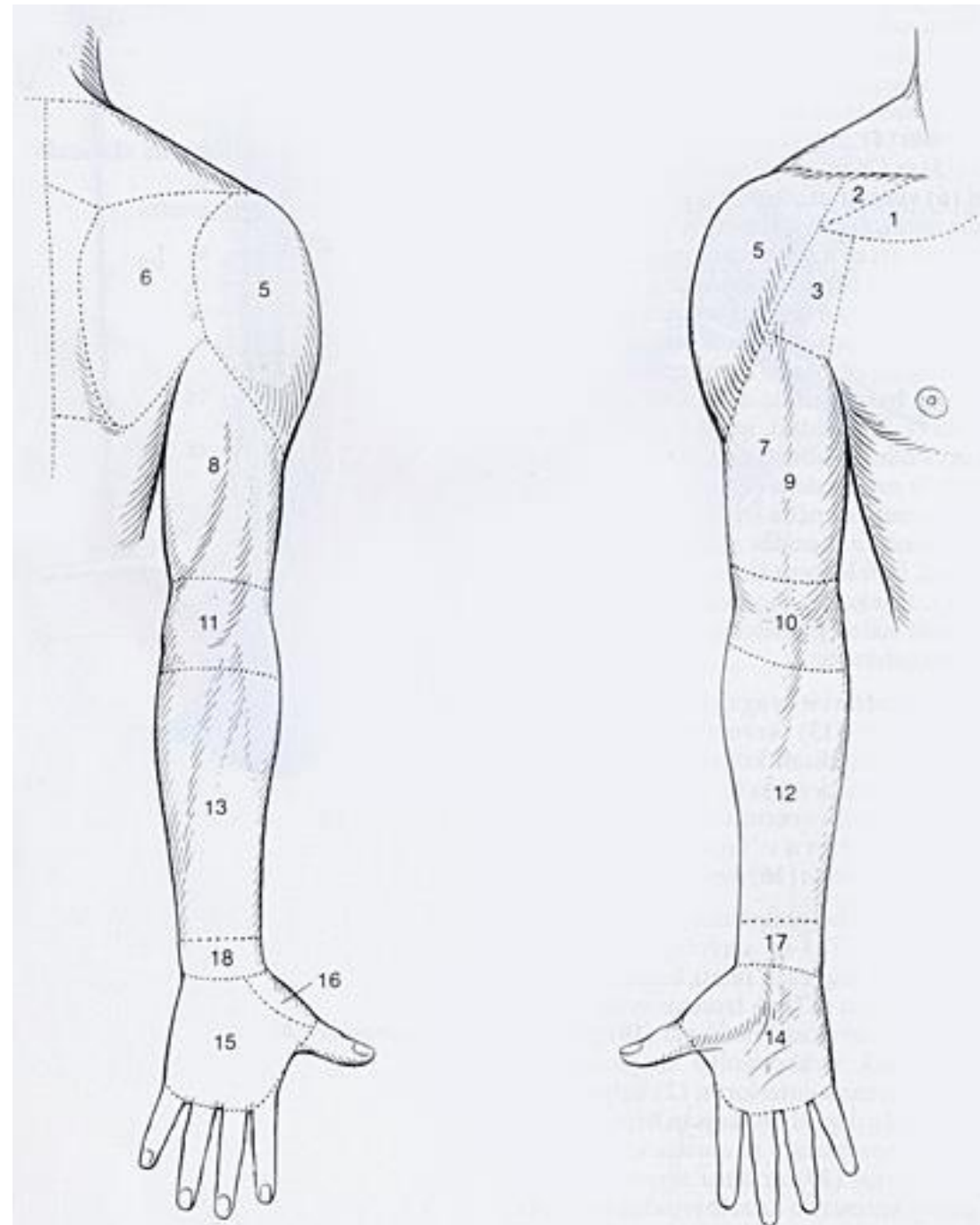
Dr. Szuák András 2019.02.12.

Today

- We don't learn the upper limb over and over!
- Synthesize our knowledge
- New - regions

Regions of upper limb

- Infraclavicular fossa (region) [1,2]
- **Axillary region/fossa** [3]
- Scapular region [6]
- Deltoid region [5]
- Anterior region of arm [7]
- Posterior region of arm [8]
- Anterior region of elbow [10]
- Posterior region of elbow [11]
- Anterior region of forearm [12]
- Posterior region of forearm [13]
- Anterior region of wrist [17]
- Posterior region of wrist [18]
- Palm [14]
- Dorsum of hand [15]
- Radial fossa [16]



Borders

line through acromion and 1st thoracic vertebra

line from inf. angle of scapula

3 cm above olecranon

3 cm below olecranon

horizontal line through basis of metacarpals

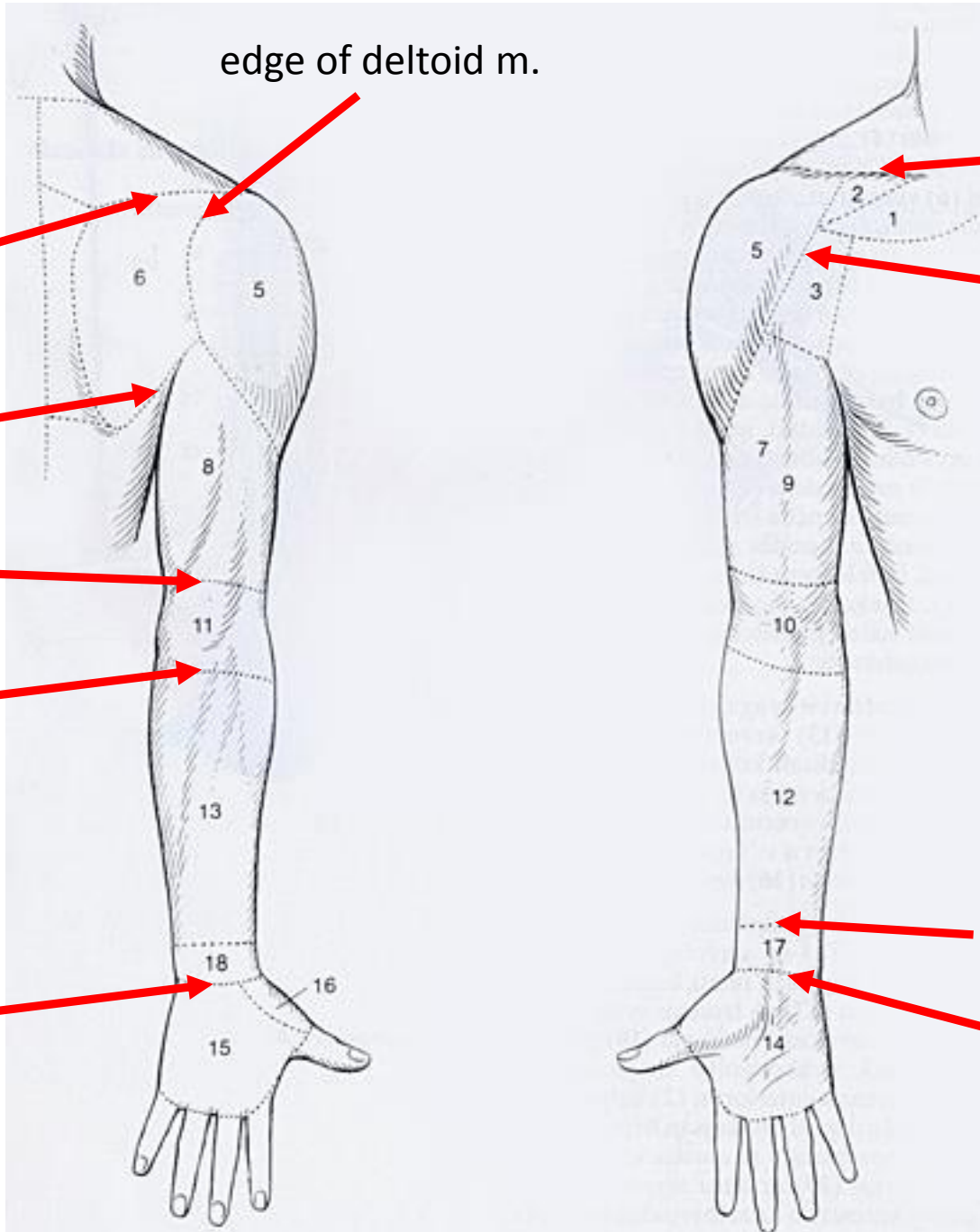
edge of deltoid m.

clavicle

edge of deltoid m.

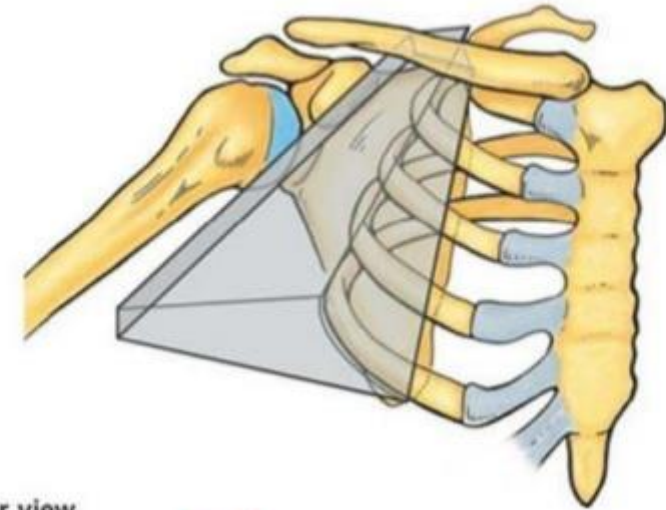
horizontal line through ulnar head

horizontal line through carpal eminences

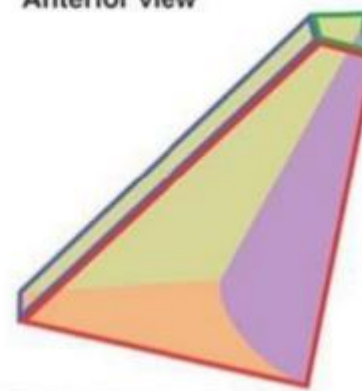


Axillary fossa

- Anterior: pectoralis major, pectoralis minor
- Posterior: latissimus dorsi, subscapularis, teres major (minor) med./lat. axillary hiatus
- Medial: serratus anterior
- Lateral: surgical neck of humerus, coracobrachials, short head of biceps brachii



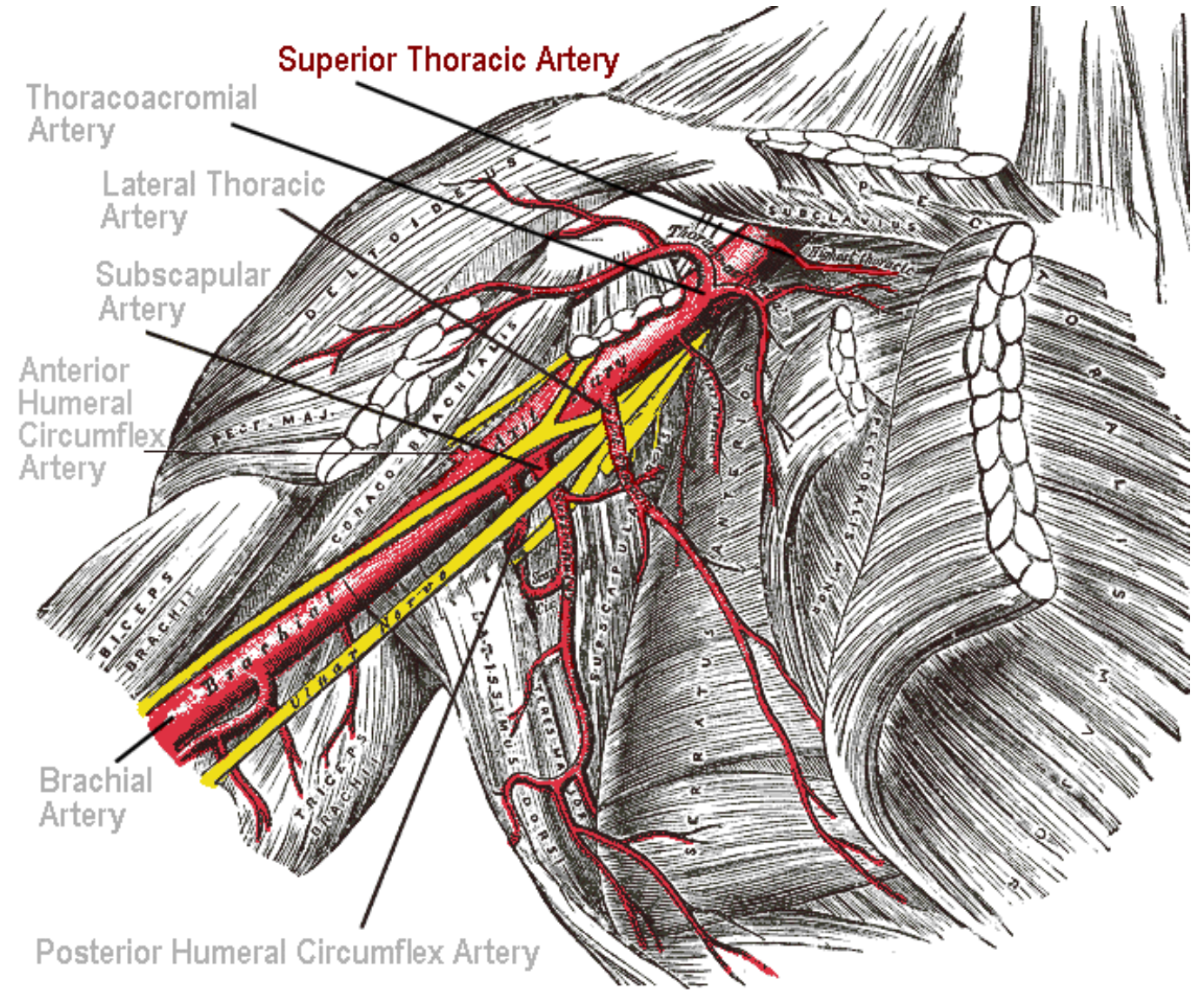
Anterior view



Boundaries of axilla	
Green	Apex
Orange	Base
Red	Anterior wall
Blue	Lateral wall
Purple	Medial wall
Yellow	Posterior wall

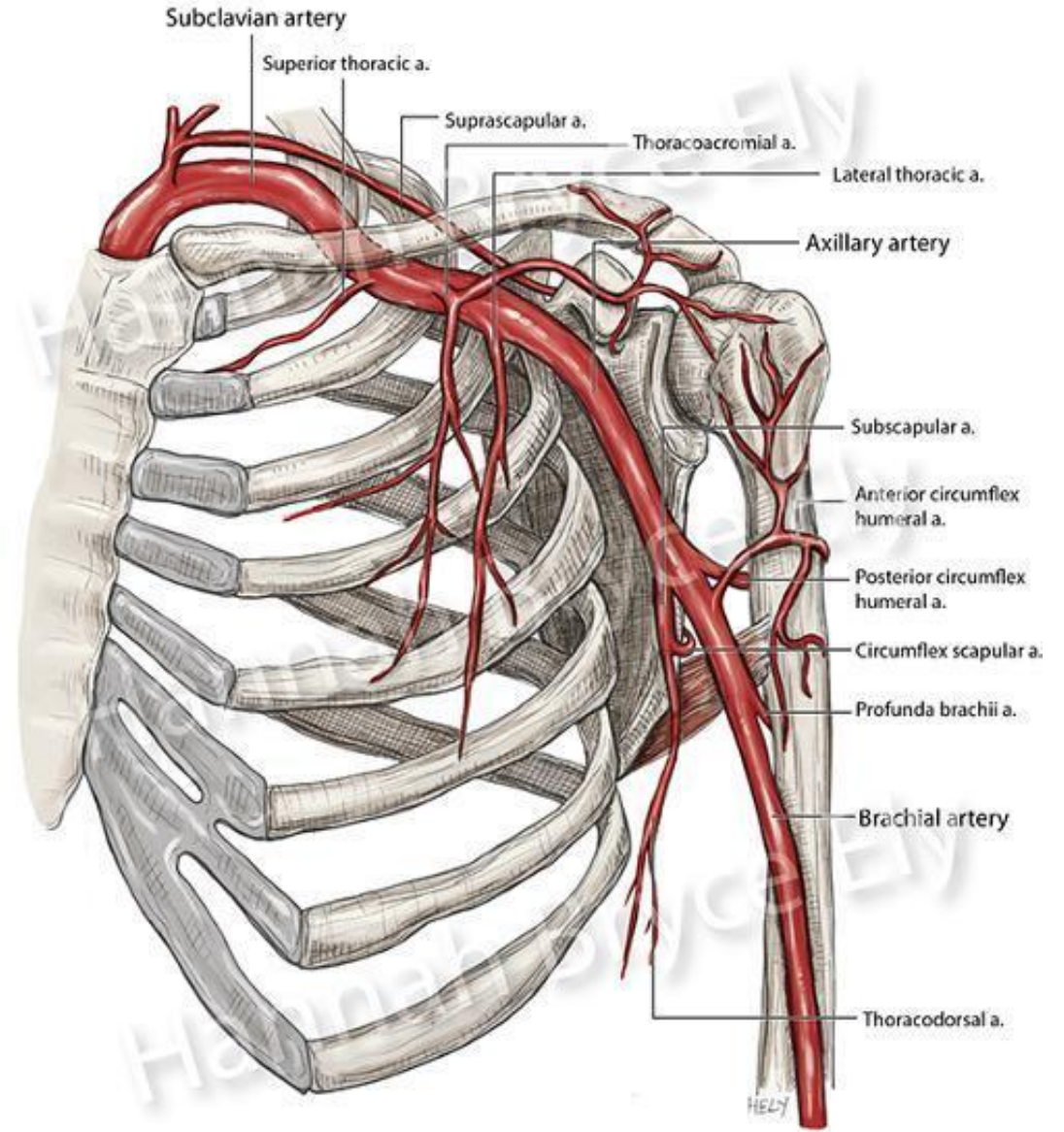
Axillary artery

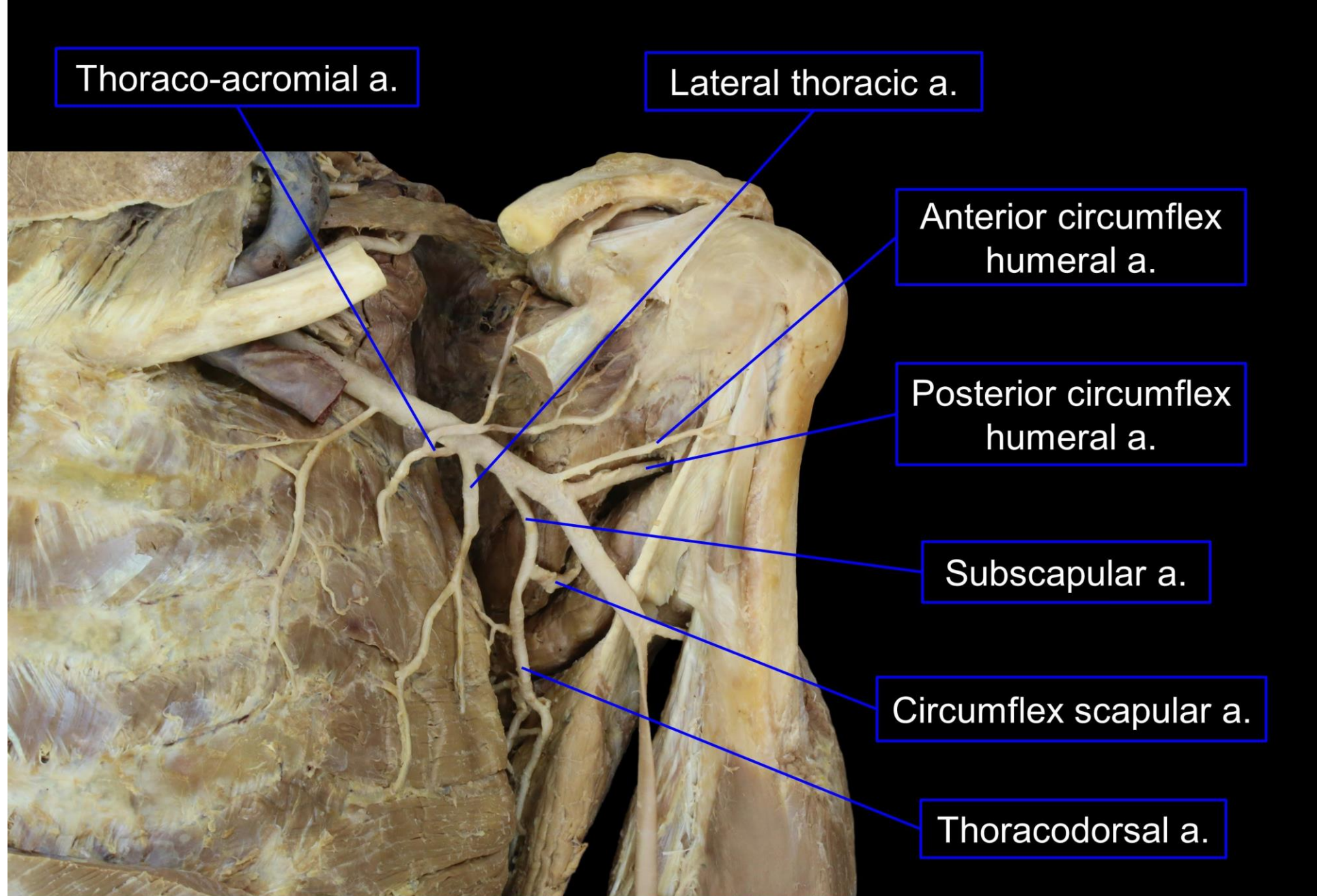
- superior thoracic a.
- thoraco-acromial a.
 - acromial br.
 - clavicular br.
 - deltoid br.
 - pectoral br.
- lateral thoracic a.
- subscapular a.
 - thoracodorsal a.
 - circumflex scapular a.
- anterior circumflex humeral a.
- posterior circumflex humeral a.



Axillary artery

- superior thoracic a.
- thoraco-acromial a.
 - acromial br.
 - clavicular br.
 - deltoid br.
 - pectoral br.
- lateral thoracic a.
- subscapular a.
 - thoracodorsal a.
 - circumflex scapular a.
- anterior circumflex humeral a.
- posterior circumflex humeral a.





Thoraco-acromial a.

Lateral thoracic a.

Anterior circumflex humeral a.

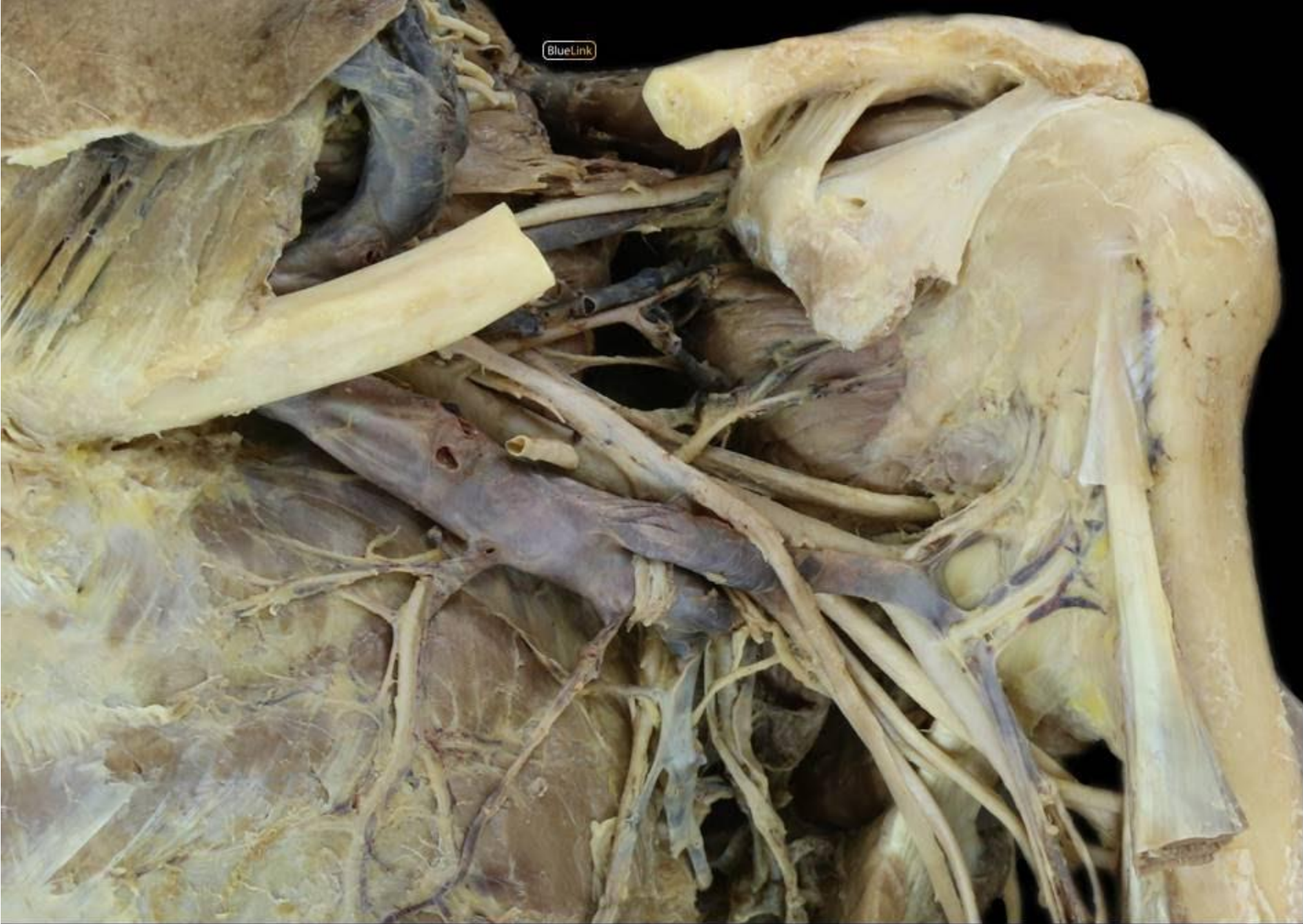
Posterior circumflex humeral a.

Subscapular a.

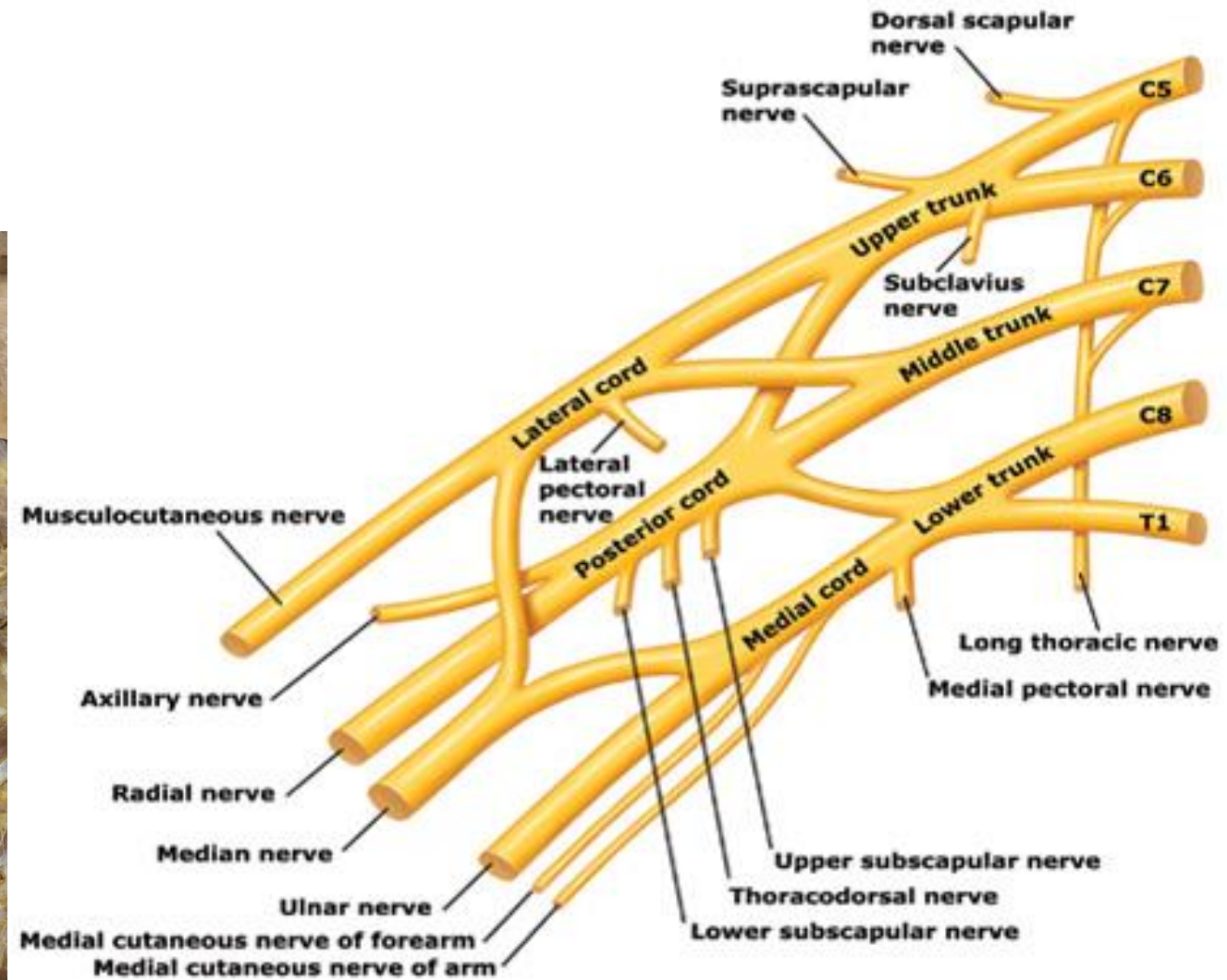
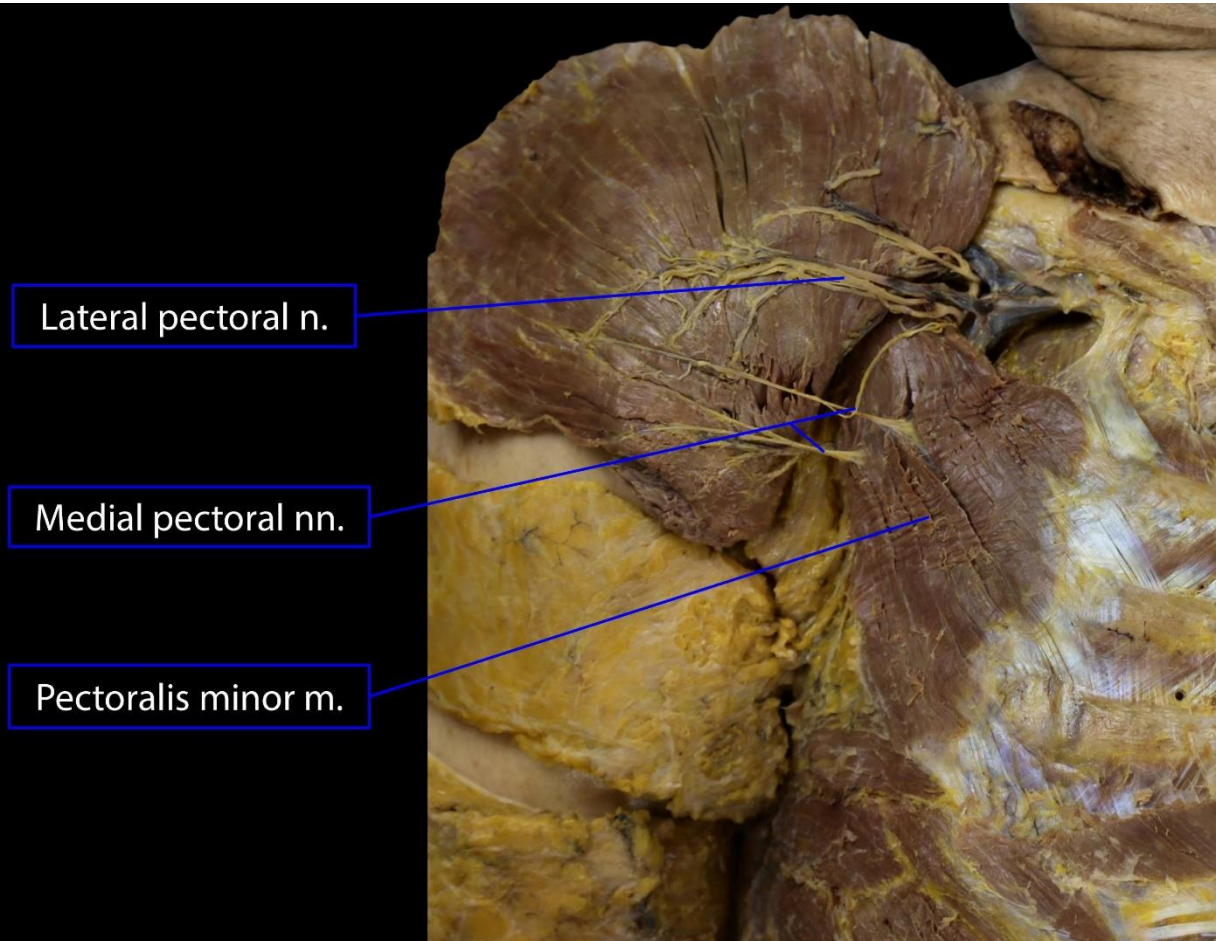
Circumflex scapular a.

Thoracodorsal a.

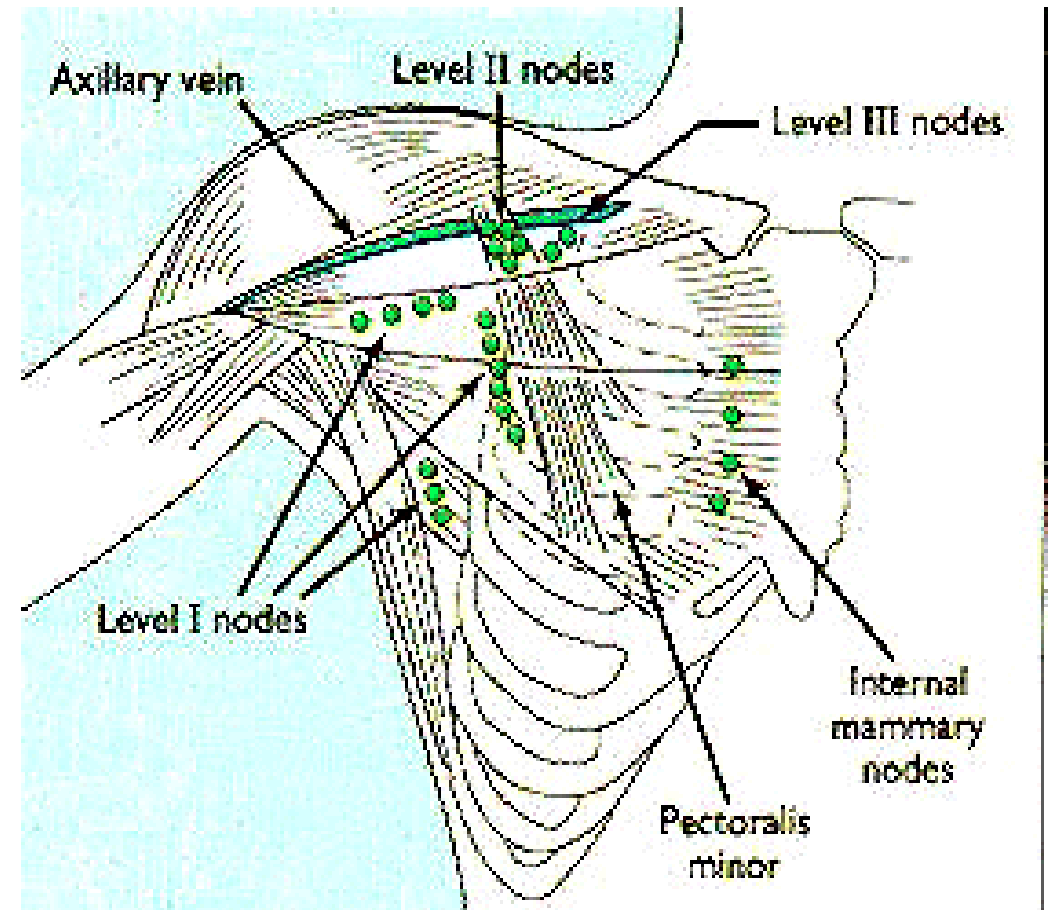
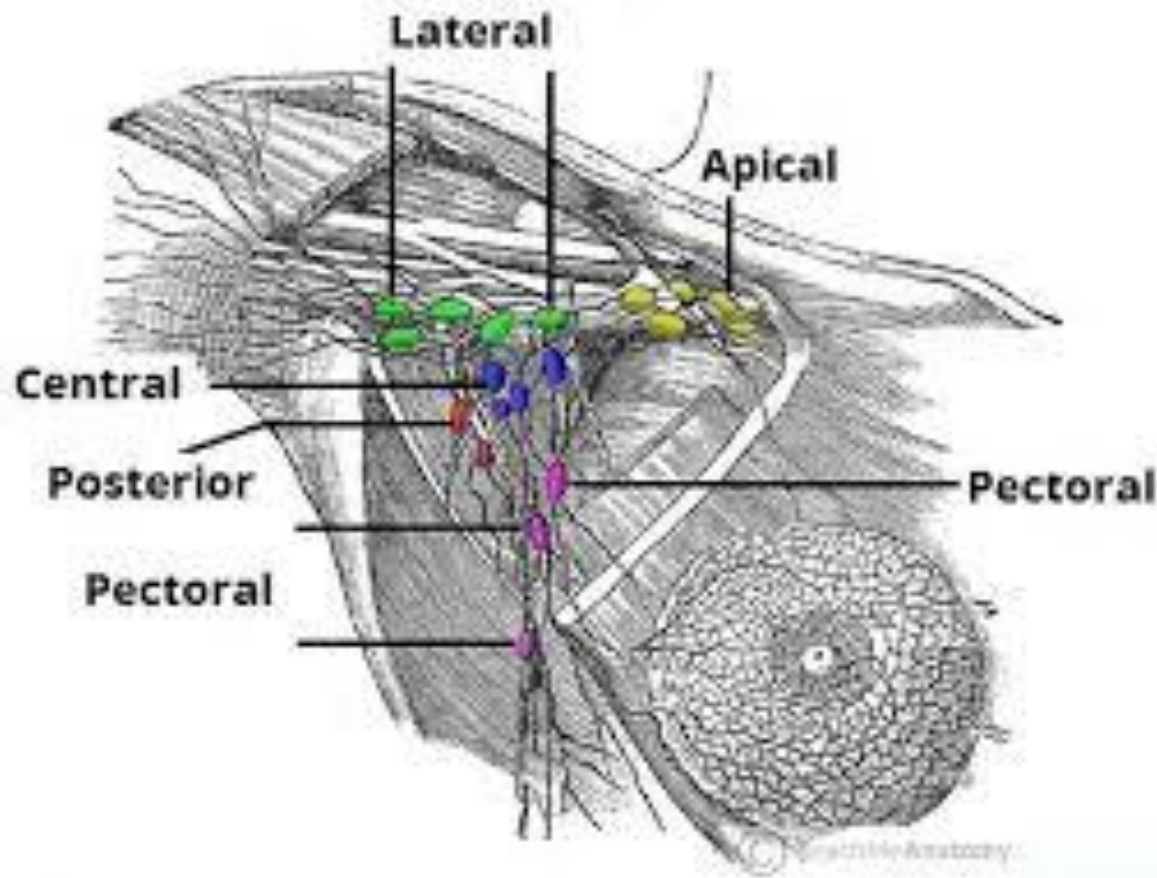
Axillary artery, anterior



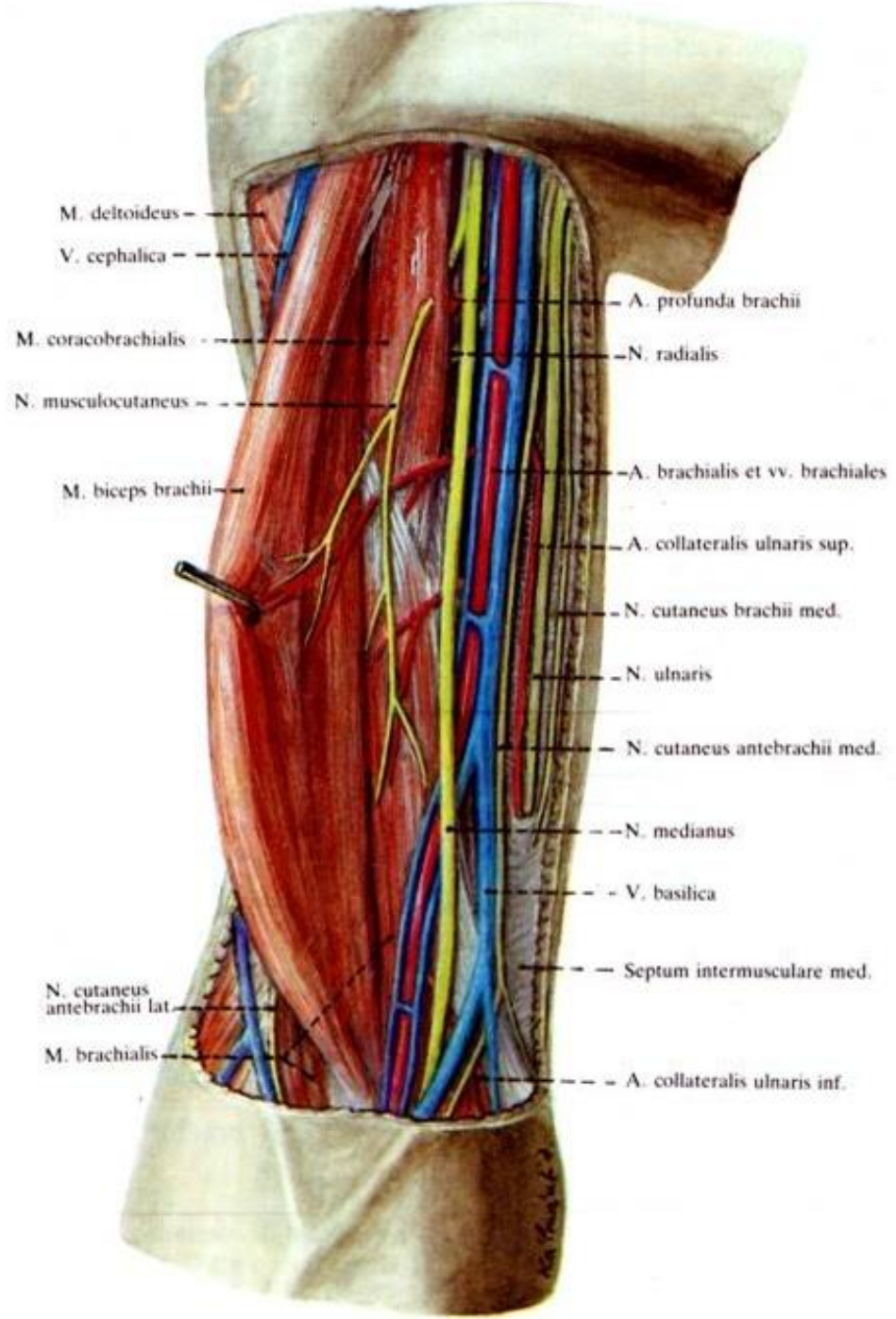
Brachial plexus



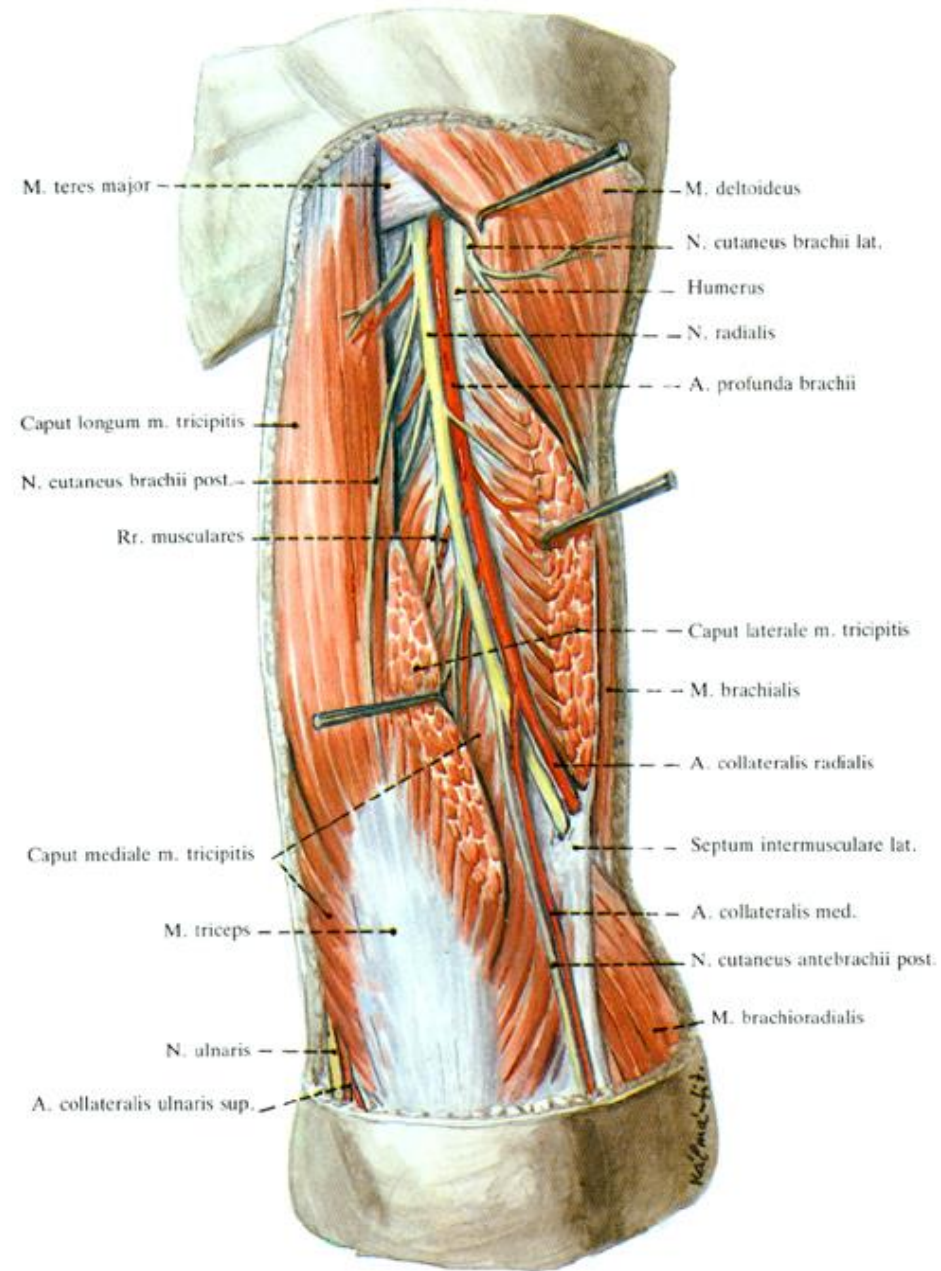
Lymph nodes



Anterior region of arm

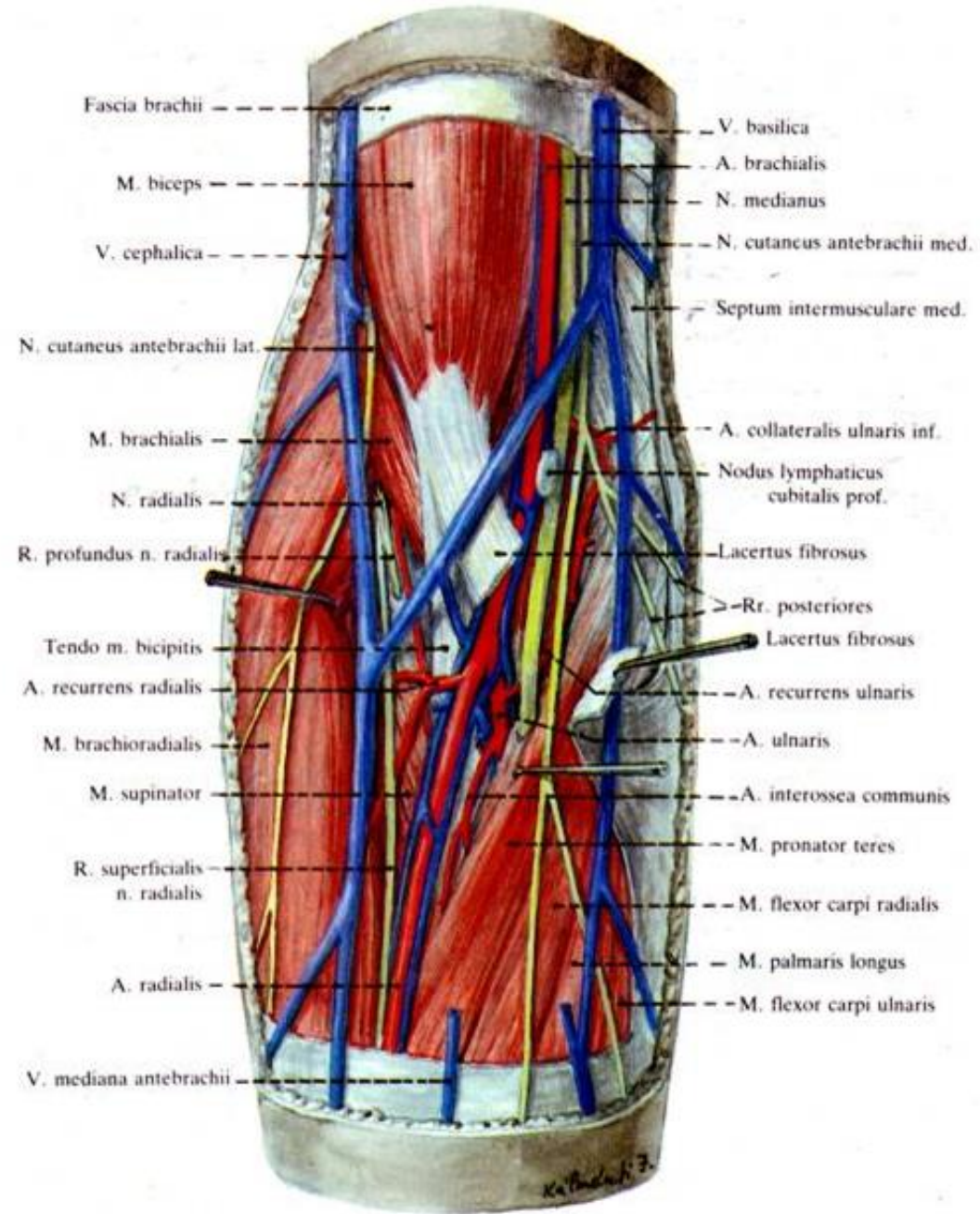


Posterior region of arm

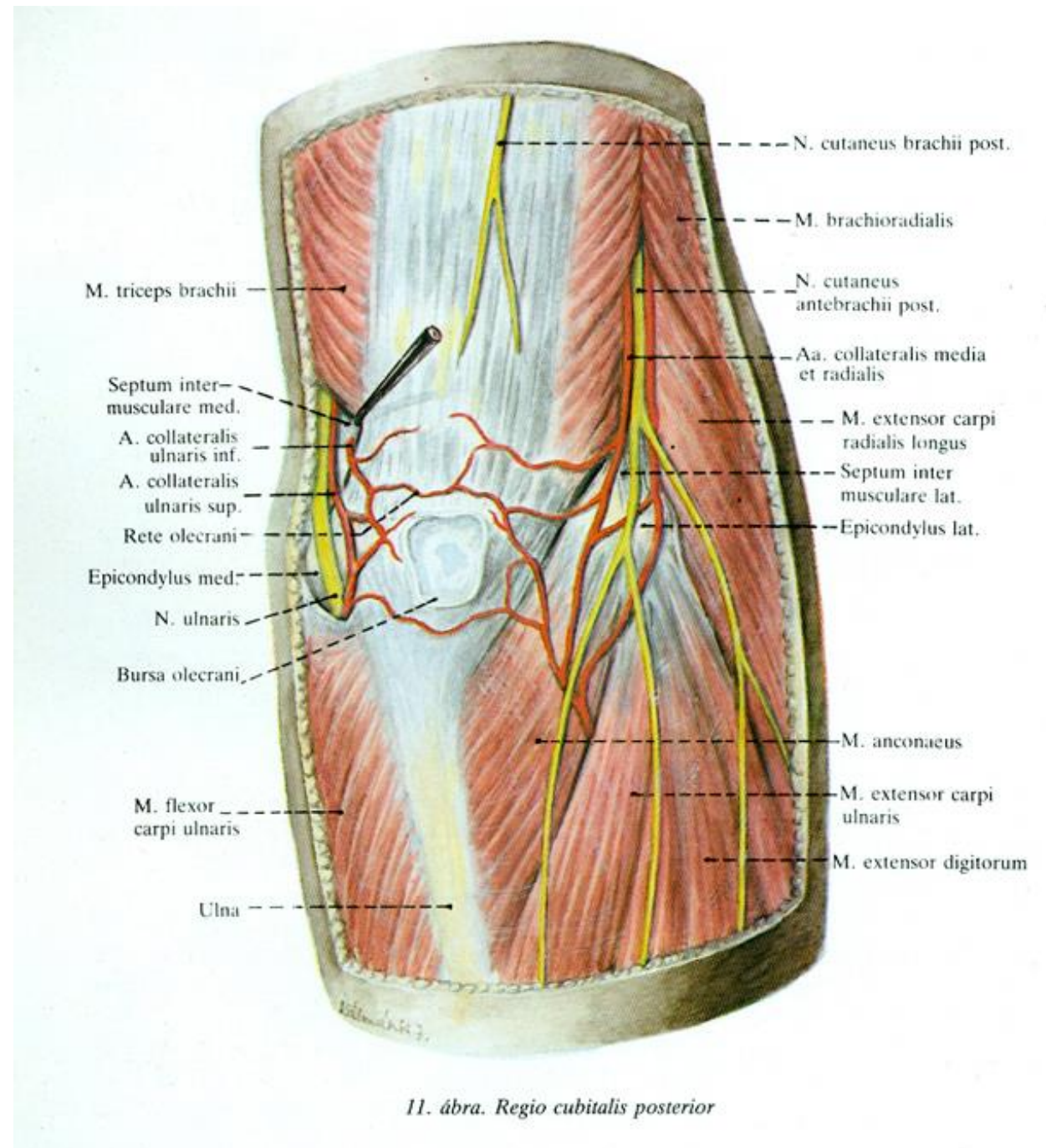


8. ábra. Regio brachialis posterior

Anterior region of elbow

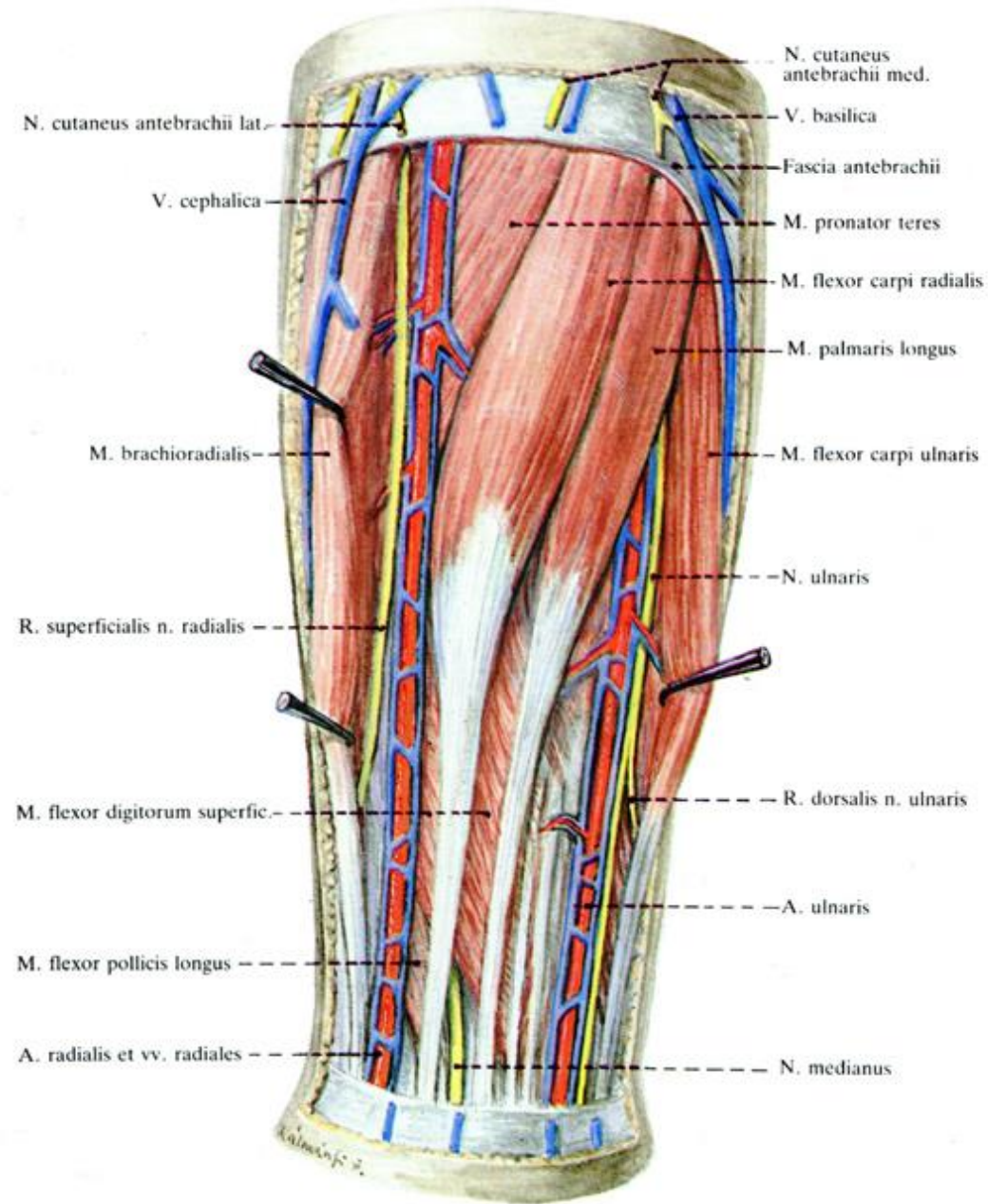


Posterior region of elbow



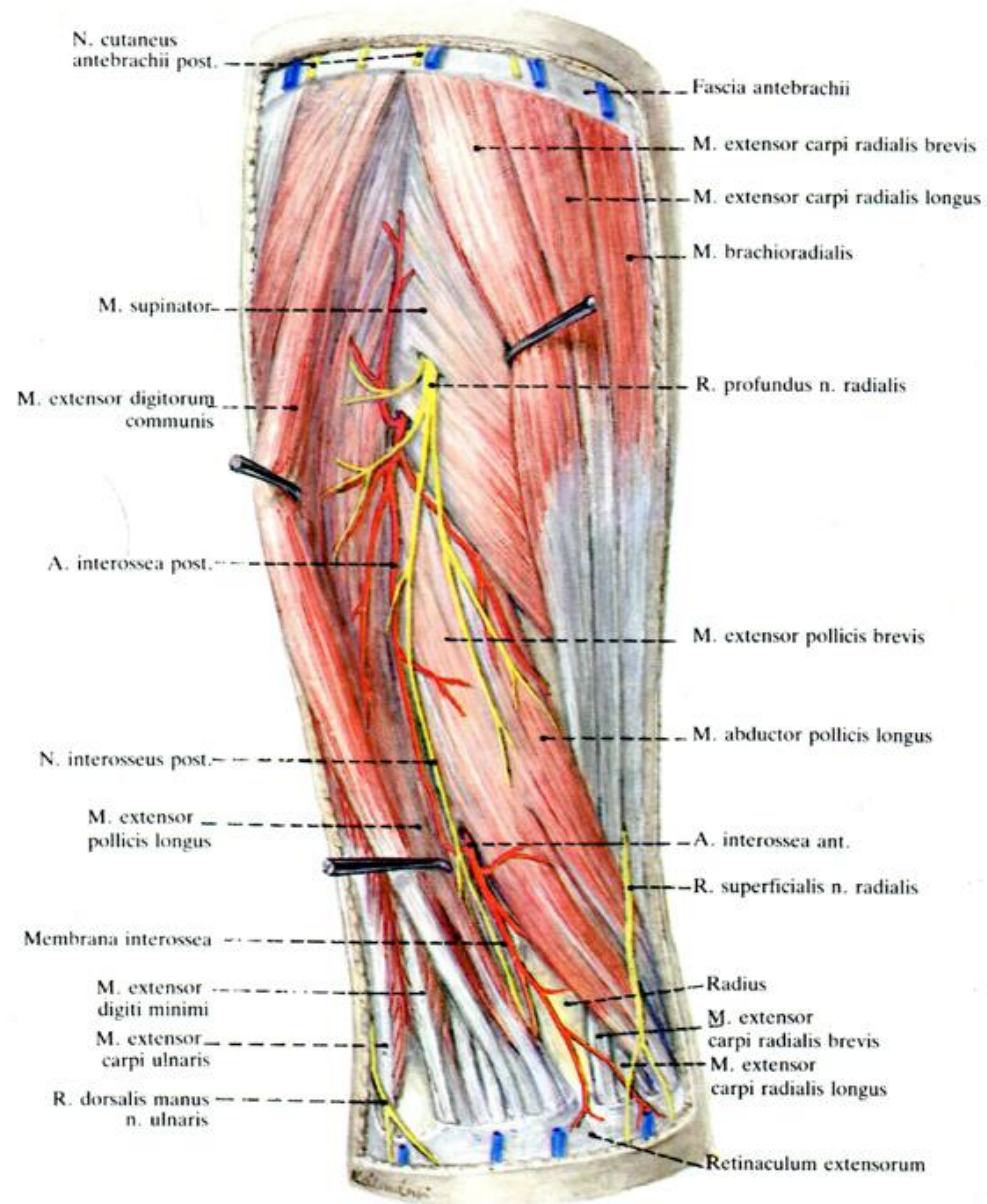
11. ábra. Regio cubitalis posterior

Anterior region of forearm



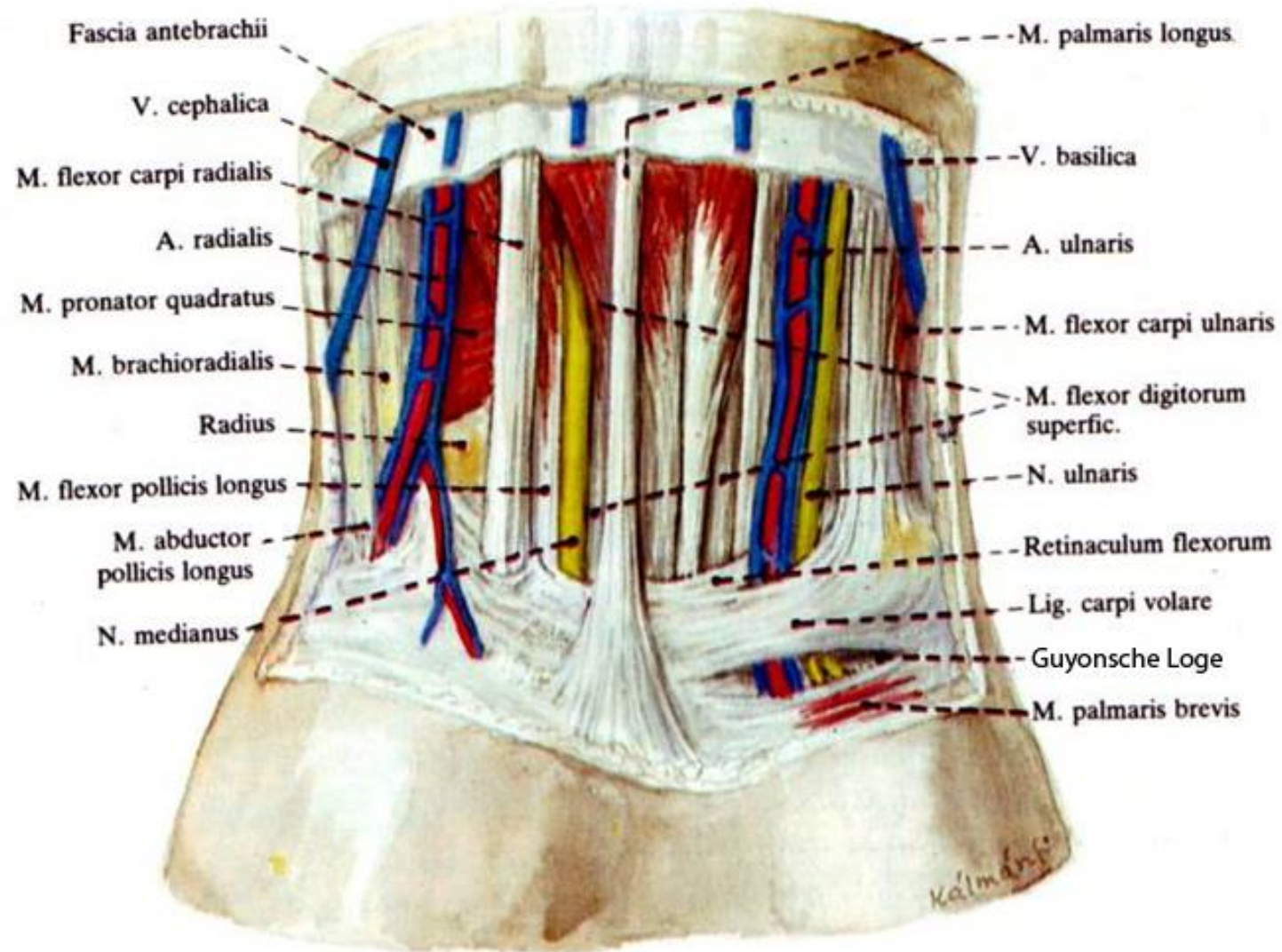
12. ábra. Regio antebrachialis anterior
Felső réteg

Posterior region of forearm

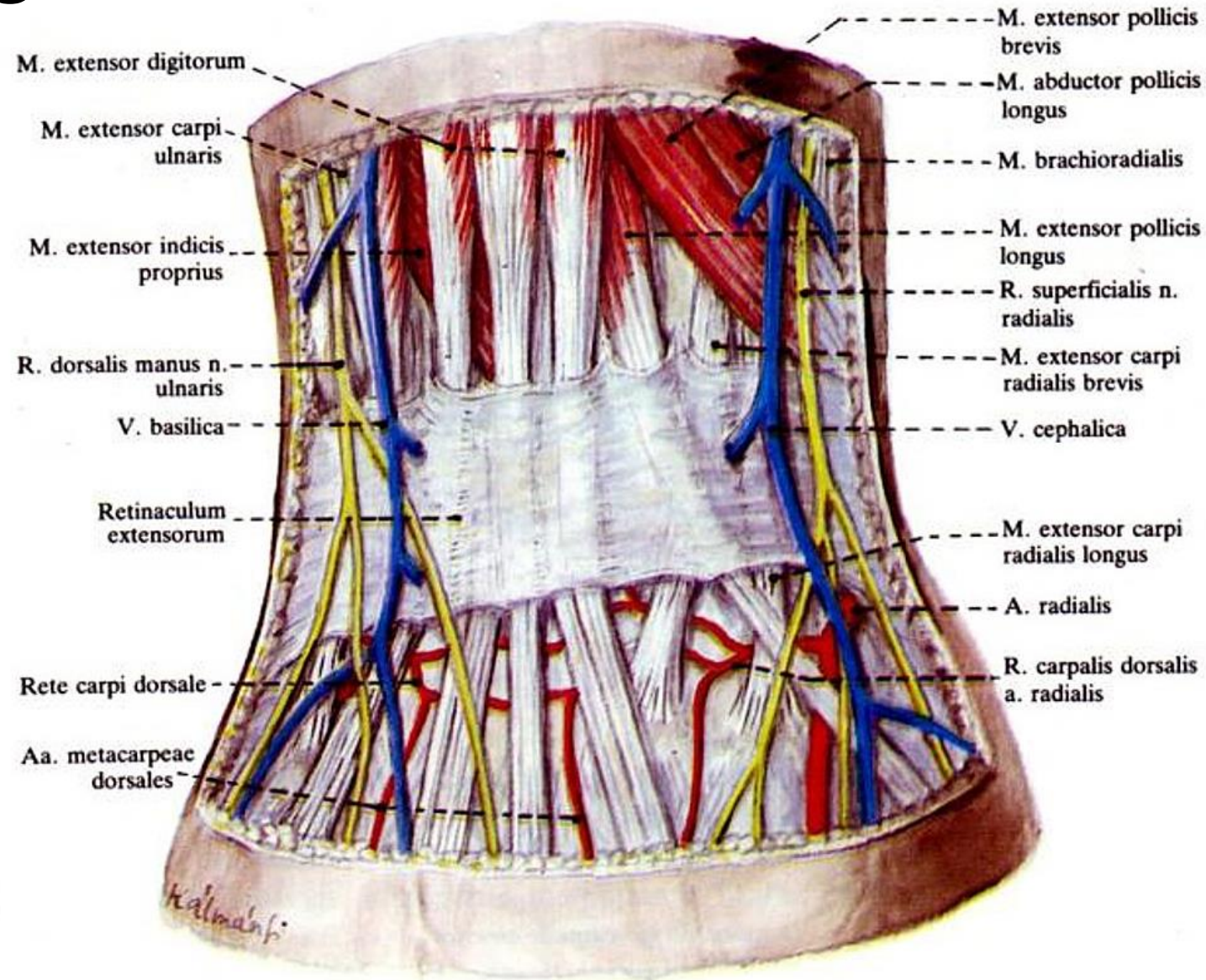


14. ábra. Regio antebrachialis posterior

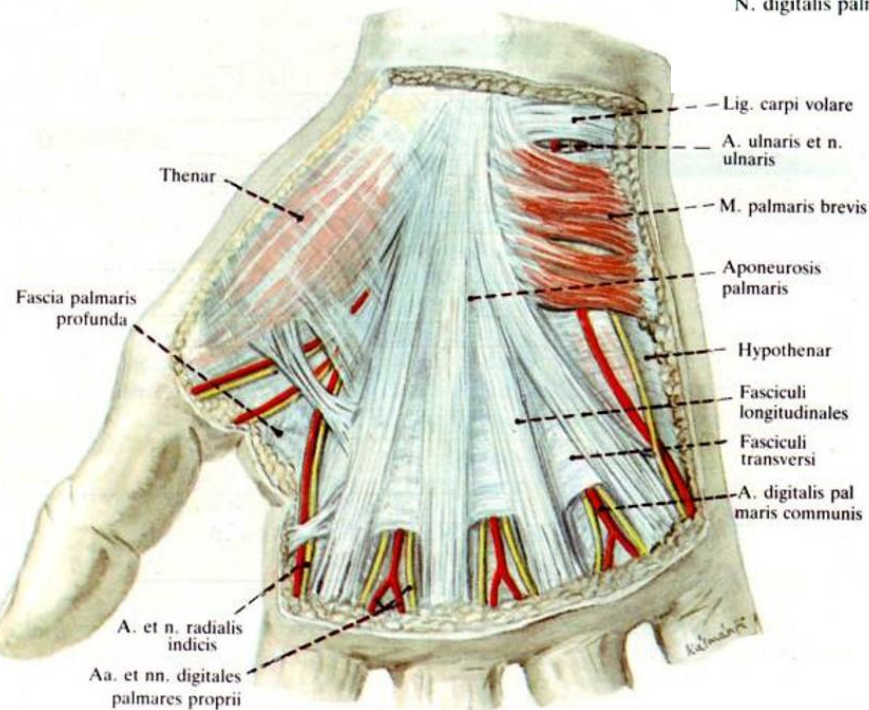
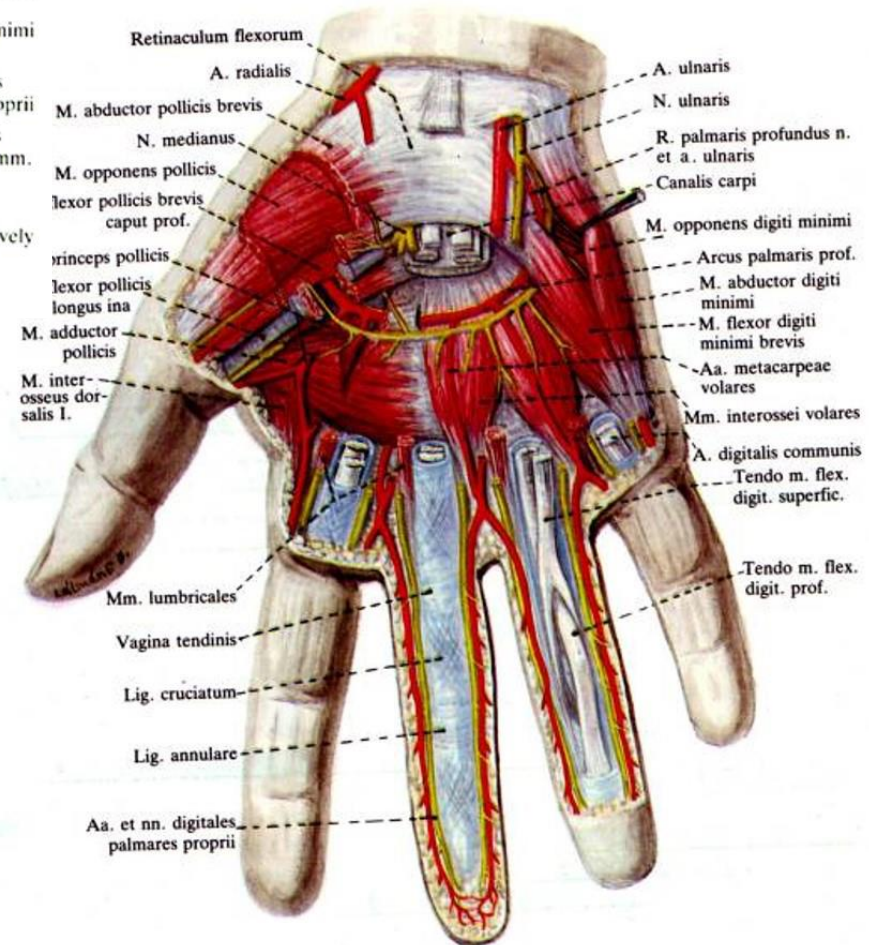
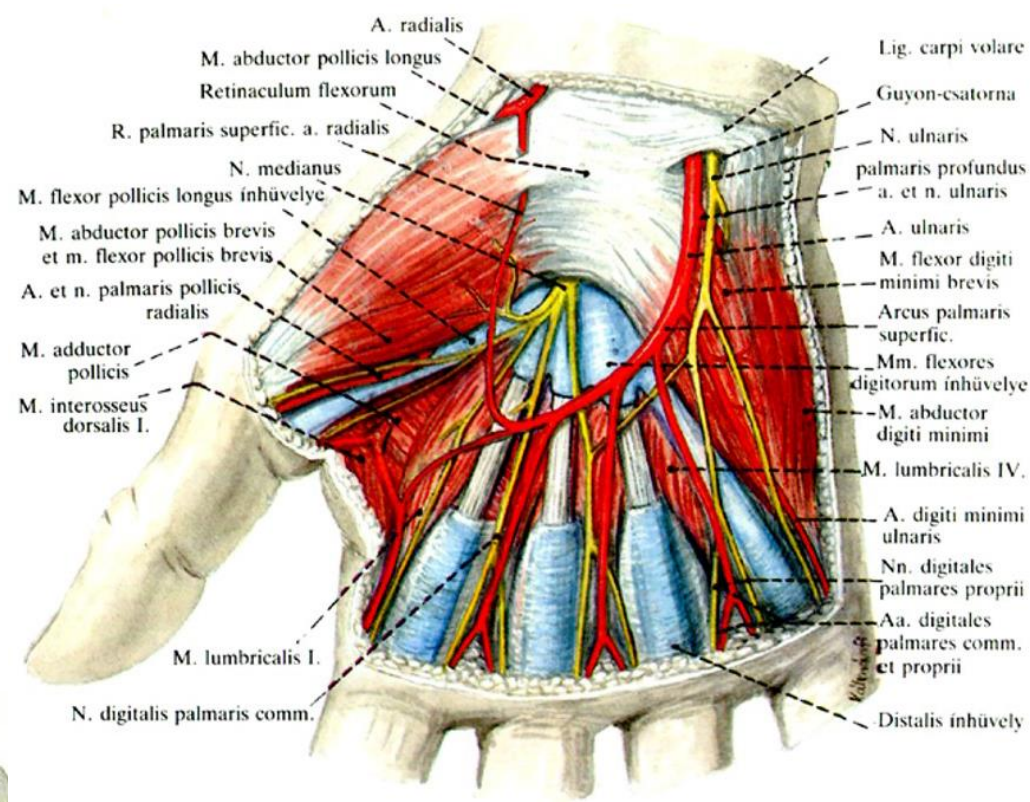
Anterior region of wrist



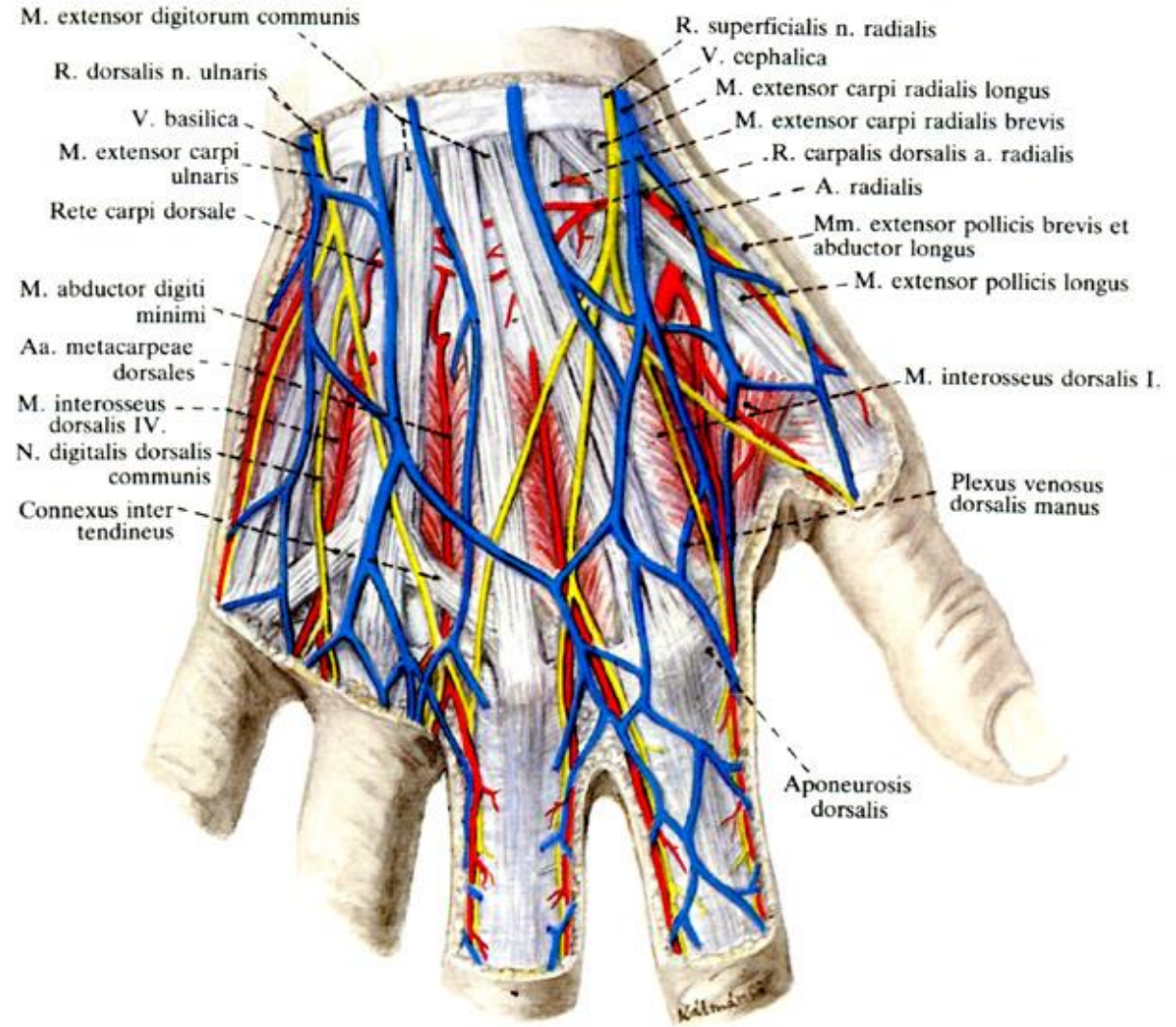Posterior region of wrist



Palm

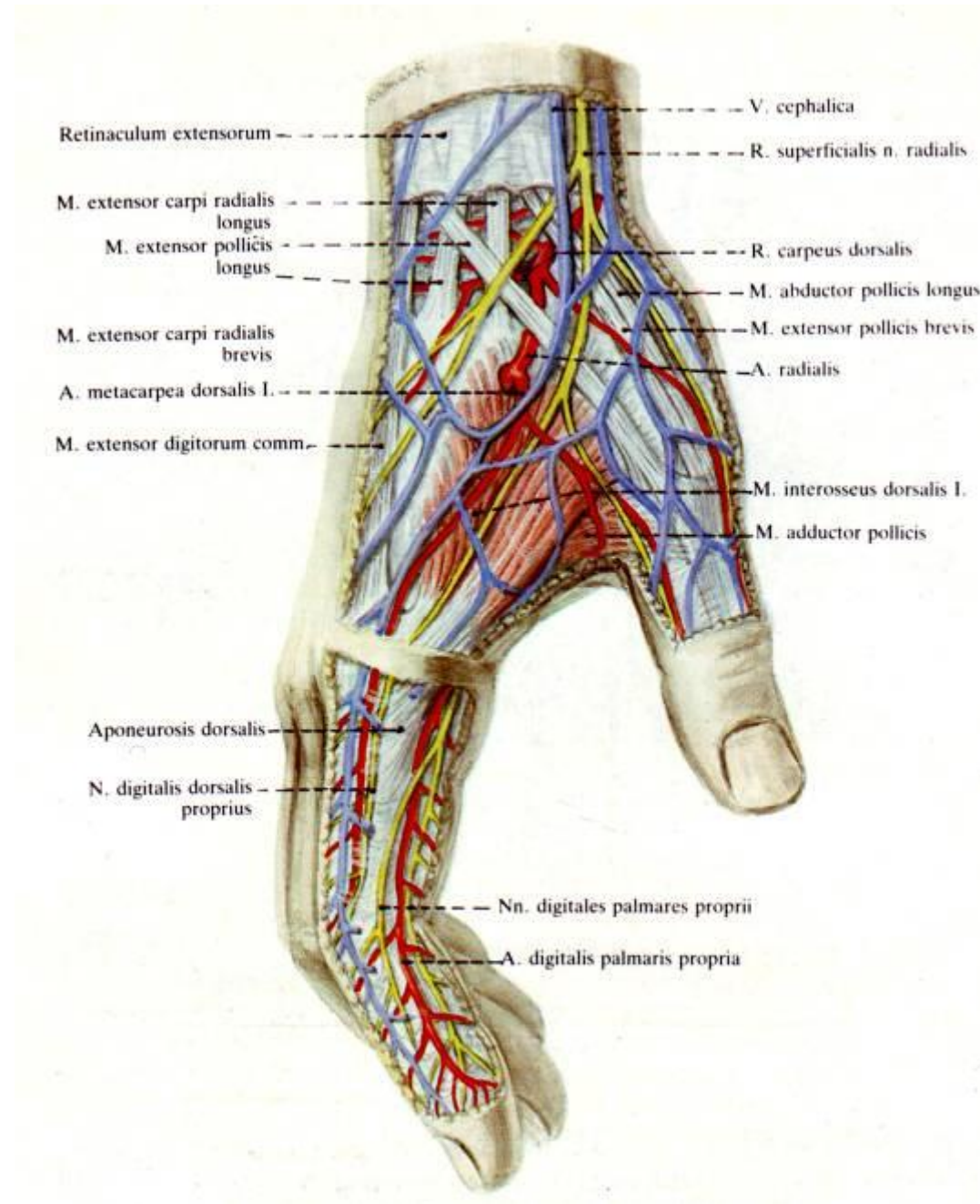


Dorsum of hand



20. ábra. Dorsum manus

Radial fossa



Thank you for your attention!