



*Servamus vitam atque  
servimus*

# Prosthodontics I.

24 March 2021



*Servamus vitam atque  
servimus*

# Prosthodontics I.

## Basic gnathological terminology

Szilvia Ambrus

Department of Prosthodontics

24 March 2021

# Gnathology

- gnathos (jaw) + logos (science)
- For some dentists: precise determination of jaw relation (upper and lower jaw, contact of the teeth)
- According to the extended definition: all the surrounding organs included (TMJ, head, neck, ear) – craniomandibular/temporomandibular disorders (CMD/TMD)



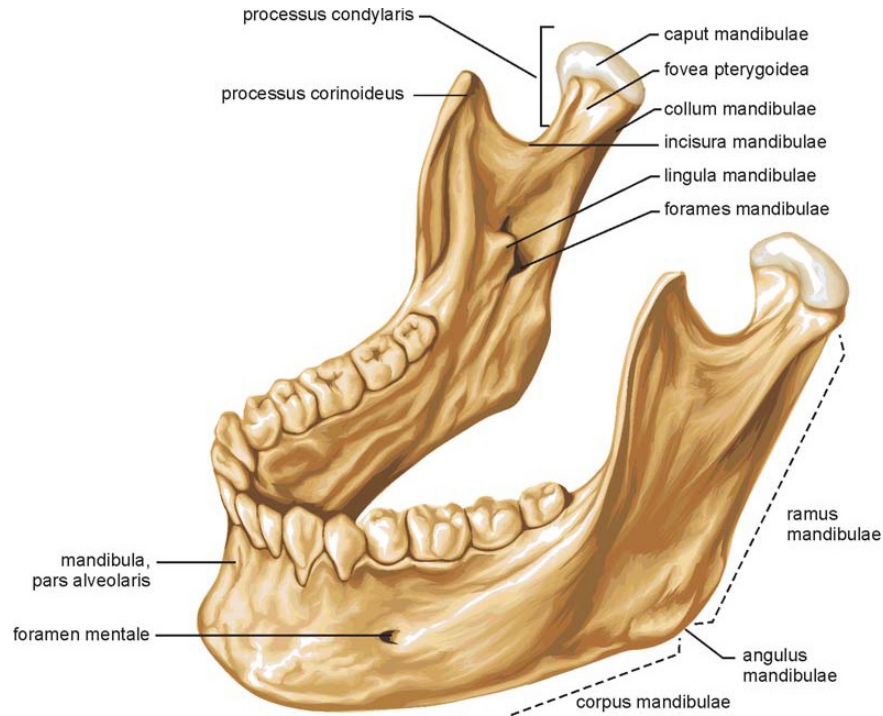
# Gnathology

A science about the anatomy,  
physiology, functional disturbances  
and treatment of the masticatory system.

/András Szentpétery/

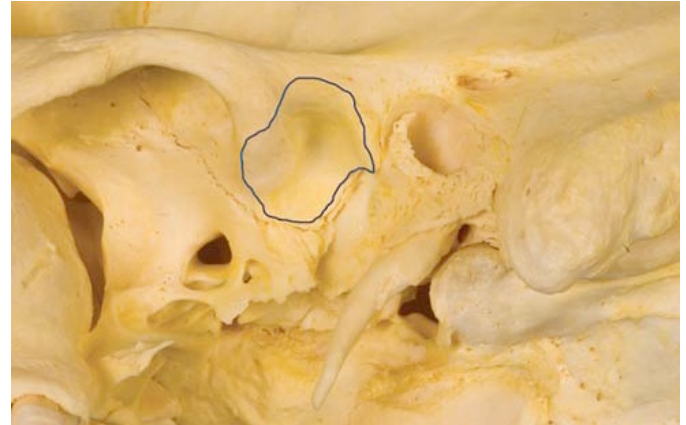


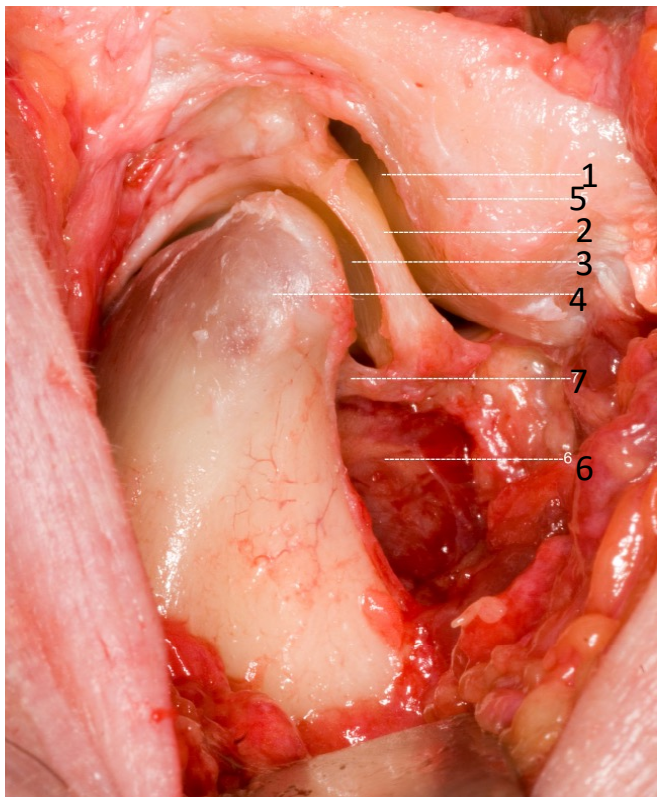
# Bony structures: mandible



## Bony structures: articular fossa (glenoid fossa)

- Os temporale fossa mandibularis and tuberculum articulare
- Mesial border: eminentia articularis
- Curved in anteroposterior és mediolateral directions

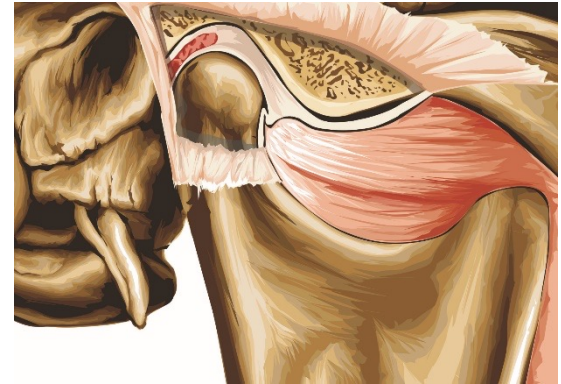




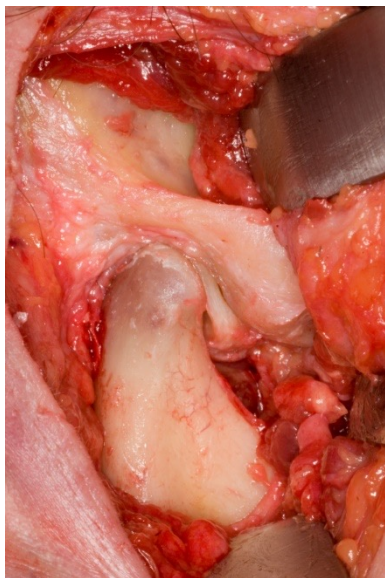- 1. articulatio disco- temporalis
- 2. discus articularis
- 3. articulatio disco-mandibularis
- 4. caput mandibulae
- 5. tuberculum articulare
- 6. m. pterygoideus lateralis
- 7. capsula articularis

# Temporomandibular joint

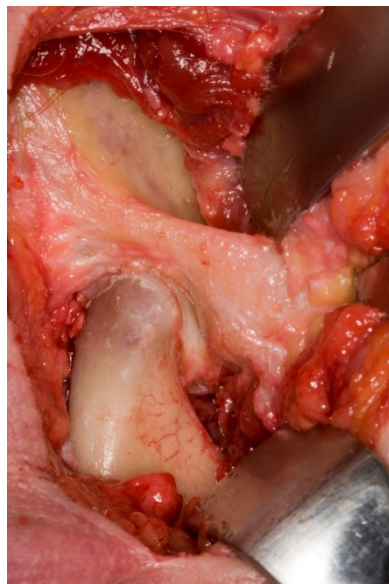
- Ginglymoarthroidal joint (inging and gliding movement), the borders of the movements are defined by the anatomical structures
- Mandible is "hanging on" two articulations
- Articular surfaces are covered by fibrocartilage, not by hyaline cartilage



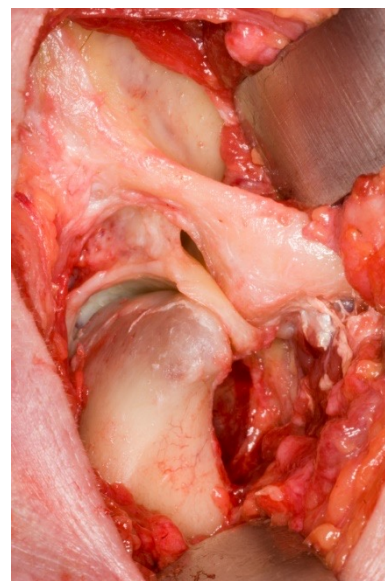




Retruded contact position  
(RCP)



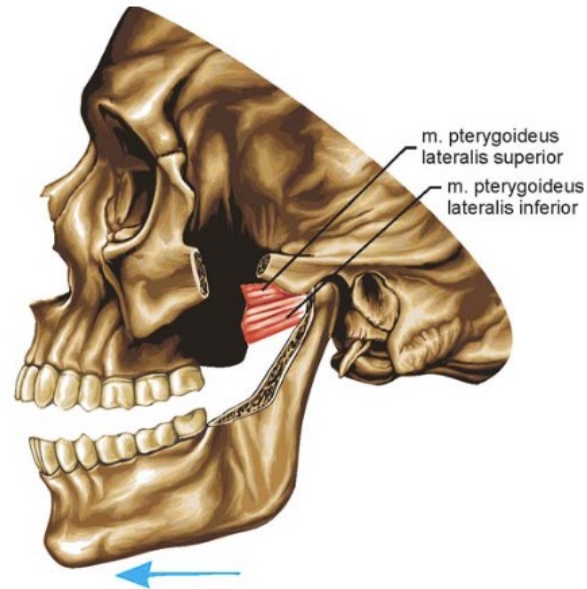
Centric relation (CR)



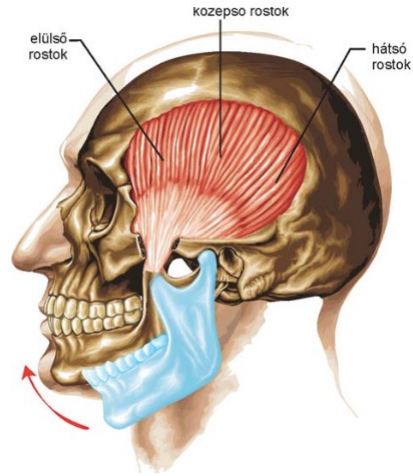
Propulsion

# Mouth opening muscles (abductors)

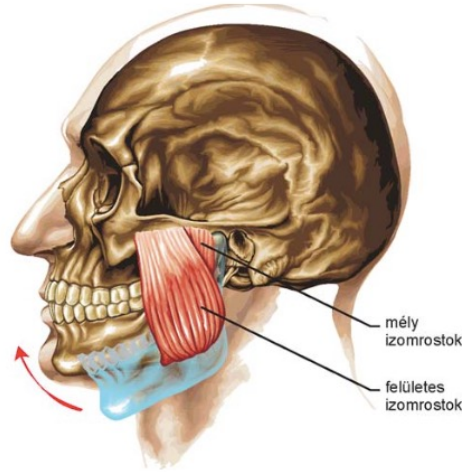
- Lateral pterygoid muscle
  - inferior head: opening and propulsive (forward) movement
  - superior head: closing and retrusive (backward) movement
- Digastric muscle, anterior belly
- Geniohyoid muscle
- Mylohyoid muscle



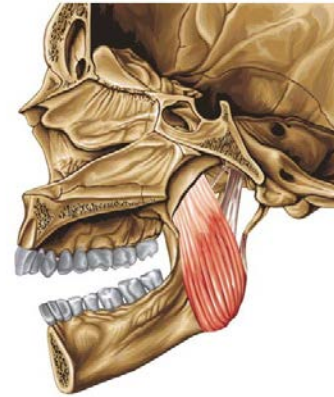
# Mouth closing muscles (adductors)



M. temporalis



M. masseter

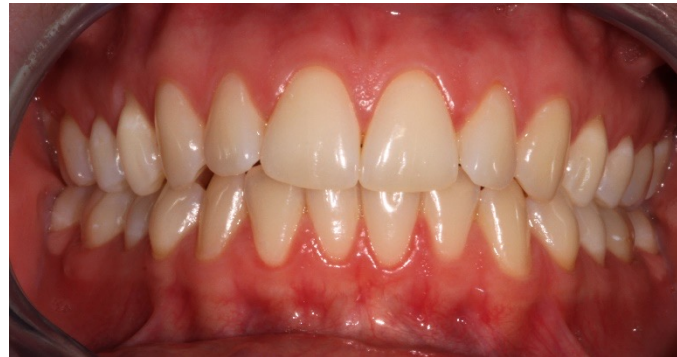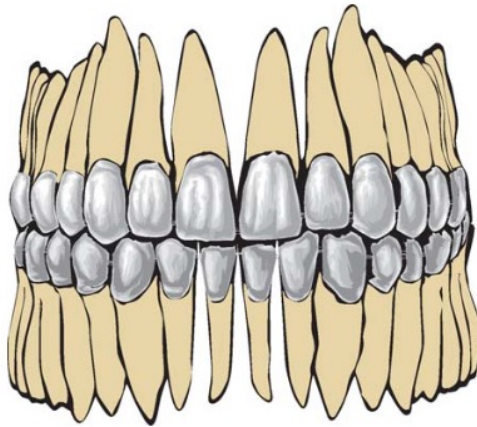


M. pterygoideus medialis

# Occlusion

Contact of the elements of the masticatory system (including the functional and morphological elements of the antagonistic teeth of prosthetic appliances) during normofunction, dysfunction and parafunction.

(Jablonski, 1982)



## Disclusion

No contact of the antagonistic teeth  
while opening or other movements

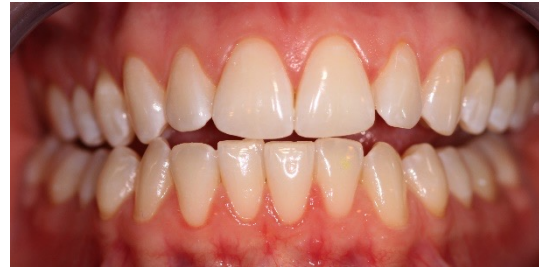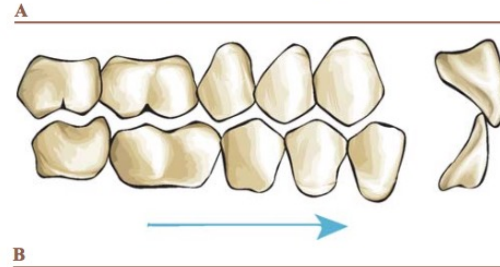
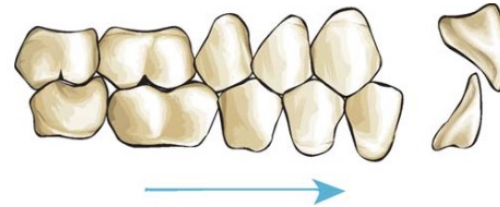
## Nonocclusion

No contact of the antagonistic teeth  
regarding one or more occlusal units  
in intercuspal position  
(dental anomalies)



# Articulation movement

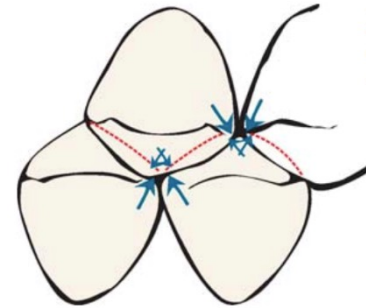
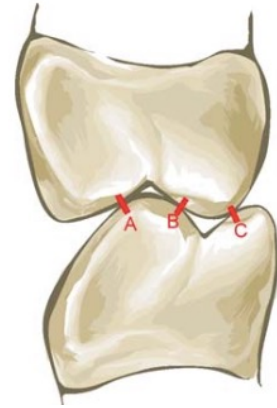
- Jaw movement while teeth are in contact
- Dynamic occlusion: occlusal contacts following each other while moving the jaw



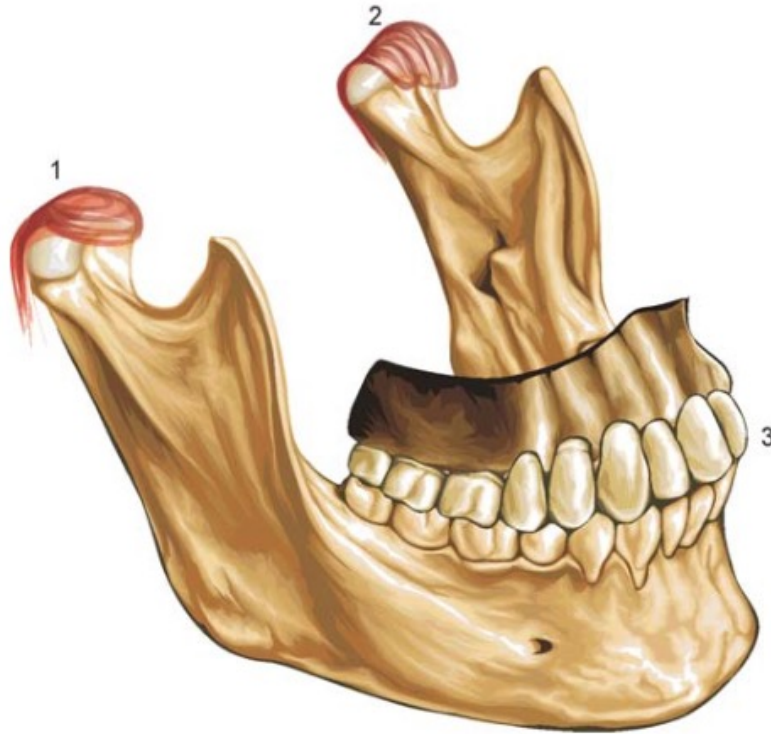


# Occlusal contacts in normal dentition

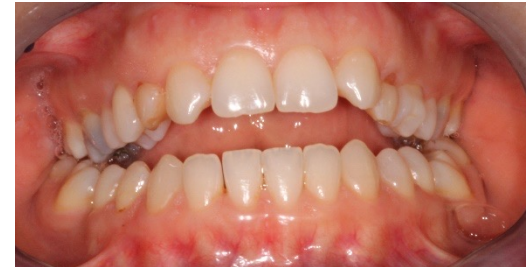- Cusp-fossa contact (tripodistic contact)
- Cusp-marginal ridge contact (bipodistic contact)



# Determinants of occlusion

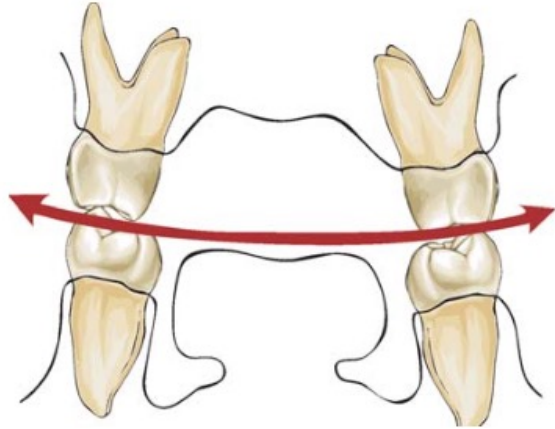


- posterior: left and right temporomandibular joints
- anterior: teeth
- neuromuscular factors



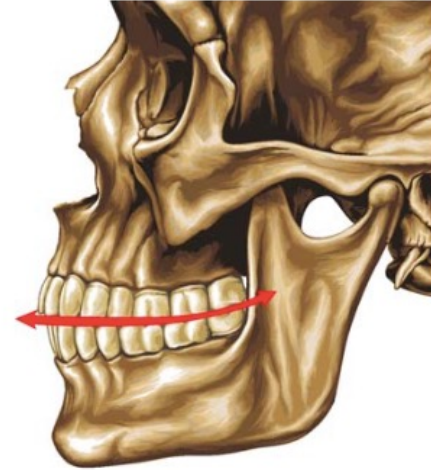


## Monson-curve / Wilson-curve



- A curve on the vestibular and oral cusps of the molars at both sides: transversal compensatory curve

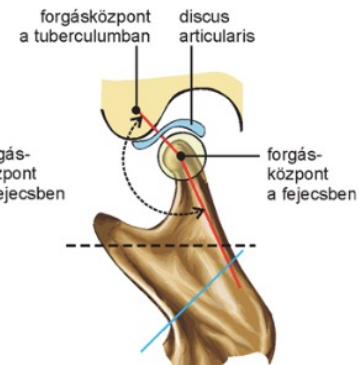
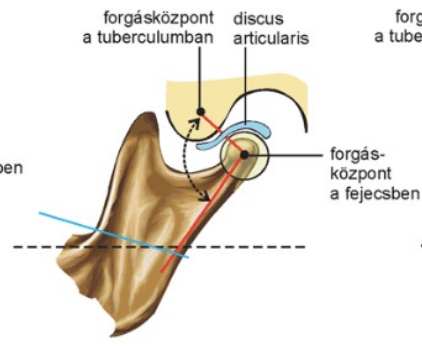
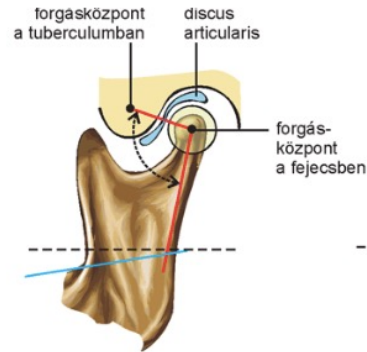
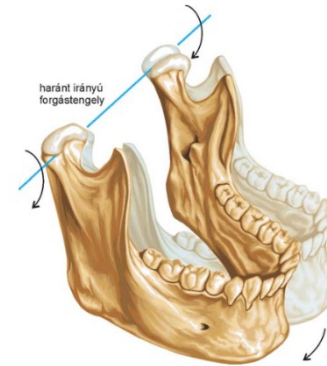
## Spee - curve



- A curve on the bucal cusps of the teeth: transversal compensatory curve

# Basic movements of the mandible

- hinge / rotation
- gliding / translation



# Reference positions of the mandible

- Rest position
- Intercuspal position
- Centric relation
- Centric occlusion
- Retruded contact position




# Change in the terminology

- Fast progression in the last decades

- eg. Condyle in centric relation

Most upper- most backward



Most upper- most forward

- Important to speak the same language...

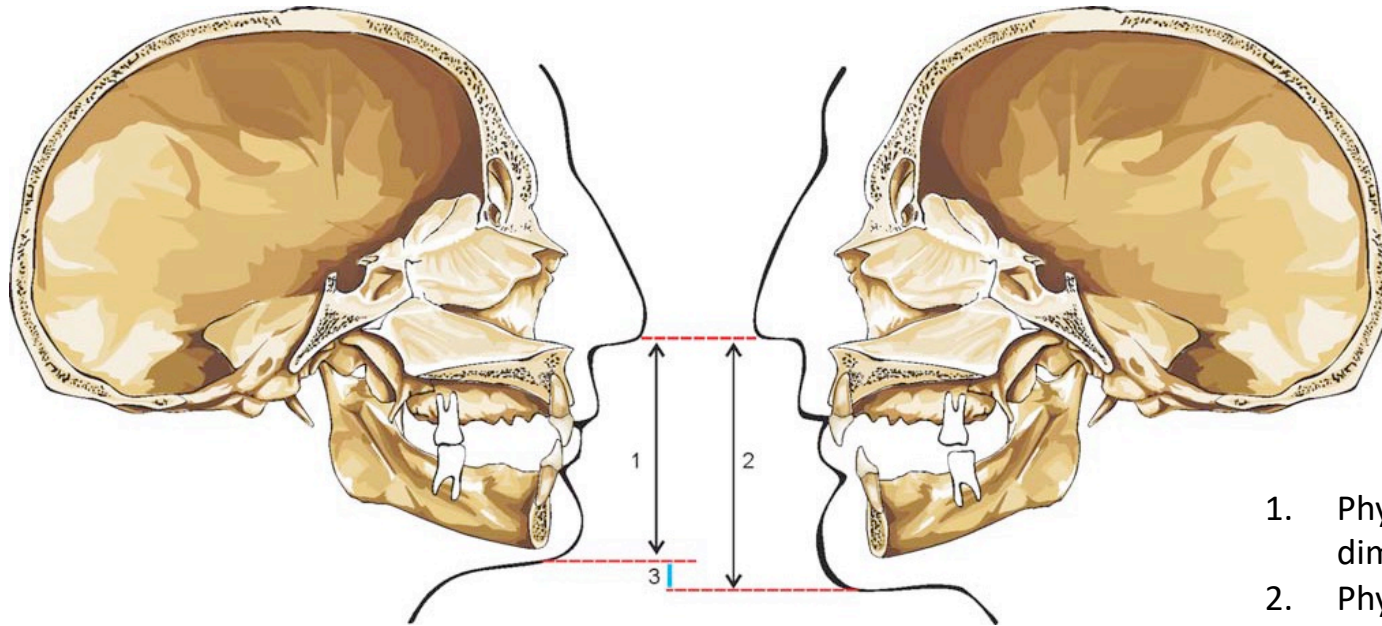
# Rest position

- normal posture, with relaxed masticatory muscles, determined by muscle physiology
- physiologic rest position = Rest Vertical Dimension (RVD)  
the distance between the upper and lower jaws in rest position

„the postural jaw relation when the patient is resting comfortably in an upright position and the condyles are in a neutral, unstrained position in the glenoid fossae”



# Importance of the rest position



1. Physical vertical dimension (OVD)
2. Physiological vertical dimension (RVD)
3. Interocclusal space

**It can be determined without occlusal units!**

# Determining the rest position (RVD)

– Two arbitrary marked points in the midsagittal plane of the face –

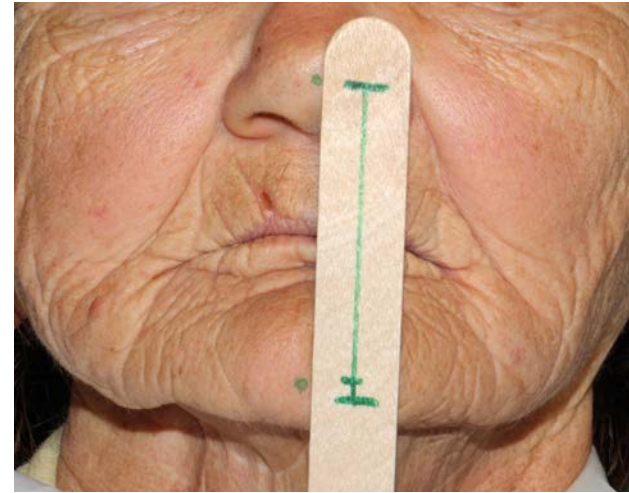
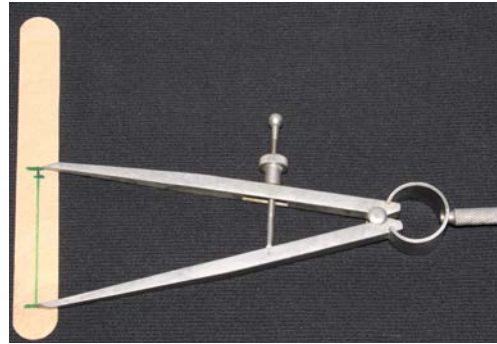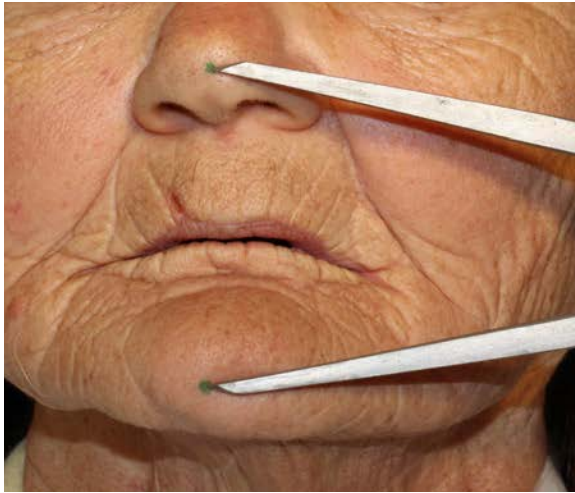
## Conventional methods

- RVD: Lips touch each other slightly
- OVD: Phonetic method (Silverman): pronunciation of sibilant sounds coincide with the OVD position /sssss/
- RVD: by swallowing

RVD → OVD (occlusal vertical dimension)



# Lips touch each other slightly





## Intercuspal position (ICP)

- *intercuspal position (ICP) = maximal intercuspal position (MIP)  
= maximal intercuspation (MI)*

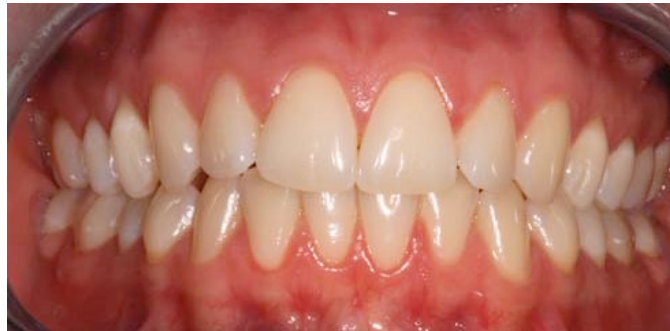*Closest possible position, contact of the teeth*

*Anterior determinant, independent of the joints*



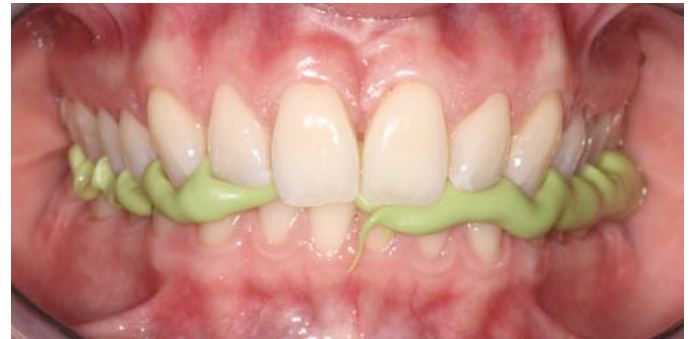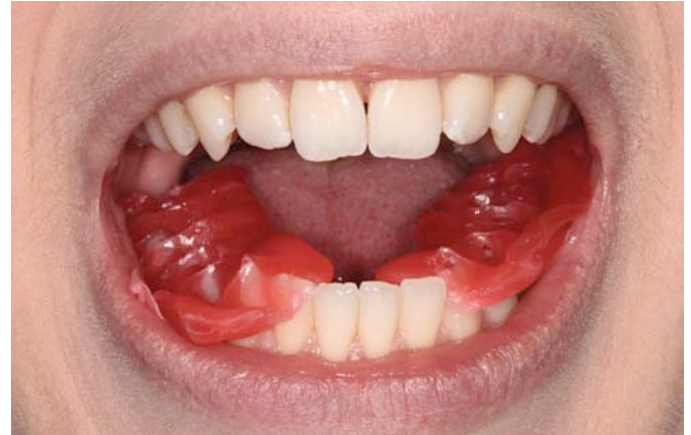# Importance of ICP

- If there are occlusal units with a stable occlusion, easy to register
- „bite registration”



# Registration of ICP

- Wax bite
- Silicon 'wax bite'



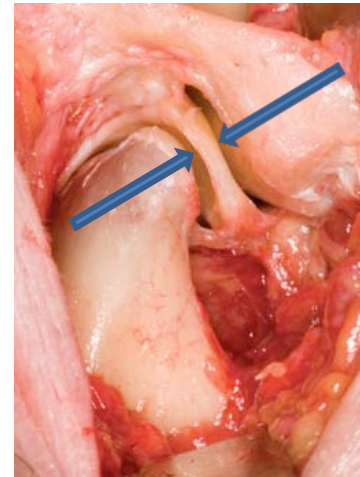
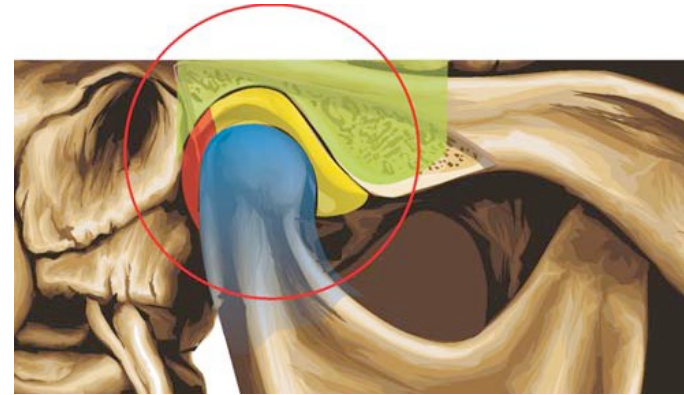
# Centric relation (CR)

- Jaw relation, where the condyles are in the most upper - most anterior position in the fossa articularis
- *Posterior determinant, independent from the teeth.*
- Rotation is possible, but only rotation is possible in this condylar position

~~Years 1950-1960: CR described in the most posterior position in the glenoid fossa~~



- According to the up-to-date view: centric relation is a musculoskeletally stable position (versus earlier views: strong ligaments-concept)



# Centric relation – summary

- independent of the teeth
- caput mandibulae touches the middle thin avascular part of the articular disc
- condyl is in the most upper most forward position in the fossa
- in centric relation: only rotating movement of the condyls
- musculoskeletally stable position
- clinically useful position



# Importance of centric relation (CR)

Prosthodontics → modelling the teeth and the relation of the jaws

Occlusal units present and we keep the vertical dimension

→ we **register** the intercuspal position (ICP)

No contact in the natural dentition

Edentulous patient

We want to change the vertical dimension

→ we **determine** the RVD → OVD

(→ centric occlusion...)



# Centric occlusion (CO)

- contact of the antagonistic teeth while the condyles are in centric relation (CR)
- Teeth are touching each other...
  - and the condyles are in the most upper – most anterior position –» CO
  - And we have no information about the condyles –» ICP
- In 0-35% of the population ICP = CO
- If ICP is not in CR: there is a 'centric slide' from CO to ICP





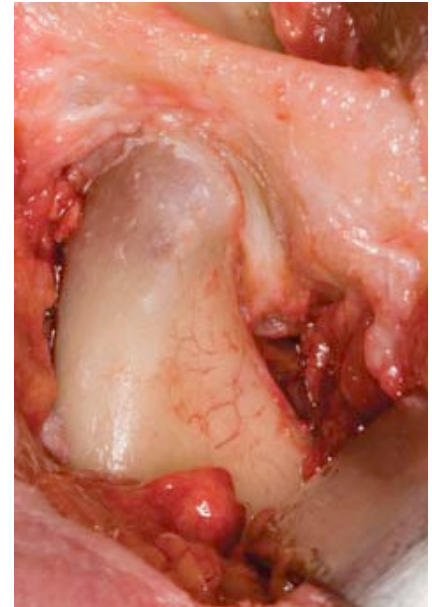
# Clinical aspects: what to register and determine

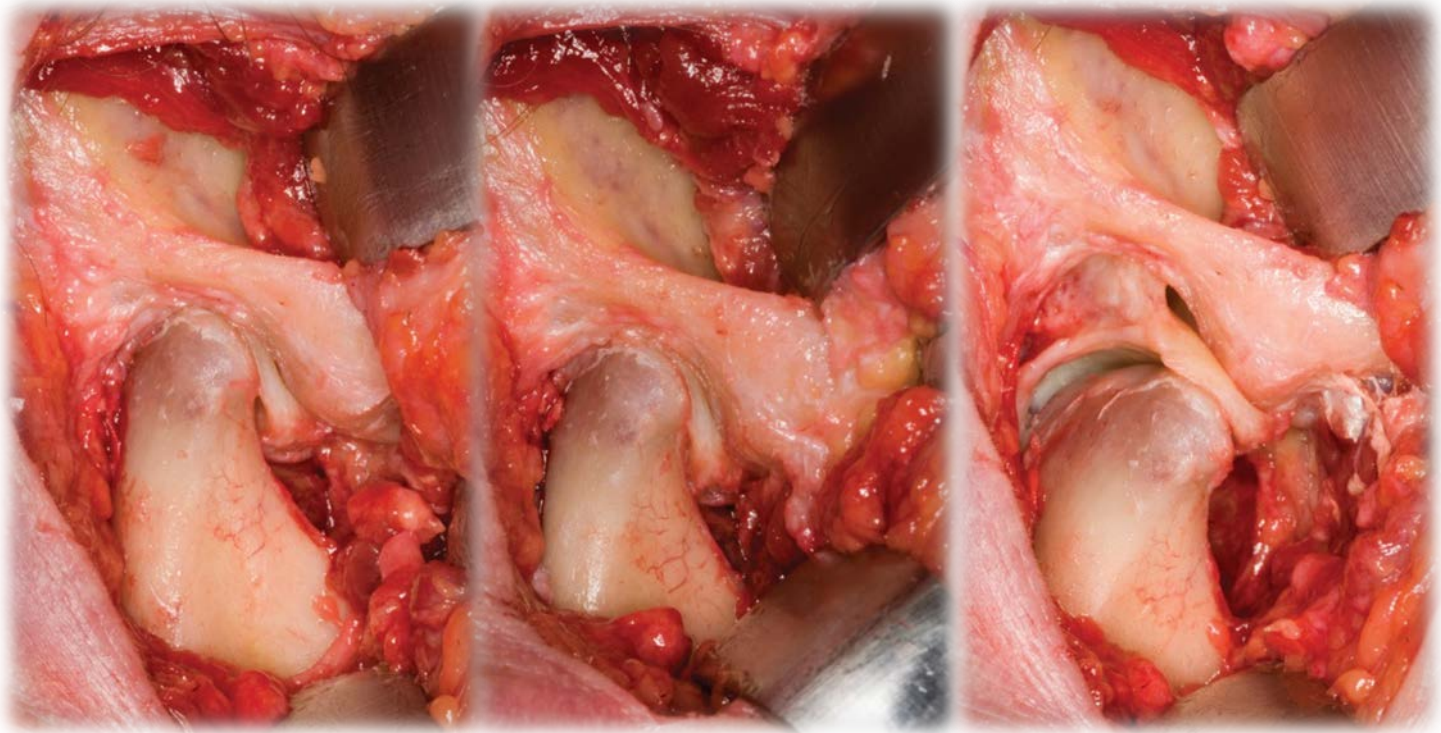
- There are occlusal units (=ICP) →» **registration** of ICP
- No occlusal units or not stable, or we want to change the ICP →» **determination** of CR
- Determining the centric occlusion (CO) = determination of centric relation (CR) and registration of "the occlusion" in this jaw position



# Retruded contact position (RCP)

- The most posterior possible position of the condyles with contact of the teeth
- Reached by muscle activity
- RCP is not ICP : RCP is not accepted any more!





RCP

CR

Opening

# Mandibular positions

	Joints	Teeth
<b>Rest Position (RP)</b>	centric	n.a.
<b>CR</b>	upper-anterior (cranioventral)	irrelevant
<b>CO</b>	upper-anterior (cranioventral)	occlusion – somewhere
<b>ICP</b>	irrelevant	Maximal intercuspal position
<b>RCP</b>	upper-posterior	present (1 occlusal unit)
<b>CR=IKP</b>	upper-anterior (cranioventral)	Maximal intercuspal position ~ 5 % -a



# Thank you for your attention



pin: ULG

