



Important information

Department of Conservative Dentistry

2018/2019 1th semester





Department of Conservative Dentistry

- Attendance list taken every time!(lecture/practice)
- Student card for certification is needed
- Student can check absences in the JENYI system
- Being late 25 %of time= absence
- Three times being late = 1 absence
- Max. 25% of classes can be missed
- No opportunity for retake!
- Manipulating the catalogue means \Rightarrow disciplinary procedure
- Topics: <http://semmelweis-egyetem.hu/konzervalo-fogaszat/education>
- **Pictures and sound recordings are not allowed!** Photos may only be taken for case report



Department of Conservative Dentistry

Practice mark, signature

- **Evaluation: Practice mark** at the end of semester:
 - Oral exam at practices, **theoretically being prepared** for own patient's treatment, result of tests written at the practices, level and quality of **practical work**, assisting, case reports (in IV. and V. year)
 - Result of **the midterm exam**: must be min. grade 2 (that is min. 50 %!)!!!
 - Being late (more than 25 % of time = absence)
 - The practice mark is not object of discussion
 - Successful practical exam in Propedeutics in 1. semester of III. year: condition of signing the semester.
 - Before the final exam at the end of the 1. semester in III year entry questions must be successfully answered.
 - Before the exam the student must prove his/her identity by showing his/her identity card.
- **Refusal of signature** (= repetition of semester), if:
 - Practice mark does not reach 2
 - Absence more than **25%** of practices (more than 3 times!)
 - Lack of one documented **case report** confirmed by the teacher (**till the end of 14. week)(Clinical practice)**
 - Fulfilling the above mentioned conditions does not automatically mean excepting the semester
 - If a student's performance in practice is insufficient the teacher can refuse the signature even if the student has met the above mentioned criteria



Department of Conservative Dentistry Clinical Practice

- Keeping to rules of „Students Practice Room Rules” is obligatory
- Submission of case report: **13th week** of semester (except: 5th year second semester: 11th week)

All students must be able to communicate with their patient.

Student cannot treat patient, if:

- student is not in Neptun system
- student is theoretically not prepared for treating own patient
- patient is not registered at patient reception
- patient is not in national healthcare system



Department of Conservative Dentistry

Midterm

- The midterm is a **30 minute exam at lecture (10th week)**
 - Topics of the first 9 lectures of the semester and the related topics of the textbook (from propedeutic subject also practical questions)
- Retakes:
 - Two times (time will later determined)
 - For those who have missed or failed the midterm
- Using any aiding methods means **disciplinary** procedure, an invalid test and a fail (1) on the midterm exam



Department of Conservative Dentistry Administration

- **Index:**

- **Practice mark:** given by practice teacher on last practice of semester, in Neptun
- **For the exam** the pre-printed **performance sheet** must be brought



Department of Conservative Dentistry Textbooks

Sturdevant's Art And Science Of Operative Dentistry.

Sixth edition. Edited by H. Heymann , Swift jr. and Ritter
Mosby, St Louis, 2012

Walton RE, Torabinejad M ed.:
Endodontics: Principles and Practice
Saunders 2009



Preventive endodontics: significance of the pulp protection. Endodontal diagnostics

Dr. Peter Komora, DMD

Semmelweis University, Faculty of Dentistry, Department of Conservative Dentistry

References:

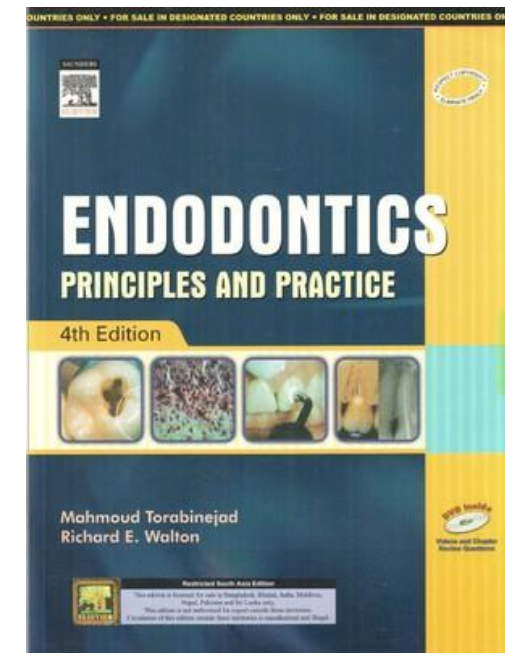
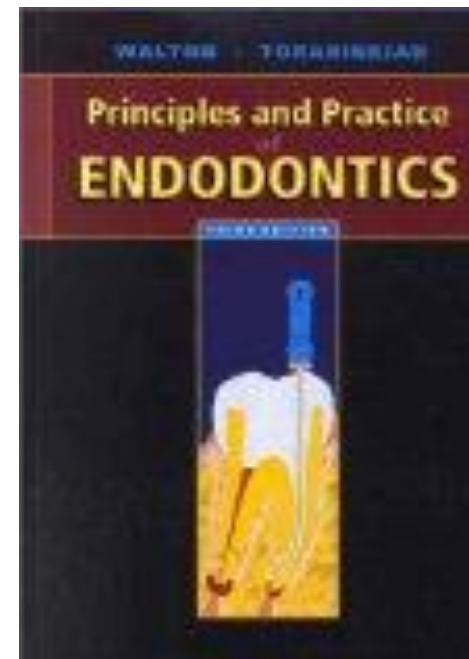
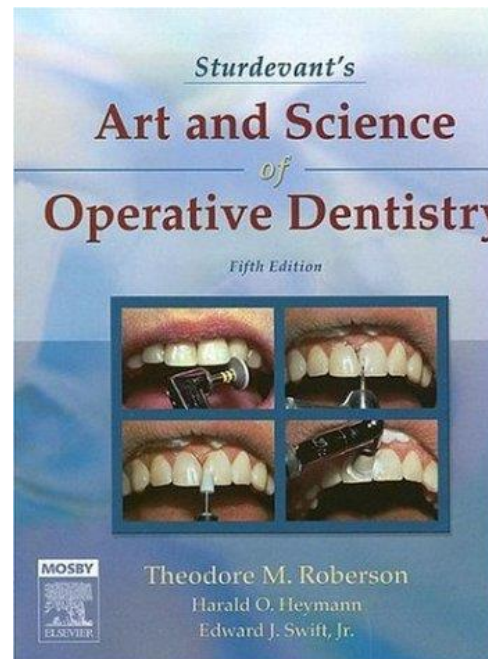
Luc van der Sluis, Edwina Kidd, Rene Gruythuysen, Linda Peters: **Preventive endodontics – an argument for avoiding root canal treatment.** ENDO (Lond Engl) 2013;7(4):259–274

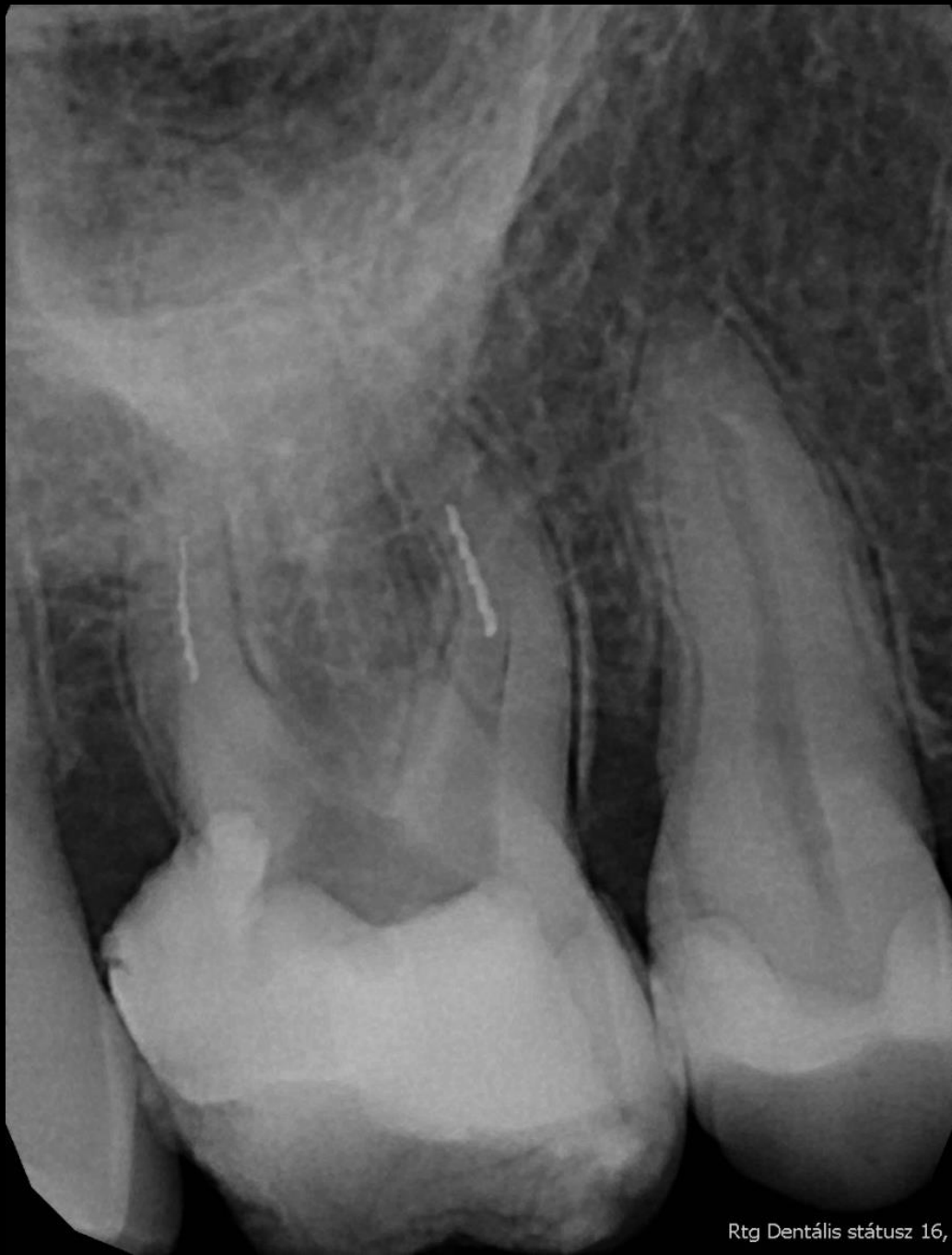Árpád Fazekas: Megtartó fogászat és endodoncia; 2006

komorapeter@gmail.com

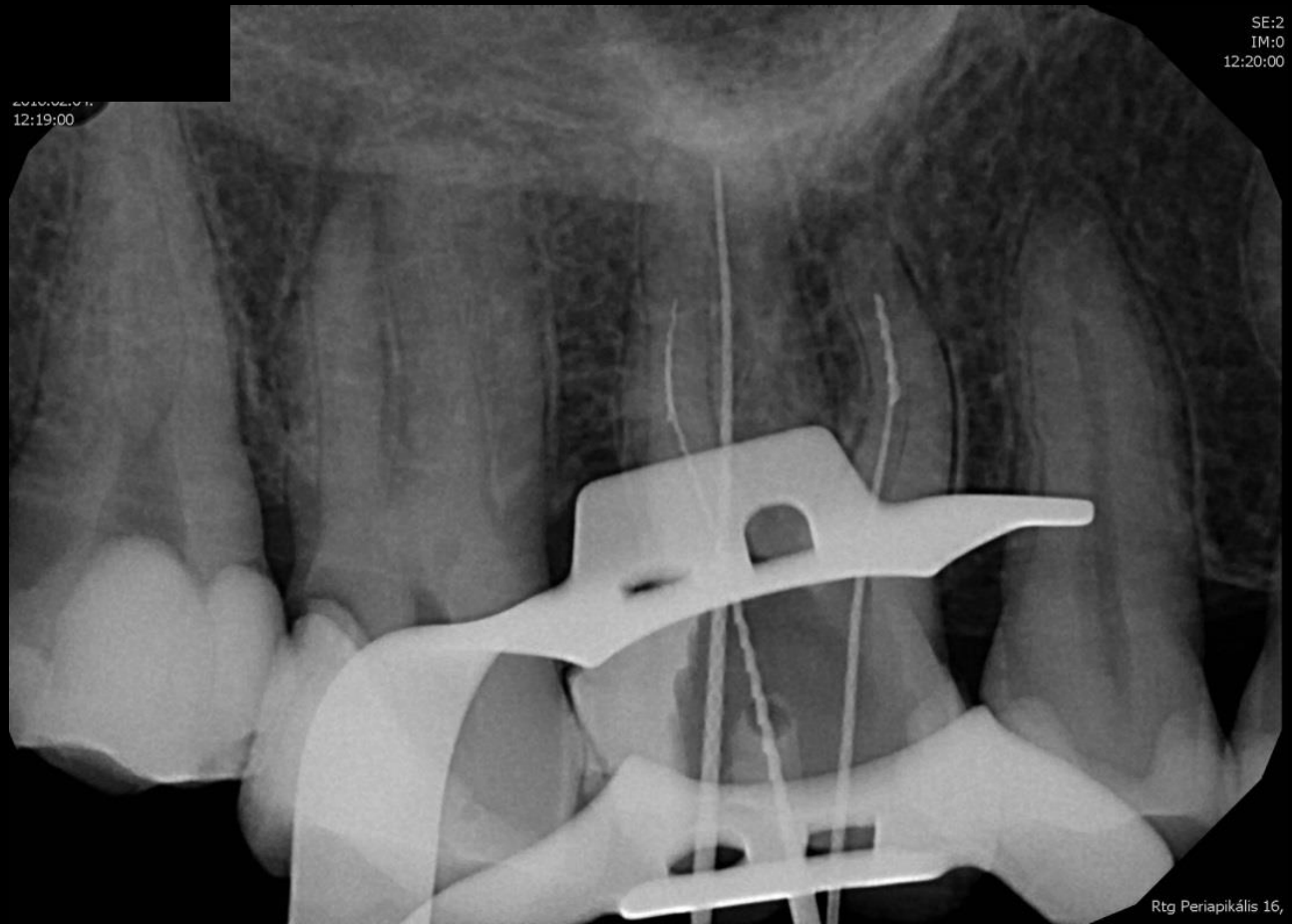


- E. Hellwig/J.Klimek/T.Attin – Einführung in die Zahnerhaltungskunde
- Fazekas Árpád – Megtartó fogászat és endodoncia
- Sturdevant's Art and Science of Operative Dentistry
- Walton RE, Torabinejad M ed.: Endodontics: Principles and Practice





Rtg Dentális státusz 16,



SE:2
IM:0
12:20:00

2010/02/01
12:19:00

Rtg Periapikális 16,

Introduction

- The success rate of endodontic treatment depends on a lot of factors (canal anatomy, microorganisms, etc.)
- Exclusively by means of a periapical radiograph, no exact diagnosis can be made
- Endodontic treatment is both time-consuming and expensive

Introduction

- Due to the root canal treatment (RCT), the physiological functions of the pulp are missing (pulpal sensation, odontoblast activity, etc.)
- Differential diagnosis of reversible and irreversible pulpitis is of great importance
- Root canal treatment is difficult, it is logical to try to prevent it

Prevention: Indications for the usage of different materials under the final restoration

- It protects against: heat, electrical stimuli, mechanical- and chemical effects
- In case of metals (amalgam, metal inlays/onlays): if the thickness of dentine is lower than 1-1.5 mm, base material is needed for the protection of the pulp against heat
- In case of adhesive materials: when the cavity is too deep (old-school): the pulp is covered with a thin layer of dentin, but the pink color of the pulp is already visible through the dentin. New-school: we do not have to use any material in this latter case, as the pulpal circulation is able to compensate the impact of acid-etching even if there is only 40-50 μm thick dentin wall left.

Prevention: Indications for the usage of different materials under the final restoration

- varnishes: 1-50 μm thick layers. They seal the dentinal tubules, and give protection against chemical agents, but not against physical effects (e.g.: heat).
- liners: 0.2-1 mm thick layers. $\text{Ca}(\text{OH})_2$ and glass ionomers.
- base materials: 1-2 mm thick layers (zinc phosphate, zinc oxide eugenol, polycarboxylate, $\text{Ca}(\text{OH})_2$, calcium phosphate, glass ionomer, etc.).

Treatment Options

- Liners
- Indirect pulp capping
- Direct pulp capping
- Vital pulpectomy

Prevention: Methods

- Liners
- Indirect pulp capping: demineralised dentin surrounding the pulp is left in place to avoid pulp exposure and is covered with a biocompatible material. Only in case of patients without any symptom

Prevention: Methods

- indirect pulp capping: mostly performed on children or young adults, but it also can work in the older patient. Although the expensive and complex restorations should be postponed in this latter case.

The philosophy of indirect pulp capping: the preservation of pulpal dentin reduces the chance of exposure, possibly facilitating pulpal regeneration. Avoiding pulpectomy/RCT reduces treatment time and cost, and preservation of the tooth and root structure may increase the longevity of the tooth.

Prevention: Methods

- direct pulp capping: the pulp tissue is uncovered, the material is placed directly on the pulp, so as to create dentin bridge (reparative dentin). Max. 1 mm² wound surface, no bleeding, rather in case of teeth with more than one root canal

Prerequisite: cross-infection of the pulp has to be avoided during the treatment for the sake of good prognosis -> rubber dam (pulp opening due to trauma or accidental perforation during the preparation: better prognosis as in case of deep cariotic lesion)

- Vital pulpectomy (pulp amputation /coronal pulp!;/; partial/total; not suggested, no satisfactory prognosis. Only in case of unclosed apex, where the completion of RCT with a perfect apical seal can not be accomplished yet!!!)

Prevention: Materials

Which material should cover the nonexcavated dentin surface or the exposed pulpal tissue?

- traditionally, calcium hydroxide (Ca(OH)_2) is used
 - alkaline
 - biocompatible
 - induces dentine remineralisation



Prevention: Materials

Which material should cover the nonexcavated dentin surface or the exposed pulpal tissue?

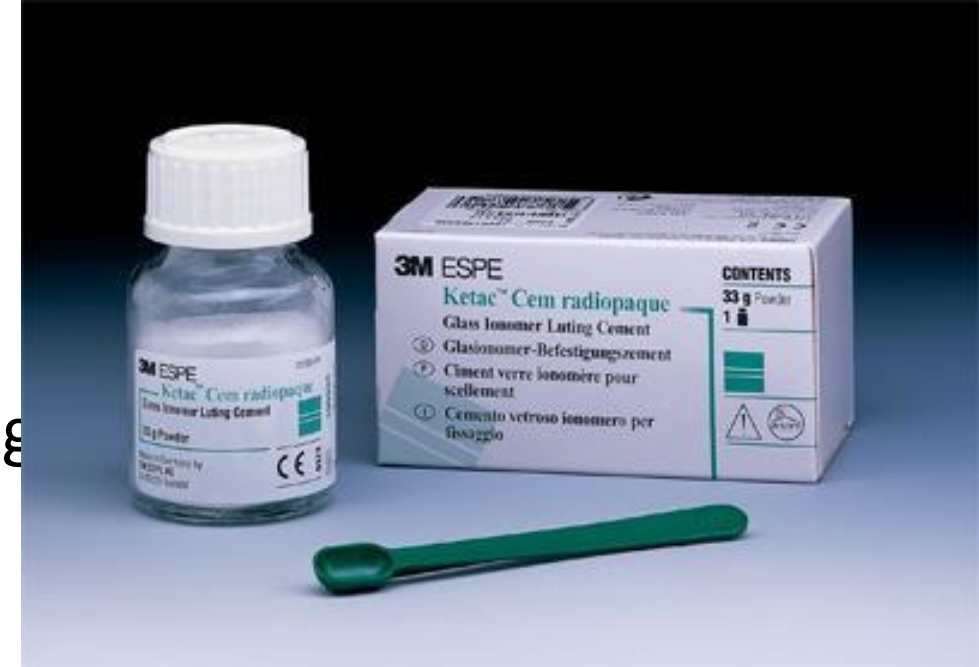- The self-setting type could dissolve in time (as the material releases $\text{Ca}(\text{OH})_2$ continuously), perhaps hampering the seal of the restoration by allowing microbial leakage.
- The mechanical properties of this type are also unsatisfactory (e.g.: even the acetone based adhesives are able to dissolve the material) -> it should be covered with a more resistant cement (like glass ionomer).
- Light-curing types are commonly used nowadays, they can be applied on their own (low solubility and better mechanical properties, although the disinfectant and reparative dentin building properties are reduced).



Prevention: Materials

Glass ionomer cements seem to have advantages

- biocompatibility
- no dissolution reported
- a bio-active material with the potential to remineralise residual carious dentine
- electron probe microanalysis (EPMA) demonstrated that both fluoride and strontium ions from glass ionomer cement can penetrate the underlying demineralised dentine



Prevention: Materials

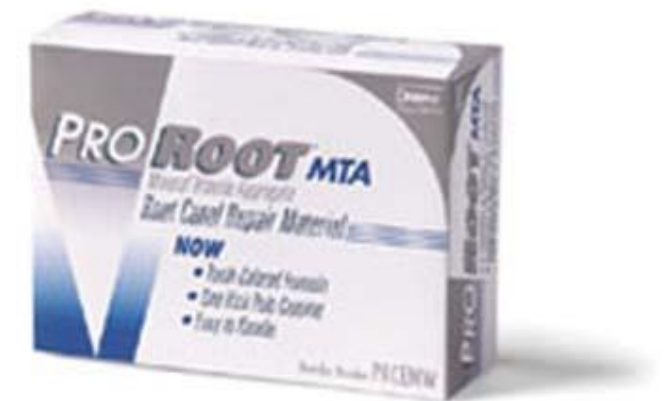Glass ionomer cements seem to have advantages:

- the sealing ability of glass ionomer is good on moist dentine due to its hydrophilic character (if we overdry the cavity, the glass ionomer will not have any adhesion!)
- resin-modified glass ionomer cement is absolutely compatible with dental bonding agents (later restoration)

Prevention: Materials

Other restorative materials on the market:

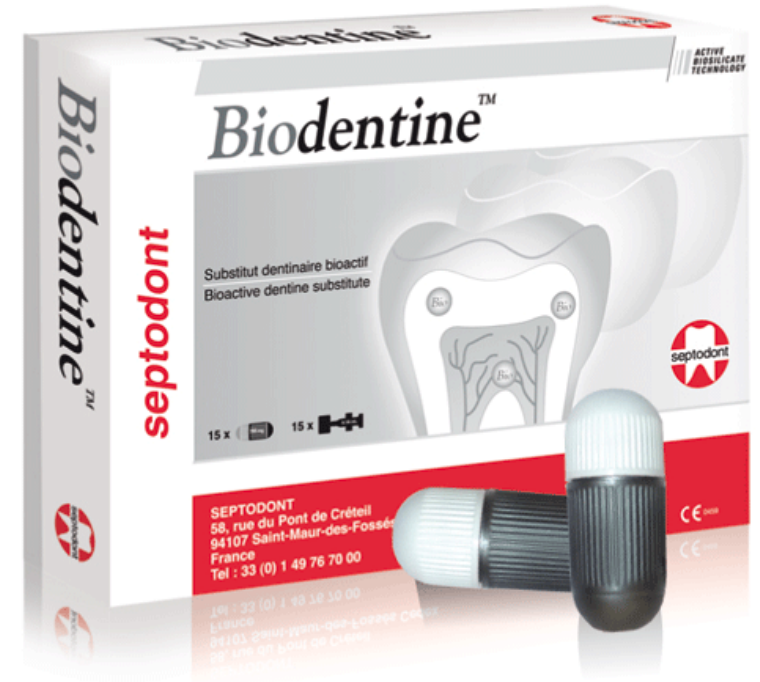- Mineral Trioxide Aggregate (MTA):
 - biocompatible
 - induces the formation of hydroxylapatite
 - exhibits good sealing ability
 - promotes the release of cytokines and growth factors that are encapsulated in the dentin
 - direct pulp capping
 - perforation closing
 - retrograde RCT
 - results in a higher pH
 - antimicrobial effect



Prevention: Materials

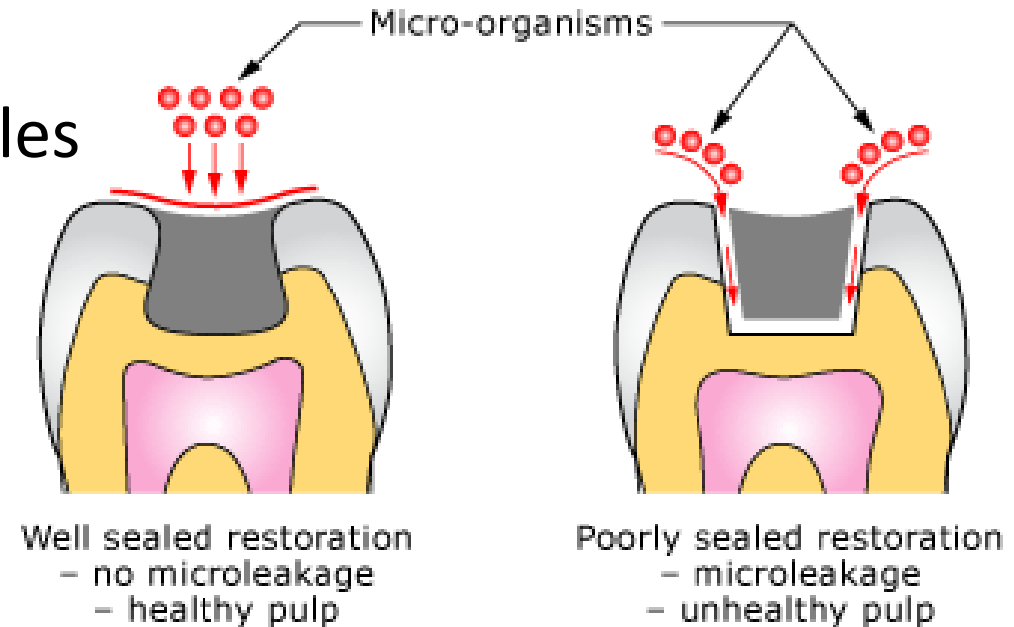
Other restorative materials on the market:

- Biodentine®:
 - temporary enamel restoration
 - permanent dentin restoration
 - deep or large carious lesions
 - deep cervical or radicular lesions
 - pulp capping
 - perforation closing




Prevention: Materials

- According to the literature, it is very possible that the factor of overriding importance is not the material over the pulp, but the cavity seal of the restoration, which ideally should hinder the passage of substrates to the microorganisms (microleakage: incomplete seal!!!)
- Importance in the sealing of dentinal tubules
- Demineralisation -> remineralisation
- Antibacterial effect



The problem of microleakage

„In conclusion, our findings using defined criteria for clinical and histologic classification of pulp conditions revealed a good agreement, especially for cases with no disease or reversible disease. This means that the classification of pulp conditions as normal pulps/reversible pulpitis (savable pulps) and irreversible pulpitis (nonsavable pulps) have high chances of directing the correct therapy in the large majority of cases.”



Correlation between Clinical and Histologic Pulp Diagnoses

Domenico Ricucci, MD, DDS, Simona Loghin, DDS,* and Jose F. Siqueira, Jr, DDS, MSc, PhD†*

JOE — Volume 40, Number 12, December 2014

EGÉSZSÉGES
PULPASZÖVET/REVERZÍBILIS PULPITIS

96,6%

IRREVERZÍBILIS PULPITIS

84,4%

Klinikai diagnózis és hisztológiai vizsgálat kapcsolata

Endodontal diagnostics

- Anamnesis (general, dental)
- Can the patient locate the pain? (radiating pain: irreversible pulpitis)
- When did the complaints start? (e.g.: the patient says to have pain on chewing, but previously he or she had sudden, strong pain)
- Might the complaints be in connection with a dental treatment performed recently? (e.g.: expronation of the pulp, periodontal treatment -> expronation of lateral canals)
- Nature of the pain? (sharp, dull, stitching, fluttering, radiating)




Endodontal diagnostics

- How long does it take? (sec, min, hours)



- Can the pain be provoked? (...or spontaneous? Horizontal position? Cold/warm stimuli?)



- Has the patient used painkillers?



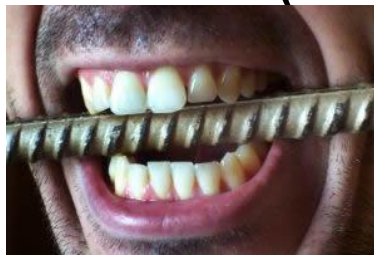Endodontal diagnostics

- Clinical examination (as soon as the patient steps in the office, e.g.: swelling on the face, sleep-deprived)
- Extraoral investigation (in the head- and neck region, e.g.: asymmetry, lymph nodes, fistula)



Intraoral investigation (inspection, palpation, percussion)

- inspection: general dental, periodontal and mucosal status
- palpation: sensitive periapical area for finger-pressure; parallel (control) tooth should also be examined! Fluctuation, crepitation
- percussion: vertical, horizontal (also on neighbouring teeth!)
- provoked pain on bite



Endodontal diagnostics

- Dental Pulp Testing (sensitivity test)

-thermal stimulus:

The concept: healthy pulp reacts for thermal (cold/warm) stimuli with sensitivity or mild pain, which ceases immediately after the stimulus

Inflammation: increased reaction

Reversible pulpitis: increased reaction, which ceases after the stimulus (immediately or in 10 seconds)

Irreversible pulpitis: increased reaction, which lasts further (minutes, hours), even after the stimulus is gone

Endodontal diagnostics

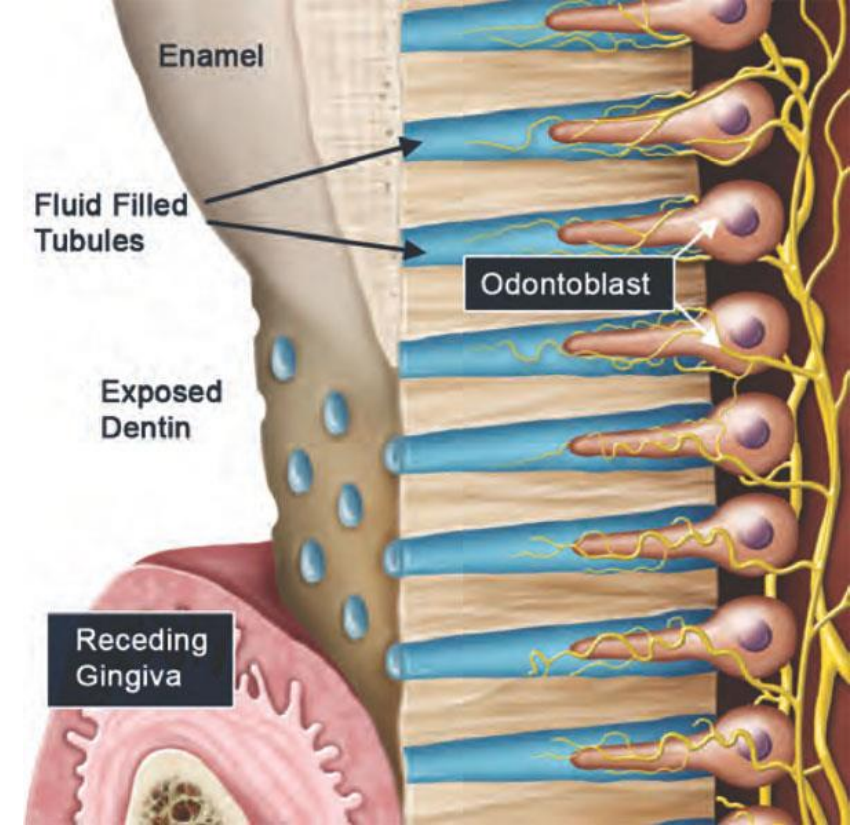
- Dental Pulp Testing (sensitivity test)

-thermal stimulus:

Explanation for the reaction in case of thermal stimulus:

Altered liquid flow in the dentinal tubules.

Pulpal necrosis: no response for thermal stimuli
(N.B.: exception!: closed pulp with necrosis -> expansion of the gases towards the nerves of the periapical area -> pain)



Endodontal diagnostics

- Dental Pulp Testing (sensitivity test)

-thermal stimulus:

Cold: Chloroethyl spray (between -10°C and -25°C), with cotton pellet

Warm: seldom (heated guttapercha, polishing bur with high-speed)



Endodontal diagnostics

- Dental Pulp Testing (sensibility test)

-thermal stimulus:

False negative, false positive (e.g.: tooth anatomy, touching the gingiva, calcification in the pulp, retraction of the pulp, etc.)

Endodontal diagnostics

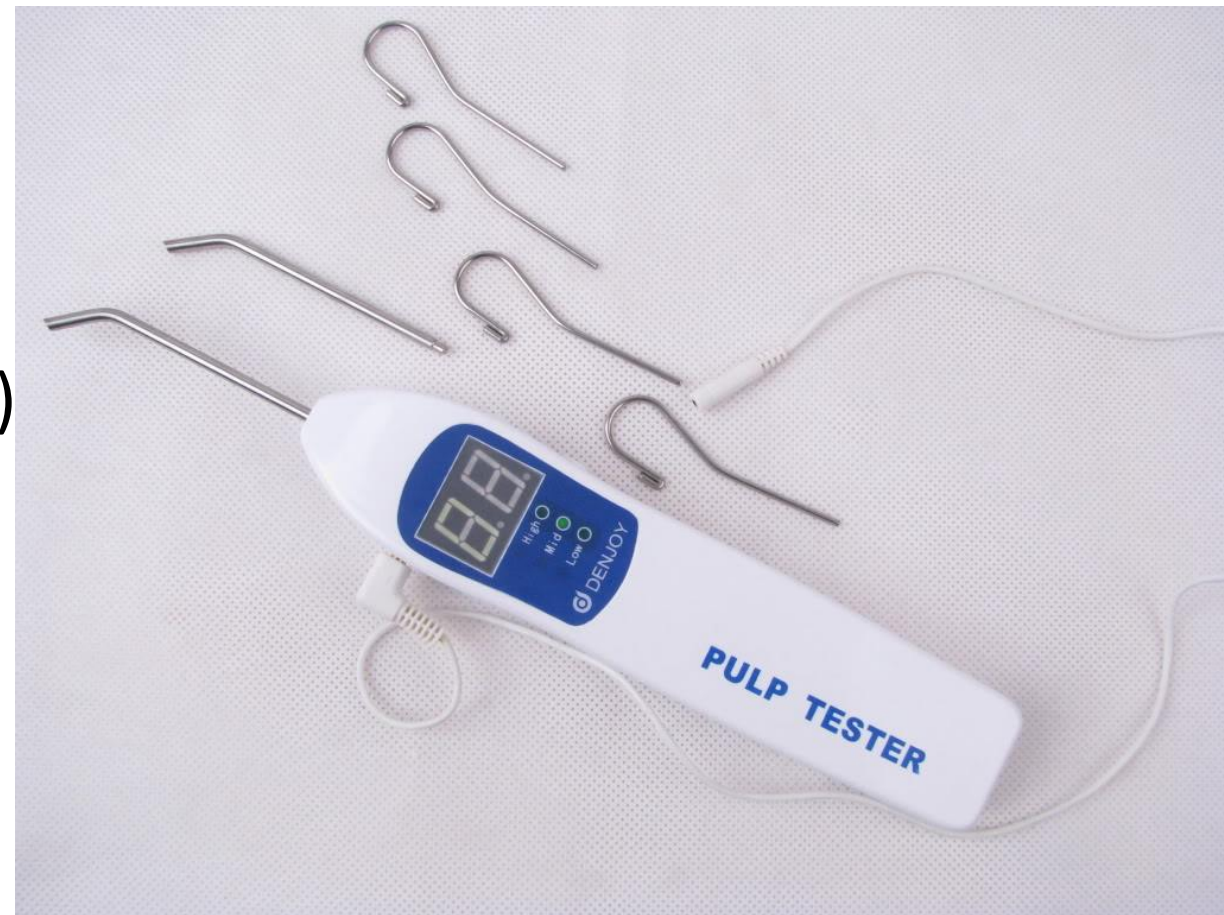- Dental Pulp Testing (sensitivity test)
-electrical stimulus:

High frequency AC or DC. One (wetted) electrode comes to the buccal surface of the tooth, the other one comes to the buccal mucosa of the patient.

Increasing the voltage -> current intensity increases -> pulpal reaction.

Positive answer: there are excitable fibers in the pulp.

False positive answer: metal filling, metal crown -> short-circuit



Endodontal diagnostics

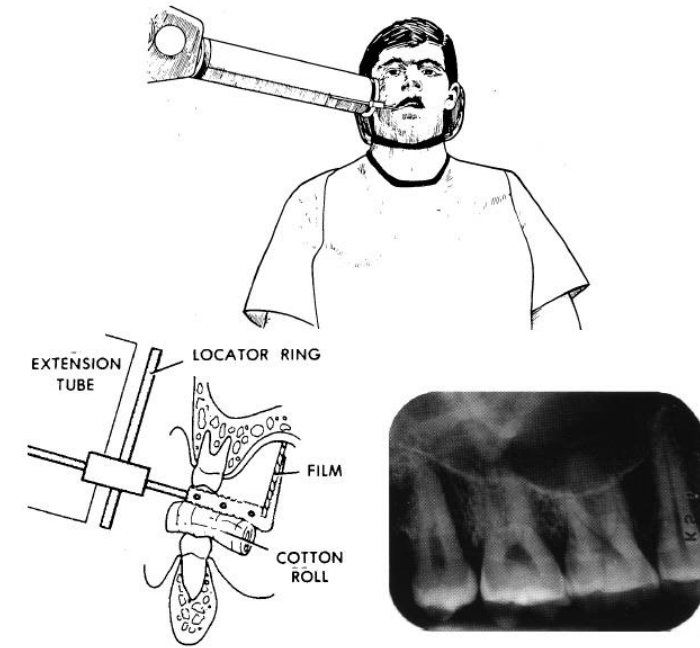
- X-Ray

In some cases **Obligatory** for the diagnosis , together with the clinical examination.

Long cone periapical x-ray.

What can we see on the x-ray?

- extension of the pulp chamber
- whether if the tooth is root canal treated or not. Quality of the RCT
- how many roots and how many canals are there
- curvature of the canal (the evaluation depends on the projection as well!)
- is there any obliteration (denticulus, hypercementosis) in the canal
- deep caries, large filling
- internal/external resorption
- state of the periapical periodontium
- chronic procedures
- estimated length of the tooth

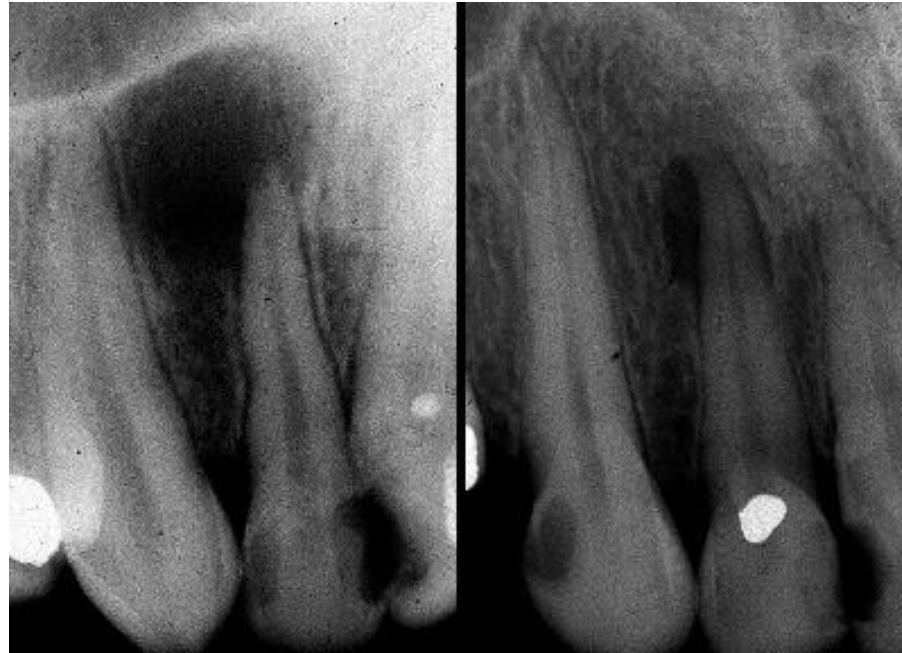

Endodontal diagnostics

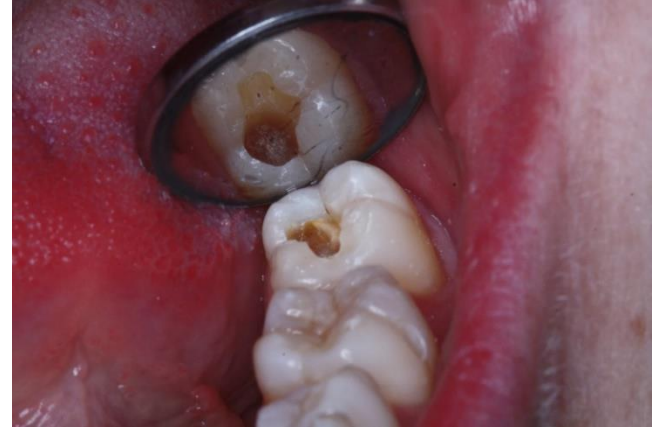- X-Ray

What can we NOT see on the x-ray?

- reversible and irreversible pulpitis
- granuloma or cyst (differential diagnosis: biopsy)



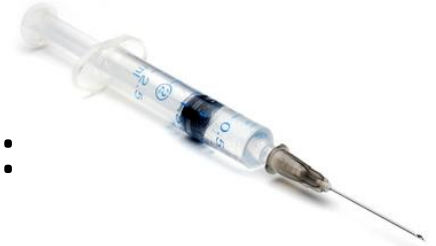Endodontal diagnostics



- Further diagnostic procedures

- test cavity preparation: without anaesthetics. Only in case when the vitality of the tooth is still questionable and exchange of the previous filling and/or caries removal with cavity preparation would be needed anyway.

- selective anaesthesia: anaesthesia of the questionable tooth (e.g.: irradiating pain because of irreversible pulpitis, several cariotic procedures / crowns, bridges in the same region). Disadvantage: solo anaesthesia of the tooth in question is usually unattainable.



- fiber optic examination: light transmittance of the necrotic teeth is lower. Noninvasive method.



- circulation measurement (velocimetry): Laser Doppler, technique of using the Doppler shift (frequency) in a laser beam to measure the velocity of blood.



Thank you for your kind attention!

