

Pneumonia clinical reports

Paula González-Jiménez^{1,2}
Raúl Méndez^{1,2}
Ana Latorre²

Pulmonary Nocardiosis. A case report

¹Pneumology Department, La Fe University and Polytechnic Hospital, Valencia Spain. Spanish Society of Pneumology and Thoracic Surgery (SEPAR)

²Respiratory Infections Research Group, Health Research Institute La Fe, Valencia Spain,

Revista Española de Quimioterapia
doi:10.37201/req/s01.24.2022

Sir,

Chronic obstructive pulmonary disease (COPD) is a chronic disease which predisposes to the appearance of opportunistic infections. Long-term corticosteroids therapy might favor this immunosuppression status. Next, we report a case of a COPD patient with a non-responding pneumonia, in which immunosuppression was potentiated by previous corticosteroid treatments and mucociliary clearance alteration.

A 75-year-old caucasian male, ex-smoker, with a medical history significant for type I obesity and severe COPD disease treated with triple bronchodilator therapy, presented at Emergency Department (ED) with dyspnea, cough and expectoration from 1 week. A blood sample analysis revealed high acute-phase reactants (leucocytosis [21,900 cells/ μ L], neutrophilia [21,150 cells/ μ L], and high C-reactive protein (CRP) [173.6 mg/L]), with normal kidney function and haemostasis. Chest-X-ray showed no new infiltrates or consolidation images. After ED medical treatment, the patient improved and was discharged with oral treatment (cefditoren and prednisone).

At home, the patient was clinically worsening and two months later he presented again at ED with pleuritic chest pain, dyspnea and tachypnoea (respiratory rate: 30 breaths per minute). New complementary explorations were completed: Blood analysis revealed high acute-phase reactants (leucocytosis [22,430 cells/ μ L], neutrophilia [18,810 cells/ μ L], high CRP [91.6 mg/L]) and a right lower lobe consolidation with ipsilateral pleural effusion was shown in chest-X-ray (Figure 1). Arterial blood gas showed moderate hypoxemia despite supplemental oxygen therapy (FiO₂ 0.35). Hence, he was hospitalized with the diagnosis of community-acquired pneumonia.

Initially, symptoms improved after endovenous levofloxacin, methylprednisolone treatment and bronchodilators. The

microbiological tests (atypical bacteria serology, urine antigens for legionella and pneumococcus, and respiratory viruses) were all negative and sputum was cultured. Seventy-two hours after admission, symptoms, blood sample analysis and oxygenation parameters worsened. Chest ultrasound showed little quantity of pleural effusion not subsidiary to thoracentesis. Sputum culture was positive for *Aspergillus fumigatus*. As considered a treatment failure, antimicrobial coverage was broadened (piperacillin/tazobactam and oral voriconazole) and a CT-scan and a bronchoscopy were requested for obtaining invasive samples.

The CT-scan showed bilateral pulmonary nodules, with many lobes involved, heterogeneous in size (4-36mm) with hypodense regions of probable necrosis. The right basal consolidation has progressed and the pleural effusion persisted (Figure 2). A bronchoscopy was performed and it revealed abundant mucopurulent secretions. A bronchoalveolar lavage (BAL) was obtained from lingula.

The BAL microbiological tests showed negative results for respiratory viruses, fungi culture, galactomannan antigen and mycobacterial tests (Ziehl-Neelsen stain and Lowenstein culture). A *Nocardia cyriacigeorgica* grew in culture and antibiotic susceptibility was performed.

Because of the moderate-grade pulmonary nocardiosis, intravenous cotrimoxazole was started (sensitivity was confirmed). The patient showed clinical improvement, then intravenous antibiotic therapy was switched to oral cotrimoxazole. After 6 months of treatment, chest X-ray showed disappearance of consolidation, the patient was asymptomatic with no adverse reactions to treatment and treatment was discontinued.

Pulmonary nocardiosis (PN) is an opportunistic infection that belongs to *Actinomycetaceae* family and mainly affects immunocompromised patients. However, in one third of cases it can occur in immunocompetent patients. *Nocardia spp.* are Gram-positive, aerobic, filamentous, and partially acid-fast bacilli. PN has a high mortality rate up to 38% according to some case series [1].

Correspondence:
Paula González-Jiménez
Pneumology Department, La Fe University and Polytechnic Hospital, Valencia Spain,
E-mail: paulagonzalezjimenez@gmail.com

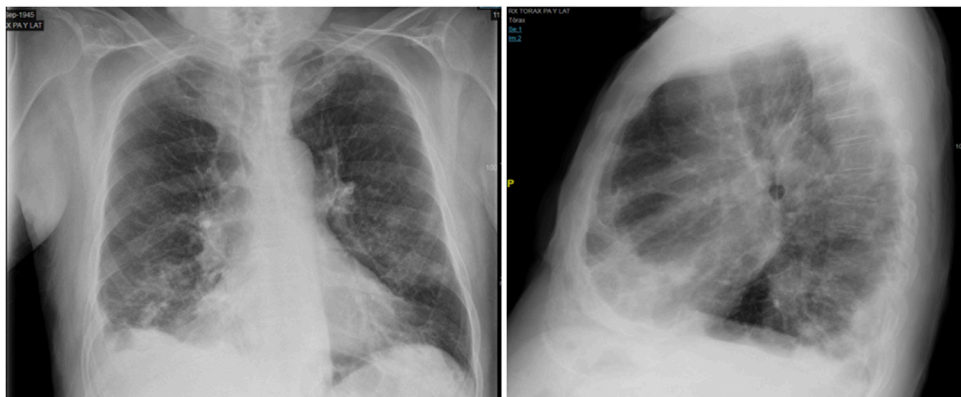


Figure 1 | Chest-X-ray. Right lower lobe consolidation with ipsilateral pleural effusion.

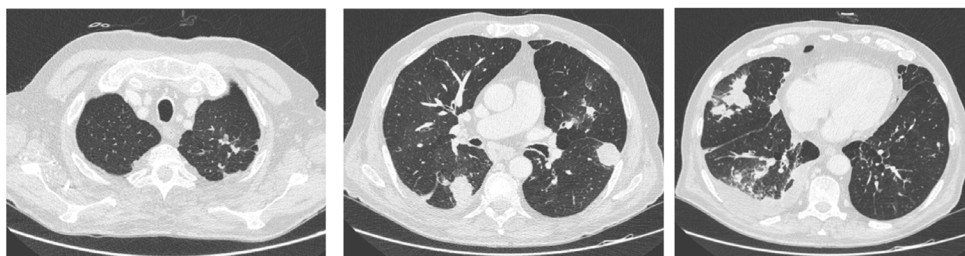


Figure 2 | CT-scan. Bilateral pulmonary nodules with hypodense regions. Progression of the right lower lobe consolidation. Pleural effusion.

Nocardiosis incidence is increasing due to the greater longevity of population, which has a senescent immune system [2] and higher number of chronic advanced comorbidities. Local alteration of the pulmonary defences predisposes to PN, as it occurs in COPD or lung sequestration [3,4].

Direct inoculation or inhalation of spores are the main transmission mechanisms of *Nocardia*. They may be found in sand, dust or in stagnant water [3].

Lung involvement is the main affectation of *Nocardia*. However, disseminated involvement may occur in some cases (≥ 2 sites involvement in 32% of patients, according to case series). Disseminated disease involves central nervous system, bacteraemia and cutaneous or soft tissue infections [5].

Differential diagnosis of PN should be made with other infectious and non-infectious diseases, such as pneumocystis pneumonia, tuberculosis, fungal infections or ANCA-mediated vasculitis [2].

Gold standard for the identification of PN is the culture of *Nocardia*. *Nocardia* is a slow-growing bacterium that requires specific stains (Kiyoun or fluorescent auramine-rhodamine) and special cultures (modified Thayer Martin agar or BCYE-alpha agar). In other non-selective media, such as media for Mycobac-

teria, it can also grow (Löwenstein-Jensen) [5]. Molecular identification methods, such as Polymerase Chain Reaction (PCR) base sequencing, provide rapid results. However, these techniques are not available in all microbiology laboratories [2].

In immunosuppressed patients, a positive sputum culture leads to diagnosis of the disease and not only colonization [3]. In 44% of lung infections, invasive diagnostic procedures for obtaining lower respiratory samples may be necessary [6].

Decontamination methods (sodium hydroxide, benzalkonium chloride and N-acetyl-L-cysteine) are toxic for *Nocardia* [2] therefore, it is essential to inform to the microbiology laboratory if there is clinical suspicion.

Standard treatment for local PN is cotrimoxazole. Initially, intravenous administration is recommended. If clinical improvement is achieved, an oral administration could be considered. The treatment total duration is 6 months, although it must be extended to 12 months in immunosuppressed patients or in disseminated disease. In severe lung diseases or immunosuppression, combined treatment (cotrimoxazole + amikacin or imipenem + amikacin) is recommended. In associated central nervous system involvement, triple therapy with cotrimoxazole + imipenem + amikacin is recommended [7].

In conclusion, PN should be considered in immunosuppressed patients and, also in patients with other associated risk factors. Clinical suspicion is very important because specific microbiological tests are required. Nocardiosis requires prolonged and sometimes combined treatment.

REFERENCES

1. Murray PR, Heeren RL, Niles AC. Effect of decontamination procedures on recovery of *Nocardia* spp. *J Clin Microbiol*. 1987 Oct;25(10):2010-1. doi: 10.1128/jcm.25.10.2010-2011.1987. PMID: 3667923.
2. Fatahi-Bafghi M. Nocardiosis from 1888 to 2017. *Microb Pathog*. 2018 Jan;114:369-384. doi: 10.1016/j.micpath.2017.11.012. Epub 2017 Nov 13. PMID: 29146497.
3. Martínez Tomás R, Menéndez Villanueva R, Reyes Calzada S, Santos Durantez M, Vallés Tarazona JM, Modesto Alapont M, Gobernado Serrano M. Pulmonary nocardiosis: risk factors and outcomes. *Respirology*. 2007 May;12(3):394-400. doi: 10.1111/j.1440-1843.2007.01078.x. PMID: 17539844.
4. Rivière F, Billhot M, Soler C, Vaylet F, Margery J. Pulmonary nocardiosis in immunocompetent patients: can COPD be the only risk factor? *Eur Respir Rev*. 2011 Sep 1;20(121):210-2. doi: 10.1183/09059180.00002211. PMID: 21881150.
5. Gutiérrez C, et al. Infección por *Nocardia cyriacigeorgica* en paciente con infección por VIH en etapa SIDA. *Rev Chilena Infectol* 2020; 37 (3): 322-326.
6. Georghiou PR, Blacklock ZM. Infection with *Nocardia* species in Queensland. A review of 102 clinical isolates. *Med J Aust*. 1992 May 18;156(10):692-7. doi: 10.5694/j.1326-5377.1992.tb121509.x. PMID: 1620016.
7. Mensa, J. Guía de Terapéutica Antimicrobiana 2021. 31ª Edición Marzo 2021. ISBN 9788488825339.