



Extrapulmonary TB

Connie A. Haley, MD MPH

Southeast National TB Center, University of Florida,
Division of Infectious Diseases and Global Medicine

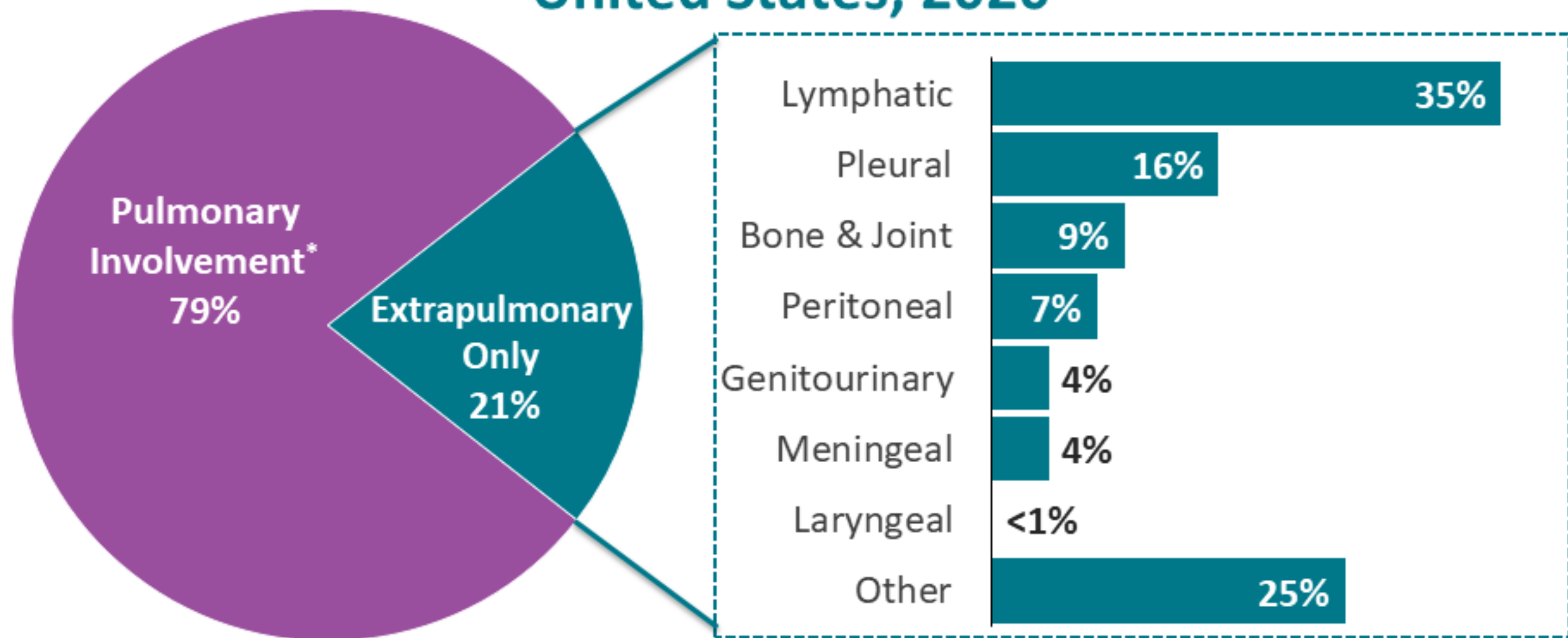
Connie.haley@medicine.ufl.edu

(615) 598-6411

Extra-Pulmonary TB

- 15% -45% of 10 million persons who develop TB each year (1.5 to 4M/y)
 - Pleura (most common)
 - Lymph nodes
 - Bones and joints
 - CNS (meningitis, tuberculoma, spinal cord)
 - Genitourinary tract
 - Larynx
 - Pericardial
 - Abdominal sites; liver and biliary tree, omentum, pancreas, bowel, etc.
 - Disseminated (miliary)
 - Adrenal
- EPTB largely undiagnosed in developing countries

Percentage of TB Cases by Site of Disease, United States, 2020



*Any pulmonary involvement which includes cases that are pulmonary only and both pulmonary and extrapulmonary. Patients may have more than one disease site but are counted in mutually exclusive categories for surveillance purposes.

Extra-Pulmonary TB

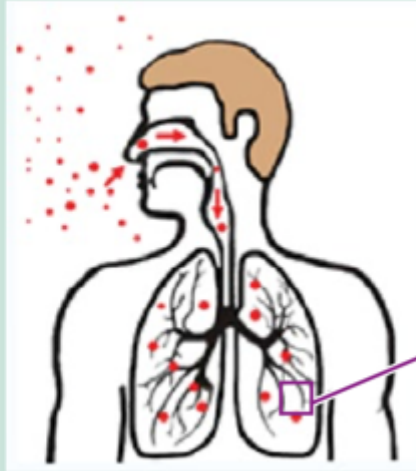- Especially common in children and people living with HIV
 - More common in persons born outside the US
- In HIV(+), TB occurs in
 - 33% with only extra-pulmonary
 - 33% with only pulmonary
 - 33% both pulmonary and extra-pulmonary
(many with negative CXRs)
- May mimic many other diseases or infections

Factors Associated with Increased Risk of EPTB

- Immunosuppression
- Younger age
- Older age
- Non-US birth
- Non-white race
- Female gender (hormonal factors, smoking or exposure risk?)
- Exposure to unpasteurized dairy products (M. Bovis TB)
- Genetic factors

Pathogenesis of TB Disease and LTBI

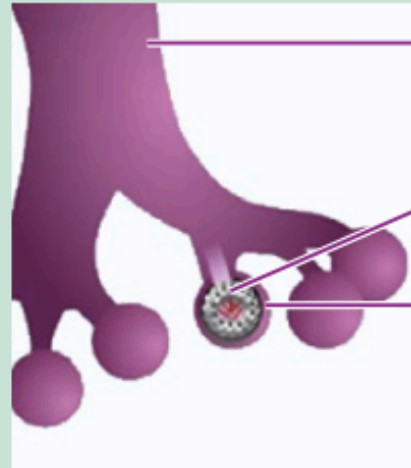1



Area of detail for boxes 2, 4, and 5

Droplet nuclei containing tubercle bacilli are inhaled, enter the lungs, and travel to the alveoli.

2



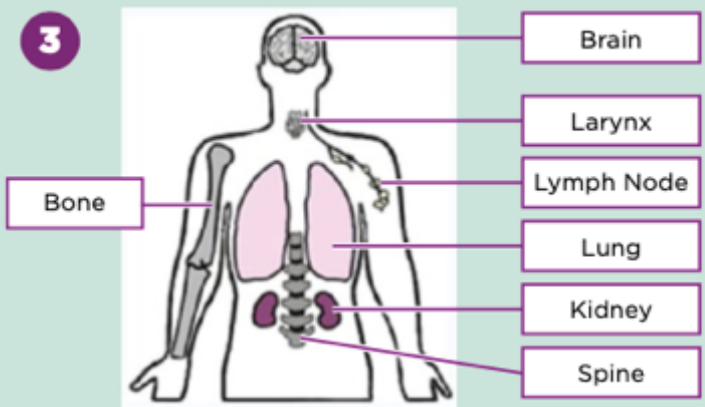
Bronchiole

Tubercle bacilli

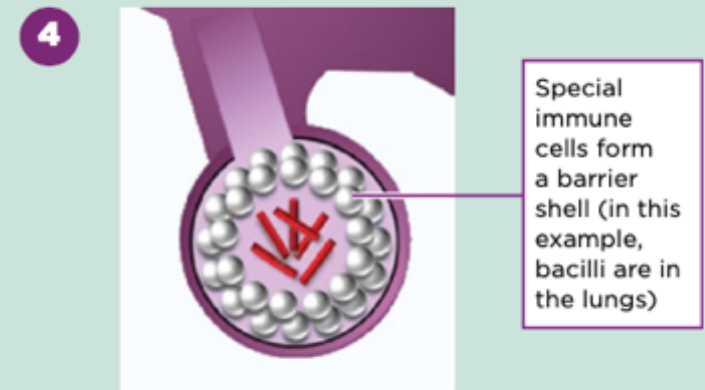
Alveoli

Tubercle bacilli multiply in the alveoli.

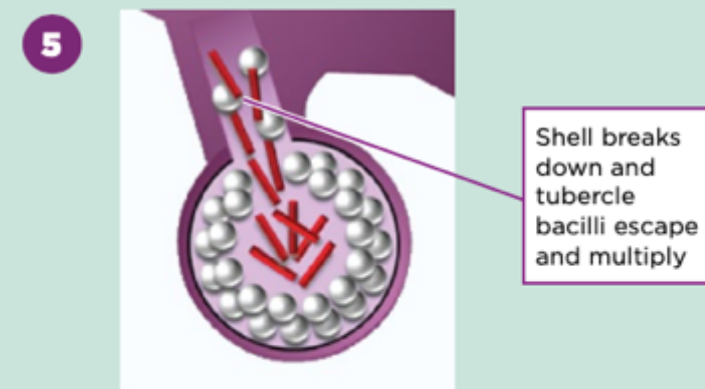
Pathogenesis of TB Disease and LTBI



A small number of tubercle bacilli enter the bloodstream and spread throughout the body. The tubercle bacilli may reach any part of the body, including areas where TB disease is most likely to develop (such as the brain, larynx, lymph nodes, lungs, spine, bone, or kidneys).



Within 2 to 8 weeks, special immune cells called macrophages ingest and surround the tubercle bacilli. The cells form a barrier shell called a granuloma that keeps the bacilli contained and under control. (This is known as **latent TB infection, or LTBI.**)



If the immune system **cannot** keep the tubercle bacilli under control, the bacilli begin to multiply rapidly (**TB disease**). This process can occur in different areas in the body, such as the lungs, kidneys, brain, or bone (see diagram in box 3).

Table 1 | Routes, sources and modes of *Mycobacterium tuberculosis* complex transmission

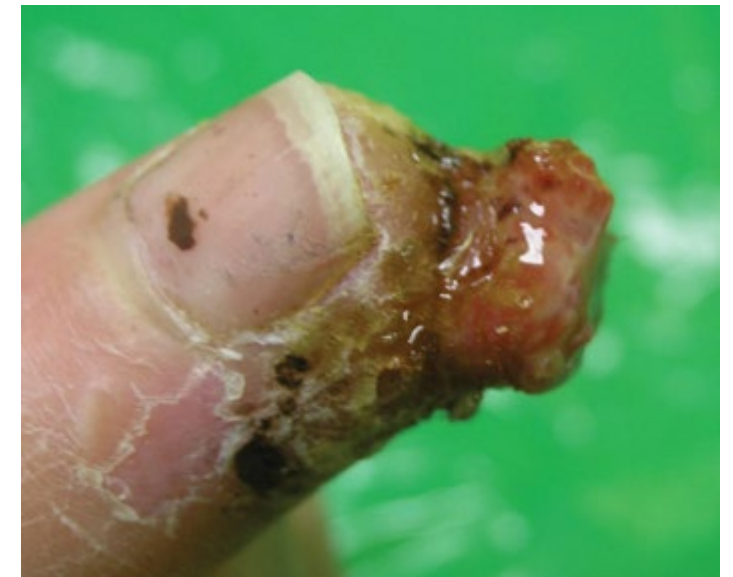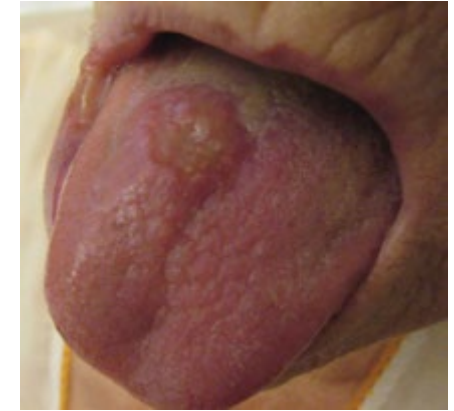Route of transmission	Mode of transmission and source of infection	Refs
<i>Common routes</i>		
Inhalation (airborne) (>95% cases)	Inhalation of <i>Mtb</i> -infected droplets from cough of patients with active pulmonary TB	5,6,53
Oral (ingestion)	Consumption of dairy products infected with <i>Mycobacterium bovis</i> from cattle with active bovine TB	27,28,30
<i>Uncommon routes</i>		
Congenital or neonatal	Possible mechanisms: transplacental transmission; via bloodstream or lymphatics from mother with active TB disease; directly from placenta with miliary TB; or aspiration or ingestion of <i>Mtb</i> -infected amniotic fluid during birth	54–59
Parenteral (injection)	Intravesical instillation of live BCG <i>M. bovis</i> vaccine strain as adjuvant treatment of carcinoma in situ of the bladder leads to local or invasive disease (bladder, epididymis, penis, prostate and renal TB have been described); BCG vaccination in HIV-infected (immunosuppressed) individuals causes disseminated BCG disease	65,67–72
Sexual	Direct contact with active genital TB lesions or exudates containing <i>Mtb</i> ; sexual transmission of <i>Mtb</i> (<i>Mtb</i> has been isolated from semen of men with TB of the prostate)	61,62,81,305

BCG, bacillus Calmette–Guérin; *Mtb*, *Mycobacterium tuberculosis*; TB, tuberculosis.

TB caused by Mycobacteria Bovis

- *M. bovis* is clinically, radiographically, and pathologically indistinguishable from *M. tuberculosis* in humans
- Higher proportion of extrapulmonary disease
- TST and IGRAs don't distinguish *M. bovis* from *M. tuberculosis*
- PZA mono-resistant - Think *M. bovis* or *M. bovis BCG* (Vaccine)
- Instillation of BCG for bladder cancer can rarely lead to TB
- Prevent by pasteurizing (Heating) dairy products before consumption

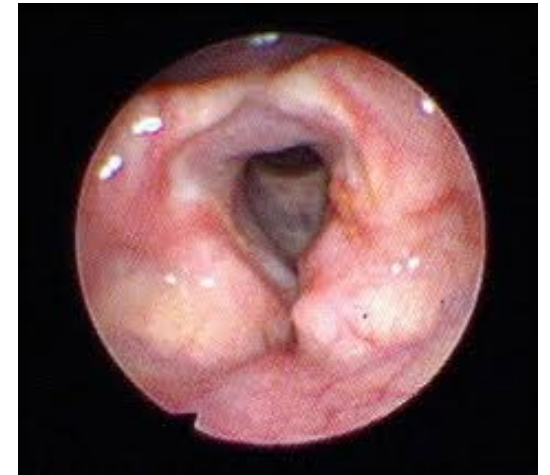Extrapulmonary TB due to *M. bovis*



Cutaneous TB caused by *M. bovis* in Veterinarian exposed to infected alpaca, *Veterinary Record* 2010

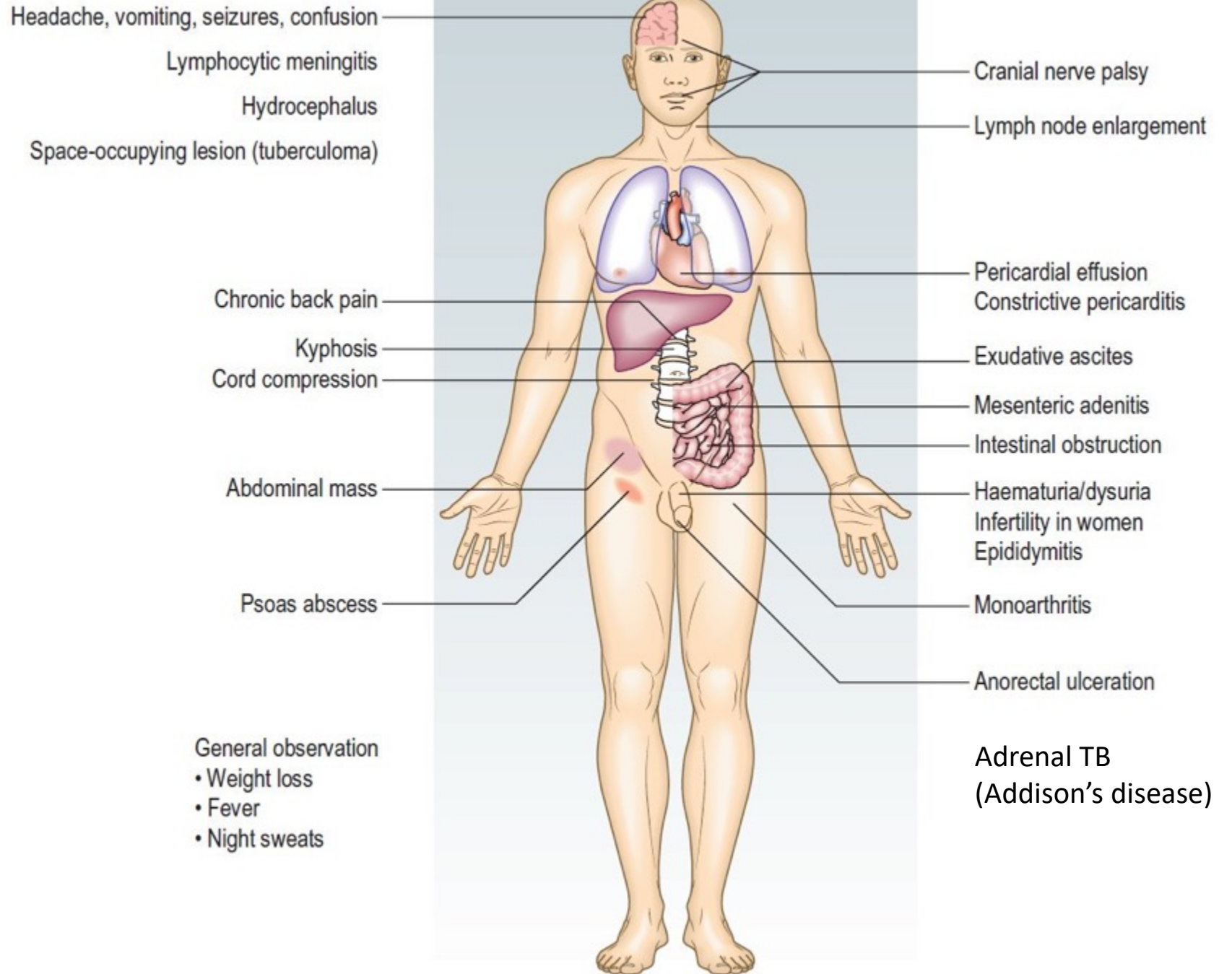
Persons with EPTB disease usually are not infectious unless...

- There is also pulmonary TB disease
- TB involves the oral cavity or the larynx; or
- There is an open abscess or lesion with a high concentration of TB organisms and extensive drainage fluid that is aerosolized.
 - Transmission from extrapulmonary sites has been reported to occur during aerosol-producing procedures such as autopsies and tissue irrigation.



Laryngeal TB

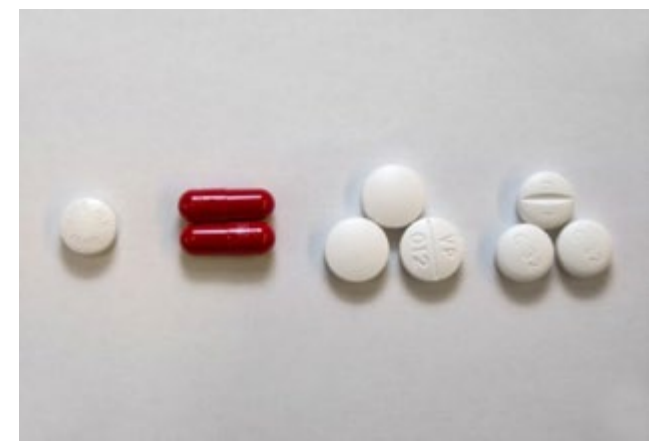Symptoms of Extrapulmonary TB depend on affected site



Diagnosis of Extra-pulmonary TB

- HIV testing
- History and Physical exam
- Collect specimens from involved sites
 - AFB smear, culture
 - NAA testing on CSF, urine, tissue, pleural fluid, joint fluid, bone marrow etc.;
 - Can have false negative if low burden of organisms
 - Many labs won't test non-respiratory specimens, FL PHL will test for free
 - Histopathologic examination and staining
 - Molecular and growth-based drug-susceptibility testing
 - CDC Infectious diseases pathology lab can extract DNA in fixed tissue
- **Always evaluate for pulmonary TB:**
 - Symptoms, CXR and sputum evaluation, *especially if immunosuppressed*

Treatment of Extra-pulmonary TB



- Same 4 drug regimen (RIPE+b6) used for pulmonary TB
- Culture-negative TB/ (culture not done)
 - Negative cultures in person with clinical evidence does not exclude TB
 - Aggressively pursue diagnosis
 - No data on duration of therapy
- Treat **HIV+** patients with EPTB the same as HIV-, low threshold to extend therapy if slow response, significant disease burden

“Roles” of different TB medications

- Rifampin (RIF) is best “sterilizing” drug
 - Prevents post-treatment relapse by eliminating “persisters”.
 - Shortens duration of TB therapy (18 to 9 months if added to INH)
- Rifabutin (RFB)
 - Similar to RIF but fewer drug interactions
 - Less effect on the liver, reduced hepatotoxicity
- Isoniazid (INH)
 - Kills actively replicating TB organisms by preventing cell-wall synthesis
 - Less effective against semi-dormant persisters not building cell wall (e.g. LTBI)
 - Good CNS penetration (thus side effects like headache, seizures, neuropathy)

“Roles” of different TB medications

- Pyrazinamide (PZA)
 - Shortens treatment to 6 months if given with INH and RIF for first 2 months)
 - Highest benefit early in treatment
- Ethambutol (EMB)
 - “Insurance policy” to protect RIF while awaiting susceptibility results
- Fluoroquinolones (FQ)
 - Good bone and CNS penetration
 - Levofloxacin renal metabolism so useful in “Liver-sparing” regimen
 - Moxifloxacin has hepatic and renal metabolism, may be better in renal disease
- Linezolid (LZD)
 - Good CNS penetration, neurologic and hematologic effects

Special Notes on Treatment of Extra-pulmonary TB

- **Disseminated TB or TB meningitis: treat for 9–12 months**
- For **bone and joint TB, 9 months** favored
- In **CNS TB**
 - High-dose steroids slowly tapered over 2-3 months
 - Consider adding a quinolone or linezolid for CNS penetration
 - Therapeutic drug monitoring (high dose RIF?)
 - Treat 12 months
- Consider adrenal involvement—replace steroids
- Account for increased metabolism of steroids on rifampin>rifabutin

ATS, CDC, IDSA. Treatment of tuberculosis. *Morbidity and Mortality Weekly Report: Recommendations and Re-ports*, 2003, 52(RR-11):1–77.

WHO. Treatment of Tuberculosis Guidelines, 4th Edition. World Health Organization 2010.

Surgery Discouraged

- Although sometimes required for diagnosis, surgery plays little role in the treatment of extra-pulmonary TB.
- It is reserved for management of late complications of disease such as:
 - Hydrocephalus
 - Obstructive uropathy
 - Constrictive pericarditis
 - Neurological involvement from Pott's disease (spinal TB).
- For large, fluctuant lymph nodes that appear to be about to drain spontaneously, aspiration or incision and drainage appear beneficial

ATS, CDC, IDSA. Treatment of tuberculosis. *Morbidity and Mortality Weekly Report: Recommendations and Re-ports*, 2003, 52(RR-11):1–77.

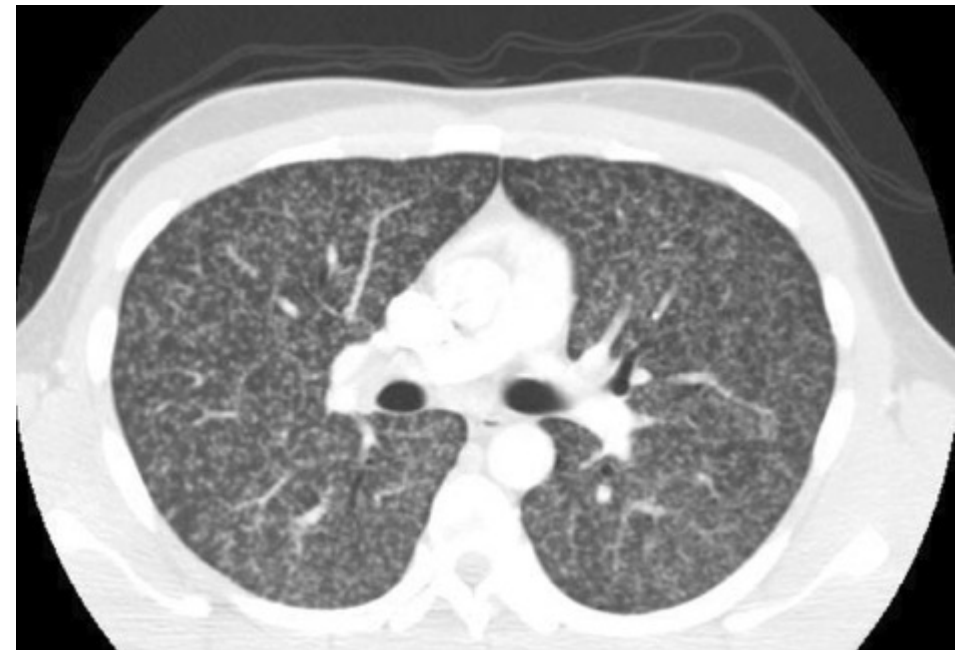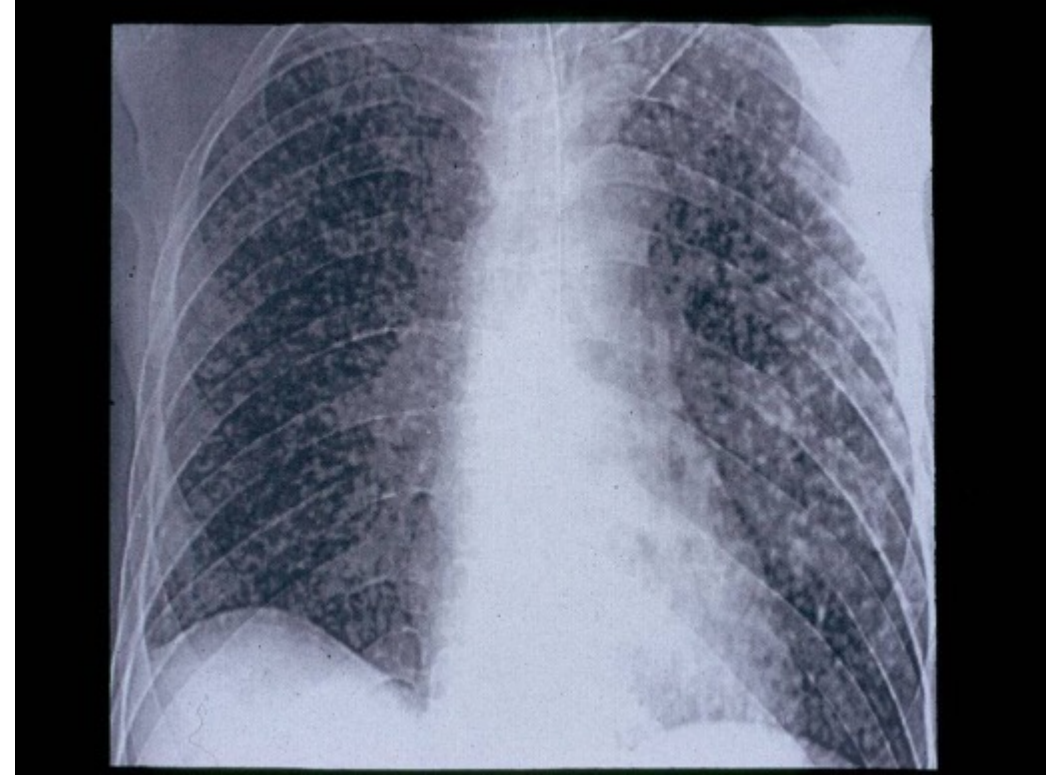
WHO. Treatment of Tuberculosis Guidelines, 4th Edition. World Health Organization 2010.

TB Pleural Effusions

- Tuberculous effusions can follow early post-primary, chronic pulmonary, or miliary tuberculosis.
- Pleural TB often acute illness with cough, pleuritic chest pain, fever, SOB
- May mask underlying pulmonary TB on CXR because the effusion fluid compresses the lung.
 - Consider patient infectious until pulmonary TB disease is excluded
- Pleural fluid paucibacillary, smears rarely +, get PCR and culture; pleural biopsy higher yield
 - Exudative, lymph predominant (may have early neutrophil predominance)
 - Adenosine deaminase (ADA >40), interferon gamma, and lysozyme in fluid
- Treatment with RIPE (unless resistance) x6 months

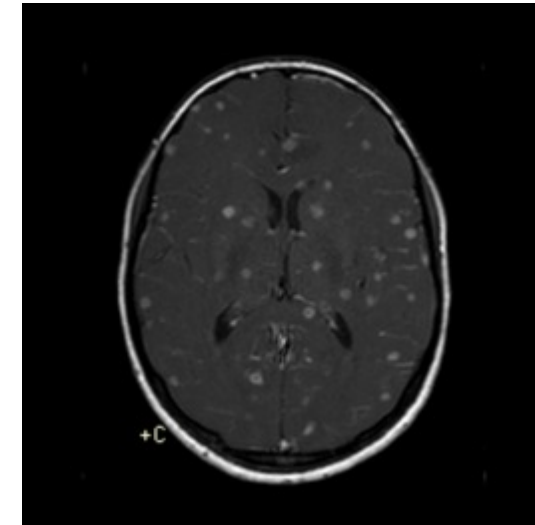
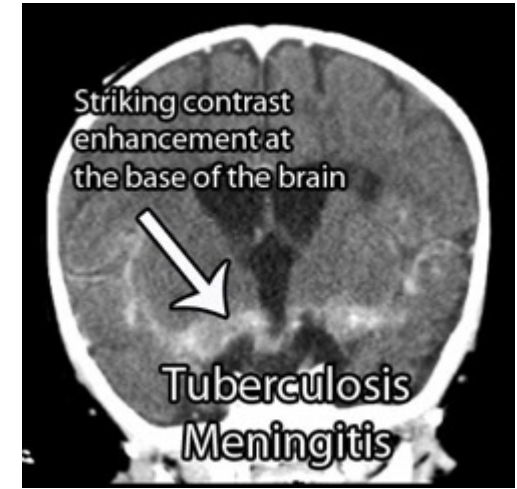
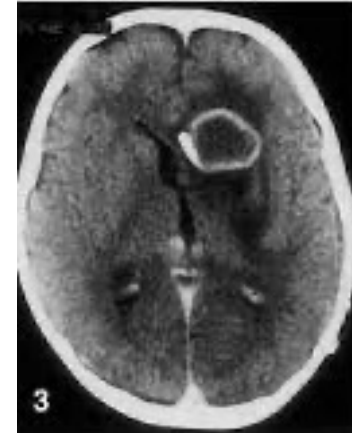Miliary TB

- TB -> bloodstream -> disseminates -> grows and causes disease in multiple sites
- “Miliary” = scattered millet seeds in lungs
- Reported as pulmonary form of TB
- Rare but serious, can be fatal if untreated
- Most common in infants, children <5 y, and the immunocompromised
- BCG vaccination of infants prevents disseminated TB, TB meningitis in children
- Characterized by large amount of TB bacilli, but may easily be missed
- Meningeal involvement in up to 25%
- Dx with sputum, BAL samples, Bx histopath



CNS TB

- Meningitis surrounding brain or spinal cord; often seen at base of brain on imaging (MRI).
- Symptoms - headache, decreased level of consciousness, neck stiffness.
- Can be acute, subacute
- Treat 12 months
- Initial steroids to avoid increased CSF pressure/herniation with immune response inflammatory syndrome (IRIS); SLOW taper
- Re-evaluate/MRI urgently if symptoms worsen after treatment begins



Extrapulmonary Tuberculosis

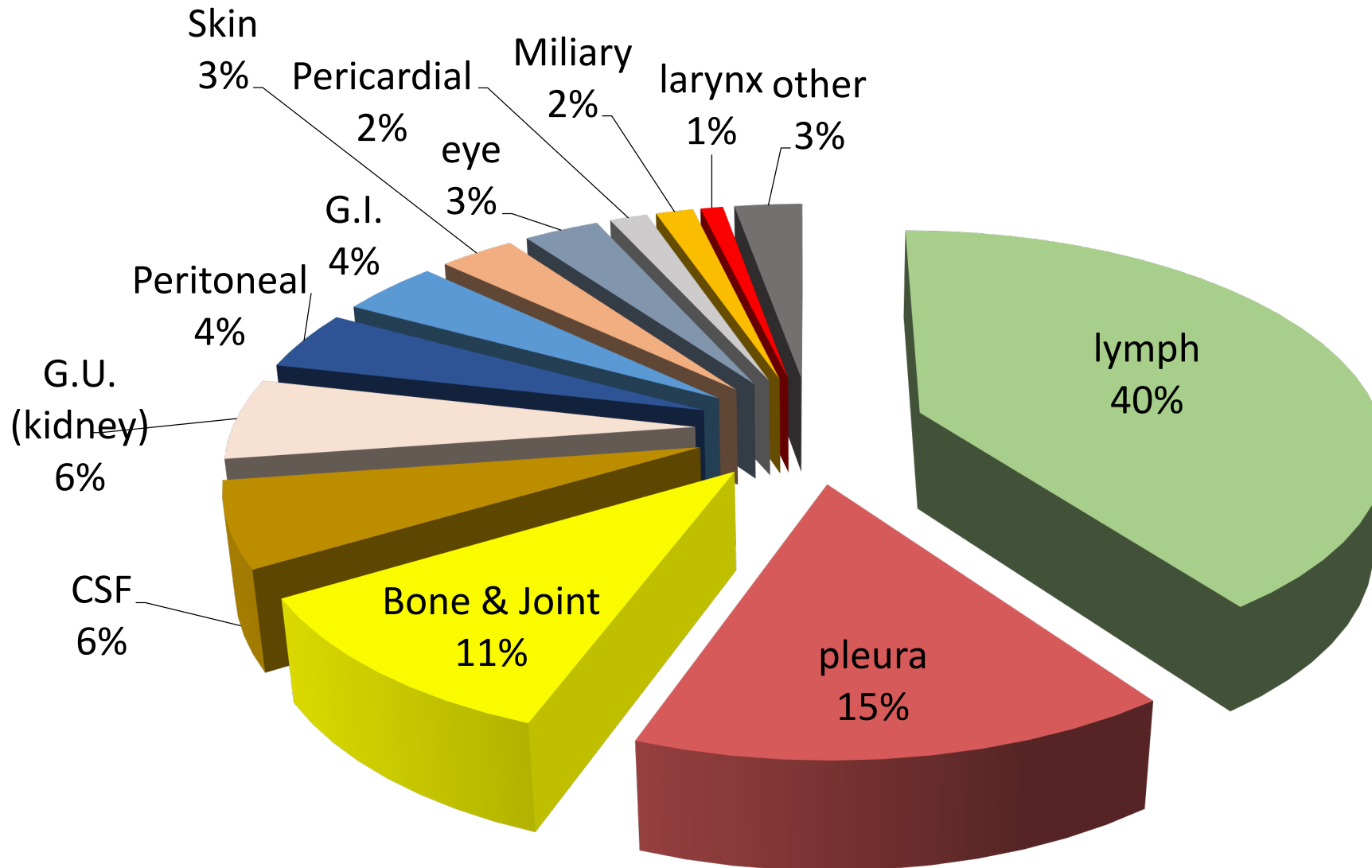
Wisconsin 2005-2020

Thank you Philip Wegner!

Reported Extra-pulmonary TB: Wisconsin 2005-2020

- 322 cases (34% of TB cases during this period)
- 69% Foreign-Born 31 % U.S. Born
- 81% culture-positive 19% clinical
- 3.4% had drug-resistance
- 6.5% were HIV+

Extrapulmonary Sites TB Cases: Wisconsin 2005-2020



Reported Extra-pulmonary TB: Wisconsin 2005-2020

79% are in five sites:

1. Lymph node
2. Pleura
3. Bones or Joints
4. G.U.
5. CSF/CNS/Brain

Bone & Joint (35)

43% (15) in spine or vertebra

Other locations include hip (3), finger (3), knee (3), wrist (2), ankle (2), sternum (2), pelvis (1), Mastoid bone (1), bone marrow (1), bone unknown (2)

Reported Extra-pulmonary TB: Wisconsin 2005-2020

Location or Site

0.9% Larynx (3)

0.6% Testes (2)

0.3% Liver (1)

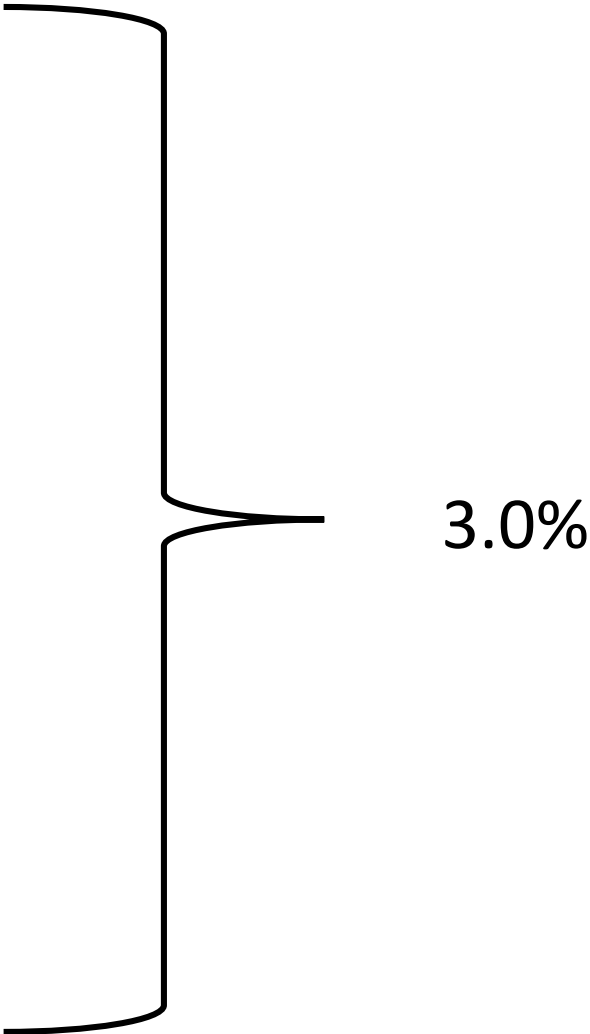
0.3% Blood (1)

0.3% Pancreas (1)

0.3% Tonsil (1)

0.3% heart (1)

0.3% Spleen (1)



Polling Question #1

Should DOT be given for extrapulmonary TB?

1. Yes
2. No

Extrapulmonary TB Case Study #1

Kim Kringel, RN, BSN
PHN, Franklin County Health Department
Milwaukee, WI

Background Information

- 43 y/o male who immigrated from Philippines 16 years ago.
- Client's mother diagnosed with TB 13 years ago (lived with family).
- Wife diagnosed with extra-pulmonary TB in the neck 13 years ago (few months after Mother-in-law). Wife was pregnant at that time.
- Client tested negative for TB at that time and he has received annual TB skin tests through work; all negative
- Client returned to Philippines in 2019 twice - first a business trip and then a family trip.
- Lives a healthy, active lifestyle

Findings

- He noticed a new swelling in his neck and went to PCP
- Nodule was painful and red, about the size of a quarter
- No fever, cough, night sweats, or weight loss
- PCP ordered a CT scan, enlarged node in the neck, and “Multiple sub-centimeter pulmonary nodules bilaterally, Moderately suspicious thyroid nodule, Ground glass opacities in RLL. No other sites of mass or lymphadenopathy. Prominent peri-aortic nodal cluster just superior to iliac bifurcation, attention on follow up is recommended.”

Images of TB Lymphadenitis in Adults

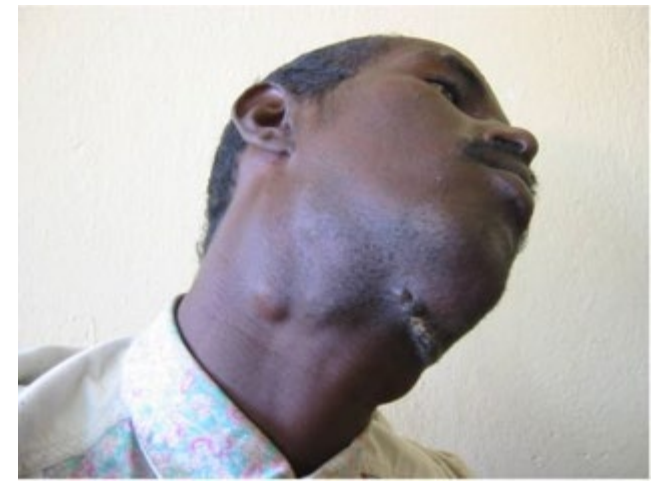
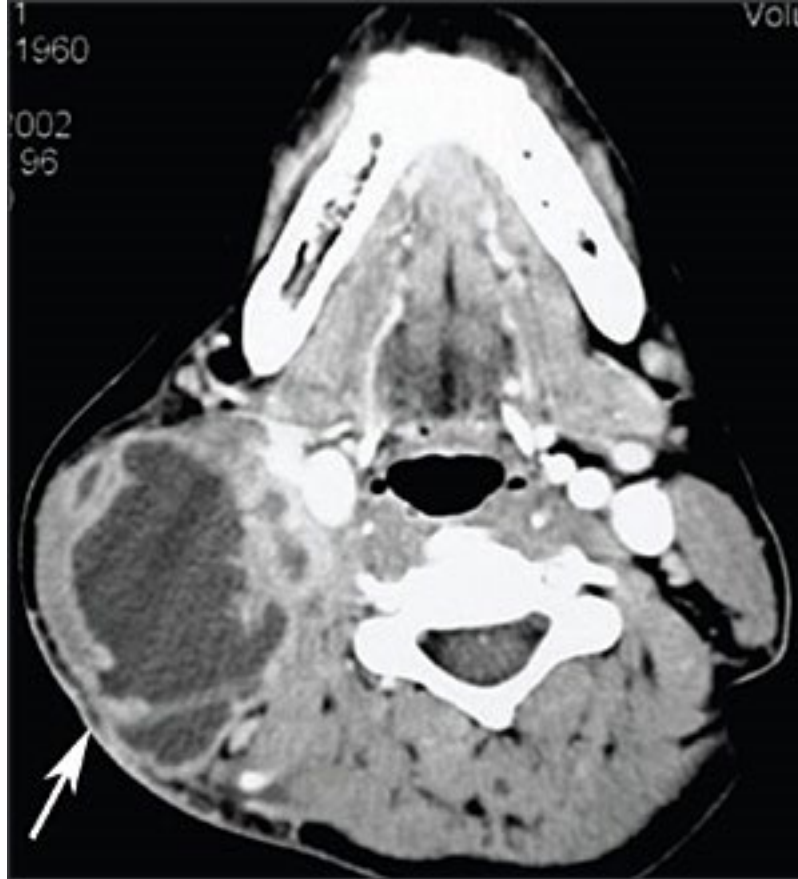
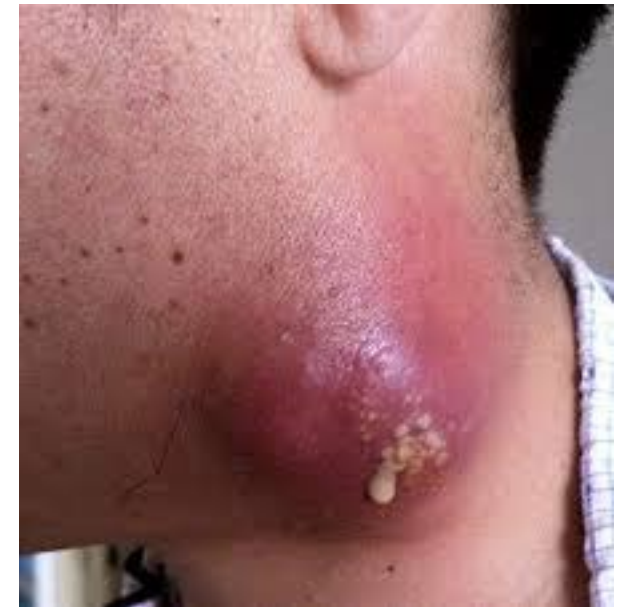Image found at: <https://slideplayer.com/slide/12455114/>



Acute paradoxical reaction of cervical tuberculous lymphadenitis
<https://casereports.bmj.com/content/2012/bcr.12.2011.5458>

Cervical TB lymphadenopathy in a child

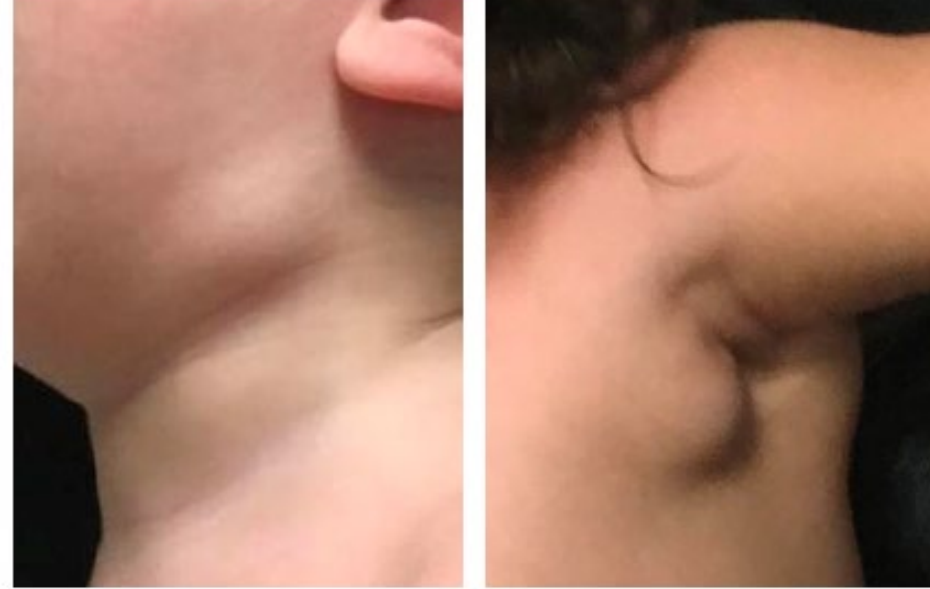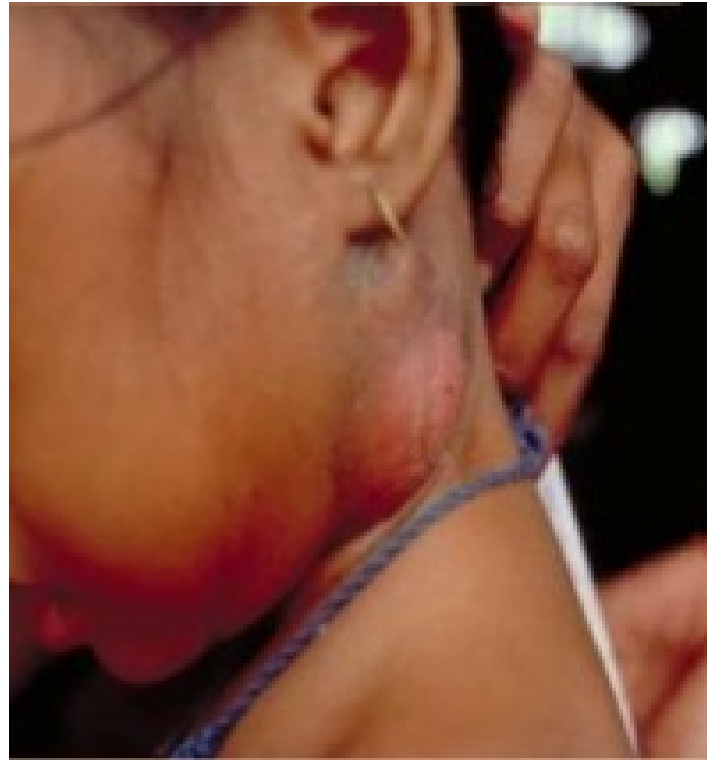

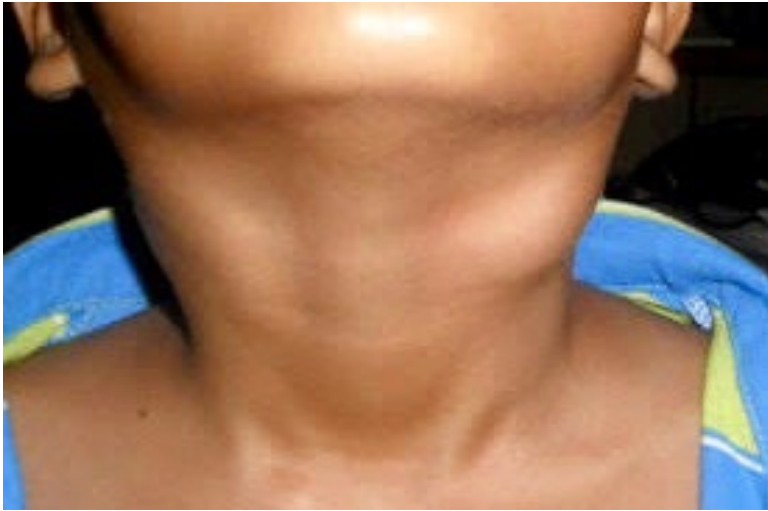
Figure 2: Cold abscess of cervical lymph node due to *Mycobacterium tuberculosis* (left) and *Mycobacterium bovis* BCG (right) infection.

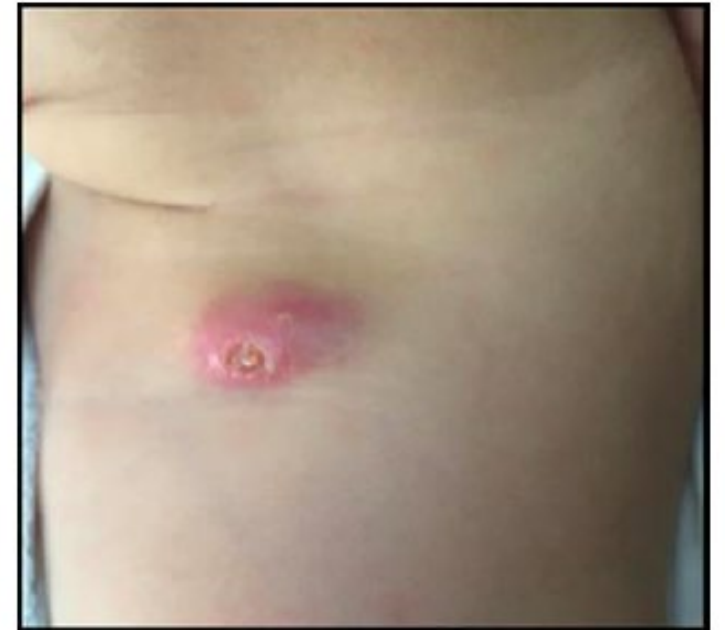

Figure 3: Spontaneously draining tuberculous lymphadenitis.

Images found at:

https://www.researchgate.net/publication/321331098_Chapter_4_Peripheral_Tuberculous_Lymphadenitis_Clinical_Approach_and_Medico-Surgical_Management/download

Diagnosis

- Abnormal IGRA-Quantiferon Gold.
- Biopsy R. lymph node: necrotizing granuloma, rare AFB on stain
- MD questioned malignancy with abnormalities on chest CT.
- Opacities in the Right lower lobe thought to be inflammation.
- Client unable to produce sputum sample and did not want to try induction since he was being treated and had no respiratory symptoms.

Polling Question #2

What is the quickest way to detect M.TB in this patient?

1. T-spotTB test
2. Liquid culture
3. Solid culture
4. PCR/NAAT (nucleic acid amplification test)
5. Genotyping

Table 2. Essential Laboratory Tests for the Detection of Mycobacterium tuberculosis

Test	Time Required
I. Nucleic acid amplification test, detection (NAAT-TB)	1 d
II. Nucleic acid amplification test, resistance markers (NAAT-R)	1–2 d
III. Acid-fast bacilli microscopy	1 d
IV. Growth detection	Up to 6–8 wk
Liquid	(average 10–14 d)
Solid	(average 3–4 wk)
V. Identification of Mycobacterium tuberculosis complex by DNA probe or HPLC	1 d ^a
VI. First-line drug susceptibility testing (liquid medium)	1 to 2 wk ^a
VII. Second-line and novel compound drug susceptibility testing	
i. Liquid (broth-based) medium	1 to 2 wk ^a
ii. Solid (agar- or egg-based) medium	3 to 4 wk ^a

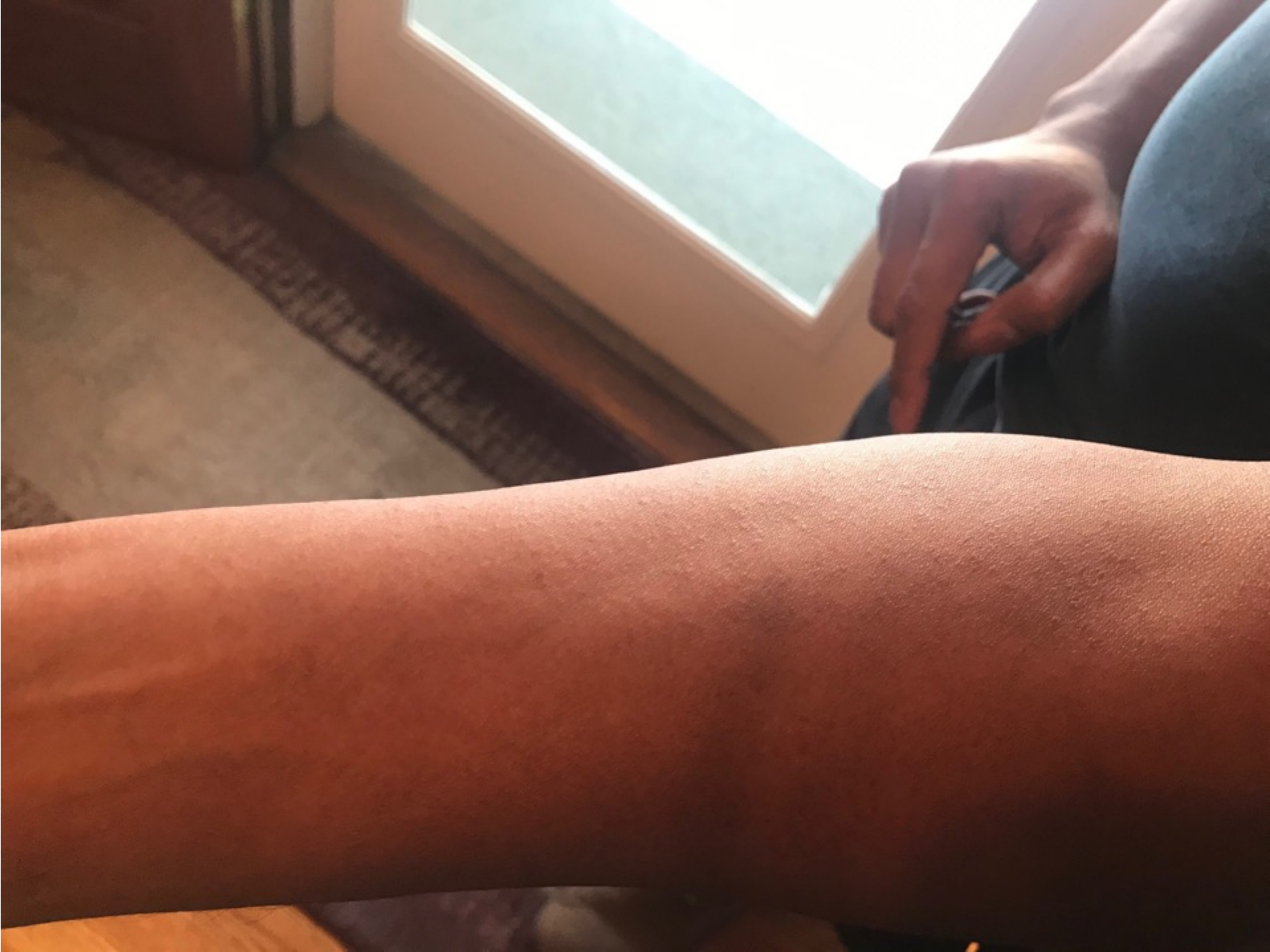Abbreviation: HPLC, high-performance liquid chromatography.^aAfter detection of growth.

Treatment

- Treatment with RIPE began.
 - Rifampin, Isoniazid, Pyrazinamide and Ethambutol
- A few weeks later, the lab reported the cultures were positive for M. tuberculosis
- A few weeks after that, the lab reported that culture-based DST indicated INH resistance.

Treatment

- INH was changed to Moxifloxacin
- Can still treat 6 months if completes 8 weeks of PZA and RIF + INH or quinolone continued for full 6 months
- Soon after starting the Moxifloxacin, client developed arm rash with itching.
- Rash lasted two weeks and improved with hydrocortisone cream.
- No change in medication and client completed 182 doses.



Contacts

- Family contacts evaluated, all without symptoms, Mom had negative QFT-gold, 2 children had TST
- One child had a positive TST 5x8mm, but QFT was negative.
- If contacts had been infected with INH-resistant MTB, cannot use 9INH or 3HP (contains INH and rifapentine); Treat with 4 months of rifampin monotherapy (4R)

Connections

Building trust and closeness with the family

Stories

- EM and the fire
- TM and karaoke
- Invitations to lunch

Pulmonary TB Confinement

WI DHS 252:

Local Health Officer may petition any court for confinement regarding:

- Infectious TB, suspect TB, or at high risk of developing TB.
- Person has failed to comply with treatment or if the TB is resistant.
- All reasonable means of voluntary compliance have been exhausted
- No treatment available
- The person poses an imminent and substantial threat to self or the public.

* A person with untreated extra pulmonary TB may be ordered into confinement because untreated extra pulmonary TB can turn into pulmonary TB

Extrapulmonary TB Confinement

Health Officer may order confinement to a facility for a person who has confirmed TB or suspect TB if these conditions are met:

- Health Officer notifies court in writing of the confinement
- Health Officer provides documentation of the diagnosis
- Health Officer provides proof the person refused to follow the treatment or the evaluation plan
- The Health Officer determines the individual poses a threat to himself or others. A written statement to the court will be provided.

Extrapulmonary TB Case Study #2

Jessica Linzmeier, RN, BSN

PHN, Marathon County Health Department

Wausau, WI

Jessica.Linzmeier@co.marathon.wi.us

Case 2. Background

Hmong client in his 70s moved to the United States in the 1980s

Comorbidities: hypertension, history of CVA with residual right-sided lower extremity weakness, gout, depression/anxiety, GERD, osteoarthritis

No known history of TB infection or prior TB disease

After CVA, right-sided weakness more in his RLE than RUE

Case 2. Presentation of Illness

Client c/o worsening back pain x 3-6 months despite receiving pain medication and a steroid injection

Also noted that his lower extremities had gotten weaker over the previous month, especially in his right lower leg

Upon assessment, client had paraspinal muscle tenderness along the right lumbar spine, but no erythema, warmth or drainage

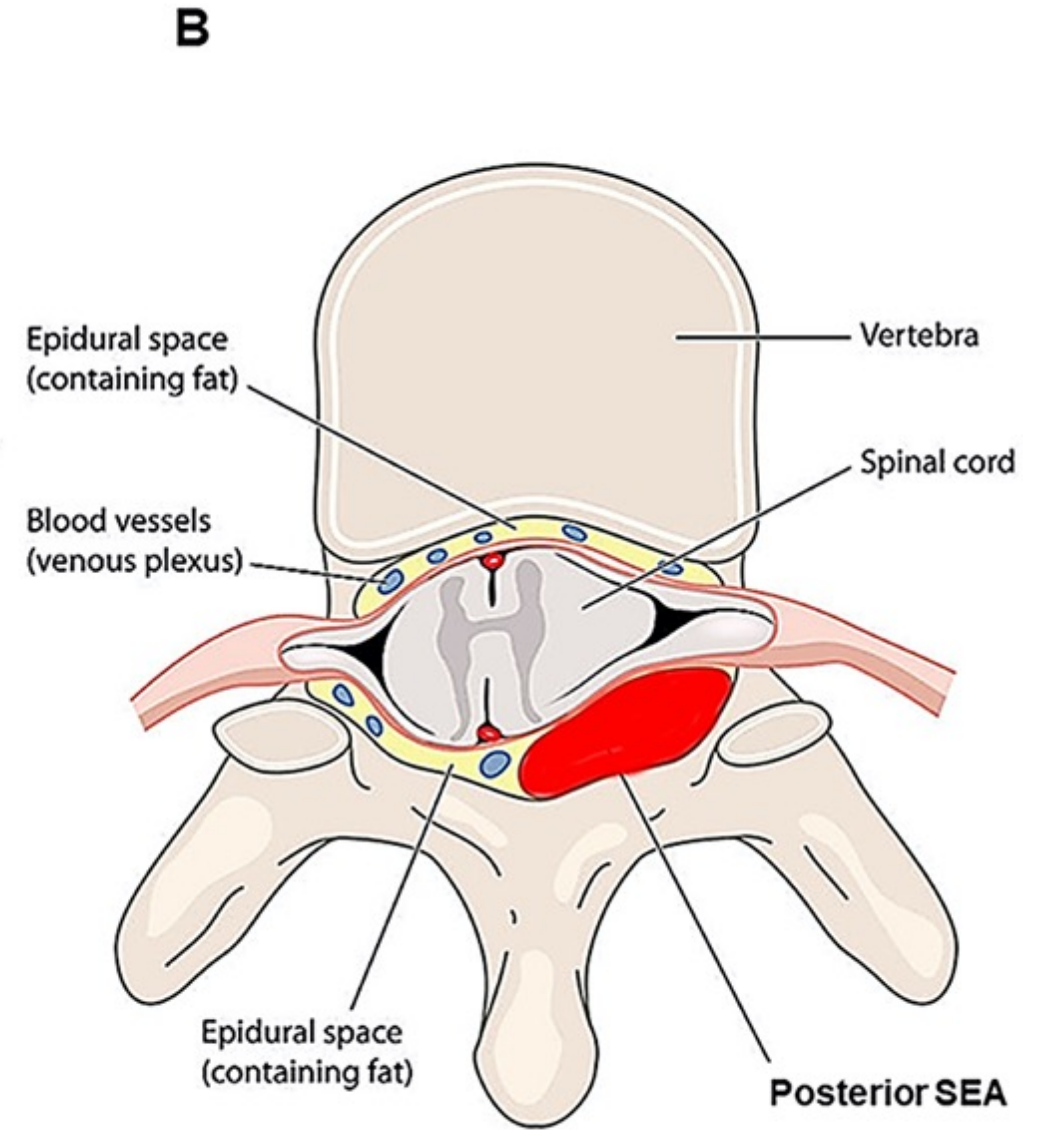
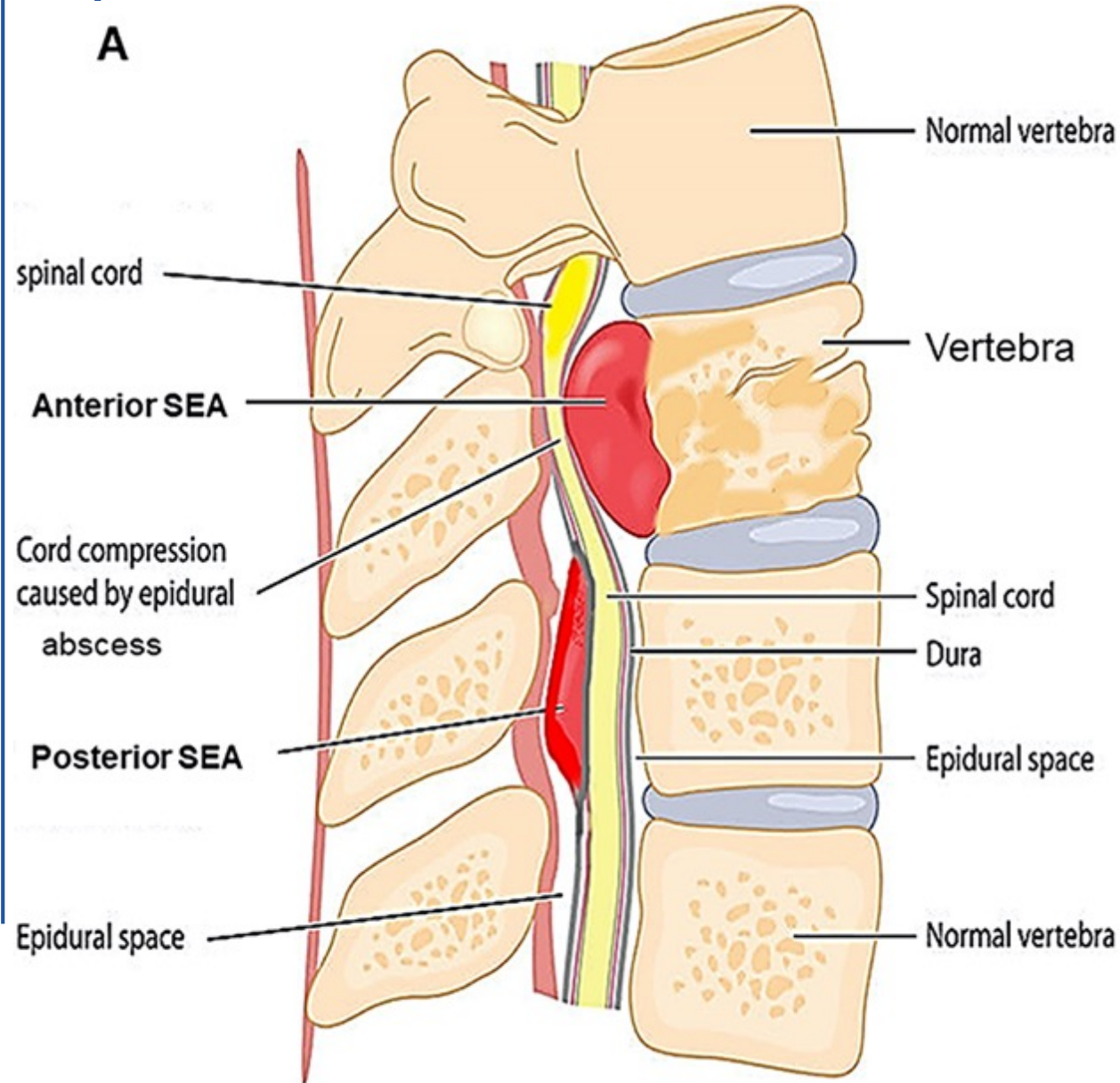
An MRI was ordered to assess his complaints

Case 2. Evaluation

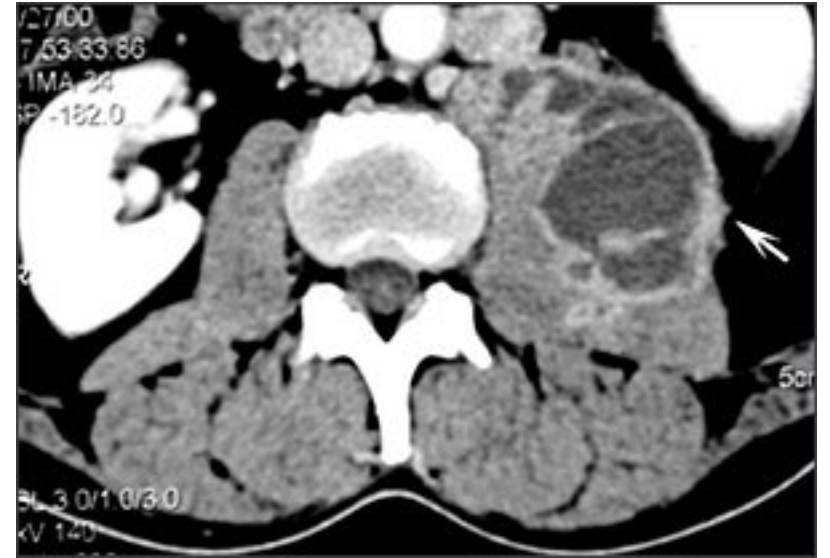
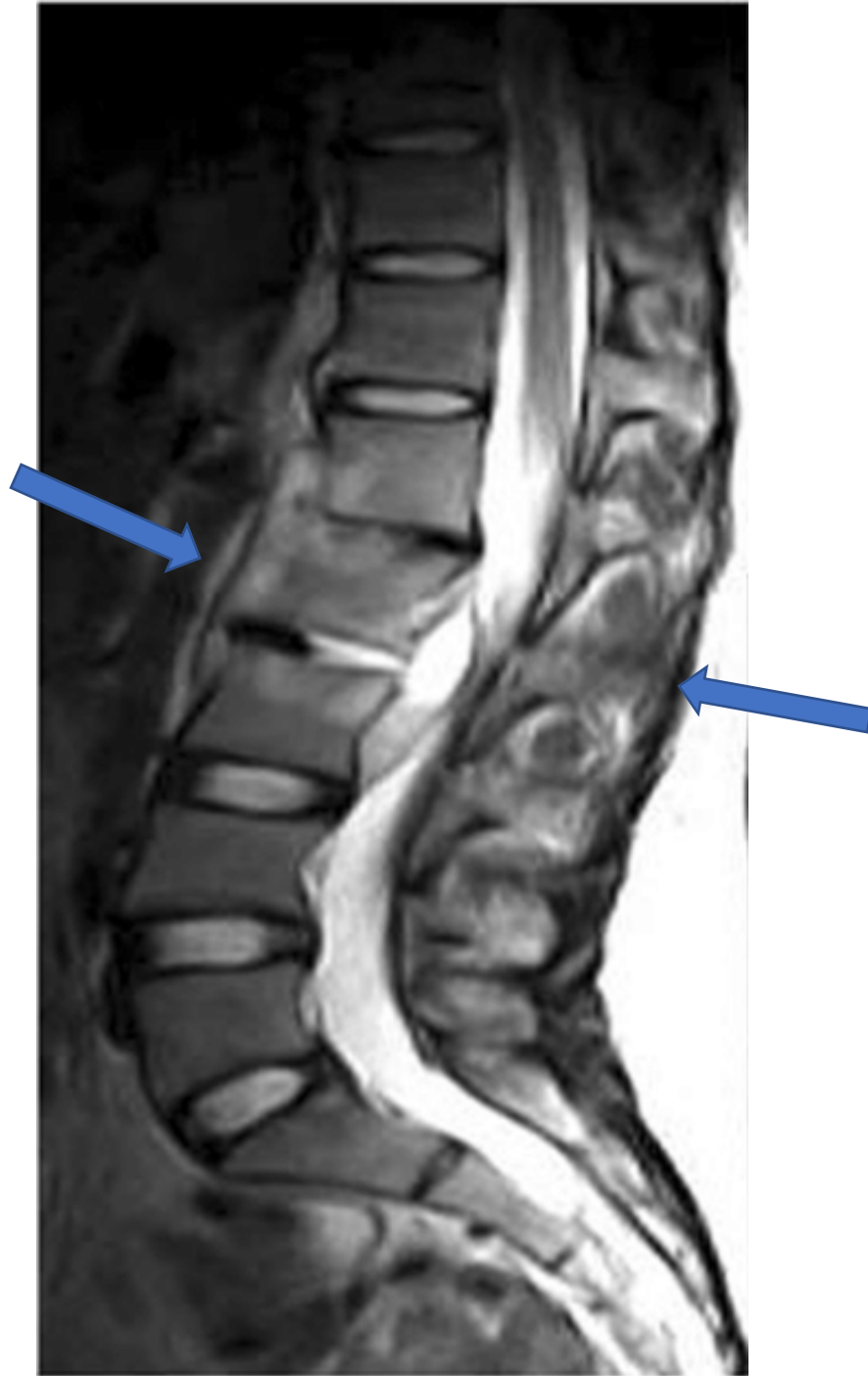MRI of lumbar spine:

- Likely discitis/osteomyelitis L3-4 interface
- Paraspinal extension to (but not inside) L psoas muscle
- Small loculated fluid collections anterior to vertebral body
- Prominent epidural abscess along the dorsal thecal sac L1-L3 compromising the thecal sac (prevented normal flow of CSF)

Epidural Abscess



Epidural
Abscess
With Spinal
Cord
compression



Polling Question #3

Which would be the most appropriate NEXT step?

1. Emergency surgery for debridement and stabilization
2. Wait for cultures to grow an organism before starting any treatment
3. Empirically treat for a bacterial abscess
4. Urgently treat for TB disease
5. Send molecular testing for MTB

Indications for Surgery in Pott's Disease

- Several trials found no additional benefit of surgical debridement with medical treatment for spinal TB
- Surgical intervention:
 - Neurologic deficits, spinal instability, poor response to treatment if large abscess
- Even if hardware is in place at time of bone/joint infection, surgical washout not required

Back to Case #2...

- Pt had L1-3 laminectomy with evacuation of epidural abscess to relieve compression.
 - Gram stain and culture of abscess was negative for bacteria
 - Abscess AFB smear negative
- Blood cultures were negative
- The client was not prescribed antibiotics for this abscess upon discharge from hospital.
 - Provider suspected either TB or blastomycosis.

Polling Question #4

Which of factors suggest TB instead of a bacterial infection?

1. Being Hmong, born outside the US
2. Symptoms worsened over months (subacute/chronic)
3. No fever despite an epidural abscess
4. Bacterial gram stain and cultures were negative
5. All of the above

Diagnosis of Spinal TB/“Pott Disease”

- 2 weeks after MRI/abscess drainage, ID Provider started client on RIPE pending AFB culture
- Diagnosis was confirmed 4 days after RIPE started
- Surgical specimens from epidural abscess were culture positive for MTB
- Culture were negative for fungal organisms

- **Provider did not notify public health of suspect TB case*

Wisconsin Statute 252.05: Reporting of Communicable Diseases in Wisconsin

- Tuberculosis is a Category 1 disease
- Doesn't specify pulmonary, so reporting of extrapul is also required
- Who is required to report?
 - Any health care provider who knows or has reason to believe a patient has TB disease
 - Laboratory identifying M.TB

Challenges

- Client lived with his wife and his son's family. Initially the family was not receptive to public health involvement and stated that public health was upsetting the client and he was not infectious.
- Client and family agreed to obtain three sputum samples to rule out pulmonary TB; public health staff wore N95 masks until pulmonary involvement ruled out.
- Question of whether public health can enforce DOT for strictly extrapulmonary TB cases

Case Management and DOT

- After additional conversations with client's family, DOT was started on weekdays M-F; client's family monitored administration on weekends
- Because initial sputum cultures were negative, no follow up sputum samples were needed
- Client initially lost weight with treatment, so weight was taken weekly and then monthly when it stabilized; no other vitals were performed by public health

Polling Question #5

How long should this patient with TB of the spine be treated?

1. 6 months
2. 9-12 months
3. >1 year
4. It depends on whether patient has surgery with hardware placement

Home Health Care

- Home care agency came to assist with patient's wound care; he did not have a drain post-op
- Staff were wearing N-95 masking during their work cleaning the wound and changing the bandage.

Polling Question #6

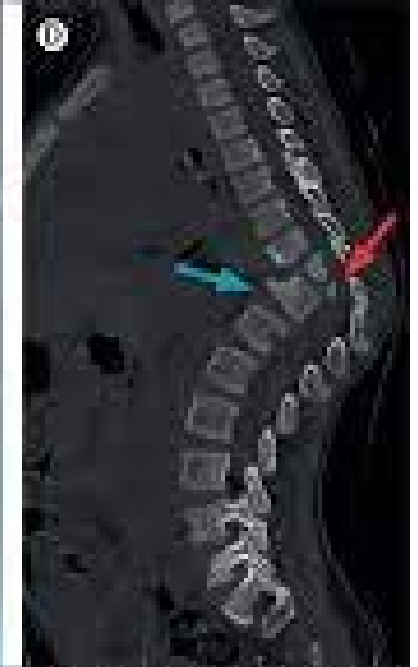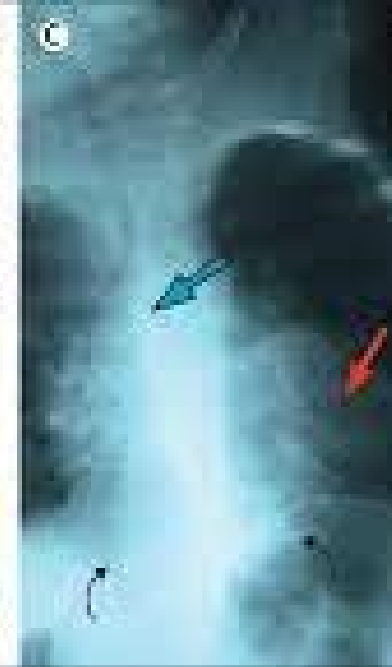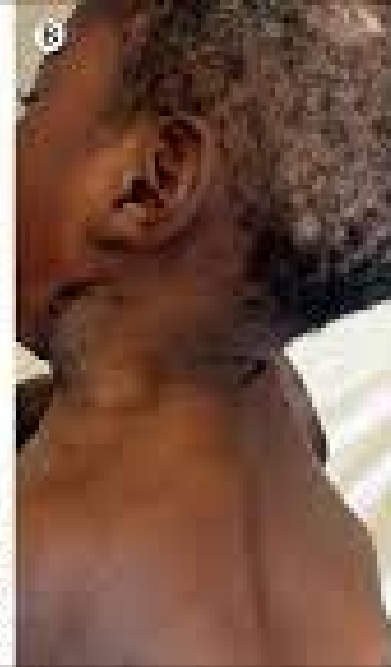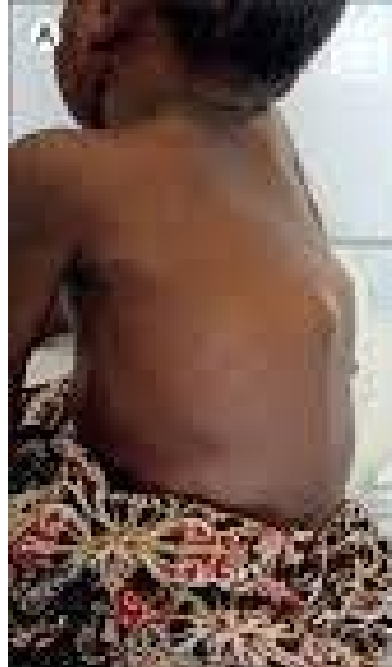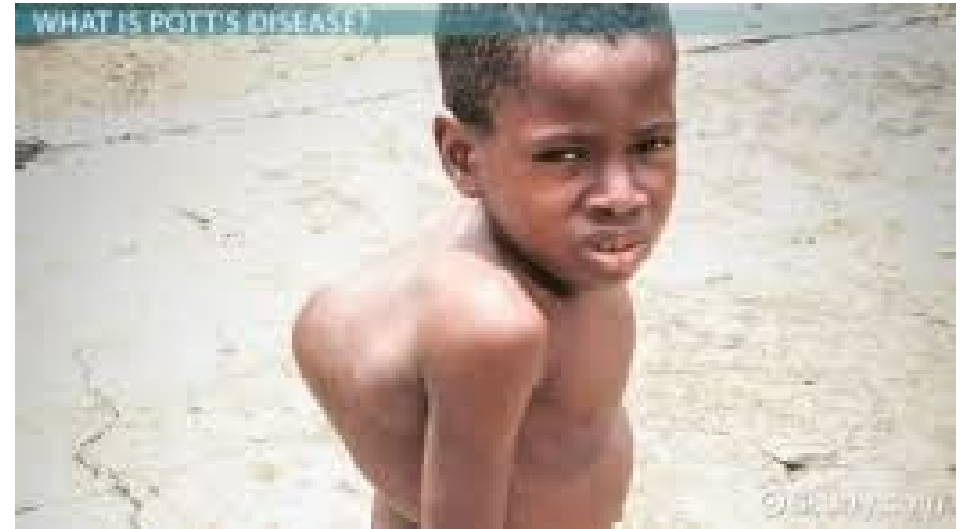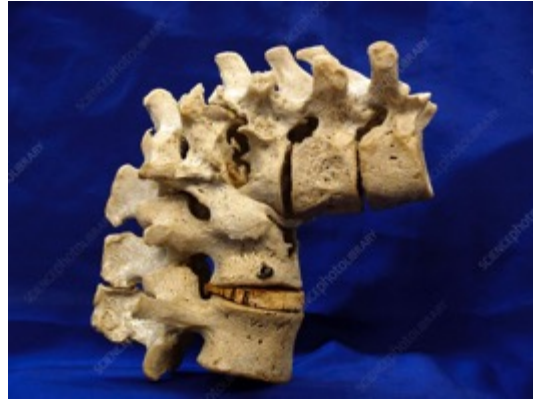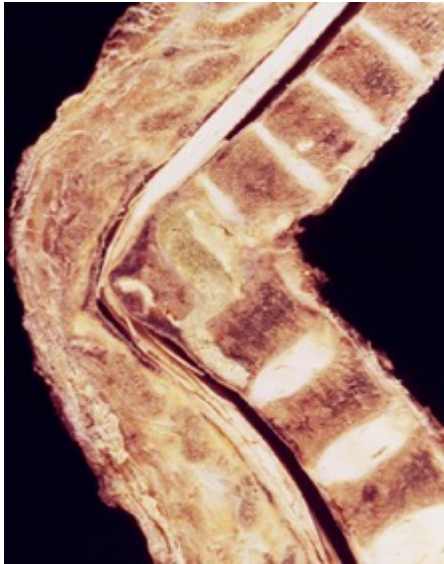
Is a N-95 mask needed to avoid TB transmission during wound care?

1. Yes
2. No
3. It depends

Case #2 Follow Up

- Gout was exacerbated by use of TB treatment
 - PZA and EMB can cause high uric acid levels
- Increased pain and swelling in his feet and was given prednisone and increased allopurinol and it improved
- He completed 12 months of therapy—2 months of RIPE and 10 months of INH/RIF (with B-6).
- As he completed treatment for spinal TB, his back pain resolved and his RLE symptoms returned to baseline.

Advanced Pott's Disease



More Cases of Extra-Pulmonary TB

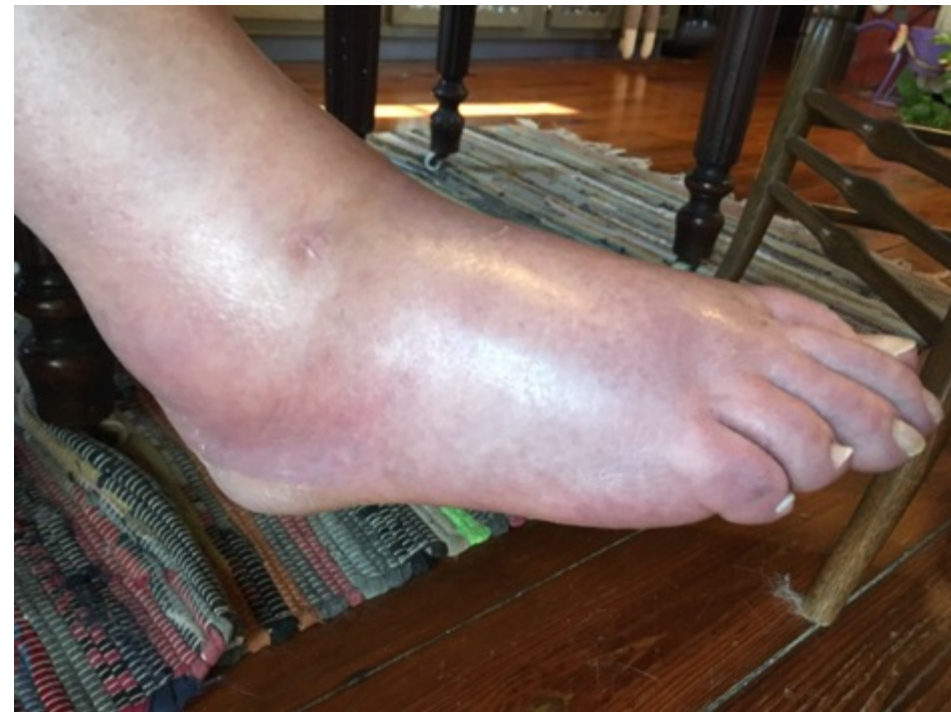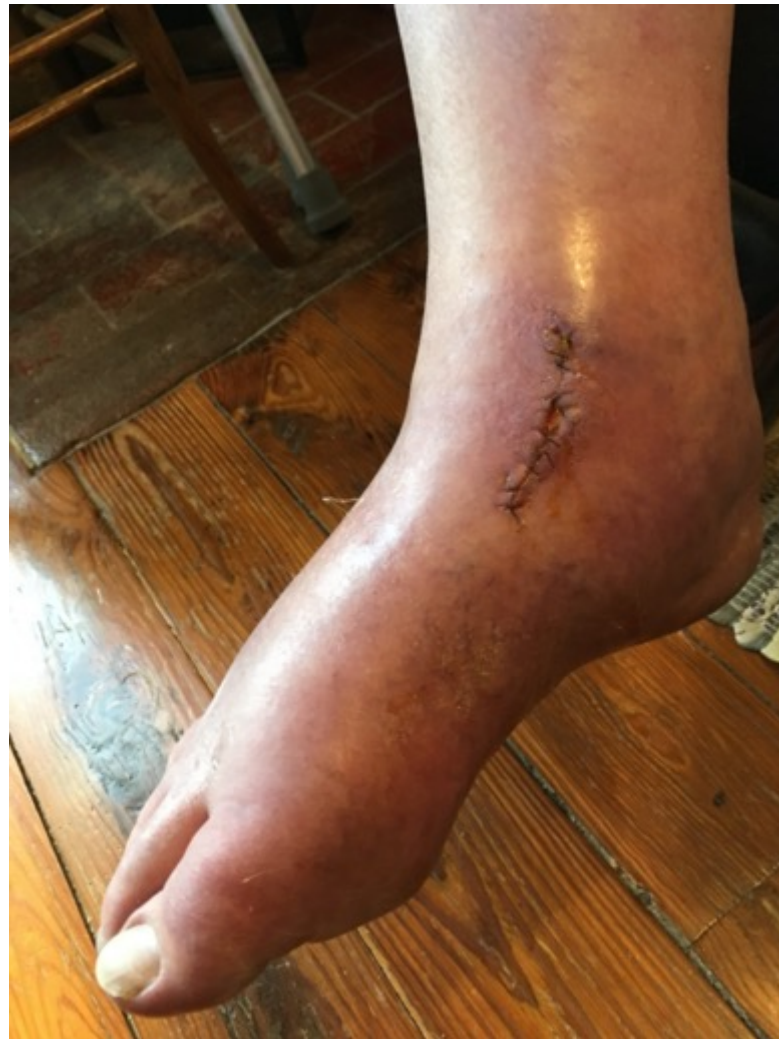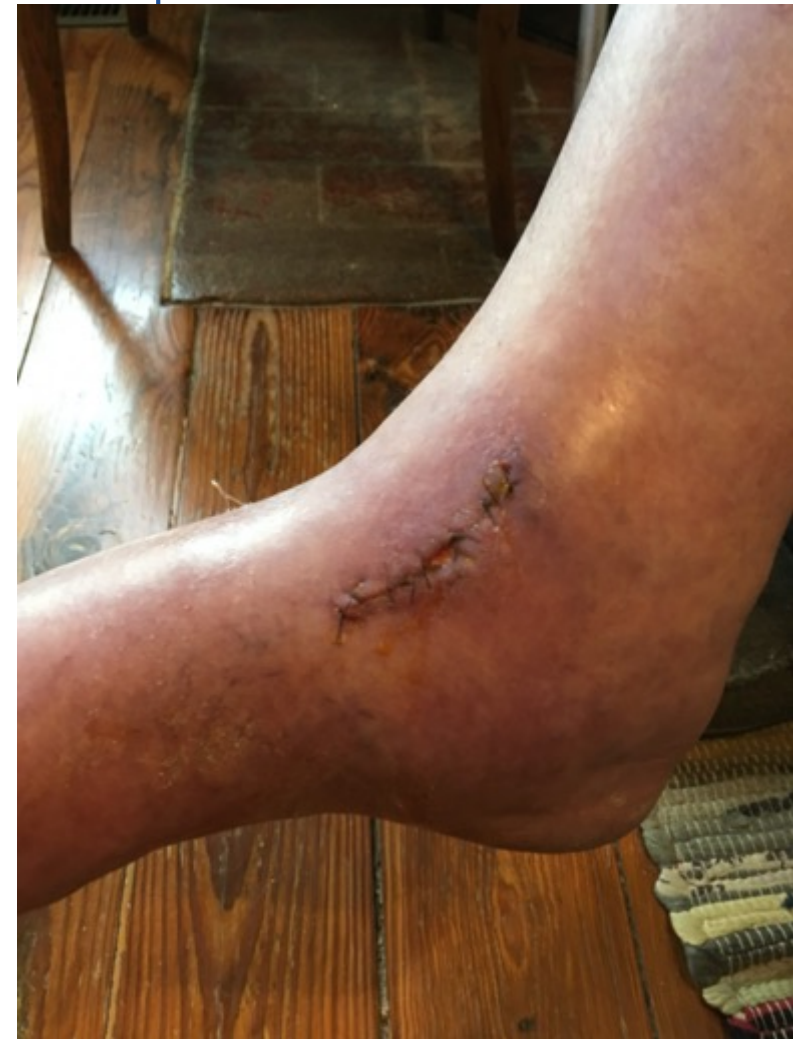Case 3. Initial Presentation

- 69 yo active Male Real Estate Agent
- 2004-2007: Sarcoidosis treated with steroids
- 2017 pulmonary histoplasmosis
- 3/2021: RUL nodules and calcified smaller RML mass
- 6/2021: Swelling of R ankle and foot
- 6/7/2021: Bronch non diagnostic
- 10/8: Incision and biopsy of ankle/foot (steroids given?); No diagnosis made

Case 3. Diagnosis

- MRI: bone erosion, osteomyelitis of the ankle
- 12/10/21 Open surgical procedure—
 - Granulomas on histopathology, PCR + MTB
 - Synovial fluid culture grew MTB
- Sputum 12/13/21: Smear neg, culture negative
12/14: Smear 1+, culture growth wk 3, probe MTB+
12/15: Smear 1+, culture growth wk 4, probe MTB+
- Patient started RIPE 12/14/21
- 12/31 CXR: many small BL nodules, not typical military pattern

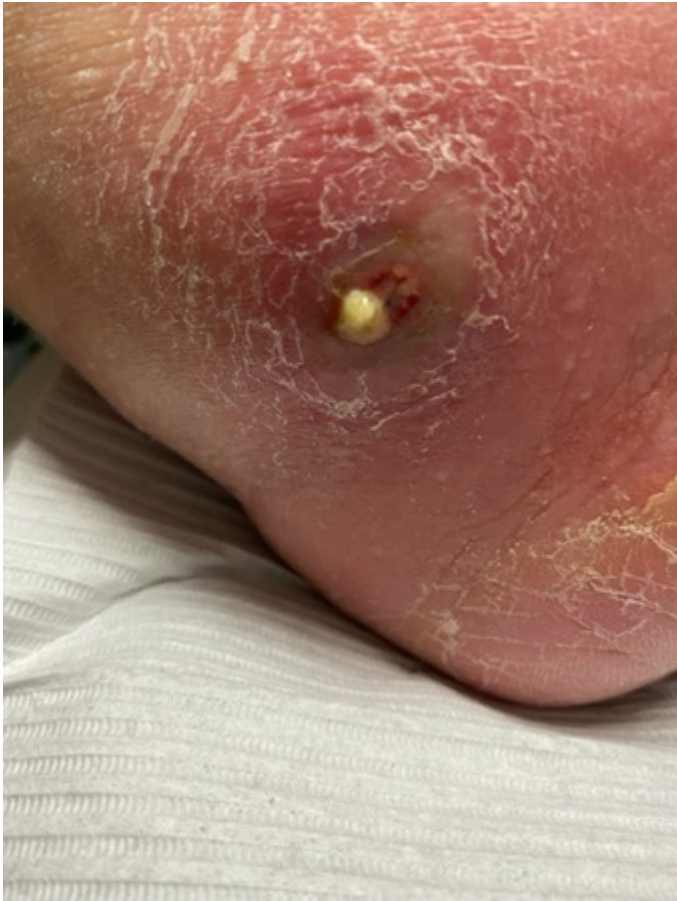Right Ankle Post-Op



Early Course of Treatment

- ~2 wks later, he developed N/V, AST 533 ALT 291 T Bili 1.0 Alk phos 79
 - No viral hepatitis, underlying liver disease, alcohol, other meds/herbals
 - Drug hepatotoxicity likely cause
- Meds changed 12/23/21 to EMB, Linezolid and Levaquin
- Ultimately rechallenged RIF and PZA, continued Levaquin and EMB
- Ankle healing with decreased swelling and pain
- CXR 2/4/22 improved from baseline

Ankle worsening again



- Increased swelling, erythema over surgical site of R ankle, AND new pustule on L side.
- 2/22/2022: MRI
 - Progressed severe erosion arthritis of tibiotalar, subtalar and distal tibiofibular joints
 - Extensive synovitis and fluid collection wrapping around lateral malleolus
 - Marked subcutaneous edema and skin thickening consistent with cellulitis.
 - Multifocal tenosynovitis with multifocal tendon thickening/inflammation.
- Additional samples collected from ankle

TB Immune reconstitution inflammatory syndrome (IRIS)

TB IRIS is a hyper-inflammatory response that can appear as a

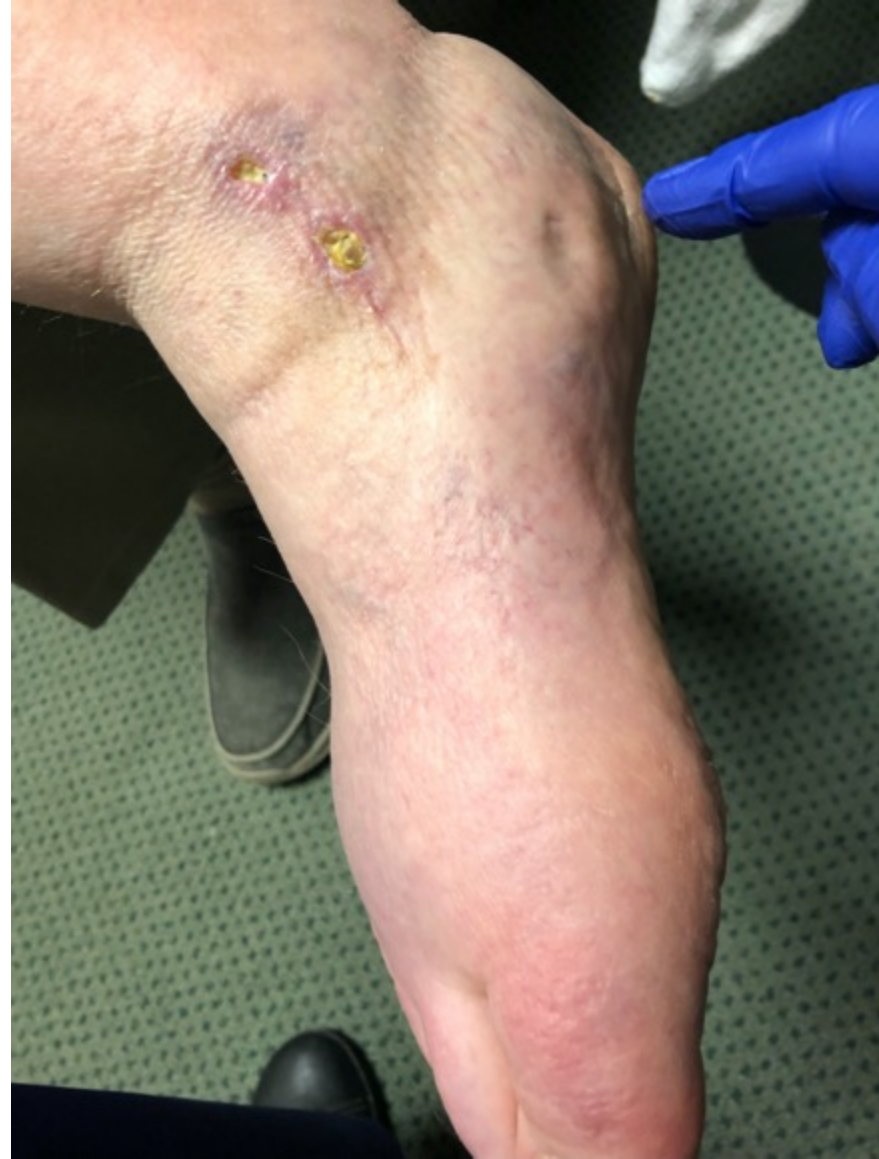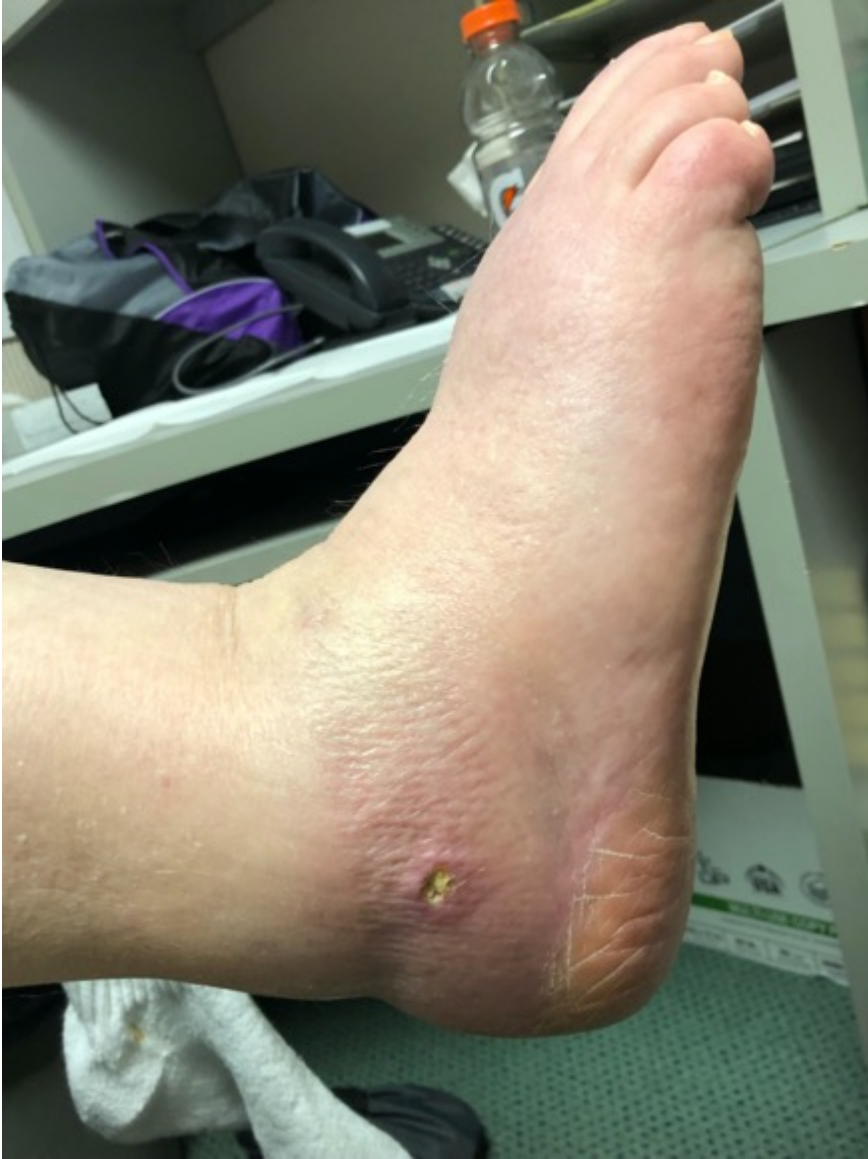- 1) Worsening of symptoms despite adequate TB therapy
- 2) Unmasking of new sites of TB disease as immunity improves

TB IRIS is a diagnosis of exclusion after ruling out

- A secondary infection
- TB treatment failure
- Patient is not taking his TB medications
- Low serum levels of TB drugs
- Resistance to TB Drugs

Management of Patient's Recurrent Symptoms

- Nurse reported he was very compliant with DOT
- Bacterial cultures negative
- TB PCR “indeterminant”, AFB smear negative (culture pending)
 - Molecular DST not possible
- Serum levels of TB drugs were therapeutic
- Patient also has new back pain – MRI recommended
- Began a steroid taper over several months
- Back pain resolved, ankle no longer draining



Right ankle after 11 days of steroids

Case 4.

- 49 yo man born in The Congo
- He worked in Kenya as a physician
- Immigrated to the U.S. 3 years ago
- Mom living in The Congo had “bone TB” in 2019

Case 4. Presentation of Illness

- 7/2020: new R. testicular pain with erection and ejaculation; new brown-colored ejaculate
- 10/3: fever >100 at night, night sweats, malaise, fatigue, hard to urinate, myalgias, anorexia, and was loosing weight.
- 10/15 ER visit: No abnormalities on blood or urine testing, CXR normal, Treated with 100mg doxycycline x14d for possible malaria
- 10/28: Went to has family MD c/o fatigue, night sweats and a new small mass in his R. testicle
- Repeated his blood work, PSA=23 (H), ordered ultrasound of his testicles and referred him to urology

Case 4. Presentation (con't)

- R. testicle increased to massive size over 2 months; persistent pain, brown discharge on ejaculation, systemic symptoms.
- Urology noted solid mass in R testicle - felt it was not cancer, referred to ID
- 12/16/20: ID evaluated for brucella, filariasis and M.TB; HIV negative
- QFT-plus “positive”
- 1/29/20: urine culture grew MTB
- 3/2/21: repeat urine AFB stain neg, culture grew MTBc at week 3
- Started RIPE 4/5/21

Case 4. Follow up

- After about 11 days of RIPE, he came in for DOT and was having difficulty walking, stood and sat with a wide stance due to testicular swelling
- On exam, the testicles were enlarged to about 10 inches diameter and the couldn't distinguish separate testicles
- 5/3/21: At TB clinic visit, reported his testicle “burst” at home, then urologist excised it releasing secretions like cottage cheese to relieve pressure

Testicular TB

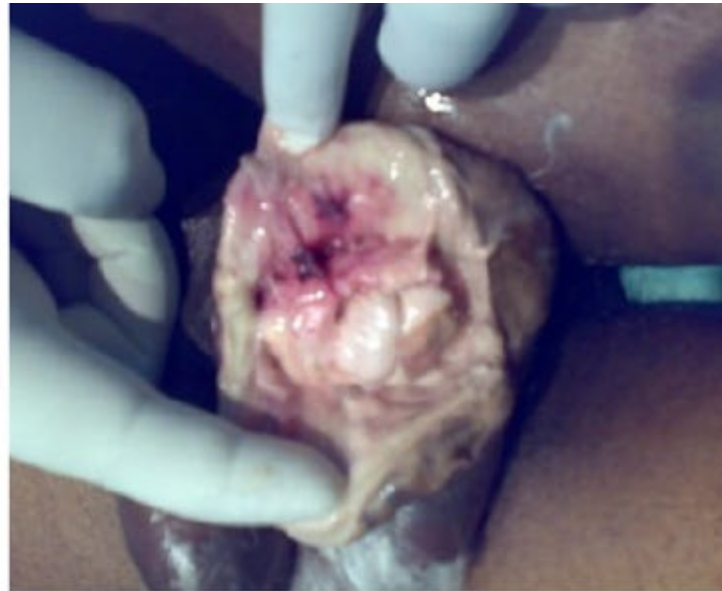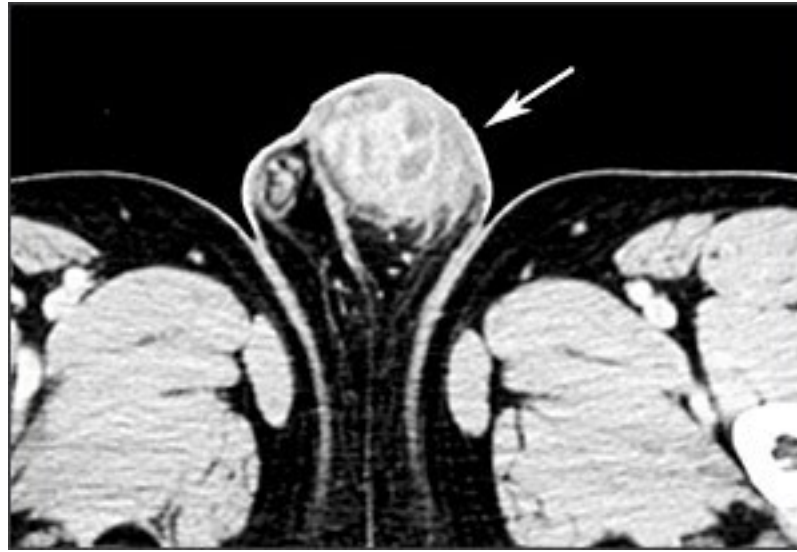


Fig.6: Patient presenting with chronic discharging sinus of scrotum with protruding testicular soft tissue and pus coming out through the sinus tract

Case 5: Wife of patient with GU TB

- 51y and just had a miscarriage in January
- Born/worked as a nurse in Kenya
- PMH: 1 spontaneous abortion, 3 induced abortions, 7 pregnancies
- Obese, anxiety and depression
- Meds: Citalopram, Miralax, Wellbutrin
- Occasional alcohol no smoking
- Only symptom is vague abdominal pain

GU TB In Females with Infertility

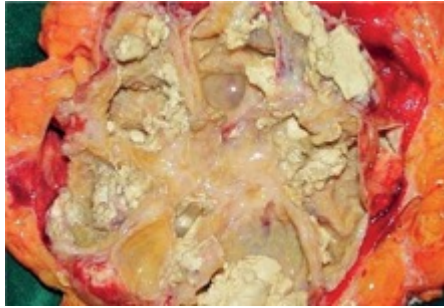
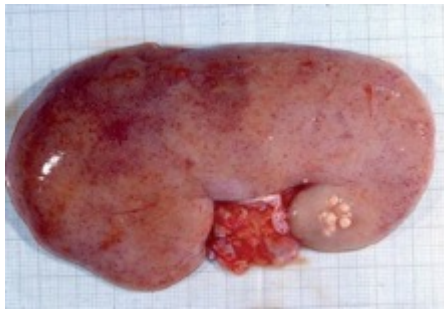
- TB responsible for up to 20% cases of infertility in developing countries
- Fallopian tubes almost always affected
- Atypical symptoms mimic other gynecological conditions
 - Menstrual abnormalities, pelvic pain, abnormal vaginal discharge, chronic PID not responding to antibiotics, post-menopausal bleeding
- Diagnosis (think TB—comprehensive exam)
 - IGRA (indicates TB infection, doesn't confirm TB disease)
 - Sputum and CXR to evaluate possible pulmonary TB
 - Pelvic exam
 - Abdominal ultrasound, image tubes and ovaries
 - Pap smear and biopsies for histopathology AFB culture and TB PCR
 - Urine testing for PCR & culture (low yield)

Case 5. Evaluation of Wife

- QFT-*plus* Negative, HIV negative
- Ultrasound was unremarkable
- Endometrial and cervical biopsies
 - Negative histopathology and AFB stains
 - Culture not sent, PCR not done
- Urine testing for PCR & culture negative
- All sputum cultures negative
- Empiric treatment not given—risk vs benefit

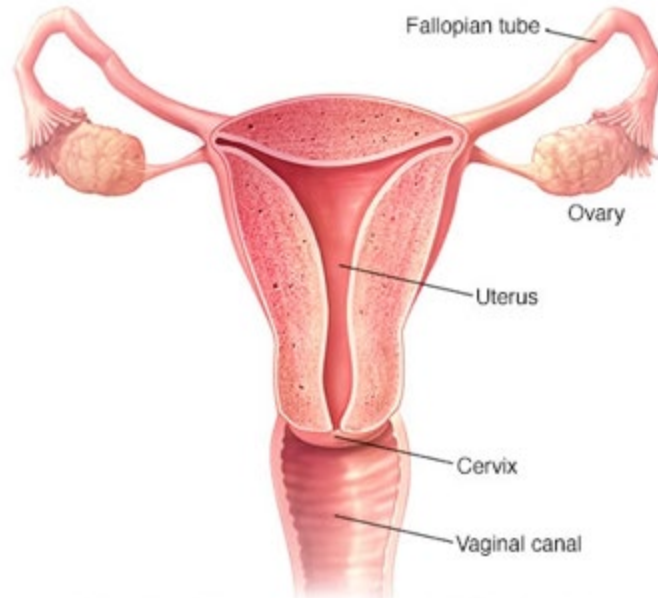
Treatment of UG-TB

- Same as pulmonary TB
- Ask if patient treated with quinolones prior to diagnosis
- If advanced renal disease, adjust doses of PZA and EMB
- Surgery only indicated for complications
 - Nephrectomy required for severely damaged kidneys

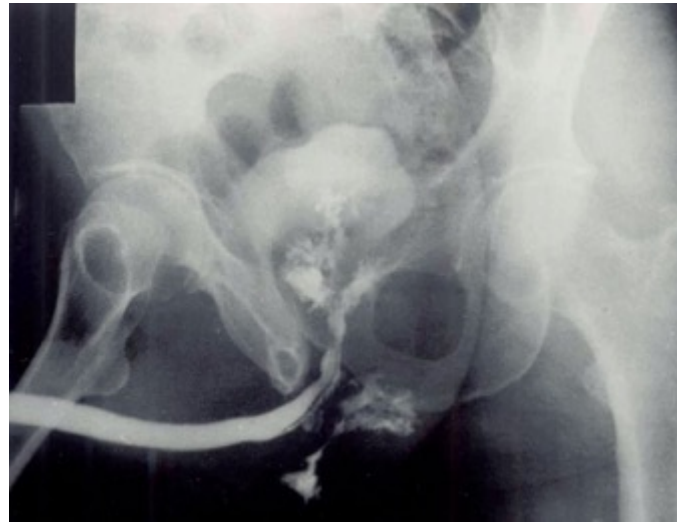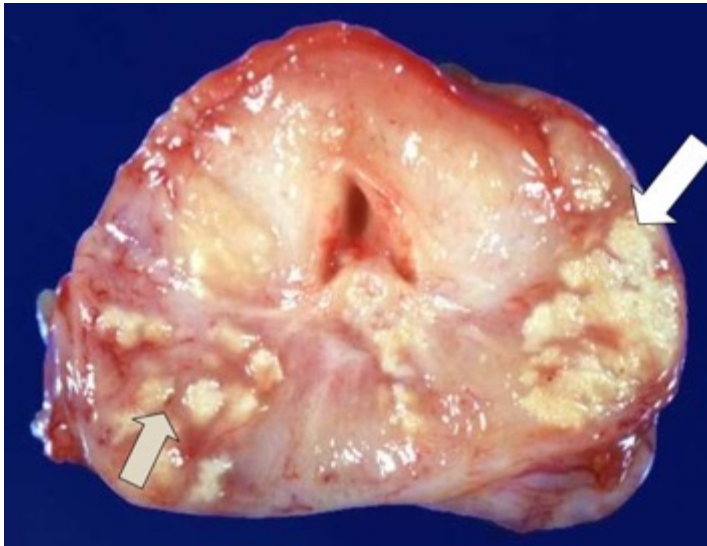
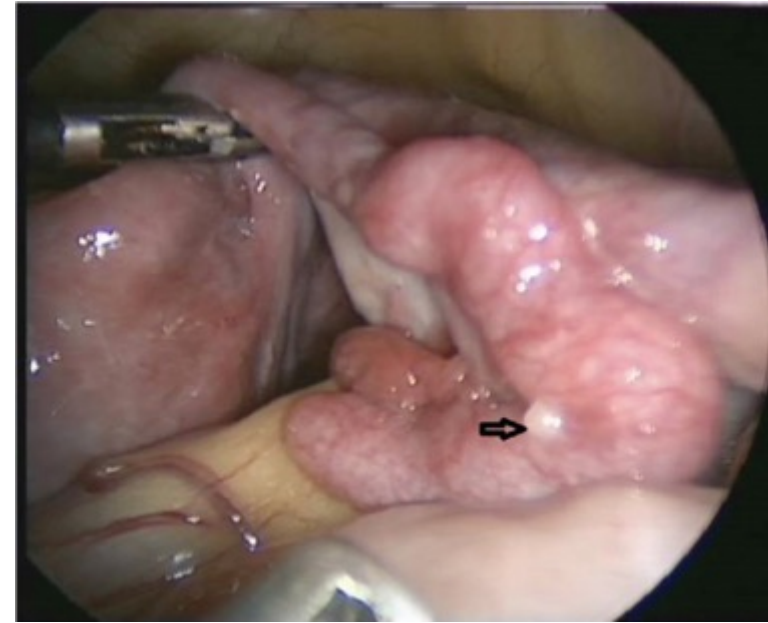


Renal TB

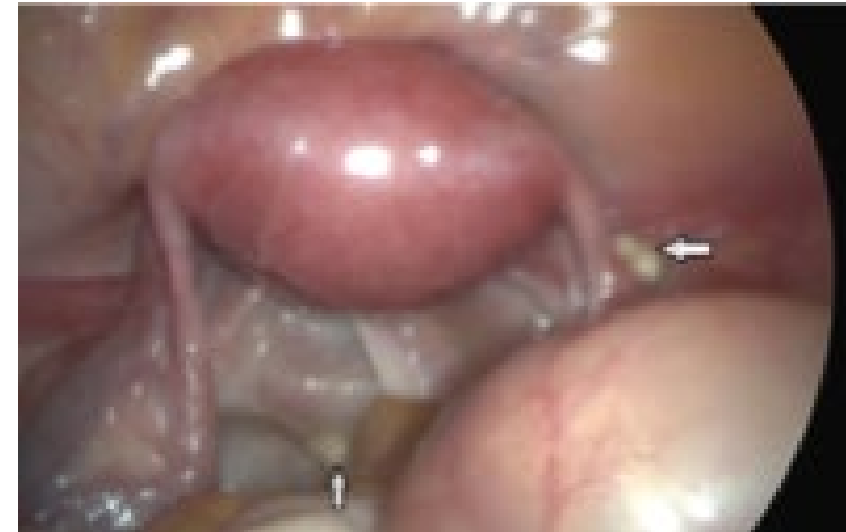Female GU Tract



© MAYO FOUNDATION FOR MEDICAL EDUCATION AND RESEARCH. ALL RIGHTS RESERVED.



Prostate TB. Contrast fistulogram showing tissue destruction and urethrocutaneous fistula



Case 6.

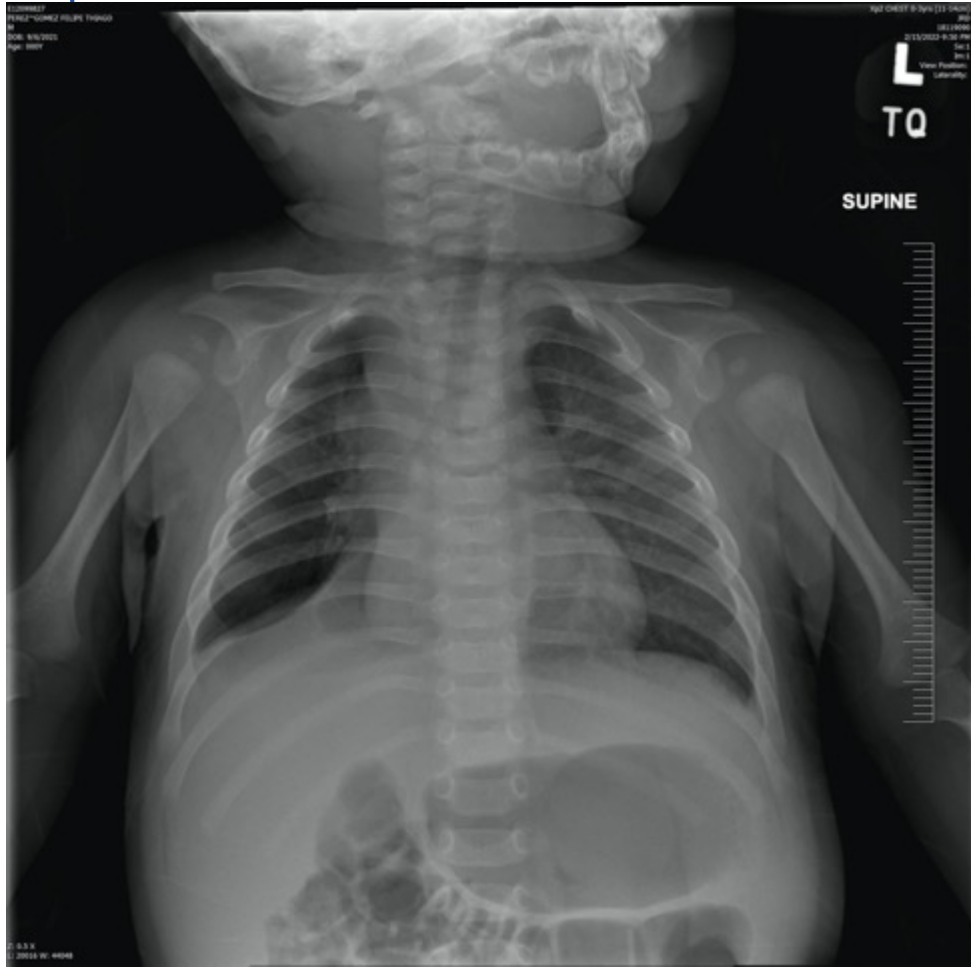
- 4mo male exposed to adult with cavitary, AFB smear+ TB
- Asymptomatic; 15mm TST
- CXR patchy opacity R. perihilar region suspicious for atelectasis vs. pneumonia
- Admitted for gastric aspirates (smear -, PCR -, culture pending)
- 1/21/22 RIPE +B6 via DOT
- 1/28/22 MDDR of source INH resistance-INH stopped (cont RIF/PZA/EMB)

Case 6.

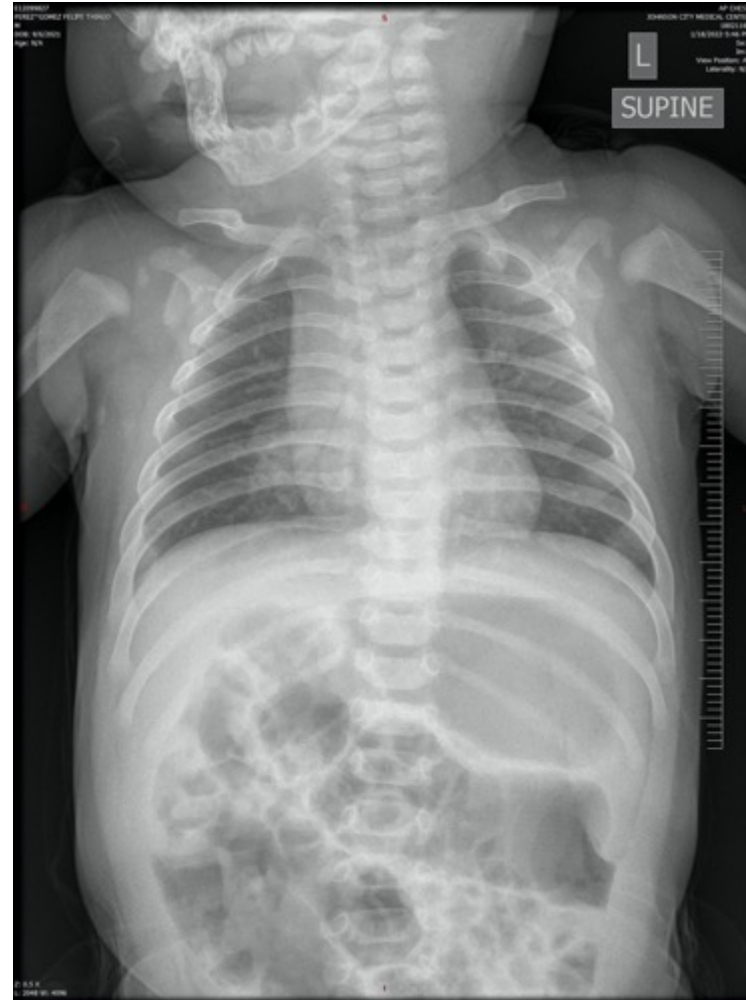- Continued cough, parents concerned that infant seemed to get SOB at times; TB staff noted dyspnea after a coughing spell.
- In clinic, breaths sounds very diminished on the R – sent to local Hospital
- Observed overnight and released without any further plan or workup.
- Family unable to drive to larger medical center for Pediatric specialist
- SNTC Pediatric TB expert reviewed CXR “increased R hilar/perihilar lymphadenopathy with R hyperinflation (suggests IRIS), empirically started prednisolone
- Returned with increased symptoms as steroids tapered (Rif increases steroid metab)
- CXR: worsening infiltrate on the right
- CT chest: Bilateral mediastinal adenopathy with very large R nodal mass (3cm x 2cm) and large 2cm node on L; post-obstructive pneumonia with opacification of almost entire RLL and mild patchy areas of pneumonitis elsewhere

Case 6.

- Family opposed to admitting the kid to the hospital several hours away
- Child eating well, and looked comfortable, stable, decided to try to manage this as outpatient with the following:
 - Increase the prednisolone dose to 3 mg/kg
 - Treat the post-obstructive pneumonia with antibiotics: **Augmentin ES to cover** Strep pneumo, other respiratory/oral flora, anaerobes, and staph (not MRSA)
 - Follow up closely, Admit for clinical deterioration or lack of response.



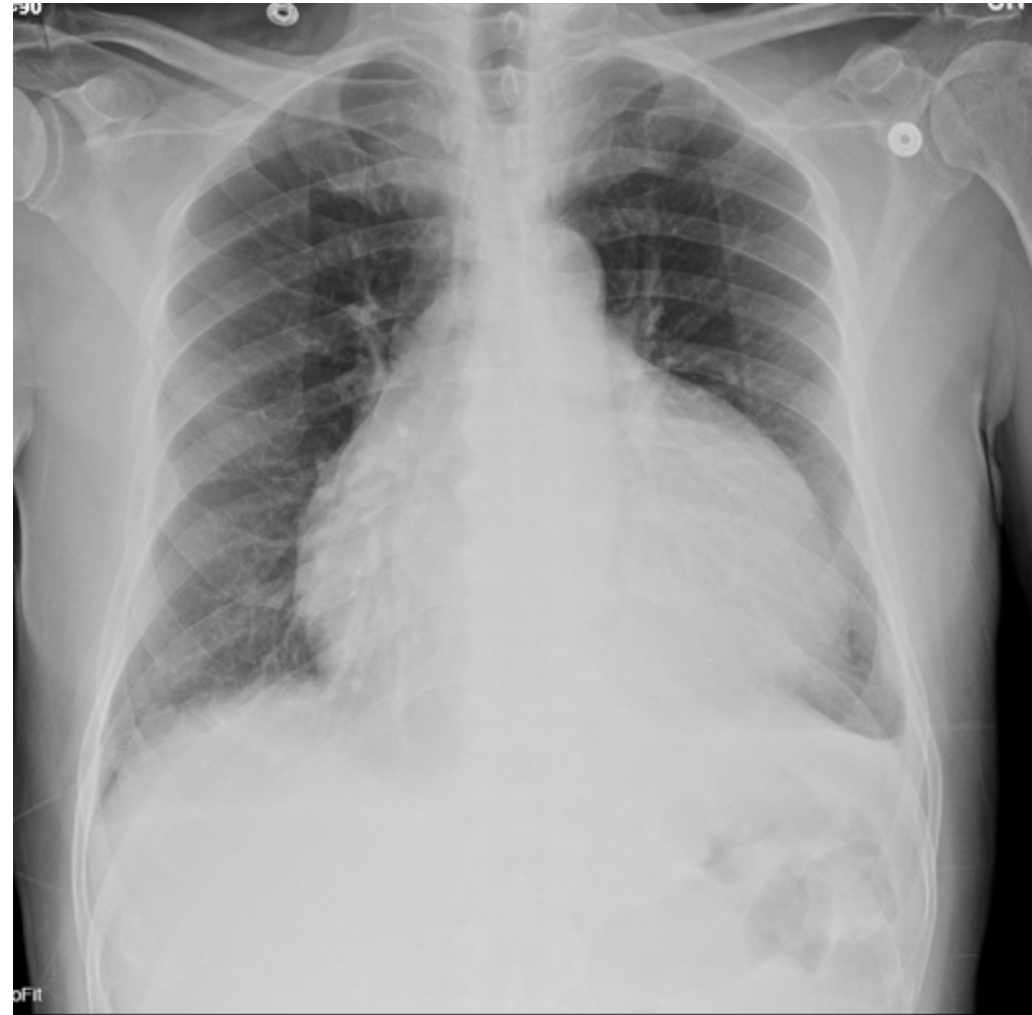2/15/22



2/18/22

TB of the Pericardium

- 70 yo M Born in/travel to India
- Symptoms: Cough, fv, SOB, anorexia and weight loss over MONTHS
- CXR: enlarged heart shaped like a “water bottle”, pleural effusion



SNTC TB Center of Excellence

- **1-800-4TB-INFO**
- <https://sntc.medicine.ufl.edu/home/index#/mcs>
- Available 24-hours, 7 days a week
- Medical consultation for TB and LTBI, program and infection control issues, etc.
- Laboratory testing (molecular, MICs, non-respiratory specimens)
- Therapeutic drug monitoring
- Drug procurement



TB Guidelines

- *Diagnosis of TB in Adults and Children*. Official ATS/IDSA/CDC Clinical Practice Guidelines <https://academic.oup.com/cid/article/64/2/e1/2629583>
- *Treatment of Drug-Susceptible Tuberculosis*, <https://academic.oup.com/cid/article/63/7/e147/2196792>
- *Guidelines for the Treatment of Latent Tuberculosis Infection: Recommendations from the National Tuberculosis Controllers Association and CDC, 2020*, https://www.cdc.gov/mmwr/volumes/69/rr/rr6901a1.htm?s_cid=rr6901a1_w.
- *Testing and Treatment of Latent Tuberculosis Infection in the United States: Clinical Recommendations*. 2021, <http://www.tbcontrollers.org/resources/tb-infection/clinical-recommendations/>.
- *Tuberculosis Screening, Testing, and Treatment of U.S. Health Care Personnel: Recommendations from the NTCA and CDC, 2019*, https://www.cdc.gov/mmwr/volumes/68/wr/mm6819a3.htm?s_cid=mm6819a3_w

TB Resources

- *TB 101 for Health Care Workers*, <https://www.cdc.gov/tb/webcourses/TB101/intro.html>
- *CDC Drug susceptibility testing*, https://www.cdc.gov/tb/topic/laboratory/drug_testing.htm
- *Report of Expert Consultations on Rapid Molecular Testing to Detect Drug-Resistant Tuberculosis in the United States*,
<https://www.cdc.gov/tb/topic/laboratory/rapidmoleculartesting/default.htm>
- *USPSTF, Latent Tuberculosis Infection: Screening*,
<https://www.uspreventiveservicestaskforce.org/uspstf/recommendation/latent-tuberculosis-infection-screening>
- *Resources for TB Screening and Testing of Health Care Personnel*,
<https://www.cdc.gov/tb/topic/infectioncontrol/healthCarePersonnel-resources.htm>
- *Implementing an Electronic Directly Observed Therapy (eDOT) Program: A Toolkit for Tuberculosis (TB) Programs*, <https://www.cdc.gov/tb/publications/pdf/TBeDOTToolkit.pdf>