

ISOLATION OF *PITHOMYCES CHARTARUM* FROM ITALIAN FLOCKS AFFECTED BY FACIAL ECZEMA

¹Agnetti F., ²Garaguso M., ³Moretta I., ⁴Danesi P., ³Moretti A., ⁵Rodolfi M.

¹Istituto Zooprofilattico Sperimentale Umbria Marche (State Veterinary Institute), Villa Fastiggi - Pesaro, Italy

²Provincial Farmers Association, Potenza, Italy

³Dep. of Biopathological Science and Hygiene for Food and Animal Productions, Perugia, Italy

⁴State Veterinary Institute, Legnaro (PD), Italy

⁵Dep. of Territorial Ecology, Pavia, Italy

Introduction and Objectives

Facial eczema (FE) is a disease typically spread among ruminants raised in tropical/subtropical areas, caused by *Pithomyces chartarum* (Berk & Curtis) Ellis, a micro fungus Ascomycota able to colonize different plant substrates and, in particular, the basal regions of cereals. The species typically produces spores rich in toxins, which spread through wind and rain, making toxic pastures (Domsch *et al.*, 1980, Comp. of soil fungi, Acad. Press, London, 657-59; Cabras *et al.*, 2004, Chim. degli Alimenti, Piccin, 683-84). Sporidesmin A is the toxin mainly produced by *P. chartarum*, responsible for liver damages and skin photosensitivity (Nicoletti *et al.*, 2000, Il Tabacco, 3, 44). The disease is described especially in sheep of Latin America, Australia and New Zealand (Di Menna *et al.*, 1973, N.Z. J. Agr. Res., 16, 343-51; Fitzgerald *et al.*, 1997, Lett. in Appl. Micr., 26, 17-21; Collin *et al.*, 1998, Myc. Res., 102, 163-66); in Europe, the first case of facial eczema in Dutch cattle is reported by van Wuijckhuise *et al.* (2006, 131(23), 858-61). Aim of this paper is the description of the *P. chartarum* infection in some flocks reared in Southern Italy.

Methods

Flocks of Italian Merinizzata race, reared in Potenza province (Southern Italy) were affected by numerous cases of FE (Figure 1). Sheep were kept outside all the year and fed with forage. Those with skin lesions were adult and represented about the 40% of the flock. Samples of faeces and forage were collected, in order to perform mycological investigation; faeces were sown, by direct print and after dilution in saline solution, on Sabouraud dextrose agar, incubated at 24±1°C in aerobiosis and daily observed to notice macro-and microscopic characteristics of the resulting mycelia. Forage specimens were analyzed by means of the moist chamber method, maintained at room temperature and daily checked for evidence fungal growth.

Results

Mycological analysis of the faeces allowed to notice fast-growing colonies (5cm in 8 days at 24°C), with cottony texture, color from white to gray-brown after sporulation (Figure 2). Microscopic examination of them showed the presence of septate hyphae, short conidiophores and single, multicellular, ovoid conidia (18-29x10-17µm), more or less intensely pigmented, with rough surface, usually restricted at the transverse septa (Figure 3). Moreover, after 5 days of moist chamber, similar conidiophores and conidia directly developed from grazed pasture samples (8-12% of colonization frequency).

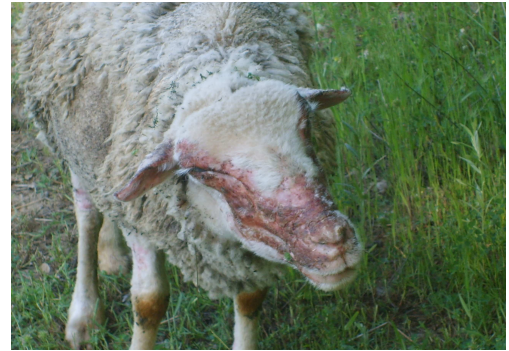

Figure 1. Sheep affected by Facial Eczema

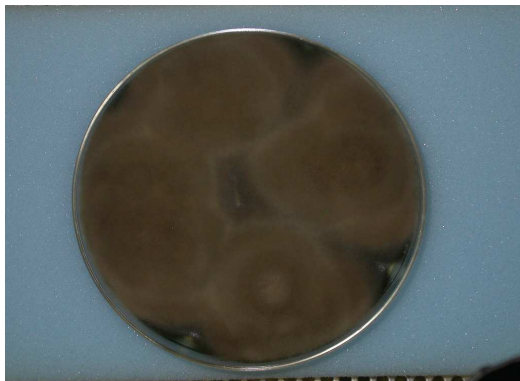

Figure 2. Colonies of *P. chartarum* on Sabouraud dextrose agar, after 10 days of incubation

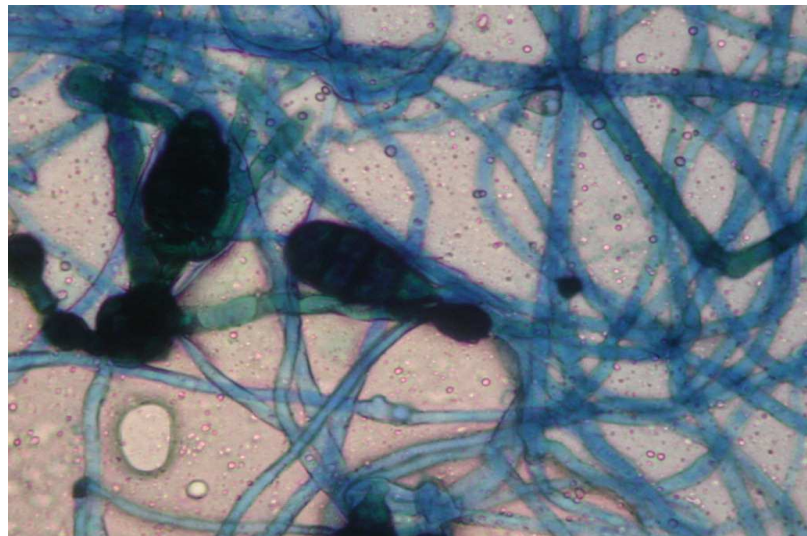


Figure 3. Microscopical picture of *P. chartarum*: septate hyphae and ovoid conidia (40X)

Discussion and Conclusions

The macro- and microscopic characteristics of the colonies collected in vitro confirmed their belonging to the species *P. chartarum*. Results obtained contribute to identify the presence of *P. chartarum* in Southern Italy, recognizing it as the main responsible for FE in sheep.

Moreover, the shearing of the flock, its admission to the stable (protected from sunlight) and administration of dried fodder for at least two months, have progressively reduced the clinical picture (Figure 4).

Further investigations, concerning other Italian ruminants and forages, will be needed to detect the fungus in different geographical and zootechnical contexts of our Country.

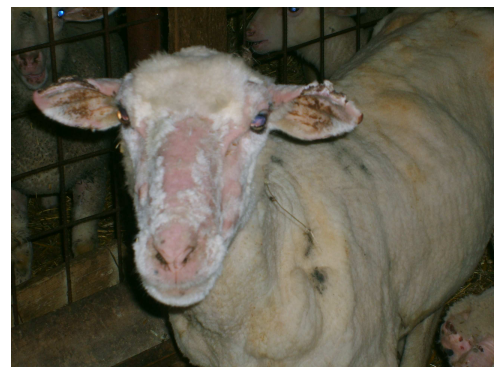

Figure 4. Clinical picture after two months of indoor farming