

Keratolytic acanthoma of the penile shaft

Sivaraman V.

Assistant Professor, Department of Dermatology, Indira Gandhi Medical College and Research Institute, kathirkamam-605009, Pondicherry, INDIA.

Email: skinsiva@gmail.com

Abstract

Epidermolytic acanthoma (EA), histologically characterised by the presence of “epidermolytic hyperkeratosis” (EH), is a rare acquired, benign cutaneous disorder. Usually it occurs as a solitary papillomatous lesion in early adulthood. The exact aetiology is not known. Few cases have been reported in the literature, we report a case of EA with unusual presentation over the male external genitalia.

Address for Correspondence

Dr. Sivaraman V Assistant Professor, No.16, First main road, Shanthi Nagar, Pondicherry-605013, INDIA.

Email: skinsiva@gmail.com

Received Date: 12/06/2014 Accepted Date: 25/06/2014

Access this article online

Quick Response Code:



Website:

www.statperson.com

DOI: 02 July 2014

CASE REPORT

A fourty year's old male was referred from Community Health Centre to our Dermatology Department with history of asymptomatic growths over the external genitalia for evaluation and to rule out the possibility of sexually transmitted disease. There was no history of extra marital sexual exposure. His family history was non contributory. Cutaneous examination revealed four discrete, contiguous skin coloured verrucous nodules of various sizes over the ventral aspect of the penile shaft (figure 1). The rest of the skin and systemic examination were normal. The differential diagnosis considered were condyloma acuminata and verrucae of the penis. Routine hematological and biochemical tests were normal. Blood VDRL, TPHA, ELISA for HIV 1 & 2, HbsAg and anti HCV antibodies were negative. Patient was referred to the surgeon for excision and the biopsy materials were sent for histopathological examination. Apart from compact hyperkeratosis and focal acanthosis, light microscopic examination of the skin biopsy specimen revealed the characteristic perinuclear clear cell changes

in the upper stratum spinosum and granular layer (figure 2). Based on the clinicopathological correlation final diagnosis of epidermolytic acanthosis was arrived.

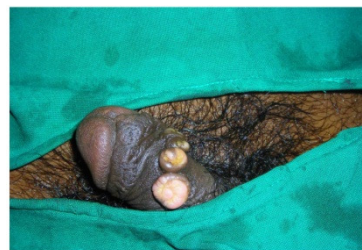

Figure 1: Discrete, Contiguous skin coloured verrucous nodule

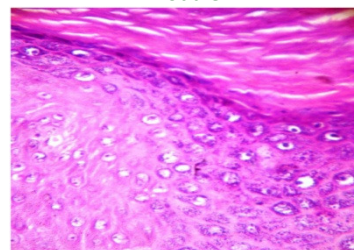


Figure 2: Perinuclear clear cell change in the upper stratum spinosum and granular layer with keratohyaline granules. (H and E x 400)

DISCUSSION

Epidermolytic acanthoma (EA) is a rare, acquired benign tumor of the epidermis, mainly characterised histopathologically by a prominent epidermolytic degeneration of the keratinocytes (Epidermolytic Hyperkeratosis). It was first described in 1970 by Sharpio and Baraf et al¹. It usually appears at or after

middle age, and has been reported in various locations including the face, abdomen², trunk, extremities² and external genitalia^{3,4}. EA usually present as asymptomatic tumor less than 1 cm in diameter with verrucous surface. Lesion can present in either an isolated solitary, localised or disseminated form with more predilection for the genitoscrotal area. Regarding pathogenesis of EA, many hypothesis including mutation in K-1 and K-10 gene has been postulated⁵, but none validated. Many attempts failed to demonstrate human papilloma virus DNA from the biopsy material of the EA⁶. In majority of reports, EA of the external genitalia are solitary and rarely seen. We report the first case, to our knowledge, of a multiple EA over the penile shaft. EA confined to the external genitalia is an under diagnosed entity and it should be considered as a differential diagnosis in asymptomatic, warty, discrete nodular lesions over the external genitalia. Various treatment options have been proposed including excision, cryotherapy, and electrocauterization. Our

patient effectively underwent local excision and the post operative period was uneventful.

REFERENCES

1. Shapiro L, Baraf CS. Isolated epidermolytic acanthoma. *Arch Dermatol* 1970; 101 : 220-3
2. Metzler G, Sonnichsen K. Disseminated epidermolytic acanthoma *Hantarzt* 1997; 48 : 740-2
3. Quinn TR, Young RH, Epidermolytic hyperkeratosis in the lower genital tract: An uncommon simulant of mucocutaneous papilloma virus infection – a report of two cases. *Int. J. Gynecol Pathol* 1997 ; 16: 163-8
4. De Coninck A, Willemsen M, De Dobbeleer G, Roseeuw D. Vulvar localisation of epidermolytic acanthoma. A light and electron microscopic study. *Dermatologica* 1986; 172 : 276-8
5. Thomas M, Geogre R, Thomas M. Linear epidermolytic acanthoma of vulva : An unusual presentation : *Indian J Dermatol venereol Leprol* 2010 ; 76 : 49-51
6. Leonardi C, Zhu W, Kinsey W, Penneya NS, Epidermolytic acanthoma does not contain human papilloma virus DNA. *J Cutan Pathol* 1991 ; 18 :103-5

Source of Support: None Declared
Conflict of Interest: None Declared