

Developmental Dysplasia of the Hip

- Definition, 513
- History, 513
- Incidence, 514
- Etiology, 514
- Associated Conditions, 517
- Pathophysiology, 519
- Natural History, 522
- Clinical Presentation, 524
- Imaging Studies, 527
- Screening Criteria, 534

- Treatment of the Neonate, 534
- Treatment of the Young Child (Ages 1 to 6 Months), 536
- Treatment of the Child (Ages 6 Months to 2 Years), 539
- Treatment of the Older Child (Ages 2 Years and Older), 568
- Complications and Pitfalls, 582
- Reconstructive Procedures for Dysplasia, 596
- Teratologic Dislocation of the Hip, 646

Definition

Developmental dysplasia of the hip (DDH) is a spectrum of disorders of development of the hip that present in different forms at different ages. The common etiology is excessive laxity of the hip capsule, which fails to maintain the femoral head within the acetabulum. The syndrome in the newborn consists of instability of the hip, such that the femoral head can be displaced partially (subluxated) or fully (dislocated) from the acetabulum by an examiner. The hip may also rest in a dislocated position and be reducible on examination. Over time, the femoral head becomes fully dislocated and cannot be reduced by changing the position of the hip. The syndrome may manifest later in childhood or adolescence as a dislocated hip, or in adolescence as a hip with a poorly developed acetabular coverage; the latter is termed dysplasia of the hip.

DDH is a disorder that evolves over time. The structures that make up the hip are normal during embryogenesis and gradually become abnormal for a variety of reasons, chiefly fetal position and presentation at birth (malposition of the femoral head, abnormal forces acting on the developing hip) and laxity of the ligamentous structures about the hip joint.

The older term *congenital dislocation of the hip* has gradually been replaced by *developmental dysplasia*, which was introduced in the 1980s to include in the disorder infants normal at birth but in whom hip dysplasia or dislocation subsequently developed.³⁷ Klisic in 1989 recommended use of the term “developmental displacement of the hip” to indicate “a dynamic disorder potentially capable of getting better or worse as the child develops . . . depending on the multidisciplinary care provided by paediatricians, obstetricians, orthopaedic surgeons, general practitioners, and

nurses.”¹⁰³ The abbreviation DDH has been used to denote both dislocation and dysplasia of the hip, and will be used in both senses in this chapter. *Dislocation* is defined as complete displacement of a joint, with no contact between the original articular surfaces. Subluxation is defined as displacement of a joint with some contact remaining between the articular surfaces. *Dysplasia* refers to deficient development of the acetabulum.

Teratologic dislocation of the hip is a distinct form of hip dislocation that usually occurs with other disorders. These hips are dislocated before birth, have limited range of motion, and are not reducible on examination. Teratologic dislocation of the hip is usually associated with other neuromuscular syndromes, especially those related to muscle paralysis, such as myelodysplasia and arthrogryposis. The pathology, natural history, and management of teratologic dislocation will be discussed separately.

History

In 1832, Guillaume Dupuytren described the condition of dislocation of the hip at birth and termed it “original or congenital dislocation of the hip.”⁴⁴ He noted foreshortening of the thigh, lack of abduction, muscle wasting, apparent widening of the pelvis, and prominence of the greater trochanters. He also recognized the increased lumbar lordosis and gave a lucid description of the abductor lurch: “In walking, persons thus deformed step on the points of the feet, alternately inclining the trunk very much towards the limb on which the weight of the body is thrown. . . . The toilsome nature of these efforts in progression [is] clearly due to the instability of the heads of the thigh-bones.”




FIGURE 15-1 Adolph Lorenz, an early pioneer in the treatment of developmental dislocation of the hip. (From Lorenz A: *My Life and Work*. New York, Charles Scribner & Sons, 1936.)

Adolph Lorenz, professor of surgery at the University of Vienna at the turn of the century, traveled extensively and demonstrated his vigorous techniques of closed reduction of the hip.¹³⁰ Because his reductions were so forceful, he has been called the “father of avascular necrosis” (Fig. 15-1).

In 1927 Putti pointed out the advantages of early treatment of hip dislocations and claimed perfect results in more than 90 percent of hips when treatment was started before the patient was a year old.¹⁶⁷ In 1935 Ortolani, another person famously associated with hip dislocation, made an astute observation. He saw a 5-month-old baby whose mother had noted a “click” every time she washed the baby’s bottom. The woman showed Ortolani how to reproduce it, and he found that the baby had a dislocated hip when he took a radiograph. He published this experience in 1937 in an article entitled “A Very Little Known Sign and Its Importance in the Early Diagnosis of Congenital Hip Redirection.”¹⁵⁸ The term he used was *segno del scotto*, which translates as a movement or a clunk. In 1946 the Italian government opened a Center for the Diagnosis, Prophylaxis and Treatment of Congenital Dysplasia of the Hip.

Incidence

The incidence of DDH is difficult to determine because of disparities in the definition of the condition, the type of examinations used to detect hip abnormalities, the differing skill levels of examiners, and the populations being studied. Estimates of the incidence of some degree of hip instability in the newborn have ranged from a low of 1 per 1,000 to

a high of 3.4 per 100. Higher incidences are reported when screening employs both clinical examination and ultrasound.¹⁷⁶ In a study in which pediatricians examined 11,868 newborns, one in 50 babies were found to have some clinical finding associated with DDH, ranging from minor clicks to true instability based on Ortolani’s sign.⁷⁸ In contrast, Gross and associates screened 10,170 newborns and found only three to four dislocatable hips per 1,000 babies screened.⁶⁷

The data on the incidence of actual dislocation of the hip are more consistent, with reports ranging from 1.0 to 1.5 cases per 1,000 live births.^{8,30,51,52,89,227,239} Severin estimated an incidence of 0.09 percent true dislocations in Sweden.¹⁸⁸ Carter and Wilkinson reported an overall incidence of one per 1,000 live births, with one in 600 females and one in 4,000 males having the disorder.²⁵ In a subsequent study, Wilkinson found the incidence in females was 1.1 per 1,000 live births, while in males it was 0.12 per 1,000 live births.²⁴⁵

There is marked geographic and racial variation in the incidence of DDH. Some areas of the world have a high endemic incidence and in other areas the condition is virtually nonexistent. The reported incidence based on geography ranges from 1.7 per 1,000 babies in Sweden¹⁷⁵ to 75 per 1,000 in Yugoslavia¹⁰⁴ to 188.5 per 1,000 in a district in Manitoba, Canada (Table 15-1).²²⁸ Certain racial groups have a low incidence of DDH. An examination of 16,000 African Bantu babies uncovered no cases of DDH,⁴⁶ and the rate among Chinese children in Hong Kong was only 0.1 case per 1,000.⁷⁹ Other groups have a high incidence, such as a group of Navajo Indian children in which one in 50 had DDH.³²

Etiology

Although there is no single cause of DDH, a number of predisposing factors have been identified. These factors include ligamentous laxity, prenatal positioning, postnatal positioning, and racial predilection. The etiology of DDH clearly is multifactorial and is influenced by hormonal and genetic elements.

Ligamentous laxity is related to DDH in several ways. The condition is associated with the development of DDH when

TABLE 15-1 Incidence of Developmental Dysplasia of the Hip

Study, Year	Geographic Area: Population	Incidence per Thousand
Walker, 1973	Island Lake Region (Manitoba, Canada): Canadian Indians	188.5
Klasic, 1975	Belgrade, Yugoslavia	75.1
Coleman, 1956	Utah	20.0
Hiertonn and James, 1968	Adademiska Sjulchuset, Uppsala, Sweden	20.0
Stanisavljevic, 1961	Detroit, Michigan	10.0
Paterson, 1976	Adelaide, Australia	6.2
Von Rosen, 1962	Malmö, Sweden	1.7
Barlow, 1962	Salford, England	1.5
Hoaglund et al., 1981	Hong Kong: Chinese	0.1
Edelestein, 1966	Africa: Bantus	0.0

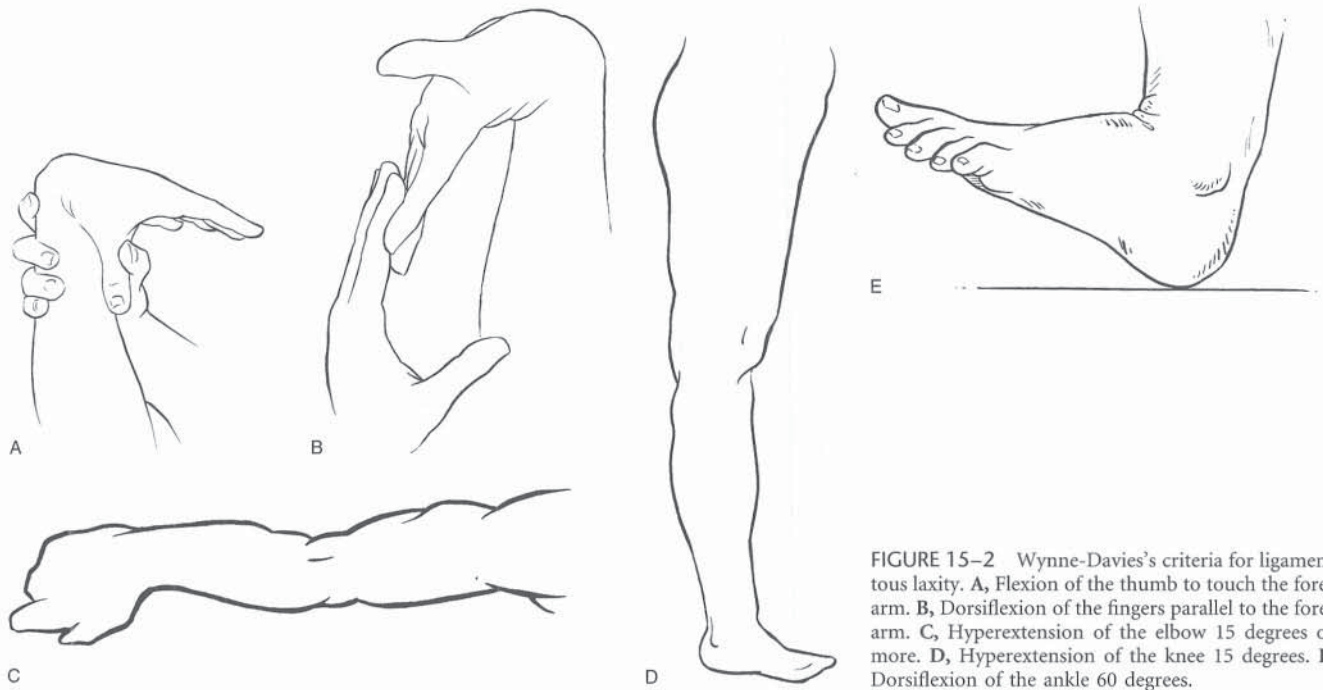


FIGURE 15-2 Wynne-Davies's criteria for ligamentous laxity. A, Flexion of the thumb to touch the forearm. B, Dorsiflexion of the fingers parallel to the forearm. C, Hyperextension of the elbow 15 degrees or more. D, Hyperextension of the knee 15 degrees. E, Dorsiflexion of the ankle 60 degrees.

laxity is a familial trait. In fact, the racial incidence of laxity may parallel racial predilections for DDH. The newborn's response to maternal relaxin hormones may explain the higher incidence of DDH in females. These hormones, which produce ligamentous laxity necessary for expansion of the maternal pelvis, cross the placenta and induce laxity in the infant. This effect is much stronger in female offspring than in males.

In an extensive genetic study of DDH, Wynne-Davies in 1970 proposed that hereditary ligamentous laxity was one of two major mechanisms for the inheritance of DDH (Fig. 15-2).²⁴⁸ She believed this was an autosomal dominant characteristic with incomplete penetrance. The fact that the risk of DDH is 34 percent in identical twins (i.e., both twins having DDH) but only 3 percent in fraternal twins also suggests a genetic influence.⁶² In Coleman's study of Navajo families, hip dysplasia in one family member increased the risk for other family members five times.³² Newborns with DDH have also been found to have a higher ratio of collagen III to collagen I than controls, suggesting a connective tissue abnormality in those with DDH.⁸⁸ In a study of laxity by distraction of the symphysis pubis, babies with DDH had twice the amount of distraction of the symphysis as controls.³

Several animal studies are relevant to the issue of laxity of the hip capsule. When the hip capsule and ligamentum teres were removed from dogs, the animals frequently developed dislocated hips.¹⁹¹ Dislocation would also result if the capsule was mechanically stretched but not removed. Removal of the acetabular roof, on the other hand, did not result in hip dislocation but only a shallower acetabulum than normal. In a classic study in male and female newborn rabbits, only the female rabbit hips dislocated when the knees were splinted in extension, an observation supporting the concept of hormonally induced laxity.²⁴⁵

Prenatal positioning is strongly associated with DDH. Although only 2 to 3 percent of babies are born in breech

presentation, Muller and Seddon found that 16 percent of babies with DDH were born in breech presentation.¹⁵⁰ Neonates that have been carried in certain breech positions have a significantly higher risk of DDH (Fig. 15-3). The breech effect is most notable when the knees are extended, with an incidence of 20 percent for a single or frank breech.²⁰⁵ On the other hand, the footling breech position, in which the hips are flexed, is associated with only a 2 percent incidence of DDH. Artz and associates reported a 7.1 percent incidence of unstable hips in female children born in breech presentation.⁴

Experimental studies in which newborn rabbits' knees were splinted in extension showed a high incidence of hip dislocation (Fig. 15-4).¹⁴⁰ If in the same rabbits the ham-

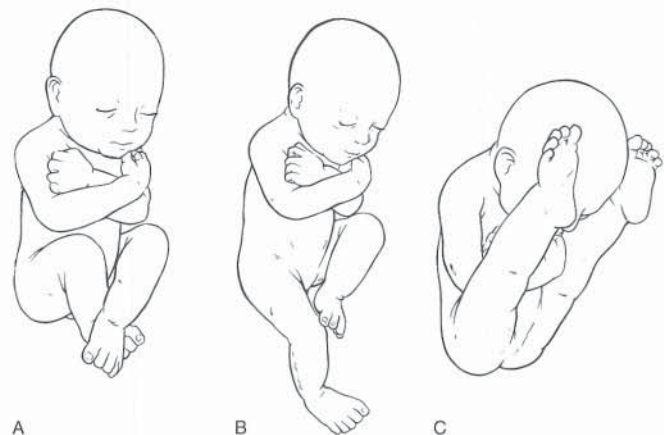


FIGURE 15-3 The breech position, associated with DDH. A, A double breech position is associated with a low incidence of DDH. B, A single footling breech is associated with a 2 percent risk of DDH. C, A frank breech, especially with the knee(s) extended, is associated with a 20 percent risk of DDH.

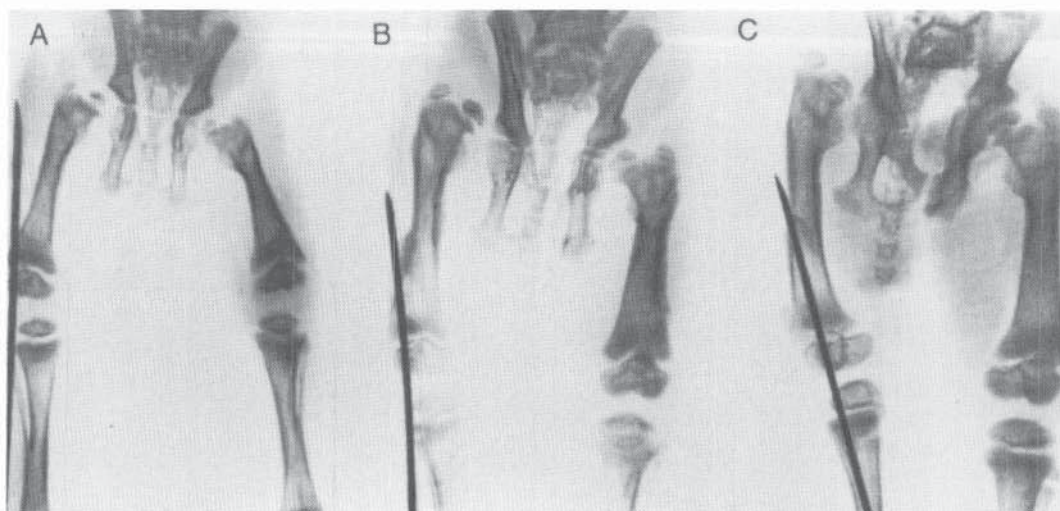


FIGURE 15-4 DDH produced in a rabbit by forced knee extension. A, Five days after fixed knee extension there is subluxation of the right hip. B, Fifteen days of knee extension has produced dislocation of the right hip. C, Twenty-one days postoperatively the hip remains dislocated. (From Michelsson J-E, Langenskiöld A: Dislocation or subluxation of the hip: regular sequela of immobilization of the knee in extension in young rabbits. *J Bone Joint Surg* 1972;54-A:1177.)

string tendons were transected, however, the hips did not dislocate, suggesting that the pull of the hamstrings across the flexed hip was the dislocating factor. The hip is affected by intrauterine position, and delivery by caesarean section does not alter the likelihood of hip dislocation.⁴³ The incidence of DDH is also higher in first-born children and in pregnancies complicated by oligohydramnios.^{25,41,43} These findings suggest that there is an intrauterine crowding effect on the developing hip. This argument is bolstered by the

increased incidence of other postural abnormalities (torticollis, metatarsus adductus) in children with DDH. Also, the left hip is more often involved than the right. Because the most common intrauterine position has the left hip adducted against the maternal sacrum (Fig. 15-5), some authors believe that this position places the left hip at greater risk for dislocation than the right hip.^{41,43}

Postnatal positioning is another factor associated with DDH. People who wrap their newborn babies in a hip-

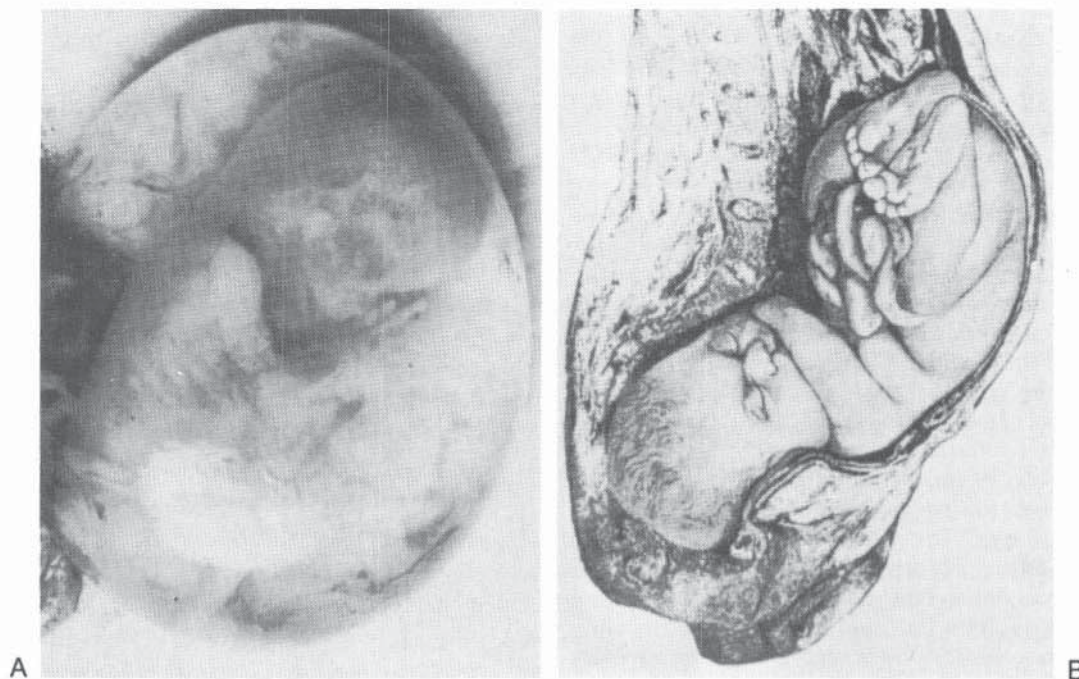


FIGURE 15-5 The importance of amniotic fluid in protecting the fetus from pressure. A, A fetus of 13 weeks' gestation lying within amniotic sac removed at hysterectomy. The fragile fetus is completely protected from mechanical pressure by the abdominal musculature. B, Frozen sagittal section of abdomen of a pregnant woman who died during labor. The fetus is flexed laterally around the sacral promontory. (From Dunn PM: Perinatal observations on the etiology of congenital dislocation of the hip. *Clin Orthop* 1976;119:13.)

extended position, such as Native Americans who use cradleboards (Fig. 15-6), have a much higher incidence of DDH than other populations.^{32,116,169} The mechanism of action is believed to be placement of the hips in full extension against the normal neonatal hip flexion contracture. In contrast, people that usually carry their babies astride the hip or in a wrap that flexes and abducts the hips have a lower incidence of DDH than other groups.²⁵ Postnatal positioning programs have been considered. In one in which new parents were given a set of “abduction pants” and wide diapers, a 65 percent decrease in the incidence of DDH was noted, an outcome attributed to the program.¹⁰⁷

Primary failure of acetabular development has been proposed as a cause of DDH. Early cadaver studies noted that the acetabulum was more shallow at birth than in the earlier fetal period.^{118,179} Morville showed that the neonatal acetabulum was shallow and that full coverage of the femoral head did not occur until the child was about 3 years old.¹⁴⁸ Ralis and McKibbin dissected 44 hips of various ages and demonstrated that the embryonic acetabulum is a deeply set cavity that becomes more shallow as the fetus approaches full term.¹⁷⁰ After birth, the acetabulum again becomes deeper throughout childhood and eventually covers the head completely. Other authors, however, have rejected the primary acetabular dysplasia hypothesis.^{42,117}

Finally, *racial predilection* apparently plays a role, since certain ethnic groups seem to be predisposed to DDH while others appear somewhat immune. Blacks and Asians have relatively low incidences of DDH, while Caucasians and Native Americans have a higher incidence. As noted earlier in the discussion of the incidence of DDH, Edlestein studied 16,000 black African Bantu babies and failed to find a single case of DDH.⁴⁶ The incidence in Chinese babies has been reported to be only 0.1 per 1,000 in Hong Kong.⁷⁹ Artz and associates found the incidence of hip dislocation to be 4.9

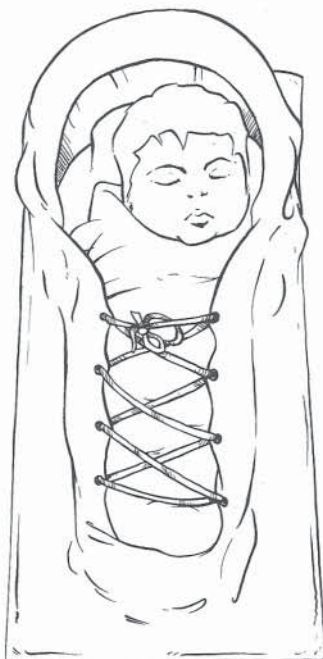

FIGURE 15-6 Postnatal positioning in extension, as in this child on a Native American cradle board, contributes to DDH.

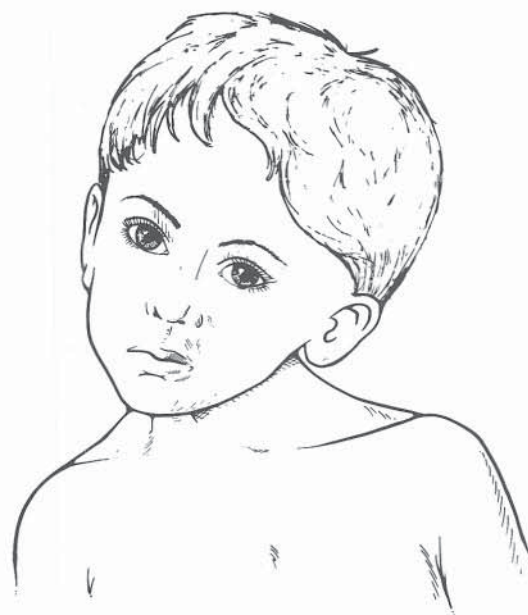


FIGURE 15-7 Torticollis should alert the examiner to the possibility of DDH, because up to 15 percent of babies with torticollis have hip instability.

per 1,000 in blacks, compared with 15.5 per 1,000 in Caucasians.⁴

Associated Conditions

Certain conditions, particularly postural abnormalities, are associated with DDH more commonly than chance alone would dictate. The association of DDH with torticollis is quite strong (Fig. 15-7). In a child with torticollis, the likelihood of also having DDH ranges from 14 to 20 percent, an occurrence thought to be due to intrauterine crowding.^{81,86} A relationship has also been noted between DDH and metatarsus adductus (Fig. 15-8), with the inci-

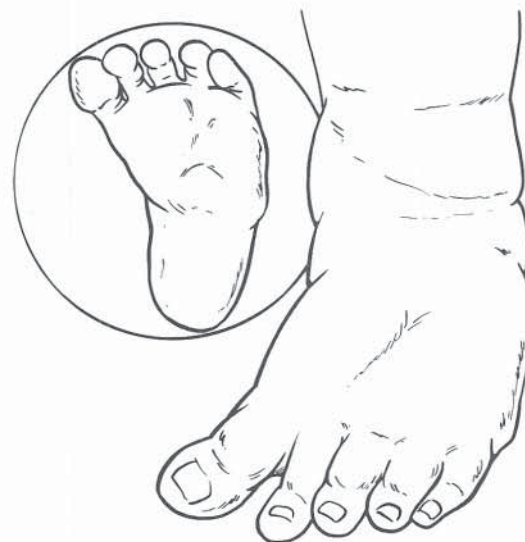

FIGURE 15-8 There is an association between metatarsus adductus and DDH: up to 10 percent of babies with metatarsus adductus have DDH.

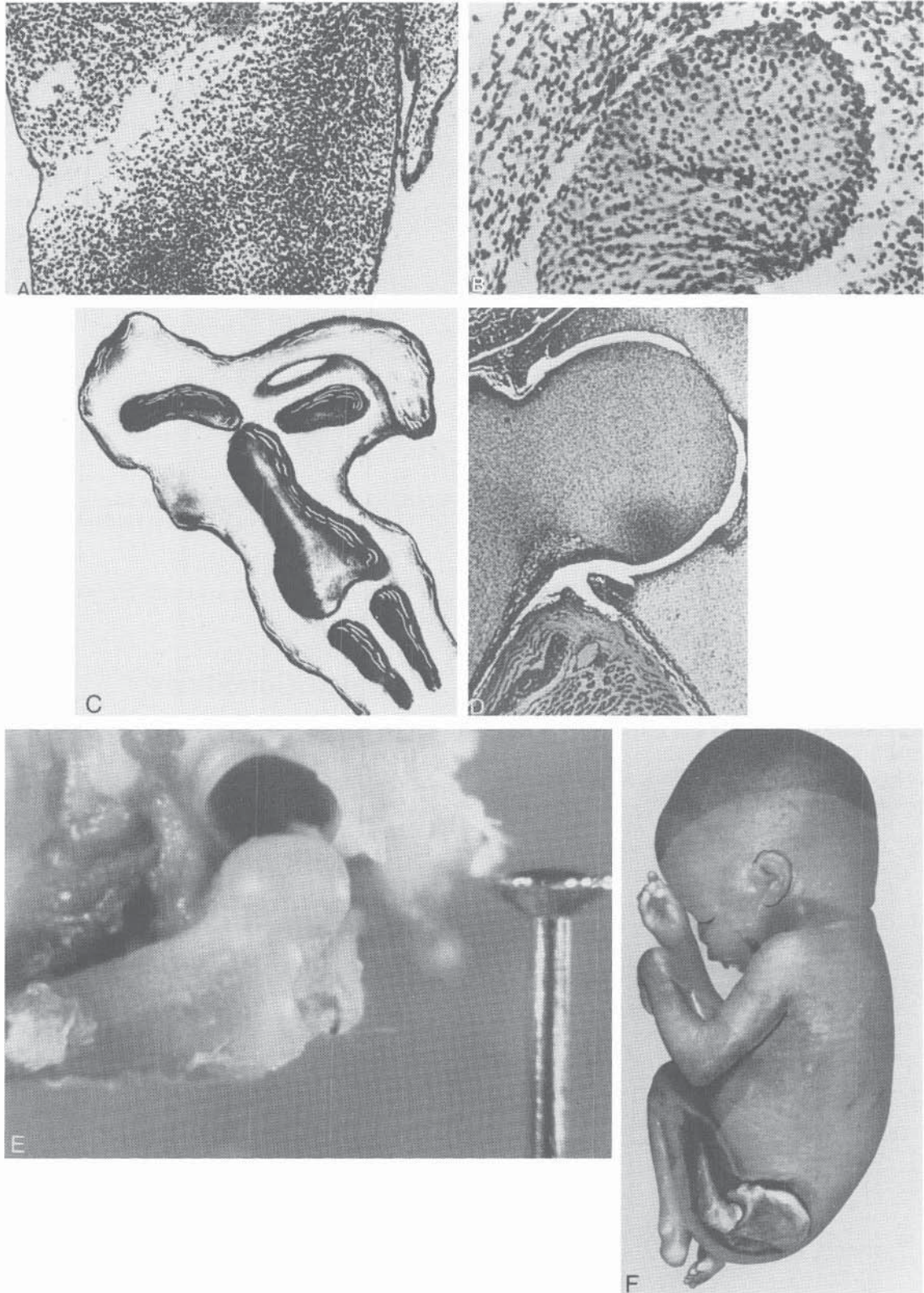


FIGURE 15-9 Embryology of the hip joint. **A**, The highly cellular blastema in the proximal and central portion of the limb bud will later form the cartilage model of the hip joint. **B**, At 8 weeks, the cartilage model of the acetabulum and femoral head has begun to form. **C**, The femur forms in the shape of a truncated cone. The disk-shaped masses mark the development of the anlagen of the ilium, ischium, and pubis. **D** and **E**, Note the spherical configuration of the femoral head and acetabulum. The limbus and transverse acetabular ligament are well-formed structures. **F**, At 16 weeks of fetal life (100 mm), the lower limbs are positioned in flexion, adduction, and lateral rotation. (From Watanabe RS: Embryology of the human hip. *Clin Orthop* 1974;98:8.)

dence of co-occurrence ranging from 1.5 to 10 percent.^{83,112} Pregnancies complicated by oligohydramnios have been associated with an increased incidence of DDH.^{41,43} First-born Caucasian infants have an increased incidence of DDH.^{2,5,6,24,25,43}

Pathophysiology

NORMAL HIP DEVELOPMENT

The hip joint begins to develop at about the seventh week of gestation, when a cleft appears in the mesenchyme of the primitive limb bud (Fig. 15–9). These precartilaginous cells differentiate into a fully formed cartilaginous femoral head and acetabulum by the 11th week of gestation.^{200,201,230} If there is a failure in normal embryogenesis of the hip, the consequence is a major anomaly such as proximal femoral focal deficiency.⁵⁴

At birth, the neonatal acetabulum is completely composed of cartilage, with a thin rim of fibrocartilage called the labrum (Fig. 15–10). The hyaline cartilage of the acetabulum is continuous with the triradiate cartilages, which divide and interconnect the three osseous components of the pelvis (the ilium, ischium, and pubis). The surface of the acetabular cartilage, which abuts the bone of the pelvis, is made up of epiphyseal cartilage in the shape of a hemisphere and functions as a major growth plate. Growth of this physis is essential for acetabular development, and any damage to the periacetabular area may induce a growth disturbance.^{73,164,165} The limbus also contributes significantly to the development of acetabular depth; consequently, any excision of the limbus during the treatment of DDH is ill-advised.

The proximal femur has a complex and often misunderstood growth pattern. In the neonate, the entire upper femur is a cartilaginous structure in the shape of a femoral head and

greater and lesser trochanters. Development of the proximal segment of the femur occurs through a combination of appositional growth on the surfaces of the upper femur and epiphyseal growth at the juncture of the cartilaginous upper femur and the femoral shaft.¹⁸⁹ In the normal femur, an ossification center appears in the center of the femoral head between the fourth and seventh months of postnatal life. This center grows until physeal closure in late adolescence, at which time it has become the adult femoral head, covered with a thin layer of articular cartilage. During the period of growth, the thickness of the cartilage surrounding this bony nucleus gradually decreases, as does the thickness of the acetabular cartilage. The thickness of the cartilage accounts for the widened radiographic appearance of a normal hip in a child.

As the child matures, three acetabular epiphyseal centers develop that are responsible for the final contours of the hip socket (Fig. 15–11). The os acetabulum, which is the largest of the three, appears at about 8 years of age and forms along the anterior wall as part of the pubis. The acetabular epiphysis, which also ossifies at around 8 years, forms along the superior edge of the acetabulum as part of the ilium and fuses at about 18 years. The third center is a small epiphysis in the posterior or ischial area, which develops at age 9 years and fuses at 17 years.

Excessive pressure on the cartilaginous upper femur can cause a loss of vascular perfusion, resulting in necrosis of the chondrocytes. Various portions of the femoral head and growth plate can be injured, with the resulting patterns of deformity corresponding to the areas of injury. The greater trochanteric area usually is unaffected and will continue to grow normally, gradually becoming more proximal than the femoral head. This “trochanteric overgrowth” is actually normal trochanteric growth in the face of upper femoral “undergrowth.”^{156,159,186}

Muscle imbalance can also significantly affect the growth and morphology of the upper femur. Excessive adductor

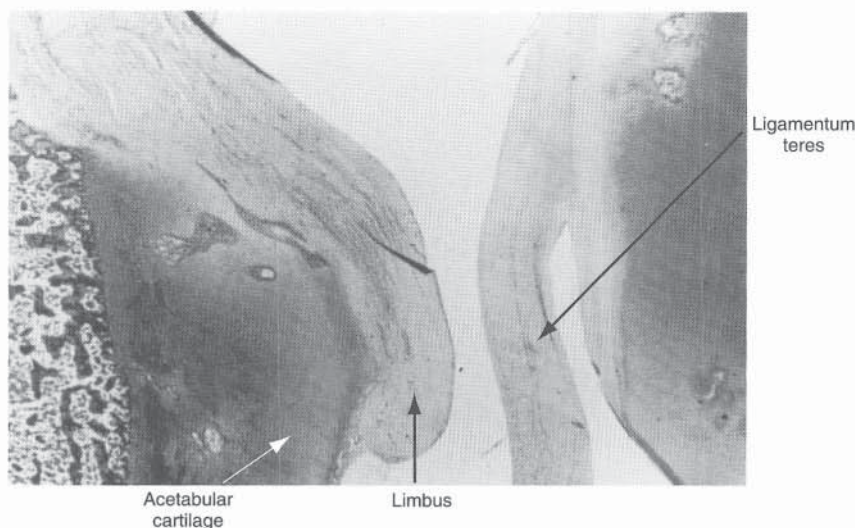


FIGURE 15–10 Photomicrograph of a limbus (hematoxylin-eosin, $\times 9$). Note the fibrous structure covering the cartilaginous labrum and projecting toward the true joint cavity. Distinct tissue planes are lacking. Small blood vessels are present in the different layers of the limbus. The femoral head and ligamentum teres are to the right of the illustration. (Courtesy of the Armed Forces Institute of Pathology, Bethesda, MD.)

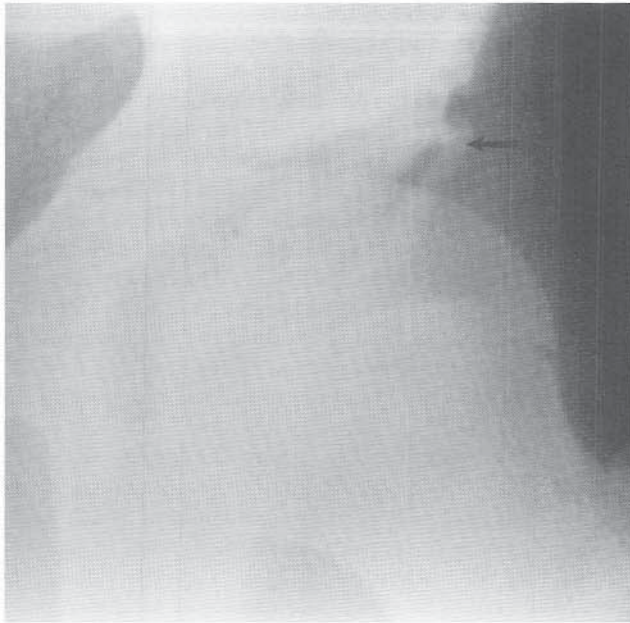


FIGURE 15-11 Acetabular epiphysis is seen as a ring of ossification along the lateral margin of the acetabular rim (arrow).

pull or inadequate abductor muscle function will result in a valgus deformity of the upper femur.^{56,159,186}

HIP DEVELOPMENT IN DDH

Developmental dislocation of the hip is a gradually progressive disorder associated with distinct anatomic changes, many of which are initially reversible. It is a malformation of anatomic structures that have developed normally during the embryologic period. Relatively gentle forces, persistently applied, probably are the cause of such deformations.⁴³ At

birth, the affected hip will spontaneously slide into and out of the acetabulum. For this to occur, the posterosuperior rim of the acetabulum has to have lost its sharp margin and become flattened and thickened in the area over which the femoral head slides (Fig. 15-12). As the head rides in and out of the socket, a ridge of thickened articular cartilage (termed the *neolimbus* by Ortolani) arises along the posterosuperior acetabular wall (Fig. 15-13). The sliding of the head in and out produces a clunk, or *scatto*, as Ortolani called it. The *neolimbus* is the structure that produces this feel as the head slides over it.^{156,157,164,165}

Some hips that are unstable at birth will spontaneously reduce and become normal, with complete resolution of the aforementioned anatomic changes. Other hips will eventually remain out of the socket permanently, and many secondary anatomic changes will take place gradually. The frequency of spontaneous reduction versus progressive dislocation is not known.

Those hips that remain dislocated develop secondary barriers to reduction. In the depths of the acetabulum, the fatty tissue known as the pulvinar thickens and may impede reduction (Fig. 15-14). The ligamentum teres also elongates and thickens, and may take up valuable space within the acetabulum. The transverse acetabular ligament is often hypertrophic as well, and may impede reduction.⁸⁴ More important, the inferior capsule of the hip assumes an hourglass shape, eventually presenting an opening smaller in diameter than the femoral head. The iliopsoas, which is pulled tight across this isthmus, contributes to this narrowing (Fig. 15-15). The capsule also narrows through a “Chinese finger-trap” mechanism.⁸⁴

When an attempt is made to reduce the hip against the narrowed hip capsule, the femoral head abuts the cartilaginous acetabular lip and tends to push this rim into the acetabulum. It is extremely important to realize that the acetabular structure is not impeding the femoral head from entering the acetabulum. Rather, the constricted hip capsule

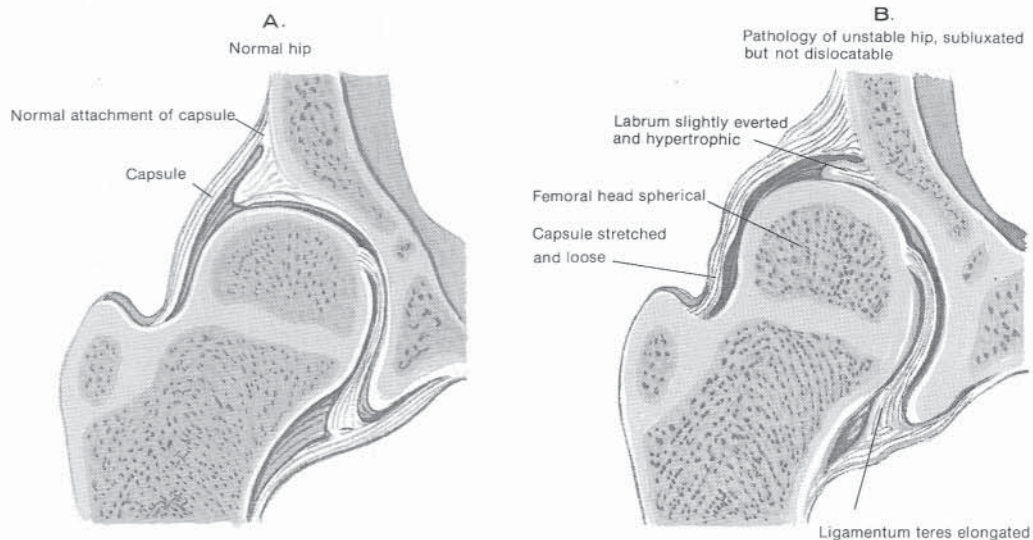


FIGURE 15-12 Pathology of the unstable hip that is subluxatable but not dislocatable. A, Normal hip; B, subluxatable hip. Note the loose hyperelastic capsule, elongated ligamentum teres, and slight eversion of the hypertrophied acetabular rim. The femoral head is normal in shape. Excessive femoral and acetabular antetorsion may be present, causing anatomic instability of the hip joint.

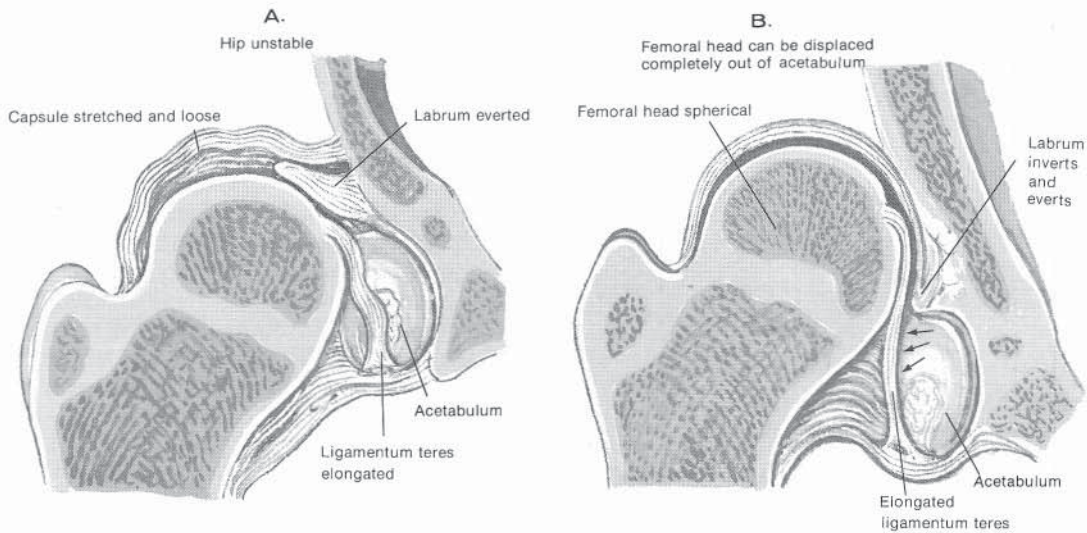


FIGURE 15-13 Pathology of the dislocatable hip. The capsule is stretched out and very loose. The ligamentum teres is markedly elongated. The labrum is definitely everted. At the fibrocartilage-hyaline junction of the labrum with the acetabulum, there may be inversion hypertrophic changes (neolimbus) (arrows). The femoral head is spherical. Acetabular antetorsion is usually excessive.

is forcing the head against the acetabular rim, and the capsule must be released or stretched to allow the head to move beneath the acetabular rim and enter the acetabulum. Clinicians often use the term *labrum* for this blocking structure, and sometimes excise it. However, the actual labrum is

a thin fibrocartilaginous rim around the periphery of the acetabular cartilage. The blocking structure encountered in DDH is not only the labrum but also a significant portion of the cartilaginous acetabulum itself. This vital cartilaginous acetabular anlage is essential for normal growth

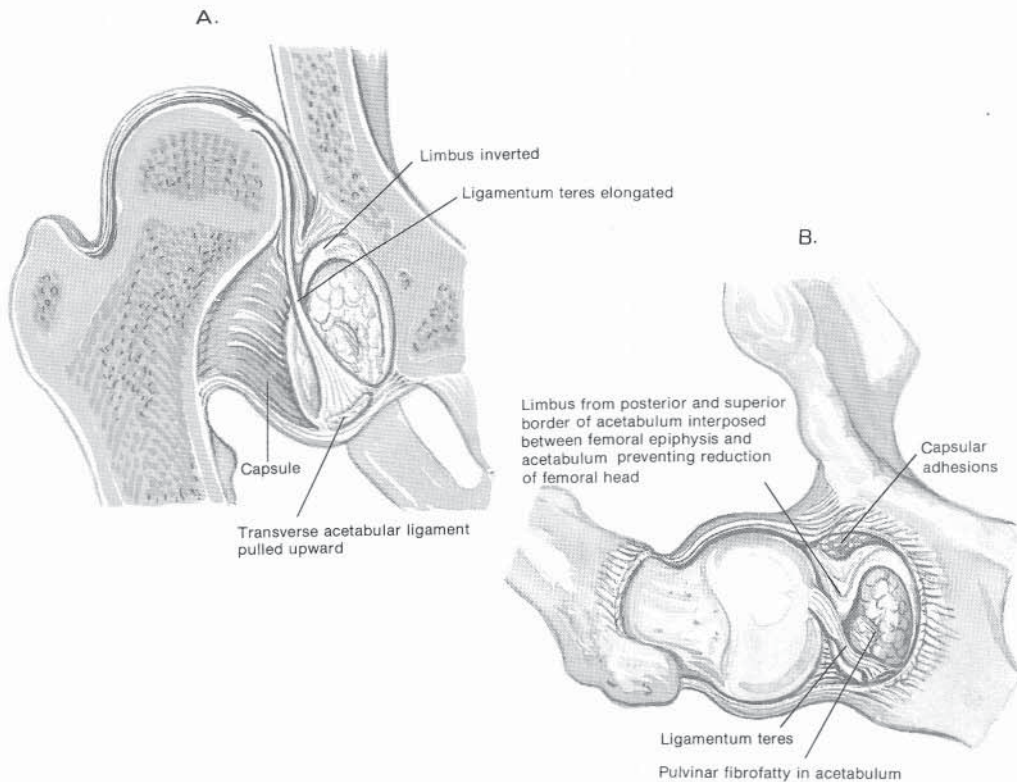


FIGURE 15-14 Pathology of the dislocated hip that is irreducible owing to intra-articular obstacles. **A**, The hip is dislocated. **B**, It cannot be reduced on flexion, abduction, or lateral rotation. Obstacles to reduction are inverted limbus, ligamentum teres, and fibrofatty pulvinar in the acetabulum. The transverse acetabular ligament is pulled upward with the ligamentum teres.

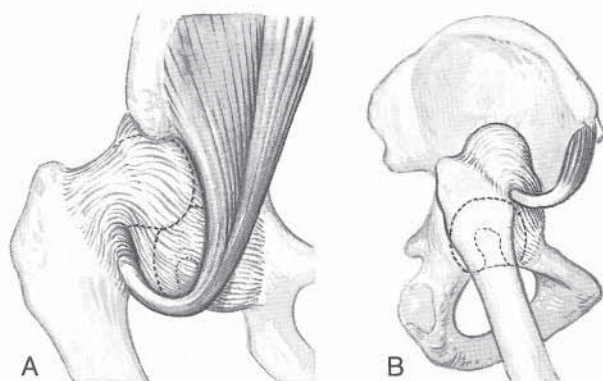


FIGURE 15-15 The iliopsoas tendon as an obstacle to closed reduction. **A**, Anterior view. The iliopsoas tendon traverses the anteromedial aspect of the hip joint before inserting into the lesser trochanter. With lateral and superior displacement of the femoral head and lesser trochanter, the iliopsoas tendon is stretched taut across the medial and anterior aspect of the hip capsule. **B**, Lateral view showing external pressure and indentation of the capsule by the iliopsoas tendon. This hourglass constriction of the capsule with formation of the capsular isthmus markedly reduces the diameter of the acetabular orifice and is a barrier to closed reduction.

and development of the acetabulum and should not be excised.

After the femoral head has been reduced, the acetabular rim may still impede deep seating of the femoral head because the rim has become thicker than normal. If the head is maintained within the acetabulum, this thickened cartilage will usually flatten out gradually and allow the head to seat deeply. Known clinically as “docking the head,” this phenomenon was described by Severin in 1941.¹⁸⁷ The femoral head itself is usually deformed into a globular shape from pressure against the lateral portion of the acetabulum and may not be congruous with the acetabulum at the time of reduction; however, this anatomic situation will also eventually resolve if reduction is maintained.⁸⁴

If the hip remains dislocated, additional changes occur in the growth and development of the acetabulum. The acetabular roof becomes progressively more oblique, the concavity gradually flattens and eventually presents a convex surface, and the medial wall of the acetabulum thickens. The acetabulum has been noted to be excessively antverted in DDH, providing diminished coverage of the femoral

head.^{119,131} In a recent study, three-dimensional reconstruction of magnetic resonance images (MRIs) of eight infants with untreated DDH showed medial twisting of the whole wing of the pelvis.²⁰³ Medial wall thickening is seen radiographically as a thickening and alteration of the shape of the teardrop body.

To a point, these changes are reversible, but the exact upper age at which hip reduction will result in normal acetabular development is uncertain. Harris suggested that a hip reduced by age 4 years could achieve “satisfactory” acetabular development. He found that significant acetabular growth continued through 8 years of age.⁷¹

In adults, the fully dislocated femoral head may lie well above the acetabular margin in a markedly thickened hip capsule, the so-called high-riding dislocation (Fig. 15-16). The adult dislocated femoral head is oval and flattened medially. The acetabulum is filled with fibrous tissue, and the articular cartilage is either atrophic or absent.¹⁴¹ The muscles that insert to the proximal femur are foreshortened and more horizontally oriented (Fig. 15-17). Fully dislocated adult hips may remain free from degenerative changes for many years, even for the individual’s lifetime.

In other cases of untreated hips, the femoral head retains some contact with the acetabulum. These subluxated hips have an unstable contact area that allows the head to slide proximally and distally against a widened, oblique acetabular surface. This instability produces degenerative changes that often become apparent in late adolescence and usually progress rapidly within a few years to severe degeneration. Late pathologic degenerative changes include subchondral sclerosis and cyst formation in the acetabulum and femoral head, osteophyte formation, and loss of articular cartilage. Reorientation of the acetabulum and redirection of the forces across the hip can ameliorate degenerative changes if the procedures are performed in the early stages of changes. With more severe degeneration, the process becomes irreversible.

Natural History

NEONATAL HIP INSTABILITY

The fate of the unstable hip remains an enigma. How often an unstable hip spontaneously reduces or, alternatively, be-

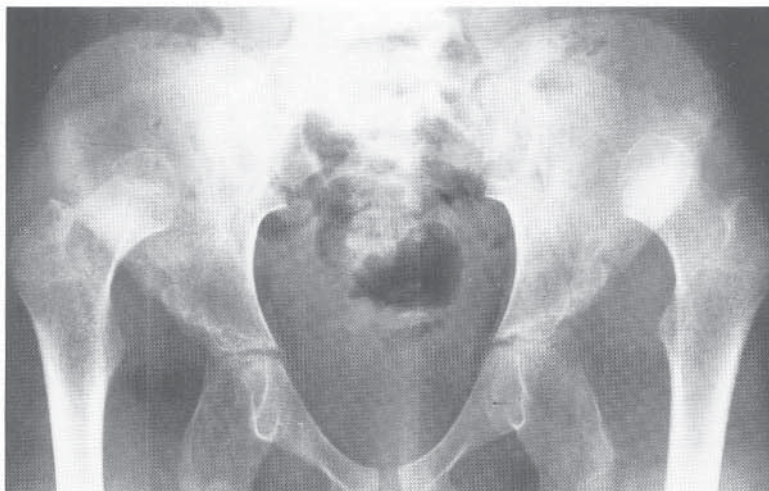


FIGURE 15-16 Untreated bilateral DDH diagnosed at 9 years of age.

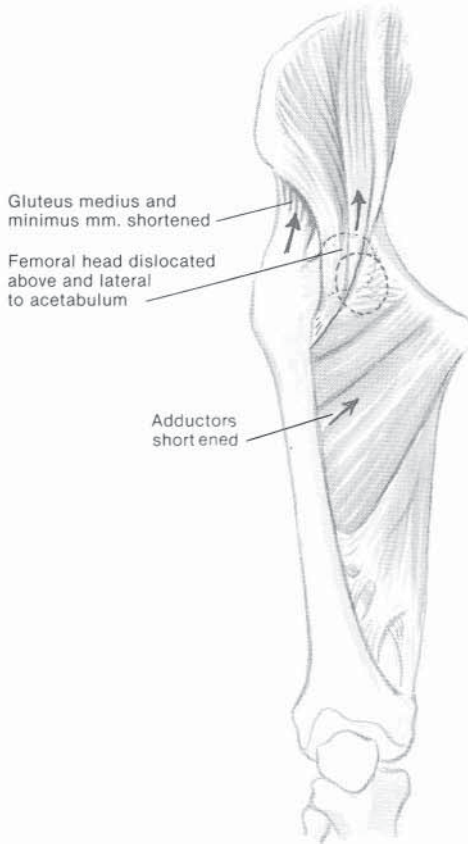


FIGURE 15–17 The pelvifemoral muscles become shortened and contracted, with progressive upward displacement of the femoral head in long-established DDH.

comes dislocated, subluxated, or dysplastic remains a subject of controversy. A primary problem is the definition of an unstable hip. Traditionally, instability has been defined by a positive result on Ortolani's or Barlow's test. The classification, however, has been complicated by the inclusion of hips that are clinically stable but have abnormal ultrasound characteristics. Thus, the criteria that an investigator uses to define abnormal hips must be taken into consideration when evaluating any study of hip instability.

Barlow addressed the issue in his classic work of 1962.⁸ He reported that 60 percent of hips that exhibited Barlow's sign (positive test) at birth spontaneously corrected in the first week of life and that 88 percent corrected within the first 2 months. However, he identified instability in one in 60 newborns, an extremely high percentage of unstable hips in a normal patient population. As a result, his reported frequency of spontaneous resolution is, in all probability, also high.

In another classic study Coleman followed 23 Navajo children with unstable hips.³² His criteria included a "jerk"-on-exit-and-entry sign (Ortolani's sign), an acetabular index greater than 40 degrees, and lateral displacement of the femoral beak in relation to the vertical line of Perkin's. Five of the 23 hips spontaneously corrected and 18 remained abnormal. Of the 18 abnormal hips, nine were dysplastic, three were subluxated, and six were dislocated during follow-up of at least 3 years.

Yamamuro and Doi studied 52 newborns with untreated

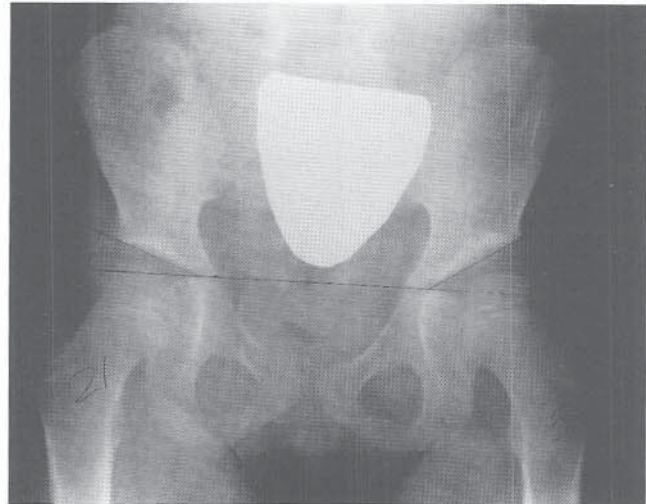


FIGURE 15–18 Neonatal hip instability: a dysplastic left hip in which the acetabulum is more oblique than normal.

instability and found that of the 42 subluxatable hips, 24 (57 percent) were normal at 5 months.²⁴⁹ Three of 12 hips that were initially dislocated spontaneously reduced. Pratt and associates studied young Navajo children with dysplastic hips, as defined by an increase in the acetabular angle and loss of acetabular concavity.¹⁶⁶ All were untreated. At 11-year follow-up, only three of 18 hips remained dysplastic.

DYSPLASIA, SUBLUXATION, AND DISLOCATION AFTER THE NEONATAL PERIOD

Dysplasia is a radiographic finding of increased obliquity and loss of concavity of the acetabulum, with an intact Shenton's line (Fig. 15–18). The term *subluxation* is used when the femoral head is not in full contact with the acetabulum (Fig. 15–19). The radiographic findings of subluxation include a widened teardrop–femoral head distance, a reduced center–edge angle, and a break in Shenton's line. The term *dislocation* specifies that the femoral head is not in contact with the acetabulum. Both subluxated and dislocated hips will have dysplastic changes.

Dysplastic hips without subluxation usually become painful and develop degenerative changes over time. These hips often become subluxated as the degenerative disease progresses. Cooperman and associates studied hips that were dysplastic but not subluxated and had an intact Shenton's line.³⁴ All hips with a center–edge angle of less than 20 degrees sustained osteoarthritic changes over a 22-year follow-up; however, there was no direct correlation of the center–edge angle with the development of arthritis. In a study of hips that were well reduced after primary treatment for DDH, osteoarthritis developed over a 13- to 15-year follow-up in five of 22 hips in which the center–edge angle was greater than normal.¹⁹⁴ It is estimated that 20 to 50 percent of cases of degenerative arthritis of the hip are secondary to subluxation or residual acetabular dysplasia.* The only guarantee of a lifetime of normal hip function is a completely normal radiographic appearance of the hip.

*See references 34, 72, 126, 152, 193, 232, 243.

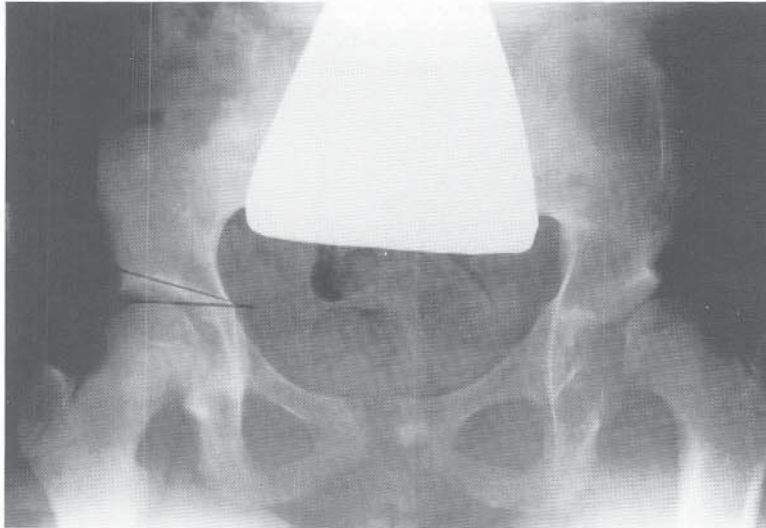


FIGURE 15-19 A subluxated and dysplastic left hip. There is only partial contact of the femoral head with the acetabulum, and the acetabulum is oblique and shallow.

The subluxated hip always leads to symptomatic degenerative hip disease.^{34,133,231,232,236,238} The affected individual often presents with gradually increasing pain in one or both hips, but no prior history of hip symptoms or treatment. Once pain begins, it tends to progress in logarithmic fashion over a period of months. Wedge and Wasylenko have noted that severe subluxation leads to symptoms in the second decade, moderately subluxated hips become painful in the third and fourth decades, and the least severely subluxated hips become symptomatic in the fifth and sixth decades. When pain starts, it tends to progress rapidly.^{231,232}

A completely dislocated hip causes symptoms much later than a subluxated hip, and in some individuals it never becomes painful. In a study of 54 adults with 80 untreated dislocations, 60 percent of the subjects had significant pain and disability.²³² Forty percent had no pain but were aware of an abnormal gait and some functional disability. The presence of a well-developed false acetabulum was the most significant predictor of pain and disability. Other studies have emphasized cases in which there were no symptoms despite lifelong hip dislocation. Crawford and Slovek studied 10 individuals with untreated complete dislocations, two of whom, in their fifties, had low back pain as their only complaint.³⁵ They also described three 55-year-old individuals who had pain only if they walked more than a mile. Walker described the attitude of members of the Cree-Ojibwa tribe in Manitoba, who viewed hip dislocation “in the same way as urban left-handedness.”²²⁸ The sole disability admitted was that it was difficult to portage a canoe with a man who limps—“He dips and you don’t.”²³⁵

People with untreated dislocated hips develop other degenerative and functional problems.^{222,231,232,236,238} Unilateral dislocations cause limb length inequality, ipsilateral valgus knee deformity, an abnormal gait, decreased agility, and postural scoliosis. Bilateral cases are associated with significant back pain secondary to increased lumbar lordosis.

Clinical Presentation

THE NEONATE

Developmental dislocation of the hip in the neonate is diagnosed by eliciting Ortolani’s or Barlow’s sign, or from sig-

nificant changes in the sonographic morphology of the hip. The unstable hip may either stabilize spontaneously or become dysplastic or dislocated over a period of several months.

The hip examination of the neonate requires an artful approach in which the setting must be controlled and the examiner experienced. The first requisite is a relaxed child. To achieve this, the baby may need a bottle, the examination surface should be warm and comfortable, and the room should be reasonably quiet. A firm examination surface is best, but if the mother’s lap keeps the baby more comfortable, it will suffice.

The “feel” of this examination is most important, not

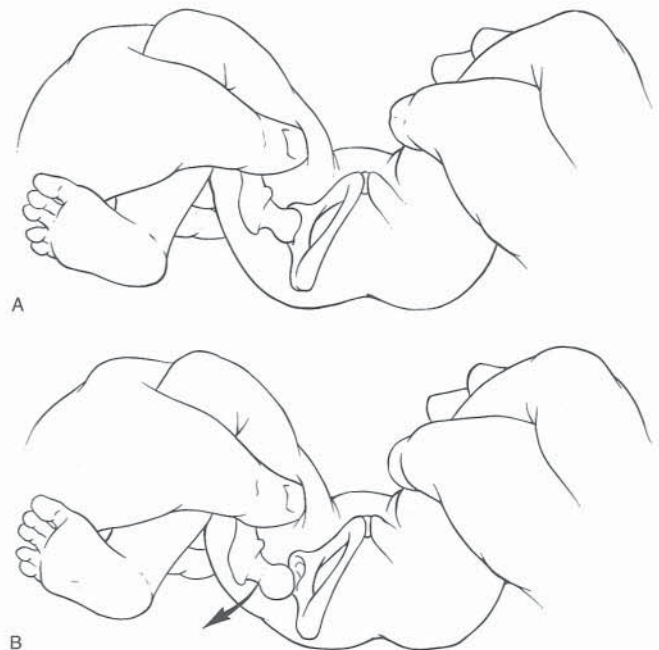


FIGURE 15-20 Barlow’s test for developmental dislocation of the hip in a neonate. **A**, With the baby supine, the examiner holds both of the baby’s knees and gently adducts one hip and pushes posteriorly. **B**, When the examination is positive, the examiner will feel the femoral head make a small jump out of the acetabulum (Barlow’s sign). When the pressure is released, the head is felt to slip back into place.

unlike palpation of the liver. Movement of the hip in and out of the socket is a delicate event that is best appreciated with a very light touch. The examiner holds the child's knees, one in each hand, and examines one hip at a time.

In the test for *Barlow's sign*, the examiner attempts to sublunate or dislocate the femoral head from within the acetabulum (Fig. 15–20). The hip is adducted and a gentle push is applied to slide the hip posteriorly. The examiner's fingers are positioned over the greater trochanter and the trochanter is allowed to move laterally. In a positive test, the hip will be felt to slide out of the acetabulum. As the examiner relaxes the proximal push, the hip can be felt to slip back into the acetabulum.

Ortolani's test is the reverse of Barlow's test: the examiner attempts to reduce a dislocated hip (Fig. 15–21). The examiner grasps the child's thigh between the thumb and index finger and, with the fourth and fifth fingers, lifts the greater trochanter while simultaneously abducting the hip. When the test is positive, the femoral head will slip into the socket with a delicate "clunk" that is palpable but not audible. The examiner should repeat this sequence four or five times to be certain of the findings, alternating Barlow's test and Ortolani's test in a gentle arc of motion. The other hip is then examined in the same manner. In the newborn period, there usually are no other signs of abnormality.

This examination is subject to many factors that can affect its effectiveness and reliability. The hurried examination will usually fail. It is possible to examine a hip for 15 maneuvers and only feel the instability the 16th time the hip is moved. The explanation is that this "feel" is quite delicate and requires just the right degree of relaxation on the part of the examiner as well as the baby. Many examiners report a

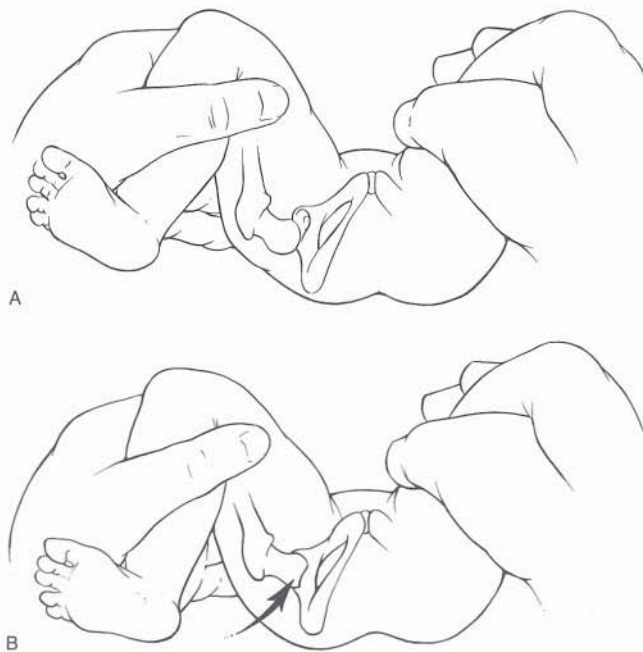


FIGURE 15–21 Ortolani's test for developmental dislocation of the hip in a neonate. **A**, The examiner holds the baby's knees and gently abducts the hip while lifting up on the greater trochanter with two fingers. **B**, When the test is positive, the dislocated femoral head will fall back into the acetabulum with a palpable (but not audible) "clunk" as the hip is abducted (Ortolani's sign). When the hip is adducted, the examiner will feel the head redislocate posteriorly.

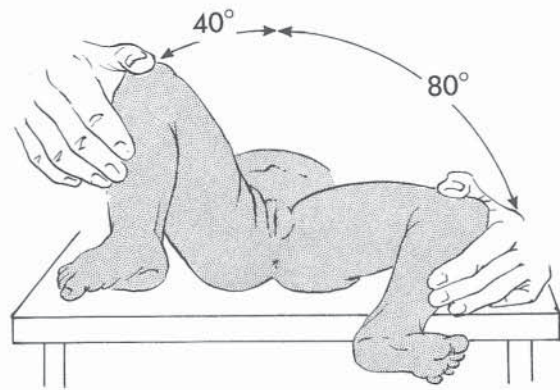


FIGURE 15–22 DDH of the right hip. One physical finding is limited abduction of the affected hip.

click (a high-pitched snap, often felt at the extremes of abduction), often elicited by a circular motion. This click usually originates in the ligamentum teres or occasionally in the fascia lata or psoas tendon and does not indicate a significant hip abnormality. The "clunk" of Ortolani is a sensation of displacement of the femoral head that is seen and felt but not heard.

THE INFANT

As the baby enters the second and third months of life, other signs of DDH appear. It is important to recall that the progression from instability to dislocation in the newborn period is a gradual process. In some children, an irreducible dislocation develops within a few weeks, while in others the hip dislocation remains reducible up to 5 or 6 months of age. When the hip is no longer reducible, specific physical findings appear, including limited abduction, shortening of the thigh, proximal location of the greater trochanter, asymmetry of the thigh folds, and pistoning of the hip.

Limitation of abduction, the most reliable sign of a dislocated hip, is best appreciated by abducting both hips simultaneously with the child on a firm surface. A unilateral dislocation produces a visible reduction in abduction on the affected side compared with the normal side (Fig. 15–22). Shortening of the thigh (the *Galeazzi sign*) is best appreciated by placing both hips in 90 degrees of flexion and comparing the height of the knees, again looking for asymmetry (Fig. 15–23). Because the thigh is foreshortened, there will be

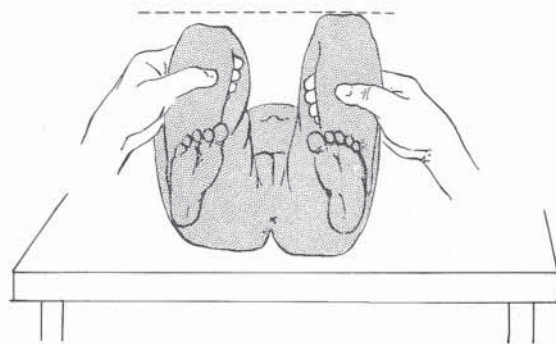


FIGURE 15–23 Galeazzi sign—apparent shortening of the femur, as shown by the difference in knee levels as assessed in a child lying on a firm table with the hips and knees flexed at right angles.

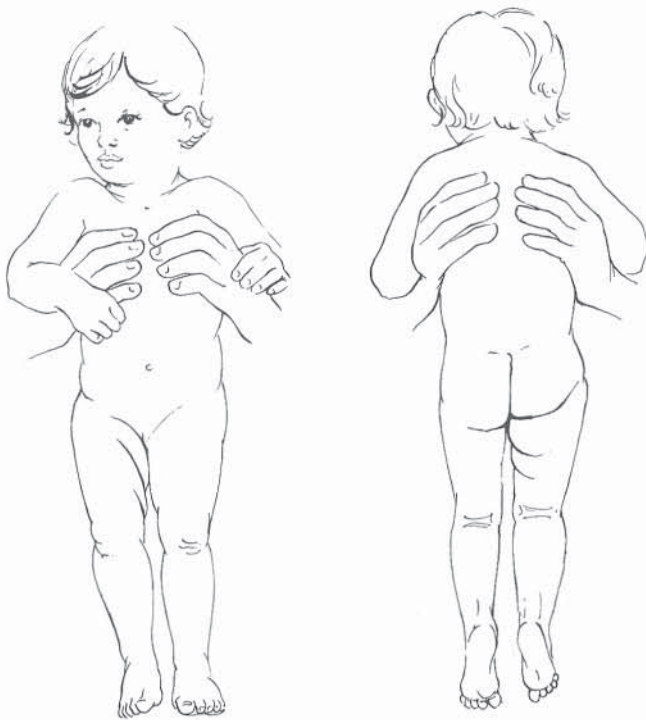


FIGURE 15-24 With DDH of the right hip, there may be asymmetry of the thigh folds and of the popliteal and gluteal creases, with apparent shortening of the extremity on the right.

more thigh folds on the affected side than on the normal side (Fig. 15-24). Although this sign is always present in a unilateral dislocation, extra thigh folds are a common normal variant and do not necessarily indicate hip dislocation.

A potentially perilous situation for the unwary examiner is the child with bilateral hip dislocation. This child has no asymmetry on abduction and the flexed knees are at the same level. Combined abduction is limited, but this is difficult to detect because the limitation is symmetric. One test that can help the examiner recognize a bilateral dislocation is the *Klisic test*, in which the examiner places the third finger

over the greater trochanter and the index finger on the anterior superior iliac spine. An imaginary line drawn between the fingers should point to the umbilicus. When the hip is dislocated, the more proximal greater trochanter causes the line to point about halfway between the umbilicus and the pubis (Fig. 15-25).

These examinations are capricious, and the clinician should use imaging studies to follow babies with questionable findings and those with risk factors associated with DDH. These risk factors include a family history of DDH, breech position, oligohydramnios, torticollis, and metatarsus adductus. The significantly higher frequency of DDH in females than in males must also be considered. Reexamination of a child a few months later will help decrease the possibility of missing a dislocation.

THE WALKING CHILD

The unilateral dislocated hip produces distinct clinical signs in a walking child. The affected side appears shorter than the normal extremity, and the child will toe-walk on the affected side. With each step, the pelvis will drop as the dislocated hip adducts, and the child will lean over the dislocated hip. This is known as an abductor lurch or Trendelenburg gait (Fig. 15-26). When the child attempts to stand on that foot with the other elevated off the floor, he or she will lean toward the affected side (Trendelenburg's sign). As in the younger child, there is limited abduction on the affected side and the knees are at different levels when the hips are flexed (the Galeazzi sign).

The walking child with bilateral dislocations is more difficult to recognize than one with a unilateral dislocation. There usually is a lurching gait on both sides, but some children mask this rather well, showing only an increase in the dropping of the pelvis in stance phase. Excessive lordosis is common and is often the presenting complaint (Fig. 15-27). The lordosis is secondary to hip flexion contracture, which is usually present. The knees are at the same level and abduction is symmetric, but limited. There usually is excessive internal and external rotation of the dislocated hips.

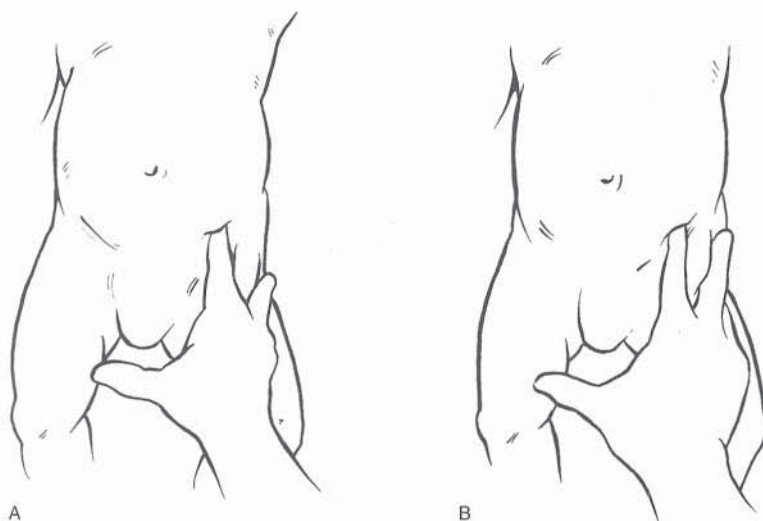


FIGURE 15-25 Klisic test for DDH. The examiner places the middle finger over the greater trochanter, and the index finger on the anterior superior iliac spine. A, With a normal hip, an imaginary line drawn between the two fingers points to the umbilicus. B, When the hip is dislocated, the trochanter is elevated and the line projects halfway between the umbilicus and the pubis.

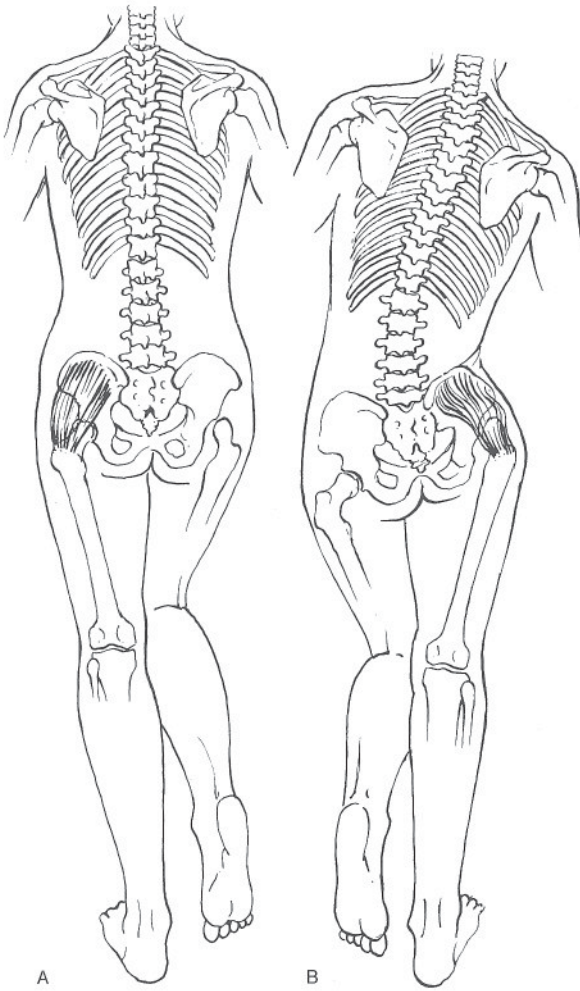


FIGURE 15-26 Trendelenburg lurch. The Trendelenburg test is positive on the dislocated right side. **A**, As the child stands with the weight on the normal side, the pelvis is maintained in the horizontal position by contraction and tension of the normal hip abductor muscles. **B**, As the child shifts weight to the side of the dislocated hip, the pelvis on the opposite, normal side drops, owing to weakness of the hip abductor muscles on the affected side. The sideways lean of the body toward the affected side is Trendelenburg's sign.

Imaging Studies

ULTRASOUND

The neonate's hip is a difficult structure to image with standard radiographic techniques because the hip is composed primarily of cartilage. Ultrasound shows the soft anatomy of the hip and the relationship of the femoral head and acetabulum very well. Technical advances have improved image quality, and dynamic techniques add significant information to that obtained from static images. Three important questions about the use of ultrasound need to be resolved, however. First, how often does ultrasound identify a "silent" hip (i.e., one with a normal clinical examination) that would become abnormal if not treated? Second, which ultrasound findings indicate that the hip must be treated? Third, does the use of ultrasound increase the rate of treatment for hips that would stabilize without such treatment?

Graf pioneered the use of ultrasound in the evaluation of the infant hip.⁶² He initially studied cadaver hips and compared sonographic findings with radiographs and arthrograms to define the sonographic anatomy of the hip. The hyaline articular cartilage of the hip had little echo, the capsule and muscles had moderate echo, and the fibrocartilaginous labrum, as well as the juncture of the femoral neck and the cartilaginous upper femur, had a strong echo. He recommended a lateral imaging technique with the transducer placed over the greater trochanter (Fig. 15-28), and noted that the examination should take no more than 2 to 3 minutes.

Graf also proposed a classification system based on the angles formed by the sonographic structures of the hip. The "baseline" is the line of the ilium as it intersects the bony and the cartilaginous portions of the acetabulum. The "inclination line" is the line along the margin of the cartilaginous acetabulum, and the third line is the "acetabular roofline," along the bony roof (Fig. 15-29). The intersection of the roofline and the baseline forms the alpha angle, while the intersection of the inclination line and the baseline forms the beta angle. A smaller alpha angle indicates a shallower bony acetabulum. A smaller beta angle indicates a better cartilaginous acetabulum. In other words, as the femoral head subluxates, the alpha angle decreases and the beta angle increases.⁶²

The Graf classification has been modified several times and can be confusing. In its simplest form, class I hips are normal, class II hips are either immature or somewhat abnormal, class III hips are subluxated, and class IV hips

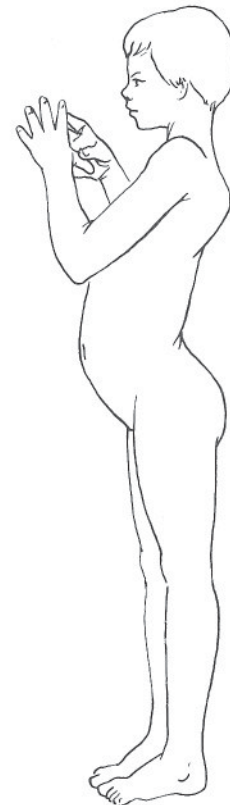


FIGURE 15-27 Bilateral hip dislocation. Note the excessive lordosis secondary to hip flexion contracture.

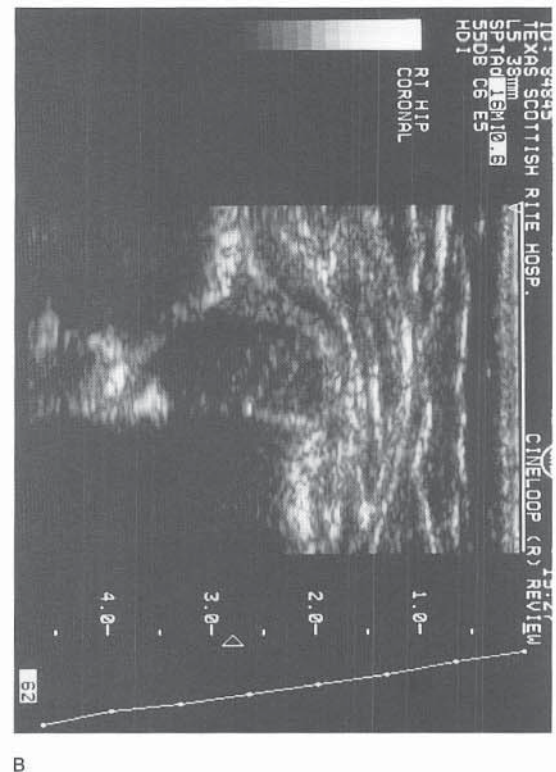
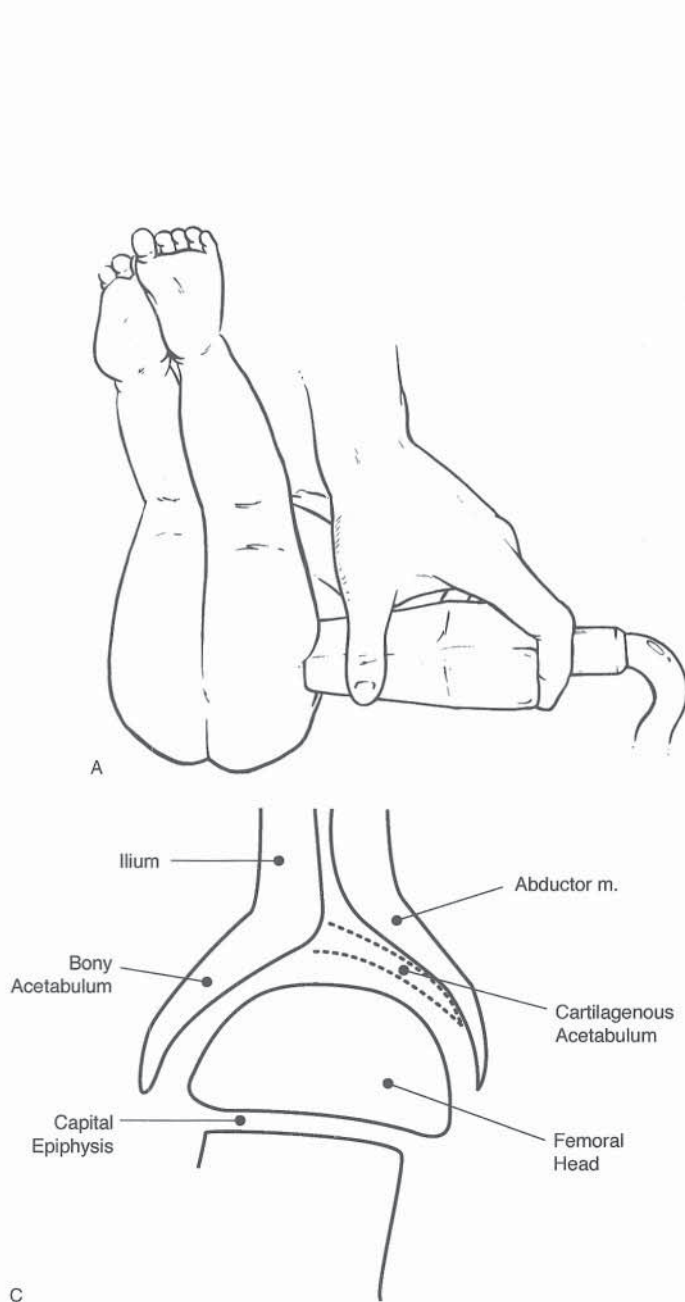


FIGURE 15-28 Ultrasound evaluation of the infant hip. **A**, The sonogram should be obtained with the child in the lateral decubitus position. **B**, Ultrasound scan showing hip structures in a child. **C**, Highlights of anatomic structures shown on the sonogram. We prefer to view the sonogram on its side, as this resembles an anatomic view.

are dislocated. Class I hips need no follow-up, while class III and IV hips usually require treatment. Class II hips form the group in which the degree of abnormality and the need for treatment are less clear. Graf has subdivided class II in several ways in different publications (Table 15-2).⁶²⁻⁶⁴

Treatment philosophies regarding abnormalities in Graf class II hips vary widely (Figs. 15-30 and 15-31). Some authors treat only those hips with clinical instability, regardless of ultrasound findings. Others treat all class II hips with abduction devices. At this writing, exact treatment guidelines are lacking. Because the ultrasound findings in most hips improve with age, treatment decisions should be based on ultrasound examinations performed at 6 weeks of age rather than at birth.

Harcke and Kumar have advocated dynamic studies in

which the hip is stressed and the degree of subluxation is documented with ultrasound.⁷⁰ In the first few days of life, 4 to 6 mm of motion is considered normal, and definite treatment indications based on stress views are still evolving.^{70,99}

Much of the current research supports the concept that ultrasound is a more sensitive indicator of abnormality of the infant hip than radiography. In a study of 60 patients with ultrasound evidence of DDH, 59 of the patients also had arthrographic evidence of dislocation. Radiographic examination of the same hips produced six equivocal cases and one case that was incorrectly diagnosed as a dislocation.¹³⁸ Sochart and Paton reported that the use of ultrasound screening resulted in splintage treatment for six in 1,000 children screened. Minor dysplasia could be observed with

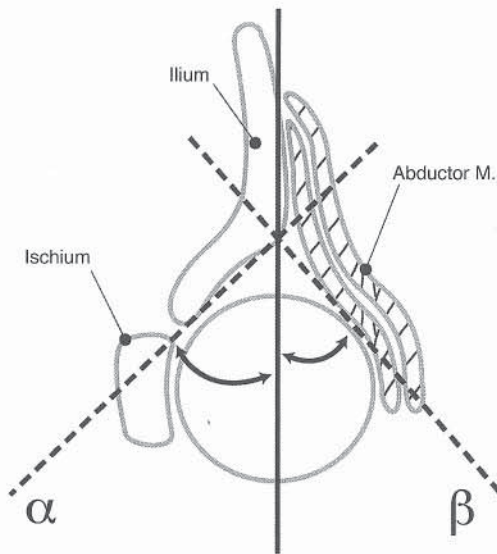


FIGURE 15-29 Measurement of alpha and beta angles on ultrasound scans to establish Graf class. The alpha angle is the angle between the baseline and the roof of the bony acetabulum. The beta angle is the angle between the baseline and the cartilaginous acetabular roof.

serial scanning, and the treatment period could be shortened by monitoring the treated hips with ultrasound.¹⁹² In a series of 4,617 babies, 448 (9.7 percent) had either clinical abnormalities or some risk factor for DDH.³¹ In the 448 patients, 17 hips required treatment. Only 4 of the 17 were clinically unstable at birth and only 8 were clinically unstable at the time of referral, indicating that some of the abnormal hips had normal clinical findings. An additional 81 hips had minor abnormal ultrasound findings that normalized without treatment. These studies suggest that screening with ultrasound does pick up clinically silent hips without increasing the rate of treatment for minor abnormalities that would resolve spontaneously.

A study by Bialik and colleagues provides some useful guidelines for the use of ultrasound.¹² Their protocol used sonography to reduce the number of hips treated unnecessarily by delaying the start of treatment pending reexamination. Neonates with hips that were stable on initial examina-

tion were reexamined clinically and with ultrasound at 6 weeks of age, while those with unstable hips were reexamined at 2 weeks of age. If the ultrasound study showed no improvement of the unstable hips at the second examination, treatment with the Pavlik harness was begun. Of 8,638 hips examined, 93 percent were normal on clinical and ultrasound examination, 0.9 percent were unstable on clinical examination, and 4 percent had ultrasound findings placing them in Graf class IIa or worse. At the end of the established waiting periods, 90 percent of the abnormal hips had become normal without treatment. The 54 hips that were treated represented 0.6 percent of the hips evaluated. Only 3 percent of the Graf IIa hips failed to normalize without treatment, while 17 percent of Graf III hips and 25 percent of Graf IV hips failed to normalize. Slightly more than half of the hips treated had no clinical instability. Their fate, had they not been treated, remains speculative.

Other authors believe that ultrasound is too sensitive and results in overtreatment of hips that would otherwise develop normally.²⁵⁰ Miranda and associates screened almost 50,000 hips clinically, without adjunct ultrasound, and found that only seven (0.012 percent) of those normal on examination had evidence of dysplasia later.¹⁴³ Baronciani and colleagues found a large number of Graf IIa hips in their screening and emphasized that over a 69-day follow-up period, 88 percent of unilaterally affected hips and 75 percent of bilaterally affected hips normalized.⁹ Rosendahl and associates screened 3,613 newborns with ultrasound and treated 3.4 percent of the children with splints.¹⁷⁷ Forty-two percent of these patients were diagnosed with ultrasound alone, not including another 13 percent who were identified as having immature hips and were not treated. They concluded that this screening doubled the treatment rate compared with using clinical findings alone. Tonnis and colleagues randomly examined 2,000 newborn babies with ultrasound and found 1,008 Graf IIa hips.²¹⁶ All of these babies were placed in abduction swaddling, and there were no subsequent dislocations. Nine hips were in Graf class III or IV, and these were treated with traction and reduction. Only 9.5 percent of the babies had clinical signs of DDH.

Terjesen and associates stated that Graf's method was unreliable in children less than 3 months old because the reference points are indistinct.²¹⁰ They recommended using

TABLE 15-2 Graf Classification System of DDH, Based on Sonographic Angles of the Hip

Class	Alpha Angle	Beta Angle	Description	Treatment
Standard Classification				
I	>60°	<55°	Normal	None
IIa	50°–60°	55°–77°	Immature (<3 mo)	Observation
IIb	>50°–60°	55°–77°	>3 mo	Pavlik harness
IIc	43°–49°	>77°	Acetabular deficiency	Pavlik harness
IId	43°–49°	>77°	Everted labrum	Pavlik harness
III	<43°	>77°	Everted labrum	Pavlik harness
IV	Unmeasurable		Dislocated	Pavlik harness/closed vs open reduction
Simplified Classification				
I	>60°	<55°	Normal	None
II	43°–60°	55°–77°	Delayed ossification	?
III	<43	>77°	Lateralization	Pavlik harness
IV	Unmeasurable		Dislocated	Pavlik harness/closed vs open reduction

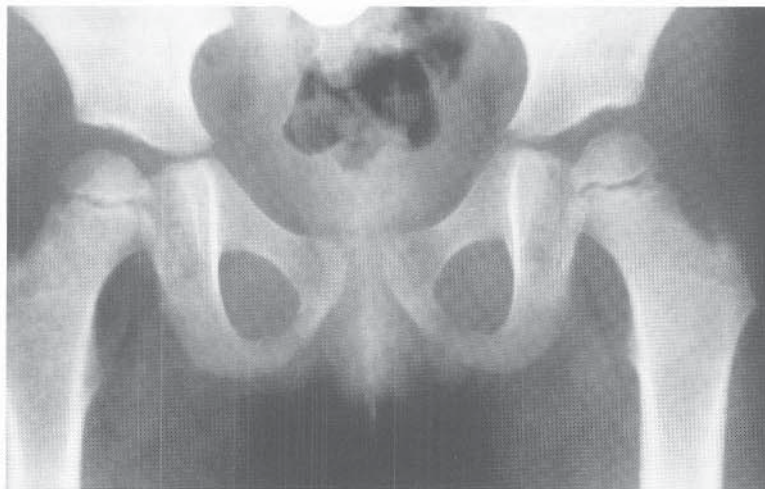
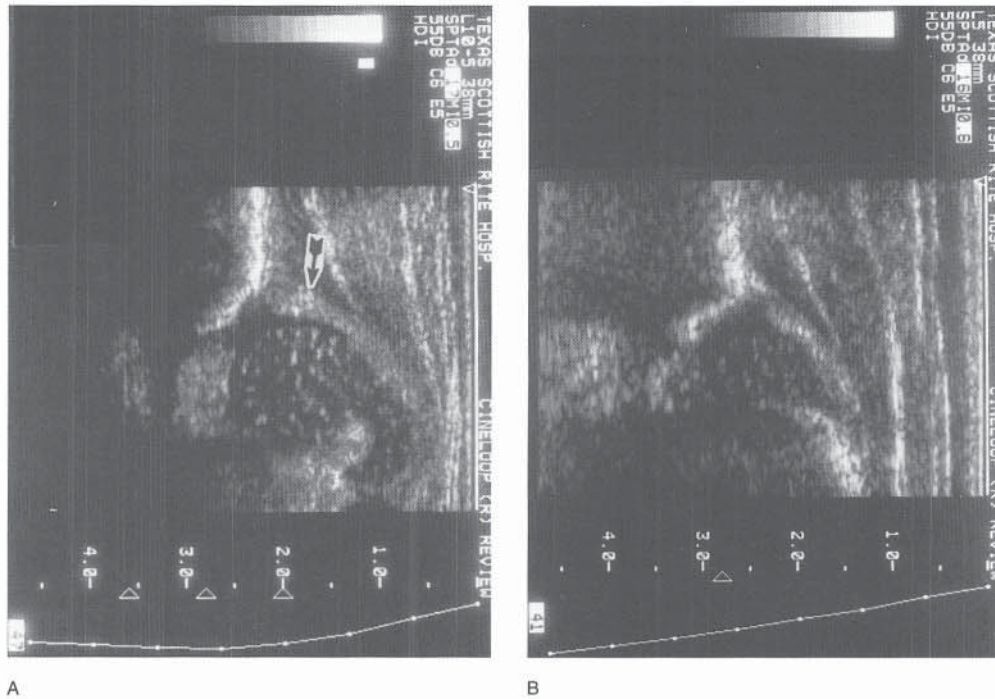


FIGURE 15-30 Sonogram of a 5-day-old girl with Barlow's sign. A, Static ultrasound film showing anterior displacement of the femoral head. The equator of the femoral head is lateral to the "bright spot" (*arrow*) of the labrum, which was considered to be an indication for treatment. B, Sonogram obtained after 6 weeks of treatment in a Pavlik harness shows a well-seated femoral head. C, Radiograph obtained at age 5 years shows normal hip development.

displacement rather than angle measurement, for greater accuracy. Castelein and associates followed 101 hips that were normal on clinical examination but abnormal on ultrasound.²⁶ Of those hips with abnormal Graf classifications, 4 of 101 had radiographically evident dysplasia by age 6 months. Of 43 with ultrasound indications of instability, none were subsequently abnormal. Vendantam and Bell found that 24 of 55 babies with abnormal findings on dynamic ultrasound normalized without treatment.²²⁰ Robinson reported that universal screening with ultrasound resulted in an increase in the number of infants needing splintage without reducing the number diagnosed "late" who needed surgery.¹⁷³ Paton and associates reported that ultrasound screening of selected infants with risk factors was of little value in reducing the incidence of late dislocation.¹⁶⁰

Perhaps we should conclude that ultrasound is a valuable

adjunct to the detection of neonatal hip abnormalities, but that it should be used judiciously to avoid overtreatment of minor abnormalities. Ultrasound is also very useful in detecting early treatment failures when using the Pavlik harness.

RADIOGRAPHY

Plain radiography of the pelvis will usually demonstrate a frankly dislocated hip in individuals of any age. In newborns with typical DDH, however, the unstable hip may appear radiographically normal. As the child reaches 3 to 6 months of age, the dislocated hip will be evident radiographically, but the examiner must be familiar with the landmarks of the immature pelvis to recognize the abnormality. In the infant, the upper femur is not ossified, and most of the

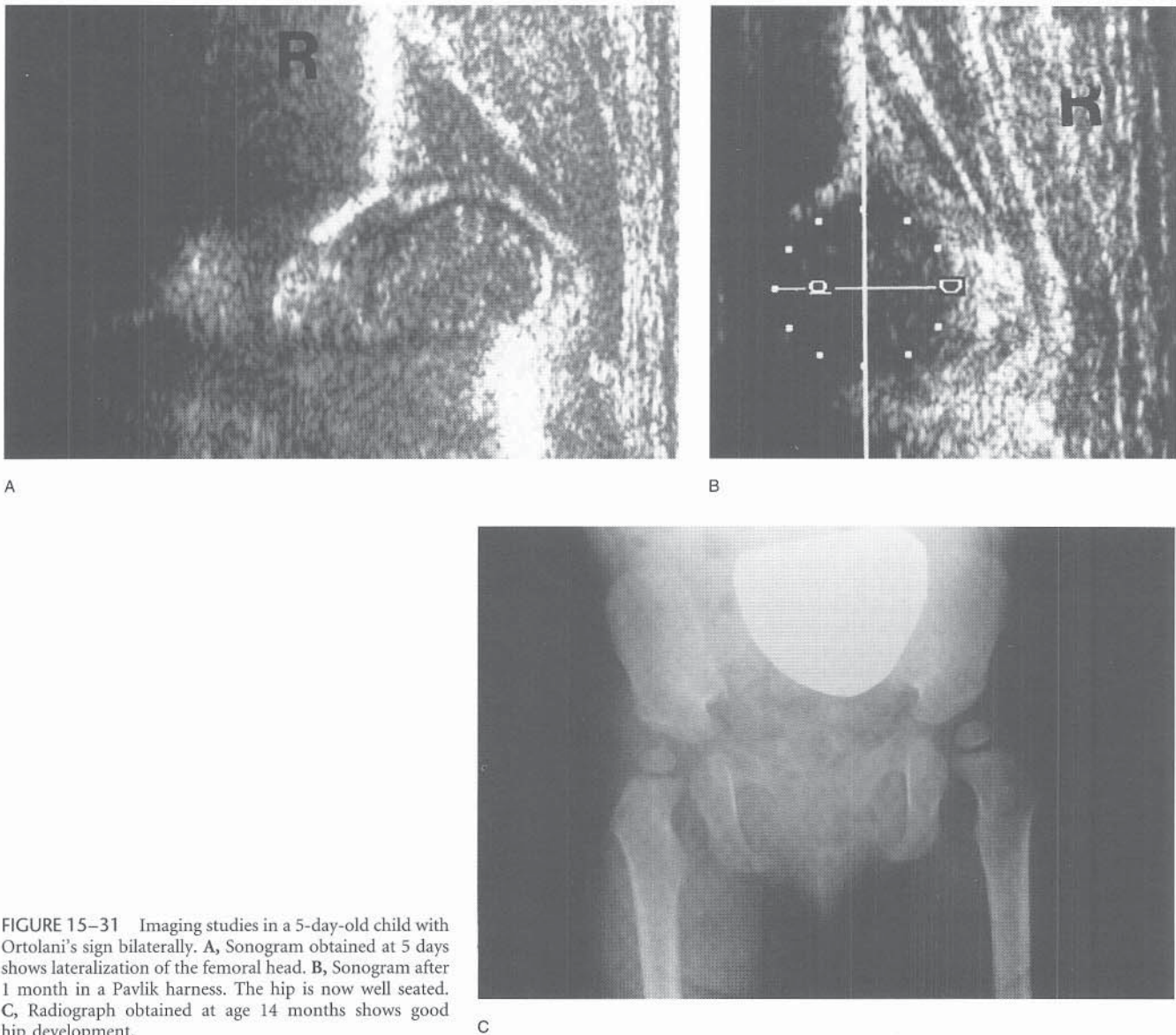


FIGURE 15-31 Imaging studies in a 5-day-old child with Ortolani's sign bilaterally. **A**, Sonogram obtained at 5 days shows lateralization of the femoral head. **B**, Sonogram after 1 month in a Pavlik harness. The hip is now well seated. **C**, Radiograph obtained at age 14 months shows good hip development.

acetabulum is cartilaginous. The triradiate cartilage lies between the ilium, the ischium, and the pubis.

Several classic lines are helpful in evaluating the immature hip (Fig. 15-32). *Hilgenreiner's line* is a line through the triradiate cartilages. *Perkin's line*, drawn at the lateral margin of the acetabulum, is perpendicular to Hilgenreiner's line. *Shenton's line* is a curved line that begins at the lesser trochanter, goes up the femoral neck, and connects to a line along the inner margin of the pubis. In a normal hip, the medial beak of the femoral metaphysis lies in the lower, inner quadrant produced by the juncture of Perkin's and Hilgenreiner's lines. Shenton's line is smooth in the normal hip. In the dislocated hip, the metaphysis will lie lateral to Perkin's line, and Shenton's line will be broken, as the femoral neck lies cephalad to the line from the pubis.

Another useful measurement is the *acetabular index*, which is an angle formed by the juncture of Hilgenreiner's line and a line drawn along the acetabular surface (Fig. 15-33). In normal newborns, the acetabular index averages

27.5 degrees. At 6 months of age, the mean is 23.5 degrees. By 2 years of age, the index usually decreases to 20 degrees. Thirty degrees is considered the upper limit of normal.^{74,102,116} The acetabular index of the weightbearing zone, or the *sourcil*, normally is less than 15 degrees.^{151,211}

In the older child, the *center-edge angle* is a useful measure of hip position (Fig. 15-34). This angle is formed at the juncture of Perkin's line and a line connecting the lateral margin of the acetabulum to the center of the femoral head. In children 6 to 13 years old, an angle greater than 19 degrees has been reported as normal, while in children 14 years old and older, an angle greater than 25 degrees is considered normal.¹⁸⁸

A helpful radiographic projection is the *Von Rosen view*, in which both hips are abducted, internally rotated, and extended.²²³ In the normal hip, an imaginary line extended up the femoral shaft intersects the acetabulum. When the hip is dislocated, the line crosses above the acetabulum.

The *acetabular teardrop* figure, as seen on an anteropost-

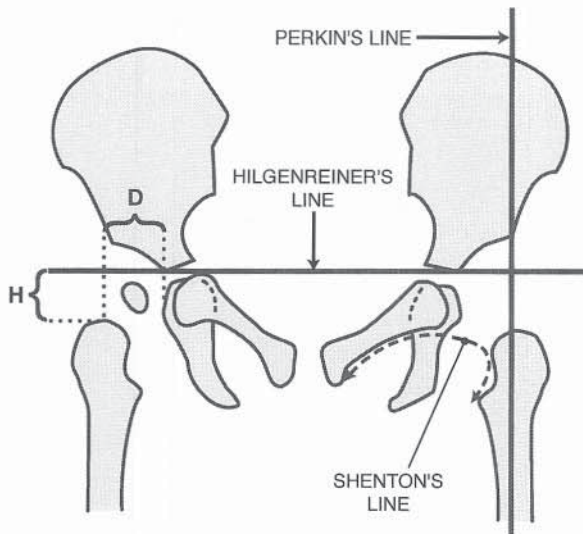


FIGURE 15-32 Radiographic measurements useful in evaluating DDH. Hilgenreiner's line is drawn through the triradiate cartilages. Perkin's line is drawn perpendicular to Hilgenreiner's line at the margin of the bony acetabulum. Shenton's line curves along the femoral metaphysis and connects smoothly to the inner margin of the pubis. Dimension H (height) is measured from the top of the ossified femur to Hilgenreiner's line. The Dimension D (distance) is measured from the inner border of the teardrop to the center of the upper tip of the ossified femur. Dimensions H and D are measured to quantify proximal and lateral displacement of the hip and are most useful when the head is not ossified.

erior (AP) radiograph of the pelvis, is formed by several lines. It is derived from the wall of the acetabulum laterally, the wall of the lesser pelvis medially, and a curved line inferiorly and is formed by the acetabular notch. The teardrop appears between ages 6 and 24 months in a normal hip, later in a dislocated hip. In a study by Smith and associates,¹⁹⁰ the teardrop did not appear until hips were reduced, but the teardrop was present in dislocated hips by age 29 months in a study by Albinana and associates.¹ When

ACETABULAR INDEX

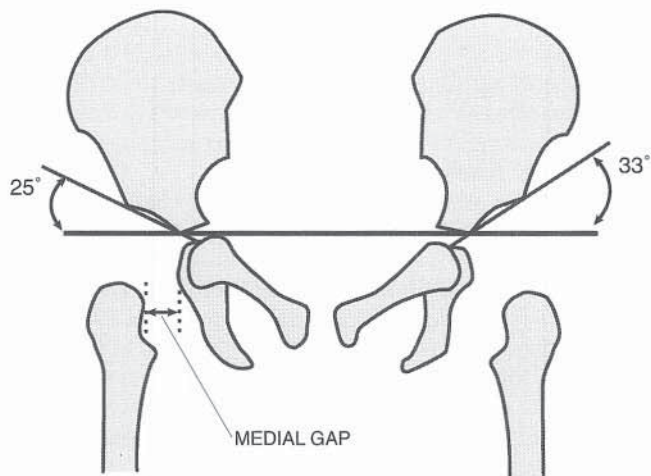


FIGURE 15-33 Acetabular index and the medial gap. The acetabular index is the angle between a line drawn along the margin of the acetabulum and Hilgenreiner's line; in normal newborns it averages 27.5 degrees and decreases with age. The medial gap is compared to the normal side.

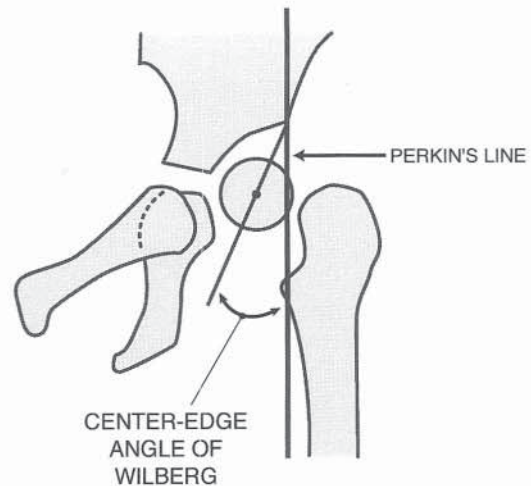


FIGURE 15-34 Wilberg's center-edge angle, the angle between Perkin's line and a line drawn from the lateral lip of the acetabulum through the center of the femoral head. This angle, a useful measure of hip position in older children, is considered normal if greater than 10 degrees in children 6 to 13 years, and increases with age.

the hip is dislocated or subluxated, the acetabular portion of the teardrop loses its convexity and the teardrop is wider from superior to inferior. The reduced hip remodels the acetabulum, and the teardrop gradually narrows. Hips in which the teardrop appears within 6 months of reduction have a better outcome than hips in which the teardrop appears later.¹⁹⁰ Four types of teardrop bodies have been noted—open, closed, crossed, and reversed.¹ The teardrops have also been described as U- or V-shaped, with a V-shaped teardrop being associated with dysplastic hips and a poor outcome (Fig. 15-35).

Another measure of acetabular dysplasia is the *acetabular index* of depth to width, in which the depth of the central portion of the acetabulum is divided by the width of the acetabular opening, with normal being greater than 38 percent.¹⁵¹ The femoral head extrusion index represents the percentage of the femoral head that lies outside the acetabulum.

The *Severin classification* has been used for many years to specify outcome in hips treated for DDH (Table 15-3).¹⁸⁷ However, in 1997 Ward and associates reported poor levels of intraobserver and interobserver reliability when the system was used.²²⁹ The interpretive ambiguities and lack of objective measures emphasize the need for a more reliable scheme.

ARTHROGRAPHY

The arthrographic anatomy of the hip was well described by Severin in 1941.¹⁸⁷ In the normal hip, the free border of the labrum is easily seen as a sharp "thorn" overlying the femoral head (Fig. 15-36). A recess of joint capsule overlies the thorn. The capsule expands beyond this recess and then is constricted by the ringlike zona orbicularis. In a child with DDH, when the hip is in the dislocated position, the acetabular edge is seen and the capsule is enlarged as it extends over the femoral head. The capsule is constricted at its midportion into an hourglass shape by the iliopsoas tendon.

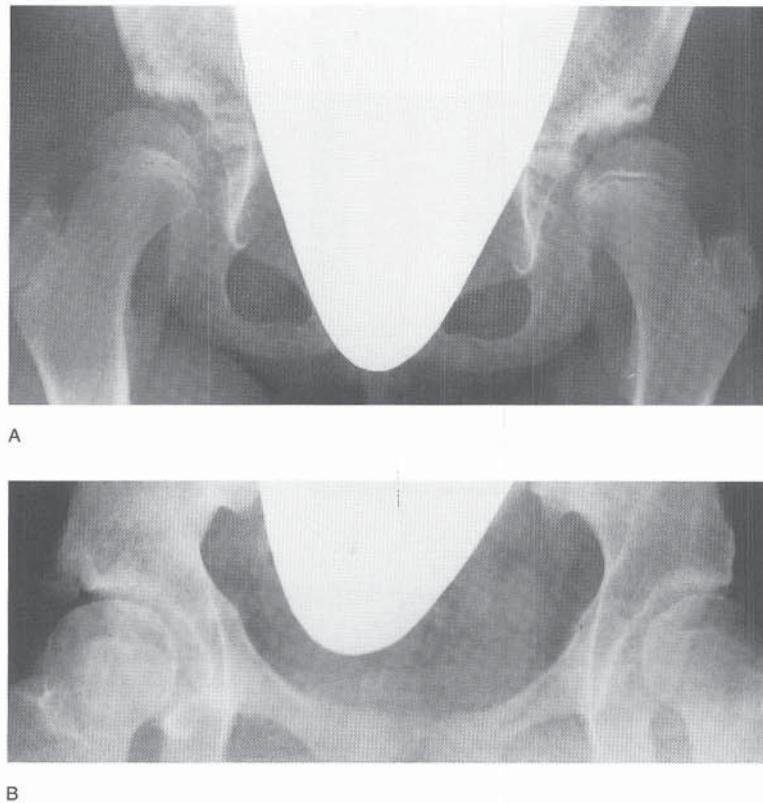


FIGURE 15-35 A wide teardrop body in a 10-year-old girl who underwent closed reduction at age 18 months. A, AP radiograph showing bilateral acetabular dysplasia. Note the wide teardrop body bilaterally, an indication of inadequate acetabular deepening since reduction. B, AP radiograph obtained 4 years after Salter osteotomies. Acetabular coverage has improved but the widened teardrop persists. It is likely that degenerative changes will develop, particularly in the left hip.

When the hip is placed into a reduced position, it may reduce fully against the acetabular wall or it may “dock” against the labrum and the capsular constriction of the iliopsoas (see Fig. 15-51B). When the reduction is deep, the labrum lies flat over the head and has a sharp border. When the head is docked, the labrum is blunted and is interposed between the head and the acetabular wall. The ligamentum teres is seen within the joint and may be outlined by contrast material. A bulge in the acetabular cartilage

beneath the labrum (the neolimbus) may be seen. If the reduction is stable and the hip is immobilized in a safe position, the femoral head will gradually overcome the capsular tightness, and arthrography repeated 6 weeks later will show the head well seated in the acetabulum.

Arthrography should usually be performed with the patient under general anesthesia. We prefer the median, subadductor approach with image intensification (Fig. 15-37). The needle is inserted just beneath the adductor longus, about 2 cm distal to its origin. If the starting point is too close to the adductor's origin, the needle will encounter the inferior portion of the acetabulum rather than the joint itself. The needle is directed medially, aimed toward the contralateral sternoclavicular joint. When resistance is encountered, the position of the needle is noted on the image. The needle should be directed toward the joint space. A small amount of contrast material is injected to be certain that the joint has been entered. The contrast agent should flow freely around the femoral head. Another 1 mL of contrast agent is injected, and the needle is removed. Permanent films should be obtained for each significant position of the hip. It is important to note the positions of maximum stability and instability.

TABLE 15-3 Severin Classification System of DDH

Class	Radiographic Appearance	Center-Edge Angle
Ia	Normal	>19° (6-13 yr old) >25° (≥14 yr old)
Ib	Normal	15-19° (6-13 yr old) 20°-25° (≥14 yr old)
IIA	Moderate deformity of femoral head, femoral neck, or acetabulum	Same as class I
III	Dysplasia without subluxation	<15° (6-13 yr old) <20° (≥14 yr old)
IVa	Moderate subluxation	≥0°
IVb	Severe subluxation	<0°
V	Femoral head articulates with pseudo-acetabulum in superior part of original acetabulum	
VI	Redislocation	

MAGNETIC RESONANCE IMAGING

Magnetic resonance imaging affords excellent anatomic visualization of the infant hip but is not commonly used

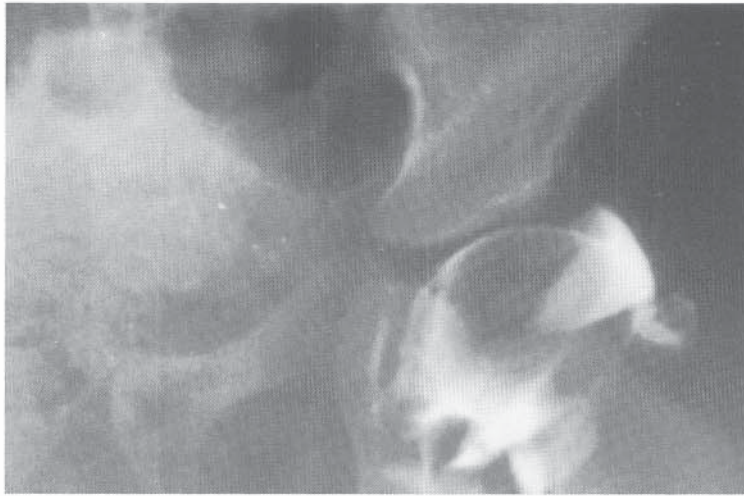


FIGURE 15-36 AP arthrogram of a normal hip in neutral position. Note the sharp lateral acetabular margin, the “thorn” with a recess of joint capsule overlying it.

because of the expense involved and the need for sedation. Kashiwagi and associates proposed an MRI-based classification of hips with DDH.⁹⁶ Group 1 hips had a sharp acetabular rim, and all were reducible with a Pavlik harness. Group 2 hips had a rounded acetabular rim, and almost all could be reduced with a Pavlik harness. Group 3 hips had an inverted acetabular rim, and none were reducible with the harness. Greenhill and associates described the MRI findings in 11 untreated DDH hips.⁶⁵ The iliac bone was widened, and there was lateral drift of the superior and posterior portions of the acetabular floor. The acetabular cartilage was overgrown, and there was a convexity of the posterior portion of the acetabular cartilage.^{16,65}

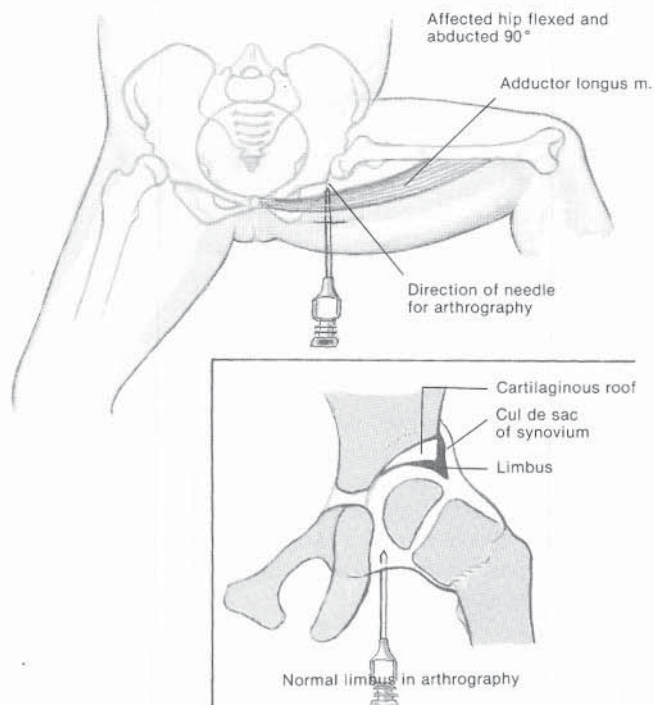


FIGURE 15-37 Subadductor approach for insertion of the needle for arthrography of the hip.

Screening Criteria

All neonates should have a clinical examination for hip instability. Beyond that recommendation, there is a lack of consensus as to further screening criteria. Most authors agree that babies with risk factors associated with DDH should receive more careful screening, at least an examination by an experienced examiner and possibly ultrasound. These risk factors include a family history of DDH, breech birth position, torticollis, metatarsus adductus, and oligohydramnios.^{81,83,86,112} Because the incidence is higher in females, these factors assume greater importance in female infants. First-born Caucasians also have an increased risk of DDH.^{2,5,6,24,25,43}

Screening with ultrasound remains controversial. In addition to the added cost, the disadvantage of general ultrasound screening is the identification of a large number of babies with a sonographic abnormality for which there are no firm treatment guidelines. In published series, the number of children treated for DDH as a result of neonatal ultrasound screening has varied from a low of 17 in 4,617 screened (0.4 percent)³¹ to a high of 1,008 in 2,000 screened (50 percent).²¹⁶ Some authors recommend ultrasound combined with clinical examination for all babies with the risk factors of breech presentation, family history, torticollis, and oligohydramnios. Others, however, have found a low yield of significant abnormalities in the absence of clinical findings, even in hips at risk.¹⁶⁰

Treatment of the Neonate

THE PAVLIK HARNESS

The Pavlik harness is the preferred method of treating neonatal DDH (Table 15-4). The first indication for treatment is a hip that is dislocated and can be reduced by the examiner (Ortolani's sign). We believe that all such hips should be treated in a harness, beginning at the time the diagnosis is made. We also recommend immediate treatment for hips that are located but can be subluxated by the examiner (Barlow's sign). Some of these hips will spontaneously stabilize, and some clinicians prefer to wait a few weeks and

TABLE 15-4 Treatment of Developmental Dysplasia of the Hip Guidelines

Neonate: Place in Pavlik harness for 6 weeks.
1 to 6 months: Place in Pavlik harness for 6 weeks after hip reduces.
6 to 18 months: ?Traction; closed reduction. If closed reduction is successful, place in cast for 3 months. If closed reduction is unsuccessful, perform open reduction. Open reduction is performed by a medial approach in children less than 12 months old and by an anterolateral approach in children more than 12 months old.
18 to 24 months: ?Trial of closed reduction, or primary open reduction (anterolateral approach). A Salter osteotomy may or may not be part of the procedure.
24 months to 6 years: Perform primary open reduction (anterolateral approach) and femoral shortening, with or without a Salter osteotomy.

reexamine the child before initiating treatment. When observation is chosen, steps should be taken to ensure follow-up, as some of these hips will subsequently dislocate if left alone.^{8,32} Less certain indications for treatment are hips that are normal on clinical examination but abnormal on ultrasound. We currently recommend close observation of such hips, with ultrasound repeated at age 6 weeks, at which time those hips that remain abnormal should be treated. As noted in the earlier discussion of ultrasound examinations, Graf class II hips are more likely to improve without treatment than are Graf class III or IV hips.

The Pavlik harness is applied by first placing the chest strap just below the nipple line (Fig. 15-38). The child's feet are placed in the stirrups, the hips are placed in 120 degrees of flexion, and the straps are secured. The posterior straps are fastened loosely, allowing abduction of the hips to occur by gravity alone. Abduction should never be forced by the straps on the harness.²¹³ In fact, the hips should be able to adduct to almost a neutral position with the straps in place. Excessive flexion must be avoided and will occur if the harness is not properly adjusted as the baby grows.

Hyperflexion of the hips may produce a femoral nerve palsy as the nerve becomes compressed by the diapers between the thigh and abdomen.¹⁴⁹ Hyperflexion may also cause the femoral head to dislocate inferiorly.¹⁷⁴ On the other hand, inadequate flexion (less than 90 degrees) will fail to reduce the hip (Fig. 15-39).

Use of the harness is most effective when there is a strong support system to educate the parents and to closely monitor the neonate's progress. We see the baby every week while the harness is being used. Reliable parents are taught to remove and replace the harness for bathing. If the social setting is poor, we prefer to have the parents keep the baby in the harness and return weekly with the child for bathing and harness change. Most babies outgrow the initial harness in 3 to 4 weeks, and a larger harness is then fitted.

The progress of the hip may be monitored by repeating the ultrasound study after 3 weeks in the harness, at which time the hip usually remains reduced. After 6 weeks of treatment, the hip is examined with the baby out of the harness and ultrasound is performed. If ultrasound shows a well-located hip and the clinical examination is normal, the harness is discontinued. (Other authors prefer to wean the baby from the harness with a period of part-time wear over several weeks or months.) The child is then followed clinically. At 3 to 4 months of age, a radiograph of the pelvis is obtained. If the hip is normal, the child is seen at 1 year of age and a standing radiograph is obtained. If the radiograph is normal, subsequent follow-up is either annual or biennial. Follow-up to skeletal maturity is recommended because there is a significant incidence of late asymmetric epiphyseal closure, resulting in valgus of the femoral head and reduced coverage of the hip. In one series, 20 percent of patients successfully treated in the harness developed acetabular dysplasia during 8- to 15-year follow-up.²¹⁸

If the hip remains dislocated after 3 to 4 weeks of harness wear, use of the harness should be discontinued and the hip should be examined under anesthesia. An arthrogram may

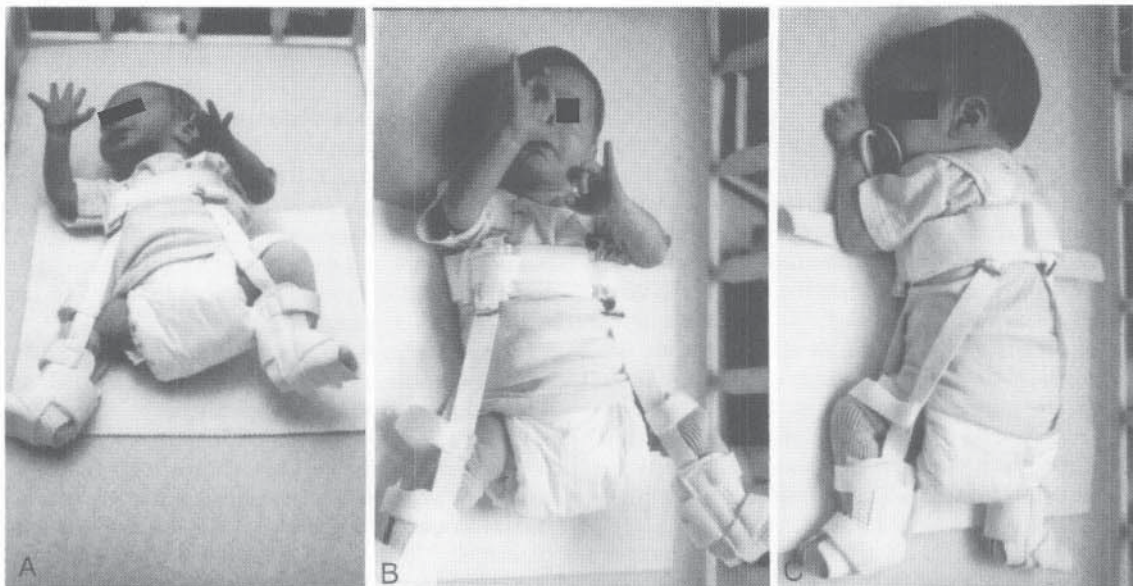


FIGURE 15-38 The Pavlik harness. The transverse chest strap should be placed just below the nipple line. The hips should be flexed to 120 degrees, and the posterior straps should not produce forced abduction.

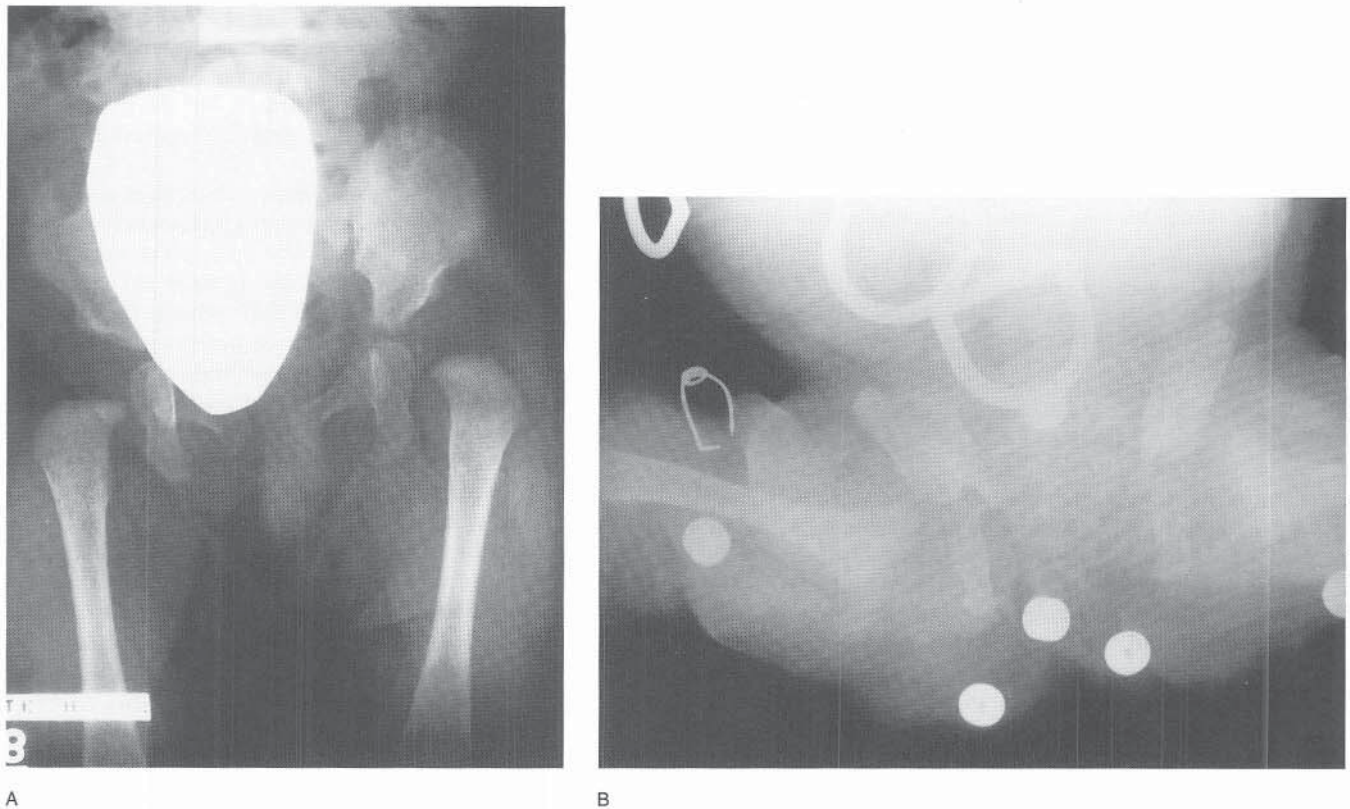


FIGURE 15–39 Use of the Pavlik harness in a child with a dislocated left hip. A, AP radiograph obtained at presentation at age 5 months shows a dislocated left hip. B, AP radiograph of patient in the harness with inadequate flexion.

show the cause of the instability, and the hip should be managed with either closed or open reduction. If the hip is reduced at 3 weeks but dislocates on examination, the harness should be worn for 3 to 6 more weeks until the hip stabilizes.

Treatment of the Young Child (Ages 1 to 6 Months)

THE PAVLIK HARNESS

The child presenting between 1 and 6 months of age may have an unstable hip similar to that seen in the neonate, or the hip may remain dislocated. The Pavlik harness is the first choice of treatment in this age group. To be effective, the harness must hold the hips in more than 90 degrees of flexion, with the position of the upper femoral metaphysis pointed toward the triradiate cartilage. An AP radiograph of the pelvis is obtained at the time of application of the harness to confirm this position. If the hip cannot be placed in this position, the harness is unlikely to relocate the hip. The hip does not have to be reducible at the time of the clinical examination to be successfully treated with the harness, but higher dislocations are less likely to reduce than lower ones.

The plan of treatment is similar to that for younger infants, but management must be continued until hip stability is assured (Fig. 15–39). The child is examined weekly, and reduction is evaluated by clinical and ultrasound exami-

nations. If reduction is not obtained within 3 to 4 weeks, the harness should be discontinued and other treatment begun. If reduction is confirmed, the harness should be continued for about 6 weeks after stability is established. When harness treatment is completed, some clinicians elect to place the child in an abduction splint for several more months. We recommend treating older children for a longer period of time to encourage acetabular development. For example, a 6-month-old child might be treated for a total of 6 months. However, exact guidelines for stopping treatment are lacking.

As the harness is discontinued, another AP radiograph is obtained to assess hip reduction and acetabular development. A notch above the acetabulum often appears after the hip is reduced, and this finding is usually followed by improved acetabular development (Fig. 15–40). Acetabular development may be enhanced by abduction splinting, but controlled studies have not been conducted to confirm the efficacy of this common practice.

Several series document the results of harness treatment. A review of a large European series of patients found that 95 percent of initially dysplastic hips were normal after treatment.⁶⁶ Eighty percent of hips that were dislocated and not initially reducible were successfully reduced with the harness. Higher dislocations had a higher failure rate. The rate of avascular necrosis (AVN) was 2.38 percent. A Japanese study found that infants who were hospitalized for harness treatment had a 28 percent incidence of AVN, whereas those managed at home had a 7.2 percent rate of AVN.⁸⁷ The explanation for this outcome was that the chil-

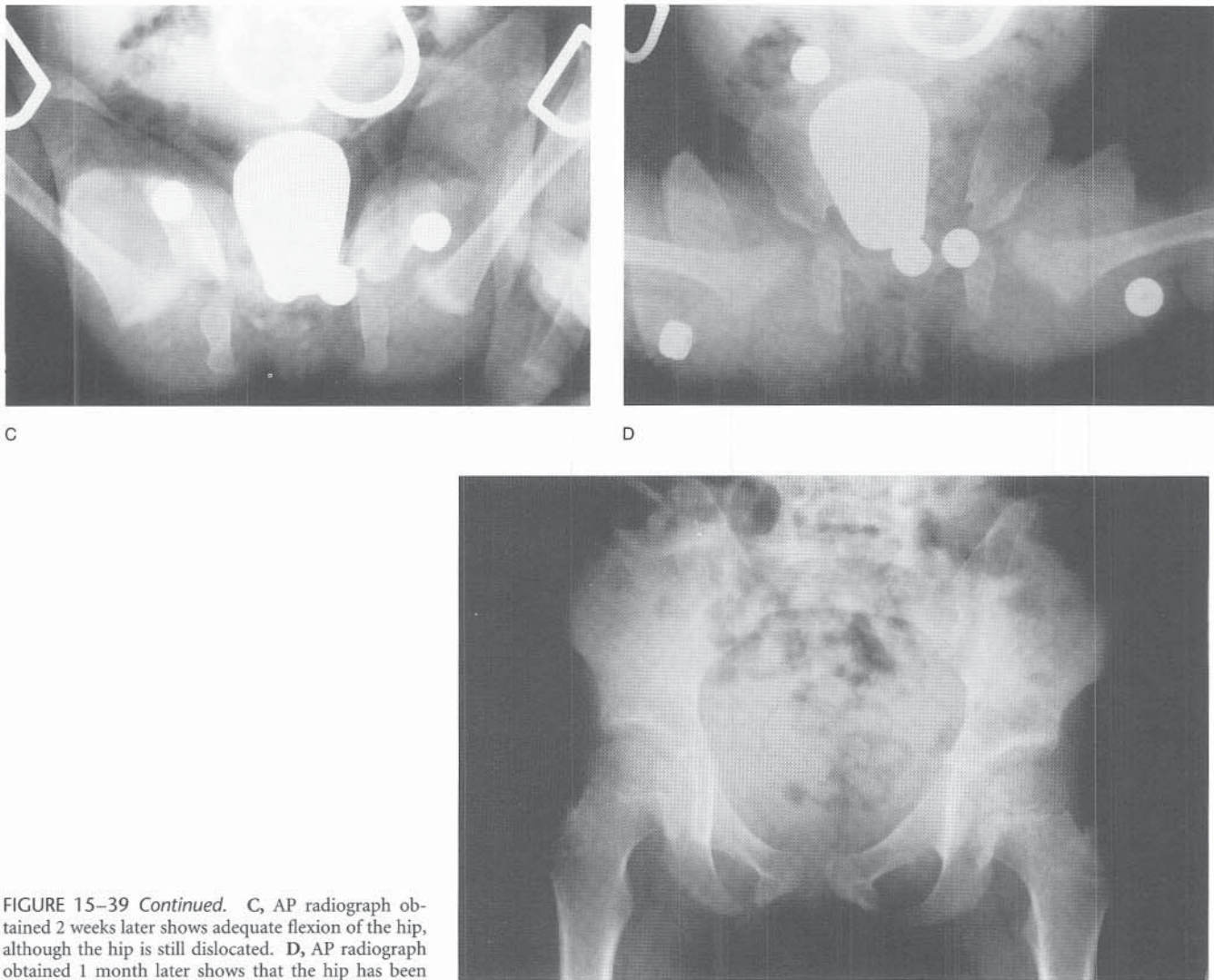


FIGURE 15-39 *Continued.* C, AP radiograph obtained 2 weeks later shows adequate flexion of the hip, although the hip is still dislocated. D, AP radiograph obtained 1 month later shows that the hip has been reduced. E, AP radiograph obtained at age 5 years shows good acetabular development.

dren in the hospital were handled less and immobilized more than those at home. Other studies have confirmed that high dislocations are less likely to reduce and are more likely to have a higher rate of AVN than low dislocations. With high dislocations, just over 50 percent of the hips in the harness reduced, and the rate of AVN was as high as 27 percent.²⁰⁴ Overall, the reported rate of AVN when the Pavlik harness is used ranges from zero to 15 percent.^{18,94,212} Factors associated with failure of Pavlik harness treatment include patient age greater than 7 weeks at treatment, bilateral hip dislocation, and an absent Ortolani sign.²²¹ Whenever the harness is used, Pavlik's credo should be remembered: "The main aim of the treatment is to achieve concentric reduction and to prevent avascular necrosis, which cripples the child for the whole of his life."¹⁶²

PROBLEMS AND COMPLICATIONS ASSOCIATED WITH THE PAVLIK HARNESS

Problems and complications other than AVN that can arise from the use of the harness include failure to reduce the

hip, femoral nerve palsy, and so-called Pavlik disease. Pavlik disease was reported by Jones and associates, who found that prolonged positioning of the dislocated hip in flexion and abduction potentiated dysplasia and resulted in a hip likely to need an open reduction.⁹⁰ They noted flattening of the posterolateral acetabulum in these hips and recommended discontinuing the harness if reduction had not occurred in 3 or 4 weeks. Tucci and associates reported on 74 hips successfully treated with the Pavlik harness that were followed to an average age of 12 years after treatment.²¹⁸ They found that 17 percent of the hips had an increased upward tilt and sclerosis of the acetabulum, and they emphasized the need for long-term follow-up of treated hips.

OTHER SPLINTS AND BRACES

A variety of other splints and braces have also been used to treat DDH. When selecting a treatment method, it is important to remember that the splint should position the hips so that reduction can occur spontaneously. The hips must never be rigidly immobilized, and forced positions

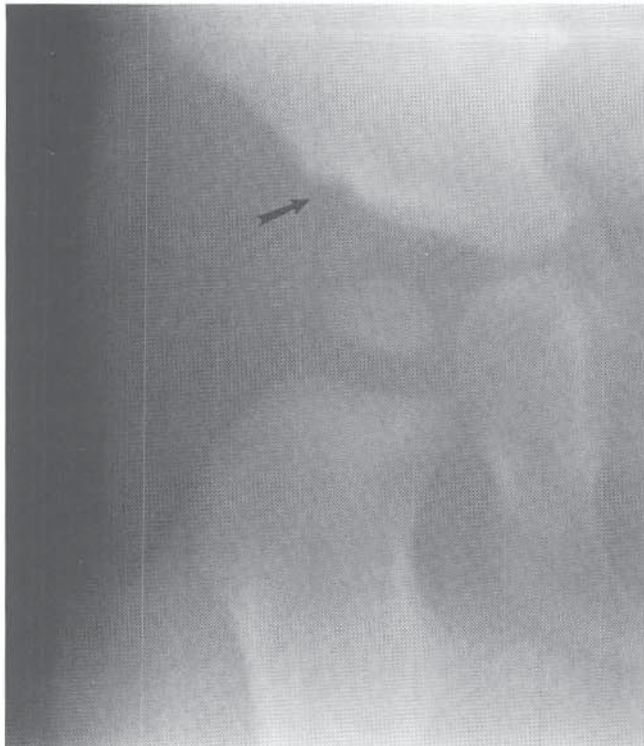


FIGURE 15-40 Radiographic appearance in a 7-month-old child after successful treatment of DDH with a Pavlik harness. The notch (*arrow*) at the lateral margin of the acetabulum represents ossification into the labrum and is often seen after successful early treatment of DDH.

should not be used. Wide abduction and forced internal rotation must always be avoided, as these positions cause AVN of the soft femoral head. The Ilfeld splint has been reported to have a high rate of success with few complications (Fig. 15-41),¹⁰⁰ as has the Von Rosen splint (Fig. 15-42).¹⁷⁸

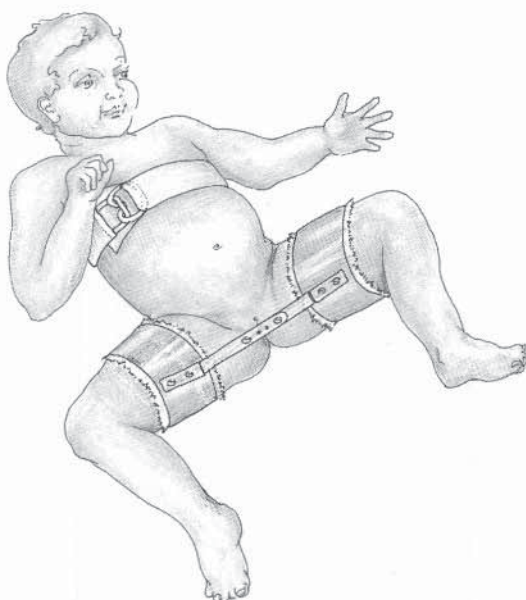

FIGURE 15-41 The Ilfeld or Craig splint.

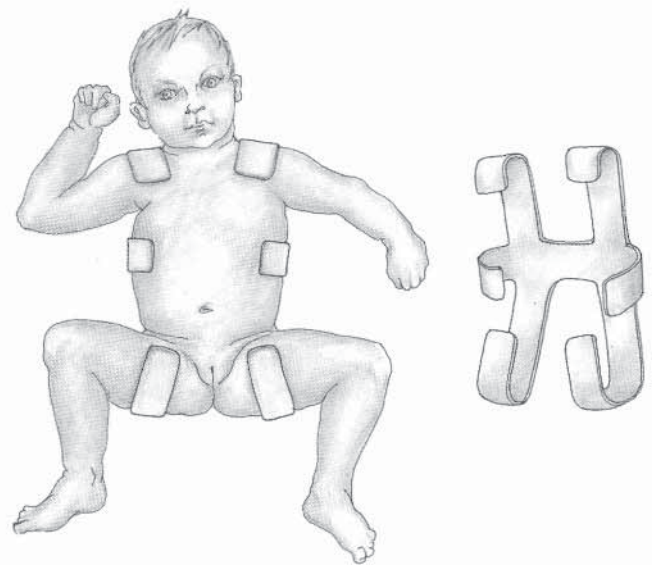


FIGURE 15-42 The Von Rosen splint.

THE FREJKA PILLOW AND TRIPLE DIAPERS

A device that is frequently associated with a poor outcome is the Frejka pillow. The Frejka pillow is capable of forcefully abducting the hips of the infant and is associated with an unacceptably high rate of AVN (Fig. 15-43). One report found that half of grade II dislocated hips developed AVN.²¹² Another study reported a 14 percent rate with the pillow.^{110,111} The use of triple diapers should also be abandoned. Triple diapers do not effectively position the hips, and their use may falsely suggest to parents that something positive is being accomplished.

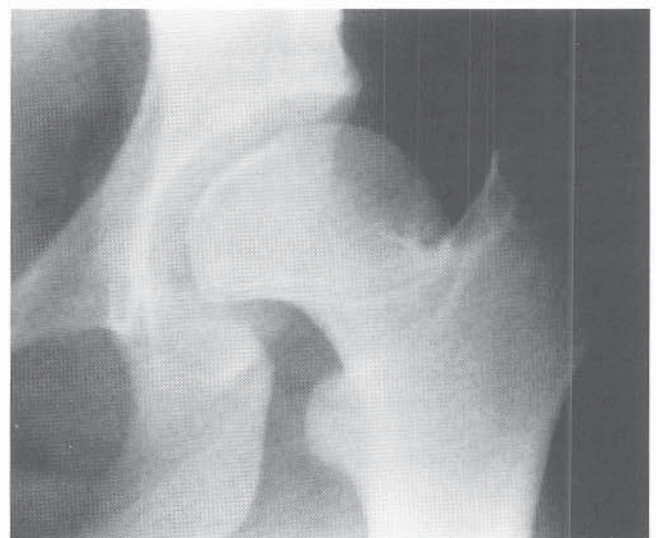


FIGURE 15-43 Avascular necrosis after use of the Frejka pillow. AP radiograph obtained at age 16 years shows a shortened femoral neck with trochanteric overgrowth. The valgus tilt of the femoral head indicates a lateral physeal injury from avascular necrosis.

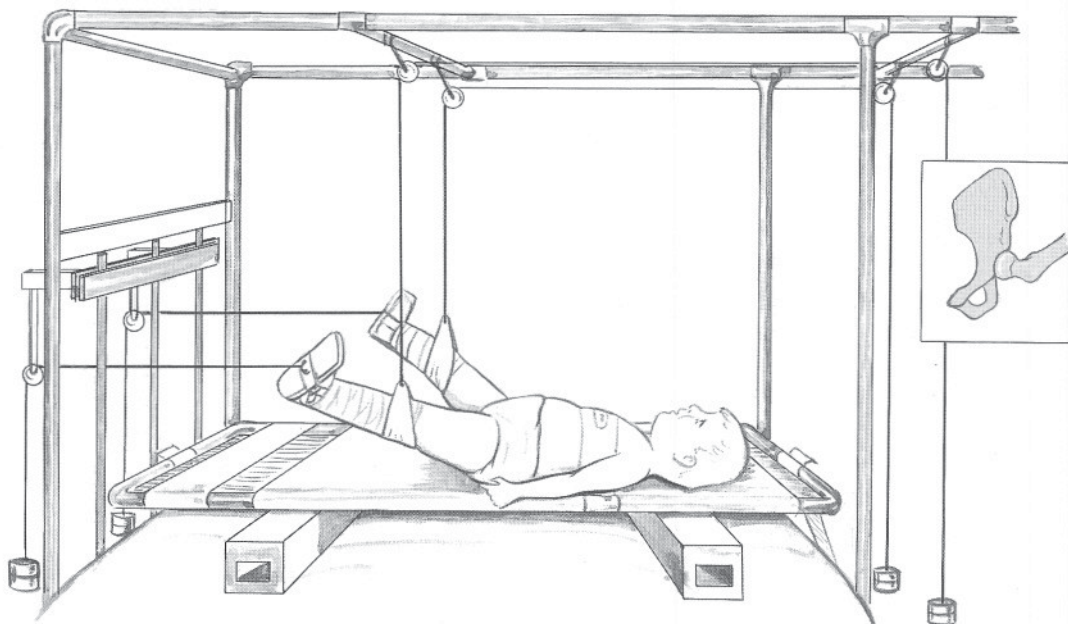


FIGURE 15-44 Traditional traction position with a frame in the bed and the hips flexed 30 degrees. (From Tachdjian MO (ed): *Congenital Dislocation of the Hip*. New York, Churchill Livingstone, 1982.)

Treatment of the Child (Ages 6 Months to 2 Years)

GENERAL GUIDELINES

The child who presents with a dislocated hip between ages 6 months and 2 years and the child in whom initial splintage has failed are managed in the same manner. The goals of the treatment are to *obtain* and *maintain* reduction of the hip without damaging the femoral head. The two principal methods of treatment are closed reduction and open reduction, either of which may be preceded by a period of traction.

TRACTION

For many years, prereluction traction was considered essential to reduce the incidence of AVN and to enable the surgeon to obtain a closed reduction.* An important early study by Salter and associates shed light on the relationship between treatment and AVN.¹⁸⁴ Three different treatment methods were analyzed. In one group, the hips were reduced into a Lorenz or Lange position of extreme abduction without preliminary traction, resulting in a 30 percent incidence of AVN. In the second group, the same cast position was used after preliminary traction, and there was a 15 percent rate of AVN. In the third group, the child was placed in the "human position" of 90 degrees of flexion and mild abduction, and the rate of AVN fell to 5 percent. A second classic study by Gage and Winter demonstrated a significant reduction in the incidence and severity of AVN when traction was used to bring the femoral head to a "station" below Hilgenreiner's line.⁵⁵

Other research has evaluated the use of traction to achieve

closed reduction and avoid open reduction. DeRosa and Feller successfully treated 85 hips with traction over an average of 18 days, achieving a closed reduction in 91 percent of these hips without a case of AVN.³⁸ Tavares and associates reported on 27 hips treated with guided abduction traction, of which 74 percent were reduced by closed reduction and only two hips developed AVN.²⁰⁹ Camp and associates compared children treated with home traction to those treated in the hospital.²² They found no difference in the rate of AVN (less than 5 percent) or in the rate of open versus closed reduction (66 percent closed reduction).

The need for traction has been challenged by a number of studies showing that hips can be safely reduced without preliminary traction. Weinstein and Ponseti treated 22 hips with open reduction through a medial approach without preliminary traction and reported a 10 percent incidence of AVN.²⁴⁰ Kahle and associates reported findings in 47 hips treated without preliminary traction.⁹² Although AVN developed in only 4 percent, open reduction was necessary in 43 percent. Although some authors have suggested that the lack of traction increases the need for open reduction,⁷⁷ others disagree. Quinn and associates studied 90 hips treated with 3 weeks of traction and found that the rate of open reduction (42 percent) was similar to that in studies in which traction was not used, and they concluded that there was no need for traction.¹⁶⁸ Weinstein has stated that there are no studies showing that traction is necessary to prevent AVN, and its use therefore is anecdotal.²⁴¹

Several aspects of current treatment of DDH that have contributed to a reduced frequency of AVN include the use of gentle reduction, the use of the human position when maintaining reduction, and avoiding the temptation to hold the hip reduced at any cost. Certainly a low rate of AVN has markedly improved the outcome of DDH. The use of traction may improve the chances of achieving a closed reduction, but there are so many different application methods that

*See references 19, 36, 38, 109, 120, 146, 233, 251.

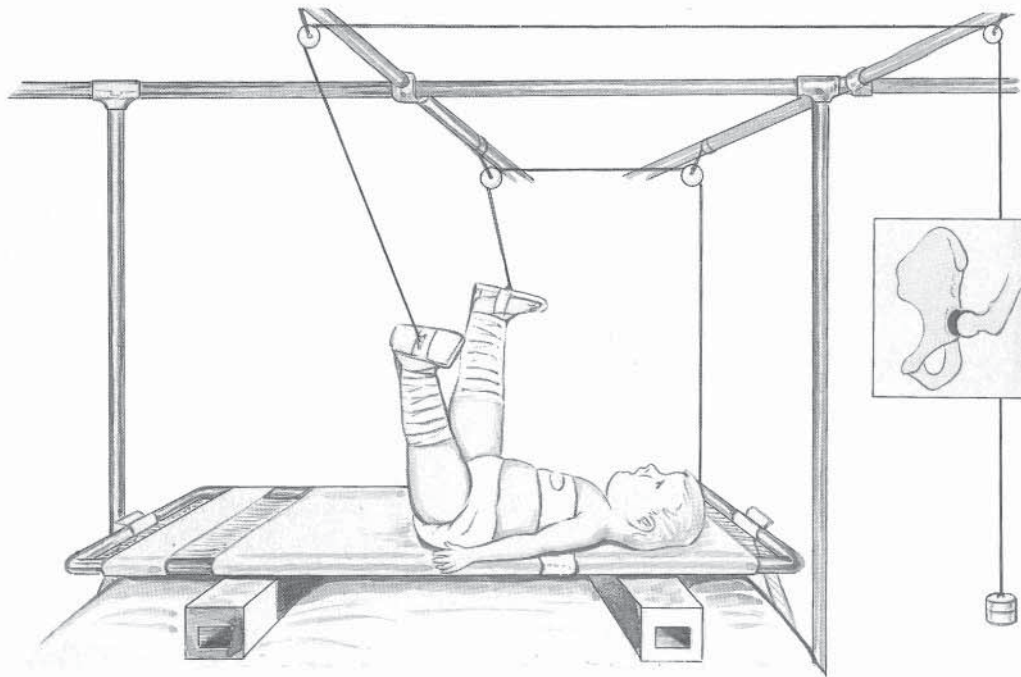


FIGURE 15-45 Bryant's traction position: the child lies in bed (or a crib) with the hips flexed 90 degrees and the knees extended. (From Tachdjian MO (ed): *Congenital Dislocation of the Hip*. New York, Churchill Livingstone, 1982.)

the need for traction remains unproved. Despite the many studies questioning its efficacy, traction continues to be used in many centers. Traditional prerduction traction is performed with the baby's hips placed in 20 to 30 degrees of flexion by means of a frame or other immobilizing device in the crib, and traction applied with adhesive straps placed on the thighs and legs (Fig. 15-44).³⁸ In Gage and Winter's classic article, the level of the femoral head was determined and traction was continued until the head was below Hilgenreiner's line, often requiring 3 weeks or more in the hospital.⁵⁵ Others prefer an alternative position, Bryant's position, in which the hips are flexed 90 degrees and the knees are extended (Fig. 15-45).

The most vigorous use of traction has been reported by Morel in France, who used traction not only to stretch the soft tissues about the hip but also to reduce the femoral head.¹⁴⁶ This "traction reduction" method involves immobilizing the child in bed and applying gradually increasing skin traction to bring the femoral head below the acetabulum. The hips are then gradually abducted and internally rotated until the hip is reduced. The traction is then reduced and a cast is applied. This approach often requires 6 or more weeks of in-hospital treatment, and results in little or no AVN.

The method we prefer is portable home traction.^{22,91} The child is placed in skin traction with the hip flexed 90 degrees in a frame made of PVC pipe, which can easily be transported in a wagon or on the parent's lap. The child is allowed free motion in the frame, except for the straps on the legs (Fig. 15-46). The straps should be carefully applied to avoid skin injuries. Some surgeons gradually abduct the patient's legs; others leave the legs in neutral position. Treatment is continued for 2 to 3 weeks. The child is allowed out of traction for feeding and diaper changes.

CLOSED REDUCTION

Closed reduction of the hip should be performed using general anesthesia or deep sedation (Plate 15-1). The young orthopaedist should be wary of this seemingly simple procedure. Proper performance and interpretation of the closed reduction is difficult and requires experience. It may be better to think of positioning the hip rather than reducing it, as no real manipulation should be done. The hip is reduced by placing it in flexion beyond 90 degrees and gradually abducting it, while gently lifting the greater trochanter, as in the Ortolani maneuver. Minimal force should be applied. After a palpable reduction is felt, the hip is

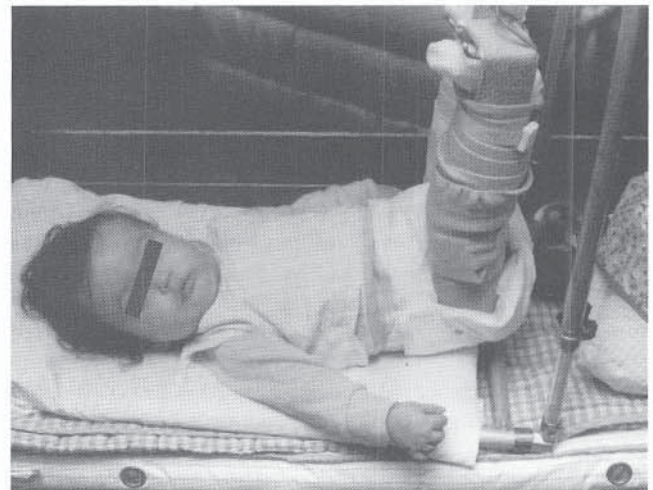


FIGURE 15-46 Portable home traction frame of PVC pipe. The "little red wagon" is an essential part of the treatment.

moved to determine the range of motion in which it remains reduced. The hip is adducted to the point of redislocation and that position is noted. The hip is again reduced and then extended until it dislocates, and the point of dislocation is noted. If the hip requires internal rotation to maintain reduction, this is also noted.

The range of motion in which the hip remains reduced is compared to the maximum range of motion. From this information, a “safe zone” is constructed, as described by Ramsey and associates (Fig. 15–47).¹⁷¹ If the zone is relatively wide, the reduction is considered stable. On the other hand, if wide abduction or more than 10 or 15 degrees of internal

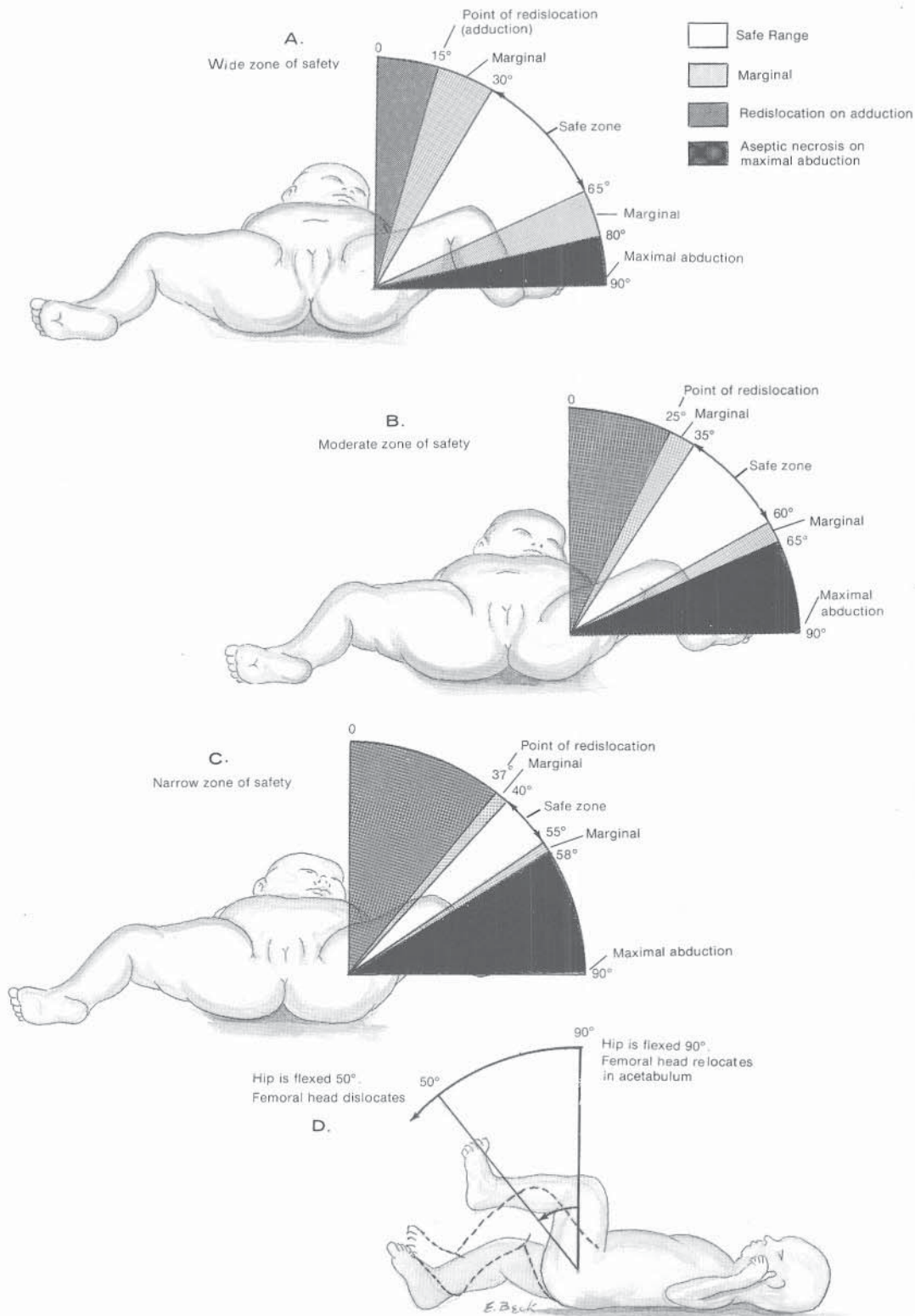


FIGURE 15–47 A to D, Zone of safety.

Closed Reduction and Casting for Developmental Dislocation of the Hip

A, The first step of this procedure, evaluating the reduction of the hip, is probably the most important. With the baby completely anesthetized, the surgeon gently performs Ortolani's maneuver by grasping the thigh, applying mild longitudinal traction, lifting the greater trochanter with the fingers, and abducting the hip to reduce the femoral head. The reduction should be done with the hip flexed about 120 degrees. Once the patient's hip reduces, the surgeon evaluates the stability by extending the hip to the point of redislocation and adducting the hip to the point of redislocation. A reduction is considered stable if the hip can be adducted 20 to 30 degrees from maximum abduction and extended to below 90 degrees without redislocation.

An arthrogram may be obtained at this time to further assess the adequacy of the reduction. If the adductors are tight on palpation in the reduced position, tenotomy of the adductor longus may be performed to reduce pressure on the hip.

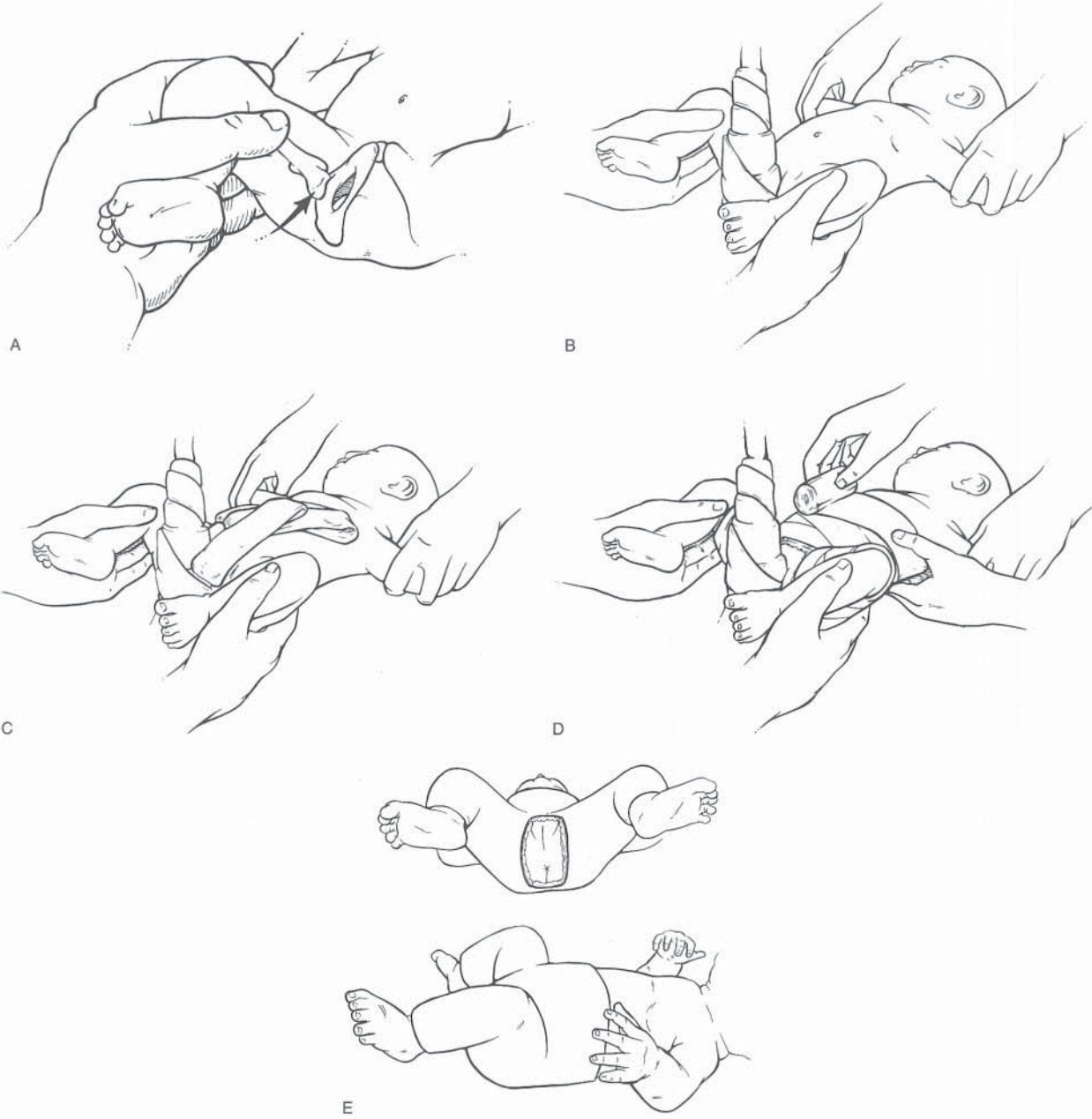B, Once the reduction is established, the baby is placed on the infant spica table for cast application. The head of the table is raised to assist in keeping the perineum against the center post. At this point, the surgeon should be certain of the reduction of the hip, and should hold the hips to maintain reduction while avoiding extremes of abduction or internal rotation.

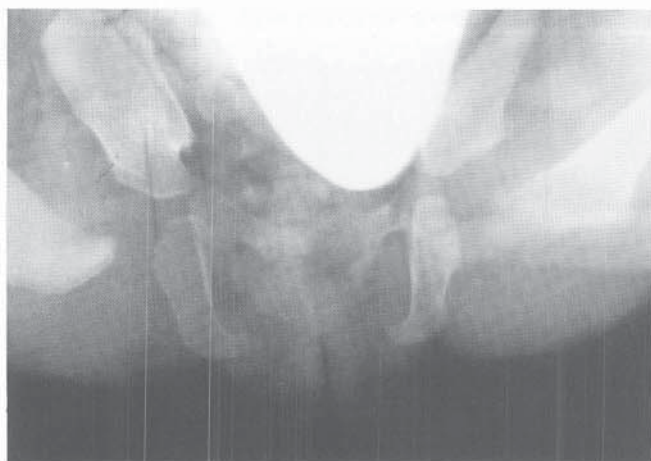
C, A rolled towel or stockinette is placed over the child's abdomen and later removed to allow for breathing room in the cast.

D, Cast padding is applied around the abdomen in a figure-eight pattern around the groin and then down the legs. The first cast is usually applied to midcalf on the affected extremity and to above the knee on the contralateral leg. If available, a layer of moisture-control material, such as Gore-Tex, may be placed against the skin to prevent wetness. Casting material, usually fiberglass, is then rolled over the areas to be enclosed. During the entire procedure the surgeon must continually assess the hip position by abducting the hips maximally and "backing off" at least 15 degrees to avoid the hip's sagging into full abduction.

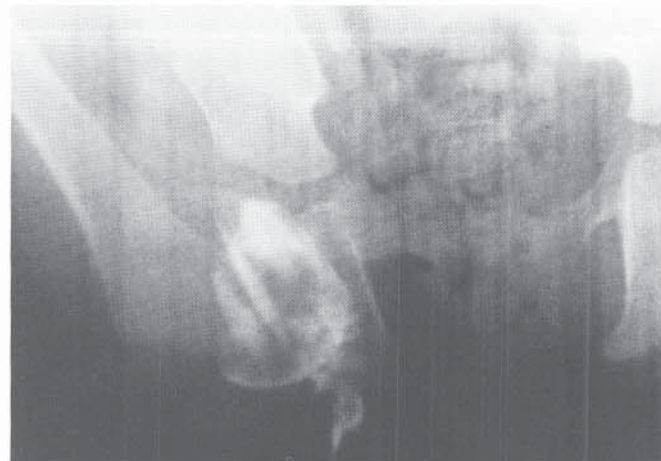
E, The baby is taken off the table and the cast is windowed for perineal access. Radiographs are obtained at this point to ensure reduction. If any doubt remains regarding reduction, minimal-cut CT is useful in confirming the hip position.

PLATE 15-1. Closed Reduction and Casting for Developmental Dislocation of the Hip

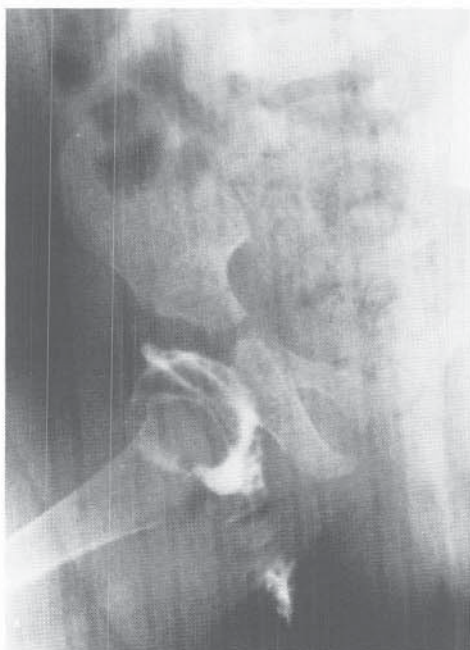




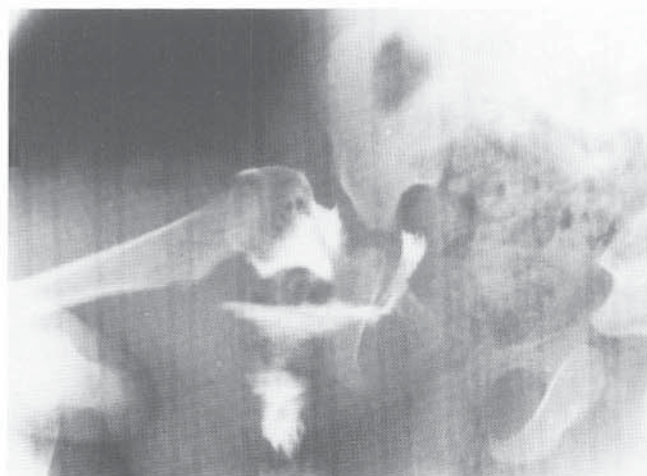A



B



C



D

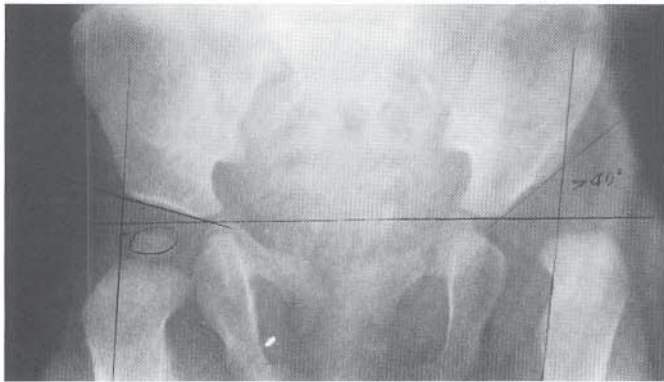
FIGURE 15-48 Images of a 10-month-old child treated with a Pavlik harness. The hip subluxated inferiorly while in the harness. Closed reduction revealed the problem. **A**, AP radiograph obtained with the child in the harness. **B**, Arthrogram obtained in the hyperflexed position shows inferior subluxation of the femoral head. **C**, Arthrogram obtained in abduction and neutral flexion shows good reduction. **D**, Arthrogram obtained in the dislocated position shows the blunted margin of the labrum.

rotation is required to maintain reduction, the reduction is considered unstable. At times, an adductor tenotomy will increase the safe zone by allowing a wider range of abduction. However, wide abduction should never be used, as this has been shown to cause AVN. Excessive internal rotation is also a known cause of AVN and must be avoided.

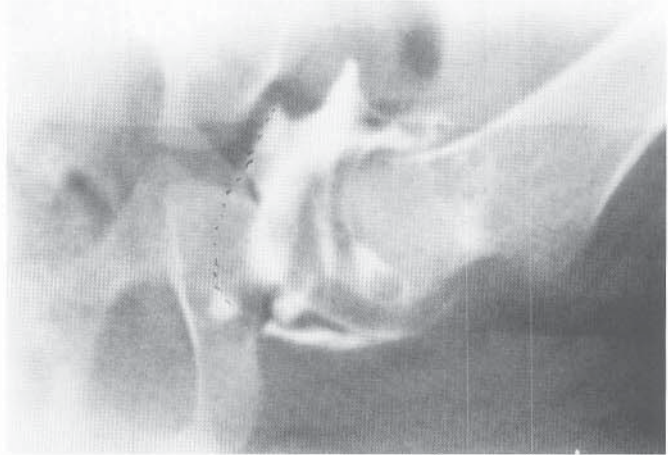
An arthrogram obtained at the time of reduction is very helpful for evaluating the depth and stability of the reduction. The positions of reduction and dislocation are noted on the arthrogram, and a “live” observation of the reduction shows the depth of reduction and the obstacles encountered. Some infolding of the labrum is commonly noted, as are constriction of the capsule by the iliopsoas and the presence of the ligamentum teres between the femoral head and the acetabular wall. The width of the medial dye pool on a standard AP radiograph indicates the likely stability of the reduction and can be rated as good, fair, or poor.¹⁶⁹ A narrow

rim of contrast agent indicates that the femoral head is well seated and stable, and the reduction can be classified as good (Fig. 15-48). A fair reduction has a 5- to 6-mm dye pool and is easily held reduced (Fig. 15-49). A poor reduction has a medial space wider than 6 mm and the reduction is difficult to hold (Figs. 15-50 and 15-51).

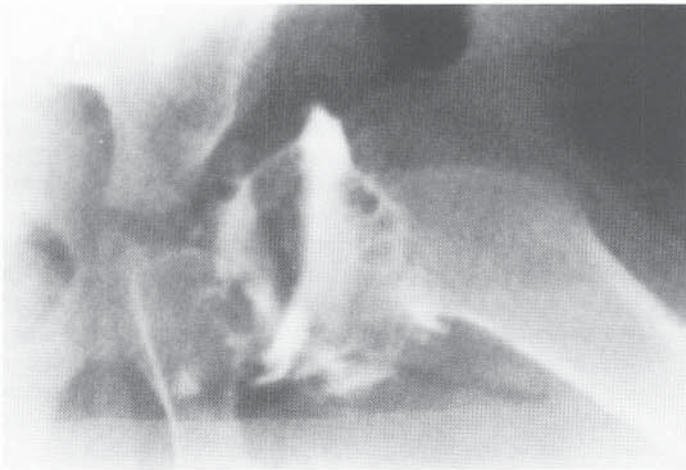
A number of factors help the clinician determine whether a hip is stable or unstable. In addition to range-of-motion considerations, there is a certain “feel” to the reduction. A stable hip remains reduced throughout most of the joint’s range of motion, dislocating only in adduction or extension. An unstable hip redislocates easily, and the examiner must continue lifting up the greater trochanter to maintain the reduction. If a reduction is difficult to maintain, closed reduction should be abandoned and open reduction performed. Forceful maintenance of an unstable reduction is likely to cause AVN. In many cases the femoral head will



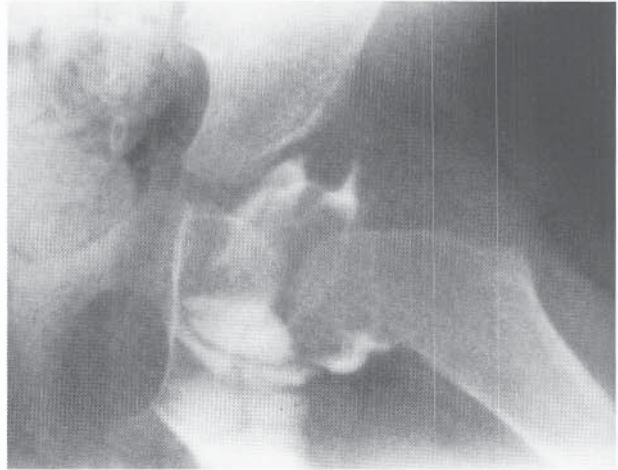
A



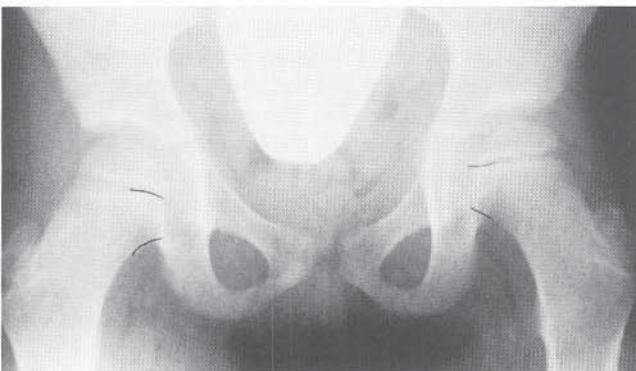
B



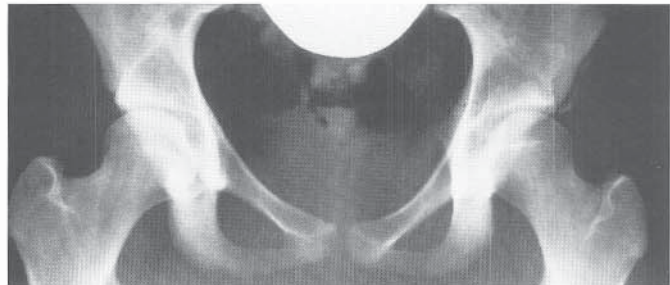
C



D



E



F

FIGURE 15-49 Girl with left-sided DDH. **A**, AP radiograph at age 1 year shows left-sided DDH. **B**, Arthrogram obtained after 2 weeks of traction. In the “human” position, the labrum is blunted and the dye pool is 5 mm wide. **C**, Arthrogram obtained with the hip in internal rotation shows better seating of the femoral head. This would be classified as a fair reduction. **D**, Arthrogram obtained at a cast change 6 weeks later shows better seating of the femoral head with persistent blunting of the labrum. **E**, AP radiograph obtained at age 6 years shows a well-developed femoral head and acetabulum. **F**, AP radiograph obtained at age 15 years shows well-developed hips.

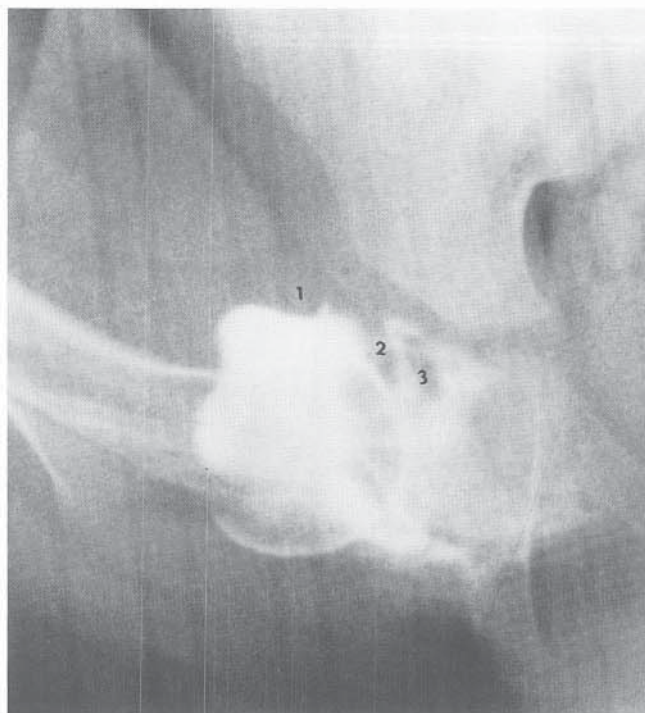


FIGURE 15-50 Example of a poor reduction, with obstruction to reduction. Labeled structures: 1, zona orbicularis; 2, infolded labrum; and 3, ligamentum teres.

“reduce” to a stable position at the introitus of the acetabulum, abutting the labrum and iliopsoas but not actually in contact with the acetabular medial wall. If stability can be maintained in a nonextreme physiologic position, the hip may be immobilized and will usually become well seated over a 6-week period. This phenomenon was described in Severin’s classic article of 1941 and by others, and our experience with this approach has also been successful.^{23,169,187,197}

Other authors believe that any widening of the joint is unacceptable and that the femoral head should not be used as a sound to dilate the acetabular opening.^{29,128,172,237} Leveuf distinguished two patterns of docking of the hip.^{123,124} He defined a subluxation pattern in which the limbus is pressed upward against the pelvis and found that these hips did well with closed reduction. He also identified a dislocation pattern in which the limbus is inverted between the femoral head and acetabulum and thought that this group needed open reduction.

If the reduction is deemed stable, the child is then immobilized in a spica cast in a safe, stable position. Some surgeons use a Pavlik harness, but most prefer a spica cast. The cast should maintain the hip in a position of more than 90 degrees of flexion and enough abduction to maintain the reduction. Some internal rotation may be used, but no more than 10 to 15 degrees, and never to the limit of internal rotation. Likewise, abduction to 30 or 40 degrees is acceptable as long as further abduction is available. Abduction to the limit of abduction should be avoided. The most experienced person should hold the hip in proper position while the cast is being applied. An effective technique to prevent excessive abduction during the cast application is to frequently abduct the hips maximally and then return to a less abducted position to be certain of the position of the hips.

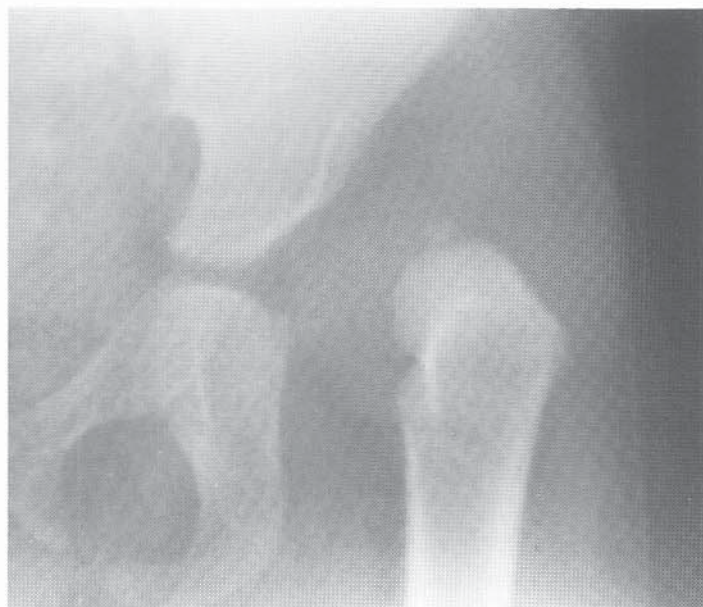After the cast is applied, an intraoperative radiograph is obtained. After the procedure single-section computed tomography (CT) (Fig. 15-52) or ultrasound may be used to confirm the reduction.^{75,76} After 6 weeks of immobilization, the cast is removed under anesthesia and the hip is gently examined for stability. No effort is made to dislocate the hip, but stability is assessed through a moderate range of motion. An AP radiograph of the pelvis is obtained and, if the hip is reduced, a new cast is applied again in the human position. If there is any question regarding reduction (either on the examination or the radiograph), arthrography should be performed. After 6 weeks the second cast is also removed under anesthesia, and the surgeon must decide on the need for further immobilization. We usually apply a third cast for another 6 weeks and discontinue immobilization at the end of that period. Others prefer to begin abduction splinting after 12 weeks in a cast, and this approach may be equally efficacious. Prolonged abduction splinting has not proved efficacious, but the practice is recommended in some centers.

OPEN REDUCTION

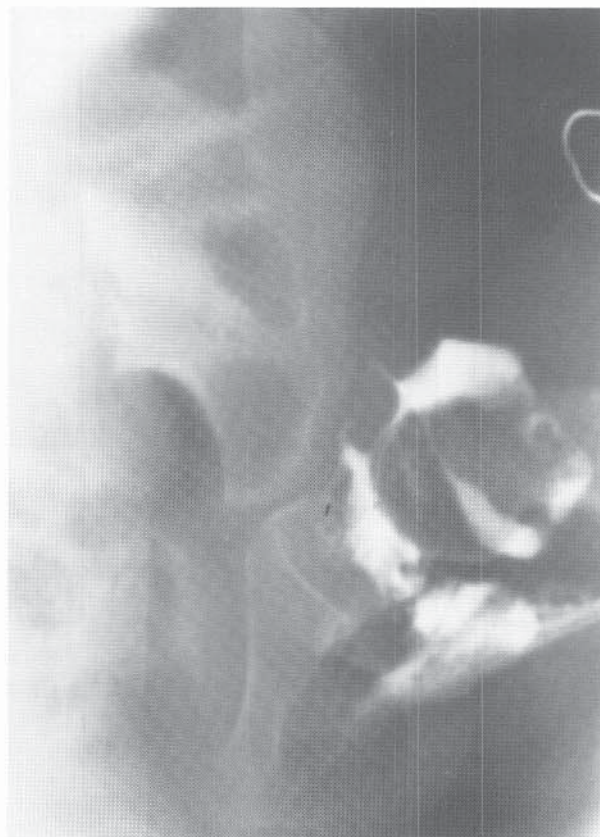
There are several indications for performing an open reduction. The first is failure to obtain a stable hip with a closed reduction. Failure may be evident at the time of the initial closed reduction, or it may become apparent when a hip redislocates in the cast or at the time of a cast change (see Fig. 15-51). In some centers, an open reduction is the preferred treatment method and a closed reduction usually is not attempted. Other clinicians accept a perfect closed reduction but recommend an open reduction if there is any widening of the joint space between the femoral head and the acetabulum. The more common approach is to accept closed reductions that are stable with mild to moderate widening of the joint, and to perform open reductions for unstable hips and those that are excessively wide on arthrography.

Open reduction may be performed from one of several medial approaches or from an anterior approach. The medial approach is preferred by many surgeons because minimal dissection is required and the obstructions to reduction are encountered directly. The disadvantages of the medial approach are a limited view of the hip, possible interruption of the medial femoral circumflex artery, and inability to perform a capsulorrhaphy. Others prefer the anterior approach because it affords better exposure and allows the surgeon to perform a capsulorrhaphy. The choice of a medial or anterior approach is also related to the presence of ligamentous laxity requiring capsulorrhaphy, the patient’s age, and the surgeon’s training and experience.

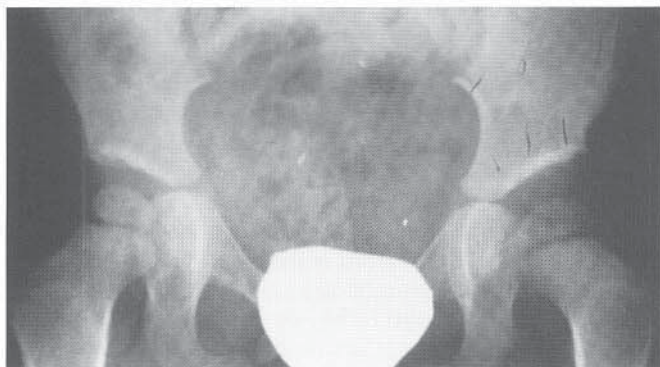
Medial Approach. The first medial approach to open reduction of a dislocated hip was reported by Ludloff in 1913.¹³¹ He approached the hip through an incision paralleling the adductors, using the interval between the pectineus and iliopsoas, anterior to the pectineus. There was little interest in this technique until 1957, when Chiari reported on 47 cases treated successfully with this approach.²⁸ Subsequent reports have indicated that this approach adequately releases or removes the obstacles to reduction, allowing the surgeon to obtain a stable reduction without undue risk of



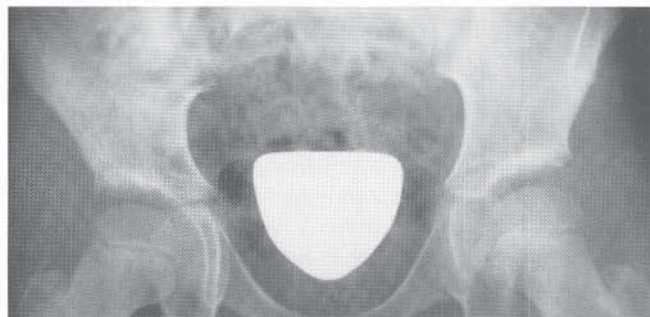
A



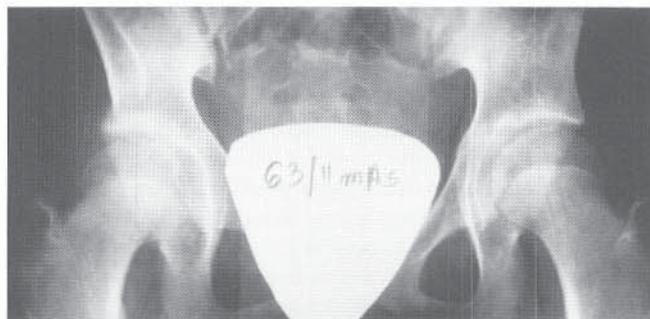
B



C



D



E

FIGURE 15–51 Child with left-sided DDH. A, AP radiograph obtained at 16 months of age shows left-sided DDH. B, Arthrogram obtained after 2 weeks of traction shows a poor reduction and a blunted labrum. An open reduction was performed via an anterior approach. C, AP radiograph obtained at age 3 years shows mild acetabular dysplasia. D, AP radiograph obtained at age 7 years shows improved acetabular development. E, AP radiograph obtained at age 13 years shows excellent acetabular development.

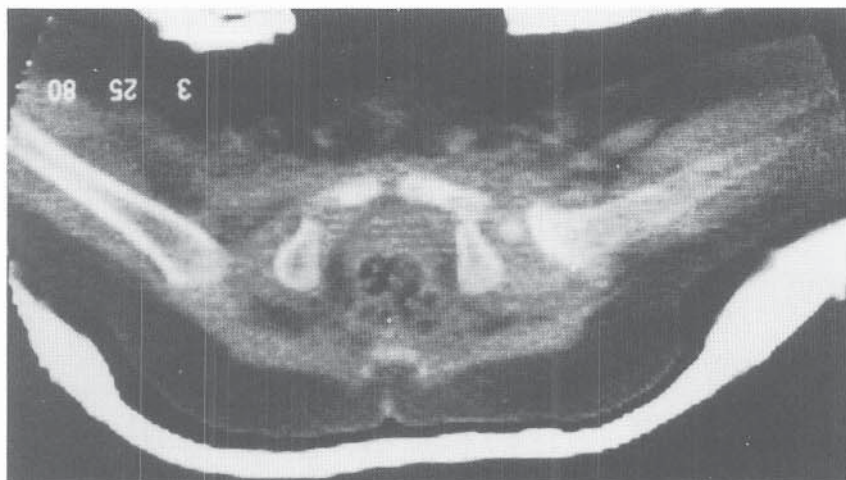

FIGURE 15-52 CT scan after a closed reduction; the patient is in a cast. Persistent dislocation of the hip is apparent on the scan.

AVN.^{135,235,239} Another medial approach, one that uses the interval between the adductor brevis and the adductor magnus, was reported by Ferguson,⁵⁰ but there are few other reports of this procedure.

Although the medial approach has been successfully used in children up to 3 years old, we recommend it for children age 1 year and younger. In the older child we prefer an anterior approach, which allows a capsulorrhaphy to be performed.^{135,235,239}

Although the anatomic details of the medial approach are uncomplicated, the procedure itself can become difficult because the exposed area is narrow and the child is often small and chubby (Plate 15-2). The medial femoral circumflex vessels cross the operative field and should be carefully retracted. Some surgeons suggest ligation of the vessels, but ligation may compromise the vascular supply of the upper femur. A small amount of bleeding from these vessels will make the operation difficult because of the narrow exposure. In short, this is not an operation for the inexperienced surgeon. The iliopsoas is transected and the hip capsule is incised to expose the joint. Removal of the ligamentum teres significantly increases the exposure and allows a deeper reduction of the femoral head. A radiograph is obtained to assess reduction. If the head is not ossified, a radiographic marker (such as a fine wire rolled into a disk shape) may be placed over the femoral head to locate it more precisely on the intraoperative radiograph.

After the open reduction, we place the child in a below-knee spica cast in the human position, with the hip in more than 90 degrees of flexion and moderate abduction (well short of maximal abduction). An intraoperative radiograph is obtained to confirm the reduction. A single-section CT scan following the procedure also is useful in this regard. The cast is changed after 6 weeks and an above-knee cast is applied with the hip in the same position. Thereafter some clinicians use abduction splinting for another 3 to 6 months, depending on the development of the acetabulum; however, the need for further splinting remains controversial.

Some authors have reported good results with the procedure, with a less than 5 percent incidence of AVN.²³⁴ Morcuende and associates recently reported a series of 93 hips in which a good result was obtained in 76 percent of cases.¹⁴⁵ A secondary procedure for residual acetabular dysplasia was

required in 26 percent of the hips. Of concern was the finding that 43 percent had significant AVN (24 percent had Bucholz-Ogden type II AVN, 14 percent had type III, and 3 percent had type IV). Because the incidence of AVN was higher in older children, they recommended that the procedure not be used in patients more than 2 years old. Reported rates of AVN after anteromedial open reduction have ranged from zero to 66 percent.* Others have reported problems with persistent lateral displacement of the femoral head and a frequent need for secondary procedures.⁴⁰

Anterior Open Reduction. The anterior approach to the open reduction of the hip has withstood the test of time (Plate 15-3).^{39,137} When performed through an oblique, almost transverse incision (the “bikini” incision), the cosmesis is excellent.¹⁸³ Wider exposure of the hip is achieved than with the medial approach, but exposure of the depths of the acetabulum may be difficult, especially in a high dislocation. After the obstacles to reduction are removed, a capsulorrhaphy should be performed to increase the stability of the reduction. The procedure should not be attempted by anyone who has not had adequate training in the technique.

A number of factors can make anterior open reduction difficult. When the femoral head is well above the acetabulum, the muscles about the hip are also displaced in a lateral and cephalad direction. Considerable dissection and retraction are necessary to expose the acetabulum. Many surgeons have mistaken the more easily exposed false acetabulum for the true acetabulum and have failed to reduce the hip. A radiograph should be obtained after the femoral head has been reduced to be sure the head abuts the triradiate cartilage. Before the radiograph is taken, the surgeon should remove the wedge from beneath the hip to level the pelvis, a step that allows more accurate evaluation of the reduction. If considerable force is required to reduce the hip and the reduction seems tight, the surgeon should perform a shortening femoral osteotomy to decompress the joint.

After the hip is reduced and the capsulorrhaphy performed, a spica cast is applied with the hip in an extended, abducted, and mildly internally rotated position. We apply the cast to below the knee on the affected side and above

*See references 50, 95, 108, 134, 135, 154, 194, 239.

the knee on the contralateral side. Bilateral open reductions may be performed in the same operative procedure by an experienced surgical team, or the second hip may be operated on after the cast has been removed from the first hip. After the procedure, single-section CT is used to confirm the reduction. After 6 weeks the hip is examined with the patient under anesthesia, and if the reduction is satisfactory, a second cast is applied. Some use a spica cast; others use long-leg plasters with a bar to maintain abduction and internal rotation. These “Petrie casts” allow flexion and extension and are used for 4 to 6 more weeks. The choice between the two is based on the perceived stability of the hip.

Open Reduction with Femoral Shortening. A femoral shortening should be considered when an open reduction has been performed and excessive pressure is placed on the femoral head when it is reduced (Figs. 15–53 to 15–55; Plate 15–4).^{58,185} Femoral shortening should be considered when a dislocated hip is reduced in a child more than 2 years old. One way to assess the tightness of the reduction is to attempt to distract the femoral head away from the acetabulum after reduction. If the reduction is safe, the

surgeon should be able to distract the joint a few millimeters without much force. We prefer to perform the shortening through a separate lateral incision. Blade plate or simple lateral plate fixation may be used with an intertrochanteric or subtrochanteric osteotomy (Plates 15–5 and 15–6).

In the past, femoral osteotomies were also used to reduce anteversion and to place the femoral neck into a varus position. However, we have not found excessive anteversion or valgus of the upper femur to be common, and therefore we do not usually do either derotation or varus correction.

Open Reduction with Innominate Osteotomy. An innominate osteotomy may be indicated at the time of an open reduction, especially in children age 18 months or older. The surgeon can assess the need for added coverage by noting the degree of acetabular coverage of the femoral head when the hip is placed in extension and neutral rotation and abduction. If more than one-third of the head is visible in this position, an innominate osteotomy will provide better hip coverage.

In some centers, most children over 18 months of age undergo a concomitant innominate osteotomy at the time of

Text continued on page 568

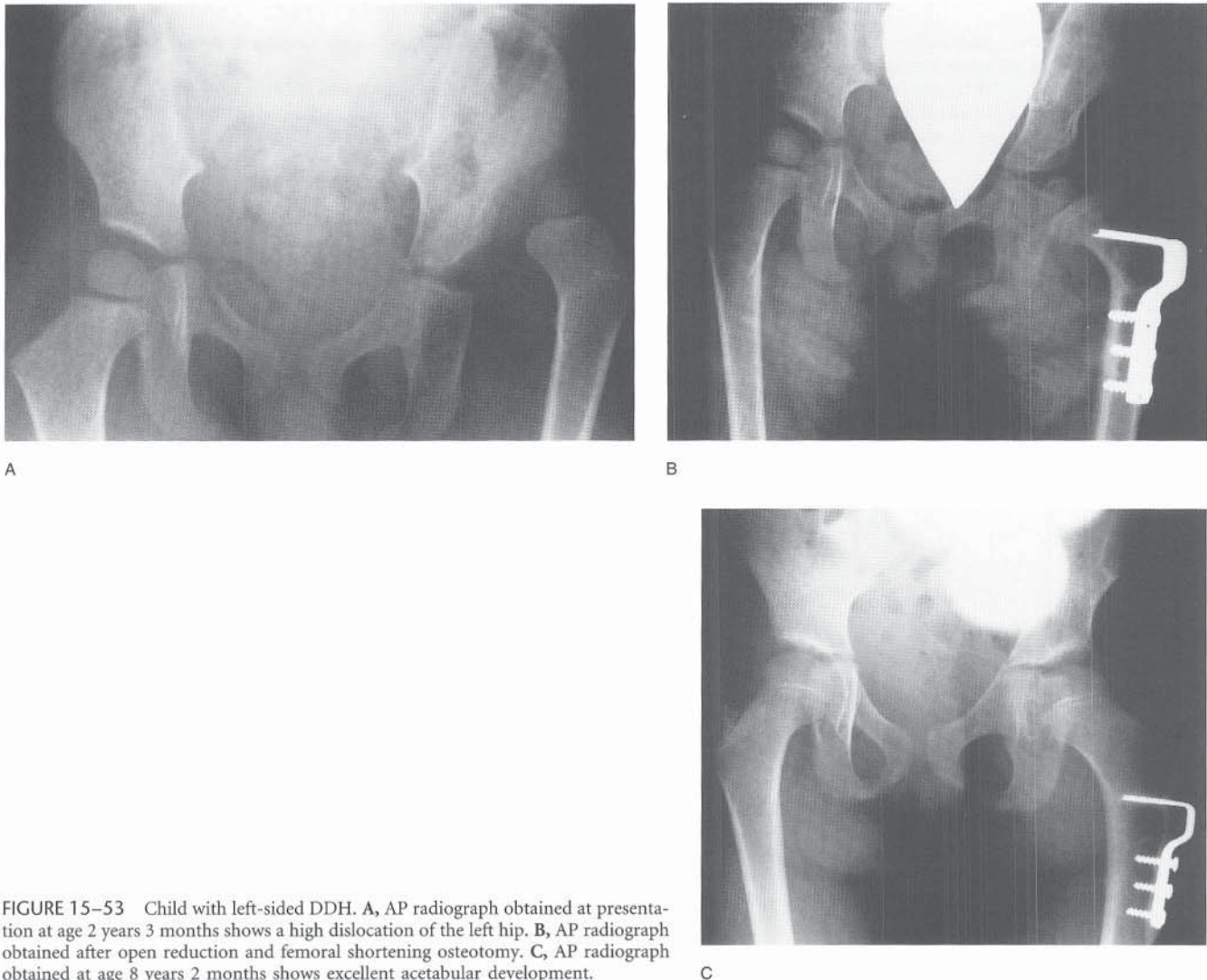


FIGURE 15–53 Child with left-sided DDH. A, AP radiograph obtained at presentation at age 2 years 3 months shows a high dislocation of the left hip. B, AP radiograph obtained after open reduction and femoral shortening osteotomy. C, AP radiograph obtained at age 8 years 2 months shows excellent acetabular development.

Medial Approach for Open Reduction of the Developmentally Dislocated Hip

The patient is placed supine and the ipsilateral hip, hemipelvis, and entire lower limb are prepared and draped in the usual fashion, allowing free mobility of the limb during surgery.

We prefer a transverse skin incision, as it affords better access to the hip and results in better cosmesis than a longitudinal incision. The hip is approached anterior to the pectineus in the traditional Ludloff technique. An alternative approach, posterior to the pectineus, will also be described.

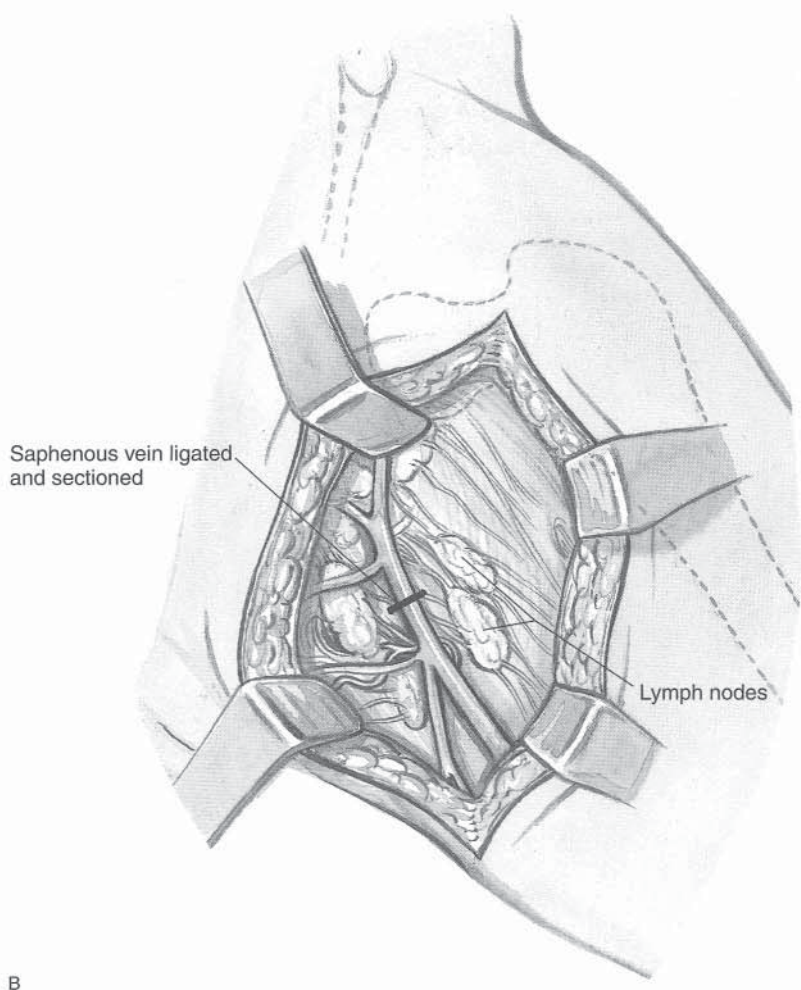
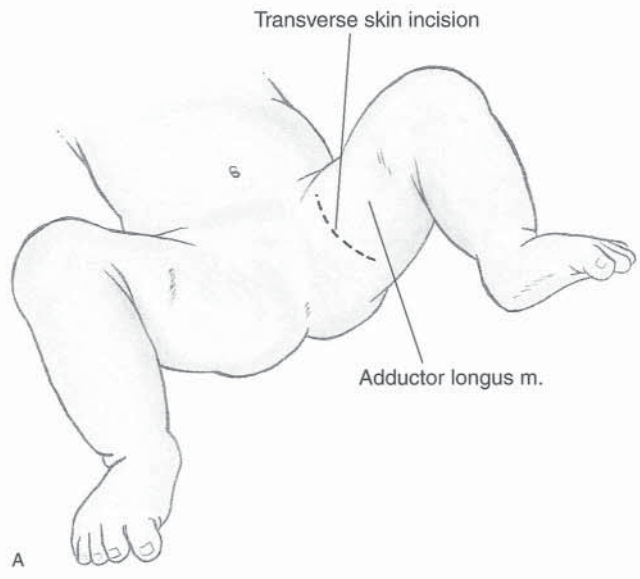
TRANSVERSE SKIN INCISION WITH SURGICAL APPROACH ANTERIOR AND LATERAL TO THE PECTINEUS

A, The preferred approach is through a transverse oblique skin incision, about 5 to 7 cm long, centered over the anterior margin of the adductor longus and about 1 cm distal and parallel to the inguinal crease.

The deep fascia is divided. The surgeon should be careful not to injure the saphenous vein, but if necessary the vein can be ligated and sectioned.

B, The adductor longus muscle is sectioned at its origin and reflected distally. At the anterior margin of the adductor longus the fibers of the pectineus muscle are identified.

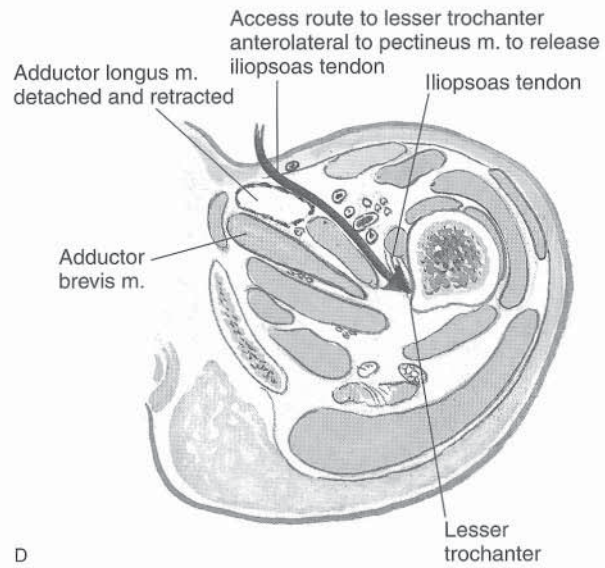
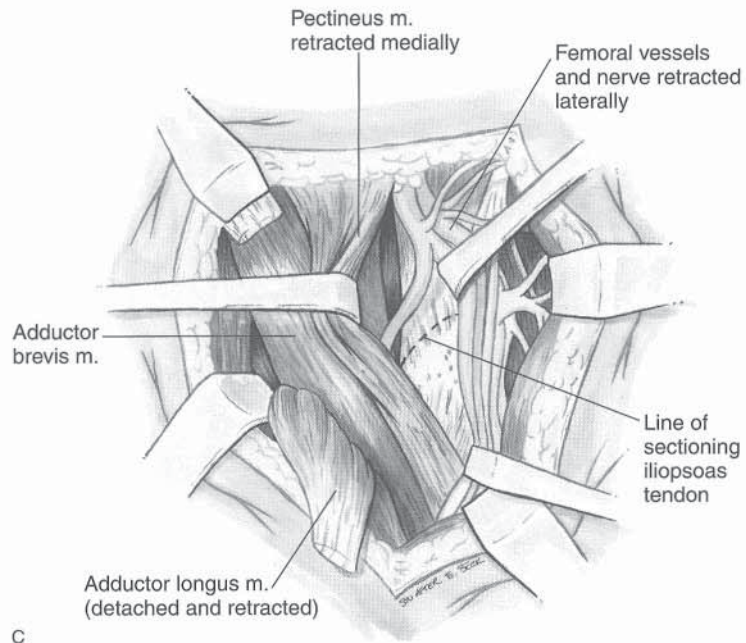
PLATE 15-2. Medial Approach for Open Reduction of the Developmentally Dislocated Hip



**Medial Approach for Open Reduction of
the Developmentally Dislocated Hip** *Continued*

C and D, The hip is approached anterior to the pectineus, between that muscle and the femoral sheath. In this approach, the pectineus muscle is retracted medially and inferiorly and the femoral vessels and nerve are retracted laterally, exposing the iliopsoas tendon at its insertion to the lesser trochanter. The femoral circumflex vessels cross the field and should be retracted laterally.

PLATE 15-2. Medial Approach for Open Reduction of the Developmentally Dislocated Hip

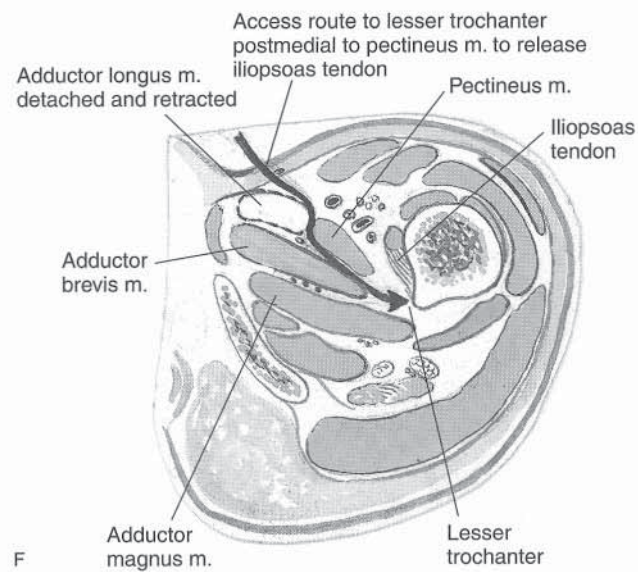
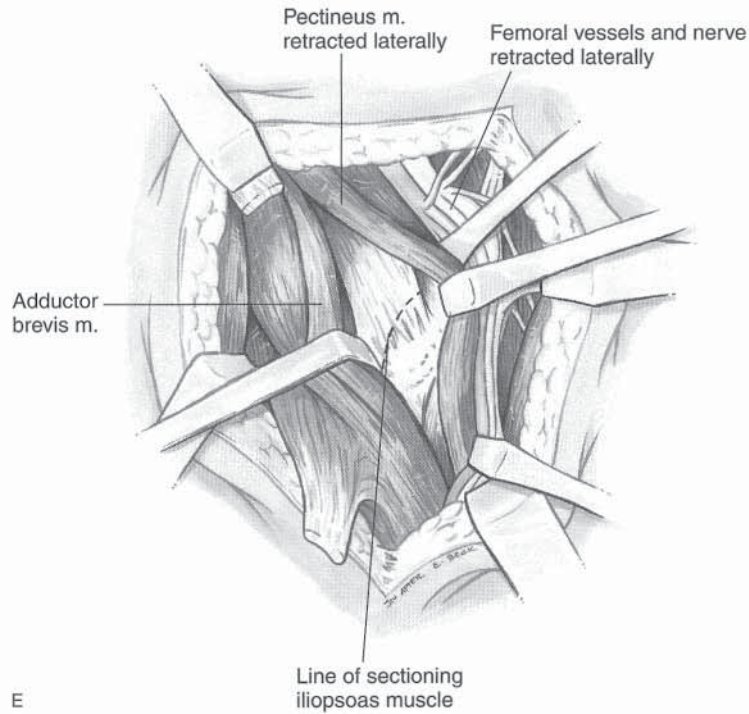


Medial Approach for Open Reduction of the Developmentally Dislocated Hip *Continued*

APPROACH MEDIAL TO THE PECTINEUS

E and F, The hip can also be approached by a route posterior and medial to the pectineus muscle. The pectineus muscle is retracted laterally, protecting the femoral vessels and nerve, and the adductor brevis muscle is retracted medially, bringing the iliopsoas tendon into view at its insertion to the lesser trochanter. A Kelly clamp is passed under the iliopsoas tendon and opened slightly, and the tendon is sectioned.

PLATE 15-2. Medial Approach for Open Reduction of the Developmentally Dislocated Hip



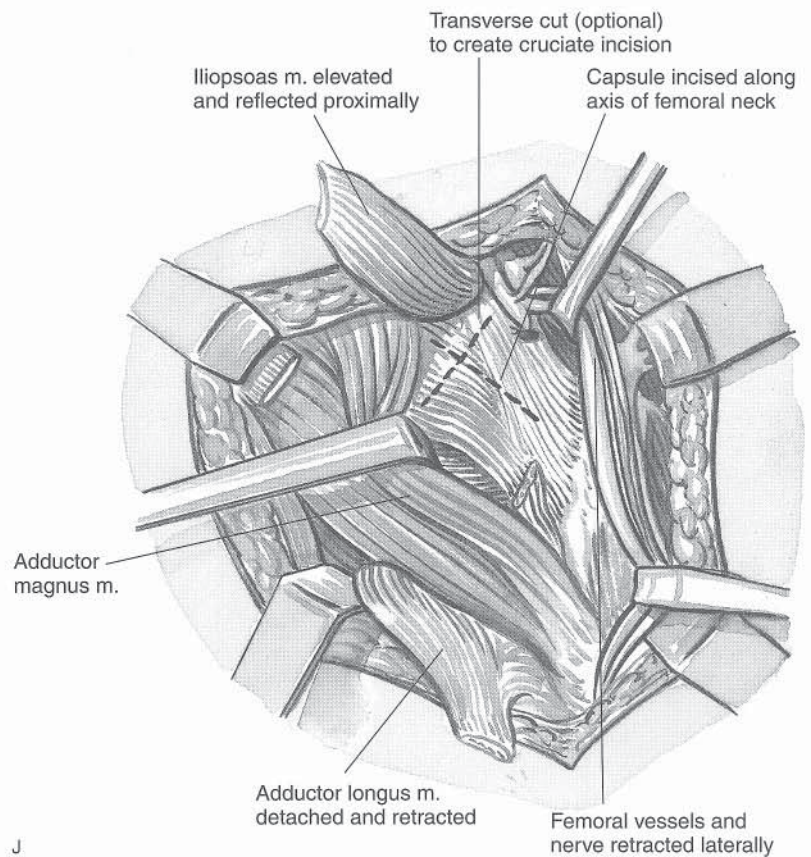
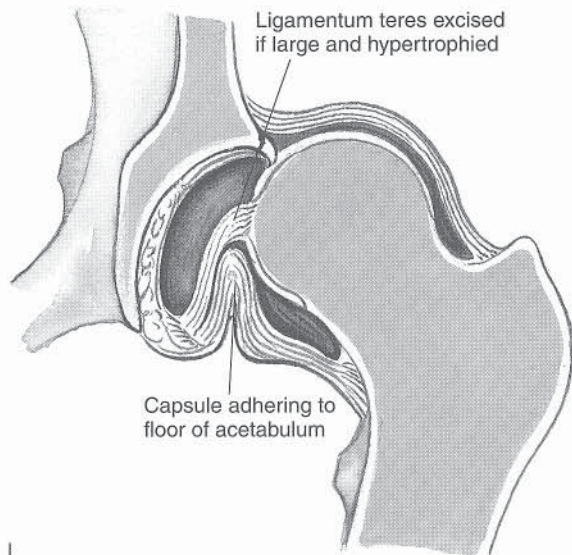
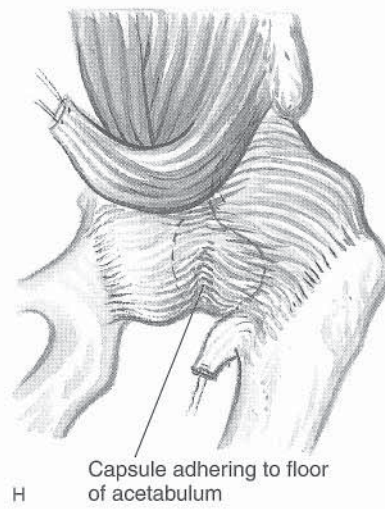
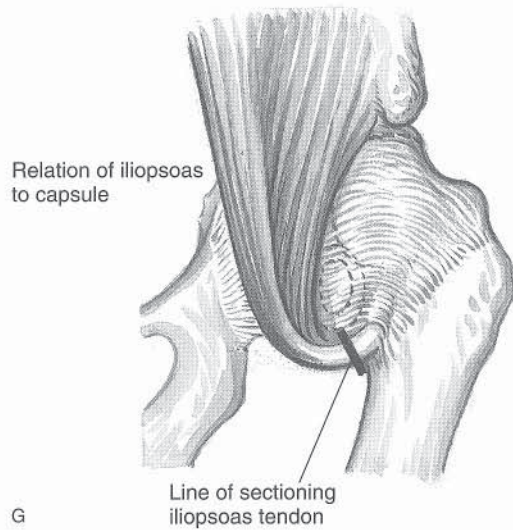
**Medial Approach for Open Reduction of
the Developmentally Dislocated Hip** *Continued*

G, In all these surgical approaches the psoas tendon is sectioned and allowed to retract proximally, and the iliacus muscle fibers are gently elevated from the anterior aspect of the hip joint capsule.

H and I, The inferior part of the capsule and the transverse ligament are pulled upward with the femoral head. The capsule may adhere to the floor of the acetabulum, and the ligamentum teres may be hypertrophic.

J, The capsule is opened with a longitudinal incision made along the long axis of the femoral neck and a transverse cut made near the acetabular margin. Incisions in the capsule should be thorough, yielding joint fluid and disclosing the femoral head. In the drawing a cruciate cut is shown; however, a single incision parallel to the acetabular margin is often sufficient.

PLATE 15-2. Medial Approach for Open Reduction of the Developmentally Dislocated Hip



Medial Approach for Open Reduction of the Developmentally Dislocated Hip *Continued*

K, The transverse acetabular ligament is sectioned and the ligamentum teres is excised if large and obstructive. The hypertrophied pulvinar is also removed.

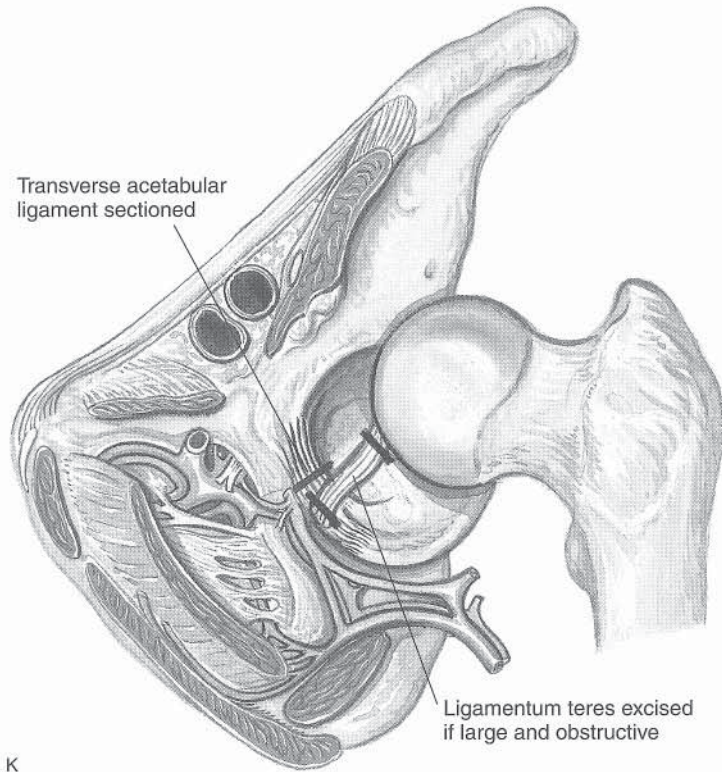
After this step, the femoral head can be easily reduced underneath the limbus, and reduction can be maintained by holding the hip in 30 degrees of abduction, 90 to 100 degrees of flexion, and neutral rotation. It is not necessary to repair the capsule. The wound is closed in the usual fashion.

L, A one-and-one-half-hip spica cast is applied with the hip in 100 degrees of flexion, 30 degrees of abduction, and neutral rotation. During application and setting of the cast, medially directed pressure is applied over the greater trochanter with the palm.

POSTOPERATIVE CARE

The cast is changed at 6-week intervals, with a total duration of cast immobilization of about 3 months.

PLATE 15-2. Medial Approach for Open Reduction of the Developmentally Dislocated Hip



Open Reduction of Developmental Hip Dislocation Through the Anterolateral Approach

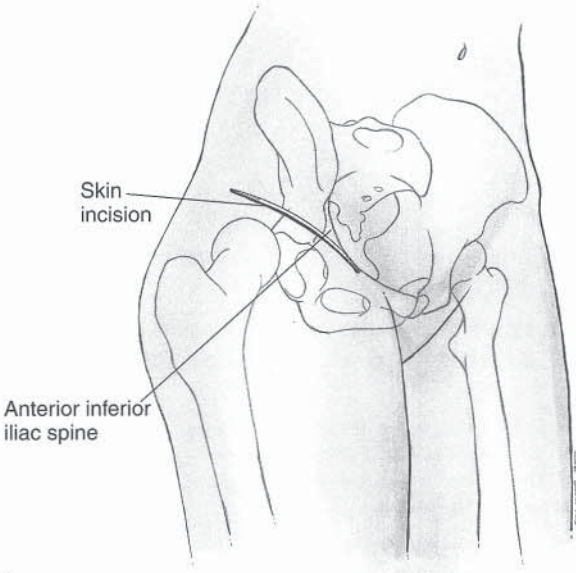
OPERATIVE TECHNIQUE

A, The patient is placed supine with a roll under the hip. The entire lower limb and affected half of the pelvis are prepared and draped to allow free motion of the hip.

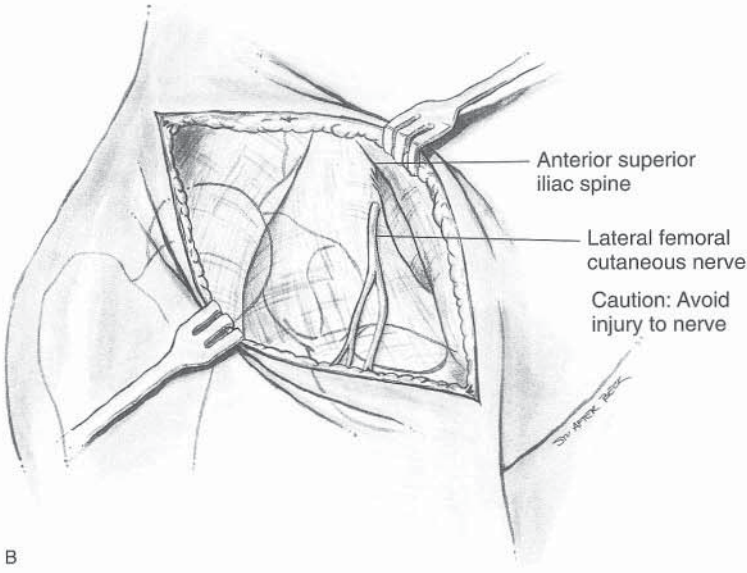
The skin incision is an oblique “bikini” incision. The incision formerly used over the iliac crest produces an unsightly scar, whereas the bikini incision affords excellent exposure and cosmesis. The anterior inferior iliac spine is palpated and marked. The incision begins about two-thirds of the distance from the greater trochanter to the iliac crest, crosses the inferior spine, and extends 1 or 2 cm beyond the inferior spine.

B, The incision is then retracted over the iliac crest and the dissection is carried down to the apophysis of the crest.

PLATE 15-3. Open Reduction of Developmental Hip Dislocation Through the Anterolateral Approach



A



B

Open Reduction of Developmental Hip Dislocation Through the Anterolateral Approach *Continued*

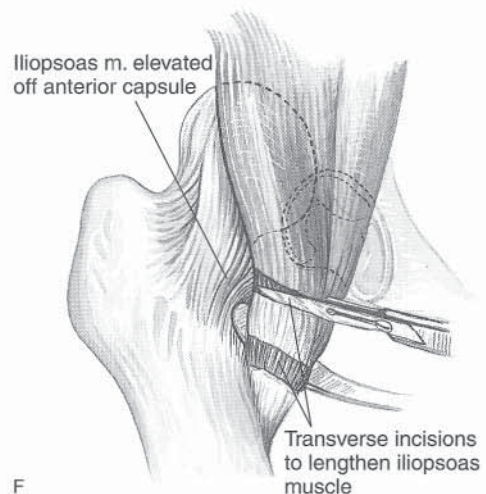
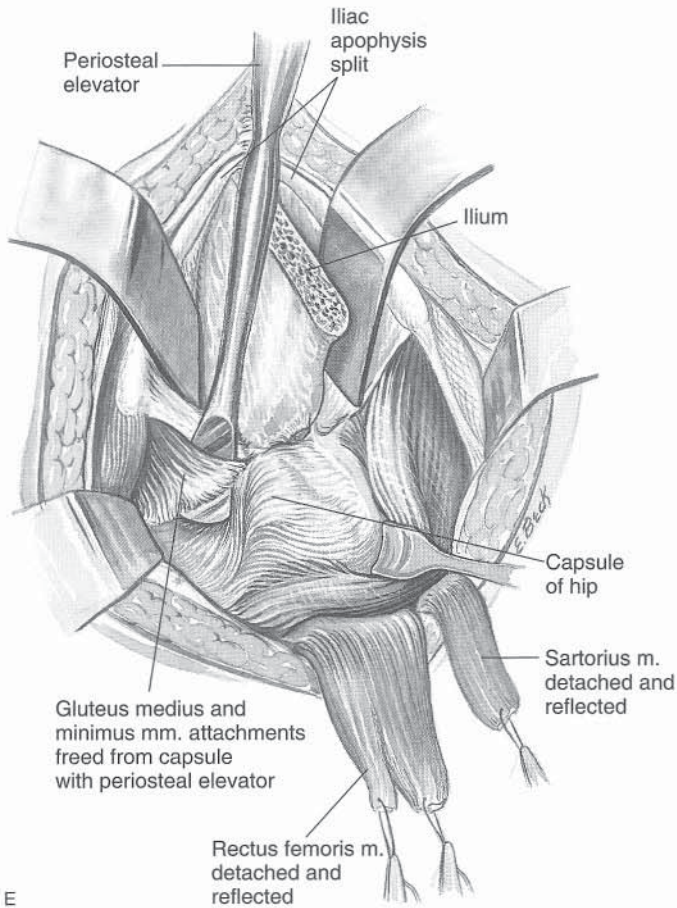
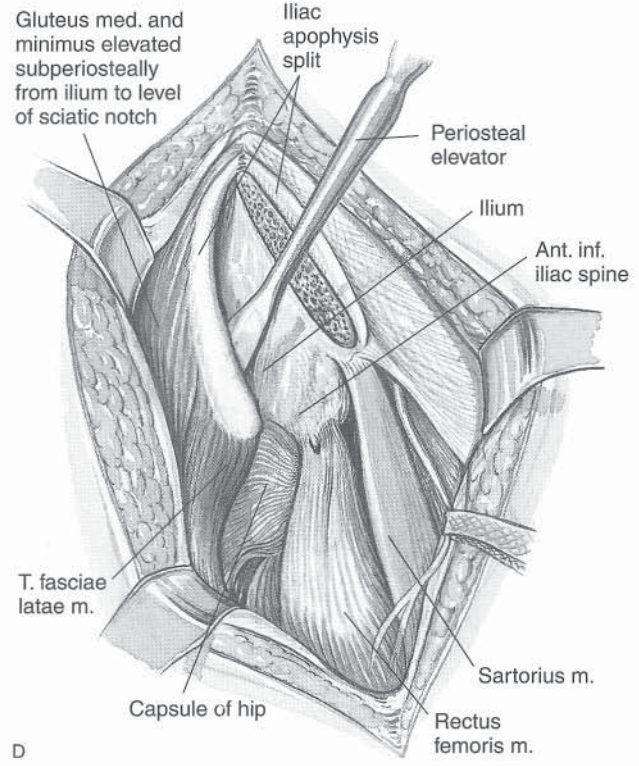
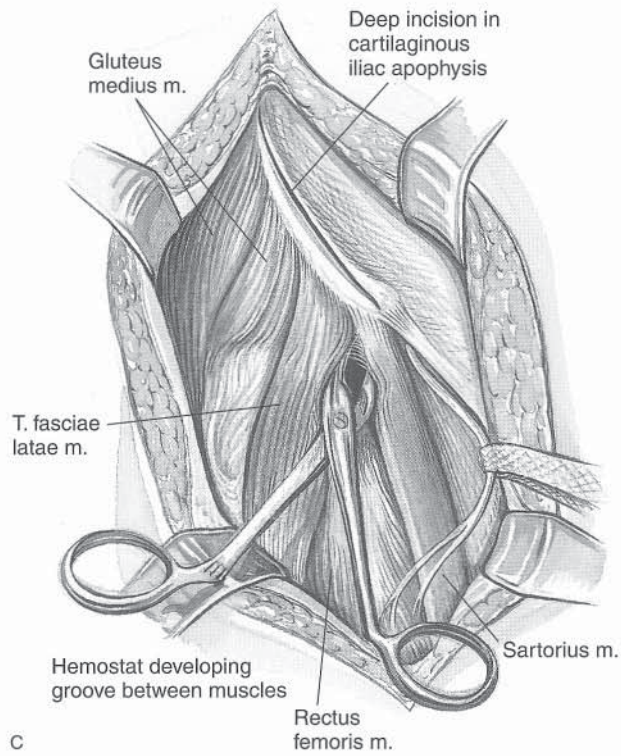
C, Anteriorly, the tensor–sartorius interval is bluntly dissected beginning distally and working proximally. The lateral femoral cutaneous nerve appears just medial to this interval and just distal to the inferior iliac spine and should be protected. The interval is widened with blunt dissection and the rectus femoris is identified as it inserts on the anterior inferior iliac spine.

D, The iliac apophysis is now split with a scalpel or cautery down to the bone of the crest. With the aid of periosteal elevators, the iliac crest is exposed subperiosteally. The surgeon must be careful to keep the periosteum intact, as it protects the iliac muscles and prevents bleeding. Bleeding points on the iliac wings should be controlled with bone wax, even if the bleeding points appear small. A dry wound makes subsequent steps in the procedure easier. Further subperiosteal dissection clears the sartorius medially and the tensor laterally, exposing the rectus femoris as it arises from the anterior inferior spine.

E, The rectus femoris is elevated from the hip capsule and the straight and reflected heads are identified, tagged, and sectioned. The hip capsule is exposed laterally, first with the aid of a periosteal elevator to clear muscle attachments from the capsule. Next, the medial portion of the capsule is exposed, again by using a periosteal elevator to dissect between the capsule and iliopsoas tendon. Flexing the hip relaxes the iliopsoas and helps gain medial exposure. The capsule beneath the iliopsoas is exposed, and strong medial retraction with army-navy retractors is necessary to access the true acetabulum.

F, If the iliopsoas tendon cannot be retracted, it may need to be sectioned.

PLATE 15-3. Open Reduction of Developmental Hip Dislocation Through the Anterolateral Approach



Open Reduction of Developmental Hip Dislocation Through the Anterolateral Approach *Continued*

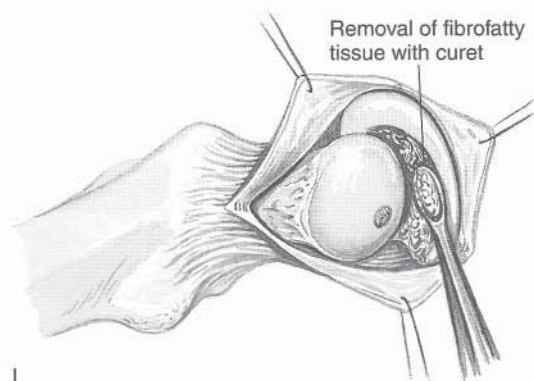
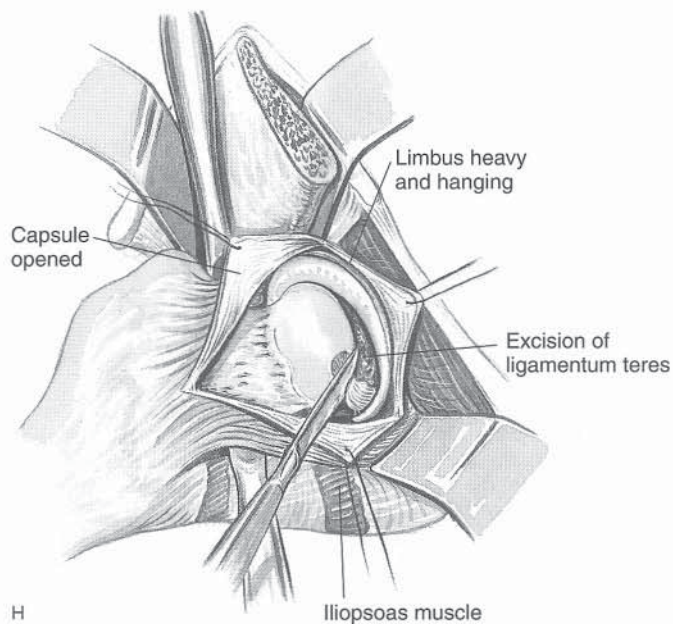
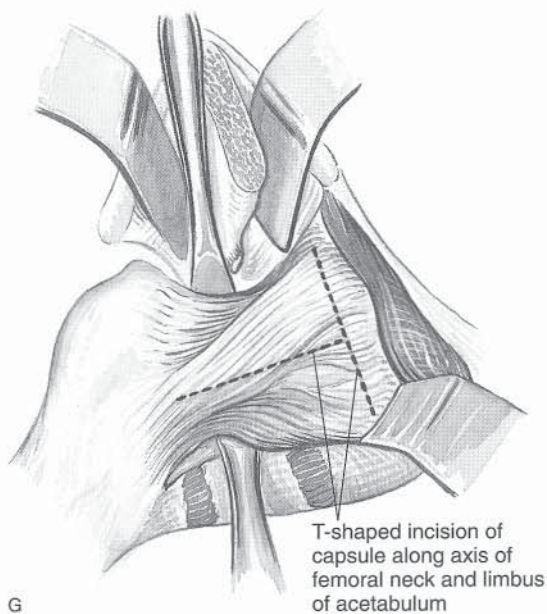
G, Once medial exposure is adequate, the capsule is opened with a knife. A hemostat is inserted into the capsule and the capsule is opened over the instrument and parallel to the acetabular margin, leaving a 5-mm margin of capsule. This incision should extend medially all the way to the transverse acetabular ligament and laterally to above the greater trochanter. A second capsular incision is made down the femoral neck, forming a T.

H, The capsule edges are grasped with Kocher clamps and a blunt probe is inserted to visualize the acetabulum. The hip should be flexed and externally rotated to open up the acetabulum. The ligamentum teres is elevated with a right-angle clamp and followed to the depths of the acetabulum. This step is essential, as many a surgeon has mistaken a false acetabulum for the true acetabulum.

I, The ligamentum teres is cut free from its base in the acetabulum with scissors. The labrum of the acetabulum may initially appear to be infolded into the acetabulum, especially when the head is reduced. This usually indicates that the medial obstacles to reduction (capsule, iliopsoas, transverse ligament) have been inadequately released. After more thorough release medially, the head should be reducible beneath the labrum, which will elevate the labrum out of the acetabulum. Excision of the labrum is almost never necessary.

Next, the surgeon inspects and determines (1) the depth of the acetabulum and the inclination of its roof, (2) the shape of the femoral head and the smoothness and condition of the articular hyaline cartilage covering it, (3) the degree of antetorsion of the femoral neck, and (4) the stability of the hip after reduction. The femoral head is placed in the acetabulum under direct vision by flexing, abducting, and medially rotating the hip while applying traction and gentle pressure against the greater trochanter. This maneuver is reversed to redislocate the hip. The position of the hip when the femoral head comes out of the acetabulum is determined and noted in the operative report. If necessary, sterile 4 or 5-0 suture wire is rolled into a circle and placed against the cartilaginous femoral head to delineate it, the hip is reduced, and radiographs are obtained. The wire is then removed. If the hip joint is unstable or if, on reduction under direct vision, the femoral head is insufficiently covered superiorly and anteriorly, the surgeon should decide whether to perform a Salter innominate osteotomy or a derotation osteotomy of the proximal femur at this time.

PLATE 15-3. Open Reduction of Developmental Hip Dislocation Through the Anterolateral Approach



Open Reduction of Developmental Hip Dislocation Through the Anterolateral Approach *Continued*

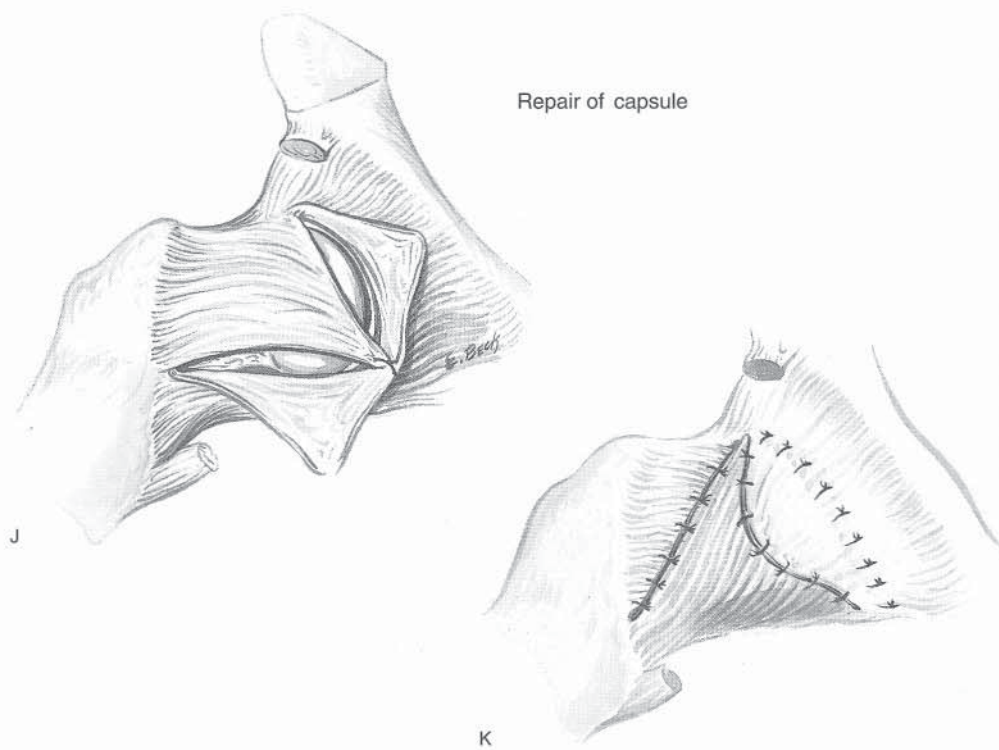
J and K, A careful capsuloplasty is performed next. It is very important to keep the femoral head in its anatomic position in the acetabulum. With the femoral head reduced, the hip joint is held by a second assistant in 30 degrees of abduction, 30 to 45 degrees of flexion, and 20 to 30 degrees of medial rotation throughout the remainder of the operation. The degree of medial rotation depends on the severity of antetorsion.

The large, redundant superior pocket of the capsule should be obliterated by plication and overlapping of its free edges. The capsule should also be tightened medially and anteriorly with a vest-over-pants closure. If it is too lax and redundant, a portion may be excised. First the medial part of the capsule that was left attached to the margin of the acetabulum is everted by pulling the previously placed Mersilene sutures anteriorly and superiorly. Next, the superolateral segment of the T is brought inferomedially and sutured with interrupted sutures to the inner surface of the capsule there. Then the inferolateral segment is brought up and over the superolateral segment and sutured with interrupted sutures to the inner superoposterior surface of the medial part of the capsule. Next, the capsule is tautened anteriorly and medially, bringing the medial segment over the lateral segments, to which it is sutured with interrupted Mersilene sutures. The two halves of the iliac apophysis are sutured together over the iliac crest. The rectus femoris and sartorius muscles are resutured to their origins. The wound is closed in routine manner. An AP radiograph of the hips is obtained to ensure a concentric reduction before a one-and-one-half-hip spica cast is applied. The roll beneath the patient's hip should be removed when the radiograph is made to have a true AP view of the pelvis. The cast is applied with the hip in about 45 degrees of abduction, 60 to 70 degrees of flexion, and 20 to 30 degrees of medial rotation. The knee is always flexed at 45 to 60 degrees to relax the hamstrings and to control rotation in the cast.

POSTOPERATIVE CARE

The patient is immobilized in a one-and-one-half-hip spica cast for 6 weeks. After 6 weeks the patient is examined under anesthesia and a Petrie type of cast is applied. This consists of long-leg plasters connected by one or two bars, with the hips abducted 45 degrees and internally rotated 15 degrees. The cast allows flexion and extension of the hips while the reduction is maintained by the abduction and internal rotation. The cast is removed in the clinic after 4 weeks. Weightbearing is allowed while the child is in the cast.

PLATE 15-3. Open Reduction of Developmental Hip Dislocation Through the Anterolateral Approach



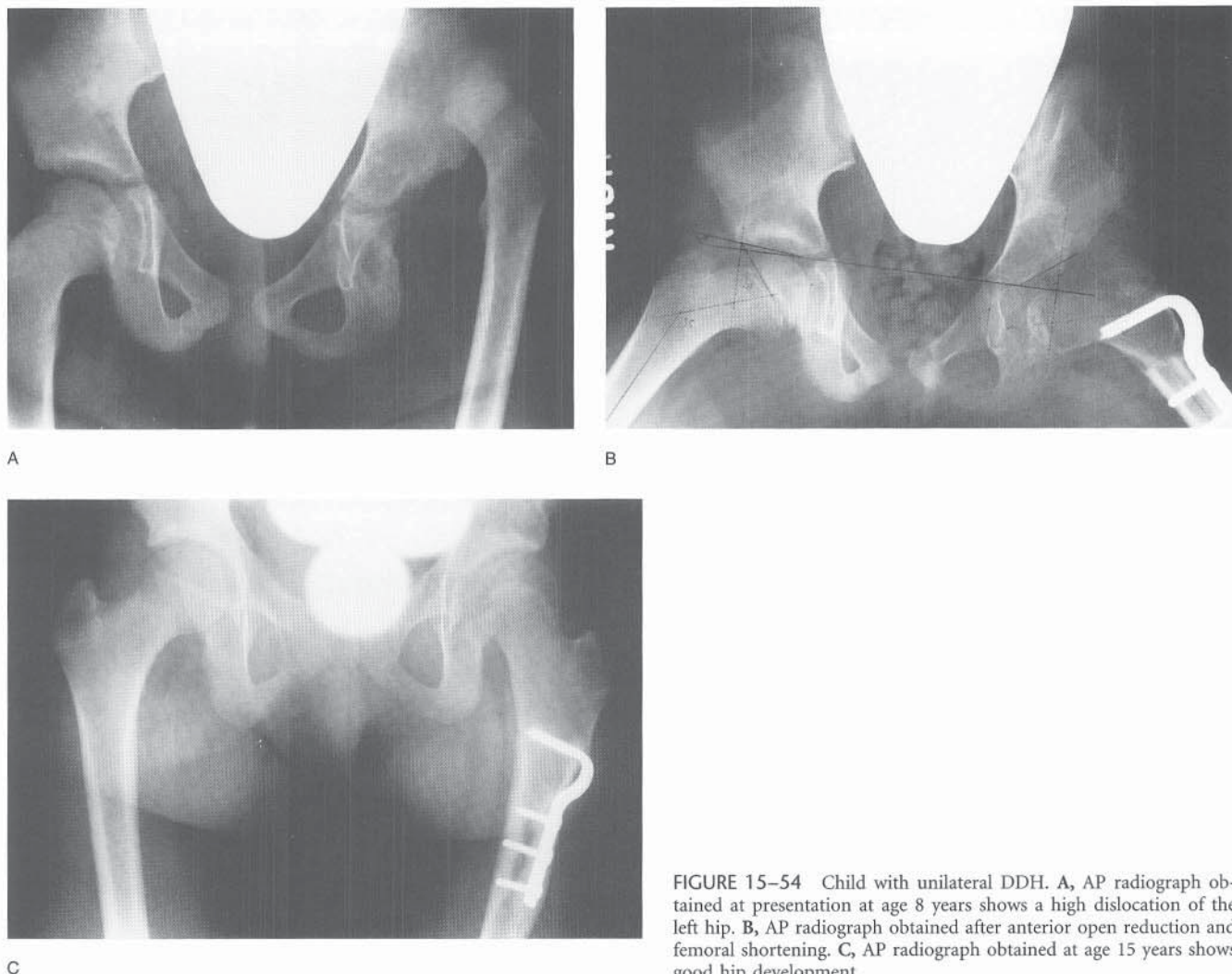


FIGURE 15-54 Child with unilateral DDH. A, AP radiograph obtained at presentation at age 8 years shows a high dislocation of the left hip. B, AP radiograph obtained after anterior open reduction and femoral shortening. C, AP radiograph obtained at age 15 years shows good hip development.

reduction, while other surgeons prefer to perform acetabular augmentation (if necessary) when the child is older. We perform an innominate osteotomy in patients over 18 months of age primarily when coverage is in doubt, using it in probably two-thirds of these cases. We prefer the Salter innominate osteotomy, whereas others choose the Pemberton or other periacetabular procedure. Whichever procedure is used, it is important to place the osteotomy high enough to avoid injury to the cartilaginous margin of the acetabulum, which is a major growth center for the acetabulum. If there is undue tension on the reduction, a concomitant femoral shortening should be considered.

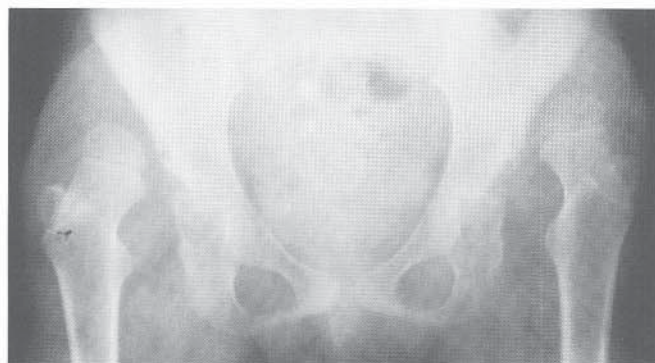
Treatment of the Older Child (Ages 2 Years and Older)

Treatment of children between 2 and 6 years of age with hip dislocation is more challenging. The femoral head is usually in a more proximal location in the older child, and the muscles that cross the hip are more severely contracted. Femoral shortening is an essential part of management in

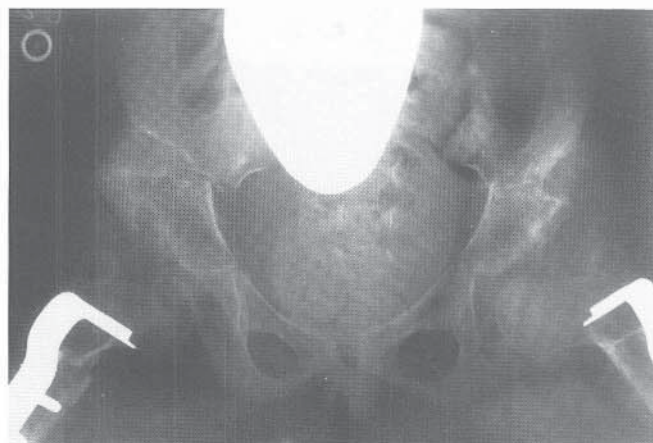
the older child, and with higher dislocations, greater shortening is necessary. In the past, long periods of skeletal traction were employed in this age group, but femoral shortening has produced better results with less morbidity. In addition, the older child is more likely to need a primary acetabular reorienting osteotomy, such as the Salter or Pemberton procedure.

For children between 2 and 3 years old, the surgeon should evaluate the stability of the hip during the open reduction. If the acetabular coverage is insufficient, a pelvic osteotomy should be performed. The Salter and the Pemberton procedures are the most commonly used techniques and are generally successful, with little additional operative time or morbidity. Children over 3 years of age at reduction usually need an acetabular procedure to adequately cover the femoral head.^{105,106,242}

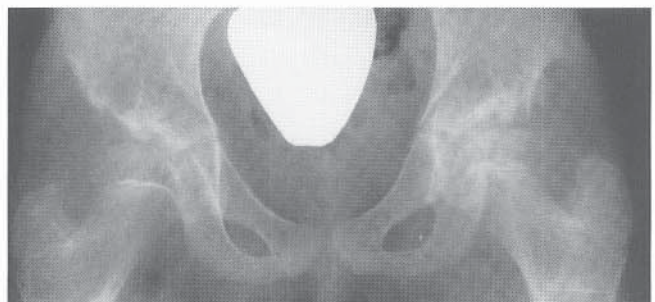
A potential complication when combining an acetabular procedure with a femoral shortening procedure is posterior dislocation of the hip. Dislocation is most likely to occur when the femur is derotated. At surgery, however, there usually is little increase in true anteversion. Thus, derotation is unnecessary, and it may predispose the hip to posterior dislocation if it is performed.



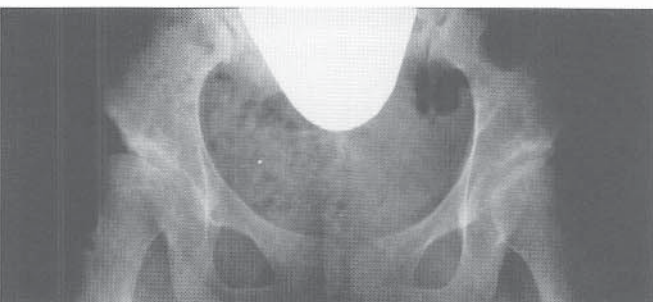A



B



C



D

FIGURE 15-55 A girl examined because of excessive lordosis and found to have bilateral dislocation of the hips. A, AP radiograph obtained at presentation at age 6 years 7 months shows bilaterally dislocated hips. B, AP radiograph obtained after staged open reductions, femoral shortenings, and Salter innominate osteotomies. Both hips are reduced. Note the widened teardrop body on the right, which may portend a poor long-term prognosis. C, AP radiograph obtained 4 years after reduction. The teardrop body remains wide on the right. D, AP radiograph obtained 10 years after reduction at age 16. Acetabular development is better on the left than on the right. Note valgus deformity of the femoral head on the neck bilaterally, probably due to early lateral physal closure. The valgus reduces the coverage of the hip and, when recognized early, may be an indication for varus femoral osteotomy.

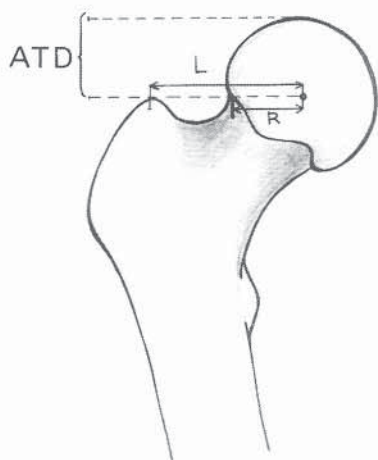


FIGURE 15-56 Diagram showing the upper end of a normal femur. In the normal hip, the distance from the greater trochanter to the center of the femoral head is 2 to $2\frac{1}{2}$ times the radius of the head ($L = 2\frac{1}{2} \times R$). The tip of the greater trochanter is at or slightly below the center of the femoral head. The articulo-trochanteric distance (ATD) normally measures 10 to 25 mm. (From Kelikian AS, Tachdjian MO: Greater trochanteric advancement. In *The Hip Society Awards Papers*. St. Louis, CV Mosby Co, 1983.)

Current results in older children are quite encouraging in comparison with outcomes in the past, when complications were frequent. Galpin and associates reported treating 33 hips in children with an average age of 4 years at treatment.⁵⁸ Sixty-six percent of the hips had good radiographic results, with only four cases of AVN, and 88 percent had good range of motion. Other authors have compared outcomes in children who underwent femoral shortening and open reduction with outcomes in children treated by traction. In the femoral shortening group, 85 percent had good results, while in the traction group, only 44 percent had good results, and AVN developed in more than 50 percent.¹⁸⁵

There is some debate as to the upper age at which a successful reduction can be carried out (see Figs. 15-54 and 15-55). The guidelines differ for unilateral and bilateral hip dislocations because gait asymmetry and function are more markedly affected in unilateral cases. However, the complication rate is considerably higher when both hips must be reduced. For unilateral dislocations, reduction should be attempted for children up to 9 or 10 years old if there is a reasonable possibility of restoring acetabular coverage. For bilateral dislocations, the results are frequently unsatisfac-

Text continued on page 582

Femoral Shortening and Derotation Osteotomy Combined with Open Reduction of the Hip

A femoral shortening and derotation osteotomy procedure is performed through a separate lateral longitudinal incision, although others use different approaches. Exposure of the upper femoral shaft through a separate longitudinal incision of the upper thigh is technically simpler, bleeding is less, and the scars are aesthetically more attractive. It is vital to expose a sufficient length of the upper femoral shaft subperiosteally.

In irreducible dislocation, femoral shortening facilitates reduction and, when reduction is difficult because of increasing pressure on the femoral head, decompresses the hip.

OPERATIVE TECHNIQUE

A, The amount of shortening is determined preoperatively by measuring the distance between the inferior margin of the femoral head and the floor of the acetabulum. The roof of the true acetabulum may be oblique and deficient, and measuring from it to the top of the femoral head may pose problems. Insufficient femoral shortening should be avoided. If the femoral shortening is inadequate, it will not permit positioning of the femoral head in the true acetabulum, and postoperatively, pressure on the femoral head will lead to cartilage necrosis and a stiff hip joint.

Another method of determining the amount of desired femoral shortening is to reduce the femoral head in the acetabulum and measure the overlap of the osteotomized segments.

Next, the anterior aspect of the femur is scored parallel to its longitudinal axis; the score serves as an orientation mark to determine the degree of rotation after osteotomy and resection. As an added safety measure, threaded Steinmann pins of appropriate diameter should be inserted, one in the upper femoral segment and another in the distal segment.

B, Next, the femur is shortened by two parallel transverse osteotomies, the first immediately distal to the inferior pole of the lesser trochanter and the second distal to it. The osteotomies are performed with an oscillating power saw. To aid in fixation, the osteotomies may be partially completed, leaving the medial cortex intact. Then a four-hole plate of appropriate size is applied to the lateral aspect of the upper femoral shaft and firmly fixed with two screws to the upper segment. The osteotomies are completed, the segment of femur is resected, the distal segment is rotated laterally, and the bone surfaces are apposed. The degree of derotation is estimated from the degree of excess femoral anteversion. In most cases minimal derotation is required.

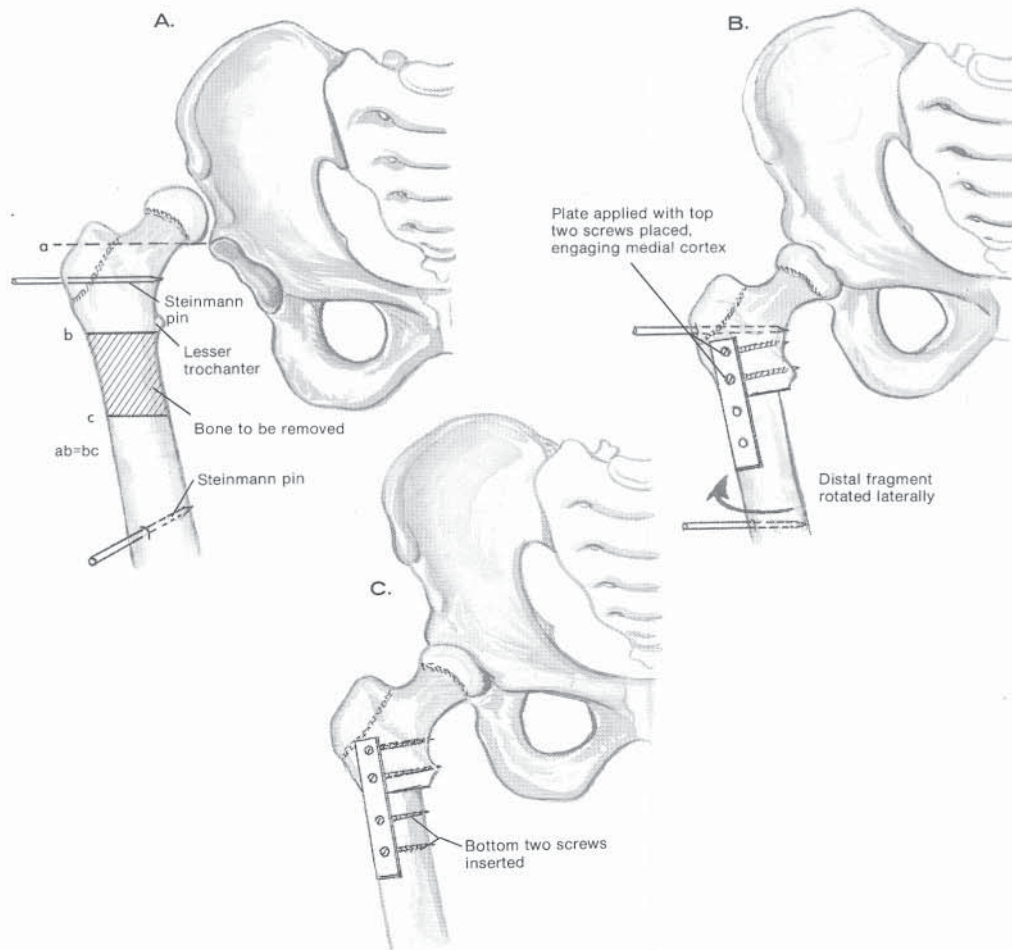
C, Next, the lower two screws are inserted, fixing the plate to the distal segment. After the femoral osteotomy is firmly fixed, the femoral head is repositioned in the acetabulum. The stability of reduction is determined, and the adequacy of “decompression” of the hip is double-checked. As a rule, the degree of hip decompression is adequate if one can distract the reduced femoral head from the socket for about 3 to 4 mm without much tension.

The lateral wound thigh is closed in the usual manner. Repair of the hip joint capsule and other steps are illustrated in Plate 15-3.

POSTOPERATIVE CARE

Postoperative care is similar to that following open reduction of the hip. The plate can be removed after 6 months, when the osteotomy has solidly healed.

PLATE 15-4. Femoral Shortening and Derotation Osteotomy Combined with Open Reduction of the Hip



Technique of Intertrochanteric Varus Osteotomy and Internal Fixation with a Blade Plate

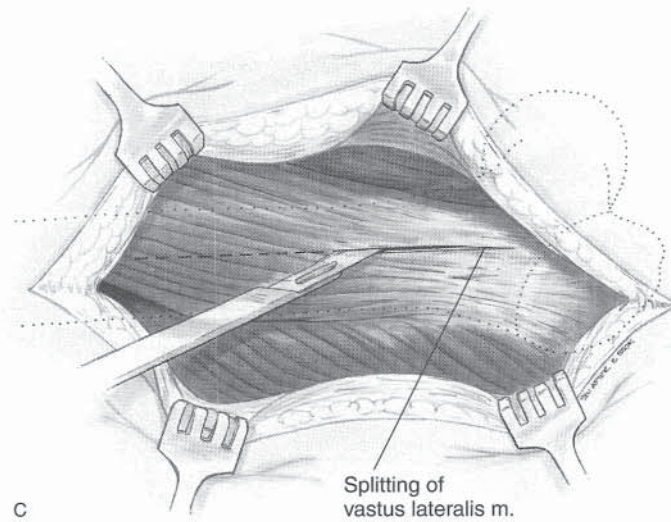
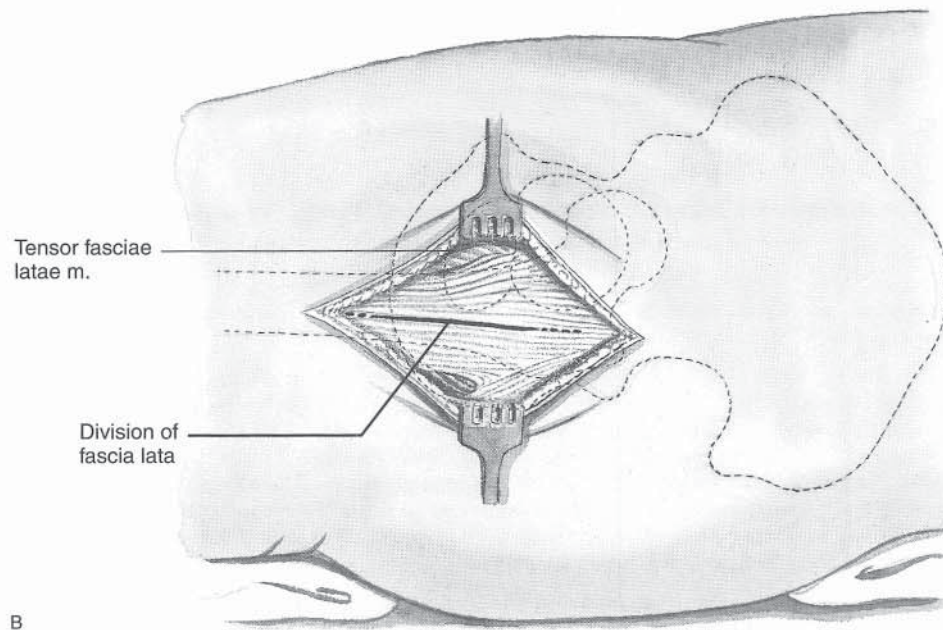
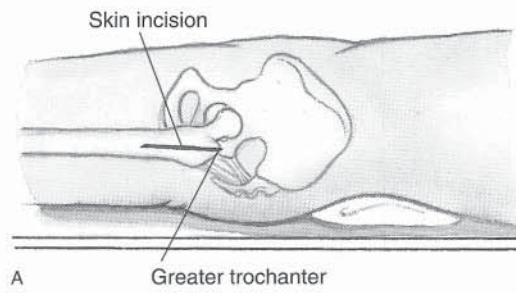
OPERATIVE TECHNIQUE

A, The operation is performed with the child supine on a radiolucent operating table. It is imperative to have image intensifier radiographic control. Some surgeons prefer to operate on an older child on a fracture table because it is technically easier to obtain a lateral radiograph of the hip. A straight, midlateral longitudinal incision is made beginning at the tip of the greater trochanter and extending distally parallel to the femur for a distance of 10 to 12 cm. The subcutaneous tissue is divided in line with the skin incision.

B, The fascia lata is exposed by deepening the dissection and is first divided with a scalpel and then split longitudinally with scissors in the direction of its fibers. The fascia lata should be divided posterior to the tensor fasciae latae to avoid splitting its muscle.

C, With retraction, the vastus lateralis muscle is visualized. Next, the anterolateral region of the proximal femur and the trochanteric area are exposed. It is vital not to injure the greater trochanteric growth plate. The origin of the vastus lateralis muscle is divided transversely from the inferior border of the greater trochanter down to the posterolateral surface of the femur. The vastus lateralis muscle fibers are elevated from the lateral intramuscular septum and the tendinous insertion of the gluteus maximus.

PLATE 15-5. Technique of Intertrochanteric Varus Osteotomy and Internal Fixation with a Blade Plate



Technique of Intertrochanteric Varus Osteotomy and Internal Fixation with a Blade Plate *Continued*

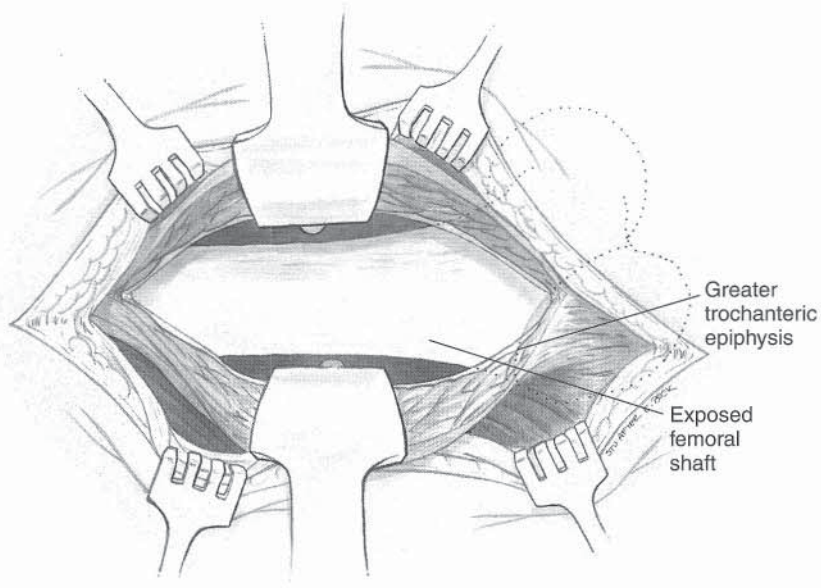
D, The lateral femoral surface is exposed by subperiosteal dissection. The greater trochanteric apophysis should not be disturbed.

E and F, The femoral head is centered concentrically in the acetabulum by abducting and medially rotating the hip, and its position is checked by image intensifier. Immediately distal to the apophyseal growth plate of the greater trochanter, a 3-mm Steinmann pin is inserted through the lateral cortex of the femoral shaft parallel to the floor of the operating room and at a right angle to the median plane of the patient. The pin is drilled medially along the longitudinal axis of the femoral neck, stopping short of the capital femoral physis. This position of the proximal femur can be reproduced at any time during the operation by placing the Steinmann pin horizontally parallel to the floor and at 90 degrees to the longitudinal axis of the patient—a very dependable, simple method for properly orienting the proximal femur.

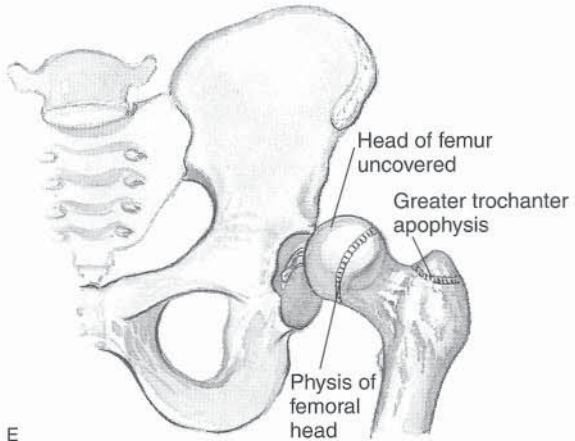
G, The chisel for the blade plate is placed at an angle that is determined as follows: if the chisel paralleled the guide pin, the 90-degree blade plate would produce a 90-degree neck-shaft angle. In this case we sought to produce a neck-shaft angle of 105 degrees. Thus a chisel placed 15 degrees off the guide pin axis adds 15 degrees to a 90-degree neck-shaft angle, resulting in a 105-degree final angle.

H, The osteotomy cuts are made while the chisel is in place. The proximal osteotomy is parallel to the chisel and the distal osteotomy is perpendicular to the femoral shaft.

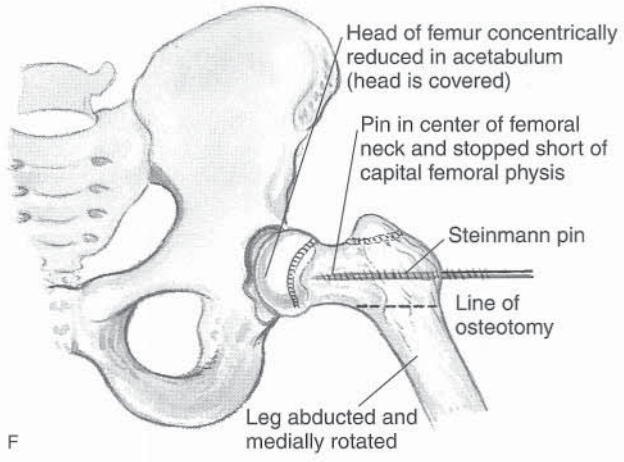
PLATE 15-5. Technique of Intertrochanteric Varus Osteotomy and Internal Fixation with a Blade Plate



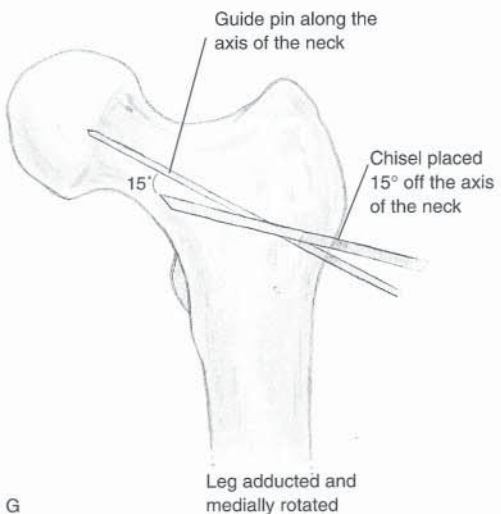
D



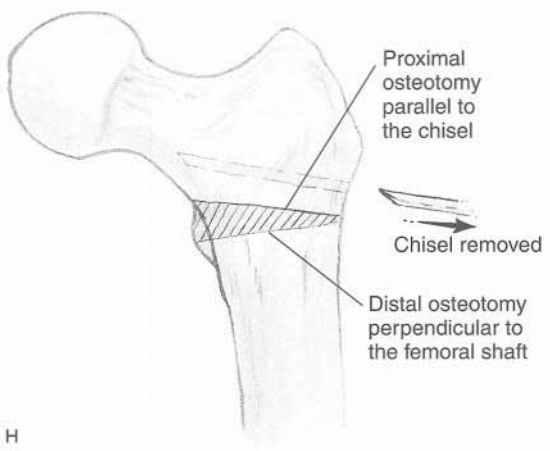
E



F



G



H

Technique of Intertrochanteric Varus Osteotomy and Internal Fixation with a Blade Plate *Continued*

I, After the osteotomized triangle is removed, the chisel is removed and the blade plate inserted. Careful control of the proximal fragment and clear visualization of the entry site of the chisel will facilitate placement of the blade.

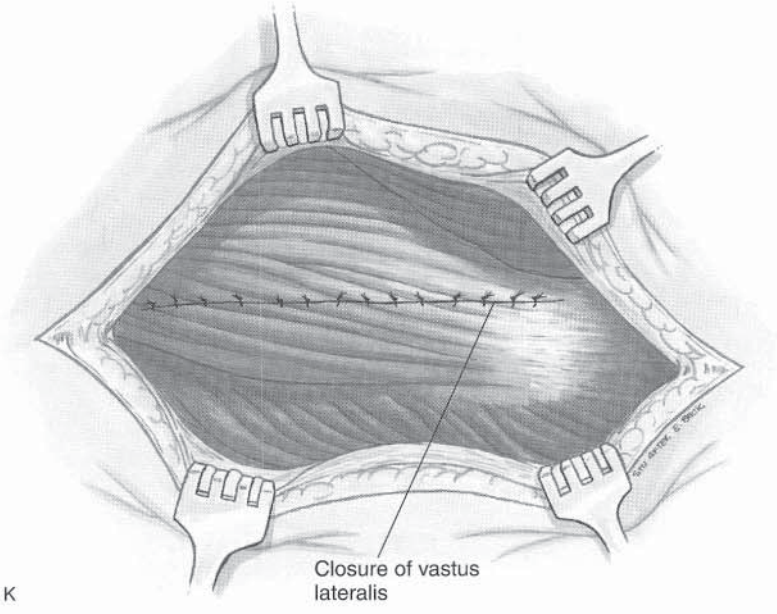
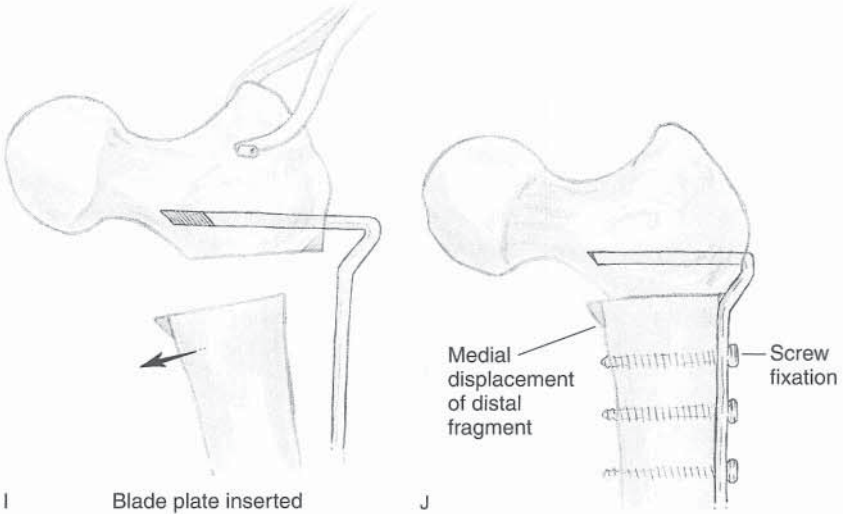
J, The blade plate is fully seated and secured with screws that are drilled and tapped. The angulation of the plate produces medial displacement of the femoral shaft, which is extremely important in the biomechanics of the hip. Failure to medially displace the distal fragments results in prominence laterally of the plate and widening of the groin.

K, The vastus lateralis is closed with running sutures, then the fascia lata. Subcutaneous and skin closure with absorbable sutures completes the procedure.

POSTOPERATIVE CARE

The osteotomy is stable when the bone is of normal strength. In reliable patients cast immobilization is not necessary. In less reliable children, in those with osteopenic bone, and always when an open reduction has been performed 6 weeks in a spica cast is required.

PLATE 15-5. Technique of Intertrochanteric Varus Osteotomy and Internal Fixation with a Blade Plate



Lloyd Roberts Technique of Intertrochanteric Oblique Osteotomy of Proximal Femur and Internal Fixation with Coventry Apparatus (Lag Screw and Plate)

The child is placed supine on a radiolucent operating table. The operation is performed under image intensifier radiographic control. The iliac region, hip, and entire lower limb are prepared sterilely and draped so that the limb can be manipulated freely.

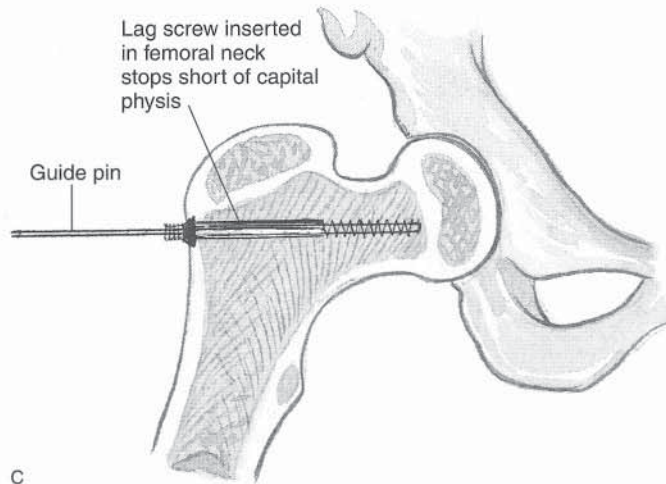
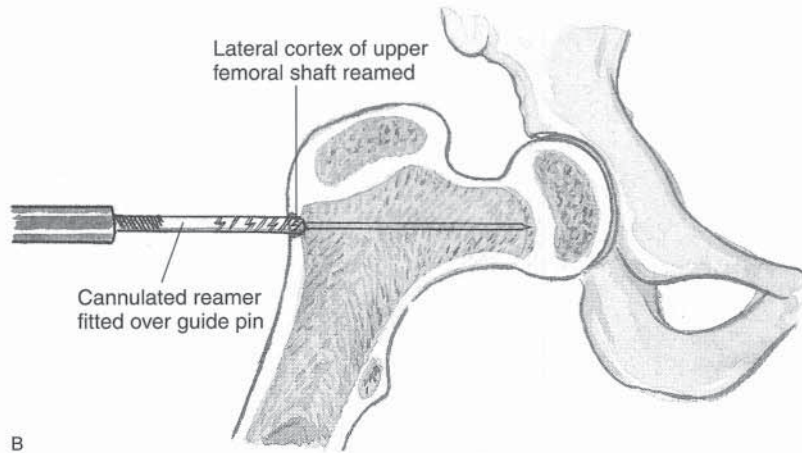
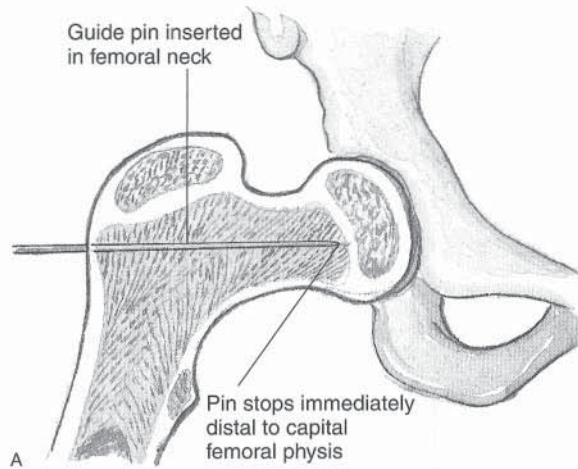
OPERATIVE TECHNIQUE

A, The incision begins 1 cm posterior and inferior to the anterior superior iliac spine, curves across to the top of the greater trochanter, and continues distally along the femoral shaft for a distance of 6 to 8 cm. The subcutaneous tissue is divided in line with the skin incision. The deep fascia is incised and the interval between the tensor fasciae latae anteriorly and the gluteus medius posteriorly is developed by blunt dissection. The vastus lateralis is divided longitudinally with an L-shaped or U-shaped incision, and the part of it that originates from the anterior aspect of the intertrochanteric area is detached. With a periosteal elevator, the intertrochanteric region and the upper femoral shaft are exposed. At this time the calcare femorale is visualized, and the femoral head can be palpated within the capsule. A sturdy stainless steel pin of appropriate diameter, usually 0.062 inches, is chosen; the operator should be sure its diameter fits the hole in the lag screw. With the hip in full medial rotation, a 3-mm hole is drilled through the center of the lateral cortex of the upper femoral shaft, 0.75 to 1.0 cm below the growth plate of the greater trochanter. To avoid injury to the growth plate of the apophysis, the surgeon should verify its site with an image-intensified radiograph. Next, the guide pin is inserted into the femoral neck parallel to the floor in a proximally inclined oblique plane parallel to the long axis of the femoral neck. The tip of the pin should stop immediately distal to the capital femoral physis. Proper placement of the guide pin is crucial; it is confirmed with AP and lateral image-intensified radiographs.

B, A cannulated reamer (with a stop to prevent more than $\frac{1}{2}$ inch penetration) is fitted over the guide pin. The lateral cortex of the upper femoral shaft is reamed to permit firm fixation of the lag screw in the cancellous bone.

C, Next, with the special lag screw inserter, a lag screw of appropriate length is inserted into the femoral neck. It should stop short of the capital physis. To avoid growth plate injury, the surgeon should confirm the position of the screw with AP and lateral radiographs.

PLATE 15-6. Lloyd Roberts Technique of Intertrochanteric Oblique Osteotomy of Proximal Femur and Internal Fixation with Coventry Apparatus (Lag Screw and Plate)



**Lloyd Roberts Technique of Intertrochanteric Oblique Osteotomy
of Proximal Femur and Internal Fixation with Coventry
Apparatus (Lag Screw and Plate) *Continued***

D, With an oscillating saw the femoral osteotomy is performed at the intertrochanteric level parallel to the calcare. The guide pin that protrudes from the lag screw is used to guide the direction of osteotomy, which is verified with image-intensified radiographs. (Drill holes may be used to mark the line of osteotomy.) Once the osteotomy is completed, the surgeon gently strips the adjacent periosteum to mobilize the bone fragments and permit free rotation of the femoral shaft.

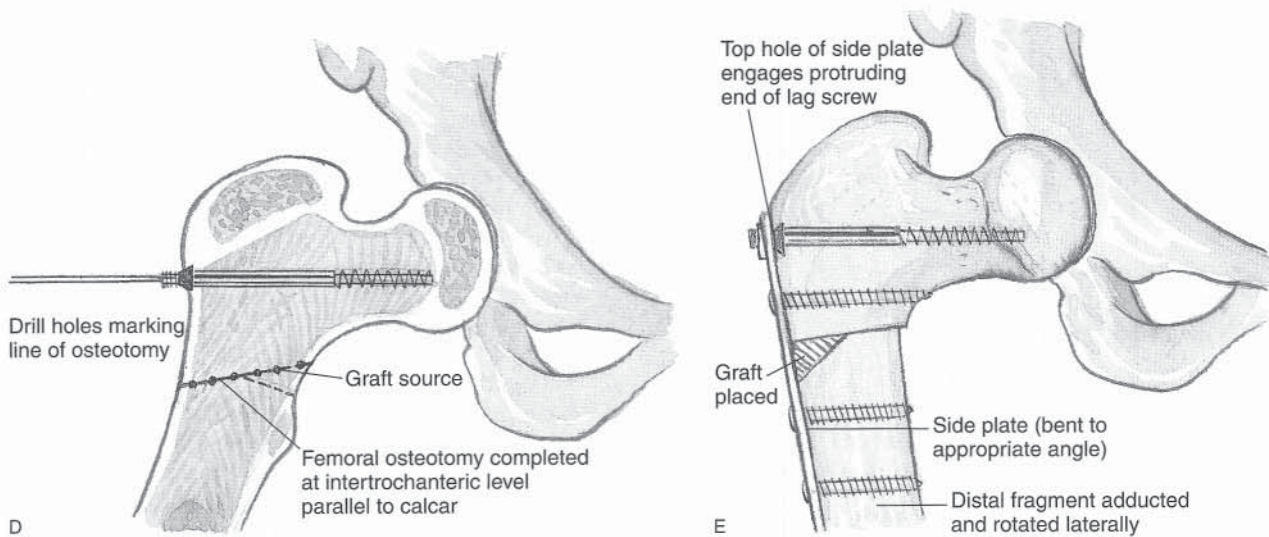
E, The side plate is bent to the appropriate angle. The guide pin is removed and the top hole of the side plate is engaged to the protruding end of the lag screw. A cannulated lever with a handle is attached to the lag screw for firm control of the upper fragment. The distal fragment is adducted and rotated laterally to the desired degree. The oblique line of the osteotomy will often make a triangle of bone at the upper end of the femoral shaft that will protrude anteriorly; this is excised and used as a local bone graft. The osteotomized fragments are apposed and secured by attaching the side plate to the femoral shaft with screws and a nut at the top of the lag screw and the proximal fragment. Final radiographs are obtained to double-check the security of the fixation device. A one-and-one-half-hip spica plaster of Paris cast is applied.

POSTOPERATIVE CARE

The child is usually sent home 3 to 4 days postoperatively and readmitted to hospital 6 weeks later. The plaster cast is removed, and the hip and knee are mobilized. When able to ambulate with crutches (three-point partial weightbearing on the affected limb), the patient is discharged, usually within 2 to 4 days.

The plate and screws are removed 6 months postoperatively.

PLATE 15-6. Lloyd Roberts Technique of Intertrochanteric Oblique Osteotomy of Proximal Femur and Internal Fixation with Coventry Apparatus (Lag Screw and Plate)



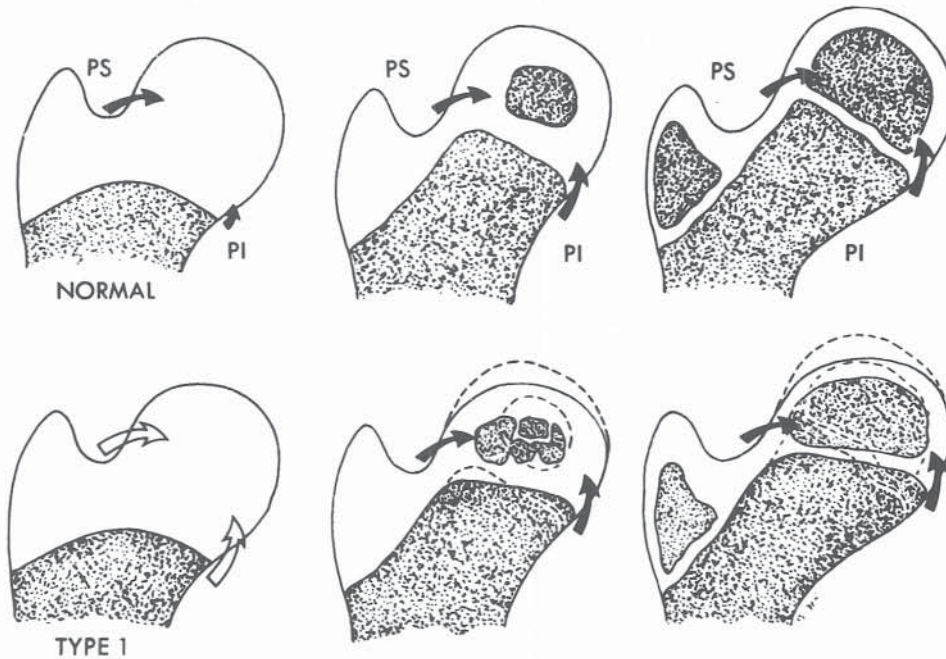


FIGURE 15-57 *Top:* Normal hip development. The PS arrow represents the posterosuperior branch of the medial femoral circumflex artery, and PI is the posteroinferior branch. *Bottom:* Irregular ossification in the capital femoral epiphysis without subsequent growth disturbance, a Buchholz-Ogden type I pattern of avascular necrosis. (From Bucholz RW, Ogden JA: Patterns of ischemic necrosis of the proximal femur in nonoperatively treated congenital hip diseases. In *The Hip: Proceedings of the Sixth Open Scientific Meeting of the Hip Society*. St. Louis, CV Mosby Co, 1978.)

tory in children more than 8 years old, although some have suggested that children ages 8 to 12 years can be successfully treated.¹⁰⁵ The rationale for not treating the child after age 8 years is that in most cases, the natural outcome of untreated bilateral dislocations is probably better than the results of treatment.

Complications and Pitfalls

AVASCULAR NECROSIS

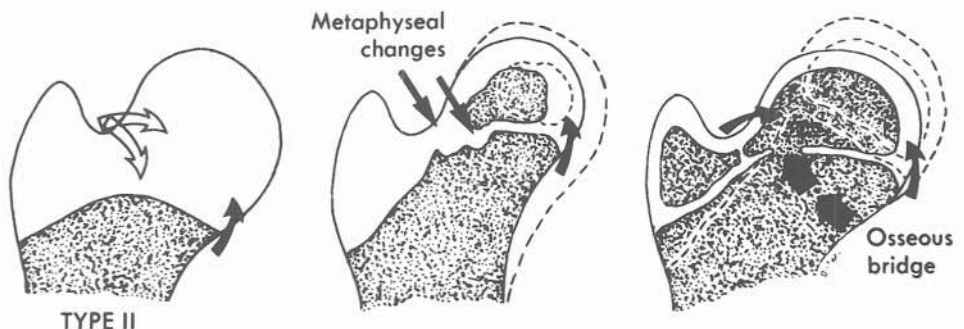
AVN is a major cause of long-term disability after the treatment of DDH. It is a problem directly associated with the treatment and is almost always preventable. With modern techniques, severe AVN should occur in less than 5 percent of cases. AVN occurs when excessive pressure is applied for an extended period of time to the femoral head, occluding its vascular perfusion. The most common cause is immobilization in a position that places excessive pressure on the femoral head, such as extreme abduction or internal rotation. Internal rotation not only increases pressure on the femoral head, it also twists the capsular blood supply. AVN

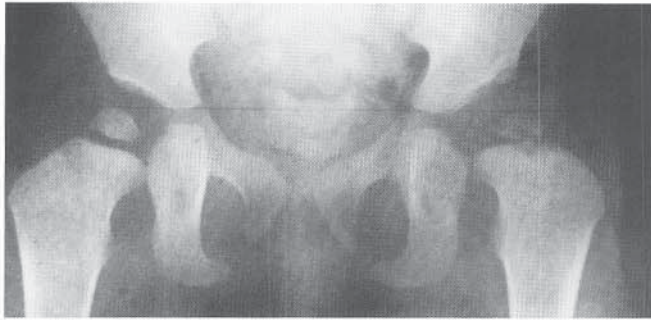
may also occur when the muscles crossing the hip are so contracted that they compress the reduced femoral head against the acetabulum. AVN can be prevented by avoiding abnormal positions and by performing femoral shortening when the reduction is too tight. Traction has also been used effectively to reduce the tightness of the hip musculature.

AVN is diagnosed when the femoral head fails to ossify or to grow within 1 year after being reduced. Other findings that indicate the presence of AVN are widening of the femoral neck within 1 year of reduction, changes in the bone density of the femoral head, and residual deformity suggesting growth disturbance.¹⁸⁴ The unique anatomy of the proximal femur in the young child allows complex changes to occur if growing areas are injured. Prior to ossification of the femoral head, the entire upper femur is one cartilaginous structure that includes the greater and lesser trochanters as well as the femoral head. The avascular insult may involve only a part of the upper femoral segment or it may affect the entire femoral epiphysis. The greater trochanter is not affected by AVN and will continue to grow when capital epiphyseal growth is arrested (Fig. 15-56).

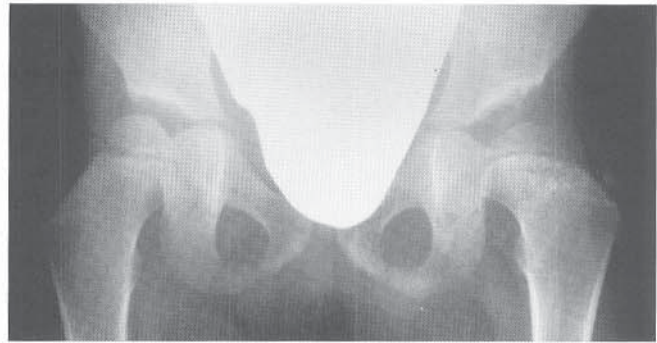
There are several classification systems for AVN, with the Buchholz-Ogden system being the most widely used.²⁰ In type I, changes are limited to the femoral head, and the

FIGURE 15-58 Buchholz-Ogden type II pattern of avascular necrosis at ages 2 months, 12 months, and 9 years. The ischemic event probably occurs laterally (*open arrows*), and there is lateral epiphyseal closure, which produces a valgus deformity of the head on the neck of the femur. (From Bucholz RW, Ogden JA: Patterns of ischemic necrosis of the proximal femur in nonoperatively treated congenital hip diseases. In *The Hip: Proceedings of the Sixth Open Scientific Meeting of the Hip Society*. St. Louis, CV Mosby Co, 1978.)





A



B

FIGURE 15–59 Bucholz-Ogden type II lateral avascular necrosis after closed reduction, following traction at age 2 months that was followed by 3 months in a spica cast. A, At age 2 years, early lucency is seen in the metaphysis. B, At 4 years, there is valgus tilt and uncovering due to lateral growth arrest secondary to avascular necrosis.

metaphysis is not involved (Fig. 15–57). These hips usually heal without significant growth disturbance and their outcome is not compromised. The hallmark of this type is irregular ossification of the femoral head with no abnormalities of ossification of the metaphysis. An early growth arrest line may indicate symmetric growth of the metaphysis, which suggests that no growth injury has occurred.¹⁵⁴ In type II the lateral metaphysis shows evidence of injury and the femoral head will grow into a valgus deformity following premature lateral epiphyseal closure (Figs. 15–58 and 15–59). In type III the entire metaphysis is affected and the femoral neck will be extremely short, with marked trochanteric overgrowth (Figs. 15–60 and 15–61). In type IV a radiolucent defect along the medial metaphysis may be seen early, indicating a growth disturbance of the medial growth plate that will cause the femoral head to grow into a varus deformity (Figs. 15–62 and 15–63). In types II, III, and IV there is relative overgrowth of the greater trochanter that in time may result in an abductor limp.

Kalamchi and MacEwen developed another classification of AVN.⁹⁴ In their system, grade 1 reflects changes confined to the ossific nucleus, grade 2 involves the lateral growth plate, grade 3 involves the central physis, and grade 4 indicates total physeal and head injury. A comparison of the Kalamchi-MacEwen and Bucholz-Ogden systems shows that Kalamchi-MacEwen grade 1 = Bucholz-Ogden type I, Kalamchi-MacEwen grade 2 = Bucholz-Ogden type II, and Kalamchi-MacEwen grade 4 = Bucholz-Ogden type III (Table 15–5).

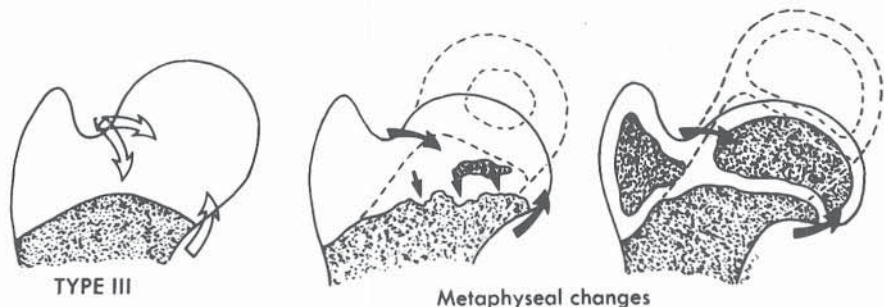
A disturbing late abnormality that may be a manifestation of AVN is closure of the lateral portion of the capital femoral growth plate in adolescence (this is probably a late Bucholz-

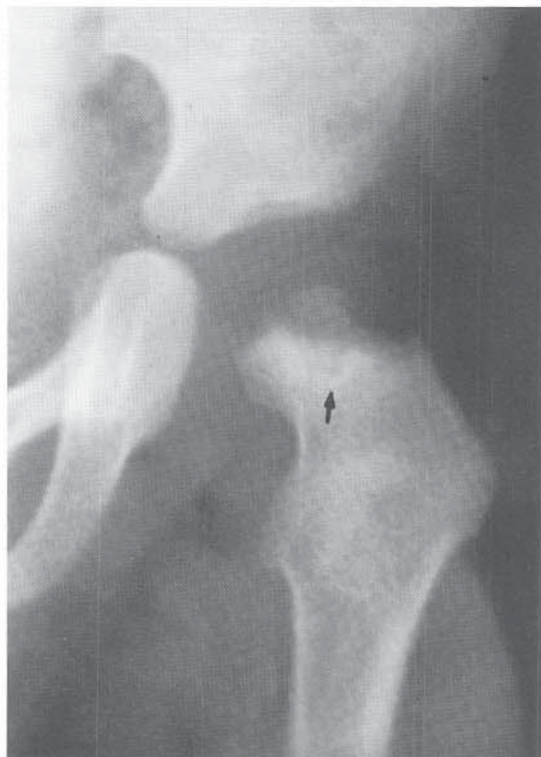
Ogden type II case). Closure can occur in a hip that has shown no early evidence of a vascular insult. Often the femoral head, which has been relatively well covered by the acetabulum, appears to gradually drift laterally. Radiographs obtained in the early teen years show early closure of the lateral portion of the growth plate, with progressive valgus tilting of the femoral head on the metaphysis. When this occurs, progressive dysplasia of the hip may follow. Corrective treatment options include varus femoral osteotomy and a redirection acetabular procedure, such as a triple innominate osteotomy. If this complication is recognized early, the surgeon could consider some form of arrest of the medial portion of the growth plate, but this has not been described to date.

In the normal hip, the tip of the greater trochanter is slightly distal to or level with the center of the femoral head. The relationship of the femoral head to the trochanter can be measured radiographically as the articulo-trochanteric distance, whose value becomes negative when the trochanter is proximal to the upper portion of the head of the femur⁴⁵ (Fig. 15–56). The relative height of the greater trochanter and the length of the femoral neck determine the biomechanical function of the gluteus medius and minimus muscles. As explained by the Blix curve, muscle fiber tension is proportional to muscle fiber length at the moment of excitation.¹⁴ When a muscle fiber is shortened to less than 60 percent of its resting length, its contractile force is lost. In the hip, when the tip of the trochanter reaches the level of the femoral head, the abductor muscle tension is altered and the patient will usually develop an abductor limp.¹¹⁵

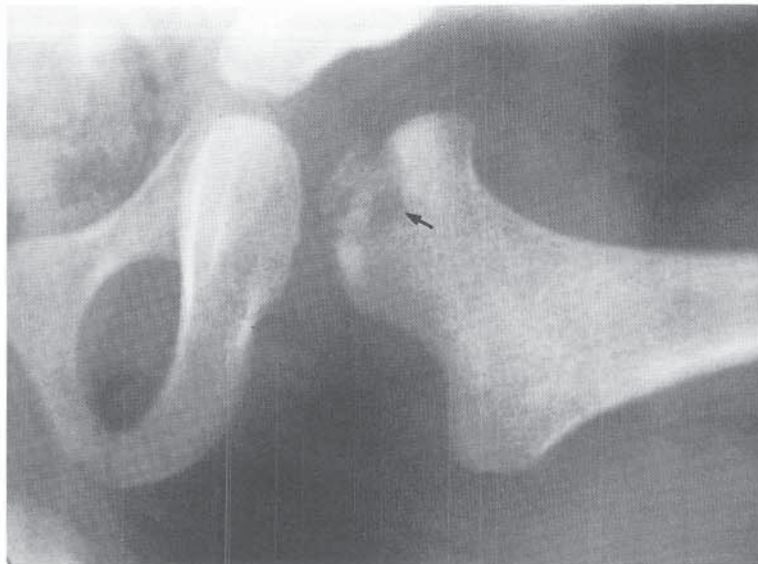
Another factor that contributes to the abductor limp is shortening of the femoral neck. The effectiveness of the

FIGURE 15–60 Bucholz-Ogden type III avascular necrosis. The ischemic effect is noted across the entire physis (open arrows), with disturbance of the complete growth of the epiphysis. (From Bucholz RW, Ogden JA: Patterns of ischemic necrosis of the proximal femur in nonoperatively treated congenital hip diseases. In *The Hip: Proceedings of the Sixth Open Scientific Meeting of the Hip Society*. St. Louis, CV Mosby Co, 1978.)





A



B

FIGURE 15-61 Bucholz-Ogden type III severe central avascular necrosis in a boy who was treated elsewhere with closed reduction and casting without traction at age 2 months. **A**, AP radiograph obtained at age 11 months shows central metaphyseal lucency and fragmentation of the femoral head, indicating extensive avascular necrosis. **B**, Frog-leg lateral radiograph obtained at age 11 months shows central metaphyseal lucency (*arrow*).

abductor muscles is decreased as the lever arm (i.e., the femoral neck) shortens. In addition, the direction of pull of the abductors is steeper when the femoral neck is shortened, which also decreases their function.¹⁶¹

INTERVENTIONS TO ALTER THE EFFECTS OF AVASCULAR NECROSIS

Some of the anatomic effects of AVN can be altered by appropriate intervention. Procedures include trochanteric epiphysiodesis, trochanteric advancement, intertrochanteric double osteotomy, and lateral closing wedge valgus osteotomy with trochanteric advancement.

Trochanteric Epiphysiodesis. Relative trochanteric overgrowth can be prevented by performing a trochanteric epiphysiodesis at the appropriate time (Plate 15-7). This procedure should be done when major AVN is recognized and the ossific nucleus of the greater trochanter is present. Studies have shown it to be most effective if performed when the child is around 5 years old and to be ineffective if done when the child is much more than 8 years old.^{56,85,115} Langenskiöld has described a technique of trochanteric arrest that is similar to the Phemister technique used in the limbs. We prefer curettage of the physis of the trochanter, performed through a small incision and using image intensification.

Trochanteric Advancement. Trochanteric advancement may be considered when an objectionable abductor limp results from trochanteric overgrowth (Fig. 15-64; Plates 15-8 and 15-9). The surgeon should consider a trochanteric transfer when the greater trochanter has reached the level

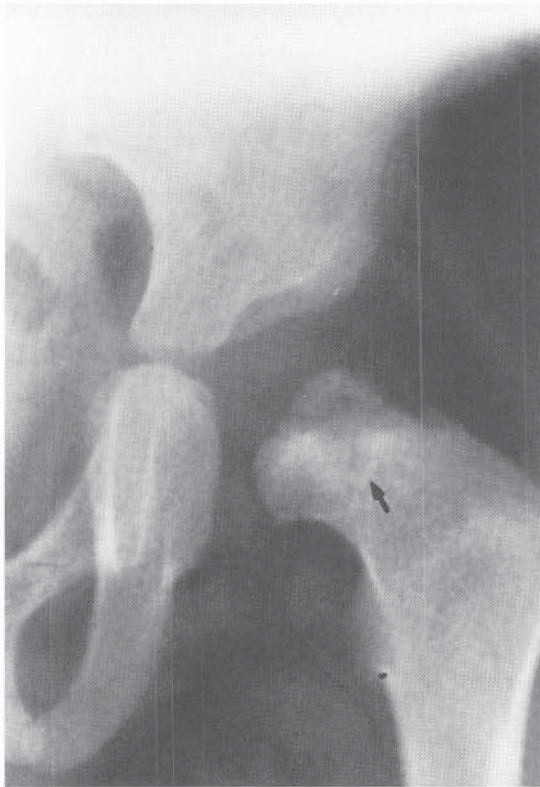
of the top of the femoral head, when there is a congruous, concentric reduction of the hip, when Trendelenburg's sign can be elicited, and when the child is over 8 years old.^{13,129,132} Significant subluxation or dysplasia of the hip will cause a similar limp, and trochanteric advancement in a dysplastic hip will not improve the patient's gait.

Wagner has recommended lateral (as opposed to distal) transfer of the greater trochanter when the neck is short and the trochanter has not grown above the femoral head.²²⁴ The indications again include an abductor limp and a congruous hip reduction.

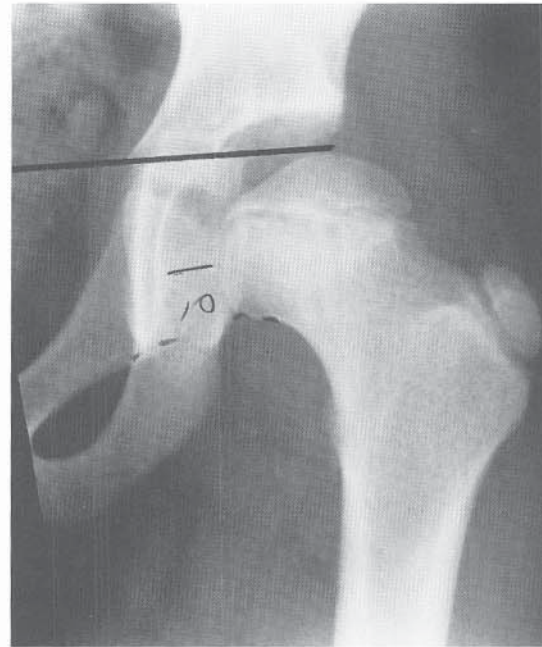
In several reports, the abductor limp either improved or resolved in most patients who underwent a trochanteric advancement procedure.^{98,208,224} However, the results of trochanteric advancement are frequently unsatisfactory if there is residual hip dysplasia.¹²⁹ The surgeon should realize that it often is difficult to advance the trochanter as far as would be ideal, and fixation is sometimes inadequate.

Intertrochanteric Double Osteotomy. Wagner has also described a procedure to improve the function of the hip when the trochanter is markedly overgrown, abutting the pelvis, and the femoral neck is very short (Plate 15-10).²²⁴ He performs a double osteotomy of the femoral neck, using a portion of the base of the trochanter to elongate the femoral neck (Fig. 15-65). This operation creates several moving parts and requires excellent fixation by an experienced hip surgeon.

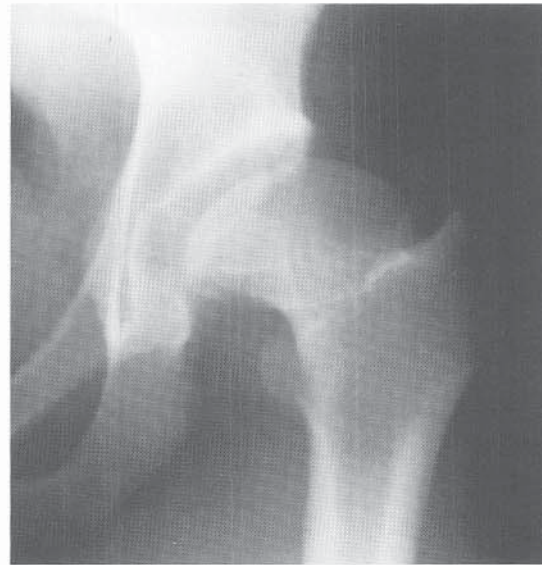
Lateral Closing Wedge Valgus Osteotomy with Trochanteric Advancement. Coxa vara with trochanteric overgrowth may also be corrected with a valgus osteotomy at the intertrochanteric level combined with a trochanteric



C



D



E

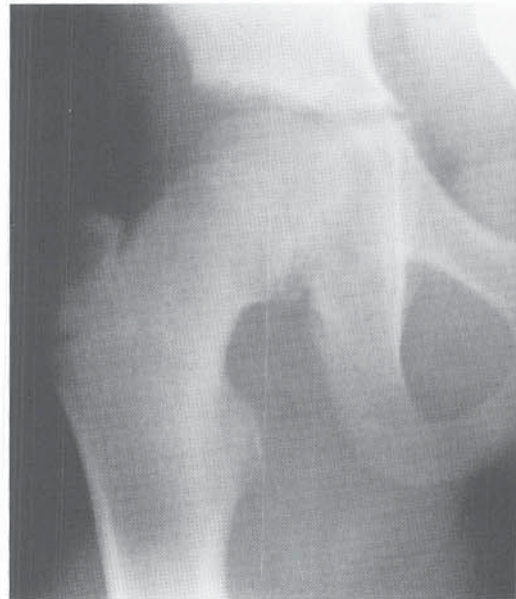
FIGURE 15-61 *Continued.* C, AP radiograph obtained at age 21 months shows extensive metaphyseal change (*arrow*) indicative of avascular necrosis. D, AP radiograph obtained at age 8 years shows a short femoral neck with early trochanteric overgrowth. This is an appropriate age for trochanteric epiphysiodesis. E, AP radiograph obtained at maturity shows trochanteric overgrowth.

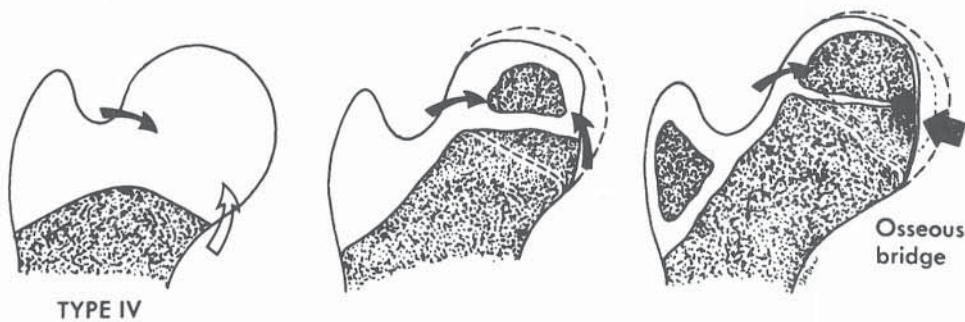
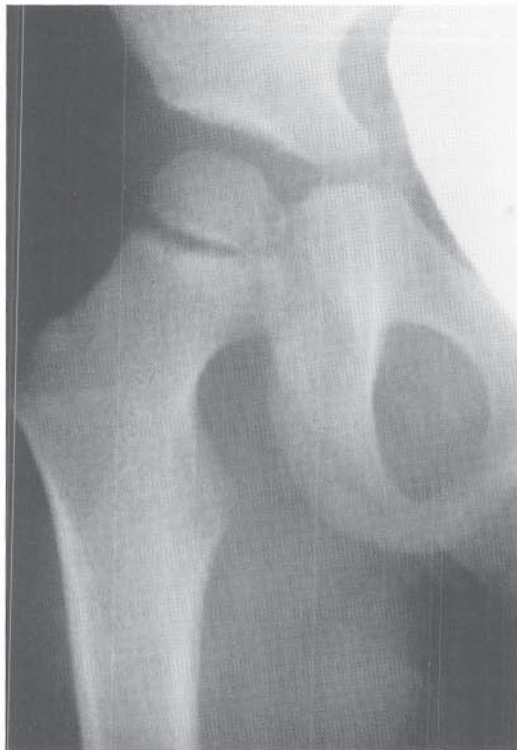
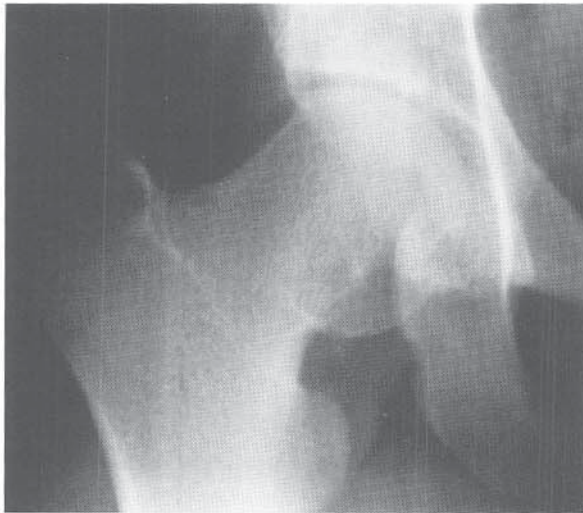
FIGURE 15-62 Bucholz-Ogden type IV avascular necrosis. The primary ischemia occurs medially (*open arrow*), producing early closure of the medial portion of the physis with resultant growth into a varus deformity. (From Bucholz RW, Ogden JA: Patterns of ischemic necrosis of the proximal femur in non-operatively treated congenital hip diseases. In *The Hip: Proceedings of the Sixth Open Scientific Meeting of the Hip Society*. St. Louis, CV Mosby Co, 1978.)



A



B



C

FIGURE 15-63 Bucholz-Ogden type IV medial avascular necrosis, with late varus developing in the untreated hip. The child underwent treatment of the left hip with traction and closed reduction at age 4 months, followed by abduction splinting. The following findings were noted in the right hip, which was initially normal. **A**, At age 3 years an irregularity of the medial portion of the physis was noted. **B**, At age 12 years the femoral head was tilted into a varus position relative to the femoral neck. **C**, At age 18 years the varus tilt of the femoral head had increased. The patient had no symptoms. The long-term significance of this abnormality is unknown.

transfer (Plate 15-11). A lateral closing wedge osteotomy is performed at the base of the greater trochanter and is combined with a trochanteric osteotomy. The osteotomy site is closed by aligning two Kirschner wires, while the neck-shaft and greater trochanteric fragments are aligned and fixed with a prebent trochanteric hook plate.

INADEQUATE REDUCTION AND REDISLOCATION

In current practice, the most common complication in the management of DDH is failure to obtain and maintain the reduction. After closed reduction, single-section CT is helpful in assessing the reduction in the cast. Failure to maintain

the reduction is not in itself a major complication, but failure to recognize the unreduced hip guarantees a poor result. If the hip has redislocated, a second attempt at reduction with the patient under anesthesia should be carried out promptly. A repeated attempt at closed reduction is occasionally successful, but the surgeon should be prepared to perform an open reduction if the hip is not stable.

A more difficult situation arises when the hip is not well reduced after an open reduction. Most often, the surgeon has not adequately exposed the acetabulum and obtained a deep reduction to begin with. The intraoperative radiographs are often misread, and what appears to be minor widening of the space between the femoral head and the

TABLE 15-5 Classification Systems of Avascular Necrosis of the Proximal Femur**Bucholz–Ogden System**

Type I	Changes limited to femoral head; metaphysis not involved; hips usually heal without significant growth disturbance; outcome not compromised. Irregular ossification of the femoral head with no abnormalities of ossification of the metaphysis is the hallmark of type I AVN.
Type II	Lateral metaphysis shows evidence of injury; femoral head grows into valgus deformity following premature lateral epiphyseal closure; relative overgrowth of greater trochanter.
Type III	Entire metaphysis affected; femoral neck extremely short, with marked trochanteric overgrowth.
Type IV	Lucent defect along medial metaphysis indicates growth disturbance of medial growth plate, which causes femoral head to grow into varus deformity; relative overgrowth of greater trochanter.

Kalamchi–MacEwen System

Grade 1	Changes confined to ossific nucleus (similar to Bucholz–Ogden type I).
Grade 2	Lateral growth plate involved (similar to Bucholz–Ogden type II).
Grade 3	Central physis involved.
Grade 4	Total physeal and femoral head injury (similar to Bucholz–Ogden type III).

acetabulum is often the difference between a well-reduced hip and a hip that remains dislocated. A repeated attempt at open reduction is usually necessary after redislocation, although in certain circumstances a closed reduction may be successful. The wise surgeon will seek an experienced assistant before repeating the procedure. The hip in which open reduction has failed is difficult to treat, especially if there is a great deal of scarring or if much time has passed since the reduction (Fig. 15–66). McCluskey and associates found that after two to seven further operations, only one-third of hips had acceptable results.¹³⁶ The rate of AVN was 44 percent. Other authors reported that two-thirds of their patients' hips developed AVN after repeated open reduction.¹⁷

Occasionally a hip that has been well reduced and immobilized for an appropriate time will redislocate or, more commonly, become subluxated. If there is significant widening of the joint, an open reduction and capsulorrhaphy will probably be necessary. In some cases the subluxated hip will respond to prolonged splinting, and this may be a treatment option if the hip is concentrically reduced. If the hip is dislocated, an open reduction will be necessary.

RESIDUAL ACETABULAR DYSPLASIA

Following reduction of a dislocated hip, the acetabulum begins to remodel in response to the pressure exerted by the femoral head (Fig. 15–67). Usually this results in gradual deepening of the acetabulum and reduction of the obliquity of the acetabular roof. Many times, however, this process is incomplete and the acetabulum will remain shallow and the roof inclined. The development of the sourcil (or “eyebrow”) is a reliable indicator of acetabular development (see Fig. 15–73B). Often the acetabular roof appears to provide adequate femoral head coverage while the sourcil is oblique and shallow. True coverage of the femoral head is repre-

sented by the position of the sourcil rather than the apparent acetabular roof.

Early reports stated that acetabular development was completed by 18 months of age.¹⁸¹ Others have found that the acetabulum continues to develop up to 8 years after reduction if the hip is reduced before age 4½ years.¹²⁵ There is good evidence that if acetabular obliquity is still present at age 5 years, after treatment of the dislocation, further acetabular development will be inadequate. Thus, if significant dysplasia persists through 5 years of age, a pelvic osteotomy should be performed to ensure adequate development of the hip. Some authors recommend a varus-derotational femoral osteotomy in younger patients with acetabular dysplasia.^{15,97,144}

ACETABULAR DYSPLASIA PRESENTING LATE

A number of patients will present with hip complaints in adolescence. Some of these patients will have a previous history of treatment of hip dislocation, but many are unaware of any prior hip problems. The affected patient complains of aching pain, often in the groin (sometimes referred laterally or down the thigh to the knee), that occurs after exertion and long periods of walking or standing. The patient will limp when tired or uncomfortable. Once these symptoms start, they usually increase steadily in frequency and severity, often over a relatively short period of time. The physical findings are usually minimal. Some patients have a Trendelenburg limp or a delayed Trendelenburg's sign, and there may be some discomfort at the extremes of hip motion. The surgeon should be alert to signs of snapping or popping, which may be caused by a tear in the labrum. In these situations, the pain will be exacerbated when the hip is maximally flexed and internally rotated. Gadolinium-enhanced MRI arthrography may demonstrate the labral pathology.¹²² When there is a labral tear, an arthrotomy may be necessary, and the torn portion may need to be excised.

Standing radiographs should be obtained. It is important for the surgeon to specifically distinguish among dysplasia, subluxation, and degenerative disease. Acetabular dysplasia is defined by loss of concavity of the acetabular roof, excessive lateral inclination of the roof, and widening of the teardrop body. Subluxation of the hip is best documented by comparing the distance from the medial acetabular wall to the femoral head on the involved and uninvolved sides. A subluxated femoral head is displaced proximally as well as laterally, and Shenton's line is broken. Degenerative disease is indicated by the presence of sclerosis and cyst formation on either side of the joint and narrowing of the cartilage joint space. Osteophyte formation is a late manifestation of degenerative disease. Any of these abnormalities may be present separately or in combination with one another.

The treatment strategy is based on whether or not the hip can be concentrically reduced. This is first assessed radiographically with the patient supine and the hip abducted and internally rotated. If the femoral head can be reduced against the medial acetabular wall, a redirection procedure is recommended. These procedures reorient the acetabulum so that the femoral head is better covered with acetabular articular cartilage. If concentric reduction is not possible, a salvage procedure in which the femoral head is not covered

Text continued on page 596

Greater Trochanter Epiphysiodesis (Langenskiöld)

OPERATIVE TECHNIQUE

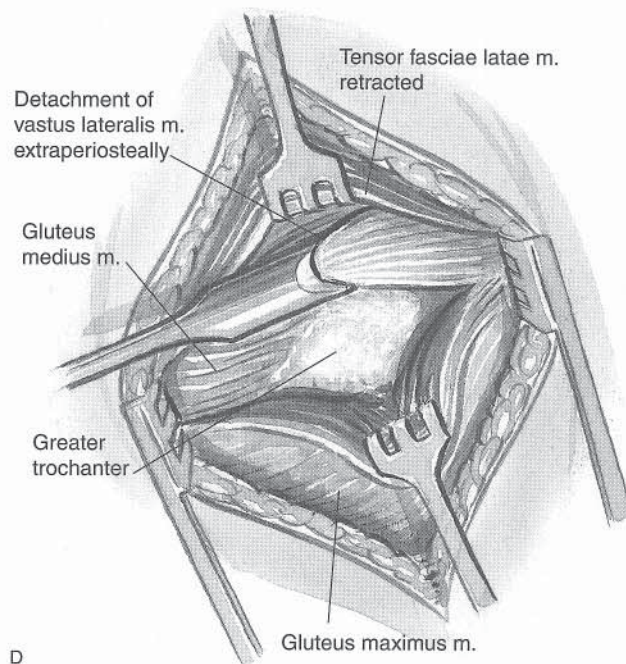
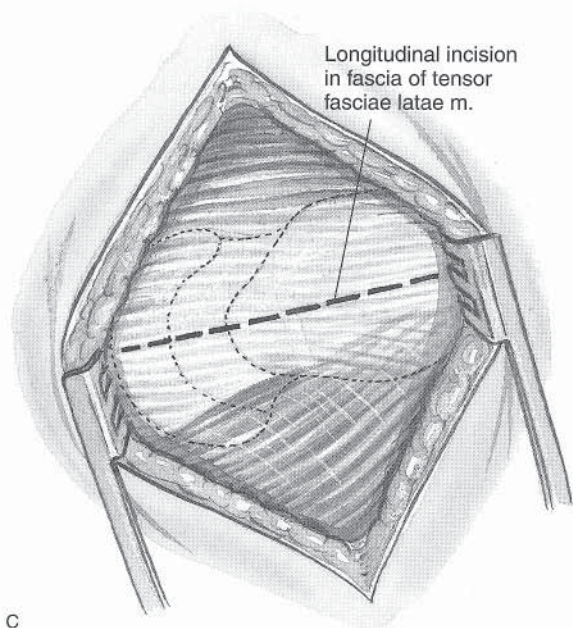
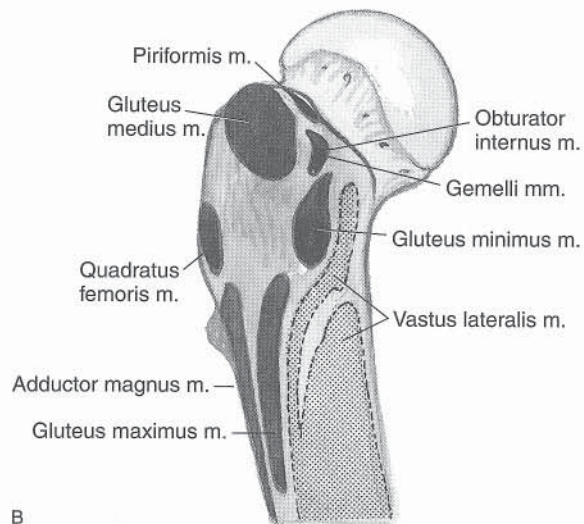
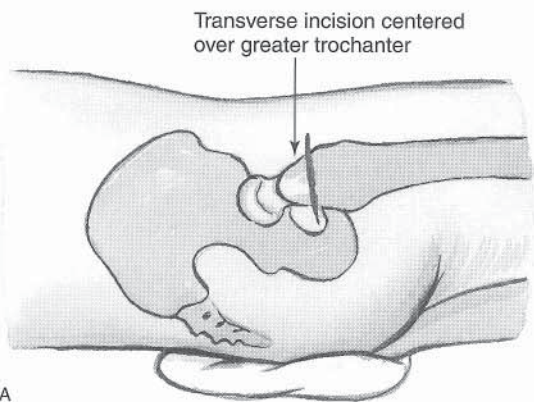
A, The child is placed supine with a sandbag under the ipsilateral hip. The entire lower limb, hip, and pelvis are prepared and draped to permit free passive motion of the hip. A 5- to 7-cm-long transverse incision is centered over the epiphysis of the greater trochanter. If desired, a longitudinal incision may be made, especially if distal transfer of the greater trochanter is anticipated in the future.

B, The site of origin of the vastus lateralis from the upper part of the intertrochanteric line, the anteroinferior border of the greater trochanter, the lateral tip of the gluteal tuberosity, and the upper part of the lateral tip of the linea aspera is shown.

C, The subcutaneous tissue is divided in line with the skin incision. The wound edges are retracted. A longitudinal incision is made in the fascia of the tensor fasciae latae muscle.

D, The tensor fasciae latae muscle is retracted anteriorly, and the origin of the vastus lateralis is detached and elevated extraperiosteally.

PLATE 15-7. Greater Trochanter Epiphysiodesis (Langenskiöld)



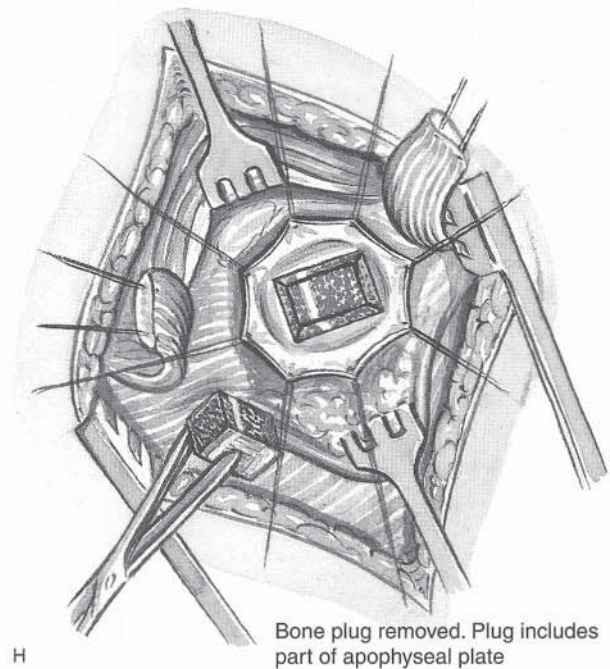
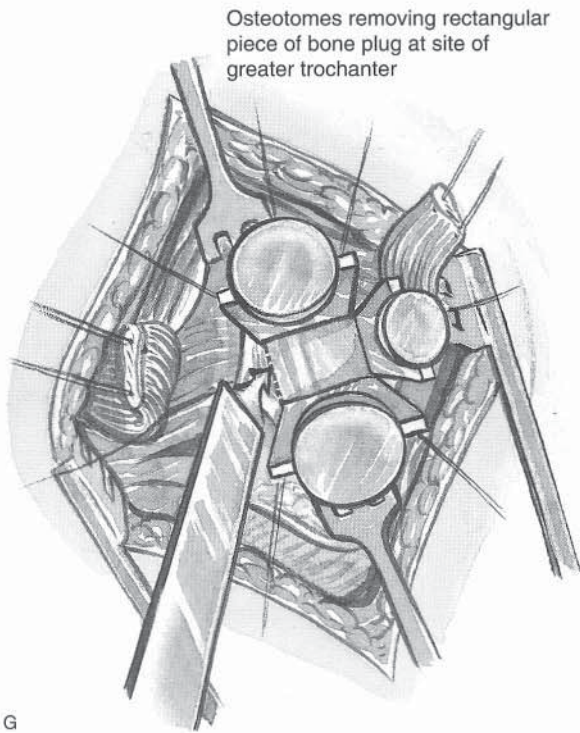
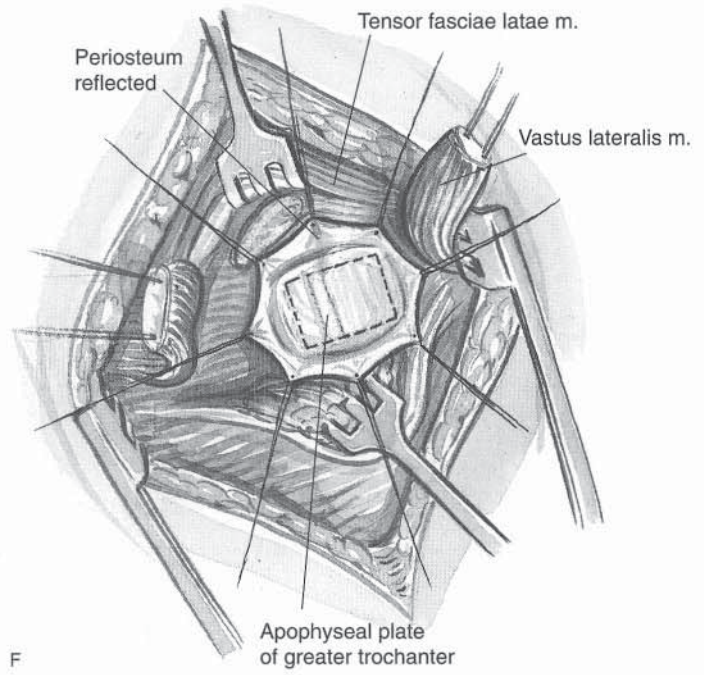
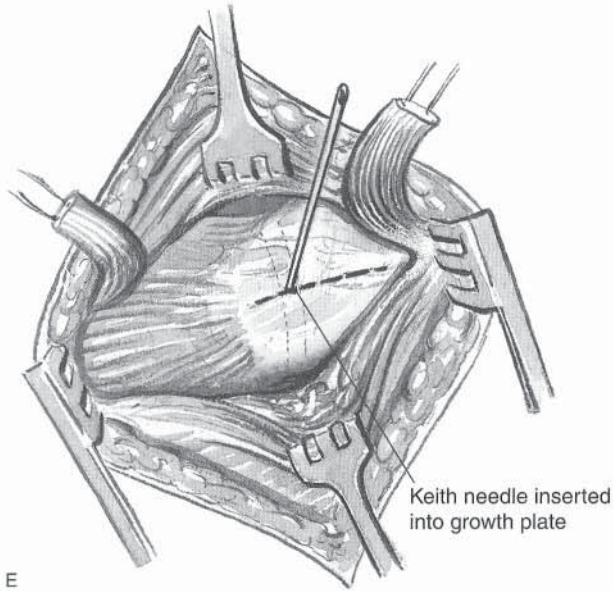
Greater Trochanter Epiphysiodesis (Langenskiöld) *Continued*

E, A Keith needle is inserted into the soft growth plate of the greater trochanteric epiphysis. AP radiographs are obtained to verify the position of the Keith needle and the growth plate.

F, The periosteum is divided by one longitudinal and two horizontal incisions. The dotted rectangle marks the bone plug to be removed and turned around. This rectangle is 2 cm long and 1.25 cm wide. In a smaller child the rectangle is 1 cm ($\frac{3}{8}$ inch) long and 0.6 cm ($\frac{1}{4}$ inch) wide.

G and H, With straight osteotomies, the bone plug is removed. Note that the growth plate is in the proximal third of the rectangle.

PLATE 15-7. Greater Trochanter Epiphysiodesis (Langenskiöld)



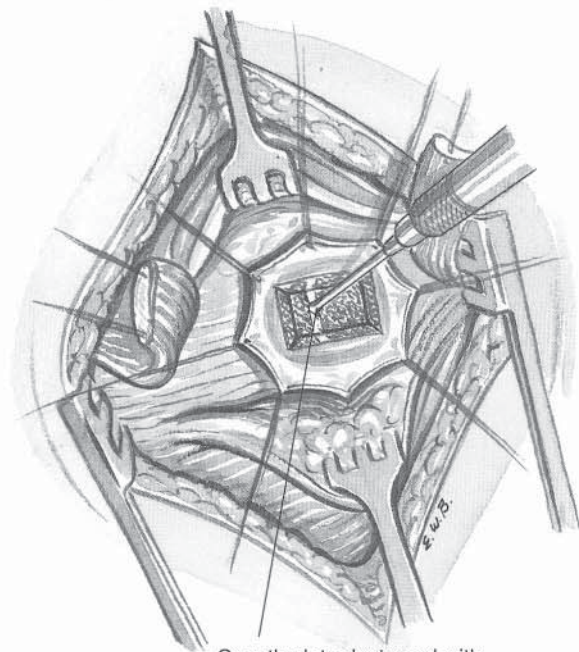
Greater Trochanter Epiphysiodesis (Langenskiöld) *Continued*

I, A diamond-shaped drill and curets are used to destroy the growth plate. The operator should be careful not to enter the trochanteric fossa and injure circulation to the femoral head.

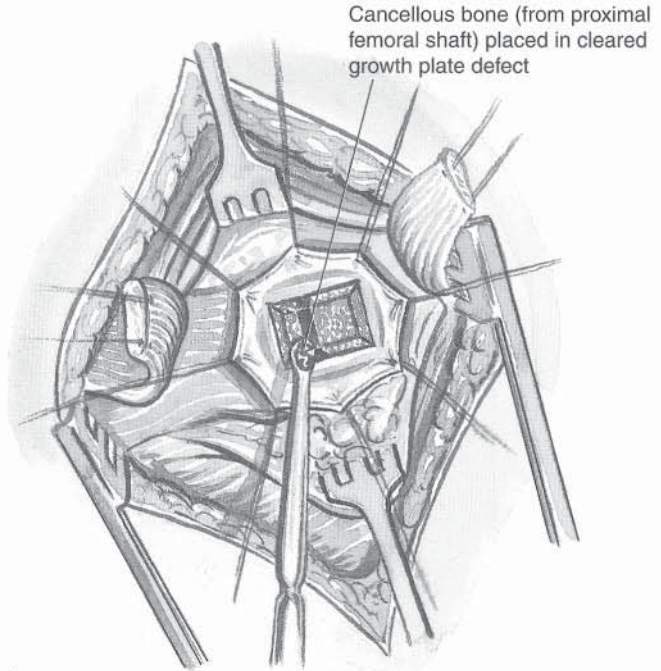
J, With a curved osteotome, cancellous bone is removed from the proximal femoral shaft and packed into the defect at the site of the growth plate.

K and L, The bone plug is rotated 180 degrees, is replaced in the defect in the greater trochanter, and with an impactor and mallet, is securely seated.

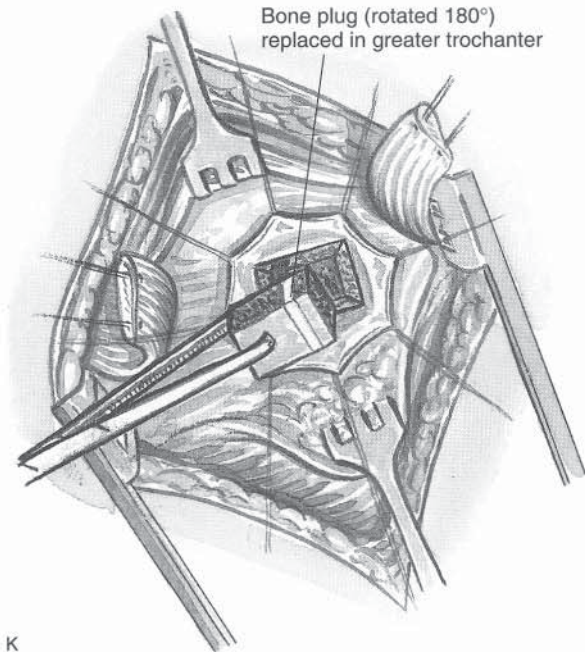
PLATE 15-7. Greater Trochanter Epiphysiodesis (Langenskiöld)



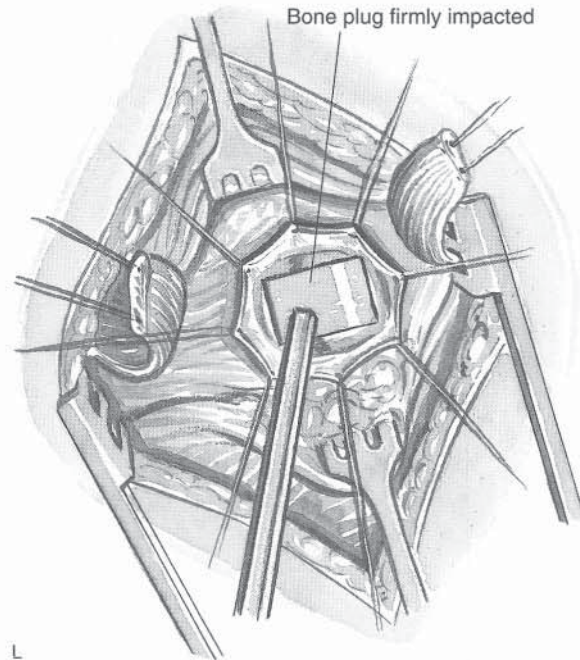
Growth plate destroyed with diamond-shaped drill and curets



Cancellous bone (from proximal femoral shaft) placed in cleared growth plate defect



Bone plug (rotated 180°) replaced in greater trochanter



Bone plug firmly impacted

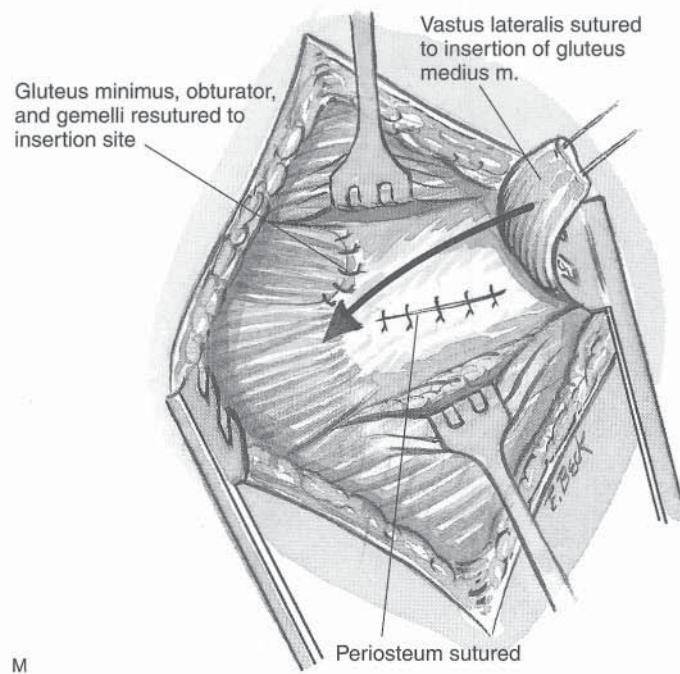
Greater Trochanter Epiphysiodesis (Langenskiöld) *Continued*

M, The muscles are resutured to their insertion sites, and the vastus lateralis is attached to gluteus medius-minimus tendons at their insertion after closure of the periosteum. The fascia lata is closed with interrupted sutures, and the wound is closed with interrupted and subcuticular sutures. It is not necessary to immobilize the hip in any cast.

POSTOPERATIVE CARE

The patient is allowed out of bed on the first postoperative day, as soon as he or she is comfortable. The patient is discharged to home within a few days and is instructed to protect the limb that was operated on by using a three-point crutch gait for 3 to 4 weeks.

PLATE 15-7. Greater Trochanter Epiphysiodesis (Langenskiöld)



M

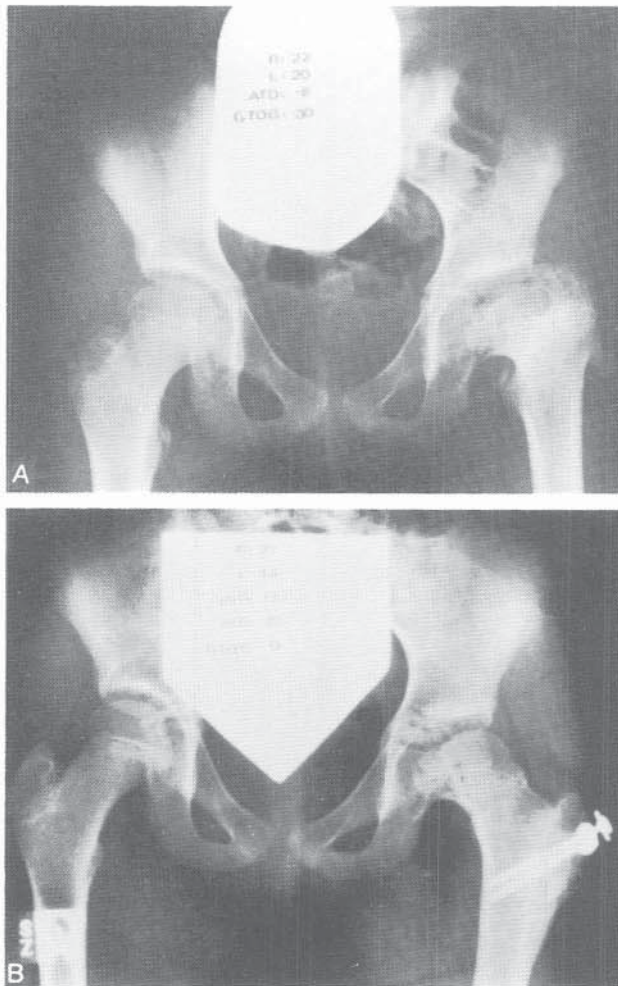


FIGURE 15-64 Avascular necrosis of the left femoral head with resultant coxa breva and relative overgrowth of the greater trochanter, treated by distal and lateral advancement of the greater trochanter. **A**, Preoperative AP radiograph of both hips showing the short femoral neck, coxa vara, and relative overgrowth of the greater trochanter. The patient has marked gluteus medius lurch and a 4-cm shortening of the femur. **B**, Postoperative AP radiograph of the hips showing a closing. (From Kelikian AS, Tachdjian MO: Greater trochanteric advancement. In *The Hip Society Awards Papers*. St. Louis, CV Mosby Co, 1983.)

by preexisting articular cartilage is indicated. There are intermediate cases that do not appear reduced on the abduction-internal rotation radiograph but that may be reduced as part of the surgical procedure. For example, these hips may be reduced with a femoral redirection procedure, or even an open reduction, and then covered with a redirection acetabular procedure.

When acetabular dysplasia is detected and the patient is asymptomatic, the treatment decision is difficult. If a repositioning procedure will restore near normal acetabular alignment, we recommend performing such a procedure in the absence of symptoms, with the goal of preventing future degenerative disease. This decision is based on the high likelihood that the patient will later develop symptoms and on the evidence that better acetabular coverage, preferably while the child is still growing, allows the hip to remodel. On the other hand, a salvage procedure is usually not indicated if the patient has no symptoms. These procedures are usually

recommended only when the patient has significant symptoms that interfere with activities.

Procedures such as the Salter innominate osteotomy and the Pemberton osteotomy are used for dysplastic hips that are concentrically reduced in children younger than 8 or 9 years. In older children and adolescents, the acetabulum must be displaced to a greater degree to provide coverage of the hip. Procedures used for this age group include the Steel triple pelvic osteotomy,^{198,199} the Sutherland double osteotomy,²⁰² the Ganz osteotomy,⁶⁰ the Tonnis procedure,^{213,215} and the Dega osteotomy.²⁰⁶ We prefer the Steel procedure for moderately severe dysplasia and recommend a Ganz-type osteotomy for the most severe dysplasia. Spherical osteotomies, described by Wagner and Eppright and others, may be used to cover severely dysplastic hips.^{47,142,225,226} However, these procedures are technically very difficult to perform and are sometimes complicated by inadvertent penetration of the acetabulum by the osteotomy. In addition, the acetabular fragment depends on the hip capsule for its vascular supply, and AVN may develop after a spherical osteotomy.

Hips that cannot be concentrically reduced may be improved by the use of procedures that cover the femoral head with structures that will become fibrocartilage. The Chiari osteotomy and the shelf procedure are two such approaches.^{39,196} In both procedures the femoral head is covered with a layer of hip capsule buttressed by bone. The Chiari osteotomy accomplishes this end by displacing the femoral head medially beneath a pelvic osteotomy, whereas the shelf procedure adds bone laterally over the head. After either procedure the hip capsule undergoes gradual metaplasia to fibrocartilage, and the overlying bone hypertrophies and remodels to conform to the femoral head. The Chiari osteotomy, because it moves the hip medially, is believed to improve the biomechanics of the hip.

Reconstructive Procedures for Dysplasia

SIMPLE PELVIC OSTEOTOMIES THAT REPOSITION THE ACETABULUM

Most of these pelvic osteotomies can be performed through a bikini incision and an anterior tensor-sartorius interval approach as described by Salter (Table 15-6).¹⁸¹ This incision results in minimal scarring. Because the traditional Smith-Peterson skin incision leaves a wide, deep scar and offers no better exposure, the procedure should be abandoned. Cast immobilization after these procedures depends on the stability of the fixation and the patient's age. Casts are used after all osteotomies in which an open reduction has been performed, and in most children less than 7 years old.

Pemberton Osteotomy. The Pemberton osteotomy repositions the acetabulum to improve anterior and lateral coverage of the femoral head (Fig. 15-68, Plate 15-12).^{49,163} The osteotomy begins anteriorly at the anterior inferior iliac spine and proceeds posteriorly and inferiorly to enter the triradiate cartilage posterior to the acetabulum. The path of the osteotome is controlled with image-intensified radiogra-

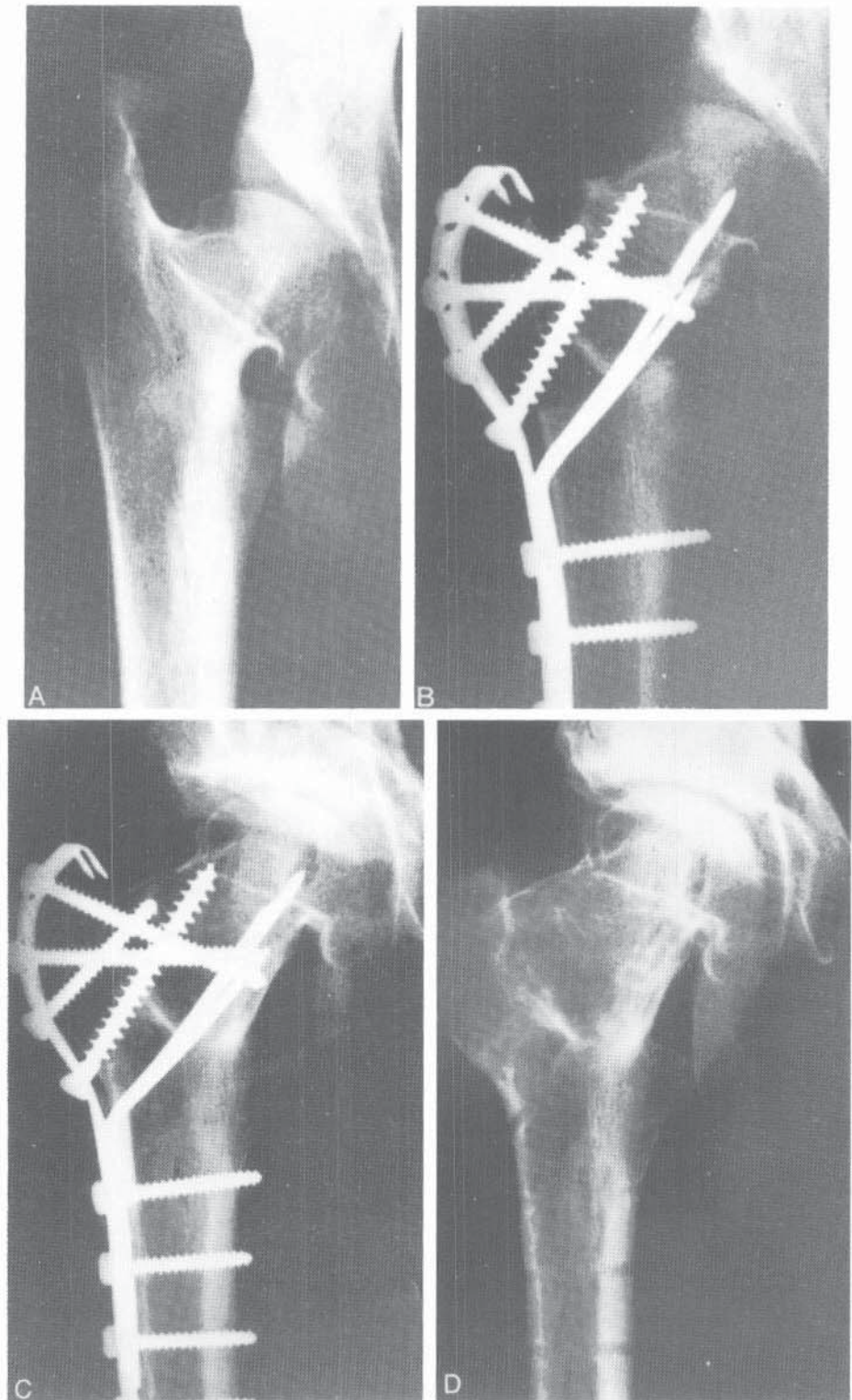


FIGURE 15-65 Wagner double intertrochanteric osteotomy. **A**, Preoperative AP radiograph showing the short femoral neck and severe relative overgrowth of the greater trochanter. **B**, Radiograph obtained immediately postoperatively shows correction of deformity with elongation of the femoral neck. **C**, Radiographic appearance 1 year postoperatively. **D**, Appearance following removal of fixation device. (From Wagner H: Femoral osteotomies for congenital hip dislocation. In Weil UH (ed): *Progress in Orthopedic Surgery*. Vol 2. Acetabular Dysplasia and Skeletal Dysplasia in Childhood, p 85. New York, Springer-Verlag, 1978.)

phy. As the osteotomy is opened, the acetabular fragment is pried into an anterolateral position and held there with a bone graft. This osteotomy is quite stable and does not require fixation. The osteotomy hinges through the triradiate cartilage, which reduces the volume of the acetabulum and makes this procedure especially appropriate for cases in which the acetabulum is capacious. On the other hand,

this operation is contraindicated if the acetabulum is small relative to the size of the femoral head. In such cases the procedure may prevent proper seating of the femoral head. A potential complication of the Pemberton osteotomy is premature closure of the triradiate cartilage caused by the osteotomy passing through the triradiate cartilage.¹⁵³ This complication has been reported but is extremely rare. *Text continued on page 618*

Distal and Lateral Transfer of the Greater Trochanter

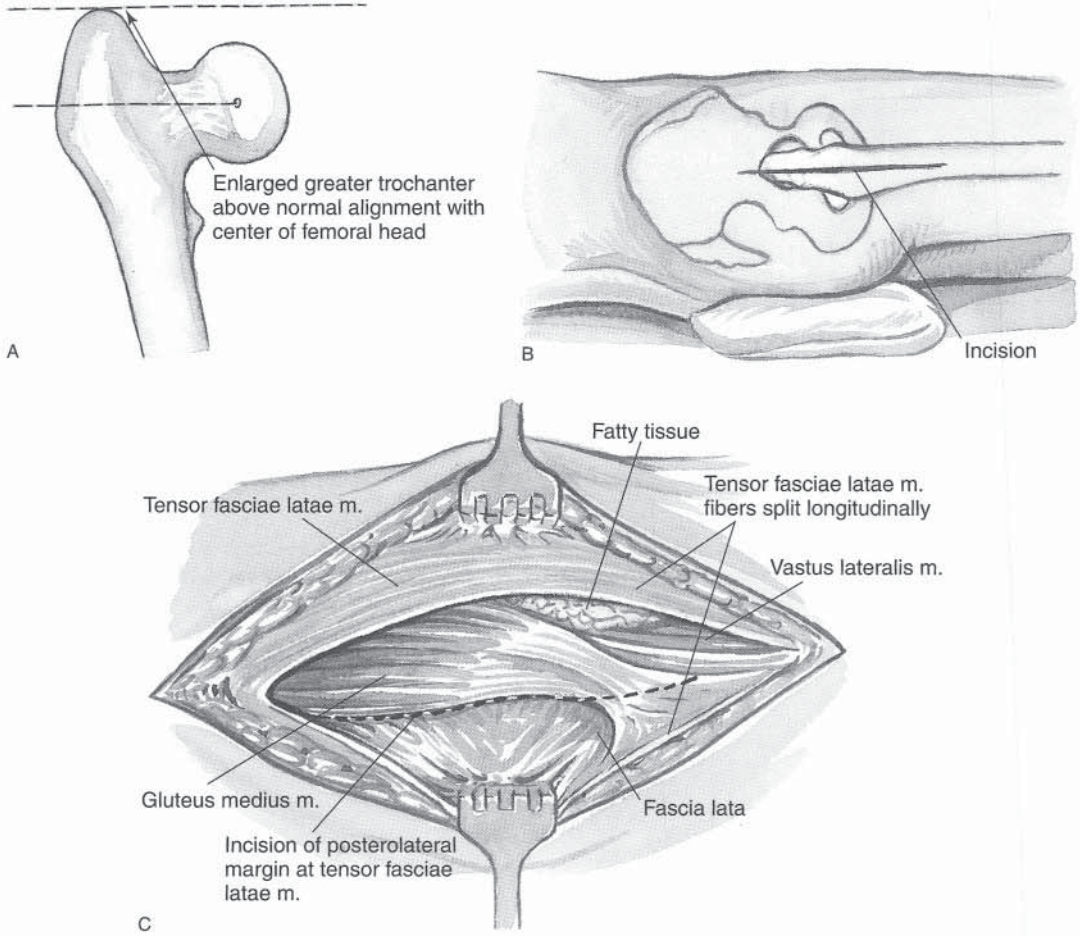
OPERATIVE TECHNIQUE

A and B, The patient is placed on the fracture table with the affected hip in neutral position as to adduction-abduction and in 20 to 30 degrees of medial rotation to bring the greater trochanter forward to facilitate exposure. The opposite hip is placed in 40 degrees of abduction. Image intensifier AP fluoroscopy is used to show the femoral head and neck, the greater trochanter, and the upper femoral shaft. The hip should be rotated medially so that the greater trochanter is seen in profile and not superimposed on the femoral neck. It is crucial to see the trochanteric fossa. The affected hip and upper two-thirds of the thigh are prepared and draped in the usual manner.

A straight lateral longitudinal incision is made from the tip of the greater trochanter and extended distally for 10 cm. The subcutaneous tissue is divided in line with the skin incision.

C, The fascia lata is split longitudinally in the direction of its fibers.

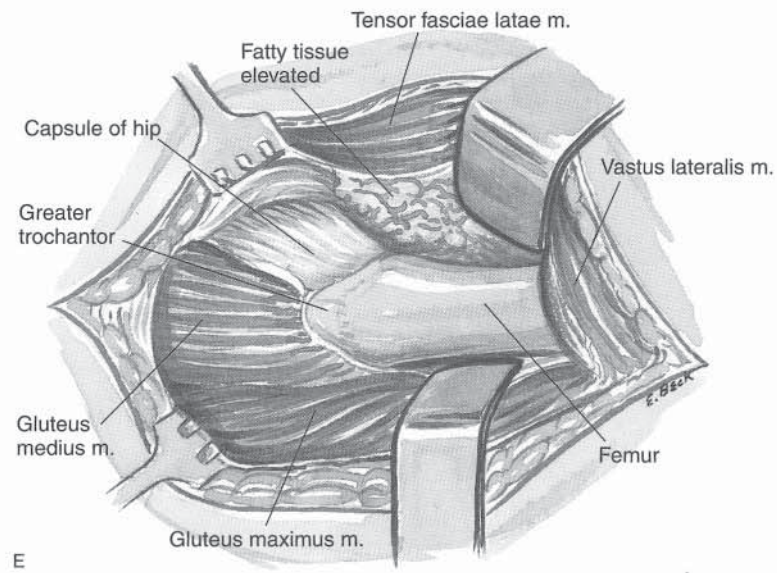
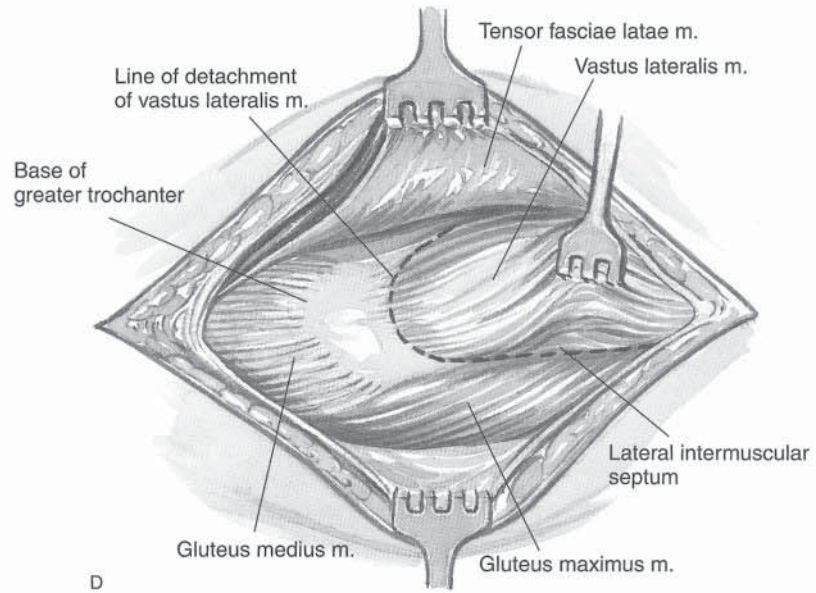
PLATE 15-8. Distal and Lateral Transfer of the Greater Trochanter



Distal and Lateral Transfer of the Greater Trochanter *Continued*

D and E, The vastus lateralis is detached proximally from the abductor tubercle by a proximally based horseshoe-shaped incision and elevated subperiosteally from the femoral shaft for 5 to 7 cm. The vastus lateralis should be elevated in its entire width.

PLATE 15-8. Distal and Lateral Transfer of the Greater Trochanter

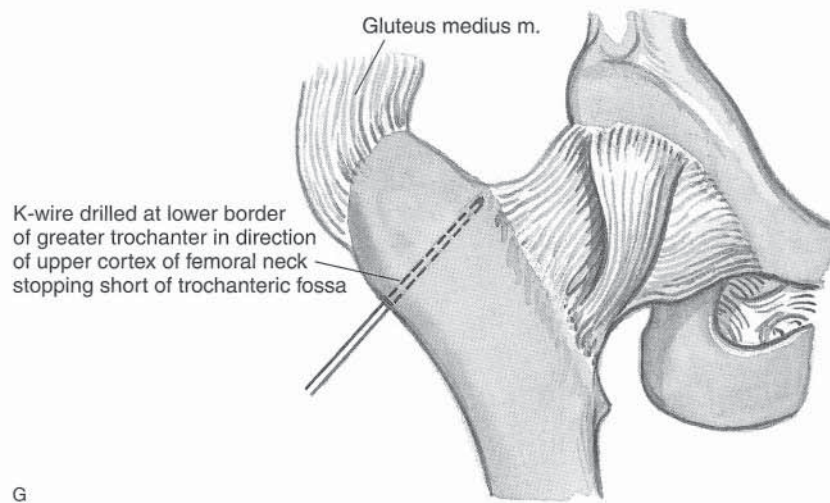
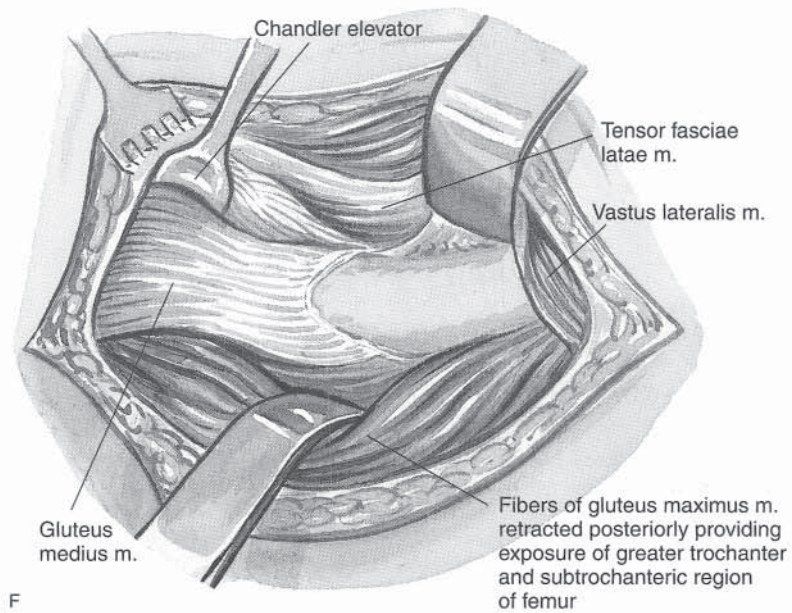


Distal and Lateral Transfer of the Greater Trochanter *Continued*

F, The anterior border of the gluteus medius is identified, and a blunt elevator-retractor is introduced beneath its deep surface, pointing in the direction of the trochanteric fossa.

G, At this time, to orient the plane of the trochanteric osteotomy properly, a smooth Kirschner wire is inserted at the level of the abductor tubercle, pointing to the trochanteric fossa along a line continuous with the upper cortex of the femoral neck. Radiography with image intensification will verify the proper level and depth of the guide wire. The point of the Kirschner wire must not protrude through the medial cortex into the trochanteric fossa.

PLATE 15-8. Distal and Lateral Transfer of the Greater Trochanter



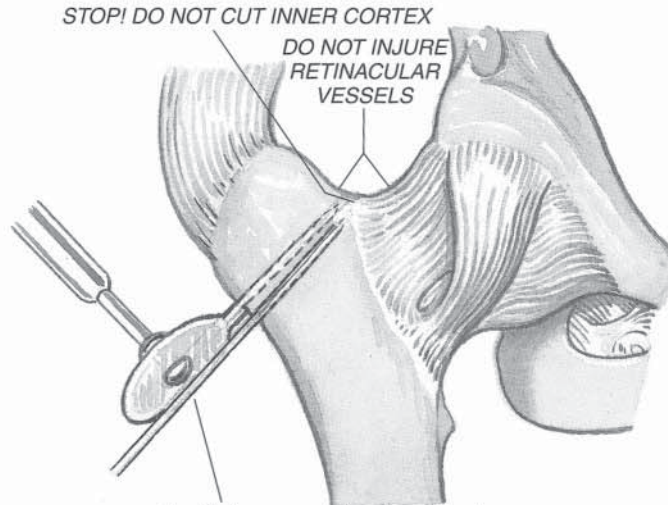
Distal and Lateral Transfer of the Greater Trochanter *Continued*

H, A blunt, flat retractor is placed beneath the posterior border of the greater trochanter to protect the soft tissues. The previously applied anterior retractor protects the soft tissues ventrally. With a 2- to 3-cm-wide reciprocating saw the greater trochanter is divided in the AP direction, following the proximal border of the Kirschner wire. The cut is stopped 3 cm short of the medial cortex of the trochanteric fossa. Injury to the vessels in the trochanteric fossa must be avoided to prevent necrosis of the femoral head.

I, Then a 3-mm-wide flat osteotome is driven through the osteotomy cleft, and the osteotomy site is wedged open by moving the handle of the osteotome cranially. By applying leverage with the osteotome in the cleft, the operator produces a greenstick fracture of the medial cortex.

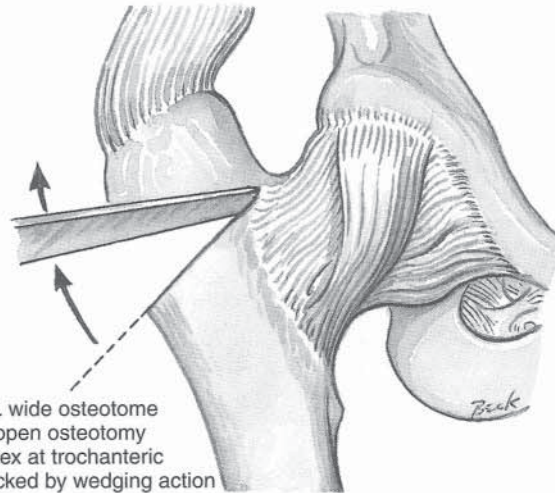
J, A large periosteal elevator is placed deep into the osteotomy cleft, opening it up medially by gently levering the handle up and down. The trochanteric fragment is lifted superolaterally with a Lewin bone clamp, and adhesions between the joint capsule and the medial aspect of the greater trochanter are released. This must be done very carefully so as not to injure retinacular blood vessels in the capsule. Do not fracture the greater trochanter! Mobilization is sufficient when, on lateral and distal traction on the greater trochanter, the muscle response is elastic; if there is still muscle resistance, it means that further adhesions are present that must be freed.

PLATE 15-8. Distal and Lateral Transfer of the Greater Trochanter



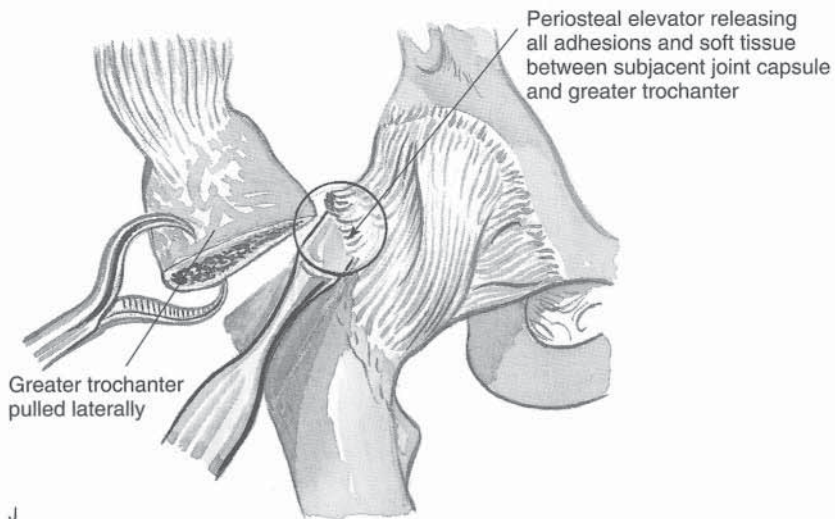
Oscillating saw performing osteotomy on proximal side of K-wire without cutting opposite cortex

H



Flat 3-cm. wide osteotome wedging open osteotomy cleft. Cortex at trochanteric fossa cracked by wedging action

I



J

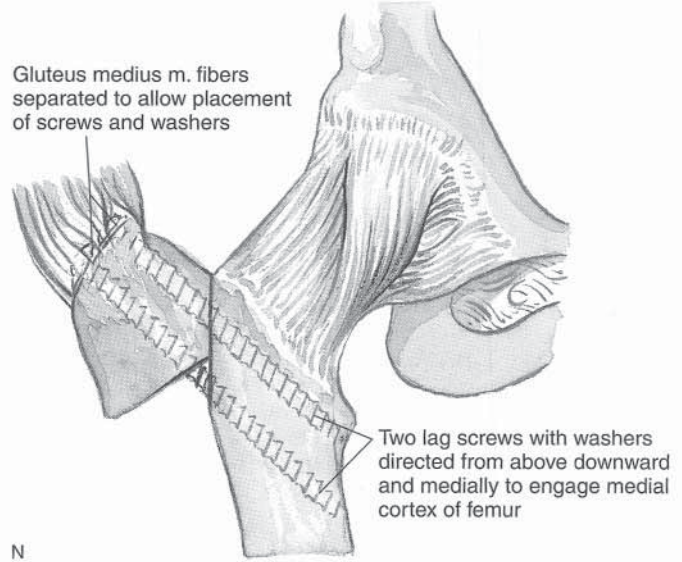
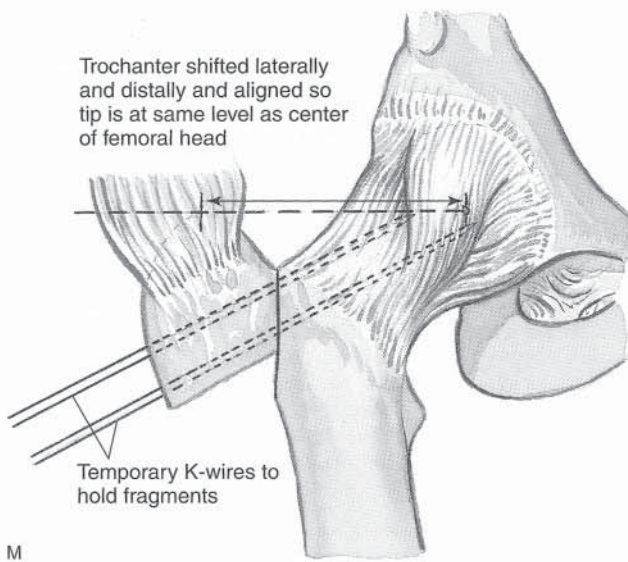
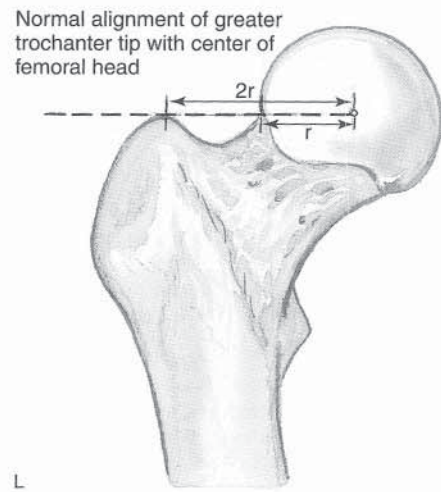
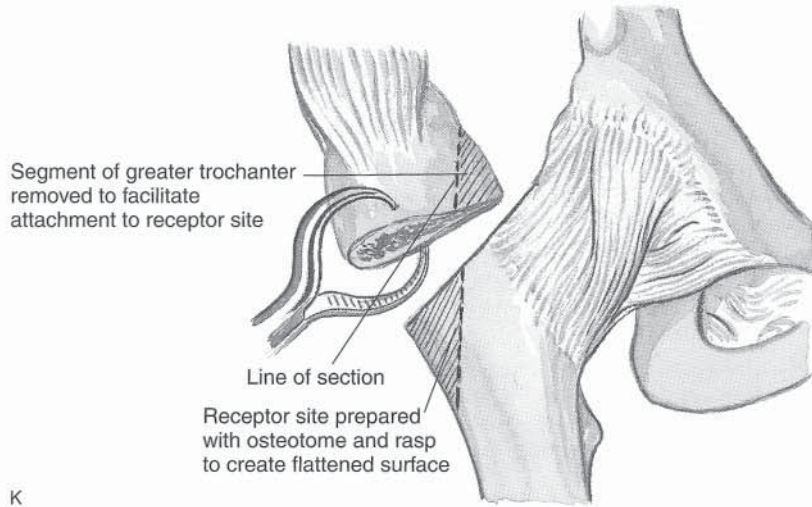
Distal and Lateral Transfer of the Greater Trochanter *Continued*

K, After sufficient mobilization of the greater trochanter, the recipient site on the lateral surface of the upper femoral shaft is prepared with a curved osteotome to create a flattened surface. The surgeon should not remove too much bone laterally. Next, the greater trochanter is displaced distally and laterally; in excessive femoral antetorsion it may be moved slightly forward. If additional distal advancement is desired, the hip may be abducted on the fracture table.

L and M, The trochanter is held in the desired position and temporarily fixed to the femur with two threaded Kirschner wires of adequate size that are drilled upward and medially. At this point the accuracy of the position of the greater trochanter is verified with image intensifier radiography. As stated previously, the tip of the greater trochanter should be level with the center of the femoral head and at a distance from it of two to two and one-half times the radius of the femoral head. If there are problems with proper visualization, a long Kirschner wire is placed horizontally and parallel to both anterior superior iliac spines, crossing the center of the femoral head; then the position of the tip of the greater trochanter is checked.

N, Prior to osteosynthesis the gluteal muscle is split in the direction of the fibers to expose the bone and to avoid muscle necrosis. The greater trochanter is fixed to the lateral surface of the upper femur with two lag screws (each equipped with a washer), which are directed medially and distally at a 45-degree angle to counteract the pull of the hip abductors. For large trochanters 6.5-mm cancellous screws with drill bits of appropriate size are used; with smaller trochanters 3.2-mm screws are used. The outer cortex of the greater trochanter may be overdrilled. Taping of the outer cortex is optional. The washers increase the surface area, help the operator avoid cutting through the cortex, ensure more secure fixation, and allow early motion. After both screws are inserted, the initial Kirschner wires are removed.

PLATE 15-8. Distal and Lateral Transfer of the Greater Trochanter



Distal and Lateral Transfer of the Greater Trochanter *Continued*

O, Alternatively, fixation can be achieved with two heavy threaded Kirschner wires directed medially and upward. The resultant pull of the hip abductors through the direction of the wires provides a force that will compress the greater trochanter against the lateral surface of the femur. I do not recommend internal fixation by this method because screw fixation is more stable. However, in an obese or uncooperative patient, threaded Kirschner wires may be used in addition to screw fixation; or a tension wire band may be used, as described in lateral advancement of the greater trochanter (Plate 15–22).

P, Final intraoperative radiographs are obtained to ensure that the trochanter has been advanced to the desired site. Next, the detached origin of the vastus lateralis is firmly sutured to the tendinous insertion of the gluteus medius and minimus muscles. This tension-band suture absorbs the pull of the hip abductors and reinforces the internal fixation of the greater trochanter. A suction drain is inserted, and the remainder of the wound is closed in routine fashion. The skin closure is subcuticular.

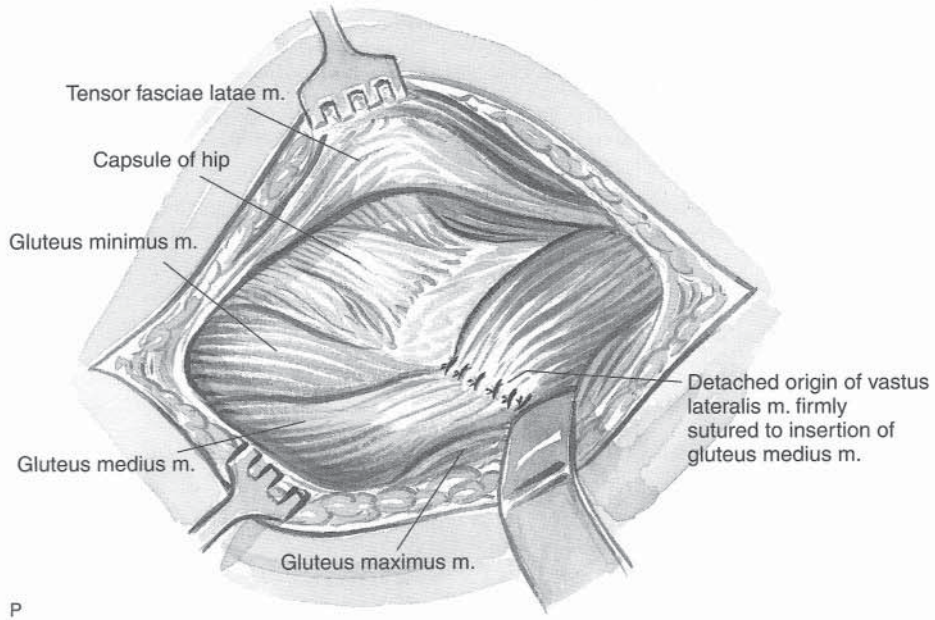
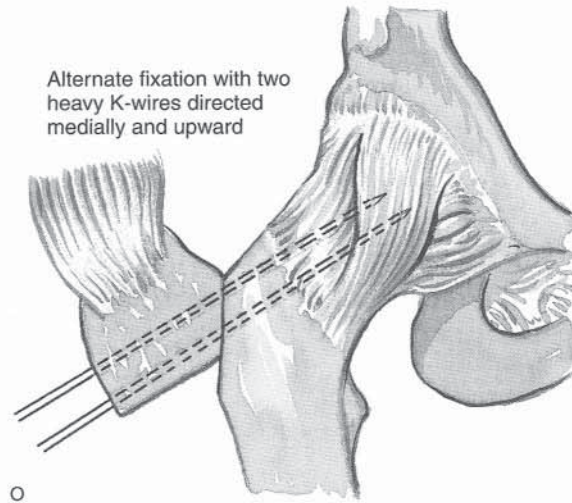
POSTOPERATIVE CARE

The patient is placed in split Russell's traction with each hip in 35 to 40 degrees of abduction. Active assisted exercises are begun as soon as the patient is comfortable, usually on the third postoperative day. Adduction and excessive flexion of the hip should be avoided. Hip abduction exercises are performed supine, which eliminates the effect of gravity. Sitting is not permitted for 3 weeks because, with 60 to 90 degrees of hip flexion, the posterior fibers of the gluteus medius muscle exert a strong lateral rotatory force on the greater trochanter and may loosen its fixation.

The patient is allowed out of bed on the third postoperative day on crutches and instructed to walk, using a three-point gait with partial weightbearing to protect the limb that was operated on. The patient is discharged to home as soon as he or she is independent and secure on crutches. Three weeks after surgery, side-lying hip abduction exercises are started, and the child is allowed to sit and to return to school. At 6 weeks bony consolidation is usually adequate to begin use of one crutch on the opposite side (to protect the hip that was operated on) and to perform standing Trendelenburg exercises. One-crutch protection should be continued until hip abductor muscles are normal or good in motor strength and Trendelenburg's sign is absent.

The screws are removed 3 to 6 months postoperatively. During screw removal, the operator should be very careful not to damage the gluteus medius and minimus muscle fibers. After removal of the screws, the hip is protected by three-point partial weightbearing on crutches for 2 to 3 weeks, and exercises consisting of side-lying hip abduction and standing Trendelenburg exercises are performed to regain the motor strength of the hip abductor muscles.

PLATE 15-8. Distal and Lateral Transfer of the Greater Trochanter



Lateral Advancement of the Greater Trochanter

OPERATIVE TECHNIQUE

A, The surgical exposure of the greater trochanter and upper femoral shaft is similar to that for distal and lateral transfer of the greater trochanter (see Plate 15–21, steps A to K).

B, The tip of the greater trochanter is at its normal level, so it is not necessary to advance it distally. It is kept horizontally level with the center of the femoral head, and its position is maintained by two wide-threaded positional cancellous screws. The screws are inserted horizontally and perpendicular to the osteotomized lateral surface of the upper femur. The threads of these “positioning” screws grip the trochanter as well as the intertrochanteric region of the femur without compression. The cleft between the greater trochanter and femur is filled with autogenous cancellous iliac bone, taken through a separate incision over the iliac apophysis.

C, Internal fixation is augmented by a taut tension band of heavy wire suture that extends from the neck of each trochanteric screw to a small unicortical screw, anchored 6 cm distally in the femur. This wire tension band counteracts the pull of the hip abductors.

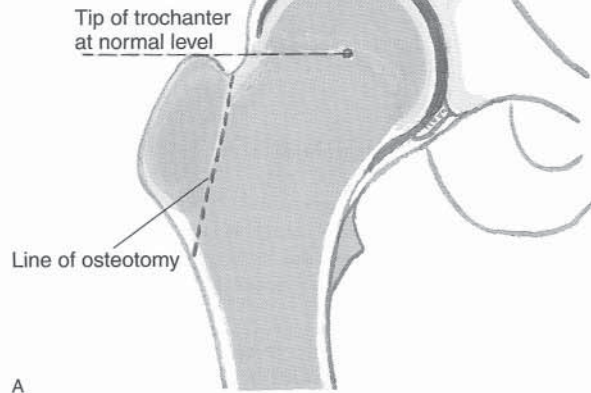
D, The detached vastus lateralis is then sutured to the insertion of the gluteus medius. The subcutaneous tissue and the skin are closed in the usual manner.

POSTOPERATIVE CARE

Postoperative care is similar to that following distal and lateral transfer of the greater trochanter (see Plate 15–21).

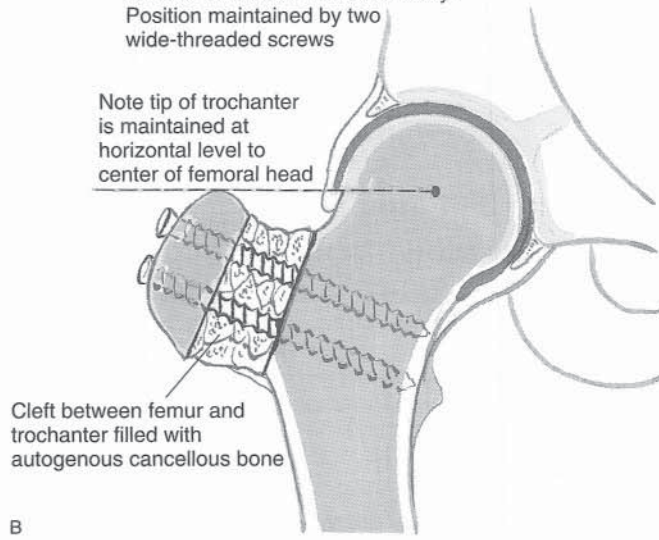
PLATE 15-9. Lateral Advancement of the Greater Trochanter

Shortened femoral neck shortens distance between tip of trochanter and center of femoral head

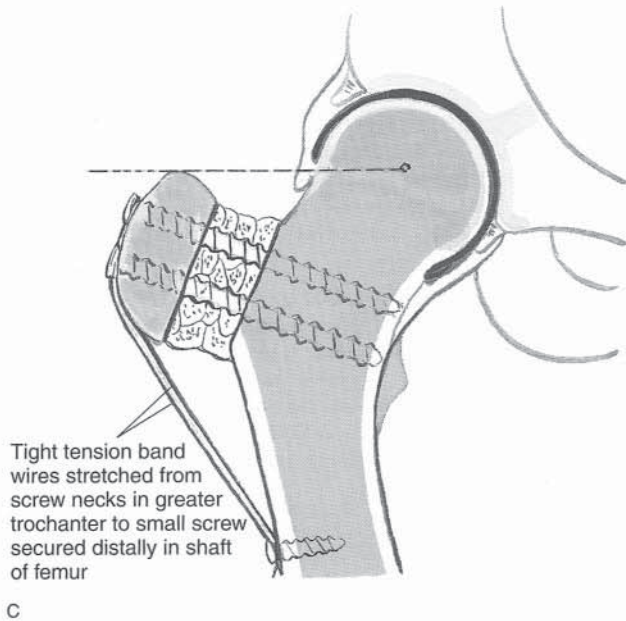


Greater trochanter shifted laterally. Position maintained by two wide-threaded screws

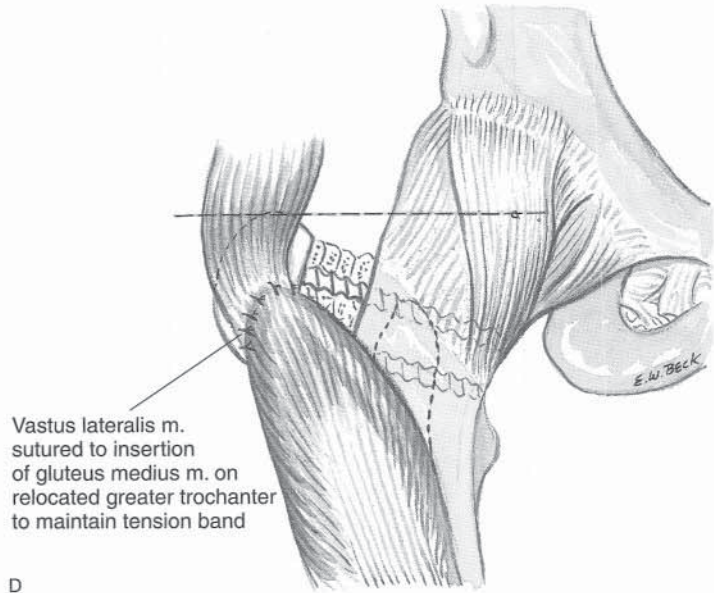
Note tip of trochanter is maintained at horizontal level to center of femoral head



Tight tension band wires stretched from screw necks in greater trochanter to small screw secured distally in shaft of femur



Vastus lateralis m. sutured to insertion of gluteus medius m. on relocated greater trochanter to maintain tension band



Wagner's Intertrochanteric Double Osteotomy

The first step of the operation is a soft tissue release of the hip adductors and iliopsoas muscle through a separate medial incision. Compressive forces between the femoral head and acetabulum should be relieved, since elongation of the femoral neck will increase intraarticular pressure. The objectives are to elongate the femoral neck, restore the neck–shaft angle to normal, and displace the greater trochanter laterally and distally.

The bony procedure consists of two horizontal osteotomies, the first at the base of the greater trochanter at the level of the upper border of the femoral neck, the second through the upper end of the femoral shaft (above the lesser trochanter), level with the lower margin of the femoral neck. The double osteotomy creates three fragments that can be moved and redirected independently of each other.

OPERATIVE TECHNIQUE

A, The proximal part of the femur is exposed through a lateral longitudinal approach, as described for distal and lateral transfer (see Plate 15–21, steps A through K).

First a heavy threaded Steinmann pin is inserted in the center of the axis of the femoral head. The pin should stop short of the capital femoral physis. The level of the two horizontal osteotomies is determined under image intensification radiography. The first should be at the base of the greater trochanter and the second at the upper end of the femoral shaft immediately distal to the base of the femoral neck. These levels are marked by inserting smooth Kirschner wires into bone.

B, A heavy threaded Steinmann pin is inserted into the midportion of the greater trochanter, stopping short of its medial cortex. Next, the two horizontal osteotomies are performed under image intensification radiographic control. It is vital to avoid injury to the vessels in the trochanteric fossa and the retinacular vessels. The deep ends of the osteotomies should stop short of the medial cortex, in which a greenstick fracture is made. First the greater trochanter is pulled cephalad to facilitate exposure. Next, the femoral neck fragment is pushed downward and medially into the desired position; then the distal femoral fragment is pulled laterally so that the medial cortex of the upper end of the femoral shaft serves as a buttress to the inferomedial corner of the femoral neck. This maneuver elongates the femoral neck.

C, When the femoral head and neck and the femoral shaft have been brought into the correct position, three smooth Kirschner wires are used to transfix and temporarily hold the fragments. Next, the greater trochanter is transferred distally and laterally and fixed to the femoral neck with the threaded pin previously inserted in its midportion. Radiographs are obtained to check the realignment of the three fragments and the correction achieved.

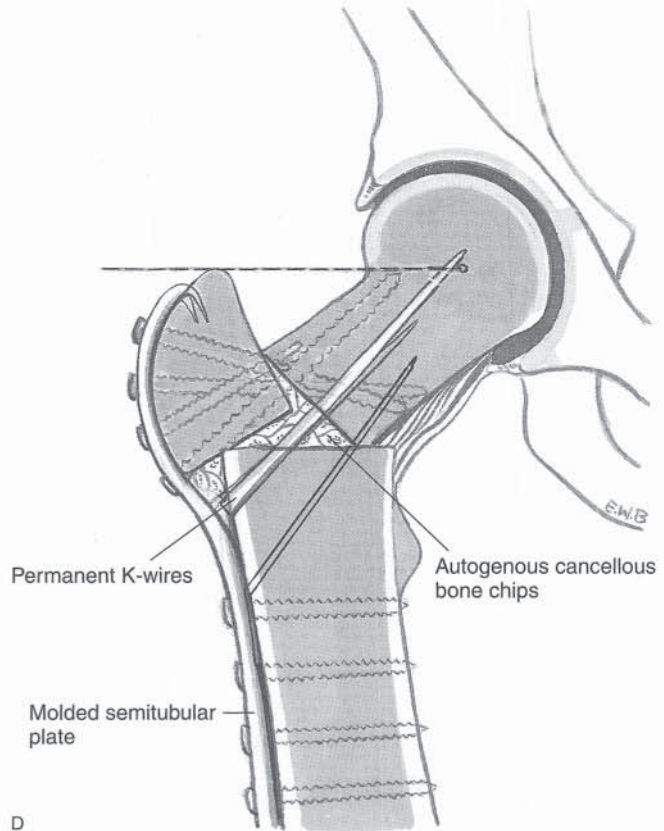
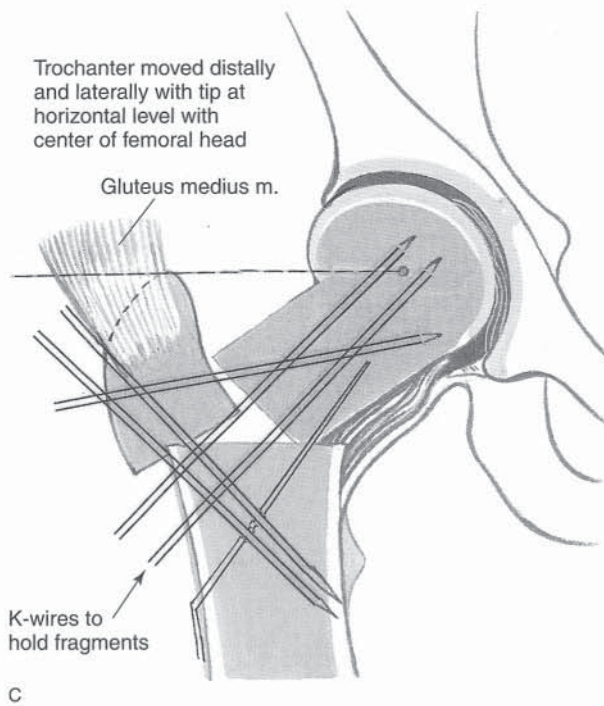
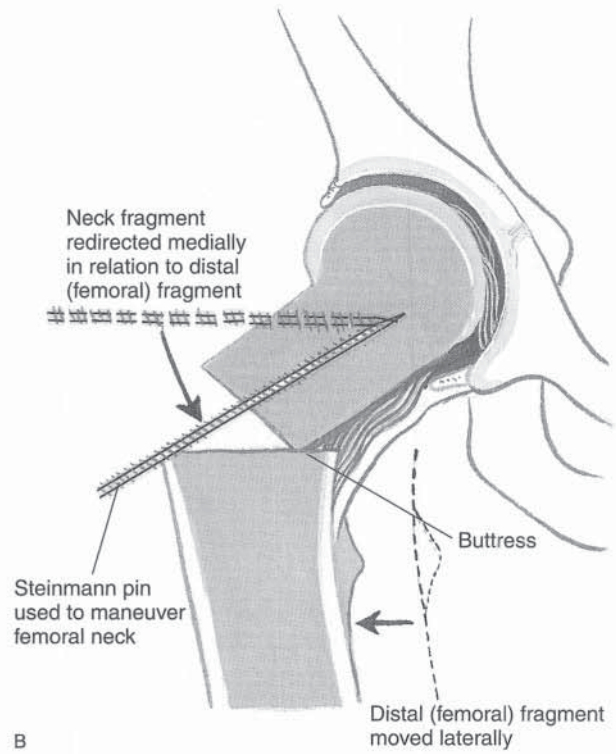
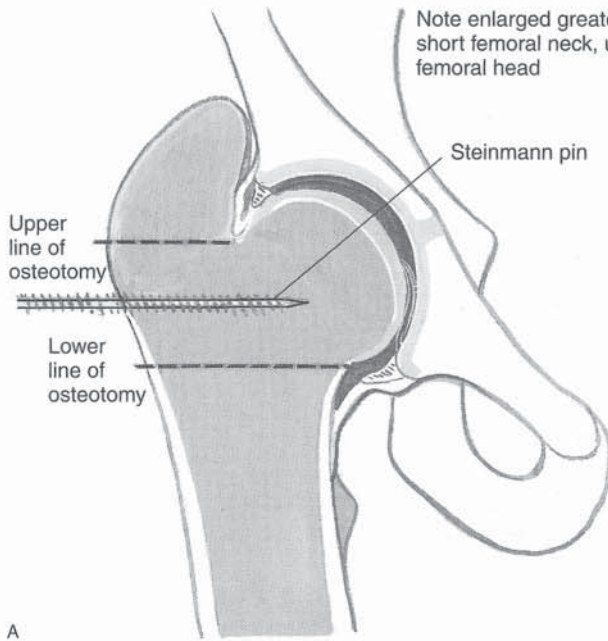
D, Osteosynthesis is performed using a molded semitubular plate that is prepared as follows. With a powerful wire cutter a vertical slot is cut out from the plate's upper end to the first screw hole. The bifurcated limbs are trimmed at their tips to sharp points and bent inward to form hooks. The semitubular plate is reshaped to fit the superolateral surface of the upper femur. The hooks are inserted in the tip of the greater trochanter, deep into cancellous bone for firm anchorage. The diagonally inserted Kirschner wires transfix the neck and shaft and prevent medial shifting of the femoral neck on the buttress provided by the upper medial cortex of the femoral shaft. All the screws are inserted, and the spaces between the fragments are packed with autogenous cancellous bone obtained from the ilium through a separate incision.

Some surgeons may prefer to use other methods of internal fixation such as a 90- or 130-degree AO right-angle plate and stabilization of the fragments with multiple screws.

POSTOPERATIVE CARE

Osteosynthesis is secure, permitting active assisted exercises 3 or 4 days postoperatively. The patient is kept in bilateral split Russell's traction for 3 weeks, until the hip develops functional range of motion. Then partial weightbearing is permitted with three-point crutch gait protection. Bone healing is usually solid in 3 months, at which time full weightbearing is allowed.

PLATE 15-10. Wagner's Intertrochanteric Double Osteotomy



Lateral Closing Wedge Valgization Osteotomy of Proximal Femur with Distal-Lateral Advancement of Greater Trochanter

The greater trochanter and the upper femoral shaft are exposed according to the technique described in Plate 15–8, steps A through K. If the hip adductors are taut they are released through a separate medial incision.

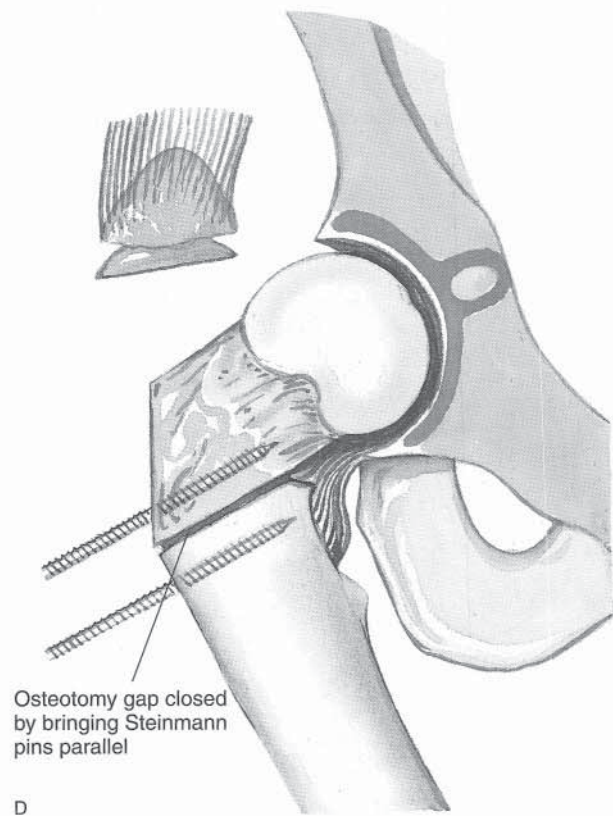
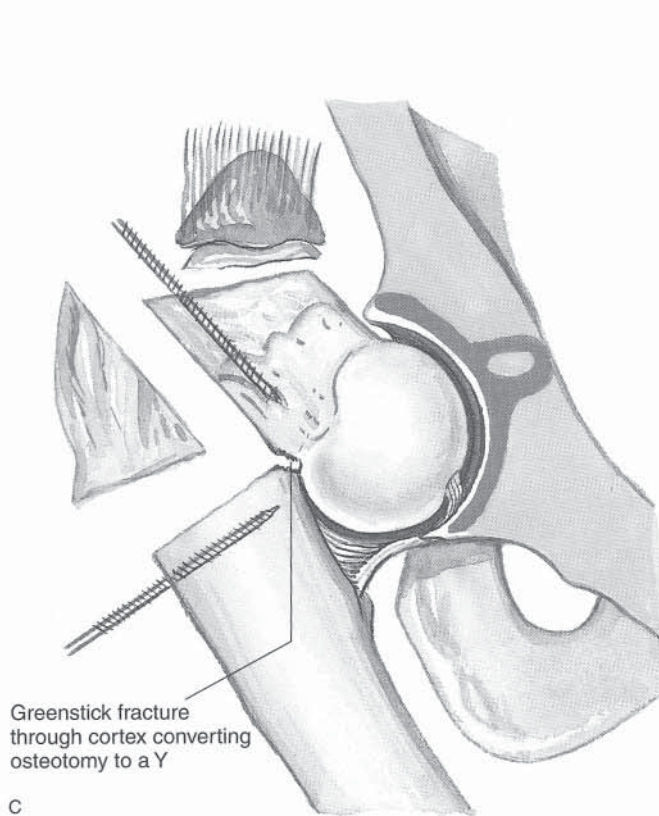
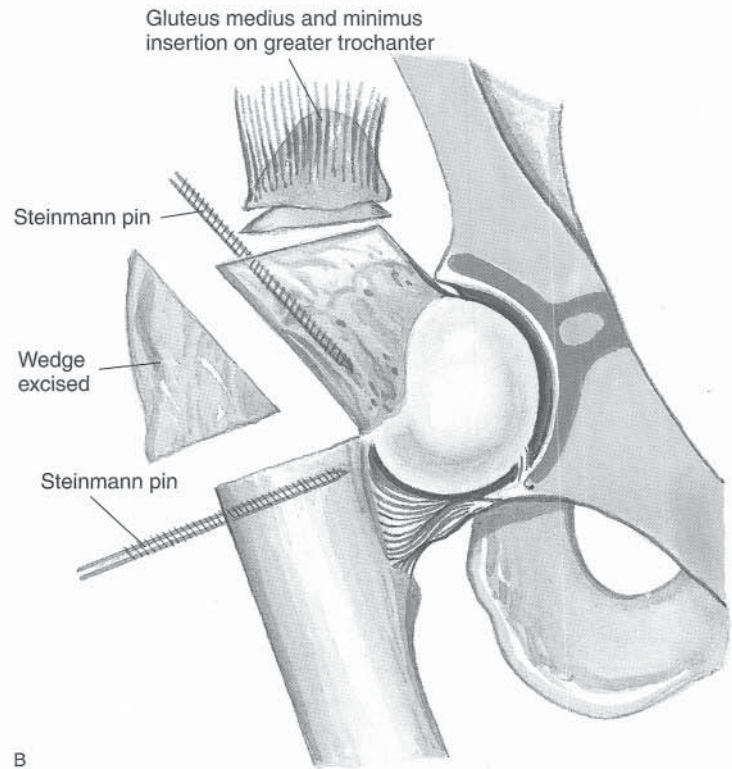
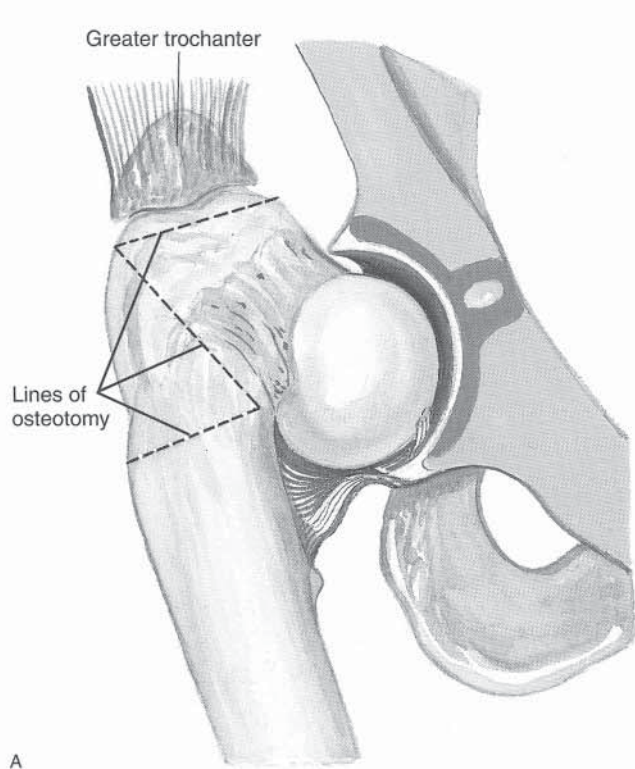
OPERATIVE TECHNIQUE

A and B, First the greater trochanter is osteotomized, following the technique described for distal and lateral advancement. Then two threaded Steinmann pins are inserted to serve as guides for the level and angle of osteotomy. The apex of the osteotomy stops 1 cm short of the medial cortex. The length of the base of the wedge depends on the degree of correction of coxa vara required. The wedge of bone is resected with an oscillating saw.

C, With a straight osteotome and leverage from the pins anchored in the femur, a greenstick fracture is produced in the medial cortex, converting the osteotomy to a short-stemmed Y.

D, The osteotomy gap is closed by bringing the two Steinmann pins together and by aligning the neck shaft and greater trochanter at a preoperatively determined angle.

PLATE 15-11. Lateral Closing Wedge Valgization Osteotomy of Proximal Femur with Distal-Lateral Advancement of Greater Trochanter



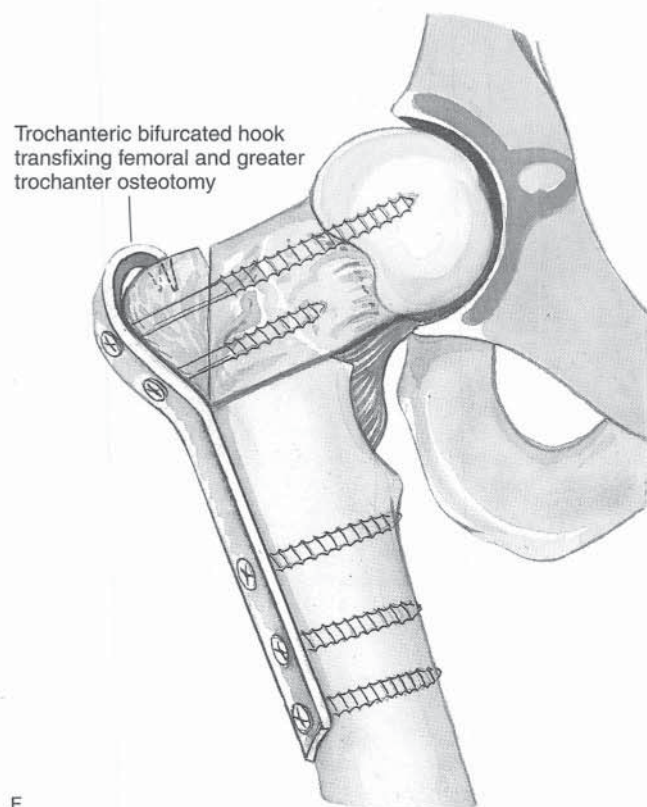
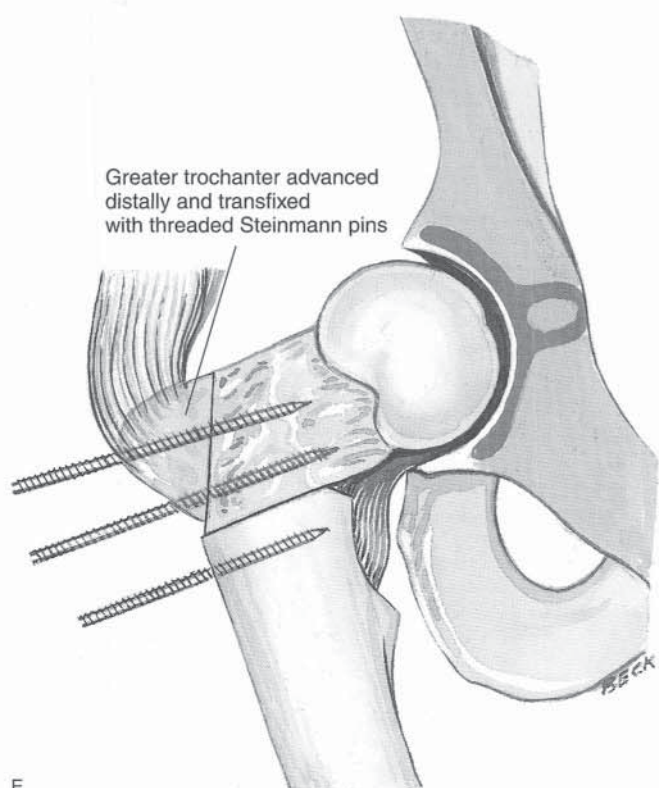
**Lateral Closing Wedge Valgization Osteotomy of Proximal Femur
with Distal-Lateral Advancement of Greater Trochanter** *Continued*

- E, The greater trochanter is transfixed with a threaded Steinmann pin driven into the neck of the femur.
- F, The three fragments are then fixed with a prebent trochanteric hook plate and screws.

POSTOPERATIVE CARE

Care following this operation is similar to that after Wagner's intertrochanteric double osteotomy.

PLATE 15-11. Lateral Closing Wedge Valgization
Osteotomy of Proximal Femur with Distal-Lateral
Advancement of Greater Trochanter



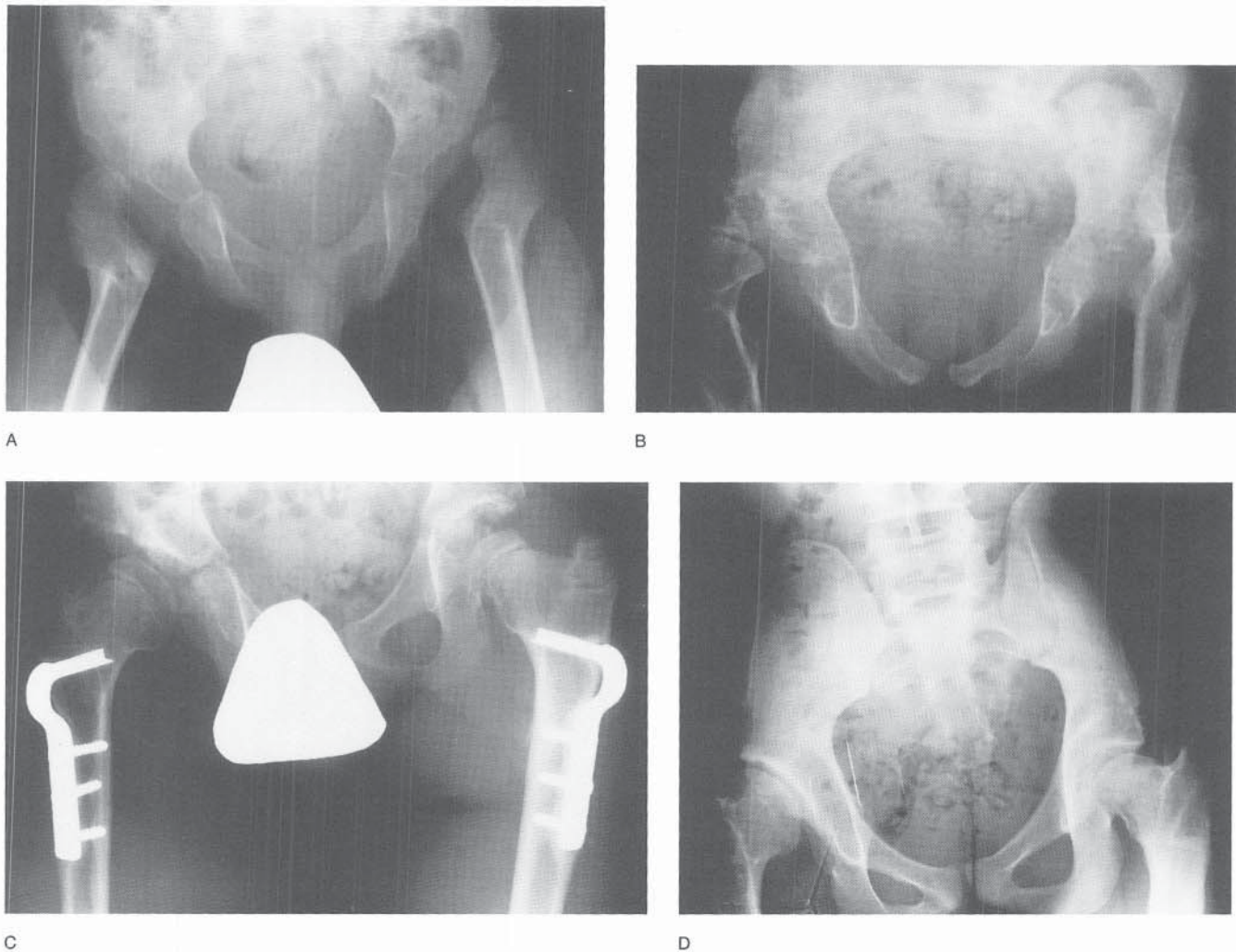


FIGURE 15-66 Failure of open reduction. **A**, At age 3 years, “varus” osteotomies were performed, with loss of position. **B**, Radiographic appearance at the time referral, at age 6 years, after repeated open reductions and bilateral Salter osteotomies. The hips remain dislocated and stiff, and a sciatic nerve injury occurred during the procedure. **C**, Appearance 9 years 10 months after bilateral open reductions and femoral osteotomies were performed. The repeated open reductions were extremely difficult and only partially successful. **D**, At age 17 years the patient had significant limitation of motion and a poor long-term prognosis.

TABLE 15-6 Pelvic Osteotomy

Type of Osteotomy	Comment
With Concentric Reduction	
<i><8 yr old</i>	
Salter	Redirects acetabulum
Pemberton	Restructures acetabulum, decreases volume
<i>8–15 yr old (triradiate open)</i>	
Triple innominate (Steel)	Greater redirection of acetabulum
Double innominate (Sutherland)	Greater redirection of acetabulum
Dega	Restructures acetabulum
<i>>15 yr old (triradiate closed)</i>	
Triple innominate	Greater redirection of acetabulum
Ganz (Bernese)	Maximum acetabular redirection; achieves stable pelvis; difficult
Spherical (Wagner, Eppright)	Maximum acetabular redirection; difficult
Without Concentric Reduction	
Shelf (Staheli)	
Chiari	

other possible complication of the procedure is damage to the acetabular growth centers caused by an osteotomy made too close to the acetabulum.

Salter Innominate Osteotomy. Salter initially recognized the anterolateral deficiency of the acetabulum in DDH and proposed correcting the deficiency with a pelvic osteotomy that displaces the acetabulum in an anterolateral direction (Figs. 15-69 to 15-71; Plate 15-13).¹⁸⁰⁻¹⁸³ The first prerequisite for the procedure is that the hip be concentrically reduced. When the hip is not well reduced, the surgeon must first obtain a concentric reduction. If the hip is subluxated, simply placing the hip in abduction and internal rotation may reduce the hip. If the hip does not concentrically reduce, an open reduction is necessary. If a concentric reduction is not achieved, the osteotomy will be of no benefit to the child. Many surgeons in the early years after Salter’s initial report failed to observe this vital point. As a result, many children underwent “Salters” in which the hip remained dislocated and the long-term outcome was very poor. Reduc-

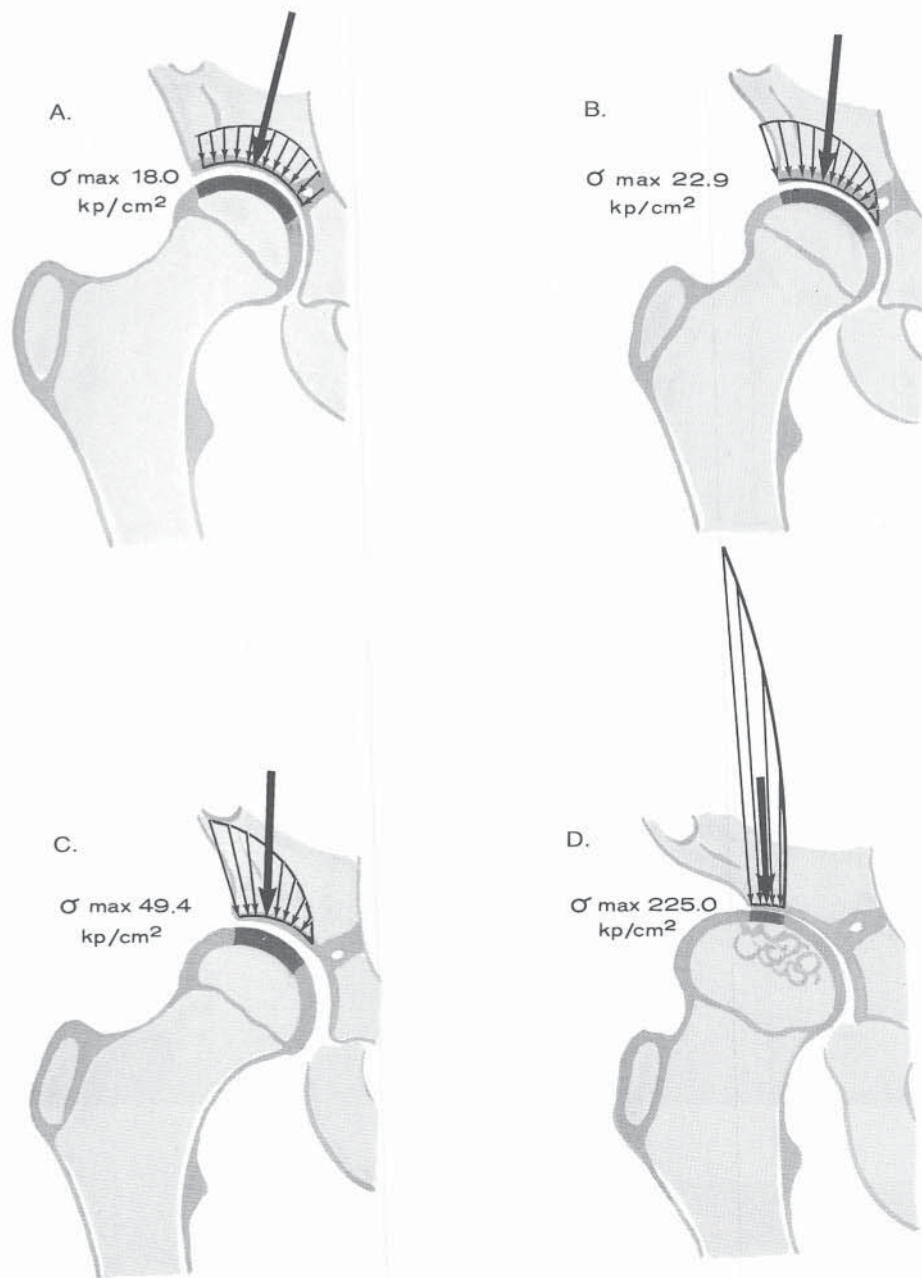


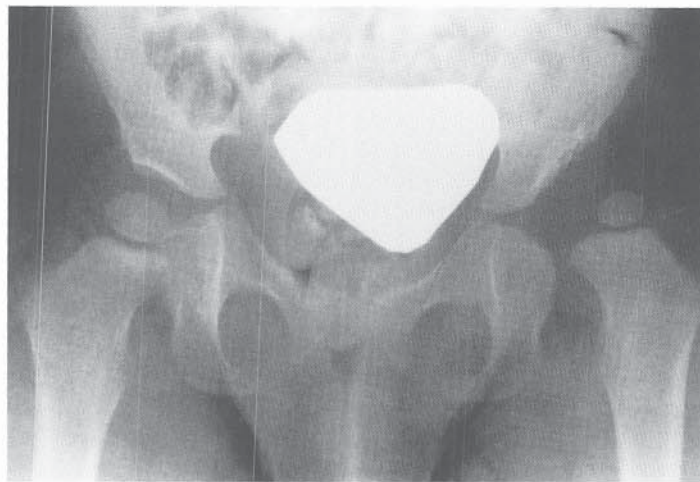
FIGURE 15-67 Magnitude of joint pressure in relation to the extent of area transmitting the load. Drawings show the gradual increase in articular pressure with progressive subluxation of the hip. A, Normal hip. B to D, Gradual subluxation. Note the increased pressure across the joint.

tion of the hip must be perfect: any compromise ensures failure.

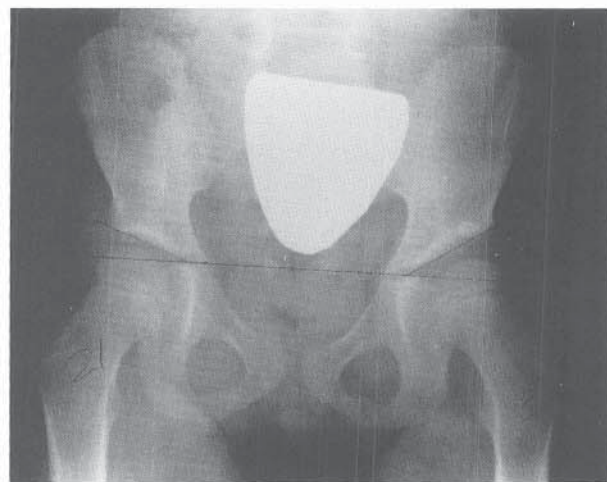
The indications for the Salter osteotomy are acetabular dysplasia persisting after primary treatment and acetabular dysplasia discovered in an untreated child. Failure of the acetabular angle to improve within 2 years following reduction and persistent dysplasia after age 5 years are definite indications for the procedure. Young children with acetabular dysplasia are asymptomatic and function normally, which makes the decision to perform surgery difficult. However, the likelihood of degenerative disease without treatment is high, and the treatment is effective. Thus, children who meet the indications should undergo an osteotomy. The Salter osteotomy is appropriate for children between 2 and 9 years of age. Children less than 18 months old usually do not have iliac wings that are thick enough to support the bone

graft. With children older than 9 or 10 years, the surgeon may not be able to achieve enough movement of the acetabular fragment to adequately cover the femoral head. It has been reported that the acetabular angle will be improved by an average of 10 degrees by the Salter osteotomy.^{147,219} Older children should undergo a complex osteotomy, especially when the dysplasia is severe.

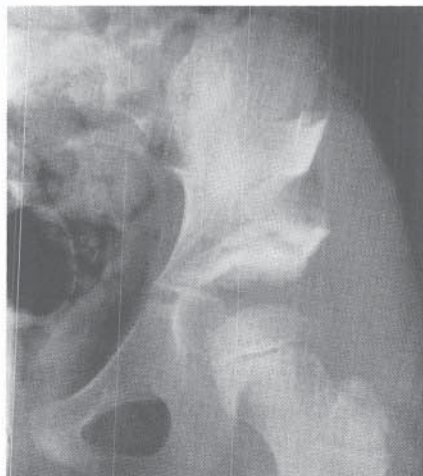The hip is approached through a bikini incision leading to the tensor-sartorius interval. The rectus femoris origin is identified, and both the inner and outer tables of the iliac wing are exposed. A straight osteotomy is made with a Gigli saw from the anterior inferior iliac spine to the sciatic notch. The acetabular portion is displaced in an anteroinferior direction by traction on a bone clamp placed over the acetabulum. The displacement may be facilitated by placing the patient's leg into a figure-four position when the capsule is



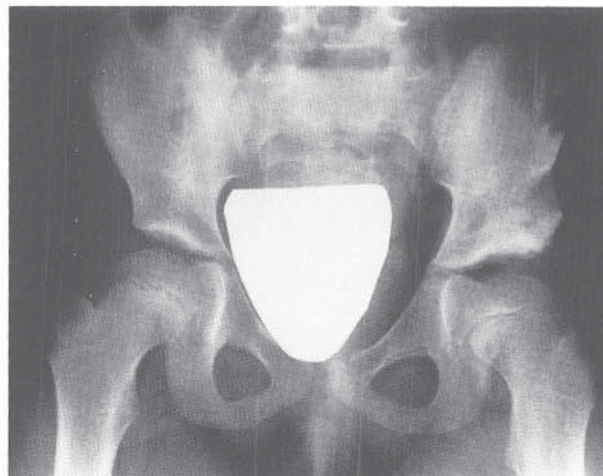
A



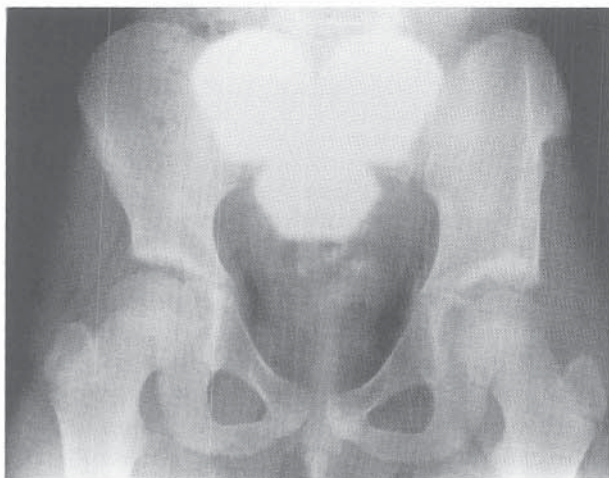
B



C



D



E

FIGURE 15-68 Results of the Pemberton osteotomy in a 16-month-old girl who presented with a limp. **A**, AP radiograph showing acetabular dysplasia in the left hip. The patient underwent a closed reduction after several weeks of home traction. **B**, AP radiograph at age 5 years shows persistent acetabular dysplasia. **C**, Radiograph obtained 6 weeks after performance of the Pemberton osteotomy. **D**, AP radiograph obtained 6 months after the Pemberton osteotomy. **E**, AP radiograph obtained 3 years postoperatively, showing good acetabular coverage.

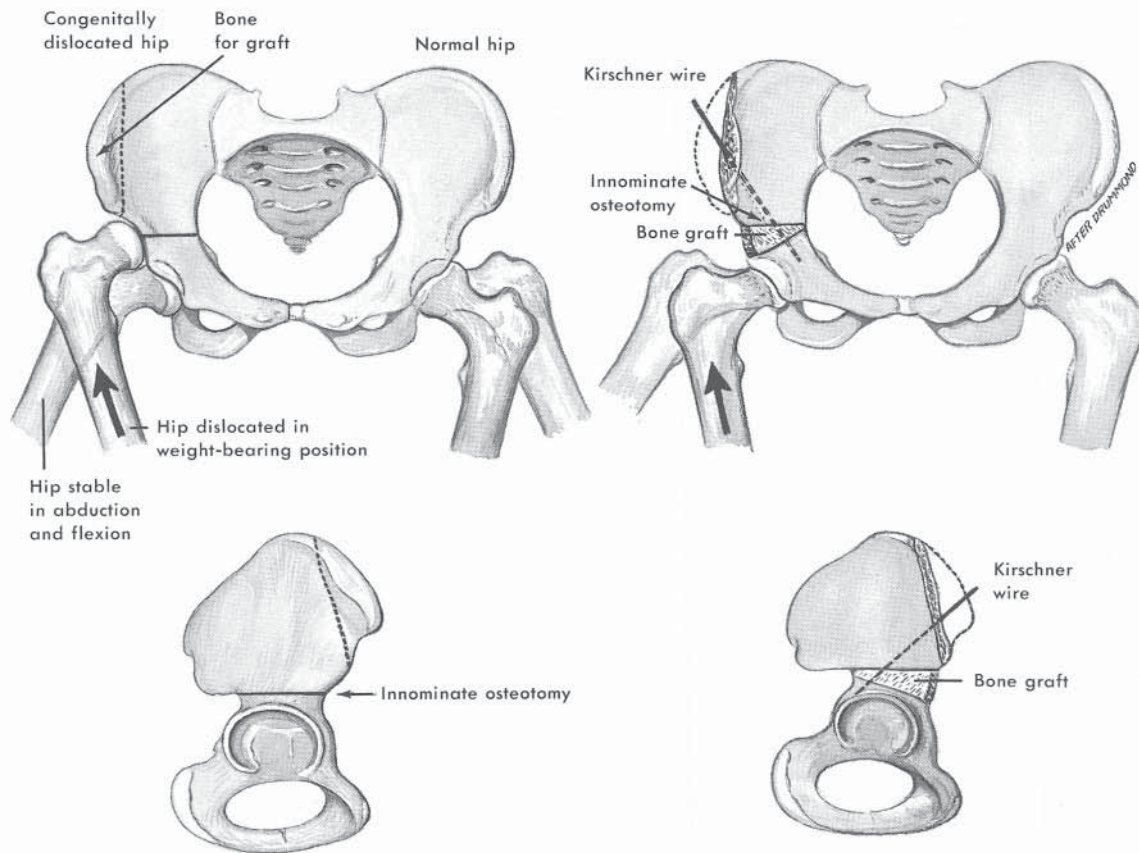


FIGURE 15-69 Principle of innominate osteotomy. (Redrawn from Salter RB: Innominate osteotomy in the treatment of congenital dislocation and subluxation of the hip. *J Bone Joint Surg* 1961;43-B:518.)

intact. The displacement is fixed by placing a triangular bone graft, taken from the anterior superior iliac spine area, into the osteotomy and fixing it there with threaded pins or screws. When properly displaced, the osteotomy is closed at the sciatic notch, with the distal fragment anteriorly displaced a few millimeters on the proximal fragment. If the osteotomy remains open posteriorly, the acetabulum will not be correctly repositioned.

The Salter osteotomy increases the tension on the muscles that cross the hip anteriorly and mildly increases the limb length. The iliopsoas is routinely lengthened with an intramuscular tenotomy at the pelvic brim. Occasionally the adductors may also need to be lengthened. In the older child, the femur should be shortened as part of the open reduction procedure to relieve pressure from the contracted muscles.

Complications are often due to lack of attention to the details of the procedure. Sciatic nerve injuries have occurred during the passage or use of the Gigli saw in the sciatic notch. This cut should always be protected by Hohman retractors. We prefer to first pass a soft tape through the notch. Then the tape is tied to the Gigli saw and the saw is pulled through the notch with the tape. This maneuver is safer than grasping the saw in the depths of the notch. Femoral nerve injuries have occurred, usually due to excessive retraction across the pelvic brim. Loss of position may occur, especially when the fixation pins are not appro-

priately placed. One pin should go behind the acetabulum and the second pin should be placed over the acetabulum, fixing the bone graft. If the distal fragment is not held in proper position, it may displace posteriorly. The posterior edges of the osteotomy should be well visualized before the surgeon pins the osteotomy, to prevent misplacing the fragment.

Pins have been placed into the acetabulum, and pins have even been inserted into the femoral head. Needless to say, care must be taken to correctly place the fixation pins, and appropriate radiographs must be obtained to ensure proper placement. Palpating the acetabulum when the hip is open may identify intra-articular pins, but pins in the subchondral position may be missed. Postoperative hip stiffness is rare in the treatment of DDH and may be due to failure to shorten the femur when there is excessive pressure after reduction. Hip stiffness will occur when the hip has not been concentrically reduced.

Excellent results have been reported using the Salter procedure. In a series of 250 children who underwent open reduction and Salter osteotomies, Salter and Dubois reported that 65 percent had excellent results, 28 percent had good outcomes, and only 7 percent had fair or poor results.¹⁸³ In patients who underwent osteotomy without open reduction for dysplasia, 100 percent of those between 18 months and 4 years of age had good or excellent results. Tonnis found that 79 percent of patients less than 3 years old and

Text continued on page 631

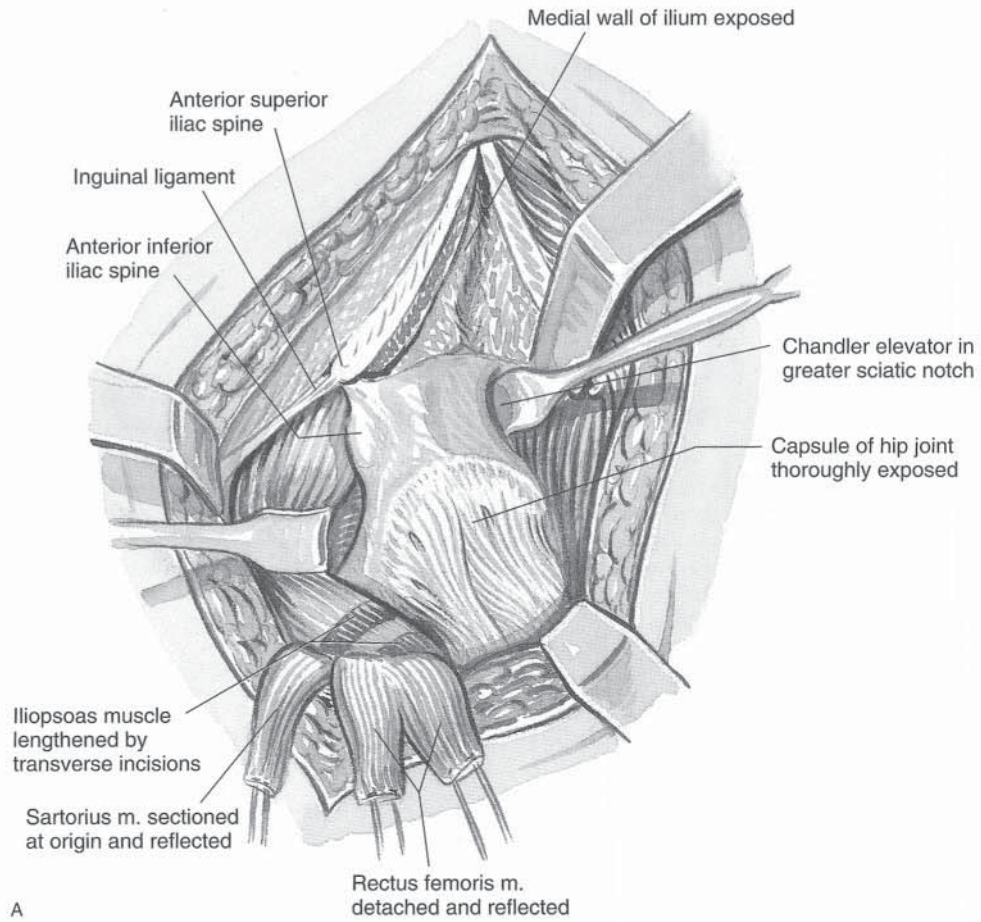
Pemberton's Osteotomy

The skin of the affected side of the abdomen and pelvis and the entire lower limb is prepared with the patient lying on the side, and the patient is draped to allow free hip motion during surgery. Then the patient is placed completely supine. The operation is performed on a radiolucent operating table. It is imperative to have image intensification fluoroscopic and radiographic control.

OPERATIVE TECHNIQUE

A, The medial and lateral walls of the ilium and the hip joint are exposed through an anterolateral iliofemoral approach. The cartilaginous apophysis of the ilium is split according to Salter's technique. The sartorius muscle is sectioned at its origin from the anterior superior iliac spine, tagged with 2-0 Mersilene suture, and reflected distally. Both heads of the rectus femoris are divided at their origin and reflected. The iliopsoas tendon is lengthened by transverse incisions. Pemberton's iliac osteotomy lengthens the pelvis. Division of the psoas tendon (not the iliacus muscle) decreases the pressure over the femoral head.

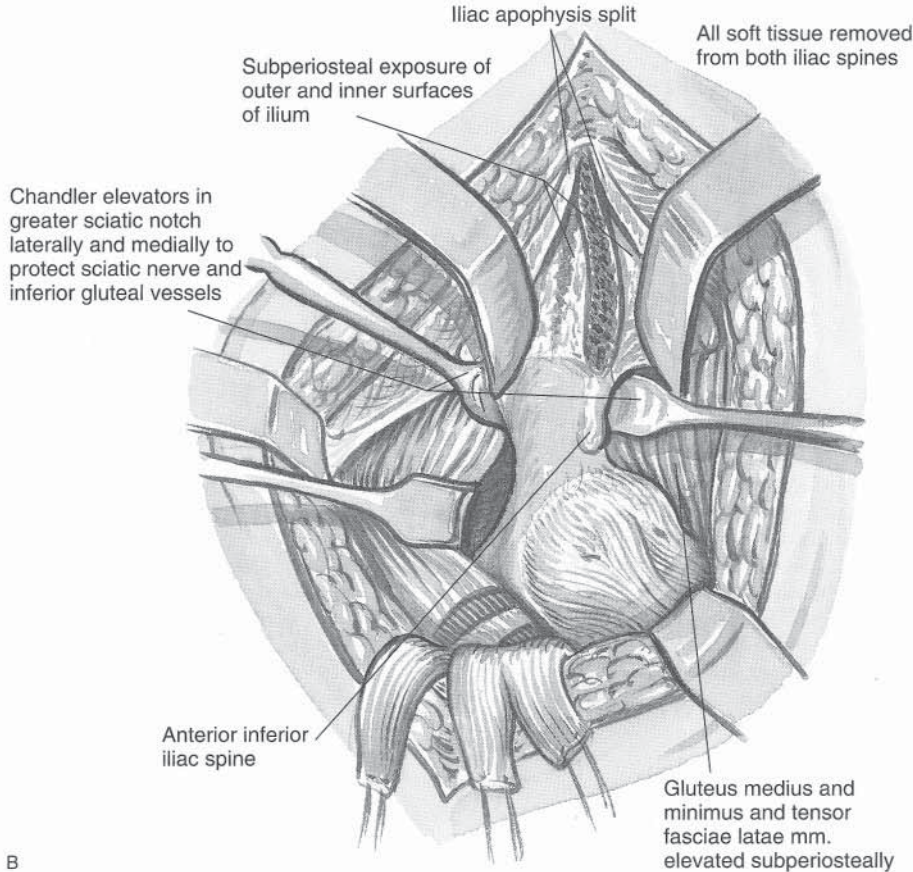
PLATE 15-12. Pemberton's Osteotomy



Pemberton's Osteotomy *Continued*

B, The ilium is exposed subperiosteally all the way posteriorly. The interval between the greater sciatic notch and the hip joint capsule posteriorly is developed gently and cautiously. The periosteal elevator meets resistance at the posterior limb of the triradiate cartilage. Chandler elevator retractors are placed in the greater sciatic notch medially and laterally to protect the sciatic nerve and the gluteal vessels and nerves. On the inner wall of the pelvis the periosteum and the cartilaginous apophysis may be divided anteriorly to posteriorly at the level of the anteroinferior iliac spine as far as the sciatic notch; this will facilitate opening up the osteotomy.

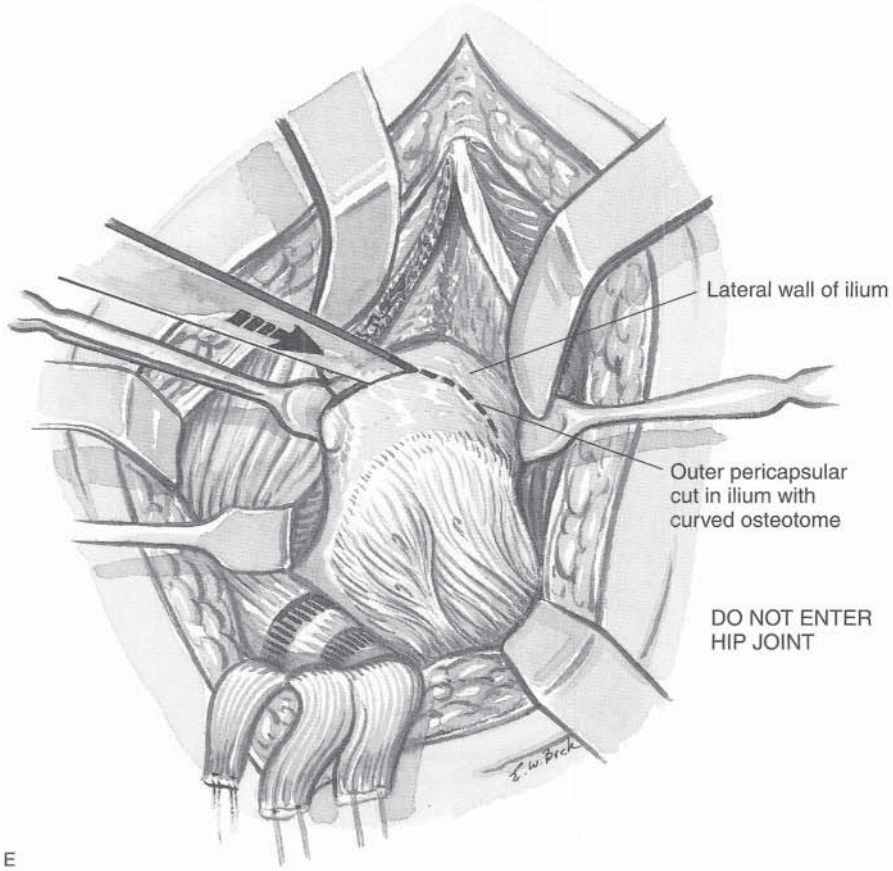
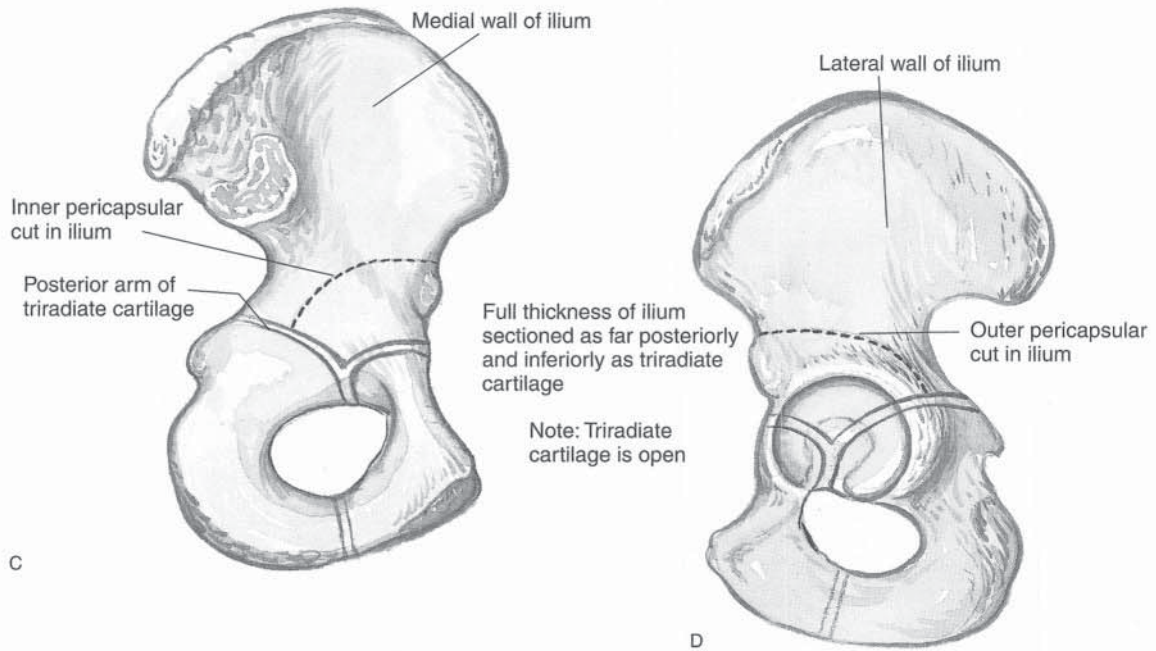
PLATE 15-12. Pemberton's Osteotomy



Pemberton's Osteotomy *Continued*

C to E, The osteotomy is first performed on the outer table of the ilium. The cut is curvilinear, describing a semicircle around the hip joint on the lateral side at a level 1 cm above the joint, between the anterosuperior and anteroinferior iliac spines. It is best to mark the line of the osteotomy with indelible ink. The sharp edge of a thin osteotome is used to make the cut. The osteotomy ends at the posterior arm of the triradiate cartilage. This is most difficult to see if the exposure is inadequate. Image intensification fluoroscopy will help determine the terminal point of the cut at the triradiate cartilage, which is anterior to the greater sciatic notch and posterior to the hip joint margin. The next cut is made on the inner wall of the ilium and should be inferior to the level of the outer cut. The more distal the level of the inferior cut, the greater the extent of lateral coverage. If more anterior than superior coverage is required, the medial and lateral cuts in the ilium are parallel. The importance of sectioning the ilium as far posterior and inferior to the triradiate cartilage as possible cannot be overemphasized. It is vital not to violate the articular cartilage of the acetabulum and enter the hip joint.

PLATE 15-12. Pemberton's Osteotomy



Pemberton's Osteotomy *Continued*

F, With sharp curved osteotomes, the cuts of the inner and outer table of the ilium are joined. Periosteal elevators are used to mobilize the osteotomized fragments, and the inferior segment of the ilium is leveled laterally, anteriorly, and distally.

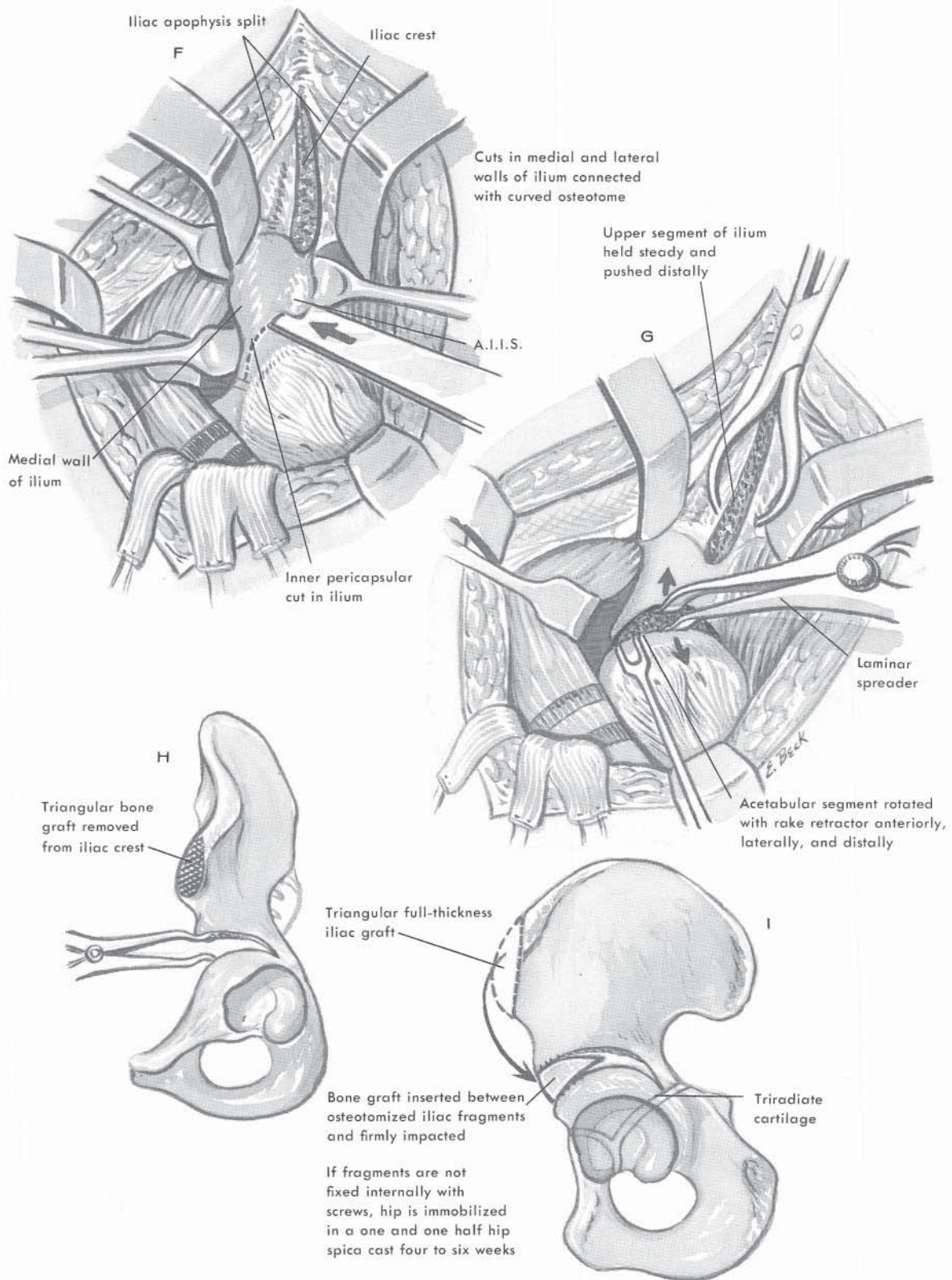
G, If necessary, a laminar spreader may be used to separate the iliac fragments. The operator should, however, be very gentle, and steady the upper segment of the ilium and push it distally. Care should be taken not to fracture the acetabular segment by forceful manipulation or crushing with the laminar spreader.

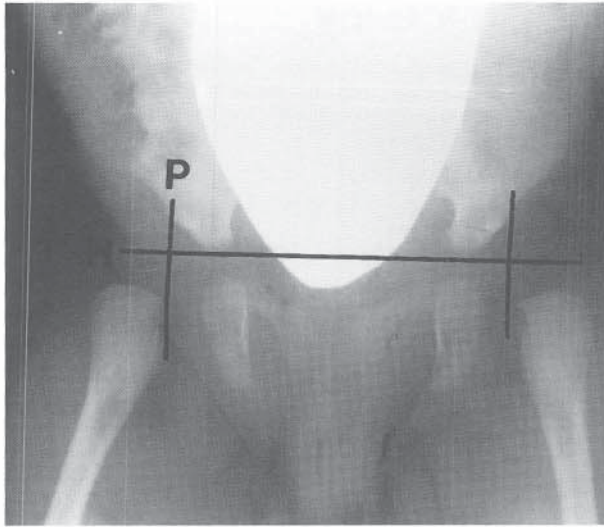
H and I, Next, a triangular wedge of bone is resected from the anterior part of the iliac wing. In the young child I remove the wedge of bone more posteriorly and avoid the anterosuperior iliac spine. This gives greater stability to the iliac fragments. The wedge of bone graft may be shaped into a curve to fit the graft site. Pemberton and Coleman recommend that grooves be made on the opposing cancellous surfaces of the osteotomy. The graft is impacted into the grooves, and the osteotomized fragment is sufficiently stable to obviate internal fixation. I do not recommend cutting grooves because of problems with splintering and weakening of the acetabulum. The fragments are fixed internally with two threaded Kirschner pins or cancellous screws. The internal fixation allows the surgeon to remove the cast sooner, mobilize the hip, and prevent joint stiffness. The sartorius muscle is reattached to its origin, the split iliac apophysis is sutured, and the wound is closed in the usual fashion. A one-and-one-half-hip spica cast is applied.

POSTOPERATIVE CARE

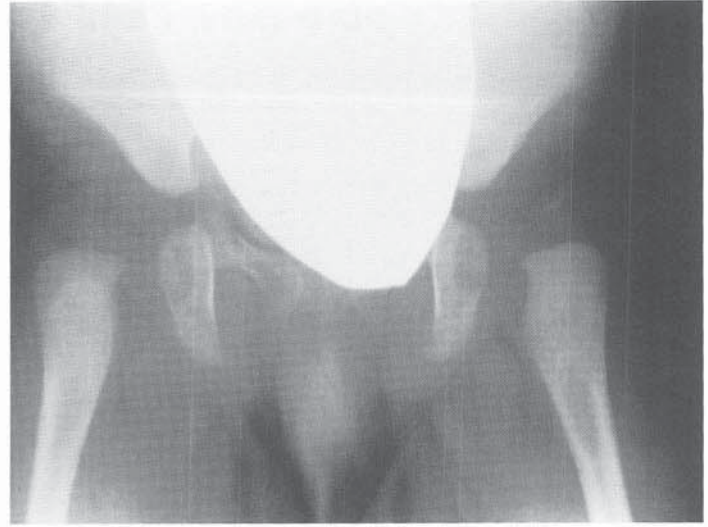
The cast is removed in 6 weeks, and healing of the osteotomy is assessed on AP and oblique-lateral radiographs. When joint motion and motor strength of the hip extensors, quadriceps, and triceps surae muscles are good, the child is allowed to ambulate. In the older patient, three-point crutch gait with toe touch on the limb that was operated on is used to protect the hip until the Trendelenburg test is negative.

PLATE 15-12. Pemberton's Osteotomy

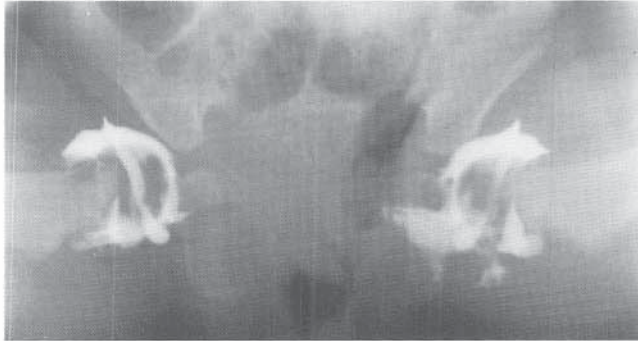




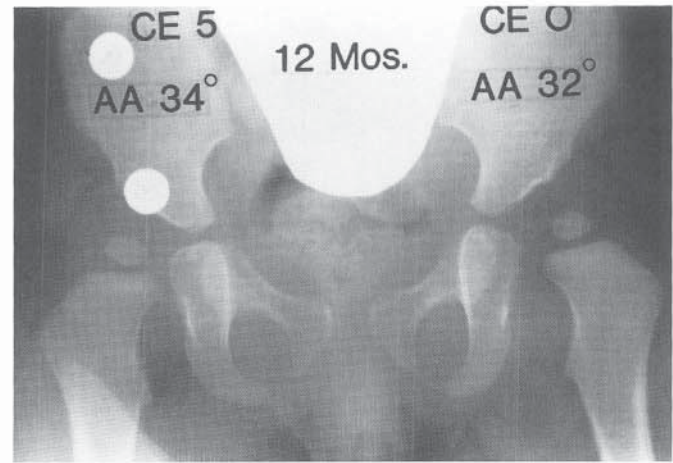
A



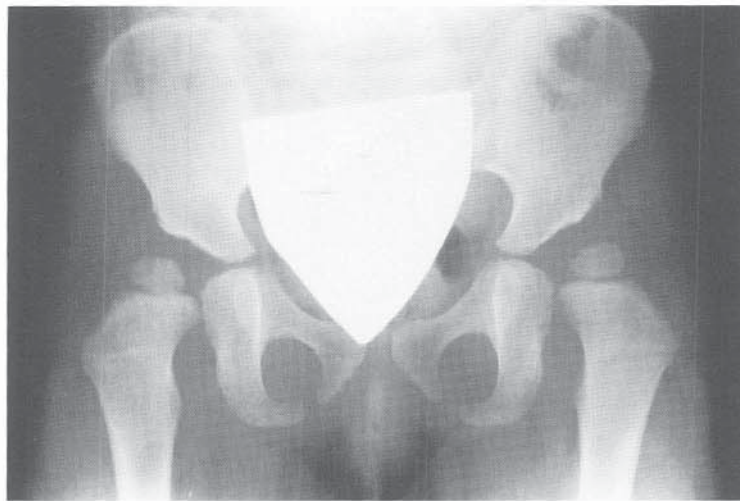
B



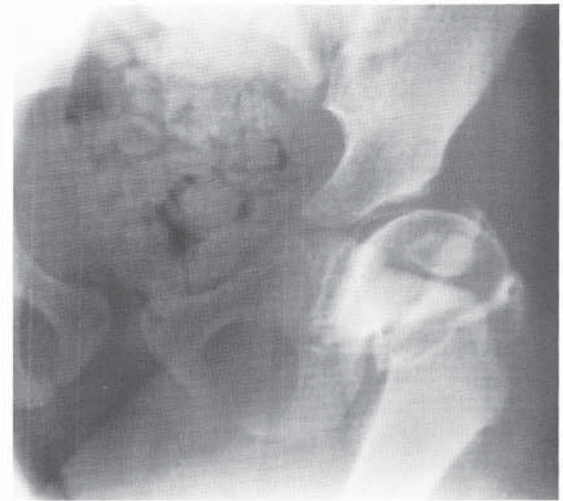
C



D

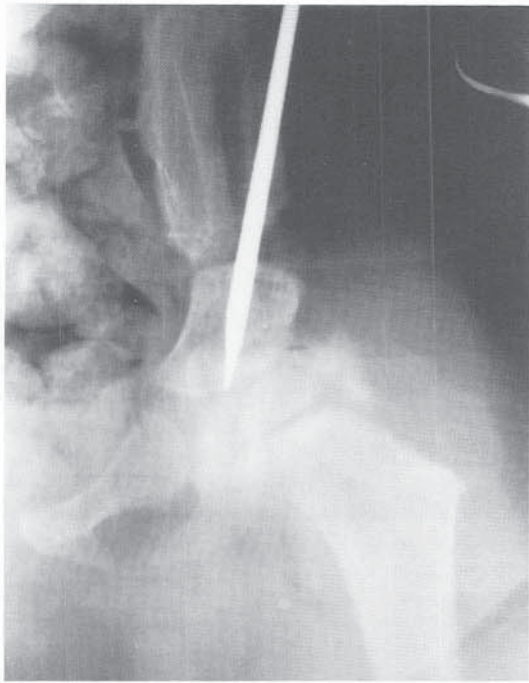


E

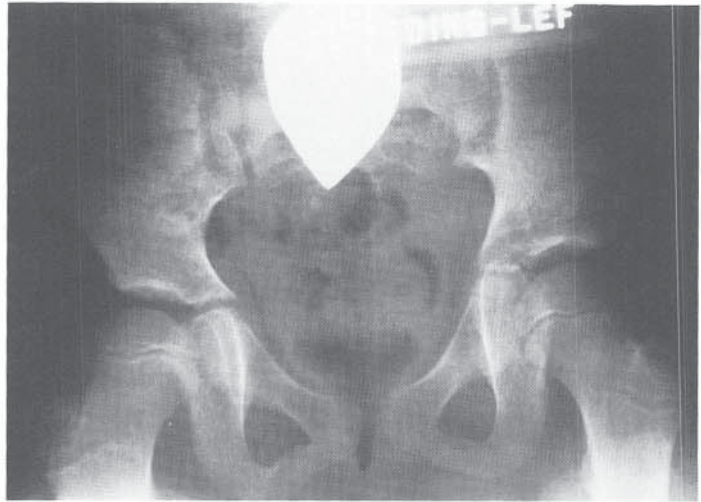


F

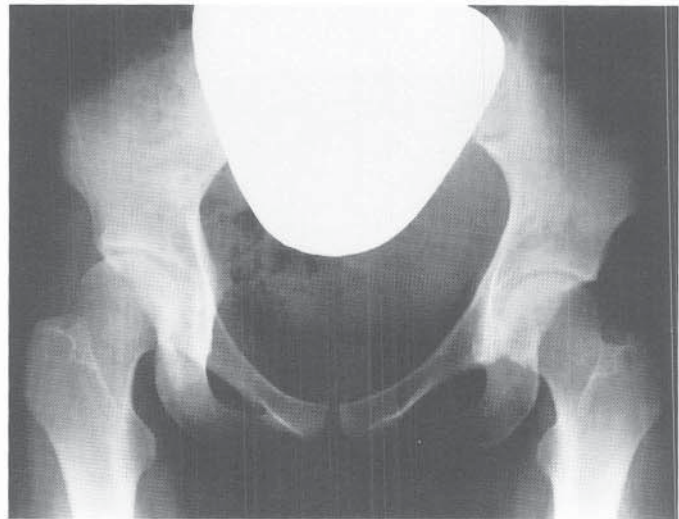
FIGURE 15-70 Imaging appearance in a girl with bilateral DDH that was diagnosed at age 18 days, and subsequent poor parental compliance with the treatment program. **A**, AP radiograph obtained at age 18 days showing bilaterally dislocated hips. Hilgenreinger's and Perkin's lines help delineate the dislocated hips. **B**, AP radiograph obtained at presentation at age 6 weeks shows bilateral dislocations. The infant was treated in a Pavlik harness for 6 weeks and in an abduction splint thereafter. The grandmother later confided that the mother did not comply with treatment instructions and did not use the devices very much at all. **C**, Arthrogram obtained at age 5 months shows good reductions. **D**, AP radiograph obtained at age 12 months shows bilateral subluxation that is worse on the left side. **E**, Standing AP radiograph obtained at age 2 years shows persistent bilateral subluxation. **F**, Arthrogram obtained at age 2 years shows mild subluxation with good reduction.



G



H



I

FIGURE 15-70 *Continued.* G, The patient underwent a left Salter osteotomy. H, AP radiograph obtained at age 5 years, 3½ years after the Salter osteotomy, shows good acetabular development. I, Final radiograph, obtained at age 15 years, shows good development bilaterally, slightly better on the left.

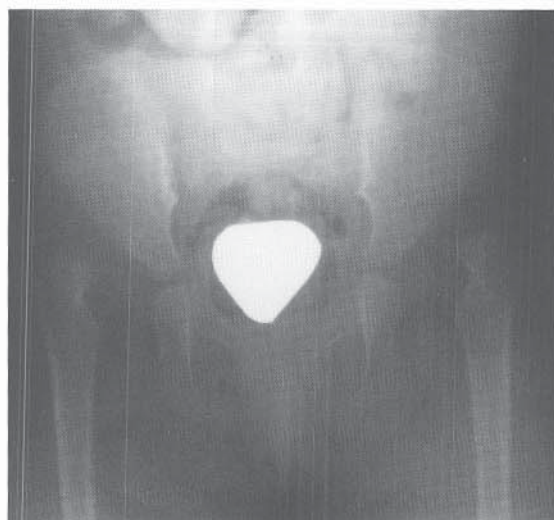
two-thirds of those between 4 and 10 years old had normal results after the Salter procedure.²¹¹

Other authors have reported less positive results. Lehman and associates found that only one-third of the subluxated hips and one-half of the dislocated hips were satisfactory at 15-year follow-up.¹²¹ Gallien and associates reported that combining the Salter osteotomy with open reduction was difficult, and they recommended that the combined procedure not be commonly done.⁵⁷ We disagree with these conclusions and find that the Salter procedure is an appropriate addition to the open reduction when necessary.

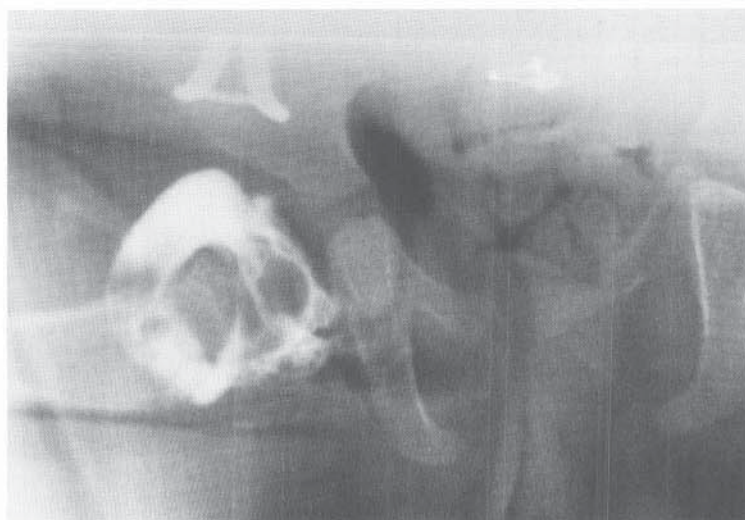
Kalamchi modified the Salter procedure by displacing the distal fragment into a posterior notch in the proxi-

malfragment to avoid increasing the pressure on the femoral head (Fig. 15-72).⁹³ Results have been comparable to those of the original procedure.

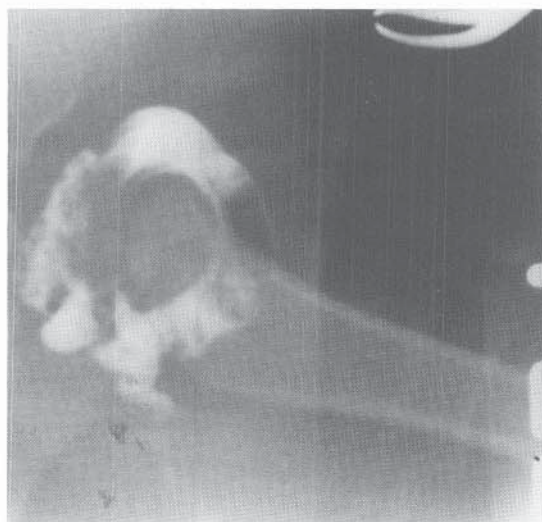Dega Osteotomy. The Dega osteotomy allows the surgeon to increase acetabular coverage either anteriorly, centrally, or posteriorly. The osteotomy starts above the acetabulum and then proceeds into the triradiate cartilage behind and beneath the acetabulum. The acetabular fragment is then pried downward and held in place with bone wedges. The placement of the wedges determines the area of acetabular coverage that is improved. Thus, if wedges are placed posteriorly, posterior acetabular coverage is augmented, as is often necessary in neuromuscular-related hip dislocations. If the



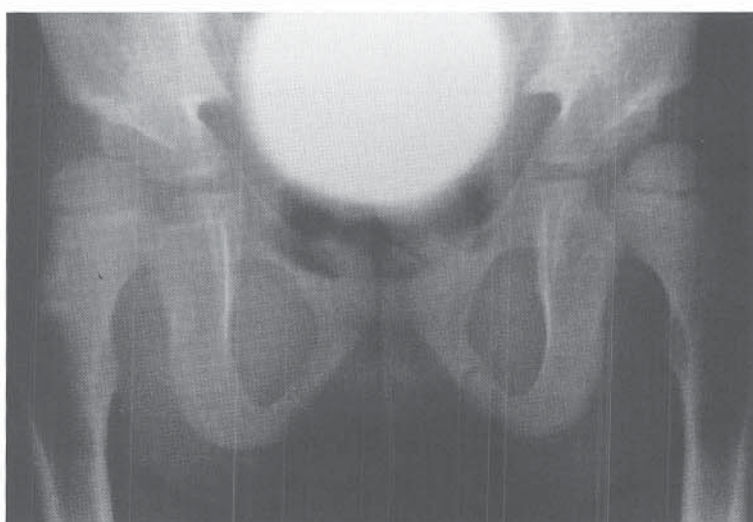
A



B



C



D

FIGURE 15-71 Bilateral Salter osteotomies. A, AP radiograph showing bilateral DDH in a 14-month-old girl. B, Arthrogram of the right hip obtained during the closed reduction, after 2 weeks of home traction. The reduction is good. C, Arthrogram of the left hip shows a fair reduction, with a small medial space between the head and acetabulum. D, AP radiograph obtained at age 4 years 9 months shows bilateral acetabular dysplasia.

wedges are placed anteriorly and superiorly, coverage is improved anterolaterally, much as in the Pemberton osteotomy. The acetabular volume may be decreased by the displacement of the osteotomy.

COMPLEX OSTEOTOMIES THAT REPOSITION THE ACETABULUM

Steel Osteotomy. The Steel procedure includes osteotomies through the ilium and both pubic rami (Fig. 15-73).^{48,69,198,199} The pubic ramus is approached through a transverse medial incision in the patient's groin. A dissection made proximally up the pectineus allows ready access to the ramus, which is then divided. The ischium is also approached through the same incision. This dissection interval is posterior to the

adductor magnus. After the ischium is transected, this wound is closed and an innominate osteotomy is made similar to that in the Salter procedure. The acetabular fragment is displaced and rotated to provide anterolateral coverage of the femoral head. Much greater rotation can be obtained with this triple osteotomy than with the innominate osteotomy alone. The surgeon may use large pins placed in the distal fragment as handles to displace and rotate the acetabulum. The osteotomy is fixed with screws or threaded pins. The triple innominate osteotomy provides considerable mobility for repositioning the acetabulum. The acetabular fragment is rotated anteriorly and laterally, and may also be displaced medially at the ischial osteotomy.

Tonnis Osteotomy. Tonnis has also modified the triple innominate osteotomy. He approaches the ischium directly,

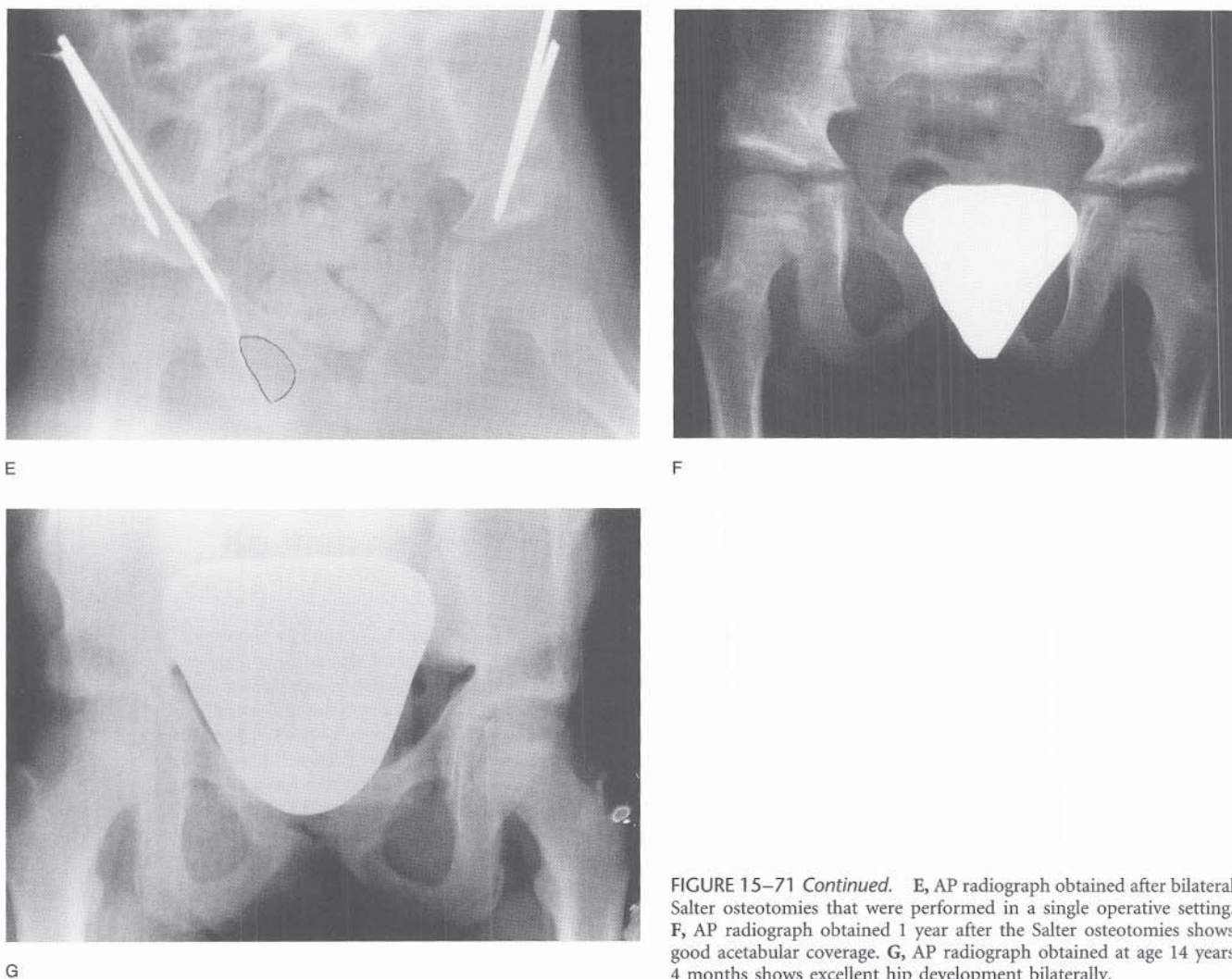


FIGURE 15-71 *Continued.* E, AP radiograph obtained after bilateral Salter osteotomies that were performed in a single operative setting. F, AP radiograph obtained 1 year after the Salter osteotomies shows good acetabular coverage. G, AP radiograph obtained at age 14 years 4 months shows excellent hip development bilaterally.

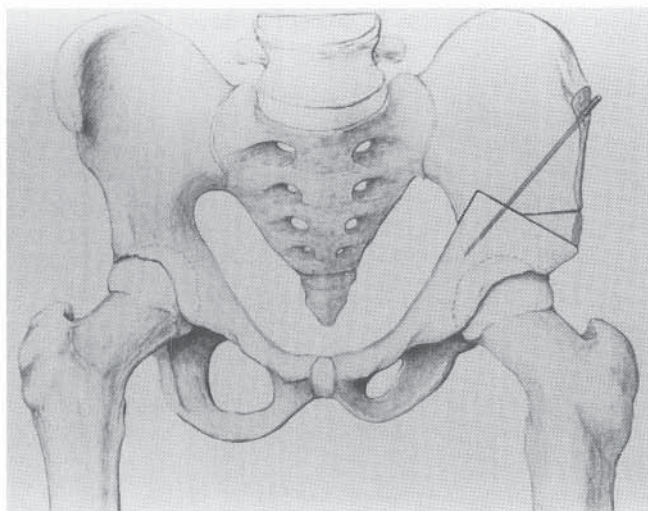


FIGURE 15-72 Kalamchi modification of the Salter osteotomy. The distal fragment is displaced into a notch on the proximal fragment. (From Kalamchi A: Modified Salter osteotomy. *J Bone Joint Surg* 1982;64-A:183.)

with the patient in the prone position.²¹³⁻²¹⁵ A long ischial cut is made that connects the obturator foramen with the sciatic notch. The long cut provides good contact after displacement to prevent pseudarthrosis. The iliac cut is slightly curved and the pubis is cut, as in the Steel procedure, from a medial approach. Fixation is obtained through the use of several screws and by attaching a cerclage wire from a screw in the pubis to a pin in the ilium. Tonnis reported that 58 percent of his patients were pain-free after the procedure and that another 32 percent had mild to moderate residual pain.²¹⁵ Nine percent had improvement in the degree of their arthrosis and 73 percent had no change over an average follow-up of 7 years.

Ganz Osteotomy. The Ganz osteotomy, also known as the Bernese periacetabular osteotomy, has gained popularity because it allows greater displacement of the acetabulum and maintains an intact posterior column (Fig. 15-74). It is indicated for more severe acetabular dysplasia in a hip that can be concentrically reduced. The advantages, as noted by Ganz and colleagues include a single approach, a large degree of possible correction, maintenance of blood supply to the acetabulum, an intact posterior column, and no alteration of the pelvic birth outlet.⁶⁰ The ischium is cut

Text continued on page 642

Salter's Innominate Osteotomy

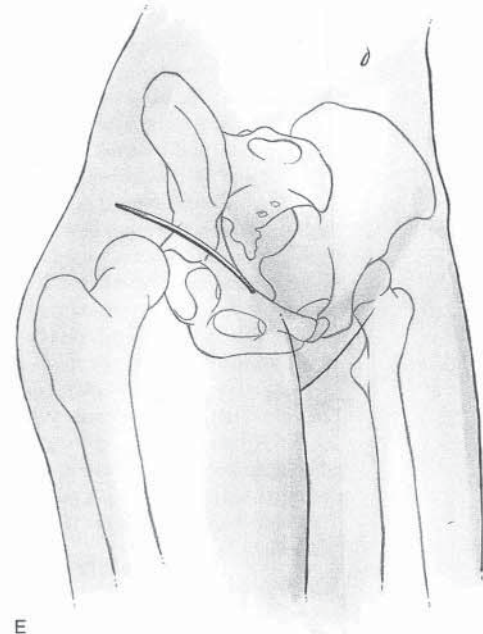
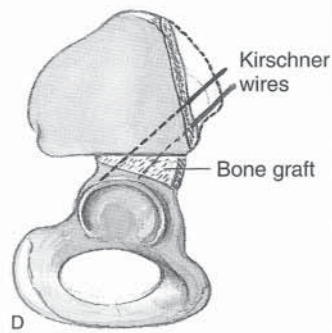
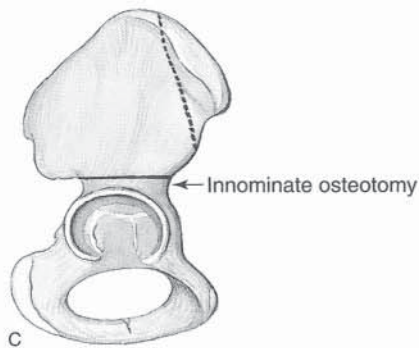
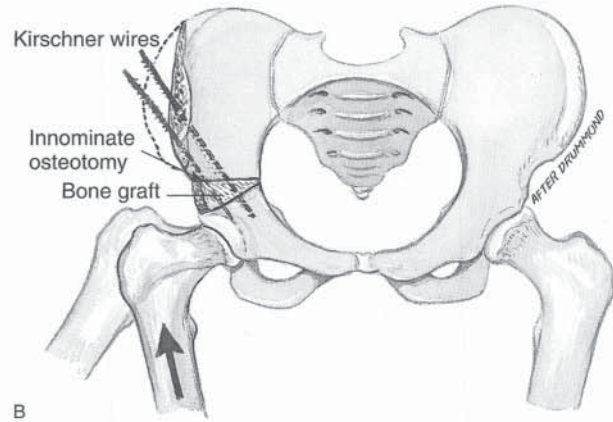
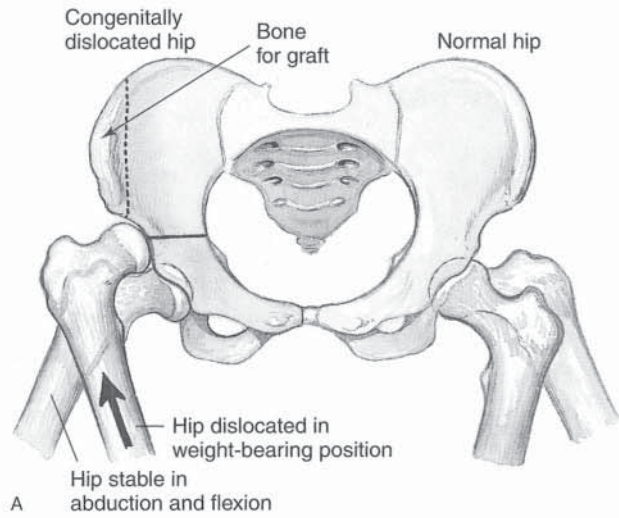
OPERATIVE TECHNIQUE

A to D, The Salter innominate osteotomy is based on redirection of the acetabulum as a unit by hinging and rotation through the symphysis pubis, which is mobile in children. It is performed by making a transverse linear cut above the acetabulum at the level of the greater sciatic notch and the anterior inferior iliac spine. The whole acetabulum with the distal fragment of the innominate bone is tilted downward and laterally by rotating it. The new position of the distal fragment is maintained by a triangular bone graft taken from the proximal portion of the ilium and inserted in the open wedge osteotomy site. Internal fixation is provided by two threaded Kirschner wires. Through the rotation and redirection of the acetabulum, the femoral head is covered adequately with the hip in a normal weightbearing position. In other words, the reduced dislocation or subluxation that was previously stable in the position of flexion and abduction is now stable in the extended and neutral position of weightbearing.

E, The skin is prepared with the patient in the side-lying position so that the abdomen, lower part of the chest, and affected half of the pelvis can be draped to the midline anteriorly and posteriorly; the entire lower limb is also prepared and draped to allow free motion of the hip during the operation. The patient is placed supine with a roll beneath the buttock.

The skin incision is an oblique bikini incision. The incision formerly used over the iliac crest produces an unsightly scar, whereas the bikini incision results in excellent exposure and cosmesis. The anterior inferior iliac spine is palpated and marked. The incision begins about two-thirds of the distance from the greater trochanter to the iliac crest and extends across the inferior spine and 1 or 2 cm beyond the inferior spine. The incision is then retracted over the iliac crest and the dissection is carried down to the apophysis of the crest. Anteriorly the tensor-sartorius interval is bluntly dissected beginning distally and working proximally. The lateral femoral cutaneous nerve appears just medial to this interval and just distal to the inferior iliac spine, and should be protected.

PLATE 15-13. Salter's Innominate Osteotomy



Salter's Innominate Osteotomy *Continued*

F, With a scalpel, the cartilaginous iliac apophysis is split in the middle down to the bone from the junction of its posterior and middle thirds to the anterior superior iliac spine. By blunt dissection the groove between the tensor fasciae latae and the sartorius and rectus femoris muscles is opened and developed. With a broad, long-handled periosteal elevator, the surgeon strips the lateral part of the iliac apophysis and the tensor fasciae latae and gluteus medius and minimus muscles subperiosteally and the greater sciatic notch posteromedially.

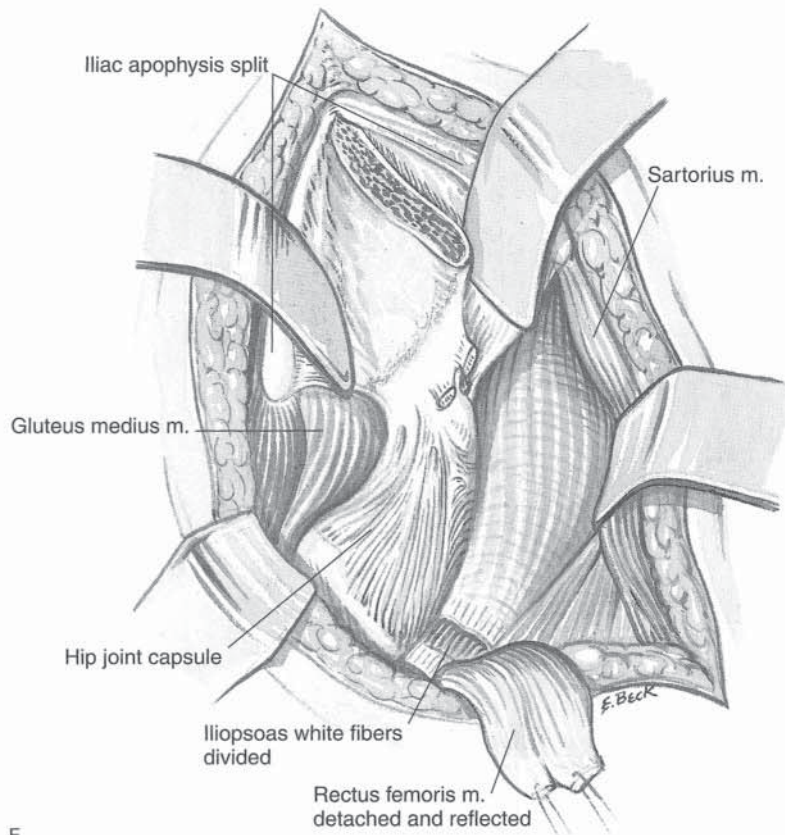
G, Next, the periosteum is elevated from the medial and lateral walls of the ilium all the way posteriorly to the sciatic notch. It is vital to stay within the periosteum to prevent injury to the superior gluteal vessels and the sciatic nerve. A common pitfall is inadequate surgical exposure of the sciatic notch, making it difficult to pass the Gigli saw behind the notch. The space on the lateral wall of the ilium is packed with sponge to dilate the interval and to control oozing of blood. Next, the periosteum is elevated from the inner wall of the ilium in a continuous sheet, exposing the sciatic notch medially. Again, it is important to stay in the subperiosteal plane to avoid injury to vessels and nerves. The medial space is packed with sponge. The sartorius muscle usually can be reflected medially with the medial half of the cartilaginous iliac apophysis. If it is difficult to do so or if more distal exposure is desired, the origin of the sartorius muscle is detached from the anterior superior iliac spine, its free end is marked with whip sutures for later reattachment, and the muscle is reflected distally and medially. The two heads of origin of the rectus femoris, the direct one from the anterior inferior iliac spine and the reflected one from the superior margin of the acetabulum, are divided at their origin, marked with whip sutures, and reflected distally.

Next, on the deep surface of the iliopsoas muscle, the psoas tendon is exposed at the level of the pelvic rim. The iliopsoas muscle is rolled over so that its tendinous portion can be separated from the muscular portion. If identification is in doubt, a nerve stimulator is used to distinguish the psoas tendon from the femoral nerve. A Freer elevator is passed between the tendinous and muscular portions of the iliopsoas muscle and the psoas tendon is sectioned at one or two levels. The divided edges of the tendinous portion retract and the muscle fibers separate, releasing contractures of the iliopsoas without disturbing the continuity of the muscle.

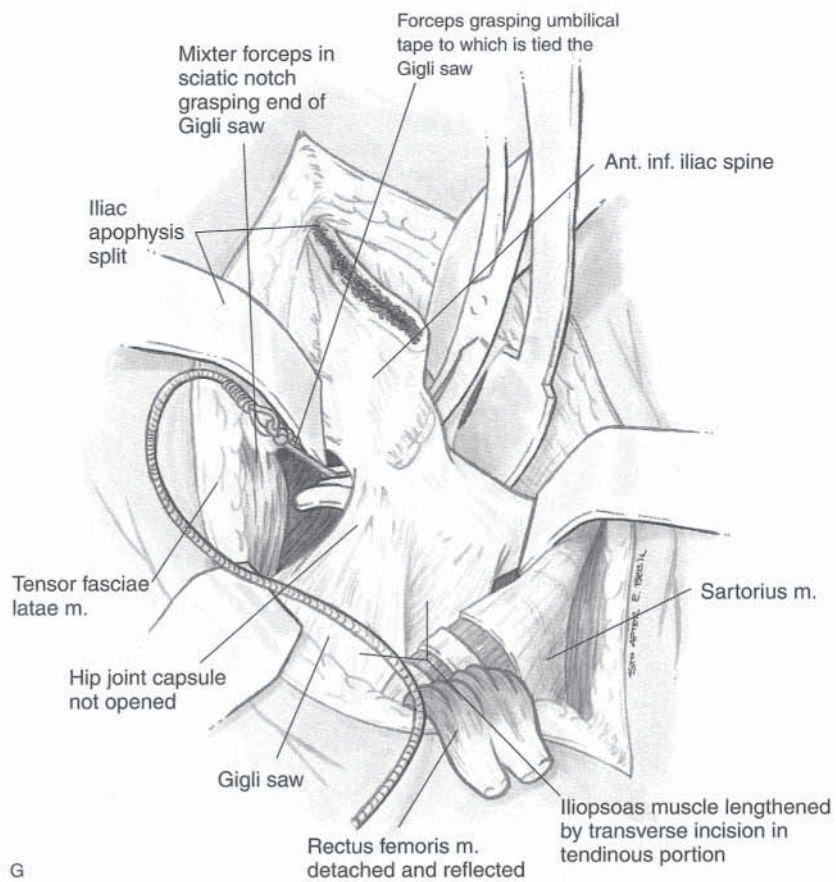
Two medium-sized Hohman elevator retractors, one introduced from the lateral side and the other from the medial side of the ilium, are placed subperiosteally in the sciatic notch. This step is crucial: besides keeping neurovascular structures out of harm's way, the Hohman retractors maintain continuity of the proximal and distal innominate segments at the sciatic notch.

A right-angle forceps is passed subperiosteally from the medial side of the ilium and guided through the sciatic notch to the outer side with the index finger of the surgeon's opposite hand. The Gigli saw is most easily passed by first passing an umbilical tape through the notch. The end of the tape is tied to the Gigli saw. The tape is grasped with the right-angle clamp and pulled through the notch; it in turn pulls the saw through the notch.

PLATE 15-13. Salter's Innominate Osteotomy



F



G

Salter's Innominate Osteotomy *Continued*

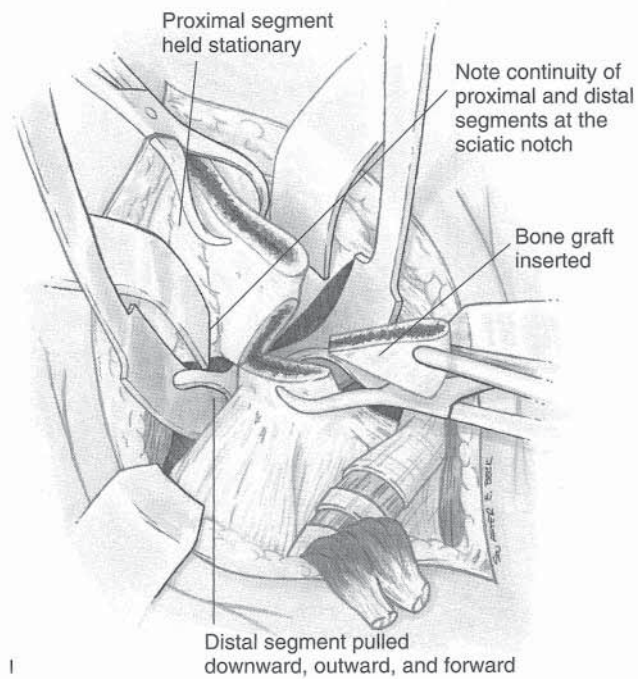
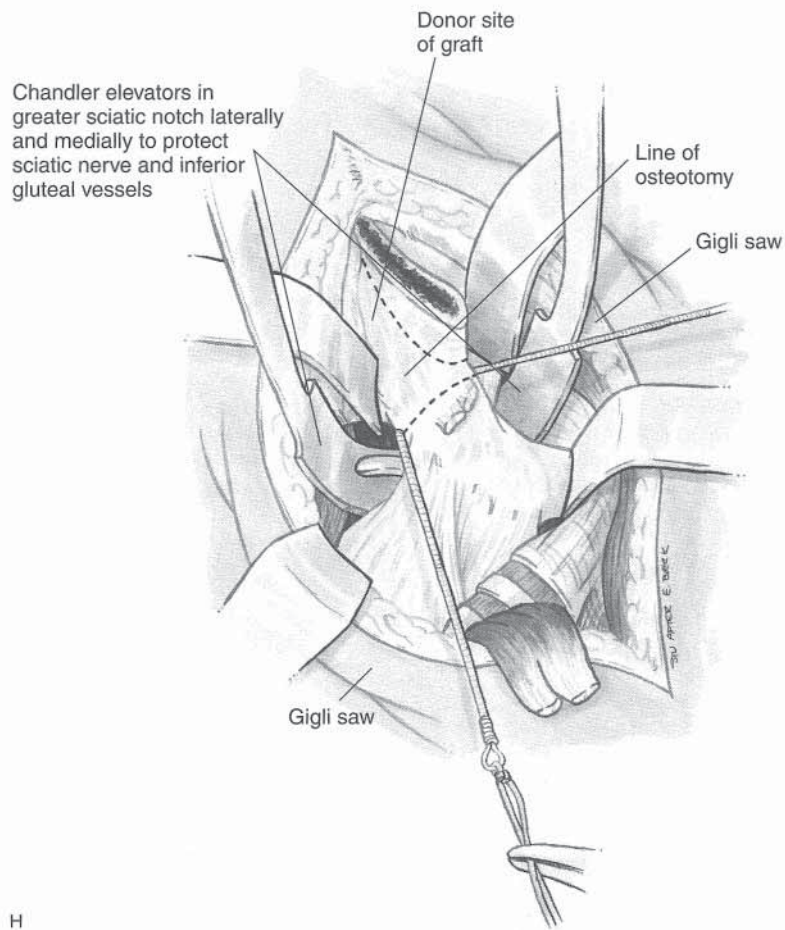
H, The osteotomy line extends from the sciatic notch to the anterior inferior iliac spine, perpendicular to the sides of the ilium. It is vital to begin the osteotomy well inferiorly in the sciatic notch; the tendency is to start too high. The handles of the Gigli saw are kept widely separated and at continuous tension in order to keep the saw from binding in the soft cancellous bone. The osteotomy, which emerges anteriorly immediately above the anterior inferior iliac spine, is completed with the Gigli saw. The use of an osteotome may subject the superior gluteal artery and sciatic nerve to iatrogenic damage.

I, The Hohman retractors are kept constantly at the sciatic notch by an assistant to prevent posterior or medial displacement of the distal segment and loss of bony continuity posteriorly. A triangular full-thickness bone graft is removed from the anterior part of the iliac crest with a large, straight, double-action bone cutter. The length of the base of the triangular wedge represents the distance between the anterior superior and the anterior inferior iliac spines. The portion of bone to be removed as bone graft is held firmly with a Kocher forceps; the operator must be sure that it does not fall on the floor or get contaminated.

The proximal fragment of the innominate bone is held steady with a large towel clip forceps, and the distal fragment is grasped with a second stout towel forceps. The affected hip is placed in 90 degrees of flexion, maximal abduction, and 90 degrees of lateral rotation; a second assistant applies distal and lateral traction on the thigh. With the second towel clip placed well posteriorly on the distal fragment, the surgeon rotates the distal fragment downward, outward, and forward, thus opening the osteotomy site anteriorly. The site must be kept closed posteriorly. Leaving it open posteriorly displaces the hip joint distally without adequate rotation and redirection of the acetabulum at the symphysis pubis; furthermore, it will lengthen the lower limb unnecessarily. Another technical error to avoid is opening the osteotomy site with a mechanical spreader (such as a laminectomy spreader or a self-retaining retractor) because that will do nothing but move the proximal fragment upward and the distal fragment downward without rotating the distal fragment through the symphysis pubis. The acetabular maldirection will not be corrected unless such rotation of the distal fragment takes place. Posterior and medial displacement of the distal fragment should be avoided.

When the periosteum on the median wall of the ilium is taut, the cartilaginous apophysis of the ilium is divided as two or three levels; this will help rotate the acetabulum.

PLATE 15-13. Salter's Innominate Osteotomy



Salter's Innominate Osteotomy *Continued*

J, Next, the bone graft is shaped with bone cutters to the appropriate size to fit the open osteotomy site. Ordinarily the graft is about the correct size for the size of the patient because the base of the triangular graft represents the distance between the anterior superior and anterior inferior iliac spines. The surgeon should avoid using a large graft and hammering it in to fit snugly into the osteotomy site, for this will open the site posteriorly. With the osteotomy site open anteriorly and the distal segment rotated, the bone graft is inserted into the opened-up osteotomy. The distal fragment of the innominate bone should be kept slightly anterior to the proximal fragment. When traction is released, the graft is firmly locked by the two segments of the bone.

A stout, threaded Kirschner wire is drilled from the proximal segment across the osteotomy site, through the graft, and into the distal segment posterior to the acetabulum, preventing any future displacement of the graft or the distal segment. The first wire should be directed posterior to the acetabulum. Radiographs are obtained to check the adequacy of correction of the acetabular maldirection and the position of the Kirschner wire. Then a second Kirschner wire is drilled parallel to the first to further stabilize internal fixation of the osteotomy. In the older child I use a third threaded Kirschner wire or two cancellous positional screws to ensure security of internal fixation. Inadequate penetration of the wires into the distal fragment will result in loss of alignment of the osteotomy. They may bend or break, or if excessively heavy they may fracture the graft or the innominate bone; the importance of choosing the correct diameter of wire or cancellous screw cannot be overemphasized. Penetration of the wires into the hip joint may cause chondrolysis of the hip or may cause the wire to break at the joint level. An AP radiograph of the hips is obtained to check the depth of the Kirschner wires and the degree of correction obtained.

The two halves of the cartilaginous iliac apophysis are sutured together over the iliac crest. The rectus femoris and sartorius muscles are reattached to their origins. The wound is closed in routine manner. Skin closure should be with continuous subcuticular 00 nylon suture. The Kirschner wires are cut so that their ends are in the subcutaneous fat and are easily palpable.

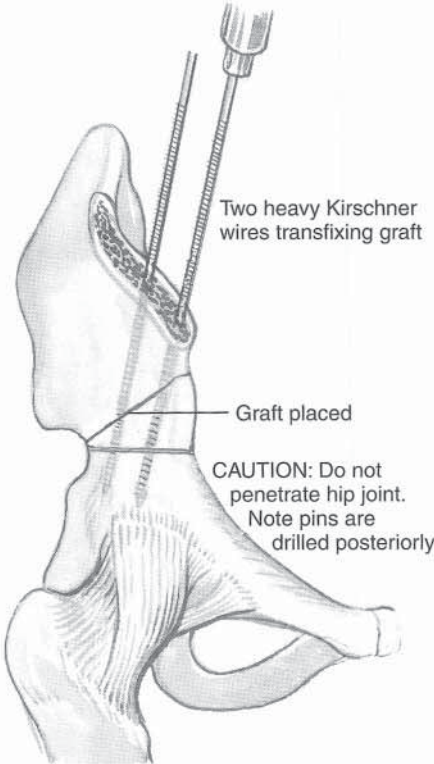
A one-and-one-half-hip spica cast is applied with the hip in a stable weightbearing position. Immobilization in a forced or extreme position should be avoided because it will cause excessive and continuous compression of articular cartilage, osteonecrosis, permanent joint stiffness, and eventual degenerative arthritis. In the cast, the knee is bent to control the position of hip rotation. When there is excessive femoral antetorsion the hip is immobilized in slight medial rotation. A common pitfall is immobilization in marked medial rotation; this mistake will result in posterior subluxation or dislocation of the femoral head. In femoral retrotorsion the hip should be immobilized in slight lateral rotation.

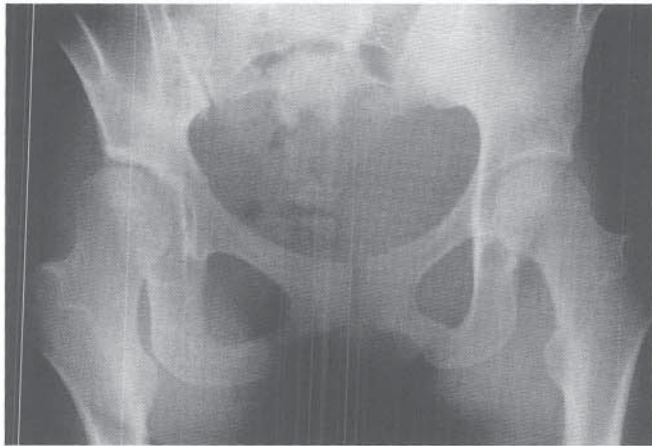
A radiograph of the hips through the cast is obtained before the child is discharged from the hospital. Another set of radiographs is obtained 2 to 3 weeks postoperatively to ensure that the graft has not collapsed, the pins have not migrated, and there is no medial displacement of the distal segments. In the older cooperative patient, when cancellous screws are used for internal fixation, a hip spica cast is not necessary.

POSTOPERATIVE CARE

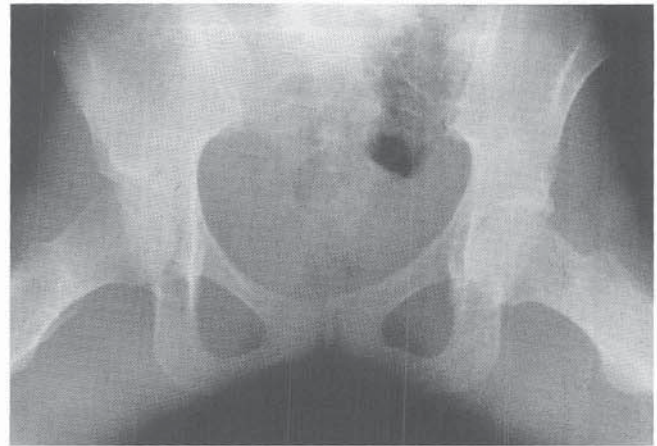
The cast is removed at 6 weeks with the child under general anesthesia, and the pins are removed through a portion of the original incision. Range-of-motion exercises are begun and the patient is allowed to ambulate with support. Older children can use crutches, while those younger than 5 years use a walker. Full weightbearing is resumed after 3 weeks, provided that knee range of motion is greater than 90 degrees. When an open reduction has been combined with a Salter osteotomy, a second period of immobilization in abduction casts (Petrie casts) for about 4 weeks is recommended. This allows the hips to regain flexion and extension while the abducted position maintains hip reduction.

PLATE 15-13. Salter's Innominate Osteotomy

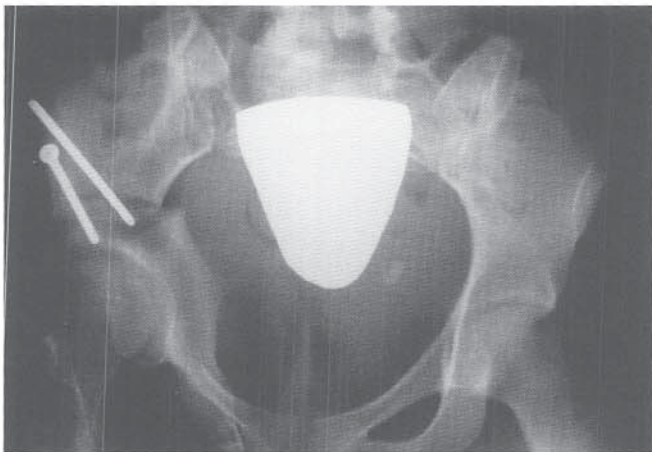




A



B



C

FIGURE 15-73 Radiographic appearance in a 20-year-old track athlete with a 2-year history of pain in the right hip. She had no prior history of hip abnormalities. **A**, AP radiograph shows right hip dysplasia with an increased acetabular index. **B**, Frog-leg lateral radiograph shows the sourcil of the right hip, which is more oblique than the apparent acetabular contour. **C**, Radiograph obtained after a Steel triple innominate osteotomy. The acetabular fragment has been rotated anterolaterally and translated medially to improve hip coverage and mechanics.

first, just below the insertion of the hip capsule. The pubic ramus is then cut just at the margin of the obturator foramen. The iliac cut goes posteriorly to just behind the acetabulum, and then a fourth cut is made posterior to the acetabulum. Special instruments and image intensification are essential for the safe execution of this procedure.^{60,101}

Complications of the Ganz osteotomy can be serious, and the learning curve for this procedure has been described as “long and steep.”²¹⁷ Ganz and associates reported two cases of intra-articular osteotomy with poor outcomes.⁶⁰ They also reported excessive lateral displacement of the acetabular fragment, which blocked hip abduction. Early weightbearing may displace the osteotomy, and delayed union has occurred.⁶⁰ Ectopic bone formation has also been reported. The surgeon is well advised to obtain as much instruction and practice in the laboratory as possible before undertaking this surgical procedure.

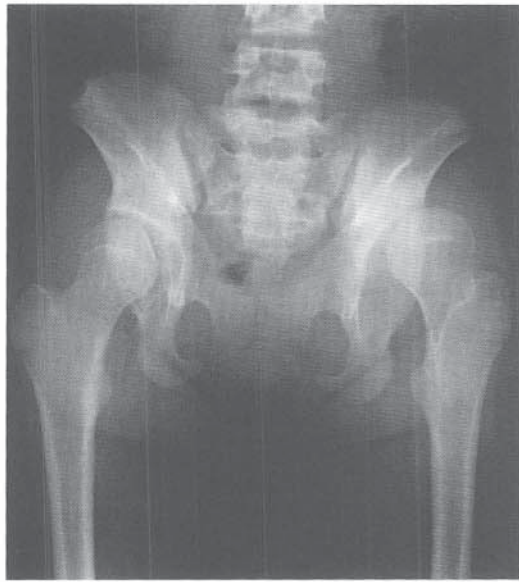
OSTEOTOMIES THAT AUGMENT THE ACETABULUM

Chiari Osteotomy. The Chiari osteotomy is indicated when it is no longer possible to achieve a concentric reduction of

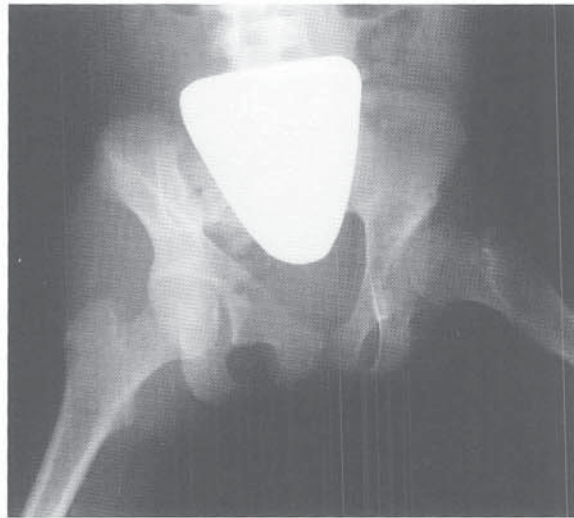
the hip. It is, in essence, a controlled fracture through the wing of the ilium, with medial displacement of the acetabular fragment over the intact hip capsule (Fig. 15-75). Over time, the hip capsule will transform into fibrocartilage, which becomes the new acetabular coverage. Because the femoral head is covered by fibrocartilage instead of repositioned acetabular cartilage, the Chiari osteotomy is considered a salvage procedure.

The Chiari osteotomy is made just above the acetabulum, in the region of insertion of the hip capsule.^{10,11,21,80,114,247} The osteotomy curves to match the acetabular contour and slopes upward from lateral to medial. The level of the osteotomy and the slope of the cut must be precise in order for the displaced iliac wing to cover the femoral head without impinging on it. The acetabular fragment is displaced medially almost the full width of the ilium at that level, and it is held there with pin or screw fixation. If anterior coverage is inadequate after displacement of the osteotomy, a bone graft from the iliac wing should be placed anteriorly over the femoral head and fixed there. If the angle of inclination of the osteotomy is too horizontal, the displaced fragment will not support the femoral head. If the inclination is too steep, the fragment will abut the head.

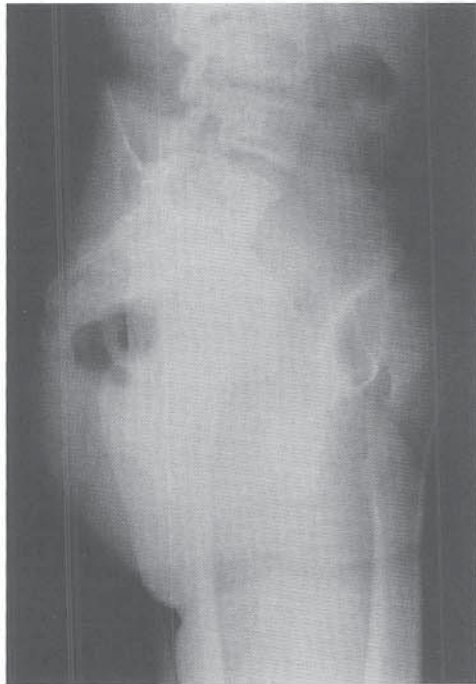
Chiari has reported that of 20 cases, results in more than two-thirds were good or excellent on follow-up ranging



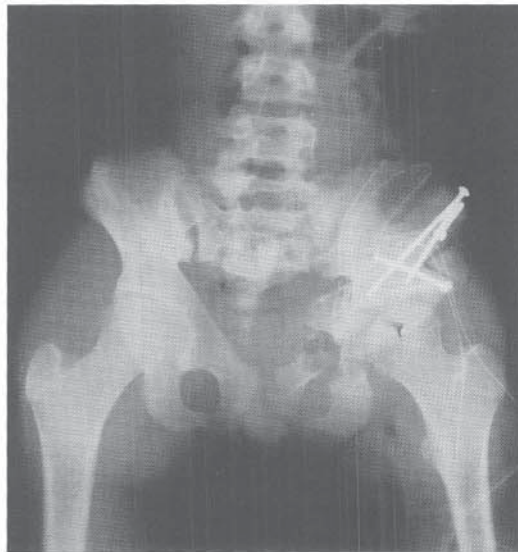
A



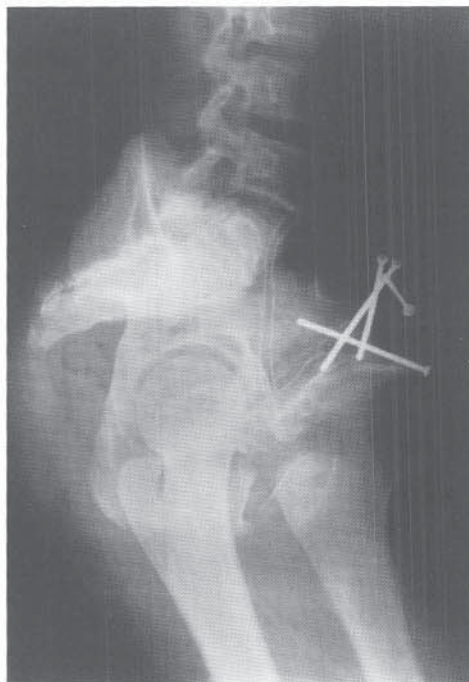
B



C

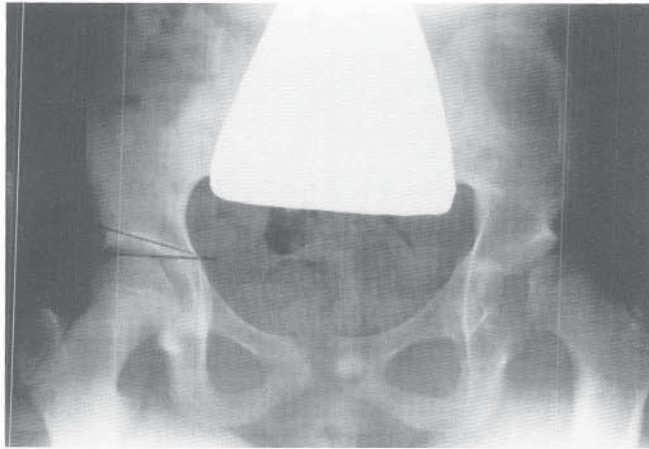


D

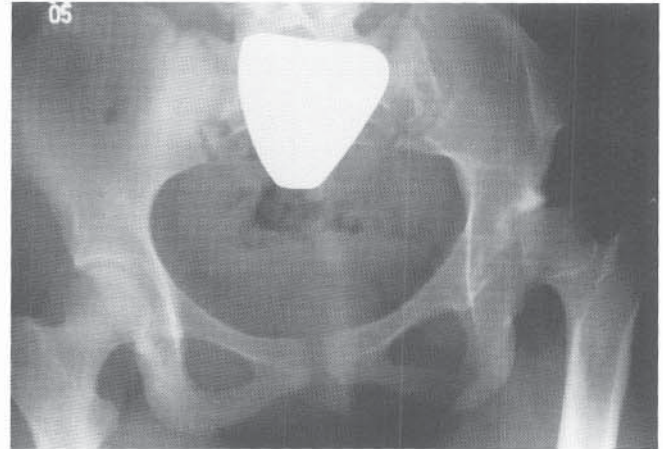


E

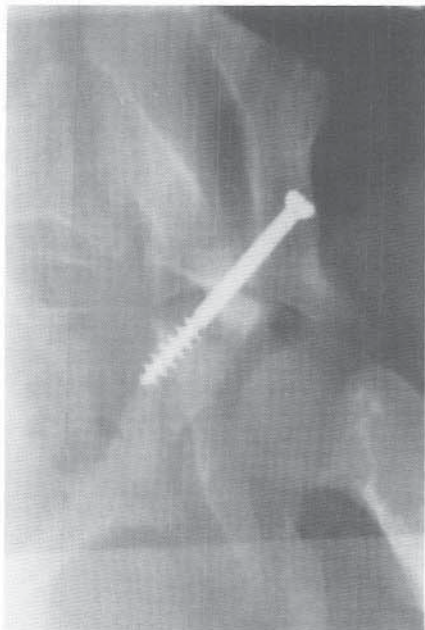
FIGURE 15-74 Ganz osteotomy in a 15-year-old girl who presented with increasing hip pain but no prior history of hip problems. **A**, AP radiograph of the pelvis. The left hip is subluxated and dysplastic. **B**, Abduction-internal rotation radiograph showing improved seating of the femoral head, with restoration of Shenton's line but some lateralization. **C**, False-profile radiograph showing marked anterior uncovering of the femoral head. **D**, Postoperative AP radiograph showing considerable improvement in acetabular coverage. **E**, Postoperative false-profile radiograph showing improvement in anterior acetabular coverage.



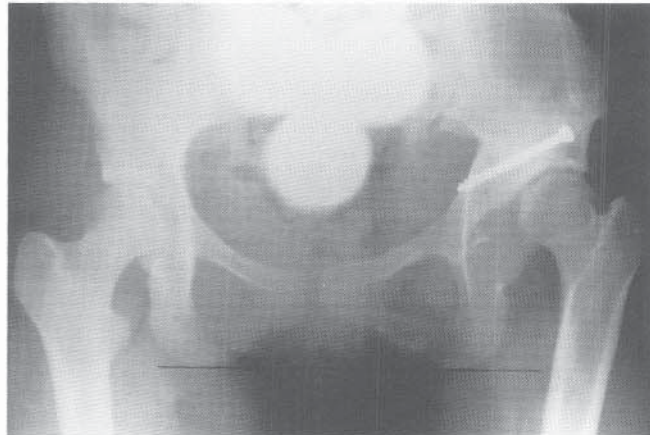
A



B



C



D

FIGURE 15-75 Chiari osteotomy. **A**, AP radiograph of 10-year-old girl who underwent a closed reduction at age 2½ years that subsequently failed. Note wide subluxation of the femoral head. **B**, AP radiograph obtained at age 14 years shows sclerosis and joint space narrowing, signs of early degenerative disease. The patient now had daily hip pain. **C**, Intraoperative radiograph shows the Chiari osteotomy with screw fixation. **D**, AP radiograph at age 16 years. The femoral head was now better covered, and the patient's symptoms had decreased.

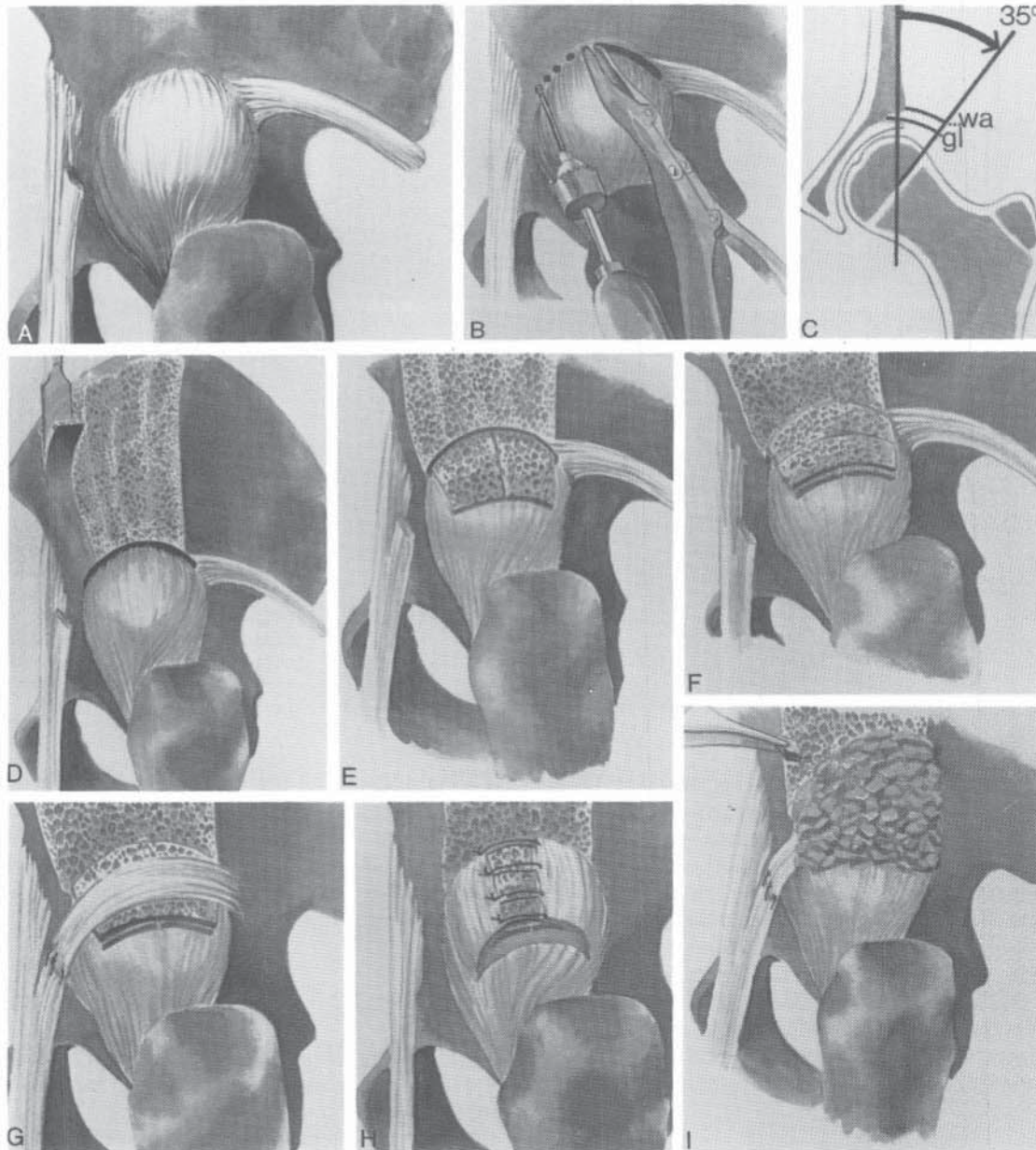

FIGURE 15-76 Slotted acetabular augmentation. **A**, The reflected head of the rectus femoris is sectioned in its anterior part, elevated, and reflected posteriorly. Note the exposure of the thickened capsule of the hip joint in its anterior, superior, and posterior aspects. **B**, The site of the slot is exactly at the margin of the acetabulum. It is made by multiple drill holes that are joined with a narrow rongeur. The slot is 5 mm wide and 10 mm deep; its length varies depending on the amount of coverage required. **C**, The width of augmentation (*wa*) is that amount of bone to give a normal CE angle. Adding the *wa* to the slot gives the graft length (*gl*). **D**, Harvesting of thin strips of cortical and cancellous bone graft from the lateral wall of the ilium. The graft strips are long, extending from the iliac crest to the upper margin of the slot. The inner wall of the ilium is left intact. **E**, First layer of augmentation. The thin strips of bone graft are placed radially into the slot with the concave side down. **F**, The second layer of augmentation is perpendicular to the first layer and parallel to the acetabular margin. **G**, The first and second layers of bone graft are held in place by reattaching the tendon of the reflected head of the rectus femoris. A capsular flap may be used as an additional measure, if necessary. **H** and **I**, The third layer of the bone graft consists of small pieces of bone that are packed above the reflected head of the rectus femoris. This layer of bone is held in place by reattaching the hip abductor to the iliac crest. (From Staheli LT: Slotted acetabular augmentation. *J Pediatr Orthop* 1981;1:321.)

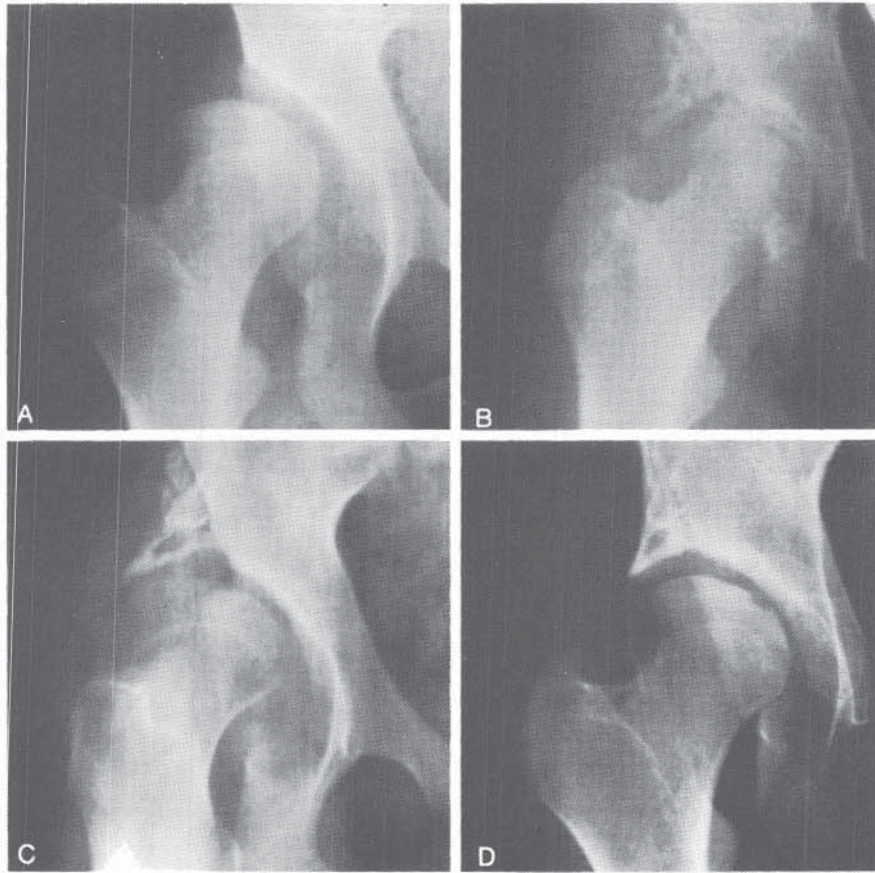


FIGURE 15-77 Developmental hip dysplasia in a 15-year-old girl that was treated by the Staheli acetabular augmentation procedure. **A**, Preoperative radiograph. **B**, Immediate postoperative radiograph. **C** and **D**, Radiographic appearance 1½ years after surgery. Note the excellent coverage of the femoral head. (From Staheli LT: Slotted acetabular augmentation. *J Pediatr Orthop* 1981; 1:321.)

from 2 to 8 years.²⁷ Bailey and Hall reported that 15 of 16 patients who underwent Chiari osteotomies for residual DDH experienced pain relief and increased function.⁷

The most frequent complications occur because of inaccurate placement of the osteotomy. Both the starting point and the slope of the osteotomy are critical to the successful displacement of the acetabulum. An osteotomy with a high starting point provides no support to the femoral head. An osteotomy that enters the sacroiliac joint cannot be displaced. If the angle of the osteotomy is too great, the displaced fragment will impinge on the femoral head. Failure to add an anterior bone graft may leave the femoral head uncovered.

Shelf Procedures. There have been numerous varieties of shelf procedures performed for severe acetabular dysplasia (Figs. 15-76 to 15-79). The indications for this procedure are similar to those for the Chiari osteotomy—chiefly, a hip in which a concentric reduction cannot be obtained. In addition, some surgeons will augment another acetabular procedure, such as the Salter, with a shelf procedure in an attempt to gain additional hip coverage. Shelf procedures that do not have an adequate buttress of bone that is continuous with the pelvis will gradually resorb or “melt” away.

The Staheli procedure can provide increased coverage for a hip that cannot be concentrically reduced. The shelf is constructed over the femoral head, particularly anteriorly and laterally. It is created by using local shavings of iliac bone, along with a large segment of bone from the iliac wing. A concave slab of bone is fixed over the femoral head

and placed over the hip capsule and beneath the reflected head of the rectus femoris. A buttress of cancellous bone is then constructed between this slab and the pelvis, over the acetabulum. As the shelf matures, the contour will remodel from the pressure of the femoral head, and the bone of the shelf will hypertrophy.

Teratologic Dislocation of the Hip

Teratologic hip dislocation, also termed *antenatal dislocation of the hip*, is defined by a fixed dislocation at birth with limited range of motion of the hip (Fig. 15-80). Most children who have teratologic dislocations have an associated syndrome or other musculoskeletal abnormalities. The most common coexisting conditions are arthrogryposis, myelomeningocele, chromosomal abnormalities, diastrophic dwarfism, and lumbosacral agenesis.

Through the 1950s and 1960s, treatment programs for teratologic dislocations were often unsuccessful. As a result, many authors suggested leaving the hips untreated.^{53,61} Modern treatment has been more successful, and the majority of such hips should be reduced.^{33,127,246} For patients with neuromuscular conditions such as myelomeningocele, the motor level should be considered and high paralytic levels may be best left untreated.

In reaching the decision to treat, the surgeon should consider the overall disability of the patient and the likelihood of future function. Most children with arthrogryposis have a restricted but adequate range of hip flexion and

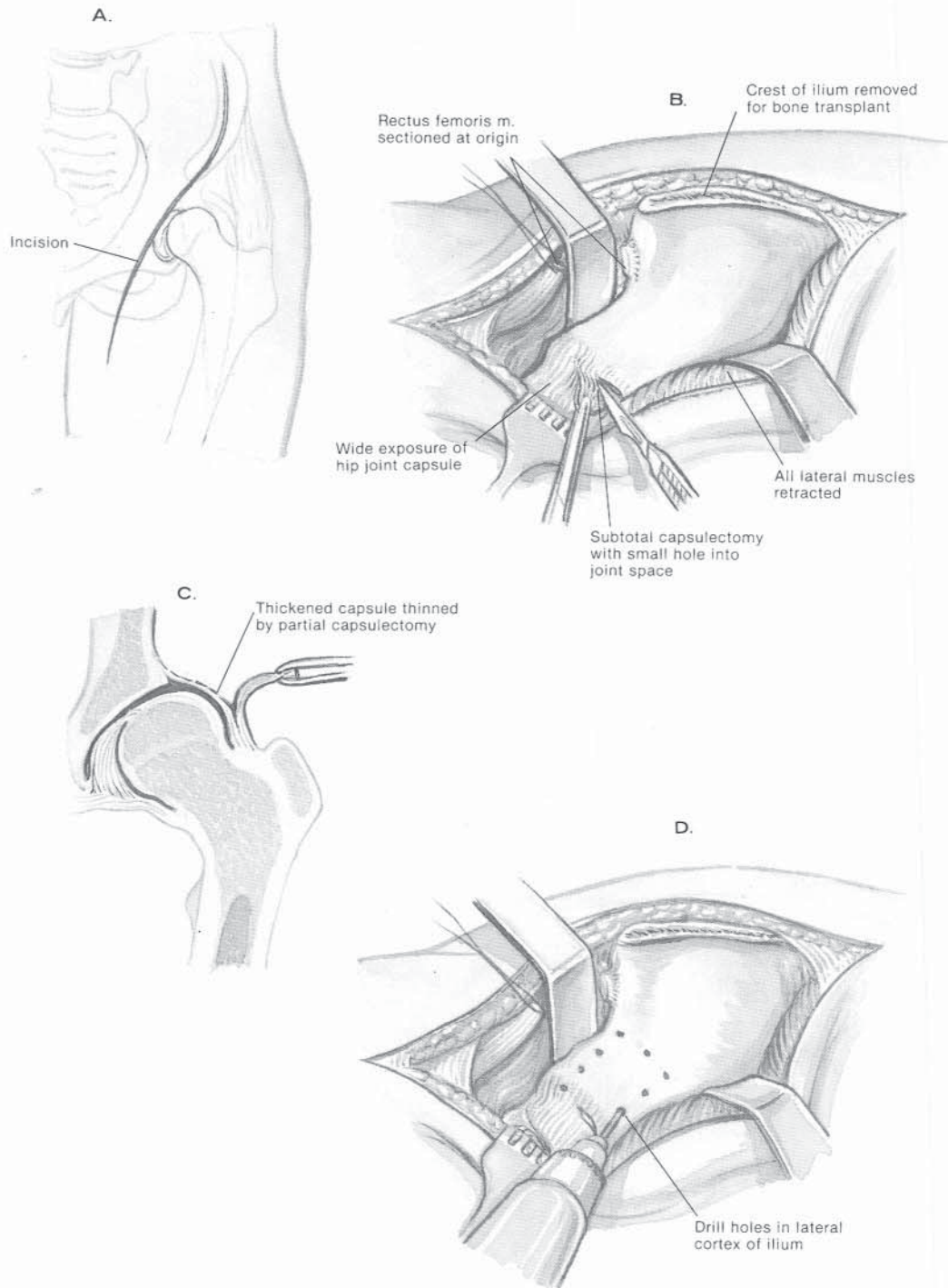


FIGURE 15-78 The Wilson shelf procedure. A, Incision and exposure of the hip joint through an anterior iliofemoral approach. B, Sectioning of the straight head of the rectus femoris at its origin and wide exposure of the hip joint capsule. C, Thinning of the thickened capsule by partial capsulectomy; only $\frac{1}{8}$ inch of capsule covering the femoral head is left. A small aperture in the capsule assists in accurate determination of the lateral margin of the acetabulum. D, Small drill holes mark the area of the ilium to be turned down over the femoral head.

Illustration continued on following page

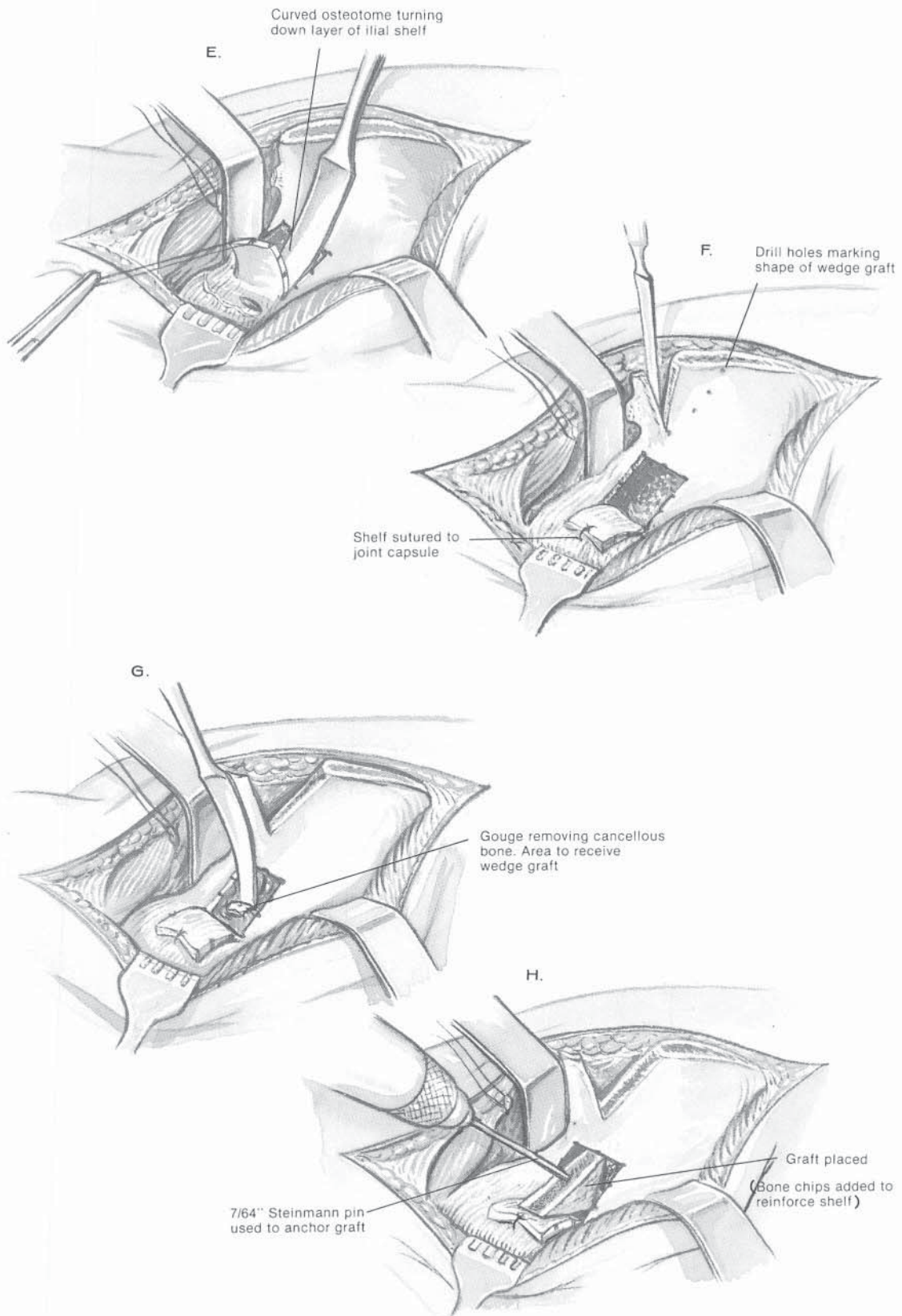
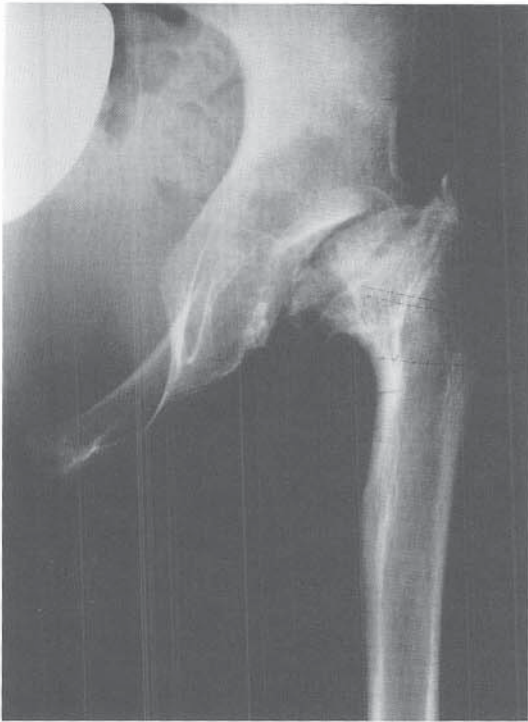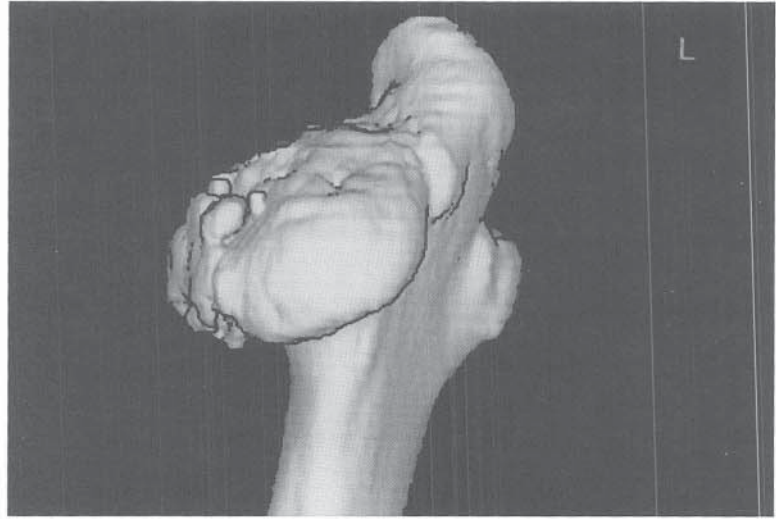


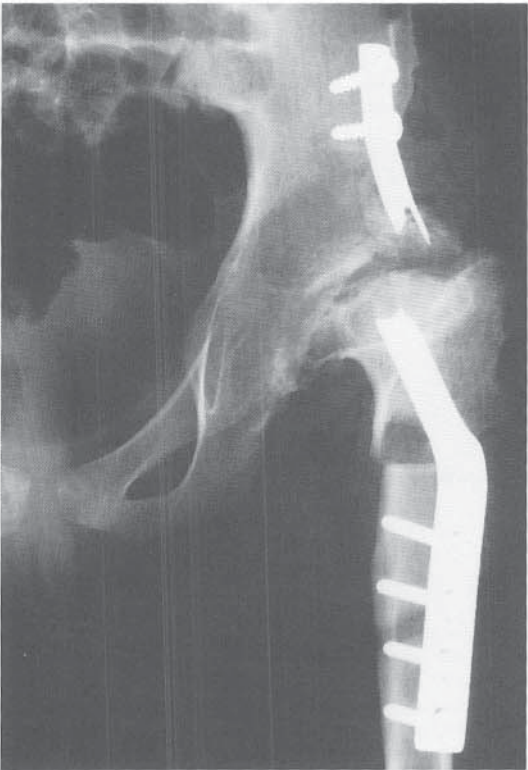
FIGURE 15-78 *Continued.* E, With a sharp, curved $\frac{1}{2}$ -inch osteotome, the first layer of the shelf is elevated and turned down. F, The first layer of the shelf is sutured to the capsule. Drill holes mark the outline of a wedge-shaped graft in the region of the anterosuperior iliac spine. G, With a gouge, a defect is made through the cancellous bone of the ilium to the inner cortex. The defect will receive the wedge-shaped graft from the anterosuperior iliac spine. H, The triangular piece of graft is anchored in place with a $\frac{7}{64}$ -inch Steinmann pin. Additional chip grafts from the ilium are used to reinforce the shelf. (Redrawn from Wilson JC Jr: Surgical treatment of dysplastic acetabulum in adolescents. Clin Orthop 1974;98:137.)



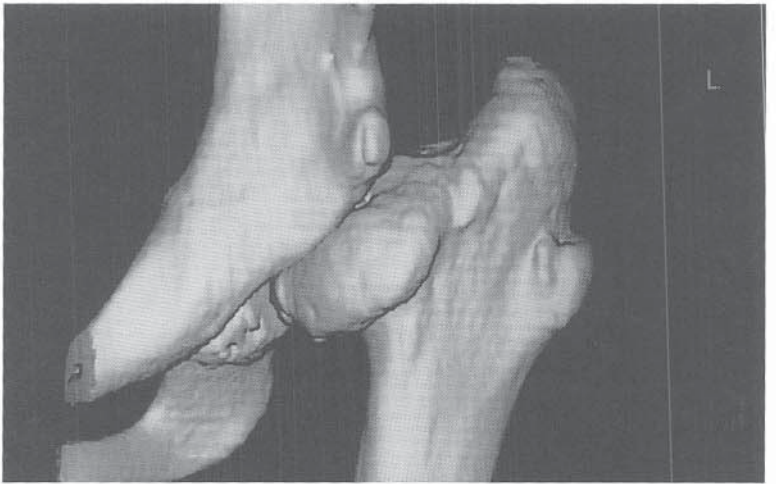
A



B

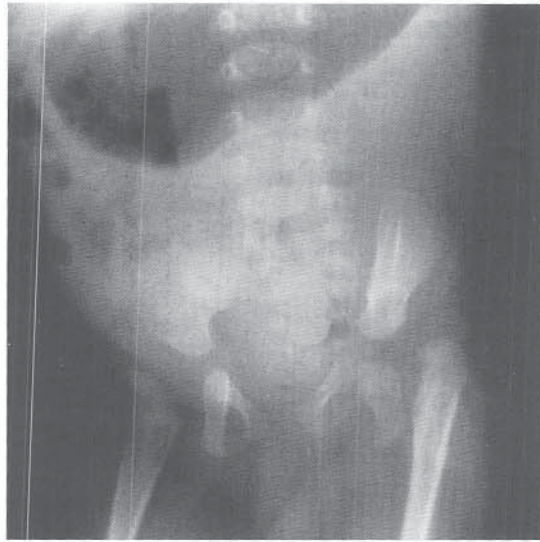


D

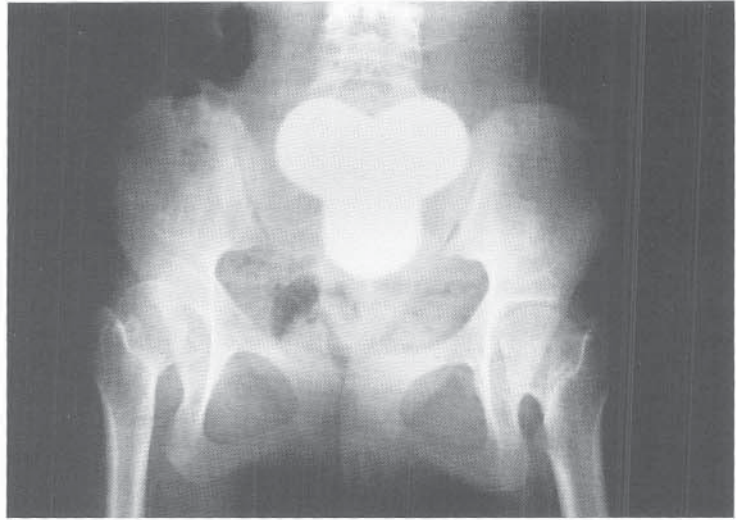


C

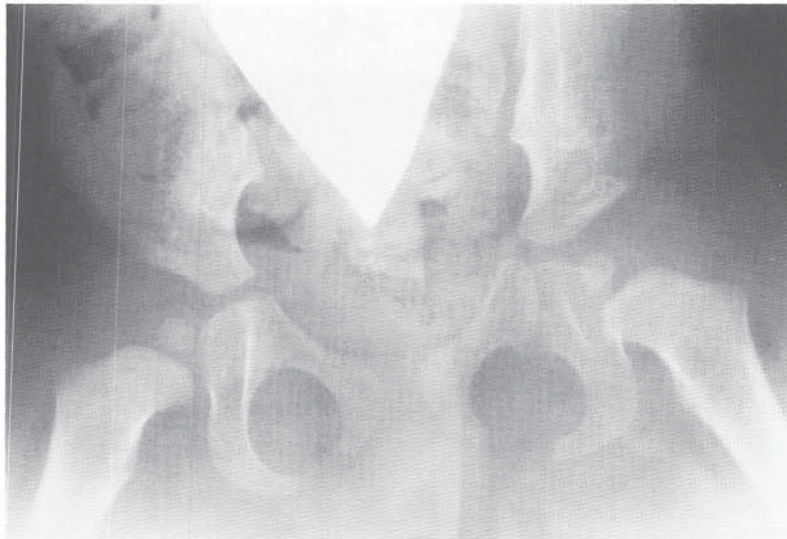
FIGURE 15–79 Imaging appearance in a 13-year-old Russian girl who had undergone multiple prior surgeries for DDH. She had regular hip pain at presentation and was limited in her functional capabilities. **A**, AP radiograph shows subluxation of the hip with a very narrow joint space. **B** and **C**, Three-dimensional reconstruction images show preservation of the femoral head anteriorly and medially, with marked trochanteric overgrowth. **D**, AP radiograph obtained after a shelf arthroplasty buttressed with a small plate. A femoral valgus extension osteotomy was performed to move the medial anterior femoral head into a weightbearing position and to lower the trochanter. The patient's symptoms were relieved over a 2-year follow-up.



A



C



B

FIGURE 15-80 Teratologic dislocation of the hip in a child with arthrogryposis. **A**, AP radiograph obtained at age 6 weeks. Both hips are widely dislocated and the left hip is adducted, suggesting teratologic dislocation. Bilateral medial open reductions were performed when the child was 6 months old. **B**, AP radiograph obtained 10 months after the bilateral medial open reductions. **C**, AP radiograph obtained at age 13 years. Both hips remain reduced, but the right hip is anteriorly subluxated. The patient has maintained a 90-degree arc of motion and has no hip pain.

extension, with limited rotation and abduction. The majority of these children also have some motor ability in the lower extremities and reasonable trunk control, and most of these hips should be reduced. Occasionally, a child with arthrogryposis has almost total motor paralysis and may not benefit from hip reduction.

Closed treatment for teratologic hip dislocation is usually unsuccessful. Our choice for management has been an open reduction from an anteromedial approach when the child is 6 months old.⁶⁸ These hips tend to remain stable without capsulorrhaphy, and the medial approach has not caused excessive stiffness. Szoke and associates have reported 80 percent good results in children with arthrogryposis who were treated by medial open reduction at about 9 months of age.²⁰⁷ In the young child, femoral shortening usually is not required. In the older child, anterior open reduction,

with femoral shortening if necessary, is the preferred approach.

REFERENCES

1. Albinana J, Morcuende JA, Weinstein SL: The teardrop in congenital dislocation of the hip diagnosed late: a quantitative study. *J Bone Joint Surg* 1996;78-A:1048.
2. Albinana J, Wuesada J, Certuicha J: Children at high risk for congenital dislocation of the hip: late presentation. *J Pediatr Orthop* 1993;13:268.
3. Andren L: Pelvic instability in newborns with specific reference to congenital dislocation of the hip and hormonal factors: a roentgenologic study. *Acta Radiol* 1962;(suppl):212.
4. Artz T, Levine D, Lim W, et al: Neonatal diagnosis, treatment, and related factors of congenital dislocation of the hip. *Clin Orthop* 1975;110:112.
5. Asher M: Orthopedic screening: especially congenital dislocation of the hip and spinal deformity. *Pediatr Clin North Am* 1977;24:713.

6. Asher M: Screening for congenital dislocation of the hip, scoliosis, and other abnormalities affecting the musculoskeletal system. *Pediatr Clin North Am* 1986;33:1335.
7. Bailey T Jr, Hall JE: Chiari medial displacement osteotomy. *J Pediatr Orthop* 1985;5:635.
8. Barlow T: Early diagnosis and treatment of congenital dislocation of the hip. *J Bone Joint Surg* 1962;44-B:292.
9. Baronciani D, Atti G, Andiloro F, et al: Screening for developmental dysplasia of the hip: from theory to practice. *Pediatrics* 1997;1:99.
10. Benson M, Evans J: The pelvic osteotomy of Chiari: an anatomical study of the hazards and misleading radiographic appearance. *J Bone Joint Surg* 1976;58-B:163.
11. Betz R, Kuman S, Palmer C, et al: Chiari pelvic osteotomy in children and young adults. *J Bone Joint Surg* 1988;70-A:182.
12. Bialik V, Bialik G, Wiener F: Prevention of overtreatment of neonatal dysplasia by the use of ultrasonography. *J Pediatr Orthop B* 1998;7:39.
13. Bialik V, Rosenberb N: Transfer of the greater trochanter. *J Pediatr Orthop B* 1994;3:30.
14. Blix M: Die Lange und die Spannung des Muskels. *Scand Arch Physiol* 1881;3:295.
15. Blockey N: Derotation osteotomy in the management of congenital dislocation of the hip. *J Bone Joint Surg* 1984;66-B:485.
16. Bos C, Bloem J, Verbout A: Magnetic resonance imaging in acetabular residual dysplasia. *Clin Orthop* 1991;265:207.
17. Bos C, Sloof T: Treatment of failed open reduction for congenital dislocation of the hip. *Acta Orthop Scand* 1984;55:531.
18. Bradley J, Wetherill M, Benson M: Splintage for congenital dislocation of the hip: is it safe and reliable? *J Bone Joint Surg* 1987;69-B:257.
19. Buchanan J, Greer RL, Cotler J: Management strategy for prevention of avascular necrosis during treatment of congenital dislocation of the hip. *J Bone Joint Surg* 1981;63-A:140.
20. Bucholz RW, Ogden JA: Patterns of ischemic necrosis of the proximal femur in nonoperatively treated congenital hip diseases. In *The Hip: Proceedings of the Sixth Open Scientific Meeting of the Hip Society*, p 43. St. Louis, CV Mosby Co, 1978.
21. Calvert P, August A, Albert J: The Chiari pelvic osteotomy: a review of the long-term results. *J Bone Joint Surg* 1987;69-B:551.
22. Camp J, Herring JA, Dworezynski C: Comparison of inpatient and outpatient traction in developmental dislocation of the hip. *J Pediatr Orthop* 1994;4:9.
23. Carliz H, Georges F: The natural history of the limbus in congenital dislocation of the hip. In Tachdjian M (ed): *Congenital Dislocation of the Hip*, p 247. New York, Churchill Livingstone, 1982.
24. Carter C, Wilkinson J: Congenital dislocation of the hip. *J Bone Joint Surg* 1960;42-B:669.
25. Carter C, Wilkinson J: Genetic and environmental factors in the etiology of CDH. *Clin Orthop* 1964;33:119.
26. Castelein R, Sauter J, Vlieger MD, et al: Natural history of ultrasound hip abnormalities in clinically normal newborns. *J Pediatr Orthop* 1992;12:423.
27. Chiari K: Medial displacement osteotomy of the pelvis. *Clin Orthop* 1974;98:55.
28. Chiari K: Die operative Behandlung am Huftgelenk bei der angeborenen Huftgelenksverrenkung. *Wien Med Wochenschr* 1957;107:1020.
29. Chuinard E, Logan N: Varus producing and derotational osteotomy in the treatment of congenital dislocation of the hip. *J Bone Joint Surg* 1963;45-A:1397.
30. Churgay C, Caruthers B: Diagnosis and treatment of congenital dislocation of the hip. *Am Fam Physician* 1992;45:1217.
31. Clarke N, Clegg J, Al-Calabi A: Ultrasound screening of hips at risk for CDH: failure to reduce the incidence of late cases. *J Bone Joint Surg* 1989;71-B:9.
32. Coleman S: Congenital dysplasia of the hip in the Navajo infant. *Clin Orthop* 1968;56:179.
33. Coleman S: Teratologic congenital dislocation. In Coleman S (ed): *Congenital Dysplasia and Dislocation of the Hip*, p 249. St. Louis, CV Mosby Co, 1978.
34. Cooperman D, Wallenstein R, Stulberg S: Acetabular dysplasia in the adult. *Clin Orthop* 1983;175:79.
35. Crawford A, Slovek R: Fate of untreated congenitally dislocated hip. *Orthop Trans* 1978;2:73.
36. Danzhou S, Hongzhi I, Weinmin Y, et al: Preoperative intermittent manual traction in congenital dislocation of the hip. *J Pediatr Orthop* 1989;9:205.
37. Davies S, Walker G: Problems in the early recognition of hip dysplasia. *J Bone Joint Surg* 1984;66-B:479.
38. DeRosa G, Feller N: Treatment of congenital dislocation of the hip: management before walking age. *Clin Orthop* 1987;225:77.
39. Dhar S, Taylor J, Jones W, et al: Early open reduction for congenital dislocation of the hip. *J Bone Joint Surg* 1990;72-B:175.
40. Diepstraten A: Open reduction of congenital hip dislocation. *Acta Orthop Scand* 1985;56:32.
41. Dunn P: The anatomy and pathology of congenital dislocation of the hip. *Clin Orthop* 1976;119:23.
42. Dunn P: Congenital dislocation of the hip: necropsy studies at birth. *Proc R Soc Med* 1969;62:1034.
43. Dunn P: Prenatal observation on the etiology of congenital dislocation of the hip. *Clin Orthop* 1976;119:11.
44. Dupuytren G: Original or congenital displacement of the heads of the thigh bones. *Clin Orthop* 1964;33:3.
45. Edgren W: Coxa plana: a clinical and radiologic investigation with particular reference to the importance of the metaphyseal changes for the final shape of the proximal part of the femur. *Acta Orthop Scand* 1965;(suppl):84.
46. Edlestein J: Congenital dislocation of the hip in the Bantu. *J Bone Joint Surg* 1966;48-B:397.
47. Eppright R: Dial osteotomy of the acetabulum in the treatment of dysplasia of the hip. *J Bone Joint Surg* 1976;58-A:726.
48. Faciszewski T, Coleman S: Triple innominate osteotomy in the treatment of acetabular dysplasia. *J Pediatr Orthop* 1993;13:426.
49. Faciszewski T, Kiefer G, Coleman S: Pemberton osteotomy for residual acetabular dysplasia in children who have congenital dislocation of the hip. *J Bone Joint Surg* 1993;75-A:643.
50. Ferguson A: Primary open reduction of congenital dislocation of the hip using a median adductor approach. *J Bone Joint Surg* 1973;55-A:671.
51. Frankenberg N: To screen or not to screen: congenital dislocation of the hip. *Am J Public Health* 1981;71:1311.
52. Fredensborg N, Nilsson B: Overdiagnosis of congenital dislocation of the hip. *Clin Orthop* 1976;119:89.
53. Friedlander H, Westin G, Wood WJ: Arthrogyrosis multiplex congenita: a review of 45 cases. *J Bone Joint Surg* 1968;50-A:89.
54. Fuller D, Duthie R: The timed appearance of some congenital malformation and orthopaedic abnormalities. *Instr Course Lect* 1974;23:53.
55. Gage J, Winter R: Avascular necrosis of the capital femoral epiphysis as a complication of closed reduction of congenital dislocation of the hip. *J Bone Joint Surg* 1972;74-A:624.
56. Gage JR, Cary JM: The effects of trochanteric epiphysiodesis on growth of the proximal end of the femur following necrosis of the capital femoral epiphysis. *J Bone Joint Surg* 1980;62-A:785.
57. Gallien R, Bertin D, Lirette R: Salter procedure in congenital dislocation of the hip. *J Pediatr Orthop* 1984;4:427.
58. Galpin R, Roach J, Wenger D, et al: One-stage treatment of congenital dislocation of the hip in older children, including femoral shortening. *J Bone Joint Surg* 1989;71-A:737.
59. Gangloff S, Onimus M: Chiari pelvic osteotomy: technique and indications. *J Pediatr Orthop B* 1994;3:68.
60. Ganz R, Vihn T, Mast J: A new periacetabular osteotomy for the treatment of hip dysplasias: techniques and preliminary results. *Clin Orthop* 1988;232:26.
61. Gibson D, Urs N: Arthrogyrosis multiplex congenita. *J Bone Joint Surg* 1970;52-B:483.
62. Graf R: Classification of hip joint dysplasia by means of sonography. *Arch Orthop Trauma Surg* 1984;102:248.
63. Graf R: The diagnosis of congenital hip joint dislocation by the ultrasonic Combound treatment. *Arch Orthop Trauma Surg* 1980;97:117.
64. Graf R: Fundamentals of sonographic diagnosis of infant hip dysplasia. *J Pediatr Orthop* 1984;4:735.
65. Greenhill B, Hugosson C, Jacobsson G: Magnetic resonance imaging study of acetabular morphology in developmental dysplasia of the hip. *J Pediatr Orthop* 1993;13:314.
66. Grill F, Bensahel H, Canadell J, et al: The Pavlik harness in the treatment of congenital dislocating hip: report on a multicenter study of the European Paediatric Orthopaedic Society. *J Pediatr Orthop* 1988;8:1.
67. Gross R, Wisnefske M, Howard T: Infant hip screening. *Hip* 1982;10:50.
68. Gruel C, Birch J, Roach J, et al: Teratologic dislocation of the hip. *J Pediatr Orthop* 1986;6:693.

69. Guille J, Forlin E, Kumar S, et al: Triple osteotomy of the innominate bone in treatment of developmental dysplasia of the hip. *J Pediatr Orthop* 1992;12:718.
70. Harcke H, Kumar J: The role of ultrasound in the diagnosis and management of congenital dislocation and dysplasia of the hip. *J Bone Joint Surg* 1991;73-A:622.
71. Harris N: Acetabular growth potential in congenital dislocation of the hip and some factors upon which it may depend. *Clin Orthop* 1976;119:99.
72. Harris WH: Etiology of osteoarthritis of the hip. *Clin Orthop* 1986; 213:20.
73. Harrison T: The growth of the pelvis in the rat: a mensural and morphological study. *J Anat* 1958;92:236.
74. Hensinger R: Standards in Pediatric Orthopedics. New York, Raven Press, 1986.
75. Hernandez R: Concentric reduction of the dislocated hip: computed tomographic evaluation. *Radiology* 1984;150:266.
76. Hernandez R, Cornell R, Hensinger R: Ultrasound diagnosis of neonatal congenital dislocation of the hip. *J Bone Joint Surg* 1994;76-B:539.
77. Herring J: Conservative treatment of congenital dislocation of the hip in the newborn and infant. *Clin Orthop* 1992;281:41.
78. Hierton T, James U: Congenital dislocation of the hip. *J Bone Joint Surg* 1968;50-B:542.
79. Hoaglund F, Kalamchi A, Poon R, et al: Congenital hip dislocation and dysplasia in southern Chinese. *Int Orthop* 1981;4:243.
80. Hogh J, MacNicol M: The Chiari pelvic osteotomy: a long-term review of clinical and radiographic results. *J Bone Joint Surg* 1987;69-B:365.
81. Hummer C, MacEwen G: The coexistence of torticollis and congenital dysplasia of the hip. *J Bone Joint Surg* 1972;54-A:1255.
82. Idleberger K: The Genetic Pathology of So-called CDH. Munich, Urban & Schwarzenberg, 1951.
83. Ilfeld F, Westin G, Makin M: Developmental dislocation of the hip. *Clin Orthop* 1982;164:234.
84. Ishi Y, Weinstein S, Ponseti I: Correlation between arthrograms and operative findings in congenital dislocation of the hip. *Clin Orthop* 1980;153:138.
85. Iverson I, Kalea V, Eberle C: Relative trochanteric overgrowth after ischemic necrosis in congenital dislocation of the hip. *J Pediatr Orthop* 1989;9:391.
86. Iwahara T, Ikeda A: The ipsilateral involvement of congenital muscular torticollis and congenital dislocation of the hip. *J Jpn Orthop Assoc* 1962;35:1221.
87. Iwasake K: Treatment of congenital dislocation of the hip by Pavlik harness. *J Bone Joint Surg* 1983;65-A:760.
88. Jensen B, Reimann I, Fredensborg N: Collagen type III predominance in newborns with congenital dislocation of the hip. *Acta Orthop Scand* 1986;57:362.
89. Jones D: An assessment of the value of examination of the hip in the newborn. *J Bone Joint Surg* 1977;59-B:318.
90. Jones G, Schoenecker P, Dias L: Developmental hip dysplasia potentiated by inappropriate use of the Pavlik harness. *J Pediatr Orthop* 1992;12:722.
91. Joseph K, MacEwen G, Boos M: Home traction in the management of congenital dislocation of the hip. *Clin Orthop* 1982;165:83.
92. Kahle W, Anderson M, Alpert J, et al: The value of preliminary traction in the treatment of congenital dislocation of the hip. *J Bone Joint Surg* 1990;72-A:1043.
93. Kalamchi A: A modified Salter osteotomy. *J Bone Joint Surg* 1982; 64-A:183.
94. Kalamchi A, MacEwen G: Avascular necrosis following treatment of congenital dislocation of the hip. *J Bone Joint Surg* 1980;62-A:876.
95. Kalamchi A, Schmidt T, MacEwen G: Congenital dislocation of the hip: open reduction by the medial approach. *Clin Orthop* 1982; 169:127.
96. Kashiwagi N, Suzuki S, Kasahara Y, et al: Prediction of reduction in developmental dysplasia of the hip by magnetic resonance imaging. *J Pediatr Orthop* 1996;16:254.
97. Kasser J, Bowen J, MacEwen G: Varus derotation osteotomy in the treatment of persistent dysplasia of the hip. *J Bone Joint Surg* 1985; 67-A:195.
98. Kelikian A, Tachdjian M, Askew M: Greater trochanteric advancement of the proximal femur: a clinical and biomechanical study. In Hungerford D (ed): *The Hip: Proceedings of the 11th Scientific Meeting of the Hip Society*, p 77. St. Louis, CV Mosby Co, 1983.
99. Keller M, Weltin G, Rattner Z, et al: Normal instability of the hip in the neonate: US standards. *Radiology* 1988;169:733.
100. Kepley R, Weiner D: Treatment of congenital dysplasia-subluxation of the hip in children under one year of age. *J Pediatr Orthop* 1981;1:413.
101. Klaue K, Sherman M, Perren S: Extra-articular augmentation for residual hip dysplasia. *J Bone Joint Surg* 1993;75-B:750.
102. Kleinberg S, Lieberman H: The acetabular index in infants in relation to congenital dislocation of the hip. *Arch Surg* 1936;32:1049.
103. Klisic P: Congenital dislocation of the hip: a misleading term. *J Bone Joint Surg* 1989;71-B:136.
104. Klisic P: Open reduction with femoral shortening and pelvic osteotomy. In Tachdjian M (ed): *Congenital Dislocation of the Hip*, p 417. New York, Churchill Livingstone, 1982.
105. Klisic P, Jankovic L: Combined procedure of open reduction and shortening of the femur in treatment of congenital dislocation of the hips in older children. *Clin Orthop* 1976;119:60.
106. Klisic P, Jankovic L, Basara V: Long-term results of combined operative reduction of the hip in older children. *J Pediatr Orthop* 1988;8:532.
107. Klisic P, Zivanovic P, Brdar R: Prevention of CDH, stimulated by distribution of baby packages. *J Pediatr Orthop* 1988;8:9.
108. Koizumi W, Moriya H, Tsuchiya K, et al: Ludloff's medial approach for open reduction of congenital dislocation of the hip: a 20-year follow-up. *J Bone Joint Surg* 1996;78-B:924.
109. Kramer J, Schleberger R, Steffen R: Closed reduction by two-phase skin traction and functional splinting in mitigated abduction for treatment of congenital dislocation of the hip. *Clin Orthop* 1990; 258:27.
110. Kruczynski J: Avascular necrosis after nonoperative treatment of developmental hip dislocation: prognosis in 36 patients followed 17–26 years. *Acta Orthop Scand* 1995;66:239.
111. Kruczynski J: Avascular necrosis of the proximal femur in developmental dislocation of the hip: incidence, risk factors, sequelae and MR imaging for diagnosis and prognosis. *Acta Orthop Scand* 1996;268(suppl):1.
112. Kumar S, MacEwen G: The incidence of hip dysplasia with metatarsus adductus. *Clin Orthop* 1982;164:234.
113. Kutlu A, Memik R, Mutlu M: Congenital dislocation of the hip and its relation to swaddling used in Turkey. *J Pediatr Orthop* 1992;12:598.
114. Lack W, Windhager R, Kutschera H, et al: Chiari pelvic osteotomy for osteoarthritis secondary to hip dysplasia. *J Bone Joint Surg* 1991;73-B:229.
115. Langenskiöld A, Salenius P: Epiphysiodesis of the greater trochanter. *Acta Orthop Scand* 1967;38:199.
116. Laurensen R: The acetabular index: a critical review. *J Bone Joint Surg* 1959;41-B:702.
117. Laurensen R: Development of the acetabular roof in the fetal hip. *J Bone Joint Surg* 1965;47-A:975.
118. LeDamany P: La cavité cotyloïde. In Alcan F (ed): *La Luxation congénitale de la Hanche*, p 187. Paris, 1912.
119. LeDamany P: Congenital luxation of the hip. *Am J Orthop Surg* 1914;11:541.
120. Lehman W, Grant A, Nelson J: Hospital for Joint Diseases' traction system for preliminary treatment of congenital dislocation of the hip. *J Pediatr Orthop* 1983;3:104.
121. Lehman WL, Grogan DP: Innominate osteotomy and varus derotation osteotomy in the treatment of congenital dislocation of the hip. *Orthopedics* 1985;8:979.
122. Leunig M, Werlen S, Ungersbock A, et al: Evaluation of the acetabular labrum by MR arthrography. *J Bone Joint Surg* 1977;79-B:230.
123. Leveuf J: Primary congenital subluxation of the hip. *J Bone Joint Surg* 1947;29-A:149.
124. Leveuf J: Results of open reduction of "true" congenital luxation of the hip. *J Bone Joint Surg* 1948;30-A:875.
125. Lindstrom J, Ponseti I, Wenger D: Acetabular development after reduction in congenital dislocation of the hip. *J Bone Joint Surg* 1979;61-A:112.
126. Lloyd-Roberts G: Osteoarthritis of the hip: a study of the clinical pathology. *J Bone Joint Surg* 1955;37-B:8.
127. Lloyd-Roberts G, Lettin A: Arthrogyposis multiplex congenita. *J Bone Joint Surg* 1970;52-B:494.
128. Lloyd-Roberts G, Swann M: Pitfalls in the management of congenital dislocation of the hip. *J Bone Joint Surg* 1966;48-B:666.
129. Lloyd-Roberts GC, Wetherill MH, Fraser M: Trochanteric advancement for premature arrest of the femoral capital growth plate. *J Bone Joint Surg* 1985;67-B:21.

130. Lorenz A: *My Life and Work*. New York, Charles Scribner & Sons, 1936.
131. Ludloff K: The open reduction of the congenital hip dislocation by an anterior incision. *Am J Orthop Surg* 1913;10:438.
132. MacNicol M, Makris D: Distal transfer of the greater trochanter. *J Bone Joint Surg* 1991;73-B:838.
133. Malvitz T, Weinstein S: Closed reduction for congenital dysplasia of the hip. Functional and radiographic results after an average of thirty years. *J Bone Joint Surg* 1994;76-A:1777.
134. Mankey M, Arntz C, Staheli L: Open reduction through a medial approach for congenital dislocation of the hip: a critical review of the Ludloff approach in sixty-six hips. *J Bone Joint Surg* 1993;75-A:1334.
135. Mau H, Doz D, Dorr W, et al: Open reduction of congenital dislocation of the hip by Ludloff's method. *J Bone Joint Surg* 1971;53-A:1281.
136. McCluskey W, Basset G, Mora-Garcia G, et al: Failed open reduction for congenital hip dislocation. Paper presented at a meeting of Am Acad Orthop Surg, Atlanta, 1988.
137. McCluskey W, Basset G, Mora-Garcia G, et al: Treatment of failed open reduction for congenital dislocation of the hip. *J Pediatr Orthop* 1989;9:633.
138. McEvoy A, Paton RW: Ultrasound compared with radiographic assessment in developmental dysplasia of the hip. *J R Coll Surg Edinb* 1997;42:254.
139. McKibbin B: Anatomical factors in the stability of the hip in the newborn. *J Bone Joint Surg* 1970;52-B:148.
140. Michelson J, Langenskiöld A: Dislocation or subluxation of the hip: regular sequela of immobilization of the knee in extension of young rabbits. *J Bone Joint Surg* 1972;54-A:1177.
141. Milgram J: Morphology of untreated bilateral congenital dislocation of the hips in a seventy-four year-old man. *Clin Orthop* 1976;119:112.
142. Millis M, Kaelin A, Schluntz K: Spherical acetabular osteotomy for treatment of acetabular dysplasia in adolescents and young adults. *J Pediatr Orthop B* 1994;3:47.
143. Miranda L, Palomo J, Monzonis A, et al: Prevention of congenital dislocation of the hip in the newborn. *J Pediatr Orthop* 1988;8:671.
144. Monticelli G: Intertrochanteric femoral osteotomy with concentric reduction of the femoral head in treatment of residual congenital acetabular dysplasia. *Clin Orthop* 1976;119:48.
145. Morcuende JA, Meyer MD, Dolan LA, et al: Long-term outcome after open reduction through an anteromedial approach for congenital dislocation of the hip. *J Bone Joint Surg* 1997;79-A:810.
146. Morel G: The treatment of congenital dislocation and subluxation of the hip in the older child. *Acta Orthop Scand* 1975;46:364.
147. Morscher E: Our experience with Salter's innominate osteotomy in the treatment of hip dysplasia. In Weil U (ed): *Progress in Orthopedic Surg. Vol 2. Acetabular Dysplasia and Skeletal Dysplasia in Childhood*, p 107. New York, Springer-Verlag, 1978.
148. Morville P: On the anatomy and pathology of the hip joint. *Acta Orthop Scand* 1936;7:107.
149. Mubarak S, Garfin S, Vance R, et al: Pitfalls in the use of the Pavlik harness for treatment of congenital dysplasia, subluxation, and dislocation of the hip. *J Bone Joint Surg* 1981;63-A:1239.
150. Muller G, Seddon H: Later results of treatment of congenital dislocation of the hip. *J Bone Joint Surg* 1953;35-A:342.
151. Murphy A, Ganz R, Muller M: The prognosis in untreated dysplasia of the hip: a study of radiographic factors that predict the outcome. *J Bone Joint Surg* 1995;77-A:985.
152. Murray R: The aetiology of primary osteoarthritis of the hip. *Br J Radiol* 1965;38:810.
153. Nishiyama K, Sakamaki T, Okinaga A: Complications of Pemberton's pericapsular osteotomy: a report of two cases. *Clin Orthop* 1990; 254:205.
154. O'Brien T: Growth-disturbance lines in congenital dislocation of the hip. *J Bone Joint Surg* 1985;67-A:626.
155. O'Hara J, Bernard A, Dwyer N: Early results of medial approach open reduction in congenital dislocation of the hip: use before walking age. *J Pediatr Orthop* 1988;8:288.
156. Ortolani M: Congenital hip dysplasia in the light of early and very early diagnosis. *Clin Orthop* 1976;119:6.
157. Ortolani M: *La Lussazione Congenita dell'Anca: Nouvi Criteri Diagnostici Profilattico Corretivi*. Bologna, Cappelli, 1948.
158. Ortolani M: Un segno poco noto e sue importanza per la diagnosi precoce di preussazione congenita dell'anca. *Pediatria* 1937;45:129.
159. Osborne D, Effmann E, Broda K, et al: The development of the upper end of the femur with special reference to its internal architecture. *Radiology* 1980;137:71.
160. Paton R, Srinivasan M, Shah B, et al: Ultrasound screening for hips at risk in developmental dysplasia: is it worth it? *J Bone Joint Surg* 1999;81-B:255.
161. Pauwels F: *Gesammelte Abhandlungen zur funktionellen Anatomie des Bewegungsapparates*. New York, Springer-Verlag, 1965.
162. Pavlik A: Stirrups as an aid in the treatment of congenital dysplasias of the hip in children. *J Pediatr Orthop* 1989;9:157.
163. Pemberton A: Pericapsular osteotomy of the ilium for treatment of congenital subluxation and dislocation of the hip. *J Bone Joint Surg* 1965;87-A:65.
164. Ponseti I: Growth and development of the acetabulum in the normal child. *J Bone Joint Surg* 1978;60-A:575.
165. Ponseti I: Morphology of the acetabulum in congenital dislocation of the hip: gross, histological and roentgenographic studies. *J Bone Joint Surg* 1978;60-A:586.
166. Pratt W, Freiburger R, Arnold W: Untreated congenital hip dysplasia in the Navajo. *Clin Orthop* 1982;162:69.
167. Putti V: Perla cura precoce della lussazione congenita dell'anca. *Arch Ital Chir* 1927;18:653.
168. Quinn RH, Renshaw TS, DeLuca PA: Preliminary traction in the treatment of developmental dislocation of the hip. *J Pediatr Orthop* 1994;14:636.
169. Race C, Herring J: Congenital dislocation of the hip: an evaluation of closed reduction. *J Pediatr Orthop* 1983;3:166.
170. Ralis Z, McKibbin B: Changes in the shape of the human hip joint during its development and their relation to its stability. *J Bone Joint Surg* 1973;55-B:780.
171. Ramsey P, Lasser S, MacEwen G: Congenital dislocation of the hip. *J Bone Joint Surg* 1976;58-A:1000.
172. Renshaw T: Inadequate reduction of congenital dislocation of the hip. *J Bone Joint Surg* 1981;63-A:1114.
173. Robinson R: Effective screening in child health. *Br Med J* 1998;316:1.
174. Rombouts J, Kaelin A: Inferior (obturator) dislocation of the hip in neonates: a complication of treatment by the Pavlik harness. *J Bone Joint Surg* 1992;74-B:708.
175. Rosen SV: Diagnosis and treatment of congenital dislocation of the hip joint in the newborn. *J Bone Joint Surg* 1962;44-B:284.
176. Rosendahl K, Markestad T, Lie R: Developmental dysplasia of the hip: a population-based comparison of ultrasound and clinical findings. *Acta Pediatr* 1996;85:64.
177. Rosendahl K, Markestad T, Lie RT: Ultrasound screening for developmental dysplasia of the hip in the neonate: the effect on treatment rate and prevalence of late cases. *Pediatrics* 1994;94:47.
178. Sahlstrand T, Malmgren N, Ahlgren S, et al: Management of neonatal hip instability: an analysis of the efficiency of a consistent treatment program. *J Pediatr Orthop* 1985;5:540.
179. Sainton R: *De l'anatomie de l'articulation de la hanche chez l'enfant et de la luxation congenitale de cette articulation*. These de Paris, No. 226. Paris, 1912.
180. Salter R: Innominate osteotomy in the management of residual congenital subluxation and dislocation of the hip in young adults. *Clin Orthop* 1984;182:53.
181. Salter R: Innominate osteotomy in the treatment of congenital dislocation and subluxation of the hip. *J Bone Joint Surg* 1961;43-B:72.
182. Salter R: Role of innominate osteotomy in the treatment of congenital dislocation and subluxation of the hip in the older child. *J Bone Joint Surg* 1966;48-A:1413.
183. Salter R, Dubois J: The first fifteen years' personal experience with innominate osteotomy in the treatment of congenital dislocation and subluxation of the hip. *Clin Orthop* 1974;98:72.
184. Salter R, Kostiuik J, Dallas S: Avascular necrosis of the femoral head as a complication of treatment for congenital dislocation of the hip in young children: a clinical and experimental investigation. *Can J Surg* 1969;12:44.
185. Schoenecker P, Strecker W: Congenital dislocation of the hip in children: comparison of the effects of femoral shortening and of skeletal traction in treatment. *J Bone Joint Surg* 1984;66-A:21.
186. Schofield C, Smibert J: Trochanteric growth disturbance after upper femoral osteotomy for congenital dislocation of the hip. *J Bone Joint Surg* 1990;72-B:32.
187. Severin E: Contribution to the knowledge of congenital dislocation of the hip joint. *Acta Chir Scand* 1941;84(suppl):1.

188. Severin E: Frekvensen av luxatio coxae congenita och pes equinovarus congenitus Sverige. *Nord Med* 1956;55:221.
189. Siffert R: Patterns of deformity of the developing hip. *Clin Orthop* 1981;160:14.
190. Smith JT, Matan A, Coleman SS, et al: The predictive value of the development of the acetabular teardrop figure in developmental dysplasia of the hip. *J Pediatr Orthop* 1997;17:165.
191. Smith W, Coleman C, Olix M, et al: Etiology of congenital dislocation of the hip: an experimental approach to the problem using young dogs. *J Bone Joint Surg* 1963;45-A:491.
192. Sochart D, Paton R: Role of ultrasound assessment and harness treatment in the management of developmental dysplasia of the hip. *Ann R Coll Surg Engl* 1996;78:505.
193. Soloman L: Patterns of osteoarthritis of the hip. *J Bone Joint Surg* 1976;58-B:176.
194. Somerville E: Congenital dislocation of the hip: the fate of the well-developed acetabulum. *Isr J Med Sci* 1980;16:338.
195. Sosna A, Rejholec M: Ludloff's open reduction of the hip: long-term results. *J Pediatr Orthop* 1992;12:603.
196. Staheli L, Chew D: Slotted acetabular augmentation in childhood and adolescence. *J Pediatr Orthop* 1992;12:569.
197. Staheli L, Dion M, Tuell J: The effect of the inverted limbus on closed management of congenital hip dislocation. *Clin Orthop* 1978;137:163.
198. Steel H: Triple osteotomy of the innominate bone. *J Bone Joint Surg* 1973;55-A:343.
199. Steel H: Triple osteotomy of the innominate bone. *Clin Orthop* 1977;122:116.
200. Strayer L: Embryology of the human hip joint. *Yale J Biol Med* 1943;16:13.
201. Strayer L: Embryology of the human hip joint. *Clin Orthop* 1971;74:221.
202. Sutherland D, Moore M: Clinical and radiographic outcome of patients treated with double innominate osteotomy for congenital hip dysplasia. *J Pediatr Orthop* 1991;11:143.
203. Suzuki S: Deformity of the pelvis in developmental dysplasia of the hip: three-dimensional evaluation by means of magnetic resonance image. *J Pediatr Orthop* 1995;15:812.
204. Suzuki S, Yamamuro T: Avascular necrosis in patients with the Pavlik harness for congenital dislocation of the hip. *J Bone Joint Surg* 1990;71-A:1048.
205. Suzuki S, Yamamuro T: Correlation of fetal posture and congenital dislocation of the hip. *Acta Orthop Scand* 1986;57:81.
206. Synder M, Zwierzchowski H: One-stage hip reconstruction with De-ga's transiliac osteotomy in the treatment of congenital hip dislocation in children. *Beitr Orthop Traumatol* 1990;37:571.
207. Szoke G, Staheli L, Jaffe K, et al: Medial-approach open reduction of hip dislocation in amyoplasia-type arthrogyposis. *J Pediatr Orthop* 1996;16:127.
208. Tachdjian M, Kelikian A: Distal and lateral advancement of the greater trochanter. In Tachdjian M (ed): *Congenital Dislocation of the Hip*, p 721. New York, Churchill Livingstone, 1982.
209. Tavares J, Gottwald D, Rochelle J: Guided abduction traction in the treatment of congenital hip dislocation. *J Pediatr Orthop* 1994;14:643.
210. Terjesen T, Bredland T, Berg V: Ultrasound for hip assessment in the newborn. *J Bone Joint Surg* 1989;71-B:767.
211. Tonnis D: *Congenital Dysplasia and Dislocation of the Hip in Children and Adults*. New York, Springer Verlag, 1987.
212. Tonnis D: Investigation of the cause of frequency of avascular necrosis in different closed reductions, primary and secondary reductions of CDH. Presented at the 14th World Congress of the Societe Internationale de Chirurgie Orthopedique et de Traumatologie, Japan, 1978.
213. Tonnis D: A modified technique of the triple pelvic osteotomy: early results. *J Pediatr Orthop* 1981;1:241.
214. Tonnis D: Surgical treatment of congenital dislocation of the hip. *Clin Orthop* 1990;258:33.
215. Tonnis D: Triple pelvic osteotomy. *J Pediatr Orthop B* 1994;3:54.
216. Tonnis D, Storch K, Ulbrich H: Results of newborn screening for CHD with and without sonography and correlation with risk factors. *J Pediatr Orthop* 1990;8:12.
217. Trousdale R: Fetal hydantoin syndrome: an unusual cause of hip dysplasia. *Orthopedics* 1998;21:212.
218. Tucci J, Kumar S, Guille J, et al: Late acetabular dysplasia following early successful Pavlik treatment. *J Pediatr Orthop* 1991;11:502.
219. Utterback T, MacEwen G: Comparison of pelvic osteotomies for the surgical correction of the congenital hip. *Clin Orthop* 1974;98:104.
220. Vendantam R, Bell MJ: Dynamic ultrasound assessment for monitoring of treatment of congenital dislocation of the hip. *J Pediatr Orthop* 1995;15:725.
221. Viere R, Birch J, Herring J, et al: Use of the Pavlik harness in congenital dislocation of the hip. *J Bone Joint Surg* 1990;72-A:238.
222. Visser J: Functional treatment of congenital dislocation of the hip. *Acta Orthop Scand* 1984;206(suppl):1.
223. Von Rosen S: Early diagnosis and treatment of congenital dislocation of the hip joint. *Acta Orthop Scand* 1956;26:136.
224. Wagner H: Femoral osteotomies for congenital hip dislocation. In Weil UH (ed): *Progress in Orthopedic Surgery*. Vol 2. *Acetabular Dysplasia and Skeletal Dysplasia in Childhood*, p 85. New York, Springer-Verlag, 1978.
225. Wagner H: Spherical Acetabular Osteotomy: Long-Term Results. Fourth Harvard Medical School Course on Osteotomy of the Hip and Knees. Boston, Harvard University Press, 1992.
226. Wagner H (ed): *The Hip: Proceedings of the 4th Open Scientific Meeting of the Hip Society*. St. Louis, CV Mosby Co, 1976.
227. Walker G: Problems in the early recognition of congenital hip dislocation. *Br Med J* 1971;3:147.
228. Walker J: A preliminary investigation of congenital hip disease in the Island Lake Reserve population, Manitoba, Winnipeg, University of Manitoba, Department of Anthropology, 1973.
229. Ward W, Voght M, Grudziak J, et al: Severin classification system for evaluation of the results of operative treatment of congenital dislocation of the hip. *J Bone Joint Surg* 1997;77-A:656.
230. Watanabe R: Embryology of the human hip. *Clin Orthop* 1974;98:8.
231. Wedge J, Wasylenko M: The natural history of congenital dislocation of the hip: a critical review. *Clin Orthop* 1978;137:154.
232. Wedge J, Wasylenko M: The natural history of congenital disease of the hip. *J Bone Joint Surg* 1979;61-B:334.
233. Weiner D, Hoyt WJ, Odell H: Congenital dislocation of the hip: the relationship of premanipulation traction and age to avascular necrosis of the femoral head. *J Bone Joint Surg* 1977;59-A:306.
234. Weinstein S: Anteromedial approach to reduction for congenital hip dysplasia. *Strategies Orthop Surg* 1987;6:2.
235. Weinstein S: Closed versus open reduction of congenital hip dislocation in patients under 2 years of age. *Orthopedics* 1990;13:221.
236. Weinstein S: Congenital hip dislocation: long-range problems, residual signs, and symptoms after successful treatment. *Clin Orthop* 1992;281:69.
237. Weinstein S: Developmental hip dysplasia and dislocation. In Morrissy R, Weinstein S (eds): *Lovell and Winter's Pediatric Orthopaedics*, vol 2, p 927. New York, Lippincott-Raven, 1996.
238. Weinstein S: Natural history of congenital dislocation of the hip. *Clin Orthop* 1987;225:62.
239. Weinstein S, Ponseti I: Congenital dislocation of the hip. *J Bone Joint Surg* 1979;61-A:119.
240. Weinstein S, Ponseti I: Congenital dislocation of the hip: open reduction through a medial approach. *J Bone Joint Surg* 1979;61:119.
241. Weinstein SL: Traction in developmental dislocation of the hip: is its use justified? *Clin Orthop* 1997;79:338.
242. Wenger D: Congenital hip dislocation: techniques for primary open reduction including femoral shortening. *Instr Course Lect* 1989;38:343.
243. Wiberg G: Studies on dysplastic acetabula and congenital subluxation of the hip joint. *Acta Chir Scand* 1939;35:65.
244. Wilkinson J: The epidemiology of congenital dislocation of the hip. *Curr Orthop* 1987;1:249.
245. Wilkinson J: Prime factors in the etiology of congenital dislocation of the hip. *J Bone Joint Surg* 1963;45-B:268.
246. Williams P: The management of arthrogyposis. *Orthop Clin North Am* 1978;9:67.
247. Windhager R, Pongracz N, Schonecker W, et al: Chiari osteotomy for congenital dislocation and subluxation of the hip: results after 20 to 34 years follow-up. *J Bone Joint Surg* 1991;73-B:890.
248. Wynne-Davies R: Acetabular dysplasia and familial joint laxity: two aetiological factors in congenital dislocation of the hip. *J Bone Joint Surg* 1970;52-B:704.
249. Yamamuro T, Doi H: Diagnosis and treatment of congenital dislocation of the hip in newborns. *J Jpn Orthop Assoc* 1965;39:492.
250. Yousefzadek D, Ramilo J: Normal hip in children: correlation of US with anatomic and cryomicrotome sections. *Radiology* 1987;165:647.
251. Zions L, MacEwen G: Treatment of congenital dislocation of the hip in children between the ages of one and three years. *J Bone Joint Surg* 1986;68-A:829.