

Principles of Tooth Preparation

Nisha Garg

CHAPTER OUTLINE

- Introduction
- Purpose of Tooth Preparation
- Classification
- Definitions
- Number of Line and Point Angles
- Steps
- Initial Stage
- Final Stage
- Viva Questions

INTRODUCTION

Tooth preparation is the mechanical alteration of a defective, injured or diseased tooth in order to best receive a restorative material which will re-establish the healthy state of the tooth including esthetic correction when indicated along with normal form and function.

PURPOSE OF TOOTH PREPARATION

Earlier when the affected tooth was prepared because of caries, cutting of tooth was referred to as cavity preparation. But nowadays many indications other than caries lead to preparation of the tooth. Hence, the term cavity preparation has been replaced by tooth preparation. Tooth preparation is done for:

- Treatment of carious teeth
- Treatment of malformed, fractured or traumatized teeth
- Replacement of old, defective restorations
- Esthetic improvement for discolored and unesthetic teeth.

CLASSIFICATION

Tooth preparation is classified according to location of the tooth defect (**Fig. 8.1**).

Class I is the only pit and fissure preparation whereas rest are smooth surface preparations.

- **Class I:** Pit and fissure preparations occur on the occlusal surfaces of premolars and molars, the occlusal two-third of buccal and lingual surface of molars and lingual surface of incisors (**Figs 8.2A and B**)
- **Class II:** Preparations on the proximal surface of premolars and molars are class II (**Figs 8.3A and B**)
- **Class III:** Preparations on the proximal surface of anterior teeth and not involving the incisal angles are class III (**Figs 8.4A and B**)
- **Class IV:** Preparations on the proximal surface of anterior teeth also involving the incisal angle falls under class IV (**Figs 8.5A and B**)
- **Class V:** Preparations on gingival third of facial and lingual or palatal surfaces of all teeth came under Class V (**Figs 8.6A and B**)

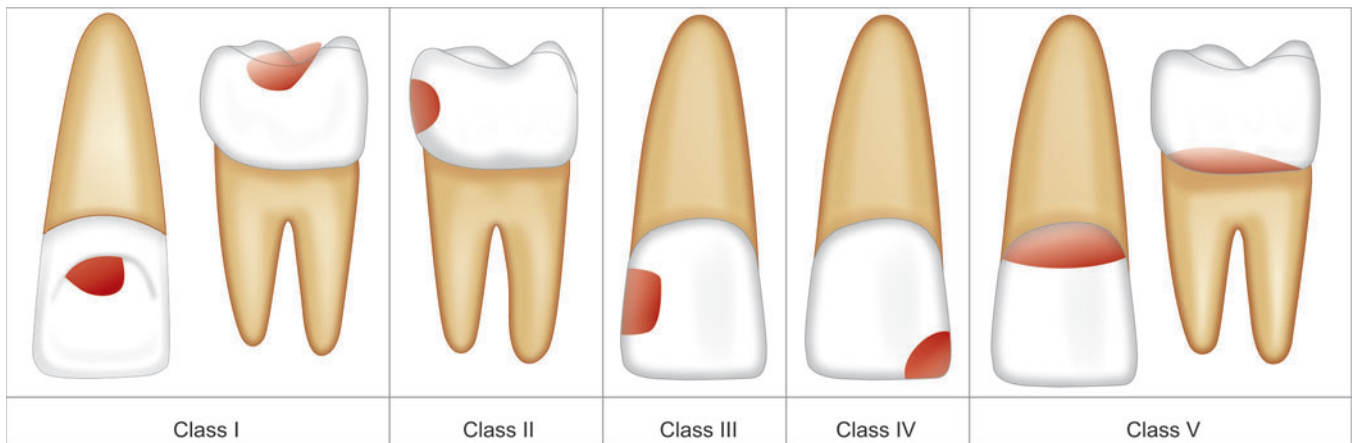
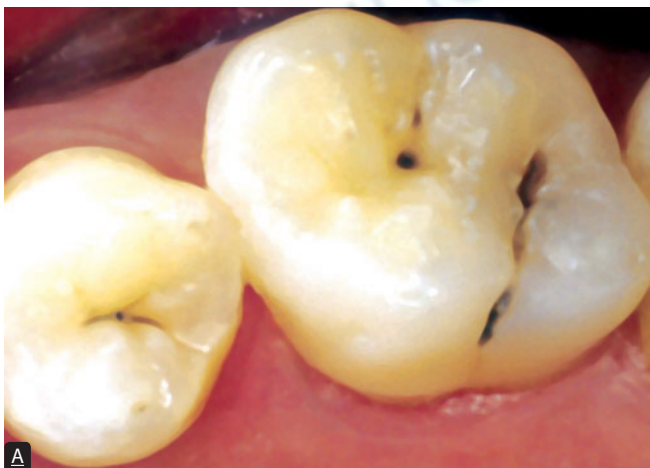
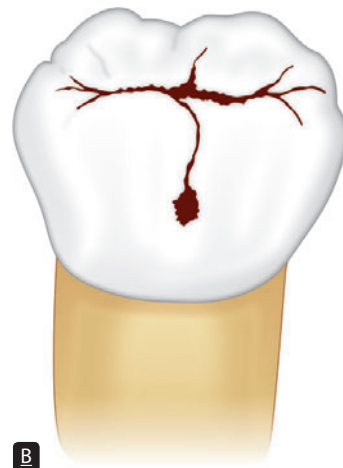
Figure 8.1: Schematic representation showing GV Black's classification of dental caries

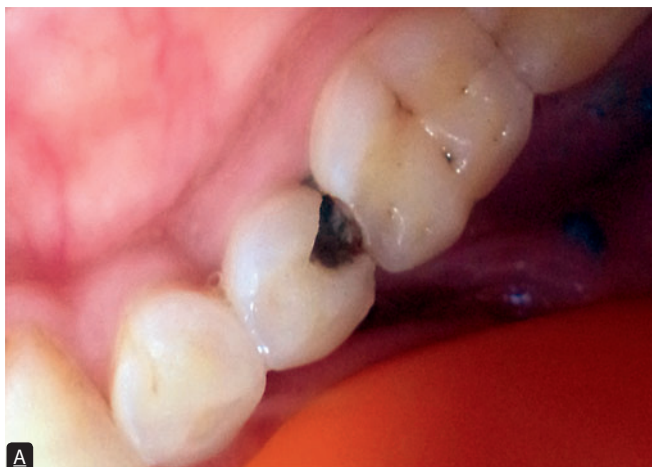

A

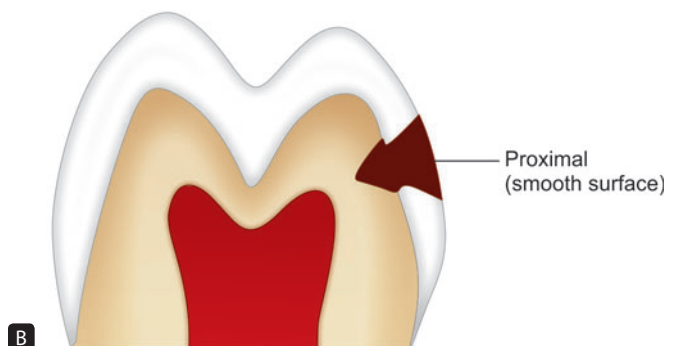


B

Figures 8.2A and B: (A) Clinical picture of class I lesion; (B) Schematic representation of class I lesion showing caries on occlusal surface of molars and premolars, lingual surface of incisors and occlusal third of buccal and lingual surface of molars

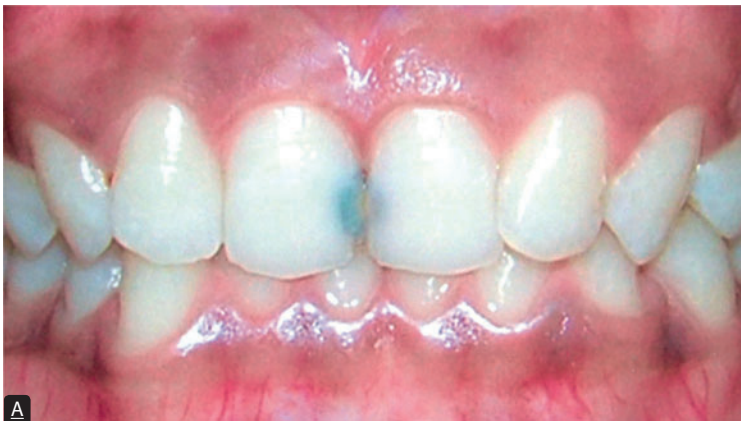

A

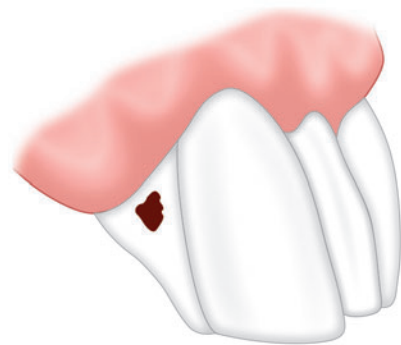


B

Figures 8.3A and B: (A) Clinical picture of Class II lesion; (B) Schematic representation of Class II lesion

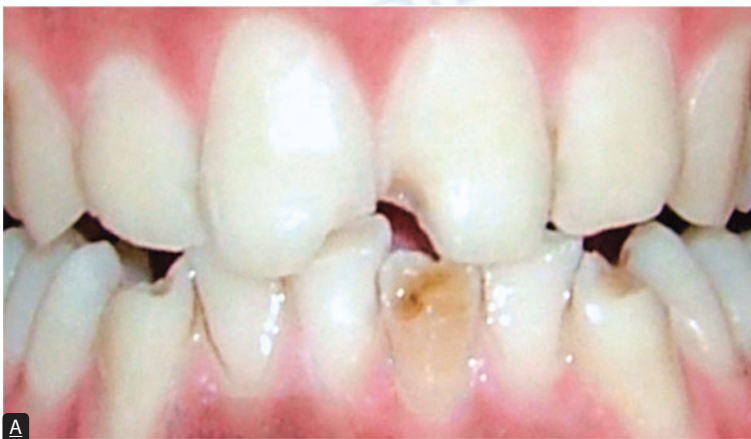

A




B

Figures 8.4A and B: (A) Clinical picture of Class III lesion; (B) Schematic representation of Class III lesion

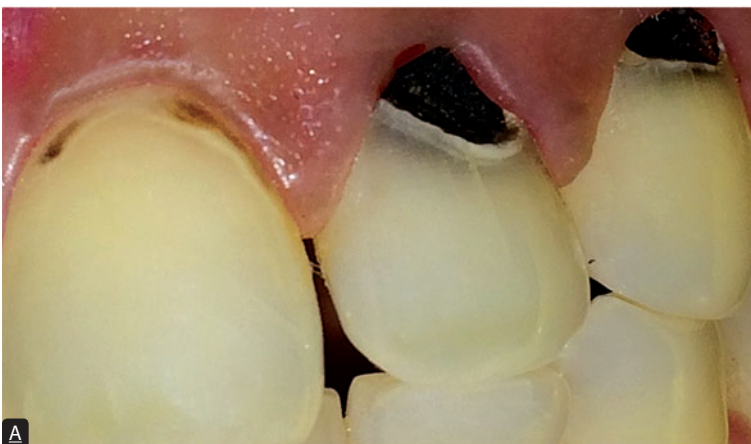

A

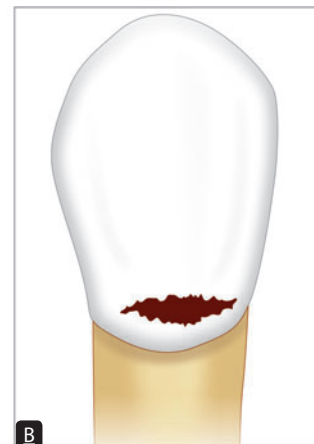

B

Figures 8.5A and B: (A) Clinical picture of Class IV lesion; (B) Schematic representation of Class IV lesion



A



B

Figures 8.6A and B: (A) Clinical picture of Class V lesion; (B) Schematic representation of Class V lesion

Modification of Black's classification was made to provide more specific localization of preparations

- **Class II:** Preparations on the single or both proximal surface of premolar and molar teeth. When there is involvement of both proximal surfaces, it is called mesio-occlusodistal (MOD) preparation (**Fig. 8.7**)
- **Class VI:** Preparations on incisal edges of anterior and cusp tips of posterior teeth without involving any other surface (**Figs 8.8A and B**) come under Class VI.

DEFINITIONS

Simple Tooth Preparation

A tooth preparation involving only one tooth surface is termed simple preparation (**Fig. 8.9**), for example, occlusal preparation.

Compound Tooth Preparation

A tooth preparation involving two surfaces is termed as compound tooth preparation (**Fig. 8.10**), for example, mesio-occlusal or disto-occlusal preparation.

Complex Tooth Preparation

A tooth preparation involving more than two surfaces is called as complex tooth preparation (**Fig. 8.11**), for example, MOD preparation.

For communication and records purpose, surface of tooth preparation is abbreviated by using first letter, capitalized.

For example

- Preparation on occlusal surface as "O"
- Preparation on distal and occlusal surfaces as "DO"
- Preparation on mesial, occlusal and distal surfaces as "MOD."

Walls

Internal Wall

It is a wall in the preparation, which is not extended to the external tooth surface (**Fig. 8.12**).

External Wall

An external wall is a wall in the prepared tooth that extends to the external tooth surface (**Fig. 8.13**). External wall takes the name of the tooth surface towards which it is situated.

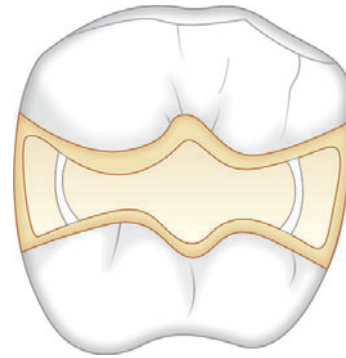
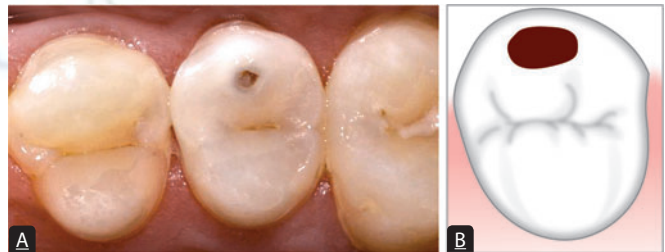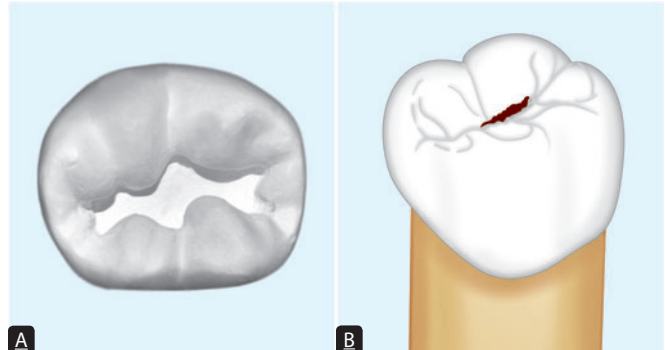


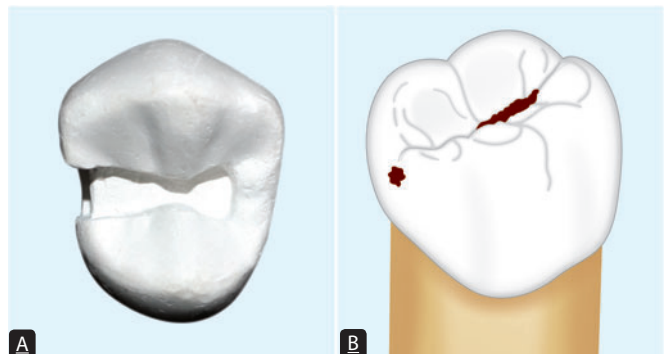
Figure 8.7: Schematic representation of MOD preparation



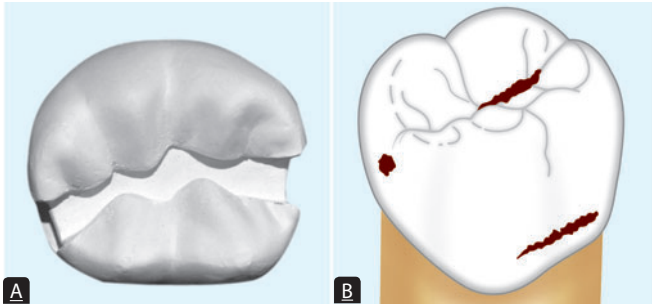
Figures 8.8A and B: (A) Clinical picture of Class VI lesion; (B) Schematic representation of class VI lesion



Figures 8.9A and B: Photograph and schematic representation showing simple tooth preparation involving one tooth surface only



Figures 8.10A and B: Photograph and schematic representation showing compound tooth preparation involving two surfaces



Figures 8.11A and B: Photograph and schematic representation showing complex tooth preparation involving more than two surfaces

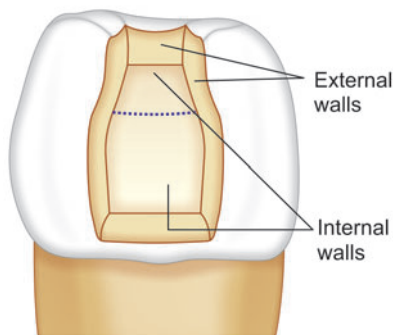


Figure 8.12: Schematic representation of internal and external wall of tooth preparation

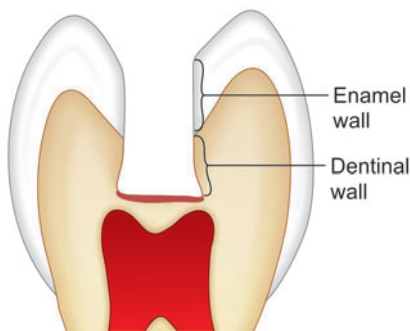


Figure 8.13: Schematic representation of external wall of tooth preparation

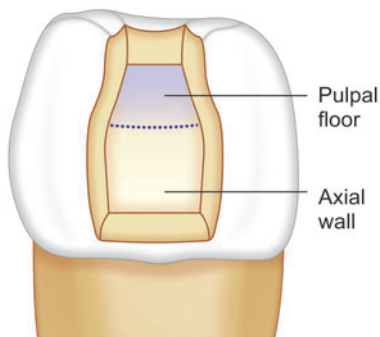


Figure 8.14: Schematic representation of pulpal floor and axial wall

Facts

When two or more surfaces are combined, the -al ending of the prefix word is changed to an -o. The angle formed by lingual and gingival wall is termed as "linguogingival" line angle. An MOD preparation is called mesio-occlusodistal preparation.

Pulpal Wall

A pulpal wall is an internal wall that is towards the pulp and covering the pulp (**Fig. 8.14**). It may be both vertical and perpendicular to the long axis of tooth.

Axial Wall

It is an internal wall which is parallel to the long axis of the tooth (**Fig. 8.15**).

Floor

Floor is a prepared wall which is usually flat and perpendicular to the occlusal forces directed occlusogingivally, for example, pulpal and gingival walls (**Fig. 8.16**).

Cavosurface Angle Margin

Cavosurface angle is formed by the junction of a prepared tooth surface wall and external surface of the tooth (**Fig. 8.17**). The acute junction is referred to as preparation margin or cavosurface margin.

Line Angle

It is a junction of two surfaces of different orientations along the line. Its name is derived from the involved surfaces.

Point Angle

It is a junction of three plane surfaces or three line angles of different orientations. Its name is derived from its involved surfaces or line angles.

NUMBER OF LINE AND POINT ANGLES

Number of line angles and point angles in different tooth preparations are enumerated in **Table 8.1**.

Line and point angles of class I to class V tooth preparations are enlisted as following.

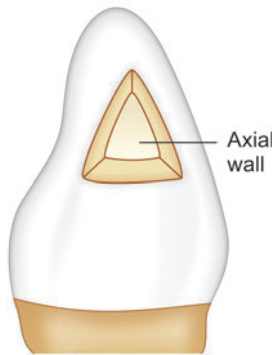


Figure 8.15: Schematic representation showing class III tooth preparation depicting axial wall

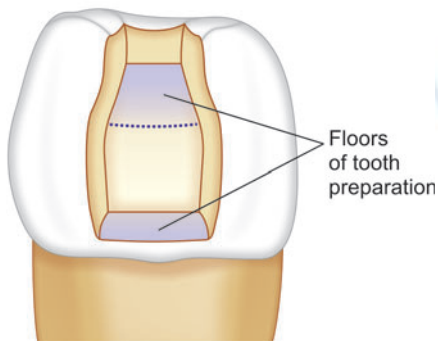


Figure 8.16: Schematic representation showing pulpal and gingival floor of class II preparation

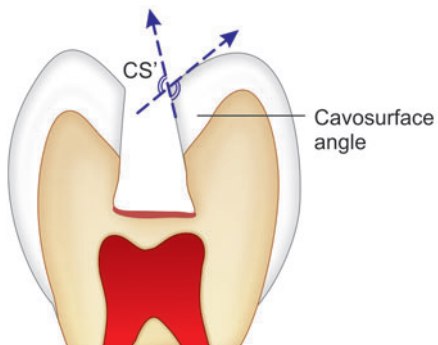


Figure 8.17: Schematic representation showing cavosurface angle is angle formed by junction of prepared tooth surface and external surface of the tooth

Table 8.1 | Number of line angles and point angles in different tooth preparation designs

Type of tooth preparation	Line angles	Point angles
Class I	8	4
Class II	11	6
Class III	6	3
Class IV	11	6
Class V	8	4

Class I Tooth Preparation

For simple class I tooth preparation involving only occlusal surface of molars eight line angles and four point angles are named as follows (**Fig. 8.18**):

Line Angles

- Mesiofacial line angle
- Mesiolingual line angle
- Distofacial line angle
- Distolingual line angle
- Faciopulpal line angle
- Linguopulpal line angle
- Mesiopulpal line angle
- Distopulpal line angle.

Point Angles

- Mesiofaciopulpal point angle
- Mesiolinguopulpal point angle
- Distofaciopulpal point angle
- Distolinguopulpal point angle.

Class II Tooth Preparation

For class II preparation (mesio-occlusal or disto-occlusal) 11 line angles and 6 point angles are as follows (**Fig. 8.19**). The following is the nomenclature for mesio-occlusal tooth preparation.

Line Angles

- Distofacial
- Faciopulpal
- Axiofacial
- Faciogingival
- Axioingival
- Linguogingival
- Axiolingual
- Axio-pulpal
- Distolingual
- Distopulpal
- Linguopulpal.

Point Angles

- Distofaciopulpal point angle
- Axiofaciopulpal point angle
- Axiofaciogingival point angle
- Axiolinguogingival point angle

Line Angles

- Faciogingival
- Linguogingival
- Mesiofacial
- Mesiolingual
- Mesiopulpal
- Faciopulpal
- Linguopulpal
- Axioingival
- Axiolingual
- Axiofacial
- Axiopulpal.

Point Angles

- Axiofaciopulpal point angle
- Axiolinguopulpal point angle
- Axiofaciogingival point angle
- Axiolinguogingival point angle
- Distofaciopulpal point angle
- Distolinguopulpal point angle.

Class V Tooth Preparation

For class V preparation, 8 line angles and 4 point angles are as follows (**Fig. 8.22**):

Line Angles

- Axioingival
- Axioincisal
- Axio mesial
- Axiodistal
- Mesioincisal
- Mesioingival
- Distoincisal
- Distogingival.

Point Angles

- Axiodistogingival point angle
- Axiodistoincisal point angle
- Axio mesioingival point angle
- Axio mesioincisal point angle.

STEPS

For optimal restoration, tooth preparation involves basic mechanical and physical principles which should be followed in an orderly sequence. Tooth preparation is divided into two stages viz; initial and final.

Steps in Tooth Preparation

- **Stage I:** Initial tooth preparation steps
 - Outline form and initial depth
 - Primary resistance form
 - Primary retention form
 - Convenience form.
- **Stage II:** Final tooth preparation steps
 - Removal of any remaining enamel pit or fissure, infected dentin and/or old restorative material, if indicated
 - Pulp protection, if indicated
 - Secondary resistance and retention form
 - Procedures for finishing the external walls of the tooth preparation
 - Final procedures: Cleaning, inspecting and sealing.

Under special conditions these sequences can be changed.

INITIAL STAGE

Outline Form and Initial Depth

Definition

Outline form means:

- Placing the preparation margins in the position they will occupy in the final tooth preparation except for finishing enamel walls and margins
- Maintaining the initial depth of 0.2–0.8 mm into the dentin
- Outline form defines the external boundaries of the preparations.

Outline form includes the external outline form and internal outline form. **External outline form** is established first to extend all margins into sound tooth tissue while maintaining the initial depth of 0.2–0.8 mm into the dentin towards the pulp (**Fig. 8.23**). During tooth preparation, the margins of preparation not only extend into sound tooth tissue but also involve adjacent deep pits and fissures in preparation. This was referred to as 'extension for prevention' by GV Black.

Factors Affecting the Outline and Initial Depth form of Tooth Preparation

- Extension of carious lesion
- Proximity of the lesion to other deep structural surface defects
- Need for esthetics
- Relationship with adjacent and opposing teeth
- Caries index of the patient
- Restorative material to be used.

Principles

- Removal of all weakened and friable tooth structure
- Removal of all undermined enamel (**Fig. 8.24**)
- Place all margins of preparation in a position to afford good finishing of the restoration
- Incorporate all faults in preparation.

Features for Establishing A Proper Outline form

- Preserve cuspal strength
- Preserve strength of marginal ridge
- Minimize the buccolingual extensions
- Limiting the depth of preparation 0.2–0.8 mm into dentin
- If distance between two faults is less than 0.5 mm, connect them
- Do enameloplasty wherever indicated.

Outline form for Pit and Fissure Lesions

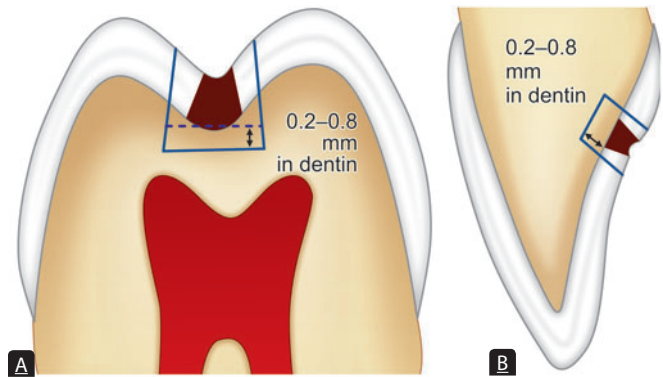
- Remove all defective portion and extend the preparation margins to healthy tooth structure
- Remove all unsupported enamel rods or weakened enamel margins
- If the thickness of enamel between two preparation sites is less than 0.5 mm, connect them to make one preparation, otherwise prepared as separate tooth preparations
- Avoid ending the preparation margins in high stress areas, such as cusp eminences
- Extend the preparation margins to include all pits and fissures which cannot be managed by enameloplasty
- Limit the depth of preparation to 0.2 mm into the dentin, though the actual depth of preparation may vary from 1.5–2 mm depending on steepness of cuspal slopes and thickness of the enamel.

External outline form

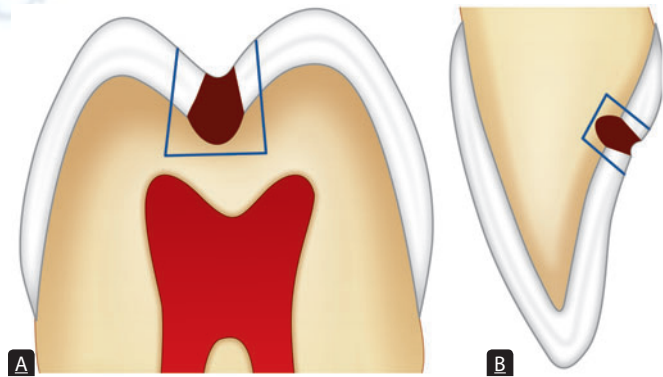
- Consists of smooth curves, straight lines and rounded line and point angles (**Fig. 8.25**)
- Weak unsupported enamel should be removed since it is liable to fracture.

Internal outline form

- It includes the relationship of occlusal walls from cavosurface angle to the pulpal floor
- Preparation depth should be at least 1.5–2.0 mm vertical from the cavosurface margin to the pulpal floor and at least 0.2–0.5 mm in dentin so as to provide adequate strength to resist fracture due to masticatory forces (**Fig. 8.26**).



Figures 8.23A and B: Schematic representation showing initial depth of preparation should be 0.2–0.8 mm into dentin



Figures 8.24A and B: Schematic representation showing removal of all undermined enamel

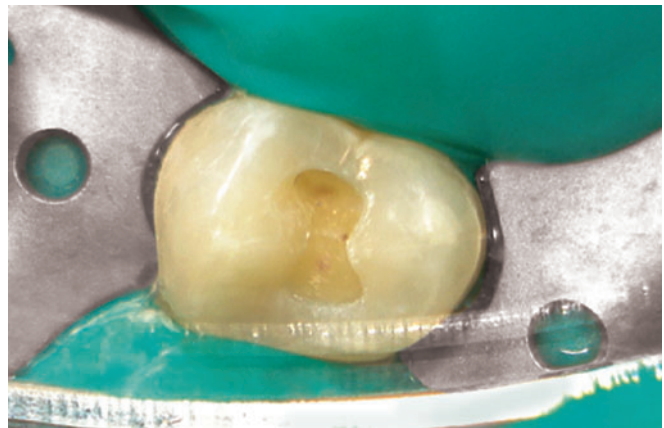

Figure 8.25: Clinical picture showing that outline form should consist of smooth curves, rounded line and point angles

Outline form for Smooth Surface Lesions—Outline form of Proximal Caries (Class II, III and IV lesions)

A class II tooth preparation consists of:

- Occlusal segment
- Proximal segment.

Rules for Making Outline form for Proximal Preparation

- Extend the preparation margins until sound tooth structure is reached (**Fig. 8.27**)
- Restrict the depth of axial wall 0.2–0.8 mm into dentin (**Fig. 8.28**)
- Axial wall should be parallel to external surface of the tooth (**Fig. 8.29**)
- In class II tooth preparation, place gingival seat apical to the contact but occlusal to gingival margin and have the clearance of 0.5 mm from the adjacent tooth (**Figs 8.30 and 8.31**).

To Recapitulate

Axial wall should

- Be placed into dentin 0.5–0.8 mm from DEJ
- Follow curvature of dentinoenamel junction buccolingually
- Follow curvature of dentinoenamel junction occlusogingivally.

Rules for Class V Cavities

- For outline form, extensions are made mesially, distally, occlusally and gingivally till sound tooth structure is reached
- Axial depth is limited to 0.8–1.25 mm pulpally.

Enameloplasty

- Enameloplasty is removal of sharp and irregular enamel margins of the enamel surface by 'rounding' or 'saucering' it and converting it into a smooth groove making it self-cleansable area.

Indications

- It is done when caries is present in less than one-third thickness of the enamel
- Presence of a shallow fissure crossing facial or lingual ridge can be removed by enameloplasty.

Significance

- Enameloplasty does not extend the outline form. This procedure should not be used unless a fissure can be made into a groove with a saucer base with mild removal of enamel.

Primary Resistance Form

Definition

Primary resistance form is that shape and placement of preparation walls to best enable both the tooth and

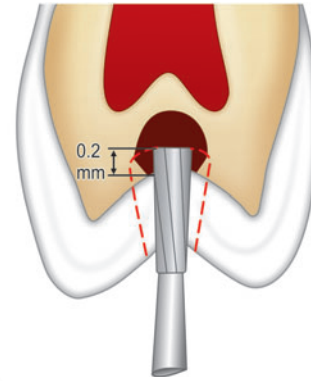


Figure 8.26: Schematic representation showing that preparation depth should be at least 1.5–2 mm from the cavosurface margin and at least 0.2–0.5 mm into dentin

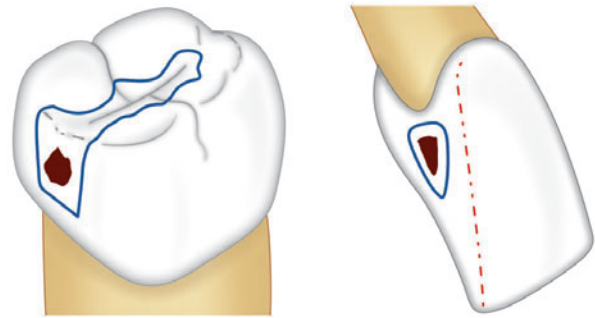


Figure 8.27: Schematic representation showing that outline form should include all the carious lesion and undermined enamel

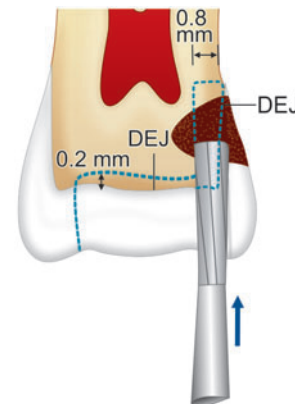


Figure 8.28: Schematic representation showing that depth of axial wall should be restricted 0.2–0.8 mm into dentin

restoration to withstand, without fracture, the stresses of masticatory forces delivered principally along the long axis of the tooth.

Features of Resistance Form

- Box-shaped preparation with flat pulpal and gingival floor: This helps the tooth to resist occlusal loading by virtue of being prepndicular to the masticatory forces directed along the long axis of the tooth (**Figs 8.32A and B**)

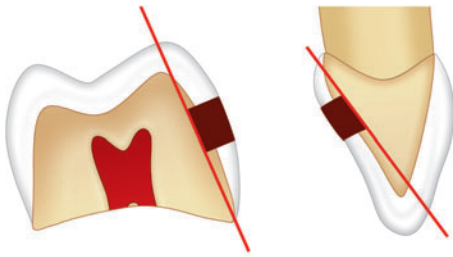
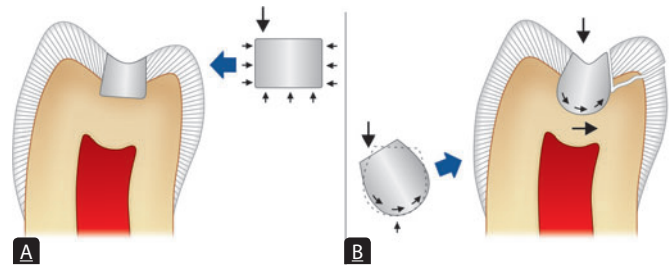


Figure 8.29: Schematic representation showing that axial wall should be parallel to external surface of tooth



Figures 8.32A and B: Schematic representation showing (A) Resistance form of tooth provided by flat pulpal and gingival floor; (B) In case of rounded pulpal floor, the rocking motion of restoration results in wedging force which may result in failure of restoration

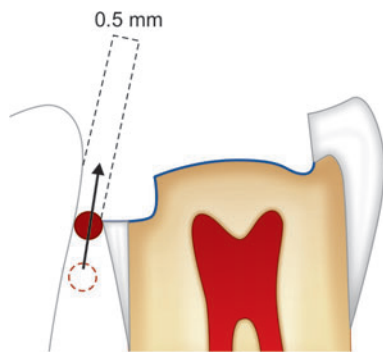


Figure 8.30: Schematic representation showing that proximal tooth preparation, gingival margin should clear adjacent tooth by 0.5 mm

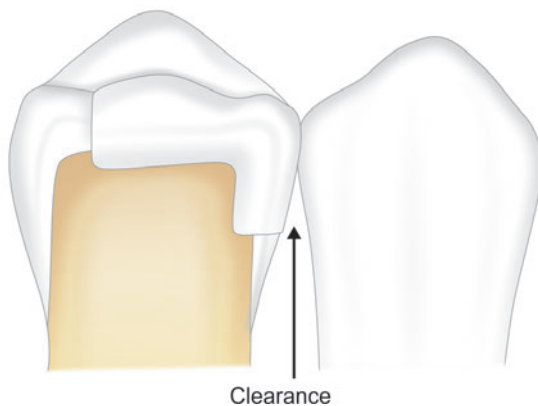


Figure 8.31: Schematic representation showing 0.5 mm clearance from adjacent tooth

- Adequate thickness of restorative material depending on its respective compressive and tensile strengths to prevent the fracture of both the remaining tooth structure and restoration (**Box 8.1**)
- In case of class IV preparations, check the faciolingual width of anterior teeth, to establish the resistance form

Box 8.1: Minimum occlusal thickness for various type of restoration

Type of restoration	Minimum occlusal thickness
Cast metal	1–2 mm
Amalgam restorations	1.5 mm
Ceramics	2 mm
Composite	1–2 mm

- Restrict the extension of external walls to allow strong marginal ridge areas with sufficient dentin support (**Fig. 8.33**)
- Inclusion of weakened tooth structure to avoid fracture under masticatory forces
- Rounding of internal line angle to reduce the stress concentration points in tooth preparation (**Fig. 8.34**)
- Consideration to cusp capping depending upon the amount of remaining tooth structure.

Factors Affecting Resistance Form

- Amount of occlusal contact
- Type of restoration used
- Amount of remaining tooth structure.

Primary Retention Form

Definition

Primary retention form is that form, shape and configuration of the tooth preparation that resists the displacement or removal of restoration from the preparation under lifting and tipping masticatory forces (**Box 8.2**).

Factors Affecting Retention Form

- Amount of the masticatory stresses falling on the restoration
- Thickness of the restoration

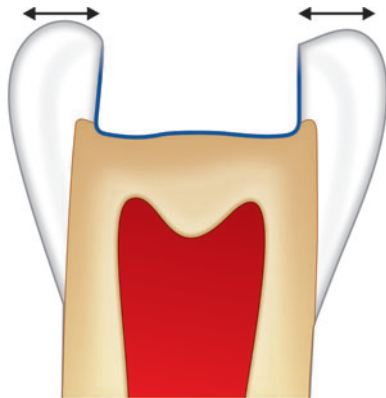


Figure 8.33: Schematic representation showing restriction of the extensions of external wall so as to have strong marginal ridge area

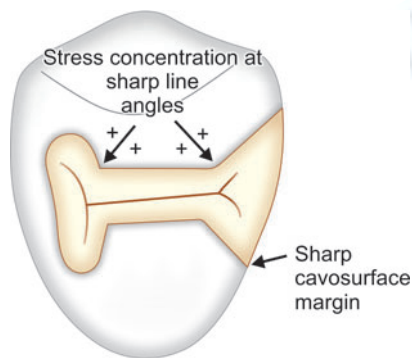


Figure 8.34: Schematic representation showing sharp line angle and cavosurface margins can lead to poor resistance form because of concentration of stresses at that point

Box 8.2: Retention form for different restorations

Restoration	Primary retention form
Amalgam class I and II	<ul style="list-style-type: none"> • Occlusal convergence of external walls (about 2°–5°) • Conservation of marginal ridges • Occlusal dovetail
Amalgam class III and IV	<ul style="list-style-type: none"> • As the external walls diverge outward, retention grooves/coves are the primary retention forms
Cast metals	<ul style="list-style-type: none"> • Parallel longitudinal walls with slight occlusal divergence of 2–5° • Occlusal dovetail • Secondary retention in the form of coves, skirts and dentin slot
Composites	<ul style="list-style-type: none"> • Micromechanical bonding between etched and primed surface with composites • Enamel bevels
Direct filling gold	<ul style="list-style-type: none"> • Elastic compression of dentin and starting point in dentin provides retention by proper condensation

- Total surface area of the restoration exposed to the masticatory forces
- The amount of remaining tooth structure.

Convenience Form

Definition

The convenience form is that form which facilitates and provides adequate visibility, accessibility and ease of operation during preparation and restoration of the tooth.

Features of Convenience Form

- Sufficient extension of distal, mesial, facial or lingual walls to gain adequate access to the deeper portion of the preparation
- Cavosurface margin of the preparation should be related to the selected restorative material for the purpose of convenience and marginal adaptation
- In class II preparations, access is made through occlusal surface for convenience form
- Proximal clearance is provided from the adjoining tooth during class II tooth preparation
- To make Class II tunnel preparation, for convenience, the proximal caries in posterior teeth is approached through a tunnel initiating from the occlusal surface and ending on carious lesion on the proximal surface without cutting the marginal ridge
- In tooth preparation for cast gold restorations occlusal divergence is one of the features of convenience form.

FINAL STAGE

Removal of Any Remaining Caries, Infected Dentin and/or Old Restorative Material, if Indicated

- A small isolated carious lesion should be eliminated by a conservative preparation. After the establishment of pulpal and axial wall, if a small amount of carious lesion remains, only this lesion should be removed, leaving concave, rounded area in the wall
- Use low speed handpiece with the round bur or spoon excavator with light force and a wiping motion. Use of a large spoon excavator decreases the chance of a pulpal exposure
- Start removal of caries from the lateral borders of the lesion. Force for removal of infected dentin should be directed laterally and not towards the center of the carious lesion

- Remove only infected dentin, not the affected dentin (**Table 8.2**).

Removal of old restorative material is indicated, if

- It affects esthetics of new restoration
- Has secondary caries beneath (seen on radiograph)
- Tooth is symptomatic
- It compromises new restoration
- Marginal deterioration of old restoration.

Pulp Protection

Pulp protection is a very important step in adapting the preparation for final restoration although actually it is not a step of tooth preparation. When remaining dentin thickness is less, pulpal injury can occur because of heat production, high speed burs with less effective coolants, irritating restorative materials, galvanic currents due to restoration of dissimilar metals, excessive masticatory forces transmitted through restorative materials to the dentin and ingress of microorganisms and their noxious products through microleakage.

Pulp protection is achieved using liners, varnishes and bases depending upon—

- The amount of remaining dentin thickness (**Table 8.3**)
- Type of the restorative material used.

Liners and varnishes are used where preparation depth is shallow and remaining dentin thickness is more than 2 mm. They provide:

- Barrier to protect remaining dentin and pulp
- Galvanic and thermal insulation.

Table 8.3 summarizes different ways of pulp protection under various restorative materials depending upon remaining dentin thickness.

Secondary Resistance and Retention Forms

This step is needed in complex and compound tooth preparations where added preparation features are used to improve the resistance and retention form of the prepared tooth. These are as follows:

Mechanical Features

Many mechanical features are added in the tooth preparation to provide additional retention and resistance form. These can be:

Grooves and Coves

Coves are small conical depressions prepared in healthy dentin to provide additional retention. These are normally prepared in the proximal walls of class II preparations at the axiofacial and axiolingual line angles, thus reducing proximal displacement of the restoration. More than one groove per wall should be avoided as they may weaken the wall. Grooves are especially useful for cast restorations.

Table 8.4 enlists type of tooth preparation and location of retention grooves.

Slot or Internal Box

These are 1.0–1.5 mm deep box-like grooves prepared in dentin to increase the surface area. These are prepared in occlusal box, buccoaxial, linguoaxial and gingival walls

Table 8.2 | Difference between infected and affected dentin

Infected dentin	Affected dentin
• It is a superficial layer of demineralized dentin	• It is a deeper layer
• Cannot be remineralized	• Can be remineralized
• Lacks sensation	• It is sensitive
• In this, intertubular layer is demineralized with irregularly scattered crystals	• In this, intertubular layer is only partly demineralized
• Collagen fibers are broken down, appear as only indistinct cross bands	• Distinct cross bands are present
• It can be stained with: <ul style="list-style-type: none"> – 0.2% propylene glycol – 10% acid red solution – 0.5% basic fuchsin 	• It cannot be stained with any solution

Table 8.3 | Showing methods of pulp protection under different restorative materials

Types of restoration	Shallow (RDT > 2.0 mm)	Moderately deep (RDT > 0.5–2 mm)	Deep (RDT < 0.5 mm)
Silver amalgam	Varnish	Base, e.g. zinc phosphate, zinc polycarboxylate	Calcium hydroxide as sub-base covered with base
Glass ionomer cement	Not required	Not required	Calcium hydroxide as liner
Composite resins	Dentin bonding agent	Dentin bonding agent	Calcium hydroxide as liner followed by glass ionomer as base
Cast gold restorations	Not required	Base	Calcium hydroxide as liner with base over it

(Fig. 8.35). For cast restorations these are prepared by tapered fissure bur to avoid undercuts and for plastic restorative materials like amalgam, these are prepared by inverted cone bur to create slight undercuts in dentin.

Locks

Locks are usually prepared for class II amalgam restorations for increasing resistance and retention form (Fig. 8.36).

Pins

Different types of pins of various shapes and sizes are used to provide additional retention in amalgam, composite and cast restorations.

Skirts

Skirts are prepared for providing additional retention in cast restorations. They increase the total surface area of the preparation. Skirts can be prepared on one or all four sides of the preparation depending upon the required retention (Fig. 8.37). Skirts have shown to improve both resistance and retention form.

Amalgapins

Amalgapins are vertical posts of amalgam anchored in dentin. Dentin chamber is prepared by using inverted cone bur on gingival floor 0.5 mm in dentin with 1 to 2 mm depth and 0.5 to 1 mm width (Fig. 8.38). Amalgam pins increase the retention and resistance of complete restoration.

Treatment of the Preparation Walls

Treatment of the preparation walls by beveling, etching and priming increases the adhesive property of tooth preparation.

Beveled Enamel Margins

Beveling of preparation, margins increases the surface area and thus, the retention in composite restorations.

Enamel Wall Etching

Etching results in microscopic roughness, which increases the surface area and thus helps in enhancing the micromechanical retention.

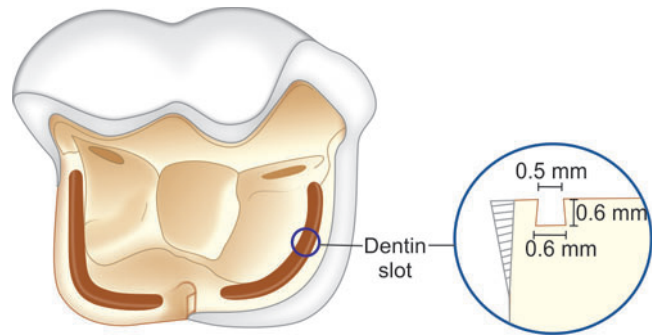


Figure 8.35: Schematic representation of slot

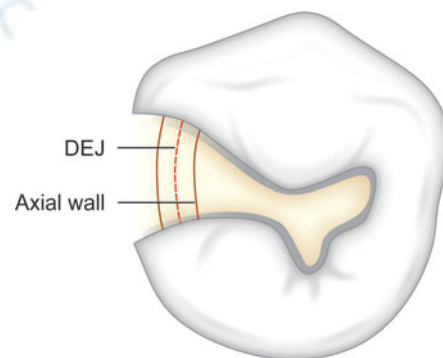


Figure 8.36: Schematic representation of retention locks

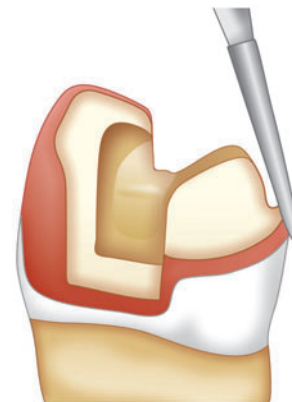


Figure 8.37: Schematic representation of skirt in cast restoration helps in increasing retention

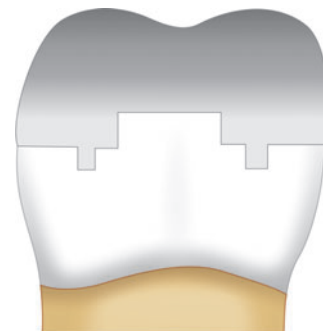


Figure 8.38: Schematic representation showing amalgapins increase retention of the restoration

Table 8.4 Location of retention grooves for different tooth preparations	
Type of tooth preparation	Location of retention grooves
Class II preparation	Proximal wall, at the axiofacial and axiolingual line angles
Class III preparation	Axiogingival line angle or axiofaciogingival point angle and lingual dovetail
Class V preparation	Axioincisal and axiogingival line angle

Dentin Conditioning (Etching and Priming)

Etching and priming of the dentin surface increases the retention.

Adhesive Luting Cements

Adhesive luting cements increase the retention of indirect restorations.

Procedures for Finishing the External Walls of the Tooth Preparation

Definition

Finishing of a tooth preparation walls is further development of a specific cavosurface design and degree of smoothness which produces maximum effectiveness of the restorative material being used.

Finishing of the Preparation Walls Results in the following

- Better marginal seal between restoration and tooth structure
- Increased strength of both tooth structure and restoration at and near the margins
- Strong location of the margins
- Increase in degree of smoothness of the margins.

Final Procedures: Cleaning, Inspecting and Sealing

Final step in tooth preparation is cleansing of the preparation. This includes the removal of debris, drying of the preparation, and final inspection before placing restorative materials.

- Cleaning of tooth preparation using warm water
- Drying the tooth preparation using air, dry cotton pellets
- Sterilization of preparation walls using very mild alcohol free disinfectant: Use of mild disinfectant in tooth preparation serves the purpose of disinfection.

Degree of Smoothness of Walls

It depends upon type of restoration used. For example, for cast metal restorations, a very smooth surface is required whereas for direct gold, amalgam and composite restorations, slight roughness is needed in the preparation walls.

Location of the Margins

During finishing of the preparation walls and margins, one should follow the principles of paralleling the direction of enamel wall. The knowledge of enamel rods is necessary

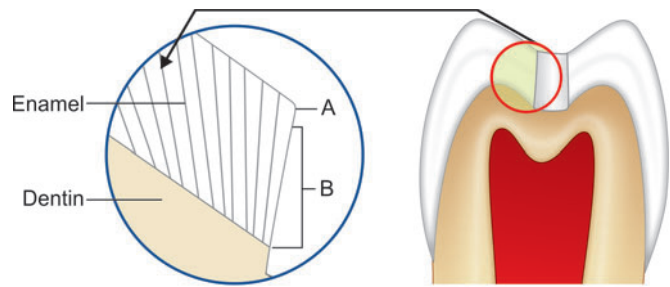


Figure 8.39: Schematic representation showing that at the margins, all the enamel walls should have full length rods supported by dentin

Table 8.5 | Showing differences between butt joint and lap joint

	Butt joint	Lap/Slip joint
Cavosurface margin	90° at margin	>90° at margin
Nature of prepared walls	Smooth	Roughened
Indications	<ul style="list-style-type: none"> • Preferred in amalgam restorations as it produces maximal strength for both tooth and amalgam • Also given in ceramic restorations 	<ul style="list-style-type: none"> • Indicated in cast and composite restorations
Esthetics	<ul style="list-style-type: none"> • Less esthetic 	<ul style="list-style-type: none"> • More esthetic

for proper finishing of the preparation margins. At the margins, all the enamel walls should have full length rods supported by dentin (Fig. 8.39). To remove unsupported enamel rods near gingival margins, it should be slightly beveled. In case of cast gold restorations, a short bevel is given and an ultrashort bevel is given in case of gold foil.

Table 8.5 shows differences between butt joint and lap joint.

VIVA QUESTIONS

Q.1. What is tooth preparation?

Ans. It is a mechanical alteration of a defective, injured or diseased tooth in order to best receive a restorative material which will re-establish the healthy state of the tooth including esthetic correction when indicated along with normal form and function.

Q.2. What are different causes of loss of tooth structure?

Ans. Most common cause is dental caries. Other causes can be trauma resulting in tooth fracture, attrition,

abrasion, erosion, tooth malformation, hypoplasia, tooth resorption, etc.

Q.3. What is simple, compound and complex tooth preparations?

Ans. A tooth preparation involving only one tooth surface is termed as simple preparation. For example, mesial, distal, occlusal, buccal, lingual tooth preparation.

A tooth preparation involving two surfaces is termed as compound tooth preparation. For example, mesio-occlusal (MO), disto-occlusal (DO), mesiolingual (ML), or distobuccal (DB) tooth preparation.

A tooth preparation involving more than two surfaces is called as complex tooth preparation. For example, mesio-occlusodistal (MOD), facio-occlusolingual (FOL) or mesioincisodistal (MID) tooth preparation.

Q.4. Define class I tooth preparation.

Ans. Class I preparations occur on the occlusal surfaces of premolars and molars, the occlusal two-third of buccal and lingual surface of molars and lingual surface of incisors.

Q.5. Define class II tooth preparation.

Ans. Preparations on the proximal surface of premolars and molars are class II.

Q.6. Define class III tooth preparation.

Ans. Preparations on the proximal surface of anterior teeth and not involving the incisal angles are class III.

Q.7. Define class IV tooth preparation.

Ans. Preparations on the proximal surface of anterior teeth also involving the incisal angle falls under class IV.

Q.8. Define class V tooth preparation.

Ans. Preparations on gingival third of facial and lingual or palatal surfaces of all teeth come under Class V.

Q.8. Define class VI tooth preparation.

Ans. Preparations on incisal edges of anterior and cusp tips of posterior teeth without involving any other surface come under Class VI.

Q.10. What are different walls and floors of a tooth preparation?

- Ans.**
- Buccal
 - Lingual/Palatal
 - Mesial
 - Distal
 - Axial wall
 - Occlusal/Incisal
 - Pupal floor
 - Gingival seat.

Q.11. Who is father of modern operative dentistry?

Ans. GV Black.

Q.12. What is floor of the cavity?

Ans. Floor is the flat surface of prepared cavity which is perpendicular to the occlusal forces which are directed occlusogingivally.

For example; pulpal and gingival floors

Q.13. What should be the isthmus width of amalgam cavity?

Ans. 1/4th of intercuspal distance.

Q.14. What is ideal depth of amalgam cavity?

Ans. 1.5–2.0 mm total depth. 0.2–0.5 mm into the dentine.

Q.15. Define a line angle.

Ans. It is a junction of two surfaces of different orientations along the line. Its name is derived from the involved surfaces.

Q.16. What is a point angle?

Ans. It is a junction of three plane surfaces or three line angles of different orientations. Its name is derived from its involved surfaces or line angles.

Q.17. Do we have line angle at cavosurface margin?

Ans. No, because line angle is the junction between two prepared parts of tooth preparation. Cavosurface margin is the junction of prepared tooth with unprepared tooth surface.

Q.18. If class II tooth preparation involves only proximal surface, why do we make occlusal preparation also?

Ans. Occlusal preparation is done for convenience form. Since directly reaching the affected area with bur is difficult because of close proximity of the adjacent tooth therefore an occlusal preparation is made through which proximal surface is reached.

Q.20. Why is class VI added to Black's classification?

Ans. Black classified the cavities according to some order and pattern of caries in affected teeth. But he did not include the areas which he assumed might not be attacked by caries, though in reality they might be affected. Simon later modified Black's classification and added class VI. The class VI are the tooth preparations which occur in the areas not covered by any of the other five classes like cusp tips, incisal two-third of anterior teeth, etc.

Q.21. What is enamel and dentinal wall?

Ans. Enamel wall is portion of prepared external wall consisting of enamel.

Dentinal wall is portion of prepared external wall consisting of dentin.

Q.22. What will be the treatment if caries involve proximal surface of anterior tooth without involving incisal edge and caries at palatal pit?

Ans. If lesions are not interconnected they are treated as separate preparations.

But if they are connected, the preparation is class III with lingual extension.

Q.23. What is treatment for caries present on buccal surface and proximal surface of a molar?

Ans. If lesions are not interconnected and small, they are treated as separate class II and class I preparations. But if lesions are large and interconnected, it is treated as proximo-occlusobuccal preparation.

Q.24. What is similarity between class II, III, IV and V preparations?

Ans. All occur on smooth surfaces.

Q.25. What is common between class II, III, IV preparations?

Ans. All these occur on proximal surfaces.

Q.26. How is tooth preparation done?

Ans. It is done by use of hand and rotary instruments.

Q.27. What are different steps of tooth preparation?

Ans. A. Stage I

Initial tooth preparation steps:

1. Outline form and initial depth.
2. Primary resistance form.
3. Primary retention form.
4. Convenience form.

B. Stage II

Final tooth preparation steps:

5. Removal of any remaining caries, infected dentin and/or old restorative material, if indicated.
6. Pulp protection, if indicated.
7. Secondary resistance and retention form.
8. Procedures for finishing the external walls of the tooth preparation.
9. Cleaning, inspecting and sealing.

Q.28. Define outline form. List the factors influencing the outline form?

Ans. *The outline form means:*

- Placing the preparation margins to the place they will occupy in the final tooth preparation except for finishing enamel walls and margins
- Maintaining the initial depth of 0.2–0.8 mm into the dentin.

Factors affecting outline form:

- Extension of carious lesion
- Proximity of the lesion to other deep structural surface defects
- Relationship with adjacent and opposing teeth
- Caries index of the patient
- Need for esthetics
- Restorative material to be used.

Q.29. What is extension for prevention?

Ans. This concept was given by GV Black which advocated involvement of all pits and fissures even if they are unaffected by caries.

Q.30. What do you mean by breaking the contact?

Ans. In case of class II, and III and IV caries, there is always a contact with the adjacent tooth. In these cases, whether caries are below or above the contact, the contact has to be broken so as to bring preparation margins into the embrasures for easy cleansability. If preparation margins end in non-cleansable areas, food stagnation in those areas may result in secondary caries.

Q.31. What should be ideal depth of the preparation?

Ans. Ideal depth should be 0.5 mm below DEJ, especially for non-adhesive materials. Since enamel is inelastic, it cannot be used for providing retentive and resistance form. So depth of preparation should be increased till elastic dentin is reached. Preparation should not end at dentinoenamel

junction. This area is sensitive because of lateral branching of dentinal tubules and cytoplasmic extensions of odontoblasts.

Q.32. How does convenience form affects outline from?

Ans. This is specially seen in case of class II, III and IV preparations where adjacent tooth is present. In these cases it is impossible to reach the proximal area without cutting occlusal surface, otherwise adjacent tooth is cut.

But if adjacent tooth is missing, one can gain entry to proximal box without cutting the occlusal surface.

Q.33. What is meant by cuspal contour?

Ans. Cuspal contour means making preparation at uniform depth providing equal dentin thickness between pulp and the preparation. Since cusps are conical in shape, if pulpal floor is made straight it may result in uneven dentin thickness. The areas where less of dentin is present, preparation will be closer to pulp, resulting in its damage.

Q.34. Why should not preparation have sharp angles?

Ans. If preparation has sharp angles, it leads to concentration of stresses at those areas which may fracture the restoration. So to avoid stress concentration, preparation should have gentle curves and smooth walls.

Q.35. What is significance of stress bearing areas?

Ans. When opposing teeth come in contact, they contact only some areas of occlusal surfaces. These areas where they contact are stress bearing areas.

Significance: Preparation margins should not end at stress bearing areas otherwise stresses are met partially by the tooth and partially by restoration resulting in separation between the two. This can fracture the restoration or may result in marginal leakage. So preparation margin should be avoided at stress bearing areas. They should be kept entirely either on tooth surface or on restorative material.

Q.36. How is outline form affected by direction of enamel rods?

Ans. Enamel rods extend perpendicular from DEJ to enamel in a slightly wavy course. In vertical direction, they appear to converge towards a pit from DEJ, whereas they diverge as they move towards cusp tip from the DEJ.

In horizontal section, enamel rods flare out from DEJ towards outer surface.

Because of the direction of enamel rods, following walls are flared externally:

1. Buccal and lingual walls of proximal box.
2. Mesial and distal walls of buccal and lingual boxes of class I extensions.
3. All walls of class V preparation.

If these walls are made to converge towards each other, this will result in unsupported enamel rods which may fracture later on.

Q.37. How does esthetics affect outline form?

Ans.

- For class III preparation, labial enamel is kept intact
- Preparation margins should be kept into embrasures for better esthetics
- Reverse curve is given in maxillary premolars.

Q.38. How does age affect outline form?

Ans. Because of presence of deep pits and fissures, young teeth are more caries prone, therefore for a young patient, a conventional preparation is indicated.

For older patients, a conservative preparation is indicated. In these patients teeth become less susceptible to caries because of following reasons:

- a. Attrition of teeth.
- b. Cumulative effect of fluoride from food, water supply, dentifrices, etc.
- c. Older patient may follow oral instructions better.

Q.39. Define resistance form.

Ans. It is that shape and placement of preparation walls to best enable both the tooth and restoration to withstand, without fracture the stresses of masticatory forces delivered principally along long axis of the tooth.

Q.40. What are factors affecting resistance form?

Ans.

- Amount of occlusal stresses
- Type of restoration used
- Amount of remaining tooth structure.

Q.41. What is extension for resistance?

Ans. When outline is extended for reinforcing the weakened tooth structure, it is referred as extension for resistance. For example, when preparation involves more than one-half of the cusp, outline is extended in which cusp is reduced and cuspal coverage is done.

Q.42. Why is floor of preparation made perpendicular to occlusal forces?

Ans. When masticatory forces are applied perpendicular to floor, there is equal and opposite force offered by preparation floor to resist the masticatory forces.

If pulpal floor is made at an angle, it will split occlusal forces into two components:

- Perpendicular component which is resisted by occlusal forces, this helps in seating of the restoration.
- Lateral component of force along the surface of floor.

Q.43. Is pulpal floor always horizontal?

Ans. No the mandibular premolar has a lingual tilt, so the pulpal floor is also made with lingual tilt.

Q.44. Why should a restorative material have bulk?

Ans. To have resistance form a restorative material should have sufficient bulk, for example for amalgam, at least 1.5–2 mm of depth is required.

Q.45. Why should be unsupported enamel removed from the preparation?

Ans. If enamel is not supported by dentin, it can fracture by masticatory forces because of its brittle nature.

Q.46. What is as isthmus and its significance?

Ans. Isthmus is the narrow connection between two portions of a preparation (occlusal and proximal). Most of the restoration failures occur at isthmus area. If it is very narrow, restoration will be very weak at that area. If isthmus is very wide, the remaining tooth structure will become very weak.

Q.47. When should two adjacent preparation be connected??

Ans. If healthy tooth structure between two preparations is less than 0.5 mm, the two adjacent preparations are joined to form one large preparation. For example, mesial and distal pits of maxillary first molar.

Q.48. What is retention form?

Ans. It is that form, shape and configuration of the tooth preparation that resists the displacement or removal of restoration from the preparation under lifting and tipping masticatory forces.

Q.49. Classify retention form

Ans.

- Intracoronal
- Extracoronal.

Q.50. What are factors affecting retention form?

Ans.

- Proximity between tooth and restoration
- Parallelism of opposing walls
- Total surface area of contact.

Q.51. What area different modes of retention?

Ans.

- Providing occlusal convergence
- Providing occlusal dovetail
- Close parallelism of the opposing walls
- Use of secondary retention in the form of coves, skirts and dentin slot
- Use of bevels.

Q.52. How is retention achieved in amalgam restoration?

Ans.

- Occlusal convergence—inverted truncated shape
- Occlusal dovetail
- Undercuts.

Q.53. What is meant by inverted truncated shape of the cavity?

Ans.

- It means internal outline form is greater than external outline form with pulpoocclusal convergence of the preparation walls
- It is indicated for incrementally added direct restoration material like amalgam.

Q.54. How does dentin help in retention?

Ans. Due to elastic nature of dentin, there is microscopic movement of dentinal walls (away from each other) when a restorative material is being condensed in the preparation. Once the restorative material sets, dentin comes back to its original position resulting in better retention and more gripping action.

Q.55. What is significance of dovetail?

Ans. It helps in retention in proximal direction. In other words, dovetail holds the proximal restoration from dislodging proximally.

Q.56. What is undercut?

Ans. Undercut is a mode of retention which is prepared with an inverted cone bur in line angles of the preparation. While preparing undercut, one should take care to make the cut in the wall and not into the floor. While restoration, one should take care that

only the restorative material should be filled in the undercut area, and not the base.

Q.57. What are secondary means of retention?

- Ans.**
- Grooves and coves
 - Slots, locks and pins
 - Internal box
 - Skirts
 - Amalgam pins
 - Beveled enamel margins.

Q.58. What is convenience form?

Ans. The convenience form is that form which facilitates and provides adequate visibility, accessibility and ease of operation during preparation and restoration of the tooth.

Q.59. What is meant by convenience for access?

Ans. In case of class II and III preparations, due to presence of adjacent tooth, one has to cut the occlusal or labial surface. This outline for gaining access to carious lesion is called as convenience for access.

Q.60. What do you mean by removal of remaining caries?

Ans. In some teeth, if any caries remain on the deeper part of preparation after gaining resistance and retention form, these are removed carefully without causing any harm to pulp. If attempts are made for complete caries removal at the initial stages only, one might end up for over cutting so it is always advised to incorporate retentive and resistance features before complete caries removal is done.

Q.61. Which instrument is used for removal of remaining caries?

- Ans.**
- Low-speed handpiece with the round bur
 - Spoon excavator.

Q.62. Difference between affected and infected dentin?

Ans. *Infected dentin:*

- It is a superficial layer of demineralized dentin
- Cannot be remineralized
- Lacks sensation
- In this, intertubular layer is demineralized with irregularly scattered crystals
- Collagen fibers are broken down, appear as only indistinct cross bands
- It can be stained with:
 - 0.2% propylene glycol

- 10% acid red solution
- 0.5% basic fuschin.

Affected dentin:

- It is a deeper layer
- Intermediate demineralized dentin
- Can be remineralized
- It is sensitive
- In this, intertubular layer is only partly demineralized
- Distinct cross bands are present
- It cannot be stained with any solution.

Q.63. What precautions should be taken while removing deep carious lesion?

Ans. Use slow-speed handpiece with the round bur or spoon excavator that will fit in the carious lesion used with light force and a wiping motion.

Forces for removal of infective dentin should be directed laterally and not towards the center of the carious lesion.

Q.64. Which instrument is used for removal of unsupported enamel rods ?

Ans. Chisel, hoe or hatchet is used for removal of unsupported rods.

Q.65. For smoothing the gingival seat which instrument is used?

Ans. GMT is used for making gingival seat.

Q.66. How do you check convenience form?

Ans. After tooth preparation, insert the small amalgam condenser into all parts of preparation. If even the small instrument does not enter some parts of tooth preparation, tooth preparation is widened.

Q.67. Is breaking of contact also required for insertion of matrix band?

Ans. No, the main reason for breaking a contact is to bring the preparation margins in self cleansable area. For matrix band insertion, teeth can be separated using separators rather than cutting natural teeth structure.

Q.68. For preparations near gingival margins, where should be gingival seat located?

Ans. As we know gingival area is a delicate area, any irritant present at tooth-gingival interface can cause inflammation of soft tissue and epithelial attachment. One should always try to keep the gingival margins supragingivally for easy