

Testicular Perfusion Imaging

Paul C. Hanson

Penrose Hospital, Colorado Springs, Colorado

Testicular imaging is a simple and noninvasive procedure used to study the vascular perfusion of the testicles. It is a reliable method for diagnosis of testicular torsion and inflammatory processes such as epididymitis. Using a wide-field-of-view scintillation camera with a parallel hole collimator, a dynamic flow study and static images are obtained following a bolus injection of [^{99m}Tc] sodium pertechnetate.

Radionuclide imaging of the testicles was first introduced by Nadel et al. (1) in 1973. Since then many other investigators have reported that the use of [^{99m}Tc] sodium pertechnetate to study testicular perfusion is an accurate method for diagnosing a wide range of intrascrotal lesions (2-5). The technique described herein is routinely used at our laboratory with very good results. This method is easily adapted to whatever type of scintillation camera is available.

The instrumentation consists of an Ohio Nuclear wide-field-of-view scintillation camera with electronic magnification capabilities (Ohio Nuclear, Inc., Solon, OH). A parallel hole medium energy collimator was routinely used for all dynamic radionuclide flow studies and static images. An Ohio Nuclear Ultimat multi-formatter was used to record all dynamic and static images. Dynamic studies were also recorded on video tape.

Materials and Methods

The patient was placed in a supine position with legs slightly abducted. A tape support was then placed across both thighs and under the scrotum so that the testicles were parallel and of equal distance from the face of the collimator. The patient's penis was then taped back to the anterior abdominal wall so as not to obscure the arterial flow to the testicles.

A standard dose of 285 μ Ci/kg of [^{99m}Tc] sodium pertechnetate was used for all adult patients; proper adjustment was made according to age and body surface area

for younger male patients. The maximum dose used for an adult male was 20 mCi. However, a minimum dose of not less than 2.8 mCi should be used for infants to ensure a good flow study. Pediatric patients may be premedicated with approximately 100-150 mg of potassium perchlorate in order to reduce radiation exposure to the thyroid gland.

Following injection of the tracer into an antecubital vein, a dynamic radionuclide flow study of the anterior pelvis and scrotal region was obtained at 4 sec per frame for a total of 16 frames. All flow studies were done using a normal unmagnified field of view. Static imaging was begun immediately following completion of the flow study. The static study consisted of four 700K images. All static images were done in this way: (a) unmagnified image of the anterior pelvis, (b) magnified view of the anterior pelvis with the scrotum centered in the field of view, (c) unmagnified image of the anterior pelvis with a lead shield under the scrotum, and (d) magnified view of the genital region with a lead shield under the scrotum.

The lead shield served to eliminate some of the background activity in the upper thigh region. The shield was made with flexible lead approximately 9 in. long and 3 in. wide and $1/16$ in. thick. The lead shield should be pushed under the scrotum as far as possible to improve the quality of the static images. The shield may have to be held in place to achieve the desired effect.

TABLE 1. Testicular Perfusion Imaging Technique Summary

Step 1.	Position: supine, legs abducted, tape support under scrotum, penis taped back.
Step 2.	Tracer: 20-mCi [^{99m} Tc] sodium pertechnetate, i.v. bolus.
Step 3.	Instrumentation: wide-field-of-view camera, parallel hole, medium energy collimator.
Step 4.	Imaging: dynamic—4 sec/frame for 16 frames; static—two 700K images without lead shield (one normal, one magnified), two 700K images with lead shield (one normal, one magnified).

For reprints contact: Paul C. Hanson, Dept. of Nuclear Medicine, Penrose Hospital, 2215 N. Cascade Ave., Colorado Springs, CO 80907.

The patient's scrotum was then palpated and examined by the nuclear medicine physician. Additional views with markers were taken if requested. Total time for the procedure, including injection time, static images, and palpation, was approximately 15 min. A technique summary may be found in Table 1.

Results and Discussion

A total of 23 testicular perfusion studies, using both dynamic and static imaging, were performed on 21 patients who presented with symptoms of scrotal pain and swelling. The age range was from 1 to 50 years. Three patients underwent surgical exploration of the scrotum at which time two were found to have acute testicular

torsion. The third patient surgically explored was found to have an acutely inflamed appendix of the testis. The surgical findings of these three patients served to document the diagnosis made at the time of testicular imaging performed before surgery. Of the remaining patients, fifteen were diagnosed as having an inflammatory process involving one testicle. Follow-up on some of these patients showed that they had been treated with antibiotic medications. Five studies were diagnosed as normal.

The appearance of normal testicular perfusion can best be described as seeing little or no blood flow to the scrotal contents on the dynamic images (Fig. 1). This is also characteristic of the flow pattern in acute testicular

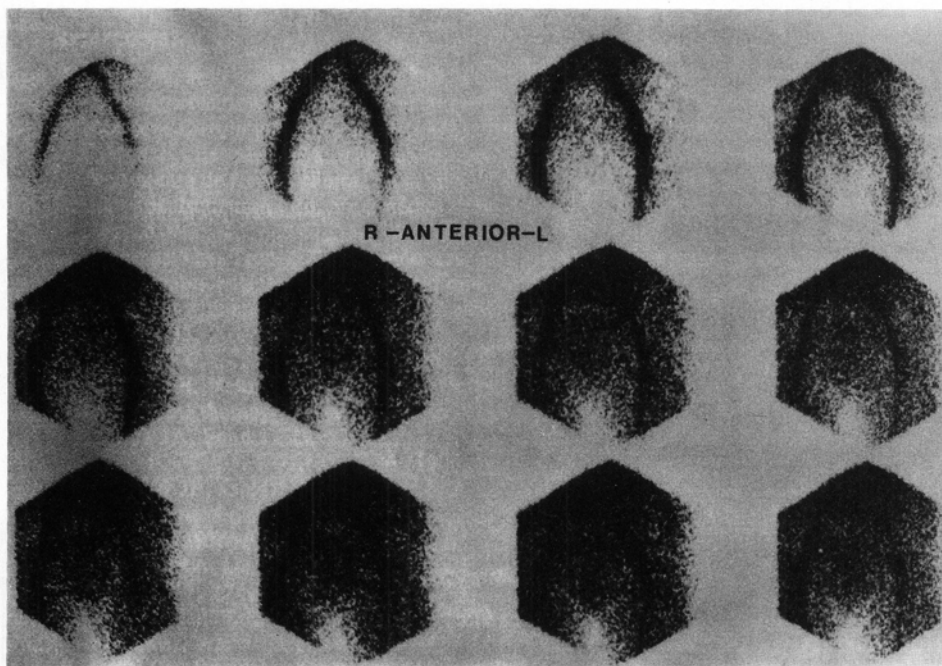


FIG. 1. Normal testicular flow study.

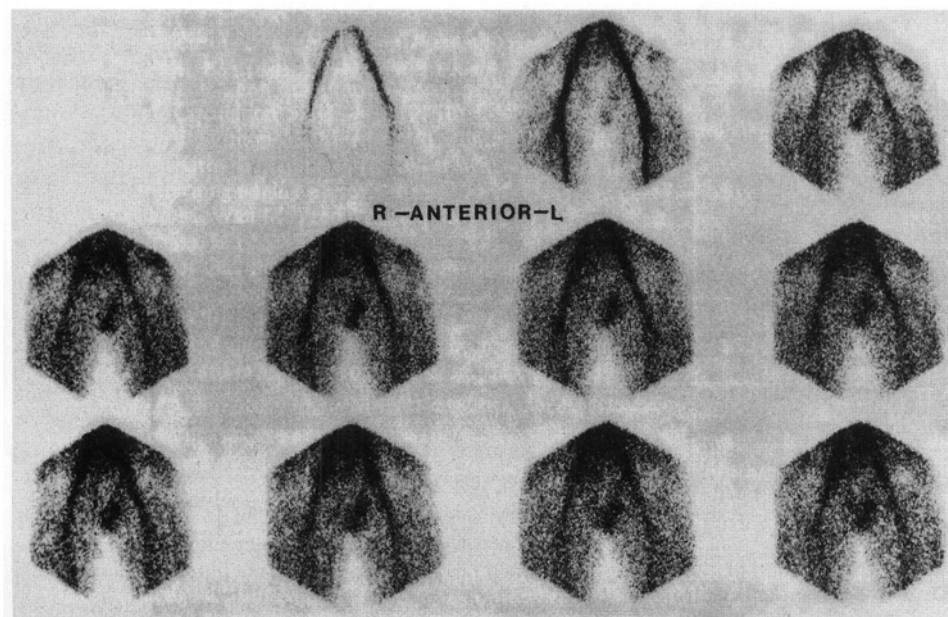


FIG. 2. Testicular flow study shows increased perfusion in left testicle.

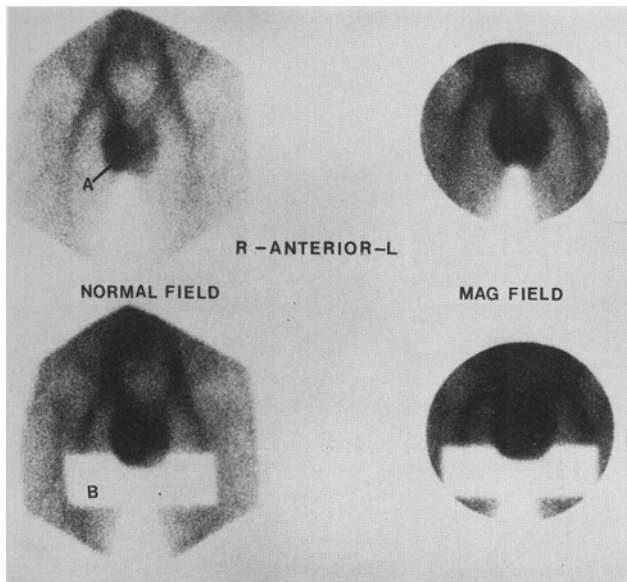


FIG. 3. Static images: (A) right orchitis; (B) lead shielding serves to eliminate background activity.

torsion; however, blood flow to the twisted testicle may be seen as being slightly decreased in some cases. With inflammatory processes, such as epididymitis and orchitis, the blood flow is seen as being greatly increased to the affected testicle (Fig. 2). On the static images involving epididymitis an increase in activity is usually seen in the region of the epididymis (Fig. 3), whereas acute torsion is usually seen as a round, cold area replacing the testicle (Fig. 4). Normal static images are characterized by symmetrical, homogenous uptake throughout the scrotum (Fig. 5).

Conclusion

Testicular imaging, when used in conjunction with

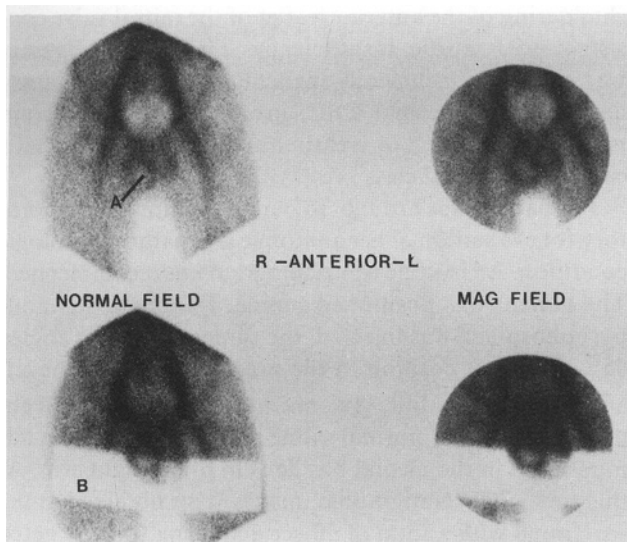


FIG. 4. Static images: (A) torsion of right testicle; (B) lead shielding.

clinical history, laboratory findings, and palpation of the scrotum by the nuclear medicine physician, is an integral part in the overall diagnosis of scrotal pathology. It is a fast and accurate method for diagnosing between inflammatory disease and acute testicular torsion. The accuracy of this procedure is well documented in the literature (1-5), as well as by follow-up done on the patients studied at this laboratory.

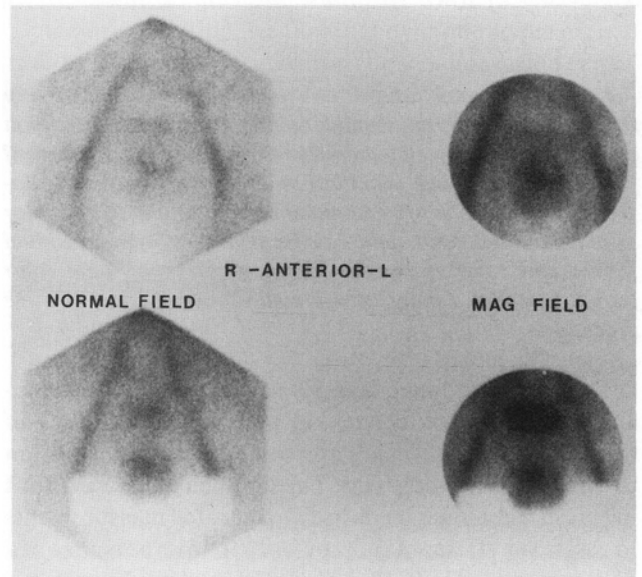


FIG. 5. Normal static images.

Testicular imaging should be available in all clinical nuclear medicine laboratories on a routine basis and as an emergency procedure. This is especially important in acute testicular torsion when surgery must be done immediately in order to prevent necrosis of the testicle.

Acknowledgment

I would like to thank Edwin R. Holmes, III, MD, for his invaluable aid in preparing this paper.

This work was originally presented as a scientific exhibit at the 25th Annual Meeting of the Society of Nuclear Medicine, Technologist Section, June 27-30, 1978, in Anaheim, CA.

References

1. Nadel NS, Gitter MH, Hahn LC, et al: Preoperative diagnosis of testicular torsion. *Urology* 1: 478-479, 1973
2. Riley TW, Mosbaugh PG, Coles JL, et al: Use of radioisotope scan in evaluation of intrascrotal lesions. *J Urol* 116: 472-475, 1976
3. Datta NS, Mishkin FS: Radionuclide imaging in intrascrotal lesions. *JAMA* 231: 1060-1062, 1975
4. Hahn LC, Nadel NS, Gitter MH, et al: Testicular scanning: A new modality for preoperative diagnosis of testicular torsion. *J Urol* 113: 60-62, 1975
5. Holder LE, Martire JR, Holmes ER, et al: Testicular radionuclide angiography and static imaging: Anatomy, scintigraphic interpretation, and clinical indications. *Radiology* 125: 739-752, 1977