

Baritosis: a benign pneumoconiosis

A. T. DOIG

Formerly HM Deputy Senior Medical Inspector of Factories

Doig, A. T. (1976). *Thorax*, 31, 30-39. **Baritosis: a benign pneumoconiosis.** Baritosis is one of the benign pneumoconioses in which inhaled particulate matter lies in the lungs for years without producing symptoms, abnormal physical signs, incapacity for work, interference with lung function, or liability to develop pulmonary or bronchial infections or other thoracic disease. Owing to the high radio-opacity of barium, the discrete shadows in the chest radiograph are extremely dense. Even in the most well-marked cases with extreme profusion of the opacities, massive shadows do not occur. When exposure to barium dust ceases the opacities begin slowly to disappear.

Nine cases of baritosis occurring in a small factory in which barytes was crushed, graded, and milled are described. Two of the cases occurred after only 18 and 21 months' exposure, and 9 of the 10 men employed for more than one and a half years had baritosis. Five of the affected men examined at intervals since their exposure to barytes ceased in 1964 showed marked clearing of their radiological abnormalities.

Until the middle 1930s no non-fibrotic forms of pneumoconiosis were known, and the term 'nodular fibrosis' was commonly used to describe the radiographic appearances in those cases which are now termed simple pneumoconiosis, on the assumption that all dust nodules were fibrotic. Doig and McLaughlin (1936), describing the siderosis of welders, were the first to postulate that some dusts might lie inertly in the pulmonary tissues without producing fibrosis or other permanent reaction, even although they were discernible on radiographs by their radio-opacity. Numerous reports have established the existence of such a benign pneumoconiosis, and Doig and McLaughlin later (1948) showed that the radiological opacities in welder's siderosis might completely disappear by natural removal of the particles once exposure to the iron fume ceased or was considerably reduced. Stannosis due to the inhalation of tin fume or dust is another example of a benign pneumoconiosis (Robertson and Whitaker, 1955). A feature of stannosis compared with siderosis and fibrotic forms of pneumoconiosis is the particular density of the discrete opacities on the *x*-ray film, this being due to the high radio-opacity of tin (atomic weight 119 compared, for example, with iron 56).

Baritosis due to the inhalation of barium dust has long been accepted as a benign condition although the first case to be described (Fiori, 1926) was in a man who had symptoms and was

probably suffering from mixed dust pneumoconiosis from silica and barium. Subsequent writers, however, stressed the benign nature of baritosis, contrasting the lack of subjective symptoms and abnormal physical signs with the intensity of the radiological changes (Arrigoni, 1933; Feci, 1933; Preti and Talini, 1938; Spedini and Valdini, 1939; Rosmanith and Knöpfelmacher, 1957; Gomboš, 1957). As with stannosis, the intensity of the individual opacities on the radiograph is outstanding and is due to the high atomic weight of barium (137). With the exception of a brief description given at the International Congress on Occupational Health in Vienna (Doig, 1966), no cases have been described in Britain. The present communication gives more detail and also the results of follow-up examinations of some of the cases then described.

BARIUM: TOXICOLOGY AND USES

The two chief ores of barium are barytes (barite), BaSO₄, and witherite, BaCO₃, the former being commercially far the more important. Its greatest single use is in the manufacture of lithopone, a white pigment consisting of barium sulphate (66%) and zinc sulphide (34%), which is used in paint making. Barium sulphate is also used as an extender or filler for paper, textiles, leather, soap, rubber, and linoleum. It is used in oil drilling, in cements and plasters, particularly when high

radio-opacity is required, in ceramics, glass, and electronic valve manufacture. Various barium salts are used in the chemical and dyestuffs industries, in sugar refining, in pyrotechnics and signal lights, and as insecticides and rodenticides; metallic barium has a limited use in the manufacture of certain alloys.

The soluble compounds of barium are highly toxic, the fatal dose of the chloride according to Sollmann (1932) being 0.8 to 0.9 g. While it has been used in a few cases of accidental or deliberate poisoning in humans, very few cases of industrial poisoning have been reported. One was described by Kipper (1926) in a worker employed for several days crushing barium peroxide in very dusty conditions. The chief features of the illness were abdominal pain, vomiting, tachycardia, dyspnoea, cyanosis, and paralysis of the right arm and leg, death occurring on the third day. The dust at the mill contained BaO 14% and BaCO₃ 38% which, together with the peroxide, were presumably converted into the soluble chloride in the stomach.

While barium chloride is readily soluble in water (1:10), barium sulphate is characterized by its extreme insolubility. One hundred parts of cold water dissolve only 0.000115 parts of barium sulphate, and of hot water only 0.000285 parts, while 100 parts of 3% hydrochloric acid dissolve 0.006 parts. This property, together with its high radio-opacity, enables it to be used safely as an opaque medium in radiographic examination of the gastrointestinal, respiratory, and urinary tracts and sinuses. It would be expected that such an insoluble substance would be inert if inhaled into the lungs and, as has been stated, most descriptions of baritosis stress the absence of symptoms in conjunction with the very marked radiographic changes.

THE PROCESS

In 1947 I visited a small factory where barytes was ground. At that time there were 18 employees although normally the number was only 12. The premises consisted of two rooms, one about 10.7 m (35 ft) square by 3.9 m (13 ft) high called 'the wash', the other about 22.9 × 18.3 × 6.1 m to the eaves (75 × 60 × 20 ft), rising to 9.1 m (30 ft) at the apices of the two bays, called 'the mill'. The raw ore was brought to the factory by road in a very moist state, tipped on the floor of the wash, and charged into a hammer mill by shovelling. The heavier material was then separated from the lighter on a sloping table with a copious supply of water. By this simple means the barytes

was recovered in three grades, one practically pure and the others with increasing quantities of impurities.

Subsequent processes were carried out in the mill. There the two better grades were separately dried in a rotary drier and pulverized in a tube mill. After passing through air separators, from which insufficiently small particles were returned to the mill, the material was elevated to a storage hopper, fed to a mechanical bagging point, and bagged in paper sacks. The third grade was dried on a hot plate in the room, the material being raked manually more or less continuously. When dried, it was shovelled into a large heap and bagged by hand. These processes gave rise to large quantities of dust, there being a continual haze in the workroom. The main points of dust evolution were the raking and shovelling of the material on the hot plate, at mechanical and hand bagging, and to a less extent at charging and discharging the drier. Local exhaust ventilation was provided at the drier and at mechanical bagging but, especially at the latter point, was poor. No respirators were worn.

1947 EXAMINATIONS

In 1947, only five of the employees had been with the firm for more than three and a half years and these were examined. Their ages ranged from 24 to 61 (mean 48) years and their exposures to barytes 3½ to 15 (mean 7½) years. Three of the men were completely free of chest symptoms and had no abnormal physical signs on examination. The remaining two had slight coughs, in one associated with slight sputum and some emphysema, and in the other a few basal crepitations were present. In one case the chest radiograph showed increased lung markings and was classed as category Z. There were no discrete opacities in any of the films and none was thought to show any evidence of dust retention.

In 1952, the work had diminished considerably, being carried out on only two days weekly, and I made no examinations then.

1961 EXAMINATIONS

In 1961, grinding was again in progress for five days weekly and, once more, vast quantities of dust were being produced. I made clinical examinations of all 12 workers employed and radiological examinations of 11, one of the men, employed for only a month, having left the employment before being x-rayed.

These 11 workers comprised eight who had

been employed for 3½ to 18 (average 9) years, only one of whom had been examined by me in 1947. Their ages ranged from 26 to 45 (mean 32) years. None of them had been exposed to significant quantities of dust in previous occupations. With the exception of one man (employed for 3½ years) who had a slight occasional cough, all were free from symptoms. Abnormal physical signs were present in only one man, the foreman-manager (employed for 14 years), in whom crepitations, dispelled by cough, were heard at the right base. Curiously, his was the only normal radiograph of the group: radiographs of the other seven all showed pneumoconiosis (undoubted baritosis) of categories 2m, 3p, 3m, or 3n (ILO classification, 1958).

The remaining three men had working histories in this factory of only 1 year, 3½ months, and 1 month respectively, and none had been previously exposed to any significant quantity of dust. Their ages were 21, 24, and 56 years. Two admitted to having slight coughs, one had occasional sputum, but clinical examinations were negative and chest radiographs were normal.

1961 DUST COUNTS

Owing to the density of the dust clouds the konimeter was useless in estimating concentrations, all samples taken with this instrument being uncountable because of superimposition of the particles. Using a thermal precipitator the following results were obtained:

| | Particles per cu ml |
|--------------------------------------|------------------------|
| In wash, near outer wall | 2734 |
| Centre of mill | 3176 |
| Centre of mill | 3256 |
| Mill 1·1 m (4 ft) from bagging point | 11365 |

1961 ANALYSIS OF BARYTES

Quartz was not detected by *x*-ray diffraction in any of six samples. Total silica and total iron were estimated by chemical methods and were found in insignificant quantities, as shown below:

| | Total Silica % | Total Iron as Fe ₂ O ₃ % |
|--|----------------------|--|
| Raw ore | 0·27 | 0·03 |
| Ground barytes— | | |
| Highest grade | 0·07 | 0·03 |
| 2nd grade | 1·24 | 0·12 |
| 2nd grade | 1·62 | 0·12 |
| 3rd grade | 1·96 | 0·16 |
| Dust deposited from air on ledge centre of mill | 0·97 | 0·89 |

1963 EXAMINATIONS

In 1963, 18 months after the 1961 examinations, I repeated the clinical and radiological examinations of the workers at this factory. One man, who had been employed for one year in 1961, had left. Four new workers had been engaged so that the total was now 14. Among the 10 employees previously examined, two new cases of baritosis were discovered. One of these was in a man employed for only 21 months, mainly on bagging, whose radiograph, previously category 0, was now category 2m. The other, in a man with 1½ years' employment mainly at the very dusty work of drying at the hot plate and hand bagging, showed evidence of slight dust retention; his radiograph, previously category 0, was now category 1m. Thus, there were nine cases of baritosis aged 22 to 57 (mean 33·8) years who had worked in the factory for periods from 1·5 to 19·5 (mean 8·2) years. Four of them had formerly had some exposure to industrial dusts, but only for short and probably insignificant periods (drawer in brickworks for 1 year; drawer in brickworks for 2 years; coal miner for 3 years; stone dresser for 2 years). Three of them said they had slight or occasional cough and one of these said he always had some sputum. None had any dyspnoea and there were no other symptoms of ill-health except indigestion in one man (heartburn relieved by antacids). No abnormal signs were found in any of the men.

If the 1961 examinations were unexpected in disclosing the presence of well-marked baritosis in men with short exposures of 3·5, 4·5, and 5 years, the 1963 examinations were even more so in showing a slight case after only 1·5 years' work and a developed case after 1 year and 9 months. Indeed, in 1963, nine of the 10 men employed for more than 1·5 years had baritosis. I have not encountered in the literature any description of such severe findings. Lévi-Valensin and his colleagues (1966) found 57 cases of baritosis among 118 workers in a barytes grinding factory and described the risk as being proportional to the time spent in the factory—10% after 3 years' exposure, 58% after 10 years.

In these circumstances it seems surprising that one man should have been employed for more than 15 years without developing any sign of dust retention. This was the foreman-manager, who spent a considerable part of his time in his office, which did not communicate directly by window or door with the working premises. While his exposure to dust would not be as great as that of those who spent all their time in the workrooms,

it was nevertheless substantial, probably amounting to at least one-third to one-half of his time. At my visits I have found him in the factory as often as in his office, and I have seen him personally undertaking and supervising clearing of blockages, rectifying stoppages, and performing other highly dusty work. I find his completely normal radiograph after 15.5 years' exposure difficult to explain.

Table I summarizes the results of the 1963 examinations.

RADIOGRAPHIC APPEARANCES

Most authors, in describing baritosis, emphasize that the outstanding feature of the radiographs is the intense radio-opacity of the discrete opacities. These are almost always stated to be profusely and evenly disseminated throughout the lung fields. The appearance is always of a simple pneumoconiosis; no massive shadows have ever been recorded, but the opacities may be so numerous as to be almost confluent (Arrigoni, 1933). The individual nodules are generally spoken of as small, although in marked cases they may reach 4 or 5 mm in diameter. Their shape is not always circular. Feci (1933) speaks of a regular dissemination of small star-like shadows of marked opacity, and Gomboš (1957) mentions a background of fine reticular concretions of micronodules the size of fine sand, their edges thin and sharp, very contrasty, and well outlined.

In my series the intensity and profusion of the shadows varied. The above descriptions were applicable to the most developed cases (1, 2, 3, and 5). In these, the individual elements were very profuse and opaque. Their size varied from 1 to 4 mm, occasionally almost 5 mm, but most were 3 mm or smaller. They were mostly irregular in shape, some being reticular or dendritic, an exception being case 1, in whose film the elements were mainly rounded. Sometimes a number of dense fine points seemed to lie in a matrix of lesser

density. The general distribution in the lung fields was even, and the profusion such that the opacities were contiguous and overlapped, and attempts at counting the number per unit area were frustrated by inability to distinguish between individual opacities. In the earlier and less well-developed cases (4, 6, 7, 8, and 9), the shadows were almost all small and rounded, 1-2 mm, and were less dense.

There were no noteworthy abnormalities of the other thoracic structures. Hilar shadows were not enlarged, there was no mediastinal distortion, no pleural adhesions, and no evidence of pleural thickening with the possible exception of case 4 in whom the horizontal fissure was visible, not necessarily thickened, but this man almost certainly has an atelectatic middle lobe. The appearances of well established baritosis are similar to those of stannosis (Robertson and Whitaker, 1955; Robertson *et al.*, 1961).

The earlier appearances, however, are not characteristic. The discrete opacities in cases 7, 8, and 9 are no more dense than in silicosis or coal-worker's pneumoconiosis, from which conditions the radiographic picture cannot be distinguished. The films of the nine cases fall into three groups:

1. four well-developed cases with very characteristic appearances (cases 1, 2, 3, and 5, with exposures to barytes dust of 20, 15, 10.5, and 6.5 years);
2. two cases in which the number and density of the opacities are less than in group 1, but in which the density is greater than in cases of silicosis or coal-workers' pneumoconiosis (cases 4 and 6, with exposures of 8 and 6 years);
3. three cases in which the opacities are of no greater density than in cases of silicosis or coal-worker's pneumoconiosis (cases 7, 8, and 9, with exposures of 5, 1½, and 1½ years).

TABLE I
BARITOSIS CASES, 1963 EXAMINATIONS

| Case | Age | Employment (years) | | Smoking (cigs daily) | X-ray ILO Classification | X-ray Change since 1961 |
|------|-----|--------------------|------------------|----------------------|--------------------------|-------------------------|
| | | Bay Grinding | Other Dusty Work | | | |
| 1 | 40 | 20 | — | 40 | 3n | Not significant |
| 2 | 35 | 15 | 1 | 0 | 3n | Not significant |
| 3 | 34 | 10½ | 2 | 20 | 3m | Not significant |
| 4 | 28 | 8 | 3 | 0 | 3m | Opacities more numerous |
| 5 | 32 | 6½ | — | 15 | 3m | Not significant |
| 6 | 28 | 6 | 2 | 0 | 3p | Not significant |
| 7 | 28 | 5 | — | 30 | 2m | Not significant |
| 8 | 57 | 1½ | — | 10 | 1m | Progression from cat. 0 |
| 9 | 22 | 1½ | — | 15 | 2m | Progression from cat. 0 |

FOLLOW-UP OF CASES

After the 1961 examinations, efforts to persuade the firm to deal effectively with the dust problem were intensified. The management made conscientious attempts to comply, experimenting with various types of enclosures and hoods with improved local exhaust ventilation at the points of dust evolution. None of these proved entirely satisfactory, and an additional difficulty was that, the firm being situated in a densely populated built-up area, complaints were being made by local residents and the staff of a nearby school about dust emitted from the discharge of the ventilation system. Their financial resources being limited, the firm decided to cease production early in 1964.

I attempted to keep in touch with the baritosis cases in 1966, 1969, and 1973. All trace had been lost of one man in 1966, and three others could not be persuaded to submit to re-examination. The five remaining men have been followed up over these years and these include the most pronounced cases. Table II summarizes the results of spirometric and radiographic examinations of these five men over the years 1963, 1966, 1969, and 1973.

LUNG FUNCTION TESTS

The lung function tests are particularly interesting in cases 2, 3, and 5 where, in spite of the vast quantities of dust present in the lungs as shown by the radiographs, the results of the tests are as

good as or even better than the predicted normal values, thus stressing the contrast, already alluded to, between the severity of the radiographic changes and the clinical picture. The performances of cases 1 and 4 are mediocre. Case 1 is poorly developed, neglected individual, who suffers from major epilepsy and is an alcoholic and heavy smoker. Case 4 is overweight and probably has had an atelectatic and consequently fibrotic right middle lobe since early childhood. All five men were capable in 1963 of carrying out very hard physical work, including carrying hundred-weight bags of material from the bagging point, stacking them, and loading them on lorries. Since the factory closed, one man (case 1) has remained unemployed but the others are in active employment and capable of hard effort.

CLEARING OF RADIOLOGICAL OPACITIES

Several authors have noted that the discrete opacities in baritosis cleared slowly over the years (Wende, 1956), and undoubtedly the most interesting outcome of the follow-up of my cases has been the regression of the radiographic abnormalities since the work with barytes ceased. The improvement was suggestive in 1966, just over two years after the last exposure, was quite evident in 1969, and marked in 1973. The individual elements are affected mainly by diminished profusion and decreased density, and only to a less extent by reduction of size. During clearing, the edges of the opacities become less sharp. This had been

TABLE II

LUNG FUNCTION TESTS: CASES 1 to 5, 1963 to 1973

| Case | Date | Age | Peak Flow Rate (ml/min) | | VC (l.) | | FEV (l.) | | FEV × 100 VC | X-ray Category |
|------|------|-----|-------------------------|---------------|----------------------|---------------|----------------------|---------------|-----------------|-------------------|
| | | | Actual (Predict.) | % Predict. | Actual (Predict.) | % Predict. | Actual (Predict.) | % Predict. | | |
| 1 | 1963 | 40 | — | — | 2.9 (4.15) | 70 | 2.4 (3.35) | 71 | 83 | 3n |
| | 1966 | 43 | 440(550) | 80 | 3.3 (4.1) | 79 | 2.6 (3.25) | 80 | 78 | 3n |
| | 1969 | 46 | 400(540) | 74 | 2.75(4.0) | 69 | 2.1 (3.15) | 67 | 76 | 2m |
| | 1973 | 50 | 440(530) | 83 | 3.05(3.9) | 78 | 2.3 (3.05) | 75 | 75 | 1m |
| 2 | 1963 | 35 | 650(580) | 112 | 4.05(4.55) | 89 | 3.45(3.7) | 93 | 90 | 3n |
| | 1966 | 39 | 630(570) | 111 | 5.1 (4.45) | 115 | 4.2 (3.55) | 118 | 82 | 3n |
| | 1969 | 42 | 600(565) | 106 | 4.45(4.4) | 100 | 3.35(3.5) | 96 | 80 | 3n |
| | 1973 | 45 | 680(560) | 121 | 4.4 (4.3) | 102 | 3.4 (3.4) | 100 | 77 | 3n |
| 3 | 1963 | 34 | 610(555) | 110 | 4.4 (4.05) | 109 | 3.6 (3.35) | 103 | 82 | 3m |
| | 1969 | 39 | 610(540) | 113 | 3.6 (3.95) | 91 | 3.2 (3.2) | 100 | 89 | 2m |
| | 1973 | 44 | 630(525) | 120 | 3.75(3.80) | 99 | 3.05(3.1) | 98 | 81 | 1m |
| 4 | 1963 | 28 | 480(585) | 82 | 3.8 (4.6) | 83 | 3.2 (3.75) | 85 | 84 | 3m |
| | 1969 | 35 | 560(575) | 97 | 3.8 (4.45) | 85 | 3.1 (3.55) | 87 | 82 | 2m |
| | 1973 | 38 | 580(565) | 103 | 3.8 (4.4) | 86 | 3.4 (3.45) | 99 | 89 | 1m |
| 5 | 1963 | 32 | 705(590) | 119 | 4.2 (4.7) | 89 | — | — | — | 3n |
| | 1966 | 35 | 640(585) | 109 | 4.7 (4.6) | 102 | 3.9 (3.75) | 104 | 83 | 3n |
| | 1969 | 38 | 620(575) | 108 | 3.65(4.5) | 81 | 3.2 (3.55) | 90 | 88 | 3n |
| | 1973 | 41 | 640(565) | 113 | 4.2 (4.4) | 93 | 3.7 (3.5) | 106 | 88 | 2m |

Predicted values according to Cotes (1965).

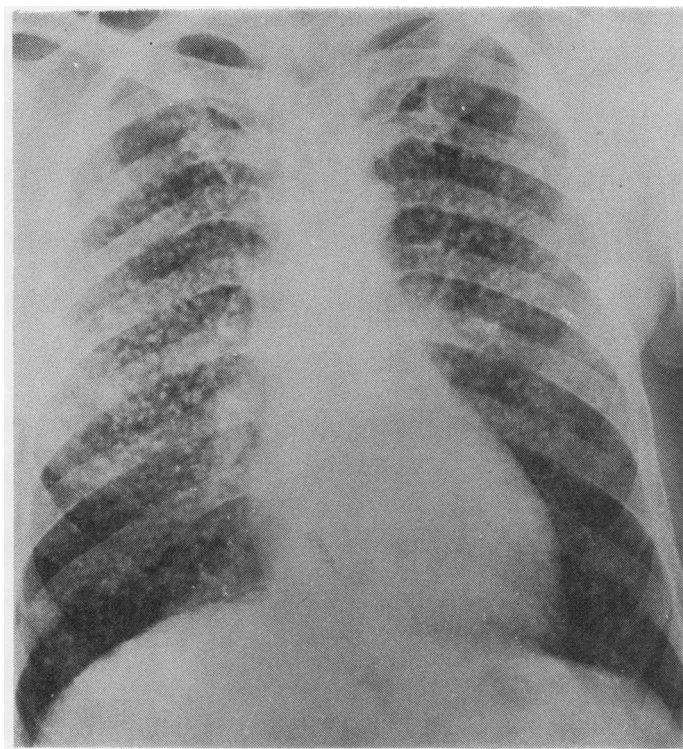


FIG. 1. *Case 1, 1961.*

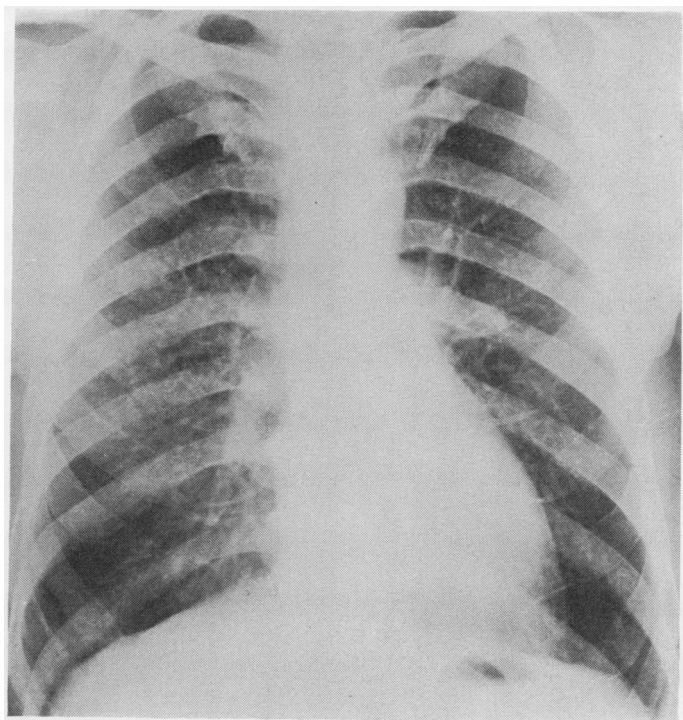


FIG. 2. *Case 1, 1973.*

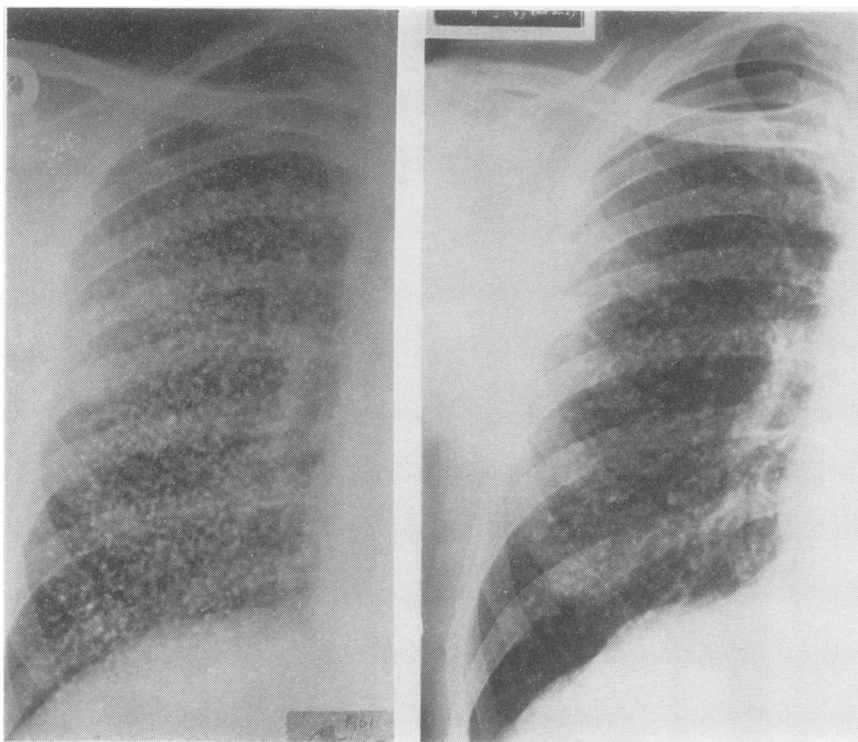


FIG. 3. Case 2: (left) 1961, (right) 1973.

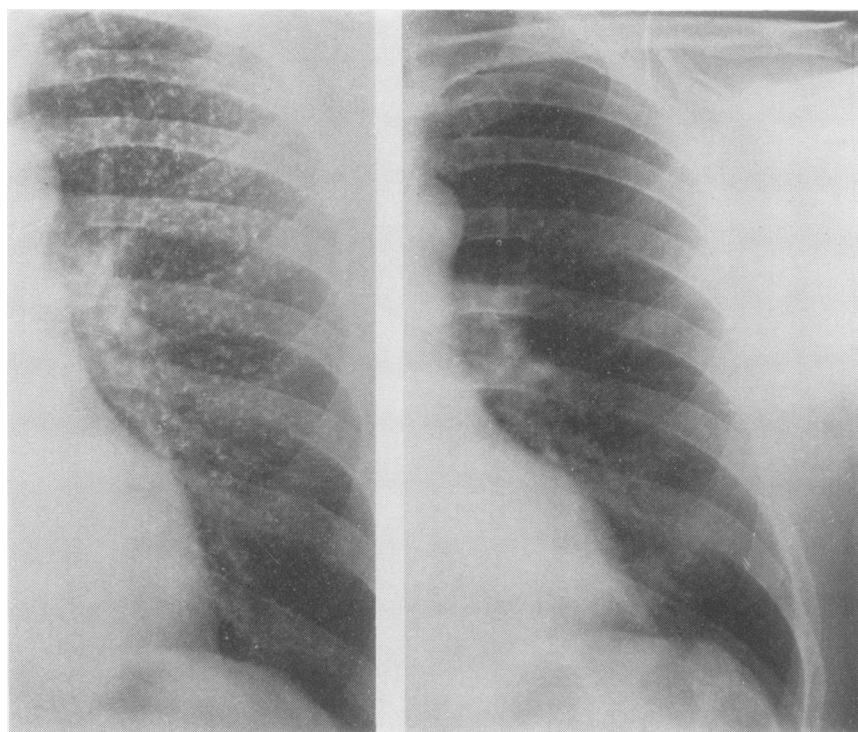


FIG. 4. Case 3: (left) 1961, (right) 1973.

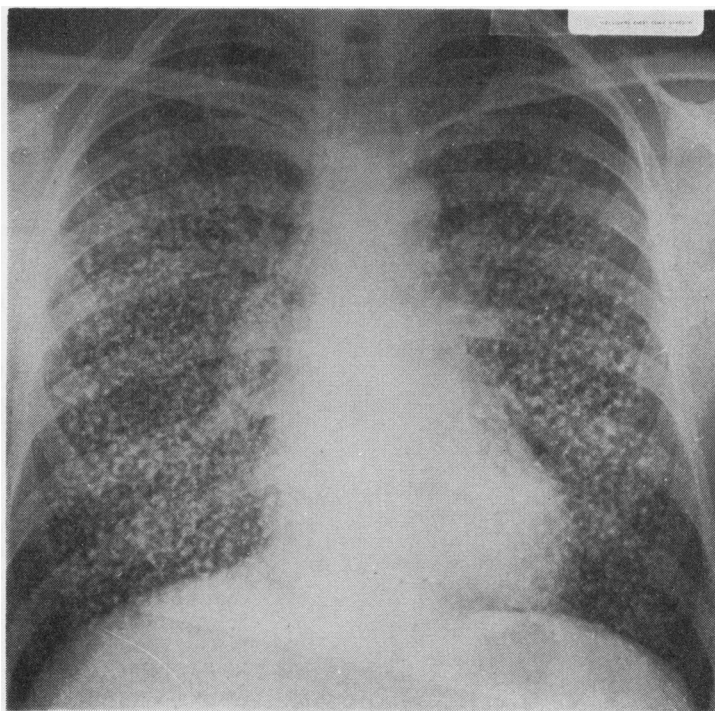


FIG. 5. *Case 5*, 1963.

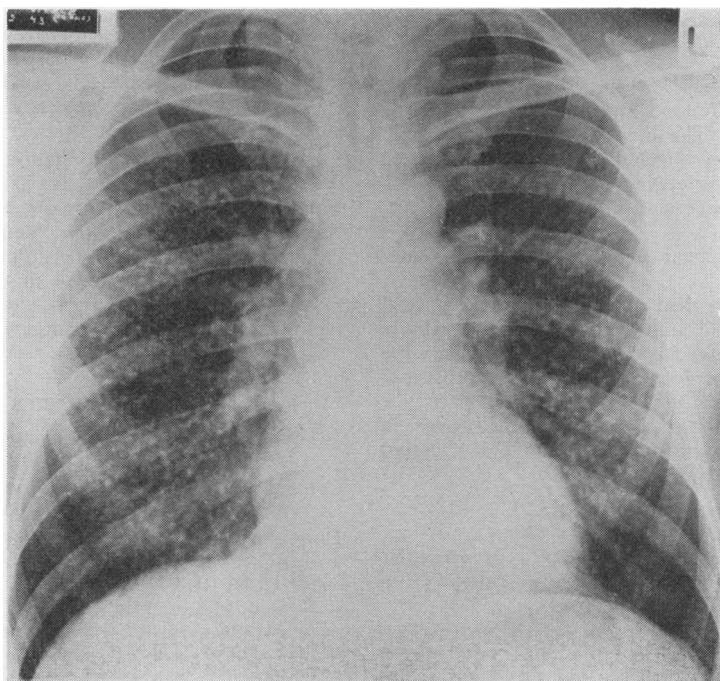


FIG. 6. *Case 5*, 1973.

noted by Doig and McLaughlin (1948) in regard to the clearing of the shadows of welders' siderosis, and they then suggested that the blurring of the edges was associated with local congestion round the dust foci, probably associated with the supply and removal of scavenging phagocytes in the area. Although some diminution in size can take place, the principal manner of disappearance of the shadows would seem to be a gradual fading away by lessening density.

The radiological progress can be described briefly as follows:

Case 1

- 1947 Normal
- 1957 Pneumoconiosis category 2m, the individual shadows being of no greater density than in the average case of silicosis
- 1961 Pneumoconiosis category 3n; lung fields packed with larger, dense, mainly circular opacities (Fig. 1)
- 1963 Similar
- 1966 Some slight clearing, especially in upper and lower thirds of both lung fields
- 1969 Further clearing; shadows less dense and less profuse—category 2
- 1973 Marked clearing; shadows now mainly confined to mid-third of right lung, density no more than in early silicosis—category 1m (Fig. 2)

Case 2

- 1961 This, and case 5, show the most intense simple pneumoconiotic changes seen by the author. The lung fields are packed with very dense, irregularly shaped, discrete (though overlapping in places) shadows—category 3n (Fig. 3a)
- 1963 Similar
- 1966 Opacities appear slightly less profuse—category 3n
- 1969 Not a great deal of change but the overall suggestion of improvement is quite definite in the infraclavicular areas where the shadows are less dense and less profuse—category still 3n
- 1973 Further definite improvement all over in density and profusion and to a less extent in size—category 3n (Fig. 3b)

Case 3

- 1961 Very dense discrete shadows of irregular shape throughout both lungs—category 3m (Fig. 4a)
- 1963 Similar
- 1969 Marked clearing in both lungs in all areas, affecting size, density, and profusion—category 2m

- 1973 Further clearing, left lung now practically normal; opacities still numerous but of no greater density than an average silicosis—category 1m (Fig. 4b)

Case 4

- 1961 Numerous small rounded shadows in both lungs—category 2m; opacity below right hilum suggests old right mid-lobe atelectasis
- 1963 Opacities more numerous—category 3m
- 1969 Some clearing; shadows less dense and more blurred in outline
- 1973 Definite improvement. Obesity makes reading difficult; film shows some increased lung markings but few discrete opacities—category 1m

Case 5

- 1961 Film comparable to that of case 2 (1961), showing very numerous extremely dense opacities packed so closely together that comparatively little air-containing lung shows between them—category 3n
- 1963 Similar (Fig. 5)
- 1966 Radiographic technique different, making film difficult to compare with previous ones but opacities seem less profuse—category still 3n
- 1969 Little definite change since 1966 but compared with 1961 and 1963 films there is a blurring and lessened profusion of the opacities—category 3n still
- 1973 Very marked improvement. Shadows less numerous, much less dense, and smaller. Clearing especially marked in outer thirds of both lungs—category 2m (Fig. 6)

I am greatly indebted to many friends and former colleagues, including Dr. E. S. Blackadder, of the Employment Medical Advisory Service, Drs. W. R. Brown and J. Black, of the Pneumoconiosis Medical Panel, Dr. J. Cuthbert, consultant chest physician, and others for their interest in these cases and help in various ways, and to Miss Rachel McIntyre for typing and retyping the manuscript.

REFERENCES

- Arrigoni, A. (1933). La pneumoconiosi da baria. *Medicina del Lavoro*, **24**, 461.
- Cotes, J. E. (1965). *Lung Function: Assessment and Application in Medicine*. Blackwell, Oxford.
- Doig, A. T. (1966). Baritosis. *Proceedings of the XVth International Congress on Occupational Health, Vienna*, A III, **149**, 693.
- and McLaughlin, A. I. G. (1936). X-Ray appearances of the lungs of electric arc welders. *Lancet*, **1**, 771.
- and — (1948). Clearing of X-ray shadows in welders' siderosis. *Lancet*, **1**, 789.

- Feci, L. (1933). La pneumoconiosi nei lavoratori di barite. *Radiologia Medica*, **20**, 620.
- Fiori, E. (1926). Contributo alla clinica e alla radiologia delle pneumoconiosi rare. *Ospedale Maggiore*, 3 s., **14**, 78. Quoted in *Occupation and Health*, Supplement (1938), Section 4, *Pneumoconiosis*, p. 21. International Labour Office, Geneva.
- Gomboš, B. (1957). Pulmonary nodulation from inhalation of barium dust. (Czech.) *Pracovní Lékařství*, **9**, 399.
- Kipper, F. (1926). Eine gewerbliche Bariumvergiftung. (*Ärztliche Sachverständigenzeitung*, **32**(6), 71. Abstract in *Münchener medizinische Wochenschrift*, **73**, 2180).
- Lévi-Valensi, P., Drif, M., Dat, A., and Hadjadj, G. (1966). A propos de 57 observations de barytose pulmonaire (résultats et une enquête systématique dans une usine de baryte). *Journal Française de Médecine et Chirurgie Thoraciques*, **20**, 443.
- Preti, L. and Talini, P. C. (1938). Barium pneumoconiosis from the radiological point of view. *Report of the VIIIth International Congress on Industrial Accidents and Occupational Diseases, Frankfurt*, vol 2, p. 963. Thieme, Leipzig.
- Robertson, A. J. and Whitaker, P. H. (1955). Radiological changes in pneumoconiosis due to tin oxide. *Journal of the Faculty of Radiologists*, **6**, 224.
- , Rivers, D., Nagelschmidt, G. and Duncumb, P. (1961). Stannosis: benign pneumoconiosis due to tin oxide. *Lancet*, **1**, 1089.
- Rosmanith, J. and Knöpfelmacher, E. (1957). Another case of pneumoconiosis caused by barium sulphate. (Czech.) *Pracovní Lékařství*, **9**, 140.
- Sollmann, T. H. (1932). *A Manual of Pharmacology*, 4th ed. Saunders, Philadelphia.
- Spedini, F. and Valdini, P. L. (1939). Contributo allo studio della pneumoconiosi da barite. *Radiologia Medica*, **26**, 1.
- Wende, E. (1956). Pneumokoniose bei Baryt- und Lithoponarbeitern. *Archiv für Gewerbepathologie und Gewerbehigiene*, **15**, 171.

Requests for reprints to: Dr. A. T. Doig, 11 Victoria Road, Lenzie, Nr. Glasgow G66 5AN.