

Pulmonary Kaposi's sarcoma in patients with acquired immune deficiency syndrome: a clinicopathological study

P J FOURET, J L TOUBOUL, C M MAYAUD, G M AKOUN, J ROLAND

From the Service d'Anatomie Pathologique and the Service de Pneumologie et de Soins Intensifs Respiratoires, Hôpital Tenon, Paris

ABSTRACT Pulmonary Kaposi's sarcoma may contribute to respiratory dysfunction in patients with acquired immune deficiency syndrome (AIDS) and features of pneumonitis. Opportunistic infections are readily recognised in endoscopic material, but pulmonary Kaposi's sarcoma is easily missed, so that patients are deprived of specific treatment. The clinical and pathological findings from nine cases of pulmonary Kaposi's sarcoma have been reviewed; these were found among 847 patients with AIDS and pneumonitis undergoing fiberoptic bronchoscopy and bronchoalveolar lavage. Diagnosis was established before death in eight patients (in five by bronchial biopsy and in three by open lung biopsy). Examination of lavage fluid showed alveolar haemorrhage in six patients. It is concluded that: (1) fiberoptic bronchoscopy may be useful in the diagnosis of endobronchial lesions of Kaposi's sarcoma; (2) alveolar haemorrhage in patients with AIDS is suggestive of pulmonary Kaposi's sarcoma. Factors that may cause difficulties in diagnosis include the focal nature of some lesions and the pleural or parenchymatous location of others. In addition, in the lung as in the skin, the early stages of Kaposi's sarcoma resemble granulation tissue. Such lesions are far more difficult to recognise than is the late nodular stage.

The epidemic of Kaposi's sarcoma in young homosexual men first described in 1982 is now well established.¹ In patients with AIDS Kaposi's sarcoma is a multicentric neoplastic process that frequently affects lymph nodes and the gastrointestinal tract. Lesions may also occur in the lung²⁻⁶ and are a cause of pulmonary infiltrates and respiratory failure. Accurate diagnosis is essential because chemotherapy or radiotherapy appears to provide palliation.⁵ Bronchopulmonary Kaposi's sarcoma, however, is often diagnosed at necropsy rather than by bronchial or transbronchial biopsy.^{4,5} Since asymptomatic sarcomas⁷ are not the sole cause of this discrepancy, there is a need to review the clinical and pathological approach to diagnosis.

During the past five years we have had the opportunity to study nine cases of pulmonary Kaposi's sarcoma. Diagnosis was established before death in eight patients, five of whom were diagnosed by bronchial biopsy and three by open lung biopsy. We report here

the clinicopathological features of these cases, with emphasis on the findings obtained by fiberoptic bronchoscopy, and the difficulties encountered in diagnosis.

Methods

During the five years up to December 1985 847 patients with AIDS and pneumonitis were referred for bronchoscopy. All patients met the diagnostic criteria for AIDS defined by the Centers for Disease Control.⁸ During bronchoscopy examination of the tracheobronchial tree was followed by bronchoalveolar lavage and biopsy of suspected lesions.

Pertinent clinical data were obtained from the clinical records. All the material from the selected patients was reviewed, and consisted of 14 specimens of lavage fluid and material from six bronchial biopsies, three pleural biopsies, six open lung biopsies, and one necropsy.

Bronchoalveolar lavage cytocentrifuge slide preparations were stained with Giemsa and methenamine silver for performing differential cell counts and detecting opportunistic infections. In addition, the

Address for reprint requests: Dr P J Fouret, Service d' Anatomie Pathologique, 4 Rue de la Chine, 75020 Paris, France.

Accepted 17 November 1986

Clinical and pathological features of nine patients with pulmonary Kaposi's sarcoma

Case No	Age	Extrathoracic Kaposi's sarcoma					Diagnostic procedure			
		Skin	Lymph node	Gastro-intestinal tract	Endoscopic appearance	Pleural effusion	Iron content in alveolar macrophages	Bronchial biopsy	Open lung biopsy	Necropsy
1	31	+	+	-	C	-	2+	+*	ND	ND
2	44	+	+	+	C	-	3+	+†	ND	ND
3	28	+	+	-	C	-	3+	ND	+	ND
4	30	-	-	-	UC	-	2+	+†	+	ND
5	28	+	-	-	C	+	-	+*	+	ND
6	45	+	+	-	C	+	-	ND	+	ND
7	37	+	+	+	S	-	2+	ND	ND	+
8	26	+	-	-	C	+	2+	+†	ND	ND
9	53	+	-	+	N	-	-	-	+	ND

*Late stage.

†Early stage.

C—characteristic; UC—uncharacteristic; S—suggestive; N—normal; ND—not done.

haemosiderin content of alveolar macrophages was estimated on Perls' stained slides on a three point scale as follows: 1+ = faint blue staining; 2+ = medium colour intensity; 3+ = deep blue staining.

The histological sections were studied with haematoxylin-eosin-safran, methenamine-silver, and Perls' stains. Three open lung biopsy specimens were embedded in plastic resin and stained with Giemsa and Masson's trichrome. Samples were also fixed in glutaraldehyde and embedded in Epon for electron microscopy.

Results

Bronchopulmonary Kaposi's sarcoma was diagnosed histologically in nine of the 84 patients, 34 of whom had extrapulmonary sarcomas. In a further three patients with suggestive or characteristic bronchoscopic appearances, the diagnosis could not be confirmed histologically.

CLINICAL FEATURES

The mean age of the patients was 35.7 (SEM 3.0) years. Eight were homosexual men, and one man, from Zaire, had had frequent sexual contact with African prostitutes.

All but one patient had cutaneous or mucocutaneous Kaposi's sarcoma and six patients also had sarcoma affecting lymph nodes or gastro-intestinal tract or both (table). The mean duration of cutaneous disease before diagnosis of bronchopulmonary Kaposi's sarcoma was 10.2 (SEM 2.7) months (range 1–23 months). In four patients the cutaneous lesions were stable, but in four others the lesions were rapidly growing. The patient with neither mucocutaneous nor visceral extrathoracic Kaposi's sarcoma when the lung sample was taken had had *Pneumocystis carinii* pneumonia 16 months before. One month after presentation, however, a cutaneous biopsy showed the early patch stage of Kaposi's sarcoma.

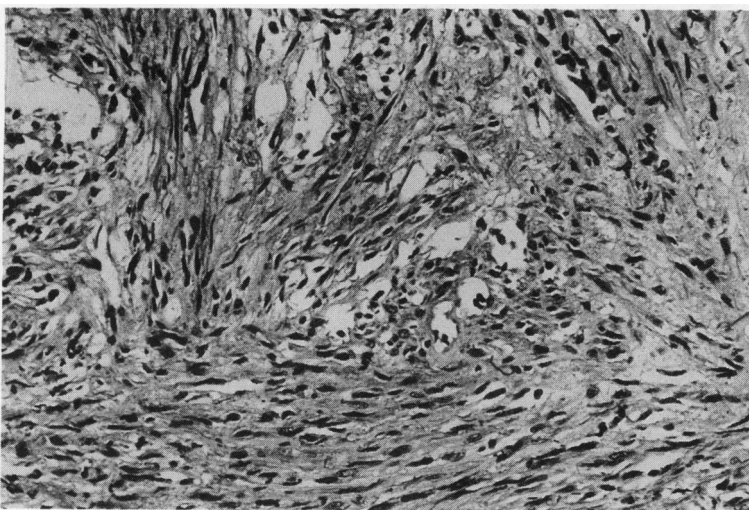


Fig 1 Kaposi's sarcoma in bronchial biopsy specimen: nodular stage. Spindle cells in strands and some capillary or slit like vessels are seen. (Haematoxylin and eosin.)

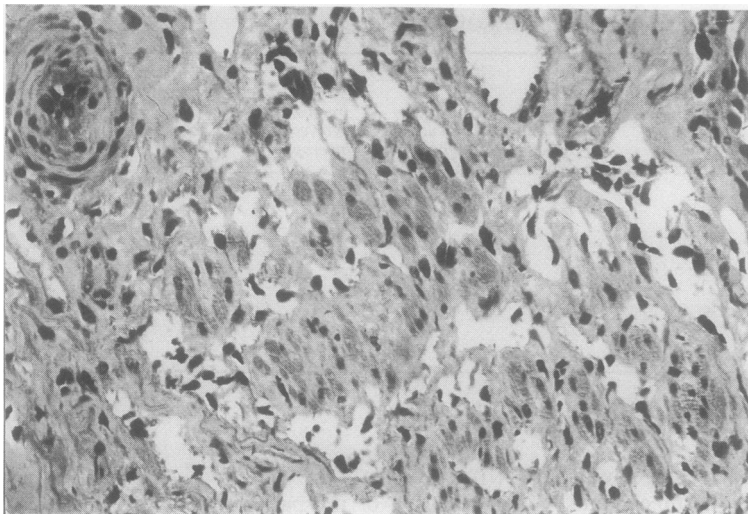


Fig 2 *Kaposi's sarcoma in bronchial biopsy specimen: early patch stage. The tangled appearance is due to the numerous dilated, irregularly shaped capillary vessels between the cells of the muscle coat. (Haematoxylin and eosin.)*

Respiratory signs and symptoms included cough in five cases, dyspnoea in eight and haemoptysis in one. Radiologically, there was a diffuse infiltrate in seven cases and a localised infiltrate in two. In five patients infiltrates had been present three months before bronchoscopy. Eight patients were afebrile but one, with bacterial pneumonia, had a temperature of more than 38.0°C. Pleural effusions were present in three patients, two of whom underwent decortication for recurrent effusion. At thoracentesis the fluid was haemorrhagic on each occasion. Pleural biopsies showed no abnormality.

BRONCHOALVEOLAR LAVAGE FLUID

Alveolar haemorrhage was diagnosed in six patients (table) on the basis of numerous (more than 30%)

haemosiderin laden macrophages in the lavage fluid. In the fluid from the other 78 patients, of whom three had pathologically documented pulmonary Kaposi's sarcoma, iron was either absent or minimal. There was no significant difference in percentage of lymphocytes in the lavage fluid from the nine patients with pulmonary Kaposi's sarcoma and in that from 69 other patients with AIDS. *Candida* was present in fluid from one patient, and cytomegalovirus and *Mycobacterium tuberculosis* were cultured from another.

ENDOSCOPIC APPEARANCE AND BRONCHIAL BIOPSIES

Fibreoptic bronchoscopy showed multiple, discrete, raised, violaceous, or bright red tracheobronchial

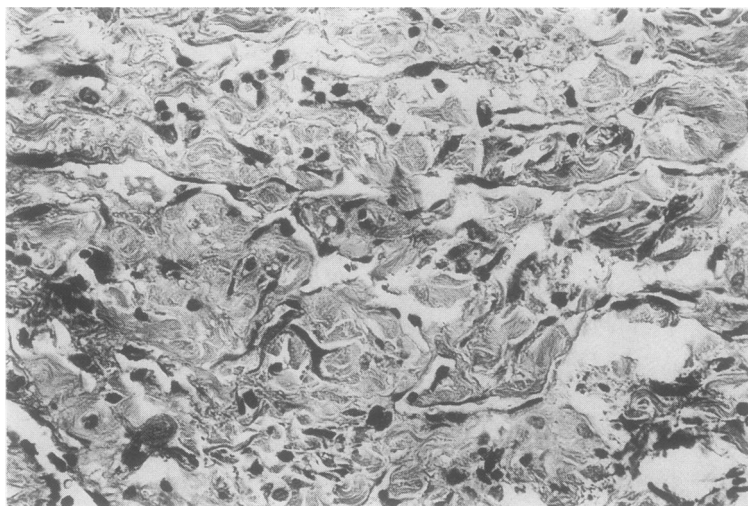


Fig 3 *Early patch stage Kaposi's sarcoma in open lung biopsy specimen. Very few endothelial cell nuclei can be seen. (Haematoxylin and eosin.)*

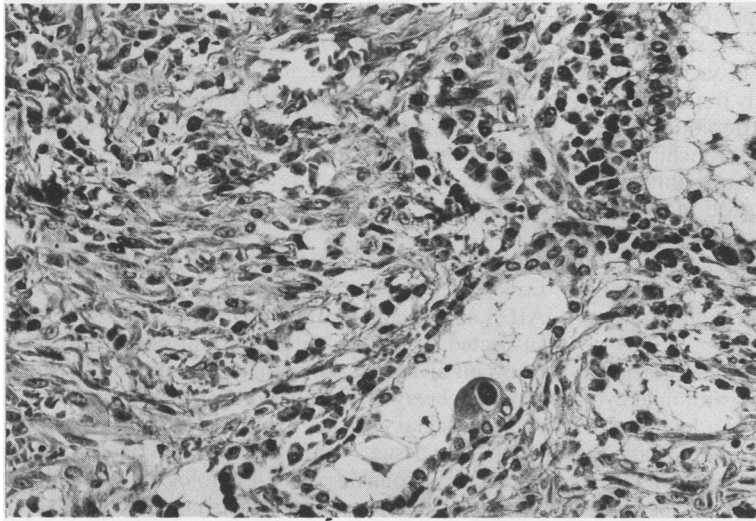


Fig 4 *Open lung biopsy specimen showing exogenous lipid pneumonia with numerous fat droplets filling bronchial lumens, a cell with an intranuclear inclusion related to cytomegalovirus infection, and Kaposi's sarcoma on the left. (Haematoxylin and eosin.)*

lesions, which were considered characteristic in six patients and suggestive in one. In one other patient we observed lesions were not suggestive, although biopsy was diagnostic. The tracheobronchial tree was normal in one patient.

Bronchial biopsy was diagnostic in five patients. In two cases lesions were at the late nodular stage (fig 1), the histological appearance varying from fibroblastic lesion to angiomatous lesion with transitional areas. In three other cases the changes were more discrete and consisted of lesions at the early patch or plaque stages (fig 2), on the basis of Ackermann's criteria.^{9 10} Characteristic lesions were found in some sections only. There was an increase in the number of the capillary vessels in the lamina propria, and careful examination showed that some were irregularly shaped

with jagged, angular outlines. Such vessels were found near an intact surface epithelium or more deeply situated, sometimes interlaced with the cells of the muscle coat. The capillaries were lined by a single layer of cells showing no nuclear atypia or mitotic activity, and were often wide or filled with crushed endothelial cells. These vessels were surrounded by prominent spindle cells, sometimes forming rudimentary fascicles, or by rounded cells resembling endothelial cells. A few plasma cells were also present; haemosiderin deposits were observed in all three cases and extravasated red cells in one.

OPEN LUNG BIOPSY

Kaposi's sarcoma lesions affected the lung parenchyma alone in two cases, predominantly the pleura

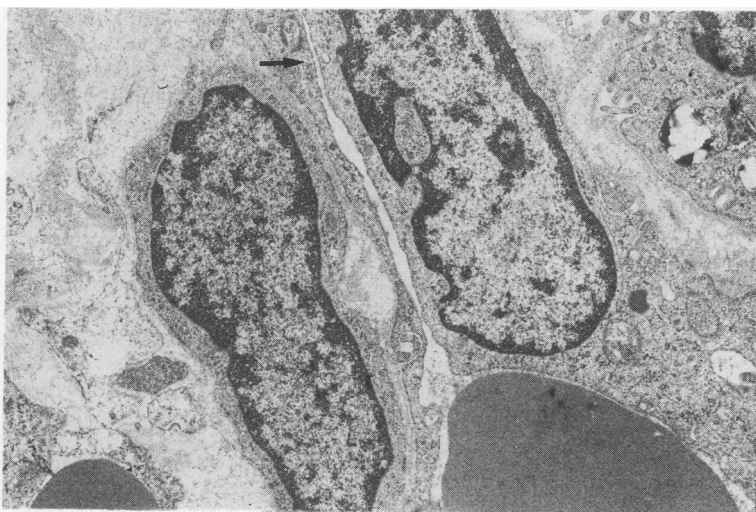

Fig 5 *Electron micrograph of an area thought to be suspicious for early Kaposi's sarcoma, showing a cleftlike vascular lumen (arrow) that was not apparent from light microscopy. (× 7000.)*

in two, and both parenchyma and pleura in one. In the parenchyma there was a tendency for spreading to occur along interlobular septa and bronchovascular connective tissue, where tumour cells frequently surrounded the outer part of the periarterial adventitia and invaded the lamina propria of bronchi. In the distal parenchyma the interstitium was infiltrated, and type 2 pneumocytes were entrapped in the more advanced lesions with obliteration of the air spaces. In addition to fully developed angiomatous or fibroblastic tumours, lesions at the early patch stage were occasionally seen in interlobular septa and periarterial fibrous tissue (fig 3).

Associated changes included haemosiderosis in two cases and exogenous lipid pneumonia with mild cytomegalovirus pneumonitis in one (fig 4). In this case, where there was also a heavy lymphoid infiltrate, the histological picture was initially misinterpreted as interstitial pneumonitis. In two other cases there were focal lymphoid infiltrates in bronchovascular connective tissue pathways and interlobular septa in areas unaffected by Kaposi's sarcoma.

Electron microscopy confirmed the differentiation, at least in part, of lesions at their late stage into capillary vessels lined by a single layer of endothelial cells and surrounded by spindle shaped cells. Ultrastructural examination was also helpful in showing erythrophagocytosis by endothelial or fibroblast-like cells. This infrequent finding, together with differentiation into capillaries, was observed in periarterial adventitia, where numerous extravasated red blood cells and spindle cells permeating the interstices between collagen bundles suggested an early stage Kaposi's sarcoma (fig 5).

TREATMENT

Four patients had been treated previously for extrathoracic lesions. One benefited from successful pleural decortication. Initial chemotherapy (α interferon or VP16 (etoposide)) was changed to etoposide or bleomycin in two patients who did not respond to their initial treatment, but they died four and seven months later. One received palliative treatment with vinblastine and was seen without respiratory symptoms seven months later. Among patients who received treatment for lung lesions, α interferon or etoposide was effective in reversing the pulmonary morbidity in two. These patients died of toxoplasmosis or aspiration pneumonia three and 18 months later.

NECROPSY

Diagnosis was made only at necropsy in one case. The lungs weighed 1250 and 970 g. Violaceous nodules measuring 0.5 cm in diameter affected the pleura, the parenchyma, and the tracheobronchial tree. Histolog-

ically, there were mature fibroblastic or angiomatous lesions, but no opportunistic infection or alveolar haemorrhage was seen. Lesions were also found retroperitoneal and mediastinal lymph nodes, and the upper gastrointestinal tract with foci of mural haemorrhage.

Discussion

The present study shows that pulmonary Kaposi's sarcoma may be recognised in living patients with AIDS and pneumonitis. This complication should be suspected in patients with recurrent pleural effusions or occult alveolar haemorrhage revealed by bronchoalveolar lavage. Definite diagnosis of cases with endobronchial lesions may be established when adequate tissue samples are obtained during fibreoptic bronchoscopy. Pathologists should be aware of the existence of early patch or plaque lesions, which are more difficult to diagnose than the late nodular stage.

Pulmonary Kaposi's sarcoma is not confined to terminally ill patients, and there is no relationship between pulmonary Kaposi's sarcoma and the extent or pace of progression of cutaneous disease, although a pulmonary presentation without concomitant extrathoracic lesions has seldom been reported.^{3 11 12} Although the clinical features and radiographic changes seen in the various lung disorders associated with AIDS tend to be non-specific and although *P. carinii* pneumonia is slowly progressive in this condition,¹³ patients with opportunistic infections usually present with fever and with pulmonary infiltrates of short duration. By contrast, five of our patients were afebrile, and presented with infiltrates of about three months' duration.

Pleural effusions are an unusual finding in patients with AIDS, and seem to be associated with the lesions of pleural Kaposi's sarcoma. Such effusions are blood stained and unresponsive to medical treatment.^{5 14} A pleural effusion in one of our patients without Kaposi's sarcoma was due to *Mycobacterium tuberculosis* infection.¹⁵ Owing to the patchy nature of the lesions, pleural Kaposi's sarcoma lesions cannot be diagnosed reliably by closed pleural biopsy,¹⁴ and the diagnosis is usually made from tissue obtained during decortication.

Bronchoalveolar lavage is a safe method of assessing alveolar cell content¹⁶ and may be helpful in revealing occult alveolar haemorrhage, which is an important complication of Kaposi's sarcoma involving the lung. Severe pulmonary haemorrhage on the other hand, may be associated with either bacterial pneumonia (due to *Pseudomonas* or *Staphylococcus*) or Kaposi's sarcoma.¹⁷ Although alveolar haemorrhage may also occur in thrombocytopenia,

patients,¹⁸ we believe that this finding greatly increases the likelihood of pulmonary Kaposi's sarcoma. In our study alveolar haemorrhage was found only in patients with pulmonary Kaposi's sarcoma, and this should be suspected when alveolar haemorrhage is diagnosed in patients with extrathoracic tumours.¹⁹ Moreover, in cases of known pulmonary Kaposi's sarcoma, alveolar haemorrhage may point to an active and life threatening disease. Absence of alveolar haemorrhage, however, does not exclude pulmonary Kaposi's sarcoma, particularly when the endoscopic appearance is suggestive.

Lavage is also useful in diagnosing opportunistic infections in AIDS.²⁰ Our failure to demonstrate opportunistic infections in nearly all our patients underlines the contribution of Kaposi's sarcoma to pulmonary dysfunction, and indicates that a non-diagnostic lavage suggests a process other than an opportunistic infection.

Lymphocytosis is observed in lavage fluid from patients with AIDS, whether or not opportunistic infection is present.²¹ Since there is no difference in the lymphocyte content of lavage fluid from patients with and without Kaposi's sarcoma, infiltration of the tumour alone cannot explain the presence of the lymphocytes. Such lymphocytosis may be related to the mild lymphoid infiltrates in bronchovascular connective tissue and interlobular septa in two of our patients. A larger and sometimes nodular lymphoid infiltration in these areas has been named pulmonary lymphoid hyperplasia,²² and we have observed this in the biopsy material from one patient with the AIDS related complex. In this case it was associated with an infiltration of lymphocytes bearing the T8 phenotype into many of the viscera, and with an excess of T8 + lymphocytes in lavage returns.²³

Bright red or violaceous endobronchial lesions are characteristic of Kaposi's sarcoma.⁶ To obtain adequate specimens for diagnostic purposes, careful examination of the bronchi is important because Kaposi's sarcoma lesions are focal and discrete, and may easily be overlooked; but also the bronchi may appear normal.¹¹ Although the vascular appearance of the lesions and fear of excessive bleeding may cause reluctance to take a sufficiently large sample,⁶ excessive bleeding did not occur after biopsy of lesions in any of our patients.

In patients with endobronchial lesions, fully developed nodular lesions can be diagnosed with confidence, but difficulty is encountered in making the diagnosis at earlier stages. As Ackermann pointed out, however, the patch or plaque stage of Kaposi's sarcoma is distinctive,^{9,10} although the recent increased incidence of aggressive Kaposi's sarcoma may cause a tendency toward overdiagnosis.¹³ It should be emphasised that there are no specific or

unequivocal cytological markers of Kaposi's sarcoma.⁵ Granulation tissue may mimic the early stages, and some non-specific scars show a prominent vascular proliferation with a plasma cell infiltrate, erythrocyte extravasation, and haemosiderin pigment. In some instances the histological picture may not be diagnostic because of crush artefacts and the small size of the tissue sample. The earliest changes (patch stage) are characterised by dilated, irregularly shaped, thin walled, jagged vessels lined by endothelial cells.^{9,10} These vessels are surrounded by a sparse mononuclear cell infiltrate, which tends to increase as the lesion progresses. The presence of abnormally shaped vessels, especially those with irregular, jagged outlines, is the best single criterion for diagnosis of Kaposi's sarcoma in its early stage,²⁴ a clue to diagnosis which may easily be missed.

The patch stage of Kaposi's sarcoma was also recognised in open lung biopsy sections and it was confirmed by the electron microscopic findings.²⁵ Although open lung biopsy appears to be more effective than transbronchial biopsy in establishing diagnosis,^{4,5} we recommend fiberoptic bronchoscopy as a more useful alternative approach in these patients. Fiberoptic bronchoscopy allows detection of alveolar haemorrhage, and bronchial biopsy of suspected lesions can be successful. Moreover, in cases consistent with pulmonary Kaposi's sarcoma, a highly characteristic endoscopic appearance may make it less crucial to establish a histological diagnosis.⁶ Since lavage is extremely effective as a means of detecting opportunistic infections,²⁶ antimicrobial treatment, which is known to have many serious side effects in patients with AIDS, may be withdrawn. Fiberoptic bronchoscopy with lavage is more easily repeated than open lung biopsy, which should not be considered unless there is some alteration in the clinical picture.

Finally, attempts to reach a diagnosis are justified by the clinical improvement that can be observed after specific treatment.^{5,27} Response to treatment does not represent lasting remission, and a response is unlikely to occur in patients in whom extrathoracic lesions have already been found to be resistant to treatment.

We thank Dr F Basset and Mr I Smart for reviewing this work, and Dr W Rozenbaum for providing clinical information.

References

- 1 Friedman-Kien AE, Laubenstein LJ, Rubinstein P, *et al.* Disseminated Kaposi's sarcoma in homosexual men. *Ann Intern Med* 1982;**96**:693-700.
- 2 Brown RK, Huberman RP, Vanley G. Pulmonary fea-

- tures of Kaposi's sarcoma. *AJR* 1982;**139**:659-60.
- 3 Kornfeld H, Axelrod JL. Pulmonary presentation of Kaposi's sarcoma in a homosexual patient. *Am Rev Respir Dis* 1982;**127**:248-9.
 - 4 Murray JF, Felton CP, Garay SM, et al. Pulmonary complications of the acquired immunodeficiency syndrome. *N Engl J Med* 1984;**310**:1682-8.
 - 5 Ognibene FP, Steis RG, Macher AM, et al. Kaposi's sarcoma causing pulmonary infiltrates and respiratory failure in the acquired immune deficiency syndrome. *Am Rev Respir Dis* 1985;**102**:471-5.
 - 6 Pitchnik AE, Fishl MA, Saldana MJ. Kaposi's sarcoma of the tracheobronchial tree. *Chest* 1985;**87**:122-4.
 - 7 Hanno R, Owen LG, Callen JP. Kaposi's sarcoma with extensive silent internal involvement. *Int J Dermatol* 1979;**18**:718-21.
 - 8 Centers for Disease Control. Update on acquired immune deficiency syndrome (AIDS)—United States. *MMWR* 1982;**31**:507-8, 513-4.
 - 9 Ackermann AB. Subtle clues to diagnosis by conventional microscopy. The patch stage of Kaposi's sarcoma. *Am J Dermatopathol* 1979;**1**:165-72.
 - 10 Gottlieb GJ, Ackermann AB. Kaposi's sarcoma—an extensively disseminated form in young homosexual men. *Hum Pathol* 1982;**13**:882-92.
 - 11 Misra DP, Sunderrajan EV, Hurst DJ, Maltby JD. Kaposi's sarcoma of the lung: radiography and pathology. *Thorax* 1982;**37**:155-6.
 - 12 Nash G, Flegiel S. Kaposi's sarcoma presenting as pulmonary disease in the acquired immunodeficiency syndrome: diagnosis by lung biopsy. *Hum Pathol* 1984;**15**:999-1001.
 - 13 Kovacs JA, Hiemenz JW, Macher AM, et al. *Pneumocystis carinii* pneumonia: a comparison between patients with the acquired immunodeficiency syndrome and patients with other immunodeficiencies. *Ann Intern Med* 1984;**100**:663-71.
 - 14 Cohn DI, O'Brien RF, Arnall MF. Pleuropulmonary Kaposi's sarcoma in AIDS: clinical, radiographic and pathological manifestations [abstract]. *Am Rev Respir Dis* 1985;**131**:A82.
 - 15 Rozenbaum W, Coulaud JP, Saimot AG, Klatzman D, Mayaud C, Carette MF. Multiple opportunistic infection in a male homosexual in France [letter]. *Lancet* 1982;**i**:572-3.
 - 16 Hunninghake GW, Gadek JE, Kawanami O, Ferrans VJ, Crystal RG. Inflammatory and immune processes in the human lung in health and disease: evaluation by bronchoalveolar lavage. *Am J Pathol* 1979;**91**:149-206.
 - 17 Nash G, Fligiel S. Pathologic features of the lung in the acquired immune deficiency syndrome (AIDS): an autopsy study of seventeen homosexual males. *Am Clin Pathol* 1984;**81**:6-12.
 - 18 Drew WL, Finley TN, Golde DW. Diagnostic lavage and occult pulmonary hemorrhage in the thrombocytopenic immunocompromised patients. *Am Rev Respir Dis* 1977;**116**:215-21.
 - 19 Touboul JL, Mayaud CM, Fouret P, Akoun GM. Pulmonary lesions of Kaposi's sarcoma, intra-alveolar hemorrhage and pleural effusion [letter]. *Ann Intern Med* 1985;**103**:808.
 - 20 Broaddus C, Dake MD, Stulberg MS, et al. Bronchoalveolar lavage and transbronchial biopsy for the diagnosis of pulmonary infections in the acquired immunodeficiency syndrome. *Ann Intern Med* 1985;**102**:747-52.
 - 21 Fouret P, Touboul JL, Picard F, Mayaud CM, Roland AP. Apport de l'examen cytologique du liquide de lavage bronchoalvéolaire chez les patients atteints de syndrome d'immunodéficience acquis et de syndrome associé. *Ann Pathol* 1986;**6**:45-52.
 - 22 Kradin RL, Mark EJ. Benign lymphoid disorder of the lungs, with a theory regarding their development. *Hum Pathol* 1983;**14**:857-67.
 - 23 Guillon JM, Fouret P, Mayaud C, et al. Extensive pulmonary visceral infiltration in a homosexual male. *Am J Med* (in press).
 - 24 Blumenfeld W, Egbert BM, Sagebiel RW. Differential diagnosis of Kaposi's sarcoma. *Arch Pathol Lab Med* 1985;**109**:123-7.
 - 25 Waldo E. Subtle clues to diagnosis by electron microscopy—Kaposi's sarcoma. *Am J Dermatopathol* 1979;**1**:177-80.
 - 26 Orenstein M, Webber CA, Cash A, Heurich AE. Value of bronchoalveolar lavage in the diagnosis of pulmonary infection in acquired immune deficiency syndrome. *Thorax* 1986;**41**:345-9.
 - 27 Gelmann EP. New concepts in Kaposi's sarcoma. *Ann Intern Med* 1985;**102**:800-13.