

Osteosarcoma and its Variants

James C. Wittig, MD

Associate Professor of Orthopedic Oncology

Chief, Orthopedic Oncology
Mount Sinai Medical Center

Osteosarcoma

■ Definitions:

- A mesenchymal malignancy (malignant spindle cells) that differentiates to produce osteoid/immature bone
- Considered an osteosarcoma no matter how much osteoid is produced
- Second most common primary malignant tumor of bone (first most common= multiple myeloma)
- 15% of all biopsied primary bone tumors

Osteosarcoma

■ Definitions:

- Primary Osteosarcoma: arises from the bone in the absence of a benign precursor lesion or treatment
- Secondary Osteosarcoma: arises from a precursor lesion to one that is metastatic from a primary osteosarcoma
- Synchronous Osteosarcoma: Lesions that affect multiple bones discovered within 6 mos of each other
- Metachronous Osteosarcoma: Lesions involving multiple bones discovered more than 6 mos apart

Osteosarcoma

■ Definitions:

- Intramedullary Osteosarcoma: Lesion arising within the medullary space of the bone (most common type)
- Juxtacortical Osteosarcoma: Lesion arising on the surface of the bone in apposition to the cortex
- Intracortical Osteosarcoma: Lesion arising from the cortex of the bone

Osteosarcoma

Classification

- **Intramedullary (75%)**
 - **Conventional**
 - Osteoblastic (82%)
 - Mixed and Sclerosing
 - Chondroblastic (5%)
 - Fibroblastic (3-4%)
 - MFH-like (3-4%)
 - Osteoblastoma-like (.5%)
 - Giant Cell-rich (.5%)
 - Small-cell (1%)
 - Epithelioid (.5%)
 - **Telangiectatic (3%)**
 - **Well-differentiated (low grade intraosseous; 4%-5%)**
- **Juxtacortical/Surface (7-10%)**
 - Parosteal
 - Periosteal
 - High-grade surface
- **Intracortical (.2%)**
- **Secondary (older population)**
 - Pagets (67-90%); Post RT (6-22%); Bone infarct; Fibrous dysplasia; Metallic implant; Osteomyelitis
- **OS with specific syndromes**
 - Familial; Retinoblastoma; Rothmund-Thomson Syndrome; Multifocal; OI

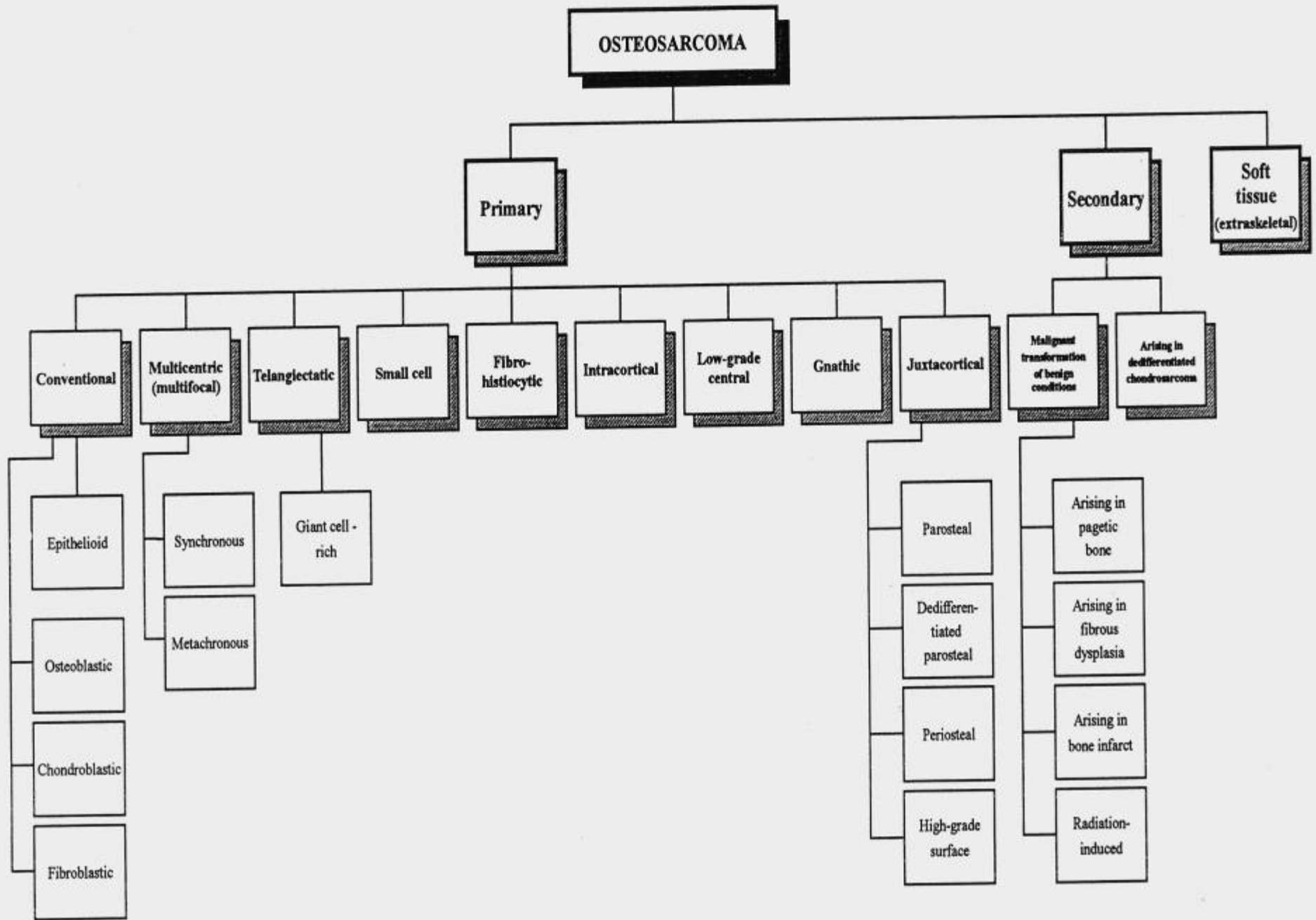
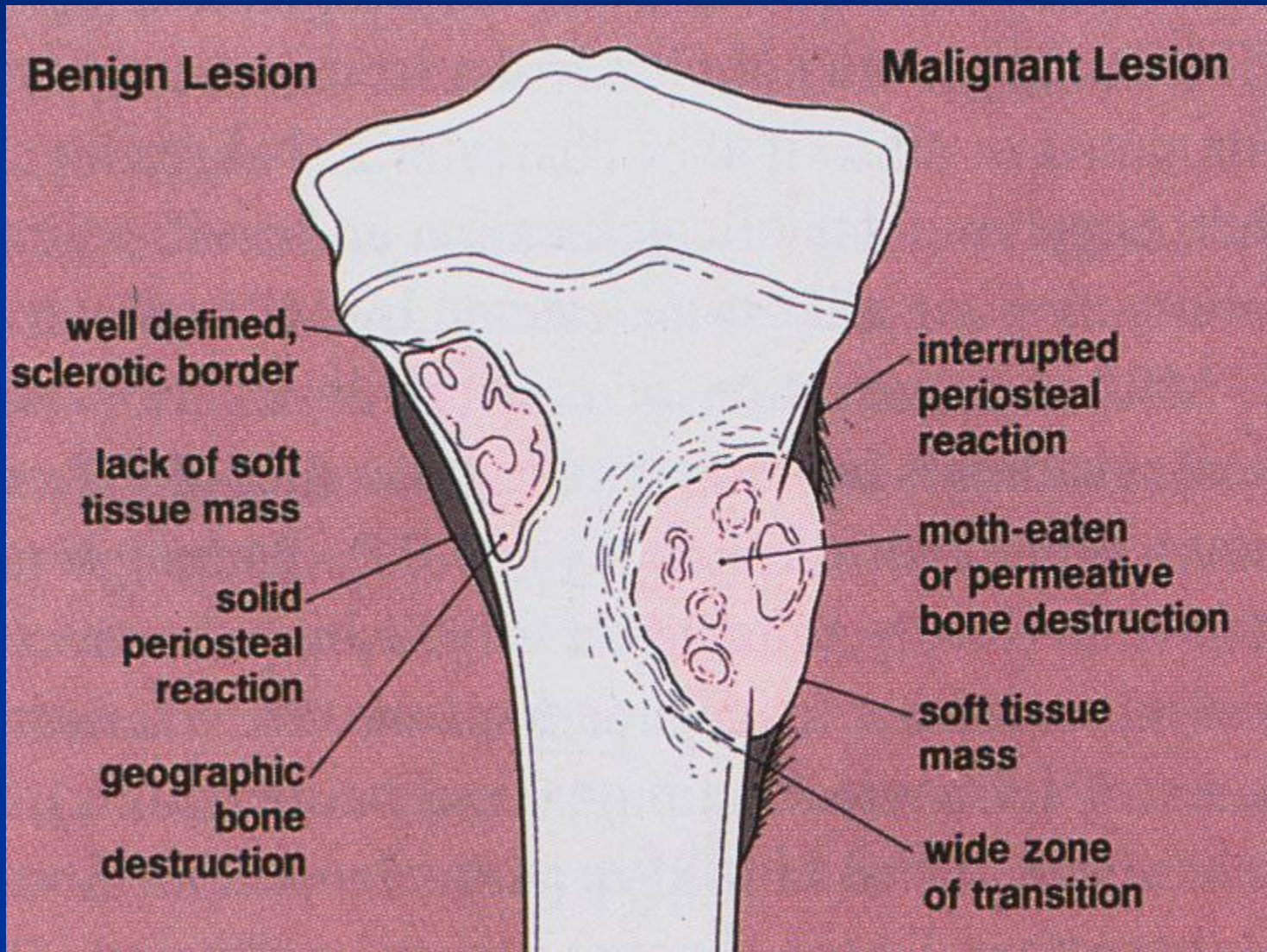


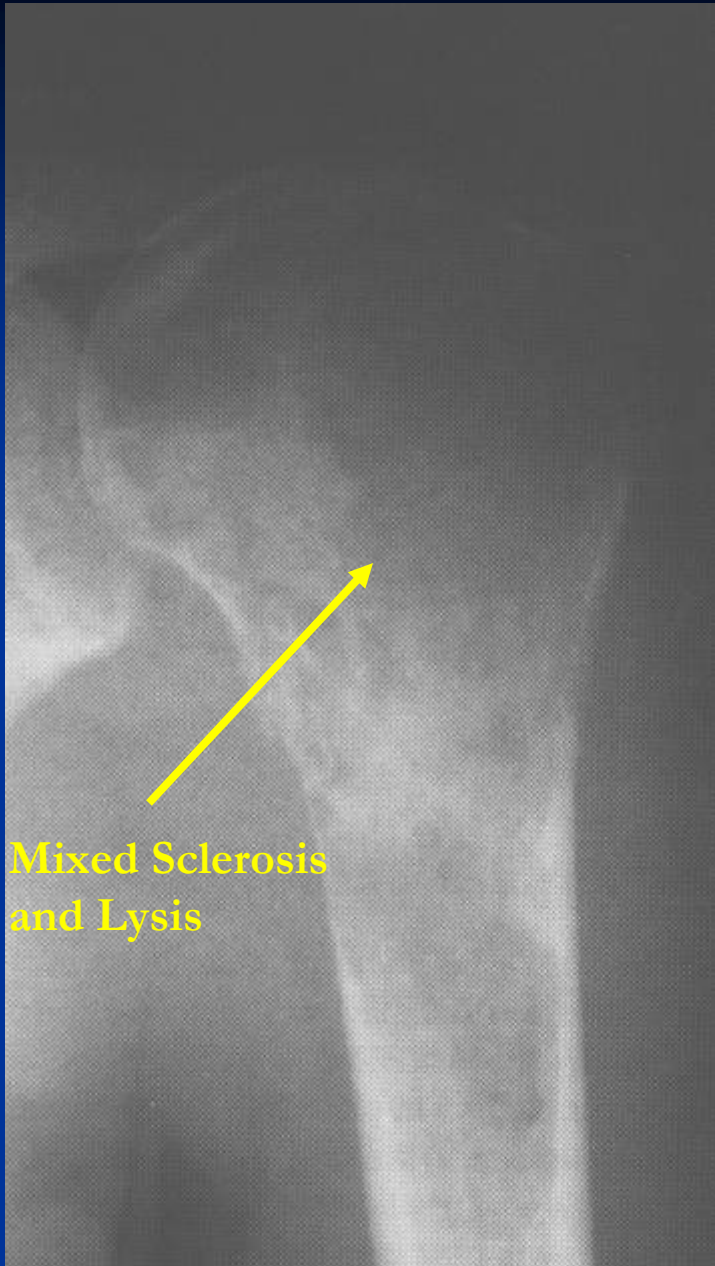
FIG. 55. Osteosarcoma and its subtypes.

General Radiology

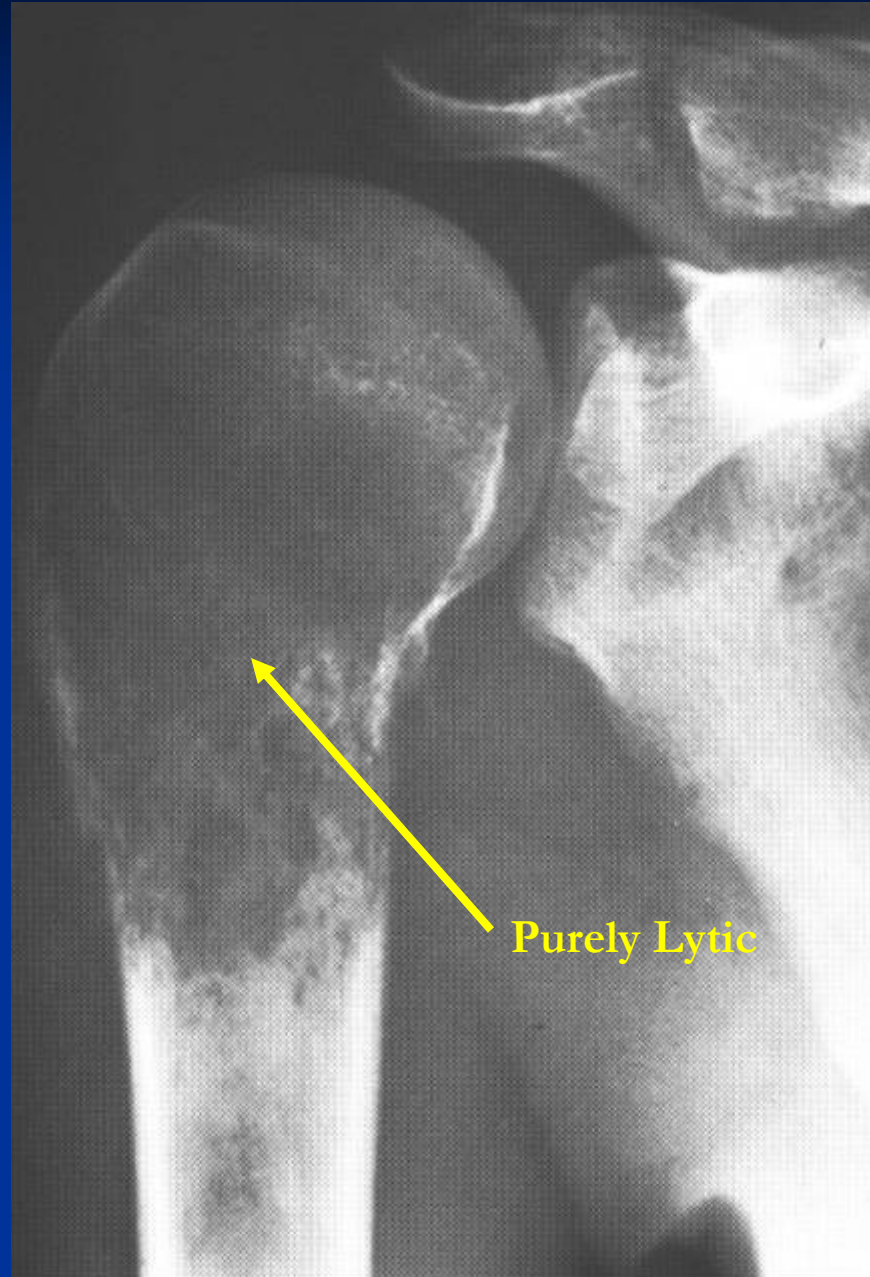


General Radiology: Plain Radiographic Presentation

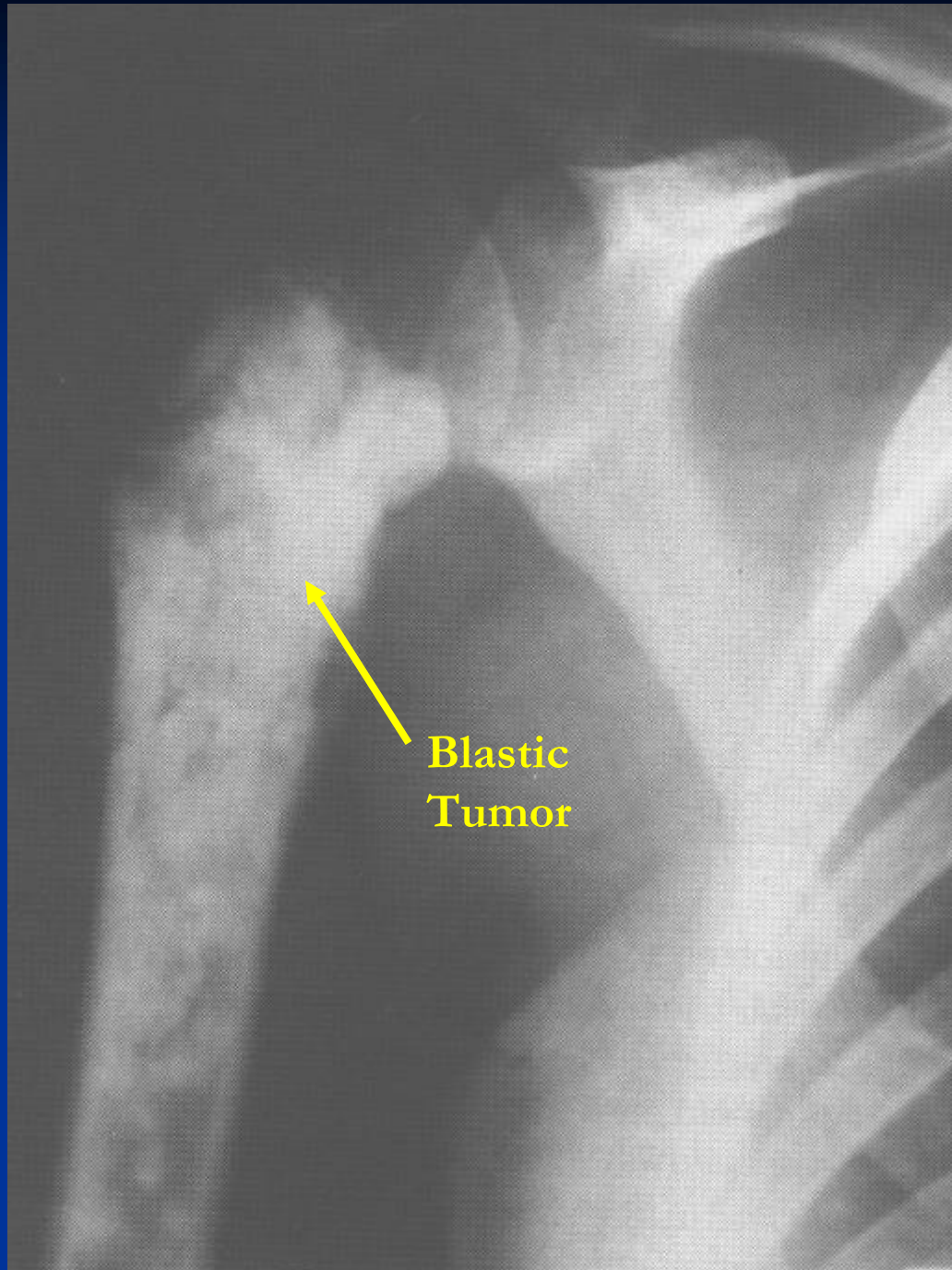
- Osteoid/Ossification production on X-Ray
- Mixed Sclerotic and Lytic Lesion—Most common radiographic presentation
- Purely Lytic
- Purely Blastic



Mixed Sclerosis
and Lysis



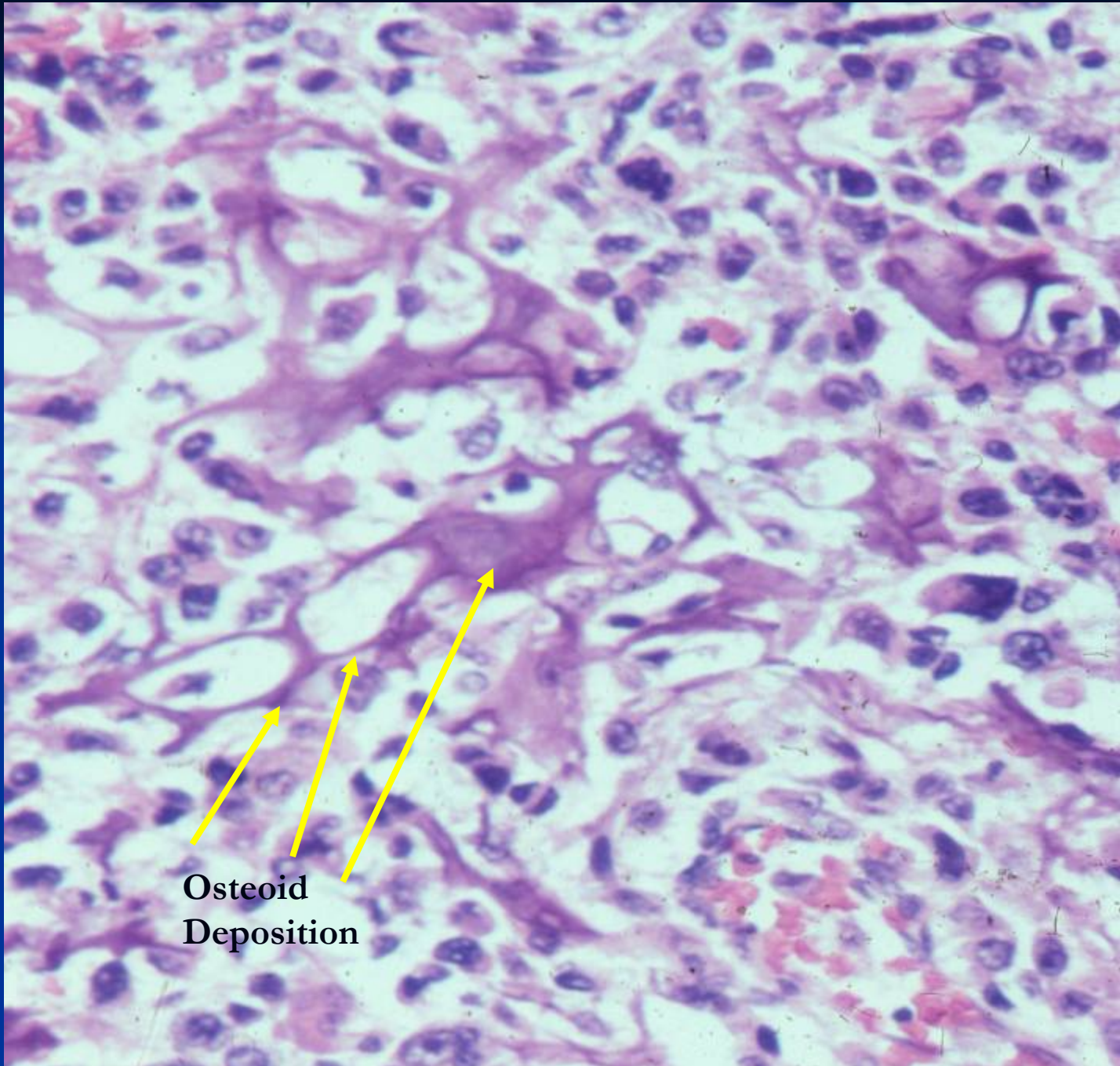
Purely Lytic



**Blastic
Tumor**

Osteosarcoma

- General Pathology:
 - Osteoid and/or immature bone production by tumor cells
 - Malignant stromal cells
 - Graded on degree of anaplasia I-IV



Osteoid
Deposition

Osteosarcoma

- Primary, High Grade, Intramedullary (Conventional)
 - About 75% of all osteosarcomas
 - Ages: 15-25 years (rare <6y or >60y)
 - Sex: Male>Female 1.5-2:1
 - Sites:
 - Long Bones: 70%-80%
 - Distal Femur (40%; about twice as common as proximal tibia)
 - Proximal Tibia (20%)
 - Proximal Humerus (10-15%)
 - Axial Skeleton
 - Pelvis
 - Jaw

Osteosarcoma

- Sites:
 - Metaphysis: 90%
 - Diaphysis: 8-10%

Telangiectatic Osteosarcoma

- Tumor largely composed of cystic cavities containing necrosis and hemorrhage
- ABC- like which can lead to a misdiagnosis on X-rays
- Sites: Similar to conventional
 - Distal femur, proximal tibia, proximal humerus
 - Metaphyseal (90%), diaphyseal (10%)

Telangiectatic Osteosarcoma

- Radiology:
 - Osteolytic and expansile on X-ray
 - Small areas of osteoid (more easily detected with CT)
 - Pathologic fracture (25%-30%)
 - MRI/CT: Fluid-fluid levels; soft tissue mass
 - Bone scan: Donut sign

Juxtacortical Osteosarcoma

- Parosteal Osteosarcoma (65%)
- Periosteal Osteosarcoma (25%)
- High Grade Surface (10%)

**JUXTACORTICAL
OSTEOSARCOMA**

**Parosteal
Osteosarcoma**

femur (frequently
posterior aspect),
humerus;
most "benign"
of all

**Dedifferentiated
Parosteal
Osteosarcoma**

same location as
conventional parosteal;
very aggressive

**Periosteal
Osteosarcoma**

tibia;
histologically
predominantly cartilaginous

**High-Grade
Surface
Osteosarcoma**

tibia, femur;
like conventional
osteosarcoma in behavior

Parosteal Osteosarcoma

- Origin: Arises from outer layer of periosteum
- Usually a low grade tumor with fibroblastic stroma and osteoid/woven bone
- Age: 20-30 yrs; usually about a decade older than conventional osteosarcoma
- Location:
 - Posterior distal femur metaphysis (65%)
 - Proximal humerus (15%); Tibia (10%); Fibula (3%)
- Clinical: painless mass in posterior distal thigh; may be present for several yrs; decreased ROM of adjacent joint
- Sex: Female > Male 2:1

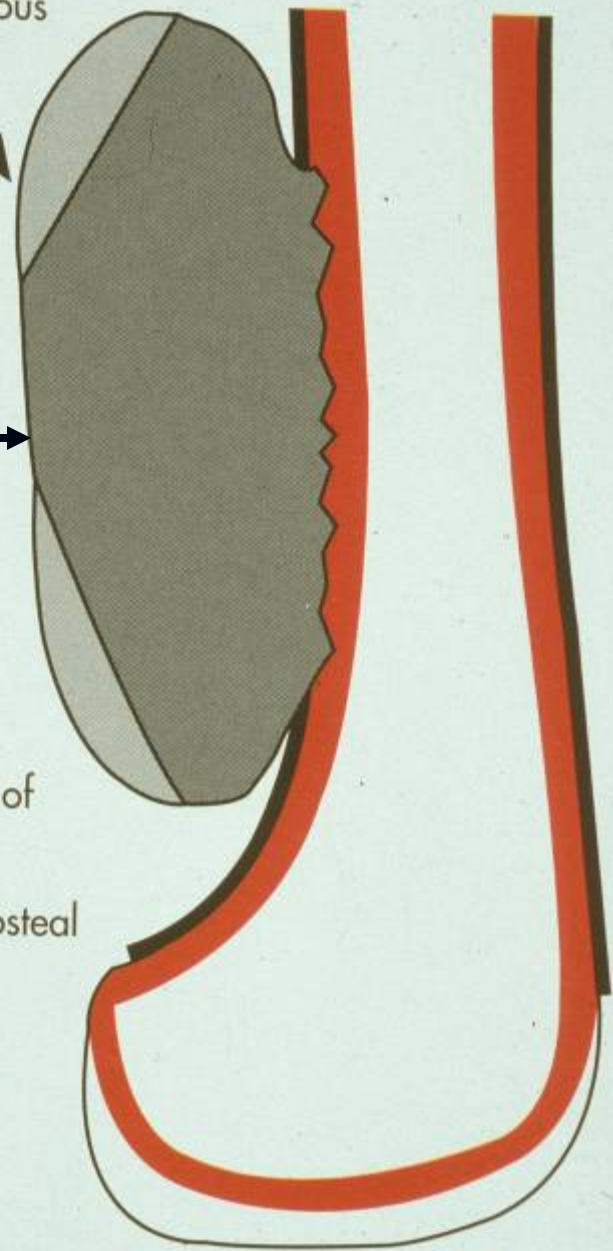
Cartilaginous cap

Tumor

No elevation of periosteum

No new periosteal bone

PAROSTEAL



Parosteal Osteosarcoma

- Radiology:

- XR:

- Lobulated and ossified exophytic mass (cauliflower-like) adjacent to the cortex with a lucent cleavage plane between lesion and the cortex
 - Radiodense centrally
 - Cortical thickening
 - Large tumors encircle the bone
 - Growth may obliterate cleavage plane between lesion and cortex and will appear to have broad attachment
 - Invasion of the medullary canal with long standing disease

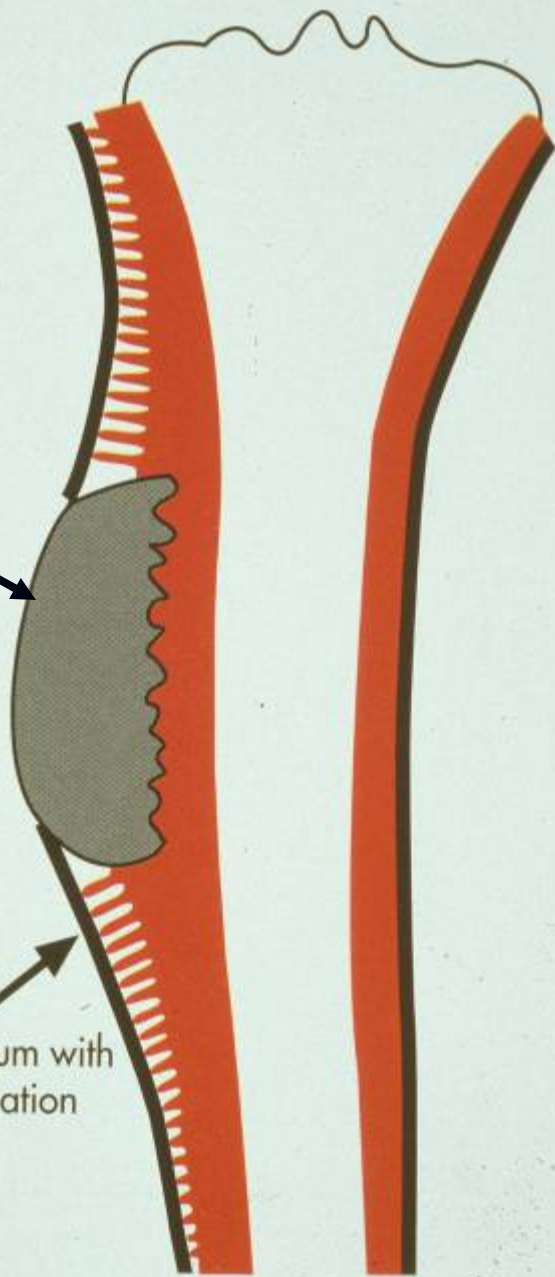
Periosteal Osteosarcoma

- Low to intermediate grade bone forming sarcoma with predominant chondroblastic differentiation tumor (>90% of tumor); <2% of osteosarcomas
- Origin: Arises from the inner layer of the periosteum
- Age: 10-20 yrs; similar to conventional osteosarcoma
- Sex: Slight male predominance
- Location: Diaphysis of femur and tibia (>85%); ulna and humerus (10%)

Tumor

Elevated periosteum with
new bone formation

PERIOSTEAL



Periosteal Osteosarcoma

■ Radiology:

■ XR:

- Diaphyseal lesion on surface of bone; medullary canal is uninvolved
- Saucerized cortex with chondroblastic soft tissue mass
- Cortical thickening at margins of erosion (40%)
- May have Codman's triangle
- Spiculated or sunburst periosteal reaction (elevates the periosteum)
- Partial matrix mineralization may be seen consistent with chondroblastic nature
- Rarely, intramedullary invasion

High Grade Surface Osteosarcoma

- High grade osteosarcoma that develops on the surface of the bone without any medullary involvement; very rare (<1% of osteosarcomas)
- Histology is the same as a conventional osteosarcoma with the same potential for mets
- Age: 2nd decade
- Sites: Femur (45%); Humerus (26%); Fibula (10%); arises usually on the metaphyseal surface

High Grade Surface Osteosarcoma

■ Radiology:

- Appearance similar to periosteal osteosarcoma but matrix mineralization is similar to conventional osteosarcoma with cloudlike opacities
- Broad based lesion arising on surface
- Codman's triangle; periosteal new bone
- Cortical erosion/destruction but medullary cavity usually uninvolved

Low Grade Intramedullary Osteosarcoma

- Intramedullary low grade fibroblastic osteoid producing sarcoma characterized by benign cytologic features of spindle cells and maturity of tumor bone
- 1% of all osteosarcomas
- Age: peak— 3rd decade; individual cases in 2nd decade and 50s
- Sites: Metaphysis of femur and tibia most common

Low Grade Intramedullary

■ Radiology:

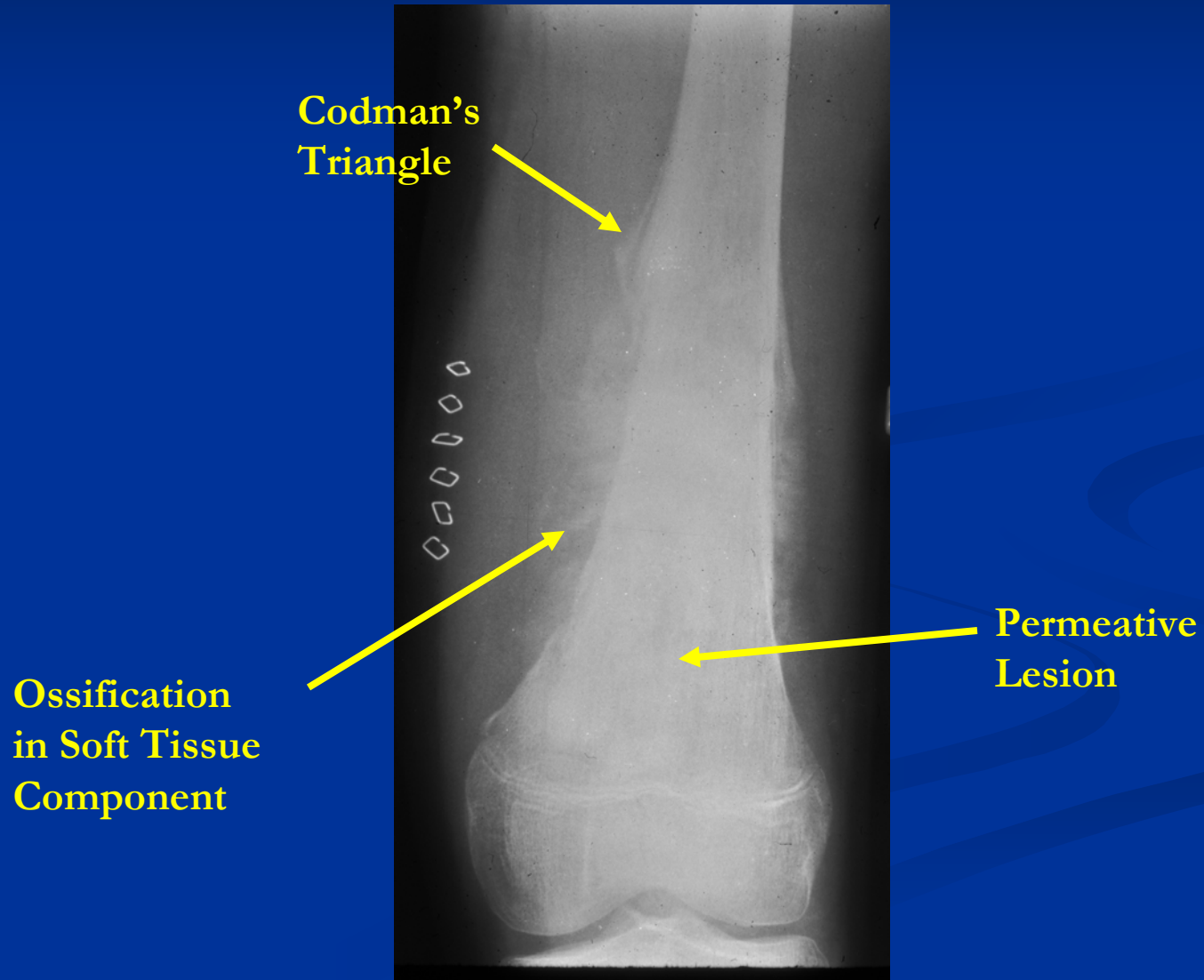
■ XR:

- Meta-epiphyseal
- Central ossification/sclerosis with expansile remodeling
- Ground glass density and internal trabeculation (simulates fibrous dysplasia)
- Usually no soft tissue mass and not as aggressive appearing
- Usually no periosteal reaction

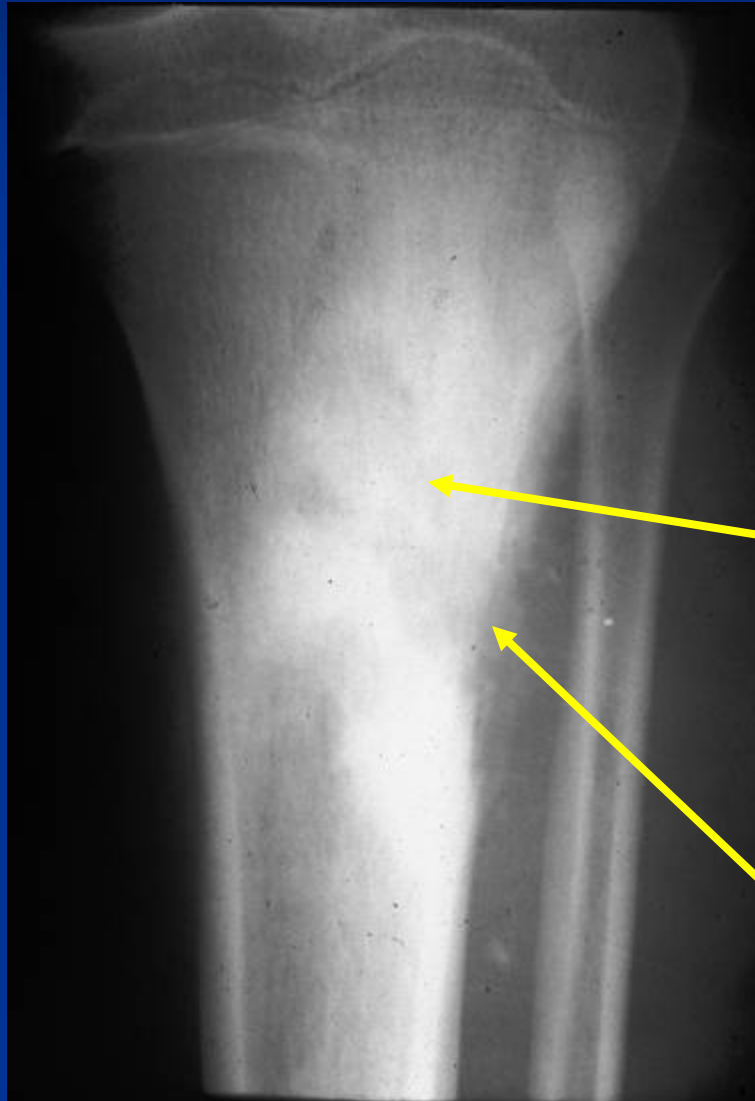
Intracortical Osteosarcoma

- High grade osteosarcoma confined to the cortex of a long bone
- Very rare; handful of cases
- Age: 10-30 yrs
- Sites: Diaphysis of femur or tibia
- Radiology:
 - Intracortical lucency with surrounding sclerosis of bone
 - No intramedullary or soft tissue involvement
 - Minimal or no periosteal reaction

Conventional Osteosarcoma of Distal Femur X-Ray

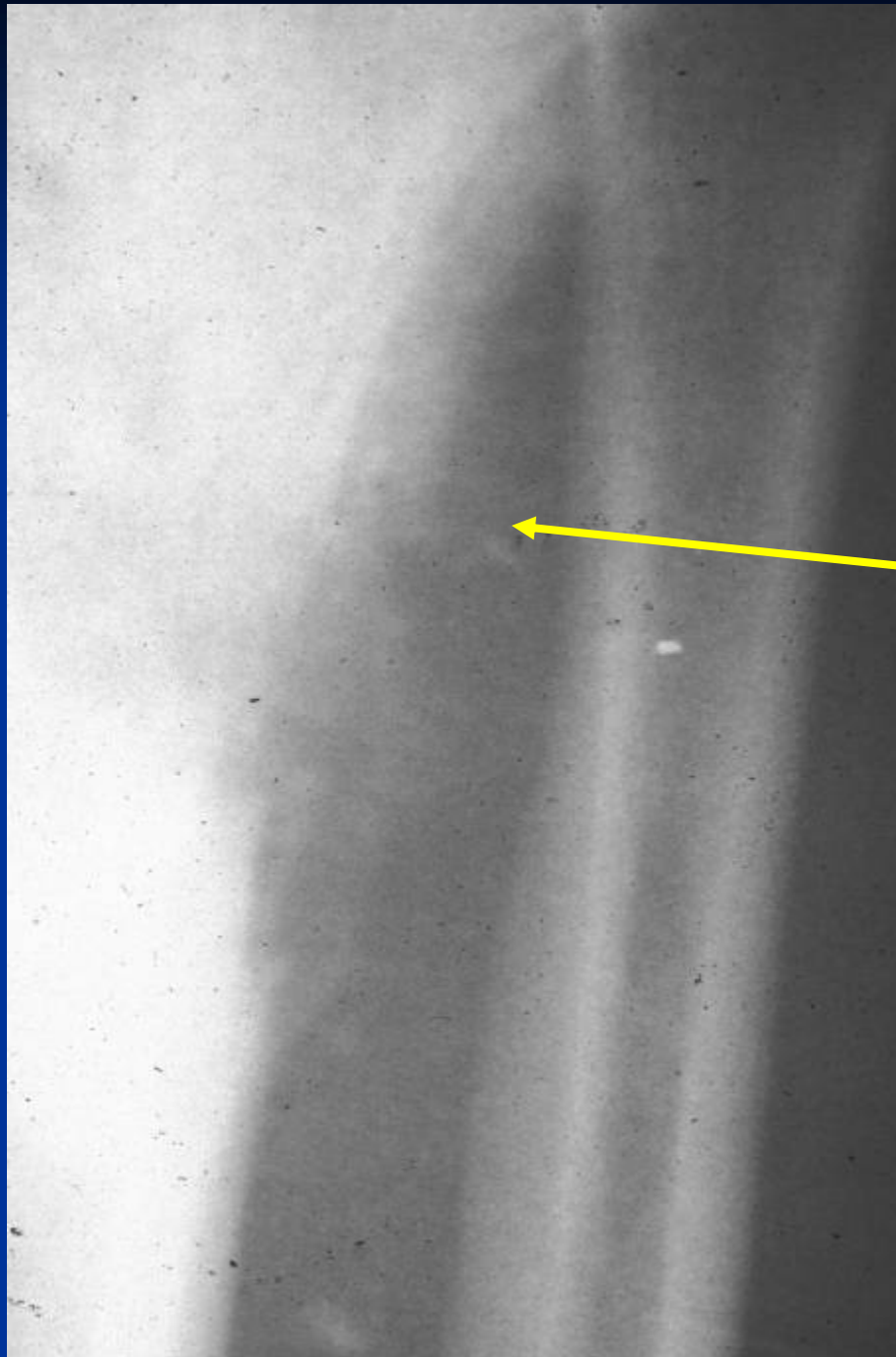


Conventional Osteosarcoma of Proximal Tibia



Permeative
Lesion with
Fluffy White
Ossification
(sclerosis)

Cortical
Destruction



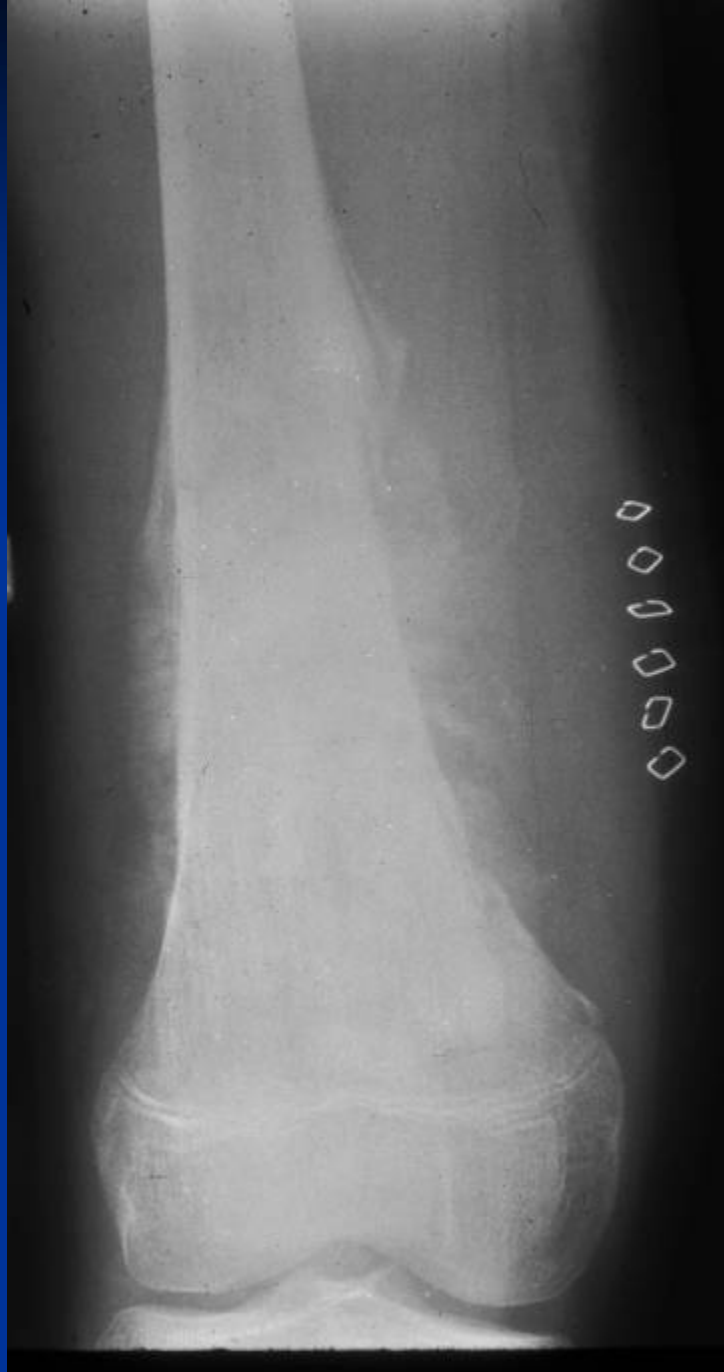**Cortical
Destruction
and Hair on
End Periosteal
Reaction**

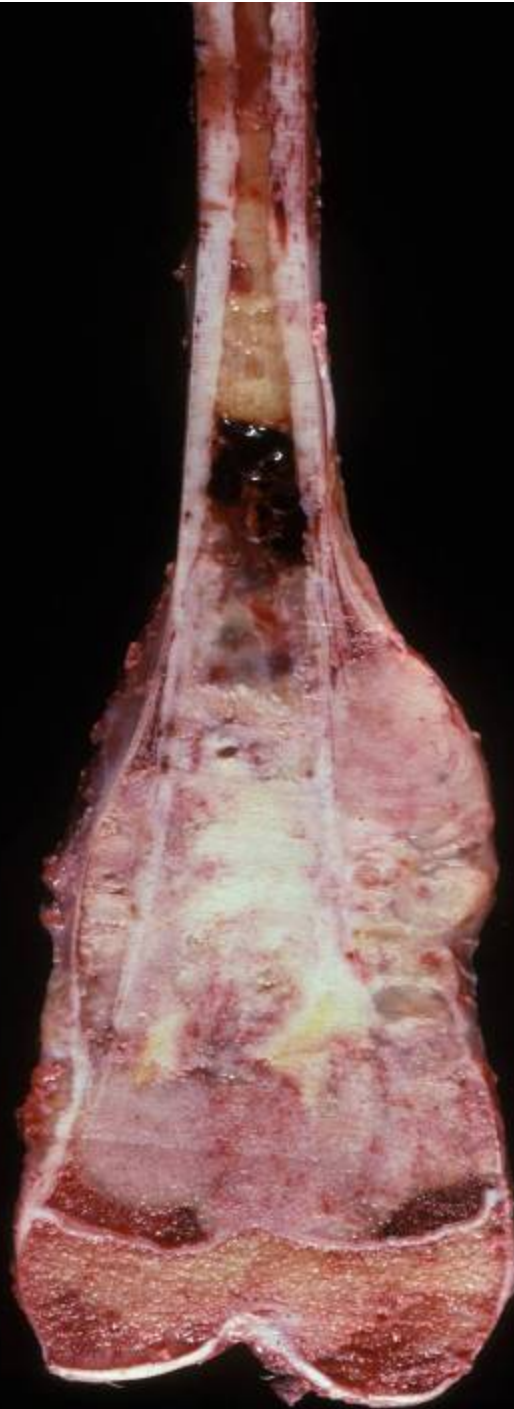Osteosarcoma

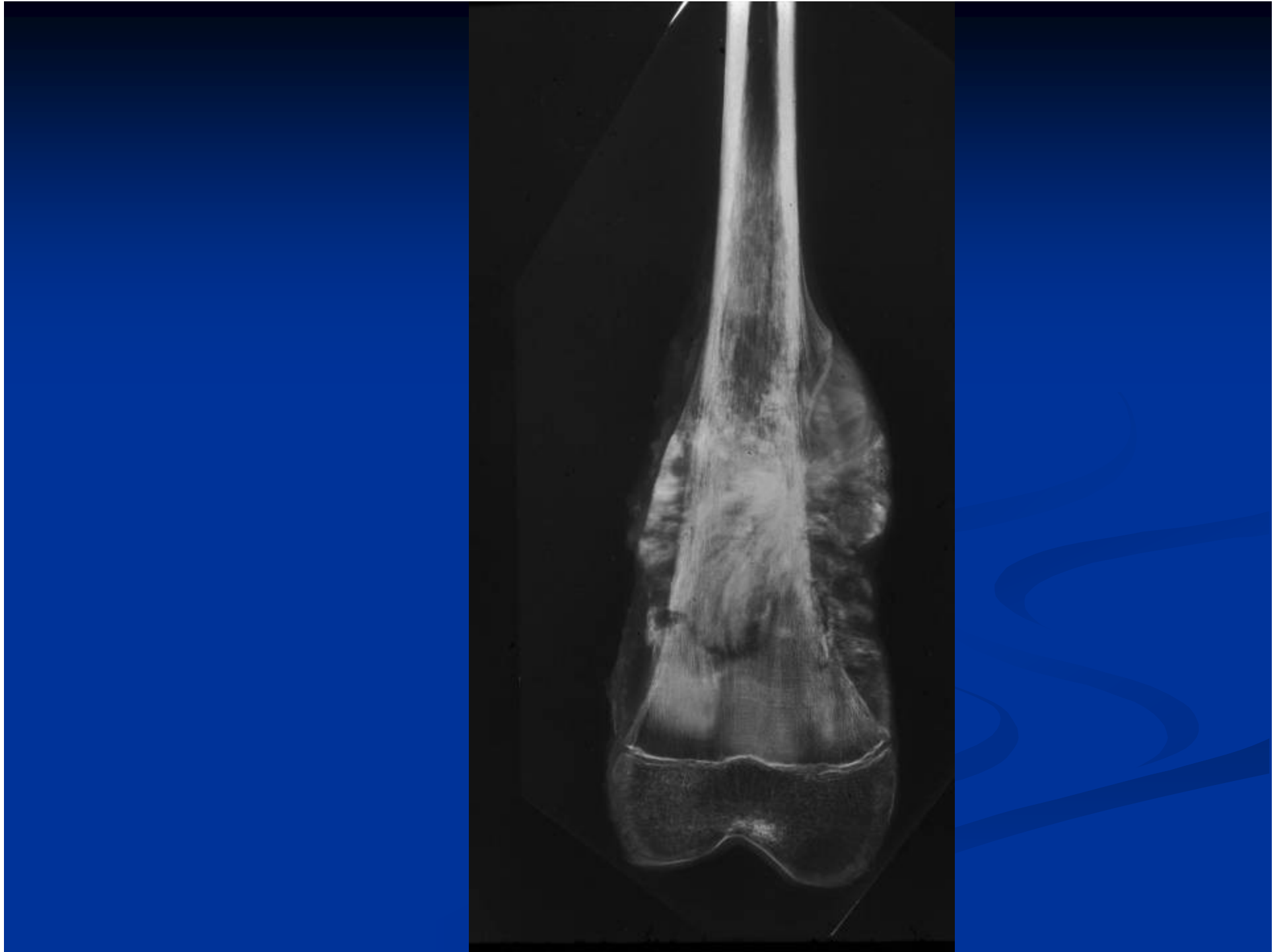Conventional

- Radiographic Differential Diagnosis:
 - Ewing sarcoma
 - Fibrosarcoma/MFH
 - Chondrosarcoma
 - Osteomyelitis
 - Osteoblastoma
 - Giant Cell Tumor

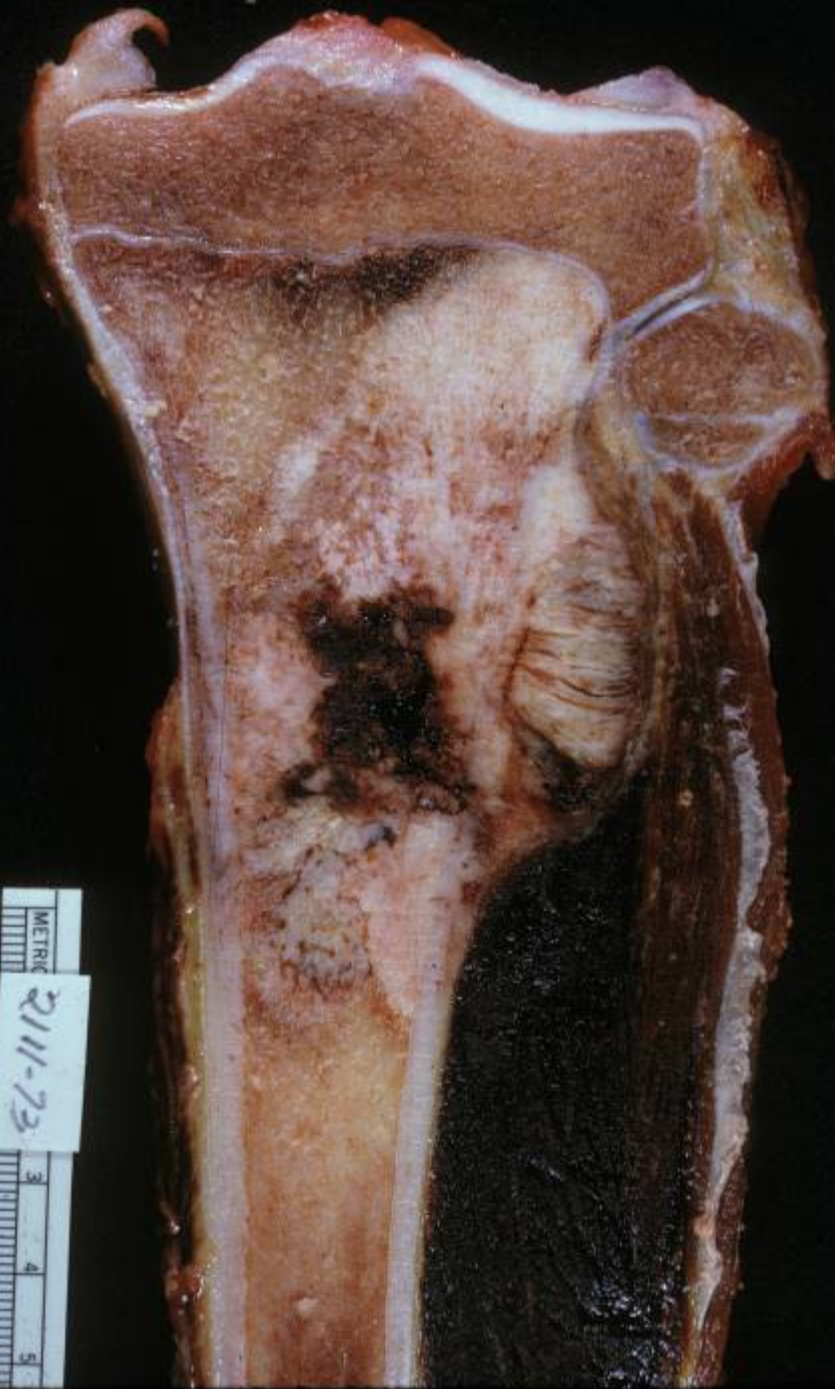**Examples of Conventional
Osteosarcomas including Gross and
Microscopic Pathology**

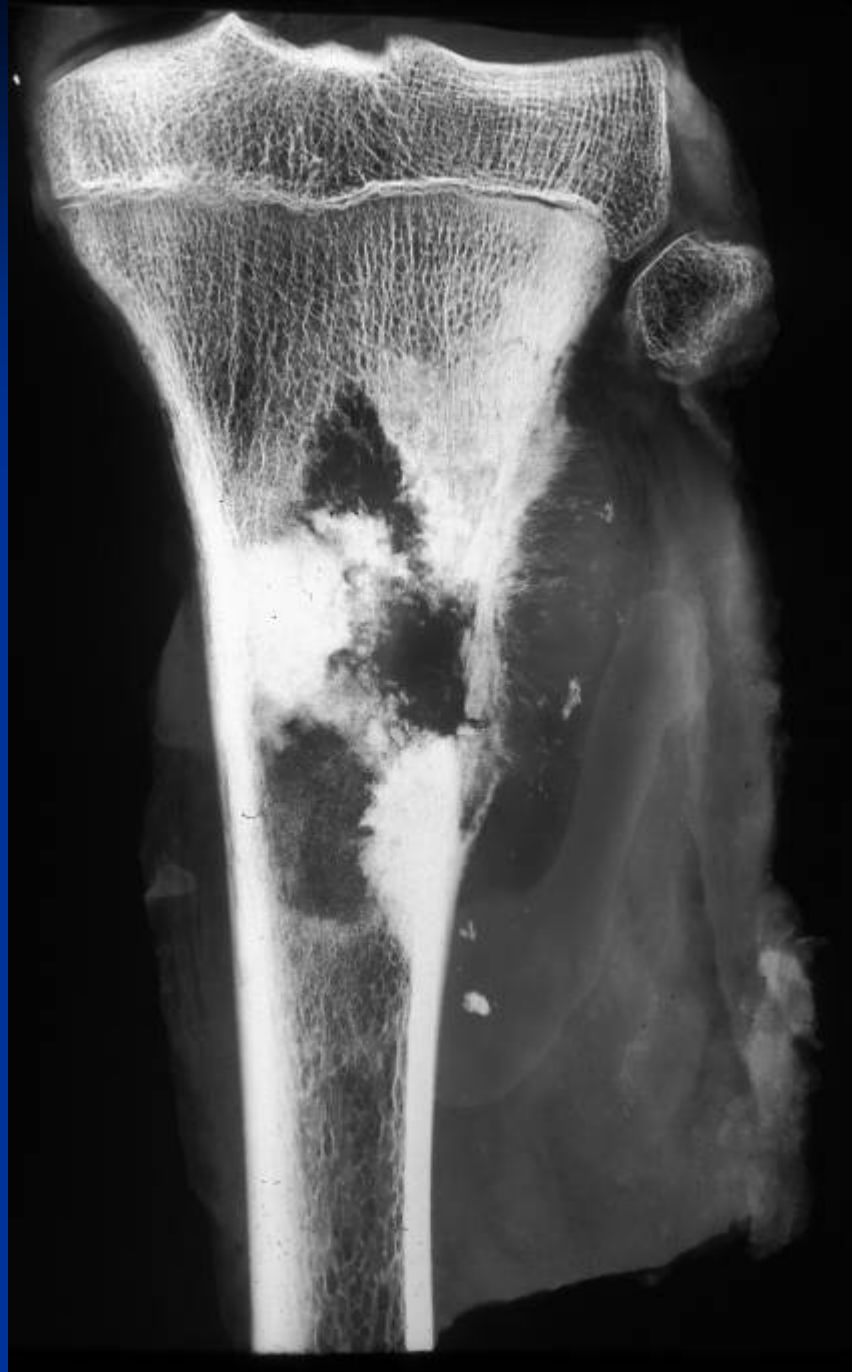


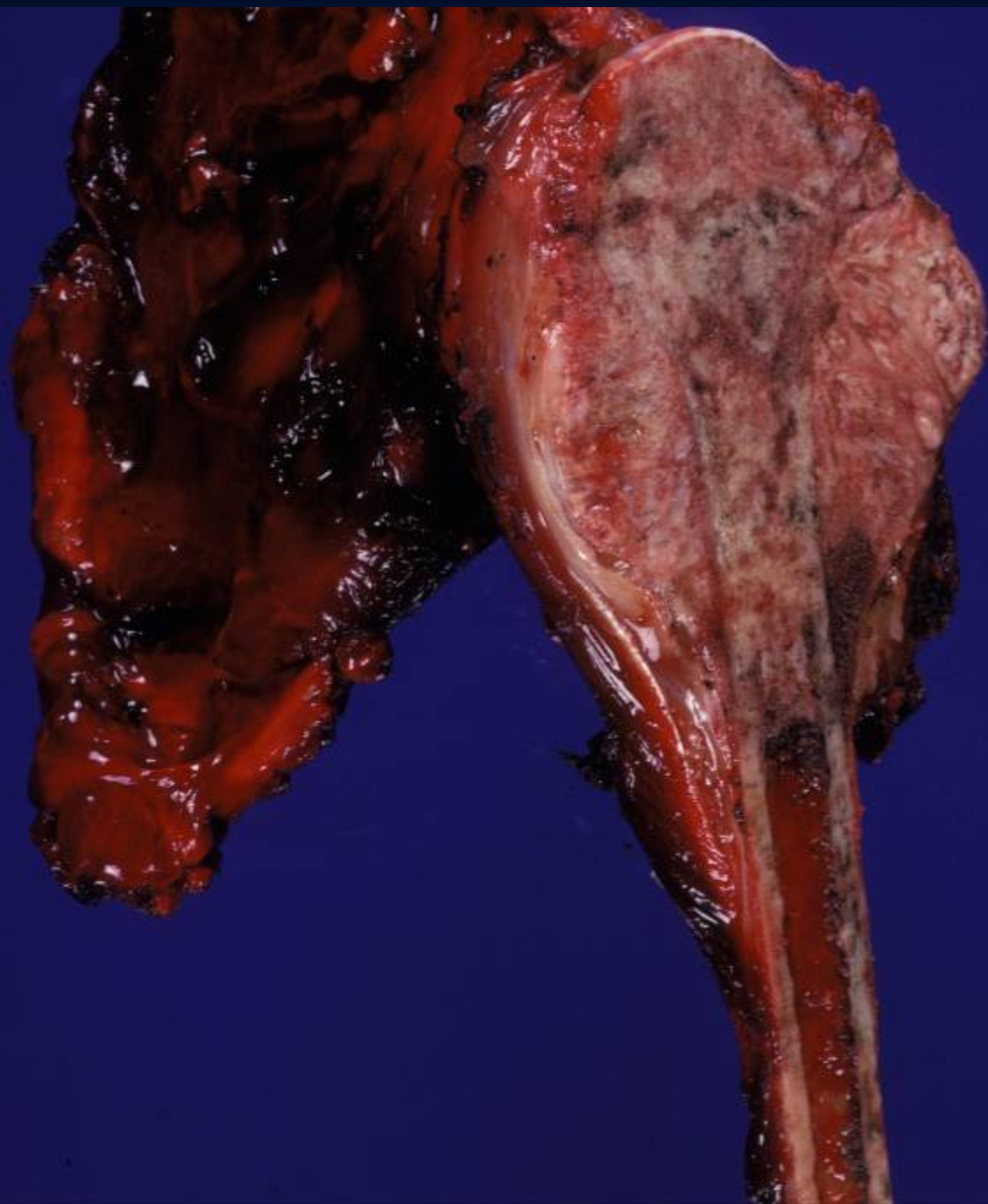

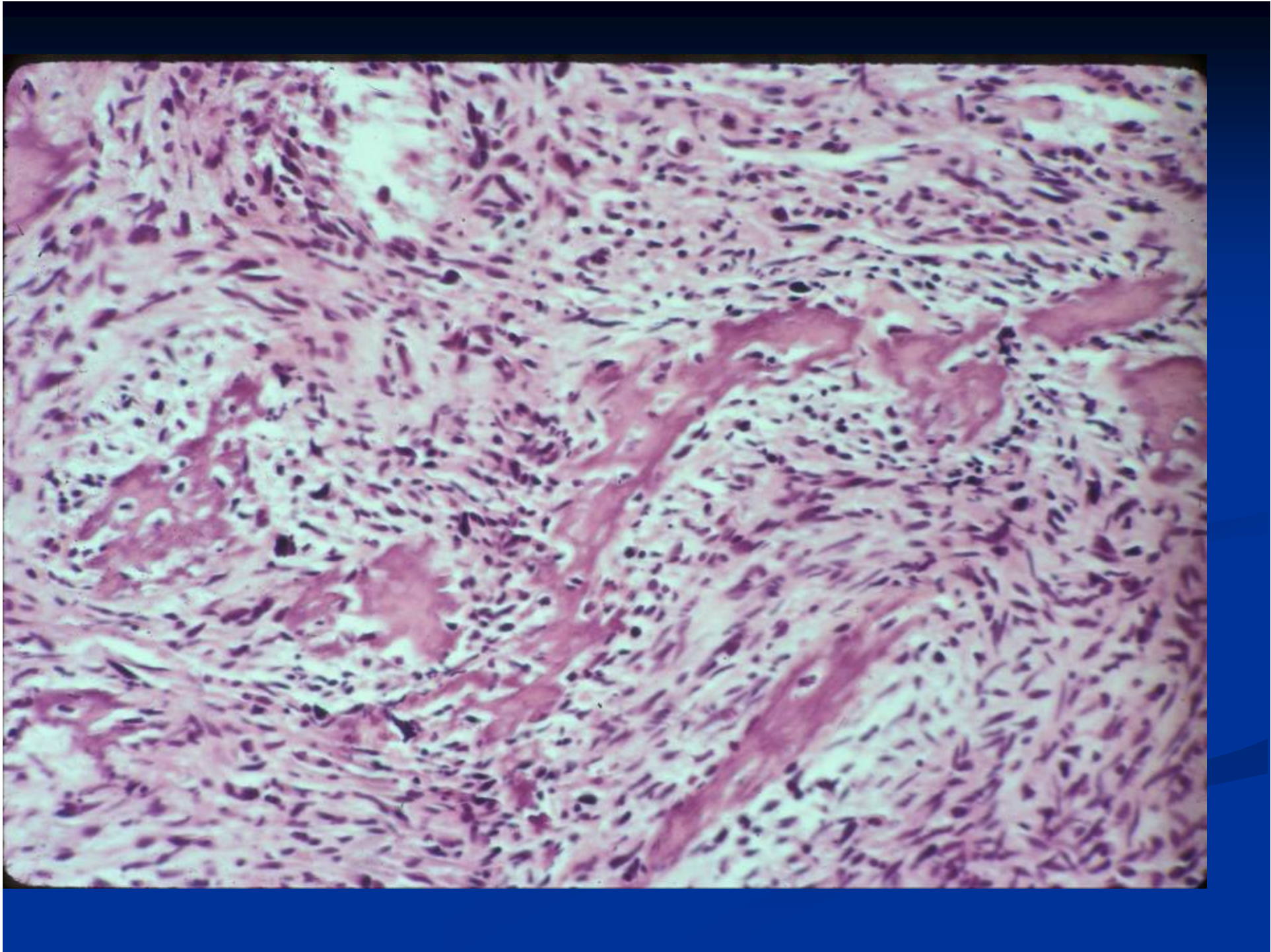


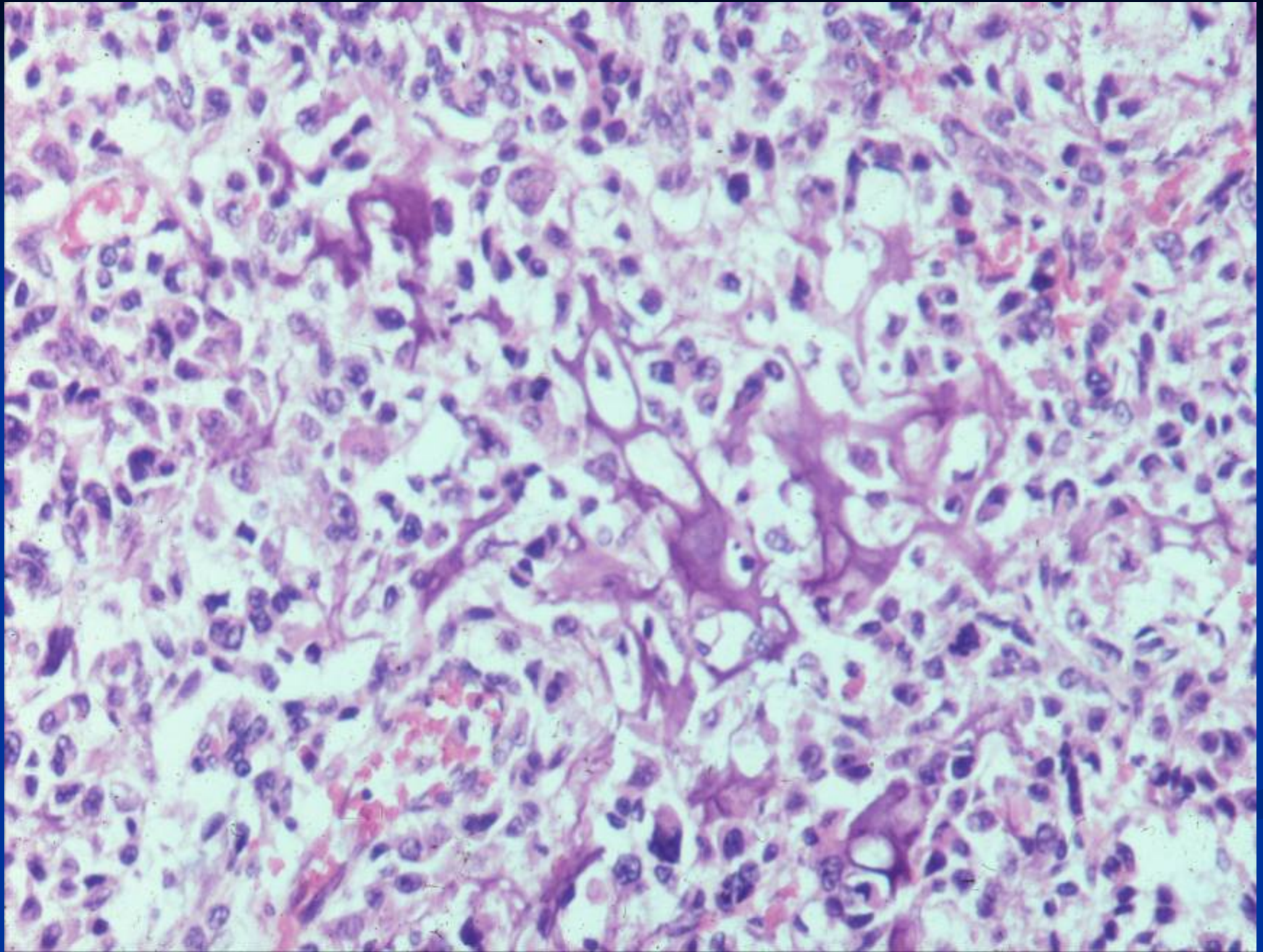
METRIC
2111-73
3
4
5

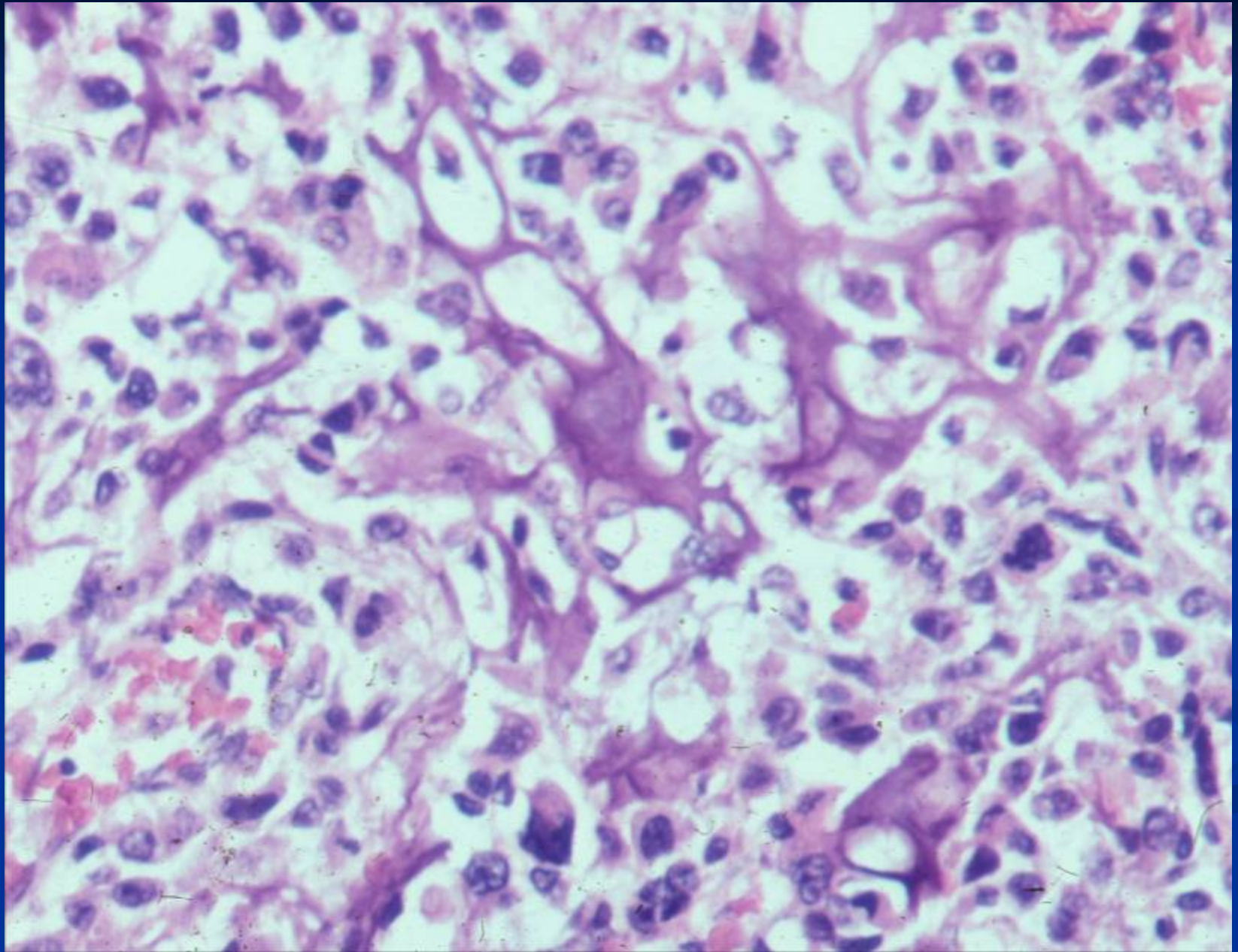


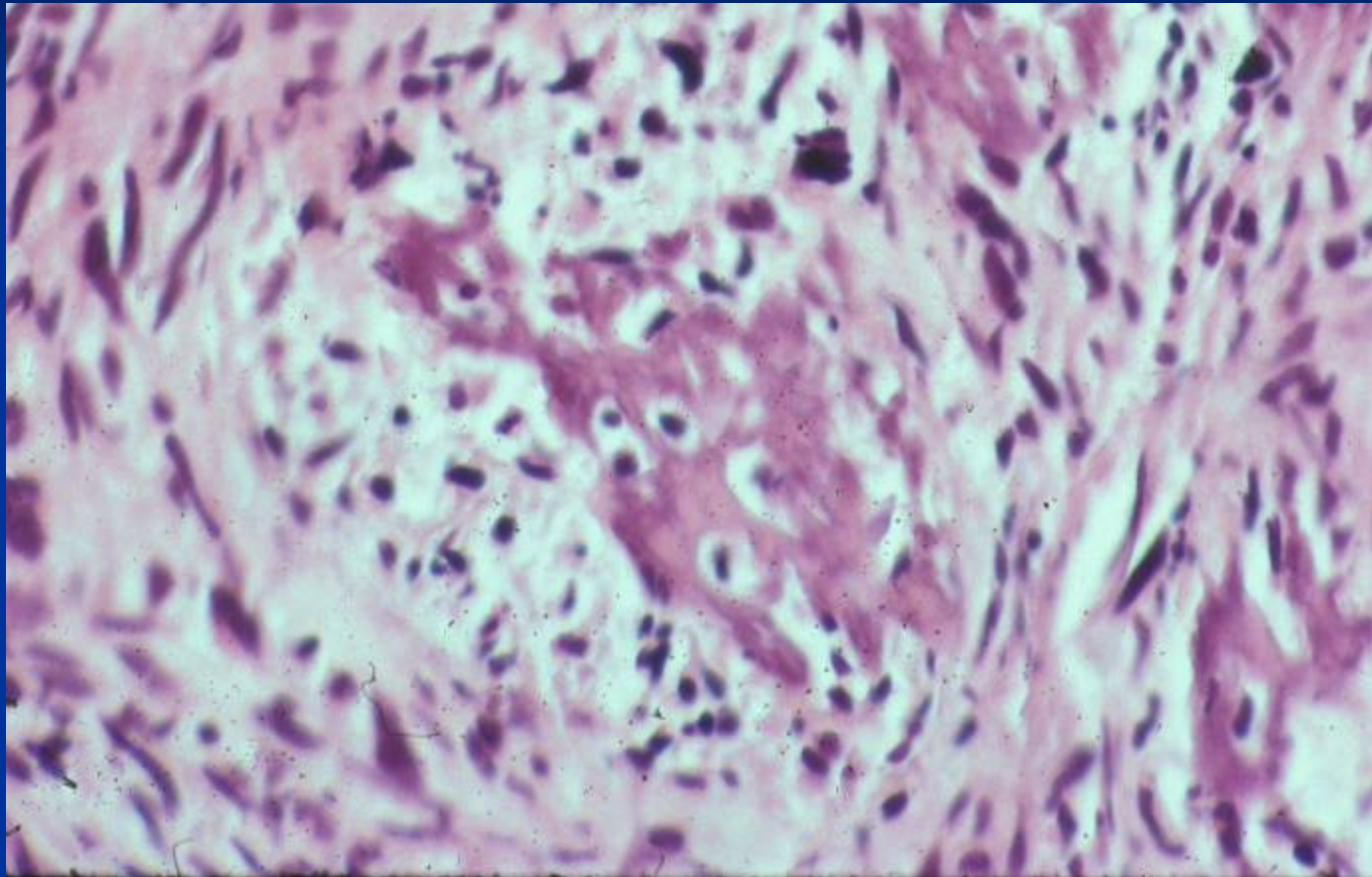




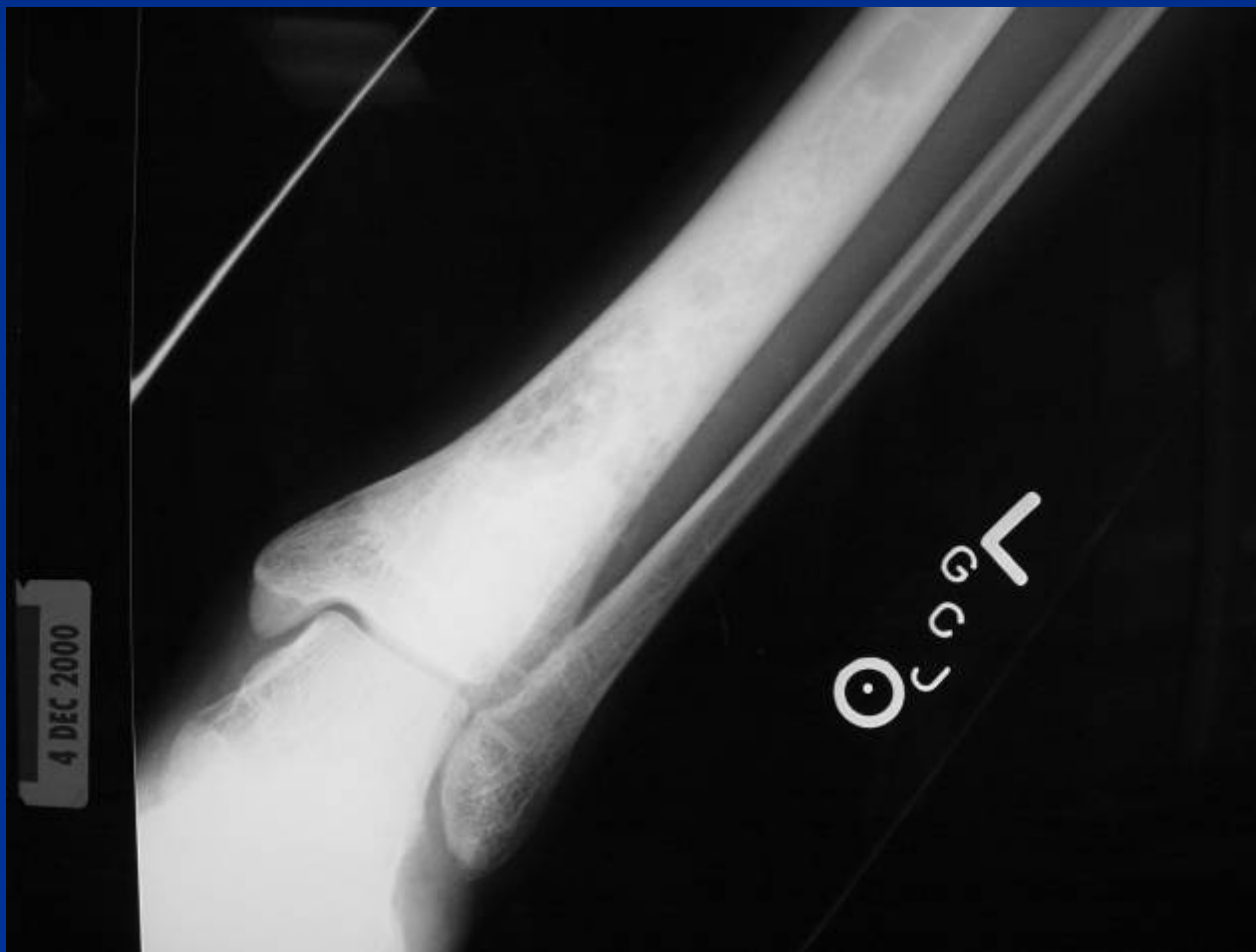


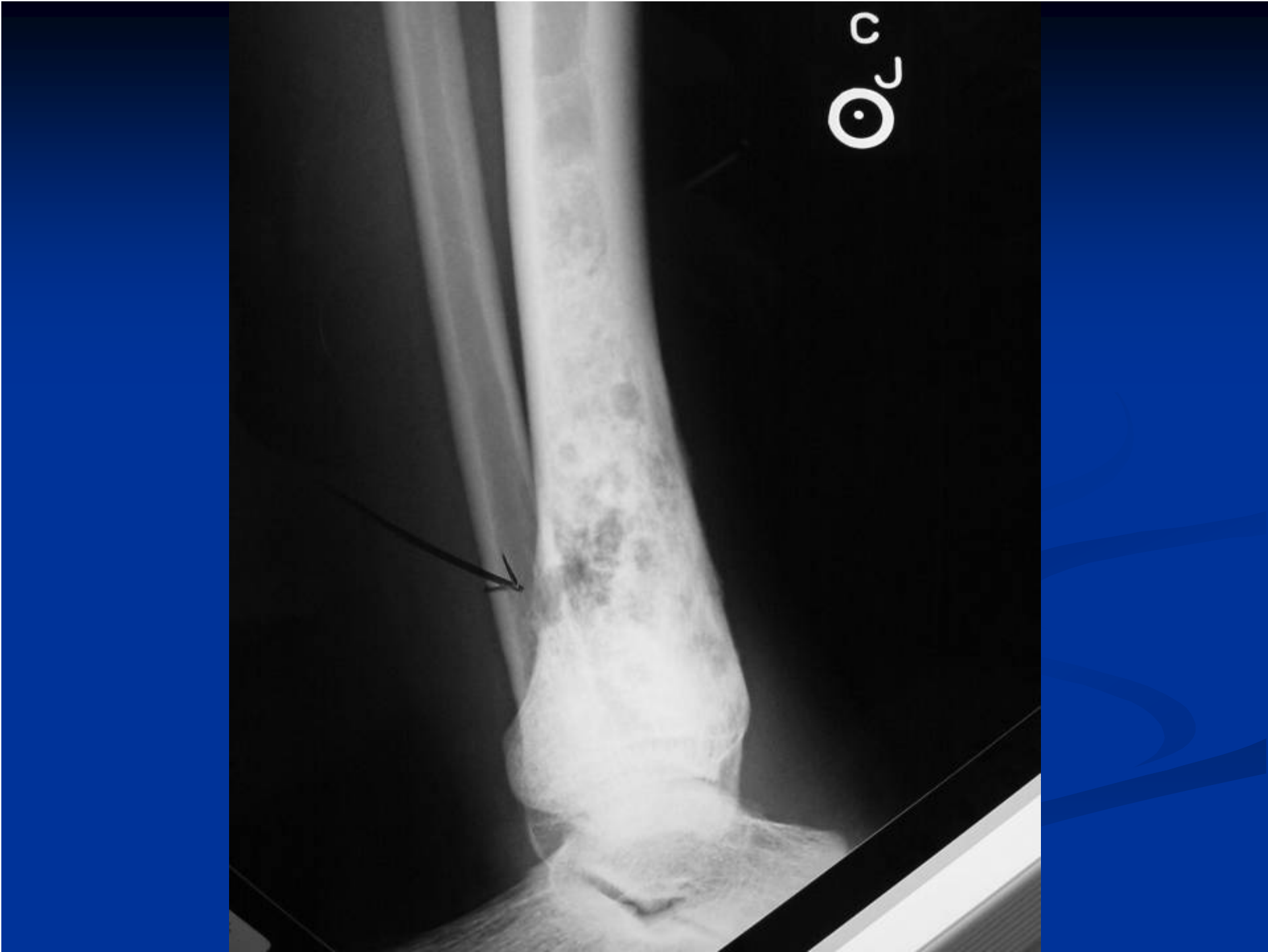
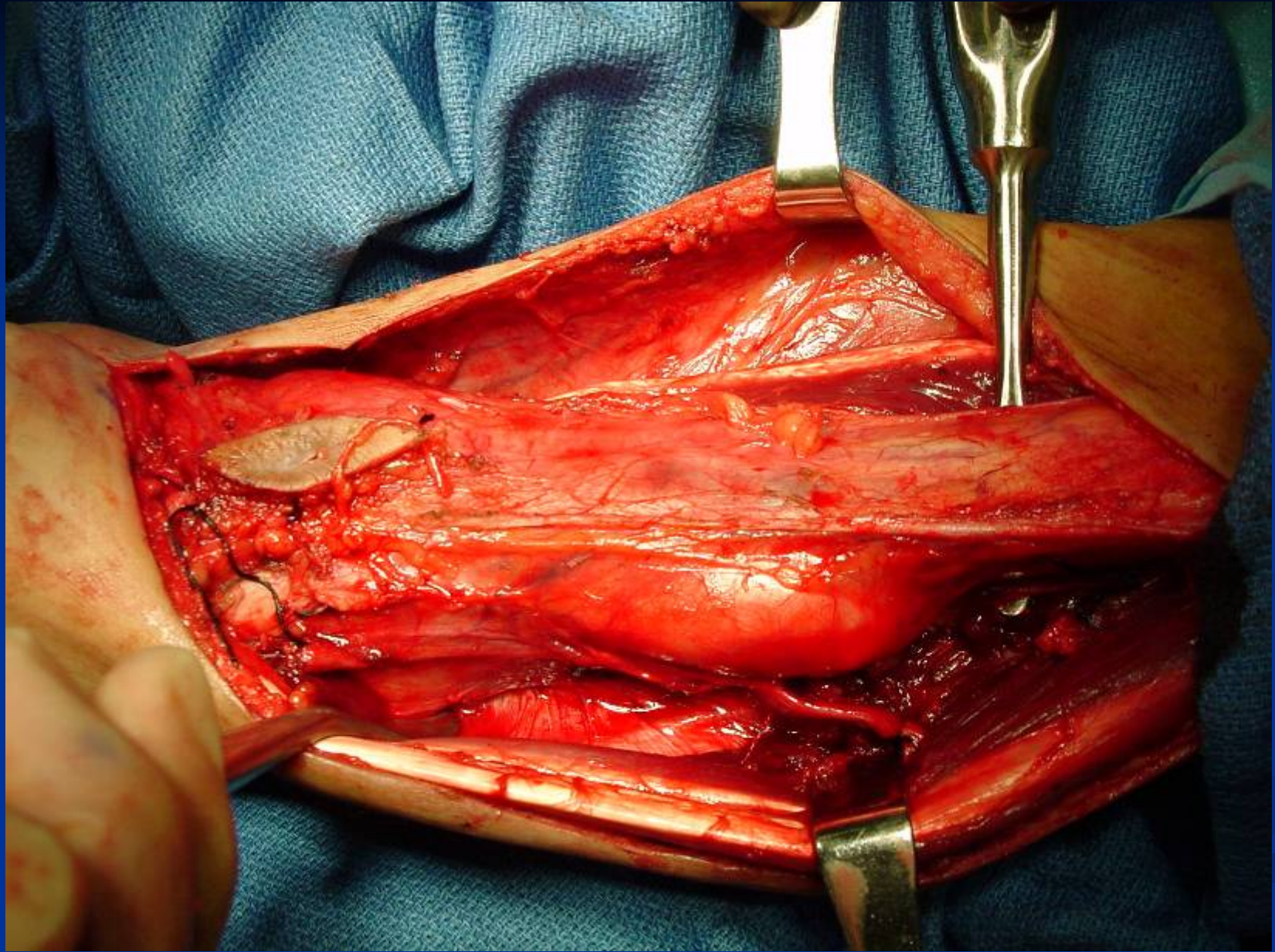




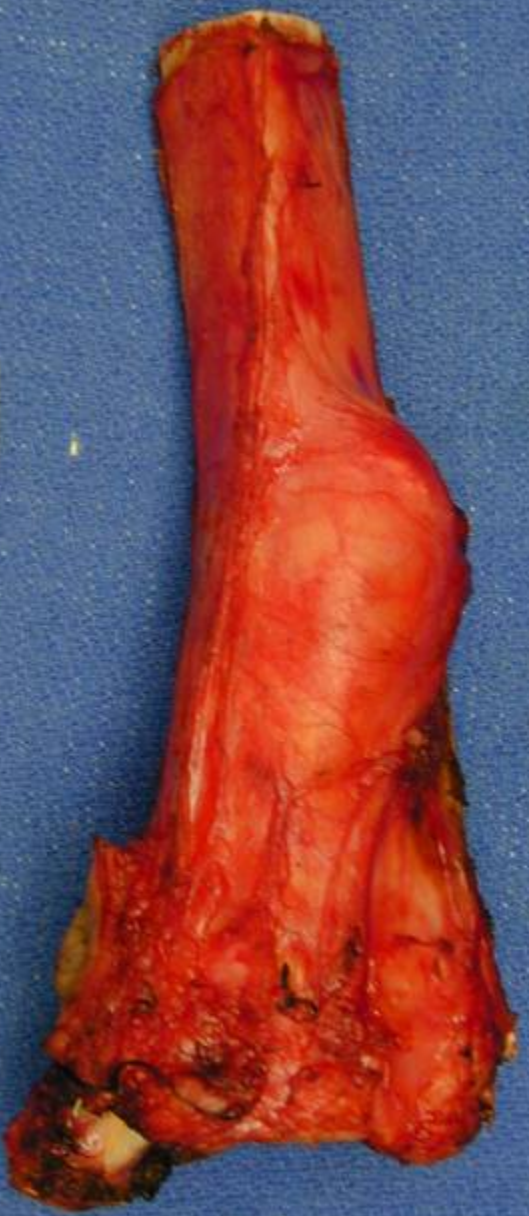Chondroblastic Subtype of a Conventional Osteosarcoma of Distal Tibia

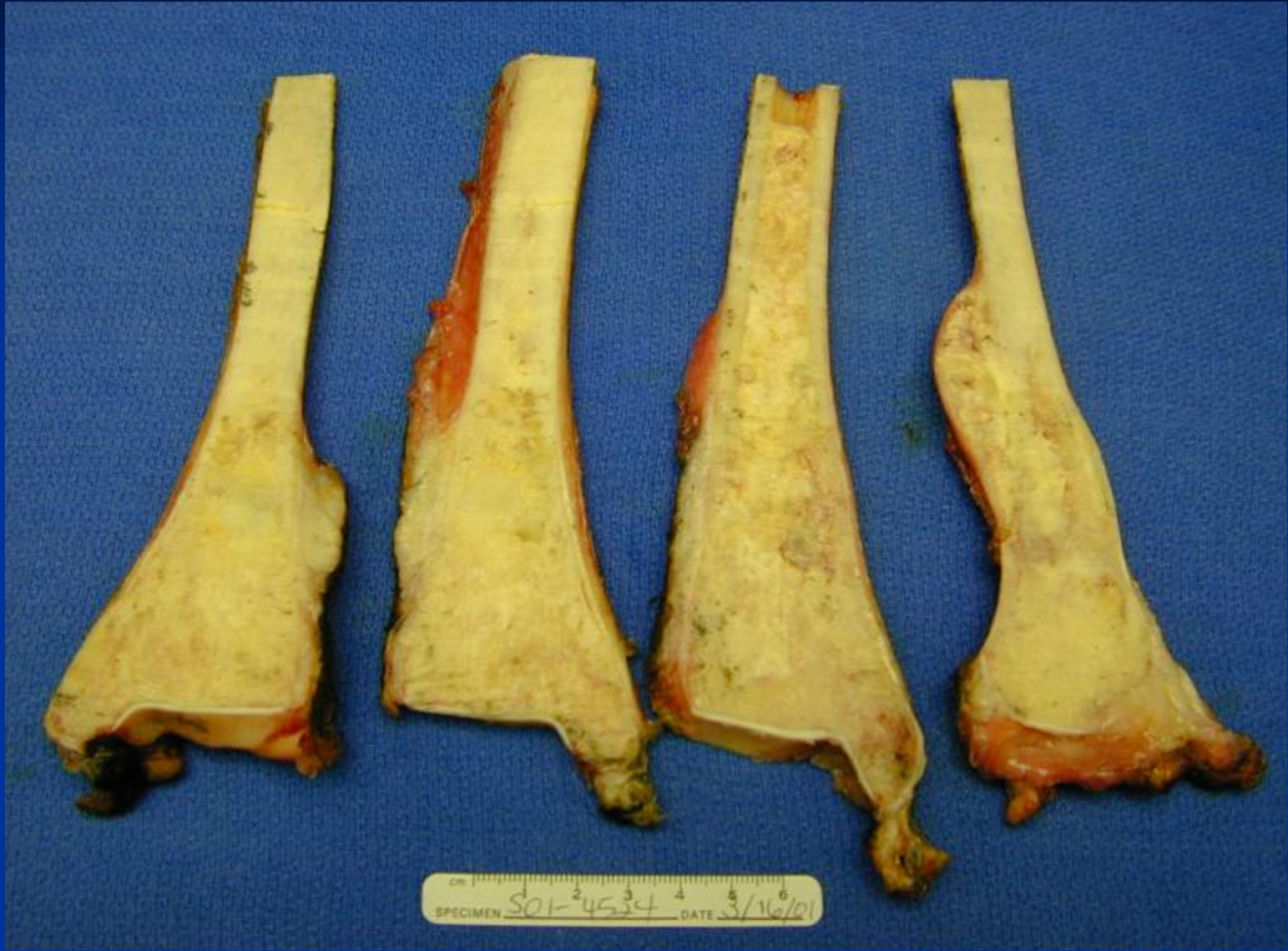







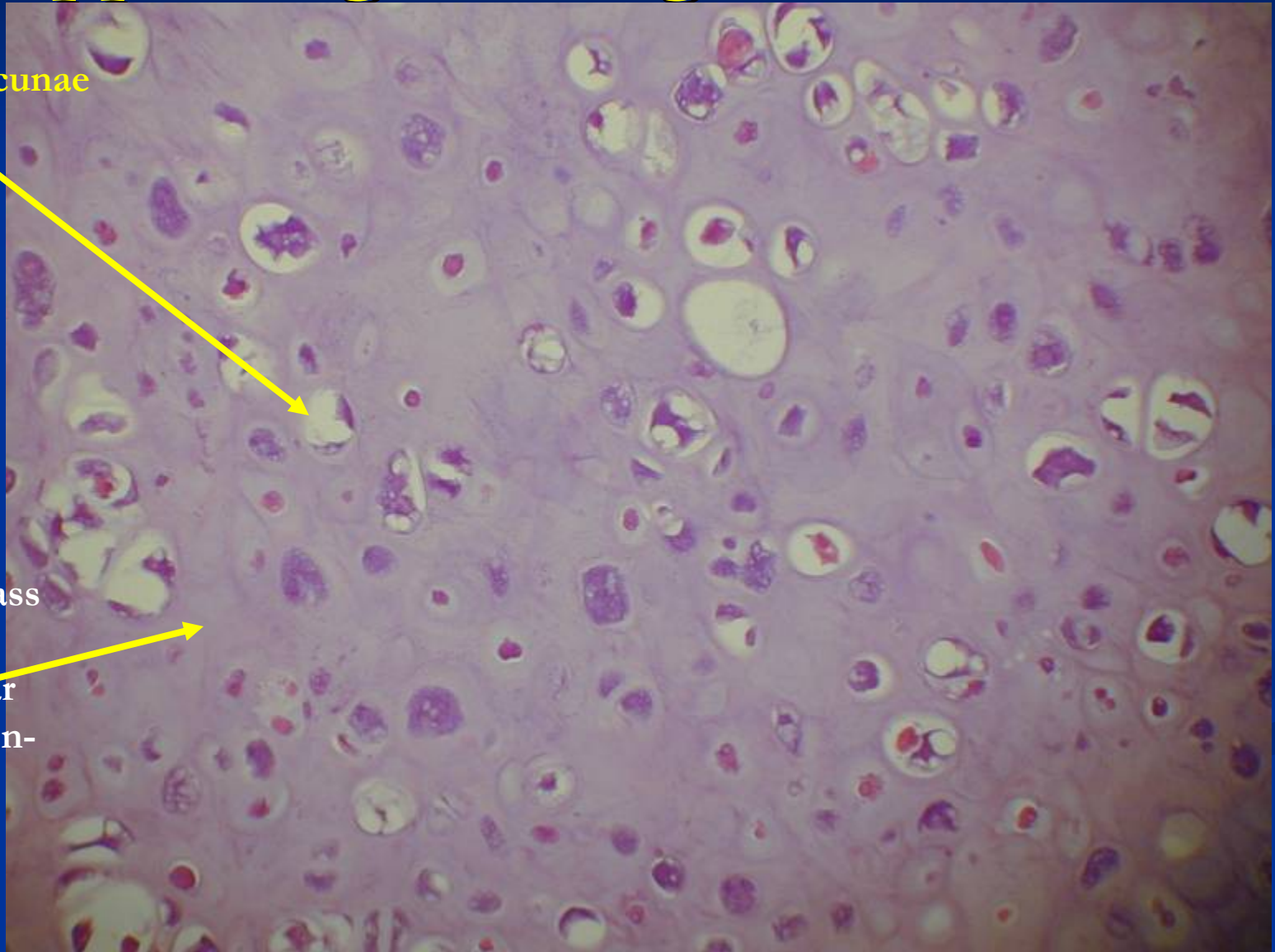
cm
SPECIMEN SD1-24634C4
DATE 3/16/01



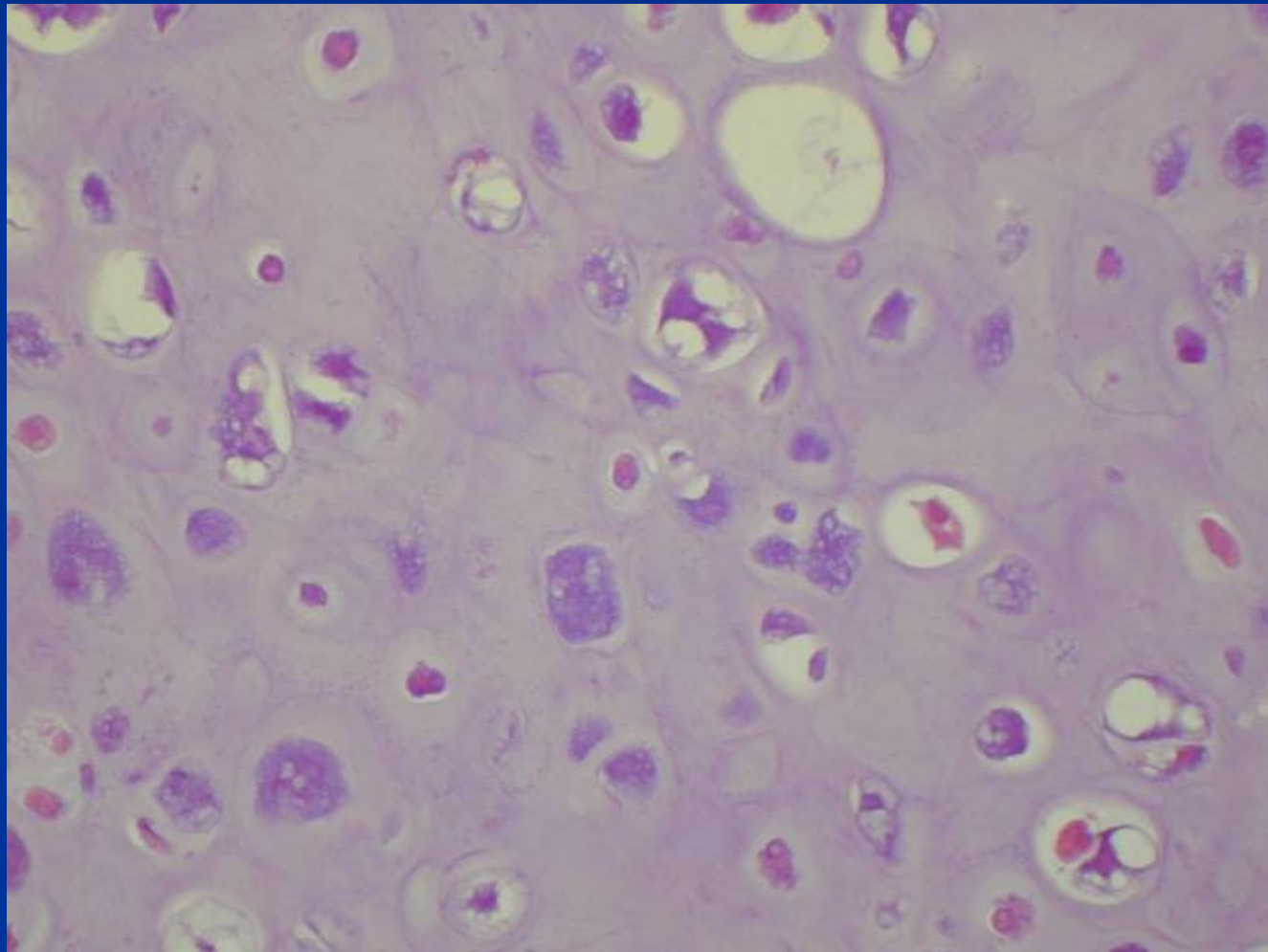
Microscopic Pathology—Malignant Appearing Cartilaginous Tissue

Cells in Lacunae

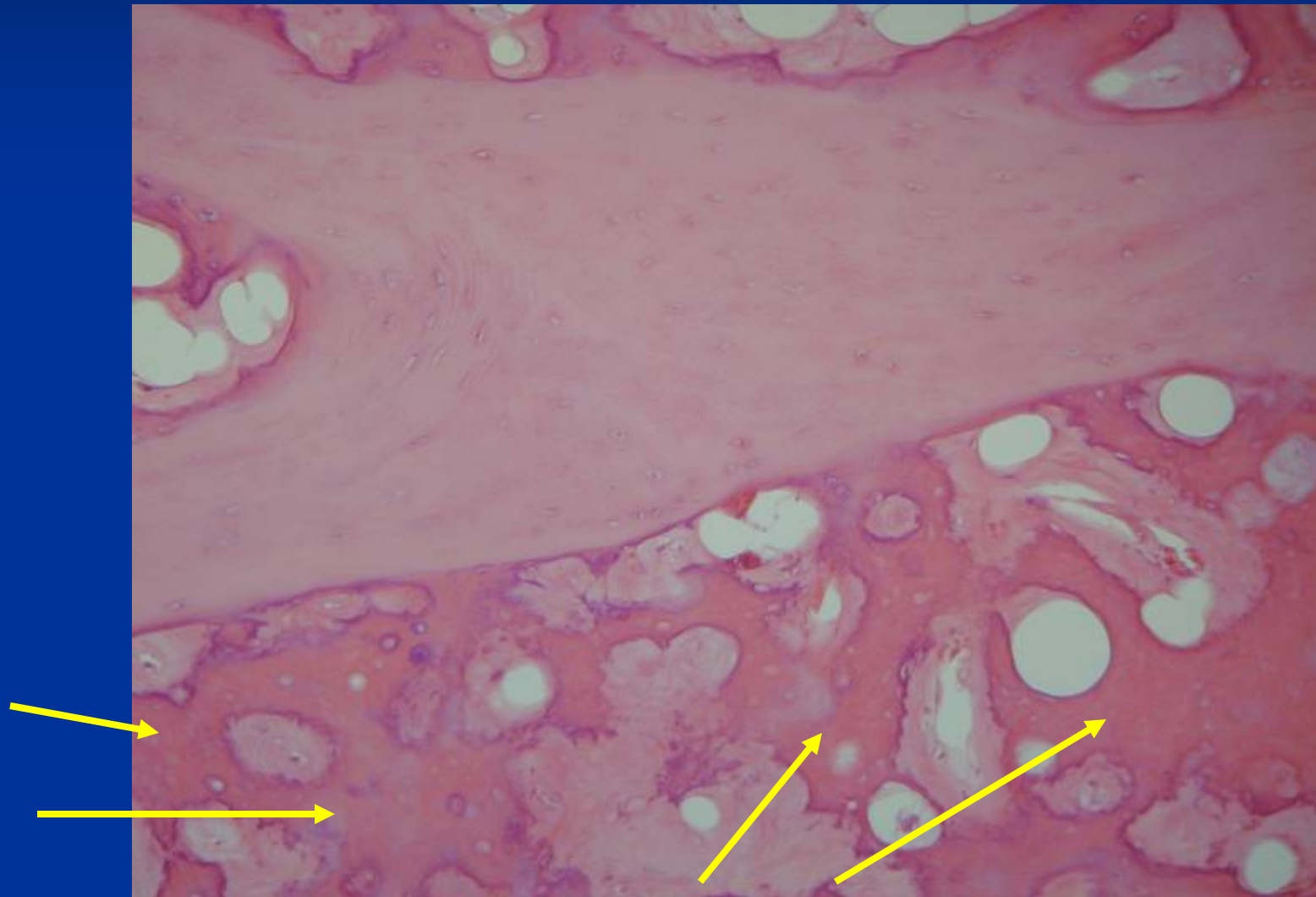
Ground Glass
Matrix—
Intercellular
Matrix (Non-
cellular
Substance)



**Hypercellular, Disorganized,
Crowded Cells, Multinucleated Cells,
Large Bizarre Nuclei**



Bone Production Identified which Categorizes it as an Osteosarcoma



Osteosarcoma

Conventional

- Pathologic Differential Diagnosis:
 - Osteoblastoma
 - Osteoid Osteoma
 - Giant Cell Tumor
 - Fracture Callus
 - Fibrosarcoma
 - Chondrosarcoma
 - MFH

Osteosarcoma

■ Treatment:

■ Preoperative (induction) chemotherapy:

- Adriamycin (doxorubicin)
- Cisplatin (cisplatin)
- High Dose Methotrexate (HDMTX)
- Ifosfamide/Etoposide in some regimens
(2 cycles and then surgery)

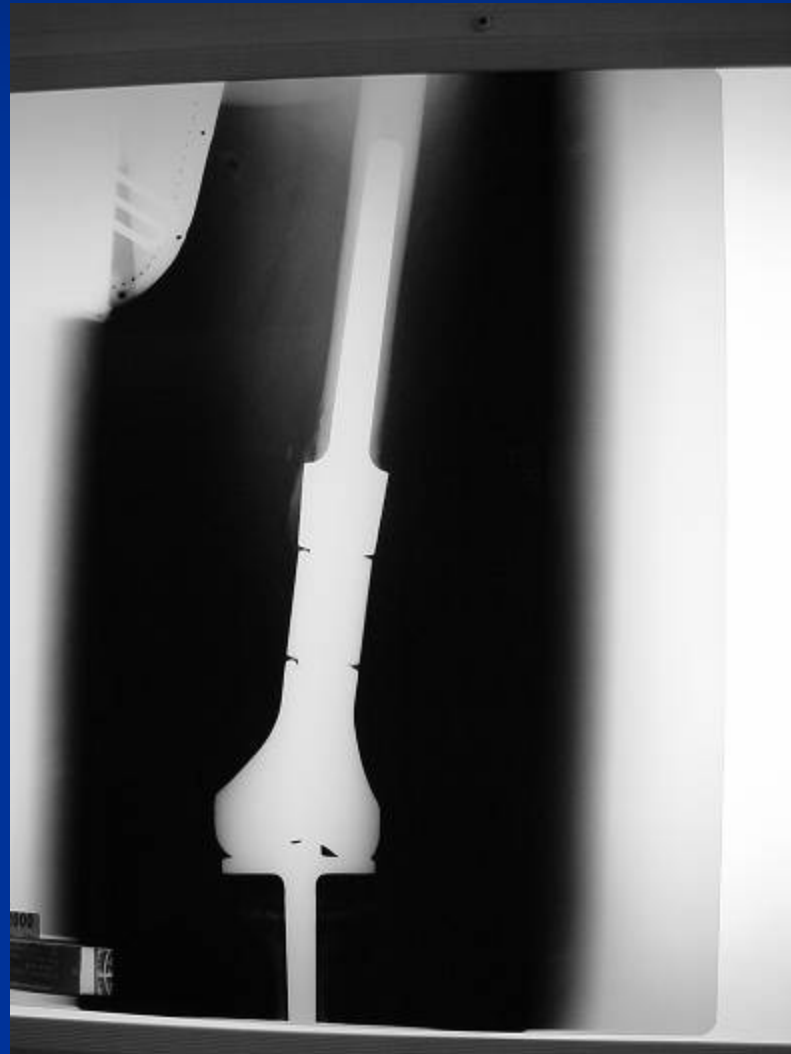■ Surgery:

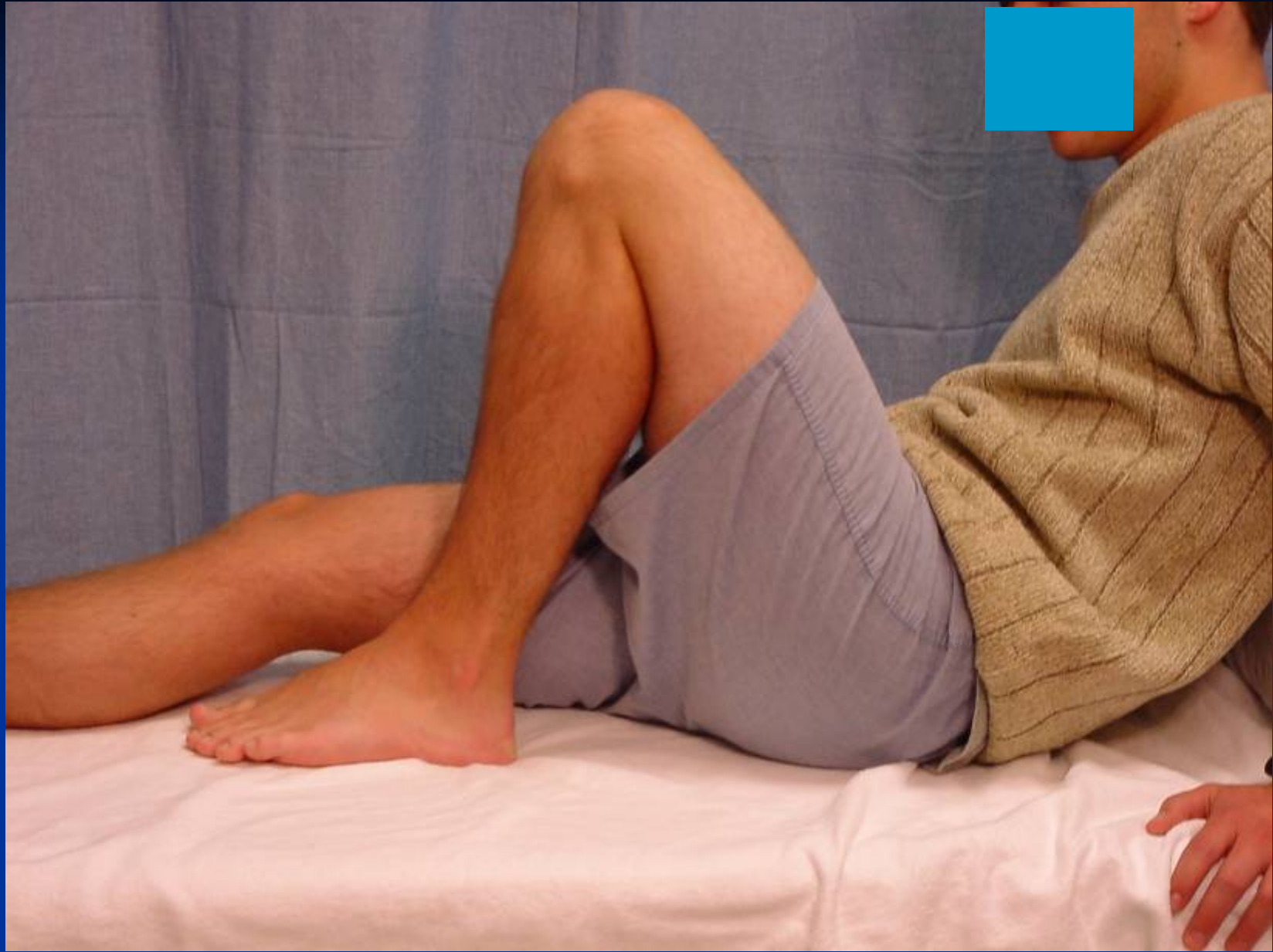- Wide surgical resection /Limb Salvage(95% of extremity lesions)
- Amputation (5% of extremity lesions)

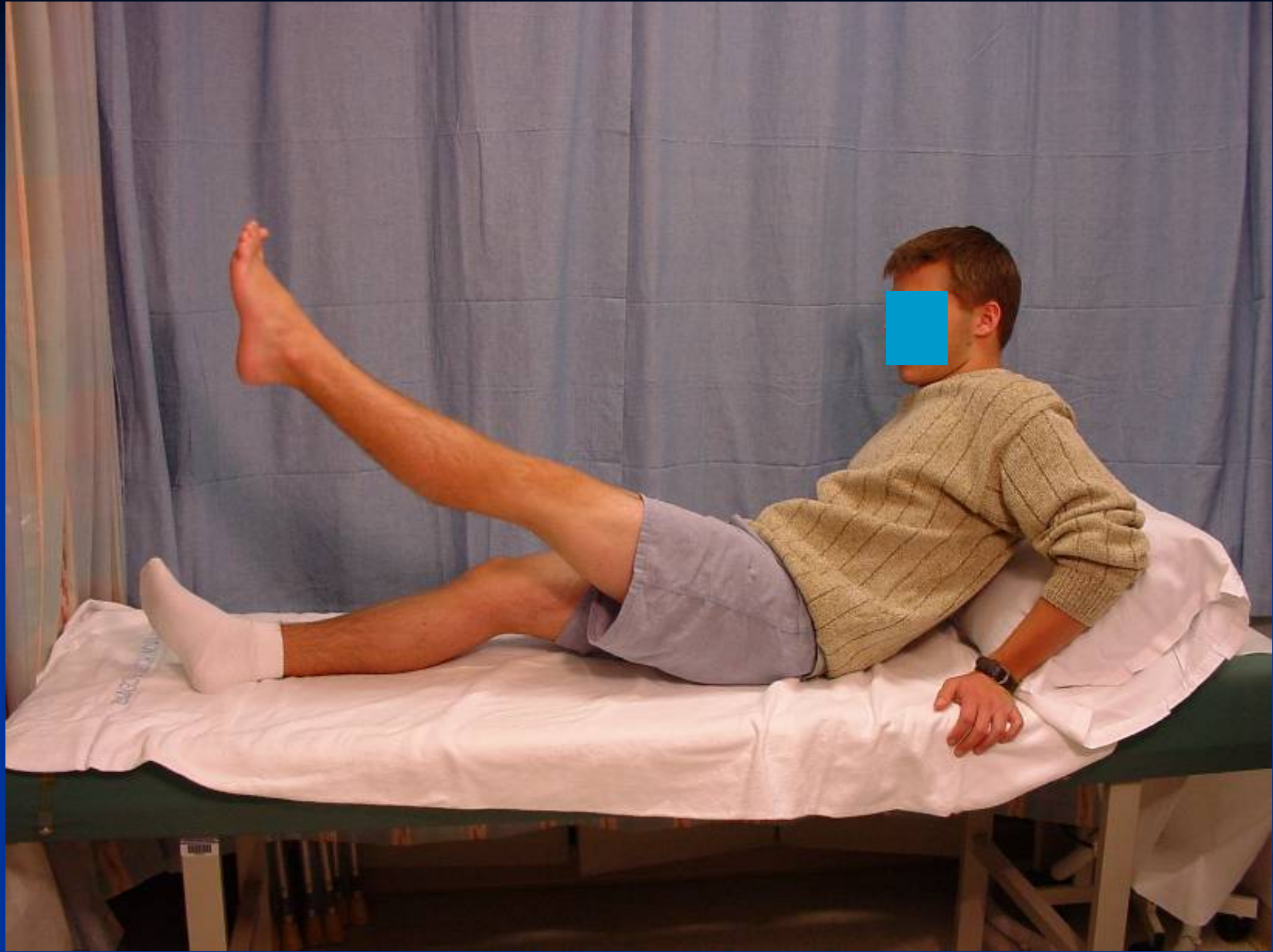
■ Postoperative (adjuvant) chemotherapy:

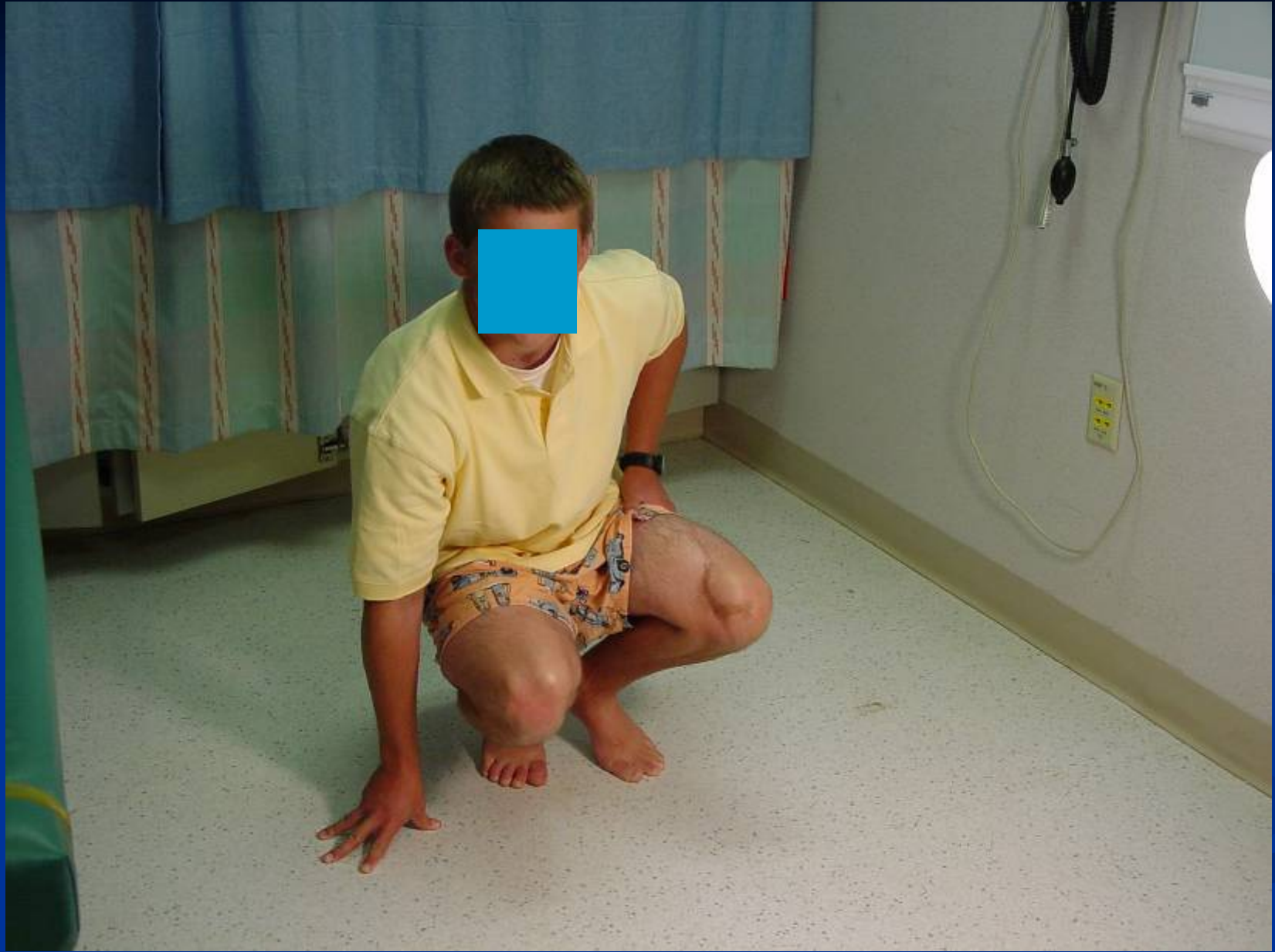- Same regimen as preop; usually 4 cycles

Limb Salvage: Radical Resection of Distal Femur Osteosarcoma and Reconstruction with Distal Femur Tumor Prosthesis

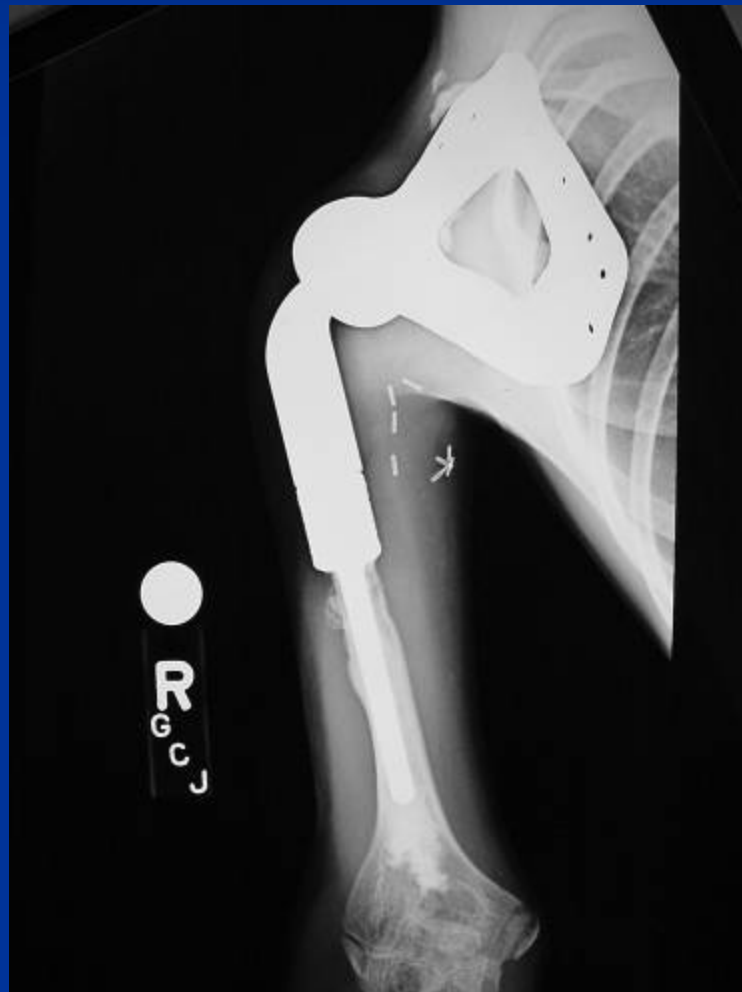

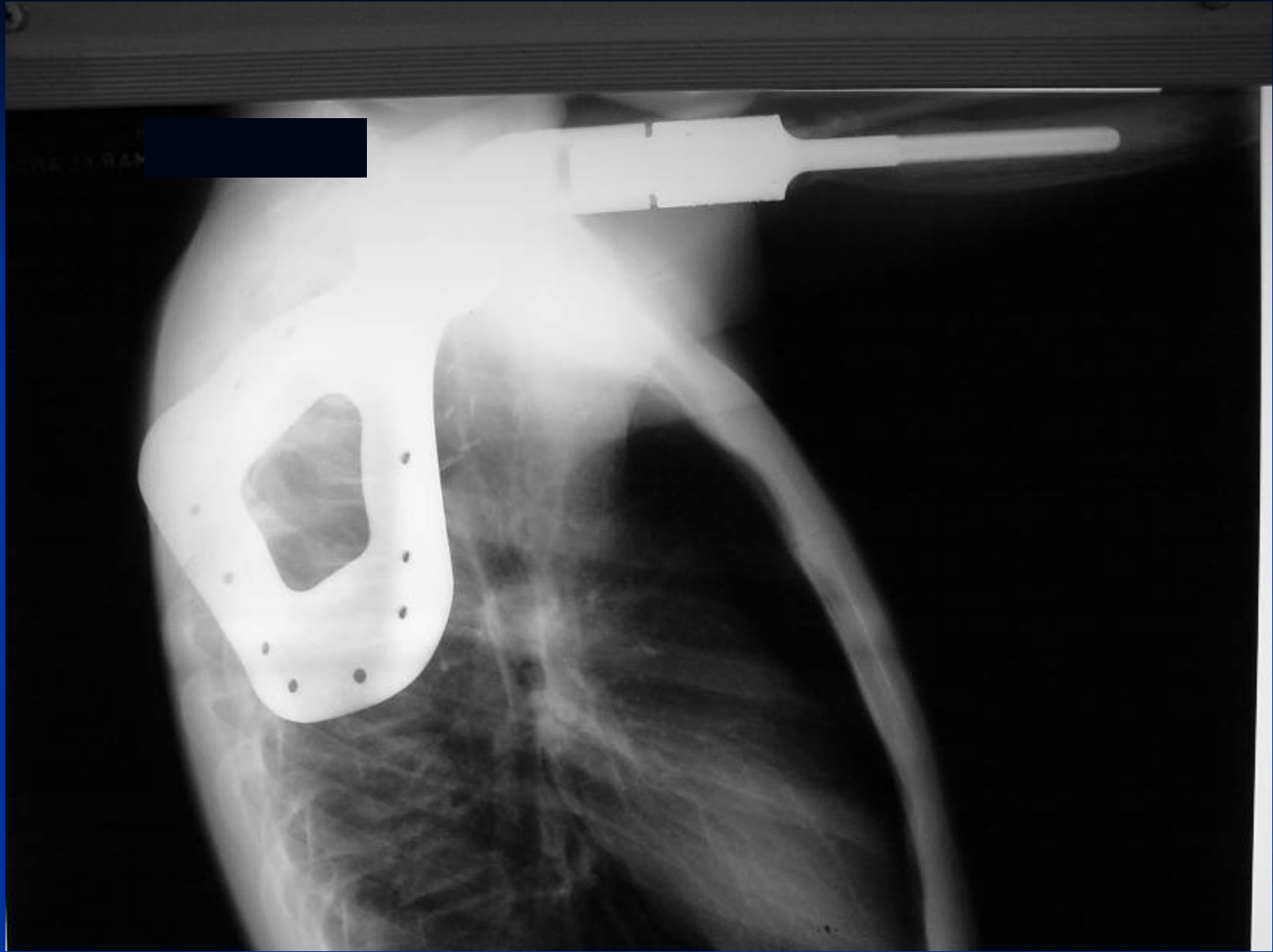



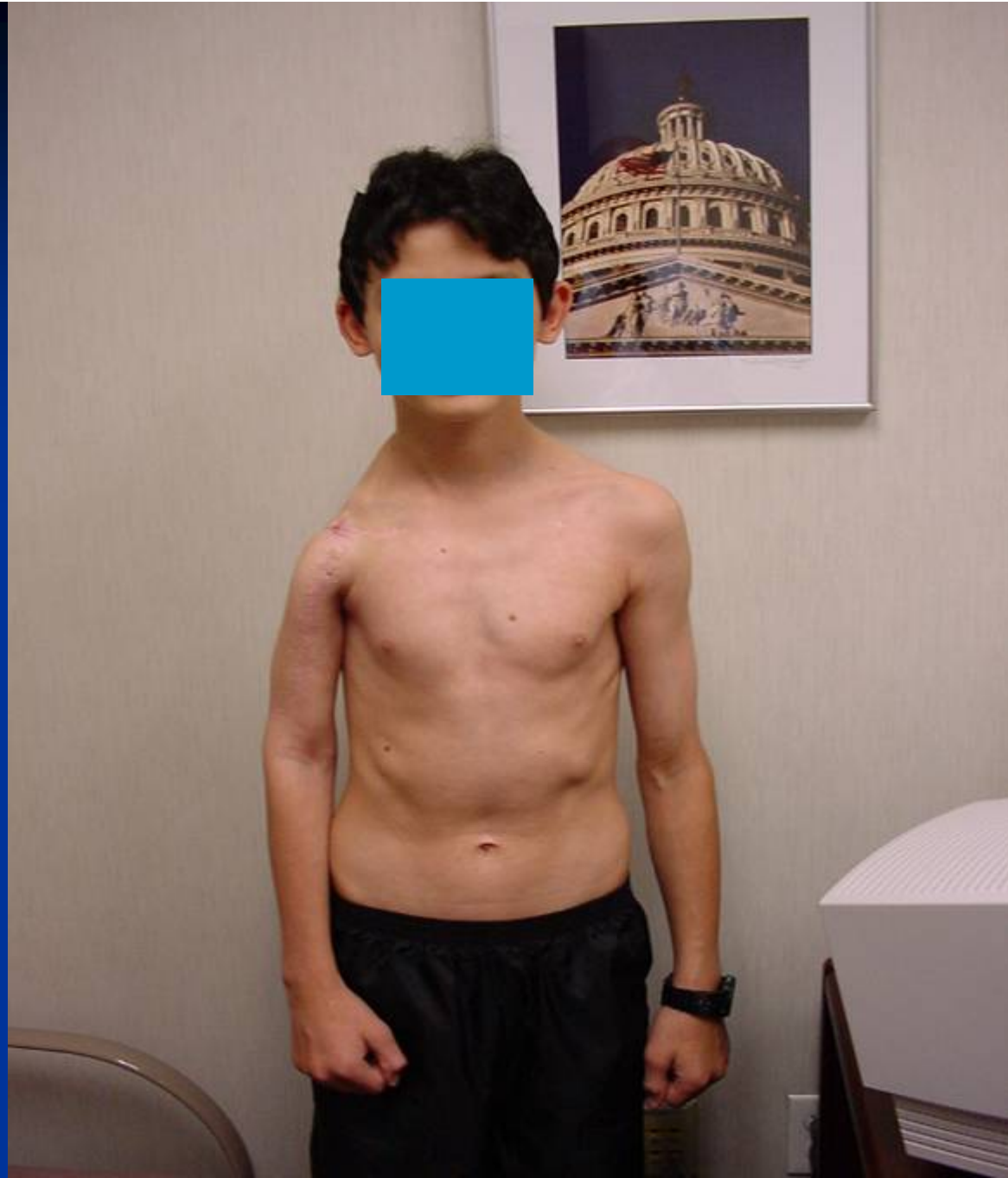
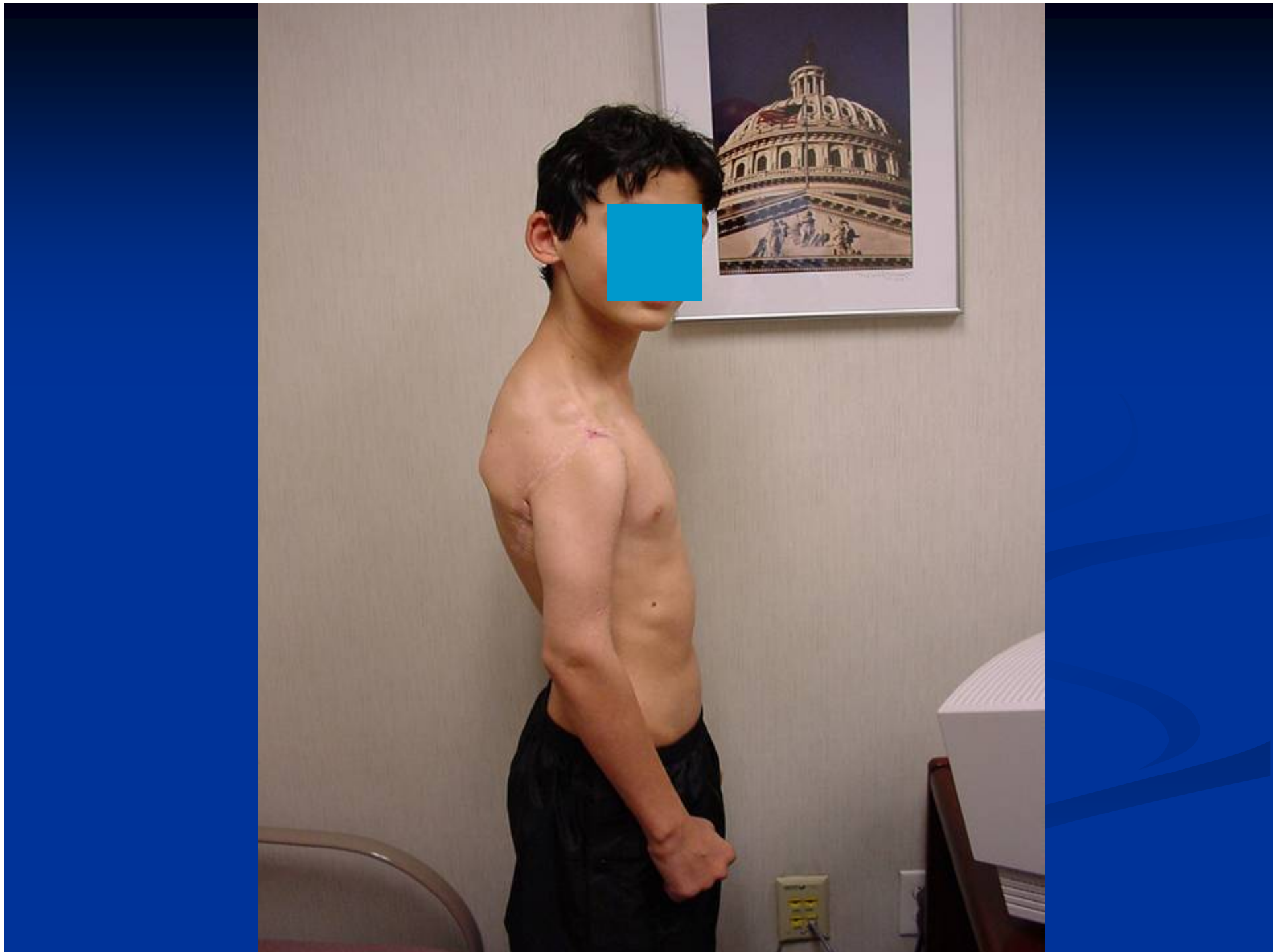


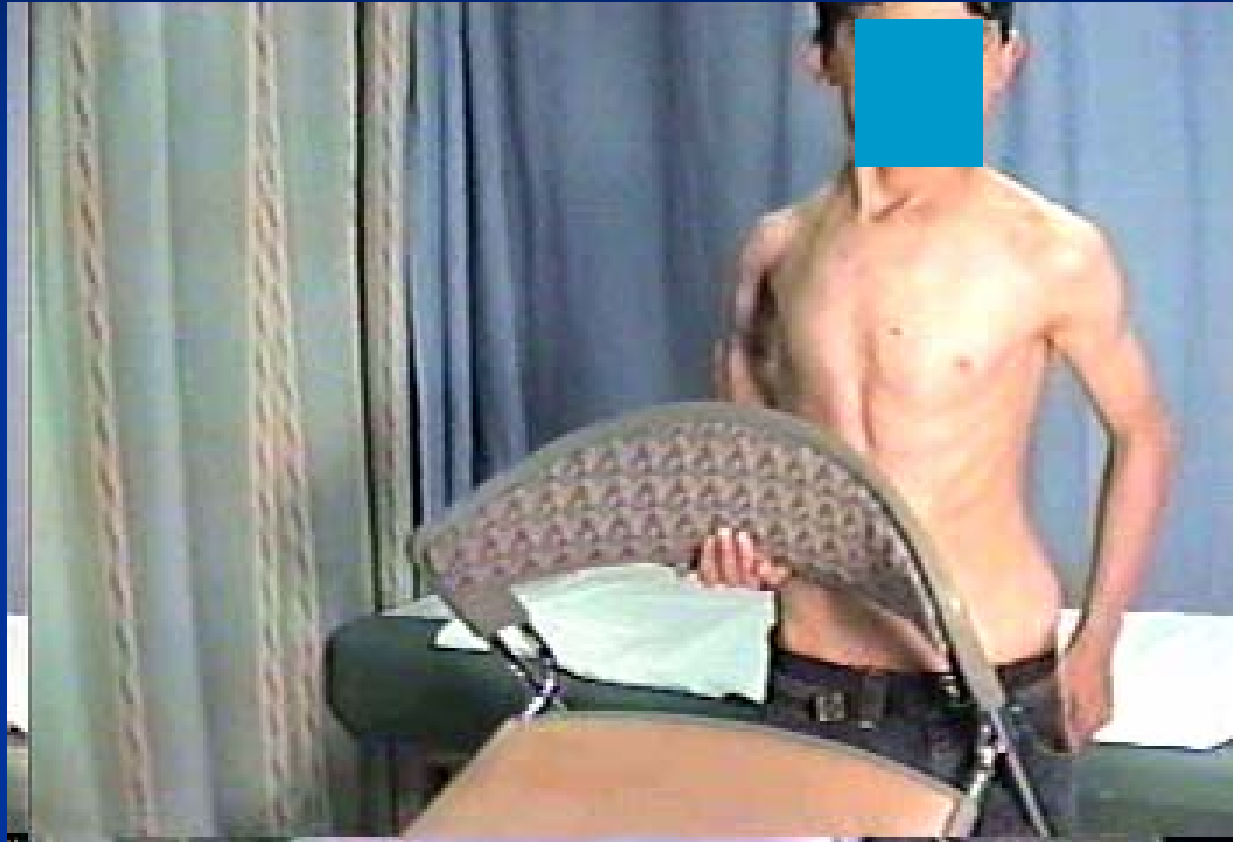Radical Resection of proximal Humerus Osteosarcoma with Metastasis to Scapula: Reconstruction with total Scapula Prosthetic Replacement



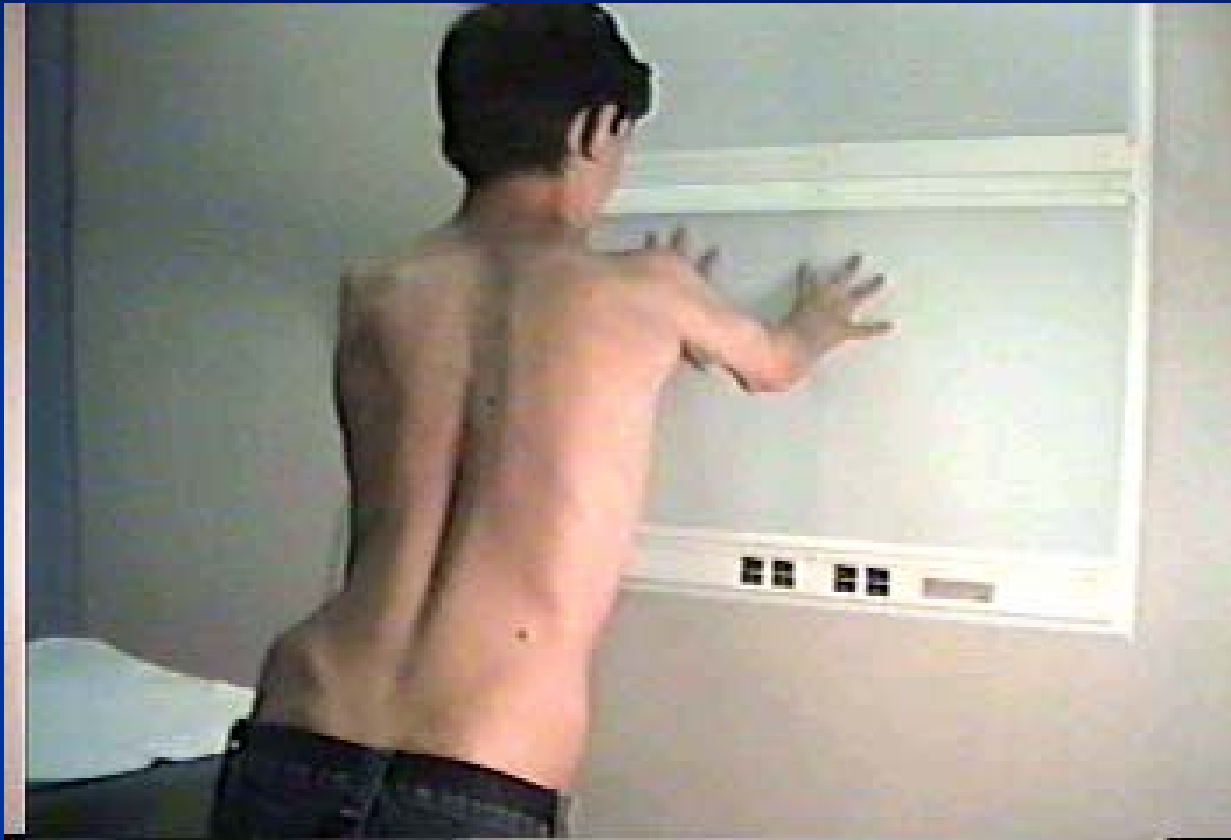




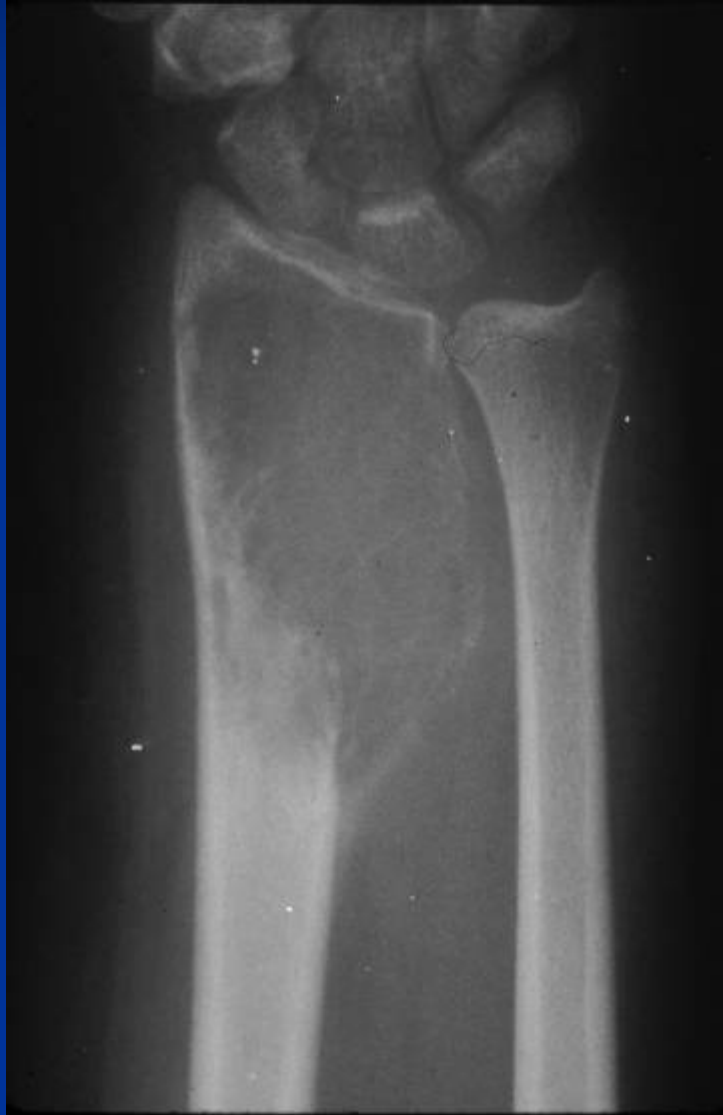


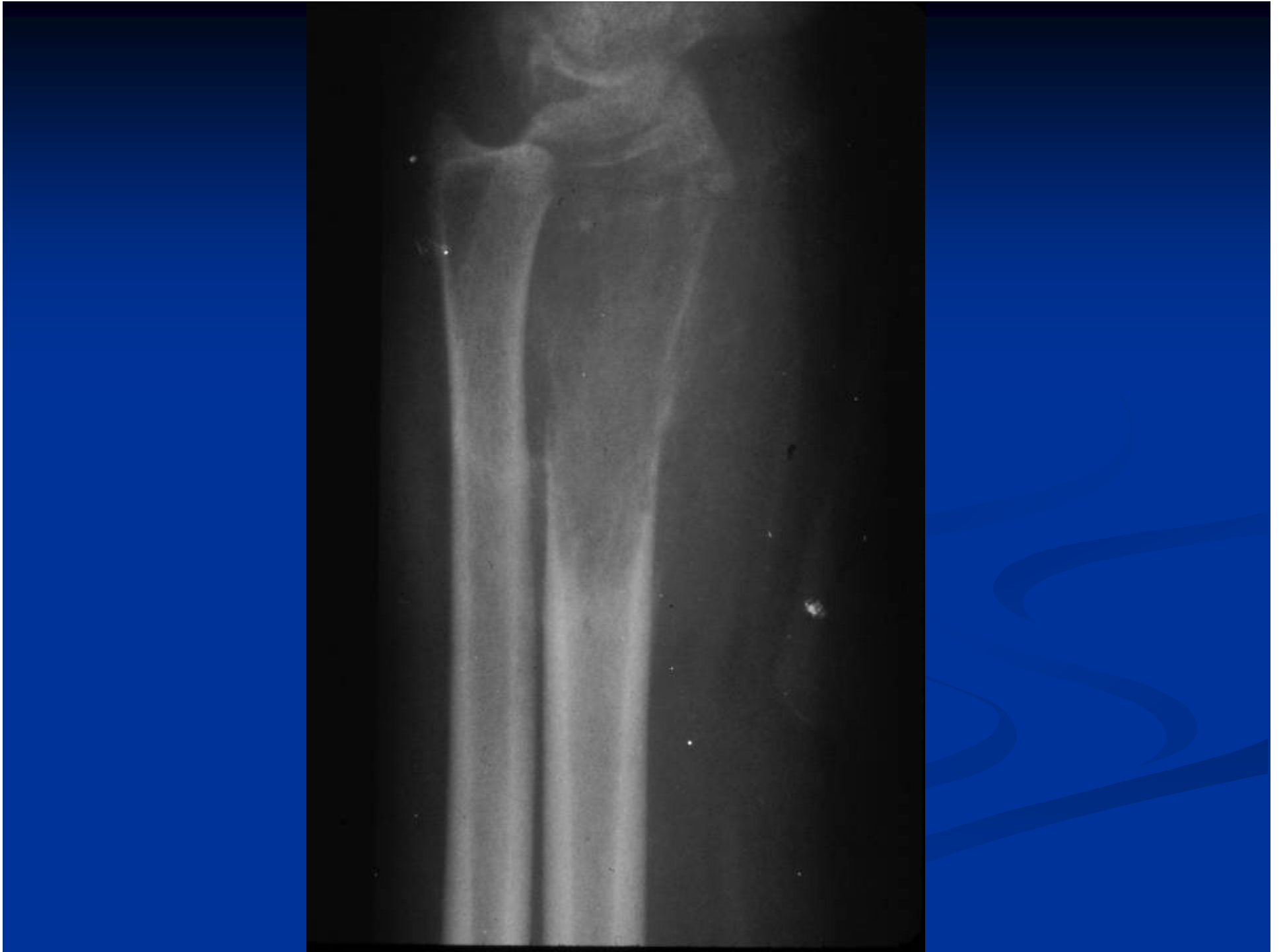

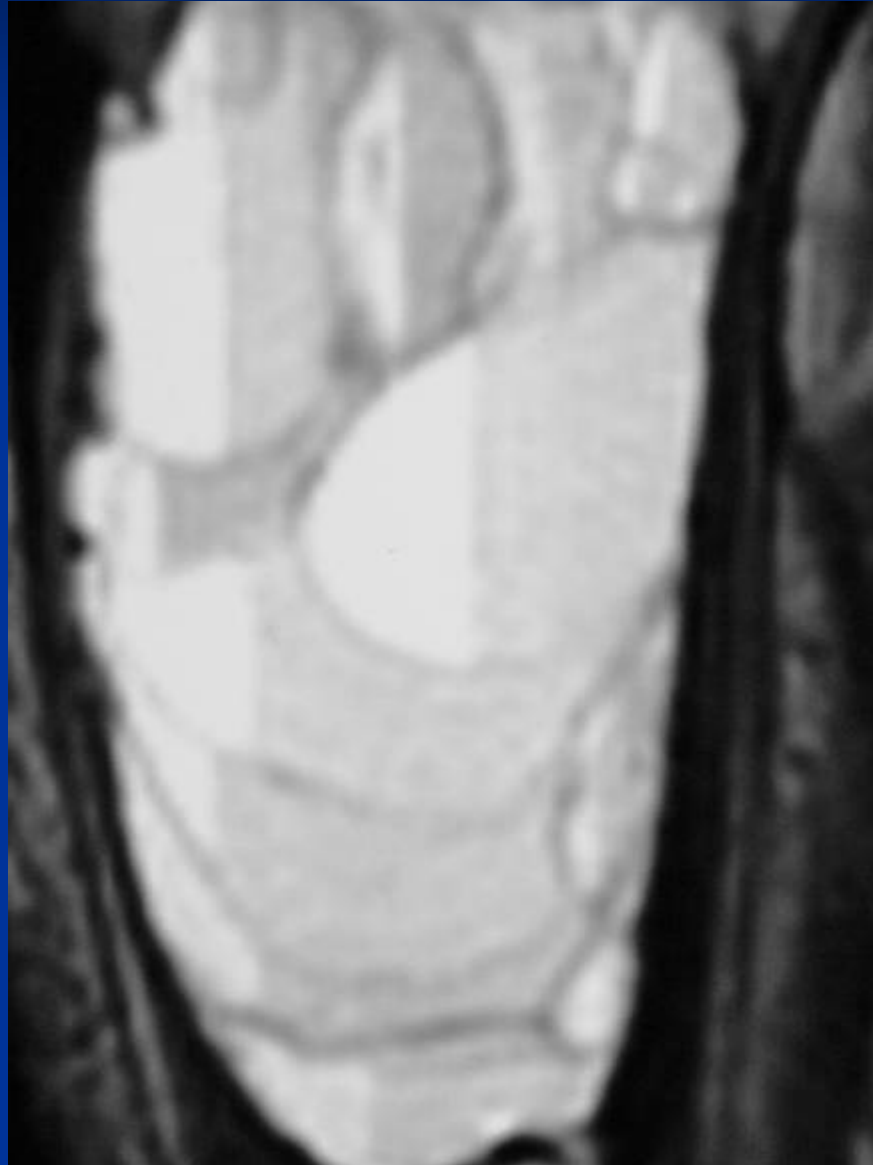


Telangiectatic Osteosarcoma of Distal Radius



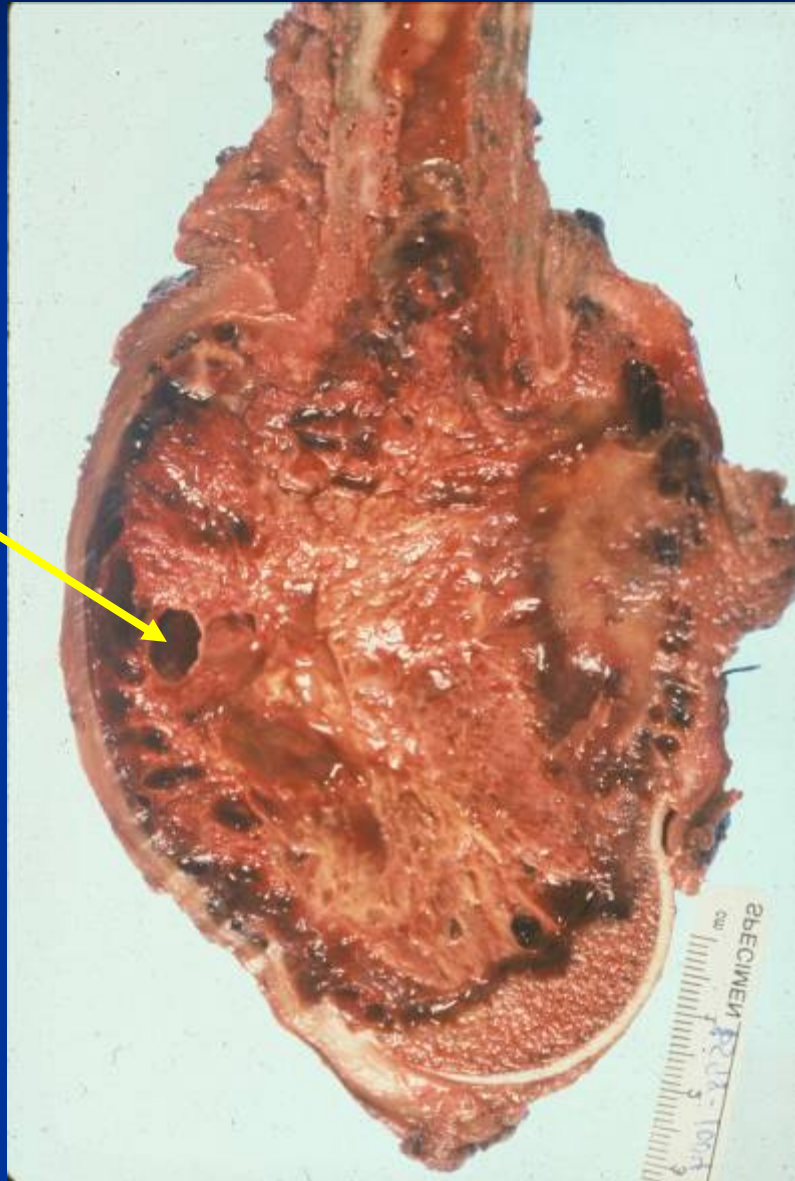


MRI Demonstrating Multiple fluid-Fluid Levels

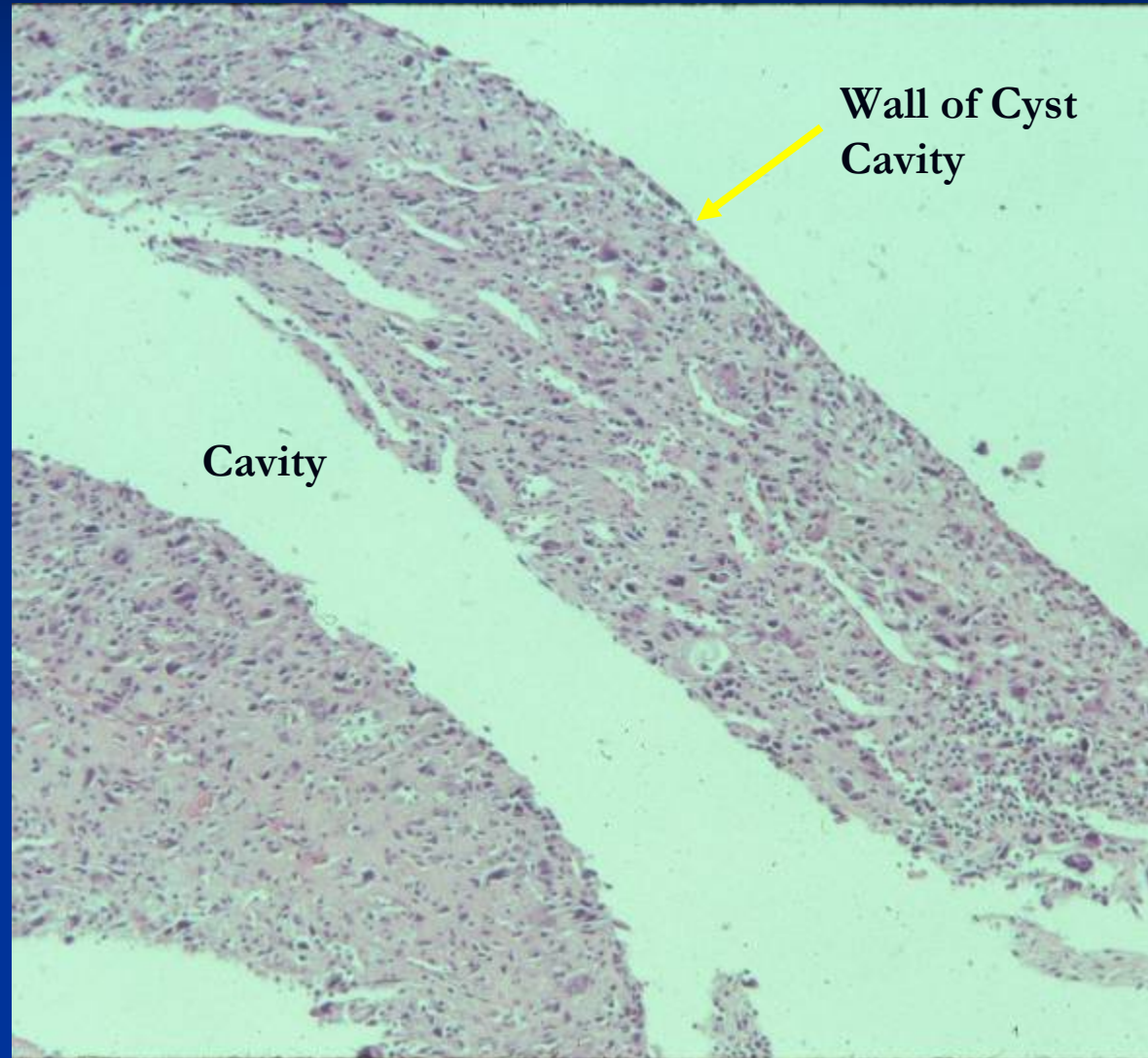


Gross Pathology: Telangiectatic Osteosarcoma

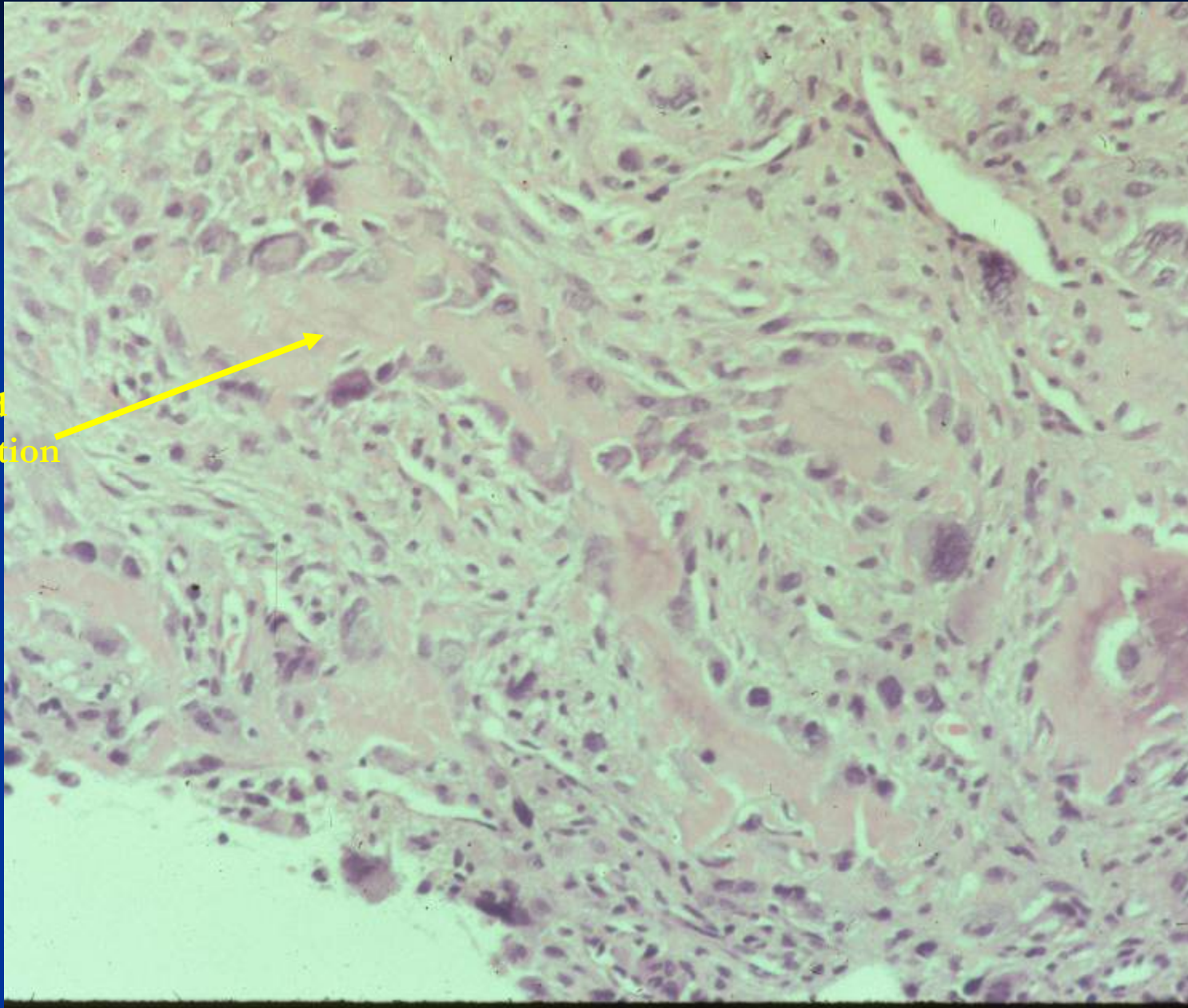
Multiple Cystic
and Necrotic
Spaces/Cavities



Microscopic Pathology



Osteoid
Production



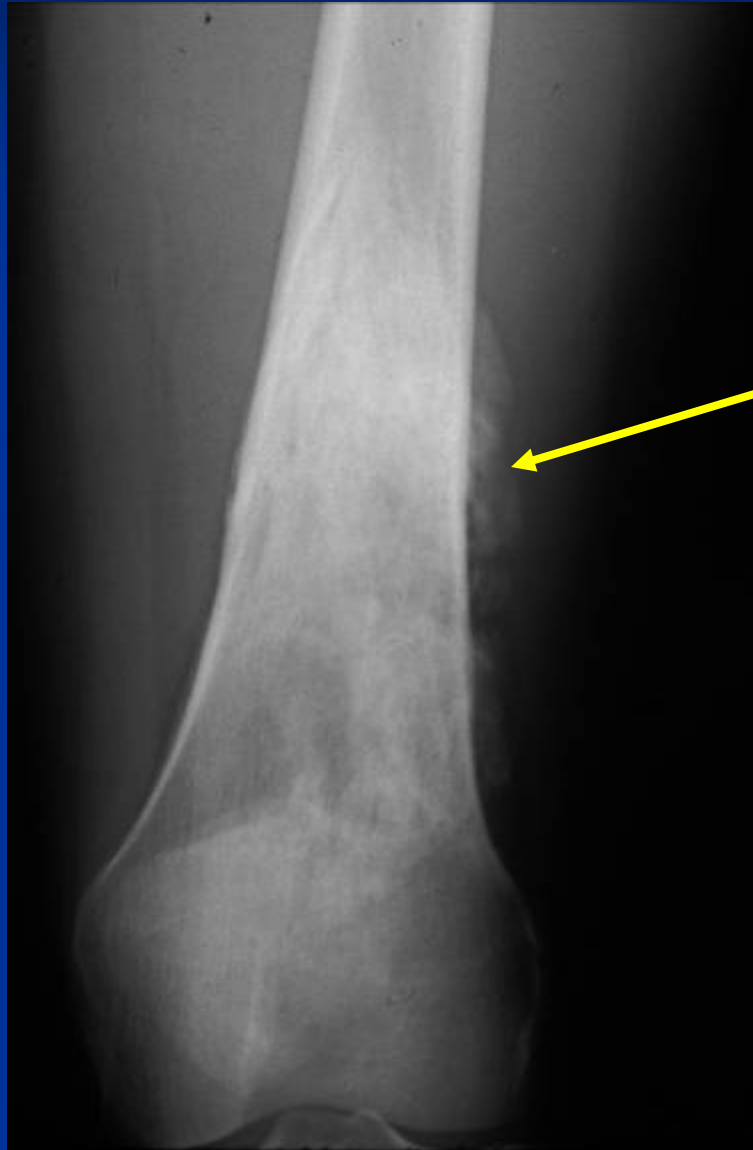Telangiectatic Osteosarcoma

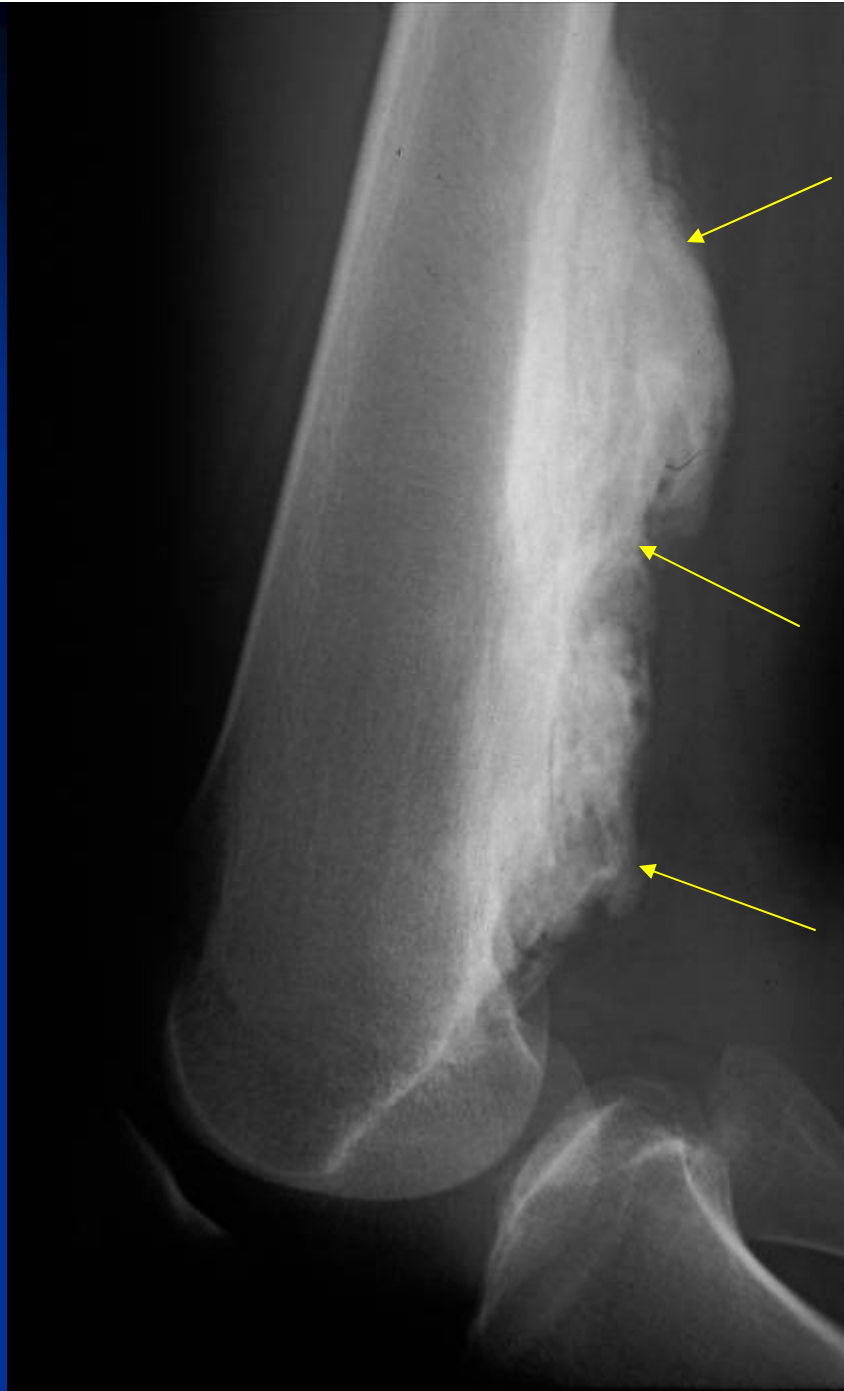
- Radiographic Differential Dx:
 - Conventional osteosarcoma
 - Fibrosarcoma
 - MFH
 - Aneurysmal Bone Cyst

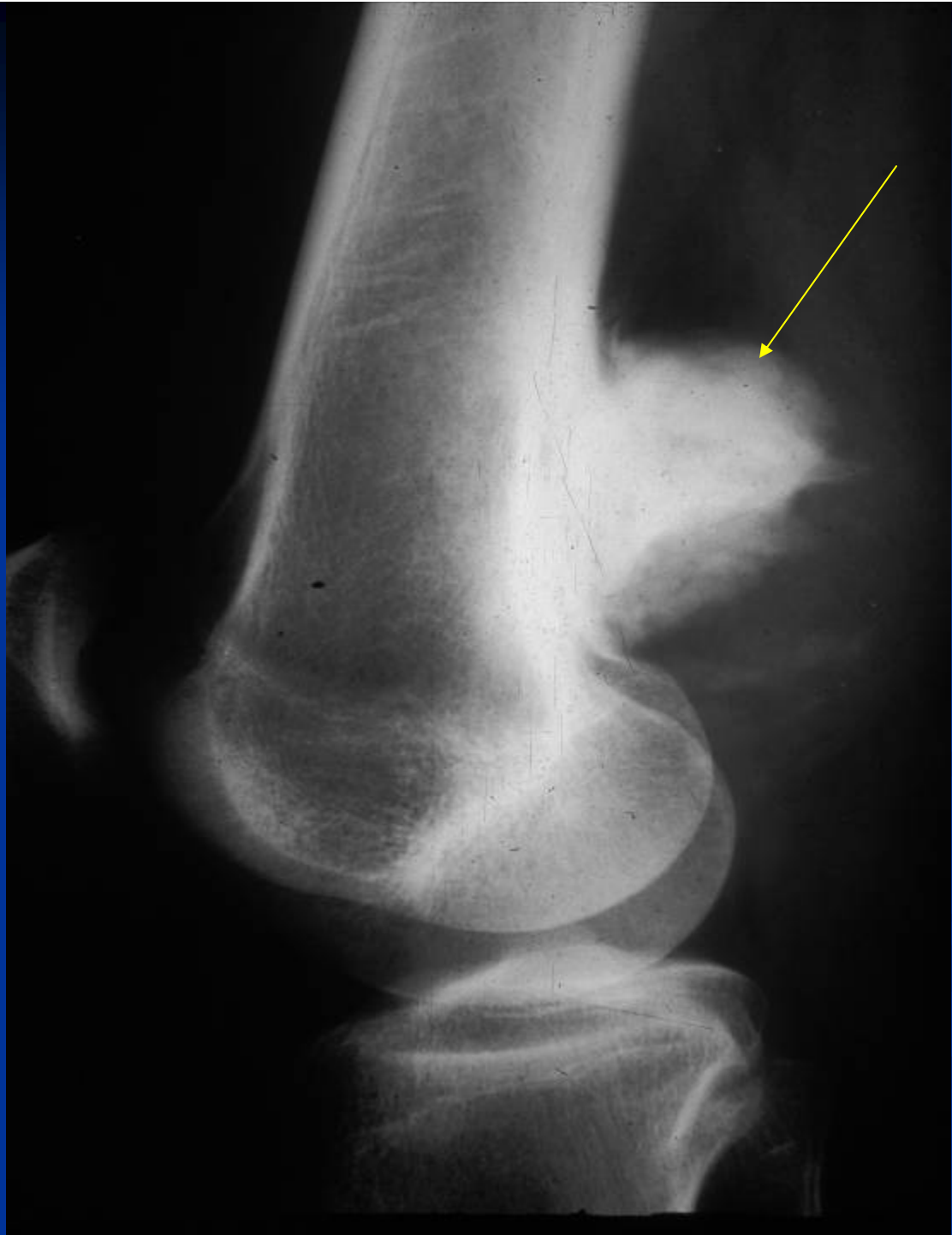Telangiectatic Osteosarcoma

- Treatment and Prognosis same as conventional osteosarcoma

Parosteal Osteosarcoma



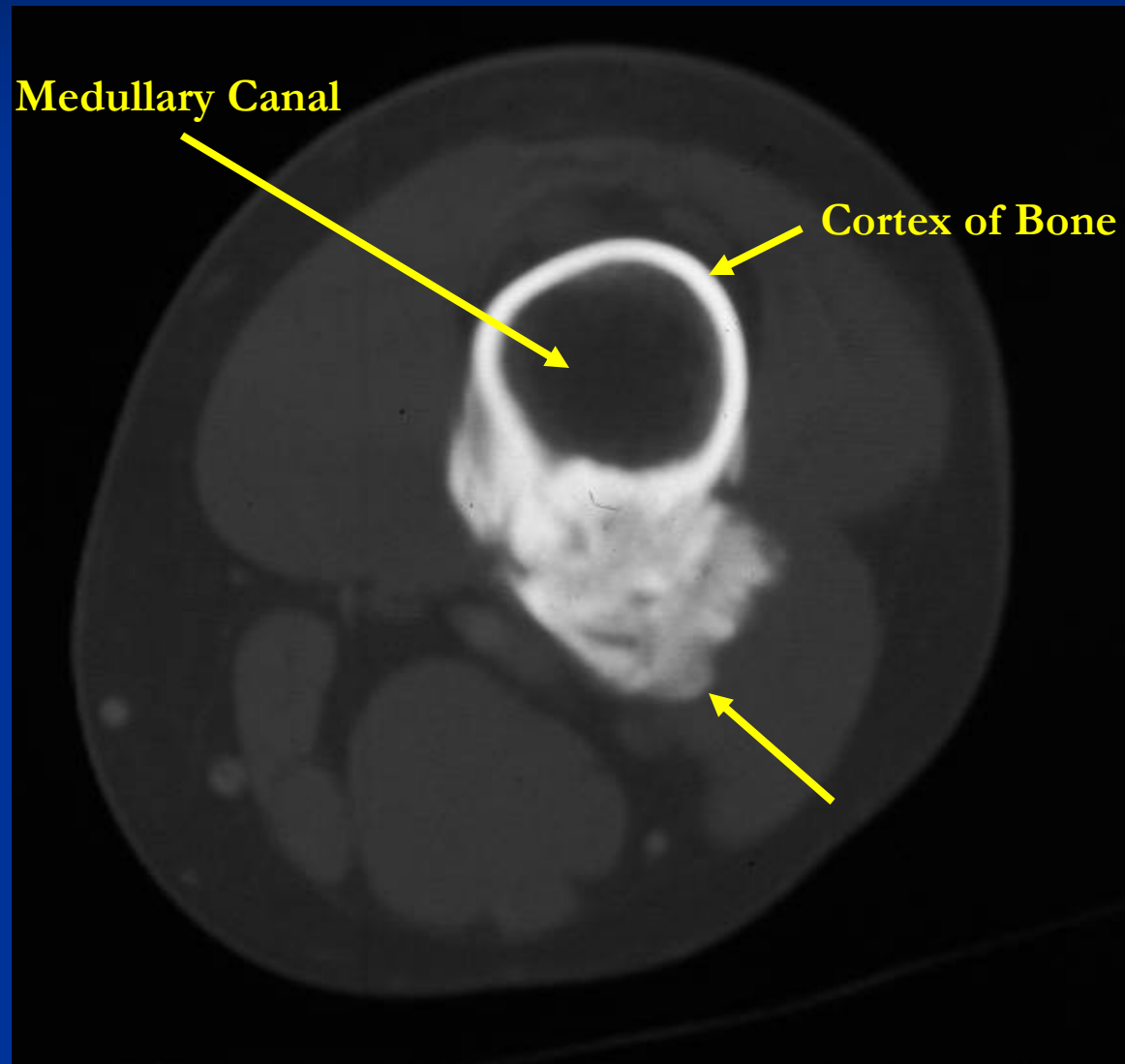




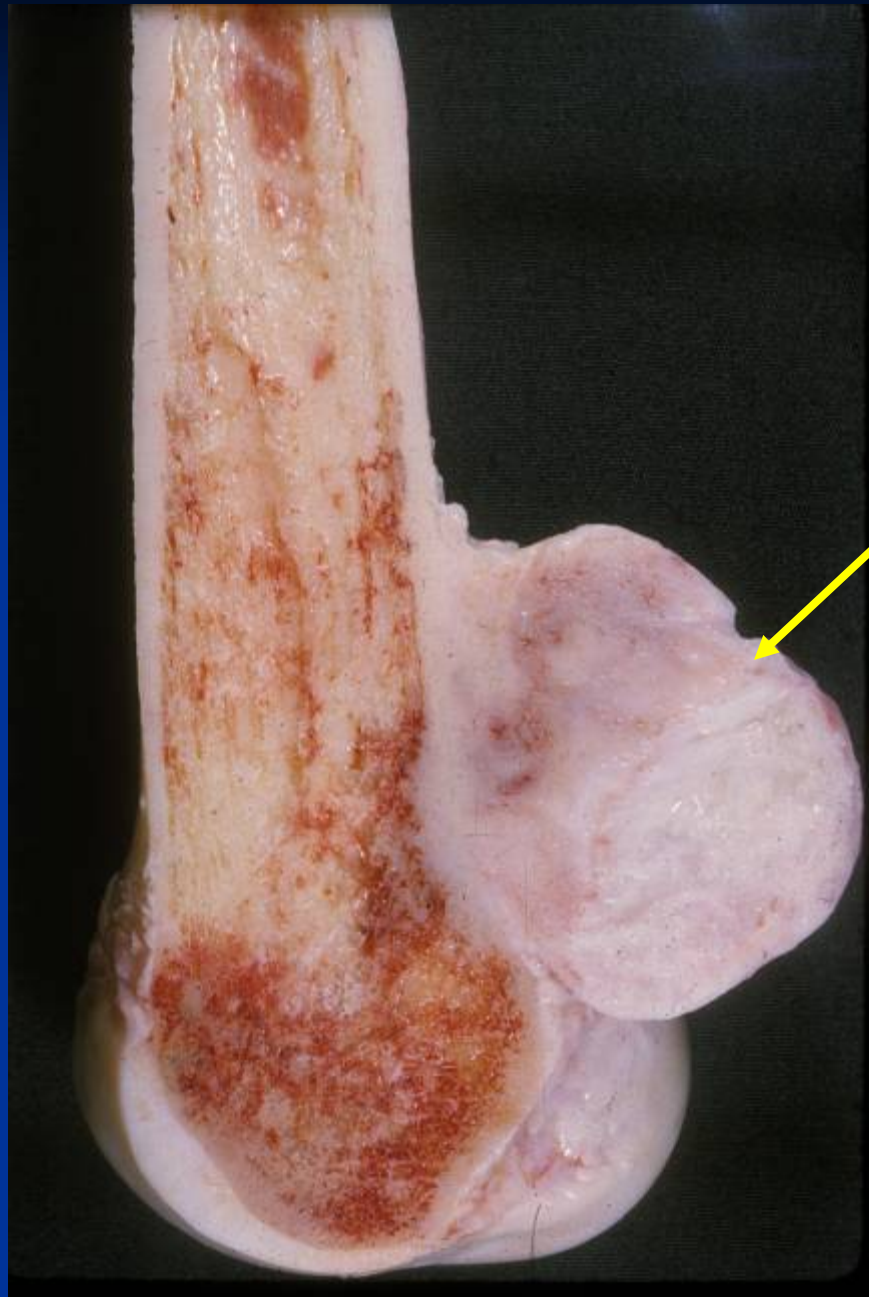
Parosteal Osteosarcoma

- Radiology:
 - MRI/CT:
 - Medullary invasion
 - Any areas that may be high grade
 - Local extent---circumference of femur
 - CT of chest for detecting pulmonary mets

CT Scan of Distal Femur Parosteal Osteosarcoma

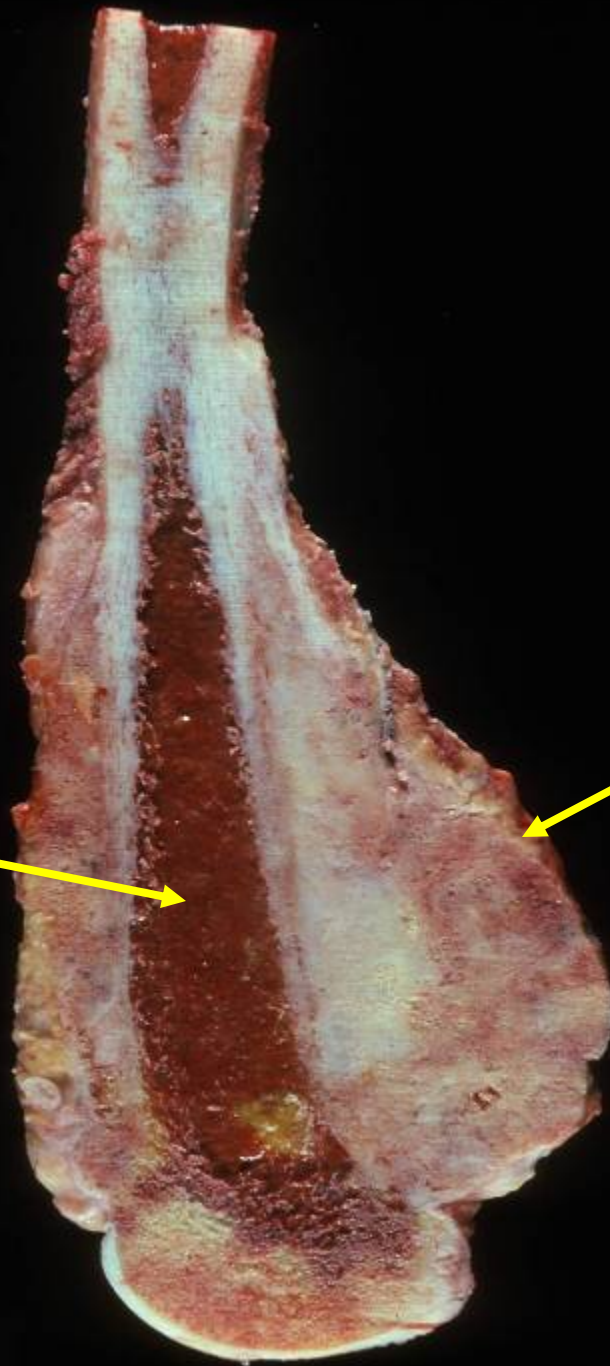


Gross and Microscopic Pathology

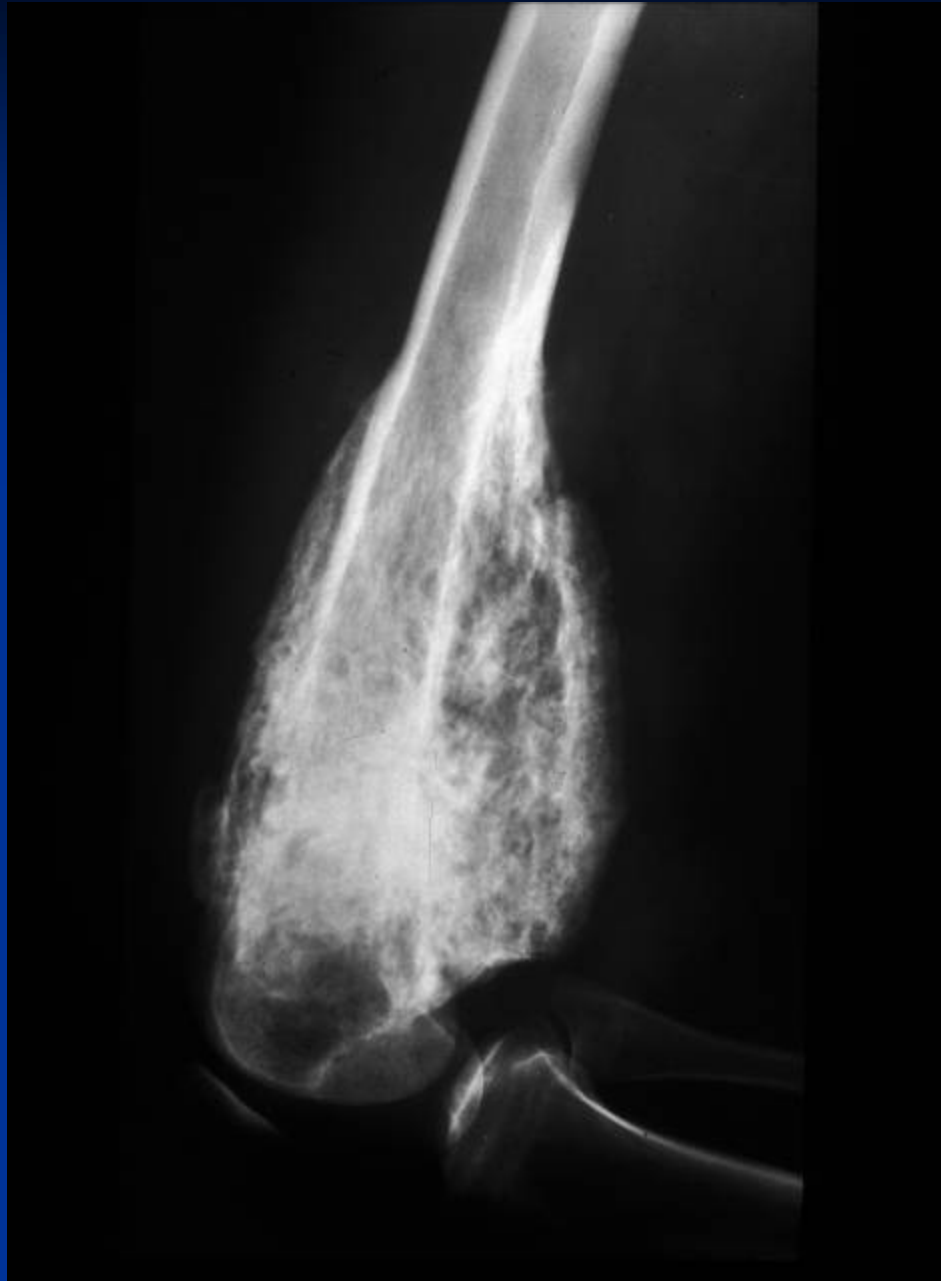


Tumor

**Medullary
Canal of Bone**



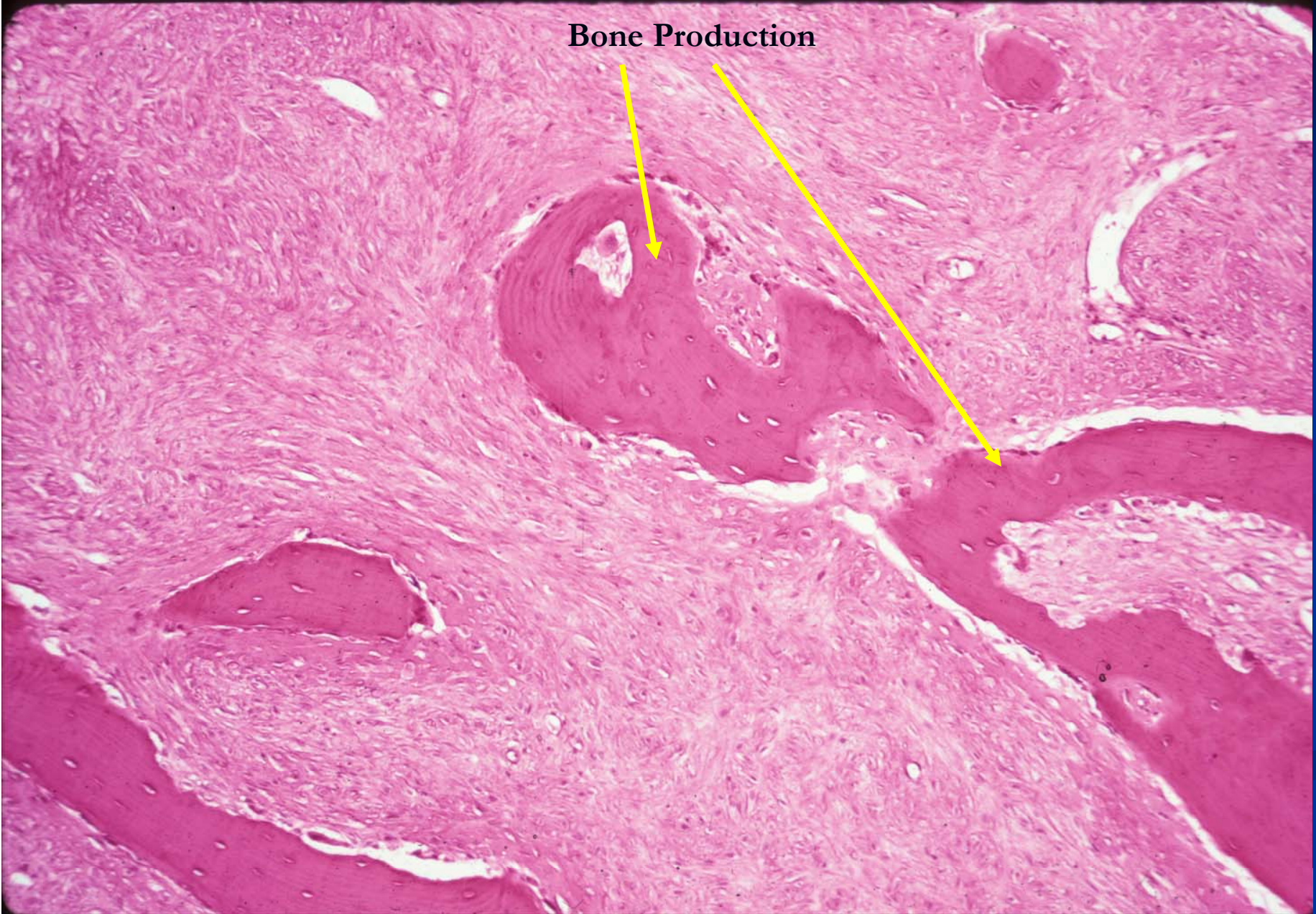**Tumor on
Surface of Bone**

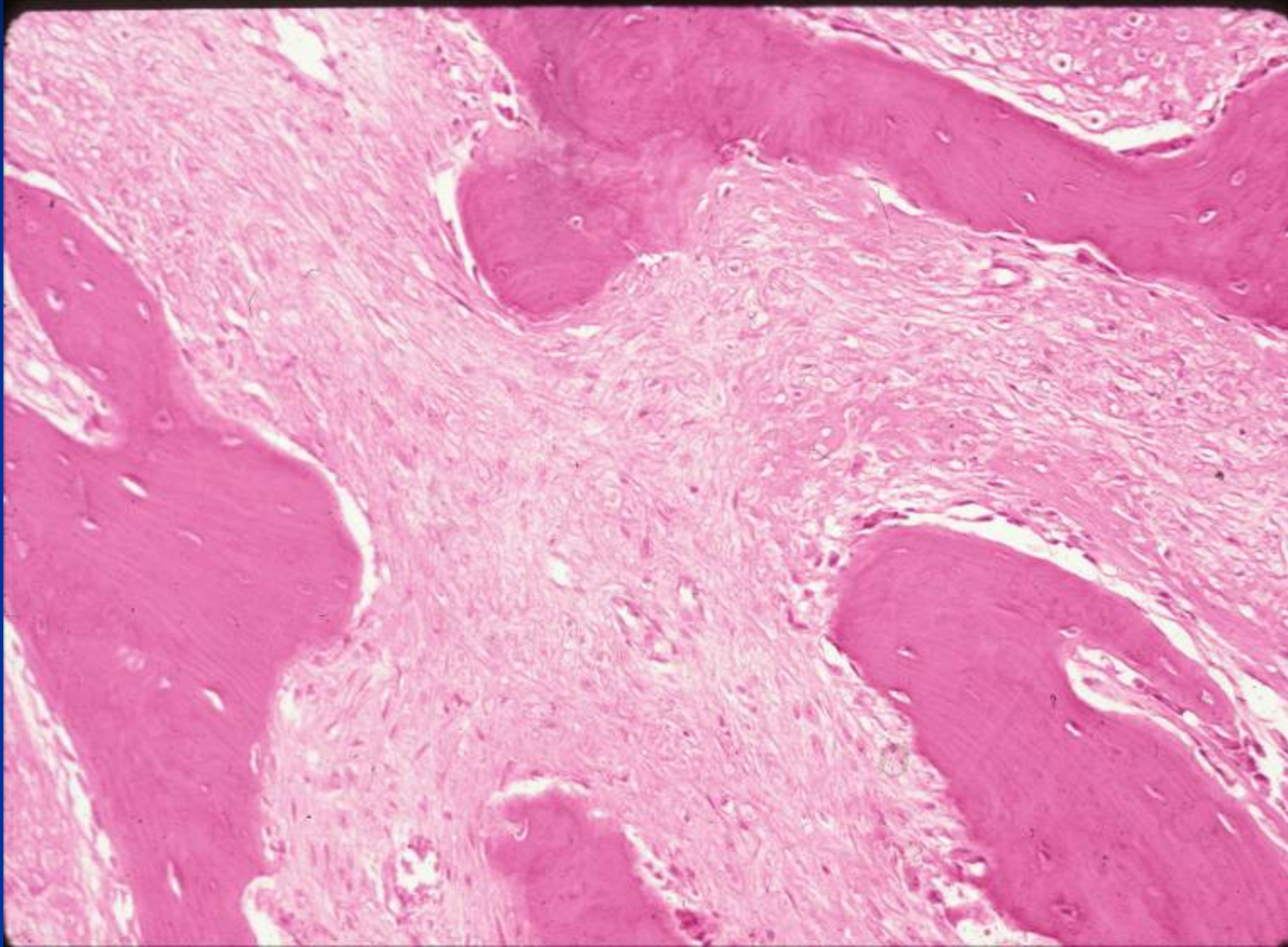


Pathology

- Microscopic pathology demonstrates a fibroblastic tumor that is producing bone and osteoid
- The islands of bone are interspersed amongst fibrous appearing tissue
- There is minimal nuclear atypia and a minimal number of mitotic figures
- The tumor is typically a low grade tumor

Bone Production





Parosteal Osteosarcoma

- Radiographic Differential Diagnosis:
 - Myositis ossificans
 - Periosteal osteosarcoma
 - Periosteal chondrosarcoma
 - High-grade surface osteosarcoma
 - Conventional osteosarcoma
 - Osteochondroma

Parosteal Osteosarcoma

- Pathologic Differential Diagnosis:
 - Osteochondroma
 - Myositis ossificans
 - High grade surface osteosarcoma
 - Periosteal osteosarcoma

Parosteal Osteosarcoma

- Typically a parosteal osteosarcoma is a low grade type of tumor with little risk of metastasizing or spreading
- Most patients are cured with surgery alone. Chemotherapy is usually not used for treatment.
- Occasionally, parosteal osteosarcomas that are present for prolonged periods of time before being identified, can dedifferentiate and develop high grade areas. These higher grade variants have a higher likelihood of spreading and may be treated with chemotherapy in addition to surgery.

Parosteal Osteosarcoma

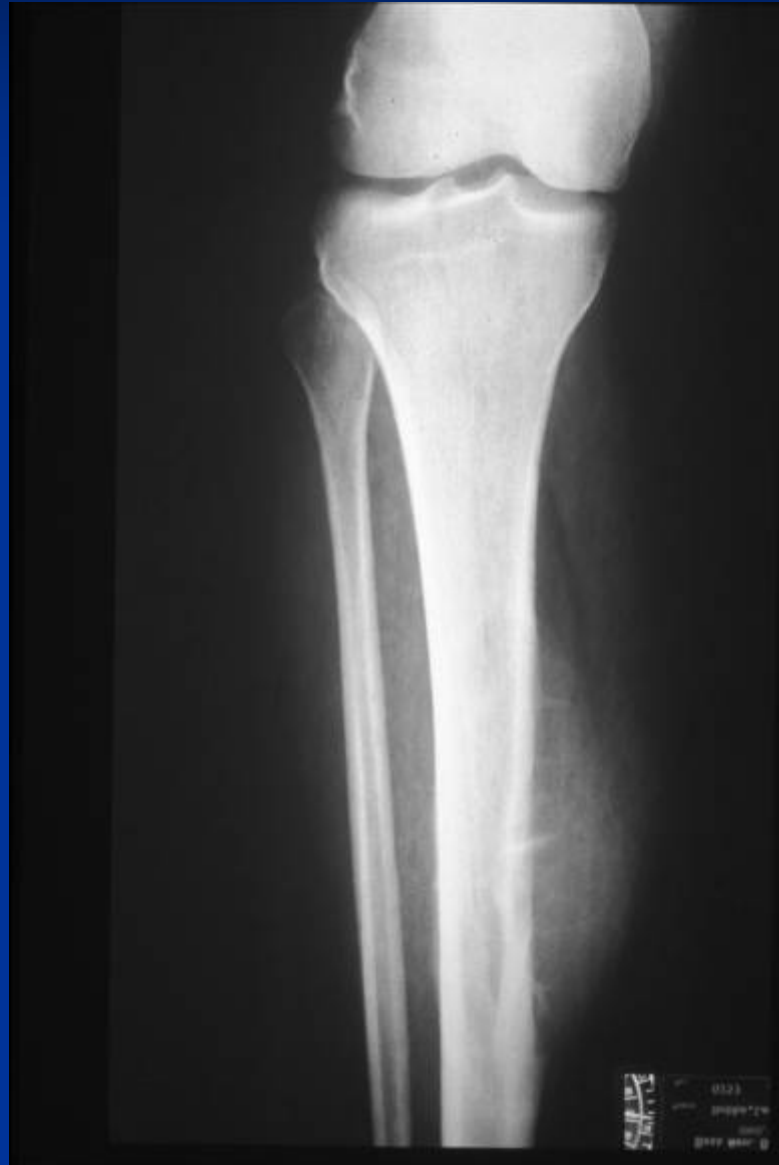■ Treatment:

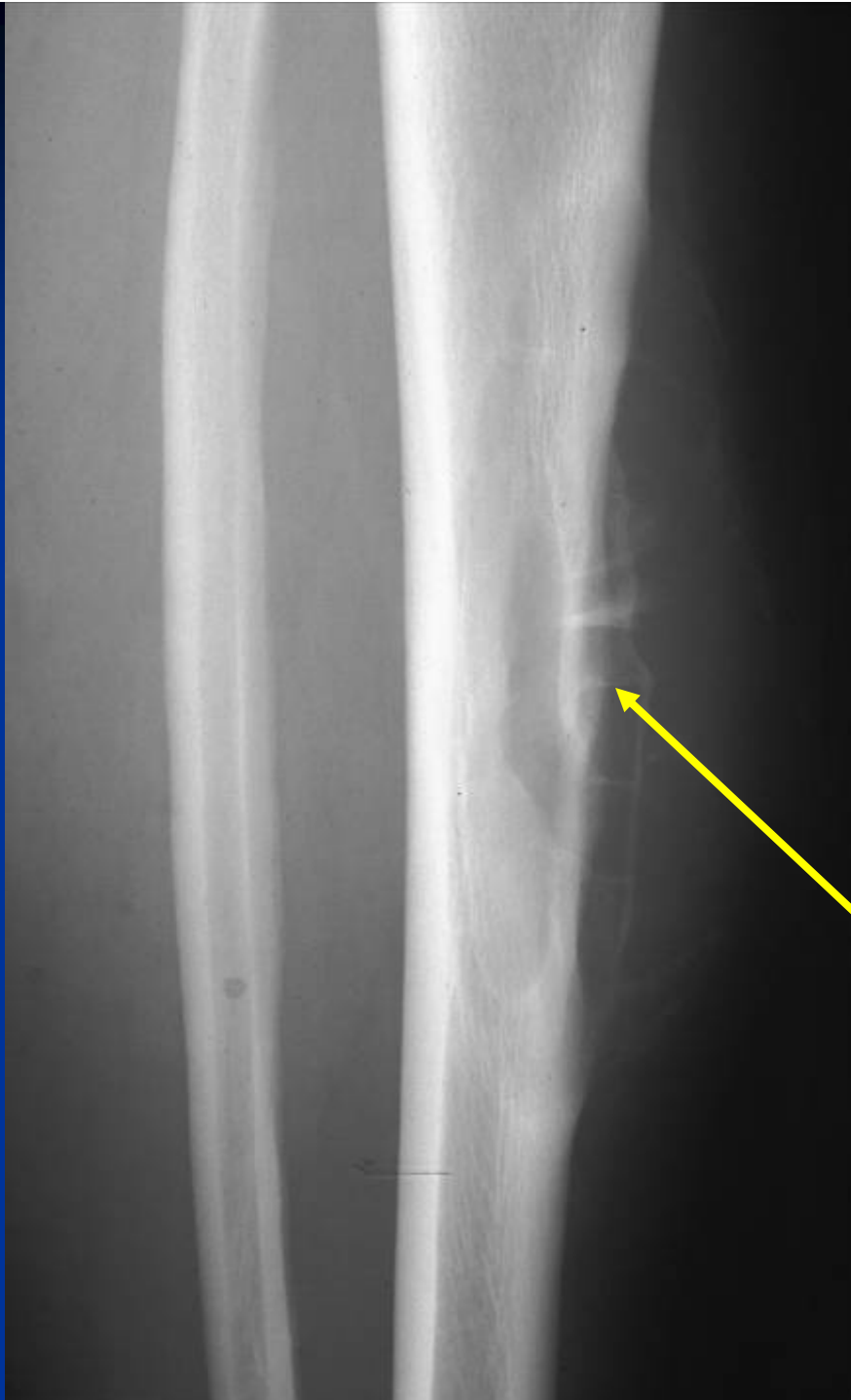- Wide surgical resection and reconstruction
- Chemotherapy only if grade 3 components or dedifferentiated components identified on biopsy or after resection (Same regimen as conventional)
- Radiation: Not used in treatment of this tumor

■ Prognosis:

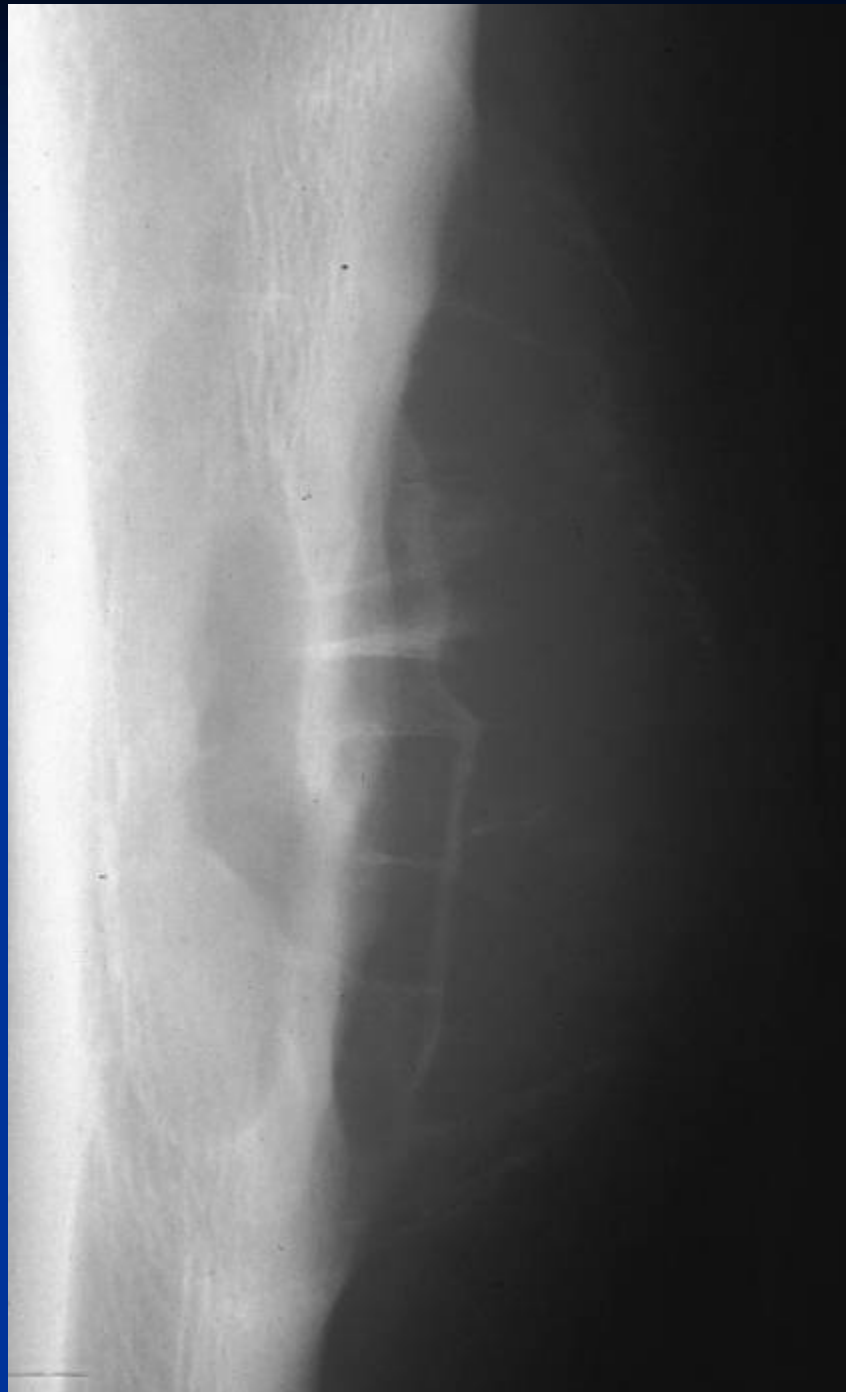- 80-90% cure rate
- Mets more common with medullary invasion and high grade components
- Medullary invasion more common with high grade components

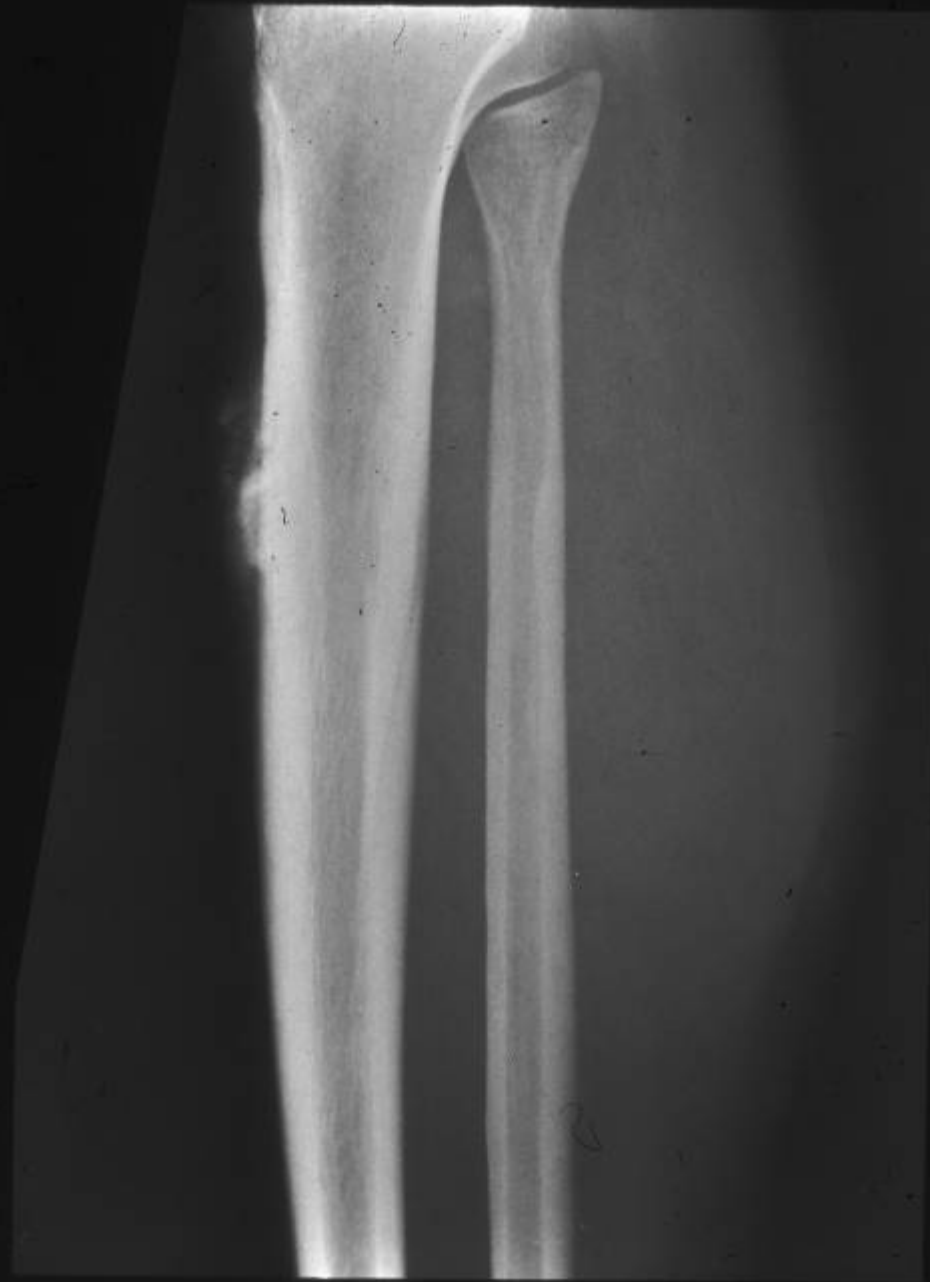Periosteal Osteosarcoma of Tibia

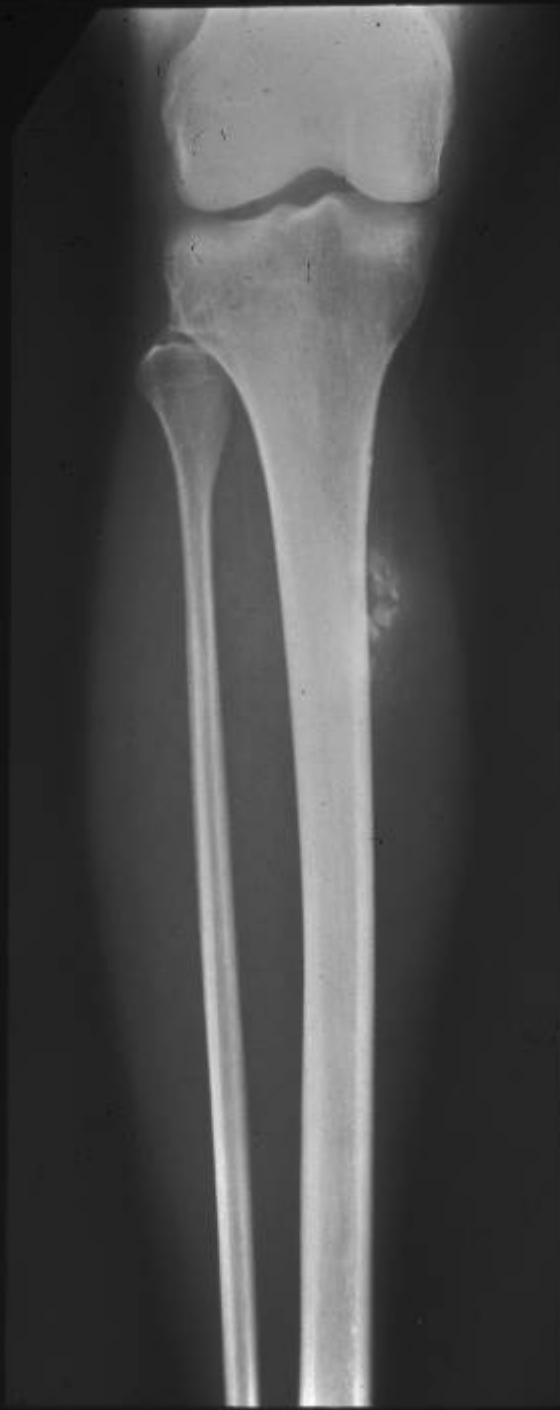



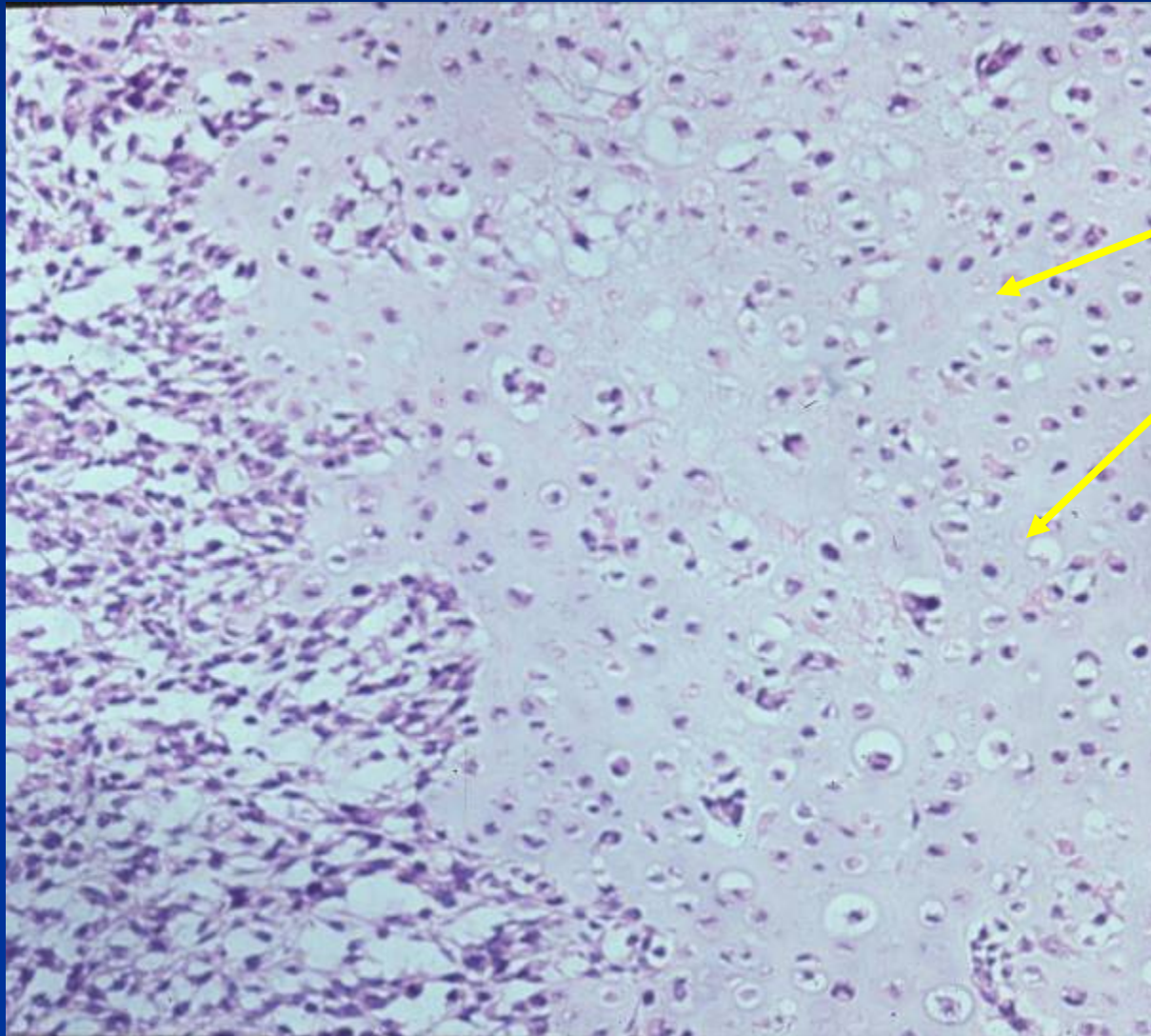
**Hair on End
Periosteal Reaction**



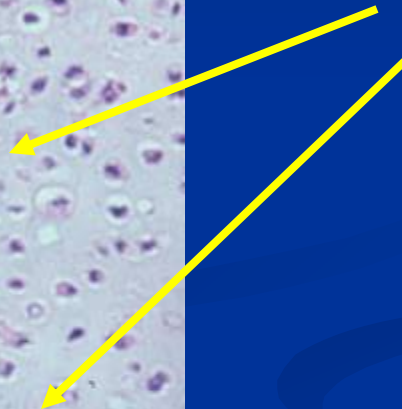


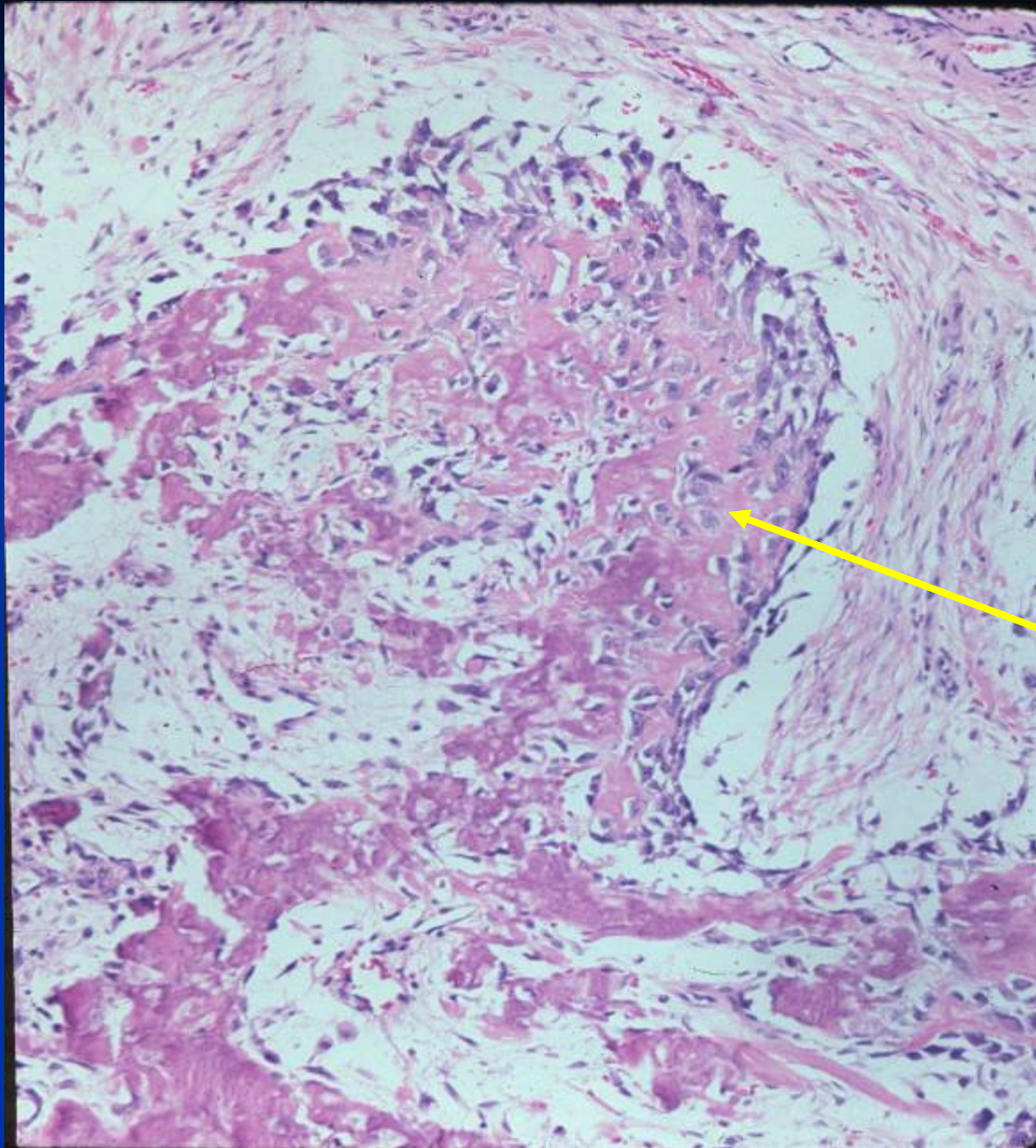


Pathology: Primarily a Chondroblastic (Cartilaginous) Tumor with Bone (Osteoid) Production



Malignant
Appearing
Cartilage





**Osteoid
Production
Identified in
Various Areas
of Tumor**

Periosteal Osteosarcoma

- Radiographic Differential Diagnosis:
 - Parosteal osteosarcoma
 - High grade surface osteosarcoma
 - Periosteal chondrosarcoma
 - Myositis ossificans

Periosteal Osteosarcoma

- Pathologic Differential Diagnosis:
 - Periosteal chondroma
 - Periosteal chondrosarcoma
 - High grade surface osteosarcoma
 - Conventional osteosarcoma with chondroblastic component

Periosteal Osteosarcoma

■ Treatment:

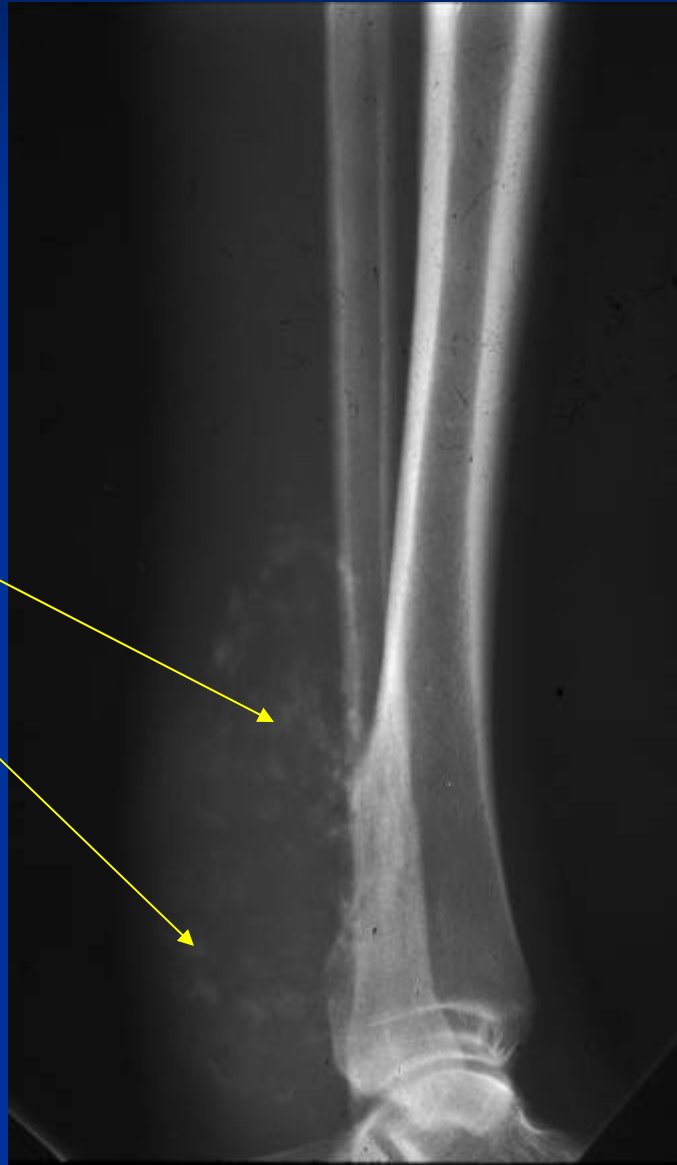
- En bloc resection and reconstruction

■ Prognosis:

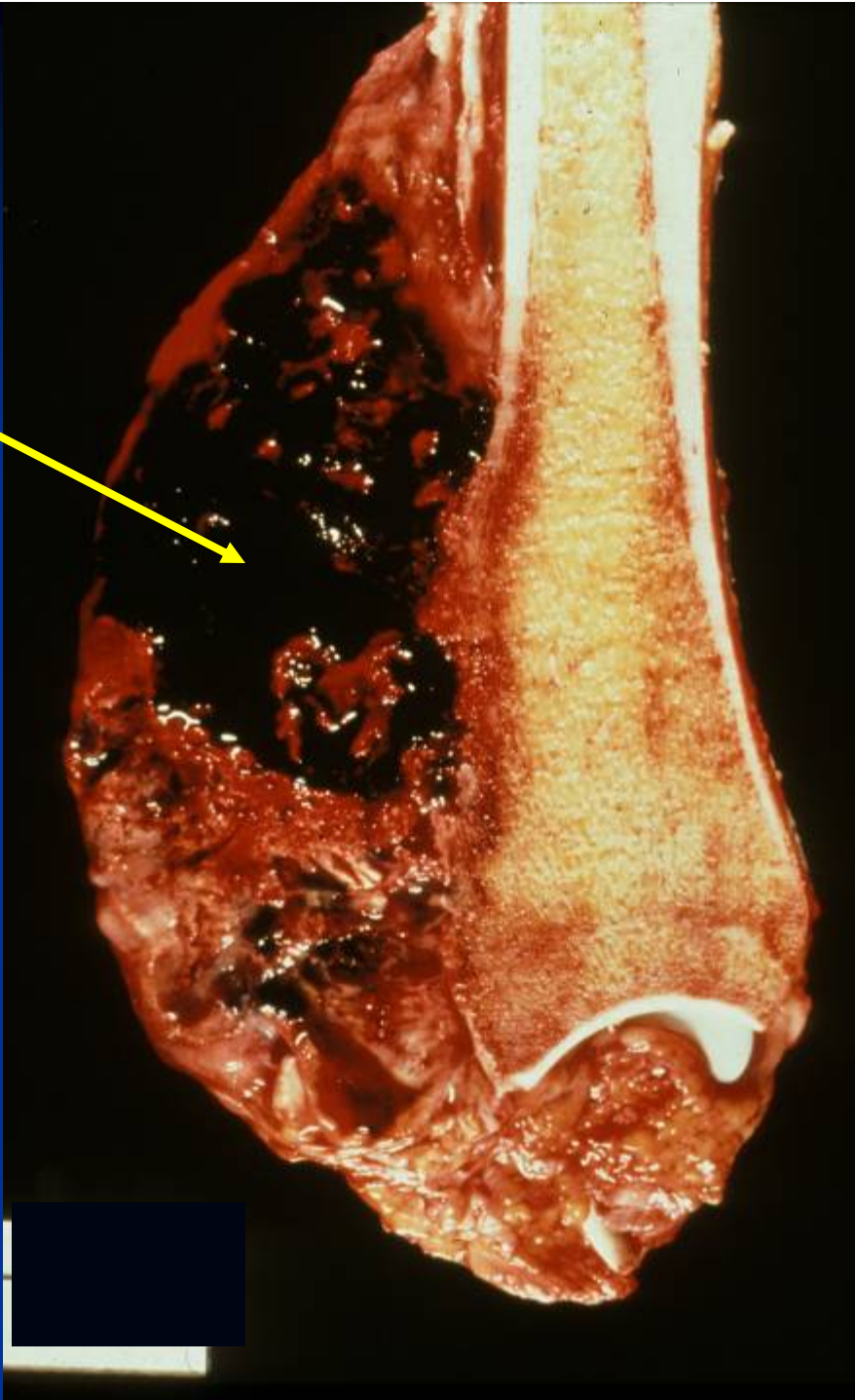
- 15-25% metastatic rate to lungs
- Role of chemotherapy is questionable

High Grade Surface Osteosarcoma of Distal Tibia

Ossification
in Tumor



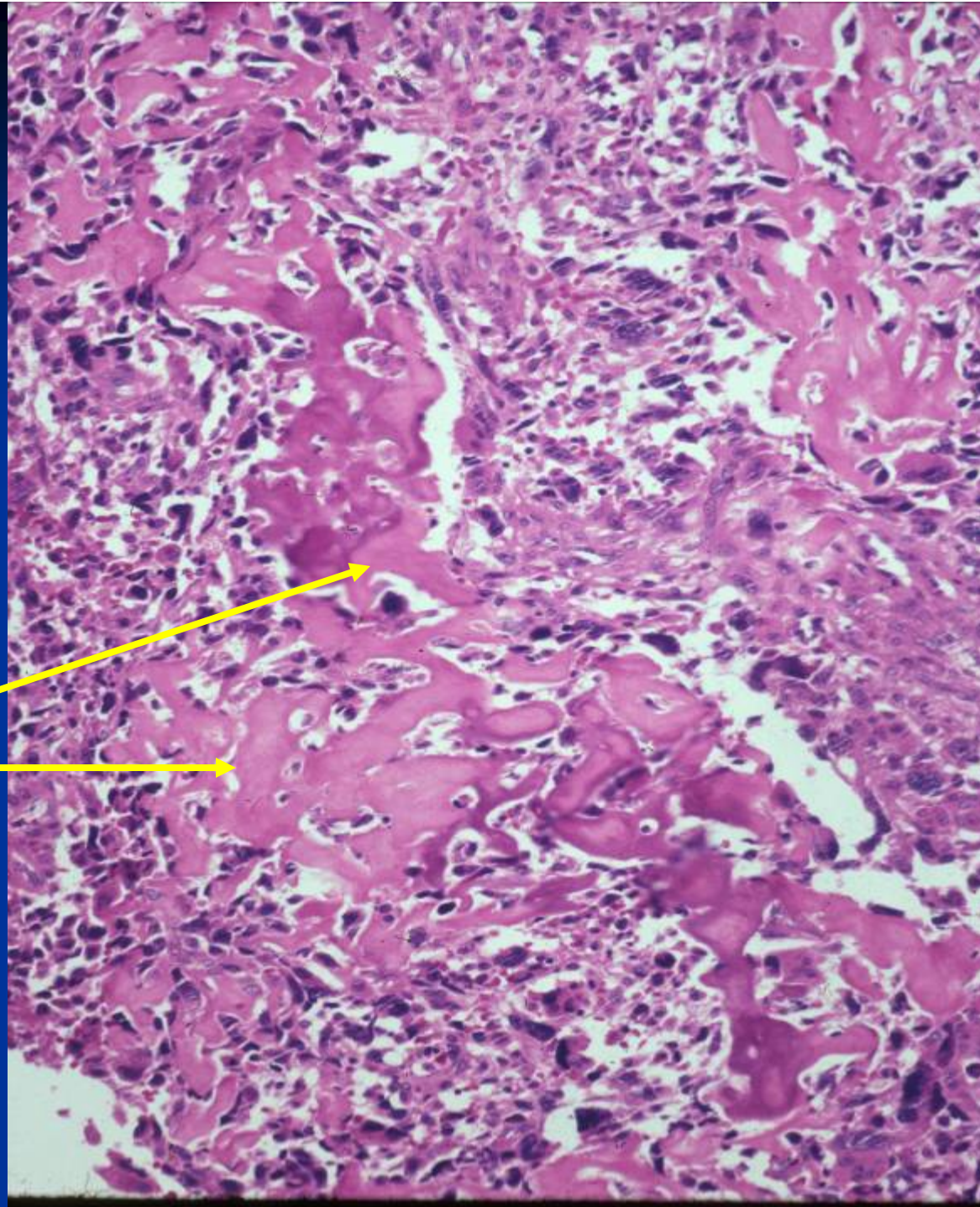
Necrotic Cystic Cavity



Pathology

- Microscopically, a high grade surface osteosarcoma looks the same as a conventional intramedullary osteosarcoma

Osteoid
Production



High Grade Surface Osteosarcoma

- Radiographic Differential Diagnosis:
 - Periosteal osteosarcoma
 - Parosteal osteosarcoma
 - Periosteal chondrosarcoma

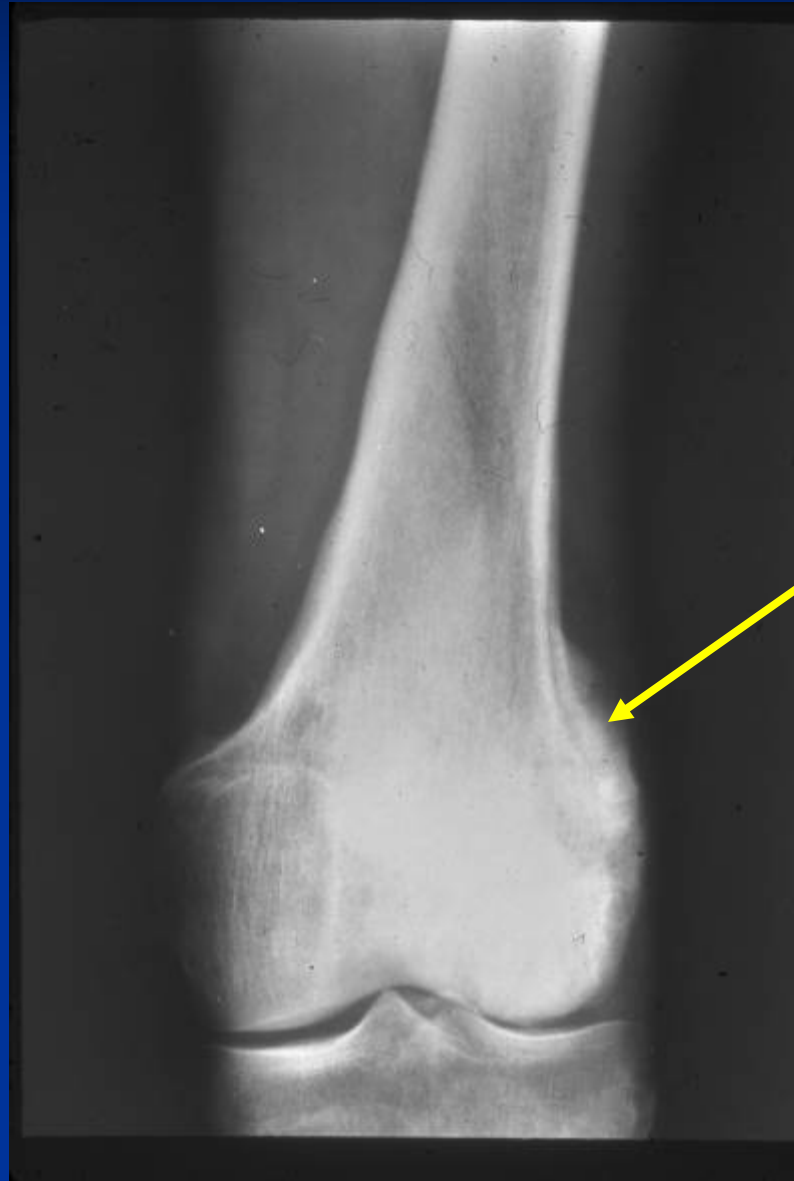High Grade Surface Osteosarcoma

- Pathologic Differential Diagnosis:
 - Myositis ossificans
 - Periosteal osteosarcoma
 - Conventional osteosarcoma with prominent soft tissue extension
 - Parosteal osteosarcoma

High Grade Surface Osteosarcoma

- Treatment and Prognosis:
 - Same as conventional osteosarcoma

Low Grade Intramedullary Osteosarcoma of Distal Femur

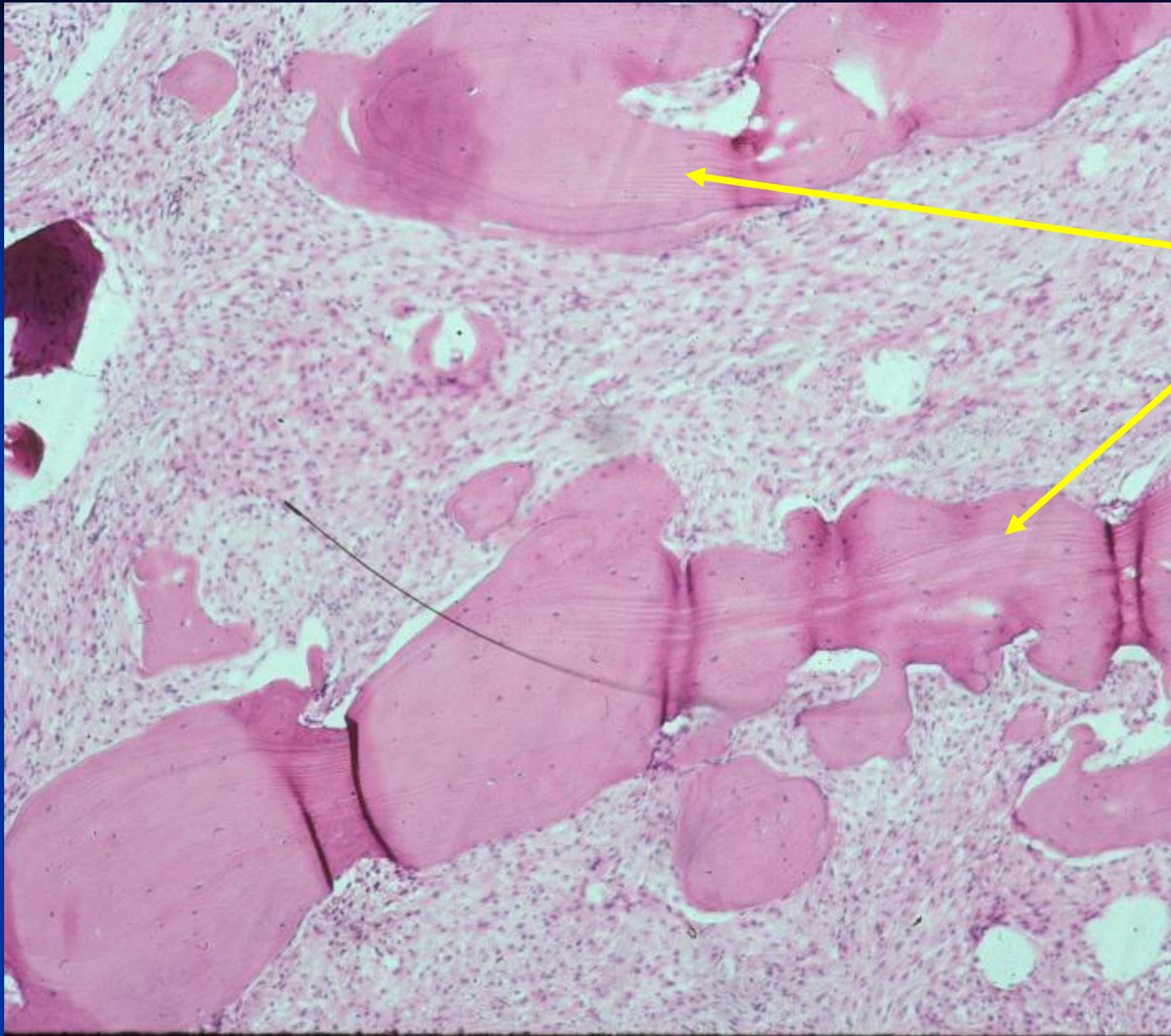


Ossification

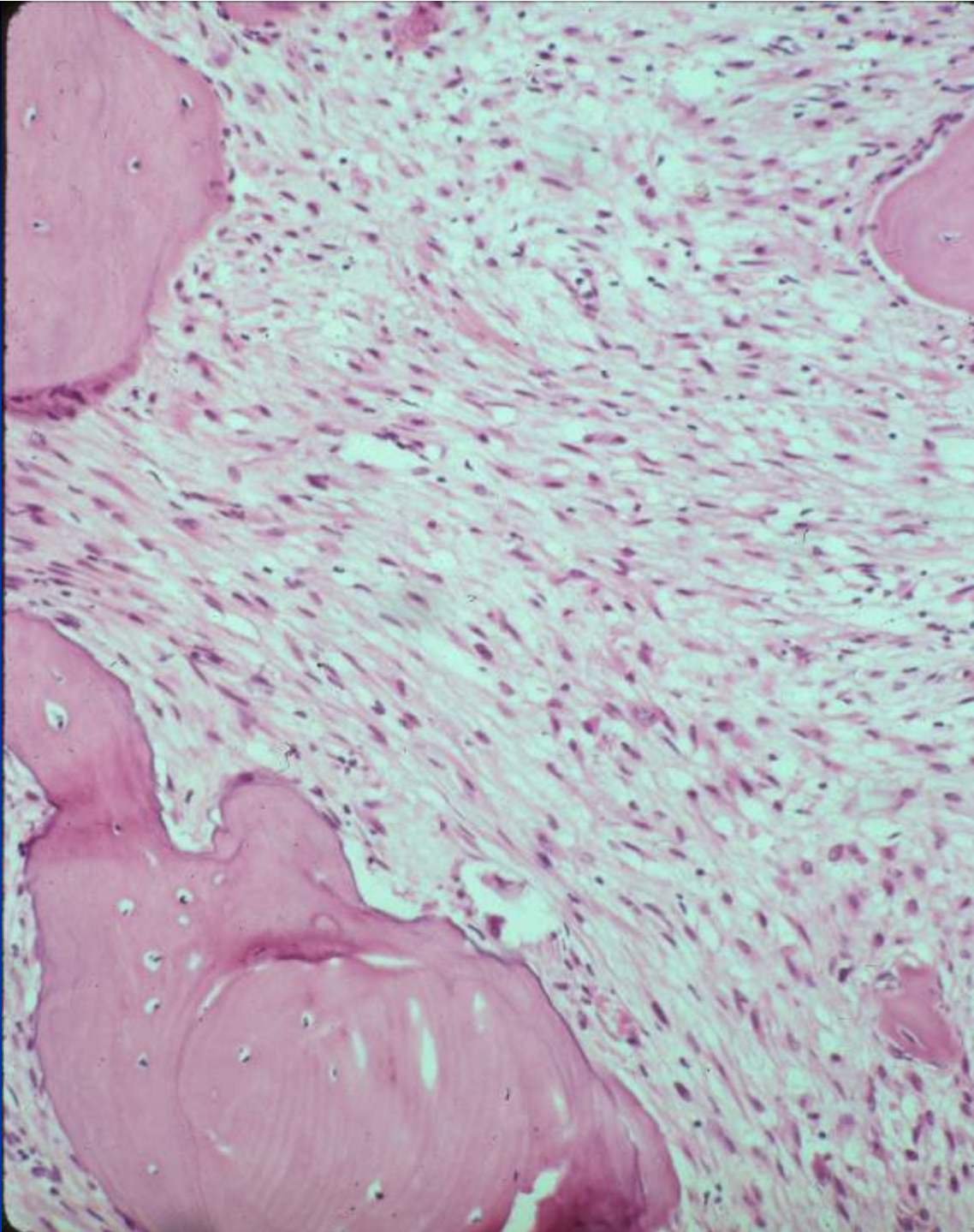
Breaking through
Cortex

Pathology

- Microscopically, low grade intramedullary osteosarcoma looks similar to a parosteal osteosarcoma
- Fibroblastic tumor producing bone (osteoid/immature bone)
- Minimal nuclear atypia, mildly hypercellular, minimal mitotic figures



Osteoid
Production



Low Grade Intramedullary

- Radiographic Differential Diagnosis:
 - Fibrous dysplasia
 - Giant cell tumor
 - Ordinary osteosarcoma
 - Fibrosarcoma
 - Malignant fibrous histiocyoma

Low Grade Intramedullary

- Pathologic Differential Diagnosis:
 - Fibrous dysplasia
 - Osteofibrous dysplasia
 - Conventional osteosarcoma
 - Parosteal osteosarcoma

Low Grade Intramedullary

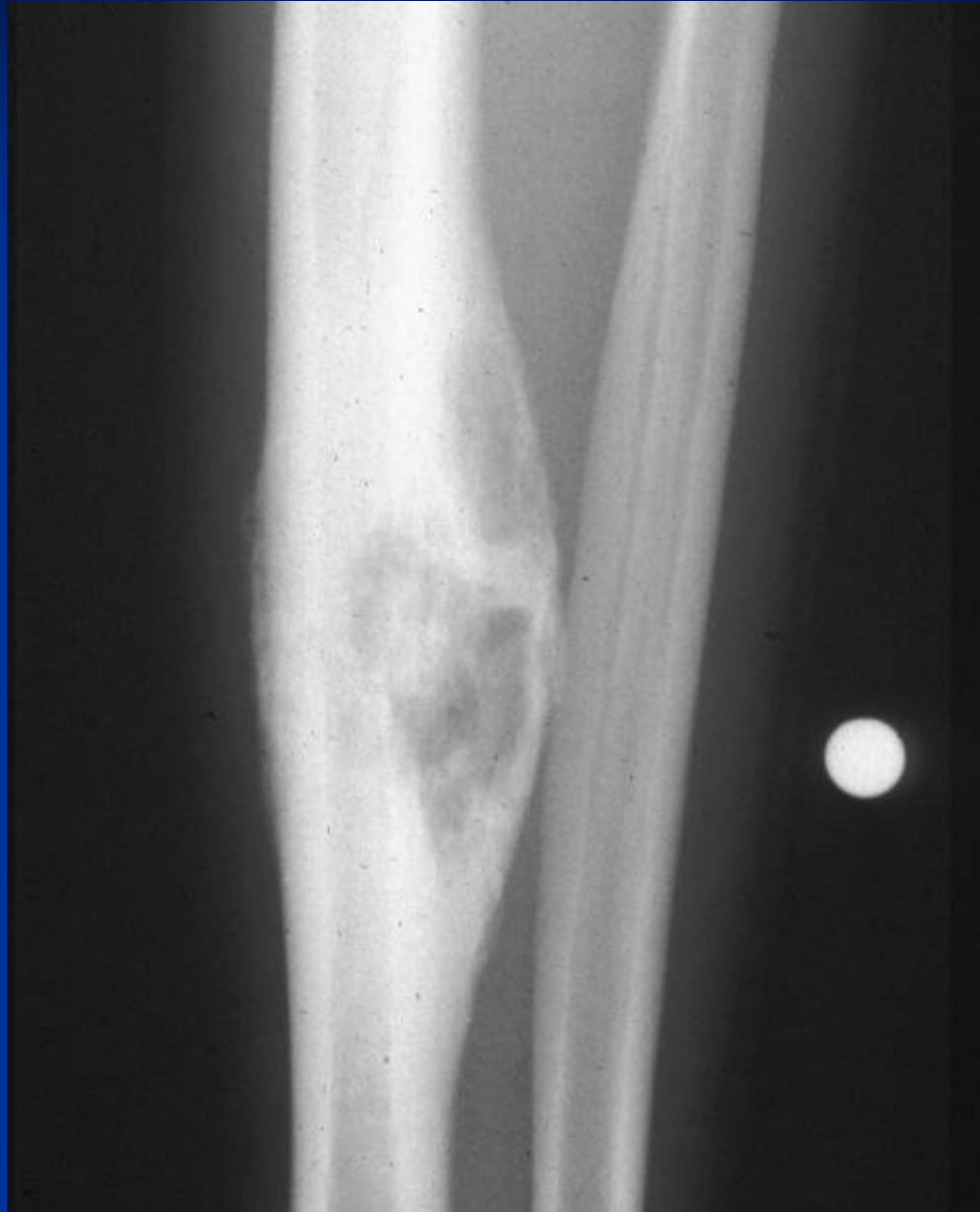■ Treatment:

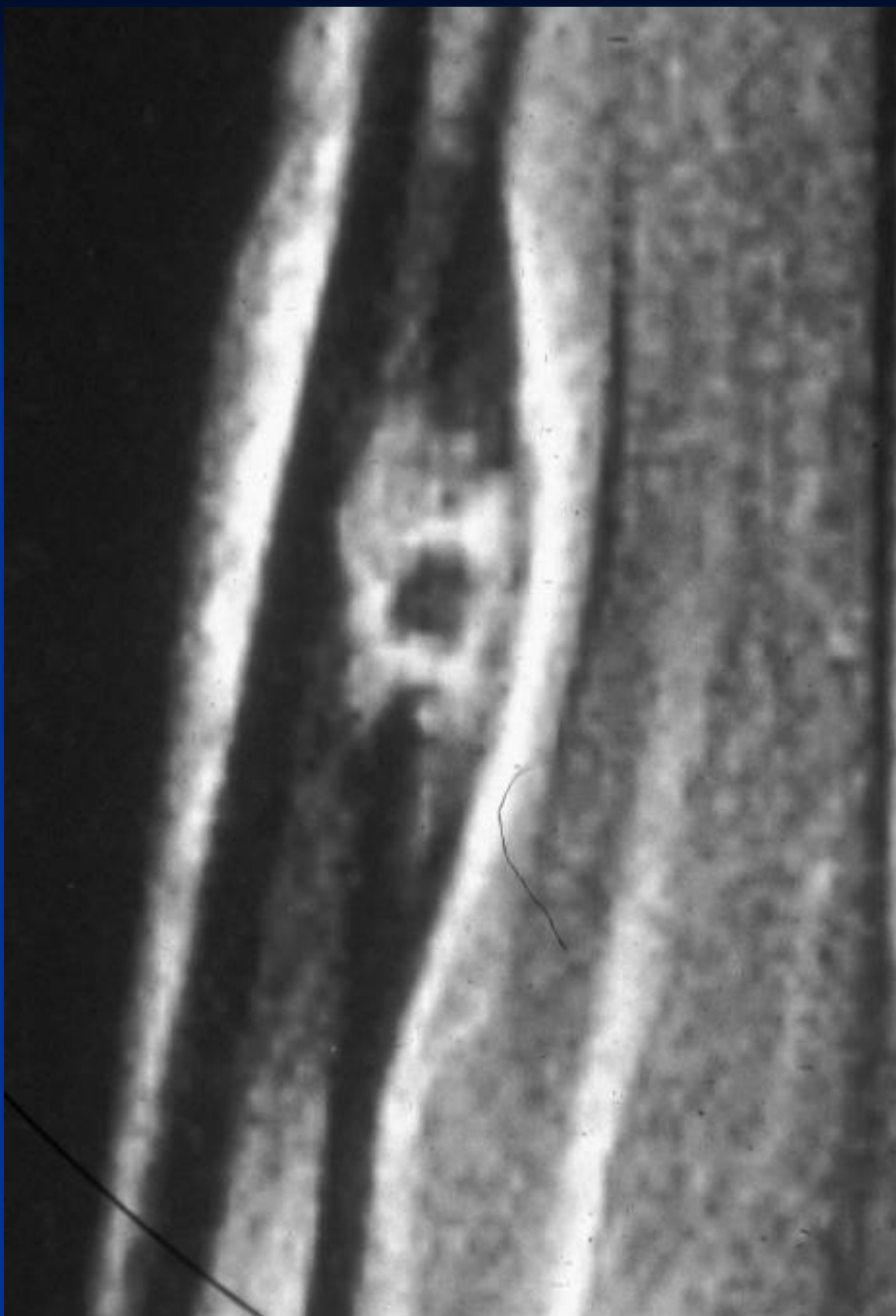
- Surgical resection and reconstruction
- No chemotherapy unless dedifferentiation is present

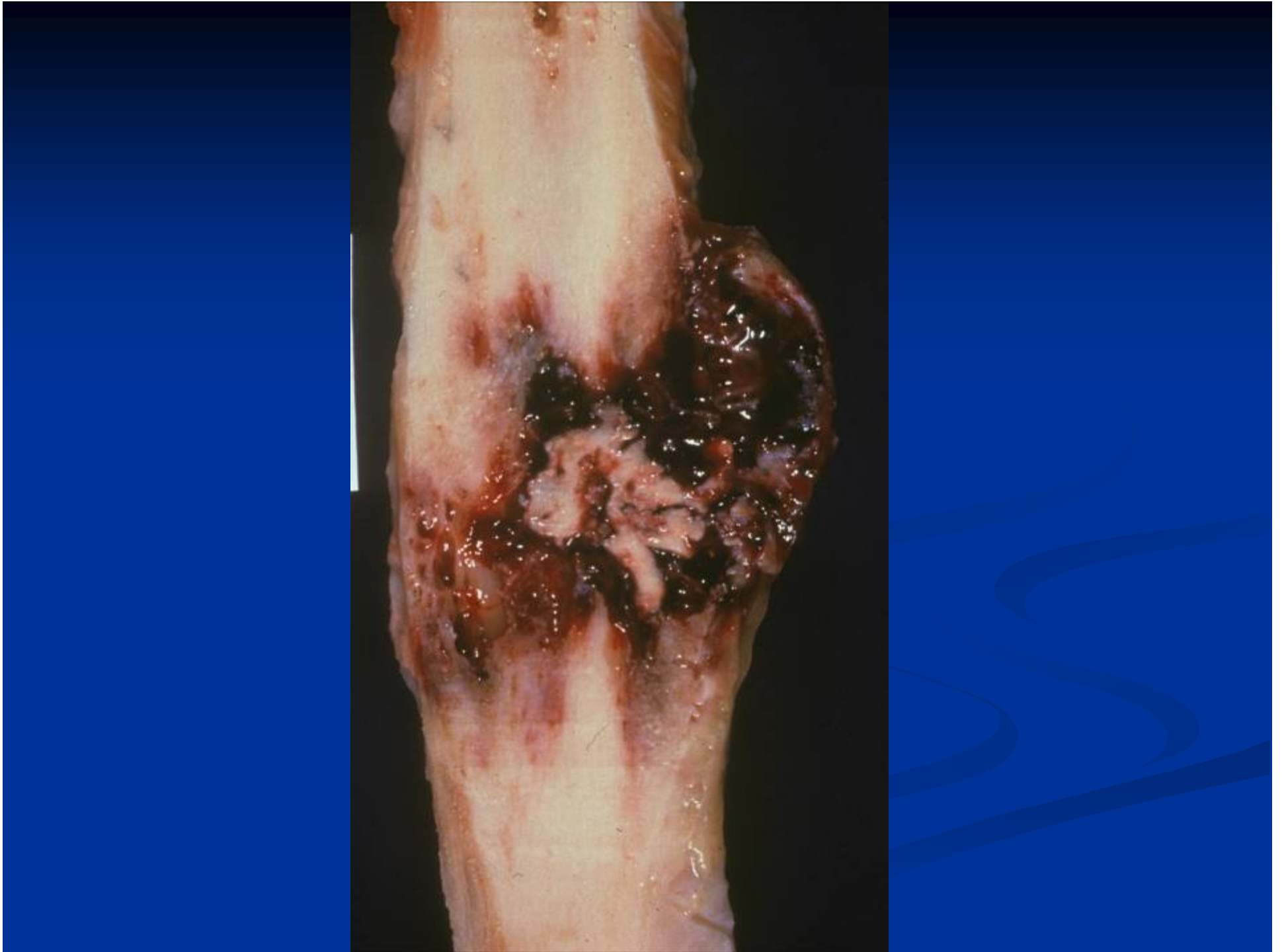■ Prognosis:

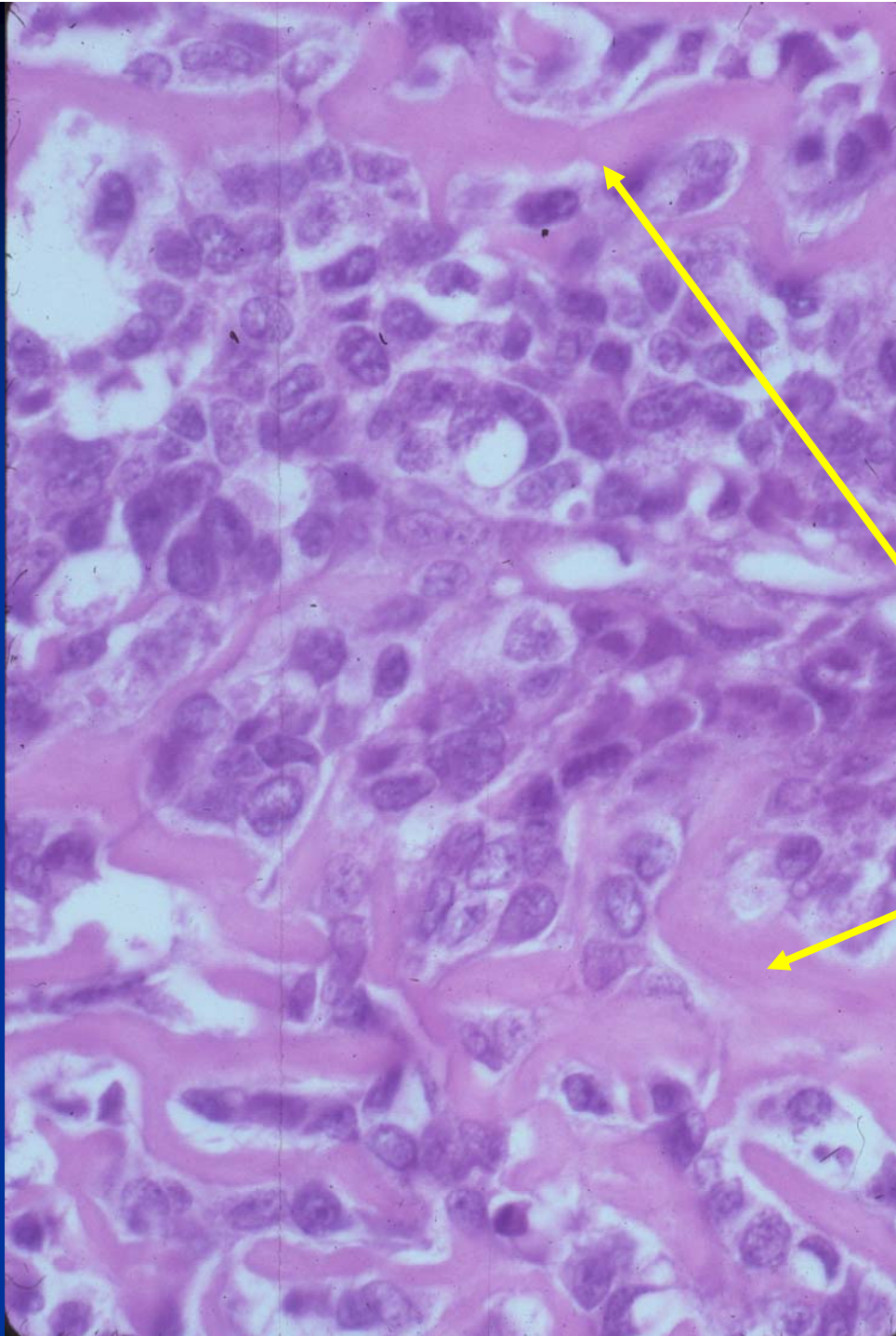
- 90% cure rate (<10% metastatic rate)

Intracortical Osteosarcoma









Osteoid
Production

Intracortical Osteosarcoma

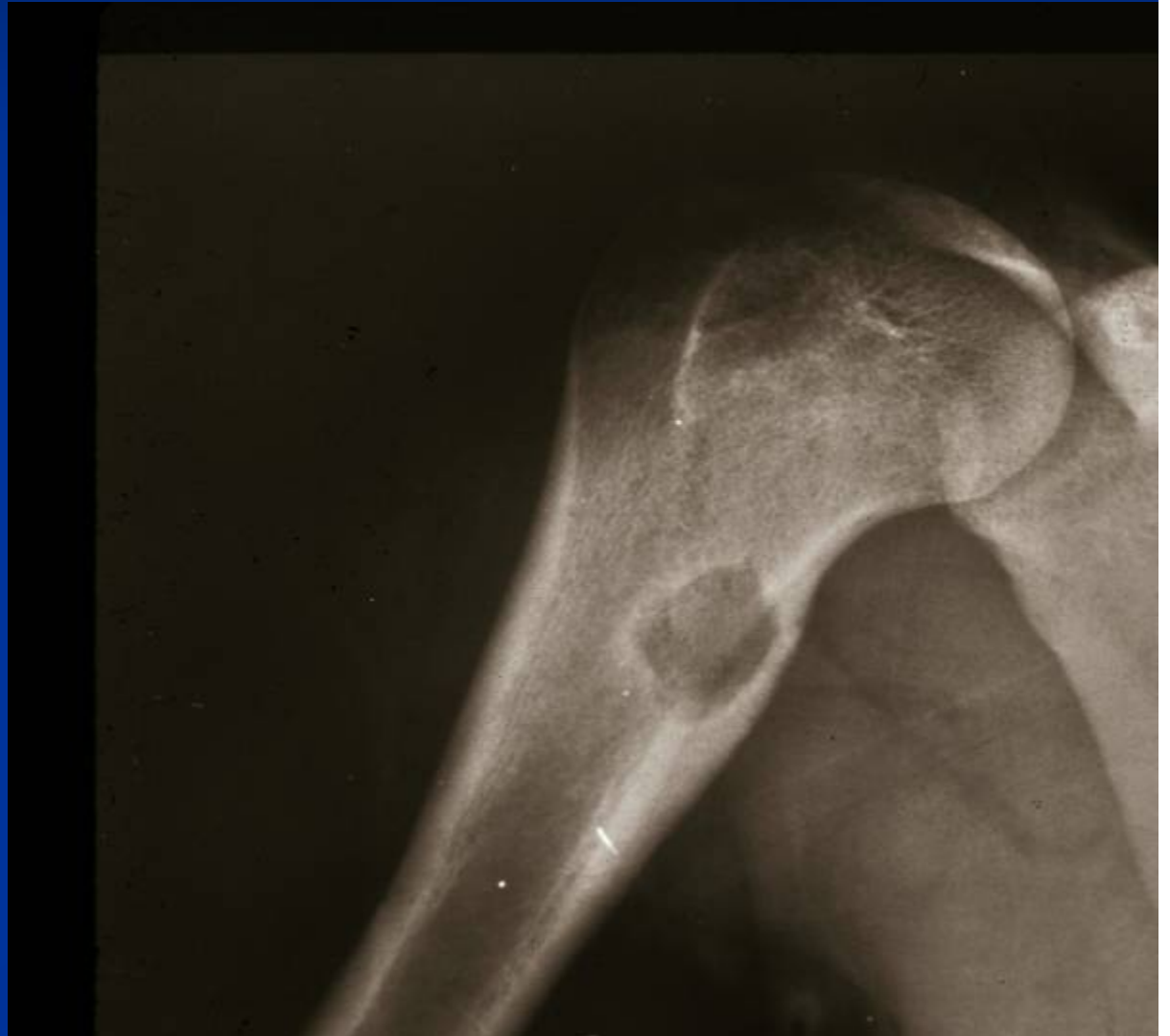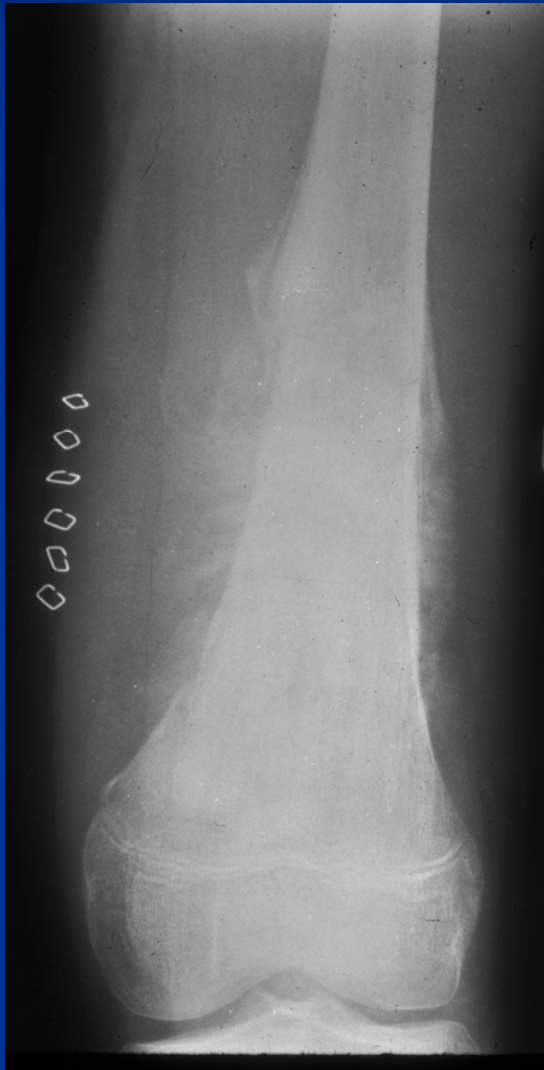■ Differential Diagnosis:

- Stress fracture
- Osteoid osteoma
- Osteoblastoma
- Intracortical abscess
- Fibrous dysplasia
- Nonossifying fibroma
- Adamantinoma

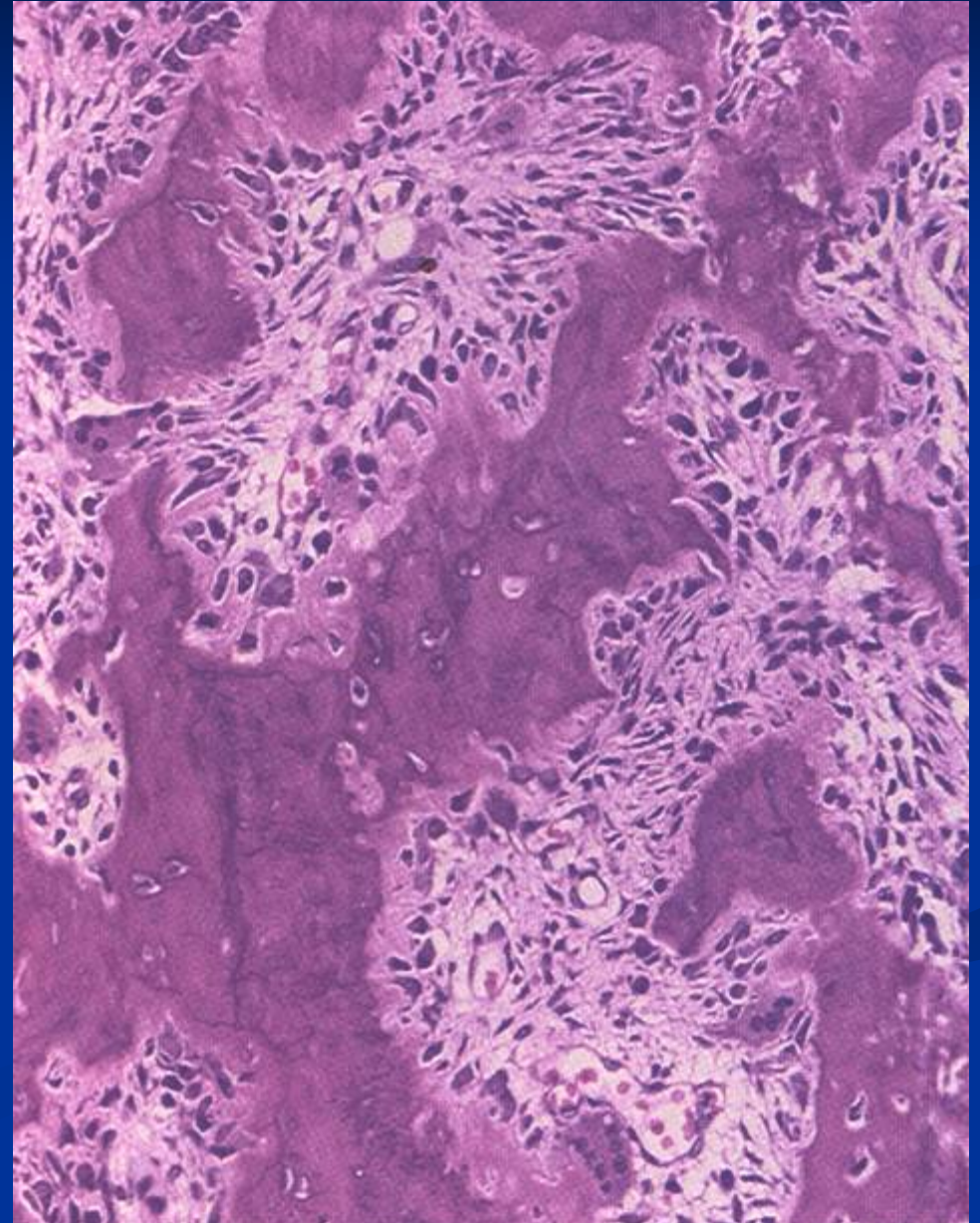
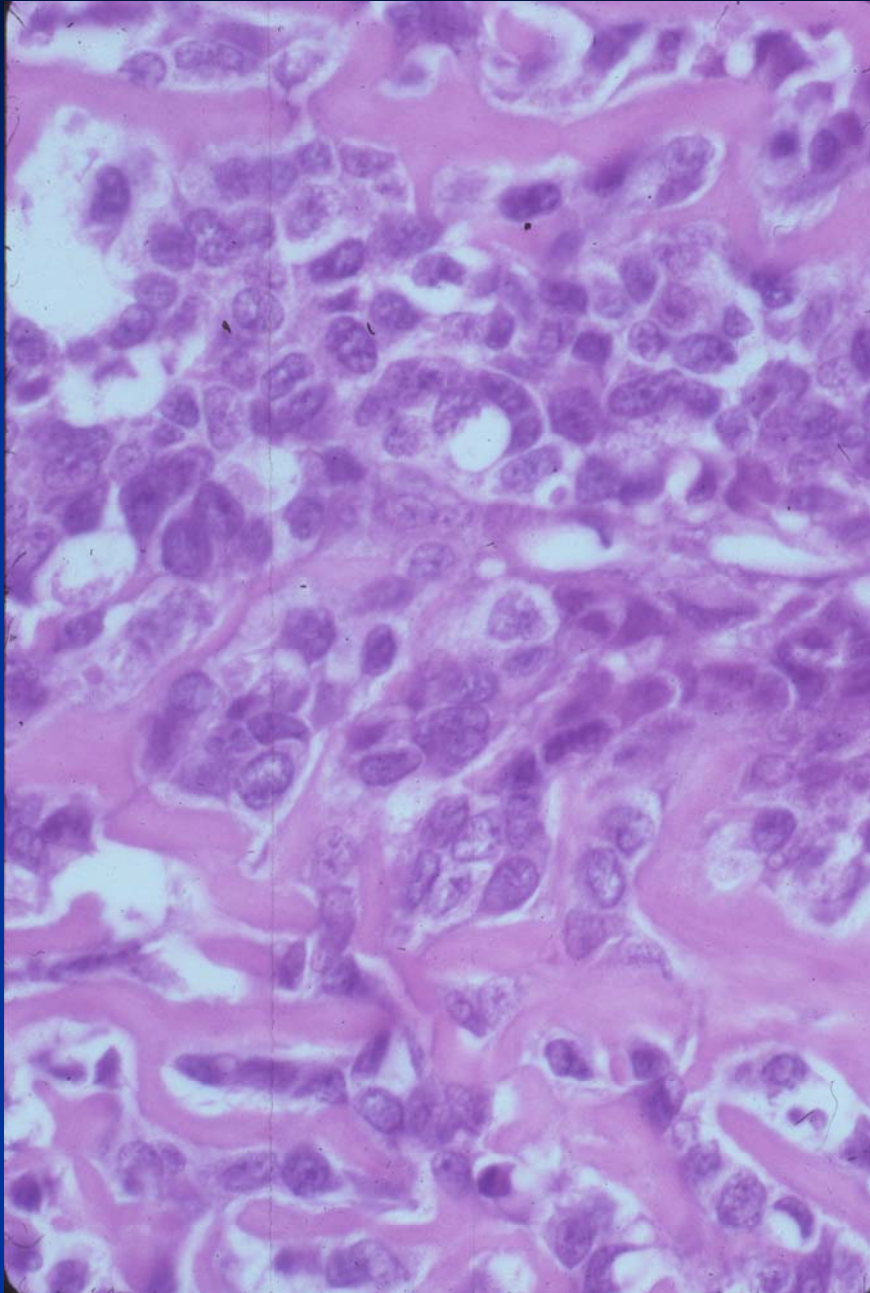
Intracortical Osteosarcoma

- Treatment:
 - En bloc resection
 - Chemotherapy

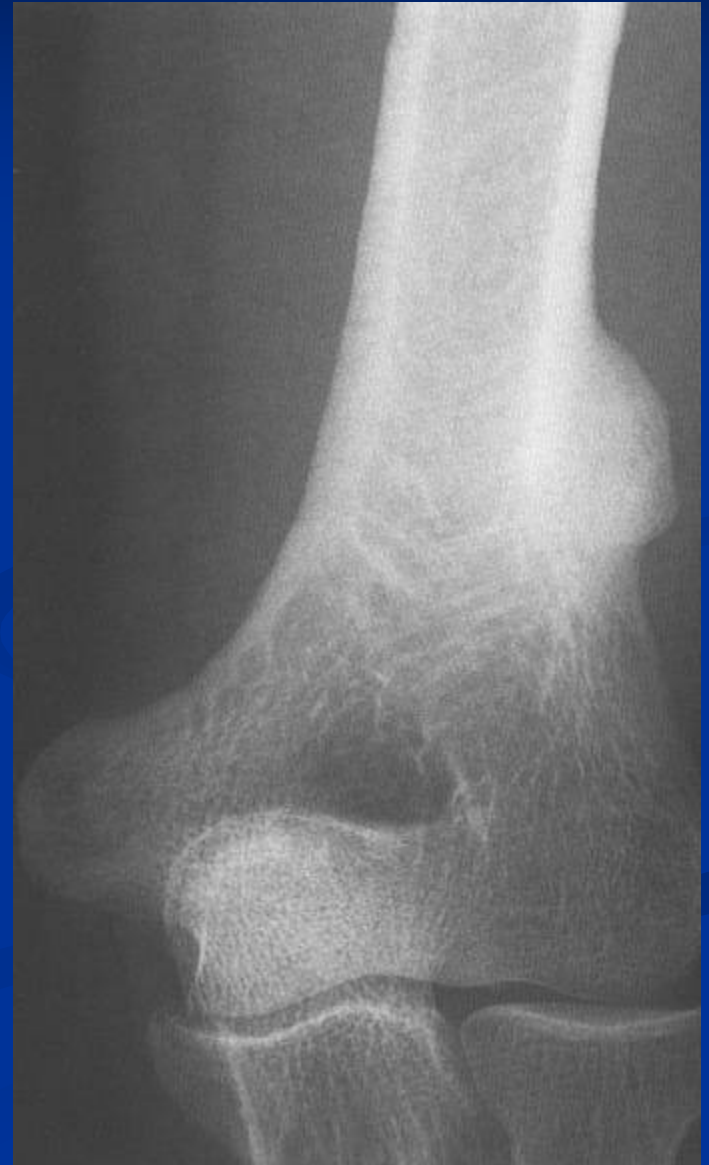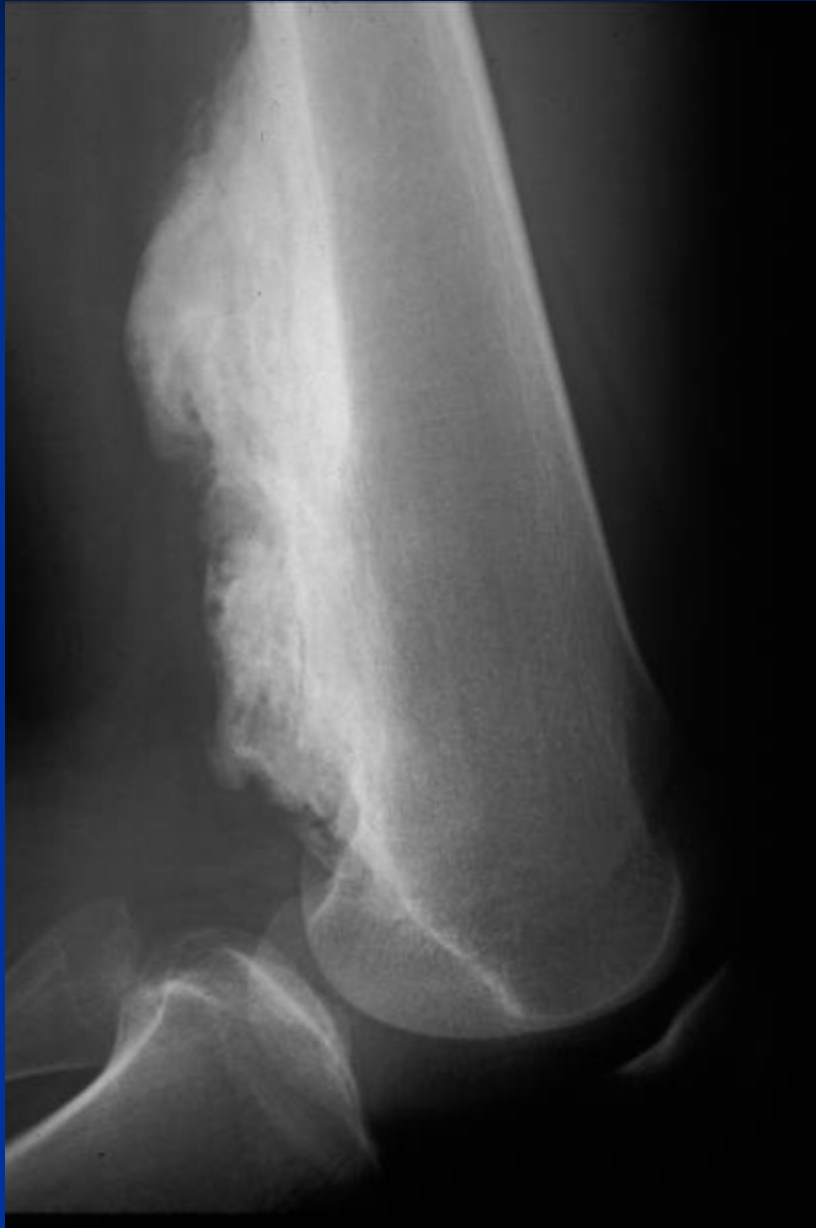Osteosarcoma vs Osteoblastoma



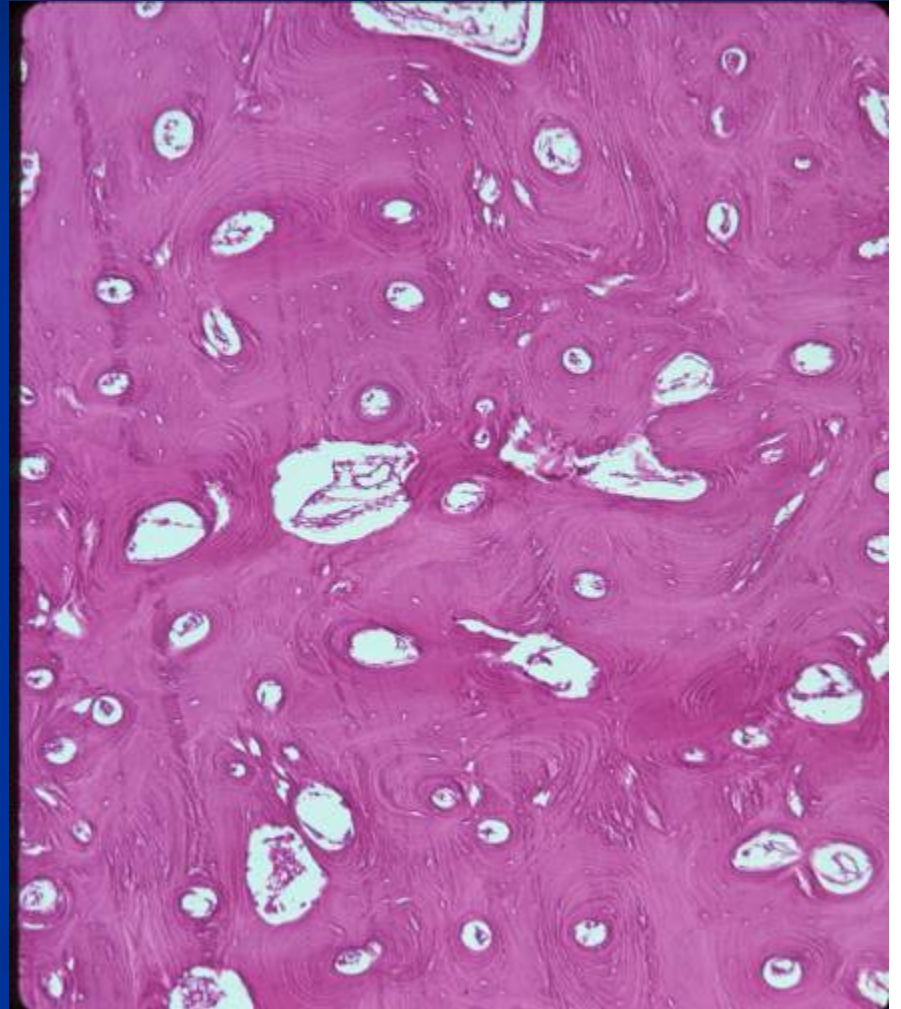
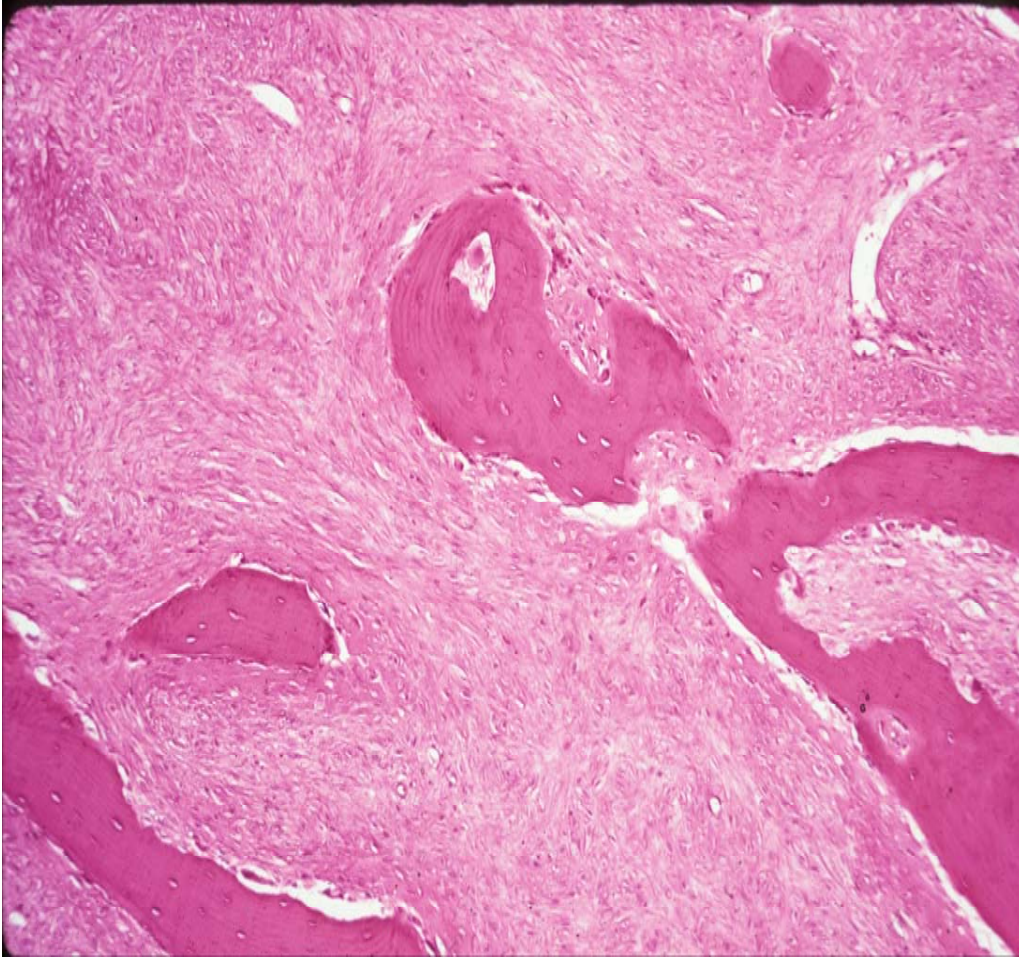Osteosarcoma vs Osteoblastoma



Parosteal Osteosarcoma vs Osteoma



Parosteal Osteosarcoma vs Osteoma



Surface Lesions of Bone: Differential Diagnosis of Parosteal Osteosarcoma

Parosteal osteoma

Parosteal osteosarcoma

Sessile osteochondroma

Juxtacortical myositis
ossificans

Periosteal osteoblastoma

Ossified parosteal (periosteal)
lipoma

Melorheostosis (monostotic)