

Endoscopy_UCTN_Code_CCL_1AG_2AD

Fitz-Hugh–Curtis syndrome in a man

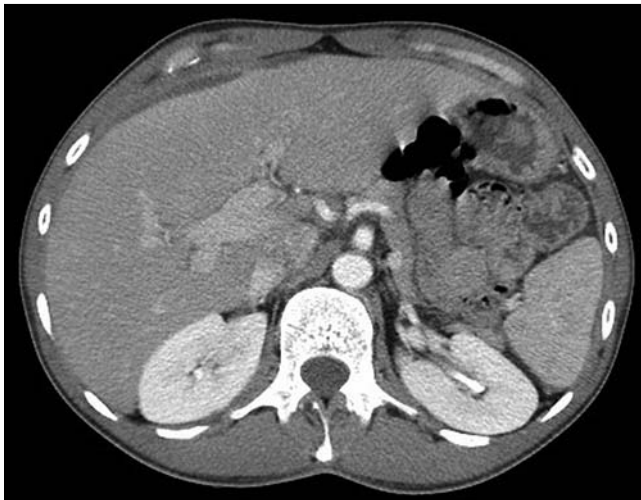


Fig. 1 CT scan: fluid in the perihepatic space in a 45-year-old man with Fitz-Hugh–Curtis syndrome.

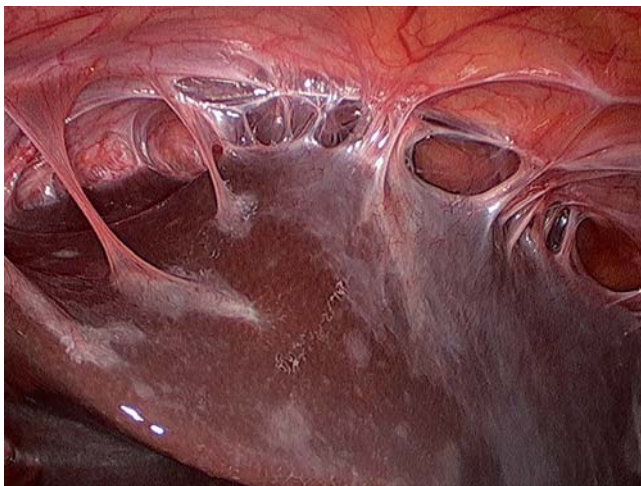

Fig. 2 Celioscopy: “violin string” adhesions, a finding specific for Fitz-Hugh–Curtis syndrome.

A 45-year-old man was admitted for pain in the upper right abdominal quadrant that had been evolving for months. His previous medical history was unremarkable. The physical examination showed a painful and tense abdomen in the right hypochondrium but the rest was pain free. Biological analysis showed an inflammatory syndrome (C-reactive protein 29.54 mg/L). Liver enzymology and urine and blood culture were negative. Abdominal ultrasonography and CT scan (● Fig. 1) showed the presence of fluid in the perihepatic space, the right paracolic gutter, and the Douglas cul-de-sac. Celioscopy (● Fig. 2) showed an inflamed liver parietal peritoneum with “violin string” adhesions, which are specific for Fitz-Hugh–Curtis syndrome [1,2]. A quinolone- and metronidazole-based treatment was administered. The pain resolved partially after the adhesiolysis,

as often described [3,4]. Bacteriological analysis of perihepatic membrane biopsies, ascites, and urine samples remained negative. The intradermal reaction was negative. The culture on the Löwenstein medium remained negative. Peritoneal carcinomatosis was excluded by histological analysis. Sporadic cases of Fitz-Hugh–Curtis syndrome have been reported associated with pyelonephritis, complicated by appendicitis, or mimicking cholecystitis, but these diagnoses were excluded in our case [5–7]. Fitz-Hugh–Curtis syndrome is exceptional in men: typically, it affects sexually active women [2,8]. In general, it is associated with pelvic inflammatory disease. The causative pathogens are *Neisseria gonorrhoeae* or *Chlamydia trachomatis*, but the bacteriology remained negative in the rare cases reported in males [2], as in our patient.

Competing interests: None

Stéphanie Rouhard¹, Philippe Maldague¹, Adrien Ramboux²

¹ Department of Gastroenterology, Clinique St Luc, Bouge, Namur, Belgium

² Department of Surgery, Clinique St Luc, Bouge, Namur, Belgium

References

- 1 Wang CL, Guo XJ, Yuan ZD et al. Radiologic diagnosis of Fitz-Hugh-Curtis syndrome. *Chinese Med J* 2009; 122: 741–744
- 2 Saurabh S, Unger E, Pavlides C. Fitz-Hugh-Curtis syndrome in a male patient: a case report and literature review. *Case Rep Surg* 2012, article ID 457272
- 3 Peter NG, Clark LR, Jaeger JR. Fitz-Hugh-Curtis syndrome: a diagnosis to consider in women with right upper quadrant pain. *Cleveland Clin J Med* 2004; 71: 233–239
- 4 Fitz-Hugh T. Acute gonococcal peritonitis of the right upper quadrant in women. *Jama* 1934; 102: 2094–2096
- 5 Kazama I, Nakajima T. A case of Fitz-Hugh-Curtis syndrome complicated by appendicitis conservatively treated with antibiotics. *Clin Med Insights Case Rep* 2013; 6: 35–40
- 6 Di Rocco G, Giannotti D, Collalti M et al. Acute abdominal pain in a 24-year-old woman: Fitz-Hugh-Curtis syndrome associated with pyelonephritis. *Hospital das Clínicas da FMUSP* 2012; 67: 1493–1495
- 7 Piscaglia F, Ugolini G, Ramini R et al. Fitz-Hugh-Curtis syndrome mimicking acute cholecystitis: value of new ultrasound findings in the differential diagnosis. *Ultraschall Med* 2005; 26: 227–230
- 8 Beak HC, Bae YS, Lee KJ et al. A case of Fitz-Hugh-Curtis syndrome in a male [in Korean]. *Korean J Gastroenterol* 2010; 55: 203–207

Bibliography

DOI <http://dx.doi.org/10.1055/s-0033-1358804>
 Endoscopy 2014; 46: E1
 © Georg Thieme Verlag KG
 Stuttgart · New York
 ISSN 0013-726X

Corresponding author

Stéphanie Rouhard, MD
 Department of Gastroenterology
 Clinique St Luc
 Rue St Luc 8
 5004 Bouge
 Namur
 Belgium
 Stephanie_rouhard@hotmail.com