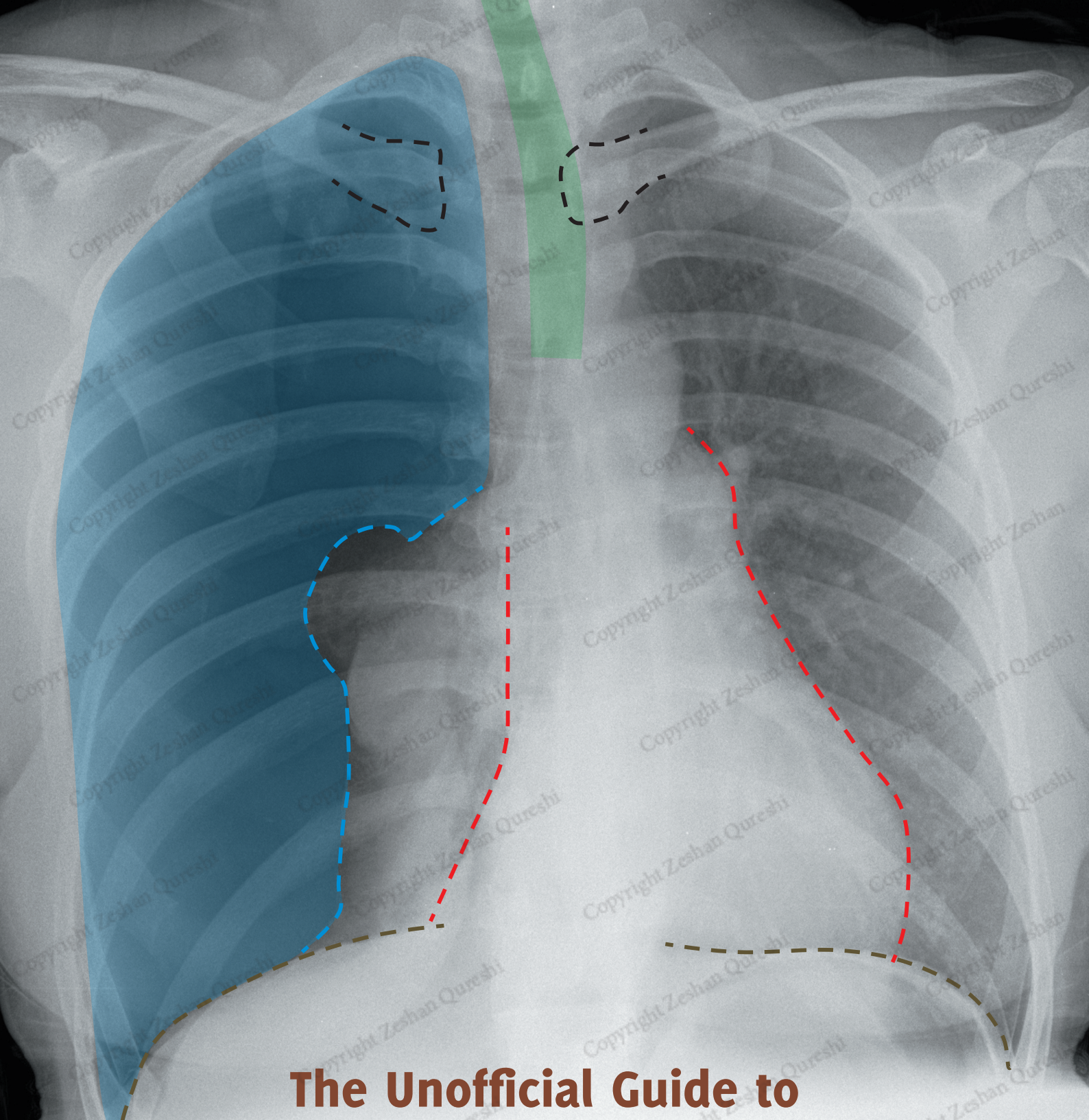

The Unofficial Guide to

Radiology: 100 Practice Chest X-Rays, with Full Colour Annotations and Full X-Ray Reports

MOHAMMED RASHID AKHTAR, NA'EEM AHMED and NIHAD KHAN
Edited by MARK RODRIGUES and ZESHAN QURESHI

Join Our Medical Book Writing Project (details inside)



The Unofficial Guide to Radiology: 100 Practice Chest X-Rays, with Full Colour Annotations and Full X-Ray Reports

FIRST EDITION

MOHAMMED RASHID AKHTAR MBBS BSc (Hons) FRCR

NA'EEM AHMED MBBS BSc

NIHAD KHAN MBBS BSc

Edited by

MARK RODRIGUES MBChB (Hons) BSc (Hons) FRCR

ZESHAN QURESHI BM BSc (Hons) MSc MRCPCH



ZESHAN
Q U R E S H I

ISBN 978-1-910399-01-9

Text, design and illustration © Zeshan Qureshi 2017

Edited by Mark Rodrigues and Zeshan Qureshi
Authored by Mohammed Rashid Akhtar, Na'eem Ahmed, Nihad Khan.

Published by Zeshan Qureshi. First published 2017

All rights reserved; no part of this publication may be reproduced, stored in a retrieval system, transmitted in any form, or by any means, electronic, mechanical, photocopying, recording, or otherwise, without the prior written permission of the publishers.

Original design by Zeshan Qureshi. Layout & typesetting by SWATT Books

Illustrated by SWATT Books

A catalogue record for this book is available from the British Library.

Acknowledgements:

We would like to thank all the authors for their hard work, and our panel of student reviewers for their unique input. We are extremely grateful for the support given by medical schools across the UK, Europe and Australia. We would also like to thank the medical students that have inspired this project, believed in this project, and have helped contribute to, promote, and distribute the book across the world.

Although we have tried to trace and contact copyright holders before publication, in some cases this may not have been possible. If contacted we will be pleased to rectify any errors or omissions at the earliest opportunity. Knowledge and best practice in this field are constantly changing. As new research and experience broaden our understanding, changes in research methods, professional practices, or medical treatment may become necessary. Practitioners and researchers must always rely on their own experience and knowledge in evaluating and using any information, methods, compounds, or experiments described herein. In using such information or methods they should be mindful of their own safety and the safety of others, including parties for whom they have a professional responsibility. With respect to any drug or pharmaceutical products identified, readers are advised to check the most current information provided (i) on procedures featured or (ii) by the manufacturer of each product to be administered, to verify the recommended dose or formula, the method and duration of administration, and contraindications. It is the responsibility of practitioners, relying on their own experience and knowledge of their patients, to make diagnoses, to determine dosages and the best treatment for each individual patient, and to take all appropriate safety precautions. To the fullest extent of the law, neither the Publisher nor the authors, contributors, or editors, assume any liability for any injury and/or damage to persons or property that may occur as a result of any person acting or not acting based on information contained in this book

Printed and bound by Finidr, Czech Republic

INTRODUCTION

Almost every patient has some form of medical imaging performed during his or her investigations and management. The commonest type of imaging modality remains the X-ray. Chest X-rays are a frequently performed and particularly important test that all doctors should be able to interpret.

Despite its universal importance, X-ray interpretation is often an overlooked subject in the medical school curriculum, making it difficult and daunting for many medical students and junior doctors. *The Unofficial Guide to Radiology: 100 Practice Chest X-Rays, with Full Colour Annotations and Full X-Ray Reports* aims to help address this.

The key to interpreting X-rays is having a systematic method for assessment, and then getting lots of practice looking at and presenting X-rays. The best-selling core radiology text *The Unofficial Guide to Radiology* was specifically designed for medical students, radiographers, physician's associates, and junior doctors. It outlines a comprehensive system for assessing X-rays, in addition to clinical and radiology based MCQs to contextualise the radiographs to real clinical scenarios. Its approach led to recognition from the British Medical Association, the British Institute of Radiology and the Royal College of Radiologists. This follow-up textbook builds upon these foundations, providing readers with the opportunity to practise and consolidate their chest X-ray assessment and presenting skills.

There are lots of radiology textbooks available, but many have important limitations. Most have small, often poor quality images which are not ideal for displaying the radiological findings. The findings are usually only described in a figure below the image, and it may be difficult to know exactly what part of the image corresponds to which finding! Many textbooks deal with X-rays in isolation rather than in a useful clinical context.

We have designed this book to allow readers to practice interpreting X-rays in as useful and clinically relevant way as possible. There are:

- 100 large, high quality chest X-rays to assess.
- Cases presented in the context of a clinical scenario and covering a wide range of common and important findings (in line with the Royal College of Radiologists' Undergraduate Radiology Curriculum).
- Detailed on-image colour annotations to highlight key findings.
- Comprehensive systematic X-ray reports.
- Relevant further investigations and management are discussed for each case.

The cases are divided by difficulty into standard, intermediate and advanced based on the imaging findings and clinical implications. Each begins with a clinical scenario and a chest X-ray for you to interpret. You can then turn over the page, and find a fully annotated version of the same X-ray with a comprehensive report. Each systematically structured report is colour coded to match the corresponding labelled image.

Each report is based on the ABCDE approach to chest X-ray interpretation, as recommended in *The Unofficial Guide to Radiology*:

Technical features: Patient ID, projection, inspiration, rotation.

Airway: Tracheal position.

Breathing: Lung parenchyma, pleural spaces, pulmonary vasculature.

Circulation and mediastinum: Heart size/shape/borders, aorta, mediastinum, hila.

Diaphragm and delicats: Diaphragm position/shape, pneumoperitoneum, skeleton, soft tissues.

Extras: Anything else e.g. ECG clips, line, tubes, surgical staples.

Review areas: Lung apices/hila/behind heart/costophrenic angles/below the diaphragm.

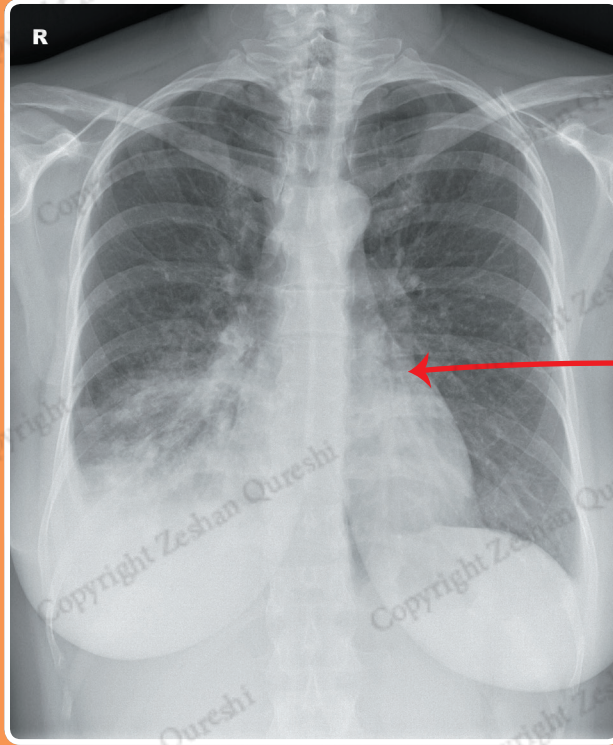
Summary: Putting together the salient findings of the X-ray with a differential diagnosis.

Investigations and management: The next steps in management after taking on board X-ray findings.

Realistic clinical history

CASE 11

A 40 year old female presents to ED with a 1 week history of cough and fever. There is no significant past medical history and she is a non-smoker. On examination, she has saturations of 85% in air, and is febrile with a temperature of 38.2°C. There is dullness to percussion and crackles in the right lower zone. A chest X-ray is performed to assess for possible pneumonia, collapse or effusion.



Large, high quality image to assess

REPORT – RIGHT MIDDLE AND LOWER LOBE CONSOLIDATION

Patient ID: Anonymous
Projection: PA
Penetration: Adequate – vertebral bodies just visible behind heart
Inspiration: Adequate – 7 anterior ribs visible
Rotation: The patient is slightly rotated to the left

AIRWAY
 The trachea is central.

BREATHING
 There is heterogeneous airspace opacification of the right lower zone consistent with consolidation. The lungs are otherwise clear. The lungs are not hyperinflated.

There is blunting of the right costophrenic angle in keeping with a small right pleural effusion. The left-sided pleural spaces are clear.

CIRCULATION
 The heart is not enlarged. The right heart border is largely clear, although its inferior margin is indistinct. Clear left heart border.

The aorta appears normal.

The mediastinum is central, not widened, with clear borders.

Normal size, shape, and position of the hila.

DIAPHRAGM + DELICATES
 The right hemidiaphragm is obscured by consolidation. Normal position and appearance of the left hemidiaphragm.

No pneumoperitoneum.

The imaged skeleton is intact with no fractures or destructive bony lesions visible.

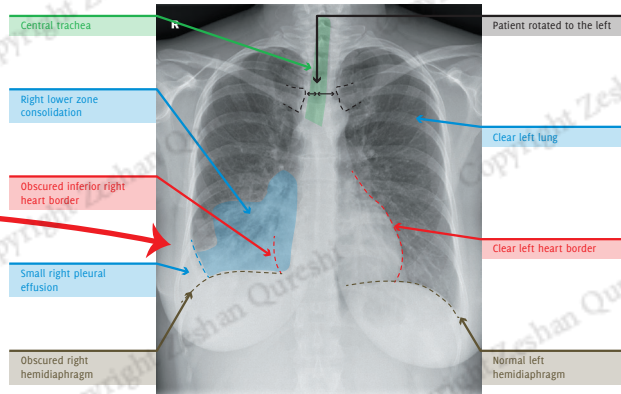
The visible soft-tissues are unremarkable.

EXTRAS + REVIEW AREAS
 No vascular lines, tubes, or surgical clips.

Lung Apices: Normal
Hila: Normal
Behind Heart: Normal
Costophrenic Angles: Blunted right costophrenic angle. Normal left costophrenic angle
Below the Diaphragm: Normal

Detailed report following a standard format

Chest x-ray review areas specifically highlighted



Clear annotations highlighting the major x-ray findings

SUMMARY, INVESTIGATIONS & MANAGEMENT

This X-ray demonstrates right lower zone consolidation which obscures the right hemidiaphragm, consistent with right lower lobe pneumonia. There may also be pneumonia affecting the right middle lobe, as the right heart border appears partially obscured. A small right parapneumonic effusion is also present. Initial blood tests may include FBC, U/Es, CRP, and blood cultures. A sputum culture may also be obtained.

The patient should be treated with appropriate antibiotics for community-acquired pneumonia, with a follow-up chest X-ray performed to ensure resolution. The antibiotics may be oral or intravenous depending on the severity of pneumonia (CURB-65). Ultrasound could be used to further assess the volume of the pleural effusion, particularly if a diagnostic pleural aspiration is being considered.

Investigations & management plan put the x-ray in the context of the overall clinical management

With this textbook, we hope you will become more confident and competent interpreting chest X-rays, both in exam situations and in clinical practice.

We also hope that this is just the beginning; we want you to get involved! This textbook has been a collaboration with junior doctors and students just like you. You have the power to contribute something really valuable to medical education; we welcome your suggestions and would love for you to get in touch. A good starting point is our Facebook page, which is growing into a forum for medical education.

Please get in touch and be part of the medical education project.



Mark Rodrigues



Zeshan Qureshi



Mohammed
Rashid Akhtar



Na'eem Ahmed



Nihad Khan



Facebook: <http://www.facebook.com/TheUnofficialGuideToMedicine>



Email: unofficialguidetomedicine@gmail.com



Twitter: @UGTM



Instagram: @the_UGTM



LinkedIn: The Unofficial Guide to Medicine

FOREWORD



Professor David
M Hansell

It is often said that interpretation of the chest radiograph is a dying art, and so it may be. Nonetheless, there are good reasons to keep alive the skills that allow accurate radiographic diagnosis. As the authors point out in their introduction, the chest radiograph is one of the most frequently ordered diagnostic tests, and this is likely to remain the case for the foreseeable future. Although the chest radiograph is ubiquitous, audits repeatedly reveal that the quality and accuracy of radiographic diagnosis is highly variable. The consequence of faulty interpretation can be unnecessary further investigations or, worse, failure to recognise important disease. This book goes a long way in helping both the novice and the more accomplished readers to hone their skills at reading chest radiographs.

The wealth of high quality teaching material in this carefully curated collection of 100 chest radiographs is impressive, and the authors have rightly concentrated on common, but clinically important, conditions. Another strength of this book is the repetition of a suggested scheme (given on the following page of each case) to ensure that the reader's evaluation of the chest radiograph is truly comprehensive - after some time this approach becomes second nature, and a good habit.

Any skill worth acquiring requires time and practice. Working through this series of chest radiographs will increase your confidence and skill at chest radiograph interpretation (n.b. confidence and skill are not synonymous) and there is considerable fun to be had along the way.

DAVID M HANSELL MD FRCP FRCR FRSM
*Professor of Thoracic Imaging, Imperial College, London
Consultant Radiologist, Royal Brompton Hospital, London*



Lana Nguyen

As a final year medical student approaching graduation, I only wish I had access to this book in my first few years on clinical placement. The high quality images, clearly labelled pathological signs and broad range of chest pathology covered, make this book an invaluable tool to anyone looking to develop a solid foundation in interpreting chest x-rays.

It is clear that this book has been written with students and junior doctors in mind. Each image is accompanied by a clinical vignette and examination findings which helps learners integrate the radiological findings with the clinical picture. Furthermore, the final "Summary, Investigations & Management" section provided in each case are precisely what supervisors and examiners want to hear when asking you to interpret an image either on the ward or in the OSCE.

This fantastic addition to the UTGM series easily meets its aim of helping students and junior doctors become more confident and competent at interpreting chest X-rays.

LANA NGUYEN
President, Western Sydney Medical Society 2015-6

ABBREVIATIONS

AC joint	Acromioclavicular joint
ACE	Angiotensin-converting enzyme
AP	Anterior-posterior
ARDS	Acute respiratory distress syndrome
ATLS	Advanced trauma life support
CABG	Coronary artery bypass graft
COPD	Chronic Obstructive Pulmonary Disease
CRP	C-reactive protein
CT	Computed tomography
CTPA	Computed tomography pulmonary angiography
CURB-65	Confusion Urea >7 mmol/l Respiratory rate ≥ 30 SBP <90 mmHg, or DBP ≤ 60 mmHg Age ≥ 65
ED	Emergency Department
ECG	Electrocardiogram
ESR	Erythrocyte sedimentation rate
ET tube	Endotracheal tube
FBC	Full blood count
HR	Heart rate
IV	Intravenous
LFTs	Liver function tests
LLL	Left lower lobe
NG tube	Nasogastric tube
PA	Posterior-anterior
PE	Pulmonary embolism
PICC	Peripherally inserted central catheter
PSA	Prostate specific antigen
RR	Respiratory rate
SVC	Superior vena cava
TFT	Thyroid function test
U/Es	Urea and electrolytes

CONTRIBUTORS

EDITORS

Mark Rodrigues
MBChB (Hons) BSc (Hons) FRCR

ECAT Clinical Lecturer, University of Edinburgh
Honorary Radiology Registrar, Royal
Infirmary of Edinburgh, UK



M. Rodrigues



Z. Qureshi

Zeshan Qureshi
BM BSc (Hons) MSc MRCPCH

Academic Clinical Fellow, Great Ormond Street,
UK and Institute of Global Health, UCL, UK


AUTHORS

Mohammed Rashid Akhtar
MBBS BSc (Hons) FRCR

Radiology Registrar, The Royal London
Hospital and Broomfield Hospital, UK



M. R. Akhtar




N. Ahmed

Na'eem Ahmed
MBBS BSc

Radiology Registrar, St George's University
Hospital NHS Foundation Trust, UK

Nihad Khan
MBBS BSc

Radiology Registrar, Nottingham
University Hospital NHS Trust, UK



N Khan

SENIOR REVIEWER

Patrick Byrne
MRCPG MRCSEd FRCP Edin

Consultant Physician & GP, Bedford
Hospital, Fort William, UK



P. Byrne


REVIEWERS

Cong Ying Hey

Medical Student, University of Nottingham



C. Y. Hey




H. Wheldon-
Holmes

Hannah Wheldon-Holmes
BA (Hons)

Medical Student, Swansea University

Sofia Arkhipkina

Medical Student, University of Leeds



S. Arkhipkina




E. I. El
Makdessi

Emma Isabella El Makdessi
BA MSc


Medical Student, University of Edinburgh

Alistair J. Roddick
BSc (Hons)

Medical Student, King's College London



A. J. Roddick



E. Gill

Emma Gill
BSc (Hons)

Medical Student, University of Edinburgh

CONTENTS

Introduction	3
Foreword	6
Abbreviations	7
Contributors	8
Standard Cases	11
Intermediate Cases	79
Advanced Cases	153
Case Study Index	217
Index	219

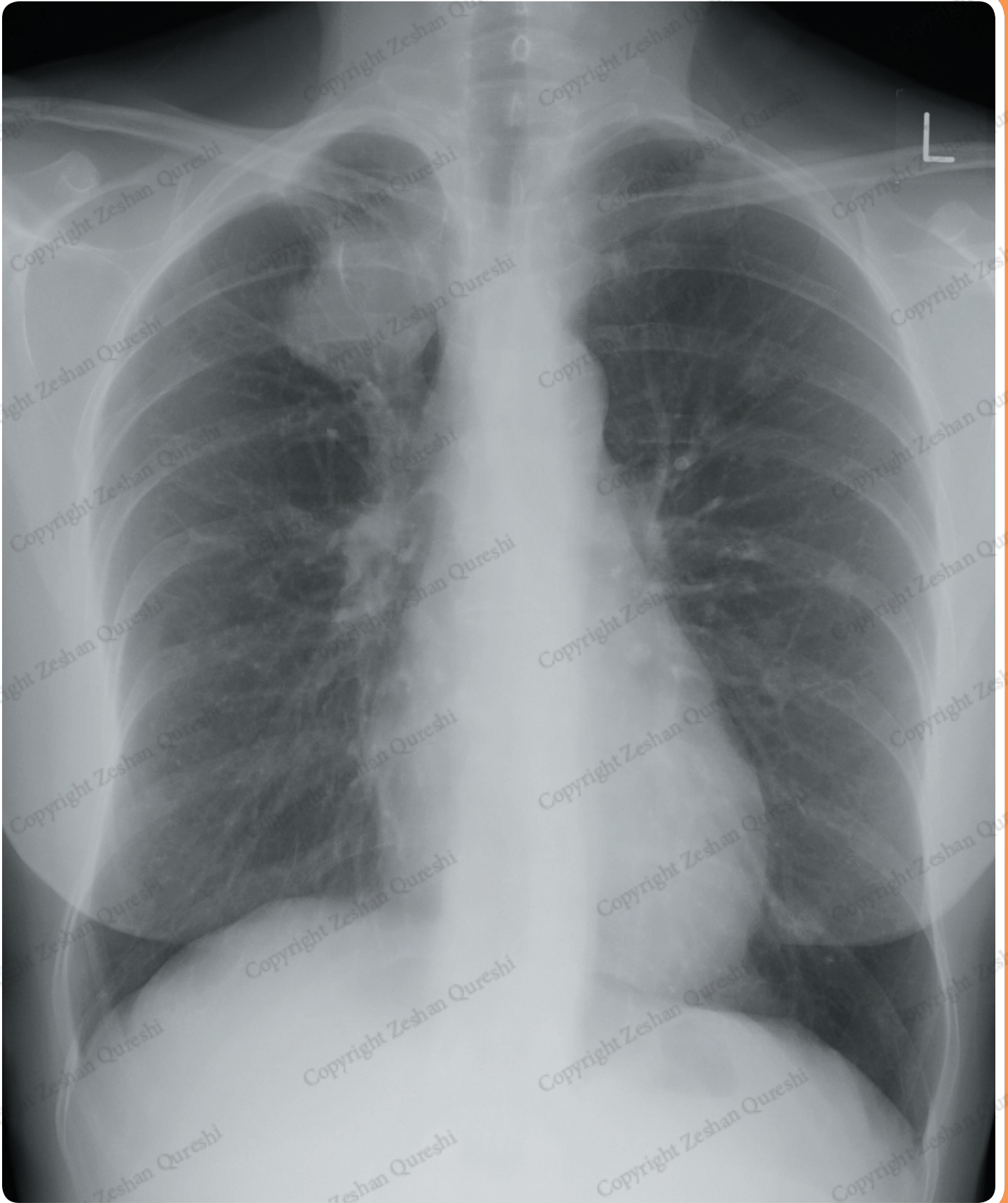
Copyright Zeshan Qureshi

STANDARD CASES



CASE 3

A 60 year old female presents to her GP with fatigue, weight loss and wheeze. There is no significant past medical history. She is a non-smoker. On examination, she has saturations of 99% in air and is afebrile. There is wheeze in the right upper zone. A chest X-ray is requested to assess for malignancy or COPD.



REPORT – LUNG AND HILAR MASSES

Patient ID: Anonymous
Projection: PA
Penetration: Adequate – vertebral bodies just visible behind heart
Inspiration: Adequate – 7 anterior ribs visible
Rotation: The patient is slightly rotated to the right

AIRWAY

The trachea is central after factoring in patient rotation.

BREATHING

There is a right upper zone mass projected over the anterior aspects of the right 1st and 2nd ribs. There are multiple small pulmonary nodules visible within the left hemithorax.

The lungs are not hyperinflated.

There is pleural thickening at the right lung apex.

Normal pulmonary vascularity.

CIRCULATION

The heart is not enlarged.

The heart borders are clear.

The aorta appears normal.

The mediastinum is central, and not widened. The right upper zone mass appears contiguous with the superior mediastinum.

The right hilum is abnormally dense. It also appears higher than the left. Normal size, shape and position of the left hilum.

DIAPHRAGM + DELICATES

Normal appearance and position of the hemidiaphragms.

No pneumoperitoneum.

The imaged skeleton is intact with no fractures or destructive bony lesions visible.

The visible soft tissues are unremarkable.

EXTRAS + REVIEW AREAS

No vascular lines, tubes, or surgical clips.

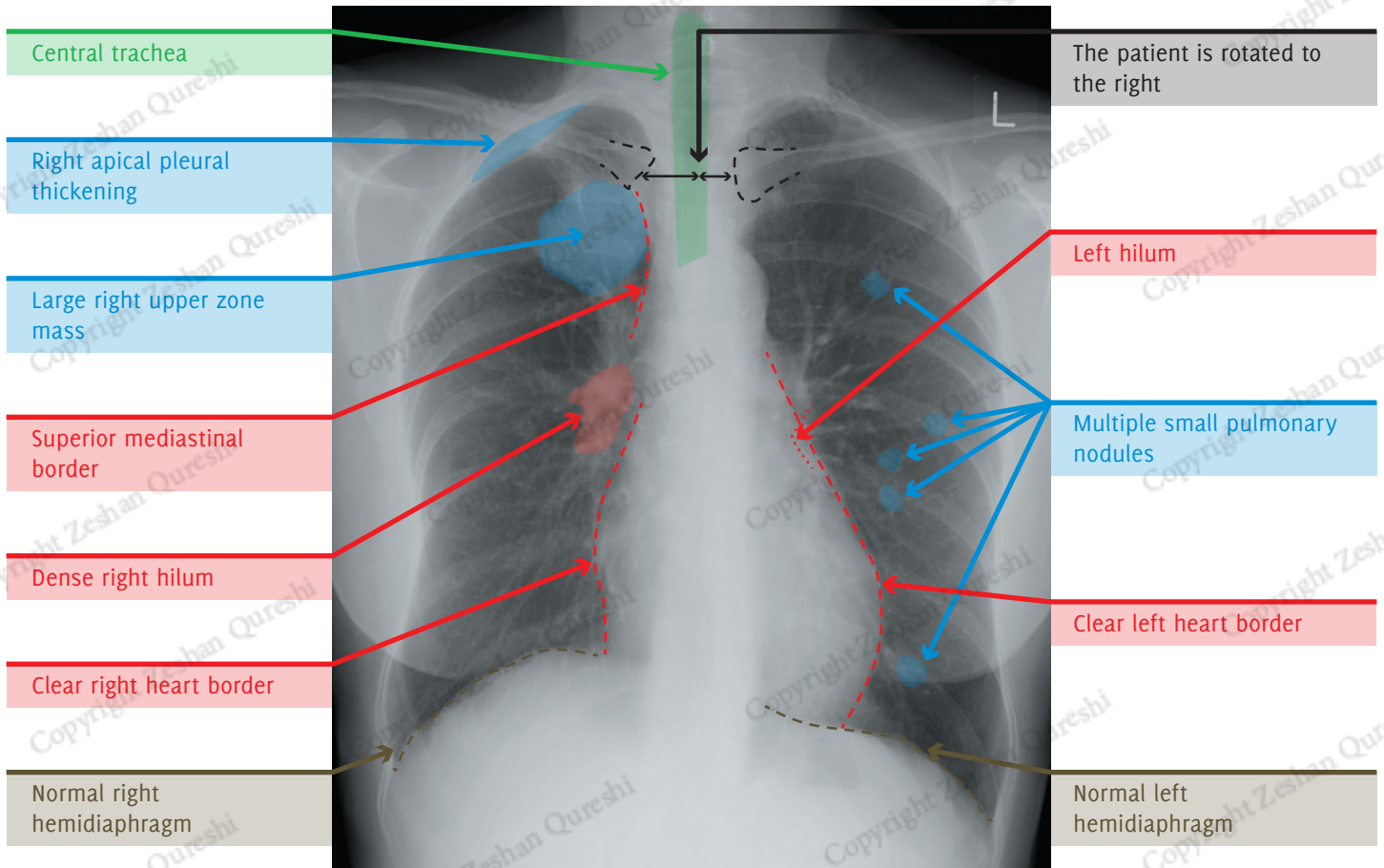
Lung Apices: Right apical pleural thickening

Hila: Dense right hilum, normal left hilum

Behind Heart: Normal

Costophrenic Angles: Normal

Below the Diaphragm: Normal



SUMMARY, INVESTIGATIONS & MANAGEMENT

This X-ray demonstrates a large, rounded right upper lobe lung lesion associated with multiple smaller nodules. This is highly suspicious of a right upper lobe primary lung cancer with lung metastases. The dense right hilum is suspicious for hilar nodal disease. The significance of the right apical pleural thickening is not clear.

Initial blood tests may include FBC, U/Es, CRP, LFTs, & bone profile.

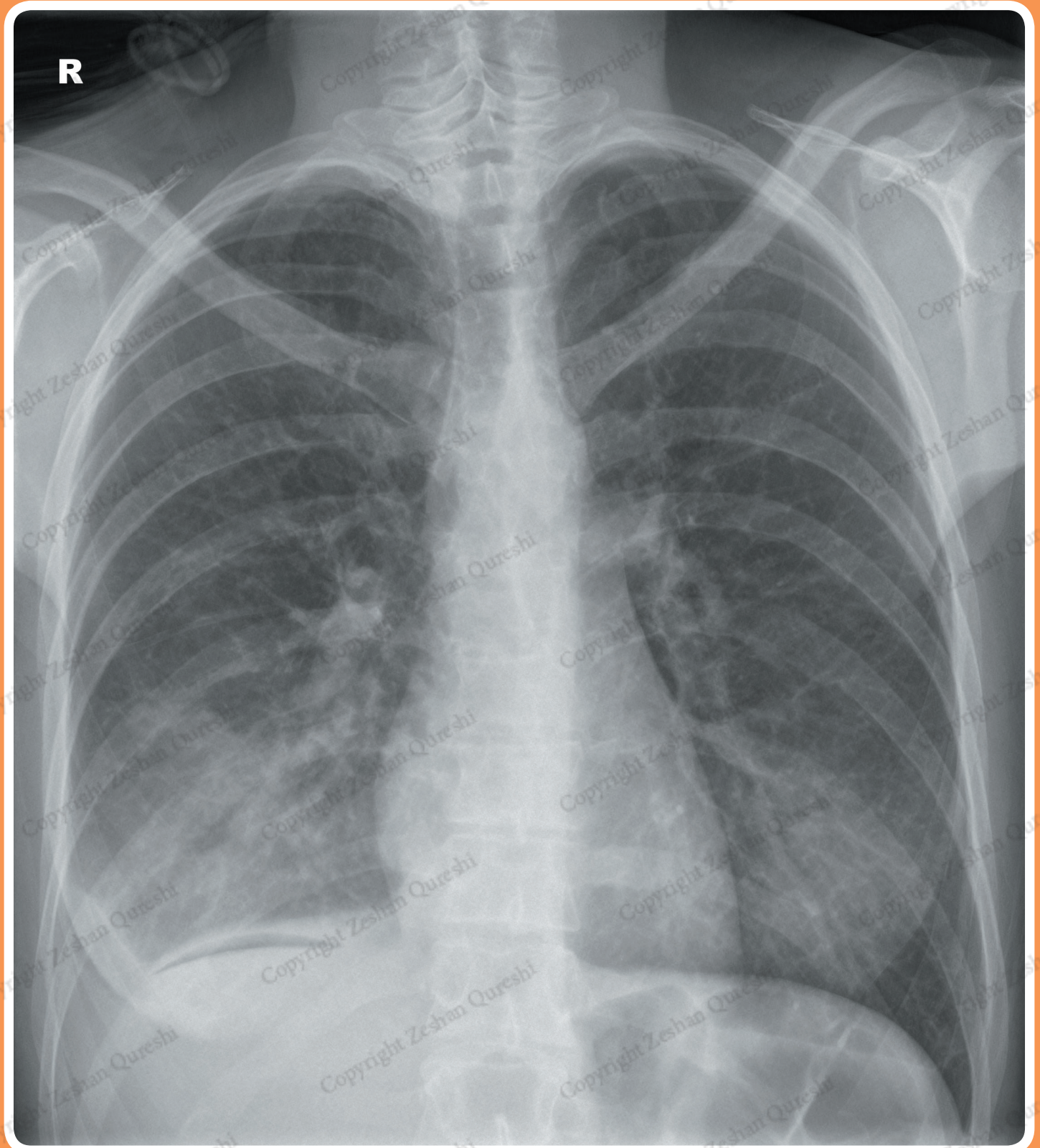
A staging CT chest, and abdomen with IV contrast should be performed.

The patient should be referred to respiratory/oncology services for further management, which may include biopsy and MDT discussion. Treatment, which may include surgery, radiotherapy, chemotherapy, or palliative treatment, will depend on the outcome of the MDT discussion, investigations, and the patient's wishes.



CASE 17

A 32 year old female on the surgical ward develops shortness of breath and a fever 36 hours post-appendicectomy. There is no other significant past medical history. She is a non-smoker. On examination, she has saturations of 91% in air, a RR of 25, a HR of 120, and is febrile with a temperature of 39.5°C. There is reduced air entry and crackles in the right lung base. A chest X-ray is requested to assess for possible pneumonia or effusion.



REPORT – RIGHT LOWER ZONE CONSOLIDATION

Patient ID: Anonymous
Projection: PA
Penetration: Adequate – vertebral bodies just visible behind heart
Inspiration: Adequate – 7 anterior ribs visible
Rotation: The patient is slightly rotated to the right

AIRWAY

The trachea is central after factoring in patient rotation.

BREATHING

There is right lower zone air space opacification in keeping with consolidation. The remainder of the lungs are clear. The lungs are not hyperinflated.

There is blunting of the right costophrenic angle, consistent with a small pleural effusion. The left pleural space is clear.

Normal pulmonary vascularity.

CIRCULATION

The heart is not enlarged.

The heart borders are clear.

The aorta appears normal.

The mediastinum is central, not widened, with clear borders.

Normal size, shape, and position of both hila.

DIAPHRAGM + DELICATES

The lateral aspect of the right hemidiaphragm is obscured by the pleural effusion. The remainder of the diaphragm is clear.

There is a lucent crescent below the right hemidiaphragm consistent with a small volume of pneumoperitoneum.

The imaged skeleton is intact with no fractures or destructive bony lesions visible.

The visible soft tissues are unremarkable.

EXTRAS + REVIEW AREAS

No vascular lines, tubes, or surgical clips.

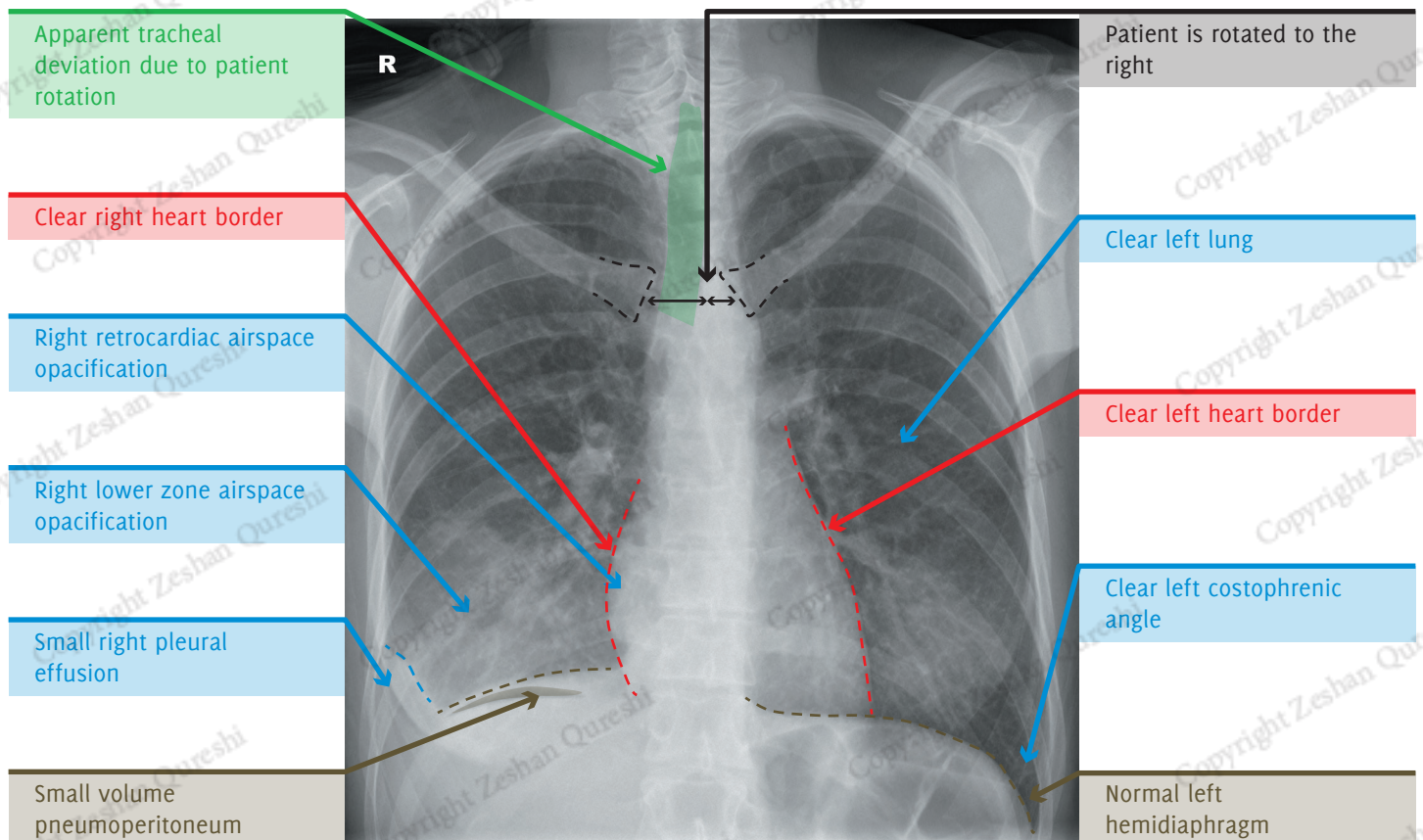
Lung Apices: Normal

Hila: Normal

Behind Heart: Increased right retrocardiac opacification consistent with consolidation

Costophrenic Angles: Blunting of the right costophrenic angle. Normal left costophrenic angle.

Below the Diaphragm: Small-volume pneumoperitoneum beneath the right hemidiaphragm



SUMMARY, INVESTIGATIONS & MANAGEMENT

The X-ray demonstrates right lower zone consolidation, associated with a pleural effusion. This is consistent with pneumonia and a parapneumonic effusion. There is also a small-volume pneumoperitoneum, which is in keeping with the recent surgery.

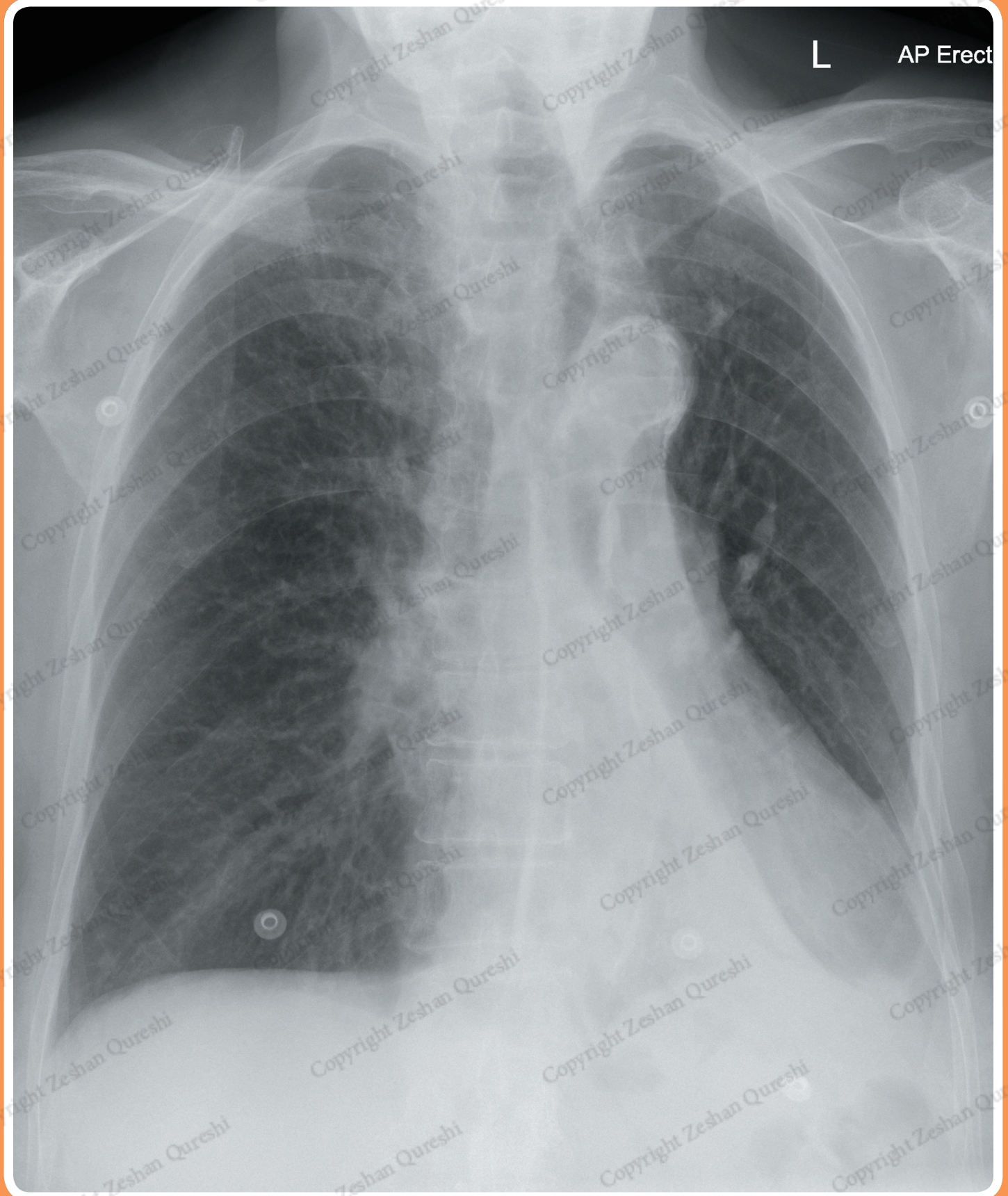
The patient should be started on supplementary oxygen. Initial blood tests may include FBC, U/Es, blood cultures, and CRP. A sputum culture may also be taken.

She will require IV fluids and appropriate antibiotics for hospital-acquired pneumonia, and a follow up X-ray to ensure resolution of the consolidation should be performed. An ultrasound could be considered to assess the size of the parapneumonic effusion, and permit ultrasound-guided aspiration/drainage if required.



CASE 33

An 88 year old male presents to the ED with 3 weeks of progressive shortness of breath, cough and some haemoptysis. He has a 60 pack year smoking history. On examination, he has saturations of 85% in air and is afebrile. There is dullness to percussion and reduced air entry in the left lower zone. A chest X-ray is requested to assess for possible pneumonia or malignancy.



REPORT – LEFT LOWER LOBE COLLAPSE

Patient ID: Anonymous
Projection: AP
Penetration: Adequate – vertebral bodies just visible behind heart
Inspiration: Adequate – 6 anterior ribs visible
Rotation: The patient is slightly rotated to the left

AIRWAY

The trachea is deviated to the left, even when allowing for the patient rotation.

BREATHING

The lungs appear hyperinflated with coarsening of the lung markings.

There is an abnormal triangular opacity projected over the medial aspect of the left mid and lower zones in keeping with the sail sign.

The right lung and pleural spaces are clear.

Normal pulmonary vascularity.

CIRCULATION

The heart does not appear enlarged, although its size cannot be accurately assessed on an AP X-ray.

There is an apparent double left heart border. The right heart border is difficult to assess as it is projected over the thoracic spine, but appears clear.

The descending thoracic aortic contour is not visible.

The mediastinum is displaced to the left.

Normal size and shape of both hila. There is mild depression of the left hilum.

DIAPHRAGM + DELICATES

The left hemidiaphragm is partially obscured indicating left lower lobe pathology. The right

hemidiaphragm is flattened, in keeping with lung hyperinflation.

No pneumoperitoneum.

The imaged skeleton is intact with no fractures or destructive bony lesions visible.

The visible soft tissues are unremarkable.

EXTRAS + REVIEW AREAS

ECG clips in situ.

No vascular lines, tubes, or surgical clips.

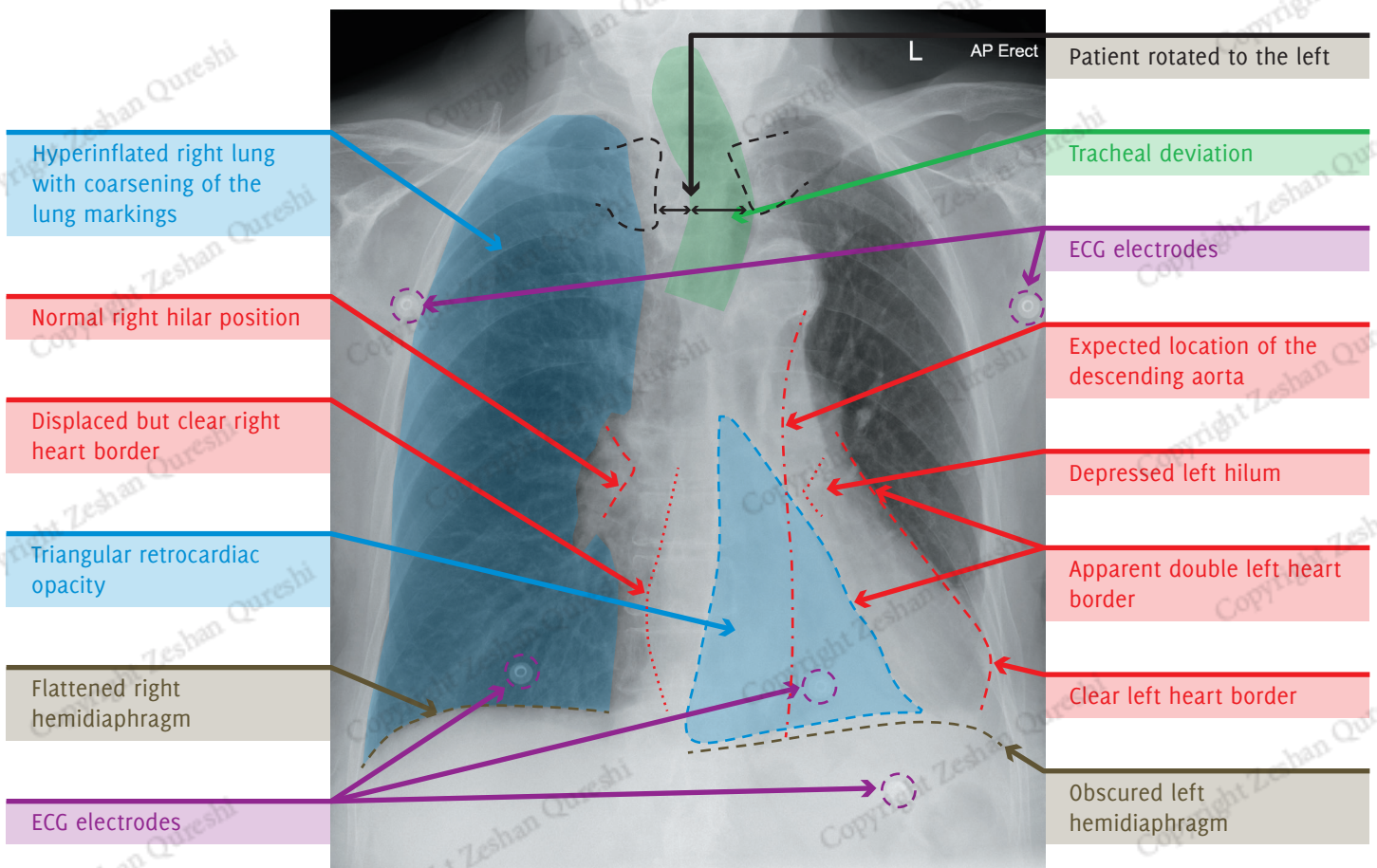
Lung Apices: Normal

Hila: Left hilum is depressed. Normal right hilum

Behind Heart: Sail sign with left double cardiac contour. Loss of outline of the descending thoracic aorta

Costophrenic Angles: Normal

Below the Diaphragm: Normal



SUMMARY, INVESTIGATIONS & MANAGEMENT

This X-ray demonstrates a left lower lobe collapse (sail sign, apparent double left heart border and loss of descending aortic outline). Resultant volume loss in the left hemithorax is indicated by mediastinal deviation and depression of the left hilum.

Coarsening of the lung markings and hyperinflation of the right lung are in keeping with chronic obstructive pulmonary disease (COPD).

Given the strong smoking history combined with 3 weeks of progressive symptoms, a proximal obstructing mass (tumour or hilar lymph node) is the most likely cause of the lobar collapse. Other differentials include a mucus plug or an inhaled foreign body.

Supplementary oxygen should be given.

Initial blood tests may include FBC, U/E/s, LFTs, bone profile, CRP, ESR and TFTs. CT chest with IV contrast to assess for a proximal obstructing lesion, such as a tumour, should be performed. A CT of the abdomen will usually also be acquired at the same time to enable lung cancer staging.

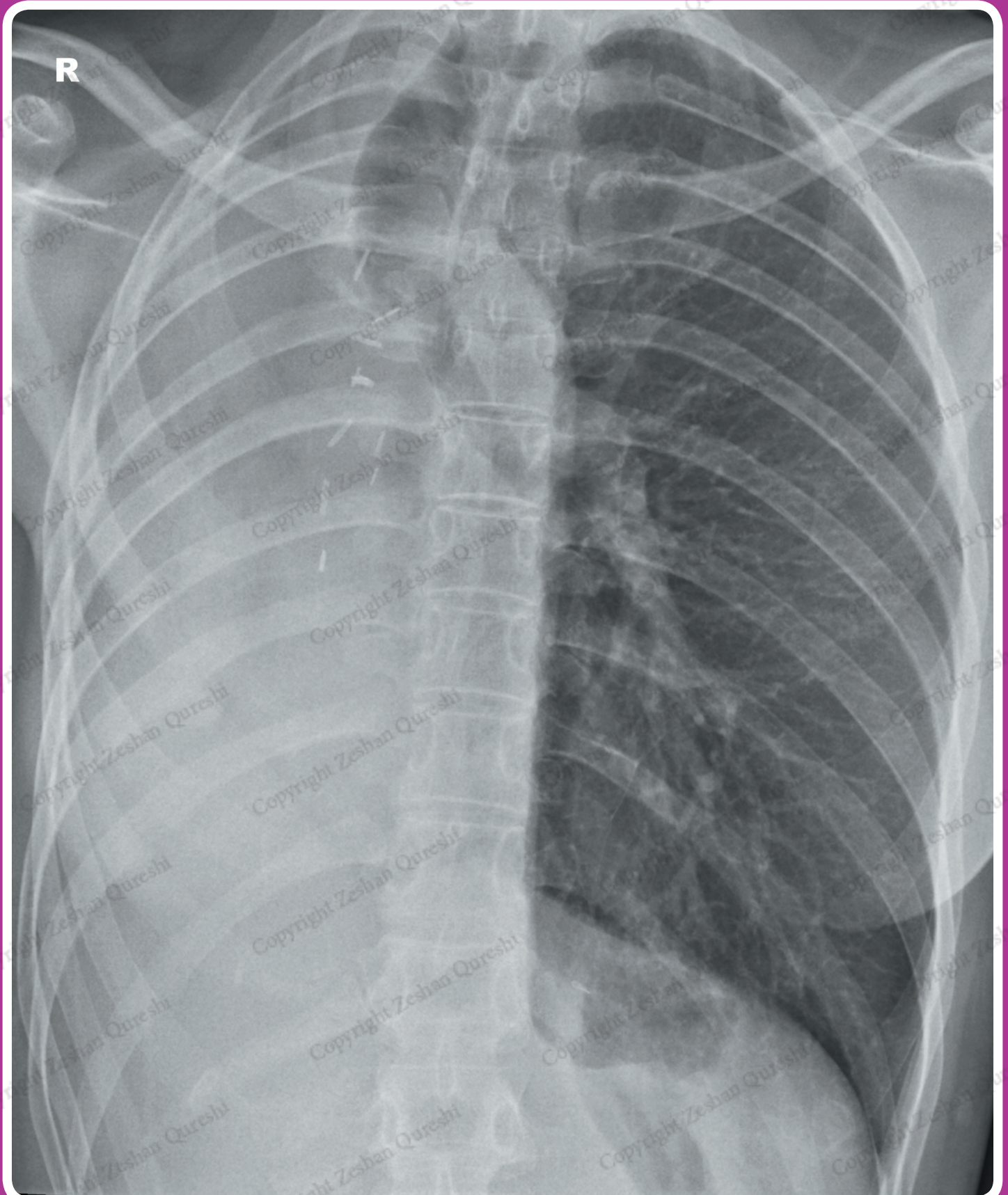
The patient should be referred to respiratory:oncology services for further management, which may include biopsy and MDT discussion. Treatment, which may include surgery, radiotherapy, chemotherapy, or palliative treatment, will depend on the outcome of the MDT investigations and the patient's wishes.

INTERMEDIATE CASES



CASE 41

A 42 year old female attends the cardiothoracic outpatient clinic for review 10 weeks post lung cancer surgery. Unfortunately her notes are unavailable. She says she has recovered well from the surgery. On examination, she is afebrile, and her saturations are 98% in air. There is reduced chest expansion on the right with no breath sounds and dullness to percussion. Examination of the left lung is normal. A chest X-ray is requested as part of the routine post-operative follow up.



REPORT – PNEUMONECTOMY

Patient ID: Anonymous
Projection: PA
Penetration: Adequate – vertebral bodies just visible behind heart
Inspiration: Adequate – 8 anterior ribs visible
Rotation: Not rotated

AIRWAY

The trachea is deviated to the right.

BREATHING

There is a white out of the right hemithorax with a total absence of bronchovascular markings.

The left lung appears hyper-expanded but clear with normal pleural spaces and pulmonary vascularity.

CIRCULATION

The heart is difficult to identify. It is presumably displaced into the opacified right hemithorax.

The mediastinum is displaced to the right.
The aorta is difficult to identify.

The right hilum is difficult to identify due to the opacification. Normal size, shape and position of the left hilum.

DIAPHRAGM + DELICATES

The right hemidiaphragm and costophrenic angle are obscured. Normal appearance and position of the left hemidiaphragm.

No pneumoperitoneum.

The imaged skeleton is intact with no fractures or destructive bony lesions visible.

The visible soft tissues are unremarkable.

EXTRAS + REVIEW AREAS

There are surgical clips projected medially over the right hemithorax, near the trachea and right main bronchus.

No vascular lines or tubes.

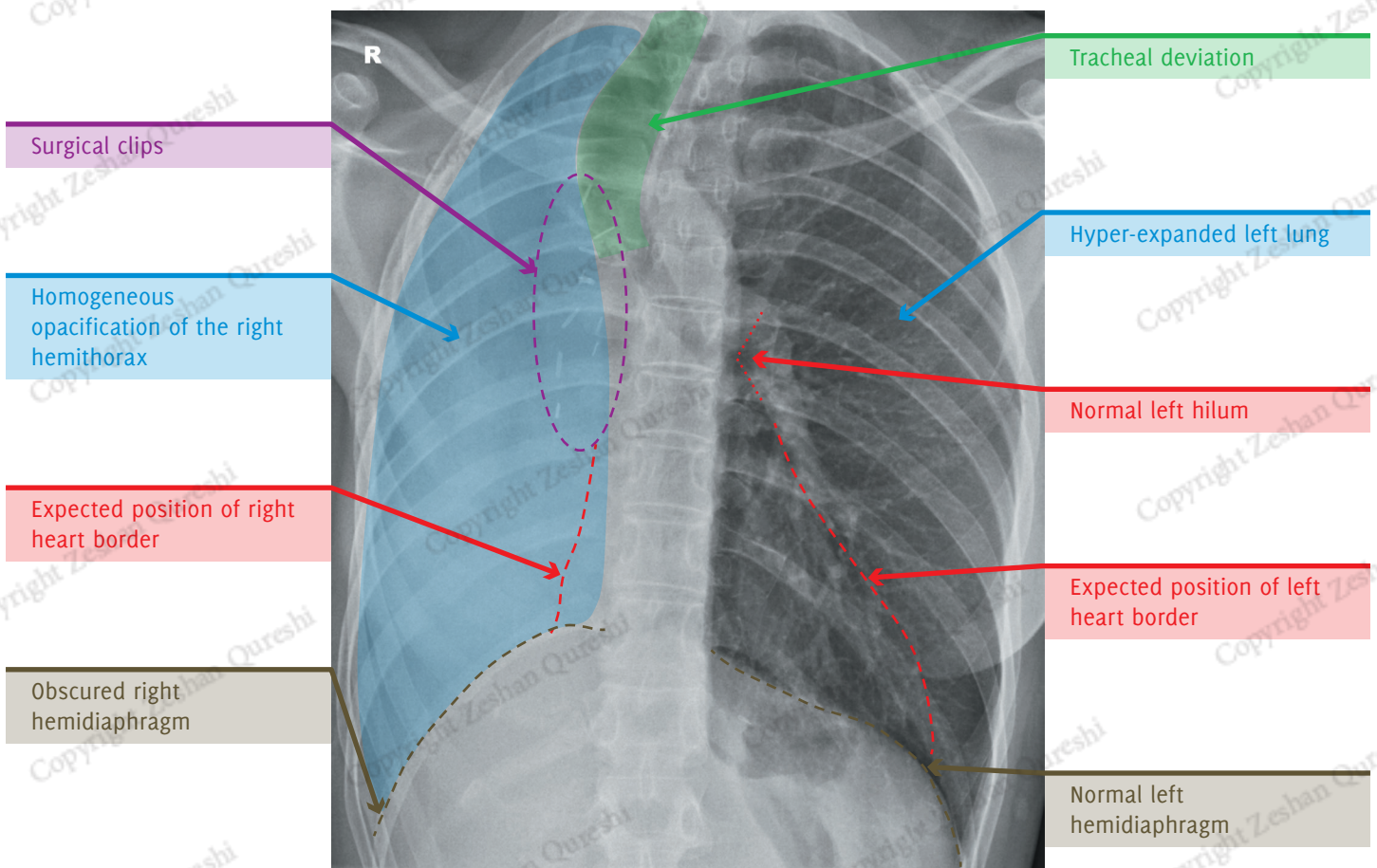
Lung Apices: Opacification of the right apex. Normal left apex

Hila: Right hilum difficult to see. Normal left hilum

Behind Heart: Difficult to assess

Costophrenic Angles: Obscured on the right. Preserved on the left

Below the Diaphragm: Normal



SUMMARY, INVESTIGATIONS & MANAGEMENT

This X-ray demonstrates a total white out of the right hemithorax with marked volume loss demonstrated by mediastinal deviation. There are surgical clips in the right mid and upper zones.

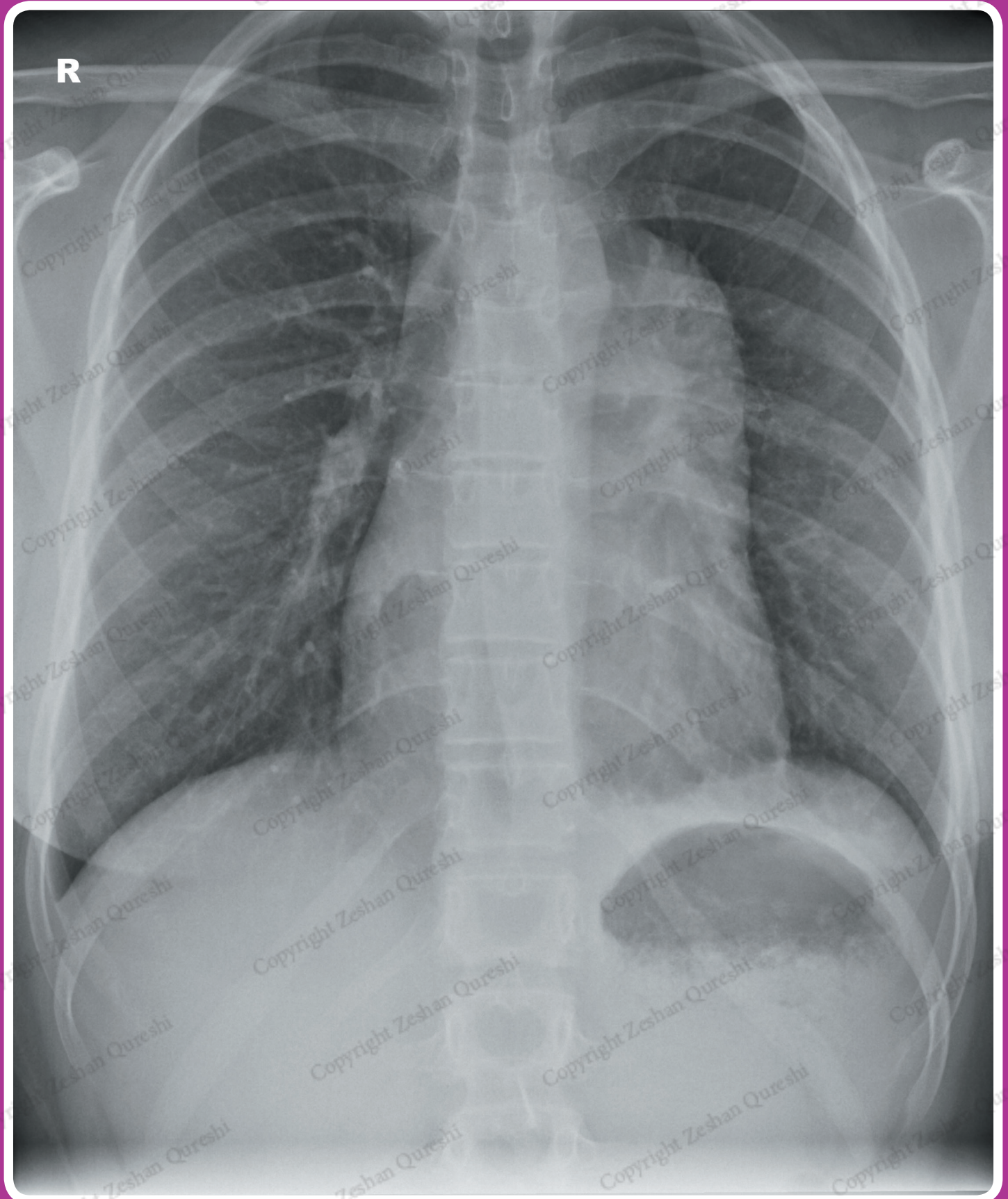
The findings are consistent with the normal appearance of a right pneumonectomy. The white out will be due to fluid filling the postpneumonectomy space. There is no air-fluid level (hydropneumothorax) to suggest a bronchopleural fistula.

It would be helpful to compare the current X-ray with previous imaging, but no specific investigation/action is required.



CASE 47

A 25 year old female presents to her GP with worsening shortness of breath. There is no significant past medical history and she is a non-smoker. On examination, she has saturations of 98% in air and is afebrile. Lungs are resonant throughout with good bilateral air entry and occasional wheeze. A chest X-ray is requested to assess for possible pneumonia, collapse, or pleural effusions.



REPORT – ANTERIOR MEDIASTINAL MASS

Patient ID: Anonymous
Projection: PA
Penetration: Adequate – vertebral bodies just visible behind heart
Inspiration: Adequate – 7 anterior ribs visible
Rotation: Not rotated

AIRWAY

The trachea is slightly deviated to the right.

BREATHING

The lungs are clear.

The lungs are not hyperinflated.

The pleural spaces are clear.

Normal pulmonary vascularity.

CIRCULATION

There is a left-sided mediastinal mass, which is continuous with the left heart border. The left hilar structures can be seen through the mass (hilum overlay sign), indicating that the mass is not in the middle mediastinum. The aortic knuckle and descending thoracic aorta are also visible through the mass, and thus the mass is not in the posterior mediastinum.

The heart is not enlarged.

The right heart border is clear.

The aorta appears normal.

Normal size, shape, and position of both hila.

DIAPHRAGM + DELICATES

Normal appearance and position of the hemidiaphragms.

No pneumoperitoneum.

The imaged skeleton is intact with no fractures or destructive bony lesions visible.

The visible soft tissues are unremarkable.

EXTRAS + REVIEW AREAS

No vascular lines, tubes, or surgical clips.

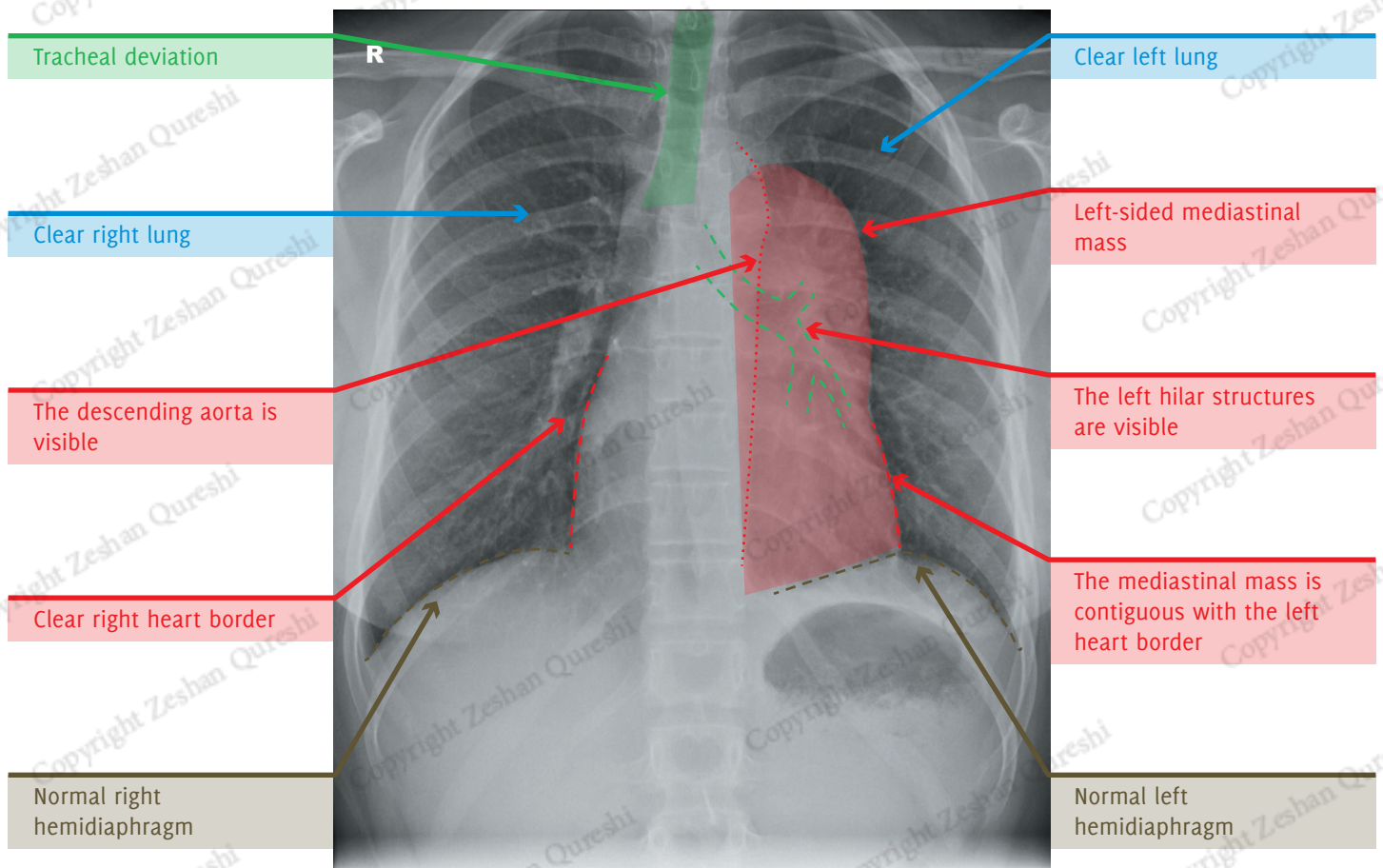
Lung Apices: Normal

Hila: Normal (Left hilum overlay sign)

Behind Heart: Normal

Costophrenic Angles: Normal

Below the Diaphragm: Normal



SUMMARY, INVESTIGATIONS & MANAGEMENT

This X-ray demonstrates a left-sided mediastinal mass. Loss of the left heart border indicates involvement of the anterior mediastinal compartment. The left hilum and descending thoracic aorta are visible separate to the mass, indicating the middle and posterior compartments are spared. The differentials includes lymphoma, thyroid malignancy, thymoma (although usually in older patients), and teratoma.

A full examination to assess for lymph node enlargement should be undertaken. Initial blood tests may include FBC, U/Es, LFTs, bone profile, and TFTs.

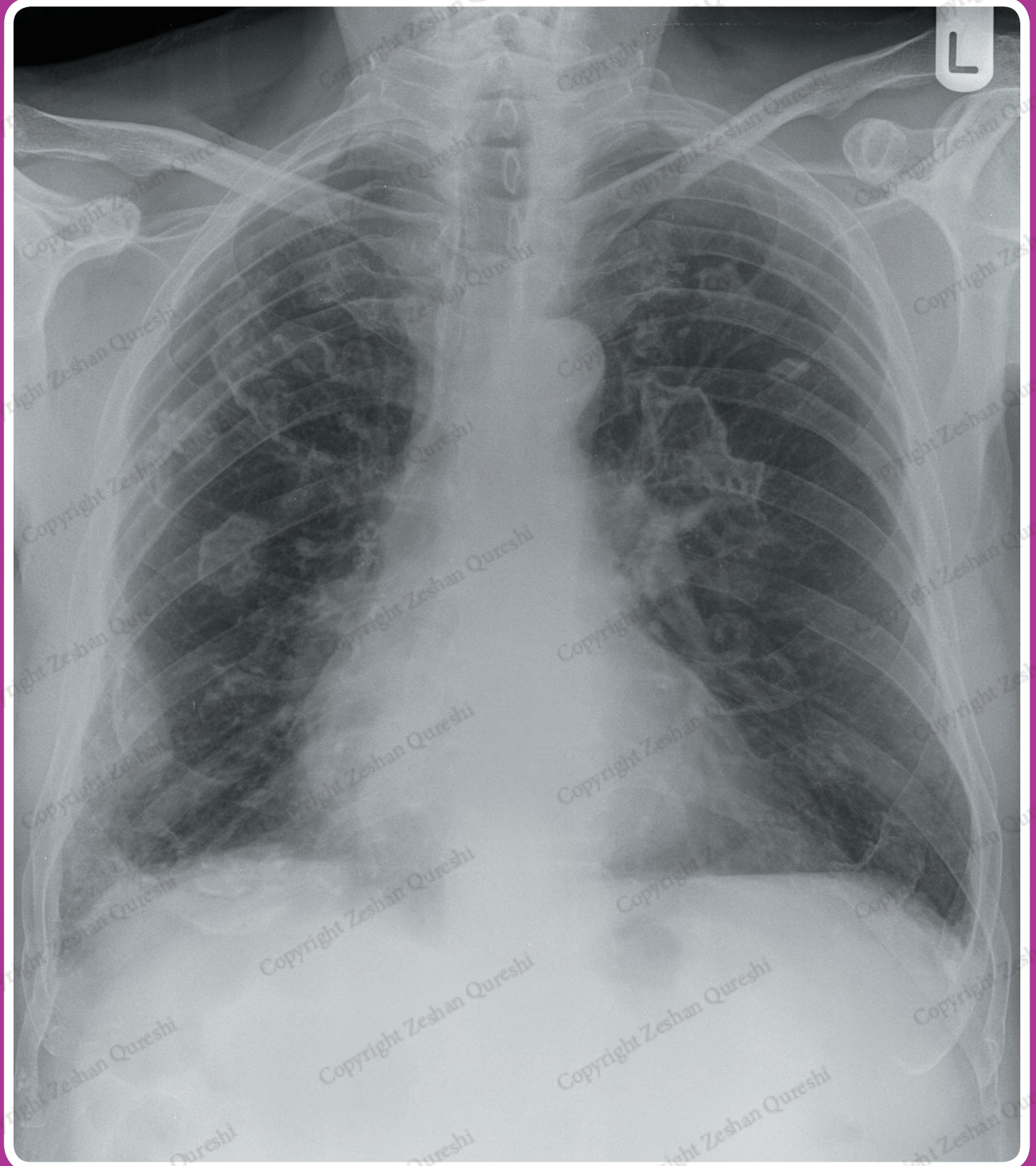
Further imaging in the form of contrast enhanced CT of the chest should be performed. If lymphoma is suspected then the neck, abdomen, and pelvis should also be included in the CT. A CT-guided anterior mediastinal mass biopsy may be required for a histological diagnosis.

The patient should be referred to respiratory/oncology services for further management, which may include biopsy and MDT discussion. Treatment, which may include surgery, radiotherapy, chemotherapy, or palliative treatment, will depend on the outcome of the MDT discussion, investigations, and the patient's wishes.



CASE 69

An 80 year old male presents to ED with progressively worsening breathlessness. He used to work in the shipyards. He has a 60 pack year smoking history. On examination, he has saturations of 92% in air and is febrile with a temperature of 38.2°C. His RR is 25 with a HR of 80 bpm. There are crackles and dullness to percussion at the right lung base. There is also finger clubbing. A chest X-ray is requested to assess for possible pneumonia or malignancy.



REPORT – CALCIFIED PLEURAL PLAQUES

Patient ID: Anonymous
Projection: PA
Penetration: Adequate – vertebral bodies just visible behind heart
Inspiration: Adequate – 8 anterior ribs visible
Rotation: The patient is mildly rotated to the right

AIRWAY

The trachea is central after factoring in patient rotation.

BREATHING

There is heterogeneous airspace opacification in the right lower zone in keeping with consolidation. The lungs are otherwise clear.

The lungs are not hyperinflated.

There are multiple irregular densities projected over the hemithoraces, consistent with calcified pleural plaques.

Normal pulmonary vascularity.

CIRCULATION

The heart is not enlarged.

The heart borders are clear. A left-sided epicardial fat pad is visible.

The aorta appears normal.

The mediastinum is central, not widened, with clear borders.

Normal size, shape, and position of both hila.

DIAPHRAGM + DELICATES

There is calcification present overlying the right hemidiaphragm in keeping

with a pleural plaque. Otherwise normal appearance and position of the hemidiaphragms.

No pneumoperitoneum.

The imaged skeleton is intact with no fractures or destructive bony lesions visible.

The visible soft tissues are unremarkable.

EXTRAS + REVIEW AREAS

No vascular lines, tubes, or surgical clips.

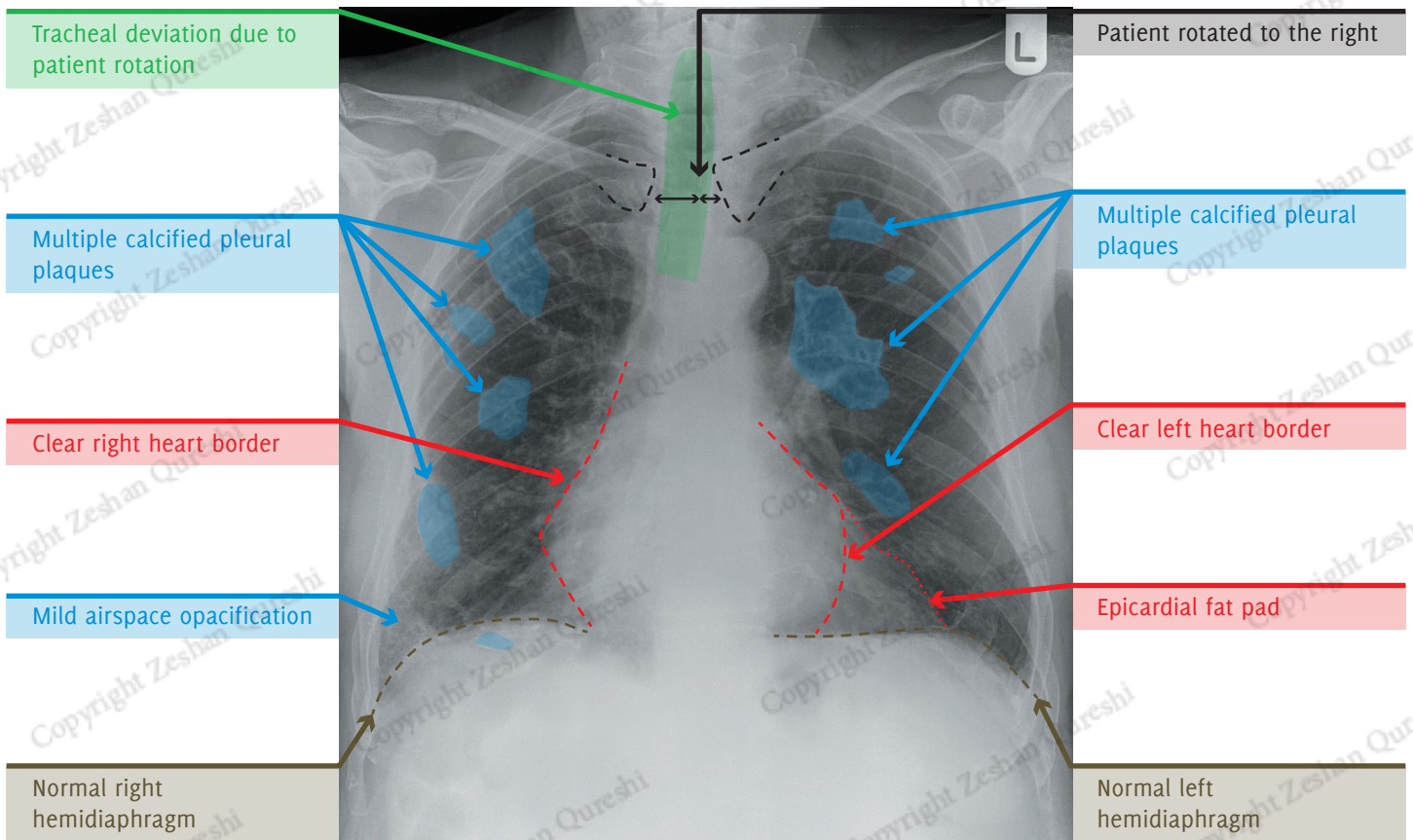
Lung Apices: Normal

Hila: Normal

Behind Heart: Normal

Costophrenic Angles: Consolidation at the right costophrenic angle

Below the Diaphragm: Normal



SUMMARY, INVESTIGATIONS & MANAGEMENT

The X-ray demonstrates multiple irregularly shaped densities throughout both hemithoraces. These are consistent with calcified pleural plaques and indicate past asbestos exposure. Focal consolidation at the right costophrenic angle is in keeping with pneumonia.

Initial blood tests may include FBC, U/Es and CRP. Sputum and blood cultures may also be helpful. A follow up chest X-ray 4-6 weeks after appropriate antibiotics should be performed to ensure resolution of the pneumonia.

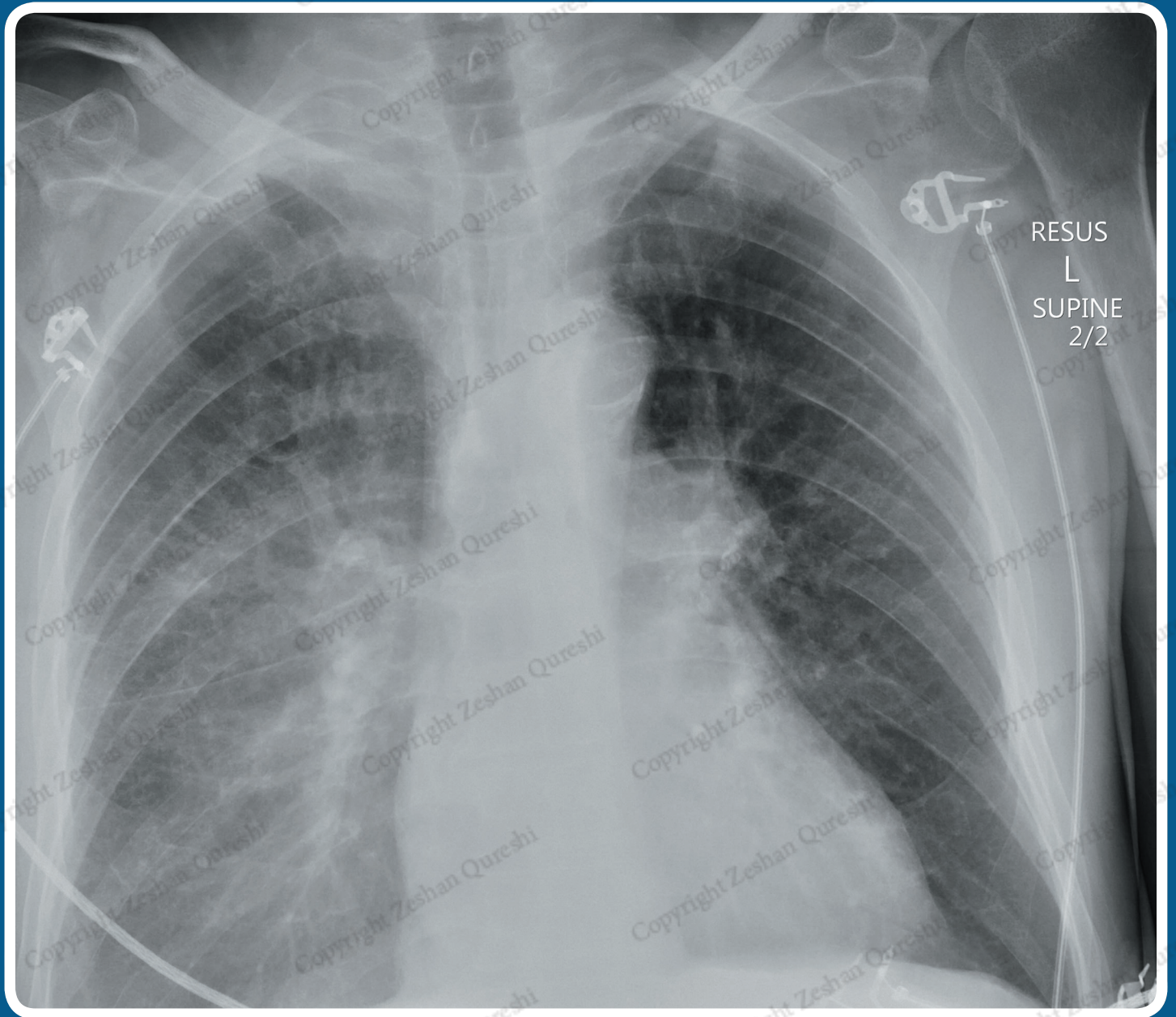
Previous imaging should be reviewed; if the pleural plaques are a new diagnosis the patient should be referred to respiratory for further assessment of asbestos-related lung disease.

ADVANCED CASES



CASE 70

A 58 year old male is brought to ED after falling off a ladder. He has right-sided chest pain and breathlessness. He has no significant past medical history. He is a non-smoker. On examination, he has saturations of 88% in air, his HR is 122 bpm and BP 108/68 mmHg. There is decreased air entry in the right hemithorax. A chest X-ray is requested to assess for a possible pneumothorax.



REPORT – SUPINE PLEURAL EFFUSION

Patient ID: Anonymous
Projection: AP Supine
Penetration: Adequate – vertebral bodies just visible behind heart
Inspiration: Adequate – 6 anterior ribs visible
Rotation: The patient is slightly rotated to the right

AIRWAY

The trachea is central.

BREATHING

The right lower zone, and costophrenic angles have not been fully included on the X-ray.

There is hazy opacification in the right hemithorax compared with the left side. This is more marked in the lower and mid zones, and fades in the upper zone. Normal bronchovascular markings are

clearly visible through the opacification and there are no air bronchograms.

The left lung is clear.

Normal pulmonary vascularity.

CIRCULATION

The heart size cannot be accurately assessed on an AP X-ray. The heart borders are clear.

The aorta appears normal.

The mediastinum is central, not widened, with clear borders.

Normal size, shape and position of both hila.

DIAPHRAGM + DELICATES

The right hemidiaphragm is not included on the X-ray. Normal appearance and position of the left hemidiaphragm.

It is not possible to accurately assess for pneumoperitoneum due to the limited X-ray coverage and supine positioning.

The imaged skeleton is intact with no fractures or destructive bony lesions visible.

EXTRAS + REVIEW AREAS

ECG monitoring leads in situ. No vascular lines, tubes, or surgical clips.

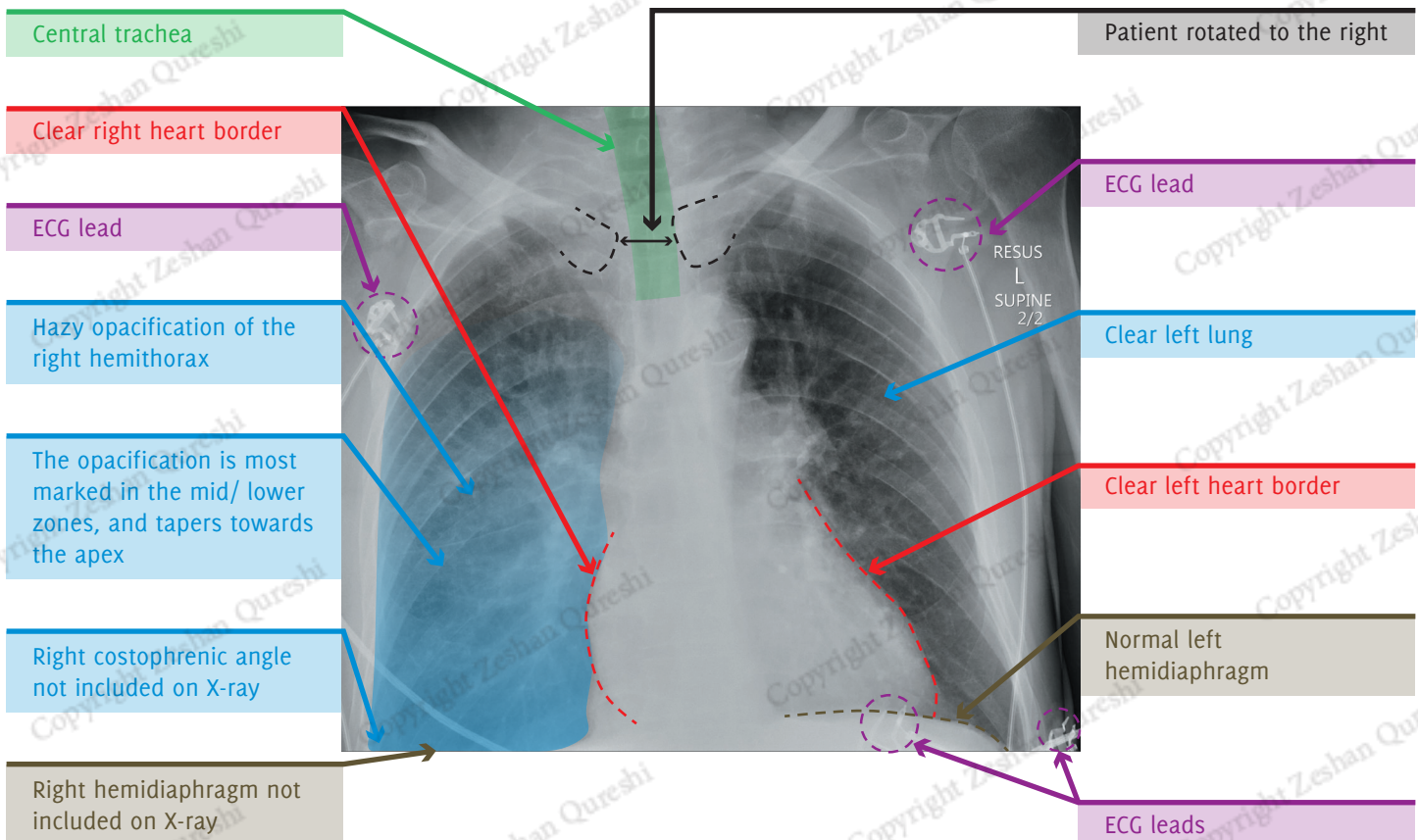
Lung Apices: Normal

Hila: Normal

Behind Heart: Normal

Costophrenic Angles: Not included on the X-ray.

Below the Diaphragm: Normal



SUMMARY, INVESTIGATIONS & MANAGEMENT

This X-ray demonstrates hazy opacification in the right hemithorax. The presence of normal bronchovascular markings indicates the abnormality is outside the lung parenchyma. Given the supine projection, these findings are in keeping with fluid layering dependently in the posterior pleural space (i.e. a moderate right-sided pleural effusion). The opacification is most marked in the mid/lower zones as this is the most dependent part of the posterior pleural space in the supine position.

In the context of trauma this effusion is likely to represent a haemothorax. There should be a high suspicion for underlying rib fractures even though none are visible on the X-ray. There is

no evidence of pneumothorax, although this can be difficult to identify on a supine X-ray.

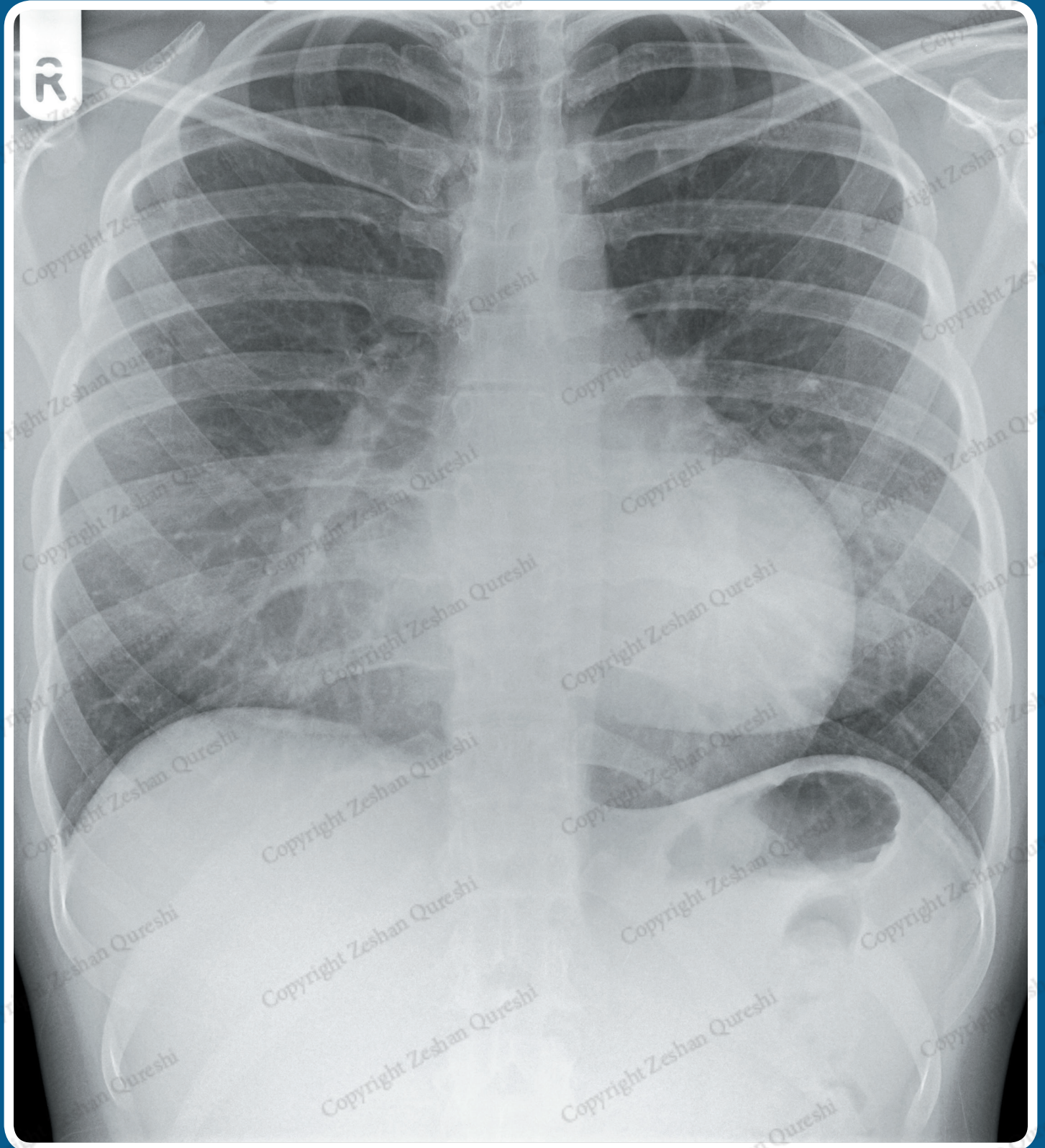
The patient needs to be assessed and resuscitated using the ATLS algorithm. Cardiothoracic surgery should be involved and a right sided chest drain will be required.

Imaging with contrast-enhanced CT will provide more accurate assessment of the thorax. Other parts of the body (head, cervical spine, abdomen or pelvis) can also be imaged with CT depending on the clinical assessment.



CASE 76

A 16 year old female presents to her GP with a chest wall deformity. There is no significant past medical history. She is a non-smoker. On examination, she has saturations of 100% in air and is afebrile. Her RR is 17 with a HR of 70 bpm. Lungs are resonant throughout, with good bilateral air entry. A chest X-ray is requested to assess for any bony abnormalities.



REPORT – PECTUS EXCAVATUM

Patient ID: Anonymous
Projection: PA
Penetration: Adequate – vertebral bodies just visible behind heart
Inspiration: Adequate – 8 anterior ribs visible
Rotation: Not rotated

AIRWAY

The trachea is central.

BREATHING

There is heterogeneous airspace opacification medially in the right lower zone. The lungs are otherwise clear.

The lungs are not hyperinflated.

The pleural spaces are clear.

Normal pulmonary vascularity.

CIRCULATION

The heart is not enlarged.

The right heart border is difficult to identify as it is projected over the vertebral column and appears indistinct. The left heart border is clear.

The mediastinum is central, not widened, with clear borders.

Normal size, shape, and position of both hila.

DIAPHRAGM + DELICATES

Normal appearance and position of the hemidiaphragms.

No pneumoperitoneum.

The ribs are abnormally orientated – their posterior aspects are horizontally

orientated while anteriorly they are nearly vertical. No fractures or other bony changes.

The visible soft tissues are unremarkable.

EXTRAS + REVIEW AREAS

No vascular lines, tubes, or surgical clips.

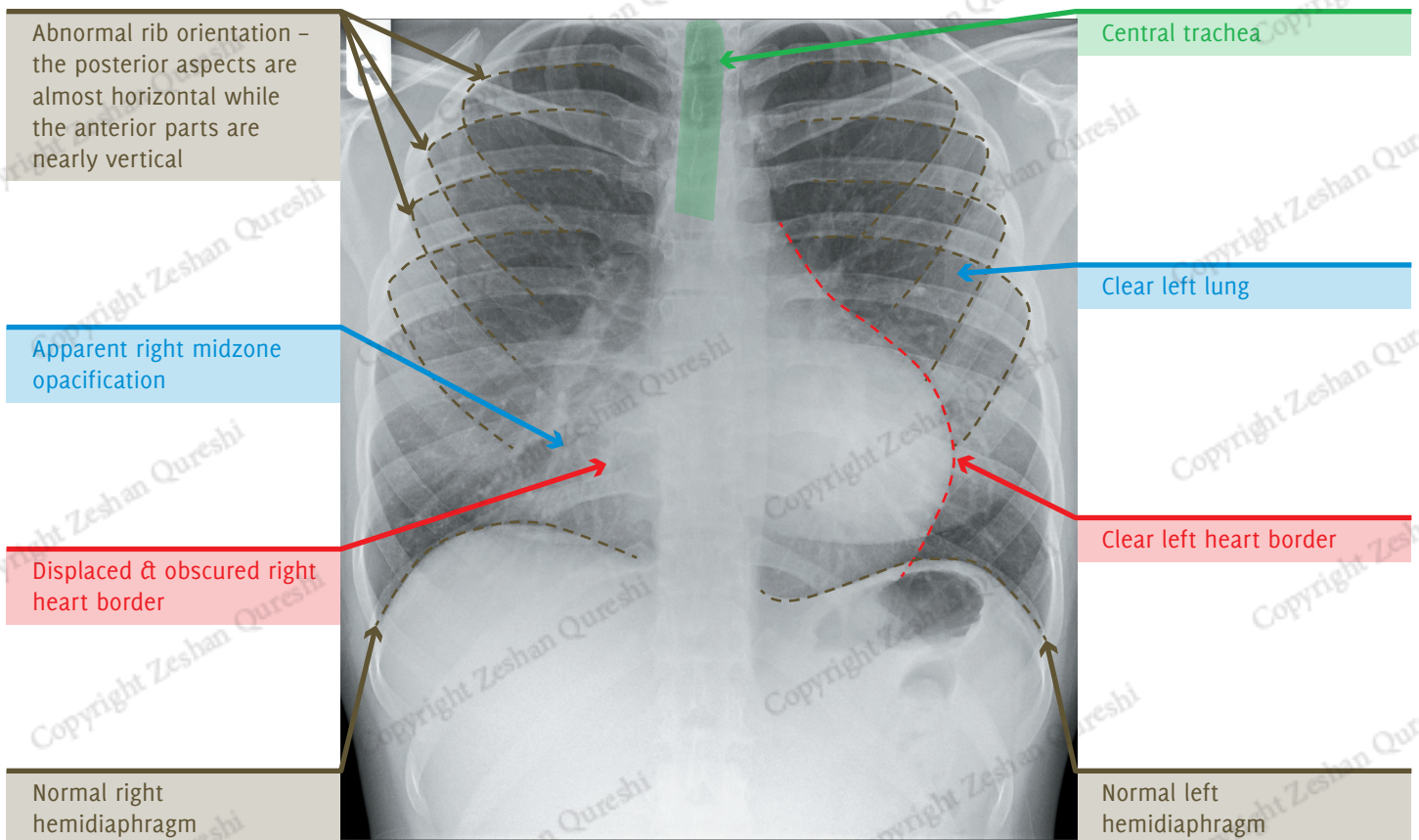
Lung Apices: Normal

Hila: Normal

Behind Heart: Obscured right heart border

Costophrenic Angles: Normal

Below the Diaphragm: Normal



SUMMARY, INVESTIGATIONS & MANAGEMENT

This X-ray demonstrates an indistinct right heart border with adjacent opacification. This may represent right middle lobe consolidation or collapse. However in combination with the abnormal rib orientation and clinical history of chest wall deformity, the appearances are consistent with pectus excavatum.

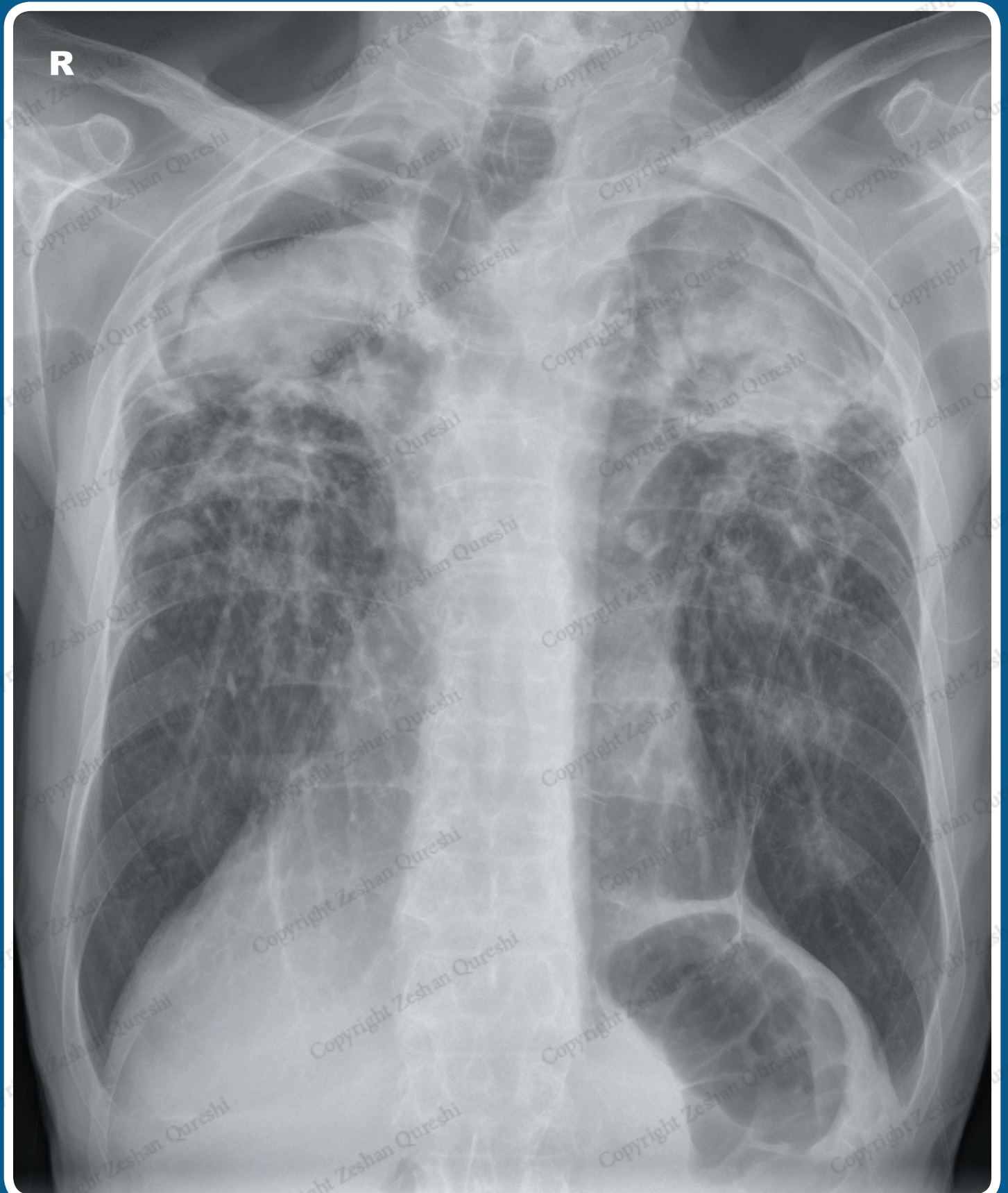Further management will depend on the effects of the chest wall deformity. No further assessment or treatment may be required. Pulmonary function tests and an ECHO can be performed to assess any pulmonary and/or cardiovascular compromise. The patient should be referred to cardiothoracics

if surgery is contemplated. A CT of the chest may be required to assess the underlying anatomy pre-surgery.



CASE 77

A 40 year old male presents to ED with recurrent episodes of haemoptysis. He is an ex-intravenous drug user and has a 20 pack year smoking history. On examination, he has saturations of 90% in air and is afebrile. His RR is 20 with a HR of 80 bpm. There are crackles and wheeze in the upper zones of both lungs. A chest X-ray is requested to assess for possible pneumonia, tuberculosis, malignancy or COPD.



REPORT – UPPER ZONE FIBROSIS WITH MYCETOMAS

Patient ID: Anonymous
Projection: PA
Penetration: Adequate – vertebral bodies just visible behind heart
Inspiration: Adequate – 7 anterior ribs visible
Rotation: The patient is not rotated

AIRWAY

The upper trachea is central. The mid trachea is deviated to the right in keeping with right upper zone volume loss.

BREATHING

There are bilateral upper and mid zone abnormalities with coarsened bronchovascular lung markings. There is increased lucency at the apices, in keeping with cavitation. In addition there are rounded/ovoid soft tissue density masses in both apices. These are outlined by thin crescents of air. There is pleural thickening

at both apices. The lower zones are unremarkable.

The lungs are not hyperinflated.

CIRCULATION

The heart is not enlarged.

The heart borders are clear.

The aorta is difficult to identify.

The mediastinum is central and not widened. Its upper borders are difficult to identify.

Both hila are markedly elevated indicating bilateral upper zone volume loss.

DIAPHRAGM + DELICATES

The medial aspect of the right hemidiaphragm is obscured by an epicardial

fat pad. Normal appearance and position of the left hemidiaphragm.

No pneumoperitoneum.

The imaged skeleton is intact with no fractures or destructive bony lesions visible. In particular there are no bony changes associated with previous radiotherapy.

The visible soft tissues are unremarkable.

EXTRAS + REVIEW AREAS

No vascular lines, tubes, or surgical clips.

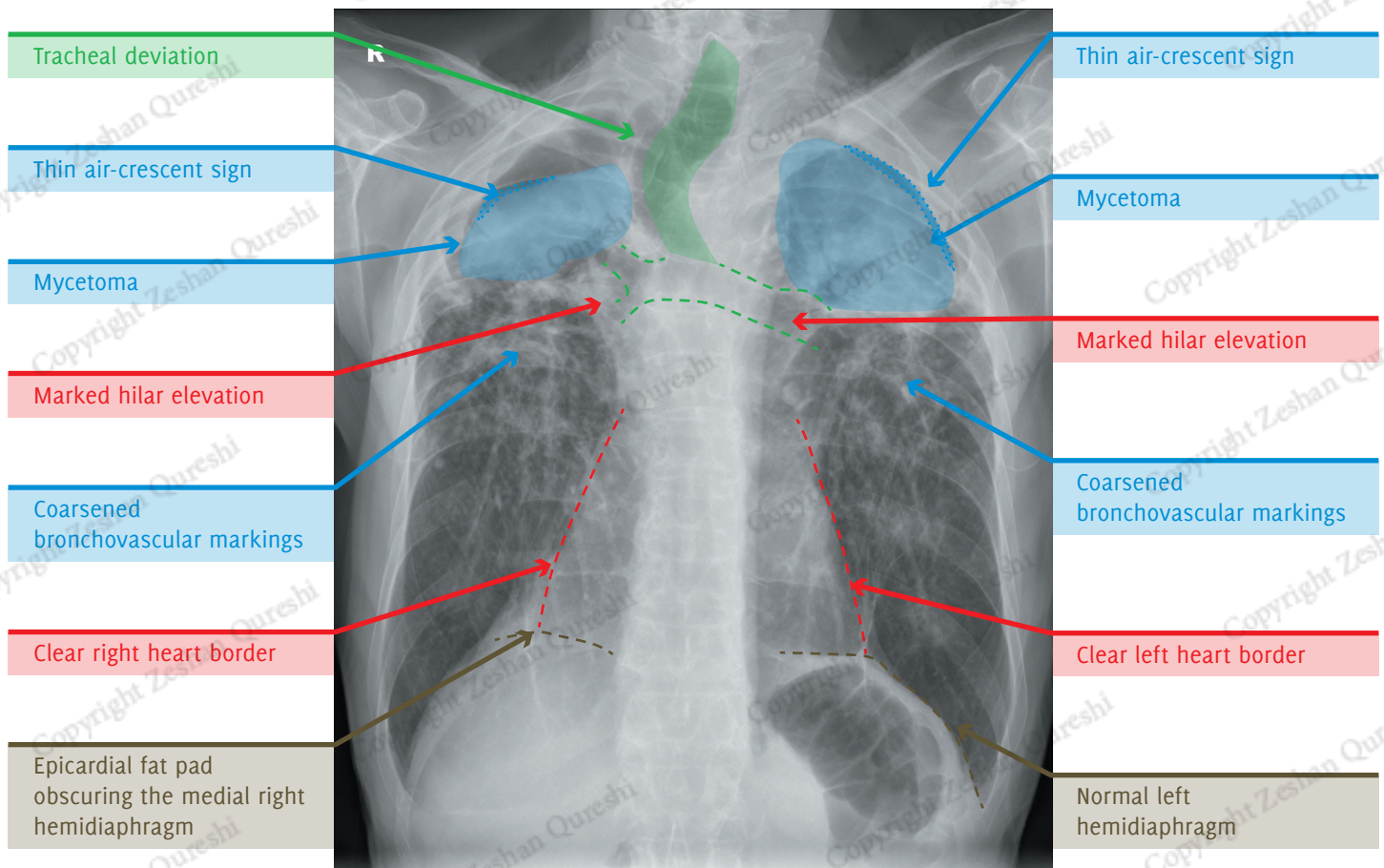
Lung Apices: Bilateral apical cavities with soft tissue masses

Hila: Bilateral elevation of the hila

Behind Heart: Normal

Costophrenic Angles: Normal

Below the Diaphragm: Normal



SUMMARY, INVESTIGATIONS & MANAGEMENT

This X-ray demonstrates bilateral upper zone fibrosis with large apical cavities. There are also bilateral apical soft tissue masses with air-crescent signs, in keeping with mycetomas.

The differential diagnosis for upper lobe fibrosis includes old TB, pneumoconiosis, ankylosing spondylitis, previous radiotherapy and sarcoidosis. Given the patient's background and the large cavities, TB is the most likely cause.

Supplementary oxygen should be given. Initial blood tests may include FBC, U/Es, and CRP. Sputum cultures should be obtained. An arterial blood gas may also be helpful.

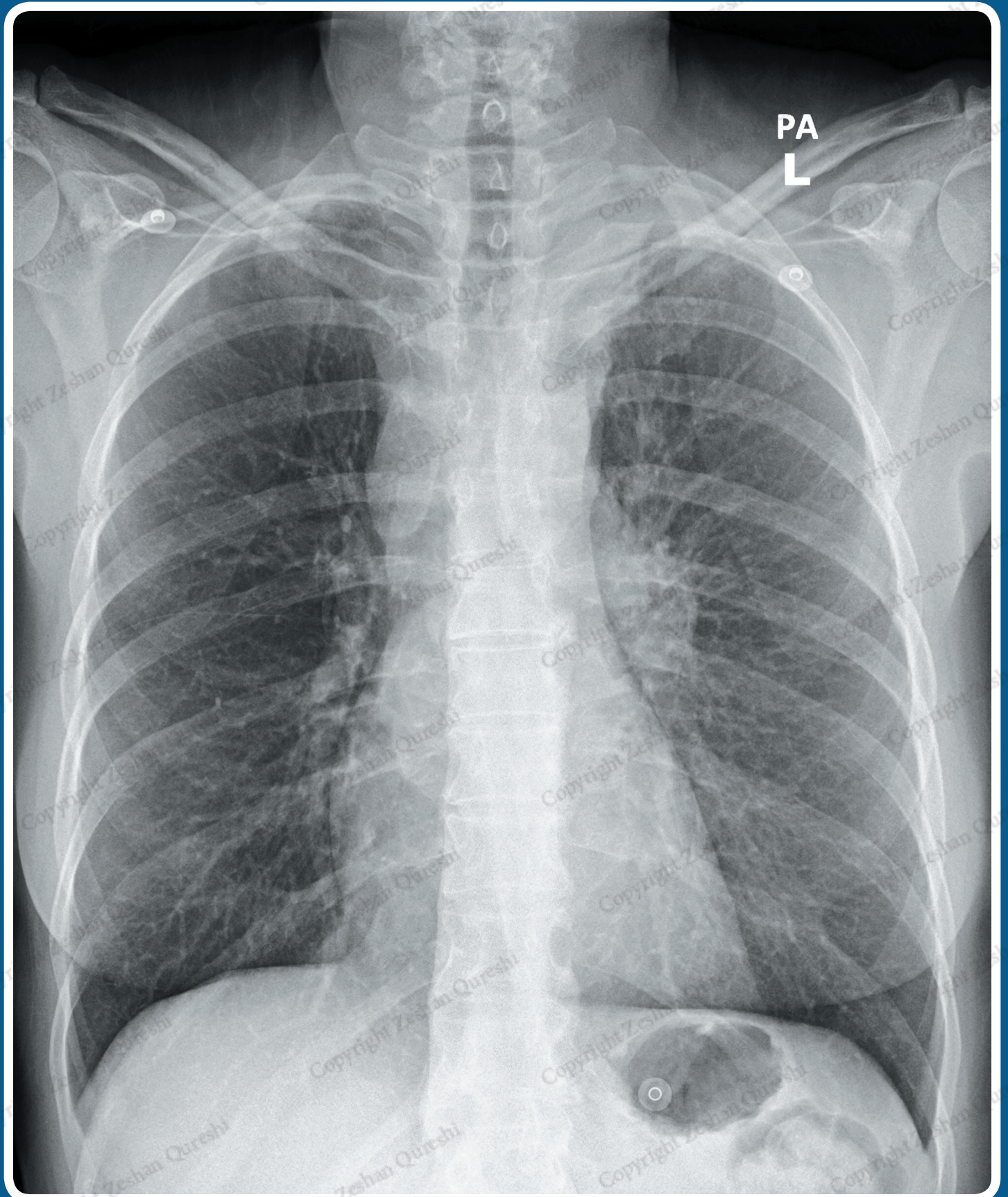
Appropriate antibiotic/antifungal therapy should be considered following discussion with respiratory and microbiology, bearing in mind that old TB does not require active treatment.

Comparison with previous imaging would be useful to assess for progression of changes. A high resolution CT (HRCT) of the chest would provide more detailed assessment if required. Input from the respiratory team would be helpful to guide further management.



CASE 91

A 68 year old female presents to her GP with unintentional weight loss. She has a 50 pack year smoking history. On examination, she has saturations of 100% in air and is afebrile. Lungs are resonant throughout with good bilateral air entry. There is a left-sided Horner's syndrome. A chest X-ray is requested to assess for possible malignancy.



REPORT – LUNG MASS AND MEDIASTINAL LYMPHADENOPATHY

Patient ID: Anonymous
Projection: PA
Penetration: Adequate – vertebral bodies just visible behind heart
Inspiration: Adequate – 8 anterior ribs visible
Rotation: Not rotated

AIRWAY

The trachea is central.

BREATHING

There is asymmetry of the lung apices with increased density in the left apex. A subtle lace-like opacification in the left lung is present, in keeping with interstitial opacification.

The right lung is clear.

The lungs are not hyperinflated. There is coarsening of the bronchovascular markings, in keeping with COPD.

The pleural spaces are clear.

CIRCULATION

The heart is not enlarged.

The heart borders are clear. There is a well-defined, lobulated mass projected over the right side of the cardiac silhouette, which is separate to the right hilum.

The aorta appears normal.

There is widening of the right paratracheal stripe. The mediastinum has clear borders.

Normal size, shape, and position of right hila. The left hilum is enlarged and dense, consistent with lymph node enlargement.

DIAPHRAGM + DELICATES

Normal appearance and position of the hemidiaphragms.

No pneumoperitoneum.

The imaged skeleton is intact with no fractures or destructive bony lesions visible. In particular, the left 1st and 2nd ribs appear intact.

The visible soft tissues are unremarkable.

EXTRAS + REVIEW AREAS

ECG electrodes in situ.

No vascular lines, tubes, or surgical clips.

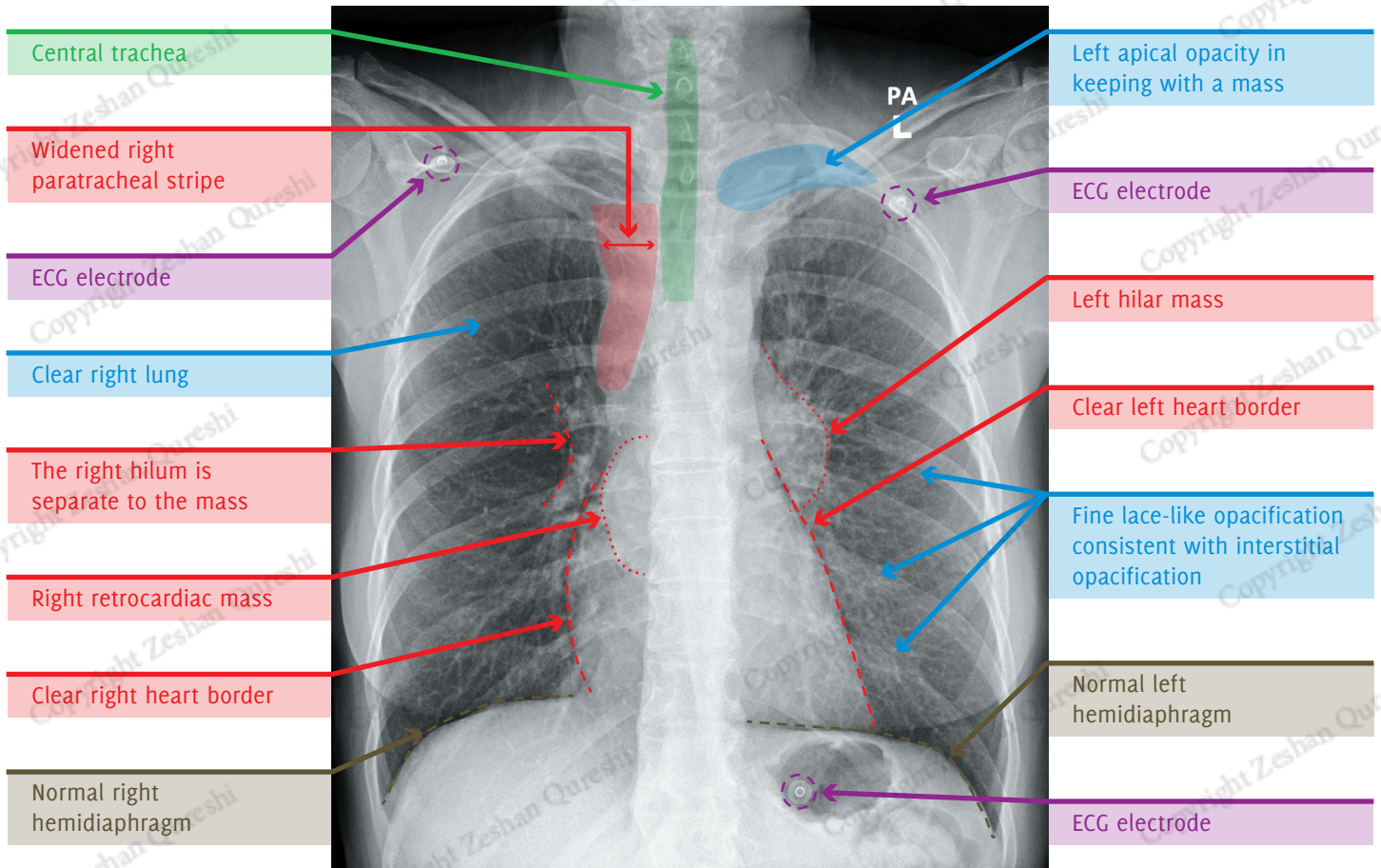
Lung Apices: Left apical mass

Hila: Enlarged, dense left hilum

Behind Heart: Right retrocardiac mass

Costophrenic Angles: Normal

Below the Diaphragm: Normal



SUMMARY, INVESTIGATIONS & MANAGEMENT

The X-ray demonstrates a left apical mass, which is likely accounting for the Horner's syndrome. There is evidence of mediastinal lymph node enlargement (widened right paratracheal stripe, dense left hilum and right retrocardiac mass). The interstitial opacification in the left lung probably represents malignant spread via the lymphatics (lymphangitis carcinomatosa).

Initial blood tests may include FBC, U/Es, LFTs and bone profile.

A staging CT chest and abdomen with IV contrast should be performed.

The patient should be referred to respiratory/oncology services for further management, which may include biopsy and MDT discussion. Treatment, which may include surgery, radiotherapy, chemotherapy, or palliative treatment, will depend on the outcome of the MDT discussion, investigations, and the patient's wishes.

CASE STUDY INDEX

CASE 1:	Right Upper Lobe Consolidation	13
CASE 2:	Pleural Effusion	15
CASE 3:	Lung and Hilar Masses	17
CASE 4:	Hiatus Hernia	19
CASE 5:	Pulmonary Oedema	21
CASE 6:	Right Lower Lobe Collapse	23
CASE 7:	Right Upper Lobe Collapse	25
CASE 8:	Left Lower Zone Consolidation	27
CASE 9:	Left Upper Lobe Collapse	29
CASE 10:	Retrocardiac Mass	31
CASE 11:	Left Lower Lobe Consolidation	33
CASE 12:	Lingula Consolidation	35
CASE 13:	Swallowed Foreign Body	37
CASE 14:	Pneumoperitoneum	39
CASE 15:	Bilateral Consolidation	41
CASE 16:	Spontaneous Pneumothorax	43
CASE 17:	Right Lower Zone Consolidation	45
CASE 18:	Lines: Peripherally Inserted Central Catheter (Malpositioned)	47
CASE 19:	Right Middle and Lower Lobe Consolidation	49
CASE 20:	Pneumoperitoneum	51
CASE 21:	Pleural Effusion	53
CASE 22:	Lung Metastases	55
CASE 23:	Right Upper Lobe Consolidation	57
CASE 24:	Pleural Effusion	59
CASE 25:	Lung Mass	61
CASE 26:	Pleural Effusion	63
CASE 27:	Nasogastric Tube (Malpositioned)	65
CASE 28:	Latrogenic Pneumothorax	67
CASE 29:	Spontaneous Pneumothorax	69
CASE 30:	Latrogenic Pneumothorax	71
CASE 31:	Lung and Hilar Masses	73
CASE 32:	Right Upper Lobe Collapse	75
CASE 33:	Left Lower Lobe Collapse	77
CASE 34:	Retrocardiac Consolidation	81
CASE 35:	Right Middle Lobe Consolidation	83
CASE 36:	Peripherally Inserted Central Catheter (Malpositioned)	85
CASE 37:	Left Upper Lobe Collapse	87
CASE 38:	Hickman Line (Fractured)	89
CASE 39:	Dextrocardia	91
CASE 40:	Breast Prostheses	93
CASE 41:	Pneumonectomy	95
CASE 42:	Hydropneumothorax	97
CASE 43:	Vagus Nerve Stimulator	99
CASE 44:	Emphysema	101
CASE 45:	Aortic Dissection	103
CASE 46:	Elevated Right Hemidiaphragm	105
CASE 47:	Anterior Mediastinal Mass	107
CASE 48:	Pulmonary Contusions Plus Pneumothorax	109
CASE 49:	Clavicle Fracture	111
CASE 50:	Apical Pneumothorax	113
CASE 51:	Acute Respiratory Distress Syndrome	115
CASE 52:	Aortic Dissection	117
CASE 53:	Traumatic Pneumothoraces	119
CASE 54:	Lung Mass	121
CASE 55:	Ventriculo-Atrial Shunt	123
CASE 56:	Pulmonary Oedema	125

CASE 57: Surgical Emphysema	127
CASE 58: Miliary Nodules	129
CASE 59: Nasogastric Tube (Malpositioned)	131
CASE 60: Pacemaker Lead (Malpositioned)	133
CASE 61: Endotracheal Tube, Internal Jugular Line and Nasogastric Tube	135
CASE 62: Lung Abscess	137
CASE 63: Traumatic Pneumothorax	139
CASE 64: Chilaiditi's Sign	141
CASE 65: Traumatic Pneumothorax	143
CASE 66: Humerus Fracture	145
CASE 67: Hiatus Hernia	147
CASE 68: Right Middle Lobe Consolidation	149
CASE 69: Calcified Pleural Plaques	151
CASE 70: Supine Pleural Effusion	155
CASE 71: Sarcoidosis	157
CASE 72: Double Lung Transplant	159
CASE 73: Hilar Lymphadenopathy	161
CASE 74: Pulmonary Oedema	163
CASE 75: Anterior Shoulder Dislocation	165
CASE 76: Pectus Excavatum	167
CASE 77: Upper Zone Fibrosis with Mycetomas	169
CASE 78: Liver Abscess	171
CASE 79: Pneumomediastinum	173
CASE 80: Anterior Mediastinal Mass	175
CASE 81: Ground Glass Opacification	177
CASE 82: Left Lower Lobe Consolidation and Pseudotumour	179
CASE 83: Lung Nodules	181
CASE 84: Azygous Lobe	183
CASE 85: Lung Mass Plus Rib Destruction	185
CASE 86: Destructive Scapular Lesion	187
CASE 87: Retained Surgical Swab	189
CASE 88: Nipple Shadows	191
CASE 89: Pleural Mass	193
CASE 90: Rib Metastases	195
CASE 91: Lung Mass and Mediastinal Lymphadenopathy	197
CASE 92: Right Middle Lobe Collapse	199
CASE 93: Apical Lung Mass	201
CASE 94: Loculated Pleural Collection	203
CASE 95: Left Atrial Enlargement	205
CASE 96: Sclerotic Bone Metastases	207
CASE 97: Sickle Cell Anaemia	209
CASE 98: Calcified Left Ventricular Aneurysm	211
CASE 99: Hiatus Hernia	213
CASE 100: Mesothelioma	215

The Unofficial Guide to Radiology: 100 Practice Chest X-Rays

Despite its universal importance, X-ray interpretation is often an overlooked subject in the medical school curriculum, making it difficult and daunting for many medical students and junior doctors. The key to interpreting X-rays is having a systematic method for assessment, and then getting lots of practice looking at and presenting X-rays. The best-selling core radiology text *The Unofficial Guide to Radiology* received recognition from the British Medical Association, the British Institute of Radiology and the Royal College of Radiologists for its unique approach to teaching. This follow-up textbook builds upon these foundations, providing readers with the opportunity to practise and consolidate their chest X-ray assessment and presenting skills through 100 large, high quality real clinical cases (in line with the Royal College of Radiologists' Undergraduate Radiology Curriculum), with full reports, and on image colour annotations.

This book is suitable for:

- Medical students
- Nurses and nursing students
- Radiographers
- Junior doctors
- Physician's associates
- Radiologists




*This excellent book presents all the classic chest radiographs in a test-yourself format, with high definition images and a systematic ABCDE approach to reporting, based on its best-selling companion text *The Unofficial Guide to Radiology*. Most importantly, the clarity of the on-image labelling gives immediate feedback, enabling the reader to make sense of each radiograph. I wish I'd had a copy when I was a medical student.*

Bob Clarke, Director, Ask Doctor Clarke Ltd.

Like the other successful books in the Unofficial Guide series, this book builds on real clinical cases that you are likely to encounter during your undergraduate training. Each image is presented clearly with the relevant anatomical features and abnormalities highlighted clearly and set in the context of the pathophysiology. I'm sure that those who read this book will never be left standing in silence at the dreaded radiology OSCE station!

Professor Simon Maxwell, Professor of Student Learning, University of Edinburgh



What I like about the book is the way in which 100 chest X-rays are systematically annotated to highlight all the features that need to be taken into account and reports are also included. I think this will be a really useful book for students and early stage trainees, as well as for doctors who are revising for exams or simply want to practice interpreting X-ray findings.

Professor Judy McKimm, Professor of Medical Education and Director of Strategic Educational Development, Swansea University School of Medicine

This is probably the easiest way of learning the basics of chest X-ray interpretation. An excellent introduction for the beginner and a superb way of revising the subject for those of us who are rather rusty.

Dr David Wilson, President of the British Institute of Radiology



ISBN 978-1-910399-01-9



RRP £19.99 / \$29.99

Join Our Medical Book Writing Project (details inside)

