

Horizontal relations

Horizontal jaw relations: The relationship of mandible to maxilla in a horizontal plane (in anteroposterior and side to side direction).

The horizontal relations include:

1- Centric jaw relation.

2- Eccentric jaw relations. A. Protrusive or forward relation.

B. Left or right lateral relation.

Centric jaw relation: It is the maxilla-mandibular relationship in which both condyles articulate with the thinnest avascular portion of their respective disks with the complex in the anterior-superior position against the shapes of the articular eminencies.

This position is clinically discernible when the mandible is directed superior and anteriorly, and from which the individual can make lateral movements at a given vertical dimension. It is restricted to a purely rotary movement about the transverse horizontal axis.

It is a clinically determined relationship of the mandible to the maxilla when the condyle disk assemblies are positioned in their most superior position in the mandibular fossae and against the distal slope of the articular eminence (*it is bone-to-bone relationship*). This position is independent of tooth contact.

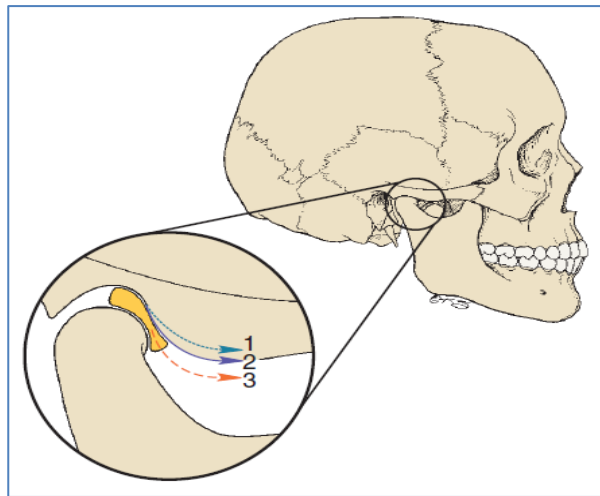
Centric occlusion: It is the occlusion of opposing teeth when the mandible is in centric relation.

Maximal intercuspal position: The most complete interdigitation of the teeth independent of condylar position. Hence maximal intercuspation is a maxilla-mandibular relationship determined by *tooth-to-tooth relationship*.

Importance of centric relation

- 1- It is a reference position.
- 2- It is learnable, repeatable and recordable position.
- 3- It is the start point for developing occlusion.
- 4- Functional movement like chewing and swallowing are performed in this position.
- 5- It is a reliable jaw relation, because it is bone to bone relation.

Centric jaw relation and centric occlusion. (Note the "condyle" and "condyle disk assembly" in relation to the mandibular fossa and distal slope of articular eminence).



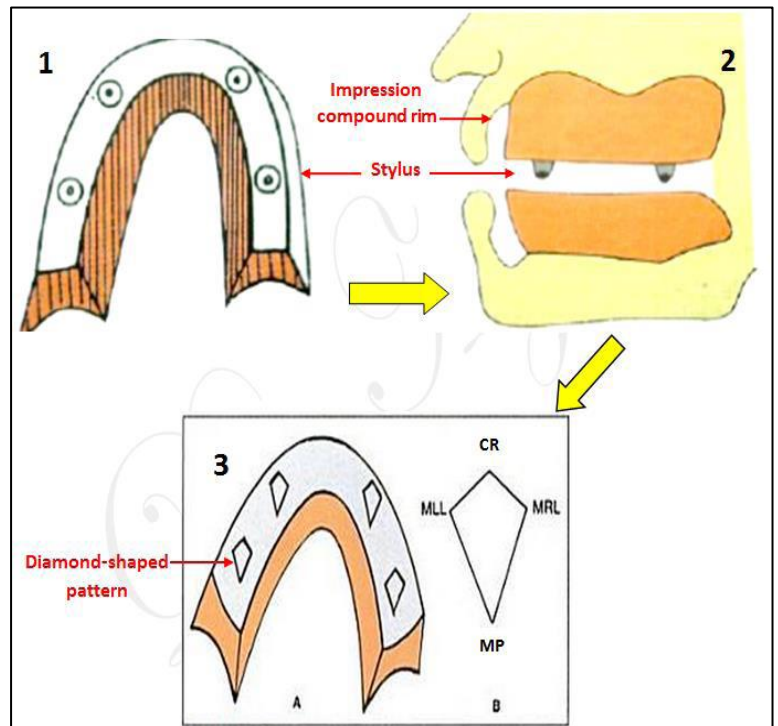
Methods of recording centric relation

- 1- Functional (chew-in) methods.
- 2- Graphic method.
- 3- Physiological (Tactile or inter occlusal check record) method.

1- Functional methods:

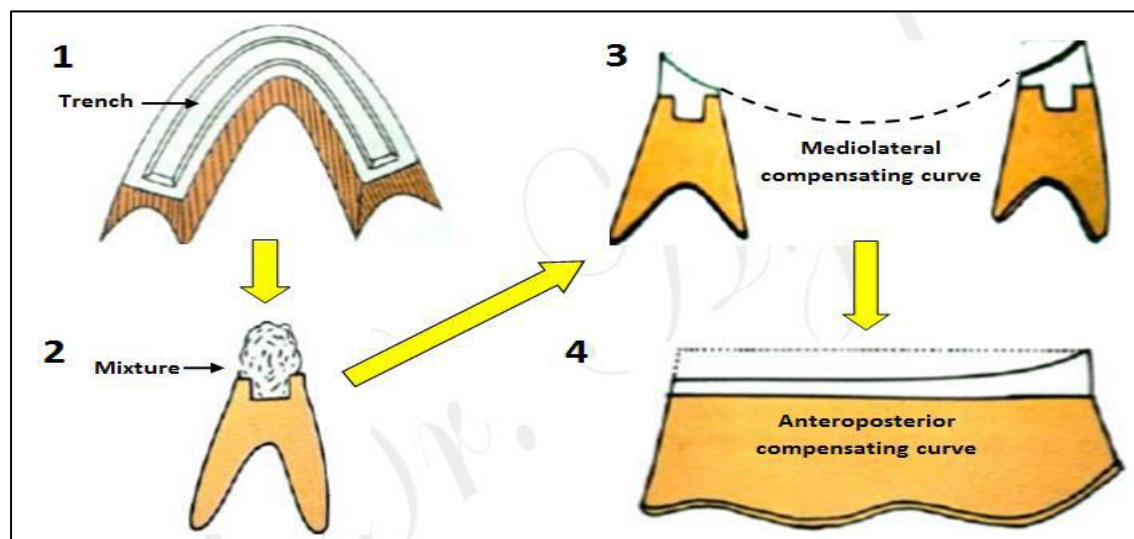
A- Needles-House technique: This method used impression compound occlusion rims with four metal styli placed in the maxillary rim. When the patient moves his mandible, the styli on the maxillary rim will create a marking on the mandibular rim, after all mandibular movements are made, and a diamond-shaped pattern is formed. The anterior most point of this diamond pattern indicates the centric jaw relation.

1. Maxillary rim made from impression compound with four metal styli inserted.
2. Recording the mandibular movements.
3. Diamond-shaped marking made on the mandibular rim. (MP maximum protrusion, MLL maximum left lateral, MRL maximum right lateral, CR centric relation).

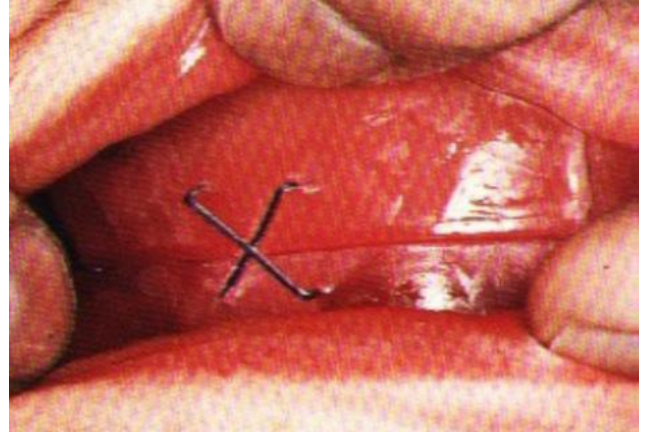


B- Patterson technique

This method used wax occlusion rims. A trench is made along the length of mandibular rim. A 1:1 mixture of pumice and dental plaster is loaded into the trench. When the patient moves his mandible, compensating curves on the mixture will be produced, and the height of the mixture is also reduced. The patient is asked to continue these movements till a predetermined vertical dimension is obtained. Finally the patient is asked to retracted his jaw and the occlusal rims are fixed in this position with metal staples.



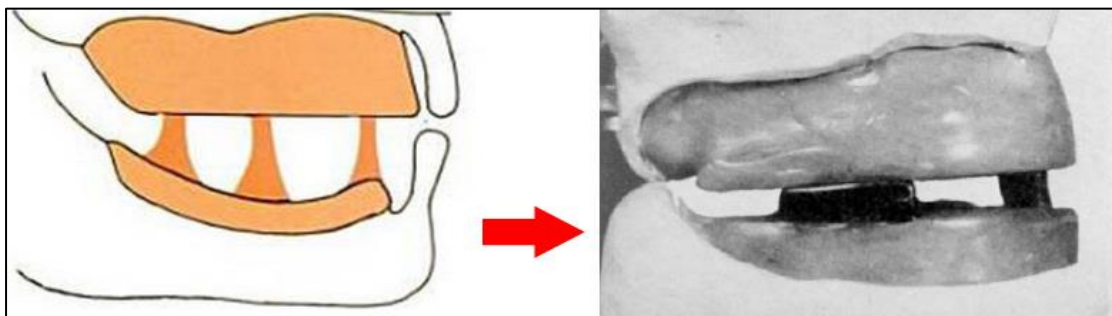
1. Trench made in mandibular rim.
2. Mixture of pumice and dental plaster loaded on the trench.
3. Mediolateral compensating curve generated on the mixture.
4. Anteroposterior compensating curve generated on the mixture.



The disadvantages of functional methods involve lateral and anteroposterior displacement of the recording bases in relation to the supporting bone while the record is being made.

C- Swallowing technique

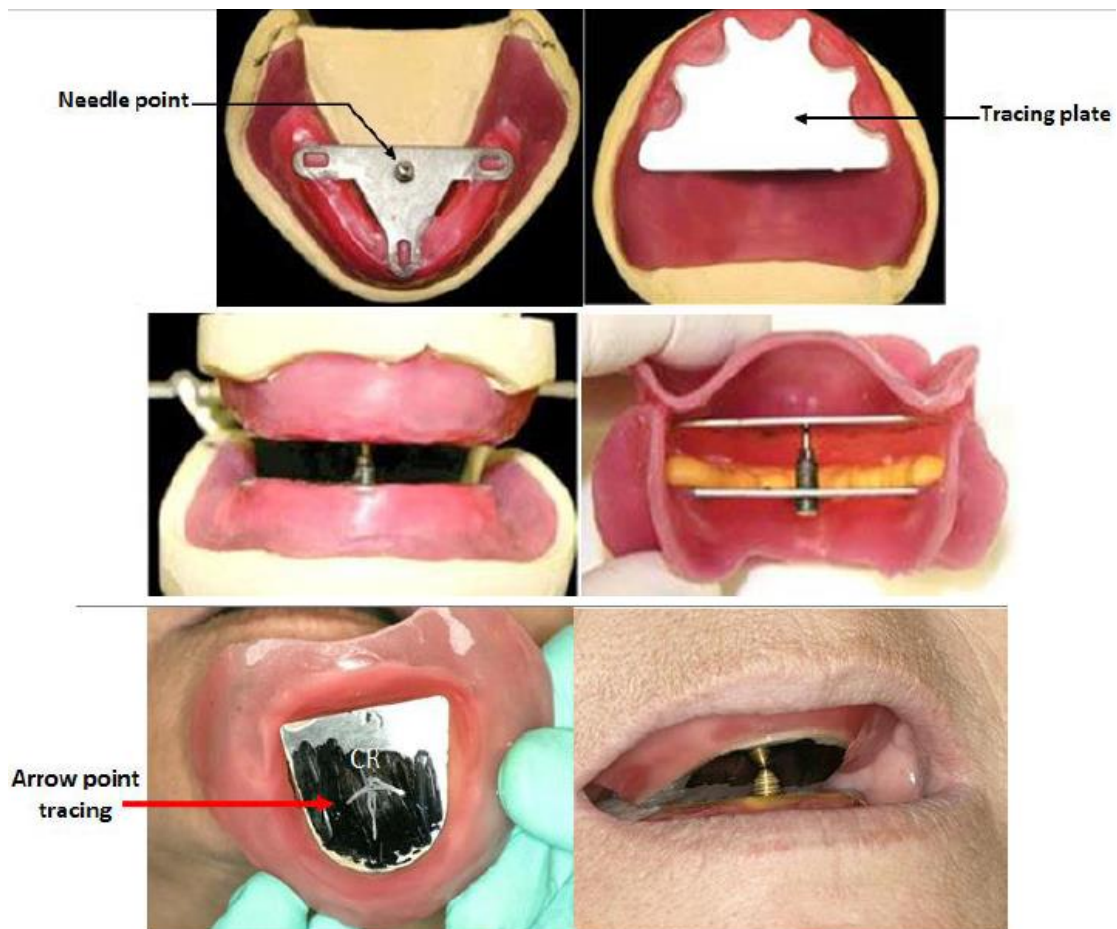
In this method, soft cones of wax are placed on the lower record base. The wax cones contact the upper occlusion rim when the patient swallows. This procedure is supposed to establish both proper vertical and horizontal relation of mandible to maxilla.



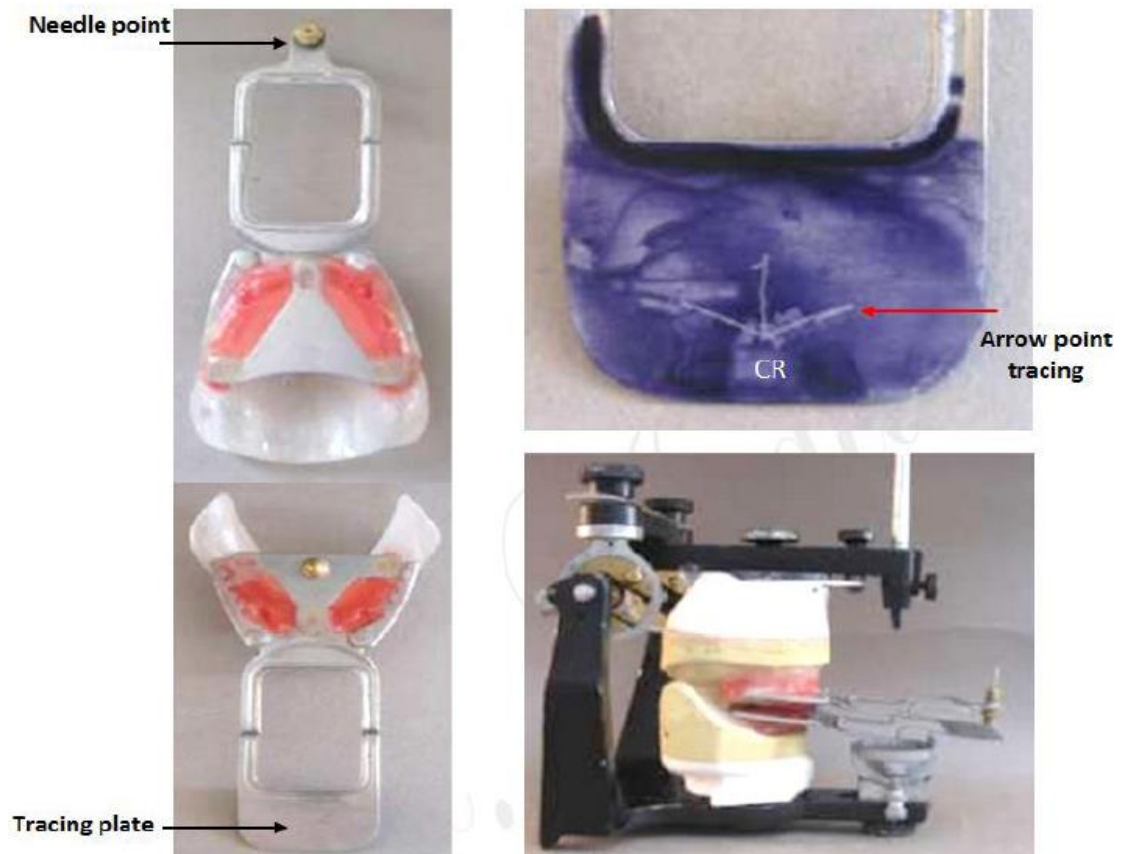
2- Graphic methods

These methods are called so because they use graphs or tracing to record the centric relation. The general concept of this technique is that a pen-like pointer is attached to one occlusal rim and a recording plate is placed on the other rim, the plate coated with carbon or wax on which the needle point can make the tracing, when the mandible moves in horizontal plane, the pointer draws characteristic patterns on the recording plate. The characteristic patterns created on the recording plate is called

arrow point tracing, also known as *Gothic arch tracing*. The apex of the arrow point tracing gives the centric relation, with the two sides of the tracing originating at that point being the limits of the lateral movements. The apex of the arrow head should be sharp else the tracing is incorrect. The graphic methods are either *intraoral* or *extraoral* depending upon the placement of the recording device. The extraoral is preferable to the intraoral tracing, because the extraoral is more accurate, more visible, and larger in comparing with the intraoral tracing.



* When the needle point attached to the mandibular record base, the shape of the arrow point tracing appears on the maxillary recording plate as the apex of the arrow point tracing (*centric relation*) *posteriorly*; usually in the intraoral method; while in the extraoral method when the plate attached to the mandibular occlusion rim the tracing appears as the apex of the arrow point tracing (*centric relation*) *anteriorly*.



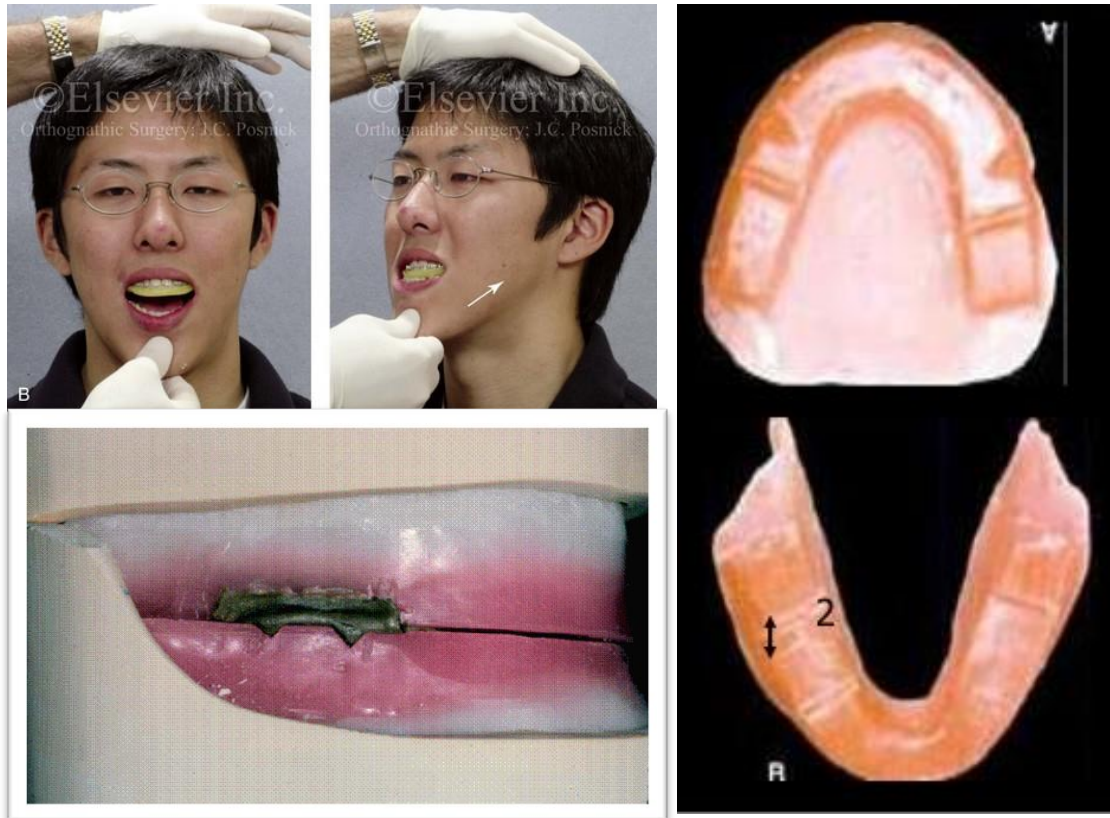
3- Tactile or inter occlusal check record method

In this method the centric relation is recorded by placing a record medium between the record bases when the jaws positioned at centric relation. The patient closes into the recording medium with the lower jaw in its most retruded unstrained position and stops the closure at predetermined vertical dimension. This method is simple, because mechanical devices are not used in the patient mouth and are not attached to the occlusion rims. This method has advantage of causing minimal displacement of the recording bases in relation to the supporting bone. This method is essential in making an accurate record, the visual acuity and the sense of touch of the dentist also inter in making of centric relation record, this phase is developed with experience and it is difficult to teach to another individual.

Materials that are commonly used for **inter occlusal check record**: wax, plaster, zinc oxide eugenol, silicon and polyether.

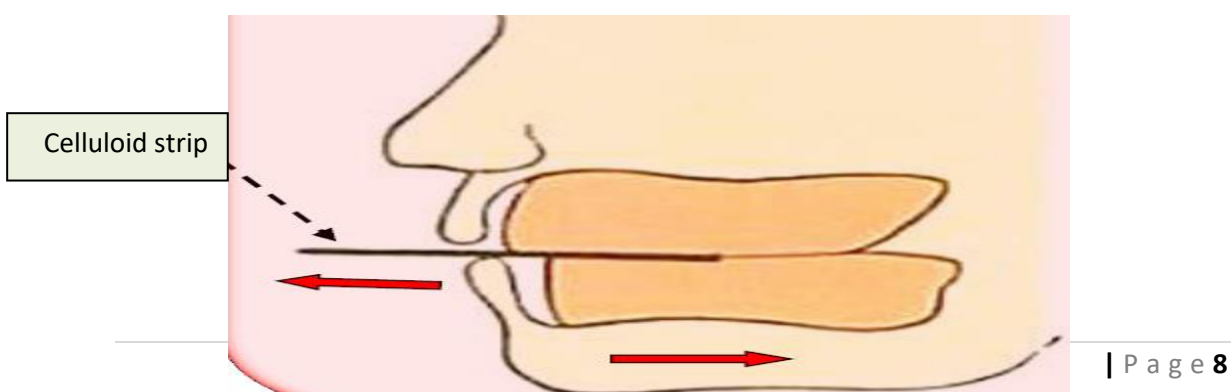
Indication of inter occlusal check record method:

- 1- Abnormally related jaws. 2- Displaceable, flabby tissue.
- 3- Large tongue. 4- Un controllable mandibular movements.
- 5- It can do for patients already using a complete denture.

**Methods for assisting the patient retruded the mandible:**

1. The patient is instructed to let his jaw relax (palpate the temporalis and masseter muscles to relax them), pull it back and close slowly on the back teeth.
2. The patient is instructed to get the feeling of pushing his upper jaw out and then close the mouth with back teeth in contact.
3. Assist the patient to protrude and retrude the mandible repeatedly with the operator holding the finger lightly against the chin.

4. **Boo's series of stretch exercise:** The patient is instructed to:
- a- Open the mouth wide and relax.
 - b- Move the jaw to the left and relax.
 - c- Move the jaw to the right and relax.
 - d- Move the jaw forward and relax, in series of movements. The results to be expected are for the patient to be able to follow the dentist's directions in moving the jaw to centric relation and the desired eccentric positions.
5. The patient is told to swallow and conclude the act with the occlusal rims in contact. However, the person can swallow when the mandible is not completely retruded. This method must be verified by other technique.
6. The patient can be instructed to turn the tongue towards the posterior border of the upper record base and close the rims together until they meet. The disadvantage with this method is the likelihood of displacing the mandibular record base by the action of the elevated tongue.
7. Tilt the patient head back, the tension of muscles under chin make protrusion more difficult.
8. Exert pressure in molars in both sides and ask the patient to close (molar reflex method).
9. Celluloid strip is placed between the rims and pulled out. Ask the patient to restrain the strip from slipping away; the mandible involuntarily goes to centric relation.



Eccentric jaw relations:

It is defined as any relation-ship of the mandible to the maxilla other than the centric relation. It includes **Protrusive, left and right lateral** relations. The main reason in making an eccentric jaw relation record is to adjust the horizontal and lateral condylar inclination in the adjustable articulator, and to establish the balanced occlusion. The protrusive and left and right lateral movements records are made in the same manner as for centric relation record and these include:

1. **Functional or chew in methods.**
2. **Graphic methods.**
3. **Physiological (tactile or inter-occlusal check record) methods.**


The interocclusal eccentric records may be made either on the occlusion rim before the teeth are set up or on the posterior teeth at the try-in appointment. When the protrusive eccentric record is made on Hanau articulator, the following formula is used to obtain an acceptable lateral inclination: **$L=H/8+12$**

L= lateral condylar inclination.

H= horizontal condylar inclination as established by protrusive record.

Factors to be considered while making eccentric jaw relation

1. The condylar path of the patient cannot be altered.
2. The condyles do not travel in straight lines during eccentric mandibular jaw movements.
3. Semi-adjustable articulators in which the condyles travel on a flat path cannot be reproduced eccentric movements exactly.
4. Fully-adjustable articulators, where the condylar and incisal guidance are fabricated individually with acrylic, can travel in the path of the condyle using pantographic tracings.



S-shaped condylar guidance in comparison to a straight condylar track in an articulator.

