

# Acute and chronic rhinitis

Acute and chronic rhinitis

**Rhinitis:** This term refer to inflammation of the mucosa of the nasal fossae

Owing to the continuity of the mucosa of the nasal mucosa and that of the sinuses some degree of inflammation is often present in the latter at the same time so constituting a rhinosinusitis

When the inflammation of the sinus is primary or overshadows that of the nasal fossae the condition called sinusitis

# HEALTHY SINUS

# SINUSITIS

Frontal Sinus

Inflamed Sinus Lining

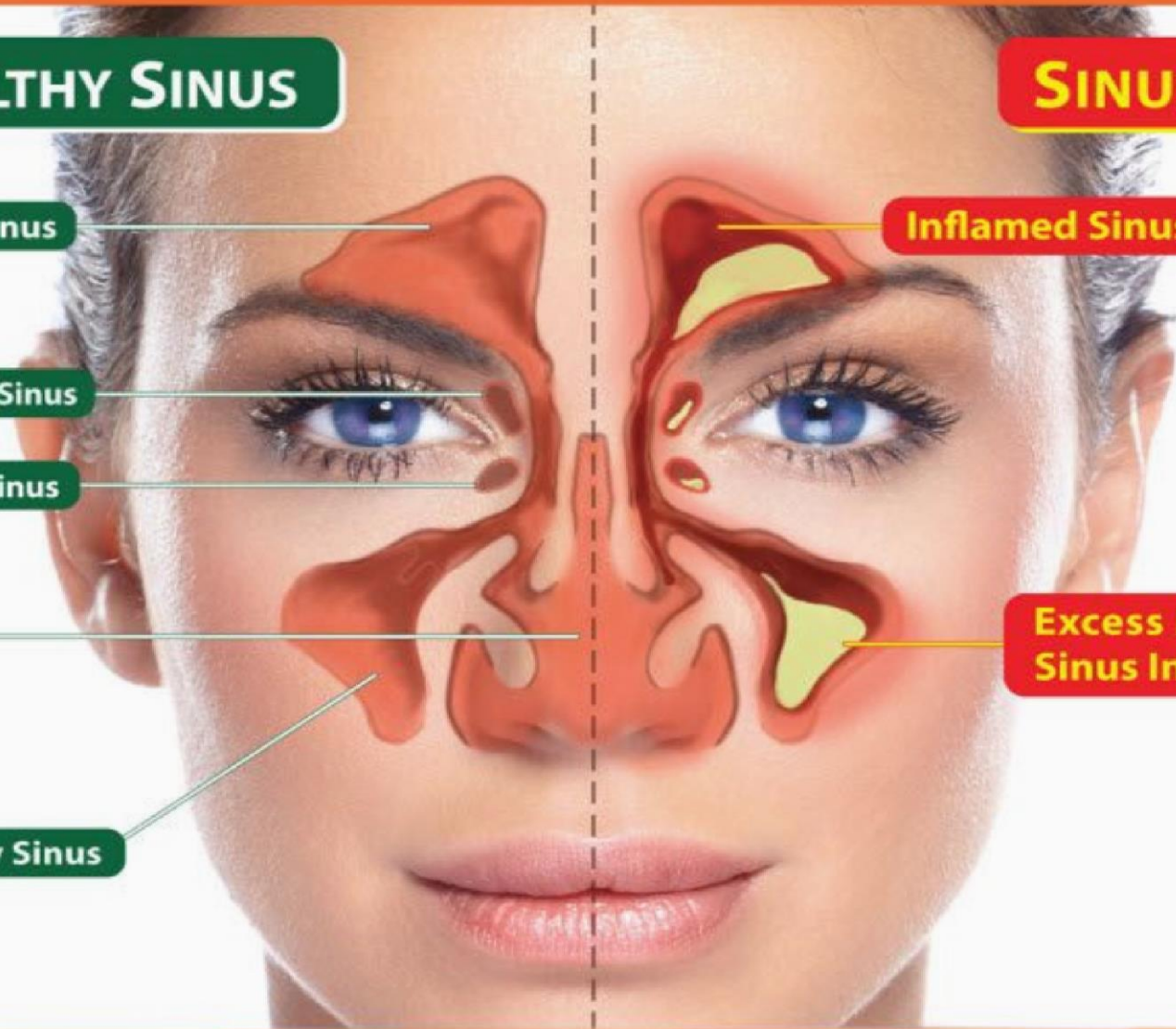
Sphenoid Sinus

Ethmoid Sinus

Excess Mucus/  
Sinus Infection

Septum

Maxillary Sinus

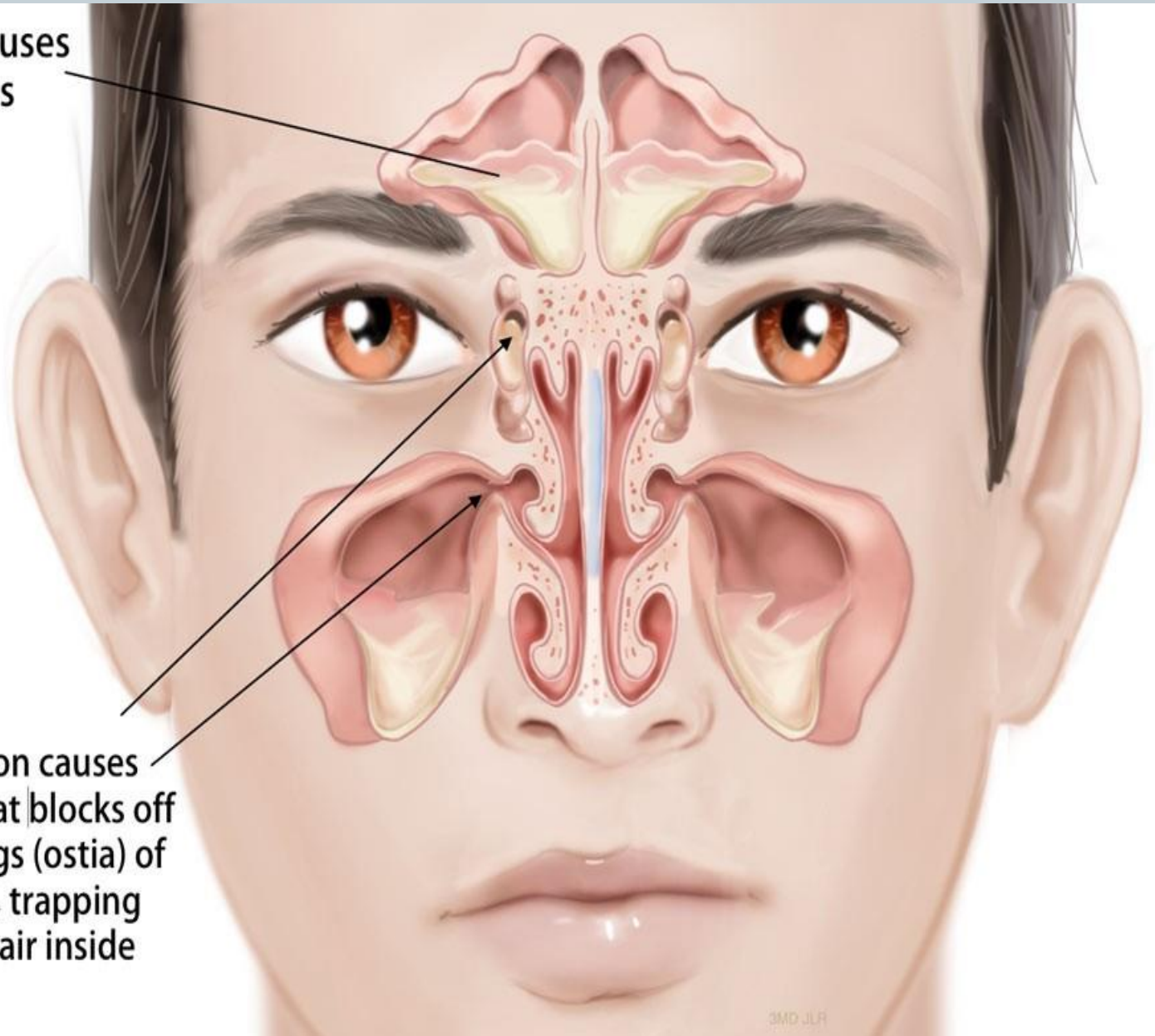


# 1. The common cold ( coryza )

## **Aetiology :**

A virus infection , which is conveyed by airborne droplet, usually complicated by secondary bacterial infection

Frontal sinuses  
with mucus



Inflammation causes  
swelling that blocks off  
the openings (ostia) of  
the sinuses, trapping  
mucus and air inside

# Pathology

Transient ischemia of the mucosa is followed by swelling, hyperemia and profuse secretion of clear seromucinous fluid. The rhinorrhoea becomes mucopurulent later owing to the rapid growth of the resident flora of the nose, which appear to be activated by the virus infection.

The organisms founds includes

Streptococcus haemolyticus

Pneumococcus

Staphylococcus

Haemophilus influenza

Klebsiella pneumoniae

Branhamella catarrhalis

The pathogenic respiratory viruses include:

1. influenza viruses

2. picorna viruses comprising :

. coxsackie virus

. reovirus

. ECHO virus

. rhinovirus ... most frequent cause of common cold

3. respiratory syncytial viruses ( bronchitis in children only )

4. para influenza viruses ( mainly in children )

5. Adenoviruses (mainly affecting pharynx)

## Clinical features

Vary greatly . four stages may distinguished :

1.*ischmia stages* . after an incubation period of 1-3 days , a burning sensation is experienced in the nasopharynx . the nasal mucosa irritate , sneezing occurs and the patient feels chilled ( shivering) . sense smell is altered or lost

2.*Hyeraemic stage* in a few hours , profuse rhinorrhoea and varying degrees of nasal obstruction ensue . pyrexia is common

3.*stage of secondary infection* . as secondary infection and leucocytic invasion occur , the discharge becomes yellow or green

4.*stage of resolution* : occurs in 5-10 days



## **Differential diagnosis**

- 1.allergic rhinitis and vasomotor rhinitis – rhinorrhoea spasmodic and the condition is a pyrexia . the discharge remains clear and contains excess of eosinophils
- 2.influenzal rhinitis in which the constitutional symptoms are much sever

## **Complications**

Secondary infection may spread throughout the mucosa and lymphatic tissue of the whole respiratory tract including the middle ear cleft .

## **Treatment**

**Prophylactic** : contact with known cases must be avoided .  
vaccines for prevention have not been widely effective

## **Therapeutic**

*General treatment* consist of

- . rest and warmth . ideally patient should stay in bed
- . analgesics . codeine . aspirin are of value
- . pseudo- ephedrine by mouth relieves congestion
- . antihistamine and vitamin c
- . antibiotic should be reserved for the treatment of secondary infective complications

## ***Local treatment***

consist of :

- . inhalation of steam comforting , Tinct. Benzoin Co or menthol may be added but it not essential
- . vasoconstrictors . in the form of drops or sprays give quick but temporary relief from the nasal obstruction . they should not abused

2. acute rhinitis associated with influenza and the exanthemata

This differs little from that of a common cold , except for the presence of the associated disease of which it is usually a prodromal features . it may however be very sever and even purulent . complications are apt to follow and may be serious

# Chronic rhinitis

## *1.non\_specific chronic infective rhinitis*

Several types are described

### **(a)simple chronic rhinitis**

#### **Etiology**

Attacks of acute rhinitis is rapid succession and the rapid maintenance of the acute inflammatory condition by one or more of the many predisposing and contributory factors these include :

- .neighboring infections such as : sinusitis , chronic tonsillitis , adenoids
- . vasomotor rhinitis . the resultant obstruction predispose to chronic infection
- . chronic irritation as from dust , smoke , tobacco , snuff and the abuse of therapeutic vasoconstrictors. Polluted atmosphere , as by overcrowding . sudden and extreme changes of the temperature . excessive dryness or humidity
- . nasal obstruction leading to retention of discharge e.g . deviation of the septum and intranasal adhesions
- . metabolic factors which includes imbalance of diet , as by excess of carbohydrate and by deficiency of vitamins . endocrine disorders , especially of the thyroid . lack of exercise and sunlight , alcoholic overindulgence , or gout .

# Pathology

.chronic hyperemia of the nasal mucosa accompanied by inflammatory cellular infiltration and sometimes chronic oedema

.swelling of inferior turbinate due to engorgement of the cavernous spaces ( sinusoids) in the submucosa , the epithelium tends to lose its cilia and the goblet cell increase .  
theses changes' are reversible

## Clinical features

- . nasal obstruction marked variable and usually alternate from side to side . on change of posture the dependent side blocks as the inferior turbinate swells
- . postnasal drip . a clear , viscid secretion trickles into the nasopharynx , to descend this tend to become mucopurulent as infection increase
- .nose –blowing
- .a blocked or heavy feeling in the nose .common , with mild headache and mental apathy
- . Transient anosmia

## Diagnosis

A history of recurrent attacks of acute rhinitis and the presence and of predisposing factors are suggestive .the soft swollen mucosa over the inferior turbinate pits with a probe and shrinks with 5% solution of cocaine . if morning sneezing is frequent the condition is likely to be associated with vasomotor rhinitis .

## Treatment

. general correction of any predisposing factors where possible e.g. tobacco . alcohol or contact with person suffering from cold change of habitat

. Local a slightly alkaline nasal douche used night and morning to remove sticky mucus

Mild vasoconstrictors used as sprays , paints or drops , usually of 1-2% ephedrine preparations to which as antibiotic may be added .such as treatment must not be prolonged .topical steroids as spray or drop will help in some cases

Treatment of any sinusitis or other adjacent infection



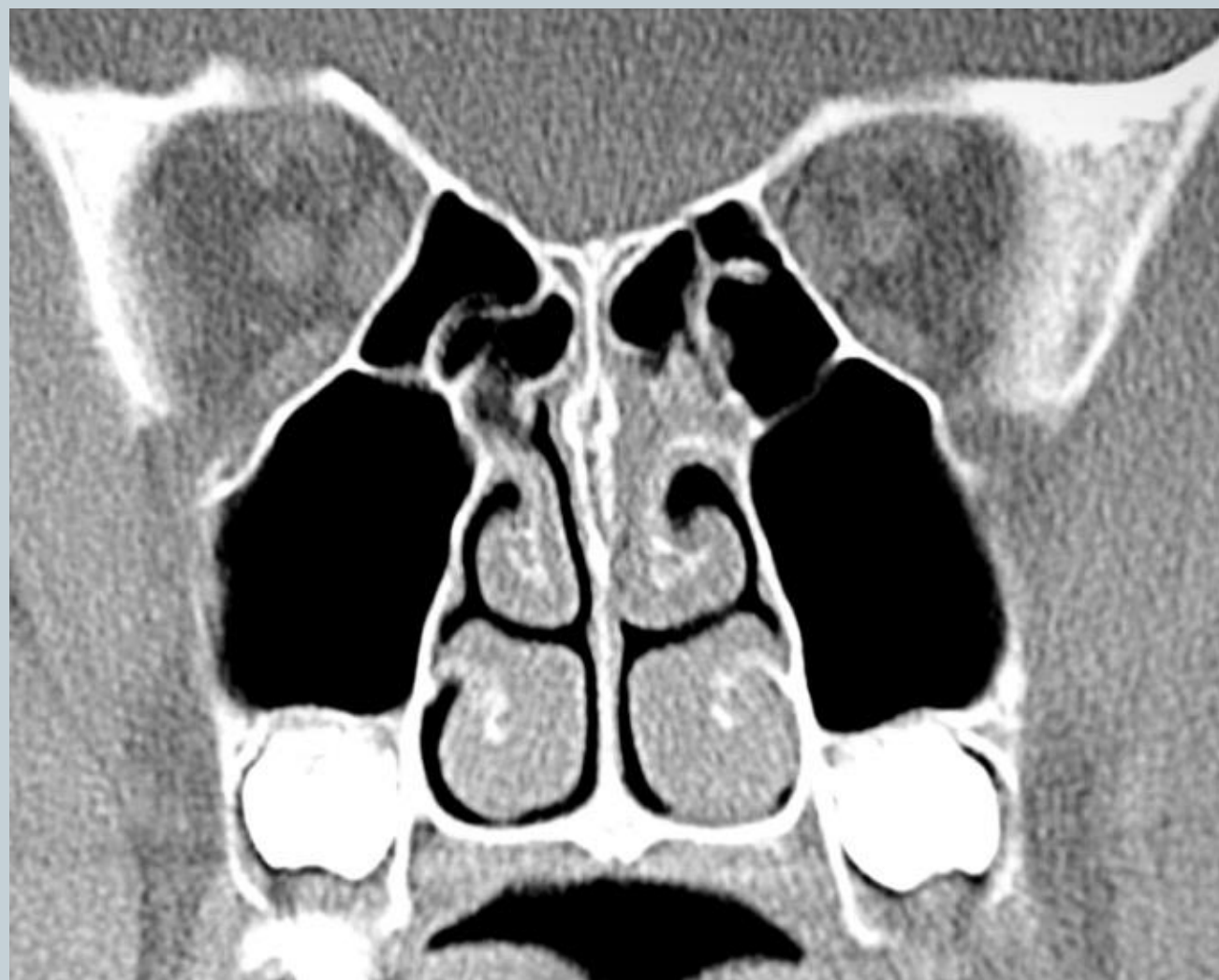
## **b) Hypertrophic rhinitis**

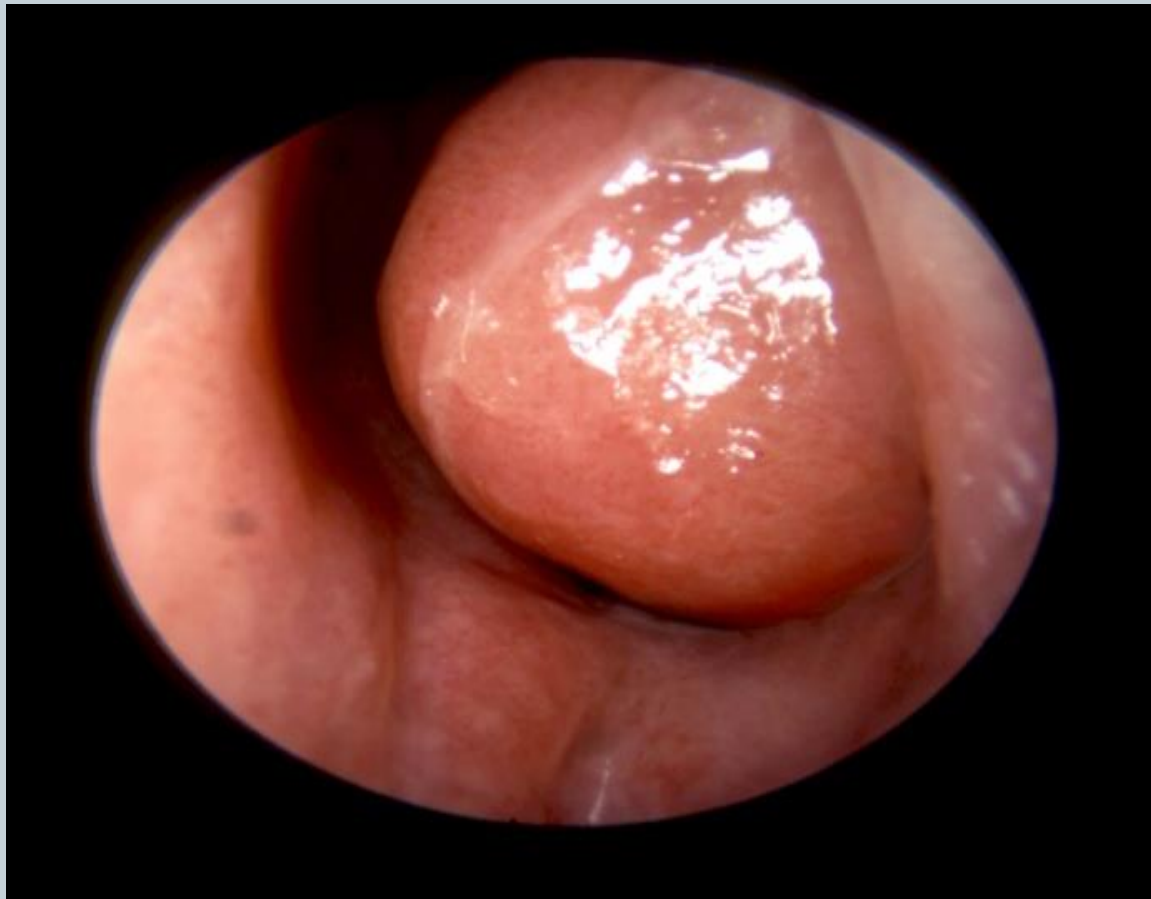
### **Aetiology**

The condition represents an advanced stage of simple chronic rhinitis, in which permanent hypertrophic changes have followed. The causes are similar, but it is frequently seen also in patients who have used topical decongestants in large quantities and/or for long periods (rhinitis medicamentosa).

## Pathology

.permanent hypertrophic changes accompany the inflammatory oedema and cellular infiltration in all the constituent parts of the mucosa i.e. stroma , glands , blood vessels , and lymphatic tissue . the epithelium loses cilia and shows a tendency to squamous metaplasia . the mucosa becomes thick and nodular , especially at the extremities and free border of the the occupy the posterior choana . fibrosis can cause venous and lymphatic obstruction . if the resulting passive edema occurs in the situation where the mucosal stroma is loose , polypi form . nasal polyposis , however , usually indicate an allergic or vasomotor origin of the rhinitis , in which the polyposis results from increases capillary permeability





## **Clinical features**

Similar to those of simple chronic rhinitis but are unremitting in character pitting of the firm mucosa with a probe and shrinkage with cocaine are less marked than in simple chronic rhinitis

## Treatment

As for simple chronic rhinitis , with the addition of limited reduction of the hypertrophied inferior turbinate and removal of any polypi . topical decongestant preparation must be discouraged or discontinued . reduction is achieved by :

- . electrocoagulation : by SMD or linear cauterization by galvanocautery

- . cryosurgical probe

Surgical trimming of the hypertrophied free border .

amputation of an posterior end end may be necessary .

avulsion or total removal of the inferior turbinate may be performed , but persistent crusting can result

## **(c)Atrophic rhinitis**

### **Definition**

A chronic inflammation of the nasal mucosa . in which its various constituents undergo atrophy as a result of per arterial fibrosis and endarteritis of the terminal arterioles .

## **Aetiology**

The exact etiology is not fully known but its incidence has markedly decrease in western Europe .

- 1.infection
2. undue patency of the nasal airway
3. endocrine disturbances
4. vitamins disturbances

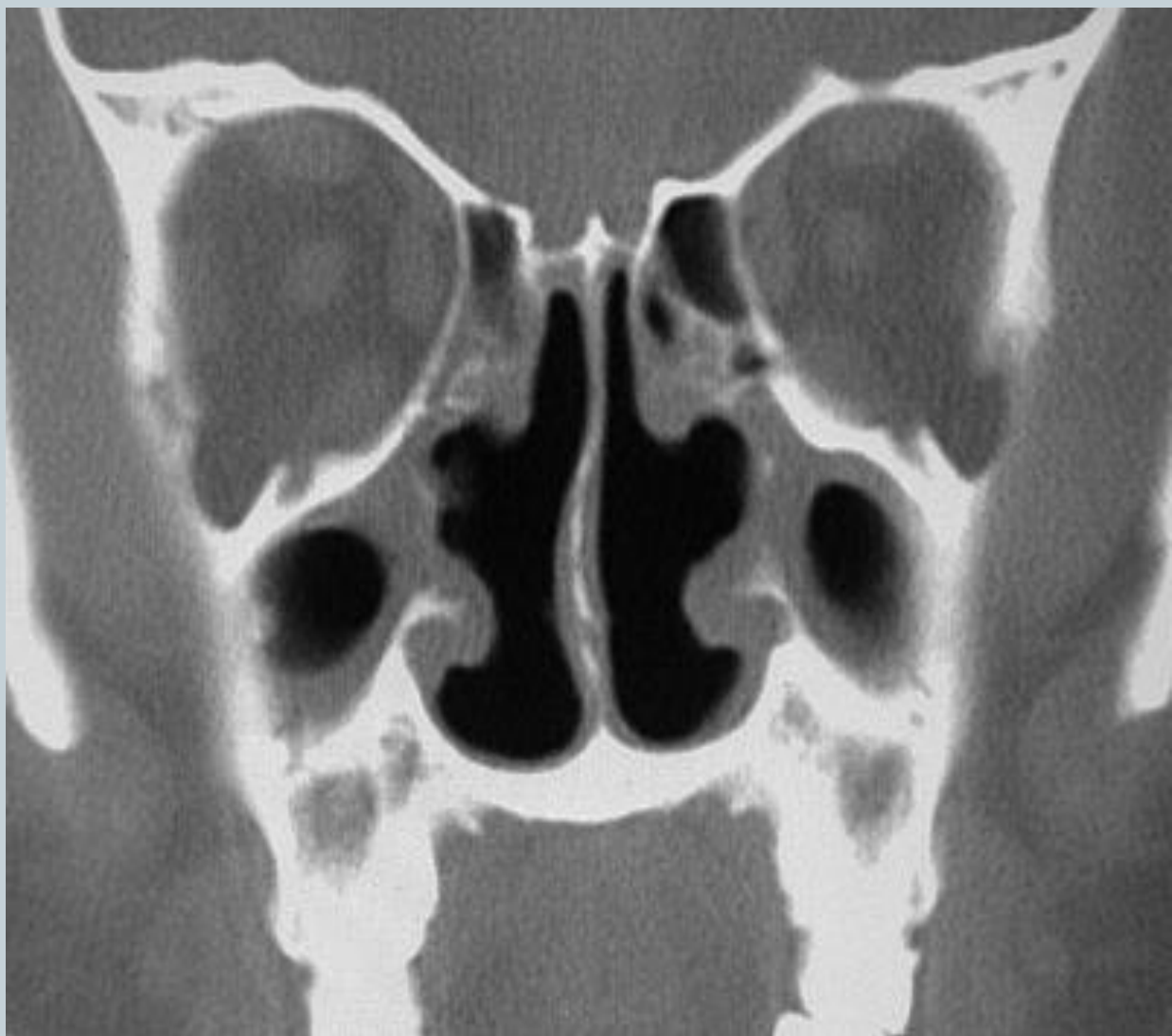
## **Types**

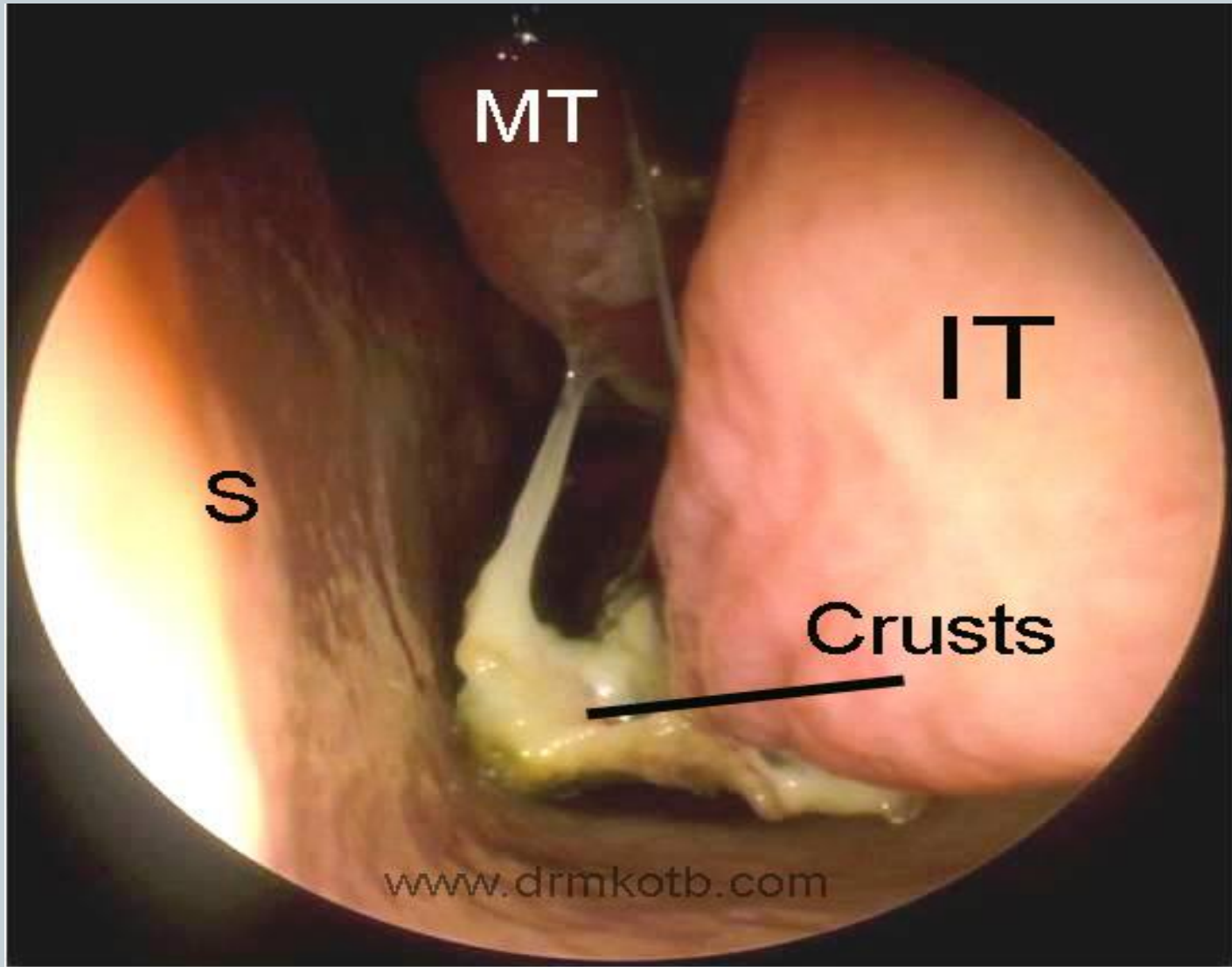
- 1.primary atrophic rhinitis ( ozaena ) : possibly the sequel of rhinitis associated with exanthema in childhood the process may passed hypertrophic stage before becoming atrophic
- 2.secondary atrophic rhinitis : destruction of the nasal mucosa and subsequent healing are associated with fibrosis of the submucosa and metaplasia of the ciliated epithelium  
it happen as result of
  - . deviated septum
  - .syphilis
  - .lupusExcessive operative procedure especially on the inferior turbinate



## **Pathology**

Degeneration of the ciliated epithelium and seromucinous glands causes the formation of thick adherent crusts in the nose these become secondarily infected with saprophytic organism the bony structures of the turbinate atrophy and the airway is widened . the sinuses may be small due to arrested pneumatization but are often normal there appear to be tendency to spontaneous recovery in later life in some cases





MT

IT

S

Crusts

www.drkotb.com

## **Clinical feature**

The conditions now seldom seen is bilateral and more common in female it appear about puberty

- 1.foul stench not noticed by the patient who is anosmic
- 2.epistaxis may follow separation of the crust
3. sensation of obstruction despite the unduly wide airway
4. similar atrophic changes may be seen in the pharynx and larynx

## **Differential diagnosis**

- 1.sinusitis
- 2.syphilis

## **Treatment**

Removal of crust is best achieved by syringing with warm isotonic solution

Glucose 25% in glycerin drops prevent adherence of fresh crust and inhibit saprophytic infection

Local or systemic antibiotic can be used initially as indicated by the sensitivity of the organism

Potassium iodide therapy and endocrine preparation such as stilboestrol locally or systemically

Surgical measures to reduce the caliber of the airway by submucosal insertion of graft , Teflon paste submucosal injection and to form adhesions between the septum and the infractured lateral nasal wall , Moistening of the mucosa has been attempted by diverting stenson's duct into the antrum

Complete surgical closure of the nostrils for periods of several months has been given striking improvement in the status of the mucous membrane ( young operation )

## **(d) Rhinitis sicca**

A rather ill defined crusting condition affecting the anterior third of the nasal cavity of patients who work in dusty surroundings

Periglandular fibrosis and metaplasia of the ciliated epithelium result in a viscid and stagnant mucus blanket which forms crust these are not foetid but are sometimes bloodstained and may lead to a septal perforation

There is no generalized atrophic change or any increase in caliber of the airway

## **Treatment**

is by correction of occupational surrounding and lubrication by sprays , paints or ointment , applied to the affected area

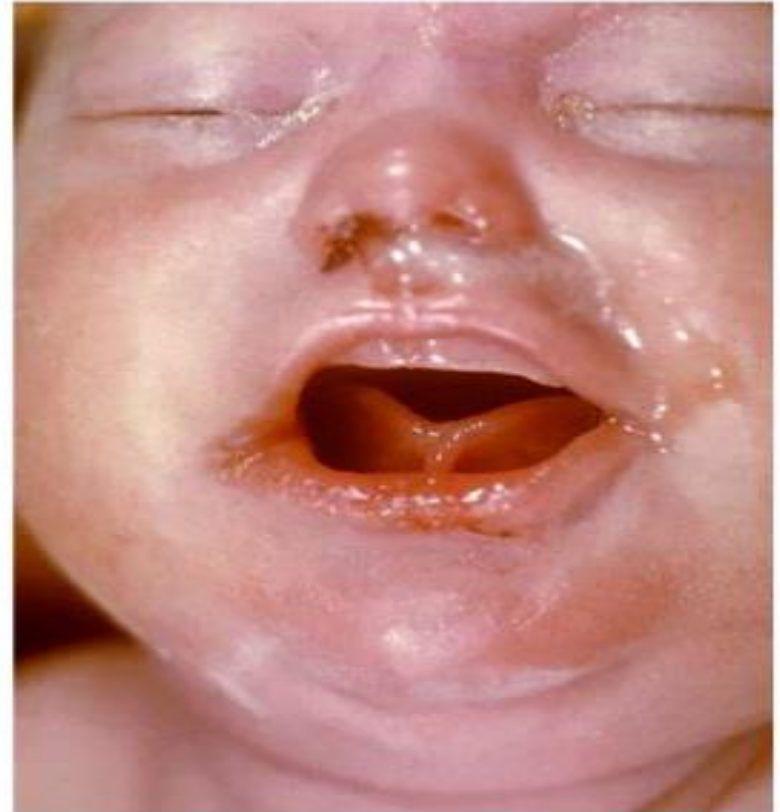# (a) Syphilis

Two forms

## **Congenital**

Two forms are distinguished:

**Congenital  
Syphilis**



1. Early form . up to the third month

A snuffle is the name given to the commonest nasal manifestation. this is a rhinitis which rapidly becomes purulent

Fissuring and crusting of the vestibule and lips are caused by the irritating discharge so that sucking may be prevented . occasionally necrosis of bone and cartilage occurs



2. Late form ( third form to puberty ) deformities similar to those in the tertiary stage of acquired syphilis result from gummatous infiltration of the nasal mucosa and subsequent destruction of the nasal framework . other stigmata affecting the eyes teeth and ears

# Acquired

Has three stages

*.primary stage* : onset 3-6 weeks after contagion

Chancre rare in the nose and appear a hard painless papule in the vestibule or on the adjacent septum it soon ulcerates to form a sore which has been linked to painless furuncle the submaxillary and preauricular glands disproportionately enlarged but painless

*Secondary stage* : onset 6-9 weeks after contagious

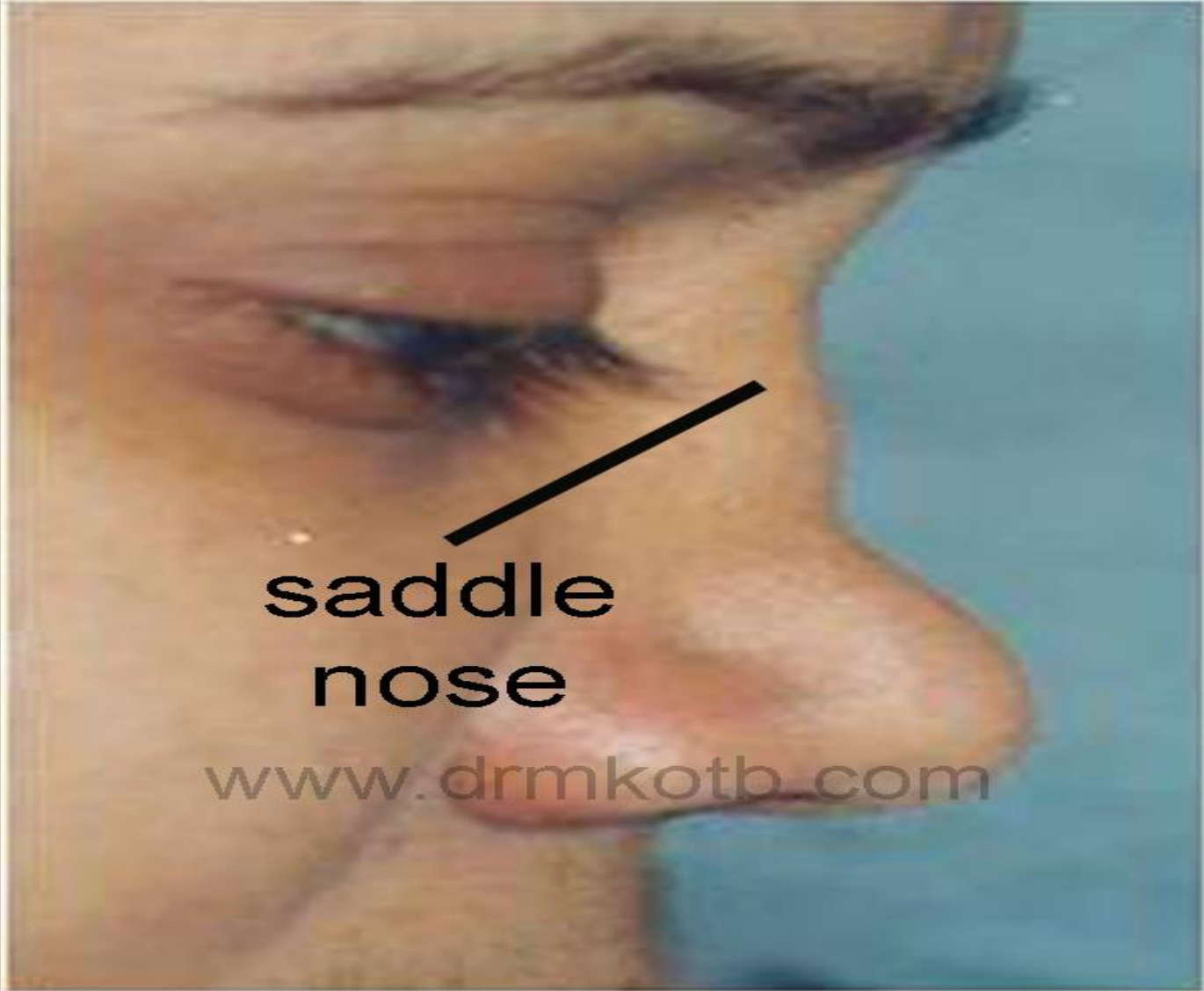Persistent coryza the presenting symptoms in the nose . mucus patches are rarely distinguishable on the nasal mucosa but they may be seen in the mouth and pharynx

*Tertiary stage* : onset usually 1-5 years after contagious a gumma of the nose is the commonest nasal manifestation of syphilis . usually starting in the periosteum of the septum it soon cause perforation . when the nasal bone are involved the bridge sinks ( saddleback deformity ) . less often the nasal floor may be perforated by gumma while the lateral wall are rarely affected . the external nose may be also attacked . when the ala .columella and adjacent upper lip are destroyed

Nasal obstruction and headache . the latter worse at night are the earliest symptoms

Before ulceration a nasal gumma present as a non- pitting rubbery swelling which is reddish purple in colour may be diffuse or localized and is accompanied by mucoid rhinorrhoea

After ulceration there is crusting and a foul bloodstained discharge the ulcer has a sloughy ( washleather ) base in which dead bone or fragment of necrotic cartilage may be detected



saddle  
nose

[www.drmarkotb.com](http://www.drmarkotb.com)

## Diagnosis

Confirmation depends upon identification of the *Treponema pallidum* in smears from primary and secondary lesions .

serological tests are negative in the primary stage but positive in 90 % of others

Biopsy

Trial therapy

## **Treatment**

General antisyphilitic treatment by systemic penicillin . nasal toilet as by irrigation with warm hydrogen peroxide (10 vol ) . in snuffles suction followed by instillation of ephedrine solution may render suckling possible

## **Sequelae**

Healing may result in vestibular stenosis , secondary atrophic rhinitis , perforation of the palate and septum and the deformities of the external nose

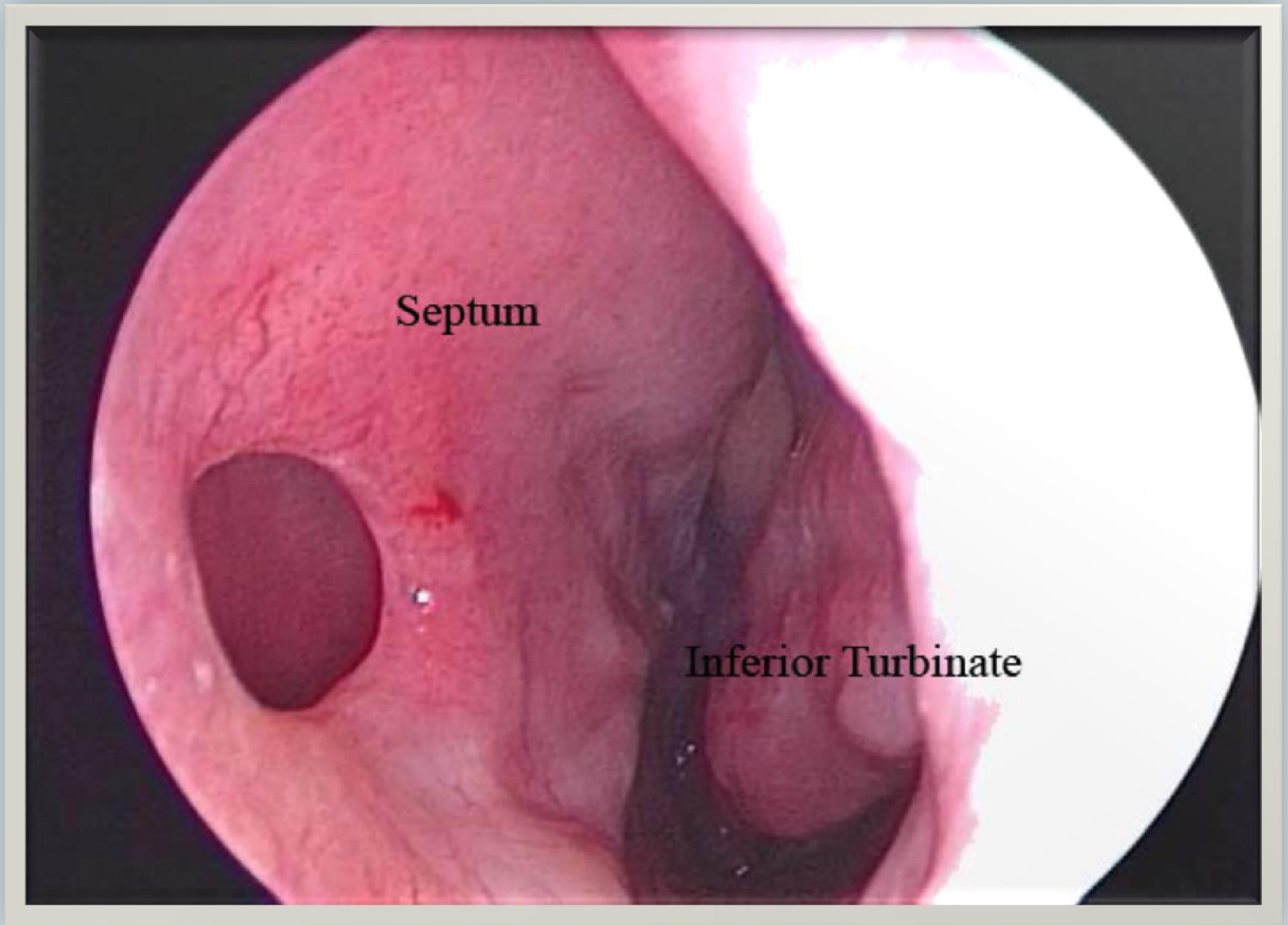
## **(d) Tuberculosis**

### **Etiology**

1. miliary spread from focus in the lung
2. fingernail inoculation , in the predispose tuberculous patient

### **Clinical features**

1. tuberculoma occurs on the cartilaginous portion of the septum
2. ulceration and perforation of the septum follow and spread to the nasal floor and inferior turbinate . nasal tuberculosis is much rarer than laryngeal tuberculosis



Septum

Inferior Turbinate



## **Treatment**

For lung condition , and includes the use of long term antituberculous drugs ( rifampicin , ethambutol , INAH, streptomycin, PAS )

## **(E) sarcoidosis**

Histological appearances are similar to tuberculosis except for the absence of caseation . mantoux test is negative . kveim test is sometimes positive

The diseases widely distributed in the body , lung , salivary , and lymphatic glands , skin and uveal tract being often affected in the nose it present as nodules on the septum and in the vestibules . spontaneous recovery is usual.

## **(F)Leprosy**

An extremely chronic tropical infection due to mycobacterium leprae . occurs as Asia, Africa and in Central and South America

### **Pathology**

M.leprae is conveyed to the septum by the fingernail. Initial coryza causes sneezing and discharge teeming with M. leprae . This is the infectious stage of the disease

After an interval of up to 10 years , a nodular thickening develops at first on the septum . the nodules show a perivascular cellular infiltration of the tissue which includes vacuolated giant cells and bacilli in parallel bundles.

Untreated progressive ulceration goes on with subsequent destruction of the nose . palate and larynx may be involved .

### **Treatment**

By rifampicine and clofazimine and dapsone for long period