

Operative Dentistry

Lec. 1

Dr Ahmed Sleibi

Operative Dentistry:

Is the art and science of the diagnosis, treatment, and prognosis of defects of teeth which do not require full coverage restorations for correction; such treatment should result in the restoration of proper tooth form, function and esthetic while maintaining the physiological integrity of teeth in harmonious relationship with the adjacent hard and soft tissues; all of which enhance the general health of the patient.

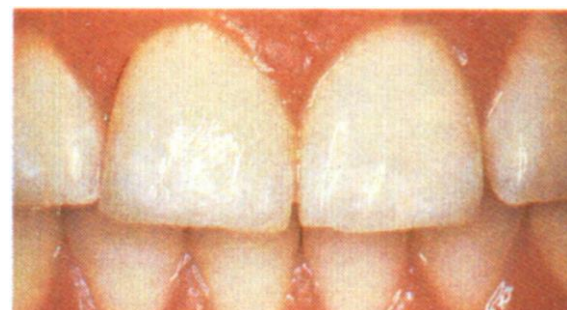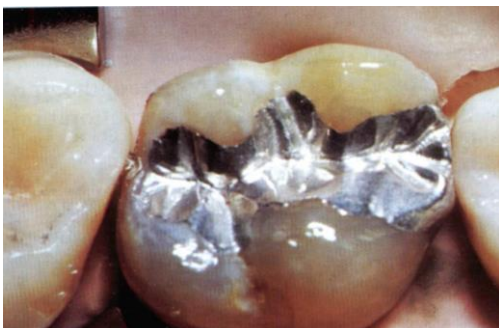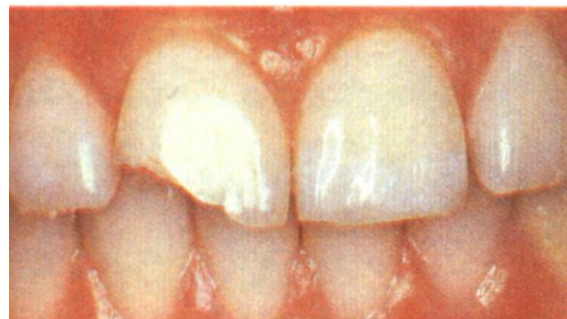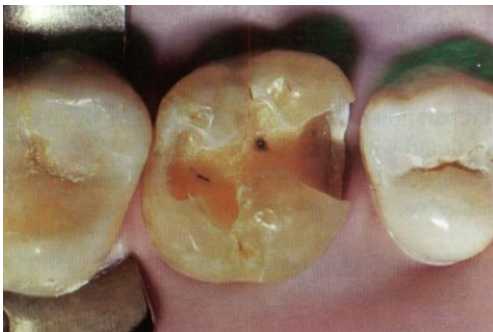Indications:

The indications for operative procedures are numerous. However, they can be categorized into three primary treatment needs:

- (1) Caries.
- (2) Malformed, discolored, or fractured teeth.
- (3) Restoration replacement or repair.

Cavity preparation:

Is the mechanical alteration of a defective, injured or diseased tooth in order to best receive a restorative material to reestablish a healthy state of the tooth including esthetic corrections when indicated, along with normal form and function.



Objectives of cavity preparation:

- 1- Remove all defects and give the necessary protection of the pulp.
- 2- Locate the margins of the restoration as conservatively as possible.
- 3- Form the cavity so that under force of mastication the tooth or the restoration or both will not fracture and the restoration will not be displaced.
- 4- Allow for the esthetic and functional placement of a restorative material.

Definitions

Cavity preparation walls:

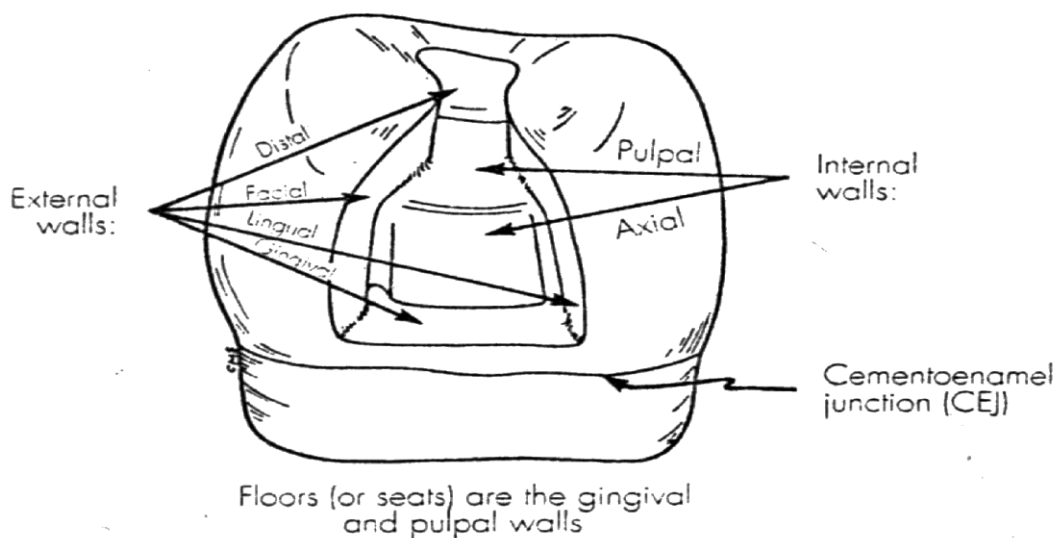
Internal walls: An internal wall is a prepared cavity surface that does not extend to the external tooth surface.

Axial wall: Is an internal wall parallel with the long axis of the tooth.

Pulpal wall: Is an internal wall that is both perpendicular to the long axis of the tooth and occlusal to the pulp.

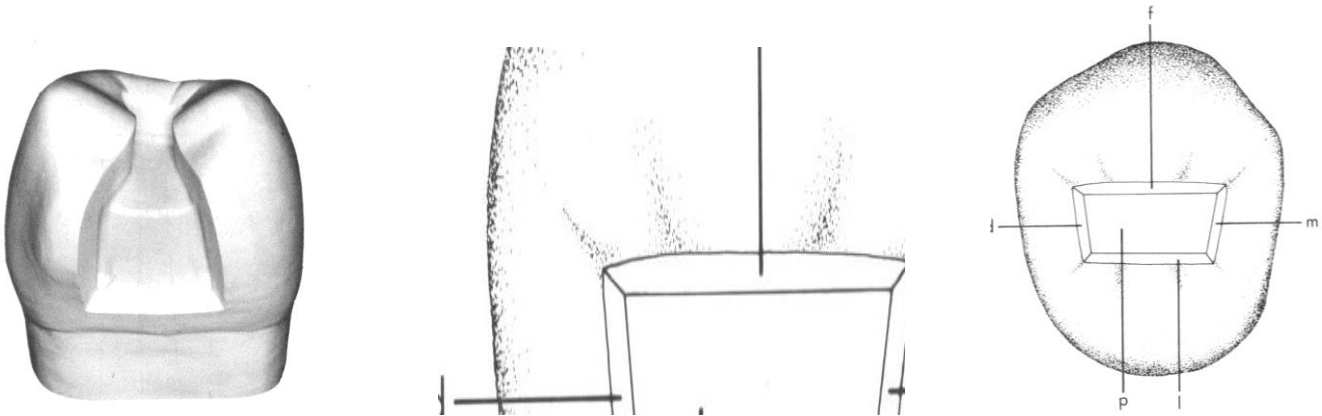
External wall: An external wall is a prepared cavity surface that extends to the external tooth surface, and such a wall takes the name of the tooth surface (or aspect) that the wall is toward.

Floor or Seat: Is a prepared cavity wall which is reasonably flat and perpendicular to those occlusion forces that are directed occlusogingivally. Ex: gingival and pulpal floor.



Enamel wall: The enamel wall is that portion of the prepared external wall consisting of enamel.

Dentinal wall: The dentinal wall is that portion of a prepared external wall consisting of dentin which may contain retention features.

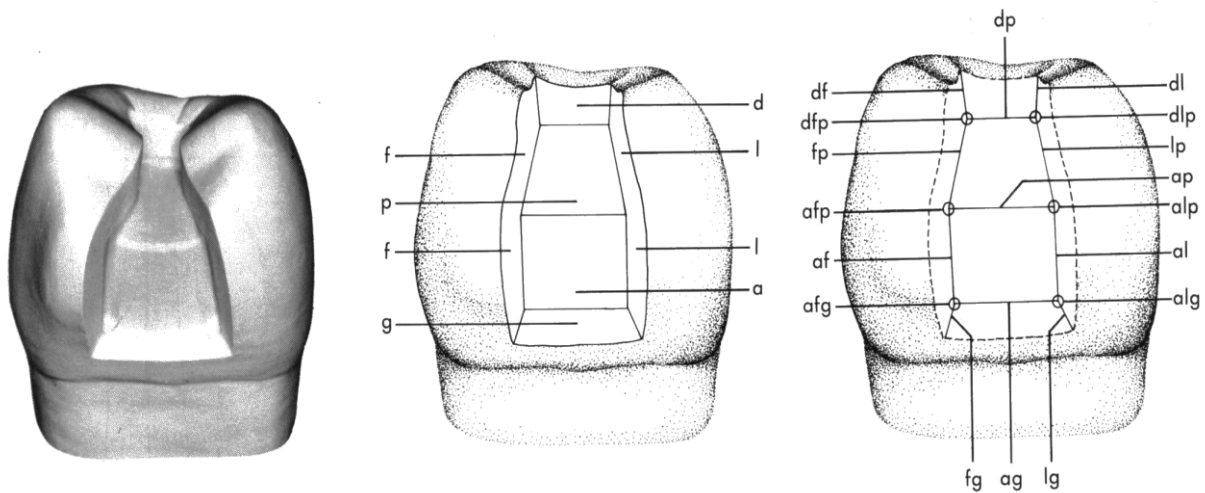


Line angle:

A line angle is the junction of two planal surfaces of different orientation along a line . It takes the name of the two surfaces forming the angle. An **internal angle** is a line angle whose apex points into the tooth. An **external angle** is a line angle whose apex points away from the tooth.

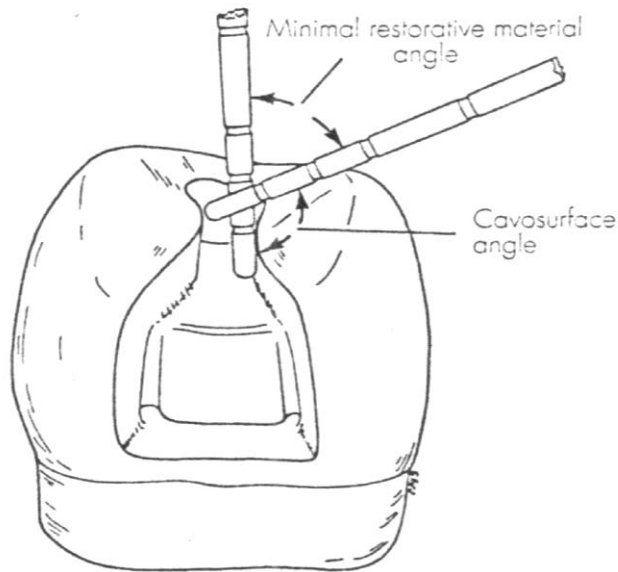
Point angle:

A point angle is a junction of three planal surfaces of different orientation at a common point. It takes the name of the three surfaces forming it.



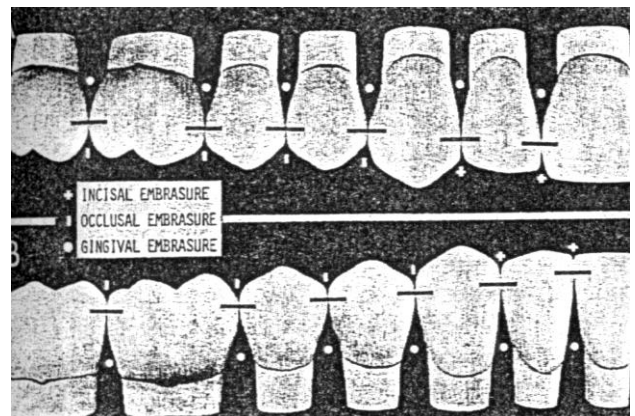
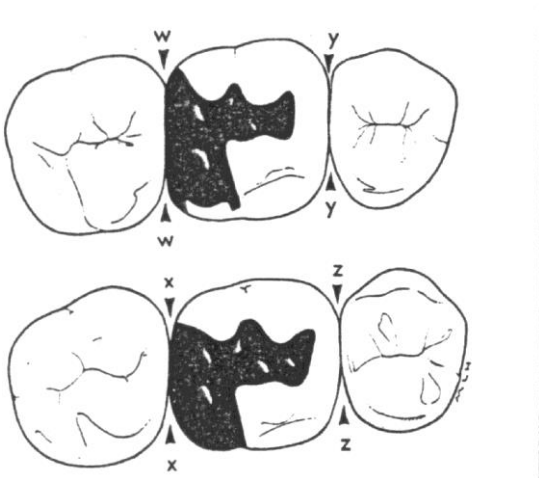
Cavosurface angle, cavosurface margin, and cavity margin:

The *cavosurface angle* is the angle of tooth structure formed by the junction of a prepared cavity wall and the external surface of the tooth. The actual junction is referred to as *cavity margin* or *cavosurface margin*.



Embrasures:

Are V - shaped spaces that originate at the proximal contact areas between adjacent teeth and are named for the direction toward which they radiate. These embrasures are: (1) facial, (2) lingual, (3) incisal or occlusal, and (4) gingival.



Undercut:

Is a portion of prepared cavity confined by the walls which converge towards the outer surface or it could be a localized channel or groove within prepared cavity.

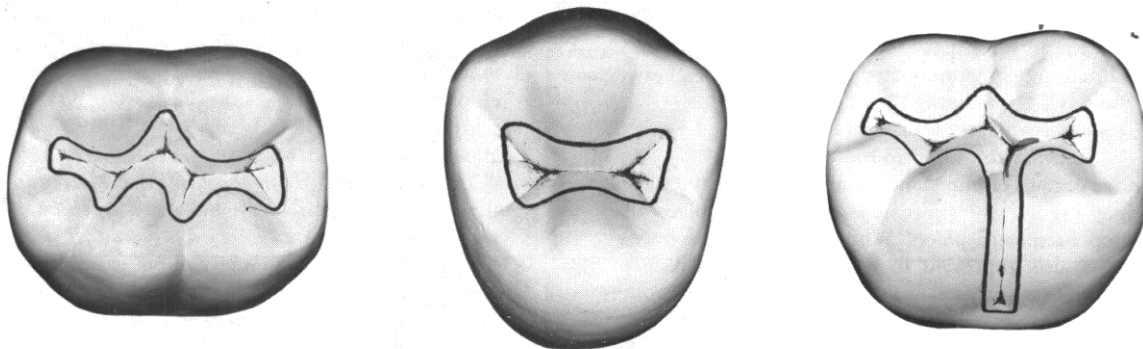
Cavity classifications

1- According to the number of surfaces involved

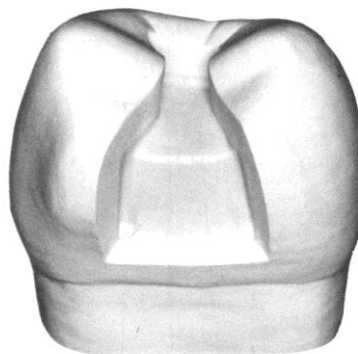
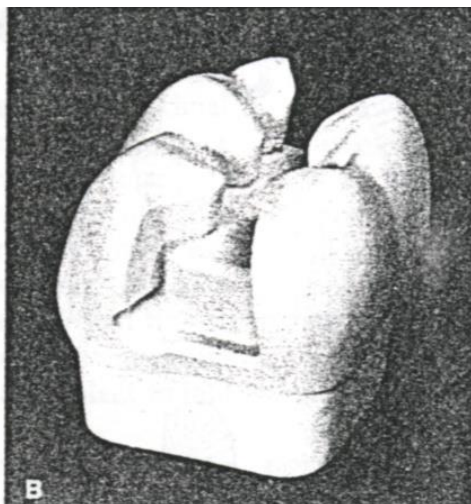
- A- *Simple cavity* : only one surface involved
- B- *Compound cavity* : two surfaces involved
- C- *Complex cavity* : Three surfaces (or more) involved

2- According to anatomical areas involved and associated type of treatment was presented by G.V Black

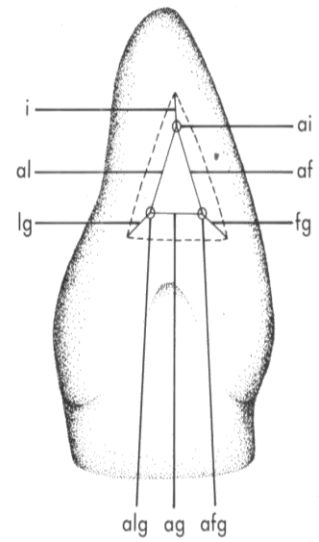
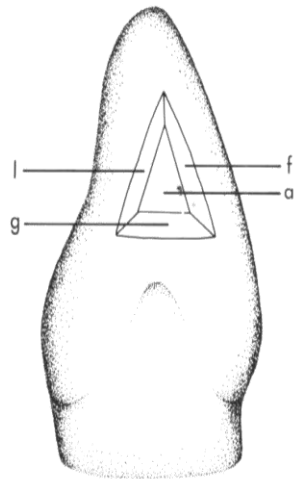
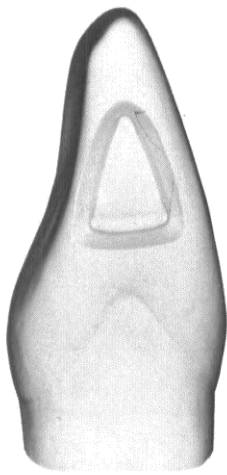
Class I : All pit and fissure cavities : cavities on the occlusal surface of premolars and molars, on the occlusal two thirds of the facial and lingual surfaces of molars , on the lingual surface of maxillary incisors.



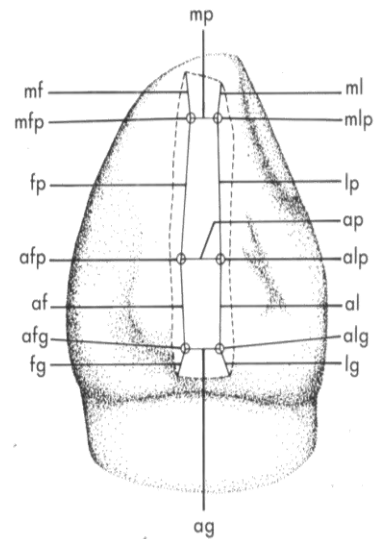
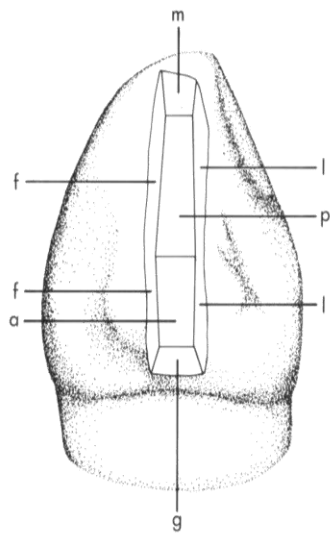
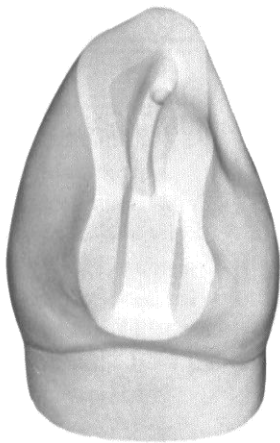
Class II : Cavities on the proximal surfaces of posterior teeth . (Mesio-occlusal MO),(Disto-occlusal DO) , (Mesio- occluso – distal MOD).



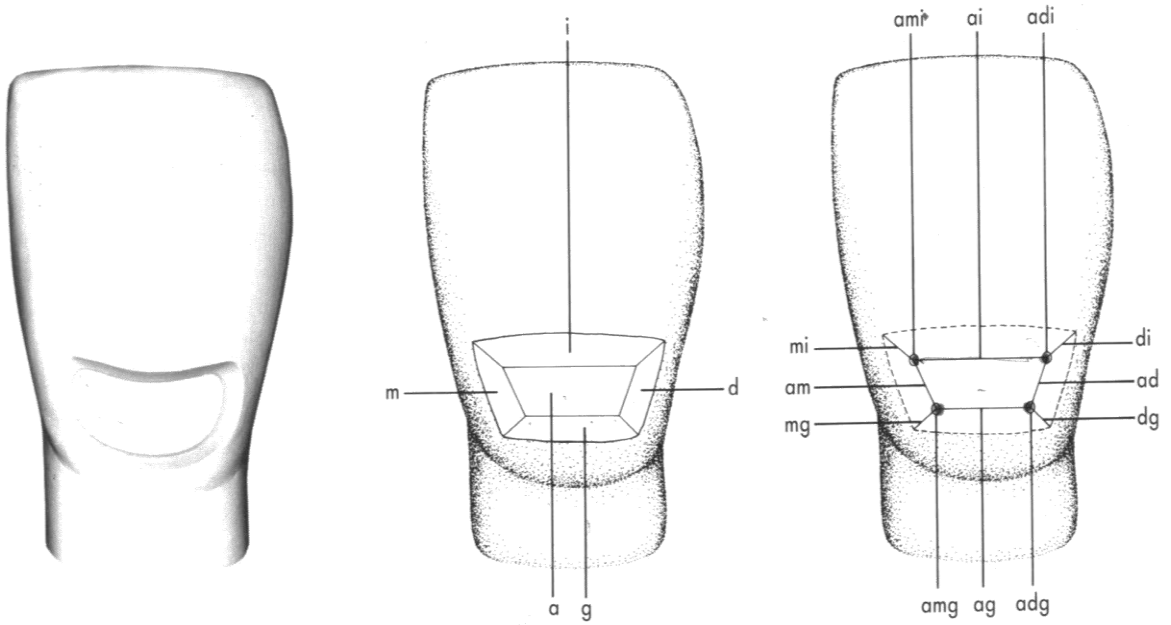
Class III : Cavities on the proximal surfaces of anterior teeth that do not involve the incisal angle.




Class IV : Cavities on the proximal surfaces of anterior teeth that do involve the incisal edge.



Class V : Cavities on the gingival third of the facial and lingual surfaces of all teeth (not pit and fissure cavities)



Class VI : Cavities on the incisal edge of anterior teeth or the occlusal cusp heights of posterior teeth.



End