

See discussions, stats, and author profiles for this publication at: <https://www.researchgate.net/publication/330309771>

Pediatric Cervical Spine Clearance: A Consensus Statement and Algorithm from the Pediatric Cervical Spine Clearance Working Group

Article in *The Journal of Bone and Joint Surgery* · January 2019

DOI: 10.2106/JBJS.18.00217

CITATIONS

4

READS

373

28 authors, including:



Julie Catherine Leonard

Nationwide Children's Hospital

64 PUBLICATIONS 621 CITATIONS

[SEE PROFILE](#)



John T Anderson

Children's Mercy - Kansas City

27 PUBLICATIONS 286 CITATIONS

[SEE PROFILE](#)



Timothy N Booth

University of Texas Southwestern Medical Center

70 PUBLICATIONS 1,572 CITATIONS

[SEE PROFILE](#)



Patrick J Cahill

The Children's Hospital of Philadelphia

161 PUBLICATIONS 1,378 CITATIONS

[SEE PROFILE](#)

Some of the authors of this publication are also working on these related projects:



Os odontoideum in [View project](#)



ACR Appropriateness Criteria - Pediatric Panel [View project](#)

THE ORTHOPAEDIC FORUM

Pediatric Cervical Spine Clearance

A Consensus Statement and Algorithm from the Pediatric Cervical Spine Clearance Working Group

Martin J. Herman, MD, Kristin O. Brown, MS, Paul D. Sponseller, MD, Jonathan H. Phillips, MD, Philip M. Petrucelli, MD, Darshan J. Parikh, BS, Kush S. Mody, BS, Julie C. Leonard, MD, MPH, Matthew Moront, MD, Douglas L. Brockmeyer, MD, Richard C.E. Anderson, MD, Adam C. Alder, MD, John T. Anderson, MD, Robert M. Bernstein, MD, Timothy N. Booth, MD, Bruno P. Braga, MD, Patrick J. Cahill, MD, Jeanne M. Joglar, MD, Jeffrey E. Martus, MD, MS, Jo-Ann O. Nesiama, MD, Joshua M. Pahys, MD, Karl E. Rathjen, MD, Anthony I. Riccio, MD, Jacob F. Schulz, MD, Anthony A. Stans, MD, Manish I. Shah, MD, MS, William C. Warner Jr., MD, and Burt Yaszay, MD

Pediatric cervical spine injury (CSI) that is related to blunt trauma occurs in 1% to 2% of all children who are admitted to the hospital after blunt trauma¹⁻³. Cervical spine clearance for potential injury is performed daily in emergency departments (EDs) throughout the world. However, in a recent survey of level-I pediatric trauma centers in North America, only 46% of institutions had a written pediatric cervical spine clearance protocol⁴.

In pediatric centers, an algorithmic approach or protocol for cervical spine clearance reduces time to cervical collar removal⁵ and limits patient exposure to ionizing radiation by reducing the use of radiography and computed tomography (CT)^{6,7}. Published protocols and clinical guidelines for pediatric cervical spine clearance differ in criteria for clinical clearance and the use of imaging⁷⁻¹².

The Pediatric Cervical Spine Clearance Working Group (PCSCWG), a subgroup of the Pediatric Cervical Spine Study Group, recognized the need for a consensus on comprehensive standardized guidelines for pediatric cervical spine clearance based on the best available evidence. We established a

multidisciplinary group of practitioners with expertise in cervical spine clearance for injured children and applied the Delphi method and the nominal group technique to create consensus statements regarding pediatric cervical spine clearance in young patients who have experienced blunt trauma^{13,14}. The consensus statements were used to develop an algorithm to guide institutional protocols for cervical spine clearance.

Materials and Methods

Working Group

The PCSCWG is a multidisciplinary panel of fellowship-trained physicians with experience in pediatric cervical spine trauma care who were recruited by the project leaders. The working group consisted of 15 pediatric orthopaedic surgeons, 3 pediatric emergency medicine physicians, 3 pediatric neurosurgeons, 2 pediatric trauma surgeons, and 2 pediatric radiologists. Participants agreed to complete a series of online surveys, participate in an in-person meeting, and collaborate with the project team to write a manuscript.

Disclosure: Dr. Martin J. Herman received a POSNA (Pediatric Orthopaedic Society of North America) Start-Up Research Grant. All costs related to the in-person meeting were donated by the Texas Scottish Rite Hospital Foundation, Dallas, Texas. On the **Disclosure of Potential Conflicts of Interest** forms, which are provided with the online version of the article, one or more of the authors checked “yes” to indicate that the author had a relevant financial relationship in the biomedical arena outside the submitted work; “yes” to indicate that the author had a patent and/or copyright, planned, pending, or issued, broadly relevant to this work; and “yes” to indicate that the author had other relationships or activities that could be perceived to influence, or have the potential to influence, what was written in this work (<http://links.lww.com/JBJS/F26>).

Delphi Method

The Delphi method and the nominal group technique are approaches to developing consensus and best-practice guidelines for completing complex tasks when there is insufficient scientific evidence to guide decision-making¹⁵. A modified version of the Delphi method was applied during a 7-month period with 4 rounds of voting. Consensus was defined as $\geq 80\%$ agreement among panelists for each statement. The only choices offered were “agree” or “disagree.”

Literature Review

A search of the PubMed database was performed using the following terms: pediatric cervical spine injury, pediatric cervical spine fracture, pediatric cervical spine clearance, pediatric cervical spine trauma, cervical spine immobilization, and pediatric spinal cord. Primary research studies and reviews published from January 1, 1987, to June 30, 2016, were included. Case reports, single-author expert opinion pieces, and non-English-language articles were excluded. The project team reviewed the articles and identified 27 for consideration.

Electronic Surveys

After reviewing the literature, the project team developed a 20-question electronic survey (Survey 1) that was distributed online to panel members via SurveyMonkey in October 2016 (see Appendix). Survey 1 had 3 objectives: (1) to collect

demographic data and clinical experience about the participants, (2) to collect practice profile data from the participants' institutions, and (3) to introduce terminology that would be used for the remainder of the project. In December 2016, a second 66-question electronic survey (Survey 2) was distributed (see Appendix). Lastly, a 9-question electronic survey (Survey 3) was distributed after the January 2017 in-person meeting to clarify the role of flexion-extension imaging, a subject that reached near-consensus during the meeting (see Appendix).

In-Person Meeting

After tabulation of the results from Surveys 1 and 2, the project team and the PCSCWG convened for a 1.5-day in-person meeting in January 2017. The project team developed 33 statements on the basis of survey results. The panel evaluated these statements using the following process: (1) a single written statement was presented; (2) research pertinent to that statement was presented by the moderator, followed by an interactive discussion; (3) if requested, the statement was revised, generating a final version; and (4) participants then were asked to vote using a commercially available anonymous polling software (polleverywhere.com; Poll Everywhere) that tabulated the voting in real time. Statements were approved for inclusion if a consensus was reached ($\geq 80\%$ agreement). If there was 70% to 79% agreement, the statement was revised, and a second real-time poll was conducted. Statements that did not reach a

TABLE 1 Pediatric Cervical Spine Clearance Definitions as Determined by the PCSCWG ($\geq 80\%$ Consensus)*

The purpose of a pediatric cervical spine clearance protocol is to identify significant CSIs in children who have sustained blunt trauma. The ideal protocol identifies all significant injuries, minimizes unnecessary radiation exposure to the child, permits removal of a rigid cervical collar or other method of cervical spine immobilization when deemed no longer necessary, and efficiently and effectively utilizes health-care and human resources.

Pediatric cervical spine clearance is the process by which a child with a suspected CSI undergoes clinical evaluation (history and physical examination) and, in select cases, is evaluated by diagnostic imaging to determine that a CSI has not occurred. A complete history includes, among other details, a determination of the MOI when possible.

Diagnostic imaging includes radiographs (anteroposterior/lateral cervical spine views at a minimum), CT of the cervical spine, and MRI of the cervical spine. Dynamic cervical spine imaging may include flexion-extension lateral cervical spine radiographs, flexion-extension and rotational CT of the cervical spine, and flexion-extension MRI of the cervical spine.

Interpretation of diagnostic imaging of the pediatric cervical spine, and the final determination of findings, is performed by personnel with advanced training and expertise in the imaging of pediatric spine conditions. Personnel generally qualified to perform this task are radiologists, neurosurgeons, orthopaedic surgeons, and emergency department physicians.

Pediatric cervical spine clearance is the responsibility of physicians with expertise in evaluating a child with a suspected CSI. Personnel generally qualified to perform this task include ED physicians, general and trauma surgeons, neurosurgeons, and orthopaedic surgeons. Additionally, midlevel care providers practicing in collaboration with any of the listed personnel or other physicians with additional specialized training in musculoskeletal medicine and experience in treating musculoskeletal injuries can clinically clear the pediatric cervical spine.

A “spine consult service” is defined as a specialist or team of specialists with advanced training and expertise in the care of pediatric spine conditions. This term generally refers to teams composed of neurosurgeons and/or orthopaedic surgeons. Additionally, midlevel care providers practicing in collaboration with any of the listed personnel or other physicians with additional specialized training in musculoskeletal medicine.

A child, regardless of age, with a GCS score of 14 or 15 (includes pediatric GCS for a nonverbal child) is considered to have normal mental status.

A child, regardless of age, with a GCS score of <14 or one who is under the influence of alcohol or drugs that alter the sensorium is considered to have an altered mental status.

*PCSCWG = Pediatric Cervical Spine Clearance Working Group, CSI = cervical spine injury, MOI = mechanism of injury, CT = computed tomography, MRI = magnetic resonance imaging, ED = emergency department, and GCS = Glasgow Coma Scale.

consensus after a second poll (<80% agreement) were deferred for later discussion or dismissed.

Results

Definitions and Terminology

Using results from Survey 1, the project team established consensus definitions and clarified terminology pertinent to the

process of pediatric cervical spine clearance (Table I). The results of Surveys 1 and 2 were used to establish the framework by which the final algorithm would be created—specifically, patients would be evaluated using an algorithmic progression for clearance according to the Glasgow Coma Scale (GCS) score and its pediatric modification^{16,17}. Three pathways for clearance were developed.

TABLE II Consensus for Best Practice Guidelines for Pediatric Cervical Spine Clinical Clearance, Pathway 1: Patient with a GCS Score of 14 or 15*

When clinical clearance is not possible, the primary imaging modality for children who are <3 years old is radiographs.

Initial radiographic evaluation for all children should consist of 1 view (lateral) as opposed to 2 views.

Other views (anteroposterior, odontoid, oblique, flexion-extension) are unnecessary for initial conventional radiographic evaluation.

For a child with a GCS score of 15 who has persistent neck findings and has a normal neurologic examination and a normal lateral radiograph, the next step is a spine service consultation before additional imaging.†

For a child with a GCS score of 15 who has an abnormal neurologic examination, the next step is a spine service consultation before additional imaging.†

For an asymptomatic child who is ≥3 years of age with a normal mental status and a normal examination, clinical clearance CAN be done regardless of MOI.

A child who presents with suspected abusive head trauma should undergo MRI of the cervical spine.

Clinical clearance of the cervical spine of a child with a significant developmental disability or preexisting musculoskeletal conditions that have the potential to affect the cervical spine is possible, but information about the type of disability, the child's baseline intellectual function, and preinjury behaviors should be considered in the clearance process.

Stronger consideration for imaging should be given to children with the following MOIs: diving, axial load, "clothes-lining," or a high-risk motor-vehicle collision.

Clinical clearance after blunt trauma that could potentially involve the neck CANNOT be performed if the child exhibits a visible or known substantial injury to the chest, the abdomen, or the pelvis.

Physical examination: if the child can maintain focus during a physical examination for clinical clearance, despite the presence of other significant injuries, clinical clearance can be performed.

Clinical clearance of the cervical spine can be performed in children who are <3 years of age.

Clinical clearance can be performed in a child with neck tenderness that is NOT in the posterior midline.

Clinical clearance CANNOT be performed if the child or parent reports persistent neck pain, abnormal head posture, or difficulty in neck movement.

For a child with a GCS score of 14 or 15 who has normal conventional radiographs, a normal physical examination, and posterior midline neck pain/tenderness, any of the following management options are acceptable:

- Placement of a rigid cervical collar with reevaluation in 1-2 weeks
- Spine service consultation
- Obtaining adequate flexion-extension radiographs (defined as ≥30° flexion and ≥30° extension) to clear potential ligamentous injury

For a child with a GCS score of 14 or 15 with normal conventional radiographs, a normal physical examination, and posterior midline neck pain/tenderness, adequate flexion-extension radiographs (defined as ≥30° flexion and ≥30° extension) are an OPTION to clear potential ligamentous injury.

For a child with a GCS score of 14 or 15 with normal conventional radiographs, a normal physical examination, posterior midline neck pain/tenderness, AND adequate flexion-extension radiographs (defined as ≥30° flexion and ≥30° extension), the cervical spine is cleared.

For a child in the subacute setting with normal conventional radiographs, a normal physical examination, and persistent posterior midline neck pain/tenderness, any of the following 3 management options are acceptable:

- Continuation of a rigid cervical collar with reevaluation after another 1-2 weeks
- Spine service consultation
- Obtaining adequate flexion-extension radiographs (defined as ≥30° flexion and ≥30° extension) to clear potential ligamentous injury

For a child in the subacute setting with normal conventional radiographs, a normal physical examination, and persistent posterior midline neck pain/tenderness, adequate flexion-extension radiographs (defined as ≥30° flexion and ≥30° extension) are an OPTION to clear potential ligamentous injury.

For a child in the subacute setting with normal conventional radiographs, a normal physical examination, persistent posterior midline neck pain/tenderness, AND adequate flexion-extension radiographs (defined as ≥30° flexion and ≥30° extension), the cervical spine is cleared.

*GCS = Glasgow Coma Scale, MRI = magnetic resonance imaging, and MOI = mechanism of injury. †This statement reached consensus in the electronic survey as written; this statement was modified to include a GCS score of 14 or 15 at the in-person meeting based on the consensus statement written in Table I that defines normal mental status as a GCS score of 14 or 15.

TABLE III Consensus for Best Practice Guidelines for Pediatric Cervical Spine Clinical Clearance, Pathway 2: Patient with a GCS Score of ≤ 8 *

Children who present with suspected abusive head trauma should undergo MRI of the cervical spine.

The initial imaging modality for a reasonable suspicion of a CSI in children with a GCS score of ≤ 8 is CT.

Clinical clearance of the cervical spine in a child with a significant developmental disability or preexisting musculoskeletal conditions that have the potential to affect the cervical spine is possible, but information about the type of disability, the child's baseline intellectual function, and preinjury behaviors should be considered in the clearance process.

Stronger consideration for imaging should be given to children with the following MOIs: diving, axial load, "clothes-lining," or a high-risk motor-vehicle collision.

If CT was chosen as the initial imaging modality for evaluating a CSI in a child with a GCS score of ≤ 8 without anticipated improvement in mental status within 72 hours of admission, and if the CT scan was negative, MRI is the next best imaging modality.

In the evaluation of a CSI for children with a GCS score of ≤ 8 , MRI is sufficient to clear the cervical spine.

*GCS = Glasgow Coma Scale, MRI = magnetic resonance imaging, CSI = cervical spine injury, MOI = mechanism of injury, and CT = computed tomography.

Consensus Statements

Pathway 1: GCS Score of 14 or 15

Pathway 1 defines the cervical spine clearance process for patients, regardless of age, with a GCS score of 14 or 15. This pathway focuses on 2 critical aspects of pediatric cervical spine clearance: (1) physical examination and historical/mechanistic factors, focusing on clinical clearance without radiographic imaging; and (2) radiographic imaging recommendations for the awake and alert patient. The consensus statements for Pathway 1 are provided in Table II.

Pathway 2: GCS Score of ≤ 8

Pathway 2 defines the cervical spine clearance process for patients with a GCS score of ≤ 8 . This pathway focuses on cervical spine clearance when a complete physical examination cannot be performed and when recovery of neurologic function to normal mental status within 72 hours of injury is unlikely, as in a child with a severe traumatic brain injury. The consensus statements for Pathway 2 are provided in Table III.

Pathway 3: GCS Score of 9 to 13

Pathway 3 defines the cervical spine clearance process for patients with a GCS score of 9 to 13. These patients are at intermediate risk for injury and, at least initially, cannot be safely cleared clinically. This pathway focuses on the judicious use of CT and the restriction of cervical spine motion with a collar for immobilization until mental status returns to normal and a follow-up examination can be performed. This group primarily includes intoxicated patients with altered sensorium and children who initially may not be able to focus during the clinical evaluation of the cervical spine because of anxiety related to traumatic events or the hospital setting. The consensus statements for Pathway 3 are reported in Table IV.

Proposed Algorithm

An algorithm for clearance of the pediatric cervical spine was generated on the basis of the consensus statements (Fig. 1).

TABLE IV Consensus for Best Practice Guidelines for Pediatric Cervical Spine Clinical Clearance, Pathway 3: Patient with a GCS Score of 9 to 13*

For a child with a suspected CSI who has a GCS score of 9 to 13 and has the potential to improve mental status to a GCS score of 14 or 15, a lateral radiograph is recommended.

Children who present with suspected abusive head trauma should undergo MRI of the cervical spine.

For a child who has a GCS score of 9 to 13 with a normal lateral radiograph and has the potential to improve mental status to a GCS score of 14 or 15, an appropriate management strategy is a repeat clinical examination after a period of observation.

For a child who has a GCS score of 9 to 13 with a normal lateral radiograph, a repeat clinical examination should be performed within 12 hours.

For a child who has a GCS score of 9 to 13 with a normal lateral radiograph who cannot be cleared by a repeat clinical examination, the spine service should be consulted.

Clinical clearance of the cervical spine of a child with a significant developmental disability or preexisting musculoskeletal conditions that have the potential to affect the cervical spine is possible, but information about the type of disability, the child's baseline intellectual function, and preinjury behaviors should be considered in the clearance process.

Stronger consideration for imaging should be given to children with the following MOIs: diving, axial load, "clothes-lining," or a high-risk motor-vehicle collision.

*GCS = Glasgow Coma Scale, CSI = cervical spine injury, MRI = magnetic resonance imaging, and MOI = mechanism of injury.

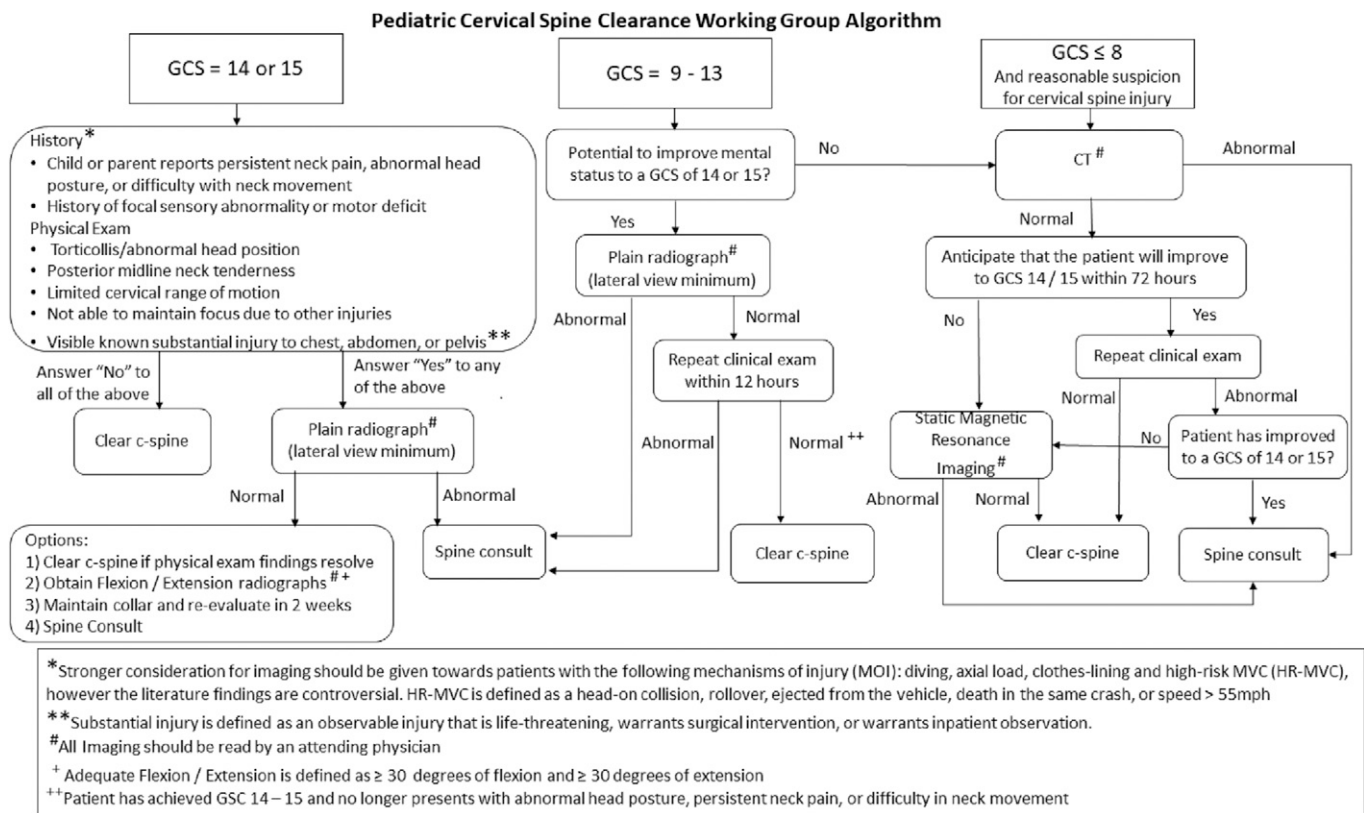


Fig. 1

The PCSCWG algorithm. C-spine = cervical spine.

Discussion

Despite substantial research addressing clearance of CSIs after blunt trauma in children, recommendations vary widely^{4,7-12}. Ideally, an algorithm for cervical spine clearance identifies all important injuries and facilitates removal of provisional cervical spinal motion restriction in an expeditious manner, while limiting the patient's exposure to ionizing radiation and using health-care resources responsibly. Failing to detect a CSI in a child may have devastating consequences. Avellino et al.¹⁸ reported the rate of missed injuries to be as high as 5%. Therefore, any algorithm must weigh the risks of missing an occult injury compared with overutilization of diagnostic imaging, particularly CT. There is disagreement in the published literature about which imaging modality to use. For example, the authors of a retrospective study involving 75 patients with confirmed CSI recommended using CT as opposed to radiography in the evaluation of suspected CSI because no injuries were detected on radiographs that were not detected with CT; additionally, the use of radiographs failed to identify 32% of the 75 cases of CSI¹⁹. However, Brenner and Hall emphasized that the level of radiation in a common CT scan raises the lifetime risks for certain cancers in adults, and even more so in children²⁰. The estimated lifetime CT-attributable cancer mortality risk as a function of age is an order of magnitude greater for children who undergo CT of the head than it is for adults who undergo a similar scan. This

greater risk is because children have more years than adults in which to develop cancers, are more radiosensitive than adults, and are anthropometrically smaller, which creates the potential for higher radiation doses²¹. A focus of our effort was to responsibly reduce the use of CT in children undergoing cervical spine clearance to diminish this risk while considering the importance of failing to detect a CSI. As a result, the use of CT is part of the algorithm for patients presenting with a GCS score of 9 to 13 or a GCS score of ≤ 8 since magnetic resonance imaging (MRI) has been shown to have a high false-positive rate when used for pediatric cervical spine screening. Additionally, CT is recommended over radiography because of its superior ability to detect critical pediatric cervical spine injuries²². The panel recognizes that our recommendation of MRI after negative CT for clearance of the cervical spine in children with a GCS ≤ 8 seems contradictory and raises the question as to why MRI should not be used primarily for clearance. Availability, need for sedation, and cost, in addition to high false-positive rates for MRI screening, were considerations that led to the panel's recommendation that CT be used as a primary screening examination despite the diminished radiation exposure associated with MRI.

Another of our primary goals was to develop guidelines regarding pediatric cervical spine clearance for blunt trauma patients that can be used by various health-care providers in any setting. We believe that these methods and our

results are unique because a multidisciplinary group, including many physicians involved in the process of pediatric cervical spine clearance, developed the consensus statements and protocol.

History and Physical Examination

In 2000, Hoffman et al. validated clinical criteria to rule out CSI in adult trauma patients in an effort to reduce the number of cervical spine radiographs to clear the cervical spine²³. With use of the National Emergency X-Radiography Utilization Study (NEXUS) criteria, the authors determined that patients who meet 5 criteria (no posterior midline cervical tenderness, no focal neurologic deficit, a normal level of alertness, no evidence of intoxication, and no distracting injury) have a very low probability of injury, reporting 99% sensitivity in identifying 810 of 818 injuries. A secondary analysis of 3,065 patients who were <18 years of age concluded that the NEXUS criteria also performed well with children³. However, only 30 children in this cohort were diagnosed with CSIs; only 4 CSIs were observed in children who were <9 years of age and none were observed in children who were <2 years of age³.

Subsequent studies of CSI in children used criteria derived from NEXUS, but have sought to refine the clinical clearance parameters^{6,7,9,12}. A study conducted by the Pediatric Emergency Care Applied Research Network served as the starting point for our panel¹². This case-controlled study of 540 children from 0 to 15 years of age with CSIs identified the following 8 risk factors for CSI: altered mental status, focal neurologic findings, neck pain, torticollis, a substantial torso injury, an injury from diving, a high-risk motor-vehicle collision, and predisposing conditions involving the cervical spine¹². Our panel reached a consensus that the report of persistent neck pain, abnormal head position or difficulty with neck movement, and reported focal sensory or motor deficit were the most reliable risk factors for CSI according to the history that was obtained at the time of the initial evaluation, and that the presence of any of these precluded clinical clearance. Physical examination findings that similarly precluded clinical clearance were, by consensus, torticollis or abnormal head posture, posterior midline cervical tenderness, limited cervical range of motion, and substantial observable or known injury, such as injury to the chest, the abdomen, or the pelvis. "Substantial injury" is defined as injury that is life-threatening or warrants inpatient observation or surgery.

It should be noted that 3 important concepts that were discussed in detail by the panel helped to clarify our final recommendations. Mechanism of injury (MOI) as the only risk factor for traumatic injury and CSI is controversial. Our consensus was that the MOI alone is not a sufficient reason for imaging in patients who may be examined reliably, but a stronger consideration of imaging should be given to those who have experienced the following MOIs: diving or other mechanism by which axial load is applied to the head, "clothes-lining" (a term used to describe blunt trauma to

the head or neck by a stationary object while the patient is in motion), or a high-risk motor-vehicle collision. A high-risk motor-vehicle crash is defined as one in which a head-on collision or rollover occurred, the patient was ejected from a vehicle, a death of another passenger occurred, or the speed of collision was reported to be >55 mph (88.5 km/hr)^{12,24}. The impact of reaching a consensus that MOI alone should not be an automatic indication for CT as the initial imaging modality is worth emphasizing. Additionally, the panel agreed that the term "distracting injury" (a term defined vaguely in the original NEXUS article and frequently misapplied in the panel's experience when physical examination is performed) should be eliminated from inclusion in the algorithm²⁵. Finally, the panel chose to postpone recommendations for children with conditions that may predispose to CSI, such as genetic conditions that involve the cervical spine or previous cervical spine surgery, for future discussions.

Imaging

Most children who present for evaluation after blunt trauma have a GCS score of 14 or 15; therefore, this group has the most potential for improved patient safety through reduction of radiation exposure². For children who cannot be cleared clinically, the panel recommended that conventional radiography be the next step in evaluation²². The radiographic views that best identify injury were considered. A consensus was reached that a high-quality lateral view with the patient in a recumbent position was essential, a conclusion that may seem controversial. Evidence suggests that the ability to obtain an adequate odontoid view diminishes as age decreases, related to several factors, including the short necks of infants and young children and the inability to cooperate fully with the technician during open-mouth positioning^{26,27}. Additionally, Silva et al. found that the anteroposterior view of the cervical spine in the setting of trauma is more commonly misinterpreted compared with the lateral view²⁸. However, we are aware that a minimum of 2 views is standard practice at most institutions. The use of flexion-extension views for cervical spine clearance of a child with a GCS score of 14 or 15 and a normal radiograph was the only recommendation incorporated into the algorithm that required additional rounds of voting²⁹. Finally, the panel emphasized that interpretation of all imaging should be reviewed by an attending physician with expertise in pediatric radiographic imaging before treatment decisions are made. Any ED physicians and personnel who are unable to interpret the importance of an abnormal imaging result should consult with cervical spine trauma experts before making clinical decisions.

An important consensus recommendation was the routine use of CT for all children who have sustained blunt trauma and have a GCS score of ≤ 8 because this cohort is at higher risk for CSI compared with children with higher GCS scores^{22,29}. However, the next treatment steps for such a patient following negative CT screening were less easily agreed upon. Although some evidence suggests that CT is an adequate examination for clearance in this group, the panel

concluded that MRI of the cervical spine was the next best step in the algorithm. MRI has been shown to be sensitive in all age groups and has been recommended for the evaluation of CSI in the obtunded child in whom rapid neurologic recovery is not expected^{5,22,30,31}.

Patients with a GCS Score of 9 to 13

A unique pathway in this algorithm pertains to patients with an intermediate GCS score. Spinal immobilization and radiographic imaging are recommended initially for patients who are expected, based on the judgment of the evaluator, to return to a GCS score of 14 or 15 within 12 hours of admission. CT is performed only for obvious physical findings or when there are abnormal radiographs. A spine service consultation is recommended if, on repeat evaluation, the GCS score has not normalized or if abnormal physical findings are noted in those who have recovered to a GCS score of 14 or 15. The use of this “next-day” repeat evaluation may be a crucial step to reduce the use of CT in this cohort who, in many other protocols, would undergo CT reflexively on hospital admission.

Limitations

The process by which the consensus algorithm was created has several limitations. The Delphi method uses expert opinion and explores topics that are not fully supported with evidence-based research. It is subject to participant bias. Although the project team attempted to create a multidisciplinary panel, pediatric orthopaedic surgeons were overrepresented compared with other specialties. Additionally, this algorithmic approach was generated by physicians practicing primarily at pediatric academic institutions. The panel recognizes that clinical expertise and resources vary widely between pediatric and adult centers, making this approach difficult for some institutions to adopt fully. We also recognize that “spine service consultation” may play an important role in each pathway. The algorithm cannot delineate recommendations made by the spine service consultation because these recommendations will vary according to the personnel available at a specific institution. Finally, we acknowledge that this algorithm represents a “best-practices” consensus. We are unable, however, to predict the sensitivity, the specificity, or the rate of false-negative findings until this protocol has been implemented and studies have been initiated to collect data prospectively, or whether this algorithm can be applied safely to children of all ages, as proposed.

Conclusions

This study presents expert multidisciplinary consensus statements and an algorithm for pediatric cervical spine clearance that were created with use of a modified Delphi method. In this proposed algorithm, 3 pathways of clearance were established based on the initial GCS score. The judicious use of CT to reduce the exposure of children to ionizing radiation is emphasized. This comprehensive approach may help inform new institutional protocols and can serve as a foundation for future study.

Appendix

eA The electronic surveys that were used to determine a consensus for the comprehensive standardized guidelines for pediatric cervical spine clearance are available with the online version of this article as a data supplement at [jbjs.org](http://links.lww.com/JBJS/F27). (<http://links.lww.com/JBJS/F27>) ■

Note: The authors thank Munish Gupta for his expertise and participation in the Delphi process.

Martin J. Herman, MD¹
 Kristin O. Brown, MS¹
 Paul D. Sponseller, MD²
 Jonathan H. Phillips, MD³
 Philip M. Petrucelli, MD⁴
 Darshan J. Parikh, BS⁴
 Kush S. Mody, BS⁴
 Julie C. Leonard, MD, MPH⁵
 Matthew Moront, MD⁶
 Douglas L. Brockmeyer, MD⁷
 Richard C.E. Anderson, MD⁸
 Adam C. Alder, MD⁹
 John T. Anderson, MD¹⁰
 Robert M. Bernstein, MD¹¹
 Timothy N. Booth, MD⁹
 Bruno P. Braga, MD⁹
 Patrick J. Cahill, MD¹²
 Jeanne M. Joglar, MD⁹
 Jeffrey E. Martus, MD, MS¹³
 Jo-Ann O. Nesiama, MD⁹
 Joshua M. Pahys, MD¹⁴
 Karl E. Rathjen, MD¹⁵
 Anthony I. Riccio, MD¹⁵
 Jacob F. Schulz, MD¹⁶
 Anthony A. Stans, MD¹⁷
 Manish I. Shah, MD, MS¹⁸
 William C. Warner Jr., MD¹⁹
 Burt Yaszay, MD²⁰

¹Orthopedic Center for Children, St. Christopher’s Hospital for Children, Philadelphia, Pennsylvania

²Department of Orthopedic Surgery, The Johns Hopkins University, Baltimore, Maryland

³Center for Orthopedics, Arnold Palmer Hospital, Orlando, Florida

⁴Department of Orthopedic Surgery (P.M.P.), Drexel University College of Medicine (D.J.P., and K.S.M.), Hahnemann University Hospital, Philadelphia, Pennsylvania

⁵Division of Emergency Medicine, Department of Pediatrics, The Ohio State University College of Medicine, and Nationwide Children’s Hospital, Columbus, Ohio

⁶Nemours/Alfred I. duPont Hospital for Children, Wilmington, Delaware

⁷Department of Neurological Surgery, University of Utah, Primary Children’s Hospital, Salt Lake City, Utah

⁸Department of Neurosurgery, Columbia University, Morgan Stanley Children’s Hospital of NewYork-Presbyterian, New York, NY

⁹Division of Pediatric Surgery, Department of Surgery (A.C.A.), Departments of Radiology (T.N.B., and J.M.J.) and Neurological Surgery and Pediatrics (B.P.B.), and Division of Emergency Medicine, Department of Pediatrics (J.-A.O.N.), University of Texas Southwestern Medical Center at Dallas, Dallas, Texas

¹⁰Department of Orthopedic Surgery, Children's Mercy and University of Missouri-Kansas City School of Medicine, Kansas City, Missouri

¹¹Department of Orthopedics, Cedars-Sinai Medical Center, Los Angeles, California

¹²Division of Orthopedic Surgery, Children's Hospital of Philadelphia, Philadelphia, Pennsylvania

¹³Department of Orthopedic Surgery, Vanderbilt University Medical Center, Nashville, Tennessee

¹⁴Shriners Hospitals for Children, Philadelphia, Pennsylvania

¹⁵Department of Orthopedic Surgery, Texas Scottish Rite Hospital for Children, Dallas, Texas

¹⁶Department of Orthopedic Surgery, The Children's Hospital at Montefiore, Bronx, New York

¹⁷Department of Orthopedic Surgery, Mayo Clinic, Rochester, Minnesota

¹⁸Section of Emergency Medicine, Department of Pediatrics, Baylor College of Medicine, Houston, Texas

¹⁹Department of Orthopedic Surgery, University of Tennessee – Campbell Clinic and Le Bonheur Children's Hospital, Memphis, Tennessee

²⁰Department of Orthopedics, Rady Children's Hospital and University of California-San Diego Medical Center, San Diego, California

E-mail address for M.J. Herman: Martin.herman@americanacademic.com

ORCID iD for M.J. Herman: [0000-0002-3083-8926](https://orcid.org/0000-0002-3083-8926)

ORCID iD for K.O. Brown: [0000-0002-7067-1622](https://orcid.org/0000-0002-7067-1622)

ORCID iD for P.D. Sponseller: [0000-0003-2934-6374](https://orcid.org/0000-0003-2934-6374)

ORCID iD for J.H. Phillips: [0000-0002-0647-7630](https://orcid.org/0000-0002-0647-7630)

ORCID iD for P.M. Petrucelli: [0000-0001-6630-8487](https://orcid.org/0000-0001-6630-8487)

ORCID iD for D.J. Parikh: [0000-0002-2930-429X](https://orcid.org/0000-0002-2930-429X)

ORCID iD for K.S. Mody: [0000-0002-5556-6728](https://orcid.org/0000-0002-5556-6728)

ORCID iD for J.C. Leonard: [0000-0003-3670-1944](https://orcid.org/0000-0003-3670-1944)

ORCID iD for M. Moront: [0000-0001-6347-7787](https://orcid.org/0000-0001-6347-7787)

ORCID iD for D.L. Brockmeyer: [0000-0001-8602-0931](https://orcid.org/0000-0001-8602-0931)

ORCID iD for R.C.E. Anderson: [0000-0001-6808-0201](https://orcid.org/0000-0001-6808-0201)

ORCID iD for A.C. Alder: [0000-0002-4877-9012](https://orcid.org/0000-0002-4877-9012)

ORCID iD for J.T. Anderson: [0000-0002-2866-1500](https://orcid.org/0000-0002-2866-1500)

ORCID iD for R.M. Bernstein: [0000-0002-9370-778X](https://orcid.org/0000-0002-9370-778X)

ORCID iD for T.N. Booth: [0000-0003-0757-0957](https://orcid.org/0000-0003-0757-0957)

ORCID iD for B.P. Braga: [0000-0001-6528-0048](https://orcid.org/0000-0001-6528-0048)

ORCID iD for P.J. Cahill: [0000-0002-7129-1007](https://orcid.org/0000-0002-7129-1007)

ORCID iD for J.M. Joglar: [0000-0002-1496-6768](https://orcid.org/0000-0002-1496-6768)

ORCID iD for J.E. Martus: [0000-0002-5768-6715](https://orcid.org/0000-0002-5768-6715)

ORCID iD for J.-A.O. Nesiama: [0000-0002-2666-6834](https://orcid.org/0000-0002-2666-6834)

ORCID iD for J.M. Pahys: [0000-0001-8965-354X](https://orcid.org/0000-0001-8965-354X)

ORCID iD for K.E. Rathjen: [0000-0003-3747-7593](https://orcid.org/0000-0003-3747-7593)

ORCID iD for A.I. Ricci: [0000-0002-8386-9312](https://orcid.org/0000-0002-8386-9312)

ORCID iD for J.F. Schulz: [0000-0002-6711-9642](https://orcid.org/0000-0002-6711-9642)

ORCID iD for A.A. Stans: [0000-0002-1072-3072](https://orcid.org/0000-0002-1072-3072)

ORCID iD for M.I. Shah: [0000-0003-0886-8747](https://orcid.org/0000-0003-0886-8747)

ORCID iD for W.C. Warner Jr.: [0000-0003-1440-0825](https://orcid.org/0000-0003-1440-0825)

ORCID iD for B. Yaszay: [0000-0001-9236-2284](https://orcid.org/0000-0001-9236-2284)

References

- Mohseni S, Talving P, Branco BC, Chan LS, Lustenberger T, Inaba K, Bass M, Demetriades D. Effect of age on cervical spine injury in pediatric population: a National Trauma Data Bank review. *J Pediatr Surg*. 2011 Sep;46(9):1771-6.
- Polk-Williams A, Carr BG, Blinman TA, Masiakos PT, Wiebe DJ, Nance ML. Cervical spine injury in young children: a National Trauma Data Bank review. *J Pediatr Surg*. 2008 Sep;43(9):1718-21.
- Viccellio P, Simon H, Pressman BD, Shah MN, Mower WR, Hoffman JR; NEXUS Group. A prospective multicenter study of cervical spine injury in children. *Pediatrics*. 2001 Aug;108(2):E20.
- Pannu GS, Shah MP, Herman MJ. Cervical spine clearance in pediatric trauma centers: the need for standardization and an evidence-based protocol. *J Pediatr Orthop*. 2017 Apr/May;37(3):e145-9.
- Frank JB, Lim CK, Flynn JM, Dormans JP. The efficacy of magnetic resonance imaging in pediatric cervical spine clearance. *Spine (Phila Pa 1976)*. 2002 Jun 1;27(11):1176-9.
- Anderson RC, Kan P, Vanaman M, Rubsam J, Hansen KW, Scaife ER, Brockmeyer DL. Utility of a cervical spine clearance protocol after trauma in children between 0 and 3 years of age. *J Neurosurg Pediatr*. 2010 Mar;5(3):292-6.
- Sun R, Skeete D, Wetjen K, Lilienthal M, Liao J, Madsen M, Lancaster G, Shilyansky J, Choi K. A pediatric cervical spine clearance protocol to reduce radiation exposure in children. *J Surg Res*. 2013 Jul;183(1):341-6. Epub 2013 Jan 16.
- Anderson RC, Scaife ER, Fenton SJ, Kan P, Hansen KW, Brockmeyer DL. Cervical spine clearance after trauma in children. *J Neurosurg*. 2006 Nov;105(5)(Suppl):361-4.
- Eubanks JD, Gilmore A, Bess S, Cooperman DR. Clearing the pediatric cervical spine following injury. *J Am Acad Orthop Surg*. 2006 Sep;14(9):552-64.
- Hannon M, Mannix R, Dorney K, Mooney D, Hennelly K. Pediatric cervical spine injury evaluation after blunt trauma: a clinical decision analysis. *Ann Emerg Med*. 2015 Mar;65(3):239-47. Epub 2014 Oct 16.
- Jaffe DM, Binns H, Radkowski MA, Barthel MJ, Engelhard HH 3rd. Developing a clinical algorithm for early management of cervical spine injury in child trauma victims. *Ann Emerg Med*. 1987 Mar;16(3):270-6.
- Leonard JC, Kuppermann N, Olsen C, Babcock-Cimpello L, Brown K, Mahajan P, Adelgais KM, Anders J, Borgialli D, Donoghue A, Hoyle JD Jr, Kim E, Leonard JR, Lillis KA, Nigrovic LE, Powell EC, Rebella G, Reeves SD, Rogers AJ, Stankovic C, Teshome G, Jaffe DM; Pediatric Emergency Care Applied Research Network. Factors associated with cervical spine injury in children after blunt trauma. *Ann Emerg Med*. 2011 Aug;58(2):145-55. Epub 2010 Oct 29.
- Fletcher ND, Glotzbecker MP, Marks M, Newton PO; Harms Study Group. Development of consensus-based best practice guidelines for postoperative care following posterior spinal fusion for adolescent idiopathic scoliosis. *Spine (Phila Pa 1976)*. 2017 May 1;42(9):E547-54.
- Vitale MG, Riedel MD, Glotzbecker MP, Matsumoto H, Roye DP, Akbarnia BA, Anderson RCE, Brockmeyer DL, Emans JB, Erickson M, Flynn JM, Lenke LG, Lewis SJ, Luhmann SJ, McLeod LM, Newton PO, Nyquist AC, Richards BS 3rd, Shah SA, Skaggs DL, Smith JT, Sponseller PD, Sucato DJ, Zeller RD, Saiman L. Building consensus: development of a best practice guideline (BPG) for surgical site infection (SSI) prevention in high-risk pediatric spine surgery. *J Pediatr Orthop*. 2013 Jul-Aug;33(5):471-8.
- Linstone HA, Turoff M. The Delphi method: techniques and applications. Reading: Addison-Wesley Educational Publishers; 1975.
- Holmes JF, Palchak MJ, MacFarlane T, Kuppermann N. Performance of the pediatric Glasgow coma scale in children with blunt head trauma. *Acad Emerg Med*. 2005 Sep;12(9):814-9.
- Teasdale G, Jennett B. Assessment of coma and impaired consciousness. A practical scale. *Lancet*. 1974 Jul 13;2(7872):81-4.
- Avellino AM, Mann FA, Grady MS, Chapman JR, Ellenbogen RG, Alden TD, Mirza SK. The misdiagnosis of acute cervical spine injuries and fractures in infants and children: the 12-year experience of a level I pediatric and adult trauma center. *Childs Nerv Syst*. 2005 Feb;21(2):122-7. Epub 2004 Dec 18.
- Hale AT, Alvarado A, Bey AK, Pruthi S, Mencio GA, Bonfield CM, Martus JE, Naftel RP. X-ray vs. CT in identifying significant C-spine injuries in the pediatric population. *Childs Nerv Syst*. 2017 Nov;33(11):1977-83. Epub 2017 Jun 27.
- Brenner DJ, Hall EJ. Computed tomography—an increasing source of radiation exposure. *N Engl J Med*. 2007 Nov 29;357(22):2277-84.
- Brenner D, Elliston C, Hall E, Berdon W. Estimated risks of radiation-induced fatal cancer from pediatric CT. *AJR Am J Roentgenol*. 2001 Feb;176(2):289-96.

- 22.** Brockmeyer DL, Ragel BT, Kestle JR. The pediatric cervical spine instability study. A pilot study assessing the prognostic value of four imaging modalities in clearing the cervical spine for children with severe traumatic injuries. *Childs Nerv Syst.* 2012 May;28(5):699-705.
- 23.** Hoffman JR, Mower WR, Wolfson AB, Todd KH, Zucker MI; National Emergency X-Radiography Utilization Study Group. Validity of a set of clinical criteria to rule out injury to the cervical spine in patients with blunt trauma. *N Engl J Med.* 2000 Jul 13; 343(2):94-9.
- 24.** Leonard JC, Jaffe DM, Olsen CS, Kuppermann N. Age-related differences in factors associated with cervical spine injuries in children. *Acad Emerg Med.* 2015 Apr;22(4):441-6. Epub 2015 Mar 16.
- 25.** Rose MK, Rosal LM, Gonzalez RP, Rostas JW, Baker JA, Simmons JD, Frotan MA, Brevard SB. Clinical clearance of the cervical spine in patients with distracting injuries: it is time to dispel the myth. *J Trauma Acute Care Surg.* 2012 Aug;73(2): 498-502.
- 26.** Buhs C, Cullen M, Klein M, Farmer D. The pediatric trauma C-spine: is the 'odontoid' view necessary? *J Pediatr Surg.* 2000 Jun;35(6):994-7.
- 27.** Swischuk LE, John SD, Hendrick EP. Is the open-mouth odontoid view necessary in children under 5 years? *Pediatr Radiol.* 2000 Mar;30(3):186-9.
- 28.** Silva CT, Doria AS, Traubici J, Moineddin R, Davila J, Shroff M. Do additional views improve the diagnostic performance of cervical spine radiography in pediatric trauma? *AJR Am J Roentgenol.* 2010 Feb;194(2):500-8.
- 29.** Pieretti-Vanmarcke R, Velmahos GC, Nance ML, Islam S, Falcone RA Jr, Wales PW, Brown RL, Gaines BA, McKenna C, Moore FO, Goslar PW, Inaba K, Barmparas G, Scaife ER, Metzger RR, Brockmeyer DL, Upperman JS, Estrada J, Lanning DA, Rasmussen SK, Danielson PD, Hirsh MP, Consani HF, Stylianos S, Pineda C, Norwood SH, Bruch SW, Drongowski R, Barraco RD, Pasquale MD, Hussain F, Hirsch EF, McNeely PD, Fallat ME, Foley DS, Iocono JA, Bennett HM, Waxman K, Kam K, Bakhos L, Petrovick L, Chang Y, Masiakos PT. Clinical clearance of the cervical spine in blunt trauma patients younger than 3 years: a multi-center study of the American Association for the Surgery of Trauma. *J Trauma.* 2009 Sep;67(3):543-9; discussion 549-50.
- 30.** Flynn JM, Closkey RF, Mahboubi S, Dormans JP. Role of magnetic resonance imaging in the assessment of pediatric cervical spine injuries. *J Pediatr Orthop.* 2002 Sep-Oct;22(5):573-7.
- 31.** Qualls D, Leonard JR, Keller M, Pineda J, Leonard JC. Utility of magnetic resonance imaging in diagnosing cervical spine injury in children with severe traumatic brain injury. *J Trauma Acute Care Surg.* 2015 Jun;78(6):1122-8.