

# QUAIN'S ANATOMY

---

E. A. SCHÄFER & G. D. THANE

VOL. III. PT. I.

THE SPINAL CORD AND BRAIN

---

E. A. SCHÄFER

M15205



22101445744



D. m. 19/9



Digitized by the Internet Archive  
in 2014 with funding from  
Wellcome Library



QUAIN'S  
ELEMENTS OF ANATOMY

EDITED BY

EDWARD ALBERT SCHÄFER, F.R.S.

PROFESSOR OF PHYSIOLOGY AND HISTOLOGY IN UNIVERSITY COLLEGE, LONDON,

AND

GEORGE DANCER THANE,

PROFESSOR OF ANATOMY IN UNIVERSITY COLLEGE, LONDON.

IN THREE VOLUMES.

VOL. III.—PART I.

THE SPINAL CORD AND BRAIN.

BY PROFESSOR SCHÄFER.

ILLUSTRATED BY 139 ENGRAVINGS.

Tenth Edition.

LONDON:  
LONGMANS, GREEN, AND CO.

AND NEW YORK: 15 EAST 16<sup>th</sup> STREET.

1893.

	PAGE		PAGE
THE CEREBRAL HEMISPHERES— <i>continued.</i>		MEMBRANES OF BRAIN AND SPINAL CORD	181
Variations in Fissures and Convolutions . . . . .	161	Dura Mater . . . . .	181
Causation of Gyri and Sulci . . . . .	162	Subdural space . . . . .	184
Structure of White Matter . . . . .	163	Pia Mater . . . . .	184
Structure of Grey Matter . . . . .	166	Arachnoid Membrane . . . . .	187
Differences of structure in different parts . . . . .	172	Subarachnoid Space . . . . .	187
MEASUREMENTS OF THE BRAIN . . . . .	176	Ligamentum Denticulatum . . . . .	189
Dimensions . . . . .	176	Glandule Pacchionii . . . . .	190
Extent of Grey Cortex . . . . .	176	BLOOD-VESSELS OF BRAIN AND SPINAL CORD . . . . .	191
Thickness of Cortex . . . . .	177	Spinal Cord . . . . .	191
Weight . . . . .	178	Brain . . . . .	193
		LYMPH-PATHS OF BRAIN AND SPINAL CORD	198

# NEUROLOGY.

## THE CEREBRO-SPINAL AXIS.

By E. A. SCHÄFER.

THE *cerebro-spinal axis* is divided into the *brain* or *encephalon*, the enlarged part within the skull, and the *spinal cord* within the vertebral canal. It is symmetrical in form, consisting of a right and a left half, separated to some extent by fissures and cavities, but united by various portions of white and grey nervous substance which cross from one side to the other, and

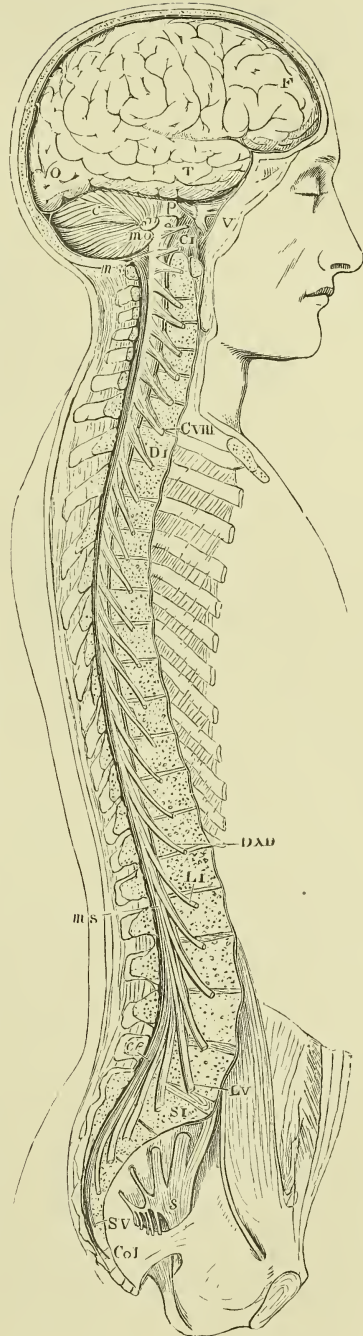
Fig. 1.—VIEW OF THE CEREBRO-SPINAL AXIS. (After Bourguery.)  $\frac{1}{2}$

The right half of the cranium and trunk of the body has been removed by a vertical section; the membranes of the right side of the brain and spinal cord have been cleared away, and the roots and first part of the fifth and twelfth cranial nerves, and of all the spinal nerves of the right side, have been dissected out and laid separately on the wall of the skull and on the several vertebrae opposite to the place of their natural exit from the cranio-spinal cavity.

F, T, O, frontal, temporal and occipital lobes of cerebrum; C, cerebellum; P, pons Varolii; *m o*, medulla oblongata; *m s*, *m s*, point to the upper and lower extremities of the spinal marrow; *c e*, on the last lumbar vertebral spine, marks the cauda equina; v, the three principal branches of the nervus trigeminus; C I, the sub-occipital or first cervical nerve; C VIII, the eighth or lowest cervical nerve; D I, the first dorsal nerve; D XII, the last dorsal; L I, the first lumbar nerve; L V, the last lumbar; S I, the first sacral nerve; S V, the fifth; Co I, the coccygeal nerve; *s*, the left sacral plexus.

form the *commissures* of the brain and spinal cord.

The cerebro-spinal axis is enveloped within the skull and vertebral canal by three connective tissue membranes, between which are spaces occupied by a clear fluid (cerebro-spinal fluid). These envelopes, which will be described later, are, 1st, a firm fibrous membrane named the *dura mater*, which is placed most externally; 2nd, a delicate membrane called the *arachnoid*; and, 3rd, a highly vascular membrane named the *pia mater*, which is next to, and closely invests the surface of the brain and cord.



## SPINAL CORD.

The **spinal cord** or **spinal marrow** (*medulla spinalis*) is about 18 inches (45 centimeters) long, and extends from the margin of the foramen magnum of the occipital bone to about the lower part of the body of the first lumbar vertebra. Above, it is continued into the bulb (*medulla oblongata*); below, it tapers conically and ends in a slender filament, the *filum terminale* or *central ligament* of the spinal cord.

Although the cord usually ends near the lower border of the body of the first lumbar vertebra, its termination is sometimes a little above or below that point, as

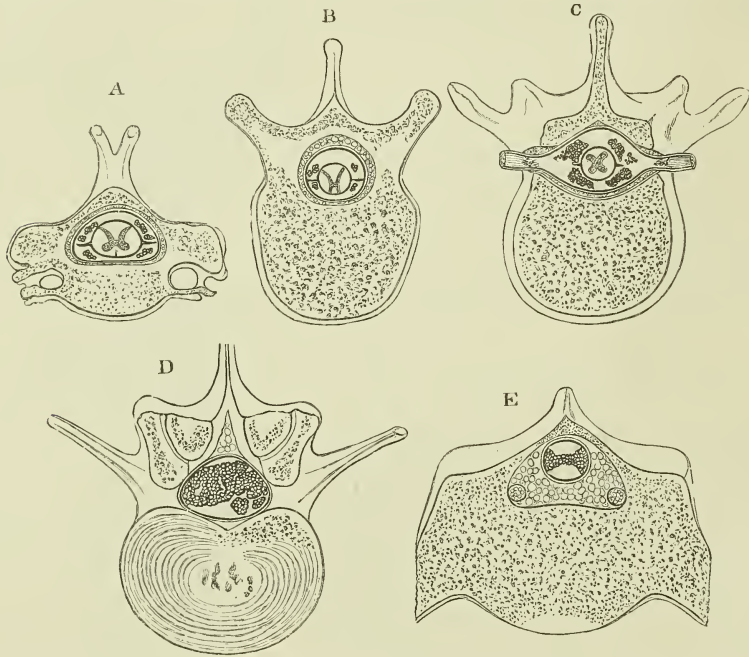


Fig. 2.—SECTIONS SHOWING THE GENERAL RELATIONS OF THE SPINAL CORD TO THE INCLOSING AND OF THIS TO THE VERTEBRAL CANAL. (Key and Retzius.)

A, through the fifth cervical vertebra; B, through the tenth dorsal vertebra; C, through the first lumbar vertebra and the foramen of exit of the twelfth dorsal nerve-roots; D, through the disk between the second and third lumbar vertebrae; E, through the first sacral vertebra. In A, B, and C, the cord, covered by pia mater, is seen in the centre, with the ligamentum denticulatum attached to it on either side; the nerve-roots on either side form small groups which, since they pass obliquely downwards to their foramina of exit, are cut across; the dura matral sheath is separated by a considerable space from the cord, and by a quantity of loose areolar and fatty tissue from the wall of the vertebral canal. This tissue is in smaller amount in C. D and E are below the termination of the cord, and show sections of the nerve-bundles of the cauda equina within the dural sheath, which is very large in D, but comparatively small in E, the vertebral canal in the latter being largely occupied by adipose tissue. In this are seen the sections of two large veins. The arachnoid is not represented in any of these sections.

opposite to the last dorsal or to the second lumbar vertebra. The position of the lower end of the cord also varies according to the state of curvature of the vertebral column, in the flexion forwards of which the end of the cord is slightly raised. In the fœtus, at an early period, the embryonic cord occupies the whole length of the vertebral canal; but, after the third month, the canal and the roots of the lumbar and sacral nerves begin to grow more rapidly than the cord itself, so that at birth the lower end reaches only to the third lumbar vertebra. After birth the thoracic part of the cord lengthens proportionately more than the other parts, so that in the infant the roots of the lower dorsal nerves come off relatively higher up than at a later age (Pfitzner).



The cord is enclosed in the vertebral canal within a sheath (*theca*) considerably longer and larger than itself, formed by the dura mater, and separated from the walls of the canal by venous plexuses, and much loose areolar tissue (fig. 2). The cavity of the sheath between the pia mater and the dura mater is occupied by cerebro-spinal fluid, and is divided by the curtain-like arachnoid into the spaces, subdural and sub-arachnoid, above mentioned. Within the latter the cord, covered closely by pia mater, is suspended, being kept in position by a ligament on each side (ligamentum denticulatum), which fixes it at frequent intervals to its sheath, and by the roots of the spinal nerves which pass across the space from the surface of the cord towards the intervertebral foramina.

The spinal nerves come off in pairs at intervals along the cord. The portion of spinal cord to which each pair of roots is attached is termed a "segment," but there is in man and mammals complete continuity from segment to segment, and not even a sign of constriction between them. Each nerve is attached to the surface of the cord by two roots, one of which is anterior or ventral and non-gangliated,<sup>1</sup> the other is posterior or dorsal and is provided with a ganglion. The uppermost two or three nerve-roots cross the subarachnoid and subdural spaces nearly horizontally (figs. 1 and 5), but the rest pass across with a more and more oblique downward inclination until their direction is almost vertical, and indeed the lower part of the theca below the termination of the cord (fig. 2, D, E), is occupied by the descending roots of the lumbar and sacral nerves, passing to the foramina between the corresponding vertebræ. This mass of nerve-roots, which conceals the delicate filum terminale, is named the *cauda equina* (figs. 4, 5, 6).

The relation between the spines of the vertebræ and the places of attachment of the nerve-roots to the cord is illustrated by the appended diagram (fig. 3) from Reid, which is founded upon observations made on six adult subjects. From this it will be seen that there is a much larger amount of variation than might have been supposed. This is especially the case with the dorsal nerve-roots, some of which show variations of their position of origin extending over a distance covered by as many as three spinous processes. Certain general facts can, however, be made out which are not without practical interest. Amongst these are the position of the second cervical nerve—opposite the arch of the atlas; that of the first dorsal or thoracic nerve, opposite the sixth or seventh cervical spine; that of the seventh thoracic nerve, opposite the fourth or fifth dorsal spines, and of the sacral nerves, the range of which extends from the eleventh dorsal to the first lumbar spine. The line of origin of the sacral nerves very nearly corresponds in vertical extent with the body of the first lumbar vertebra.

No doubt this variation is largely accounted for by the variations in length and obliquity of the spinous processes of the vertebræ, and accordingly we find that there is least fluctuation of relative position at the top and bottom of the series. The anterior and posterior (ventral and dorsal) nerve-roots belonging to the same segment of the cord leave it practically at the same level (Reid).

The cervical enlargement (see next page) about corresponds in vertical extent with the spines of the cervical vertebræ, while the lumbar enlargement corresponds with the spines of the tenth, eleventh, and twelfth thoracic and the interval between the last named and the first lumbar.

In section the cord is nearly circular, especially in the thoracic region, but it is somewhat flattened before and behind. In the thoracic region, it measures about ten millimeters (0.4 inch) from side to side, and about eight from before back. The

<sup>1</sup> Some animals (*e.g.*, cat) have a few ganglion-cells interpolated amongst the fibres of the anterior or ventral nerve-roots. Hoche finds that in the anterior roots of the lower lumbar and sacral nerves of man, just at their junction with the cord, ganglion-cells, like those of the posterior root, are almost constantly present, lying singly or in groups, and connected with some of the issuing nerve-fibres by a T-shaped junction.

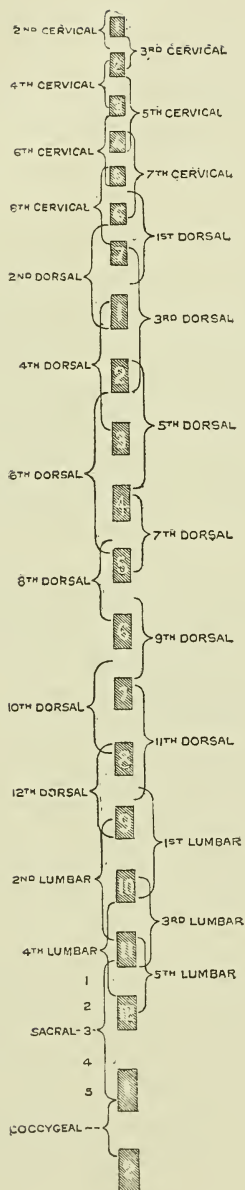


Fig. 3.—DIAGRAM SHOWING THE VARYING RELATIONS OF THE ROOT-ORIGINS OF THE SPINAL NERVES TO THE SPINES OF THE VERTEBRÆ. (After R. W. Reid.)

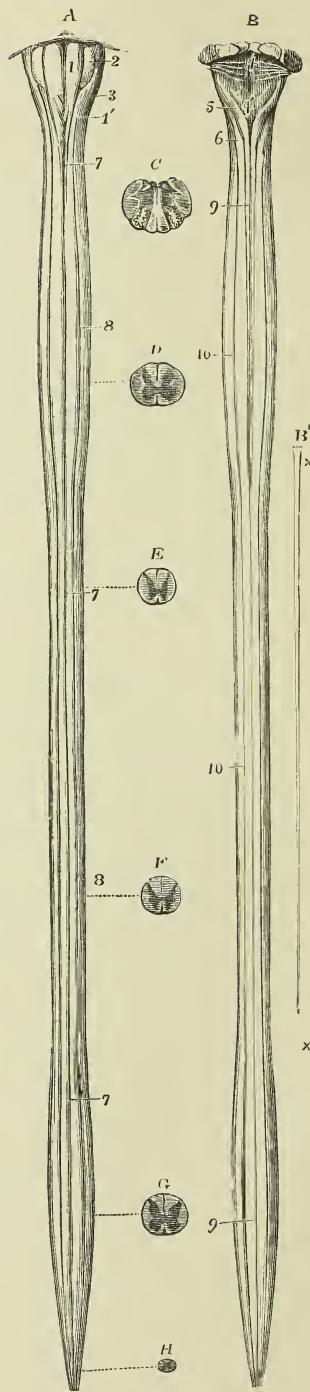


Fig. 4.—A, VENTRAL (ANTERIOR) AND B, DORSAL (POSTERIOR) VIEWS OF THE MEDULLA OBLONGATA AND SPINAL CORD WITH SECTIONS. (Allen Thomson.)  $\frac{1}{2}$

The cord has been divested of its membranes and of the roots of the nerves. The filiform prolongation, represented separately in B', has been removed. C, a transverse section through the middle of the

medulla oblongata; D, a section through the middle of the cervical enlargement of the cord; E, through the upper dorsal region; F, through the lower dorsal region; G, through the middle of the lumbar enlargement; and H, near the lower end of the conus medullaris.

1 to 6 refer to parts of the medulla oblongata; the remaining numbers to parts of the spinal cord.

1, pyramids; 1', their decussation; 2, olivary bodies; 3, lateral columns; 4, fourth ventricle; 4', calamus scriptorius; 5, funiculus gracilis; 6, funiculus cuneatus; 7, 7, anterior median fissure of the spinal cord; 8, 8, posterolateral groove corresponding to the attachments of the posterior nerve-roots; 9, 9, posterior median fissure; ×, tapering extremity of the cord; ×, ×, in B', filum terminale.

cord is not, however, of uniform diameter throughout, but is swollen out in the cervical and lower dorsal regions, two enlargements being thereby produced—an upper or cervical (brachial), and a lower or lumbar (crural) (fig. 4). Of these the cervical enlargement is of greater size and extent than the lumbar. It extends from the upper limit of the cord to the body of the first or second thoracic vertebra; it is largest opposite the fifth or sixth cervical vertebra, where it measures from 13 to 14 mm. from side to side. The lower or lumbar enlargement begins at the tenth thoracic vertebra, is largest opposite the twelfth (11—13 mm. across), and from this point becomes gradually smaller; its antero-posterior diameter is more nearly equal to the

Fig. 5.—DIAGRAMMATIC VIEW FROM BEFORE OF THE SPINAL CORD AND MEDULLA OBLONGATA, INCLUDING THE ROOTS OF THE SPINAL AND SOME OF THE CRANIAL NERVES, AND ON ONE SIDE, THE GANGLIATED CHAIN OF THE SYMPATHETIC. (Allen Thomson.) †.

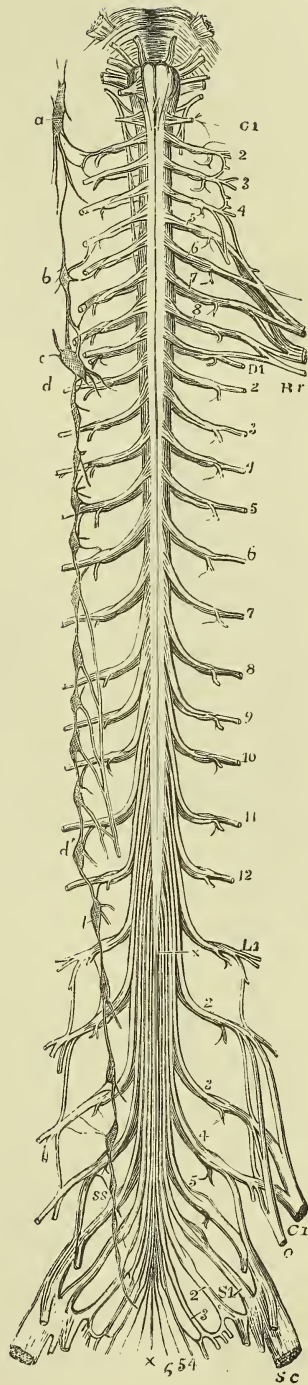
The spinal nerves are enumerated in order on the right side of the figure. *Br*, brachial plexus; *Cr*, anterior crural, *O*, obturator, and *Se*, great sciatic nerves, coming off from lumbosacral plexus; ×, ×, filum terminale.

*a*, *b*, *c*, superior, middle and inferior cervical ganglia of the sympathetic, the last united with the first thoracic, *d*; *d'*, the eleventh thoracic ganglion; *l*, the twelfth thoracic (or first lumbar); below *ss*, the chain of sacral ganglia.

transverse than is the case in the cervical enlargement. Below the lumbar enlargement the cord tapers in the form of a cone (*conus medullaris*), from the apex of which the small filiform prolongation is continued downwards.

The cervical and lumbar enlargements have an evident relation to the large size of the nerves which supply the upper and lower limbs, and which are connected with those regions of the cord. At the commencement of its development in the embryo the spinal cord is destitute of these enlargements, which, in their first appearance and subsequent progress, correspond with the growth of the limbs.

The **terminal filament** (filum terminale, central ligament) (fig. 6, *b*, *b*) descends





in the middle line amongst the nerves composing the cauda equina, and, reaching the lower end of the sheath opposite to the second sacral vertebra, perforates the dura mater, and receiving an investment from it, passes on to be attached with this to the periosteum of the lower end of the sacral canal, or to the back of the coccyx. It is a prolongation of the pia mater, enclosing for about half its length an enlarged continuation of the central canal of the cord (see p. 9), with a little grey matter near the upper end. Below the termination of the canal, the filum is mainly composed of connective tissue, with blood-vessels prolonged from the anterior spinal vessels, and on either side there run in it three or four small bundles of medullated nerve-fibres, some of which have a few ganglion-cells. These nerve-bundles are regarded by Rauber as representing rudimentary coccygeal nerve-roots. They have no connection with the coccygeal nerves proper.

The filum terminale is distinguished by its silvery hue from the nerves among which it lies.

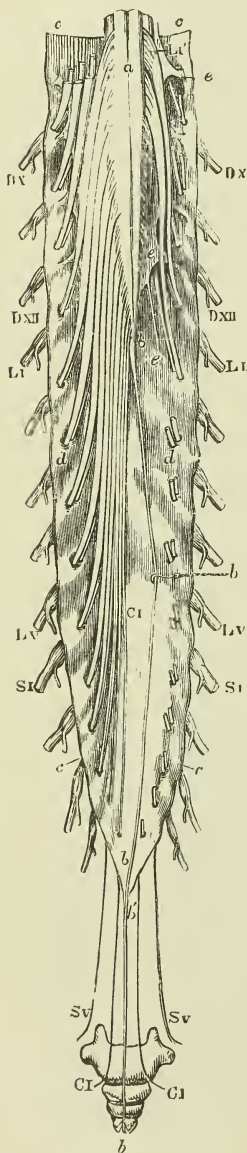


Fig. 6.—VIEW FROM BEHIND OF THE LOWER END OF THE SPINAL CORD WITH THE CAUDA EQUINA AND DURAL SHEATH. (Allen Thomson.)  $\frac{1}{2}$

The sheath has been opened from behind and stretched towards the sides; on the left side all the roots of the nerves are entire; on the right side both roots of the first and second lumbar nerves are entire, while the rest have been divided close to the place of their passage through the sheath. The bones of the coccyx are sketched in their natural relative position to show the place of the filum terminale and the lowest nerves.

*a*, placed on the posterior median fissure at the middle of the lumbar enlargement of the cord; *b, b'*, the terminal filament, drawn slightly aside by a hook at its middle, and descending within the dural sheath; *b', b'*, its prolongation beyond the sheath and upon the back of the coccygeal bones; *e*, the dural sheath; *d*, double foramina in this for the separate passage of the ventral and dorsal (anterior and posterior) roots of each of the nerves; *e*, ligamentum denticulatum; *Dx*, and *Dxii*, the tenth and twelfth thoracic (dorsal) nerves; *Lx*, and *Lv*, the first and fifth lumbar nerves; *Sx*, and *Sv*, the first and fifth sacral nerves; *C1*, the coccygeal nerve.

**Fissures.**—The spinal cord is incompletely divided into a right and left half by two fissures which pass in from the middle of the anterior and posterior surfaces, and penetrate through the greater part of its thickness. Of these two *median fissures* the *anterior* or *ventral* (fig. 7, 1) is wider and therefore more distinct than the posterior or dorsal, although it does not, in most parts, penetrate to more than one-third the thickness of the cord, while the posterior fissure may reach more than half-way from back to front. The anterior contains a fold of the pia mater and also many blood-vessels, which are thus conducted to the centre of the cord. At the bottom of this fissure is a transverse connecting portion of white substance named the *anterior* or *white commissure*.

The *posterior* (fig. 7, 2) is not an actual fissure, for, although the lateral halves of the cord are quite separate dorsally, there is not so much a fold of the pia mater between them, as merely a septum of connective tissue and blood-vessels prolonged from that membrane which

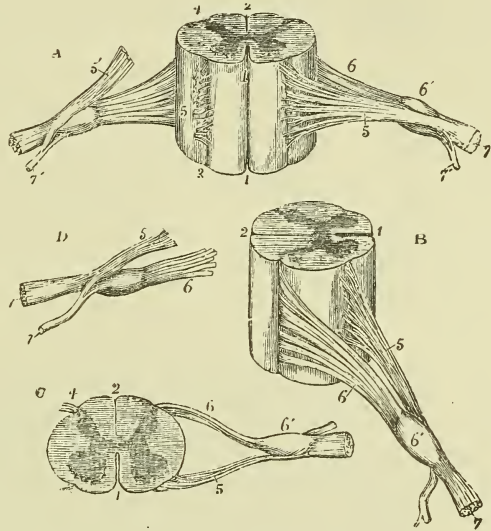


passes in nearly to the centre of the cord (*posterior septum*). Its position is marked, especially in the lumbar enlargement and in the cervical region, by a superficial furrow. At its end is the *posterior* or *grey commissure*.

Besides these two median fissures, a lateral furrow is seen on each side of the cord, corresponding with the line of attachment of the posterior roots of the spinal nerves. It is named the *postero-lateral groove* (fig. 7, c, 4). Each lateral half of the cord is

Fig. 7.—DIFFERENT VIEWS OF A PORTION OF THE SPINAL CORD FROM THE CERVICAL REGION WITH THE ROOTS OF THE NERVES. Slightly enlarged. (Allen Thomson.)

In A, the anterior or ventral surface of the specimen is shown, the anterior nerve-root of the right side having been divided; in B, a view of the right side is given; in C, the upper surface is shown; in D, the nerve-roots and ganglion are shown from below. 1, the anterior median fissure; 2, posterior median fissure; 3, antero-lateral impression, over which the bundles of the anterior nerve-root are seen to spread (this impression is too distinct in the figure): 4, postero-lateral groove into which the bundles of the posterior root are seen to sink; 5, anterior root; 5', in A, the anterior root divided and turned upwards; 6, the posterior root, the fibres of which pass into the ganglion, 6'; 7, the united or compound nerve; 7', the posterior primary branch, seen in A and D to be derived in part from the anterior and in part from the posterior root.



divided superficially by the postero-lateral groove into a posterior and an antero-lateral part. The attachment of the anterior roots, however, subdivides the latter into anterior and lateral portions.

An antero-lateral groove has sometimes been described in the line of origin of the anterior roots of the nerves, but usually has no real existence. The fibres of these roots in fact, unlike the posterior, do not dip into the spinal cord in one narrow line, but spread over a space of some breadth.

On the posterior surface of the cord, at least in the upper part, there is on each side of the middle line a slightly marked longitudinal furrow (fig. 11) situated about one millimeter from the posterior median fissure, and marking off, in the cervical region, a slender tract, the *postero-mesial column*. This sulcus, which is better marked in some individuals than in others, is termed the *posterior intermediate furrow*. An incomplete connective tissue septum (*posterior intermediate septum*) extends from the furrow into the white substance of the cord. The larger remaining part of the posterior column is termed the *postero-lateral column*.

#### INTERNAL STRUCTURE OF THE SPINAL CORD: RELATIVE PROPORTIONS OF GREY AND WHITE MATTER.

**Grey matter.**—When the spinal cord is cut across (figs. 8, 11, 14) it is seen that the grey matter occupies the more central parts, being almost completely enclosed by the white matter. The grey matter appears in the form of two irregularly crescentic portions on either side, united across the middle line by the posterior grey commissure before mentioned, so that its section may be compared in shape to the letter H.

The concave side of each lateral crescent faces outward, and in consequence of the depth of the posterior median fissure the commissure of grey matter joins the crescents nearer their anterior than their posterior ends, except in the lumbar region of the cord.

The two horns or cornua of each crescent are named from their position anterior and posterior (or, better, ventral and dorsal); the *anterior* or *ventral horn* (fig. 8, *a. c.*) is the shorter and broader, and is everywhere separated from the surface of the cord by white matter which is traversed by the bundles of the anterior roots at the part where these enter the cord. The *posterior* or *dorsal horn* (*p. c.*) is longer and narrower, and tapers almost to a point (*apex cornu posterioris*), which closely

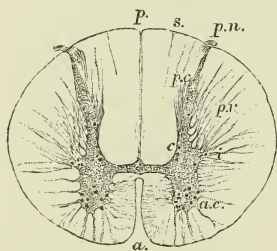


Fig. 8.—SECTION OF THE SPINAL CORD IN THE UPPER PART OF THE DORSAL REGION. (E. A. S.)  $\frac{1}{4}$

*a.*, anterior median fissure; *p.*, posterior-median fissure; *p. n.*, posterior nerve-roots entering at the postero-lateral groove; *a. c.*, anterior cornu of grey matter; *p. c.*, posterior cornu; *i.*, intermedio-lateral tract (lateral cornu); *p. r.*, processus reticularis; *c.*, posterior vesicular column of Clarke; *s.*, pia-matral septum forming the lateral boundary of the postero-mesial column.

approaches the external surface of the cord at the postero-lateral groove, with which it is connected by a process of the superficial neuroglia which here dips in towards the horn, but is interrupted by a stratum of fine nerve-fibres known as the *marginal bundle*. The posterior horn is slightly narrowed at its base (*cervix cornu*); from that place it gradually expands into the main part of the horn (*caput cornu*), and from this it tapers in the way just noticed. Near its tip the caput cornu has a peculiar semi-transparent aspect, an appearance due to the *substantia gelatinosa* of Rolando (fig. 14), which forms a kind of cap to the cornu. The part of the grey crescent between the two horns is known as the *intermediate grey substance* (Gowers).

Near the middle of the outer surface of each crescent the grey matter is less sharply marked off than elsewhere from the white matter; portions of grey matter extending into the lateral white column and uniting with one another into what in sections appear like a network enclosing portions of white substance (*p. r.*). This is known as the *processus reticularis*; it is best marked in the cervical region (fig. 14). At the postero-lateral part of the anterior horn, immediately in front of the processus reticularis, the grey matter forms in the upper dorsal (thoracic) region (fig. 11, D 1) a somewhat pointed triangular projection, which is sometimes distinguished as the *lateral horn* but is better known as the *intermedio-lateral tract* of Lockhart Clarke (*intermediate process* of Gowers) (fig. 8, *i.*). Above, in the cervical region, this blends with and forms part of the enlarged anterior horn. This is also the case in the lumbar enlargement, but in the sacral region the lateral horn again becomes distinct.

The grey crescents vary in form in different parts of the cord (see fig. 9). In the dorsal (thoracic) region both anterior and posterior cornua are narrow. In the cervical and lumbar regions the anterior cornua are large and broad. The posterior cornua are narrow in the cervical and thoracic, but very broad in the lumbar region. The grey matter is seen in a series of sections to be most abundant in the lumbar region of the cord, and least in the thoracic.

It is clear that what appear in section as irregular crescentic areas of grey matter are in reality long irregularly fluted columns, and that the commissural band uniting the convex edge of the crescents is a flattened expansion, connecting the columns along their whole length. But it is both customary and convenient to speak of the various parts of the grey matter of the cord according to their appearance in sections, although the term "columns" is very generally applied to what appear in section

as groups of nerve-cells, occurring in different parts of the grey matter, as well as to the several portions of the white matter immediately to be described.

**Central canal.**—Extending through the whole length of the spinal cord, in the substance of the grey commissure, there is a minute canal (fig. 8) which, in sections of the cord, is barely visible as a speck, with the naked eye. It is continued above into the medulla oblongata, where it gradually approaches the posterior surface and eventually opens out at the calamus scriptorius of the fourth ventricle. At the lower end of the cord, near the extremity of the conus medullaris, it becomes enlarged, and shaped like the letter T, and is stated by some observers to open on the dorsal or posterior surface of the cord; but this is denied by others. This central canal, though minute, is an object of considerable interest as a typical part of the structure of the cord, since it is the permanent remains of the epiblastic canal from which the spinal cord is developed. It is more distinct in lower vertebrata than in mammals.

**White matter.**—The white substance of each half of the cord completely encloses the grey matter except opposite the posterior horn. This last therefore serves to separate off a smaller *posterior white column*, which is somewhat wedge-shaped in section and is bounded internally by the posterior median fissure, from the



Fig. 9.—SECTION OF THE SPINAL CORD NEAR THE EXTREMITY OF THE CONUS MEDULLARIS. Magnified about six diameters.




Fig. 10.—DIAGRAM SHOWING BOTH THE ABSOLUTE AND RELATIVE EXTENT OF THE GREY MATTER AND OF THE WHITE COLUMNS IN SUCCESSIVE SECTIONAL AREAS OF THE SPINAL CORD, AS WELL AS THE SECTIONAL AREAS OF THE SEVERAL ENTERING NERVE-ROOTS (adapted from Ludwig and Woroschiloff). (E. A. S.)

The sectional areas of the several entering nerve-roots (*n.r.*) as well as the extent of the grey matter (*gr.*), and of the lateral, posterior, and anterior columns of white matter (*l. c.*, *p. c.*, and *a. c.*), are represented in superposed curves, the common abscissa of which (*abs.*) is intersected at equal intervals by as many ordinates as there are pairs of spinal nerves. In the ordinates each millimeter above the abscissa represents about one square millimeter of sectional area.

rest of the white substance which forms a large *antero-lateral white column* (figs. 7 to 9). The antero-lateral column is sometimes arbitrarily divided into anterior and lateral white columns, the place of passage of the bundles of the anterior nerve-roots being taken as the limit between the two; but since these are scattered over a considerable part of the transverse section it is clear that the limit cannot be distinctly fixed.

The white substance is traversed by imperfect septa of connective tissue prolonged inwards from the pia mater. Most of these are irregular and somewhat variable in position, with the exception of one in the cervical region extending inwards towards the grey commissure from the sulcus before described as bounding the postero-mesial column. This, the posterior intermediate septum before mentioned (p. 7) (fig. 8, *s*) cuts off a small portion of the posterior column next to the posterior median fissure, corresponding to the projection of the postero-mesial column on the surface.



The lateral symmetry of the spinal cord is not always perfect. The white columns especially are found slightly to vary, the variation being generally caused by the fact that the amount of the pyramidal tracts of white matter differs somewhat on the two sides of the cord (see p. 24). More rarely considerable malformations have been found to occur.

The white matter of the cord, especially that of the lateral and posterior columns, increases gradually in amount from below upwards, receiving a considerable accession opposite the roots of the larger nerves which supply the limbs. These relations are strikingly shown in the appended curves (fig. 10) which have been constructed by Ludwig and Woroschiloff from measurements by Stilling. The amount of the grey matter in the different regions is also given, as well as the sectional areas of the roots of the spinal nerves. It is seen that opposite to the origins of the large nerves there is a marked increase in the amount of grey matter.

The anterior or white commissure is likewise proportional in size to the entering nerve-roots.

**Characteristic features of the different regions of the cord.**—In the sacro-coccygeal region the bulk of the spinal cord is formed of grey matter which has a comparatively thin mantle of white substance surrounding it. The posterior cornua are nearly as thick as the anterior, and the isthmus of grey matter is relatively thick. The lateral cornu (in the sacral region) is well marked. Both here and in the lumbar region the number of nerve-cells imbedded in the grey matter is relatively very large, a fact which is probably connected with the circumstance that these regions are concerned with numerous and important reflex acts.

In the lumbar region the white matter begins to predominate, owing chiefly to the accession of the large nerve-roots of the sacral and lumbar plexus, many of the fibres to and from which are now running down and up the white columns of the cord. The posterior horn and the grey matter in general is still thick, although in the upper part of the lumbar region it has become thin and has more of the character which is met with in the thoracic region. The lateral horn is not distinct. The outline of the cord is beginning to be more circular, a shape which is maintained as far as the second thoracic segment.

In the dorsal or thoracic region the chief characteristic is the relatively small amount of grey matter, which forms two long slender crescents united by a narrow isthmus, which both here and in the cervical region is placed nearer the ventral than the dorsal aspect of the cord, whereas in the lumbar and sacral regions it lies near the middle of the dorso-ventral axis. The white matter is absolutely as well as relatively greater in amount than in the lumbar region. The lateral horn forms a distinct acute prominence throughout the whole of the thoracic region, but is most marked in the upper part. Clarke's column (see p. 16) is also to be seen near the base of the posterior horn: it is most prominent at the lower part of the thoracic region. In the upper part the postero-mesial column begins to be marked off from the postero-lateral.

The cervical region is characterized by the fact that the cord, except at the uppermost part, is of large size and tends to be somewhat flattened dorso-ventrally. The increase in size affects both grey and white matter. The postero-mesial column is now sharply marked off from the postero-lateral. Fibres of the spinal accessory roots may be seen passing out from the lateral cornu. A reticular formation is seen at the outer edge of the grey matter. Both the lateral and anterior cornua are large and are fused together to form a mass of grey matter, triangular in section, and tapering off dorsally into the base of the posterior horn. This horn and the substance of Rolando are but slenderly developed, contrasting with the large development of the same parts in the lumbar enlargement. The isthmus is thin, and the central canal flattened dorso-ventrally.

In the uppermost segments (upper part of the cervical enlargement) the grey matter is again diminished in amount and the cord has become circular in outline, as in the dorsal region. The section has however the other cervical characteristics, and there is a much more strongly marked anterior commissure than in the thoracic cord. Opposite the first cervical nerve-roots the cord begins to merge into the medulla oblongata or spinal bulb, and the passage of the pyramidal fibres from the pyramids on one side of the bulb to the lateral tract on the other side of the cord

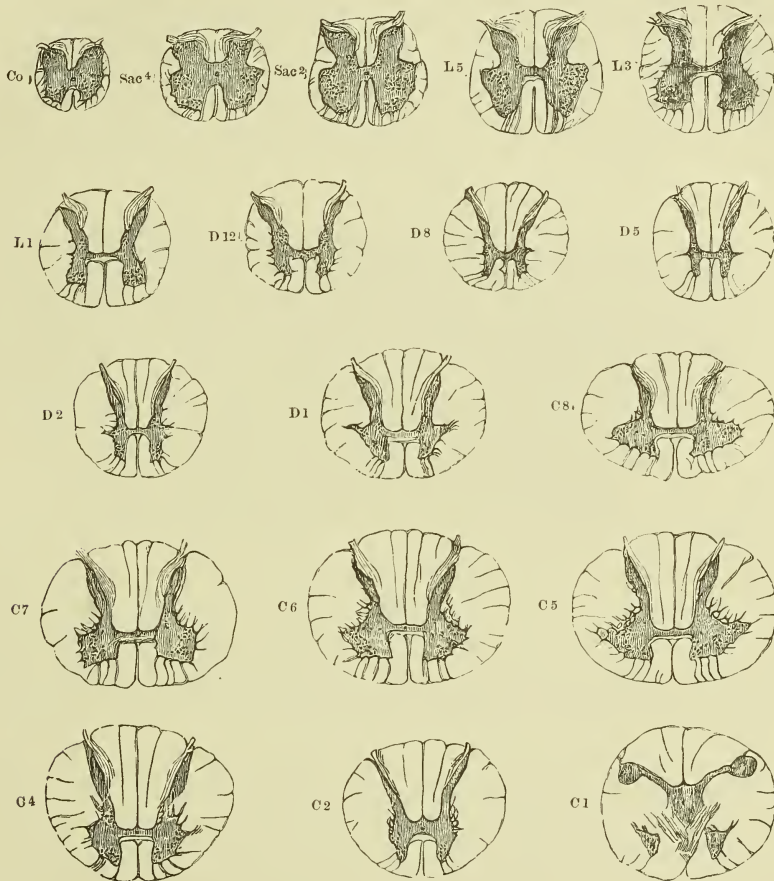


Fig. 11.—TRANSVERSE SECTIONS OF SPINAL CORD AT DIFFERENT HEIGHTS. (W. R. Gowers.) TWICE THE NATURAL SIZE.

The letters and numbers indicate the position of each section: Co. at level of coccygeal nerve; Sac. 4 of 4th sacral; L3 of 3rd lumbar, and so on. The grey substance is shaded dark, and the nerve-cells within it are indicated by dots.

tends partially to obliterate the anterior median fissure and to cut up the grey crescent.

In the cervical region the nerve-roots leave the cord nearly at a right angle and close together; in the other regions at an angle which is more or less oblique, the roots being directed from the intervertebral foramina upwards towards the cord; in the thoracic region they succeed one another at relatively longer intervals than elsewhere.

## MICROSCOPIC STRUCTURE OF THE SPINAL CORD.

The white substance of the spinal cord is almost wholly composed of longitudinally coursing medullated nerve-fibres, which in carmine-stained transverse sections of the cord (fig. 12) appear as clear rings with a stained dot—the section of the axis-cylinder—either in the middle of the ring or shifted somewhat to one side. The fibres vary much in size, and in many parts of the section larger and smaller fibres are intermixed, but some parts are characterised by containing many large fibres, others for the most part small fibres. The largest fibres are in the circumferential part of the anterior and lateral columns (and especially in the direct cerebellar tract), the smallest in the part of the lateral column in the neighbourhood of the *processus reticularis*, in the marginal bundle of Lissauer near the apex of the posterior horn, and in the postero-mesial column. Very small fibres also occur scattered over the white

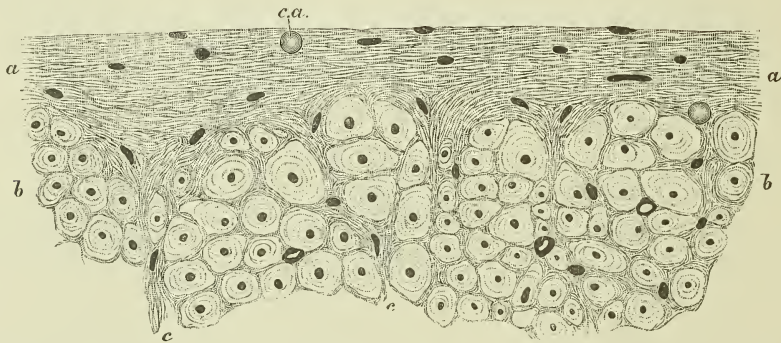


Fig. 12.—A SMALL PORTION OF A TRANSVERSE SECTION OF THE WHITE MATTER OF THE HUMAN SPINAL CORD. HIGHLY MAGNIFIED. (E. A. S.)

*a, a*, superficial neuroglia; *b, b*, transverse section of part of the lateral column of the cord (direct cerebellar tract). The dark points are the axis-cylinders, and the clear areas the medullary substance of the nerve-fibres; the superficial neuroglia exhibits the appearance of a fine network in which only the nuclei of the neuroglia-cells are seen. One or two *corpora amylacea* (*c. a.*) are embedded in the neuroglia, which extends inwards among the nerve-fibres.

substance, especially in the anterior column. The white columns are imperfectly divided into secondary columns by incomplete septa of fibrillar connective tissue which are prolonged inwards from the inner layer of the pia mater, and convey blood-vessels to the interior of the cord.

Immediately beneath the pia mater and closely investing the cord externally is a layer of what in the fresh condition appears a homogeneous substance with nuclei embedded in it here and there. In sections of the cord hardened in alcohol or chromic salts, the substance in question is finely reticulated (fig. 12, *a, a*). The layer which it forms is very thin over some parts of the surface but comparatively thick in others, and where the pia septa pass into the cord, it accompanies and invests them and their ramifications in the white substance, passing with them between the irregular bundles of nerve-fibres. Not only does this subpial reticular substance accompany the prolongations of the fibrillar tissue and largely assist in forming the incomplete septa above mentioned, but it extends independently amongst the individual nerve-fibres, occupying the interstices between them, and serving as a uniting medium in which they are embedded. Hence it was named by Virchow the *neuroglia* (nerve-cement). The nuclei in it belong for the most part to branched fibrillated cells (neuroglia-cells) which occur in considerable numbers and may be

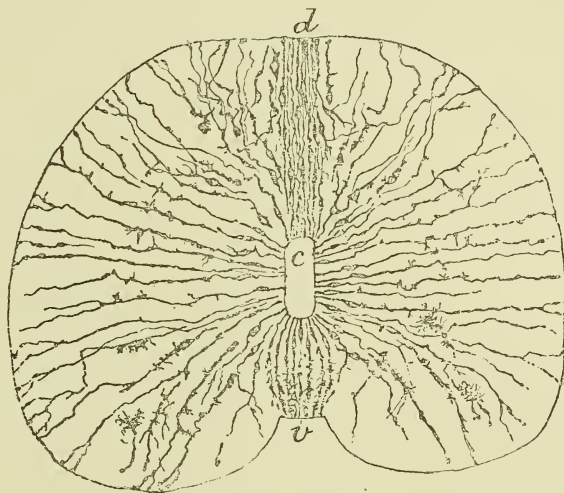


said to form the tissue ; some which are more conspicuous are known as the cells of Deiters ; they appear stellate in section and are found in the larger interstices between the nerve-fibres. Along the line of origin of the posterior roots the superficial neuroglia dips inwards towards the horn of grey matter, and expands within it to join the gelatinous substance of Rolando. This, as before mentioned, presents a transparent jelly-like appearance in the fresh condition, but in sections of the hardened cord it is finely reticular, containing numerous neuroglia-cells. Some of the bundles of nerve-fibres of the posterior root traverse this substance, and it contains many nerve-cells ; these are mostly of small size, but here and there one of larger dimensions is met with.

In the constitution of the rest of the cornua the neuroglia takes part to a far less extent than in the substantia gelatinosa. It is true that it is prolonged both from this and from the white substance into the grey matter, and pervades the

Fig. 13.—SECTION OF THE THORACIC SPINAL CORD OF A CHICK EMBRYO OF 9 DAYS INCUBATION, STAINED BY GOLGI'S METHOD. (Ramón y Cajal.)

*c*, central canal ; *v*, ventral or anterior ; *d*, dorsal or posterior surface. The spongioblasts alone are coloured and are seen to extend from the central canal to the periphery of the cord. Some appear to be detached and in process of conversion into neuroglia-cells.



latter throughout in every part. But it is in great measure obscured by the proper nervous elements, which in the grey substance comprise both cells and fibres. In the first place are found multipolar nerve-cells, many of large size, scattered singly or occurring in groups throughout the grey substance. In connection with these and especially accumulated around the cells and cell-groups, is an interlacement of the finest nerve-fibrils, which is derived partly from the ramified processes of the nerve-cells, and partly from the ramification of nerve-fibres or of collateral fibres which enter the grey matter from the nerve-fibres of the white columns. Occupying a considerable portion of the grey matter, are nerve-fibres, mostly of the medullated kind ; these and the axis-cylinder processes of the nerve-cells traverse the grey matter in different directions, coursing for the most part in bundles which intercross with one another, and confer on the grey matter a spongy appearance. Hence it is sometimes known as the *substantia spongiosa*.

Some of these bundles, which are fairly constant in position in many sections of the spinal cord, have recently been described by Pal (see Bibliography).

The structure of the neuroglia is described in the part of this work which deals with General Anatomy (Vol. I., p. 322). It is developed from the spongioblasts of His (see Embryology, Vol. I., p. 57), which at an early period of development extend from the central canal in the middle of the grey matter to the periphery of the cord (fig. 13). (The same holds good for other regions of the cerebro-spinal axis). At a subsequent period their continuity from the central canal to the surface can no longer be recognized, although it is certain that even in the adult the cells which line

the central canal and ventricles of the brain extend a long and indefinite distance into the grey matter. It is probable however that it is by transverse division of the spongioblasts, preceded by division of their nuclei, that the neuroglia-cells are originally formed. At the same time it appears clear that although nerve-cells and neuroglia-cells are functionally very different, their origin is not so dissimilar as was at one time believed to be the case. It was taught formerly that the neuroglia is a form of connective tissue (which it resembles functionally), and it was supposed that its cells were developed from mesoblast, but of late years there has been much doubt cast upon its supposed mesoblastic origin, and the question is not yet fully decided. The researches of His have tended however to show that both the spongioblasts from which the neuroglia-cells are believed to originate and the neuroblasts which give origin to the nerve-cells are both formed from the (at first undifferentiated) cells of the neural epiblast (see Embryology, development of central nervous system). The investigations of Ramón y Cajal upon the development of these elements in the embryo chick and mammal further indicate that the distinction into spongioblasts and neuroblasts is not a fundamental one, for cells which from their shape and position would be classed amongst the spongioblasts of His may alter their character and by throwing out an axis-cylinder process become transformed into nerve-cells.

Small concentrically striated globules, termed *corpora amylacea*, are frequently met with in the neuroglia of the cord in man, as well as in many of the parts of the central nervous axis. They appear to be composed of proteid substance but, although long recognized, their mode of formation and their meaning are unknown.

#### DISTRIBUTION OF NERVE-CELLS IN THE SPINAL CORD.

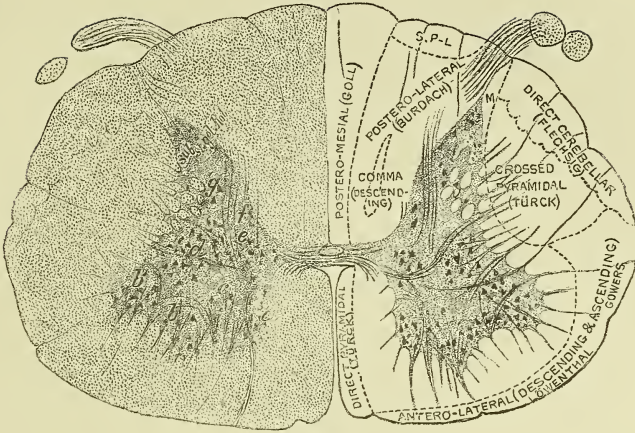
In transverse sections of the cord it is seen that the nerve-cells are not equally distributed throughout the grey substance, but are arranged in definite groups, which occupy nearly the same relative position in successive sections. The groups are therefore the sections of longitudinal tracts of grey matter rich in nerve-cells, and these tracts are named the *ganglionic* or *cell-columns* of the grey matter. The longitudinal continuity of the groups can be seen in sections of the cord made parallel with its long axis and passing through the part of the grey matter where the groups occur. In such longitudinal sections it may also be observed that the cells tend, speaking generally, to be more extended parallel to the longitudinal axis of the cord the longer the segments of the cord, as indicated by the entering nerve-roots (Toldt). It may further be stated as a probable law, applicable at least to the cells belonging to the same group or column, that the longer the nerve-fibre which issues from a cell, the larger is the cell. Those segments of the cord from which the longest nerve-fibres issue by the anterior root have the largest anterior horn cells (Pierret).

**Cell-column of anterior horn.**—Of these groups or columnar tracts of nerve-cells, the one which is most constant and contains the largest cells is found along the whole of the ventral part of the anterior horn where the nerve-cells lie among the issuing fibres of the anterior roots. There seems to be no doubt that many of these anterior or motor nerve-fibres are directly continuous with the axis-cylinder processes of nerve-cells of this group. Hence it is sometimes named the *motor cell-column*, but it is more generally known as the *cell-column of the anterior horn*. Its cells are in most parts collected into two groups, a *lateral* or *ventro-lateral* (fig. 14, *b*) nearer the lateral column of white matter, and a *mesial* (*a*) nearer the anterior column; in the cervical and lumbar enlargements there is a third, more deeply seated, *dorsal* or *dorso-lateral* group (*b'*).

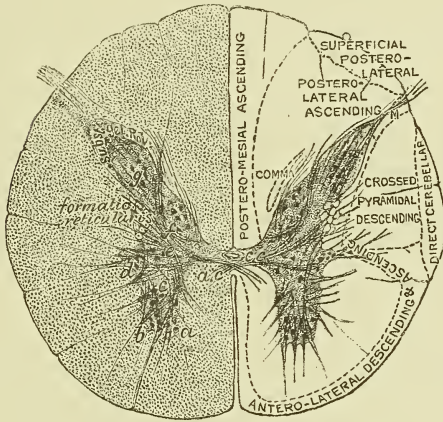
Of these several groups of cells into which the anterior horn cell-column is divisible, the one which is most constant along the whole length of the cord is the



CERVICAL.



DORSAL.



LUMBAR.

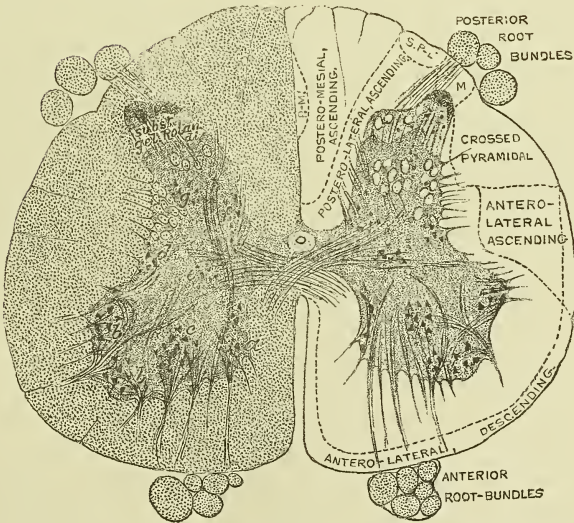


Fig. 14.—SECTIONS OF SPINAL CORD IN LOWER CERVICAL, MID-DORSAL, AND MID-LUMBAR REGIONS. (E. A. S.)

On the right side of each section the conducting tracts are indicated.

mesial group: on this account it is thought to give origin to the nerves which supply the dorsal muscles of the spinal column. It is sometimes described as forming two sub-groups, viz.: a dorso-mesial and a ventro-mesial.

The ventro-lateral group probably gives origin to the nerves which supply the lateral and ventral muscles of the trunk, including the muscles of respiration. In the cervical region it is described as consisting of two parts, one more laterally situated, which gives origin to fibres of the spinal accessory, and another, more mesially placed, which is believed to give off the fibres of the phrenic nerve. In the lumbar enlargement it also tends to be sub-divided.

The dorso-lateral group is mainly developed in the cervical enlargement and lumbar enlargement, and has an evident relationship to the nerve-roots of the brachial and sacral plexuses. It also shows subordinate groupings, which probably have special connections with particular groups of the limb-muscles. For various conjectures regarding both these and other cell-groupings in the grey matter, the reader may consult the paper by Kaiser, which is given in the Bibliography.

Some of the cells which are nearer the anterior commissure send their axis-cylinder processes through this commissure to the anterior white column of the other half of the cord: it is believed that these processes may be connected with nerve-fibres of the corresponding anterior root of the other side.

In some of the lower vertebrates it may be made out that there are variations in the size of the column of cells of the anterior horn in successive portions of the cord, the cells being more numerous opposite the points of entrance of the nerve-roots, the attachment of which to the cord is in them more localized than in man and higher vertebrates. In this way somewhat of a segmental formation of the column is indicated, and in some fishes and reptiles the enlargement of the group of cells and its enclosing grey matter is sufficiently marked to produce an external swelling opposite each nerve-pair. A similar segmentation is indicated in an early stage of development in all vertebrates, including man, by the fact that the cord is somewhat enlarged opposite each pair of nerve-roots.

**Clarke's column.**—A second very well marked group or column of large cells, which occupies in transverse section an area at the inner or mesial angle of the base of the posterior horn (fig. 14, *f*), and appears cut off from the rest of the grey matter by a curved bundle of fibres derived from the posterior root, extends along the middle region of the cord from about the third lumbar to the seventh cervical nerve. This was termed by Lockhart Clarke the *posterior vesicular column*; it is usually known as *Clarke's column*, although the cells were first noticed by Stilling. It is best developed in the lower part of the dorsal (thoracic) region. From the fact that it is almost entirely confined to the thoracic region of the cord it was termed by Stilling the "dorsal nucleus." But although ceasing above and below the points mentioned, it is not altogether unrepresented in other parts, for groups of cells are found in a similar situation opposite the origin of the second and third sacral nerves ("sacral nucleus" of Stilling) and opposite the origin of the third and fourth cervical nerves ("cervical nucleus"); and elsewhere there are scattered cells of the same character in the same part of the section of the cord. The cells of this column, like most, if not all, the cells of the spinal cord, are multipolar, and their axis-cylinder processes tend towards the lateral column, where they are believed to form the direct cerebellar tract (Flechsig). The cells themselves are surrounded by a fine plexus of nerve-fibrils, probably derived from collaterals of the posterior root-fibres. They are of large size, measuring, according to Mott, in their longest diameter, which is directed longitudinally, from  $40\mu$  to  $90\mu$ , the largest being found in the lowermost part of the column. In the fetus and even in the new-born child they are much smaller ( $25\mu$  to  $30\mu$ ), but by the second or third year after birth they have nearly attained the same size as in the adult.

**Lateral cell-column.**—A third column of cells lies in the intermedio-lateral



tract (*lateral cell-column*, fig. 14, *d*). Like that tract, the ganglionic column it contains chiefly appears as a distinct formation in the thoracic region; in other parts the cells do not form so distinct a group, but they appear nevertheless to be represented to some extent along the whole cord. Its cells are bipolar or multipolar, and measure on an average  $30\mu$  in diameter, being considerably smaller than those of Clarke's column or those of the anterior horn. In the upper part of the cervical region a group of cells becomes distinct in a similar situation (*lateral nucleus*), and is traversed by the roots of the spinal accessory nerve.

**Middle cell-column** (Waldeyer).—This is formed of what in sections of the cord forms an ill-defined group of moderately-sized cells placed in the middle of the grey matter of the crescent. The cells are most distinct as a group in the cervical region, and also more numerous there, becoming fewer in number as Clarke's column becomes more evident. In the dorsal region they lie mostly at the side of Clarke's column, but further down they again move nearer the middle of the crescent. They are distinguishable right down into the sacral region. It is not known with what fibres they are connected, but fibres from the postero-lateral columns course amongst them, and it may be that, on the other hand, they give off nerve-processes to one of the conducting tracts (? to the antero-lateral ascending tract). They stain less deeply with carmine than those of the motor column or of Clarke's column.

**Cells of posterior horn; solitary cells.**—The cells of the posterior horn are not grouped very definitely, but for purposes of description they may be roughly sub-divided into—1, those at the base of the horn; 2, those near the middle of the horn; 3, those at the margins; and 4, those of the gelatinous substance of Rolando. They vary in size, some of the largest being found near the mesial margin of the horn; these often have a characteristic long curved process (*comet-cell*, Waldeyer); and even within the same group both large and small cells may be found intermixed.

But in addition to the groups, a number of scattered cells are met with, distributed through the posterior horn. These cells vary much in form and size, but are for the most part spindle-shaped. They are usually spoken of as the *solitary cells*. The axis-cylinder processes both from some of these cells and from cells of the lateral cell-column pass towards the anterior horn and also towards the anterior commissure, and they are believed to give origin to the smaller fibres which issue with the anterior roots. Some of the axis-cylinder processes of these cells do not however leave the grey matter but are branched and their ramifications lose themselves in the interlacement of fibrils which invests other cells. In the lamprey it has been shown by Freud that cells which appear to correspond with the solitary cells send their axis-cylinders into the posterior roots, and more than one observer has described a direct passage of the axis-cylinder process of one of the more deeply lying cells of the anterior horn through the grey matter into the posterior root, and thence past the ganglion into the mixed nerve without coming into connexion with any of the ganglion-cells.

The cells of the substance of Rolando were first noticed by Gierke. They are small round granule-like cells, closely packed and staining with difficulty. They appear to have been often taken for neuroglia cells, but, according to Gierke and H. Virchow, there is little doubt about their nervous nature.

Cells are occasionally found separated from the general mass of grey matter and lying out amongst the fibres of the white columns. These "outlying cells" have been described by Stilling and others, recently in detail by Sherrington.

It has been shown by Golgi that the nerve-cells of the central nervous system may be primarily classified under two heads, viz., 1, those with a long axis-cylinder process which becomes a medullated nerve-fibre; and 2, those with a short axis-cylinder process which may or may not become medullated, and soon ramifies and loses itself in neighbouring parts of the grey matter. Golgi is of opinion that the former are to be looked upon as "motor or

efferent" cells, and the latter as "sensory or afferent," but it is doubtful if this physiological distinction will hold good. In the spinal cord the cells of the anterior horn, those of Clarke's column, and many of the cells of the lateral cell-column and of the posterior horn belong to the first category, while many of the solitary cells, the small cells of the substance of Rolando, and some of those of the lateral cell-column, belong to the latter.

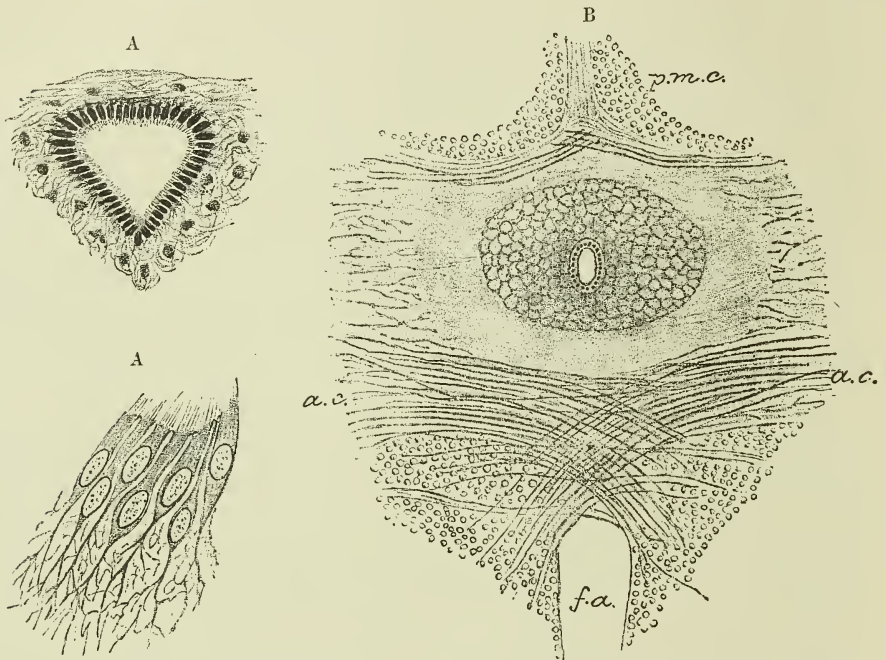


Fig. 15.—CENTRAL CANAL SHOWING ITS EPITHELIUM (E. A. S.)

A, from a child of six. Magnified 150 diameters. A', some of the ciliated cells, highly magnified.

B, section of the isthmus from the lumbar cord of an adult (at. 33), showing the central canal in the middle surrounded by the substantia gelatinosa centralis. *f.a.*, anterior median fissure; *p.m.c.*, posterior white column; *a.c.*, anterior white commissure. Magnified 30 diameters.

**Commissures.**—The **anterior commissure** (fig. 15, B, *a.c.*) consists of medullated nerve-fibres which pass on each side, some into the anterior white column, others into the anterior horn of grey matter. Their course is not strictly transverse, many fibres which enter the ventral part of the commissure at one side leave it at the dorsal portion on the other side. There is thus an oblique decussation at the middle line (fig. 15). This decussation is most distinctly seen in the comparatively short and wide commissure of the lumbar region, and in the upper part of the cervical region. In the latter situation it appears as a continuation of the decussation of the pyramids of the medulla oblongata, to be afterwards described. In addition to the transverse there are a few longitudinal bundles of fibres in the region of this commissure. The fibres are often somewhat displaced by vessels which pass into the grey substance from the anterior fissure.

The **posterior commissure** also contains medullated fibres running transversely or with a slight obliquity, but there is a large amount of neuroglia between them, and this gives the commissure a grey aspect. In this commissure is contained the central canal of the spinal cord surrounded by an area free from medullated nerve-fibres, and occupied by a substance which, like the superficial neuroglia and the substance of Rolando, has in the hardened condition a reticulated structure and in the fresh state a gelatinous aspect. It is termed *substantia gelatinosa*

*centralis*. In this gelatinous substance many of the fibres of the posterior commissure appear to end (see fig. 15, B). There is rather more of the posterior commissure behind the central canal than in front. The fibres of the posterior part curve backwards on reaching the crescents of grey matter and pass towards the bundles of the posterior roots, whereas the rest diverge at various angles into the crescent.

The **central canal** is lined with a layer of ciliated epithelium (fig. 15, A, A'). Each cell is provided with a bunch of cilia on the side which is turned towards the

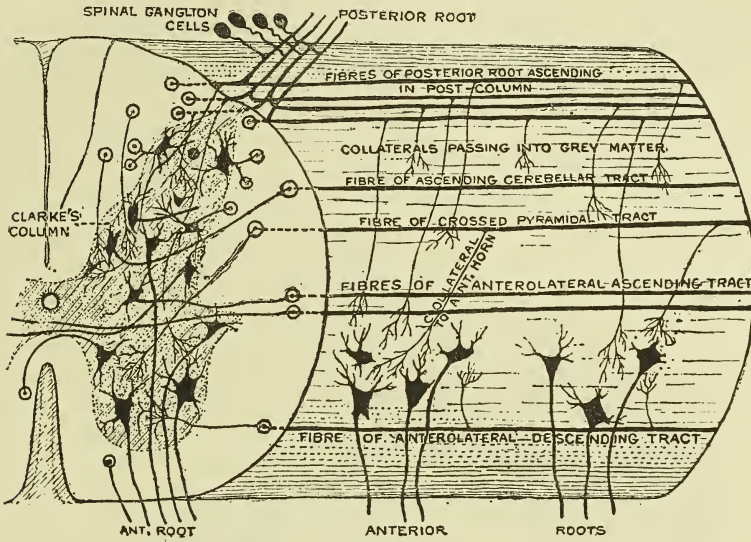


Fig. 16.—DIAGRAM TO ILLUSTRATE THE RELATIONS OF THE ENTERING NERVE-ROOTS, AND THE FIBRES OF THE WHITE COLUMNS OF THE SPINAL CORD TO THE NERVE-CELLS IN THE GREY MATTER. (E.A.S.)

lumen of the canal: the other end of the cell is prolonged into the reticular substance just mentioned, and there becomes lost to view.

In the adult human subject the lumen of the central canal is not unfrequently obliterated, being filled up by detached cells.

ORIGIN OF THE SPINAL NERVES.

The roots of the spinal nerves are attached along the sides of the cord, opposite to the corresponding horns of the grey matter; the posterior roots entering along a straight line at the postero-lateral groove, and the anterior roots being scattered somewhat irregularly upon the surface (fig. 7, B).

The **anterior roots** are seen in a transverse section to pass through the white substance and to enter the grey cornu in several bundles, which have a slight upward inclination, so as to be often cut obliquely if the section be exactly in a transverse plane. Some of the fibres on reaching the grey matter are directly connected with the axis-cylinder processes of the large nerve-cells of the cornu. Others pass by the cells without, so far as can be seen, entering immediately into relation with them.

As soon as the bundles enter the grey matter, their fibres diverge from one another, some passing mesially, others laterally, and others straight backwards (fig. 16). Of those which pass mesially some are continued into the axis-cylinder processes of



the mesial group of cells of the anterior cornu, and others to the other side of the cord through the anterior commissure, there perhaps to become connected with the corresponding cells. The outwardly directed fibres of the root are connected with the cells which form the lateral groups of the anterior horn, and partly with some of the cells of the intermediate cell-column. The middle fibres are partly connected to the cells of the anterior horn, and partly pass on to the posterior horn, where they are probably continued into some of the cells there present.

In the cervical region of the cord, from the sixth nerve upwards, the root-fibres of the spinal part of the spinal accessory nerve may also be seen passing out of the anterior horn through the lateral column (fig. 31, p. 40). They arise from a group of somewhat large cells, which in the uppermost region of the cord lies in the antero-lateral part of the horn, close to

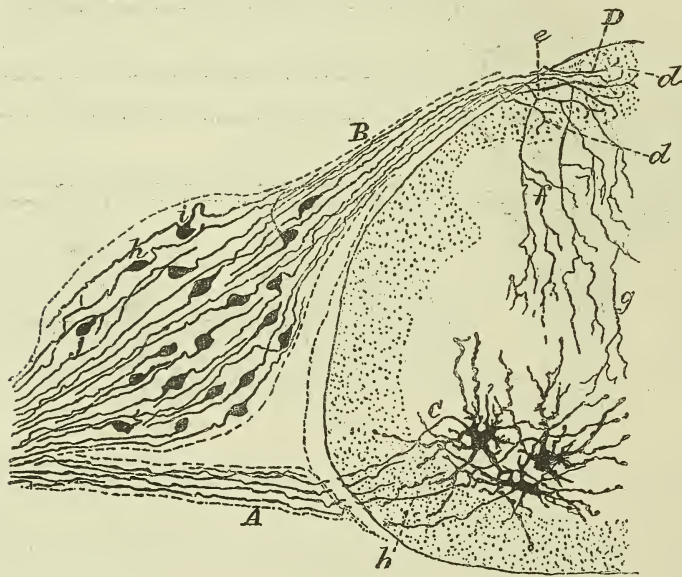


Fig. 17.—TRANSVERSE SECTION OF THE SPINAL CORD OF A CHICK ON THE 9TH DAY OF INCUBATION, PREPARED BY GOLGI'S METHOD (Ramón y Cajal).

*A*, axis-cylinders of anterior root-fibres issuing from large cells of the anterior horn, *C*.

*B*, Posterior root-fibres passing from the bipolar cells of the spinal ganglion, into the posterior column of the spinal cord, *D*, where they bifurcate, *d*, and become longitudinal: *e*, *f*, *g*, collaterals from these fibres, passing into the grey matter.

its ventral edge, but in the middle and lower cervical regions tends gradually to occupy a position nearer the base of the horn (see p. 16). This group of cells is the direct continuation downwards of the accessory nucleus which will be seen in the lower part of the medulla oblongata.

The **posterior roots** at their entrance into the cord are seen to separate into two sets. Of these the lateral, which contains most of the smallest fibres of the root, enters opposite the tip of the posterior horn and joins a bundle of fine longitudinal fibres which lies close to the periphery of the cord in this situation. This bundle is known as the *marginal bundle* or *column of Lissauer*. Its fibres, which are evidently different from most of those which enter with the posterior root, for they acquire their medullary sheath considerably later (Bechterew), appear, as they pass vertically, gradually to lose themselves in the adjacent gelatinous substance. The mesial set containing the larger and some smaller fibres of the posterior root passes into the

postero-lateral white column, with the longitudinal fibres of which its fibres become continuous; from this column many of them sweep with bold curves into the adjacent grey matter. At their entrance into the cord their direction like that of the bundles of fibres of the anterior roots is in most regions of the cord obliquely upwards.

Fig. 18.—LONGITUDINAL SECTION OF THE POSTERIOR COLUMN OF THE SPINAL CORD OF A CHICK ON THE 8TH DAY OF INCUBATION (Ramón y Cajal).

This figure shows the course of 5 entering fibres of the posterior root and some of the longitudinal fibres of the posterior column.

A, A, fibres of the posterior root; B, bifurcation of one of them in form of a Y; C, D, origin of collateral branches; E, fibres of Goll's tract, also giving off collaterals.

**Collateral fibres of the posterior roots and of the white columns.**—It has been definitely shown by Ramón y Cajal, whose researches into this subject have been confirmed by Kölliker and v. Gehuchten, that the fibres of the posterior roots as they enter the cord join by a Y- or T-shaped junction with longitudinal fibres of the posterior column; in other words that they bifurcate as they enter the cord into two principal branches which run upwards and downwards in the posterior white column or in the adjacent part of the posterior cornu. It has also been proved by the same observers

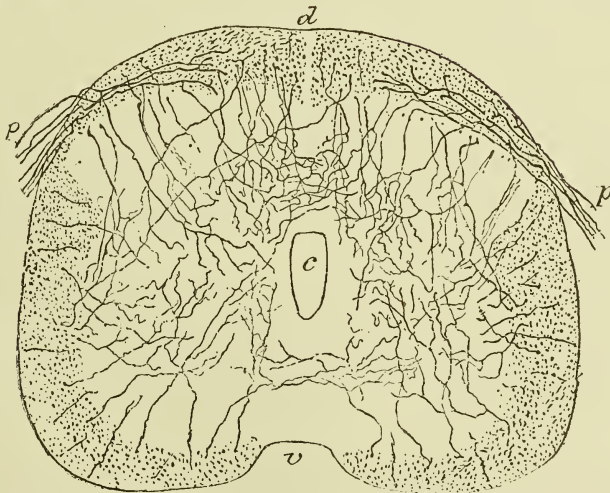
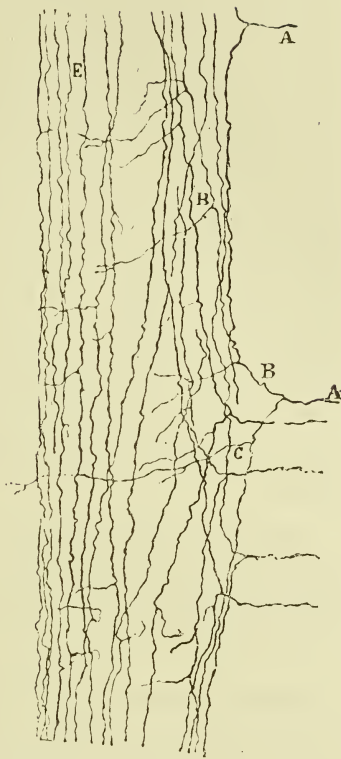


Fig. 19.—TRANSVERSE SECTION OF THE CORD OF A CHICK ON THE 9TH DAY (Ramón y Cajal).

This figure shows collaterals passing into the grey matter from all the white columns of the cord. They are seen to form an especially close plexus in the posterior horn, just within the substance of Rolando, and in the posterior commissure.

c, central canal; v, anterior and d, posterior surface of the cord; p, p, posterior roots.

that both from the root-fibre before its bifurcation and from its ascending and descending stems there are given off at tolerably frequent intervals "collateral" branches which are directed inwards towards the grey matter; into which they penetrate for a variable distance and within which they ultimately end by breaking up into a ramification of nerve-fibrils which may frequently be seen to have a close relationship to cells of the grey matter. In this way collateral fibres are given off from the posterior root-fibres and from their longitudinal extensions, some of which penetrate as far as the anterior horn of the same side, others pass through the posterior commissure into the grey matter of the opposite side, others towards the lateral horn and intermediate cell-column, whilst others do not extend beyond the posterior horn, passing towards Clarke's column or the solitary cells of the crescent, while many end in or near the substance of Rolando. These collateral fibres can be seen in sections of the embryonic cord which have been prepared by Golgi's method, to pass into the grey matter in large numbers from the posterior columns, most of the fibres of which are in fact prolongations of posterior roots which have entered the cord. But they are by no means confined to the fibres of the posterior columns, for from all the longitudinal white columns of the cord the same convergence of collateral fibres into the grey matter can be seen (see figs. 16 to 20).

The passage of collateral fibres into the grey matter from the white columns of the cord was first noticed by Golgi, who stated that the fibres of the anterior roots also give off in their passage towards the surface of the cord fine lateral ramuscles which become lost in the adjacent nervous matter. Other observers have for the most part failed to detect these collaterals of the anterior root-fibres.

#### COURSE OF NERVE-FIBRES WITHIN THE SPINAL CORD: CONDUCTING TRACTS.

It is impossible mechanically to unravel the tracts of nerve-fibres in their passage along the spinal cord, and it is exceedingly difficult to trace the same fibre or fibres for any distance in microscopical sections of the organ. But the task of following out the course of certain sets of fibres has been much facilitated of late years by the application to the subject of certain special developmental and pathological methods of observation. Thus it is found that if the development of the spinal cord is carefully observed, the medullary substance of the nerve-fibres is formed later along certain tracts of the white columns than in the rest of the white matter, appearing first in those tracts which are the immediate prolongations of peripheral nerves, and being longest delayed in those which are connected with the higher centres in the brain, so that in transverse sections of the cord these non-medullated tracts are easily distinguishable by their more transparent grey appearance and by their different behaviour with staining fluids (Flechsigs).

The following list (from Kahler) gives the order of formation of the myelin-sheath in the several tracts of the cord:—1. Fibres in anterior column derived from anterior roots. 2. Postero-lateral column (its posterior part somewhat later than its anterior part). 3. The lateral column near grey matter (the anterior part first, then the narrow posterior part between pyramidal tract and posterior horn). 4. Postero-mesial column. 5. Direct cerebellar tract. 6. Antero-lateral ascending tract. 7. Pyramidal tracts (shortly before birth).

Another method by which similar results are arrived at consists in tracing the course which the degeneration of the fibres pursues in consequence of a lesion either in the encephalon, or in the spinal cord itself, or even in the peripheral nerves; the lesions being produced by accidental injury, by pathological changes, or experimentally in animals. The degenerations which follow are either the result of the Wallerian law that separation of a nerve-fibre from the nerve-cell with which it is connected and from which it has grown out is followed by degenerative changes in





the part of the fibre thus separated from that centre (*secondary degenerations*), or they may follow from the prolonged disuse of a nervous tract, especially in young animals, as when a limb has been removed or from some other cause (*tertiary degenerations*). The degeneration which follows a lesion of part of the nervous centre, and especially section of the spinal cord, is in some tracts above the lesion, in which case the degenerated tract is styled "ascending," in others below ("descending") (see also p. 27). The place of the degenerated nervous substance is ultimately taken by a non-nervous fibrillar tissue, which, by its difference of behaviour to staining fluids, can easily be distinguished from the surrounding undegenerated white substance (*stage of sclerosis*). In new-born and young animals, after a longer interval, groups of nerve-cells are affected by the degenerative processes, and the cells may even eventually disappear altogether (v. Gudden). When this is the case it may be assumed that they are in connection with the fibres which have been cut; these being probably the axis-cylinder processes of the cells.

Thus in a rabbit in which immediately after birth the sciatic trunk is resected, when the animal is full-grown the corresponding anterior cornual cells are found to have become atrophied, and similar results are obtained with motor nerves generally, both spinal and cranial (v. Gudden, Forel, Ganser, Mayser).

**Tracts of the antero-lateral column.**—Several tracts can by these methods be traced in the antero-lateral column, not only along a great part of the spinal cord, but into or from certain parts of the encephalon. The long tracts in this column are the *direct and crossed pyramidal (descending)*, the *antero-lateral or ventro-lateral ascending*, the *antero-lateral or ventro-lateral descending*, and the *dorso-lateral ascending (or direct cerebellar)*.

**Descending tracts in the antero-lateral column.**—The **pyramidal tract** is directly traceable down from the opposite pyramid of the medulla oblongata, and ultimately from the cerebral cortex (Rolandic region). The greater number of the fibres which compose the pyramid cross at the upper limit of the spinal cord, down which they pass in the posterior part of the lateral column as a compact bundle of fibres occupying in transverse section a somewhat triangular area, which lies in the angle between the posterior horn and the outer surface of the cord, but is in most parts separated from both by fibres belonging to other systems. This *lateral or crossed part of the pyramidal tract* (figs. 14 and 24), can be traced as far as the third or fourth pair of sacral nerves, becoming gradually smaller below and approaching the surface of the cord.

A few fibres of the pyramidal tract are found scattered in other parts of the antero-lateral column.

Some of the fibres of the pyramids of the medulla oblongata do not decussate at the upper limit of the cord. These pass down close to the anterior median fissure, forming the *anterior or direct portion of the pyramidal tract* (fig. 14) (*column of Türck*), which gradually diminishes as it is traced downwards, and usually ceases altogether at about the middle of the dorsal region of the cord. It is probable that the decussation of these anterior pyramidal tracts goes on along their whole course, their fibres passing through the anterior commissure and through the grey matter of the opposite side to reach the lateral pyramidal tract on the other side of the cord.

There is much variation in the development of the anterior pyramidal tracts in different individuals. In some they are so well marked as to form a visible prominence on the surface of the cord close to the anterior median fissure and separated from the rest of the anterior column by a groove, the *anterior intermediate sulcus* of Rauber. In others they are quite small, or may even fail altogether. In this case it may be assumed that the decussation of the pyramids, which is known to be subject to considerable variation, has been more complete than usual. In other cases again the anterior pyramidal tracts may be unsymmetrical, being

more developed on one side than on the other, or the tract on one side may be wholly undeveloped. The direct tract is said to be wanting in 15 per cent. of cases in man. In different animals there is also much variation in the position and size of the pyramidal tracts. A well-marked direct pyramidal tract appears to be absent in most animals, even in monkeys. In some (mouse, rat, guinea-pig) the pyramidal tracts are in the posterior columns, but in most animals (rabbit, cat, dog) they run in the lateral columns as in man. The fibres of the pyramidal tract are probably connected with the anterior horn by collateral fibres, which ramify amongst the large cells that give origin to the anterior nerve-roots (figs. 16, 20).

The pyramidal tracts are undoubtedly the paths by which voluntary impulses pass from the brain to the various spinal segments. All the fibres within the area embraced by the "tract" are not, however, of the same nature, although fibres of the one function predominate: and this is probably correct of all the so-called "tracts" of conduction.

There are at least two descending tracts in the antero-lateral column, besides the direct and crossed pyramidal. One, the **antero-lateral descending cerebellar tract** (*anterior marginal bundle* of Loewenthal), consists of fibres which are connected with cells in the cerebellar cortex of the same side, and which undergo degeneration on removal of the corresponding half of the cerebellum (Marchi). These fibres form an extensive circumferential tract in the anterior three-fourths of the antero-lateral column, spreading inwards in front of the crossed pyramidal tract to reach the intermedio-lateral tract of the grey matter. The tract which is thus marked out (see fig. 26, p. 32) embraces (in the dog) the part of the anterior column which in man is occupied by the direct pyramidal tract, and also the whole region of the tract of Gowers (see below), the fibres of these two tracts being intermingled. Some of the fibres of the anterior roots also exhibit degeneration after removal of the cerebellar hemisphere, and are therefore probably directly continued from fibres of this tract.

In the monkey a few fibres in this column degenerate after lesions of the cerebral hemisphere of the opposite side. They are intermingled with those of the descending cerebellar tract and with those of the tract of Gowers, and are connected with cells in the Rolandic region of the cerebral cortex, as shown by the fact that they degenerate after lesions of that region. These fibres may perhaps be regarded as belonging to the system of the direct pyramidal tract, which in the monkey does not exist as a well-marked tract as in man: it has not yet been ascertained whether they occur in man as well as the direct pyramidal.

**Ascending tracts in the antero-lateral column.**—The **dorso-lateral ascending cerebellar tract** (*direct lateral cerebellar tract* of Flechsig) (fig. 14) lies between the lateral pyramidal tract and the outer surface of the cord, occupying a somewhat narrow area of the transverse section, which in the upper regions of the cord reaches to the tip of the posterior horn, but lower down becomes more limited, and is separated from the horn by the intervention of the adjoining pyramidal tract. It begins to appear at the lower dorsal region in man, and is then seen in all sections of the cord and lower part of the bulb, passing eventually by the restiform body into the cerebellum (middle lobe) (see fig. 27, p. 33).

It is found that there are a few fibres scattered through the neighbouring parts of the lateral column which, from their development simultaneously with those of the cerebellar tract, should be apparently reckoned with it. The axis-cylinder processes of the cells of Clarke's column are said to give origin to the fibres of the dorso-lateral cerebellar tract. The fibres of this tract acquire their medullary sheath somewhat earlier than those of the pyramidal tract. They are also considerably larger.

The **ventro-lateral** or **antero-lateral ascending cerebellar tract** (*antero-lateral ascending tract* of Gowers) occupies a position in the sectional area of the lateral column which is anterior or ventral to the dorso-lateral cerebellar tract, and it has in section an arched shape curving from immediately in front of the crossed



pyramidal tract (where it is most strongly marked) round the superficial part of the lateral column in front of the dorso-lateral cerebellar tract, and tailing off gradually between the issuing anterior roots to reach the anterior column. It can be traced upwards into the medulla oblongata and pons Varolii (fig. 27), and eventually enters the cerebellum along with the superior peduncle, passing mainly to the vermis. It is uncertain from what cells the axis-cylinders of its constituent fibres spring, but it is probable that they arise from some of the cells of the posterior horn. Its fibres are intermingled with those of the descending cerebellar tract.

The remainder of the antero-lateral column which is not comprised in the above tracts encircles the anterior cornu; it is termed the **antero-lateral ground-bundle**. It varies in sectional area with the size of the nerve-roots and of the grey matter, and many of its fibres not improbably are of a commissural nature, serving to connect the grey matter of different segments of the cord. It receives fibres also from the grey matter of the other side through the anterior commissure (fig. 15, B, *a.c.*), and is in part composed of fibres of the anterior roots which course for a certain distance obliquely within it before leaving the cord. Many intersegmental fibres also occur scattered amongst the fibres of the long tracts.

**Tract of Lissauer.**—At the posterior part of the lateral column, close to the entering fibres of the posterior roots and directly derived from them, there is constantly to be seen a well-marked bundle of fine nerve-fibres, which was first described by Lissauer, and since by Bechterew and others. It is not always confined to the lateral column, but may extend into the postero-lateral column.

**Tracts of the posterior white column.**—This column is mainly composed of two long **ascending tracts**, viz., the *tract of Goll*, which about corresponds with the postero-mesial column, and the *tract of Burdach*, which embraces the remainder of the posterior column. In the lower part of the cord these two tracts are not marked off from one another in the adult, but from the middle of the dorsal region upwards the postero-mesial column is separated from the postero-lateral by a septum of pia mater. Of the two parts of the posterior column the **tract of Burdach** is mainly composed of rather large fibres which are joined by, *i.e.*, are continuous with, the large fibres of the entering posterior roots. After a certain course, in which they give off numerous collaterals to the grey matter, they appear to enter the grey matter and to come into intimate relationship, although not into actual continuity, with its cells, especially those of Clarke's column. The fibres of the **tract of Goll**, on the other hand, are for the most part of smaller diameter. They also are derived from posterior root-fibres, but instead of soon entering the grey matter of the cord many of them run up the postero-mesial column into the medulla oblongata, where they terminate amongst the cells of the nucleus gracilis.

The column of Goll in the embryo shows a distinction into two parts, one mesial, close to the posterior median fissure, and a dorso-lateral part, lying near the dorsal surface of the cord (Flechsig).

**Descending fibres of the posterior column.**—In the middle of the sectional area of the postero-lateral column a few fibres are constantly found, which undergo descending degeneration after lesions of the cord. These are often described as constituting a special tract ("comma" tract), but they are a good deal intermingled with fibres of the adjacent ascending tracts. Whether they originate from cells higher up in the cord or are derived from the descending branches of the posterior root-fibres is uncertain. The latter, it may be remembered, extend a certain distance down the cord from the Y-shaped division of those fibres, giving off collaterals to the grey matter, and ultimately themselves turning into the grey matter. The extent to which these descending branches of the posterior roots may pass down the cord has not as yet been determined.

## DEGENERATIONS IN THE SPINAL CORD AS THE RESULT OF LESIONS.

It necessarily results from the Wallerian law of degeneration of nerve-fibres (Vol. I., p. 356) that every lesion of the nervous system in which fibres are cut or crushed must be followed by degeneration of nerve-fibres either above or below the lesion according to the position of the cells from which the fibres have originally grown, and which serve throughout life to maintain the nutrition of the fibres with which they are connected. Any such degeneration which occurs above the lesion is usually termed "ascending," and below the lesion "descending."

These terms must not be taken to imply, as is erroneously done by some authors, either that the degeneration starts from the lesion and extends upwards or downwards along the fibres, or that the nervous impulses which the fibres conduct necessarily have an ascending or a descending direction. For it is known (1) that the degeneration in the peripheral part of a cut nerve-fibre occurs simultaneously along its whole course; (2) that a nerve-fibre may undergo "descending" degeneration, although it normally conveys ascending impulses, *e.g.*, the peripheral afferent nerves.

Since the terms ascending and descending as applied to nerve-degeneration lead to much confusion of ideas it would be better, if possible, to discard them and to adopt words which merely imply that the degenerative process occurs above or below a lesion. But unfortunately those terms have taken such deep root in the literature of the subject that this course would be very difficult, and might lead to even worse confusion than their retention.

Similarly, if the nerve-cells from which the fibres are thus derived are removed or destroyed, the fibres, with any branches which they may give off, will degenerate along their whole course. Hence any tracts of fibres in the spinal cord which are derived from cells in parts of the brain, degenerate on destruction of those parts. Further, those fibres which have grown into the spinal cord or brain from nerve-cells situated external to those organs (*e.g.*, the fibres of posterior roots of spinal nerves and corresponding fibres of cranial nerves) will, if cut between the spinal cord or brain and the ganglion-cells from which they are derived, undergo degeneration from the point of section, not only as far as the surface of the central organ, but also along their whole course within that organ, and the degenerative process will include all their branches. Thus much having been said to explain the meaning of the results which are obtained by the study of nerve-degenerations, we may proceed to consider the degenerations which occur within the spinal cord: (1) from section of the posterior roots of the nerves; (2) from lesion or removal of parts of the brain; (3) from section or other lesion of the spinal cord itself.

**1. Degenerations resulting from section of the posterior roots.**—These have been investigated in the dog by Singer and Kahler, in the monkey by Mott and Tooth. It is convenient in describing the effect of sections of the posterior nerve-roots to consider them in the sacro-lumbar and in the dorso-cervical regions respectively, although the course of the degenerative process is essentially similar in both.

(*a.*) *Section of the posterior roots of the sacro-lumbar nerves.*—This has been most satisfactorily investigated by Singer in the dog and by Mott in the monkey. Section of these nerves, *e.g.*, of the whole cauda equina, is followed by "ascending" degeneration in the posterior column of the same side along the whole length of the spinal cord and as far as the nucleus gracilis of the medulla oblongata. But the degeneration does not occupy the same position and extent in every part of the cord. At the lowest part it involves the whole of the posterior column (fig. 21, *a*), but as soon as a point is reached at which uncut nerve-fibres enter the cord, these now occupy the part of the column nearest the horn of grey matter, while degenerated fibres are seen in that part only which is nearest the posterior median fissure (*b*).

In this situation they pass up the cord, diminishing in number, at first rapidly and afterwards more slowly, until at length a relatively small tract of degeneration is found, occupying the postero-mesial angle of Goll's tract, in which it runs to the nucleus gracilis (fig. 21, *c*).

(*b.*) *Section of the posterior roots of the dorsal and cervical nerves.*—After section of one or more of these roots degeneration occurs immediately above the section in the part of the postero-lateral column which is next to the posterior horn (figs. 22, 23, *a*). Somewhat higher up this becomes separated from the horn by other uncut (and therefore undegenerated) nerve-root-fibres, and approaches the postero-mesial column. Still higher it is found to have reached that column, where it is represented by a smaller

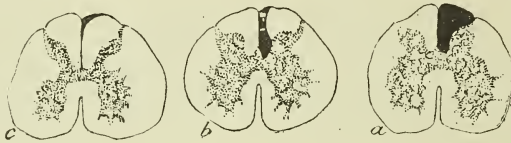

Fig. 21.—DIAGRAM SHOWING THE DEGENERATIONS IN THE POSTERIOR COLUMN WHICH RESULT FROM SECTION OF THE POSTERIOR ROOTS OF THE SECOND SACRAL TO THE SIXTH LUMBAR NERVES OF THE DOG. (Singer.)

*a*, section at the level of the sixth lumbar; *b*, at the fourth lumbar; *c*, from the middle of the thoracic region.

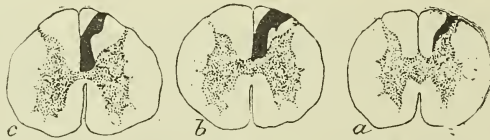

Fig. 22.—DIAGRAM OF DEGENERATIONS FOLLOWING SECTION OF THE ELEVENTH AND TWELFTH THORACIC POSTERIOR NERVE-ROOTS OF THE DOG. (Singer.)

*a*, section at the level of the twelfth thoracic; *b*, at the third thoracic; *c*, at the middle of the cervical region.

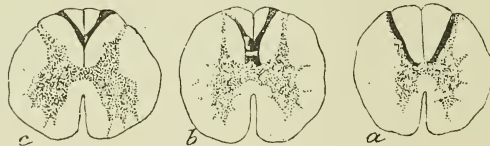


Fig. 23.—DIAGRAM OF THE DEGENERATIONS FOLLOWING BILATERAL SECTION OF THE SECOND THORACIC TO THE FIFTH CERVICAL POSTERIOR NERVE-ROOTS OF THE DOG. (Kahler.)

*a*, at the level of the first thoracic; *b*, at the sixth cervical; *c*, at the first cervical.

(Figs. 21, 22, and 23 are copied from Toldt's "Gewebelehre.")

tract of degeneration, which in section lies obliquely across the column. With regard to this degeneration in the postero-mesial column it is to be noted that while that which results from section of the lower (lumbo-sacral) roots occupies in the higher parts of the cord the postero-median angle, as above described, the degeneration resulting from section of dorsal roots lies next to this, that resulting from section of lower cervical roots passes up Goll's column in its lateral part next to the column of Burdach, and finally that resulting from section of upper cervical roots is confined to Burdach's column, and ends in the nucleus cuneatus of the medulla oblongata. In other words, the lower the root the more mesial is the resulting long degeneration in the higher parts of the cord and in the medulla oblongata. The fibres, as they enter the cord with the posterior nerve-roots, form



in fact a succession of lamellar tracts, which lie in each case at first next to the posterior cornu, and become gradually shifted medianwards by those which enter the cord with the higher nerve-roots.

It is further to be noted that in all cases the degeneration falls off markedly in amount as we trace it up the cord, and that what remains is eventually confined to a part of the posterior column which contains normally fine or medium-sized fibres only. From this it may be inferred that the larger fibres of the posterior roots—which in fact form the bulk of those roots—have a relatively limited course after entering the cord. They probably end by their collateral branches, and ultimately by their main ascending branches, turning into the grey matter and breaking up into terminal ramifications in the fine interlacements of nerve-fibrils which occur in the neighbourhood of the nerve-cells and cell-groups. These terminal branches and the nerve-fibrils which result from their ramifications, should also, of course, from the Wallerian law, degenerate after section of the roots, and there is no doubt that they actually do so, although from their scattered course in the grey matter it is difficult to prove the fact. It has, however, been shown by Mott that after section of the lower posterior roots, the fine nervous interlacement which surrounds the cells of Clarke's column disappears for some little distance above the entrance of the cut nerve-roots, and it may therefore be fairly inferred that some of the fibres of the posterior roots give origin directly and by collaterals to this interlacement. Others, probably, are similarly related to other cells, both in the posterior and anterior horns of the same side, and even on the other side of the cord, for it will be remembered that ramifying collaterals can be traced from the posterior root-fibres to all these parts (see figs. 16 and 20). Thus all the larger and some of the smaller<sup>1</sup> fibres of the posterior roots gradually end as they are prolonged up the cord, until finally only those remain which pass up the postero-mesial column towards the medulla oblongata. Even these become gradually diminished in number, no doubt from the fact that some of them terminate in the grey matter as they proceed.

It will further be remembered that the fibres of the posterior roots divide on their entrance into the cord into two main longitudinal branches, ascending and descending. Of these the ascending only has been traced by the above degenerations, but the descending branch must also undergo degeneration. It is, however, not easy to trace out its course. The only known "descending" degeneration in the posterior columns is along the narrow curved tract in the postero-lateral column which is known as the "comma," but would be better termed the *posterior descending tract*. Mott has found that this degeneration results not only in sections of the cord, but also after section of posterior nerve-roots, and that it has a limited extent, one or two centimeters only. It is therefore not improbable that this degeneration may represent the descending branches of the cut posterior root-fibres (cf. p. 26, and fig. 20, 8 to 9).

It will be convenient here to sum up what is known or may be inferred as to the course of the fibres of the posterior roots within the cord as determined by anatomical, embryological and experimental (degenerative) methods. (1.) Each fibre on entering the cord divides into an ascending and a descending branch, which form the longitudinal fibres of the posterior column. Both from the root-fibre before division and from the branches, collaterals come off which lose themselves in terminal ramifications enveloping nerve-cells in the grey matter. Probably also after a longer or shorter course the main branches terminate by passing in like manner into the grey matter. (2.) From each root on entering the cord a lateral bundle of small fibres (Lissauer's bundle) is given off, which lies partly lateral and partly mesial to the apex cornu posterioris, while the remainder of the root forms a large lamellar bundle of mixed large and small fibres which run longitudinally in the postero-lateral column close to the cornu of grey matter. (3.) From this lamellar bundle many fibres pass upward

<sup>1</sup> Those of Lissauer's bundle.

along the whole length of the cord, being gradually shifted inward towards the postero-mesial column, and forming as they reach this column the tract of Goll, which becomes the funiculus gracilis in the medulla oblongata; from the tract of Goll the fibres eventually pass, some into the grey matter of the upper part of the spinal cord, others into grey matter in the nucleus gracilis of the bulb, whilst yet others derived from the uppermost cervical roots do not reach the tract of Goll but pass up to the bulb in the funiculus cuneatus and end in its nucleus. (4.) The remainder of the fibres which have entered by the

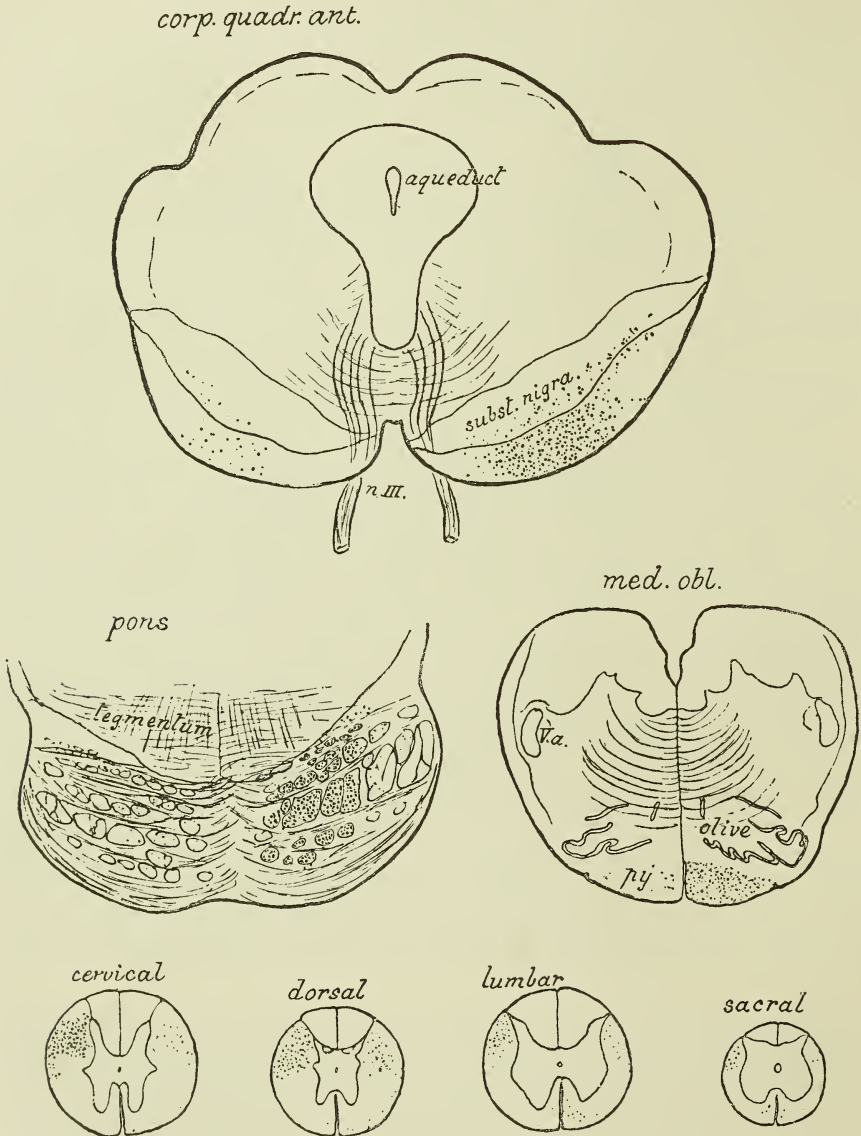


Fig. 24.—DEGENERATIONS IN THE MESENCEPHALON, PONS VAROLII, MEDULLA OBLONGATA, AND SPINAL CORD OF A MONKEY, FOLLOWING A LESION OF THE ASCENDING FRONTAL CONVOLUTION. (E.A.S.).

The lesion was on the right side of the brain. The section outlines are drawn to one scale. The degenerated fibres are shown by black dots.

The degeneration is mainly on the same side in the mesencephalon, pons, and bulb, but on the opposite side in the spinal cord. A few fibres are degenerated in the antero-lateral region in the cord, but the degeneration is otherwise confined to the pyramidal tracts.



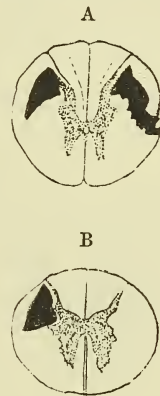
posterior roots have only a limited course up the postero-lateral column, passing, as they ascend, into the grey matter, in which they and their collaterals form the fine nervous plexus around many of the nerve-cells which has been already mentioned. From some of the large fibres the plexus around the cells of Clarke's column (and perhaps also around the cells of the nucleus cuneatus of the medulla oblongata) is in this way formed, whilst others furnish an enveloping plexus to the cells of the anterior horn and to those of other parts of the grey matter. (5.) The descending main branches of the posterior root-fibres have, like many of the ascending branches, only a limited course, during which they give off collaterals, by means of which, and also ultimately by directly passing into the grey matter, they assist in forming the enveloping plexus around the nerve-cells of the segments of the cord immediately below that at which the parent root has entered (compare figs. 16 and 20).

**2. Degenerations in the spinal cord resulting from lesions of parts of the brain.**—Removal of the cortex of the so-called "motor" region of the cerebral hemisphere is followed by degeneration extending along the pyramidal tract in the brain and cord (fig. 24). In the spinal cord this tract has for the most part crossed to the opposite side, but in man a portion runs for a time as the direct tract along

Fig. 25.—DIAGRAMS SHOWING THE DEGENERATIONS IN THE SPINAL CORD WHICH RESULT FROM REMOVAL OF PORTIONS OF THE CEREBRAL CORTEX OF THE MONKEY (France).

A, upper thoracic cord from a monkey in which the left marginal gyrus had been removed some months before death. Sclerosis in both crossed pyramidal tracts, but most on the opposite side.

B, mid-thoracic cord from a monkey in which the right gyrus fornicatus had been destroyed some months before death. Sclerosis in the opposite pyramidal tract.



the anterior median fissure on the same side as the lesion (fig. 14). Although this direct pyramidal tract is usually considered to be confined to the anterior column, it is found in the monkey as the result of lesions of the motor regions of the cortex that there are a few scattered fibres in the circumferential part of the antero-lateral column which also undergo degeneration (descending cerebral fibres of the antero-lateral column, see p. 25). The crossed tract lies in the posterior part of the lateral column between the direct (dorso-lateral) cerebellar tract and the posterior horn, and in this situation the degeneration can be traced downwards, decreasing in amount, and, in the lower parts of the cord, with the disappearance of the dorso-lateral cerebellar tract, approaching the surface of the cord near the tip of the posterior horn. In the cervical region the crossed pyramidal degeneration may reach the surface of the cord in front of, *i.e.*, ventral to the dorso-lateral cerebellar tract, which is partly enclosed by the degenerated fibres; this, at least, is the case in the monkey (fig. 25, A). After a unilateral lesion of the cortex there is also a certain amount of degeneration in the lateral tract of the cord on the same side as the lesion. This is especially the case when the lesion has involved the marginal convolution (fig. 25, A). These are not, as might be supposed, fibres which have passed from the pyramid of the medulla oblongata directly to the lateral column of the same side of the cord, but they may be traced from the lesion of the cerebral cortex across the corpus callosum into the internal capsule of the opposite side, whence they run down the crista and pyramid bundles of the pons and bulb to re-cross at the decussation of the pyramids, and thus to reach the pyramidal tract of the cord on the same side as the lesion. Although most numerous in the higher parts of the nerve-centres, a few of these re-crossed fibres are found to extend right along the spinal cord.

On the other hand, section of the pyramidal tract in the cord of the new-born animal is followed by atrophy of the large cells of the "motor" area of the cortex (*v.* Monakow).

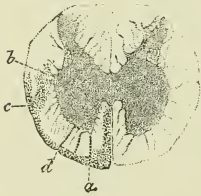
Destruction of the gyrus fornicatus of one hemisphere is also followed by degeneration extending down the pyramidal tract, although the gyrus fornicatus cannot be reckoned in with the "motor" region of the cortex cerebri, but rather appears to be connected with the appreciation of sensory impressions. Since, however, it is not possible to cut away the gyrus fornicatus without pushing aside and thus somewhat injuring the motor cortex, it may be alleged that the degeneration in question is really the result of such injury to that cortex. Nevertheless there is no serious improbability in supposing that afferent as well as efferent fibres are conveyed along the course of the pyramidal tract. Indeed, so far as experimental evidence upon animals is of value in determining the course of afferent impressions along the cord, it is rather in favour of some kinds at least of those impressions passing up this part of the lateral column.

Marchi and Algieri found extensive degeneration in the tracts of Burdach after removal of a part of the cortex a little behind the motor zone in the dog, and also after removal of the occipital lobe; in the latter case combined with some degeneration in Goll's column. Singer and Munzer were unable to confirm these results.

Sherrington finds, after removal of parts of the cortex cerebri, a few scattered degenerated fibres in the anterior and lateral cornua of the spinal cord (and also in the grey matter of the pons and in the substantia nigra of the crus cerebri). The same observer has noticed that even when the cortical lesion is entirely confined to the so-called "arm-area" of the cortex, a certain number of fibres are found to degenerate right down the pyramidal tract of the opposite side, even as far as the lumbo-sacral region.

**3. Degenerations in the spinal cord resulting from lesions of the cerebellum.**—These have been described by Marchi, who has found, as above mentioned

Fig. 26.—SECTION OF SPINAL CORD OF DOG (LUMBAR REGION) KILLED THREE MONTHS AFTER REMOVAL OF THE RIGHT HALF OF THE CEREBELLUM (Marchi). THE DEGENERATED PART IS SHADED WITH DOTS.



(p. 25), that removal of one lateral half of the cerebellum in the dog is followed by degeneration extending down the circumferential part of the antero-lateral column. The degeneration is most extensive in the upper regions, and gradually lessens in the lower parts of the cord, but can be traced almost to its termination. It also extends

along some of the fibres of the anterior roots, thus indicating a direct connection between these and the cerebellar cortex (fig. 26, *a, d*).

**4. Degenerations resulting from lesions of the cord itself.**—*a.* Section of the spinal cord in any part is followed by certain degenerations above and certain below the section. These may be classed as 1, Short degenerations which extend only a limited distance above or below the plane of section; and 2, long degenerations which extend an unlimited distance upwards or downwards in the cord. Of the short degenerations, the most marked are in the anterior column and the anterior part of the lateral column near the grey matter (antero-lateral ground-bundle), where there are seen numerous scattered degenerated fibres both ascending and descending; they probably are due to the section of fibres which serve to connect cells of one segment of the cord to the grey matter of other segments above or below. Of the long degenerations, the "descending" ones are those of the pyramidal tracts, crossed and direct; the descending cerebellar tract of the antero-lateral column, and, for a few centimeters, the small descending tract (comma tract) of the posterior column; the "ascending" are in the posterior column, where they are the same as would have resulted from section of all the posterior roots below the point of section, and in the lateral column in the situation of the direct (dorso-lateral) cerebellar tract and of the antero-lateral ascending tract. The continuation of these towards the brain has already been mentioned (p. 25) and will again be referred to in connection with the medulla oblongata and pons Varolii.

If the section of the cord is confined to one lateral half the tracts of degeneration are limited to the side of the hemisection, but a few degenerated fibres are seen in the corresponding tracts upon the other side above the hemisection (fig. 27).

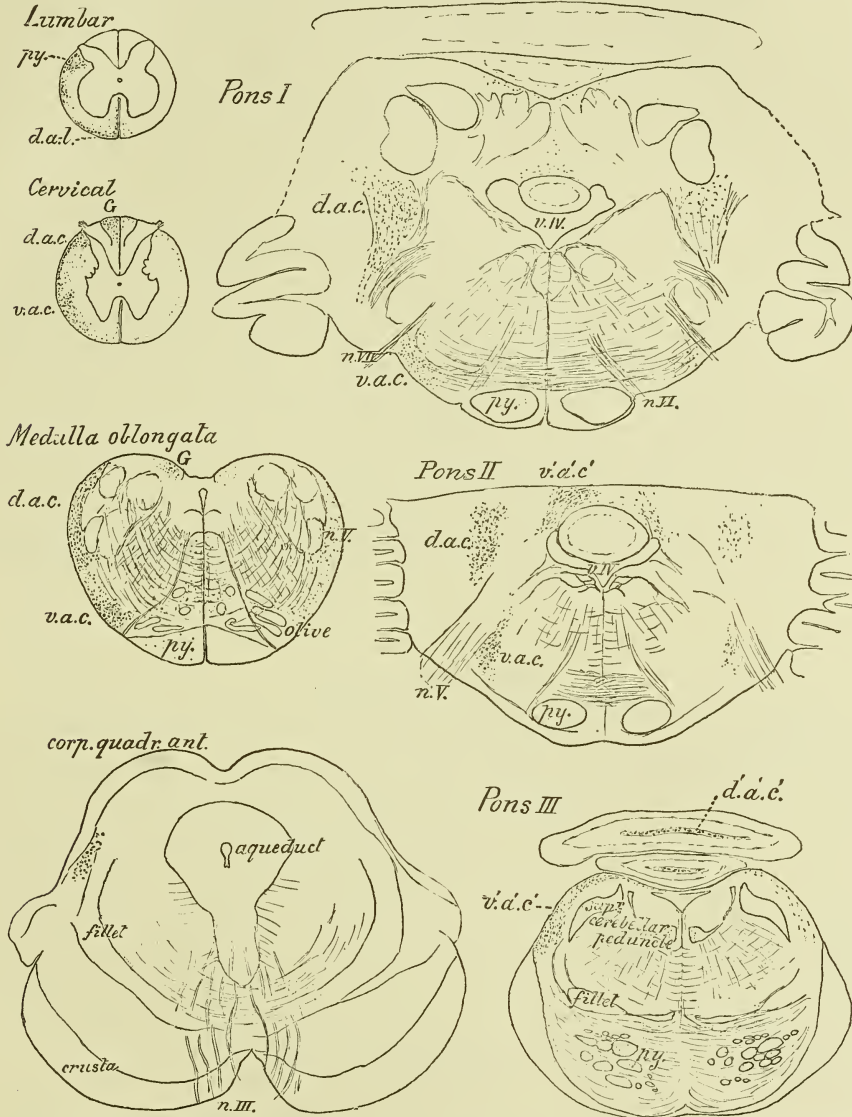


Fig. 27.—DEGENERATIONS IN THE SPINAL CORD, MEDULLA OBLONGATA, PONS VAROLII AND MESEN-  
CEPHALON OF A MONKEY, FOLLOWING HEMISECTION AT THE 12TH DORSAL NERVE. (E.A.S.)

The hemisection was on the left side of the cord and complete. The section-outlines drawn to one scale with a camera lucida. The degenerated fibres shown by black dots. Those in the section of the lumbar cord are descending, all the rest are ascending. *py.*, pyramidal tract; *d.a.l.*, descending antero-lateral tract; *d.a.c.*, dorso-lateral ascending cerebellar tract; *d.a.c'*. (in Pons III.), degeneration of fibres of this tract in the white matter of the cerebellar worm; *v.a.c.*, ventro-lateral ascending cerebellar tract (Gower's tract); *v.d.c'*. (in Pons II. and III.), degenerated fibres of this tract passing dorsally into the valve of Vieussens (in Pons III.) and into the white matter of the vermis (in Pons II.); *n.III.*, *n.V.*, *n.VI.*, *n.VII.*, issuing fibres of the 3rd, 5th, 6th, and 7th nerve-roots; *v.IV.*, 4th ventricle.

Nearly all the degeneration is on the same side as the lesion. A few fibres are degenerated on the opposite side (perhaps from a slight accidental injury of that side of the cord).



According to L. Auerbach destruction in the cat of a considerable length of the posterior part of one half the spinal cord, including the posterior white column, the posterior horn of grey matter, and the posterior part of the lateral column, is followed by degenerations (ascending) in the dorsal cerebellar tract and antero-lateral remainder of the *opposite* side, with degenerated fibres in the anterior commissure (besides the well-known ascending degenerations of the *same* side). The number of degenerated fibres diminishes gradually as they are traced upwards. In the medulla oblongata they are few in number and mostly on the side opposite the lesion, dorsal to the olivary nucleus; a very few on the same side dorsal to the nucleus lateralis. The degeneration following a lesion in the lumbar cord is in the ventro-lateral (antero-lateral) tract, and is traceable up to the ventral part of the superior worm of the cerebellum; the dorso-lateral cerebellar tract ends more dorsally, also in the superior worm. Some degenerated fibres pass through the corpus dentatum cerebelli into the dorsal part of the superior peduncle.

*b. Destruction of the grey matter of the spinal cord.*—This lesion can be experimentally produced in the rabbit by compression of the aorta, lasting for about an hour (Ehrlich and Brieger). The immediate result of the experiment is to cause necrosis of all the nerve-cells in the lumbar region of the spinal cord, without immediately affecting the white matter or the nerve-roots, a condition which is followed in the course of a few days by degeneration of certain fibres, which may be assumed to be those which emanate from the necrosed cells. If the animal is kept until this degeneration is well marked and is then killed and the cord examined in sections, it is found that in the necrosed region and immediately above it there is extensive degeneration in all the white columns of the cord, but least in the posterior columns and in the posterior parts of the lateral columns, where the long tracts of connection with the brain are situated. In sections taken higher up and well above the region of necrosis this diffuse degeneration has disappeared, but there is well-marked degeneration along the whole length of the cord in the tract of Goll and in the antero-lateral ascending tract. It has been inferred, therefore, by Singer and Munzer that these tracts contain long fibres which are derived from the cells of the grey matter (of the lumbar region).

*c. Destruction of the cells of Clarke's column* along a certain length of the cord is followed by well-marked "ascending" degeneration in the dorso-lateral (direct) cerebellar tract (Mott).

## RECENT LITERATURE.

**Auerbach, L.**, *Zur Anatomie d. aufsteigenden degenerirenden Systeme des Rückenmarks*, Anat. Anzeiger, 1890.

**Bastian, H. Charlton**, *On the symptomatology of total transverse lesions of the spinal cord*, Medico-Chirurgical Transactions, vol. 73, 1890.

**Bechterew, W.**, *Ue. d. Bestandtheile der Hinterstränge des Rückenmarks*, Neurol. Centralbl., 1885; *Ueber einen besonderen Bestandtheil der Seitenstränge des Rückenmarks und über den Faserwürgung der grossen aufsteigenden Trigeminuswurzel*, Arch. f. Anat. u. Physiol., Anat. Abth. 1886; *Ueber die hinteren Nervenwurzeln, ihre Endigung in der grauen Substanz des Rückenmarks und ihre centrale Fortsetzung im letzteren*, Archiv f. Anat. u. Phys., Anat. Abth., 1887; *Le cerveau de l'homme dans ses rapports. &c.*, Arch. slaves de biologie, 1887; *Ueber die Pyramidenbahnen beim Menschen u. d. Thieren, &c.*, Neurol. Centralbl., 1890.

**Bechterew u. Rosenbach**, *Ueber die Bedeutung der Intervertebralganglien*, Neurol. Centralbl., 1884.

**Bertelli**, *Le sillon intermédiaire antérieur de la moelle humaine dans la première année de vie*, Extract in Arch. ital. de biol. xi., 1889.

**Birge, E. A.**, *Die Zahl der Nervenfasern und der motorischen Ganglienzellen im Rückenmark des Frosches*, Archiv f. Anat. u. Phys., Phys. Abth., 1882.

**Burckhardt, K. R.**, *Histologische Untersuchungen am Rückenmark der Tritonen*, Arch. f. mikrosk. Anat., Bd. xxxiv., 1889.

**Colman, W. S.**, *Notes on the minute structure of the spinal cord of a human fetus*, Journ. of Anat. and Physiol., 1884.

**Corning, H. K.**, *Ueber die Entwicklung der Substantia gelatinosa Rolandi beim Kaninchen*, Arch. f. mikrosk. Anat., xxxi., 1888.

**Dickinson**, *On the changes in the nervous system which follow amputation*, Journal of Anat. and Physiol., 1868.

**Dreschfeld, J.**, *On changes in the spinal cord after amputation of limbs*, Journ. of Anat. and Physiol., 1880; *Rückenmark u. Gehirn i. e. Falle v. angeb. Mangel eines Vorderarms*, Virch. Arch. 89, 1882.

**Edinger, L.**, *Vorlesungen ü. d. Bau der nervösen Centralorgane*, Leipzig, 1889; *Ue. die Fortsetzung der hinteren Rückenmarkswurzeln zum Gehirn*, Anat. Anzeiger, iv., 1889; *Einiges vom Verlauf der Gefäßbahnen im centralen Nervensysteme*, Deutsche medicin. Wochenschrift, 1890.

**Ehrlich u. Brieger**, *Ueber die Ausschaltung des Lendenmarks*, Zeitschr. f. klin. Medicin, vii., 1884.

- Flechsig, P.**, *Ist die Tabes dorsalis eine "System-Erkrankung"?* Neurol. Centralbl., 1890 (contains remarks on the differentiation of the posterior columns in the spinal cord of the fœtus).
- France, E. P.**, *On the descending degenerations which follow lesions of the gyrus marginalis and gyrus fornicatus in monkeys*, Philos. Trans. B., 1889.
- Francotte**, *De la dégénérescence ascendante secondaire du faisceau de Gowers*, Bruxelles, 1889.
- Fraser**, *On the pyramidal tracts of certain rodents*, *Dubl. Journ.*, Aug., 1889.
- Friedländer u. Krause, F.**, *Ueber Veränderungen der Nerven u. des Rückenmarks n. Amputationen*, Fortschr. der Medicin, 1886.
- Gad, J.**, *Ueber Centren und Leitungsbahnen im Rückenmark des Frosches*, Verhandl. der physiol. Gesellsch. zu Berlin; Arch. f. Anat. u. Phys., Phys. Abth., 1884.
- Gaule, J.**, *Zahl u. Vertheil. der markhaltigen Fasern im Froschrückenmark*, Sächs. Abhandl., Bd. xv., 1889.
- Gehuchten, A. van**, *La structure des centres nerveux: la moelle épinière et le cerveau*, La Cellule, vii., 1891.
- Golgi, C.**, *Recherches sur l'histologie des centres nerveux*, Archives italiennes de biologie, iii. & iv., 1883; Anat. Anzeiger, 1890.
- Gotch, F., and Horsley, V.**, *On the mammalian nervous system, its functions, and their localisation determined by an electrical method*, Phil. Trans., Vol. 182, B, 1891.
- Gowers, W. R.**, *Diagnosis of diseases of the spinal cord*, 1879; *Diseases of the nervous system*, i., 1886; *Bemerkungen über die antero-laterale aufsteigende Degeneration im Rückenmark*, Neurolog. Centralbl., No. 5, 1886; *Weitere Bemerkungen über den aufsteigenden antero-lateralen Strang*, Neurolog. Centralbl., No. 7, 1886.
- Guldberg**, *Ue. d. Centralnervensystem der Bartenwale*, Christiania, 1886.
- Hadden**, *On a symmetrical degeneration of the spinal cord and medulla oblongata*, Trans. of the Pathol. Soc., 1882.
- Hadden and Sherrington**, *On a case of bilateral degeneration in the spinal cord, &c.*, Brain, 1886; *The pathological anatomy of a case of locomotor ataxy. &c.*, Brain, 1888.
- Hayem and Gilbert**, *Note sur les modifications du système nerveux chez un amputé*, Arch. de physiol., 1884.
- Helweg**, *Studien über den centralen Verlauf der vasomotorischen Nervenbahnen*, Archiv f. Psychiatrie, xix., 1887.
- Herter**, *A study of experimental myelitis*, Journ. of nervous and mental disease, 1889.
- Herzen, A., et Löwenthal, N.**, *Trois cas de lésion médullaire au niveau de jonction de la moelle épinière et du bulbe rachidien*, Archives de physiol., 1886.
- Hill, A.**, *Plan of the central nervous system*, 1885.
- Hoche, A.**, *Beiträge zur Kenntniss d. anatom. Verhaltens d. menschlichen Rückenmarkswurzeln, &c.*, Heidelberg, 1891.
- Hofrichter**, *Ueber aufsteigende Degeneration des Rückenmarkes, &c.*, Dissert. Jena, 1883.
- Hollis, W. Ainslie**, *Researches into the Histology of the Central Grey Substance of the Spinal Cord and Medulla Oblongata*, Journal of Anat. and Physiol., 1883 and 1884.
- Homén, E. A.**, *Ueber secundäre Degeneration im verlängerten Mark und Rückenmark*, Virchow's Archiv, Bd. 88, 1882; *Exper. Beitr. z. Pathol. u. pathol. Anat. d. Rückenmarkes*, Fortschr. d. Medicin, 1885; *Die histol. Veränderungen in d. periph. Nerven, d. Spinalganglien u. d. Rückenmarke in Folge von Amputation*, Neurol. Centralbl., 1888.
- Horsley, V.**, *Relation of posterior columns of cord to excito-motor area of cortex cerebri*, Brain, 1886.
- Joseph, M.**, *Zur Physiol. der Spinalganglien*, Neurol. Centralbl., 1887; Arch. f. Anat. u. Physiol., 1887.
- Kahler, O.**, *Ueber d. Veränderungen im Rückenmarke nach Compression, nebst einem d. secund. Degeneration im Rückenmarke des Hundes betreffenden Anhang*, Zeitschr. f. Heilkunde, iii., 1882; *Faserverlauf in den Hintersträngen*, Berliner klin. Wochenschr., 1882; *Ueber die Unheilbarkeit gew. Rückenmarkserkrankungen*, Prag. med. Wochenschr., 1889; *Der Nervenapparat*, In Lehrbuch der Gewebelehre, von Dr. C. Toldt, 1888.
- Kaiser, O.**, *Die Functionen der Ganglienzellen des Halsmarkes*, Haag, 1891 (contains a full bibliography of the topography of the nerve-cells of the cord).
- Kölliker, A. v.**, *Zur feineren Anatomie des Centralnervensystems; Zweiter Beitrag: Das Rückenmark*, Zeitschr. f. wissen. Zoologie, 51, 1890.
- Kronthal, P.**, *Histologisches von den grossen Zellen in den Vorderhörnern*, Neurologisches Centralbl., Jahrg. ix., 1889.
- Lachi, P.**, *Contrib. alla istogenesi d. neuroglia d. midollo spinale del pollo*, Atti d. soc. tosc. d. sc. nat., xi., 1891; *Contributo all' istogenesi del midollo spinale nel pollo*, Atti acad. med. chir. di Perugia, 1889.
- Langley, J. N.**, *Recent observations on degeneration, and on nerve tracts in the spinal cord*. A critical account. Brain, 1886 (contains references to most important literature of the subject up to that date).
- Langley and Grünbaum**, *On the degenerations resulting from removal of the cerebral cortex and corpora striata in the dog*, Journal of Physiol., xi., 1890.
- Laura, J. B.**, *Sur la structure de la moelle épinière*, Archives italiennes de biologie, Tom I., 1882.
- Lavdowsky, M.**, *Vom Aufbau d. Rückenmarkes*, Arch. f. mikr. Anat., Bd. 38, 1891.
- Lenhossék, M. v.**, *Ueber d. Verlauf d. Hinterwurzeln im Rückenmark*, Arch. f. mikr. Anat., Bd. 34, 1889; *Ueber Nervenfasern in d. hinteren Wurzeln, welche a. d. Vorderhorn entspringen*, Anat. Anzeiger, 1890, also in the Proceedings of the Hungarian Academy of Sciences, vol. 19; Zur

- Kenntniß der Neuroglia des menschlichen Rückenmarkes*, Verhandl. d. Anat. Gesellsch., 1891; *Untersuchungen über die Entwicklung der Markscheiden und den Faserverlauf im Rückenmark*, Archiv. f. mikrosk. Anat., Bd. xxxiii., 1889.
- Lissauer, H.**, *Beitrag zum Faserverlauf im Hinterhorn des menschlichen Rückenmarks und zum Verhalten desselben bei Tabes dorsalis*, Archiv f. Psychiatrie, xvii., 1886; *Ue. Veränderungen d. Clarke'schen Saule bei Tabes dorsalis*, Fortsch. d. Medicin, 1889.
- Löwenthal, N.**, *Contribution expérimentale à l'étude des atrophies secondaires du cordon postérieur et de la colonne de Clarke*, Recueil zool. Suisse, T. iv., 1886; *La région pyramidale de la capsule interne chez le chien et la constitution du cordon antéro-latéral de la moelle*, Revue medic. de la Suisse romande, No. 9, 1886; *Ue. d. Unterschied d. secund. Degeneration des Seitenstrangs nach Hirn- u. Rückenmarksverletzungen*, Pflüger's Arch., 31, 1883; *Des dégénérationes secondaires de la moelle épinière consécutives aux lésions expérimentales médullaires et corticales*, Dissert., Genève, 1885.
- Lüderitz, Ueber das Rückenmarks-segment**, Arch. f. Anat. u. Phys., Anat. Abth., 1881.
- Lustig, A.**, *Zur Kenntniß des Faserverlaufes im menschlichen Rückenmarke*, Sitzungsber. d. Wiener Akad., Bd. 88, iii. Abth., 1883.
- Marchi, V.**, *Sulle degen. consec. alla estirpazione totale e parziale del cervello*, Rivista sperim. di freniatria, &c., 1888.
- Marchi e Algeri, S. degen. consec. a lesioni sperim. d. corteccia cerebrale**, Rivista sperim. di freniatria, 1887.
- Mayer, P.**, *Experim. Beiträge zur Kenntniß d. Baues des Kaninchenrückenmarks*, Arch. f. Psychiatrie, Bd. vii. and Bd. ix.
- Mott, F. W.**, *Shape and size of the cells of Clarke's column*, British Medical Journal, 1887; *Microscopical examination of Clarke's column in man, the monkey, and the dog*, Journal of Anat. and Phys., xxii., 1888; *Bipolar cells of the spinal cord and their connections*, Brain, 1890; *Results of hemisection of the spinal cord in monkeys*, Phil. Trans., B., 1891.
- Obersteiner, The Anatomy of the Central Nervous Organs**, translated by A. Hill, London, 1890.
- Oddi and Rossi, Sur les cours des voies afférentes de la moelle épinière, &c.**, Archives ital. de biol., xv., 1891.
- Pfützner, W.**, *Ueber Wachstumsbeziehungen zwischen Rückenmark und Wirbelkanal*, Morphol. Jahrb., 9, 1883.
- Pitres, Recherches anatomo-cliniques sur les scléroses bilatérales de la moelle épinière, &c.**, Arch. de Phys., 1884.
- Popoff, N.**, *Recherches s. l. structure des cordons postérieures, &c.*, Arch. de Neurologie, 1889.
- Ramón y Cajal, Estructura de los centros nerviosos de las aves**, Revista trimestr. de histologia, 1888; *Contrib. al estudio de la estructura de la medula espinal*, Ibid., 1889; *Sur l'origine et les ramifications des fibres nerveuses de la moelle embryonnaire*, Anat. Anzeiger, 1890; *Nuevas observaciones sobre la estructura de la medula espinal de los mamíferos*, 1890; *A quelle époque apparaissent les expansions des cellules nerveuses de la moelle épinière du poulet?* Anatom. Anzeiger, 1890.
- Ravenel, M.**, *Die Massenverhältnisse der Wirbelsäule u. des Rückenmarkes beim Menschen*, Zeitschr. f. Anat. u. Entw., ii.
- Reid, R. W.**, *The relations between the superficial origins of the spinal nerves from the spinal cord and the spinous processes of the vertebrae*, Journal of Anatomy, xxxiii., 1889.
- Renaut, J.**, *La neuroglie et l'épendyme*, Arch. de Phys., 1882.
- Reynolds, E. S.**, *On changes in the nervous system after amputation of limbs*, Brain, 1887 (includes good bibliography of this subject).
- Ross, J.**, *On the segmental distribution of sensory disorders*, Brain, 1888.
- Rossolimo, G.**, *Experimental researches into the question of the sensory and motor paths in the spinal cord*, Inaug. Diss., Moscow (Russian), Abstr. in Neurol. Centralbl., 1887, also in Arch. de Neurol., vol. xxii., 1891.
- Saint Remy, G.**, *Recherches sur la portion terminale du canal de l'épendyme chez les vertébrés*, Paris, Savy, 1887.
- Sandmeyer, W.**, *Ueber secundäre Degeneration nach Exstirpation motorischer Centra*, Zeitschr. f. Biologie, x., 1891.
- Schäfer, E. A.**, *Report on lesions in brain and spinal cord of a macaque monkey*, Journal of Phys., 1883, and in Trans. Int. Med. Congress, 1881.
- Schaffer, K.**, *Vergleichend-anatom. Untersuch. ü. Rückenmarksfaserung*, Arch. f. mikr. Anat., Bd. 38, 1891.
- Schultz, R.**, *Zur Vacuolenbildung i. d. Ganglienzellen d. Rückenmarks*, Neurol. Centralbl., 1884.
- Schultz, Beitr. zur Lehre v. d. secundären Degeneration im Rückenmarke des Menschen, &c.**, Arch. f. Psychiatrie, xiv.; *Einige Bemerkungen ü. d. Mittheilung von Becker u. Rosenbach, &c.*, Neurol. Centralbl., 1884.
- Sherrington, C. S.**, *On secondary and tertiary degeneration in the spinal cord of the dog*, Journal of Phys., 1885; *Note on two newly-described tracts in the spinal cord*, Brain, Oct., 1886; *Nerve-tracts degenerating secondarily to lesions of the cortex cerebri*, Journal of Physiology, 1889; *Note on bilateral degeneration in the pyramidal tracts resulting from unilateral cortical lesion*, British Medical Journal, Jan., 1890; *Further note on degenerations following lesions of the cortex cerebri*, Journ. of Physiol., 1890; *Outlying nerve-cells in the mammalian spinal cord*, Phil. Trans., vol. clxxxi.
- Siemerling, Ue. ein gesetzmässiges anatom. Verhalten der Wurzeln in d. verschiedenen Höhen d. Rückenmarks**, Neurol. Centralbl., 1886 (Monograph publ. by Hirschwald, Berlin, 1887).
- Singer, J.**, *Ueber secundäre Degeneration im Rückenmarke des Hundes*, Sitzungsberichte der Wiener Akad., Bd. 84, iii. Abth., 1882; *Ue. d. Veränderungen am Rückenmark nach zeitweiser Verschlussung der Bauchorta*, Wiener Sitzungsber., iii. Abth., 1887.



**Singer u. Munzer**, *Beitr. z. Anatomie d. Centralnervensystems, insbesondere des Rückenmarkes*, Wiener Denkschr. lvii., 1891.

**Spitzka, E. C.**, *The comparative anatomy of the pyramidal tract*, Journal of comparative medicine and surgery, New York, 1886; *Kurze Notiz die Lumbalanschwellung des Rückenmarks betr.*, Neurol. Centralbl., 1885.

**Spronck, C.**, *Contrib. à l'étude expérim. des lésions de la moelle épinière déterminées par l'anémie passagère de cet organe*, Arch. de phys. norm. et pathol., 1888.

**Steinlechner-Gretschischnikoff, Alexandra**, *Ueber den Bau des Rückenmarks bei Mikrocephalen*, Arch. f. Psychiatrie, Bd. xvii., 1886.

**Strümpell**, *Beitr. z. Pathologie des Rückenmarkes*, Arch. f. Psychiatrie, x. and xii.

**Takács, A.**, *Ueber den Verlauf der hinteren Wurzelfasern im Rückenmark und den Aufbau der weissen Substanz am hinteren Abschnitte des Rückenmarks*, Neurolog. Centralbl., 1887.

**Tooth, Howard**, *A contribution to the path. anatomy of the spinal cord*, St. Barth. Hosp. Reports, vol. 21; *Note on the antero-lateral ascending tract*, St. Barth. Hosp. Reports, vol. 23; *Gulstonian Lectures on Degenerations of the spinal cord*, 1889.

**Unverricht**, *Ueber doppelte Kreuzung cerebrospinaler Leitungsbahnen*, Neurol. Centralbl., 1890.

**Vejas, P.**, *Ein Beitrag z. Anat. u. Physiol. der Spinalganglien*, München, 1883.

**Vignal, W.**, *Sur le développement des éléments de la moelle des mammifères*, Archives de Physiol., 1884.

**Virchow, H.**, *Ueber Zellen in der Substantia gelatinosa Rolandi*, Neurol. Centralbl., 1887; *Ueber das Rückenmark der Anthropoiden*, Anatom. Anzeiger, iii., 1888.

**Wagner, J.**, *Zur Anatomie des Rückenmarks und der Medulla oblongata*, Centralbl. f. Nervenheilkunde, 1886.

**Waldeyer, W.**, *Ueber d. Verlauf d. hinteren Nervenwurzeln*, Sitzungsber. d. Gesellsch. naturf. Freunde, Berlin, 1889; *Ueber einige neuere Forschungen im Gebiete der Anatomie d. Centralnervensystems*, Deutsche med. Wochenschr., 1891; *Das Gorilla-Rückenmark*, Abhandl. d. Königl. Preuss. Akad. d. Wissensch., 1888.

**Weigert, C.**, *Bemerkungen ü d. Neurogliaerüst des menschlichen Centralnervensystems*, Anat. Anzeiger, 1890.

## THE BRAIN OR ENCEPHALON.

The brain or encephalon comprises the medulla oblongata and pons Varolii, the cerebellum, the mid-brain, and the cerebrum. The *medulla oblongata* (fig. 28, D) is the part continuous with the spinal cord; it is the lowest part of the encephalon, and rests against the basilar process of the occipital bone. The *pons Varolii* (c) is a direct continuation upwards and forwards of the medulla oblongata, but the name also includes the transversely coursing fibres of the middle cerebellar peduncle. The *cerebellum* (B) occupies the posterior fossa of the cranium. Its central part forms the dorsal boundary of a space, which is bounded ventrally by the dorsal surface of the medulla oblongata and pons Varolii, and which is named the fourth ventricle of the

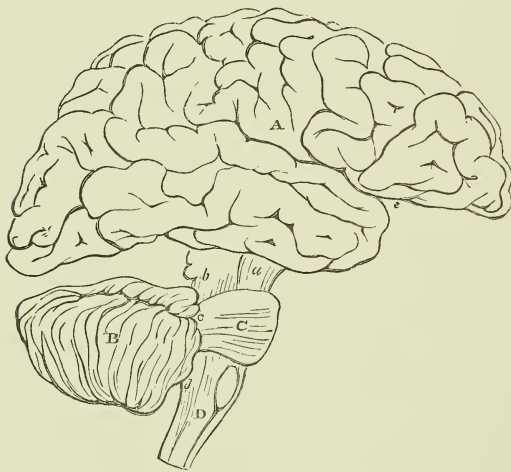

Fig. 28.—PLAN IN OUTLINE OF THE ENCEPHALON, AS SEEN FROM THE RIGHT SIDE.  $\frac{1}{3}$

The parts are represented as separated from one another somewhat more than natural so as to show their connections. A, cerebrum; e, fissure of Sylvius; B, cerebellum; C, pons Varolii; D, medulla oblongata; a, peduncles of the cerebrum; b, c, d, superior, middle, and inferior peduncles of the cerebellum; the parts marked a, b, form the isthmus encephali.

brain. The cerebellum is connected by peduncles below with the medulla oblongata, above with the cerebrum, and in the middle with the pons Varolii (c). The *mid-brain* is continued from the pons Varolii and comprises the two crura of the cerebrum (a), which are surmounted in man and mammals by two pairs of tubercles named the *corpora quadrigemina* (b), but in oviparous vertebrates by one pair only, then named the *corpora bigemina* or *optic lobes*. The *cerebrum* (A) includes all the remaining and by far the largest part of the encephalon. It is united with the parts below by the mid-brain, which forms a comparatively narrow and constricted portion or *isthmus*. The cerebrum is mainly composed of the large convoluted *cerebral hemispheres*, and within it are the third and two lateral ventricles. It occupies the vault of the cranium, the anterior and middle cranial fossæ, and the superior fossæ of the occipital bone. The cerebral hemispheres are united together by a large commissure termed the *corpus callosum*, and by smaller commissures (anterior, middle, and posterior).

## THE MEDULLA OBLONGATA AND PONS VAROLII.

## EXTERNAL CHARACTERS.

The *medulla oblongata* or *spinal bulb* (*bulbus rhachiticus*, Meckel) is continuous below with the spinal cord, on a level with the lower margin of the foramen magnum. Its upper limit is marked off on the ventral aspect from the pons Varolii, into which it is continued above, by the lower margin of the mass of transverse fibres which unite the two hemispheres of the cerebellum; its ventral surface rests in the basilar groove

of the occipital bone, its dorsal or posterior surface is directly continued into that of the pons, and lies in the fossa named the vallecule between the hemispheres of

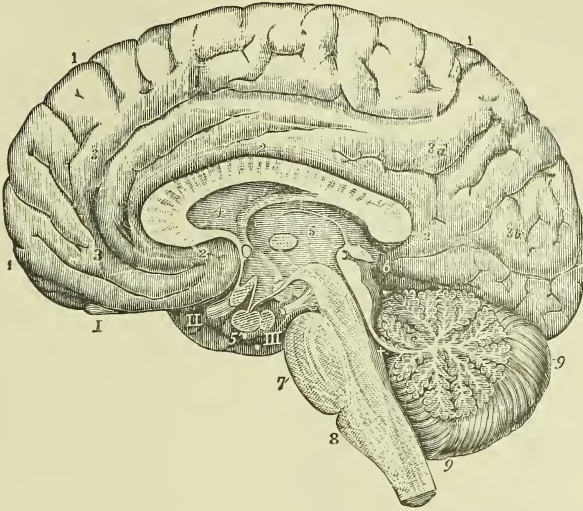


Fig. 29.—RIGHT HALF OF THE BRAIN DIVIDED BY A VERTICAL ANTERO-POSTERIOR SECTION (from various sources and from nature). (Allen Thomson.)  $\frac{1}{2}$

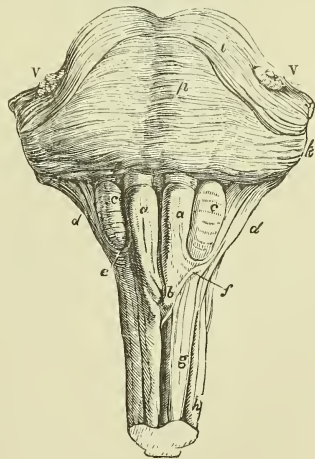
1, 2, 3, 3a, 3b, are placed on convolutions of the cerebrum ; 4, the fifth ventricle, and above it the divided corpus callosum ; 5, the third ventricle ; 5', pituitary body ; 6, corpora quadrigemina and pineal gland ; +, the fourth ventricle ; 7, pons Varolii ; 8, medulla oblongata ; 9, cerebellum ; I, the olfactory bulb ; II, the right optic nerve ; III, right third nerve.

the cerebellum. From its front and sides the sixth to the twelfth cranial nerves issue, while the fifth nerve emerges from between the commissural fibres of the pons.

The term medulla oblongata, as employed by Willis and Vieussens, and by those who directly followed them, included the crura cerebri and pons Varolii, as well as that part to which by Haller first, and by most subsequent writers, this term has been restricted.

Fig. 30.—VIEW OF THE ANTERIOR SURFACE OF THE PONS VAROLII AND MEDULLA OBLONGATA, WITH A SMALL PART OF THE SPINAL CORD ATTACHED.

a, a, pyramids ; b, their decussation ; c, c, olives ; d, d, restiform bodies ; e, external arciform fibres, curving round the lower end of the olive ; f, fibres described by Solly as passing from the anterior column of the cord to the cerebellum ; g, anterior column of the spinal cord ; h, lateral column ; p, pons Varolii ; i, i, its upper fibres ; v, v, roots of the fifth pair of nerves.



The combined mass of the medulla oblongata and pons has an oblong or rhomboidal form, being expanded in the middle, where it is continuous with the crura cerebelli, and tapering towards the spinal cord below and the mid-brain above. The transversely coursing fibres of the cerebellum produce a considerable prominence (*tuber annulare*) on the ventral surface of the upper or pontine part of the mass ; these fibres are arched upwards so as largely to conceal the crura cerebri from the ventral aspect. The length of the medulla oblongata from the lower part of the decussation of the pyramids to the pons is



nearly an inch (20 to 24 mm.), its greater breadth is about three-fourths of an inch (17 to 18 mm.); its thickness, from before backwards, is rather less (15 mm.). In the lower part where it joins the spinal cord, its diameters differ but little from those of the cord. The pons Varolii is about an inch long and rather more than an inch broad; it is considerably thicker than the medulla oblongata.

The *anterior* and *posterior median fissures* which partly divide the spinal cord are continued into similar fissures in the medulla oblongata. The anterior fissure terminates immediately below the pons in a recess, the *foramen cæcum* of Vicq d'Azyr; it is partly interrupted below by the decussating bundles of the pyramids; the posterior fissure is continued upwards to about the middle of the bulb, it ceases at the lower end of the fourth ventricle.

The structure of the medulla oblongata and pons will be most easily made clear by tracing the several parts of the spinal cord upwards.

In doing this it will be found that the relative position and extent of many of the parts are gradually altered, and that other parts which are not, so far as is known, represented in the spinal cord, become interpolated between those which are there met with. It will further be found that the change of relative position of the parts is largely owing to two causes. In the first place the sudden passage of large bundles of medullated fibres from the posterior part of the lateral column of the cord to the opposite side of the anterior median fissure appears to break up to a great extent the grey matter of the anterior horn, which is traversed by the bundles. In the second place the opening up of the central canal and separation of the lips of the posterior median fissure bring the grey matter to the surface in the fourth ventricle, whilst the posterior horn is coincidentally shifted to the side, much in the same way as it would be if a median incision were made from the posterior surface of the spinal cord into the central canal, and the two lateral halves were then turned outwards so that the sides of the posterior median fissure became the posterior surface of the cord.

The lines along which the cranial nerve-roots issue from the sides of the bulb mark the surface of the latter off into three chief columns on either side, which may

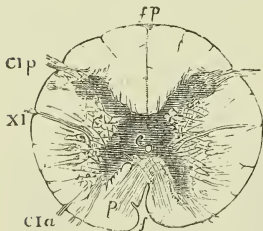


Fig. 31.—SECTION OF UPPER END OF SPINAL CORD AT THE JUNCTION WITH THE MEDULLA OBLONGATA. (After Lockhart Clarke.)

*f*, anterior; *fp*, posterior fissure; *p*, end of decussation of pyramids; *Cl**a*, *Cl**p*, anterior and posterior roots of first cervical nerve; *XI*, root of spinal accessory nerve; *c*, central canal.

be termed dorsal, lateral, and ventral respectively. Thus the spinal accessory or eleventh cranial nerve (figs. 32, 34, 35, *XI*) begins to take origin as far down as the lower end of the cervical region of the cord where its roots issue from the side of the cord, and lateral to the posterior roots of the cervical nerves (fig. 31). At the upper end of the cervical region, however, they are approached by the line of the posterior roots, and some of their bundles arise in conjunction with the posterior roots of the first and sometimes of the second cervical nerve. They are succeeded by the bundles of the vagus root, and these again by those of the glossopharyngeal. At the junction of the pons with the medulla oblongata the seventh nerve also is seen issuing along the same line, and still higher the large root of the fifth is given off from the lateral aspect of the pons. The line of exit of this series of nerve-roots is marked below by a shallow sulcus, but if traced upwards it will be seen that the sulcus is obliterated or nearly so before long, so that the issuing series of nerve-roots alone serves to mark its position. As it passes upwards it becomes gradually diverted outwards; so that opposite the place where the central canal opens into the calamus scriptorius of the fourth ventricle, the line in question has left the posterior surface and in the rest of its course runs along

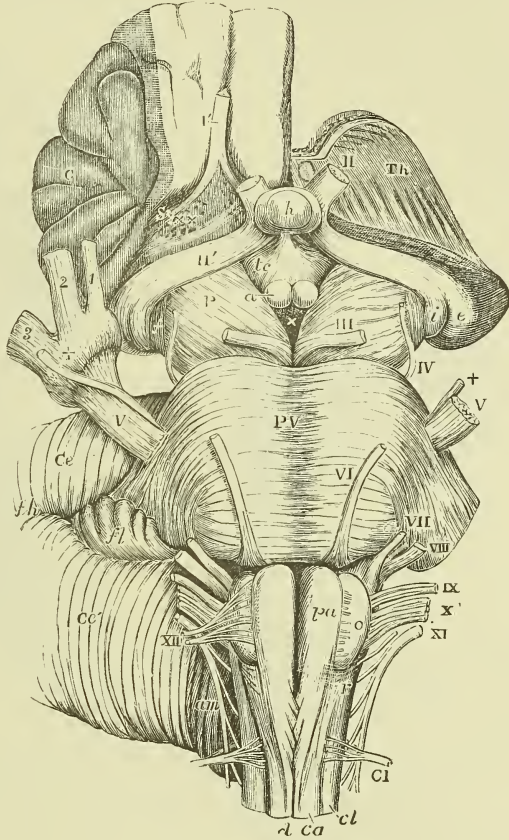
the lateral surface of the bulb. Towards the upper end it passes near the posterior margin of an oval prominence on the surface of the bulb termed the *olivary body* or *lower olive* (*o*), but is separated from that prominence by a tract of longitudinal fibres. In transverse sections of the lower part of the medulla

Fig. 32.—VIEW FROM BEFORE OF THE MEDULLA OBLONGATA, PONS VAROLII, CRURA CEREBRI, AND OTHER CENTRAL PORTIONS OF THE ENCEPHALON. (Allen Thomson.) NATURAL SIZE.

On the right side the convolutions of the central lobe or island of Reil have been left, together with a small part of the anterior cerebral convolutions: on the left side these have been removed by an incision carried between the thalamus opticus and the cerebral hemisphere.

I', the olfactory tract cut short and lying in its groove; II, the left optic nerve in front of the commissure; II', the right optic tract; *Th*, the cut surface of the left thalamus opticus; *C*, the central lobe or island of Reil; *Sy*, fissure of Sylvius; × ×, anterior perforated space; *e*, the external, and *i*, the internal corpus geniculatum; *h*, the hypophysis cerebri or pituitary body; *tc*, tuber cinereum with the infundibulum; *a*, one of the corpora albicantia; *P*, the cerebral peduncle or crus; III, close to the left oculo-motor nerve; ×, the posterior perforated space.

The following letters and numbers refer to parts in connection with the medulla oblongata and pons. PV, pons Varolii; *V*, the greater root of the fifth nerve; +, the lesser or motor root; *VI*, the sixth nerve; *VII*, the facial; *VIII*, the auditory nerve; *IX*, the glossopharyngeal; *X*, the pneumogastric nerve; *XI*, the spinal accessory nerve; *XII*, the hypoglossal nerve; *C I*, the suboccipital or first cervical nerve; *o*, olive; *d*, anterior median fissure of the spinal cord, above which the decussation of the pyramids is represented; *c a*, anterior column of cord; *r*, lateral tract of bulb continuous with *c l*, the lateral column of the spinal cord.



oblongata (fig. 33) it is seen that the bundles of fibres of these nerve-roots traverse the substance of the bulb to reach a group of nerve-cells in the grey matter near the central canal and thus mark off a somewhat oval area on each side at the posterior part of the section. This area is termed by Flechsig the *posterior area of the medulla oblongata*, and the tracts of white fibres which can be traced, as will be immediately noticed, upon the surface of this part, may therefore be conveniently termed its *posterior columns*. They correspond in position to the posterior columns of the spinal cord.

The line of origin of the anterior roots of the spinal nerves, although not marked in the spinal cord by a distinct furrow like that whence the posterior roots issue, yet when traced upwards into the bulb, deepens into a well-marked longitudinal groove which is continued almost vertically as far as the lower border of the projecting mass of the pons. In its upper part this groove separates the olivary prominence from the prominence of the pyramid. Just below the olive it is often obliterated for a certain part of its course by a band of transverse fibres. The root-bundles of the hypoglossal nerve (figs. 32, 33, 34, *XII*) pass out from this furrow,



and those of the sixth nerve emerge in the same line with it but at the lower border of the pons Varolii. In transverse sections of the medulla oblongata and pons these root-bundles may be traced back through the substance of the organ to a group or column of nerve-cells situated in a portion of grey matter close to the antero-lateral side of the central canal in the lower closed part of the bulb (fig. 43), and close to the middle of the fourth ventricle in the upper opened-out part (figs. 44, 45). This

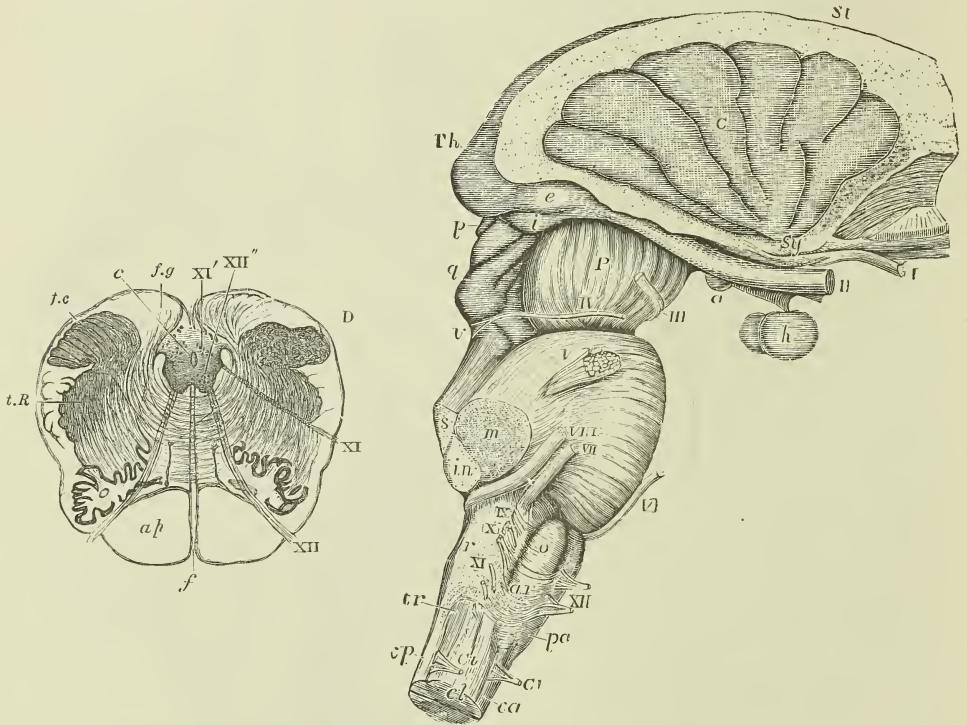


Fig. 33.—SECTION ACROSS THE MEDULLA OBLONGATA A LITTLE BELOW THE POINT OF THE CALAMUS SCRIPTORIUS. (Lockhart Clarke.)

*c*, central canal; *f*, anterior median fissure; *f.g.*, funiculus gracilis; *f.c.*, funiculus cuneatus; *t.R.*, tubercle of Rolando; *o*, olivary body; *a.p.*, pyramid; XI, XII, spinal accessory and hypoglossal nerves; XI', XII', their nuclei.

Fig. 34.—VIEW OF THE MEDULLA OBLONGATA, PONS VAROLII, CRURA CEREBRI, AND CENTRAL PARTS OF THE ENCEPHALON FROM THE RIGHT SIDE. (Allen Thomson.)

The corpus striatum and thalamus opticus have been preserved in connection with the central lobe and crura cerebri, while the remainder of the cerebrum has been removed.

*St*, upper surface of the corpus striatum; *Th*, back part of the thalamus opticus (pulvinar); *C*, placed on the middle of the five or six convolutions constituting the central lobe or island of Reil, the cerebral substance being removed from its circumference; *Sy*, fissure of Sylvius, from which these convolutions radiate, and in which are seen the white striae of the olfactory tract; *I*, the olfactory tract divided and hanging down from the groove in the convolution which lodges it; *II*, optic nerves a little way in front of the commissure; *a*, right corpus albicans with the tuber cinereum and infundibulum in front of it; *h*, hypophysis or pituitary body; *e*, external, and *i*, internal corpus geniculatum at the back part of the optic tract; *P*, peduncle or crus of the cerebrum; *III*, right oculo-motor nerve; *p*, pineal gland; *q*, corpora quadrigemina; *IV*, trochlear nerve rising from *v*, the valve of Vieussens.

The following numbers and letters refer chiefly to parts in connection with the medulla oblongata and pons. *V*, placed on the pons Varolii above the right nervus trigeminus; *s*, the superior, *m*, the middle, and *in*, the inferior peduncle of the cerebellum cut short; *VI*, the sixth nerve; *VII*, facial nerve; *VIII*, auditory nerve; *IX*, the glosso-pharyngeal nerve; *X*, placed opposite to the cut end of the pneumogastric nerve; and *XI*, the uppermost fibres of the spinal accessory nerve; *XII*, the hypoglossal nerve; *p a*, pyramid; *o*, olive; *a r*, arciform fibres; *r*, restiform body; *tr*, tubercle of Rolando; *c a*, anterior, *c p*, posterior, and *c l*, lateral columns of the spinal cord; *C I*, *C i*, anterior and posterior roots of the first cervical nerve.



portion of grey matter is continuous below with part of the anterior horn, and the roots of the hypoglossal and sixth nerve appear to correspond generally with the anterior roots of the spinal nerves. In traversing the substance of the bulb they mark off an *anterior area*, wedge-shaped in transverse section, which is placed between them and the anterior median fissure. This area is on the surface marked by the prominence known as the *pyramid* or *anterior pyramid*, which corresponds in position (but only to a small extent in the fibres of which it is composed) with the anterior column of the spinal cord. The remainder of the transverse section of the bulb, after the posterior and anterior areas are deducted, lies between the line of nerve-root bundles of the hypoglossus and sixth on the one side, and that of the successive bundles of the spinal accessory, vagus, glosso-pharyngeal, and seventh on the other. This is termed by Flechsig the *lateral area*, and on the surface it is marked by a continuation of part of the lateral column of the cord, and by the prominence of the lower olive already alluded to.

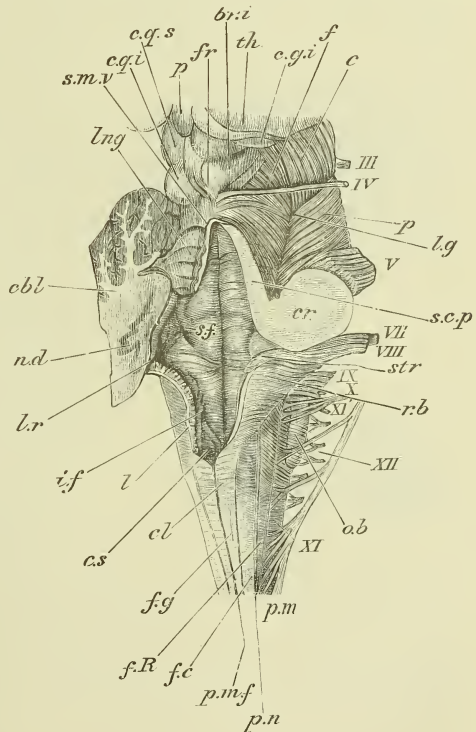
We may now proceed to describe in detail the several parts which appear upon the surface of the bulb in the three regions thus marked off by the two sets of nerve-roots, commencing with the posterior area.

**Posterior area.** It will be remembered that in the upper region of the spinal cord a small portion of the whole posterior column is marked off from the rest by a well-developed pia-matral septum, and is indicated on the surface by a distinct

Fig. 35.—POSTERIOR AND LATERAL VIEW OF THE MEDULLA OBLONGATA, FOURTH VENTRICLE AND MESENCEPHALON. (E.A.S.) NATURAL SIZE.

The cerebellum and inferior medullary velum, and the right half of the superior medullary velum, have been cut away, so as to expose the fourth ventricle.

*p.n.*, line of the posterior roots of the spinal nerves; *p.m.f.*, posterior median fissure; *f.g.*, funiculus gracilis; *cl.*, its clava; *f.c.*, funiculus cuneatus; *f.R.*, funiculus of Rolando; *r.b.*, restiform body; *c.s.*, lower end of the fourth ventricle (calamus scriptorius); *l.*, section of the lingula or tænia; part of the choroid plexus is seen beneath it; *l.r.*, lateral recess of the ventricle; *str.*, striæ acusticæ; *i.f.*, inferior (posterior) fovea; *s.f.*, superior (anterior) fovea; between it and the median sulcus is the funiculus teres; *cbl.*, cut surface of the left cerebellar hemisphere; *n.d.*, central grey matter (nucleus dentatus) seen as a wavy line; *s.m.v.*, superior (anterior) medullary velum; *lng.*, lingula; *s.c.p.*, superior cerebellar peduncle cut longitudinally; *cr.*, combined section of the three cerebellar peduncles (the limits of each are not marked); *c.g.s.*, *c.q.i.*, corpora quadrigemina (superior and inferior); *fr.*, frænulum veli; *f.*, fibres of the fillet, seen on the surface of the tegmentum; *c.*, crusta; *l.g.*, lateral groove; *c.g.i.*, corpus geniculatum internum; *th.*, posterior part of thalamus; *p.*, pineal body. The Roman numbers indicate the corresponding cranial nerves.



longitudinal prominence bounded laterally by a shallow groove. The portion thus marked off is the postero-mesial column (tract of Goll), and the prominence, which is continued up into the medulla oblongata, becomes there still better marked, and is known as the *funiculus gracilis* (fig. 35, *f.g.*). This, as it is traced upwards, especially as the fourth ventricle is approached, broadens out into an expansion termed the *clava* (*cl.*), and as the ventricle opens out the clavæ of opposite sides diverge and form the lateral boundary to the

ventricle in its lower part. Above, the clavæ are tapered off and soon become no longer traceable.

The funiculi graciles with their clavæ are sometimes described as the *posterior pyramids*.

Between the postero-mesial column and the postero-lateral groove from which the posterior roots of the cervical nerves pass out there is found in the upper part of the cord a single distinct column, viz., the postero-lateral column (tract of Burdach). This is also prolonged into the medulla, and also like the funiculus gracilis expands as it is traced upwards: it is here known as the *funiculus cuneatus*. Outside this funiculus cuneatus and between it and the line of roots of the spinal accessory another longitudinal prominence is caused by the fact that the substantia gelatinosa of Rolando begins near the lower end of the bulb to project towards the surface as a distinct funiculus, narrow below but broadening as it is traced upwards, where it forms a considerable eminence known as the *tubercle of Rolando*. The longitudinal prominence which passes up into it, is termed therefore by Schwalbe, the *funiculus of Rolando* (fig. 35, *f.R.*).

The funiculus of Rolando is termed by Henle the lateral cuneate funiculus.

On a level with the adjoining clava of the funiculus gracilis, the enlarged part of the cuneate funiculus also, like that, exhibits a slight eminence, which is best marked in children, and has been termed the *cuneate tubercle* (Schwalbe).

In the upper part of the medulla oblongata, the cuneate funiculus is concealed by a set of fibres (*external arched or arcuate fibres*) which issue from the anterior median

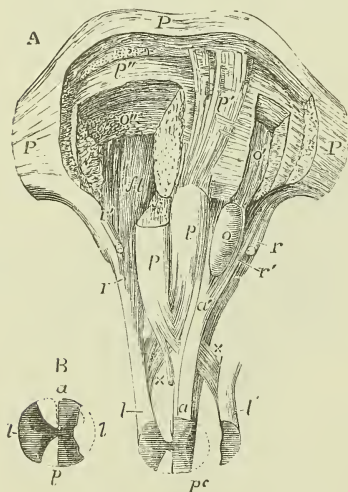


Fig. 36.—DISSECTION OF THE MEDULLA OBLONGATA AND PONS VAROLII SHOWING THE COURSE OF THE PYRAMIDAL TRACTS IN THEM. (Allen Thomson.)

P, pons Varolii; *p*, the pyramids, the upper part of the right one has been cut away; *p'*, the fibres of the left pyramid, as they ascend through the pons, exposed by the removal of the superficial transverse fibres; *p''* is placed on some deeper transverse fibres of the pons on the right side, below the divided fibres of the right pyramid; *a*, left anterior column of the cord, its median part passes upwards into the outer part of the pyramid, the remainder dips beneath the pyramid and olivary body; *o*, olivary body; *o'*, the continuation of part of the lateral column ascending through the pons and exposed by the removal of a small portion of the deeper transverse fibres; *o''*, some of the same fibres divided by a deeper incision on the right side; *l*, *l'*, the lateral columns of the cord; *x*, their deeper parts passing by decussation into the pyramids; *r*, direct cerebellar tract passing from the lateral column into the inferior peduncle of the cerebellum, or restiform body; *r'*, fasciculus passing from the anterior column to the same; *ft*, deep longitudinal fibres derived from the anterior and lateral columns of the cord.

B, explanatory outline of the section of the spinal cord, *a*, anterior columns; *p*, posterior; *l*, lateral.

fissure and passing laterally over the surface of the pyramid and olive, turn upwards to join the restiform body. There is also a narrow strand of fibres from the lateral column of the cord, marked by its white appearance, which joins this tract of oblique fibres just above the level of the tubercle of Rolando. This is the *dorso-lateral (direct) cerebellar tract* which has been already noticed in the description of the spinal cord. These obliquely crossing fibres turn upwards as they cross the funiculus of Rolando, and appear to blend with that column and with the cuneate funiculus. They do not, however, actually blend with them, but are reinforced by a large number of fibres coming from the opposite side of the bulb (see p. 52, fig. 44), and the whole mass of fibres thus produced forms a rounded, prominent cord, the *corpus restiforme*, or like body (fig. 36, *r'*), which passes directly into the corresponding hemisphere of the cerebellum, constituting its inferior peduncle.

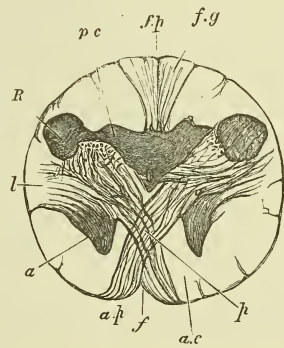
**Lateral area.**—The lateral column of the spinal cord appears, on the surface, to be directly continued upwards into the lateral area of the medulla oblongata. In reality, however, a considerable tract of the white fibres—that which in the spinal cord we have noticed as the lateral pyramidal tract—is found, at the upper end of the spinal cord, to cross obliquely in stout bundles through the grey matter of the anterior horn, and across the anterior median fissure to the other side of the bulb, where it forms the mesial and larger part of the pyramid (figs. 36, 37). The rest of the lateral column can be traced vertically upwards (with the exception of the dorso-lateral cerebellar tract which passes backwards into the restiform body) as far as the lower end of the olive where its longitudinally coursing fibres become concealed by this prominence and by the arched fibres already noticed.

The **olivary body** or **lower olive** (figs. 32, 34, 36, *o*) is, as its name implies, an olive-shaped prominence, which lies in the upper part of the bulb, immediately above the apparent termination of the lateral column, and extending nearly as far as the lower border of the pons, being only separated from this by a deep groove in which is sometimes a small band of arched fibres. The line of exit of the hypoglossal nerve-roots lies on its inner or mesial border, that of the accessory, vagus and glosso-pharyngeal roots along its outer side, but the latter are separated from it by a groove in which longitudinal fibres prolonged from the ventro-lateral cerebellar tract can be seen. Sometimes there is a small longitudinal tract running along its inner border also, and in such case, with the arched fibres above and below, the olive appears to be entirely enclosed by a fibrous strand, which has sometimes been described as its capsule (*siliqua olive*). This name is, however, more applicable to a layer of fibres which immediately surrounds the dentate nucleus of the olive (see note on p. 56, and fig. 44, *s.o.*). The longitudinal tracts on either side of the olive are often concealed in great measure by the arched fibres, which may form a complete superficial layer over the olive, and indeed over the whole anterior and lateral surface of this upper part of the medulla oblongata.

**Anterior area.**—The anterior columns of the cord, although on superficial inspection they appear to be prolonged into the pyramids of the bulb, are so

Fig. 37.—SECTION OF THE MEDULLA OBLONGATA AT THE MIDDLE OF THE DECUSSATION OF THE PYRAMIDS. (Lockhart Clarke.)

*f*, anterior; *f.p.*, posterior fissure; *a.p.*, pyramid; *a*, remains of part of anterior cornu, separated by the crossing bundles from the rest of the grey matter; *l*, continuation of lateral column of cord; *R*, continuation of substantia gelatinosa of Rolando; *p.c.*, continuation of posterior cornu of grey matter; *f.g.*, funiculus gracilis.



only to a small extent. For the lateral pyramidal bundles, crossing the anterior median fissure from the lateral column, are continued upwards close to that fissure, and unite with the comparatively small anterior pyramidal bundle to constitute the prominence known as the *pyramid* (anterior pyramid). The prolongation upwards of the rest of the anterior column of the cord lies deeply, being altogether concealed from view by the pyramids.

The **pyramids** (figs. 30, *a*, 32, *pa*), are more prominent above than below. They are bounded mesially by the anterior median fissure, and laterally by the olivary bodies, being separated from these by the groove before mentioned, from which the roots of the hypoglossal nerve issue. At their upper end they are constricted, and become more completely separated from the rest of the medulla oblongata. They are here very frequently crossed by a band of arched fibres, the



*ponticulus* of Arnold. Each pyramid then enters the substance of the pons in one large bundle, which soon breaks up into several bundles, and these may be traced through the pons into the corresponding peduncle of the cerebrum.

The *decussation of the pyramids* is the name given to the obliquely crossing bundles of the lateral pyramidal tract which are seen in the anterior median fissure at the lower part of the medulla oblongata. The extent to which the decussation is visible varies considerably in different individuals; for in some the bundles take a deeper, in others a more superficial course. Further, in some cases a larger share than usual of the longitudinal fibres of the pyramids passes down in the anterior pyramidal tract and a correspondingly smaller share in the lateral pyramidal tract. And since the anterior tract, which in the pyramid is external to the lateral tract, does not cross in the medulla oblongata but merely passes obliquely at its lower end to attain the side of the anterior median fissure, the decussation in these cases is of less extent. On the other hand, in rare cases, the whole of the fibres of the pyramid may cross over at the lower part of the bulb and become lateral pyramidal tract, in which case the anterior or uncrossed tract is wanting in the cord, and the bulbar decussation is very well marked. All transitions are found between these two conditions (see p. 24).

The **pons Varolii** forms a prominence marked by transverse fibres above and in front of the medulla oblongata, and between the lateral hemispheres of the

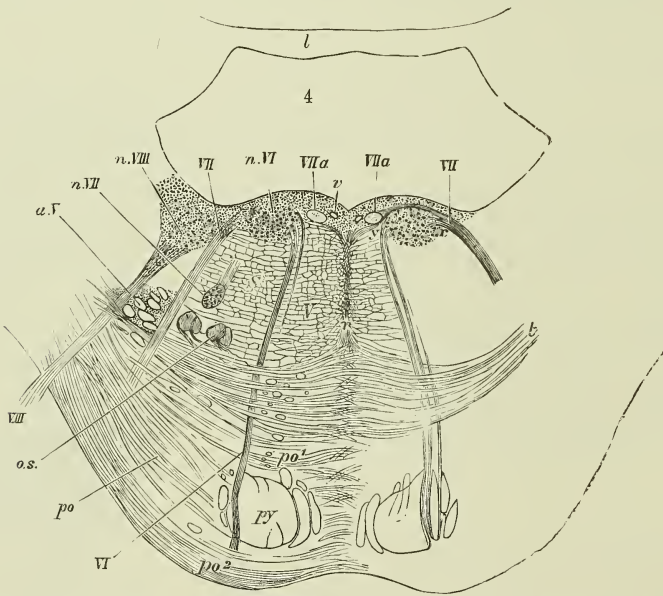


Fig. 38.—TRANSVERSE SECTION THROUGH LOWER PART OF PONS VAROLII. (After Stilling and Schwalbe.)

The description of this figure is given on p. 61.

cerebellum (fig. 38); at the sides its transverse fibres are gathered together into a compact mass, which passes into the cerebellum, and is named the *middle crus* or *middle peduncle of the cerebellum*. On its ventral surface the pons has a shallow median groove along which the basilar artery runs, and it is perforated by small branches of the artery. The groove is in some measure due to the circumstance that the pyramids of the medulla oblongata are continued up through the pons with a slightly divergent course, and thus produce a prominence on either side of the middle line, covered, however, by the superficial transverse fibres.

The pons consists ventrally of transverse cerebellar fibres, between which the longitudinal fibres prolonged upwards from the medulla oblongata pass ; together with a large intermixture of grey matter. The superficial fibres on the ventral surface (fig. 30, *p*) are transverse in their general direction, but while the middle fibres are exactly transverse, the lower set ascend slightly, and the superior fibres (fig. 30, *i*), which are the most curved, descend obliquely to reach the crus cerebelli on each side ; some of the upper fibres cross obliquely the middle and lower ones, so as to conceal them at the sides. When the superficial transverse fibres are removed, the prolonged fibres of the pyramids come into view (fig. 36) ; these, as they ascend through the pons, are separated into smaller bundles, intersected by other transverse white fibres, which, with those upon the surface, are all continued into the middle peduncle of the cerebellum.

At the lower part of the pons, dorsal to the fibres from the pyramids, is a special set of transverse fibres (fig. 38, *t*), named the **trapezium** (*corpus trapezoides*)—so called because in most mammals, in which the inferiorly situated fibres of the pons are less developed and the pyramids are small, these transverse fibres partially appear on the surface in an area of a somewhat four-sided shape. Laterally they curve round a collection of grey matter, called the superior olivary nucleus (fig. 38, *o.s.*), and probably many of them are connected with its cells. They then course lateralwards, across the bundles of the facial nerve-roots (*VII*), and ventral to the upward prolongation of the substantia gelatinosa of the tubercle of Rolando and the bundles of fibres belonging to the ascending root of the fifth nerve (*a.V*), and appear to become connected with the accessory auditory nucleus (p. 55) and with the ventral root of the auditory nerve, of which, according to Flechsig, the trapezium forms a cerebral commissure.

**The fourth ventricle.**—The external characters of the medulla oblongata and pons may be completed by a description of those parts which enter into the boundaries of the fourth ventricle. This is the space into which the central canal of the cord, after becoming somewhat enlarged and cleft-like, opens out superiorly (fig. 39). The opening-out seems as if effected by the divergence of the funiculi graciles et cuneati on either side at an acute angle. These funiculi, which form the lateral boundaries of the lower part of the ventricle, bend round laterally at about the middle (in length) of the medulla oblongata, so that the ventricle, which is at first narrow, rapidly broadens. Opposite the middle peduncle of the cerebellum it has attained its greatest width. From this point its upper part again narrows, converging gradually above to be continued into the comparatively narrow Sylvian aqueduct. The ventricle is therefore irregularly lozenge- or diamond-shaped, and is sometimes named *fossa rhomboidalis*. The pointed lower end of the ventricle has the shape of a writing pen, and is termed the *calamus scriptorius* (fig. 39, *c.s.*). At its widest part the fourth ventricle is continued for a short distance on either side between the cerebellum and bulb where these come in contact, in the form of the pointed *lateral recess* (*l.r.*). The **lateral boundaries of the ventricle** are, in its lower or medullary part, the clavæ of the funiculi graciles, the funiculi cuneati, and the restiform bodies ; in its upper half the superior peduncles of the cerebellum (fig. 39, *s.c.p.*). These pass gradually to the roof of the ventricle as they extend upwards. They are at first separated from one another by a tolerably wide interval which, however, gradually narrows near the end of the ventricle, the two crura of opposite sides there approaching one another, and their margins coming in contact. **Roof of the ventricle.** The triangular interval between the two crura is bridged over by a lamina of white matter marked across with grey streaks. This is the *superior medullary velum* or *valve of Vieussens* (fig. 39, *s.m.v.*), and, with the crura, forms the roof or dorsal boundary of the upper part of the fourth ventricle. The white substance of which it is mainly composed

is marked dorsally by three or four flat transverse grey laminae, with intervening sulci, which together constitute the *lingula* (fig. 39, *lng*). This is continued laterally into the grey cortex of the cerebellum, while the subjacent white substance of the velum is in direct continuity with the central white matter of the cerebellum,

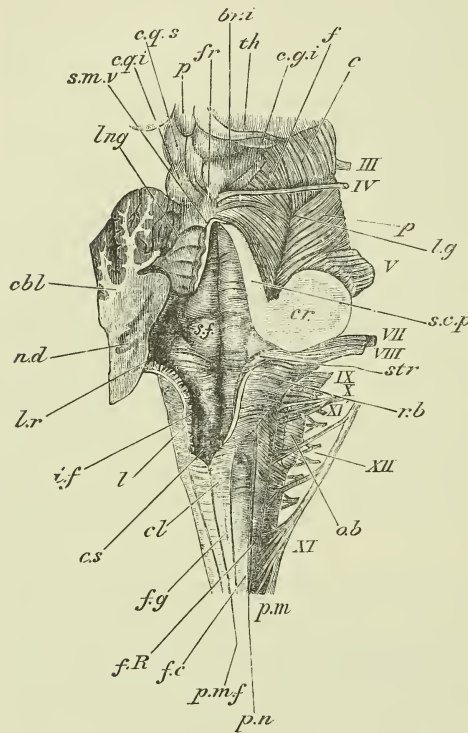


Fig. 39.—POSTERIOR AND LATERAL VIEW OF THE MEDULLA OBLONGATA, FOURTH VENTRICLE AND MENENCEPHALON. (E. A. S.) NATURAL SIZE.

The cerebellum and inferior medullary velum, and the right half of the superior medullary velum, have been cut away, so as to expose the fourth ventricle.

*p.n.*, line of the posterior roots of the spinal nerves; *p.m.f.*, posterior median fissure; *f.g.*, funiculus gracilis; *cl.*, its clava; *f.c.*, funiculus cuneatus; *f.R.*, funiculus of Rolando; *r.b.*, restiform body; *c.s.*, lower end of the fourth ventricle (calamus scriptorius); *l*, section of the ligula or tania; part of the choroid plexus is seen beneath it; *l.r.*, lateral recess of the ventricle; *str*, strie acusticæ; *i.f.*, inferior (posterior) fovea; *s.f.*, superior (anterior) fovea; between it and the median sulcus is the funiculus teres; *cbl*, cut surface of the left cerebellar hemisphere; *n.d.*, central grey matter (nucleus dentatus) seen as a wavy line; *s.m.v.*, superior (anterior) medullary velum; *lng*, lingula; *s.c.p.*, superior cerebellar peduncle cut longitudinally; *cr.*, combined section of the three cerebellar peduncles (the limits of each are not marked); *c.g.s.*, *c.g.i.*, corpora quadrigemina (superior and inferior); *fr*, frænulum veli; *f*, fibres of the fillet, seen on the surface of the tegmentum; *c*, crusta; *l.g.*, lateral groove; *c.g.i.*, corpus geniculatum inferum; *th*, posterior part of thalamus; *p*, pineal body. The Roman numbers indicate the corresponding cranial nerves.

into which a pointed tent-shaped projection of the roof of the ventricle extends (fig. 59, A, in longitudinal section). This projection is bounded below by the *inferior medullary velum*, which in like manner is prolonged from the white substance of the central part of the cerebellum. It is less easily displayed than the superior velum, being concealed by

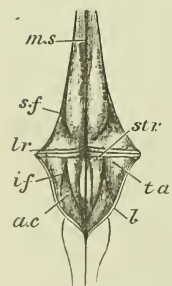


Fig. 40.—ANTERIOR BOUNDARY (FLOOR) OF THE FOURTH VENTRICLE. (E. A. S.) NATURAL SIZE.

*m.s.*, median sulcus; *str*, strie acusticæ, marking the limit between the pontine part of the ventricle and the medullary part or calamus scriptorius; *l.r.*, lateral recess; *i.f.*, inferior (posterior) fovea; *a.c.*, ala cinerea; *t.a.*, trigonum acustici; *s.f.*, superior (anterior) fovea, close to the lateral margin of the superior part of the ventricle.

a part of the cerebellum, which is attached to its under or posterior surface. It will be further noticed in the description of the cerebellum. Below the inferior velum the roof is formed by a simple layer of flattened epithelium covered by pia mater; but it is not quite complete, for there is a hole in it termed the *foramen of Majendie* a little above the place where the central canal opens out into the ventricle, and there are two other apertures in the epithelial roof in the lateral recesses just mentioned. At the sides and below, this layer of epithelium passes into continuity with the epithelium covering the floor,



but it is somewhat thickened by the addition of white nervous matter before reaching the lateral boundaries of the floor. This thickening is left as a slightly prominent and often ragged membrane when the epithelium of the roof of the

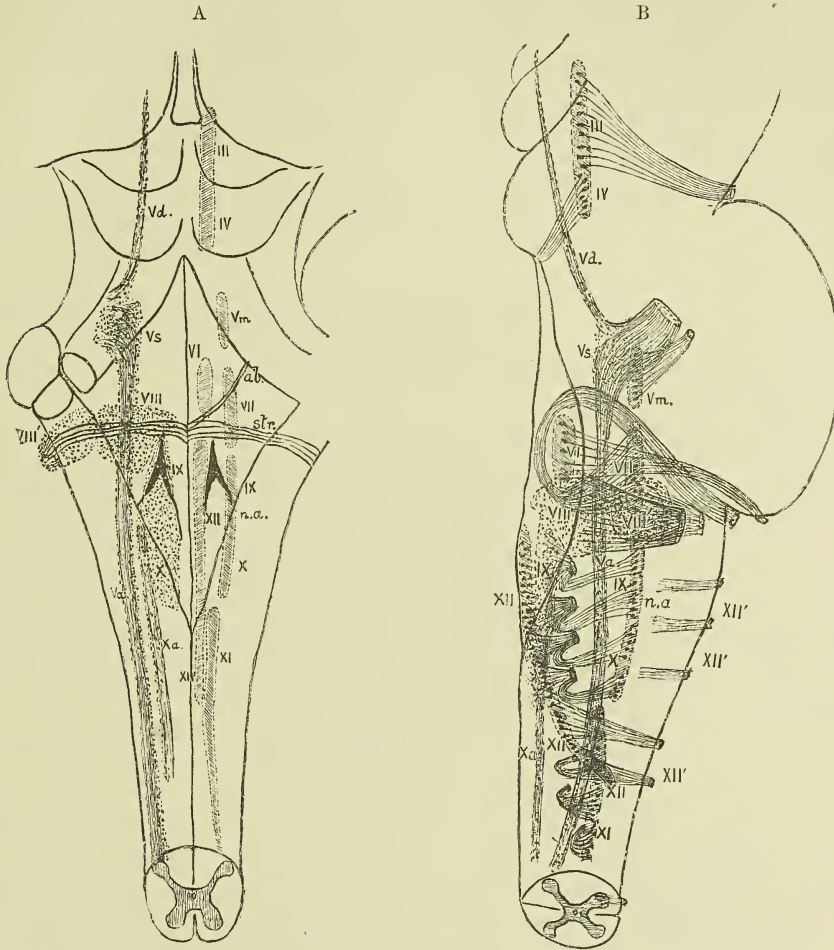


Fig. 41.—DIAGRAMS TO SHOW THE SITUATION OF THE CHIEF NERVE-NUCLEI IN THE MEDULLA OBLONGATA AND PONS NEAR THE FLOOR OF THE 4TH VENTRICLE. TWICE THE NATURAL SIZE.

A, from behind; B, profile view of the right half, the medulla and pons being supposed to be transparent. The efferent or motor nuclei are shaded with oblique lines, the afferent or sensory nuclei with dots. In A the efferent or motor nuclei are represented on the right side only, the afferent or sensory nuclei on the left. III, IV, oculomotor and trochlear nucleus; Vd., descending root of the fifth nerve; Vs., so-called sensory nucleus of the fifth; Va., ascending root of the fifth; Vm., motor nucleus of fifth nerve; VI, nucleus of abducens; VII, nucleus of facial; n. VII, root of facial curving round abducens nucleus; VIII, inner or dorsal nucleus of auditory; VIII', outer or ventral nucleus of auditory; IX, X, vago-glossopharyngeal nucleus; n.a., nucleus ambiguus, accessory or efferent vago-glossopharyngeal nucleus; XI, nucleus of spinal accessory; XII, nucleus of hypoglossal; XII', issuing roots of hypoglossal.

ventricle is torn off with the pia mater. It commences at the apex of the clava, and accompanies the lateral boundary for a short distance; then turns over the surface of the restiform body and terminates close to the place whence the roots of the vagus and glosso-pharyngeal nerves issue. It is termed the *tenia* or *ligula* (fig. 44, *t*), and its upper transverse part forms the lower boundary of the lateral

recess of the ventricle. Another thickening of the roof is seen at the apex of the ventricle covering the point of the calamus scriptorius : this is named the *obex*.

Two longitudinal vascular inflexions of the pia mater, known as the choroid plexuses of the 4th ventricle, project from the roof into the cavity, one on either side of the middle line, covered everywhere, however, by the epithelium of the roof. Offsets from these pass also into the lateral recesses, from the apices of which they emerge, encircled by a duplicate of the ligula, which was termed by Bochdalek the *cornucopia*. The epithelial layer of the roof of the ventricle follows all the convolutions of the choroid plexuses, but is nowhere pierced by them ; it is generally described as the epithelium of the plexuses.

The **floor or ventral boundary of the 4th ventricle** is marked at its widest part, *i.e.*, at the level of the lateral recesses, by some transverse white lines, which cross the grey matter of the floor, and are known as the *striae medullares seu acusticae* (figs. 39, 40, 41, *str*).

These striae are caused by bundles of white fibres which emerge from the raphe, within which they can be traced to the ventral surface of the bulb, and curve outwards over the restiform body, where they are usually described as passing into the lateral root of the auditory nerve. It is certain, however, that this is not the destination of most of the fibres of the medullary striae, which are distinctly to be traced to the flocculus of the cerebellum (fig. 49, p. 59). They vary greatly in development even upon the two sides of the same brain (compare especially Bechterew, *Neurol. Centralbl.*, No. 10, 1892).

One bundle of these *striae* is sometimes seen, usually on one side only, taking a course obliquely upwards and outwards, passing at the lateral boundary of the ventricle into the middle cerebellar peduncle (*aberrant bundle of striae medullares, Klangstab* of Bergmann).

The floor of the ventricle is bisected by a slight median groove. A little on either side of this groove and immediately below the striae medullares, is a small triangular depression (*inferior fovea*, fig. 40, *i.f.*), the apex of which extends only as far as the striae, but the base is prolonged into two grooves extending one from each angle. The inner of the two grooves passes with a slightly curved course towards the point of the calamus scriptorius, and thus cuts off a pointed triangular area, which is bounded mesially by the median sulcus, and the base of which is turned towards the striae acusticae. This area (*trigonum hypoglossi*) is slightly prominent, and constitutes the lower end of the fasciculus teres ; in it is the prolongation of the tract of nerve-cells from which the roots of the hypoglossal nerve take origin. The outer of the two grooves passes downwards with a slight outward obliquity nearly to the lateral boundary of the ventricle, and marks off externally another triangular area (*trigonum acustici, t.a.*), the base of which is also directed upwards, where it can be traced into a prominence (best marked in children) over which the striae acusticae course. To this prominence the name *tuberculum laterale seu acusticum* has been applied, since the main part of the auditory nerve arises in connection with it and with the triangular lateral area below it.

Included between the two grooves is a third triangular area (*trigonum vagi*), the apex of which is at the inferior fovea, while its base looks downwards and outwards. This area has a distinctly darker colour than the rest of the floor of the ventricle, and especially than the trigonum hypoglossi on the inner side, which has a whitish grey appearance, and it has accordingly been named the *ala cinerea (a.c)*. Towards the apex it is somewhat depressed, but below it is elevated into a distinct prominence (*eminentia cinerea*). It contains the nucleus of the vagus, and superiorly, near the inferior fovea, of the glosso-pharyngeal nerve.

Above the striae acusticae the floor of the fourth ventricle is marked in the middle of each lateral half by a distinct somewhat angular depression in a line with the inferior fovea, from which it is separated by the eminence over which the striae acusticae pass. This depression is termed the *superior fovea (s.f.)*. Between it and the median sulcus is the prolongation of the funiculus teres, which is pro-

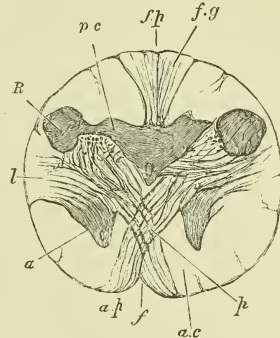
minent (*eminentia teres*) opposite the fovea but becomes gradually less so above and below. Extending from the superior fovea to the upper end of the ventricle, where this narrows to the Sylvian aqueduct, is a shallow depression (*locus caeruleus*) distinguished in the adult by its dark grey or slaty tint, which is due to a subjacent tract of pigmented nerve-cells (*substantia ferruginea*). The trophic fibres in the fifth nerve have been supposed to be derived from these cells.

## INTERNAL STRUCTURE OF THE MEDULLA OBLONGATA.

The internal structure of the medulla, like the external form, will be best understood by tracing its several parts upwards from the spinal cord; and this can be

Fig. 42.—SECTION OF THE MEDULLA OBLONGATA AT THE MIDDLE OF THE DECUSSATION OF THE PYRAMIDS (Lockhart Clarke).

*f.*, anterior; *f.p.*, posterior fissure; *a p.*, pyramid; *a.*, remains of part of anterior cornu, separated by the crossing bundles from the rest of the grey matter; *l.*, continuation of lateral column of cord; *R.*, continuation of substantia gelatinosa of Rolando; *pc.*, continuation of posterior cornu of grey matter; *f.g.*, funiculus gracilis.

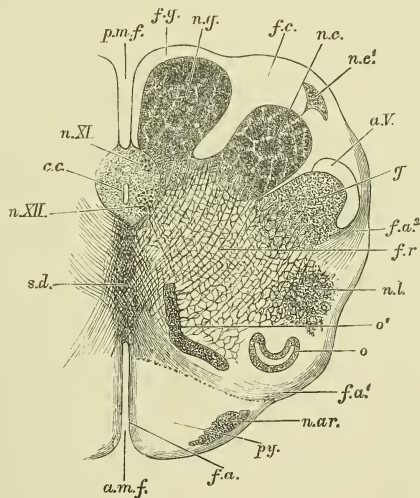


most readily done by a comparison of the appearances of successive transverse sections.

**Lower or closed part of the medulla oblongata.**—The first changes are produced, in its internal structure as in its external form, by the passage of the fibre-bundles of the lateral pyramidal tract obliquely through the grey matter of the anterior horn, and across the anterior median fissure to the pyramid of the opposite side (fig. 42). By this abrupt passage of a large number of white fibres through it, the anterior horn is broken up, and one part, the caput cornu (*a.*), is entirely separated from the rest of the grey matter; whilst only

Fig. 43.—SECTION OF THE MEDULLA OBLONGATA IN THE REGION OF THE SUPERIOR PYRAMIDAL DECUSSATION. (Schwalbe.) †

*a.m.f.*, anterior median fissure; *f.a.*, superficial arciform fibres emerging from the fissure; *py*, pyramid; *n.ar.*, nucleus of the arciform fibres; *f.a.*, deep arciform fibres becoming superficial; *o.*, lower end of olivary nucleus; *o'*, accessory olivary nucleus; *n.l.*, nucleus lateralis; *f.r.*, formatio reticularis; *f.a.*<sup>2</sup>, arciform fibres proceeding from formatio reticularis; *g.*, substantia gelatinosa of Rolando; *a.V.*, ascending root of fifth nerve; *n.c.*, nucleus cuneatus; *n.c.*<sup>1</sup>, external cuneate nucleus; *f.c.*, funiculus cuneatus; *n.g.*, nucleus gracilis; *f.g.*, funiculus gracilis; *p.m.f.*, posterior median fissure; *c.c.*, central canal surrounded by grey matter, in which are, *n.XI.* nucleus of the spinal accessory, and, *n.XII.* nucleus of the hypoglossal; *s.d.*, decussation of fillet or superior pyramidal decussation.



the base of the horn remains, as a small portion of grey matter close to the anterolateral aspect of the central canal.

The separated portion of the anterior horn becomes pushed over to the side by the development of the pyramid and the interpolation higher up of the olivary body between them, so that it comes to lie close to the separated caput cornu posterioris (see below). The greater part of the grey substance is broken up into a *formatio reticularis* (fig. 43, *f.r.*), i.e. a compara-



tively coarse network of grey matter containing nerve-cells, intersected by bundles of white fibres; but a small part, probably representing the lateral horn of the cord, and like that containing numerous nerve-cells many of relatively large size, remains for a time in the lateral column, near the surface, and is known as the *nucleus lateralis* (fig. 43, *n.l.*).

Meanwhile the posterior horns have become gradually shifted laterally, simultaneously with an increase in size of the posterior columns of the medulla, so that in place of forming an acute angle with the posterior median fissure, they now lie almost at right angles to it (fig. 42). Moreover, the caput cornu enlarges and

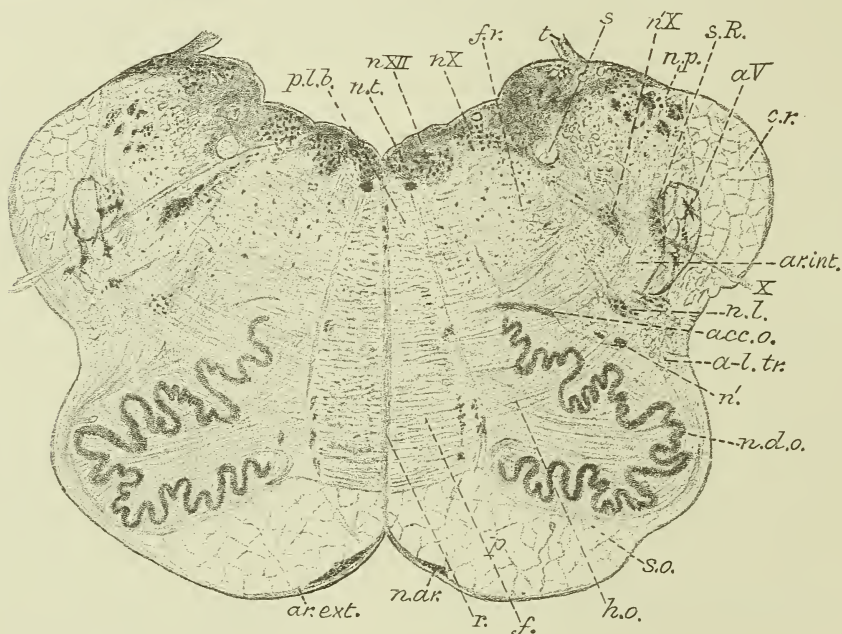


Fig. 44.—TRANSVERSE SECTION OF THE MEDULLA OBLONGATA SOMEWHAT ABOVE THE MIDDLE OF THE OLIVARY BODY. (E.A.S.) MAGNIFIED 5 DIAMETERS. (From a photograph.)

*p.l.b.*, posterior longitudinal bundle; *n.t.*, nucleus of funiculus teres; *n.XII*, nucleus hypoglossi; *n.X*, nucleus vagi; *n'X*, nucleus ambiguus; *s.*, fasciculus solitarius; *n.p.*, nucleus posterior (cuneatus); *f.r.*, formatio reticularis; *t.*, tænia; *s.R.*, substantia Rolandi; *a.V.*, ascending root of fifth; *c.r.*, corpus restiforme; *ar.int.*, internal arcuate fibres; *X*, issuing root of vagus; *n.l.*, nucleus lateralis; *n'*, groups of large cells, perhaps belonging to nucleus lateralis; *a-l.tr.*, antero-lateral ascending tract; *n.d.o.*, nucleus dentatus olivæ; *acc.o.*, accessory olivary nucleus; *s.o.*, siliqua olivæ; *h.o.*, hilum olivæ; *p.*, pyramid; *f.*, fillet; *r.*, raphe; *n.ar.*, nucleus of arcuate fibres; *ar.ext.*, external arcuate fibres.

comes close to the surface, where it presently forms a distinct projection, the funiculus of Rolando, which, a little higher up, swells into the tubercle of Rolando (fig. 42, *R.*). At the same time the cervix cornu diminishes in size and like the anterior cornu is eventually broken up by the passage of transverse and longitudinal bundles of white fibres through it, into a reticular formation, which then separates the caput cornu posterioris (fig. 43, *g.*) from the rest of the grey matter, and joins the reticular formation derived from the rest of the grey matter. In the tubercle of Rolando the caput cornu is close to the surface, and its grey substance can readily be seen, but above the tubercle it lies deeper, being covered by a well-marked bundle of white fibres, the so-called **ascending root of the fifth nerve** (*a.V.*), and by the oblique arched fibres which are passing over it to form the restiform body.

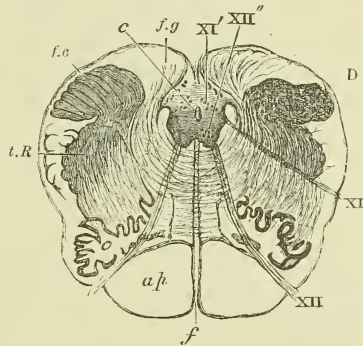
The fibres of the ascending trigeminal root have been supposed to take origin from the cells of the tubercle of Rolando, but this is not the case, for firstly they do not grow from these

cells, but from the cells of the Gasserian ganglion (His), and secondly, if the sensory root of the fifth is cut at its exit from the pons, the fibres of the so-called ascending root degenerate, but the cells of the adjacent gelatinous substance remain unaffected (Bechterew). There may, however, be a physiological connection established with these cells by means of collateral fibres, as in the case of the fibres of the posterior columns of the cord and the substance of Rolando of the posterior horn.

The grey matter of the base of the posterior horn undergoes a considerable increase as we trace it upwards in sections. Portions of grey matter are soon found to extend from it into the funiculi graciles and cuneati, forming the so-called nuclei of those columns (fig. 43, *n.g.*, *n.c.*). These nuclei are at first narrow in transverse section; but as the central canal approaches the posterior surface of the medulla they appear as comparatively thick masses, which produce externally the

Fig. 45.—SECTION ACROSS THE MEDULLA OBLONGATA A LITTLE BELOW THE POINT OF THE CALAMUS SCRIPTORIUS (Lockhart Clarke).

*c*, central canal; *f*, anterior median fissure; *f.g.*, funiculus gracilis; *f.c.*, funiculus cuneatus; *t.R.*, tubercle of Rolando; *o*, olivary body; *a.p.*, pyramid; XI, XII, spinal accessory and hypoglossal nerves; XI', XII', their nuclei.



eminences of the clava and the cuneate tubercle. Outside the nucleus of the funiculus cuneatus an accessory or external nucleus becomes formed (fig. 43, *n.c.*). From this nucleus fibres pass directly into the restiform body. The nerve-cells of the gracile nucleus are for the most part larger than

those of the cuneate nucleus, but those of the accessory cuneate are larger than either ( $50\mu$  to  $80\mu$ ). The accessory cuneate nucleus is supposed to represent a continuation of Clarke's column of the cord (Blumenau), while in the grey matter of the nucleus gracilis and principal nucleus cuneatus most of the ascending fibres of the posterior column of the cervical cord become lost.

From the lower parts of these nuclei fibres are seen to emerge and to sweep forwards and inwards in a curved manner (*internal arched or arcuate fibres*) towards the raphe or septum which unites the two halves of the medulla oblongata. Having here intercrossed with those from the opposite side in a decussation which lies above that formed by the fibres of the pyramids (*decussation of the fillet*), they form a considerable bundle of longitudinally coursing fibres which lies just dorsal to the pyramid and is known as the *fillet (lemniscus)*. Its fibres receive their myelin much earlier than those of the pyramid. On section of the fillet higher up some of its fibres degenerate downwards and the degeneration also affects internal arched fibres connecting them with the opposite nuclei. These therefore have their origin from cells higher up in the brain.

**Upper or ventricular part of the medulla oblongata.**—When the slit-like upper end of the central canal opens out into the fourth ventricle, the small remaining portion of the base of the anterior horn, which in the closed part was ventro-lateral to the central canal, comes to the surface at the floor of the ventricle, and as the sections are traced upward increases gradually in size, producing the prominence of the funiculus teres. In it, both in the lower part of the bulb where the canal is still closed and above where it has opened out, a group of large nerve-cells (*n.XII.*) is seen in all transverse sections. From this group (column) of cells the successive bundles of the roots of the hypoglossal or twelfth cranial nerve arise and pass obliquely through the substance of the bulb to leave it on its anterior aspect. The tract of nerve-cells is accordingly known as the **hypoglossal nucleus**.

At the fourth ventricle the hypoglossal nucleus lies a short distance from the surface covered by a flattened bundle of longitudinally running white fibres, which gives this mesial triangle of the calamus scriptorius (trigonum hypoglossi) a white appearance.

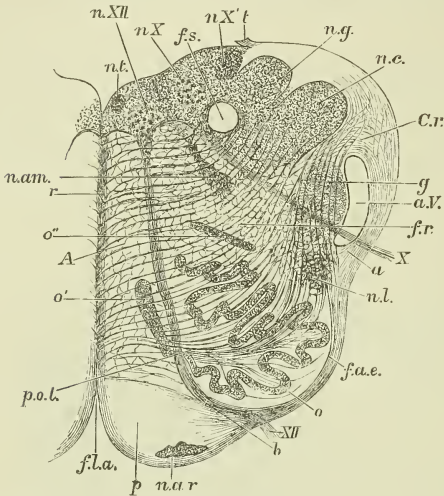


Fig. 46.—SECTION OF THE MEDULLA OBLONGATA AT ABOUT THE MIDDLE OF THE OLIVARY BODY. (Schwalbe.) †

*f.l.a.*, anterior median fissure; *n.ar.*, nucleus arciformis; *p.*, pyramid; *XII.*, bundle of hypoglossal nerve emerging from the surface; at *b*, it is seen coursing between the pyramid and the olivary nucleus, *o.*; *f.a.e.*, external arciform fibres; *n.l.*, nucleus lateralis; *a.*, arciform fibres passing towards restiform body partly through the substantia gelatinosa, *g.*, partly superficial to the ascending root of the 5th nerve, *a.V.*; *X.*, bundle of vagus root, emerging; *f.r.*, formatio reticularis; *c.r.*, corpus restiforme, beginning to be formed, chiefly by arciform fibres, superficial and deep; *n.c.*, nucleus cuneatus; *n.g.*, nucleus gracilis; *t.*, attachment of the ligula; *f.s.*, funiculus solitarius; *n.X.*, *n.X'*, two parts of the vagus nucleus; *n.XII.*, hypoglossal nucleus; *n.t.*, nucleus of the funiculus teres; *n.am.*, nucleus ambiguus; *r.*, raphe; *A.*, continuation of anterior column of cord; *o'*, *o''*, accessory olivary nuclei; *p.o.l.*, pedunculus olivæ.

Nearer to the surface of the floor and nearer also to the median groove is a small group of cells, known sometimes as the **nucleus of the funiculus teres** (fig. 46, *n.t.*). The cells are small and appear to give origin to fibres which belong to the vago-glossopharyngeal roots.

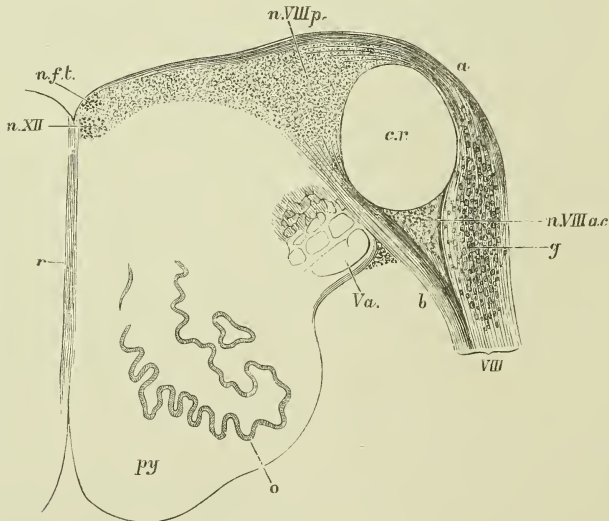


Fig. 47.—TRANSVERSE SECTION OF THE UPPER PART OF THE MEDULLA OBLONGATA. (Schwalbe.)

*py.*, pyramid; *o.*, olivary nucleus; *V.a.*, ascending root of the fifth nerve; *VIII.*, root of the auditory nerve, formed of two parts, *a.* and *b.*, which enclose the restiform body, *c.r.*; *n.VIII.p.*, principal (dorsal) nucleus of the auditory nerve; *n.VIII.ac.*, accessory nucleus; *g.*, ganglion cells in the root; *n.ft.*, nucleus of the funiculus teres; *n.XII.*, nucleus of the hypoglossal; *r.*, raphe.

At the base of the posterior horn in the lower part of the bulb, and near the central canal, a group of cells (fig. 43, *n.XI.*) is seen in section, which if traced upwards is found to be pushed to the side as the central canal opens, so that in the



floor of the ventricle it lies lateral or dorso-lateral to the hypoglossal nucleus. These cells form the upper or bulbar part of the **nucleus of the spinal accessory**.<sup>1</sup> Above the level where the roots of this nerve cease to come off a mass of grey matter with numerous cells is seen lying lateral to the hypoglossal nucleus in a situation near the floor of the ventricle corresponding to the prominence of the ala cinerea (trigonum vagi) which appears on the surface, and it extends upwards as far as the fovea inferior. In connection with it there arise successively bundles of fibres of the roots of the vagus and glosso-pharyngeal nerves (10th and 9th cranial nerves): those of the vagus beginning at the commencement of the ventricle, and arising along the length of the ala cinerea; and those of the glosso-pharyngeal coming for the most part from the upper part of the ala cinerea, and from beneath the inferior fovea. The grey matter in question forms then the **principal nucleus of the pneumogastric and glosso-pharyngeal nerves**.

It has been inferred from the clinical and pathological evidence met with in cases of bulbar paralysis that the motor fibres to the palate and vocal cords, which leave the medulla oblongata by the spinal accessory roots, have their real origin in the hypoglossal nucleus. On the other hand the *pars intermedia of the seventh nerve* is said to arise from the upper end of the glossopharyngeal nucleus (Duval.)

Close to this nucleus, but placed somewhat more deeply in the grey matter, is a round longitudinal bundle of white fibres termed the *funiculus solitarius* (figs. 44, s., 46, f.s.). This bundle, which is surrounded by gelatinous grey matter with many small nerve-cells, occupies the same relation to the ninth and tenth nerves that the so-called ascending root of the fifth occupies to the trigeminal. Its fibres appear to lose themselves amongst the cells of the enclosing grey matter, and this and the bundle gradually disappear when traced towards the spinal cord: traced upwards they pass out with the bundles of nerve-roots which go to form the vagus and glosso-pharyngeal, especially the latter. Both this bundle and those forming the ascending root of the fifth have their myelin sheath developed at an early period. As His has shown, they grow into the medulla oblongata from the ganglia of the vagus and glosso-pharyngeal, in the same way as the posterior roots grow into the medulla spinalis from the spinal ganglia.

Lying in the reticular formation and ventral to the principal mass of grey matter which here occupies the floor of the fourth ventricle, is a small detached pear-shaped mass of grey matter containing nerve-cells, which is connected by a kind of stalk with the rest of the grey matter. This nucleus, which was formerly termed the *nucleus ambiguus*, gives origin to fibres which pass along the stalk obliquely towards the floor of the fourth ventricle and then turn outwards and forwards to issue with the root-bundles of the tenth nerve from the side of the bulb. It is therefore an **accessory vagal nucleus** and, in its relation to the grey matter and in the size and character of its cells it is a counterpart of the nucleus of the seventh nerve, which appears in sections somewhat higher up (in the pons). A prolongation of this nucleus gives origin higher up to fibres of the glossopharyngeal.

The issuing bundles of the auditory nerve pass partly dorso-lateral and partly ventro-mesial to the restiform body. The dorsal division contains a large number of nerve-cells (**ganglion radialis cochlearis**), which probably give origin to many of its fibres. Ventral to the restiform body and between the two roots is another mass of ganglion-cells, which has been termed the **accessory auditory nucleus** (Schwalbe) (fig. 47, n. VIII.ac). From these cells fibres are seen both in the upper part of the bulb and in the pons passing transversely towards the opposite side: they belong to the

<sup>1</sup> The bulbar or accessory part of the nerve: the spinal part of the nerve takes origin in the ventro-lateral group of cells of the anterior horn of the spinal cord (cervical region).

system of the trapezium (p. 47). Higher up this nucleus blends with the ganglion of the lateral root, the two together forming a **ventral nucleus** for the auditory nerve (fig. 49, *VIII.v.*).

Towards the upper part of the bulb an extensive tract of grey matter containing small scattered nerve-cells becomes developed outside the vago-glossopharyngeal nucleus. This tract corresponds to the lateral triangular area (trigonum acustici) which is seen on the surface outside the ala cinerea. Into it most of the fibres of the ventral or vestibular division of the auditory nerve apparently pass; it is termed the **inner or dorsal auditory nucleus** (fig. 47, *n.VIII.p.*). Ventral to this nucleus is a collection of grey matter with large nerve-cells, the **nucleus of Deiters**. Its cells appear to be connected with the cerebellum, for it becomes atrophied after removal of the cerebellar hemisphere of the same side in the newborn animal.<sup>1</sup> Associated with this group of cells is a longitudinal bundle of nerve-fibres which has been termed by Roller the ascending root of the auditory nerve (fig. 49, *R.*), but the precise connection of these fibres with the roots of the eighth nerve has yet to be established. Most of these collections of cells will be again noticed in dealing with the structure of the pons.

The nerve-cells in the hypoglossal nucleus are largest; those in the principal nucleus of the spinal accessory of moderate size, and those in the vago-glossopharyngeal nucleus are small and fusiform; those of the principal (dorsal) auditory nucleus are the smallest. There are a number of small cells in the ventral part of the hypoglossal nucleus (small-celled hypoglossal nucleus of Roller), but they do not give origin to any of the fibres of the nerve (Forel).

**Nucleus of the olivary body.**—Besides those collections of grey matter which are traceable from the grey matter of the spinal cord, portions occur in certain parts of the medulla oblongata, which are not represented in the cord. Of these the most striking is the *nucleus of the olivary body*, which has been termed, from its appearance in section, the *corpus dentatum of the olive* (fig. 44). It is enclosed in the olivary prominence, and is therefore situated in the lateral area of the bulb, but the grey matter is not visible from the surface, being covered by both longitudinal and transverse white fibres. It takes the form of a thin wavy lamina, which is curved round at its edge so as to form an ovoid scalloped capsule. The open part or hilum of this looks towards the middle line and receives a considerable tract of white fibres, which emanate from the raphe, being derived to all appearance from the opposite olive, and pass into the hilum along its whole extent, forming the so-called *olivary peduncle (p.o.)*.<sup>2</sup> Under the microscope the nucleus appears as a wavy band of neuroglia, with small multipolar nerve-cells embedded in it. The fibres of the olivary peduncle diverge as they pass to the grey lamina. They are partly lost in the grey matter of the olivary nucleus but mostly pass in small bundles through the lamina, those which are more posterior turning backwards and coursing obliquely through the posterior part of the lateral area to join the restiform body and thus to pass to the cerebellum as internal arched fibres. These internal arched fibres are easily distinguishable by their small diameter from the large internal arched fibres which belong to the tract of the fillet: moreover they develop their myelin sheath later. Others after coursing through the grey lamina and running between the longitudinal fibres which cover the olive reach the surface, where they bend round and are continued as part of the layer of external arched fibres into the restiform body. Through the restiform body, the arched fibres and the fibres of the olivary peduncles, the cerebellar hemisphere of one side is connected therefore with the olivary nuclei

<sup>1</sup> The nucleus of Deiters was formerly regarded as giving origin to part of the auditory nerve, and is also known as the *outer or superior auditory nucleus* (see p. 62).

<sup>2</sup> Some fibres emerge from the hilum and turn sharply round the ventral and lateral borders of the dentate nucleus, to which they form a kind of capsule (fig. 44, *s.o.*).



of both sides. But the connection with the opposite side is the more intimate, for it is found that in cases of atrophy of the cerebellar hemisphere of one side, the olive of the opposite side is atrophied while that of the same side is intact. And it was found by Gudden that after removal in the new-born animal of the one cerebellar hemisphere, the opposite olive was atrophied. On the other hand the olivary nucleus appears to be connected with the cerebral hemisphere of the same side by a tract of longitudinal fibres which lies lateral and dorsal to the nucleus in the medulla oblongata, and passes up towards the brain in the reticular formation. Thus

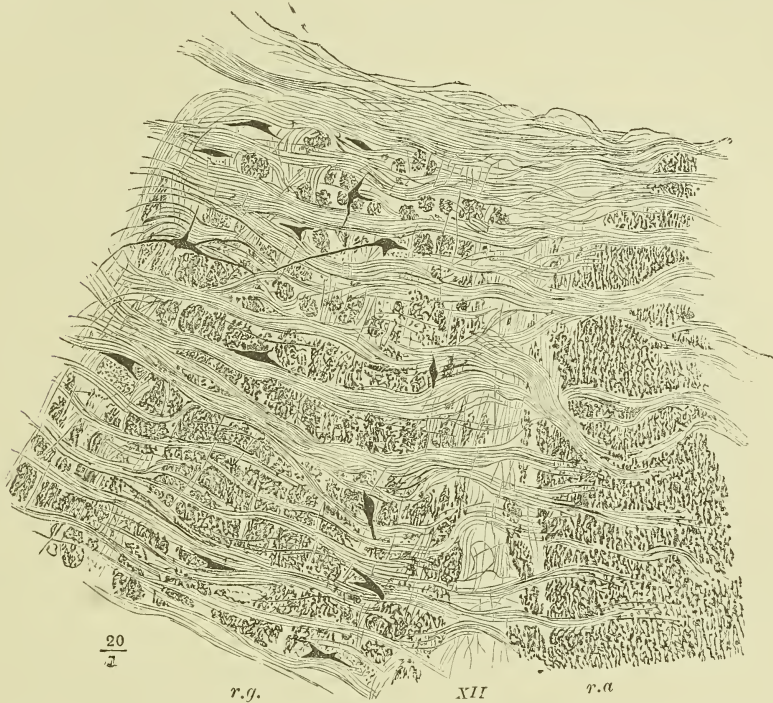

Fig. 48.—PART OF THE RETICULAR FORMATION OF THE MEDULLA OBLONGATA (Henle).

*r.a.*, reticularis alba; *r.g.*, reticularis grisea; between them a root-bundle of the hypoglossus (XII). The longitudinal fibres of the reticular formation are cut across; the transversely coursing fibres are internal arcuate fibres, passing on the right of the figure towards the raphe.

the olives are intermediary stations between the cerebrum and cerebellum: they have no direct connection with the cord (Flechsig).

Besides the main olivary nucleus two smaller isolated bands are generally seen (figs. 43, 44, 46), looking like separated portions of the chief nucleus. They are situated one on the dorsal, and the other on the mesial aspect of the chief nucleus, and are known as the outer and inner *accessory olivary nuclei*. They are traversed like the main nucleus by bundles of internal arched fibres going to the restiform body, and are frequently connected at one or two places to the main nucleus. The inner accessory nuclei are sometimes termed the pyramidal nuclei, for they lie immediately behind the pyramids. The root-bundles of the hypoglossal nerves generally pass between them and the chief olivary nucleus after traversing the olivary peduncle, but sometimes the nerve pierces the chief nucleus near its mesial edge.

Other small collections of grey matter and nerve-cells are scattered in certain parts of the formatio reticularis, as well as one or two distinct tracts in connection



with the external arched fibres, and a considerable amount in the median septum or raphe. These three structures may therefore next be described.

The **formatio reticularis** (figs. 43, 44, 46, *f.r.*) occupies the whole of the anterior and lateral areas of the bulb, dorsal to the pyramids and olives respectively. It is thus named on account of the appearance which it presents in a transverse section viewed under a moderate magnifying power. This reticular appearance is caused by the intersection of bundles of fibres belonging to two sets which run at right angles to one another. Those of the one set are longitudinal, and these are intersected by transverse fibres, which pass obliquely from the raphe outwards and somewhat backwards with a curved course towards the funiculus gracilis and funiculus cuneatus, and the olivary nucleus ; and also in the upper part of the medulla oblongata towards the restiform body.

In some parts grey matter with nerve-cells enters into the constitution of the formatio reticularis. The cells are especially large and numerous in the reticular formation of the lateral area near the anterior area, where in the lower part of the medulla oblongata is situated a remnant of the anterior horn ; and its grey matter is presumably derived in great measure from the latter. In the anterior or mesial area of the bulb, nerve-cells are mostly absent from the formatio reticularis, and this is therefore sometimes distinguished as the *formatio reticularis alba* (fig. 48, *r.a.*), from the other or *formatio reticularis grisea* (*r.g.*).

The longitudinal fibres of the reticular formation of the anterior area comprise at least two sets, viz. :—(1) those which occupy the tract nearest to the pyramids and which belong to the tract of the fillet above described ; and (2) those which are prolonged from the remainder of the anterior column of the spinal cord after the passage of the anterior (direct) pyramidal tract into the outer side of the pyramid. The latter become in the higher levels of the medulla oblongata gradually obscured or replaced by an accumulation of grey matter which resembles that of the grey reticular formation and has been termed by Roller, *nucleus centralis*. But some of the longitudinal fibres of the anterior area remain distinct, and become in the upper regions of the medulla oblongata collected into a compact bundle which is known as the *posterior* or *dorsal longitudinal bundle*.

The fibres of the reticular formation of the lateral area are prolonged from the remains of the lateral column after the lateral pyramidal tract and the dorsolateral cerebellar tracts have passed to their respective destinations. Those which are nearest the olivary nucleus mostly belong to the anterolateral cerebellar tract (fig. 44). The fibres of the lateral area are added to as we trace them upwards in sections, the increase being due either to the turning upwards of some of the inner arched fibres or to the accession of fibres which are derived from nerve-cells in the grey matter near the posterior surface, or in the grey reticular formation.

According to Deiters, the nerve-fibre processes of the nerve-cells of the reticular formation all pass downwards, while their branched processes are directed horizontally.

The **arched or arcuate fibres** of the medulla oblongata, which have been more than once alluded to, are the curved fibres which are seen in transverse sections coursing in the plane of the section. From their position they are distinguished into external and internal, or superficial and deep.

The *outer* or *superficial arched fibres* (figs. 44, 46) emerge for the most part from the anterior median fissure, and passing over the pyramids and olives, many of them go to the restiform body. They are added to by deep fibres which come to the surface partly in the groove between the pyramids and olives, partly after passing through the olives, as before mentioned. Traced back in the anterior median fissure they are seen to enter the raphe, and to cross over in it ; after which it is supposed that they may become longitudinal, but their further course is not certainly known.

The *inner* or *deep arched fibres* emerge from the raphe, and traverse the thickness of the bulb, tending towards the olives, the restiform body, and the nuclei of the cuneate and slender funiculi. Those which pass through and in front of the olives are in continuity with the superficial arched fibres.

Traced backwards into the raphe, the deep arched fibres cross obliquely to the other side of the medulla, where some become longitudinal, joining the fibres of the fillet. Others are the fine fibres before alluded to as connecting the cerebellar hemisphere with the opposite olive.

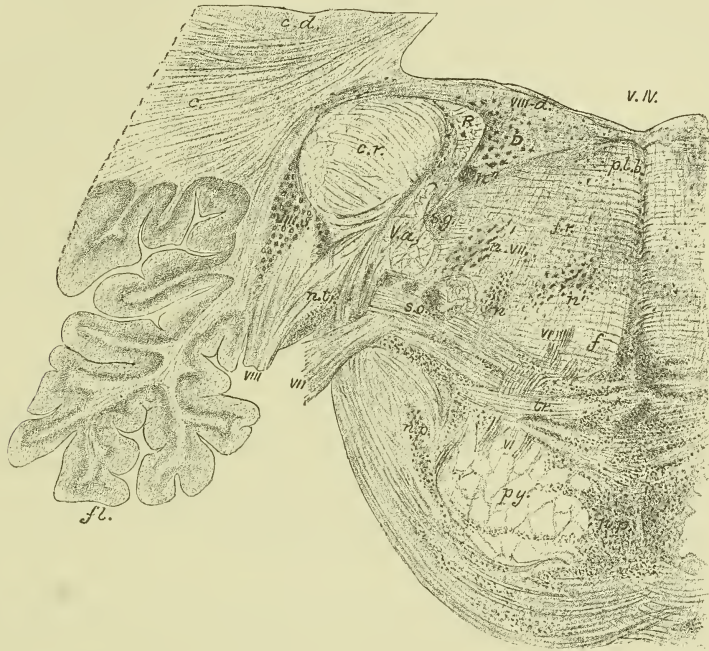


Fig. 49.—TRANSVERSE SECTION OF PONS VAROLII THROUGH THE ORIGIN OF THE AUDITORY NERVE. (E.A.S.) (From a photograph.) Magnified about 4 diameters.

*v.IV.*, 4th ventricle; *c.*, white matter of cerebellar hemisphere; *c.d.*, corpus dentatum cerebelli; *fl.*, flocculus; *c.r.*, corpus restiforme; *R.*, Roller's ascending auditory bundle; *D.*, Deiter's nucleus; *VIII.*, issuing root of auditory nerve; *VIII.d.*, dorsal nucleus; *VIII.v.*, ventral (accessory) nucleus of auditory; *n.tr.*, small-celled nucleus traversed by fibres of the trapezium; *tr.*, trapezium; *f.*, fillet; *p.l.b.*, posterior longitudinal bundle; *f.r.*, formatio reticularis; *n.*, *n'*, *n''*, nuclei in formatio reticularis; *V.a.*, ascending root of 5th; *s.g.*, substantia gelatinosa; *s.o.*, upper olive; *VII.*, issuing root of facial; *n.VII.*, nucleus of facial; *VI.*, root bundles of abducens; *py.*, pyramid bundles; *n.p.*, nuclei pontis.

**Nuclei of the superficial arched fibres.**—Amongst the superficial arched fibres, or between them and the subjacent columns of the bulb, small collections of grey matter with nerve-cells are here and there met with, which are distinguished by the above name. The principal group of cells lies superficial to the pyramid on either side (figs. 44, 46, *n.ar.*). This group becomes very largely developed at the junction of the medulla oblongata with the pons Varolii.

The **raphe** or septum (fig. 44, *r*) is composed of fibres which run in part dorso-ventrally (fibræ rectæ), in part longitudinally, and in part across the septum more or less obliquely. Intermixed with the nerve-fibres are a number of nerve-cells in grey matter. The fibræ rectæ are continuous ventrally with the superficial arched fibres, which emerge at the anterior median fissure; dorsally in the upper part of the bulb with fibres from the medullary striæ (cf. p. 50). The longitudinal are chiefly

fibres which have passed into the raphe as fibræ rectæ or as superficial or deep arched fibres, and in it have altered their direction and become longitudinal. The obliquely crossing fibres are the deep arched fibres which enter or emerge from the raphe. Others, however, seem to come from the nuclei of the nerve-roots, and these may pass more directly across as commissural fibres either into the reticular formation or into the pyramid of the other side, in either case becoming longitudinal. The nerve-cells of the raphe are multipolar cells, those in the middle being chiefly spindle-shaped. The latter are connected with fibræ rectæ (Clarke), whilst the more laterally situated ones, at least those near the anterior median fissure, are connected with some of the superficial arched fibres.

**Internal structure of the pons Varolii.**—Sections of the pons are greatly modified by the appearance of the transversely coursing fibres between the two halves of the cerebellum which have already been noticed. These occupy the whole of the ventral portion and enclose and conceal from view the bundles of the pyramids, which can be traced upwards into and through the pons from the medulla oblongata.

Between the bundles of fibres of this ventral portion of the pons grey matter with small multipolar nerve-cells is everywhere found (*nuclei pontis* (fig. 49, *n.p.*)). It is probable that many of the transverse fibres terminate in this grey matter and are through it connected in some way with the longitudinal fibres of the pyramidal tract ascending through the pons; but the transverse fibres do not appear to turn upwards, for they are smaller than the longitudinal fibres.

The posterior or dorsal portion of the pons is chiefly constituted by a continuation upwards of the reticular formation and of the grey matter of the medulla oblongata. As in the latter, there exists here also a median septum or raphe, which is similar in structure to that of the medulla oblongata. It does not extend through the ventral half, being obliterated, or nearly so, by the great development of the obliquely and transversely passing fibres, except near the upper and lower borders where the superficial transverse fibres of the pons turn in at the middle line; and especially at the upper border where bundles of the same fibres encircle the crura cerebri as they emerge from the pons.

In the reticular formation, in addition to the scattered and reticularly arranged grey matter with nerve-cells everywhere met with, there are one or two more important collections which lie embedded in this formation and from which nerve-fibres arise. One of these is the superior olivary nucleus, another is the nucleus of the seventh or facial nerve, and others give origin to portions of the fifth nerve.

The **superior olivary nucleus** (fig. 50, *o.s.*) is a collection of small nerve-cells which lies dorsal to the outer part of the trapezium, in what would correspond (as indicated by the passage outwards of the roots of the sixth and seventh nerves) to a prolongation of the lateral area of the medulla oblongata. In man it is very much smaller than the inferior olive, to which it does not present much resemblance in form, although in structure and in the size of its cells there is a close similarity. In some animals, however, it is larger, and has a distinctly sinuous outline. From it, as above mentioned (p. 47), fibres pass into the trapezium; it may be connected through these with the accessory auditory nucleus of the opposite side (p. 55). Running upwards on the mesial side of the superior olive between this and the fillet is a bundle of fibres which has been termed the *central tract of the tegmentum*, but its connections have not yet been satisfactorily ascertained.

Besides its connection with the contra-lateral accessory auditory nucleus through the corpus trapezoides, the upper olive is connected, according to Bechterew, (1) to both the posterior (inferior) corpora quadrigemina through the lower fillets, (2) to the cerebellum through the restiform body, (3) with the nucleus of the sixth nerve (and perhaps, also, with that of the third and fourth nerves) through the posterior longitudinal bundle, and (4) with the spinal cord through fibres passing down the anterior column.



The **nucleus of the facial nerve** (*n. VII*) lies in the reticular formation just dorsal to the superior olivary nucleus, and at some depth, therefore, below the floor of the fourth ventricle. It begins to be visible in sections immediately above the medulla oblongata, in the form of small isolated groups of nerve-cells, from which separate bundles of fibres proceed, and extends three or four millimeters upwards. Its cells are of moderate size, and their axis-cylinder processes are directed inwards and backwards towards the grey matter of the floor of the ventricle, where they collect

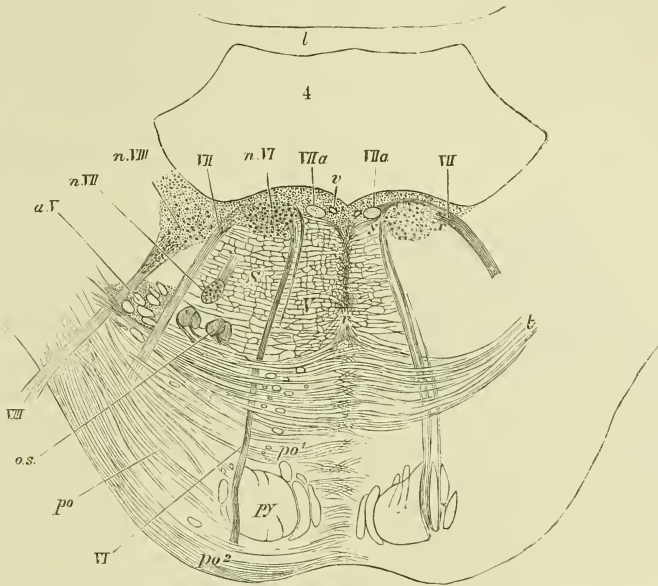


Fig. 50.—SECTION ACROSS THE LOWER PART OF THE PONS (after Stilling and Schwalbe).  $\frac{3}{1}$

*py*, pyramid-bundles continued up from the medulla; *po*, transverse fibres of the pons passing from the middle crus of the cerebellum, before (*po*<sup>2</sup>) and behind (*po*<sup>1</sup>) the chief pyramid bundles; *t*, deeper transverse fibres, constituting the trapezium; the grey matter between the transverse fibres is not represented either in this or in the following figures; *r*, raphe; *o.s.*, superior olivary nucleus; *a.V*, bundles of the ascending root of the fifth nerve, enclosed by a prolongation of the grey substance of Rolando; *VI*, the sixth nerve; *n.VI*, its nucleus; *VII*, the facial nerve; *VIIa*, ascending portion of the facial root; *n.VII*, its nucleus; *VIII*, superior root of the auditory nerve; *n.VIII*, part of the nucleus of Deiters; *v*, section of a vein.

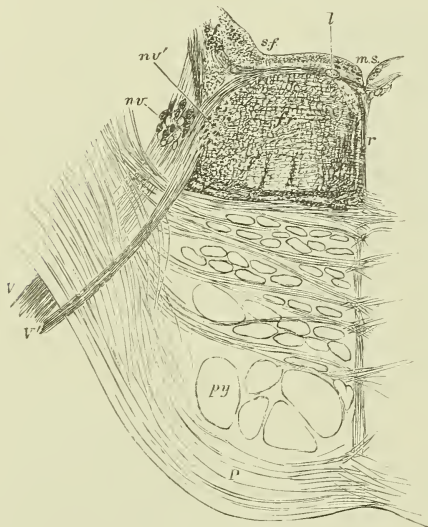
to form a longitudinal bundle, oval in section, which runs for a short distance upwards in the grey matter and then turns sharply in a ventrolateral direction, traversing the thickness of the pons to emerge on its lateral aspect (fig. 41, B.) From facts brought forward by Mendel and supported by Tooth and Turner the facial nerves appear to receive some fibres through the posterior longitudinal bundles from the oculomotor nuclei; these fibres probably being those for the frontalis, corrugator supercilii, and orbicularis palpebrarum. On the other hand the fibres to the orbicularis oris may arise from the hypoglossal nucleus.

The **motor nucleus of the fifth nerve** (fig. 51, *nV'*) comes to view in higher sections through the pons, situated a little below the surface close to the lateral margin of the fourth ventricle. It contains large pigmented multipolar nerve-cells, the axis-cylinders of which pass out into the motor root of the trigeminal. Fibres are also seen in the grey matter of the floor of the ventricle connecting both this motor nucleus (and also the sensory nucleus, immediately to be described) with the raphe, and through this probably with higher parts of the brain.

The so-called **upper sensory nucleus of the fifth nerve** (*n.V*) lies on the

outer side of the motor root. The cells are small and arranged in clusters separated by the fasciculi of origin of the sensory nerve-root. This collection of cells is more extensive than the motor nucleus, being seen in sections higher up the pons, and passing below into the so-called "lower sensory nucleus," which is a continuation of the grey matter of the tubercle of Rolando, and ultimately, therefore, of the *substantia gelatinosa* of the posterior horn of the spinal cord. Passing towards this nucleus into the issuing roots of the fifth nerve is seen, as has just been mentioned, in all sections through the middle part of the pons a well marked tract of fine fibres which are traceable over the posterior longitudinal bundle to the raphe, and ultimately pass, it is believed, upwards towards the mid-brain. This tract is known variously as the *crossed root*, the *raphe-root*, or the *central tract* of the trigeminal. Its fibres pass by and

Fig. 51.—OBLIQUE TRANSVERSE SECTION OF THE PONS ALONG THE LINE OF EXIT TRAVERSED BY THE FIFTH NERVE (E.A.S.).



The section passes through the lower part of the motor nucleus (*nv'*) from which a bundle of fibres of the motor root, *V'*, is seen passing; a part of the upper sensory nucleus (*nv*) is also shown in the section in the form of a number of small isolated portions of grey matter. Amongst these are a few bundles of the ascending root cut across, but most of these have already become diverted outwards to join and assist in forming the issuing part of the main or sensory root, *V*; *ar*, arcuate fibres near the fourth ventricle, which come partly from the raphe, partly from a small longitudinal bundle of fibres (*l*) near the median sulcus (*m.s.*), and pass outwards to join the root of the fifth nerve; *f.r.*, *formatio reticularis*; *r.*, raphe; *s.f.*, *substantia ferruginea*.

may in part be continuous with a small oval bundle of longitudinal fibres (fig. 51, *l*), which lies in the grey matter not far from the median sulcus, and which resembles in appearance the ascending part of the facial root.

The rest of the grey matter of the pons lies near the dorsal surface and appears in the floor of the upper part of the fourth ventricle. Besides scattered nerve-cells, others are collected at certain parts into definite groups or nuclei from which some of the remaining cranial nerves take origin. Like the similarly placed nuclei in the medulla oblongata, these also do not lie close to the epithelium which covers the surface, but are separated from it by a layer of gelatinous substance (*neuroglia*) free from nerve-cells, termed the *ependyma* of the ventricle.

The **dorsal nucleus of the auditory nerve** (fig. 47, *n. VIII p.*), is prolonged upwards underneath the *striae acusticae* into the pons (fig. 49, *VIII. d.*). It is widest at about the junction of the medulla and pons, where it extends almost to the middle line; further up it rapidly narrows and becomes shifted towards the lateral boundary of the ventricle as the nucleus of the sixth nerve makes its appearance between it and the median sulcus. Its cells are small, and it is much broken up by the passage through it of fine transverse nerve-fibres.

The so-called outer or superior nucleus of the auditory nerve, or the **nucleus of Deiters** (Laura) (fig. 49, *D*; fig. 50, *n. VIII*), is characterized by the large size of its cells, and lies immediately ventro-lateral to the dorsal nucleus, which has just been described. It does not begin to be visible so far down as the latter, but is continued as far upwards, rather increasing in size superiorly, whereas the dorsal

nucleus diminishes. It is much broken up by longitudinal fibres (ascending auditory fibres of Roller). The connection of this nucleus with the auditory nerve is very doubtful. It undergoes no alteration when the auditory nerve is severed in the new-born animal, whereas section of the spinal cord in the upper cervical region of the new-born rabbit is followed by degeneration and atrophy of this nucleus (Monakow). It becomes atrophied after removal of the cerebellar hemisphere of the same side in the new-born animal (see also p. 55).

The **ventral nucleus of the auditory nerve** (see p. 55) which is represented in the upper part of the medulla oblongata by a collection of nerve-cells lying in the angle between the restiform body and the two portions of the root of the auditory nerve (fig. 47, *n. VIII.ac*) and by cells interpolated amongst the fibres of the cochlear root (p. 55), is placed in the region of the pons between the restiform body and the flocculus, and the cochlear root here issues directly from it (fig. 49). Its cells, which are small and rounded but multipolar, are enclosed like those of a ganglion, each in a nucleated capsule.

The **nucleus of the sixth nerve** (common nucleus of the sixth and seventh of some authors) consists of a group (column) of large multipolar cells lying on either side of the median sulcus (fig. 50, *n. VI*). It corresponds to the part of the fasciculus teres which lies immediately above the medullary striæ on the floor of the fourth ventricle. It has a close relation to the root of the facial, which runs along its mesial side (*VIIa*), curves round it eventually, and appears to receive some fibres from it, but it is doubtful if this is really the case (Gowers). The fibres of the nerve run in bundles obliquely ventralwards and downwards (caudalwards) to emerge at the lower border of the pons. Between this nucleus and the median groove, along the middle of the fourth ventricle, is an oval bundle of nerve fibres (fig. 50), which runs longitudinally upwards for about 5 mm., and occupies nearly the same position with regard to the nucleus of the sixth nerve that the longitudinal fibres which cover the hypoglossal nucleus occupy with regard to the origin of that nerve. The bundle in question is the ascending part of the root of the seventh nerve (p. 61), and when followed upwards in sections its fibres are seen to turn sharply outwards and ventralwards, and to become the issuing root of the facial. From the nucleus of the abducens, nerve-fibres pass to join the posterior longitudinal bundle, and in this they run upwards to the mid-brain, where as Duval and Laborde have shown they join the issuing oculomotor roots of the opposite side. This crossed connection between the third and sixth nerves explains those cases of lesion of the pons in which paralysis of the external rectus muscle of one side is accompanied by that of the internal rectus of the opposite eye.

**Course of nerve-fibres from the spinal cord upward through the medulla oblongata and pons.**—Assuming for convenience of description the existence of three white columns of the spinal cord on each side, the various parts of these are continued upwards as follows:—

The *posterior column* is continued in the medulla oblongata as the white substance of the funiculus gracilis and funiculus cuneatus. The longitudinal fibres appear to end by terminal arborisations in the grey matter which forms the nuclei; and numerous deep arched fibres enter or emerge from the same collections of grey matter, passing through the raphe from the other side of the medulla, where they are continuous with the longitudinal fibres dorsal to the pyramids which form the main tract of the fillet (Edinger) (interolivary layer of Flechsig). The solitary bundle and the “ascending” root of the fifth morphologically represent, as their mode of development from ingrowing nerve fibres shows, parts of the postero-lateral column of the cord.

Some fibres also pass from these nuclei, especially from the outer or large-celled cuneate nucleus directly into the restiform body of the same side.



A large part of the *lateral column* of the cord, viz., the *lateral pyramidal tract*, passes into the opposite pyramid of the bulb and proceeds in this and in the

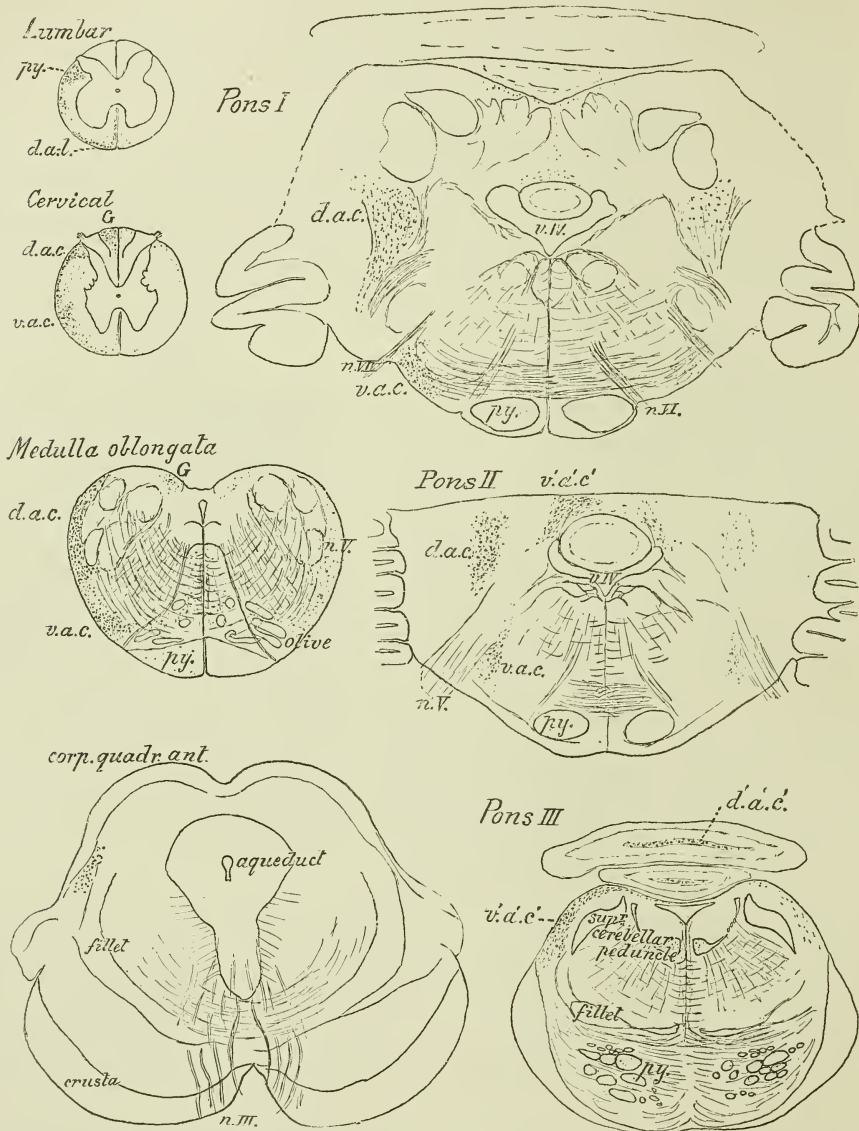


Fig. 52.—DEGENERATIONS IN THE SPINAL CORD, MEDULLA OBLONGATA, PONS VAROLII, AND MESENCEPHALON OF A MONKEY FOLLOWING HEMISECTION AT THE TWELFTH DORSAL NERVE. (E.A.S.)

The hemisection was on the left side of the cord, and was complete. The section outlines drawn to scale with a camera lucida. The degenerated fibres shown by black dots. Those in the section of the lumbar cord are descending, all the rest are ascending. *py*, pyramidal tract; *d.a-l*, descending antero-lateral tract; *d.a.c*, dorso-lateral ascending cerebellar tract; *d.a'.c'* (in Pons III.), degeneration of fibres of this tract in the white matter of the cerebellar worm; *v.a.c*, ventrolateral ascending cerebellar tract; *v.a'.c'* (in Pons II. and III.), degenerated fibres of this tract passing dorsally into the valve of Vieussens (in Pons III.) and into the white matter of the vermis (Pons II.); *n.III.*, *n.V.*, *n.VI.*, *n.VII.*, issuing fibres of the 3rd, 5th, 6th, and 7th nerve-roots; *v.IV.*, 4th ventricle.

ventral part of the pons towards the crista (see fig. 24, p. 30). Together with the small part of the anterior column of the cord which also enters into the constitution

of the pyramid, it there forms the *pyramidal tract of the isthmus* of Flechsig (*peduncular tract* of Meynert). Some of the fibres of the pyramid, however, emerge as external arcuate fibres, and joining the restiform body pass to the cerebellum. Moreover, the pyramidal tract is larger in the pons and medulla oblongata than in the spinal cord, for as it passes downwards it gives off numerous fibres to end by terminal ramifications in the nerve-nuclei of the efferent cranial nerves. Collaterals also pass off from the fibres of the pyramids, and even more numerous from the longitudinal fibres of the posterior and lateral areas of the medulla oblongata and pons to end by terminal ramifications in the grey matter (Kölliker). A part of the lateral column of the cord forming the *dorso-lateral cerebellar tract* (see fig. 52, *d.a.c.*), passes at about the middle of the medulla oblongata obliquely backwards in the restiform body to the cerebellar worm. The *ventro-lateral ascending cerebellar tract* (*v.a.c.*) passes into the upper part of the pons and turning dorsally at about the level of the exit of the fifth nerve curves backwards and enters the cerebellum over and along with the superior peduncle and in the valve of Vieussens.

The rest of the lateral column runs up dorsal to the olives and contributes to form the longitudinal fibres of the reticular formation. These are continued through the dorsal parts of the encephalic isthmus towards the corpora quadrigemina and optic thalamus. Some of the fibres become collected as they pass up towards the pons into the well-marked flattened bundle of fibres (*fillet*) lying dorsal to the pyramid. For the fillet is not, according to Edinger, wholly formed of the arched fibres which emanate from the nuclei of the contra-lateral posterior columns; it receives an accession of fibres which have already crossed over in the spinal cord from the posterior horn (through the anterior commissure), and have passed up the antero-lateral column to the medulla oblongata. According to Flechsig and v. Bechterew the fillet also contains fibres which are passing from the ventral auditory nucleus through the trapezium to the inferior corpora quadrigemina.

The *anterior column* of the cord in part is continued into the pyramid of the same side, but chiefly dips under the pyramid and forms the longitudinal fibres of the white reticular formation in the dorsal part of the mesial area. These pass upwards towards the isthmus cerebri. In the pons Varolii one tract of them becomes collected into a well marked fasciculus (*posterior* or *dorsal longitudinal bundle*, figs. 53, 54, *p.l.*), and some of the others join the fillet; their further destination will be afterwards noticed. In the region of the medulla oblongata they are indistinguishable from one another in the adult, but in the foetus they are found to develop at different periods and are then readily differentiated (Flechsig).

A small bundle of fibres of the anterior column of the cord was described by Solly as passing obliquely upwards below the olive, to join the restiform body (see fig. 30, *f.*). This is seldom distinct.

**Transition from the pons Varolii to the mid-brain.**—In sections through the upper part of the pons (fig. 53) the fourth ventricle, which here becomes rapidly narrowed, is roofed over by the two superior peduncles of the cerebellum which are passing to the mesencephalon, and by the superior medullary velum and lingula, which lies between them. The grey matter of the floor of the ventricle (central grey matter) shows on either side near the median groove a group of nerve-cells continuous below with the nucleus of the funiculus teres, and above with the nucleus of the aqueduct. More to the side is the mass of pigmented nerve-cells known as the substantia ferruginea (fig. 53, *s.f.*), and still more laterally at the angle which the roof makes with the floor, a column of large spherical scattered cells, along the outer border of which a well marked white bundle—the descending root of the fifth nerve (*v.d.*)—runs downwards towards the middle of the pons where it issues with the motor root. These cells and the fibres of the descending root can be traced upwards

as far as the superior corpora quadrigemina. Between the central grey matter and the reticular formation on either side of the raphe is the now sharply defined dorsal (posterior) longitudinal bundle (*p.l.*). The fibres which compose this, which receive

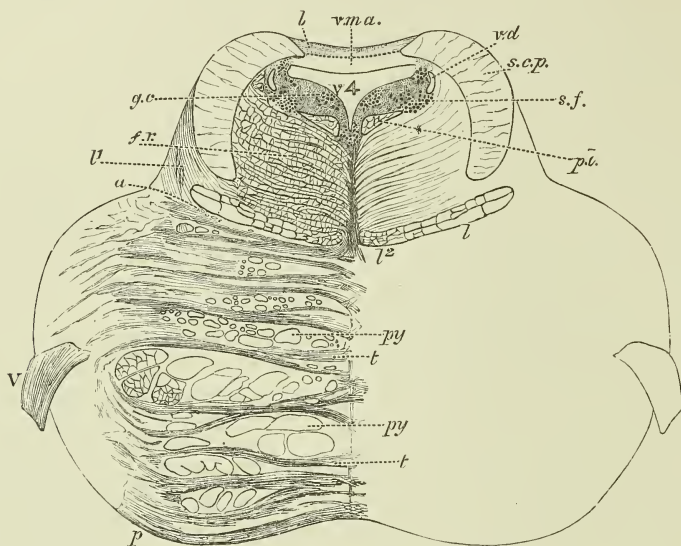


Fig. 53.—TRANSVERSE SECTION THROUGH THE UPPER PART OF THE PONS (Schwalbe, after Stilling). Rather more than twice the natural size.<sup>1</sup>

*p*, transverse fibres of the pons; *py, py*, bundles of the pyramids; *a*, boundary line between the tegmental part of the pons and its ventral part; *l*, lateral; *l'*, mesial fillet; *f.r.*, formatio reticularis; *p.l.*, posterior longitudinal bundle; *s.c.p.*, superior cerebellar peduncle; *v.m.a.*, superior medullary velum; *v*, grey matter of the lingula; *v 4*, fourth ventricle; in the grey matter which bounds it laterally are seen, *v.d.*, the descending root of the fifth nerve, with its nucleus; *s.f.*, substantia ferruginea; *g.c.*, group of cells continuous with the nucleus of the aqueduct.

their myelin sheaths very early, serve partly as a medium of communication between the nucleus of the sixth nerve and the third and fourth nerves, and are partly prolonged downwards towards the spinal cord and upwards towards the optic thalamus.

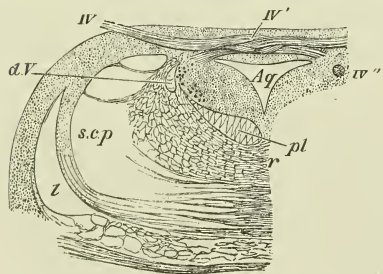


Fig. 54.—SECTION ACROSS THE JUNCTION OF THE PONS VAROLII AND MID-BRAIN AT THE PLACE OF EXIT OF THE FOURTH NERVE (Stilling). THE DORSAL PART ONLY OF THE SECTION IS REPRESENTED.

*Aq*, aqueduct of Sylvius; *IV*, issuing fourth nerve; *IV'*, its bundles decussating in the valve of Vieussens; *IV''*, a bundle cut across in the central grey matter of the aqueduct; *d.V*, descending root of the fifth nerve; *p.l.*, posterior (dorsal) longitudinal bundle; *r*, reticular formation; *l*, lateral fillet; *s.c.p.*, superior cerebellar peduncle.

The fillet is also now more distinct from the neighbouring longitudinal bundles of the reticular formation, and a considerable part of it, known as the *lateral fillet*, is seen to be passing to the side of the pons, where its fibres as they course obliquely towards the corpora quadrigemina overlap the superior cerebellar peduncle of the same side. As the fillet thus passes gradually to the side it gives place to a round

<sup>1</sup> The details of this and of several of the preceding figures are filled in under a somewhat higher magnifying power than that used for tracing the outlines.



bundle of longitudinal fibres, which begins to be distinct in this region, and which passes upwards to form the *mesial bundle of the crusta* (mesial fillet). The superior cerebellar peduncle as the sections are traced upwards is seen gradually to shift ventral- and mesialwards until in sections through the lower part of the mesencephalon it reaches the raphe, and decussates with its fellow of the opposite side.

In sections through the upper part of the pons the fibres of the middle peduncles which arch upwards as before mentioned, are cut obliquely, and their entrance into the cerebellar hemisphere is no longer seen. The pyramidal bundles are more scattered and also more numerous than in the lower part, and the grey matter between them is increased in amount. In the highest sections this grey matter is beginning to accumulate ventral to the lemniscus and reticular formation, and to contain a considerable amount of pigment in its cells (commencement of *substantia nigra* of mesencephalon).

LITERATURE OF MEDULLA OBLONGATA AND PONS VAROLII.<sup>1</sup>

- Baginski, B.**, *Ueber den Ursprung und den centralen Verlauf des Nervus acusticus des Kaninchens u. der Katze*, Sitzungsber. d. Berliner Akad., 1886 and 1889, and Virch. Archiv, 1890; *Zur Kenntniss des Verlaufes der hinteren Wurzel des Acusticus, &c.*, Arch. f. Psych., Bd. xxiii., 1891.
- v. Bechterew, W.**, *Ueber die Längsfaserzüge der formatio reticularis medullae oblongatae et pontis*, Neurol. Centralbl. 1885; *Untersuchungen über die Schleifenschicht*, Berichte der Kgl. Sächsischen Gesellsch. der Wissensch., Math.-Physik. Klasse, 1885; *Ueber eine bisher unbekannte Verbindung der grossen Oliven mit dem Grosshirn*, Neurol. Centralbl., 1885; *Ueber die innere Abtheilung des Strickkörpers und den achten Hirn-nerven*, Neurol. Centralbl., 1885; *Ueber die Bestandtheile des Corpus restiforme*, Archiv f. Anat. u. Phys., Anat. Abth., 1886; *Ueber die Trigeminiwurzeln*, Neurolog. Centralbl., 1887; *Zur Frage über den Ursprung des Hörnerven und über die physiologische Bedeutung des N. vestibularis*, Neurolog. Centralbl. 1887; *Le cerveau de l'homme dans ses rapports et connexions intimes*, Archives slaves de biologie, t. iii., 1887; *Ueber centrale Endigungen des Vagus und über die Zusammensetzung des sogen. Fasciculus solitarius* (Russian), Abstract in Neurolog. Centralbl., 1888; *Zur Frage ü. d. Strick medullares, &c.*, Neurol. Centralbl., 1892.
- Blumenau, L.**, *Ueber d. äusseren Kern des Keilstranges im verlängerten Mark*, Neurol. Centralbl., No. 8, 1891; *Einige Bemerkungen ueber d. äuss. Kern d. Keilstranges*, Neurol. Centralbl., No. 19, 1891.
- Bruce, A.**, *On the connections of the inferior olivary body*, Proc. of the Royal Society of Edinburgh, 1891.
- Darkschewitsch, Ue. d. Ursprung u. d. centralen Verlauf d. N. access.**, Arch. f. Anat. u. Phys., Anat. Abth., 1885.
- Darkschewitsch, L., u. Freud, S.**, *Ueber die Beziehung des Strickkörpers zum Hinterstrang und Hinterstrangkern nebst Bemerkungen über zwei Felder der Oblongata*, Neurolog. Centralbl., 1886.
- Dees, O.**, *Ue. d. Ursprung u. d. centralen Verlauf d. Nervus accessorius*, Allg. Zeitschr. f. Psych., Bd. xliii., 1887; *Ueber die Beziehung d. N. accessorius z. d. Nn. vagus u. hypoglossus*, ibid. xlix., 1888; *Zur Anat. u. Phys. d. Nervus vagus*, Arch. f. Psych. xx., 1888, and Neurol. Centralbl., 1888.
- Edinger, L.**, *Zur Kenntniss des Verlaufes der Hinterstrangfasern in der Medulla oblongata und im unteren Kleinhirnschenkel*, Neurolog. Centralbl., 1885; *Vorlesungen ü. d. Bau d. Centralnervensystem*, Leipzig, 1889.
- Flechsig, Paul**, *Ueber die Verbindung der Hinterstränge mit dem Gehirn*, Neurolog. Centralbl., 1885; *Zur Lehre vom centralen Verlauf der Sinnesnerven*, Neurolog. Centralbl., No. 23, 1886.
- Flechsig u. Hösel**, *Die Centralwindungen ein Centralorgan der Hinterstränge*, Neurol. Centralbl., 1890.
- Forel, A.**, *Ueber d. Verhältniss, &c., Ursprung des IX., X., u. XII. Hirnnerven*, Festschr. f. Nägeli u. Kölliker, 1891.
- Freud, S.**, *Zur Kenntniss der Olivenzwichenschicht*, Neurolog. Centralbl., 1885; *Ueber den Ursprung des N. acusticus*, Monatsschr. f. Ohrenheilkunde, xx., 1886.
- Gudden, H.**, *Beitrag z. Kenntniss d. Wurzeln d. Trigeminierven*, Allg. Zeitschr. f. Psych., Bd. xlvi., 1891.
- Hess, C.**, *Das Foramen Magendii und die Oeffnungen an den Recessus laterales des vierten Ventrikels*, Morpholog. Jahrbuch, x., 1885.
- Hill, A.**, *The grouping of the cranial nerves*, Brain, vol. x., 1888.
- Hollis, W. Ainslie**, *Some points in the histology of the medulla oblongata, pons Varolii, and cerebellum*, Journal of Anat. and Physiol., vols. 18 and 19.
- Homén, E. A.**, *Ueber secundäre Degeneration im verlängerten Mark u. Rückenmark*, Arch. f. pathol. Anat., Bd. lxxxviii., 1882.
- Jelgersma, G.**, *Ueber die Nuclei arciformes*, Centralbl. f. Nervenheilk., 1889.
- Kazzander, G.**, *S. radice dorsale del nervo ipoglosso, &c.*, Anat. Anz., 1891.
- Koch, P. D.**, *Untersuchungen über den Ursprung und die Verbindungen des Nervus hypoglossus*, Archiv f. mikrosk. Anat., Bd. xxxi., 1887.
- v. Kölliker, A.**, *Der feinere Bau des verlängerten Markes*, Anat. Anzeiger, 1891.

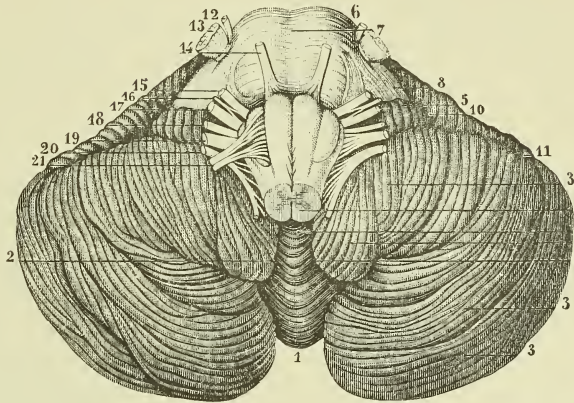
<sup>1</sup> See also Literature of cerebellum and of origin of cranial nerves.

- Löwenthal, N.**, *Dégénération secondaires ascendantes dans le bulbe rachidien, dans le pont et l'étage supérieur de l'isthme*, Revue médicale de la Suisse romande, v., 1885.
- Marchi, V.**, *Sopra un caso di doppio incrociamiento dei fasci piramidali*, Archiv. ital. per le malad. nervos., xxii., 1885.
- Mendel**, *Ueber das solitäre Bündel*, Arch. f. Psychiatrie, xv., 1884; *Ueber den Kernursprung des Augenfacialis*, Deutsche medic. Wochenschr., Jahrg. xiii., 1887.
- Meyer, P.**, *Beitrag zur Lehre der Degeneration der Schleife*, Archiv f. Psychiatrie, Bd. xvii. 1886; *Ueber ein Fall von Pons-hämorrhagie mit secundären Degenerationen der Schleife*, Arch. f. Psych., xiii., 1882.
- Mingazzini, G.**, *Intorno alla fina anatomia del nucleus arciformis, &c.*, Atti della R. Accad. medica di Roma, Anno xv., 1889; *Intorno alle origine del n. hypoglossus*, Ann. di freniatria, ii., 1891.
- v. Monakow**, *Zur Kenntniss d. "äusseren Acusticuskerns" u. d. Corpus restiforme*, Neurol. Centralbl., 1882; and in Archiv f. Psych., Bd. xiv., 1883; *Experimentelle Beiträge zur Kenntniss der Pyramiden- und Schleifenbahn*, Correspondenzblatt für Schweizer Aerzte, 1884; *Neue experimentelle Beiträge zur Anatomie der Schleife*, Neurol. Centralbl., 1885; *Striae acusticae u. untere Schleife*, Arch. f. Psych., xxii., 1890.
- Pal, J.**, *Ueber d. Verlauf der Fibrae arcuatae externae anteriores*, Arbeiten a. d. Instit. f. allg. u. xp. Pathologie, Wien, 1890.
- Roller, C.**, *Der centrale Verlauf d. N. access.*, Zeitsch. f. Psych., 1881; *Ueber die Schleife*, Arch. f. mikr. Anat., Bd. xix., Neurol. Centralbl. 1890.
- Sala, L.**, *Sull' origine del nervo acustico*, Monitore zoologico italiano, 1891 (French in Archives ital. de biol., t. xvi., 1891).
- Spitzka, E. C.**, *Contributions to the anatomy of the lemniscus*, Medical Record, 1884.
- Sutton, J. B.**, *The lateral recesses of the fourth ventricle; their relation to certain cysts and tumours of the cerebellum, and to occipital meningocele*, Brain, 1886.
- Tooth, H. H., and Turner, W. A.**, *Study of a case of bulbar paralysis, with notes on the origin of certain cranial nerves*, Brain, 1891.
- Vejas, P.**, *Experimentelle Beiträge zur Kenntniss der Verbindungsbahn des Kleinhirns und des Verlaufs der Funiculi graciles und cuneati*, Archiv für Pyschiatrie, xvi., 1885.
- Vincenzi, L.**, *Note histologique sur l'origine réelle de quelques nerfs cérébraux*, Arch. ital. de biologie, 1884.
- Virchow, H.**, *Ueber die Striae acusticae des Menschen*, Verhandl. d. phys. Gesellsch. zu Berlin, Arch. f. Anat. u. Physiol., 1888. Physiol. Abtheil.
- Werdrig, G.**, *Concrement in der rechten Substantia nigra Soemmeringii mit auf- und absteigender Degeneration der Schleife und theilweiser Degeneration des Hirnschenkelfusses*, Wiener med. Jahrbücher, Bd. viii., 1889.
- Wilder, Burt G.**, *Notes on the foramina of Magendie in Man and the Cat*, Journal of Nervous and Mental Disease, vol. xiii., 1887.

THE CEREBELLUM.

The cerebellum (figs. 55, 56, and 58) consists of two lateral *hemispheres* joined together by a median portion called, from the peculiar appearance caused by the transverse furrows or ridges upon it, the *worm* or *vermiform process*. This is seen

Fig. 55.—INFERIOR SURFACE OF THE CEREBELLUM WITH THE PONS VAROLII AND MEDULLA OBLONGATA. (From Sappey after Hirschfeld and Leveillé.)  $\frac{2}{3}$

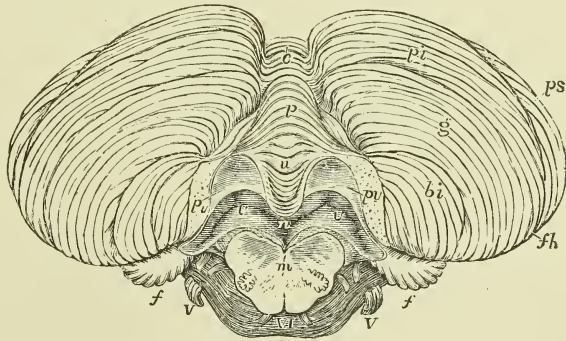


1, 1, inferior vermiform process; 2, 2, median depression or vallecule; 3, 3, postero-inferior lobe of the hemisphere; 4, amygdala; 5, flocculus; 6, biventral lobe; 7, pons Varolii; 8, middle peduncle of the cerebellum; 9, medulla oblongata; 10, 11, anterior part of the great horizontal fissure; 12, 13, smaller and larger roots of the fifth pair of nerves; 14, sixth pair; 15, facial nerve; 16, pars intermedia; 17, auditory nerve; 18, glosso-pharyngeal; 19, pneumo-gastric; 20, spinal accessory; 21, hypoglossal nerve.

on the under surface in the fossa between the hemispheres as a well-marked projection named the *inferior worm*, but above forms only a slight elevation, the *superior worm*. In birds, and in animals lower in the scale, this middle part of the cerebellum alone exists, and in mammals it is the first part to be developed and to be marked off into subdivisions; moreover, in most mammals it forms a large median lobe very distinct from the hemispheres.

The cerebellum occupies the posterior fossa of the cranium. Its median portion lies behind the 4th ventricle and behind and below the corpora quadrigemina, to

Fig. 56.—LOWER SURFACE OF THE CEREBELLUM WITH THE INFERIOR (POSTERIOR) MEDULLARY VELUM. (Allen Thomson after Reil and Reichert, and from nature.)  $\frac{2}{3}$



The medulla oblongata is cut across near the pons Varolii; and the latter has been separated somewhat from the cerebellum in order to bring into view the posterior medullary velum. To display this better the amygdalæ have been removed.

*f h*, horizontal fissure; *p s*, postero-superior lobe; *p i* and *g*, postero-inferior lobe; *g*, slender lobe; *b i*, biventral lobe; *f*, flocculus; *c* to *n*, inferior vermiform process, on which are, *c*, tuber valvulæ, *p*, pyramid, *u*, uvula, *n*, nodule; *p v*, on each side, placed on the cut surface where the amygdalæ have been removed, points by a line to the lateral part of the inferior (posterior) medullary velum; its median part is lost under the nodule; *v, v*, cavity of the fourth ventricle; the cavity extends on each side into the lateral recess; *m*, cut surface of medulla oblongata; *V, VI*, roots of the fifth and sixth cranial nerves.

which it appears suspended by its superior peduncles. Below and at the sides it receives the inferior peduncles (restiform bodies) from the medulla oblongata, and



from the anterior part of each hemisphere the thick mass of the middle peduncle passes forwards and inwards into the pons Varolii. Between the two superior peduncles and behind the upper part of the 4th ventricle is a white lamina continuous with the white centre of the worm, which thins off into it. This is the *superior* (or anterior) *medullary velum* or *valve of Vieussens*; it extends as far as the corpora quadrigemina, filling up the interval between the superior peduncles,

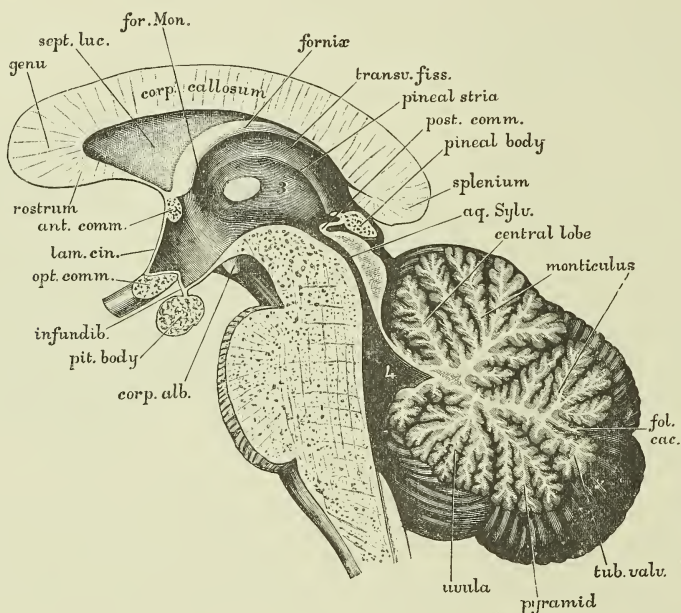


Fig. 57.—PORTION OF A MEDIAN SECTION OF THE BRAIN, SHOWING THE CORPUS CALLOSUM, THIRD VENTRICLE, AQUEDUCT AND FOURTH VENTRICLE, PONS, CEREBELLUM, &C. (G. D. T.)  $\frac{3}{4}$

and becoming continued into the roof of the aqueduct of Sylvius. Below, there is a similar white lamina prolonged under and on either side of the nodule from the white centre, and stretching over this part of the ventricle towards its lateral boundaries (fig. 56, *p v*). It does not, however, extend far down, but ends with a somewhat thickened margin, concave downwards, being prolonged towards the calamus scriptorius merely by the ventricular epithelium, which covers its ventral surface. To the semilunar lamina thus formed the name *inferior* (or posterior) *medullary velum* is applied.

The hemispheres are separated below and behind by a deep notch (*posterior cerebellar notch*, *incisura marsupialis*), and above and in front by a broader, shallower notch (*anterior cerebellar notch*, *incisura semilunaris*). The upper vermiform process, although slightly elevated, is not sharply marked off from the dorsal surface of the hemispheres, so that the upper surface of the organ, which is on the whole flattened but somewhat ridged in the middle (*culmen monticuli*), slopes downwards uninterruptedly on each side and behind (*clivus*). On the inferior surface each hemisphere is convex both from before backwards and from side to side, but is separated from its fellow by a deep median fossa, named the *vallecula*, which is continuous behind with the posterior notch, and in which the inferior vermiform process (fig. 56, *c to n*, fig. 58 B, *t.v. to n.*) lies concealed. Into this hollow the medulla oblongata is received in front, and the falx cerebelli behind.

The greatest diameter of the organ is transverse, and extends to about four inches (10 centimeters) : its greatest width from before backwards is about two inches (5 centimeters) : of the middle part about one inch and a half (4 centimeters) ; and its greatest depth is about two inches, but it thins out towards the lateral border. It weighs about 5 oz.

The cerebellum is characterised by its laminated or foliated appearance, its surface being everywhere marked by deep, closely set, transverse and somewhat curved, fissures, which extend a considerable depth into its substance, but do not all entirely encircle the organ, for many of them coalesce with one another, and some of the smaller furrows have even an oblique course between the others. Moreover, on opening the larger fissures, other folia are seen to lie concealed within them, not reaching the surface of the cerebellum.

The depth of the fissures can best be estimated in sections through the organ taken across the laminae : in such sections each lamina is seen to have a white centre and a grey cortex, and the white centres of the laminae appear in the form of processes ramifying from a larger white centre near the middle and anterior part of the organ : to the arborescent appearance thus obtained in section the name *arbor vitæ cerebelli* has been applied.

Externally the most conspicuous fissure is the **great horizontal fissure** (figs. 56, 58, *fh*), which beginning in front at the middle peduncle of either side extends round the outer and posterior border of each hemisphere, dipping down into the posterior notch. This fissure divides the cerebellum into an upper and lower portion, corresponding in fact to the upper and lower surfaces, in each of which several lobes, separated by fissures for the most part deeper than the rest, are described. Taking the great horizontal fissure to divide the cerebellum into an upper and a lower half or surface, we may first consider the parts which are present upon the upper surface and which compose the upper half of the organ in both the worm and the hemispheres.

**UPPER SURFACE.**—The upper worm begins at the superior medullary velum between the two superior peduncles and ends at the bottom of the posterior notch in a short, concealed transverse lamina, termed the folium cacuminis. It is usually described as being formed of five successive parts or lobules, which are termed from before back the *lingula*, the *central lobe*, the *culmen* (culmen monticuli), the *clivus* (clivus monticuli), and the *folium cacuminis*. Corresponding with these in each hemisphere are the large *postero-superior lobe*, continued laterally from the small folium cacuminis, the *posterior crescentic*, continued from the clivus, the *anterior crescentic lobe*, continued laterally from the culmen, the *ala lobuli centralis*, continued from the central lobe, and sometimes a lateral extension of the lingula.

Of the fissures which separate these lobes of the upper surface from one another, four in number, the first, or most anterior, which may be termed the *precentral sulcus*, lies in front of the central lobe, and separates it from the lingula. The next, or *postcentral sulcus*, divides the central lobe and its *alæ* from the culmen and anterior crescentic lobes. The third, or *preclival fissure* (also called the antero-superior), separates the culmen and anterior crescentic from the clivus and posterior crescentic lobes. Lastly, the fourth, or *postclival fissure* (also called the postero-superior), lies immediately over the folium cacuminis, and separates this and the postero-superior lobes from the clivus and posterior crescentic. Below the folium cacuminis and the postero-superior lobes comes the great horizontal fissure which has been already described.

Besides these interlobar fissures, all of which extend deeply down towards the central white substance, there are certain other sulci which on the upper surface of the hemispheres are almost or quite as well marked as the interlobar ones, but which are less deep or are not seen on the upper worm. They are best made out in



vertical sections of the hemisphere. Two of these intralobar fissures occur in the posterior crescentic (clival) lobe and one or two in the anterior crescentic (culmi-

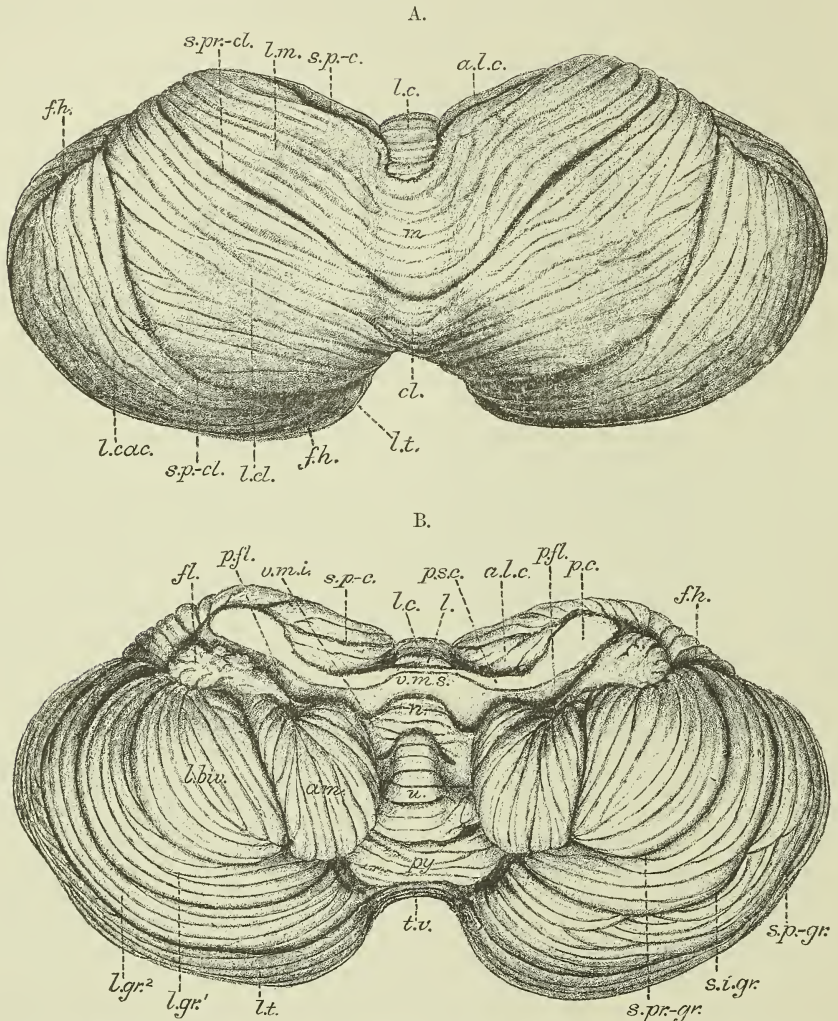


Fig. 58.—VIEWS OF THE UPPER (A) AND LOWER (B) SURFACES OF THE CEREBELLUM, NATURAL SIZE. FROM PHOTOGRAPHS. (E.A.S.)

In A. *l.c.*, lobulus centralis; *a.l.c.*, ala lobuli centralis; *m.*, culmen monticuli; *l.m.*, lobus culminis; *cl.*, clivus; *l.cl.*, lobus clivi; *l.cac.*, lobus cacuminis; *l.t.*, lobus tuberis; *s.p.-c.*, sulcus postcentralis; *s.pr.-cl.*, sulcus preclivalis; *s.p.-cl.*, sulcus postclivalis; *f.h.*, *f.h.*, fissura horizontalis magna.

In B. *l.*, lingula; *l.c.*, lobulus centralis; *a.l.c.*, ala lobuli centralis; *s.p.-c.*, sulcus postcentralis; *v.m.s.*, velum medullare superius; *p.s.c.*, pedunculus cerebelli superior; *p.c.*, pedunculi cerebelli medius et inferior; *n.*, nodulus; *v.m.i.*, velum medullare inferius; *p.fl.*, pedunculus flocculi; *fl.*, flocculus; *u.*, uvula; *am.*, amygdala; *py.*, pyramis; *l.biv.*, lobus biventralis; *t.v.*, tuber valvulae seu posticum; *l.t.*, lobus postero-inferior; *l.gr.1*, lobulus gracilis anterior; *l.gr.2*, lobulus gracilis posterior; *s.pr.-gr.*, sulcus pregracilis; *s.i.-gr.*, sulcus intra-gracilis; *s.p.-gr.*, sulcus postgracilis; *f.h.*, fissura horizontalis magna.

The vallicula has been somewhat opened out to display the parts of the lower worm.

nate) (fig. 59). The laminae and fissures of the upper surface all have a subparallel transverse direction, curving forwards as they traverse the hemisphere to lose themselves at the antero-lateral border in the great horizontal fissure.



**Lobes of the upper surface.**—We may now describe in detail the subdivisions of the upper surface, taking (since they are directly continuous with one another) those of the worm and hemispheres together.

**The lingula.**—This is usually confined to the worm, and from the surface it is entirely concealed by the next lobe : it is best seen in a median section of the organ (figs. 57 and 59). It consists of a small tongue-shaped group of four or five transverse laminae, which may be said to lie upon the middle of the superior medullary velum (fig. 58, *l*). Its medullary centre is in continuity with the velum, and forms part of the roof or dorsal boundary of the fourth ventricle which here has a tent-shaped projection into the middle of the cerebellum (fig. 57, 4).

The lingula gradually shades off at the sides and is usually unrepresented in the hemispheres, but its laminae are sometimes prolonged laterally for a little distance over the superior cerebellar peduncle (*frænulum lingulae*).

**The central lobe and its alae.**—The central lobe is largely concealed by the culmen when the cerebellum is in its natural position, but when the organ is cut away from the adjacent structures this lobe is seen in the anterior notch, where its laminae appear at the surface. They are prolonged beyond the limit of the worm for some distance along the upper and anterior part of the hemispheres, where they form wing-like continuations of the central lobe which are known as the *alae lobuli centralis* (fig. 58). The central lobe receives a primary branch of the arbor vitæ which passes upwards and forwards into it from the enlargement of the white centre which is known as the trapezoidal body, but the fissures (*pre-central* and *postcentral*) which separate it from the lingula and culminate lobe respectively, are not better marked at the surface than those which intervene between the laminae of the culminate lobe, and, as a glance at the sections (fig. 59) shows, its laminae all belong to the same (ascending) group of folia as those which constitute the culminate lobe.

**The culmen and anterior crescentic lobes : lobus culminis.**—The culmen occupies rather more than half of the upper surface of the worm, and, as its name implies, constitutes the most prominent part of the upper worm. Its surface shows three or four well-marked lamellae, beset by a number of secondary and tertiary folia. It is separated from the next part of the worm by a deep groove which descends to the middle of the organ ; this sulcus is prolonged, as we have already seen, on to either hemisphere, having there been termed the antero-superior sulcus, and passing in a curved manner parallel with the general disposition of the laminae on this surface to the antero-lateral margin, where it runs into the anterior part of the great horizontal fissure. The antero-superior sulci together may conveniently be termed the *preclival*. The subdivision of the hemisphere which is cut off between this preclival fissure behind and the postcentral sulcus in front has been known as the *anterior crescentic lobe* (*lobus lunatus anterior*, Kölliker). The two anterior crescentic lobes, together with the culmen with which they are in complete lateral continuity, form a main subdivision of the upper surface of the cerebellum, which may appropriately be termed the *lobe of the culmen*. The lateral parts of the lobe each receive three well-marked branches of the medullary centre of the hemispheres ; in the central part they come off by a common stem from the corpus trapezoides of the worm (fig. 59).

**The clivus and posterior crescentic lobes : lobus clivi.**—Behind the antero-superior or preclival fissure, and extending as far as the folium cacuminis (from which it is separated by the *postero-superior* or *postclival fissure*), is another considerable group of laminae which receive their branches from the upper aspect of the horizontal stem of the arbor vitæ. In a median section of the worm these laminae appear to form one group with the folium cacuminis and the laminae of the tuber valvulae (fig. 59 A), and this group has been described by Schwalbe as con-

stituting a posterior lobe. In fact, however, the great horizontal fissure below the folium cacuminis and the postclival fissure above this folium separate the group into three well-marked divisions, of very unequal size it is true in the worm, owing to the rudimentary character of the central or cacuminate division, but far more distinct and equal in the hemispheres; they may therefore be conveniently thus subdivided in the worm also, and of them, two (the clivus and folium cacuminis) belong to the upper worm, the third, tuber valvulæ, to the lower.

Two or three secondary laminae of the clivus reach the surface of the worm, but they are beset with many tertiary folia, and other important folia belonging to the same group lie concealed in the preclival fissure.

The lateral extension of the clivus on to each hemisphere is known as the *posterior crescentic lobe* (*l. lunatus posterior*, Kölliker), and the two posterior crescentic lobes with the clivus between them, bounded in front by the preclival, behind by the postclival fissure, may collectively be termed the *lobe of the clivus*. The lateral parts of this lobe each receive two or three primary branches of the medullary centre of the hemisphere (fig. 59).

The combined anterior and posterior crescentic lobes of each hemisphere were formerly termed the quadrilateral lobe.

**The folium cacuminis and postero-superior lobes: lobus cacuminis.**

—The folium cacuminis is formed by the extremity or apex of the main horizontal stem of the arbor vitæ vermis (figs. 57, 59). As the vertical section shows, it is composed of but a single primary folium, which may be either plain or beset with rudimentary folia. But at the side of the worm it rapidly expands, with divergence of its bounding fissures and a great increase of size of its main branch of the arbor vitæ and the formation of numerous secondary and tertiary folia, a large lobe being thereby produced at the posterior and upper part of each hemisphere which has been termed the *postero-superior lobe*. The expansion occurs mostly above the horizontal plane, and its branch of the arbor vitæ has a direction no longer directly backwards, but rather upwards and backwards; this upward shifting appears to be due to the great development of the lobes of the lower surface of the hemisphere. The postero-superior lobes are bounded, like the folium cacuminis itself, in front and above by the postclival fissure, below by the great horizontal fissure; joined as they are in the middle line by the folium cacuminis, they form a great winged mass which occupies the posterior third of the upper surface of the cerebellar hemispheres, and forms the rounded postero-lateral border; to this conjoined mass the term *lobus cacuminis* may be applied.

**UNDER SURFACE.**—Turning now our attention to the under surface of the organ, we here meet with considerably greater complexity, and the correspondence between the parts of the worm and those of the hemisphere is less clearly apparent. The lower worm extends from the inferior medullary velum to the folium cacuminis (great horizontal fissure), and the parts or lobules which are enumerated in it are four in number, viz.: from before back (1) the *nodule*, (2) the *uvula*, (3) the *pyramid*, and (4) the *tuber valvulæ seu posticum*. On the hemisphere a greater number of lobes are distinguished, viz.: (1) the *flocculus*, corresponding with the nodule; (2) the *tonsil (amygdala)*, corresponding with the uvula; (3) the *bi-ventral lobe*, corresponding with the pyramid; (4) the *slender lobe*, formed of an anterior and a posterior part well marked off from one another; and (5) the *inferior semilunar lobe*, which also shows a tendency to subdivision. This last lobe corresponds with and is directly in lateral continuity with the tuber posticum of the worm. The slender lobes are interpolated in the hemisphere, and have not any obvious prominence of the worm corresponding with them, but they appear to represent a development of certain rudimentary folia which are seen in

sagittal sections of the worm on the lower part of the stalk of the tuber valvulæ, entirely concealed by the pyramid (see fig. 59 B). If this is the case, then the combined slender and inferior semilunar lobes may be reckoned as collectively forming a primary subdivision of the hemisphere, corresponding with the tuber posticum of the worm and to which the term postero-inferior may be applied,<sup>1</sup> and the two postero-inferior lobes, together with the tuber valvulæ which unites them in the middle line, may collectively be spoken of as the *lobus tuberis*. This large lobe occupies at least two-thirds of the inferior surface of the cerebellum; of the remaining third more than one-half is occupied by the combined pyramid and biventral lobes, about one-third by the uvula and amygdalæ, and the small remaining portion by the nodule and flocculus.

**Fissures of the under surface.**—The lobes of the under surface of the organ are separated from one another by fissures extending deeply into both the worm and hemispheres. In the worm there are three such interlobar depressions, viz. : one between the nodule and the uvula (*postnodular*), one between the uvula and pyramid (*prepyramidal*), one between the pyramid and tuber valvulæ (*postpyramidal*), besides the middle of the great horizontal fissure separating the tuber valvulæ from the folium cacuminis. In the hemispheres a larger number is apparent. The *postnodular sulcus* passes laterally into a groove curved with its convexity forwards which first limits the amygdala in front and then passes between the flocculus and biventral lobe to join the anterior end of the great horizontal fissure. The *prepyramidal sulcus* curves laterally round the outer side of the amygdala, separating it from the biventral lobe: it joins the postnodular in front of the amygdala. From the sides of the *postpyramidal sulcus* three deep fissures, concentric with one another, curve outwards and forwards over the under surface of the hemisphere. The most anterior of these, and also the shortest, passes at first more forwards, concealed by the amygdala before curving round in the manner described. It lies between the biventral and slender lobes, and may be termed the *anterior arcuate* or *pregracile sulcus*. The second of the three concentric fissures subdivides the slender lobe into two nearly equal parts (lobulus gracilis anterior and lobulus gracilis posterior); we may distinguish it as the *middle arcuate* or *midgracile*. The third, which is the longest, separates the slender lobe from the inferior semilunar lobe; like the other two it arises at the mesial edge of the hemisphere opposite the depression (postpyramidal sulcus) between the pyramid and the tuber valvulæ, and arches round on the lower surface of the hemisphere with its concavity forward to fall into the great horizontal fissure at the antero-lateral margin. This fissure may be termed the *posterior arcuate* or *postgracile*. Behind this again there is a fairly well marked deep fissure, serving to subdivide the inferior semilunar lobe. This may be termed the *lower* or *lesser horizontal sulcus*. Lastly, the deep antero-posterior grooves which mark off the lower worm may conveniently be termed the *sulci vallecule* (*dexter et sinister*).

**Lobes of the under surface.**—The lobes of the under surface of the organ as already enumerated may be now more particularly described in order from before back.

The **nodule and flocculus: lobus noduli**.—The nodule occupies much the same position relatively to the inferior medullary velum and tent of the fourth ventricle that the lingula occupies with regard to the superior medullary velum, but it is usually better developed than the lingula. Although sometimes merely composed of a few transverse laminae set upon the median part of the inferior medullary velum, it more often appears as a distinct prominence having a separate branch of the

<sup>1</sup> In the previous edition of this work, the term postero-inferior was used as a synonym for the inferior semilunar lobe.



arbor vitæ (fig. 59 A). It can only be seen after the cerebellum is separated from the medulla oblongata and pons, or in a median section, being almost entirely concealed by the uvula when the organ is viewed from below. The lateral part of the inferior medullary velum is continued on either side of the nodule as a thin white semilunar band with a thickened concave free lower border (fig. 58 B. *v.m.i.*). Traced laterally towards the hemisphere, the white lamella becomes thickened and covered with grey matter (*pedunculus flocculi*), and at length expands into a small irregular lobule lying in the groove between the biventral lobe and the middle peduncle of the cerebellum, and composed of a few short irregular laminae, which tend to diverge from the attachment of the stalk. The nodule, with the inferior medullary velum, the stalk of the flocculus, and the flocculus itself constitute collectively a small but distinct subdivision of the cerebellum (*lobus noduli*).

Other small portions of laminated grey matter sometimes occur attached to the flocculus, usually lying between it and the middle peduncle. These have been termed *accessory flocculi*.

**The uvula and tonsils: lobus uvulae.**—The uvula forms a considerable portion of the lower worm, being elongated from before back; three considerable secondary laminae, beset with eight or more tertiary folia, appear at the surface. It is least prominent close to the nodule, and from this part it enlarges rapidly downwards and backwards to attain its greatest prominence next to the pyramid. Like the nodule and the pyramid it is purely a median prominence, being separated from the hemispheres by the deep groove (sulcus vallecule) which prolongs the vallecule on either side of this part of the worm. At the bottom of this groove on either side of the uvula is a low corrugated greyish ridge which connects the narrow stalk of the uvula with the stalk of the tonsil: this concealed connecting ridge is known as the *furrowed band*. From its outer extremity the rounded amygdala projects downwards and backwards into the vallecular groove, concealing the sides of the uvula mesially, and the narrow connection between the pyramid and biventral lobe posteriorly. The uvula, furrowed band and tonsil constitute collectively another distinct subdivision of the hemisphere (*amygdalo-uvular lobe, lobus uvulae*). The amygdala or tonsil forms a rounded projection of about 10 or 12 folia, which run nearly in a sagittal direction, so that in a sagittal section of the cerebellum passing through the tonsil, its branch of the arbor vitæ appears expanded and not obviously dendritic (fig. 59 C). Above and in front it has a few transverse laminae which are only seen in sections, being concealed, in the natural position of the parts, by the rest of the projection. Opposite the inferior medullary velum its white matter comes for a certain distance to the surface, covered, of course, by pia mater. The amygdala is lodged in a depression (*nidus avis*) at the front of the vallecule, which is bounded by the uvula mesially and the biventral lobe laterally; the surface which rests against the uvula is nearly smooth, as is the corresponding concave surface of the uvula; a continuation of the postnodular sulcus separates it from the inferior medullary velum.

**The pyramid and biventral lobes: lobus pyramidis.**—The pyramid forms the most marked prominence of the lower worm, but as seen from the surface, it shows only three or four transverse laminae. It is in reality a long clavate projection attached to the stem of the arbor vitæ by a narrow stalk, and it is not only separated from the uvula and tuber valvulae by deep fissures, but also from the hemispheres by the sulcus vallecule on either side of it. Its connection with the biventral lobe of the hemisphere is here maintained by a low narrow ridge, which joins the stalk of the pyramid with the mesial pointed extremity of the biventral lobe. This *connecting ridge* is evidently analogous with the furrowed band of the preceding lobe, but it is an even less distinct structure. To see it the amygdala must be

removed, or a vertical section made through the organ, passing just to the outer side of the pyramid. The biventral lobe is roughly triangular in shape, with the base forwards abutting on the postnodular sulcus, and the apex directed backwards and inwards towards the root of the pyramid. The outer side is bounded by the outwardly curved pre-gracile fissure, the inner by the side of the vallecule, but is concealed by the amygdala, which projects over the lobe. The laminae have a curved direction radiating from the apex towards the base of the triangle. The lobe is partly bisected by a fissure (midventral) deeper than the rest, and becoming better marked towards the base. This fissure divides the lobe into an inner and an outer portion; from this subdivision its name has been derived. Collectively, the pyramid, the connecting ridges, and the biventral lobes constitute a distinct division of the cerebellum, to which the name *lobe of the pyramid* may be applied.

**The tuber posticum and postero-inferior lobes: lobus tuberis.**—The tuber valvulæ seu posticum, which constitutes the hindermost division of the inferior worm, exposes about five or six tertiary folia (laminae transversales inferiores) at the surface between those of the pyramid and the folium cacuminis. It differs from the other constituents of the inferior worm, and resembles those of the superior worm in being obviously prolonged laterally into and gradually enlarging to form the corresponding hemisphere lobes (fig. 58 B, *l.v.*, *l.t.*). These conjoined postero-inferior lobes of the hemispheres with the tuber valvulæ of the worm collectively form a large alate mass (*lobus tuberis*), bounded in front by the anterior arcuate or pregracile fissure, which separates it from the pyramidal (biventral) lobe; behind by the great horizontal fissure, which also limits it antero-laterally. Its laminae run in a curved manner, concentrically with these fissures, and it is separated into four crescentic parts by three concentric fissures two deep and complete, the middle arcuate and the posterior arcuate and a third only slightly less deep, the lesser horizontal fissure. Of these four parts the two anterior, about equal in size, form what has been termed the slender lobe (*lobus gracilis*); the two posterior, of which the hinder one is the larger, together form what has been termed the inferior semilunar lobe.

The whole cerebellar worm may thus be regarded as subdivided by deep sulci into nine parts or lobes, each of which has a corresponding lobe of the hemisphere continuous with it. This continuity is obvious upon the upper and posterior aspects of the organ, but on the inferior aspect it tends to be rudimentary and is moreover concealed within the sulci vallecule. The combined lobes which are thus formed by the continuity of the lobes of the worm with those of the hemispheres are as follows:—(1) lobus lingulæ, (2) lobus centralis, (3) lobus culminis, (4) lobus clivi, (5) lobus cacuminis, (6) lobus tuberis, (7) lobus pyramidis, (8) lobus uvulæ, and (9) lobus noduli. The hemisphere-parts of the lobus lingulæ and of the lobus centralis are rudimentary, but otherwise the hemisphere-parts of the lobes are considerably larger than those of the worm, in some cases, as in that of the lobus cacuminis and the lobus tuberis, the difference of size being very great. The former (*lobus cacuminis*) is, in fact, represented in the worm by a single concealed folium only, while a large portion of the lobus tuberis, viz., the lobus gracilis, can hardly be said to be represented in the worm. These nine lobes are separated from one another by interlobar fissures, which are all nearly equally well marked in the hemispheres, whilst in the worm some are less developed, particularly those above and below the folium cacuminis. This median part of the lobus cacuminis is, therefore, imperfectly marked off from the clivus above and the tuber valvulæ below, the three together forming a very distinct posterior subdivision of the worm.

The relations between the parts of the worm and those of the hemispheres, and the fissures which separate the several lobes from one another, as well as those which serve to subdivide the lobus tuberis, are indicated in the accompanying table:—

DIAGRAMMATIC TABLE to show the corresponding parts of the worm and hemispheres and the fissures which separate them into lobes. The positions of the principal intra-lobar fissures of the hemisphere are marked by thin lines.

	HEMISPHERE.	WORM.	WORM AND HEMISPHERE.
	Frænulum lingulæ	Lingula	} Lobus lingulæ
Sulcus precentralis.....	Ala lobuli centralis	Lobulus centralis	
Sulcus postcentralis ...	Lobus lunatus anterior	Culmen monticuli	} Lobus culminis
Sulcus preclivalis .....	Lobus lunatus posterior	Clivus monticuli	
Sulcus postclivalis .....	Lobus postero-superior	Folium cacuminis	} Lobus cacuminis
Sulcus horizontalis } magnus .....	Lobus semilunaris inferior	Tuber valvulæ	
Sulcus postgracilis .....	Lobulus gracilis anterior	} Lobus postero-inferior	} Lobus tuberis
Sulcus intragracilis ...	Lobulus gracilis posterior		
Sulcus pregracilis } s. postpyramidalis }	Lobus biventralis		
Sulcus prepyramidalis...	Amygdala	Uvula	} Lobus uvulæ
Sulcus postnodularis ...	Flocculus	Nodulus	} Lobus noduli

**Description of the arbor vitæ cerebelli.**—When a section is made through the worm or through either hemisphere across the direction of the folia, the organ is seen, as already mentioned, to be composed of a white or medullary centre and of a uniform cortex of grey matter, and the section presents a dendritic appearance (arbor vitæ cerebelli) in consequence of the fact that the larger laminæ are themselves formed of secondary, and these again are beset with tertiary folia. It is only in such sections that the relative depth and importance of the fissures can be estimated, and a description of the sections is therefore fully as important as that of the surface-markings, and is in fact necessary for the elucidation of the latter.

The mode of transition of the parts of the worm into those of the hemispheres can also best be made out by the inspection of successive sagittal sections; beginning with a median section through the worm, and passing gradually to the side, the successive sections being made in planes parallel with the median plane, or only so far inclined to it, and to one another, as to cut the majority of the lamellæ at right angles.

1. *Section of the cerebellum in the median plane of the worm* (fig. 59 A, and fig. 57). In front we notice the tent of the fourth ventricle projecting with a sharp angle into the enlargement of the white substance known as the *corpus trapezoides (c.tr)*. The apex of the angle is directed backwards with a slight downward tilt, so as to leave only a thin layer of white matter—the middle part of the inferior medullary velum—between it and the nodule. The corresponding layer of



white matter between the cavity of the fourth ventricle and the lingula is the middle part of the superior medullary velum. The two vela are prolonged like roots upwards and downwards from the anterior or ventral side of the corpus trapezoides. From the upper part of the corpus trapezoides two branches diverge, one upwards with a slight inclination forwards, this is the branch to the central lobe; the other, the thickest and strongest of all the branches of the arbor vitæ of the worm, passes upwards and backwards into the culmen. This stem of the culmen gives off secondary branches on either side. Of those which are directed upwards and forwards, the one nearest the base is rudimentary, and enters a small lamina concealed at the bottom of the post-central fissure: the next two are large, and enter laminae which reach the surface, but before attaining it they may themselves fork. The prolongation of the stem also reaches the surface, being first bifurcated, but the branches from the lower or posterior side of the stem of the culmen, two, three or more in number, pass into short laminae which mostly lie concealed within the pre-clival fissure.

Prolonged backwards from the postero-inferior angle of the corpus trapezoides is a narrow horizontal stem, which after a course of about two centimeters, ends directly in the medullary centre of the folium cacuminis, often passing round a slight curve just before reaching this. From the upper side of this horizontal stem about five branches pass upwards and backwards, and from the lower side about as many pass downwards and backwards, but all are not of equal importance, for some merely enter rudimentary lamellæ which are concealed at the bottom of the interlobar fissures, and only a few enter lamellæ which reach the surface.

Of those which pass from the upper side of the horizontal stem all may be considered to belong to the clivus. Of the more anterior of these some are rudimentary, one or two less so, but all enter lamellæ which are completely concealed in the preclival fissure. The hindmost is larger and longer and reaches the surface; it gives off a vertical branch which passes into the upper part of the lobe nearest the culmen, bifurcating near the surface, and is then continued on in a nearly horizontal direction parallel to and overlying the folium cacuminis.

Of the branches from the lower side of the white centre and its horizontal prolongation three are of great importance. The foremost one passes from the corpus trapezoides almost vertically downwards for about six or eight mm. into the uvula, giving off only small lateral branches; it then gives off successively two or three branches which course downwards and forwards, usually bifurcating before reaching the surface. Only short branches are given off backwards from the main part of the uvula stem.

About two or three mm. behind the branch to the uvula, that to the pyramid passes off. This has a general direction downwards and backwards; it gives off lateral branches as it proceeds, most of which are small, but one or two longer branches come off on its anterior aspect and pass to the surface nearly vertically downwards.

Following the horizontal stem back, two or three rudimentary offshoots are seen entering small lamellæ which are concealed within the postpyramidal fissure, until finally, about 15 mm. from the corpus trapezoides and 5 mm. from the base of the folium cacuminis, another considerable branch passes off at an acute angle, with a curve forwards and downwards into the tuber valvulæ. Its lateral offshoots, which are at first short, become gradually longer, corresponding with the expanding form of this lobe of the worm.

The deepest fissures of the median section are the precentral, the postcentral, the preclival, the prepyramidal, the postpyramidal, and the postnodular (see fig. 59 A). The postclival fissure is here quite shallow, the great horizontal only slightly deeper. The general grouping of the branches of the arbor vitæ is into

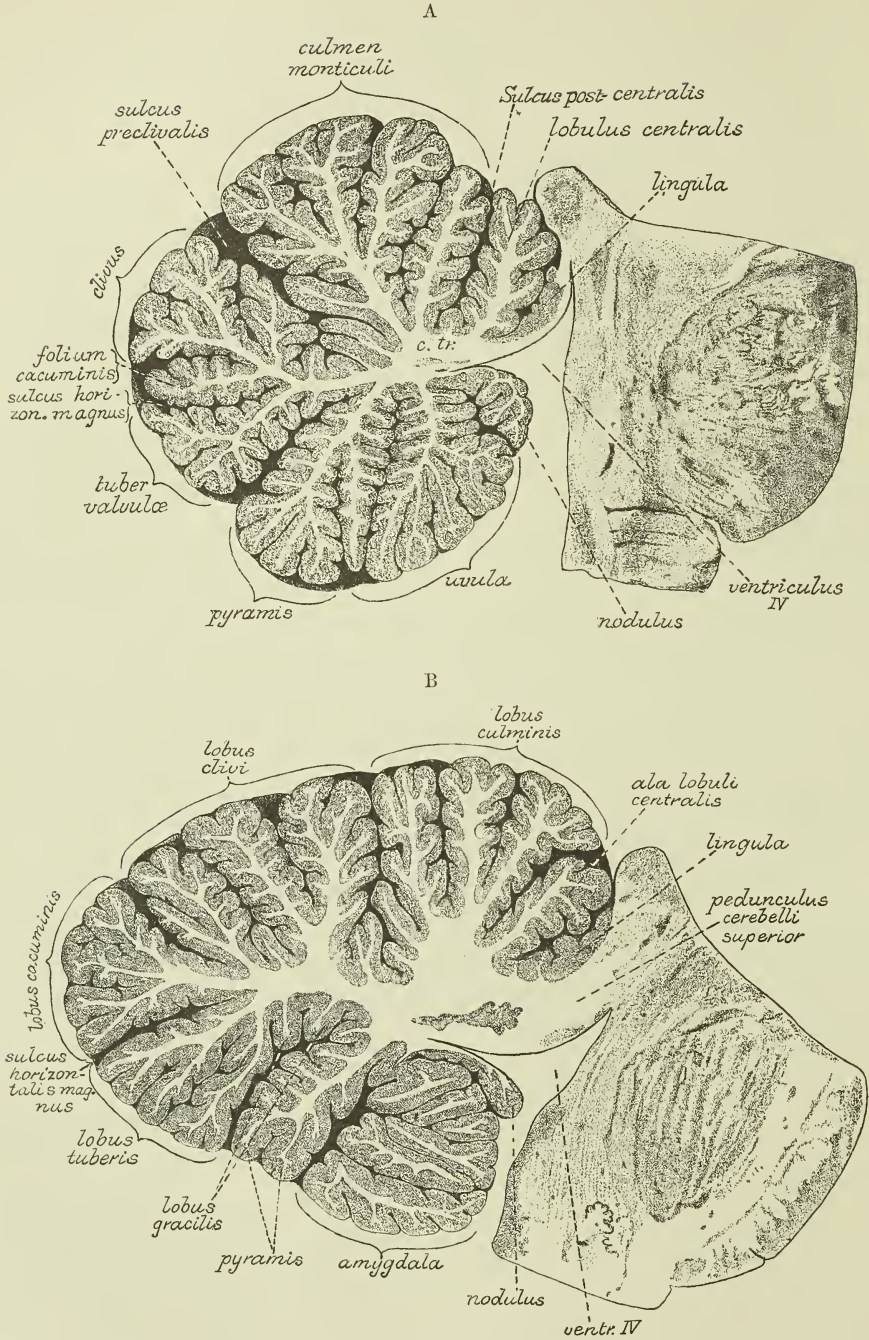
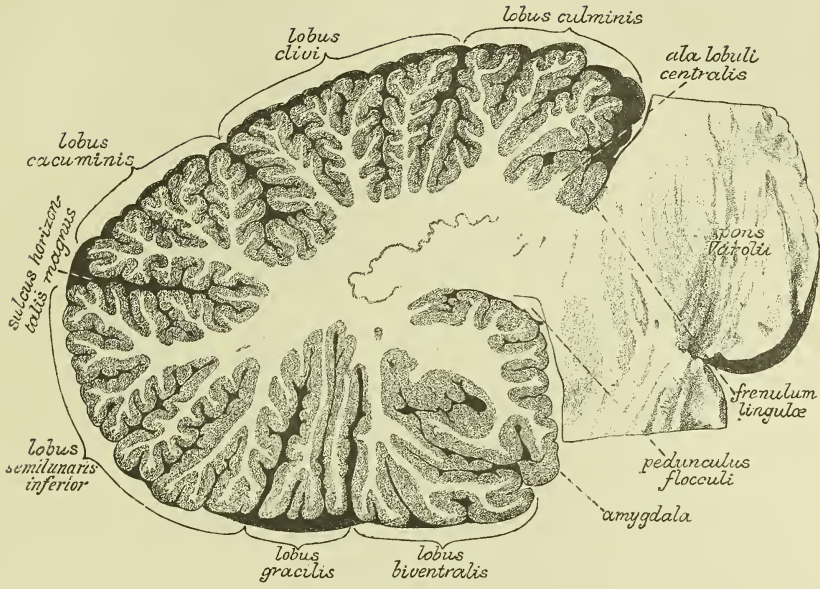


Fig. 59.—FOUR SUCCESSIVE SAGITTAL SECTIONS OF THE CEREBELLUM TO SHOW ITS INTERNAL STRUCTURE, THE RELATIVE DEPTH OF THE FISSURES, AND THE GROUPING OF THE LAMINÆ. (E. A. S.) Nearly twice the natural size. (From photographs.)

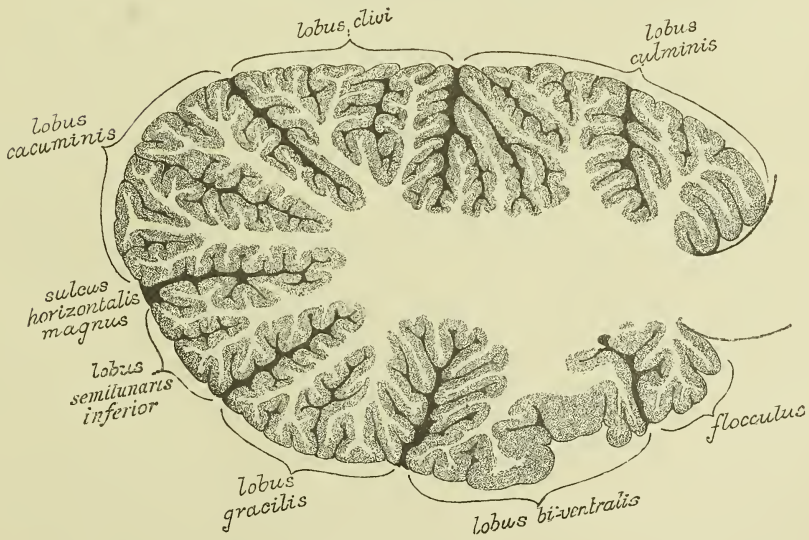
- A, median section of the worm.
- B, section near the edge of the worm at the transition into the hemisphere.
- C, at the edge of the hemisphere.
- D, through the middle of the hemisphere.



C



D





five divisions (irrespective of the white matter of the lingula and nodule), viz., two ascending (central lobe and culmen), a posterior group (clivus, folium cacuminis, and tuber valvulæ), and two descending (pyramid and uvula).

2. *Arbor vitæ at transition of worm into hemisphere* (fig. 59 B). With the general enlargement of the organ as the worm passes into the hemisphere the white centre becomes greatly increased in amount. This affects all parts of it, but first and most markedly the corpus trapezoides and the root of the branch into the culmen, which is here a large square mass of white matter from which three distinct branches pass towards the upper surface of the culmen, which is subdivided by two deep fissures (anterior and posterior intraculminate) into as many parts. A short branch also passes forwards from the corpus trapezoides into the ala lobuli centralis. The lingula is still seen in this section, and the superior medullary velum is becoming thickened by the fibres of the superior cerebellar peduncle. The horizontal stem of the arbor vitæ is also much thicker, and from it the branches of the clivus pass upwards as two main stems, which go towards the surface, bifurcating as they approach it; there are concealed folia in the pre- and post-clival fissures. The postclival fissure is now deep, as is also the great horizontal, and between the two a lobe, fan-shaped in section (the postero-superior), is now visible, having a distinct large bifid branch of the arbor vitæ directed upwards and backwards into it, each ramus dividing more than once before reaching the surface. Between the great horizontal and the postpyramidal fissure a large branch passes downwards and backwards, and gives off several well-marked rami from its lower border, three or more reaching the surface. The branch into the pyramid is broader at its root; in fig. 59 B, the section passes outside the uvula, and has taken a slice off the amygdala.

3. *In a sagittal section altogether beyond the vermis and just within the limit of the hemisphere*, what in the worm constitutes the horizontal stem of the arbor vitæ, has become greatly enlarged, and has now blended with the enlarged corpus trapezoides to form the large central white mass of the hemisphere (fig. 59 C). In this the nucleus dentatus is now seen, and appears as a thin irregularly triangular wavy band of grey matter, with the blunt apex of the triangle directed posteriorly towards the horizontal fissure and the open base looking forwards and receiving the great mass of fibres of the superior cerebellar peduncle which now replaces the superior medullary velum. Above the level of the horizontal fissure seven or eight principal processes of the white centre extend into the lobes of the upper surface: the most anterior is small, and passes forwards into the diminishing ala lobuli centralis; three enter the anterior crescentic lobe (in the section here figured they still appear to come off from a common stalk); two or three, the posterior crescentic; and a large branch directed obliquely upwards and backwards passes into the postero-superior or cacuminate lobe: between these principal branches are a few rudimentary ones passing into concealed lamellæ, of which there are groups at the bottom of the pre- and postclival fissures. Besides the postcentral and the pre- and postclival fissures, two other fissures divide the anterior crescentic lobe into three parts, and other fissures divide the posterior crescentic. The cacuminate lobe is not thus subdivided by complete fissures.

Below the level of the great horizontal fissure six or seven main branches come off from the white centre. Two of these pass into the inferior semilunar lobe; one, the posterior, being very large and bifid or trifid; one passes into each division of the lobus gracilis, one into the biventral lobe, and a broad anteriorly directed branch into the amygdala. A seventh small offshoot, directed almost due forward, belongs to the stalk of the flocculus. In sections still further outwards (fig. 59 D) the conditions are much the same as here described, except that the ala lobuli centralis, and the amygdaloid branch are no longer seen, and the branch into the

biventral has become distinctly bifid. The nucleus dentatus does not extend far into the lateral part of the hemisphere, and the superior cerebellar peduncle is no longer cut; but fibres are seen streaming from the white centre of the hemisphere into the middle and inferior peduncles. The general conformation of the section is somewhat altered, but the number and relations of the sub-divisions of the hemisphere is not materially different, and the several branches of the arbor vitae and the more important fissures are readily recognizable.

**Nuclei in the white matter of the cerebellum.**—The **dentate nucleus** (corpus ciliare, corpus dentatum) of the cerebellum (figs. 59 C, and 60, *n.d.*), very

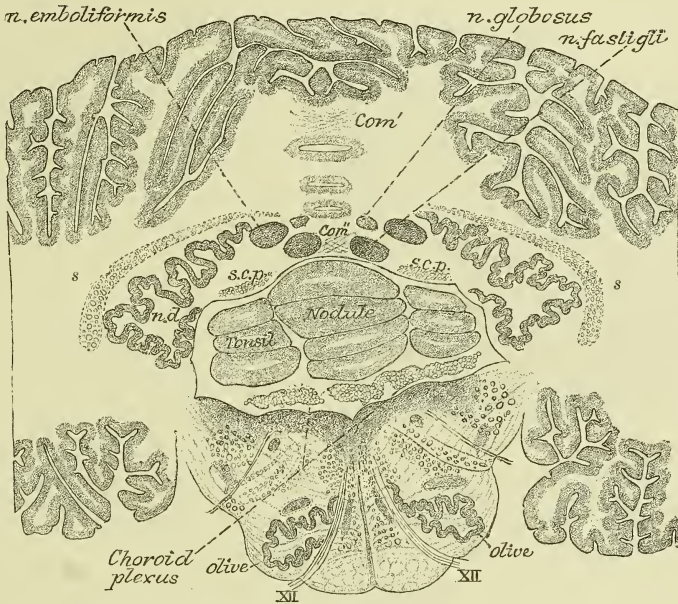

Fig. 60.—SECTION ACROSS THE CEREBELLUM AND MEDULLA OBLONGATA SHOWING THE POSITION OF THE NUCLEI IN THE MEDULLARY CENTRE OF THE CEREBELLUM. (Stilling.)  $\frac{2}{1}$ .

*n.d.*, nucleus dentatus cerebelli; *s.*, band of fibres derived from restiform body, partly covering the dentate nucleus; *s.c.p.*, commencement of superior cerebellar peduncle; *com'*, *com''*, commissural fibres crossing in the median white matter.

similar to that already described in the olivary body of the medulla oblongata, presents the appearance of a wavy line of compact yellowish brown substance, containing white matter within. The wavy character is more apparent in horizontal than in vertical sections through the hemisphere. The line is interrupted at its anterior and mesial part (*hilum*), where the superior cerebellar peduncle emerges from it. The dentate nucleus may be described as consisting of a plicated pouch or capsule of grey substance open at one part and enclosing white matter in its interior, like the dentate nucleus of the lower olivary body.

In addition to the corpus dentatum certain other portions of grey matter, which have been only more recently recognised, are found in the white centre of the cerebellum (Stilling). They are three in number on each side and are termed respectively the nucleus emboliformis, nucleus globosus, and nucleus fastigii (figs. 60, 61). The **nucleus emboliformis** is a small clavate mass of grey substance lying mesially to and partly covering the hilum of the dentate nucleus. On the inner side of the nucleus emboliformis, between it and the middle line, is a streak of grey matter passing antero-posteriorly and ending behind in an enlarged extremity. This has been named the **nucleus globosus**. Finally, close to the middle line, where



it is only separated from its fellow by a narrow septum of white matter, is a rather larger portion of grey substance, which lies in the anterior part of the white centre of the worm, and close to the upper wall of the tent-like projection in the roof of the fourth ventricle. It is termed the **nucleus of the roof** or **nucleus fastigii**.

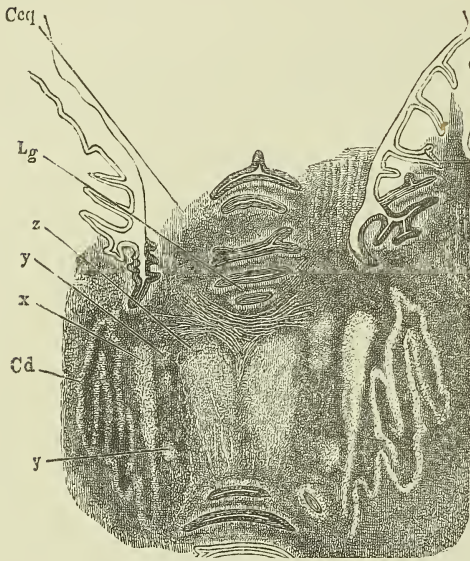


Fig. 61.—HORIZONTAL SECTION THROUGH THE WHITE CENTRE OF THE CEREBELLUM, SHOWING THE NUCLEI OF GREY MATTER. (From Henle, after Stilling.)  $\frac{3}{1}$

The section is taken just over the roof of the fourth ventricle. The nuclei are represented lighter than the white matter in which they are embedded.

C d, corpus dentatum; x, nucleus emboliformis; y, y, nucleus globosus; z, nucleus fastigii. Above the two coalesced roof-nuclei are seen some of the fibres of the superior (anterior) decussation, and above these again the laminae and furrows of the lingula (Lg); whilst below the roof-nuclei one or two laminae and furrows of the inferior verniform process are included in the section. Ccq, superior cerebellar peduncle.

These several portions of grey matter are not entirely isolated, but are connected here and there both with one another and with the dentate nucleus.

The structure of the *corpus dentatum* resembles that of the olivary body. Stellate cells  $\frac{1}{1500}$ th to  $\frac{1}{2500}$ th inch ( $6\mu$  to  $10\mu$ ) in size, lie in grey matter which is traversed by bundles of nerve-fibres, passing in various directions but chiefly from without inwards.

The *nucleus emboliformis* agrees closely in structure with the nucleus dentatus, to which it seems to bear the same relation as do the accessory olivary nuclei to the chief olivary nucleus. The *nucleus fastigii* and *nucleus globosus* differ somewhat in structure from the dentate nucleus, and chiefly in the much larger size of their cells, which, according to Meynert, are very similar to those of the nucleus of Deiters in the medulla oblongata (see p. 56).

**Commissural fibres in the white matter of the cerebellum.**—Two chief sets of *decussating commissural fibres* were described by Stilling in the middle line of the cerebellum; one at the superior part of the worm at the base of the central lobule—the *superior commissure* (fig. 60, *com'*); the other at the inferior part (*inferior commissure* (*com''*)). Commissural fibres also pierce the nuclei of the roof. In addition to these crossing fibres, which connect the two halves of the white centre, other *association fibres* connect one lamina with another, passing in the white substance of the laminae across their general direction, and arching round the fissures between the laminae.

**Peduncles of the cerebellum.**—The cerebellar peduncles are constituted by white fibres which pass out from or into the white medullary substance of the hemispheres.

The *superior peduncles* (*crura ad cerebrum*) emerge from the upper and mesial part of the medullary substance of the hemispheres, and run upwards and forwards towards the corpora quadrigemina, under which they eventually pass and thus disappear from the surface. They are situated at first at the side, but subsequently in the roof, of the upper part of the fourth ventricle. These peduncles are concealed by the upper part of the cerebellum, so that to see them properly this must be



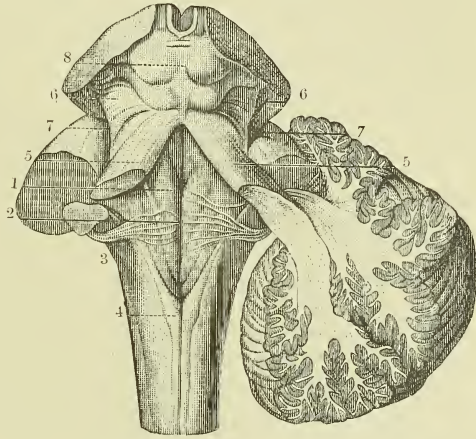
divided in the middle line and turned aside. When this is done the superior crura, with the superior medullary velum stretched out between them, are brought into view. Their further course in the mid-brain will be subsequently traced.

The fibres of the superior peduncle pass almost entirely out of the interior of the dentate nucleus (intraciliar fibres), but some fibres curve round the outer side of this without passing into it (extraciliar), and some of the mesial fibres are traceable directly into the white substance of the worm. Probably many of the fibres of these peduncles which emerge from the dentate nucleus are connected with its cells, but others pass in bundles through the grey lamina which composes it, without

Fig. 62.—FIGURE SHOWING THE THREE PAIRS OF CEREBELLAR PEDUNCLES. (From Sappey after Hirschfeld and Leveillé.)

On the left side the three cerebellar peduncles have been cut short; on the right side the hemisphere has been cut obliquely to show its connection with the superior and inferior peduncles.

1, median groove of the fourth ventricle; 2, the same groove at the place where the auditory striæ emerge from it to cross the floor of the ventricle; 3, inferior peduncle or restiform body; 4, funiculus gracilis; 5, superior peduncle; on the right side the dissection shows the superior and inferior peduncles crossing each other as they pass into the white centre of the cerebellum; 6, fillet at the side of the crura cerebri; 7, lateral grooves of the crura cerebri; 8, corpora quadrigemina.



being thus connected. They appear to go eventually to the superficial grey matter of the laminae.

From the superior medullary velum longitudinal fibres can be traced passing into the white centre of the worm. These are chiefly fibres belonging to the antero-lateral ascending cerebellar tract (see pp. 25 and 65).

Many, if not most, of the fibres of the superior peduncle originate in cells within the cerebellum, and undergo degeneration as the result of lesions of that organ (see p. 93). But in a case, reported by Mendel, of lesion of the left thalamus opticus, a well-marked bundle of degenerated fibres was traceable through the tegmentum of the left side mesial to the nucleus tegmenti, across to the right side at the decussation of the superior peduncles, and along the outer side of the right superior peduncle to the right hemisphere.

The *middle peduncles (crura ad pontem)*, distinguished by the small size of their fibres, coming from the pons Varolii, enter the lateral part of the white matter in two main bundles. One of these, composed of the superior transverse fibres of the pons which pass obliquely downwards over the others (fig. 30, *i*), radiates into the lateral and lower parts of the medullary centre of the hemispheres. The other bundle, which is formed of the lower transverse fibres of the pons, is joined at its passage into the white centre by the restiform body or inferior peduncle (fig. 30, *k*), and the fibres of both turn upwards and radiate into the upper parts of the medullary centre of the hemisphere, and partly into the upper part of the worm (but most of the pons fibres enter the hemisphere). Those peduncular fibres which pass into the worm are derived chiefly from the restiform body, and include the large fibres of the dorso-lateral cerebellar tract, most of which go to the same side but some pass across to the opposite side. Those which enter the hemisphere curve over the corpus dentatum, and are termed by Stilling the semicircular fibres (fig. 60, *s*). They come mainly from the opposite olivary through the restiform body. A small part of the fibres of the restiform body is said by Stilling to end in the corpus dentatum.

The fibres of the middle peduncle, when traced ventralwards into the pons, reach the middle line and there undergo decussation. After this intercrossing many of their fibres appear to end in the grey matter which is so abundant in the ventral part of the pons (nuclei pontis, fig. 49, *n.p.*). A certain number of fibres, however, take a sagittal direction in the raphe and pass towards the reticular formation, where they appear to give fibres to the posterior longitudinal bundle; by which means a direct connection seems to be established between the cerebellum and the nuclei of the third, fourth, and sixth nerves (Mingazzini).

The *inferior peduncles (crura ad medullam)* issue from the white matter of the lateral hemispheres, between the other two, and pass forwards immediately outside the superior peduncles to reach the lateral wall of the fourth ventricle. Here they turn sharply downwards, at a right angle, and become the restiform bodies of the medulla oblongata.

The restiform body consists of several sets of fibres having a distinct origin, and obtaining their medullary sheath at different periods of development. These fibres are as follows:—(1) Fibres of small size derived from the contra-lateral lower olives. These, which are the last to become medullated, are seen passing as arched fibres through the corresponding half of the medulla oblongata and across the raphe to enter the hilum of the opposite olivary nucleus. After passing through the band of grey matter, whether joining its cells or not is not certainly known, these fibres appear to pass longitudinally upwards in the reticular formation of the medulla oblongata and pons, and in the tegmentum of the cerebral peduncle, and thus to reach the cerebral hemisphere without again crossing: ultimately they are in all probability connected with the cerebral cortex (? of the psychomotor region only). The existence of this connection may probably explain those cases in which atrophy of one of the cerebral hemispheres, especially of the psychomotor region, has been found associated with atrophy of the inferior olive of the same side and of the restiform body and cerebellar hemisphere of the opposite side.

(2) Fibres which emerge from the adjacent cuneate nucleus (especially its outer portion), and perhaps also from the gracile nucleus, and pass directly into the restiform body of the same side. These fibres may represent a bulbar ascending cerebellar tract homologous with the dorso-lateral cerebellar tract of Flechsig which is seen in the spinal cord, in which case the outer cuneate nucleus may very probably represent Clarke's cell-column of the cord.

According to some authorities, the restiform body also receives a contribution through the arched fibres from the contra-lateral nucleus gracilis and nucleus cuneatus.

(3) Fibres of the dorso-lateral ascending cerebellar tract of Flechsig, which are traceable along the whole length of the cord from the lumbar region upwards, and which pass into the restiform body, and through this mainly into the same side of the worm.

(4) Fibres of the descending cerebellar tract (see p. 25) which, after removal of the cerebellar hemisphere, undergo degeneration down the whole length of the antero-lateral column of the cord near its periphery (see p. 32, and fig. 71, A, B, C).

(5) Fibres which are passing to or are derived from the root of the auditory nerve and perhaps others to or from some of the other cranial nerves (see p. 93).

#### MICROSCOPIC STRUCTURE OF THE LAMINÆ.<sup>1</sup>

Each lamina of the cerebellum has a central part or core of white substance which is an offshoot (secondary or tertiary) from the white centre of the organ,

<sup>1</sup> Our knowledge of the actual relationship of cells and nerve-fibres in the cerebellar cortex has been only quite recently entirely remodelled, owing to the introduction of the method invented by Golgi, and its fruitful application firstly by Golgi himself and subsequently by Ramón y Cajal.



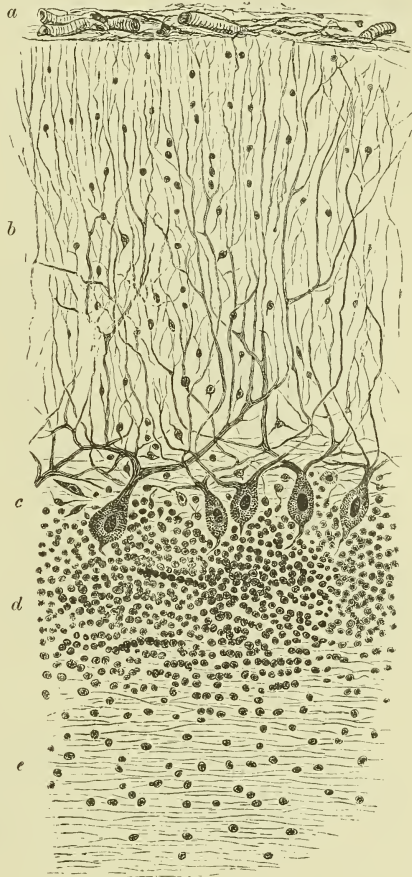
and a cortex of grey matter consisting of two layers, an inner and outer, the latter being covered superficially by pia mater. Between the inner and outer layers of grey matter is an incomplete stratum of large nerve-cells, the *corpuscles of Purkinje*. The fibres of the white matter are medullated, and are disposed in bundles which have a parallel course as they pass from the principal offshoots of the white centre

Fig. 63.—SECTION OF CORTEX OF CEREBELLUM.  
(Sankey.)

*a*, pia mater; *b*, external layer; *c*, layer of corpuscles of Purkinje; *d*, inner or granule layer; *e*, medullary centre.

of the organ into the secondary laminæ. This parallelism is maintained in their passage through the centre of the laminæ, but the fibres gradually turn off obliquely into the grey matter, so that the white core gradually thins off towards the extremities of the laminæ. Owing to the turning outwards and passage into the grey matter of these bundles of white fibres, the white core is not sharply marked off under the microscope from the grey cortex; but it is more distinctly marked off at the bottom of the fissures which separate the laminæ than in the laminæ themselves. As the fibres pass radially into the grey matter they lose their parallel arrangement, and tend to branch amongst the small nerve-cells of the adjacent inner layer of the grey matter; many pass through this and end in the axis-cylinder processes of the cells of Purkinje, whilst others pass beyond these cells into the outer or "molecular" layer of the grey matter.

The grey matter of the cerebellar cortex is disposed, as already intimated, in two distinct layers. The *inner* or *granule layer* is so called because it contains numerous small nerve-cells known as "granules:" this layer has a reddish or yellowish-brown colour in the fresh condition, hence it is sometimes termed the "rust-coloured" layer. The granules are more closely packed in the outer part of the layer; near the medullary centre of the lamina they are separated by the entering bundles of white fibres, between which they may penetrate for some distance within the white centre. Besides small nerve-cells the granule-layer includes a few glia-cells. The *outer* or *molecular layer* has, under the microscope, a finely punctated (molecular) appearance. It is of fairly uniform thickness, whereas the granule-layer is thicker near the extremities of the laminæ than in the furrows. It contains nerve-cells, but they are neither so numerous nor so small as the "granules" of the inner layer, many nerve-fibres, mostly running parallel to the surface, and also a number of fibres which run vertically to the surface (*Bergmann's fibres*), and end below the pia mater. These fibres are derived from cells which are situated in the granule-layer, and which are usually regarded as glia-cells (see p. 92).





The molecular layer is further in large part occupied by the dendritic protoplasmic processes of the large nerve-cells which lie at the junction of the granule and medullary layers, already mentioned as the *cells* or *corpuscles of Purkinje*. These are conspicuous flask-shaped cells, each with a number of ramified protoplasmic processes directed peripherally, and an axis-cylinder or nerve-process which passes centrally into the granule-layer, where it becomes medullated, and passes directly into a nerve-fibre of the medullary centre. As with the axis-cylinder processes of

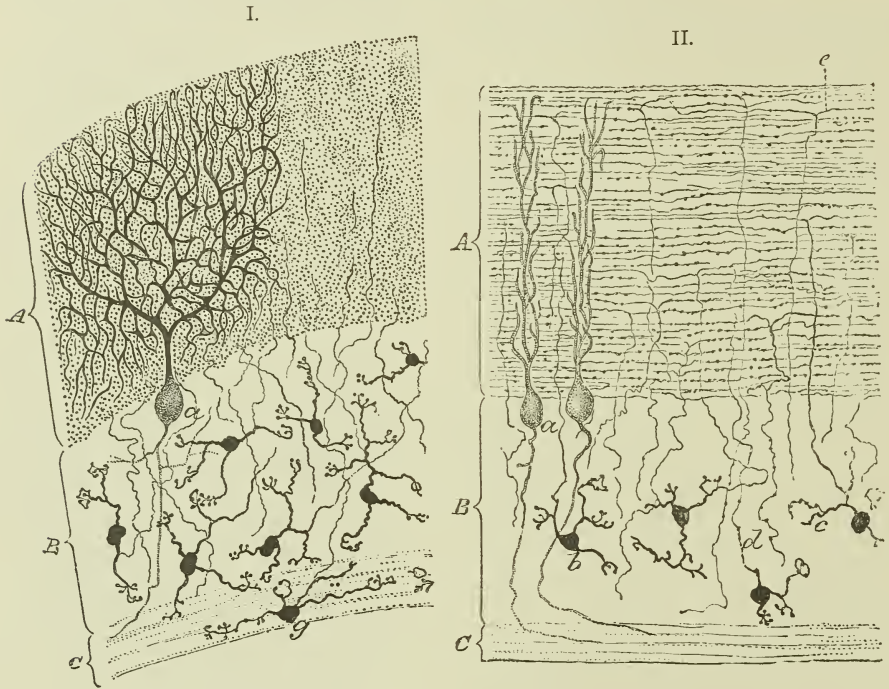


Fig. 64.—SECTIONS OF CORTEX CEREBELLI STAINED BY GOLGI'S METHOD. (Ramón y Cajal.)

I.—Section taken across the lamina.

II.—Section made in the direction of the lamina.

A, outer or molecular layer; B, inner or granule layer; C, medullary centre.

a, corpuscle of Purkinje; b, small granules of inner layer; c, a protoplasmic process of a granule; d, nerve-fibre process of a granule passing into the molecular layer, where it bifurcates and becomes a longitudinal fibre (in I. these longitudinal fibres are cut across and appear as dots); e, bifurcation of another fibre; g, a granule lying in the white centre.

the cells of the cerebral cortex, and, according to Golgi, with those of the anterior horn-cells of the spinal cord, these axis-cylinder processes of Purkinje's cells also give off lateral ramuscles (collaterals) which lose themselves amongst the granules, some turning backwards to enter the molecular layer (figs. 69, 70). The protoplasmic processes of the cells of Purkinje are spread out in planes which run transversely to the laminae (Stilling), so that they are seen in their full extent only in sections cut vertically to the surface but across the laminae (fig. 64, I.); whereas in vertical sections taken parallel to the laminae, the ramifications appear limited to a comparatively narrowed tract (fig. 64, II.). The protoplasmic processes (dendrites) may arise by a single root or by two roots; in either case there is a frequent dichotomous division, with slight enlargements at the points of division, and also the giving off laterally of numerous ramuscles which take a more horizontal course in the molecular layer than do the principal branches. The branches do not anastomose nor

join with those of other cells, but have free terminations, often curling back for a short distance before ultimately ending.

Besides these dendritic processes of Purkinje's cells, the molecular layer contains great numbers of very fine horizontal fibres, running longitudinally as regards the laminæ. These pass into the molecular layer from the small cells of the granule layer. The axis-cylinder processes of the small "granules" in fact pass vertically between the corpuscles of Purkinje and enter the molecular layer, where they join, by a T- or Y-shaped junction, with one of the horizontal fibres just mentioned (fig. 64, II.); these fibres may therefore be regarded as the branches of the axis-cylinder processes of the granule-cells. They appear to end after a short course either simply or by slightly ramifying. They are probably not medullated.

The nerve-cells of the molecular layer are divisible, according to their relative position in the layer, into two kinds, outer and inner. The outer cells, *i.e.*, those

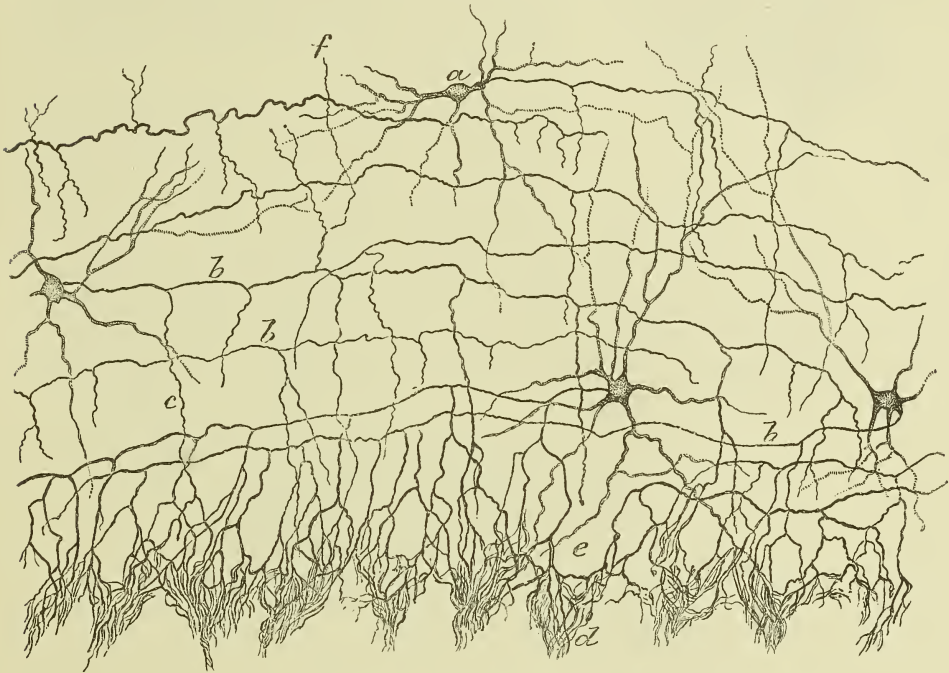


Fig. 65.—CELLS OF THE MOLECULAR LAYER OF THE CEREBELLUM. (Ramón y Cajal.)

*a*, a cell from the outer part of the layer with a horizontally directed branched axis-cylinder process; *b*, nerve-fibre processes of cells which send processes *c* to aid in forming the basket-work *d e* around the cells of Purkinje; *f*, a process directed towards the surface of the lamina.

in the outer half or so of the layer, somewhat smaller than the inner, have extensive protoplasmic processes and an axis-cylinder process which extends for some distance horizontally or obliquely in the layer, ramifying freely (fig. 65, *a*); its mode of ending is somewhat doubtful. The inner cells, called also "basket"-cells, usually lie near the cells of Purkinje, but they may be placed some little distance within the molecular layer. Their protoplasmic processes pass in all directions, some of them even reaching the surface of the organ; the axis-cylinder process, which seems not to be provided with a medullary sheath, usually emerges from the side of the cell and extends laterally for some distance, giving off at intervals, as it passes along, a number of vertical branches which pass inwards towards the cell-bodies of Purkinje's corpuscles, near which they become considerably enlarged (fig. 65, *b*, *c*). Having

reached these they break up into a close feltwork of filaments (terminal ramification) which surrounds the corpuscles of Purkinje, and with similar ramifications from other cells, envelopes the corpuscle in a sort of basket-work of nerve-filaments. This basket-work extends even for a short distance along the axis-cylinder process of the corpuscle (fig. 66).

The "granules" of the inner, or rust-coloured, layer of the grey matter are mostly small nerve-cells, nearly spherical, and provided with several small protoplasmic processes, which soon end in close bunch-like terminal ramifications within the layer (fig. 64, *b*). But the axis-cylinder process is of far greater extent, and taking a peripheral course, passes vertically beyond the corpuscles of Purkinje for

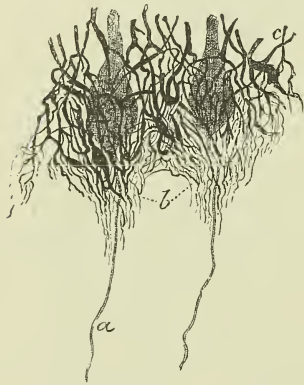

Fig. 66.—BASKET-WORK OF FIBRES AROUND TWO CELLS OF PURKINJE. (Ramón y Cajal.)

*a*, axis-cylinder or nerve-fibre process of one of the corpuscles of Purkinje ; *b*, fibres prolonged over the beginning of the axis-cylinder process ; *c*, branches of the nerve-fiber processes of cells of the molecular layer, felted together around the bodies of the corpuscles of Purkinje.

a variable distance into the molecular layer, where it becomes connected with the horizontal fibres of that layer (fig. 64, *e*) in the manner before described.

A few of the "granules" are larger ; their cell-bodies lie chiefly in the outer part of the granule-layer, near the cells of Purkinje. They are somewhat stellate, and have long, ramified, protoplasmic processes ; these may penetrate both into the white centre of the lamina, and into the molecular layer. Their axis-cylinder processes are singularly branched, losing themselves in a ramification which may extend

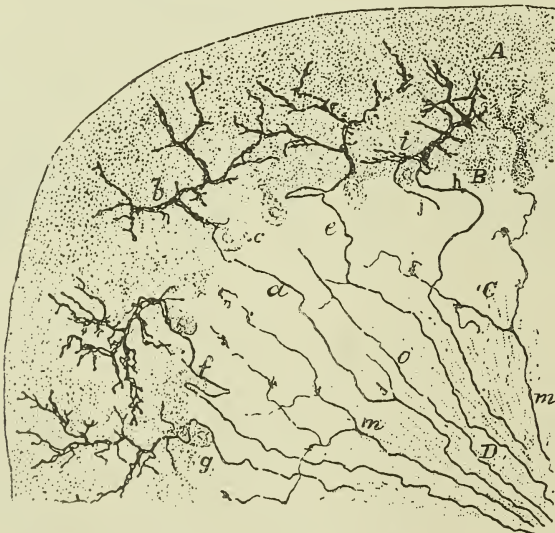

Fig. 67.—TRANSVERSE SECTION OF A CEREBELLAR LAMELLA OF THE ADULT RAT SHOWING THE FIBRES WHICH PASS FROM THE WHITE CENTRE TO THE GREY MATTER. (Ramón y Cajal.)

A, molecular layer ; B, cells of Purkinje ; C, granule-layer ; D, white substance.  
*a*, *c*, *f*, *g*, fibres which end in plexuses enveloping the principal protoplasmic processes of the cells of Purkinje ; *b*, an enveloping plexus ; *c*, body of cell of Purkinje ; *m*, "moss" fibres.

throughout the whole thickness of the granule-layer ; it is not certainly known if they are medullated, nor if they are connected with fibres of the white centre.



Of the fibres which pass from the white centre into the grey matter of the laminæ some, which have already been described, are the nerve-processes of the cells of Purkinje. But others are derived from the medullated fibres of the white centre, which appear to have two modes of termination in the grey matter. Some of these white fibres traverse the granule-layer, and, branching within that layer, exhibit peculiar moss-like appendages, both on their ramuscles and at the place whence these come off; they have on this account been termed by Ramón y Cajal the "moss-fibres" (fig. 67, *m*). Each such fibre, with its ramifications, extends over a considerable area of the granule-layer, but the branching and moss-like efflorescences are especially well marked near the level of the cells of Purkinje, beyond which they pass into the molecular layer, where they appear to become longitudinal and horizontal, whilst breaking up yet again into fresh branches.

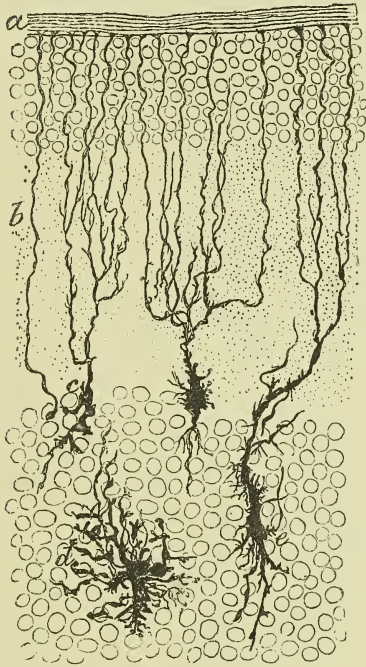


Fig. 68.—SECTION OF CEREBELLAR LAMINA OF A 15-DAY KITTEN, SHOWING SOME OF THE NEUROGLIA ELEMENTS. GOLGI'S METHOD. (Ramón y Cajal.)

*a*, pia mater; *b*, processes of the neuroglia-cells passing towards the surface where they end in conical enlargements; *c, e*, elongated neuroglia-cells; *d*, stellate neuroglia-cell.

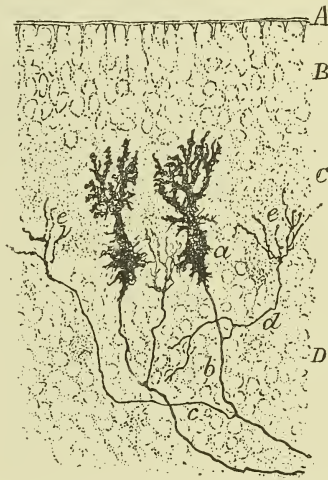

Fig. 69.—TWO CELLS OF PURKINJE FROM THE CEREBELLUM OF A NEW-BORN PUPPY, SHOWN BY GOLGI'S METHOD. (Ramón y Cajal.)

A, cuticular layer of cerebellum with insertion of radial fibres.  
 B, layer of superficial granules.  
 C, molecular layer showing the longitudinal fibres derived from the granules of the next layer D cut across and appearing as points.  
 D, granule-layer.  
*a*, bodies of Purkinje's cells, the protoplasmic processes of which are still short and very irregular.  
*b*, nerve-fibre process of one of the cells; *c, d*, two collaterals from the same fibre; *e, e, e*, their terminal arborisations in the molecular layer.

The second kind of fibre from the medullary centre (fig. 67, *a, e, f, g*, fig. 70, *j, n, o, s*), has been described by the same observer as passing towards the cells of Purkinje, and enveloping their principal dendrites in a terminal ramification, or close plexus, in the same manner that the bodies or bases of the cells and the commencement of their axis-cylinder processes are enveloped in "baskets," formed, as we have seen (p. 89), by the vertical branches of the nerve-processes of the inner cells of the

molecular layer. The cell-origin of the fibres which pass from the white centre into the grey cortex is entirely unknown, but in many cases it is probably situated in the spinal cord (see diagram, fig. 20, p. 23).

**Neuroglia-cells.**—Lying amongst the nerve-cells of the granule-layer which are nearest the cells of Purkinje, are a number of relatively large cells (fig. 68) giving off dendritic processes which are directed towards the periphery, and which course through the molecular layer as the fibres of Bergmann before mentioned. From the other side of these cells other processes pass off and become lost, partly amongst the granules, partly amongst the fibres of the white centre. These centrally-directed fibres somewhat resemble the axis-cylinder processes of nerve-cells, but the cells in question are usually regarded as glia-cells, belonging, therefore, to the supporting

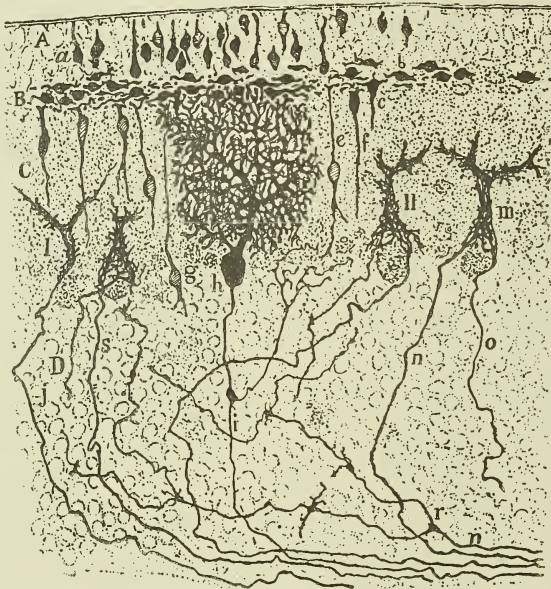


Fig. 70.—TRANSVERSE SECTION OF THE CEREBELLUM OF A 16-DAY OLD PUPPY, GOLGI'S METHOD. (Ramón y Cajal.)

A, epithelium-like layer of superficial zone; B, layer of horizontal bipolar cells; C, molecular layer; D, granule-layer.

*a*, epithelium-like cell; *b*, bipolar horizontal cell; *c*, cell sending a process downwards into the molecular layer; *e*, *f*, *g*, bipolar vertical cells; *h*, cell of Purkinje; *i*, its nerve-fibre process giving off a collateral towards the molecular layer; *j*, *n*, *o*, *s*, fibres from the white substance passing to form plexuses (*l*, *m*) which envelop the upper part of the bodies and the proximal part of the dendrites of cells of Purkinje; *r*, "moss" fibre.

tissue of the nerve-centre. The peripherally-directed fibres expand at the surface of the organ immediately underneath the pia mater into small conical enlargements, with their bases directed superficially; here they form a sort of limiting membrane similar to the internal limiting membrane of the retina, which is formed by the fibres of Müller. Although many of the neuroglia-cells have this arrangement, others, which are stellate in form, lie more deeply amongst the granules, or amongst the nerve-fibres of the medullary centre.

In the embryonic cerebellum and in most animals for a few days after birth, there is a layer of granule-like cells, several deep, superficial to the molecular layer. This has been termed by Ramón y Cajal, the zone of superficial granules, and he has shown that it is formed at a certain stage of development of two distinct strata, one the more superficial composed of epithelium-like elements set perpendicularly to the surface, and the other next to the molecular layer composed of bipolar cells placed parallel to the surface, and to the direction

of the cerebellar lamellæ (fig. 70, A, B). But the further development of these cells has not as yet been ascertained, and it can only be conjectured that they become gradually transformed into cells of the molecular layer, for no such superficial zone can be seen in the adult cerebellum. At early stages of development there are also to be seen in the molecular layer, bipolar cells placed with their axes vertical, and having protoplasmic processes extending down towards or into the rust-coloured layer, and axis-cylinder processes extending towards the surface, and becoming continued by T-shaped junctions into fibres running parallel with the processes of the horizontal bipolar cells which have just been described. These vertical bipolar cells may perhaps be derived from the horizontal ones, and represent a stage in the formation of the smaller granules of the rust-coloured layer, but we have no clear evidence as to their further course of development. Like the superficial granules they also are only found in young animals. The cells of Purkinje in the cerebellum of embryonic and very young animals are very irregular multipolar cells, with relatively short protoplasmic processes, but a well-developed axis-cylinder process, which already has two or three collateral fibres extending towards and ramifying in the deeper part of the molecular layer (fig. 69). It is not until two or three weeks after birth (in the dog) that the dendrites begin to assume the characteristic form and arrangement. The arborescence which in the adult cerebellum envelopes the principal dendrites of the cells of Purkinje (see p. 91 and fig. 67), is at this early stage chiefly confined to the upper part of the body of the cell (fig. 70).

## DEGENERATIONS FOLLOWING CEREBELLAR LESIONS.

The degenerations of nerve-fibres which follow lesions of the cerebellum have been investigated by Marchi in animals (dogs and monkeys) operated upon by Luciani.

**Hemiextirpation** (see fig. 71).—After removal of one half of the organ extensive degeneration is seen in all three peduncles of the same side; very little, if any, in the peduncles of the opposite side. It may therefore be inferred that none of the peduncles contain commissural fibres connecting the two halves of the organ.

The degenerated fibres in the *superior peduncle* pass partly to the tegmental nucleus of the opposite side, and partly to that of the same side; in other words, the decussation of these peduncles in the region of the inferior corpora quadrigemina is not complete. Some fibres can be traced as far as the optic thalamus.

The *middle peduncle*, after removal of the corresponding half of the cerebellum, is completely degenerated as far as the raphe. Degenerated fibres are seen intermingled with the pyramidal fibres both of the same side and of the opposite side, and with the fibres of the fillet and posterior longitudinal bundle, mainly of the same side. Degeneration and atrophy are also produced in the grey matter of the pons (nuclei pontis) of the same side. The degeneration in the fillet and posterior longitudinal bundle is most marked on the side of the lesion; it can be followed upwards to the region of the corpora quadrigemina, and downwards to a tract at the periphery of the antero-lateral column of the spinal cord. A bundle of degenerated fibres is also seen passing to the pyramidal tract. These appear to pass upwards towards the corpora quadrigemina, and probably to the corpus striatum, chiefly of the same side; a few are traceable downwards into the cord.

The *inferior peduncle*, after hemiextirpation of the cerebellum, is notably degenerated in its inner and outer parts. A small degenerated bundle is traceable with the inner arched fibres, across the raphe to the opposite lower olive which undergoes complete atrophy; other arched bundles pass from the restiform body to the tract of the fillet, and of the posterior longitudinal bundle of the same side; and from these, as above stated, many degenerated fibres are traceable down the periphery of the antero-lateral column of the cord, some down the pyramidal tract, but most are situated ventral to the direct cerebellar tract of Flechsig in the antero-lateral descending cerebellar tract.

It is also stated by Marchi that after hemiextirpation of the cerebellum, degenerated fibres are seen passing along with the roots of nearly all the cranial nerves, especially the second, third, fifth (ascending root), sixth, seventh, and twelfth, and



the *striae medullares*, and along with the anterior roots of the spinal nerves. These degenerated fibres are numerous on the same side as the lesion, but a few occur in the opposite nerves. Those which pass to the cranial nerves run along the posterior

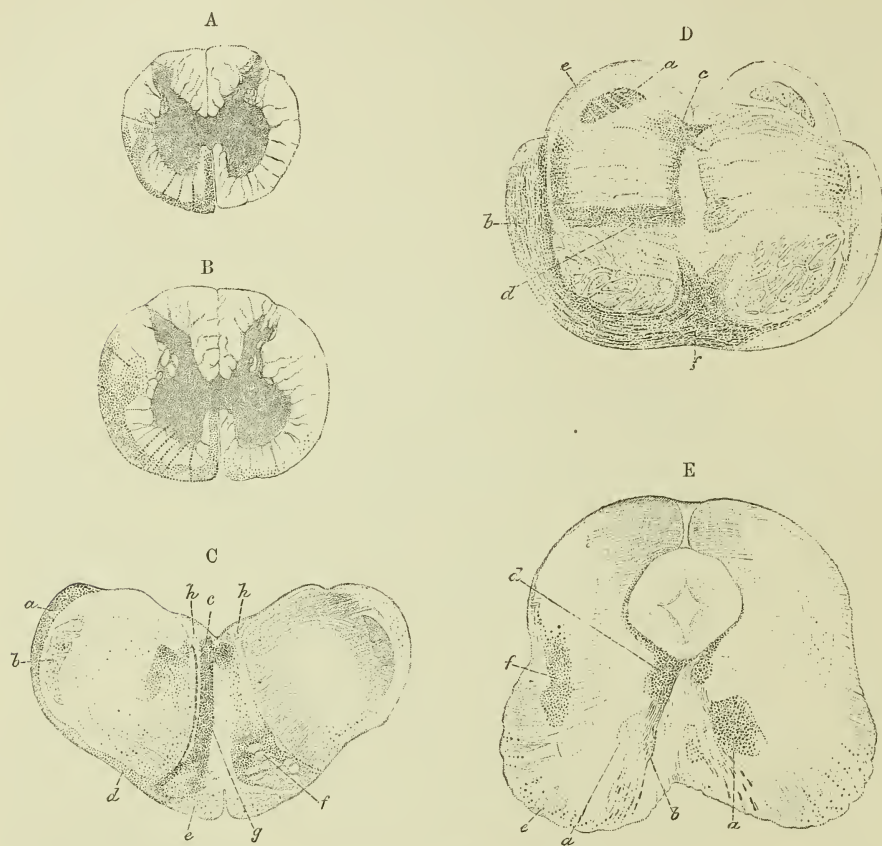


Fig. 71.—OUTLINE OF SECTIONS SHOWING THE DEGENERATIONS FOLLOWING EXTIRPATION OF THE LEFT HALF OF THE CEREBELLUM IN THE DOG. (Marchi.)

A, lumbar cord; B, cervical cord; C, medulla oblongata; D, pons Varolii; E, mid-brain at nucleus of third nerve.

In A and B, the degeneration is in the antero-lateral column of the same side as the lesion, except in B, where there is a little degeneration on the opposite side.

In C, *a* indicates the restiform body; *b*, the ascending root of the fifth; *c*, the posterior longitudinal bundle; *d*, the antero-lateral tract; *e*, the pyramids; *f*, the olivary nucleus; *g*, the fillet; *h*, the hypoglossal nucleus.

In D, *a* is the superior cerebellar peduncle; *b*, the middle peduncle; *c*, the posterior longitudinal bundle; *d*, the fillet; *e*, the antero-lateral tract; *f*, the raphe.

In E, *a* is the nucleus tegmenti (most degeneration in the crossed superior cerebellar peduncle); *b*, the issuing fibres of the third nerve; *d*, the posterior longitudinal bundle; *e*, the crusta; *f*, part of the fillet.

longitudinal bundle, those which pass to the spinal nerves down the descending antero-lateral tract of the cord.

**Extirpation of worm.**—After hemi-extirpation of the middle lobe only of the cerebellum the degeneration in the superior peduncle is comparatively slight, and entirely crosses at the decussation to pass to the tegmental nucleus of the opposite side. The degeneration of the middle peduncle is most marked in the upper third of the pons; but little occurring in the lower two-thirds.

That of the inferior peduncle is limited to the outer or lateral part of the restiform body. A few fibres pass from this across the raphe to the lower olive of the opposite side. Others pass as arched fibres to the tract of the fillet, to the posterior longitudinal bundle, and through this to the cranial nerve-roots, especially the third, fifth, eighth, and twelfth. Others are traceable down the antero-lateral columns of the cord, but those to the pyramidal tract are lacking.

RECENT LITERATURE OF THE CEREBELLUM.<sup>1</sup>

- Bechterew, W.**, *Zur Anatomie der Schenkel des Kleinhirns, insbesondere der Brückenarme*. Neurolog. Centralbl., 1885; *Ueber die Bestandtheile des vorderen Kleinhirnstiels*, Neurolog. Centralbl., 1887, and Arch. f. Anat. u. Phys., Anat. Abth., 1888.
- Beevor, Ch. E.**, *Die Kleinhirnrinde*, Arch. f. Anat. u. Physiol., 1883.
- Bellonci, G. e Stefani, A.**, *Contribuzione all' istogenesi della corteccia cerebellare*, Memoria letta all' Accademia de Ferrara, 1886: Archives italiennes de biologie, t. xi, 1889.
- Borgherini**, *Contribution à l'histologie normale du cervelet*, Archives ital. de biol., xii, 1889.
- Brosset, J.**, *Contribution à l'étude des connexions du cervelet*, Thèse, Lyon, 1890.
- Cramer, A.**, *Einseitige Kleinhirnatrophie, &c., nebst einem Beitrag z. Anatomie der Kleinhirnstiele*, Beiträge zur pathol. Anatomie, Bd. xi., 1891.
- Fusari**, *Sull' origine delle fibre nervose nello strato molecolare delle circonvoluzioni cerebellari dell' uomo*, Atti della R. accad. delle scienze di Torino, 1883.
- v. Gehuchten, A.**, *La structure des centres nerveux*, La Cellule, t. vii, 1891.
- Golgi, C.**, *Recherches sur l'histologie des centres nerveux*, Arch. ital. de biologie, t. iii. et iv., 1882.
- v. Gudden, P.**, *Ueber d. Verbindungsbahnen des Kleinhirns*, Berichte d. deutsch. Naturf.-Versammlung, 1882 (Neurol. Centralbl.).
- v. Kölliker, A.**, *Das Kleinhirn*, Zeitschr. f. wissenschaft. Zoologie, Bd. 49, 1890.
- Luciani, L.**, *Il cervelletto*, Firenze, 1891.
- Marchi, V.**, *Des dégénération consécutives à l'extirpation totale et partielle du cervelet*, Archives italiennes de biologie, t. vii, 1886.
- Mendel, E.**, *Secundäre Degeneration im Bindearm*, Neurol. Centralbl., 1882.
- Mingazzini, G.**, *Intorno al decorso d. fibre appart. al pedunculus medius cerebelli ed al corpus restiforme*, Arch. p. l. scienze mediche, 1890.
- Obersteiner, H.**, *Der feinere Bau der Kleinhirnrinde*, Biol. Centralbl., Bd. iii., 1885.
- Ramón y Cajal, S.**, *Sobre las fibras nerviosas de la capa molecular del cerebelo*, Revista trimestrial de histologia normal y patologica, 1888 and 1889; *Sur l'origine et la direction des prolongations nerveuses de la couche moléculaire du cervelet*, Internationale Monatsschr. f. Anat. u. Phys., Bd. vi, 1889; *Sur les fibres nerveuses de la couche granuleuse du cervelet et sur l'évolution des éléments cérébelleux*, Ibid., Bd. vii, 1890; *Appropos de certains éléments bipolaires du cervelet avec quelques détails nouveaux sur l'évolution des fibres cérébelleuses*, Ibid., vol. vii, 1890.
- Retzius, G.**, *Die nervösen Elemente der Kleinhirnrinde*, Biol. Untersuch. Neue Folge, iii., 1892.

<sup>1</sup> See also Literature of Medulla Oblongata and Pons Varolii.

MID-BRAIN, OR MESENCEPHALON, AND REGION OF THIRD VENTRICLE, OR THALAMENCEPHALON (INTER-BRAIN).

The parts of the brain next to be described are entirely covered by the cerebral hemispheres. They comprise the crura cerebri and corpora quadrigemina, the optic thalami with the middle commissure, and the pineal body, in addition to the following structures which are seen when the brain is removed from the skull and its under-surface or base is examined, viz. :—the posterior perforated space, the corpora albicantia, the tuber cinereum with the infundibulum and pituitary body, the optic tracts and chiasma, and the lamina cinerea. Of these the corpora quadrigemina and crura cerebri are found in connection with the aqueduct of Sylvius, and belong to the mid-brain, while the optic thalami and the other structures above enumerated occur in connection with the third ventricle, and belong to the inter-brain.

The **aqueduct of Sylvius** (iter a tertio ad quartum ventriculum) is a narrow passage into which the upper end of the fourth ventricle gradually narrows, and which in front expands abruptly into the third ventricle. It is rather more than




Fig. 72.—SECTIONS THROUGH THE ORIGIN OF THE FOURTH NERVE (Stilling).  $\frac{3}{4}$

A, transverse section at the place of emergence of the nerve-fibres. B, oblique section carried along the course of the bundles from the nucleus of origin to the place of emergence. *Aq*, Sylvian aqueduct, with its surrounding grey matter; *IV*, the nerve-bundles emerging; *IV'*, decussation of the nerves of the two sides; *IV''*, a round bundle passing downwards by the side of the aqueduct to emerge a little lower down; *n.IV*, nucleus of the fourth nerve. *l*, fillet; *s. c. p.*, superior cerebellar peduncle; *d. V.*, descending root of the fifth nerve; *pl*, posterior longitudinal bundle; *r*, raphe.

half an inch long. In shape it varies in different parts, being T-shaped in section below (near the fourth ventricle), triangular above (near the third), and in the intermediate part of an elongated oval form, but somewhat shield-shaped in the region of the superior corpora quadrigemina. It is lined by ciliated columnar epithelium, outside which is a thick layer of grey matter, continuous with that of the fourth ventricle. Outside this *central grey matter of the aqueduct*, the lateral and ventral parts (basal part) of the mesencephalon are composed of the thick masses of the cerebral peduncles (*crura cerebri*), whilst the dorsum is formed by the *lamina quadrigemina*, so called from bearing the four mamillated tubercles known as the corpora quadrigemina.

The epithelium which lines the Sylvian aqueduct is ciliated (as elsewhere in the ventricles of the brain) and the attached ends of the cells extend as radiating ependymal fibres through the thickness of the mid-brain to reach the surface—at least, this can be seen to be so in the embryo and in small vertebrates, and is probably also true for all. But some of the ependymal fibres are attached to neuroglia cells which occur at various levels in the course of the fibres; they have



probably been formed by the detachment of some of the epithelium cells. The fibres which extend from them often branch dichotomously besides possessing many small lateral offsets.

The Sylvian aqueduct expands suddenly immediately after passing beneath the posterior commissure into a comparatively large, laterally compressed cavity, termed the **third ventricle** (fig. 73). This, which is deeper in front than behind, passes at its anterior and lower extremity to a conical termination which lies over the

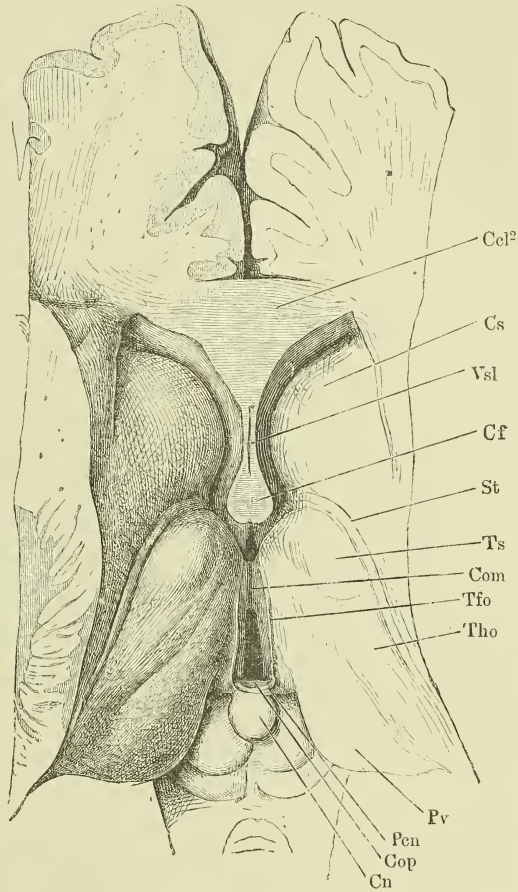
Fig. 73.—VIEW FROM ABOVE OF THE THIRD VENTRICLE AND A PART OF THE LATERAL VENTRICLES (Henle).

The brain has been sliced horizontally immediately below the corpus callosum, and the fornix and velum interpositum have been removed.

*Tho*, thalamus opticus; *Ts*, its anterior tubercle; *Pv*, pulvinar; *Com*, middle commissure stretching between the two optic thalami across the middle of the third ventricle; *Cf*, columns of the fornix; *Cn*, pineal gland projecting downwards and backwards between the superior corpora quadrigemina; *St*, stria terminalis; *Cs*, nucleus caudatus of the corpus striatum; *Vsl*, ventricle of the septum lucidum; *Ccl<sup>2</sup>*, section of the genu of the corpus callosum; *Pcn*, commencement of the pineal stria or peduncle, *Tfo*; *Cop*, posterior commissure.

optic commissure (*optic recess*). Below and behind this is a conical depression, the *infundibulum*, leading towards the *pituitary body* (*hypophysis cerebri*). At the posterior extremity, immediately above the entrance of the aqueduct, and separated from it by the posterior commissure, is another smaller depression (*pineal recess*) (fig. 90, p. 126) extending into the stalk of the *pineal gland* or *conarium* (fig. 73, *Cn*), which here projects backwards over the mid-brain. Another depression extends backwards

over the pineal stalk; this is termed the *suprapineal recess* (fig. 90). The ventricle is bounded laterally by the *optic thalami* (fig. 73, *Tho*), which come almost in contact with one another in the median plane; and a little in advance of the middle of the ventricle, are actually united by a connecting band of grey matter of variable extent, termed the *middle* or *soft commissure* (fig. 73, *Com*; fig. 83, *m.c.*). This is sometimes double and occasionally wanting: it is liable to be torn across in removing the brain. The lateral walls of the cavity are slightly convex, and each is marked towards the anterior end by a white curved band, with its convexity forwards, which becomes more prominent as it passes upwards towards the roof. These bands are named the *anterior pillars* or *columns of the fornix* (fig. 73, *Cf*). Immediately behind the most prominent part of each of these, between it and the anterior part of the thalamus, is an aperture (*foramen of Monro*) leading into the ventricle of the hemisphere (lateral ventricle.)



All along the upper curved margin of the lateral wall, from the pillar of the fornix to the pineal gland, runs a white stria, known as the *stria pinealis*, *stria medullaris*, or *tenia fornicis* (fig. 73, *Tfo*). The floor of the ventricle is formed posteriorly by the *tegmenta* of the crura cerebri, and where the crura diverge from one another by the following parts, which have been already mentioned as seen at the base of the cerebrum; viz., commencing from behind, the grey matter of the *posterior perforated space*, the *corpora albicantia*, seu *mamillaria*, the *tuber cinereum* and *infundibulum*; the *lamina cinerea* serves to close the ventricle in front. The roof of the cavity is limited before and behind by two *commissures*, named from their position, *anterior* and *posterior*. Of these the anterior will be described with the cerebral hemispheres.

The third ventricle is lined, like the other cavities already described, by ciliated epithelium, which is thin and flattened over the roof, *i.e.*, lining the velum and choroid plexuses, but longer and more columnar at the bottom and sides. The floor, which is narrow, is formed, underneath the epithelium, of grey matter continuous with that of the Sylvian aqueduct, and this central grey matter extends a short distance upwards on the wall of the thalamus. The central grey substance rests behind upon the still conjoined part of the tegmenta; but anteriorly, after these have diverged, it comes to the surface at the base of the brain as the posterior perforated lamina and the tuber cinereum. The lateral walls of the ventricle have but a thin covering of neuroglia (ependyma) underneath the lining epithelium; so that the white covering (stratum zonale) of the thalami comes to view through it.

The epithelial covering of the roof of the ventricle is not free but covers the under surface of the median portion of an expansion of pia mater named the *velum interpositum*, which overlies the third ventricle as well as the larger part of the optic thalami. The epithelium follows all the inequalities of two fringed vascular tracts (*choroid plexuses* of the third ventricle) which project downward from the membrane, and it becomes torn away when the pia mater is removed. At the pineal stria (fig. 73, *Tfo*) on either side it is continuous with the epithelium covering the lateral wall. This stria therefore represents the limit of the third ventricle so far as the lateral boundaries of the roof are concerned: the upper surface of each optic thalamus is excluded from this cavity.

The **central grey matter of the aqueduct** (fig. 76, *c. gr.*) is a layer 2 to 3 millimeters thick which surrounds the aqueduct, and is prolonged from the grey matter of the fourth ventricle. It contains, scattered through its substance, nerve-cells of varying size, the largest being prolonged upwards from the locus ceruleus of the fourth ventricle; the cells are very numerous and small at the dorsal side of the aqueduct. In addition to these scattered cells the grey matter of the aqueduct contains certain more defined groups or columns of cells which are connected with the roots of the third and fourth, and of the fifth cranial nerves. Amongst the cells there is a network of fine medullated nerve fibres, whilst near the aqueduct and immediately under the ependymal layer many fine longitudinal fibres are seen.

The **nuclei of the third and fourth nerves** (fig. 76, *n. III., IV.*) extend on either side along almost the whole length of the ventral part of the aqueduct, close to the middle line, the nuclei of the two sides being only separated from one another by the raphé: at one part they even meet across this (fig. 78, *n. III.*). The cells of these nuclei are large and irregular in shape, and of a yellowish colour. The nucleus from which the root-bundles of the fourth nerve spring does not begin to show itself until the level of the upper part of the inferior corpora quadrigemina, and it here lies just below and rather to the side of that from which the bundles of the third originate. From here the bundles of the fourth pass obliquely downwards towards the pons, and just before reaching this the nerve turns sharply dorsal-wards, and passes into the superior medullary velum, in which it crosses horizontally, decussating with that of the opposite side (fig. 72).

The nucleus from which the third nerve takes origin extends upwards underneath the superior corpora quadrigemina, ventral to the Sylvian aqueduct, and even extends into a corresponding situation in the posterior part of the third ventricle. The anterior (superior) part is composed of smaller cells than the other portion: it extends forwards into the wall of the third ventricle, and from the experiments of Hensen and Voelckers and the observations of Starr, it appears to be subdivided into two portions, of which that which is the more mesial, and lies just above the corpora mamillaria, is connected with the fibres of the third nerve to the ciliary muscle, whilst that which is the more lateral is connected with the fibres concerned with the contraction of the sphincter pupillæ. The main part of the oculomotor nucleus is formed by large cells, which tend to be grouped (see diagram, fig. 74). Thus, there are two distinct groups on each side which are dorso-lateral (*dorsal nuclei*), and two which are ventro-mesial (*ventral nuclei*). These four nuclei are grouped around a *central nucleus* which lies in the middle line. Besides these, there is an elongated nucleus of small cells which inferiorly (caudalwards) lies in close contact with the central nucleus but superiorly curves outwards. This is known as the *nucleus of Edinger and Westphal*, but it is uncertain whether it gives origin to any fibres of the third nerve. It has not been certainly ascertained from which of the several groups the fibres to particular muscles moving the globe of the eye proceed. From the several groups of cells which constitute the oculomotor nucleus the fibres of the third nerve pass with a curved course through the tegmentum, to emerge at the inner margin of the crusta of the same side; but the fibres from the posterior of the dorsal groups undergo decussation. These fibres are believed to pass to the internal rectus of the opposite side.

In a case recorded by Kahler and Pick, in which there was paralysis of the levator palpebræ, the rectus superior and the obliquus inferior, a lesion was found involving the postero-lateral bundle of the nerve-roots. The observations of Starr point to these three muscles being innervated from the dorsal (dorso-lateral) groups, and the rectus internus and rectus inferior from the ventral (ventro-mesial) groups, in the order here given (from above down).

It has been shown by Duval and Laborde that the third nerve receives fibres from the mesial part of the posterior longitudinal bundle of the opposite side (possibly some fibres also pass to it from the posterior longitudinal bundle of the same side). These fibres are derived mainly from the nucleus of the sixth nerve, and pass out along with the fibres of the third nerve to the internal rectus, so that the nucleus of the sixth thus supplies both the external rectus of the same side entirely, and the internal rectus of the opposite side partially (fibres derived from the nucleus of the third also going to the internal rectus). These are, it may be noted, the muscles which are brought together into action in conjugate deviation of the eyes to either

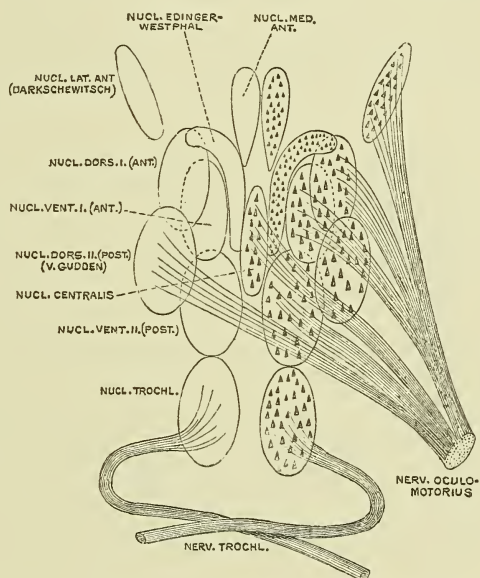


Fig. 74.—DIAGRAM OF THE GROUPS OF CELLS FORMING THE NUCLEI OF THE THIRD AND FOURTH NERVES. (Perlia.)



side, and the cases which are sometimes met with of conjugate paralysis involving the internal rectus of one side, and the external rectus of the other side, which are accompanied by atrophy of the nucleus of the sixth, are thus accounted for.

The prolongation of the **upper nucleus of the fifth nerve** consists of a small number of large globose cells (figs. 75, 76, *d.V.*), which lie at the extreme lateral margin of the grey matter of the aqueduct close to the bundles of the descending root of the fifth nerve, towards which their axis-cylinder processes are directed. This nucleus and root gradually become smaller, and disappear before the superior end of the mesencephalon is reached.

The **crura cerebri** (fig. 32, *P*) emerge from the upper border of the pons and diverge from one another, leaving between them the posterior perforated space and the corpora mamillaria and disappearing in the cerebral hemispheres under the optic tract. The triangular interval seen at the base of the brain to be enclosed between the diverging crura has been termed *trigonum interpedunculare* by Schwalbe. Near the point of the angle of divergence the roots of the third nerve issue in several bundles from a groove along their inner side (fig. 32, *III.*); and this groove serves to indicate the separation between the more prominent ventral part of the peduncle (*pes s. basis s. crusta pedunculi*, fig. 75, *cr.*) and the dorsal and larger part (*tegmentum, t.*) which is in great measure concealed from view by

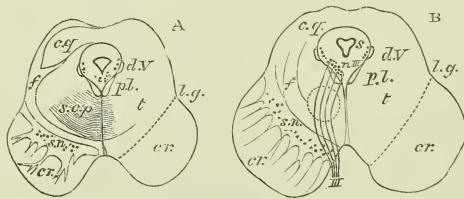


Fig. 75.—OUTLINE OF TWO SECTIONS ACROSS THE MESENCEPHALON. Natural size. (E. A. S.)

A, through the inferior pair of the corpora quadrigemina : B, through the superior pair.

*cr.*, crusta ; *s.n.*, substantia nigra ; *t.*, tegmentum ; *s.*, Sylvian aqueduct with the central grey matter ; *c.g.*, grey matter of quadrigeminal bodies ; *l.g.*, lateral groove ; *p.l.*, posterior longitudinal bundle ; *d.V.*, descending

root of fifth nerve ; *s.c.p.*, superior cerebellar peduncle ; *f.*, fillet. The dotted circle in B indicates the tegmental nucleus.

the pes when viewed from below and in front. A section into the crus cerebri shows the two parts of which it is composed to be separated from one another by a tract of dark coloured grey substance known as the *substantia nigra* (fig. 75, *sn*), which comes to the surface on the inner side at the groove above mentioned from which the third nerve issues (*sulcus oculomotorii*), and on the outer side also along a grooved line—the *sulcus lateralis* (fig. 75, *l.g.*).

Of the two main parts of each peduncle the *crusta* (*cr*) is formed almost entirely of lamellated bundles of longitudinal fibres, some of which are continuous with the pyramid-fibres of the medulla oblongata and pons, whilst others are superadded ; and the *tegmentum* is a continuation of the *formatio reticularis* of those parts, with the addition of much grey matter and white fibres, amongst the latter being those of the superior peduncle of the cerebellum. The two ventral portions (*crustæ* or *pedes*) are entirely distinct from one another (as shown in the accompanying sections, fig. 75), and each is marked off externally from the tegmentum of the same side by the grooves just mentioned ; but the two tegmenta are united in the median plane by a prolongation of the raphé, and extend dorsally at the sides of the aqueduct to become continuous with the bases of the corpora quadrigemina.

**Crusta.**—The crusta is semilunar in section, the substantia nigra projecting into it with an irregular convex border. It is made up of longitudinal white fibres which become arranged in the higher parts of the mid-brain into flattened bundles, with their edges dorsal and ventral, separated from one another by processes of pia mater. The main part is a direct prolongation of the longitudinal bundles of the pons and passes superiorly towards the internal capsule of the cerebral hemisphere.

Close to the substantia nigra, the bundles of white fibres are smaller and somewhat separated by projections of the grey matter extending between them. They have received the name of *stratum intermedium*. These are usually stated to have a different origin and destination from the other fibres of the crura, passing, according to Meynert, between the lenticular nucleus of the corpus striatum (see p. 131), and the substantia nigra and reticular formation of the bulb and pons. It is doubtful, however, if this is true for any of these fibres, and is certainly not the case with the majority, for (in monkeys) after a lesion of the Rolandic region, most if not all the fibres of the stratum intermedium undergo degeneration along with the fibres of the pyramidal tract, to which, therefore, they must be regarded as belonging.

The pyramidal tract of the mesencephalon, or continuation of the pyramidal-bundles of the pons, occupies about the middle third of the crura. Superiorly its fibres pass through the middle part of the internal capsule to the fronto-parietal or Rolandic region of the hemisphere. By far the majority arise from the cortical cells, but a few have their cell-origin in the cord or bulb, and degenerate after lesions of these parts.

It is remarkable that whereas in the lower part of its course (spinal cord and bulb) the fibres of the pyramidal tract acquire a medullary sheath later than the other fibres of the white columns, in the upper part (crura cerebri and cerebrum) it is acquired earlier than in the other fibres.

The outer or lateral third of the crura is formed of fibres which are traceable downwards to the lateral longitudinal bundles of the pons, and upwards to the posterior part of the internal capsule, but their origin and destination have not yet been satisfactorily made out. They are probably connected superiorly with the occipito-temporal regions of the cerebral cortex, and according to Flechsig they arise below from the cells of the nuclei pontis.

The mesially situated bundles of the crura are also distinct from the pyramidal tract proper (Flechsig), being developed at a later period. They are perhaps connected through the anterior part of the internal capsule with the prefrontal region of the hemisphere. Finally, one well-marked bundle in the crura is connected with the fillet (*mesial fillet*, pp. 66, 67, and 103). This bundle is at the lateral border of the pyramidal tract in the upper part of the crura, but lower down crosses obliquely over or between the fibres of that tract to attain the mesial border of the crura, whence it is traceable to the fillet. It contains, according to Spitzka, the afferent cerebral tracts of the cranial nerves. Traced upwards it is lost in the subthalamie region.

Lastly the crura includes some fibres derived originally from the cerebellum and joining the pyramidal tract in its passage through the pons, such fibres being scattered amongst the fibres of the other tracts.

The **substantia nigra** is a mass of grey matter which is characterised by the presence of a number of very darkly pigmented irregular nerve-cells, which give the substance in which they are scattered the appearance from which it derives its name. It forms a layer which separates the crura from the tegmentum. It is thicker near the mesial border of the peduncle than laterally, where the tract of the fillet may be but incompletely separated by it from the longitudinal bundles of the crura. It commences at the upper margin of the pons, and can be traced as far forwards as the posterior border of the corpora albicantia. At the origin of the third nerve it is traversed in its mesial part by some of the issuing fibres of the nerve-root. The grey matter of the substantia nigra projects here and there between the adjacent bundles of the crura; one considerable projection in particular in the lower part of the mesencephalon serving to mark off the mesial portion of the crura from the rest. The cells in this projection are much smaller, and relatively more numerous than in the rest of the substantia nigra.

The **tegmentum**, like the formatio reticularis of the bulb and pons, of which it is the prolongation upwards, is composed of small longitudinal bundles of white fibres, separated by transversely coursing or arched fibres, together with a considerable amount of grey matter containing scattered nerve-cells.

In addition to these diffused bundles of longitudinal fibres there are others which are collected into more defined tracts. One such tract constitutes the **posterior or dorsal longitudinal bundle**, which is seen in all sections of this part of the brain as a pyriform area of transversely cut fibres which lies on each side of the middle line between the grey matter underlying the aqueduct, and the formatio reticularis (fig. 76, *p.l.b.*). The fibres which constitute this bundle below

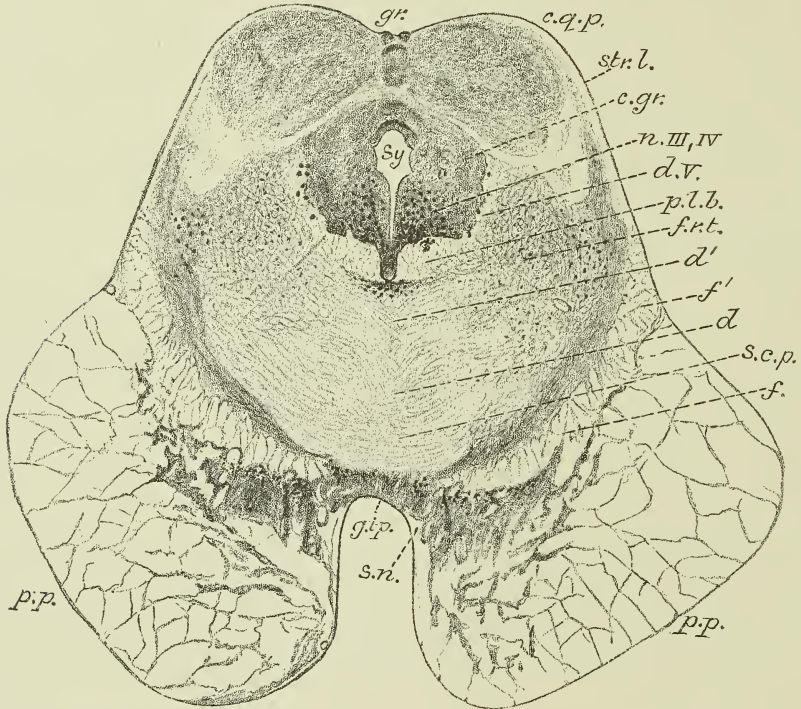

Fig. 76.—TRANSVERSE SECTION ACROSS THE MID-BRAIN, THROUGH THE INFERIOR CORPORA QUADRIGEMINA. MAGNIFIED ABOUT  $3\frac{1}{2}$  DIAMETERS. (E. A. S.) From a Photograph.

*gr.*, dorsal quadrigeminal groove (sulcus longitudinalis); *c.q.p.*, corpus quadrigeminum posterius; *str.l.*, stratum lemnisci; *c.gr.*, central grey matter; *n. III, IV*, oculo-motor nucleus; *d.V.*, descending root of fifth nerve; *p.l.b.*, posterior longitudinal bundle; *f.r.t.*, formatio reticularis tegmenti; *d, d'*, decussating fibres of tegmentum; *s.c.p.*, decussating fibres of superior cerebellar peduncles; *f*, upper fillet; *f'*, lower or lateral fillet; *p.p.*, pes pedunculi; *s.n.*, substantia nigra; *g.i.p.*, interpeduncular grey matter; *Sy*, Sylvian aqueduct.

have already been noticed (see p. 65 and figs. 53, 54); traced upwards its fibres become related to the nuclei of the third and fourth nerves, and mostly pass out with the roots of these nerves. The posterior longitudinal bundle is composed exclusively of large nerve-fibres, which acquire their myelin at an early stage, in fact, as soon as the roots of the nerves themselves. Although its fibres are large, it gives off principally fine nerve-fibres (Köppen). If this is the case they are probably collaterals. It appears to be developed in nearly all vertebrates, and in some is better marked than in mammals; *e.g.*, in the lizard it can be traced right down the cord dorsal to the anterior or ventral commissure. Although mainly related to the



sixth, fourth and third nerve-roots, fibres also pass from it to the auditory nucleus, and others to the cerebellum. After giving off fibres to the root of the third nerve the posterior longitudinal bundle is continued into the posterior commissure (see p. 109), and partly upwards into the subthalamic region (? to the substantia interansalis, see p. 112). The posterior longitudinal bundles come close together at the raphé, and fibres pass from one to the other. These are probably the fibres which effect a crossed connection between the abducens nucleus of the one side and the fibres passing to the internal rectus by the third nerve of the other side (see pp. 63 and 99). Perhaps, also, a connection is established through the posterior longitudinal bundle between the facial and the oculomotor nucleus (Mendel). The posterior longitudinal bundle is very small in the mole (Forel), large in reptiles and amphibia (Spitzka).

**Brachium conjunctivum; superior cerebellar peduncle.**—Another tract of longitudinal and decussating fibres is derived from the superior peduncle of the cerebellum, which we have already traced as it passes forwards over the superior end of the fourth ventricle. Reaching the sides of the aqueduct as a well-marked bundle, of semilunar shape in section (fig. 72, *s.c.p.*), it gradually takes a more ventral position as it is traced upwards in the mesencephalon, and its fibres soon begin to pass across the raphé, decussating with those of the other side (fig. 75 A, and fig. 76, *s.c.p.*), the decussation extending as far upwards as the superior pair of corpora quadrigemina. Having thus crossed to the opposite side the tract in question pursues its course longitudinally upwards, appearing at first as a white bundle, but higher up enclosing in its passage a tract of grey matter with numerous large pigmented cells, known as the *nucleus of the tegmentum* or *red nucleus* (fig. 75, B, and fig. 78, *r.n.*), and probably receiving an accession of fibres from these cells. Above, the tract passes into the ventral part of the optic thalamus. Some fibres do not cross, but enter the red nucleus of the same side.

Between the two red nuclei a small white bundle (*Meynert's bundle*) passes backwards on either side of the raphé from the ganglion of the habenula near the roof of the third ventricle to a small mass of grey matter which lies between the crura (*ganglion interpedunculare*, fig. 76, *g.i.p.*).

**Tract of the fillet.**—The fillet, which, in sections across the upper part of the pons, forms a considerable flattened bundle of longitudinal fibres at the ventral border of the formatio reticularis, is traceable upwards into the ventral part of the tegmentum. Soon, however, the large laterally situated part of this tract is seen to pass obliquely outwards and emerge at the side of the crus cerebri, curving obliquely over the outer side of the prolongation of the cerebellar peduncle (fig. 75, A, *f*), and tending for the most part towards the inferior corpora quadrigemina. It is seen on the surface as a band of obliquely curved fibres, occupying a triangular area at the side of the tegmentum (fig. 76, *f'*), and it was to this band that the name of fillet was originally applied by Reil. It is now known as the *lower* or *lateral fillet*. It is reinforced by fibres from the superior medullary velum which also curve round the superior cerebellar peduncle, and which are probably derived from the antero-lateral ascending tract of the cord, for they undergo degeneration after section of the cord (see below). The fillet is covered externally by a thin layer of grey matter containing nerve-cells.

But all the fibres of the tract of the fillet do not take the course above indicated. Those nearest the middle line (*mesial fillet*) separate themselves from the rest, and pass at the lower part of the mesencephalon into the crusta (see p. 101), where they form a mesial bundle (Wernicke), which is traceable up into the subthalamic region, where it joins the ansa lenticularis. Those next in order (*middle portion*) are for the most part, according to Forel, continued upwards in the formatio reticularis of the tegmentum, but many of the fibres become lost amongst its cells, and are not traceable further as a distinct tract. According to Edinger, they have a cell-

station in a special group of nerve-cells (*upper nucleus of the fillet*) at the level of the inferior corpora quadrigemina. Some of the lateral fibres of this middle portion, however, pass to the upper corpora quadrigemina (*upper fillet*), and even extend beyond the superior quadrigeminal region to the subthalamie region (Flechsig), eventually reaching the parieto-occipital part of the cerebral hemispheres by the posterior part of the internal capsule (v. Gudden). Both the upper and lower fillet receive fibres from the antero-lateral columns of the spinal cord, for after hemisection of the cord degenerated fibres are seen on the same side, both in the lateral fillet of the mesencephalon, where they are mingled with the mass of undegenerated fibres which have been derived from the nucleus gracilis and nucleus cuneatus (see p. 53 and below), and in the bundle of the upper fillet, which enters the superior corpora quadrigemina; a few degenerated fibres are also seen in corresponding positions on the opposite side. Traced downwards the fibres of the lower fillet pass, as we have seen, a few by means of the trapezium towards the auditory nucleus of the opposite side, a few to the antero-lateral column of the medulla oblongata and cord (antero-lateral ascending tract), but most are traceable to the anterior column of the medulla oblongata dorsal to the pyramids, and passing across the raphé, proceed as internal arched fibres to the nuclei of the posterior columns, from the cells of which they in all probability arise.

To sum up:—The fillet as a whole is composed of ascending fibres, most of which are derived from the nuclei of the opposite posterior columns of the medulla oblongata, but a few from other sources. The fibres of the antero-lateral ascending tract which enter the fillet may, according to Edinger, be derived from cells of the opposite posterior horn of the spinal cord; if so, all the fillet-fibres may be regarded as having crossed over from the opposite side, some in the cord, others at the superior or sensory decussation in the medulla oblongata. The fact that they are thus derived is however by no means certain. Superiorly the fillet may be described as being prolonged upwards above the pons in three parts, of which one—the lower fillet—goes to the inferior of the corpora quadrigemina of the same side, a second—upper fillet—to the superior corpora quadrigemina and occipital region of the cerebral hemisphere, and a third, mesial fillet, to the base of the cerebrum through the crusta.

#### DORSAL PART OF THE MID-BRAIN: CORPORA QUADRIGEMINA.

As before stated the Sylvian aqueduct is covered on its dorsal aspect by the quadrigeminal lamina, bearing the bodies of the same name. The median part of the lamina is marked by a comparatively wide groove (*sulcus longitudinalis, s. sagittalis*), shallower inferiorly, which serves to separate the corpora quadrigemina of opposite sides (fig. 77). This grooved surface, which is raised above the level of the upper medullary velum, is connected with the velum by a small median strand of longitudinal fibres termed the *franulum veli* (fig. 77, *fr*). In front of the upper (anterior) pair of corpora quadrigemina the groove is interrupted by a transverse white prominence—the *posterior commissure*; but both this and the upper end of the median groove are in the natural condition concealed by the pineal body (*p*), which projects backwards and downwards from the posterior wall of the third ventricle and rests between the upper pair of quadrigeminal bodies. A well-marked narrow transverse groove (*sulcus transversus*) which commences a short distance from the middle line, and is curved round the lower border of the upper tubercle, separates this from the lower tubercle of the same side.

The **corpora quadrigemina** are two pairs of rounded eminences which are mainly composed of grey matter, although covered externally by and containing in their interior many white fibres. The upper or anterior tubercles (fig. 77, *c.g.s.*)

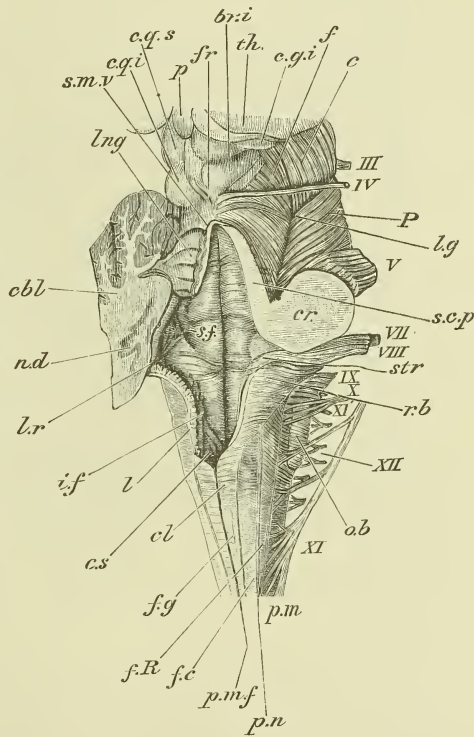
are broader and longer and also darker in colour, but slightly less prominent than the lower or posterior (*c.q.i.*)<sup>1</sup>. Laterally the corpora quadrigemina are not bounded by a distinct groove, but each appears to be prolonged obliquely upwards and forwards into a prominent white tract, known as the *brachium* of the corresponding tubercle. The lower (posterior) brachium (fig. 77, *br.i.*) loses itself underneath an oval prominence which is seen at the side of the upper end of the crus cerebri, and is termed the *inner geniculate body* (fig. 77, *c.g.i.*; fig. 78, *c.g.m.*). The upper (anterior) brachium passes between the same geniculate body, and the prominent posterior extremity of the optic thalamus into the *external geniculate body* (fig. 78, *c.g.l.*) and the optic tract, of which it may be regarded as the main prolongation (see also fig. 86, p. 117). The continuity is much better seen externally in some animals than in man.

The connection of the superior quadrigeminal bodies with the optic tract and the sense of sight is far more intimate than that of the inferior. For if in a young animal the eye on the one side be extirpated, the operation is found to be followed

Fig. 77.—VIEW OF THE MEDULLA, PONS, AND MESENCEPHALON FROM THE RIGHT SIDE AND BEHIND. (E. A. S.)

The cerebellum, the inferior medullary velum, and the right half of the superior medullary velum, have been cut away, so as to display the fourth ventricle.

*c.q.s.*, *c.q.i.*, superior and inferior quadrigeminal bodies of the left side; the pineal gland, *p*, is seen projecting backwards between the superior bodies, and the frænulum, *fr.*, passes up from the superior medullary velum, *s.m.v.*, to the interval between the posterior quadrigeminal bodies; *th.*, right thalamus opticus; *br.i.*, brachium of the inferior quadrigeminal body passing underneath the inner geniculate body, *c.g.i.*; *f.*, superficial stratum of fibres of the fillet, covering the tegmentum of the crus cerebri; *c.*, crusta of the crus cerebri, separated from the tegmentum by the lateral groove, *l.g.*; *P*, upper part of the pons; III, IV, &c., the corresponding cranial nerves. The rest of this figure will be found described at p. 43.



after some time by atrophy of the superior quadrigeminal body and of its brachium, whereas the inferior quadrigeminal body and brachium is unaltered (Gudden). Moreover, in the mole the inferior quadrigeminal body is well developed, whereas the superior is atrophied.

The **lower or posterior quadrigeminal bodies** are composed almost entirely of grey substance (the so-called *nucleus* of these bodies (fig. 76, *c.q.p.*) which is separated by a thin layer of the fillet from the central grey matter of the aqueduct and contains numerous small and some larger nerve-cells. The connections of these have not yet been satisfactorily worked out, but they are believed to be closely related to the termination of the fibres of the lower fillet. The nuclei are united across the middle line by a commissural portion of grey matter which is bounded superficially and deeply by transverse white fibres derived from the fillet.

<sup>1</sup> The term *nates* is often applied to the superior or anterior corpora quadrigemina, and *testes* to the inferior or posterior. These names were used by Vesalius, but are somewhat misleading, and have fallen into disuse.



The superficial fibres are continuous laterally and above with the fibres of the brachium of the inferior quadrigeminal body, and laterally and below with those of the lower fillet. On the other hand, if the fibres of the lower fillet are traced downwards, they are partly found as we have already seen (p. 104) to be continuous with fibres of the trapezium; which again is connected with the principal nucleus of the auditory nerve (cochlear division) of the opposite side (Flechsig). This would appear to indicate a close connection between these posterior or inferior quadrigeminal bodies and the auditory nerve, and in conformity with this view it is noticeable that it is only those animals (mammals) which have a well-developed spirally wound cochlea that show the inferior corpora quadrigemina as distinct prominences. In nearly all vertebrates below mammals there are merely corpora bigemina, and these seem mainly to represent the anterior pair of the quadrigemina of mammals. As

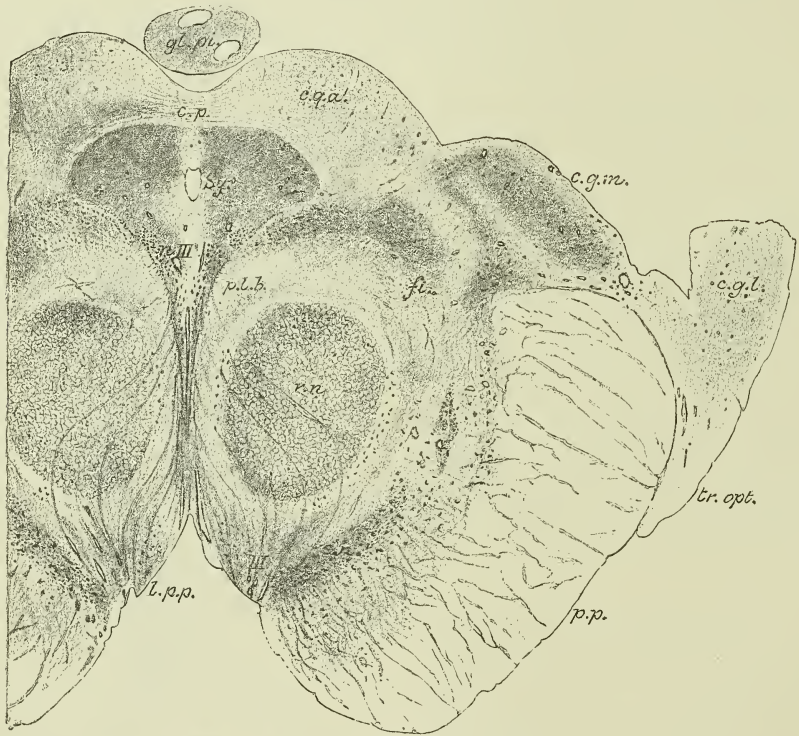


Fig. 78.—SECTION ACROSS THE MID-BRAIN, THROUGH THE SUPERIOR CORPORA QUADRIGEMINA. Magnified about  $3\frac{1}{2}$  diameters. (E. A. S.) From a Photograph.

*Sy.*, aqueductus Sylvii; *c.p.*, commissura posterior; *gl. pi.*, glandula pinealis; *c.g.a.*, grey matter of one of the superior corpora quadrigemina; *c.g.m.*, corpus geniculatum mesiale; *c.g.l.*, corpus geniculatum laterale; *tr. opt.*, tractus opticus; *p.p.*, pes pedunculi; *p.l.b.*, posterior longitudinal bundle; *fi.*, upper fillet; *r.n.*, red nucleus; *n.III*, nucleus of third nerve; *III*, issuing fibres of third nerve; *l.p.p.*, locus perforatus posticus.

already mentioned, this anterior pair is chiefly connected with the optic nerves and therefore with the visual sense.

The **upper or anterior quadrigeminal bodies** of man have been carefully investigated by Tartuferi. Most externally or uppermost is a thin layer of superficial neuroglia, containing no nerve-cells or fibres, but only fine stellate glia-cells and the ends of glia-fibres which radiate from the central canal (aqueduct) towards the periphery. Excluding this neuroglia-layer, and also the central grey matter around the Sylvian aqueduct, Tartuferi distinguishes four strata in vertical sections.

1. *Stratum zonale*; *superficial white layer*.—This is a relatively thin stratum of transversely coursing fine nerve-fibres, which are derived through the superior brachium from the optic tract and retina.<sup>1</sup> Many of them dip down and lose themselves in the next layer, but some appear to be continued towards the middle line and to decussate with others from the same stratum of the opposite side.

2. *Stratum cinereum*; *grey cap*.—A layer of grey matter, semilunar in section, being of considerable thickness opposite the most prominent part of the tubercle, but thinning off at its margins. Its nerve-cells are numerous but vary in size, the smaller ones being near the stratum zonale, the larger in the deeper part of the layer. They mostly send their dendrites or protoplasmic processes outwards, *i.e.*, towards the stratum zonale, while their nerve-processes (axis-cylinder processes) are directed inwards towards the deeper layers.

3. *Stratum albo-cinereum superius*; *upper grey-white layer*; *stratum opticum*.—The grey matter of this layer is largely interrupted by nerve-fibres, which are continued like those of the stratum zonale from the optic tract, which enters by the superior brachium at the antero-lateral aspect. The fibres differ in calibre in the different parts of the layer, and it may be subdivided accordingly into ( $\alpha$ ) a medio-dorsal zone of coarse medullated fibres, ( $\beta$ ) an intermediate zone of fine medullated fibres, and ( $\gamma$ ) a central zone containing much grey matter interspersed with bundles of white fibres.

These are described by Ganser as three distinct layers, and termed the third, or superficial medullated layer, the fourth, or middle medullated, and the fifth, or middle grey layer; while the fourth layer of Tartuferi, immediately to be mentioned, becomes the sixth and seventh of Ganser.

The whole stratum is richly beset with large nerve-cells, which send their axis-cylinder processes mostly into the next or fourth stratum. Of the nerve-fibres, those of the intermediate zone ( $\beta$ ) are retinal fibres according to Tartuferi; those of the central zone ( $\gamma$ ) are probably derived from the corona radiata of the occipital region of the brain, whilst the coarse fibres of the medio-dorsal zone are perhaps derived from the opposite side.

4. *Stratum albo-cinereum inferius*: *deep grey-white layer*: *stratum lemnisci*.—This, although composed of grey matter, is also traversed by many nerve-fibres which appear to be connected with the upper fillet, and probably end in the layer. Some of the fibres, however, are derived from the large cells of the fourth layer, and others from the nerve-cells of this stratum itself (which contains many cells of large size). It is possible that some fibres are derived (over the aqueduct) from the fillet of the opposite side.

Ganser subdivides this layer into two, which he terms respectively the deep white (sixth), and the deep grey (seventh) layers.

**Structure of the optic lobes of birds.**—The relations of the cells and fibres have not been very satisfactorily made out in the corpora quadrigemina of mammals, but in the optic lobes of the bird, which correspond, as we have seen, to the anterior or superior quadrigeminal bodies of the mammal, these relations have recently been considerably elucidated by the investigations of Ramón y Cajal.

All who have specially worked at this subject distinguish more strata in the optic lobes of birds than in the corresponding bodies of mammals. Thus Bellonci makes the number of layers (exclusive of the central grey matter of the aqueduct) nine, Stieda, twelve, whilst Cajal distinguishes as many as fourteen strata. Of these the most superficial (1.) is a layer of thick medullated fibres coming directly through the optic tract and chiasma from the retina of the opposite side. (In birds all the optic nerve-fibres cross at the chiasma.) They pass in from the side (so that they are cut across in a sagittal section, fig. 79), and after a variable course turn downwards into the deeper layers, where they end at four different levels (as far as the seventh layer) in non-medullated terminal arborisations. Of these terminal

<sup>1</sup> Monakow states that in the dog the anterior brachium contains some fibres from the occipital cortex.



ramifications, that in the seventh layer is flattened horizontally, the others are more extended vertically (fig. 80). Some of these terminal arborisations end in a special circumscribed part of the lobe, which is known as the *ganglion of the roof*. This contains a large number of nerve-cells, the protoplasmic processes of which interlace with the optic arborisations, whilst their nerve-fibre processes are directed towards the deeper layers of the lobe. All the layers below the first contain nerve-cells, as well as nerve-fibres, but the seventh is mainly composed of the

expanded ramifications of the optic fibres just mentioned, and of similar expansions of the superficially directed nerve-fibre processes of cells from the tenth layer (fig. 79, *j, j*). The cells vary in size and shape in the different layers, but on the whole they are smallest nearer the surface and largest in the deeper layers (tenth to thirteenth). With the exception of the cells of the tenth layer just mentioned, the cells send their axis-cylinder processes downwards to pass away as nerve-fibres of the fourteenth layer, which is chiefly formed of large medullated nerve-fibres, although some nerve-cells are even here interspersed. But some of the smaller cells of the more superficial layers (fig. 79, *d*) belong to Golgi's second type of nerve-cell, *i.e.*, their axis-cylinder processes do not pass into nerve-fibres, but break up into a terminal arborisation a short distance from the cell, and interlace amongst the cells of some of the other layers. The third, fifth, seventh, and ninth layers all have relatively few cells and a molecular aspect, due apparently to the fine arborisations of the nerve-fibre or axis-cylinder processes which they contain. The protoplasmic processes of the cells are, some

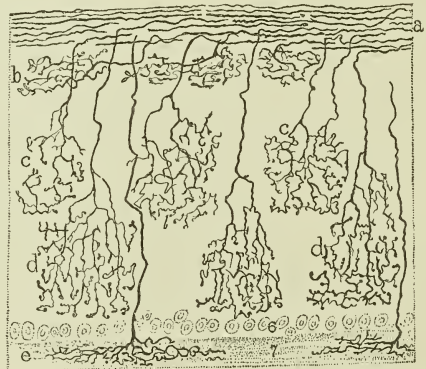
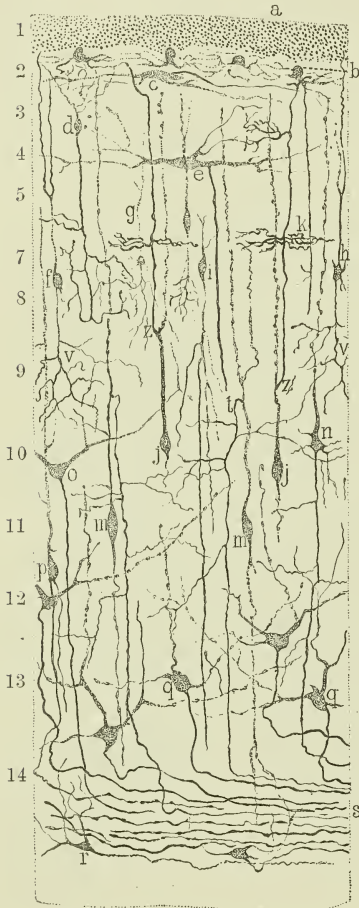


Fig. 79.—ANTERO-POSTERIOR SECTION OF THE OPTIC LOBE OF A BIRD PREPARED BY GOLGI'S METHOD (R. y Cajal).

*a*, optic fibres cut across; *b*, stellate cell of second layer; *c*, fusiform cell of third layer; *d*, cell with axis-cylinder ending in a varicose arborisation in the eighth layer; *e*, large horizontal cell of fourth layer; *f, g, h*, globular cells of eighth layer; *i*, cell with descending axis-cylinder of this layer; *j*, cell with axis-cylinder ascending to optic layer; *k*, collateral arborisation of this axis-cylinder in the seventh layer; *m*, large fusiform cells with recurrent axis-cylinders; *n*, pyramidal cell with descending axis-cylinder; *o*, large cell of tenth layer; *p, q, r*, cells of the lowest layers, all with axis-cylinders directed towards the deep layer of nerve-fibres, *s*.

Fig. 80.—TRANSVERSE SECTION OF OPTIC LOBE OF A BIRD, GOLGI'S METHOD (R. y Cajal).

The superficial part only is represented, as far as the seventh layer.

*a*, optic fibres; *b*, their arborisation in the second layer; *c*, that in the fourth layer; *d*, that in the fifth layer; *e*, that in the seventh layer.

of them, very long, and when coursing vertically often extend as far as the layer of optic fibres, on the one hand, and the deep medullary layer on the other. The axis-cylinder processes sometimes come off from the dendrites, sometimes from the body of the cell. Of the fibres which form the deepest layer, although many, as just stated, are derived from the



cells of the optic lobe, and are therefore passing away by that layer (probably to the higher parts of the brain, on the one hand, and to the bulb and spinal cord, on the other), some have a contrary direction and are passing *into* the grey matter, where they end in extensive ramifications extending as far towards the surface as the sixth layer.

The fibres of the deep medullary layer, on leaving the optic lobe, partly encircle, partly traverse, four groups of nerve-cells, which are known as the *optic ganglia*. It is probable that these may in part represent the external or lateral geniculate body of mammals. The fibres give off collaterals, which end in ramifications amongst the cells of these ganglia; some of the fibres appear altogether to terminate in this way. On the other hand, some of the ganglion-cells send their axis-cylinder processes to join the stream of traversing nerve-fibres. It is not known what ultimately becomes of these processes, but from analogy with what obtains in mammals (see diagram, p. 119), it is not improbable that they may pass to the cortex cerebri.

The **posterior commissure** (fig. 73, *Cop.*, fig. 78, *c.p.*), which overlies the upper end of the aqueduct and appears in the posterior wall of the third ventricle, is generally described with that cavity. It appears, however, to be in part a con-

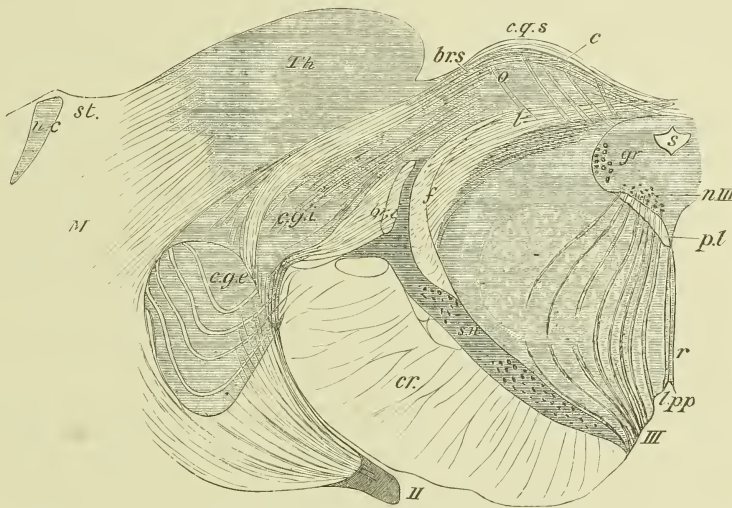


Fig. 81.—SECTION THROUGH THE SUPERIOR PART OF ONE OF THE SUPERIOR CORPORA QUADRIGEMINA AND THE ADJACENT PART OF THE OPTIC THALAMUS (after Meynert).

*s*, aqueduct of Sylvius; *gr*, grey matter of the aqueduct; *c.g.s*, quadrigeminal eminence, consisting of: *l*, stratum lemnisci; *o*, stratum opticum; *c*, stratum cinereum; *Th*, thalamus (pulvinar); *c.g.l*, *c.g.e*, internal and external geniculate bodies; *br.s*, *br.i*, superior and inferior brachia; *f*, upper fillet; *p.l*, posterior longitudinal bundle; *r*, raphé; *III*, third nerve; *n.III*, its nucleus; *l.p.p*, posterior perforated space; *s.n*, substantia nigra; above this is the tegmentum with its nucleus, the latter being indicated by the circular area; *cr*, crusta; *II*, optic tract; *M*, medullary centre of the hemisphere; *n.c*, nucleus caudatus; *st*, stria terminalis.

tinuation of the commissural fibres of the fillet above mentioned. Its fibres, according to Meynert, coming from the tegmental part of the mesencephalon, cross to the other side, and after passing through the thalamus diverge into the white substance of the cerebral hemispheres. They may in part comprise commissural fibres between the two thalami, and some are connected with the pineal roots. According to Darkschewitsch they are divisible into two categories. Some form a ventral portion of the commissure, being derived from the posterior longitudinal bundle and the nucleus of the third nerve, and pass across to the root of the pineal body of the opposite side, while the rest, which form a dorsal portion of the commissure, connect the deep white layers of the superior corpora quadrigemina with the corona radiata of the opposite side.

The **geniculate bodies** are intimately related to this region of the brain, the

mesial (internal) with the inferior quadrigeminal bodies, the lateral (external) with the superior quadrigeminal bodies and optic tract. The two are separated by a part of the optic tract which sweeps round the internal geniculate body in passing as the superior brachium, to the grey matter of the corp. quadrig. sup. (fig. 86, p. 117). Both the geniculate bodies are continuous with the posterior part of the thalamus, lying between this and the lateral margin of the crista. The internal geniculate body receives ventrally and mesially the inferior brachium, which passes forwards to it by the side of the tegmentum from the corp. quadrig. inf., and appears to dip under it. Some of the fibres of the optic tract appear to pass out of it on its latero-ventral aspect, but as the internal geniculate body remains unaffected when the eye is extirpated, and is, moreover, as well as the corp. quadrig. inf., well developed in the mole, it is probable that this connection with the optic fibres is more apparent than real.

The lateral or external geniculate body is, on the other hand, intimately related to the optic tract and corp. quadrig. sup. as well as to the visual area of the cortex cerebri (occipital region). It is of a somewhat darker colour than the adjacent part of the thalamus with which it is intimately connected, and is formed of several curved layers of grey matter with white lamellæ of optic nerve-fibres separating them (fig. 81, *c.g.e.*)

Its cells are large and pigmented, and appear chiefly to send their nerve-fibre processes to the cortex of the occipital region, for if this region is removed on one side in young animals the cells of the external geniculate body of the same side undergo atrophy (Monakow.) On the other hand, if the eyes are extirpated, the atrophy which extends along the optic tracts involves the grey matter between the cells, but not the cells themselves. From this it is inferred that the intercellular grey matter of these bodies is largely composed of ramifications (? of collaterals) of the retinal fibres. The same statements apply to the adjacent part of the optic thalamus (pulvinar) which appears intimately associated both in structure and function with the lateral geniculate bodies.

The **optic thalami** (fig. 82, *Tho*), as seen from above after the removal of the corpus callosum, fornix, and velum interpositum, are large oval-shaped masses of grey substance covered dorsally by a thin stratum of white fibres. The dorsal surface is marked by a shallow longitudinal groove, which inclines inwards as it passes forwards, and terminates a short distance from the anterior extremity of the surface. This anterior extremity is raised into a prominence termed the *anterior tubercle* (fig. 82, *Ts*), and together with the part of the upper surface which is placed outside the groove, projects into the ventricle of the corresponding cerebral hemisphere (fig. 88), and is covered by the lining epithelium of that cavity. This part of the upper surface is limited externally by a white band, the stria terminalis (*Sf*), which separates it from the part of the corpus striatum which is seen in the lateral ventricle. The longitudinal groove above mentioned corresponds with the thickened margin of the fornix, the edge of which extends over the surface of the thalamus along the line of the groove. The part of the upper surface behind the groove does not appear in either the third or the lateral ventricle, and is therefore not covered with epithelium like the rest. It is limited internally by a sharp edge which separates it from the mesial surface and which is marked by a white stria (*tænia fornicis*, fig. 82, *Tfo*) leading to the pineal body. It is along this stria, which is surmounted by a ridge-like extension of ependymal tissue that the thin epithelium which roofs in the ventricle is attached laterally: this epithelium always comes away when the covering of the velum interpositum is removed. At the posterior and inner extremity of the thalamus, there is seen, as in front, a well-marked prominence (*posterior tubercle* or *pulvinar* (*Pv*)) which projects over and partially conceals the brachia of the corpora quadrigemina. Between the pulvinar and the peduncle of the

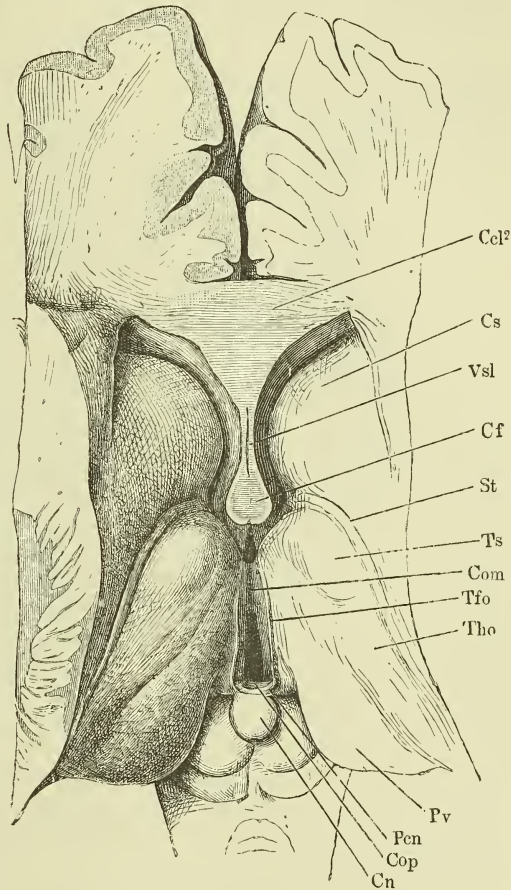


pineal body (*habenula*) (*Pcn*) lies a triangular depressed surface, separated posteriorly from the mesencephalon by a transverse groove and passing mesially into the stalk of the pineal body. This triangular surface is termed the *trigonum habenulae*. It is bounded laterally by the *sulcus habenulae*. The mesial surface of the thalamus lies in the third ventricle. It is covered with epithelium and is joined with that of the opposite side by the middle commissure. The posterior rounded surface is occupied almost entirely by the pulvinar. Below and external to this is the outer geniculate body, which is placed just above the inner geniculate body before mentioned (p. 105), the two being separated from one another by one of the roots of the optic

Fig. 82.—VIEW FROM ABOVE OF THE THIRD VENTRICLE AND A PART OF THE LATERAL VENTRICLES (Henle).

The brain has been sliced horizontally immediately below the corpus callosum, and the fornix and velum interpositum have been removed.

*Tho*, thalamus opticus; *Ts*, its anterior tubercle; *Pv*, pulvinar; *Com*, middle commissure stretching between the two optic thalami across the middle of the third ventricle; *Cf*, columns of the fornix; *Cn*, pineal gland projecting downwards and backwards between the superior corpora quadrigemina; *St*, stria terminalis; *Cs*, nucleus caudatus of the corpus striatum; *Vsl*, ventricle of the septum lucidum; *Ccl<sup>2</sup>*, section of the genu of the corpus callosum; *Pcn*, pineal peduncle; *Tfo*, pineal stria; *Cop*, posterior commissure.



tract (upper brachium) (fig. 86). From this brachium and from the two geniculate bodies the optic tract curves downwards and forwards around the crus cerebri.

The lateral and ventral surfaces of the thalamus are not free, but are united with other parts of the brain. The ventral surface is united with a prolongation of the tegmental part of the crus cerebri, and more anteriorly the corpus albicans and the side of the tuber cinereum lie below

it. The lateral surface is covered by white substance which is formed of the fibres of the crusta, which here diverge into the substance of the hemisphere, and pass between the thalamus and the lenticular nucleus as the internal capsule.

The thalami optici are covered on their free surfaces (mesial and dorsal) (fig. 83), by a layer of white fibres, most marked upon the dorsal surface (*stratum zonale*), and mainly running antero-posteriorly. On their outer surface, as just mentioned, is the white matter of the inner capsule (*i. c.*) formed by fibres diverging from the crusta into the hemispheres. Next to the thalamus on this side is a denser layer of white fibres, termed the *outer medullary lamina*. All along this surface radiating fibres pass out of the thalamus to mingle with the fibres of the inner capsule and to pass with these to the surface of the cerebral hemispheres. Those in



front pass to the frontal lobe of the hemisphere; those in the middle region to the posterior part of the frontal and to the parietal lobe, besides some to the temporal lobe; those behind partly to the temporal lobe, but chiefly to the occipital lobe. The fibres to the occipital lobe pass out from the lateral margin of the pulvinar, and have at first a curved course round the posterior horn of the lateral ventricle, afterwards radiating, with a generally sagittal direction, towards the cortex of the occipital lobe. They are often spoken of as the *optic radiations*. These radiating fibres are continuous with others passing from the optic tract to the pulvinar. The lower surface of the thalamus is continuous posteriorly with the prolongation of the tegmentum (*subthalamie tegmental region*), but in front this

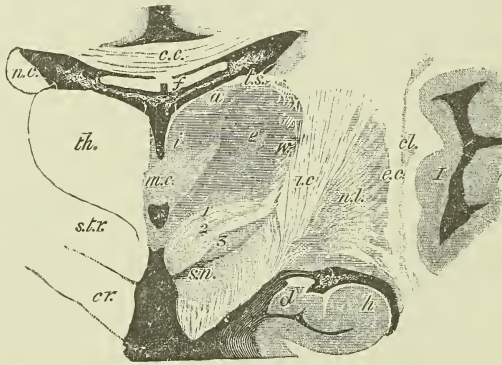


Fig. 83.—SECTION ACROSS THE OPTIC THALAMUS AND CORPUS STRIATUM IN THE REGION OF THE MIDDLE COMMISSURE (E. A. S., after a preparation by Mr. S. G. Shattock). Natural size.

*th.*, thalamus; *a., e. i.*, its anterior, external and internal nuclei respectively; *w.*, its latticed layer; *m. c.*, middle commissure; above and below it is the cavity of the third ventricle; *c. c.*, corpus callosum; *f.*, fornix, separated from the third ventricle and thalamus by the velum interpositum. In the middle of this are seen the two veins of Galen and the choroid plexuses of the third ventricle; and at its edges the choroid plexuses of the lateral ventricles; *t. s.*, tænia semi-

circularis; *cr.*, forward prolongation of the crusta passing laterally into the internal capsule, *i. c.*; *s. t. r.*, subthalamie prolongation of the tegmentum, consisting of (1) the dorsal layer, (2) the zona incerta, and (3) the nucleus of Luys; *s. n.*, substantia nigra; *n. c.*, nucleus caudatus of the corpus striatum; *n. l.*, nucleus lenticularis; *e. c.*, external capsule; *cl.*, claustrum; *I.*, island of Reil.

prolongation inclines to the outer side and becomes lost in a layer of grey matter which is continuous internally with the grey matter of the floor of the ventricle, and is seen at the base of the brain as the anterior perforated lamina. At its anterior end the thalamus merges into a tract of fibres which stream from it through the internal capsule into the frontal lobe of the hemisphere (*anterior stalk of thalamus*). Other fibres curve downwards and outwards towards the white substance of the hemisphere forming the so-called *lower stalk of the thalamus (ansa peduncularis)*. Above this is another tract (*ansa lenticularis*), sweeping from under the thalamus round the mesial part of the crusta to the lenticular nucleus of the corpus striatum. The layer of grey substance which is interpolated between the two tracts may be termed *substantia interansalis*; including the two ansæ it has been designated *substantia innominata*.<sup>1</sup>

The body of the thalamus is chiefly formed of grey matter with large and small nerve-cells scattered in it, but their arrangement and connections with nerve-tracts have not been satisfactorily ascertained. Its grey matter is partially subdivided into two parts, the so-called inner and outer (mesial and lateral) nuclei of the thalamus (Burdach), by a vertical white lamina, S-shaped in section (*internal medullary lamina*). The *lateral nucleus (e)*, is the larger and extends into the pulvinar; it is marked externally by the radiating white lines before mentioned as passing from the thalamus into the inner capsule, and these confer upon its external layer somewhat of a reticulated aspect (*latticed layer, w.*). The *mesial nucleus (i)* does not extend into the anterior tubercle, but this part of the grey substance of the

<sup>1</sup> The term "anse pédonculaire" was originally used (by Gratiolet) to include the whole substantia innominata.

thalamus is cut off from it by another septum of white matter. The anterior separated part is the *anterior nucleus* of the thalamus or *nucleus of the anterior tubercle* (*a*). It contains comparatively large nerve-cells and from its depth a number of fibres pass downwards and converge to form a well-marked bundle (*bundle of Vicq-d'Azyr*), which, entering the corpus albicans, forms within that tubercle a sharp bend, and appears to pass upwards again in the wall of the ventricle as the anterior pillar of the fornix. There would seem, however, to be no actual continuity between the two (see pp. 129, 130). The middle commissure unites the mesial nuclei across the third ventricle, and is also continuous below on each side with the grey matter of the cavity. It contains nerve-cells and transversely coursing fibres, but many of the fibres are said to loop backwards near the median plane in place of passing across to the opposite side.

In the **trigonum habenulæ** is a collection of nerve-cells termed by Meynert the *ganglion of the habenula*. To it, fibres pass from the peduncle of the pineal body, and from it a bundle of fibres (*fasciculus retroflexus*, *Meynert's bundle*) (fig.

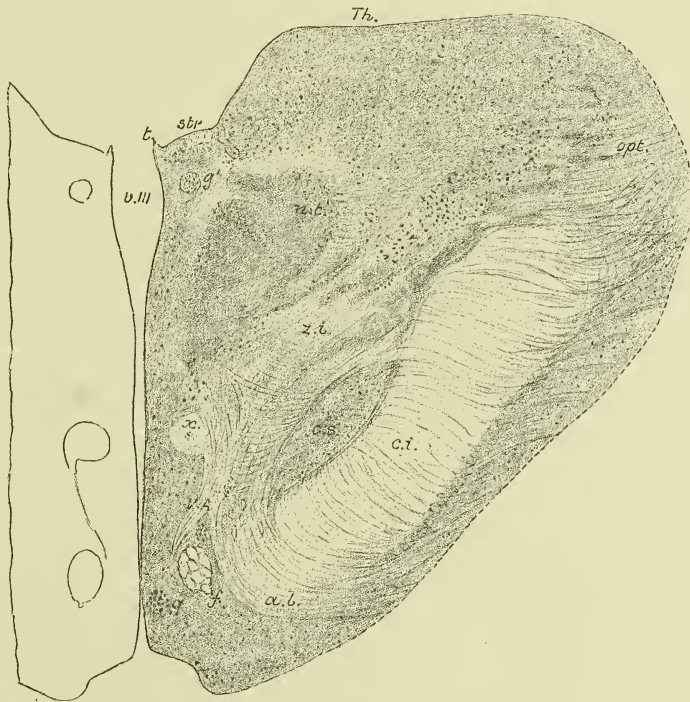


Fig. 84.—SECTION OF THE INTER-BRAIN NEAR THE JUNCTION WITH THE MID-BRAIN, SHOWING THE SUBTHALAMIC TEGMENTAL REGION. Magnified about  $2\frac{1}{2}$  diameters. From a photograph (E. A. S.).

The section passes nearly horizontally, so as to cut the fibres of the internal capsule across transversely. It is just above and in front of the corpora mamillaria.

*t.*, tænia (attachment of epithelial roof of ventricle); *v.III.*, ventriculus tertius; *str.*, stria pinealis; *Th.*, thalamus; *n.t.*, mesial nucleus of thalamus; *opt.*, optic fibres passing to pulvinar; *z.l.*, zona incerta; *c.s.*, corpus subthalamicum; *c.i.*, capsula interna; *a.l.*, ansa lenticularis; *f.*, anterior pillar of fornix passing backwards towards corpus albicans; *V.A.*, bundle of Vicq d'Azyr, passing upwards and forwards from corpus albicans into thalamus; *x.*, white bundle containing a central nucleus of grey matter (? the fasciculus retroflexus of Meynert); *g, g'*, special groups of nerve-cells, of which *g'* is the hinder end of the ganglion habenulæ.

84, *x*) passes with a curved course through the tegmentum on the mesial side of the red nucleus towards the place where the cerebral peduncles diverge; where,

according to Forel, it passes to another collection of nerve-cells, better marked in most animals than in man, termed the *interpeduncular ganglion* (see p. 103).

**Subthalamic tegmental region; transitional region.**—The prolongation of the tegmentum under the posterior part of the thalamus is divided by Forel into three layers, which are named respectively from above down, the *stratum dorsale*, the *zona incerta*, and the *corpus subthalamicum* or *nucleus of Luys* (fig. 83, 1, 2, 3). The latter has here taken the place of the substantia nigra, lying next to the prolongation of the crusta, the fibres of which are seen at the side of the subthalamic tegmental region forming the internal capsule. The *stratum dorsale* consist chiefly of fine longitudinal fibres—prolonged from the posterior longitudinal bundle according to Meynert, or from the fibres enclosing the tegmental nucleus according to Forel, possibly from both sources. The red nucleus of the tegmentum is prolonged into its posterior part, and from this a considerable number of fibres stream into the internal medullary lamina of the thalamus, and a well-marked bundle passes across the internal capsule to the lenticular nucleus. Some fibres of this layer, which are traceable downwards into the upper fillet (Wernicke), turn into the external medullary lamina of the thalamus, which lies along the mesial side of the internal capsule, and from here they probably diverge into the white matter of the hemisphere; whilst others, coursing through the *zona incerta*, and crossing the inner capsule, join a tract (*ansa lenticularis*, fig. 84, *a.l.* and p. 112) which leads to the lenticular nucleus of the corpus striatum. Finally another bundle of fibres is said to be traceable from the mesial nucleus of the thalamus backwards through the subthalamic region into the dorsal part of the posterior commissure, and thus over the Sylvian aqueduct into the tegmentum of the opposite side.

The *zona incerta* is a reticular formation prolonged from that of the tegmentum; it passes anteriorly into the substantia interansalis.

The *corpus subthalamicum*, or *nucleus of Luys* (figs. 83, 84, *c.s.*), is a well-marked brown stratum of grey matter containing numerous nerve-cells, and a close plexus of very fine medullated fibres. It is lens-shaped in section, and has an enclosing envelope of white substance, through which strands of fine fibres pass from the interior of the body mesially towards the *zona incerta*, and outwards and downwards through the internal capsule. This stratum is distinct only in the Primates.

The **pineal body** or **gland** (*conarium*, *epiphysis cerebri*) (fig. 82, *Cn*, fig. 91), is a reddish body about the size of a small cherry-stone, and is named from its supposed resemblance in shape to a fir-cone. It is connected with the posterior part of the third ventricle, projecting backwards and downwards between the superior pair of corpora quadrigemina. It is attached on each side by a broad but flattened stalk of white fibres (*pedunculus conarii*) which is separated by the pineal recess of the ventricle (p. 97) into a dorsal and ventral portion. The ventral portion curves downwards; it belongs to the ventral portion of the posterior commissure. These fibres are said to be derived from the optic tract near the lateral geniculate body, and to go to the oculomotor nucleus of the opposite side (compare p. 109). The upper portion extends on either side along the ridge-like junction of the upper and mesial surfaces of the thalamus as the pineal stria or *tænia fornicis* (fig. 82, *Tfo.*). At the sides the stalk merges into the trigonum habentulæ. The pia mater which invests the mesencephalon, covers the pineal gland with a special investment before being prolonged as the *velum interpositum* over the third ventricle and thalamus; and the gland is liable to be torn away in removing the pia mater.

The pineal gland is composed of a number of hollow follicles generally spherical, but in some cases tubular, separated from one another by ingrowths of connective tissue. The follicles are almost filled with epithelial cells and often contain much gritty calcareous matter (*acervulus cerebri*, *brain-sand*), composed of microscopic



particles, aggregated into masses and formed of earthy salts (phosphate and carbonate of lime, with a little phosphate of magnesia and ammonia) combined with animal matter.

The same sandy matter is frequently found on the outside of the pineal body, or deposited upon its peduncles. It is found also in the choroid plexuses; and in a scattered form occurs in other parts of the membranes of the brain. It occurs at all ages, frequently in young children, and sometimes even in the foetus. It cannot, therefore be regarded as the product of disease. The pineal body is larger in the child and the female than in the adult male (Huschke). In the brains of other mammals it is proportionally larger than in the human subject, and less loaded with brain-sand.

The pineal body is developed originally as a hollow outgrowth from that part of the embryonic brain which afterwards forms the third ventricle; the diverticulum becomes subsequently cut off from the ventricle, and undergoes ramification to form tubes which are afterwards separated for the most part into isolated vesicles.

The pineal body is present in all vertebrates, Amphioxus only excepted. In elasmobranch fishes and in most reptiles, as the researches of de Graaf, Baldwin Spencer, and others, have shown, it is continued into a long tubular prolongation from the third ventricle, which passes through an aperture in the skull (parietal foramen) and ends under the skin in a small vesicle lined with ciliated epithelium. But in some reptiles (*e.g.*, Hatteria, blind-worm, lizard) this vesicle becomes developed into a structure which bears a close resemblance to an invertebrate eye (*pineal eye*), the part nearest the surface becoming thickened to form a kind of lens, and the part connected with the stalk becoming pigmented and stratified like a retina, whilst the stalk itself becomes solid and has nerve-fibres developed in it. It is doubtful how far this structure serves as an eye in any living reptile, but in certain extinct forms it was probably more completely developed. In birds and mammals the pineal eye is not developed, but the organ is similar in structure to that of man.

The **posterior perforated space** (*locus perforatus posticus*) (fig. 32,  $\times$ ), lies in a deep fossa (*fossa Tarini*, His) at the base of the brain, at the bottom of which is greyish matter, connecting the diverging crura. It is perforated by numerous small openings for the passage of blood-vessels; and some horizontal white striæ usually pass out of the grey matter and turn round the peduncles close to the upper border of the pons, entering which they reach eventually the medullary centre of the cerebellum (*tania pontis*). It corresponds posteriorly, as far as a line joining the anterior borders of the third nerves, to the floor of the aqueduct of Sylvius, but in front of those nerves to the posterior part of the floor of the third ventricle. In the grey matter over the space are a few scattered nerve-cells.

The **corpora albicantia** or **mamillaria** (fig. 32, *a*; fig. 86) are two round white eminences in front of this space, each about the size of a small pea, connected together across the middle line. Each corpus albicans contains grey matter concealed within its superficial white fibres, the nerve-cells being arranged in two groups, the lateral and mesial (nuclei of the corpus albicans); of these the lateral contains larger nerve-cells than the mesial.

The white matter of the corpora albicantia is formed by the anterior pillars of the fornix: hence they have also been named *bulbs of the fornix*; and by the bundle of Vicq d'Azyr, which enters the anterior part of each tubercle at the dorso-mesial aspect. Posteriorly each corpus albicans receives a bundle of nerve-fibres, which is termed its *peduncle*. This, which in man is concealed within the grey matter of the floor of the third ventricle, but which is seen at the base of the brain in many animals, and is connected with the lateral nucleus of the body, is traceable to the tegmentum and ultimately to the mesial part of the crusta (v. Gudden). In most vertebrates there is but one (median) corpus albicans in place of two.

An isolated bundle of one of the anterior pillars of the fornix is sometimes visible at the base of the brain passing to the corpus albicans (*stria alba tubervis*, Lenhossék).

The **tuber cinereum** (fig. 86 ; fig. 32, *t.c.*) is a lamina of grey matter extending forwards from the corpora albicantia to the optic commissure, to which it is attached. It forms part of the floor of the third ventricle. In the middle it is prolonged forwards and downwards into a hollow conical process, the **infundibulum** (fig. 85, *i*), to the extremity of which is fixed the pituitary body. On its outer side close to the optic tract is a tract of grey matter with nerve-cells, termed by Meynert the *basal optic ganglion* (see p. 119). According to Lenhossék this is distinctly subdivided into three successive groups of nerve-cells, the most anterior being just above the chiasma, the most posterior near the corpus albicans.

The **pituitary body** or *hypophysis cerebri* (figs. 32, 39, *h*, and fig. 85), formerly called pituitary gland, from its being erroneously supposed to discharge *pituita* into the nostrils, is a small reddish grey mass, of a somewhat flattened oval shape, widest in the transverse direction, and occupying the sella turcica of the sphenoid bone. The pituitary body has a special prolongation of the dura mater completely enclosing it, except above where there is a small aperture for the passage of the infundibulum (see p. 182). The body consists of two lobes, of which the anterior is the larger, and is concave behind, where it embraces the smaller posterior lobe. The two lobes are entirely different, both in their structure and development ; and it is only in mammals that they come into close connexion with one another.

The *posterior lobe* is developed as a hollow downgrowth of the part of that cavity of the embryonic brain, which afterwards becomes the third ventricle. In the lower vertebrates, and especially in fishes, the cells which compose its walls become converted into nerve-cells and -fibres, and as the *lobus infundibuli* it becomes an integral part of the brain. But in the higher vertebrates it remains small and almost undeveloped ; its cavity is obliterated, and all nervous structure becomes obscured by the ingrowth of vessels and of connective tissue into the now solid organ. The connective tissue forms reticulating bundles, between which occur

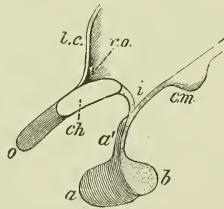


Fig. 85.—SAGITTAL SECTION OF THE PITUITARY BODY AND INFUNDIBULUM WITH THE ADJOINING PART OF THE THIRD VENTRICLE (Schwalbe).

*a*, anterior lobe ; *a'*, a projection from it towards the front of the infundibulum, *i* ; *b*, posterior lobe connected by a solid stalk with the infundibulum ; *l.c.*, lamina cinerea ; *o*, right optic nerve ; *ch*, section of chiasma ; *r.o.*, recess of the ventricle above the chiasma ; *c.m.*, corpus mamillare.

numerous spindle-shaped and branched cells, as well as a few larger corpuscles containing pigment-granules in their protoplasm. Sometimes remains of the original hollow are seen in the form of a cavity lined by columnar ciliated cells.

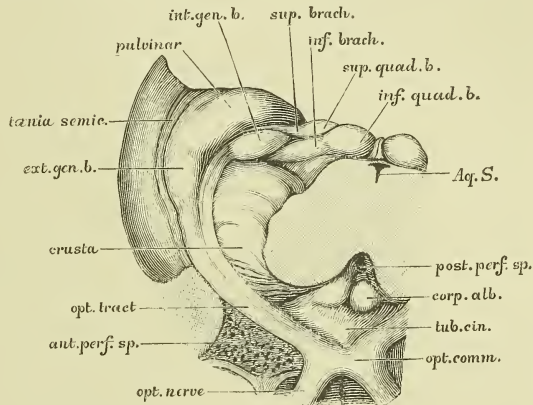
The *anterior lobe*, darker in colour than the posterior, is developed as a tubular prolongation from the epiblast of the buccal cavity, with which it is therefore originally in connection, although it soon becomes separated by the growth of intervening tissue. In the adult it is constituted by a large number of slightly convoluted tubules or alveoli, similar to those of a secreting gland, and in like manner lined by epithelium, which in some cases fills up the tubule. The tubules are united by connective tissue, which is especially abundant in the neighbourhood of the larger blood-vessels, and also forms a sort of capsule to the organ. Moreover, portions of the tubules are frequently cut off by the connective tissue so as to form isolated vesicles. The outer layer of epithelium is columnar ; and in some of the larger tubes, especially those next to the posterior lobe, cilia may be detected on the cells. The blood-vessels are numerous, and the capillaries form a close network

around the walls of the tubules. The lymphatics of the organ originate in cleft-like spaces between the tubules and pass to a network in the capsule. In its microscopic structure the anterior lobe of the pituitary body bears a resemblance to the thyroid body, the vesicles of which are also originally a network of anastomosing tubules, and in some animals remain throughout life in this condition. Moreover, a colloid substance like that in the thyroid vesicles, is found sometimes in the alveoli of the anterior lobe of the hypophysis.

In the middle line of the base of the brain, in front of the optic commissure, is the anterior portion of the great longitudinal fissure, which separates the two hemispheres. At a short distance in front of the chiasma, this fissure is crossed transversely by the anterior recurved extremity of the corpus callosum. On gently

Fig. 86.—ORIGIN AND RELATIONS OF THE OPTIC TRACT (G. D. Thane).

The parts are viewed from below, the mid-brain having been divided transversely immediately above the pons, and the pons, cerebellum and medulla oblongata removed. The lower part of the figure is the more anterior.



turning back the optic commissure, a thin connecting layer of grey substance, the **lamina cinerea**, is seen occupying the space between the corpus callosum and the chiasma, and continuous above the chiasma with the tuber cinereum. It is connected at the sides with the grey substance of the anterior perforated space, and forms part of the anterior boundary of the third ventricle (fig. 57, p. 70): it is somewhat liable to be torn in removing the brain from the skull; and, in that case, an aperture is made into the fore part of the third ventricle.

The **optic tracts** and **optic commissure or chiasma**. The optic tracts curve round the crusta on each side to unite with one another immediately in front of the tuber cinereum, where they form the X-shaped commissure which is known as the chiasma. The optic tracts form the posterior limbs of the X; the optic nerves, passing into the optic foramina, the anterior limbs (fig. 86).

Each tract arises posteriorly by a broad root, which is divided by a longitudinal groove into two distinct parts, a lateral and a mesial. The lateral root is the larger. It is connected with and emerges from the posterior and ventral part of the thalamus (lateral geniculate body and pulvinar), and is partly continuous with the brachium of the superior quadrigeminal body. The mesial root, when traced backwards, is seen to curve round the crusta and then to lose itself beneath the mesial geniculate body, in which it appears to end, although it may perhaps ultimately pass into the inferior quadrigeminal body as its brachium. Although this root appears connected with the internal geniculate body, it is doubtful if there is any functional connexion between this body and the optic nerve, the part of the tract which enters the mesial geniculate body being Gudden's commissure, which joins the mesial geniculate bodies of the two sides (see below). Before reaching the chiasma the optic tract lies postero-mesially to the anterior perforated space.

Darkschewitsch describes the passage of some of the fibres of the optic tract to the ganglion habenulæ and pineal peduncle, and ultimately by the posterior commissure to the oculomotor nucleus (compare pp. 109 and 114). He regards these as fibres subserving the reflex changes of the pupil.

As for the course of the optic fibres in the tract and chiasma it may be stated



that although in many mammals (mouse, guinea-pig), and in all vertebrates below mammals, the decussation is complete, so that all the fibres pass from one tract into the opposite optic nerve, in other mammals (rabbit, dog, cat, monkey) and in man, it is incomplete, so that some of the fibres from the left optic nerve pass into the left tract and others into the right tract, and the same *mutatis mutandis* for those of the right nerve. This fact has been conclusively proved both by experiment and clinical observation. At the same time it must be stated that cases have occasionally been recorded which, if correct, are only to be explained on the supposition that the crossing is complete : in these we must suppose that there has been a reversion to the lower and more primitive type of chiasma.

The two sets of nerve-fibres are usually spoken of as the crossed and uncrossed bundles, although they are not to be regarded as formed into entirely separate funiculi, nor are their limits sharply defined either in the nerve, chiasma, or tract. The uncrossed bundle is distributed exactly to the lateral half of the retina, the crossed bundle to the mesial half; and on the whole the fibres of the uncrossed bundle keep to the lateral side of the optic nerve, whilst the crossed bundle is on the mesial side of the nerve. In the chiasma and tract they are usually more commingled, and their relative position is very variously described. In a case of atrophy of one nerve which has been clearly described by Williamson, the uncrossed fibres chiefly occupied the middle of the tract, the crossed being chiefly at the periphery and lower part. Similar results were obtained by Henschen.

According to Salzer's enumeration, there are nearly half a million fibres in each optic nerve. The fibres vary in size. According to v. Gudden they are divisible, according to their calibre, into two classes, finer and coarser. The former of these he regarded as being concerned in the production, as afferent fibres, of the pupil-reflexes, the latter as conveying visual impressions. The finer fibres degenerate after destruction of the anterior corpora quadrigemina (in the cat and rabbit). It must be remembered that not only afferent, but also efferent impressions are carried by the optic tracts; governing the chemical changes which occur in the retina, and also the movements of some of its elements (pigment-cells, cones).

Besides the optic nerve-fibres, there is a bundle at the posterior part of the chiasma, and running along the mesial side of the optic tracts to join the internal geniculate bodies of the two sides.<sup>1</sup> This is known as the *inferior commissure* or *commissure of Gudden*. It appears to have no relation to the visual function, for it undergoes no change when the rest of the optic tracts become atrophied after extirpation of both eyes in young animals. Its fibres are of extremely small diameter.

In structure the optic tract resembles an extension of the white matter of the brain, being very soft and not divided up into bundles by connective tissue, nor are its fibres provided with membranous sheaths. These structures are found, however, in the chiasma, and in the optic nerve, which are strong and tough and invested with sheaths continuous with the pia mater and arachnoid. At its entrance into the orbit the optic nerve receives a strong investment from the dura mater, which is continued around it into the sclerotic coat of the eye. The nerve is subdivided by intercommunicating connective-tissue septa into a large number of compartments, which contain the nerve-fibres, but the latter are not gathered up into round funiculi invested by perineurium, as in the case of the ordinary peripheral nerves.

Stilling has described the optic tract as sending a prolongation directly into the outer part of the crus cerebri. This prolongation is said to contain fibres which pass (1) to the oculomotor nuclei; (2) to the cerebellum by the inferior peduncle; (3) to the pons Varolii, even extending to the inferior olive.

The name *tractus transversus pedunculii* was given by Gudden to a band of fibres, first noticed by Inzani and Lemoigne, which is sometimes seen emerging from the base of the anterior quadrigeminal body, and coursing obliquely over the brachia of the quadrigeminal bodies to enter the crus cerebri. It is much better marked in some animals than in man. It becomes atrophied after extirpation of the eye, and may be a part of the prolongation of the optic tract described by Stilling.

<sup>1</sup> It is stated by Darkschewitsch, that this commissure unites each mesial geniculate body with the lenticular nucleus of the opposite side.

As regards the course of the optic fibres, the results of experiment show that whilst some have their cell-origin in the periphery—presumably in the nerve-cells of the retina—others take origin in nerve-cells of parts of the brain (superior corpora quadrigemina, external geniculate body, and pulvinar). Of those nerve-fibres which have their cell-origin in the retina, and which, therefore, undergo degeneration backwards after section of the optic nerve or tract, some end by arborisations between the nerve cells of the external geniculate body and pulvinar, others by arborisations in the more superficial layers of the superior corpora quadrigemina (see figs. 79, 80, and 87). It has been found that after enucleation of the eye the grey matter between the cells in these several parts undergoes atrophy. Those fibres which have their cell-origin in the nerve-centres end by terminal arborisations within the retina. Their course will there be followed in the part of this work which deals with the structure of the eye.

Finally, whilst dealing with the course of the optic nerve-fibres, it may be as well to mention the probable intercentral connections of the nervous visual apparatus. (1.) There is in all probability a double connection between the cortex of the occipital lobe (which represents the higher visual centre) and the lower visual centres of the thalamencephalon and mesencephalon by two sets of fibres, one set arising from the cortex and passing through the corona radiata and caudal end of the internal capsule, finding their terminal arborisation in the grey matter of the lower optic centres, and another set arising in cells of those centres and finding their terminal arborisation in the occipital cortex. These connections are confined to the parts of the same side of the brain; there is no evidence of any crossing of the fibres. (2.) There appears to be an intimate connection between the lower optic centres and the grey matter of the bulb and cord. This connection is probably mainly effected through the upper fillet. (3.) The nuclei of the nerves to the muscles of the globe of the eye, both external and internal, are certainly connected with the optic centres. It is possible that this connection may be partly effected through the posterior commissure and posterior longitudinal bundle; it is probably both crossed and uncrossed: but the

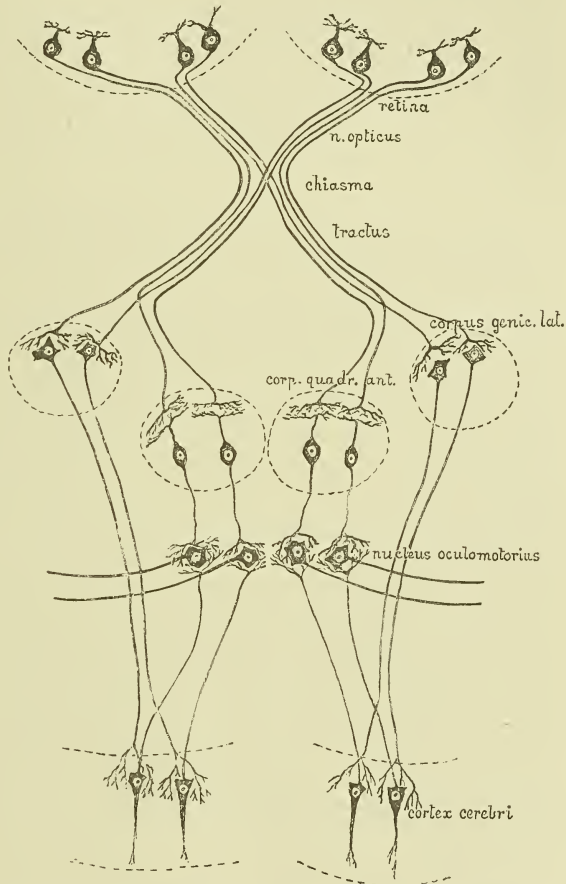


Fig. 87.—DIAGRAM OF THE PROBABLE COURSE AND RELATIONS OF SOME OF THE OPTIC FIBRES.

actual tracts of connection have not yet been elucidated. (4.) There appears to be a direct connection between some of the fibres of the optic tract and the cerebellum, since after removal of one half of the latter organ, many of the fibres of the corresponding optic tract undergo the Wallerian degeneration (Marchi). This connection may also take place along the tract of the upper fillet.

In the grey matter which lies between the third ventricle and the optic chiasma, a small collection of nerve cells (basal optic ganglion) is seen on each side, as already noticed (p. 116). These ganglia do not appear to have any direct connection with the optic nerve, as was supposed by Meynert to be the case, but from each a tract issues, which, after decussating with that of the opposite side (*Meynert's commissure*), applies itself to the mesial side of the optic tract, close to Gudden's commissure, and passes backwards to the subthalamie region to enter the nucleus of Luys, and perhaps to be connected with the continuation of the upper fillet. Antero-laterally this tract may be connected, beyond the basal optic ganglion, with the lenticular nucleus.

## RECENT LITERATURE.

- Ahlborn, F.**, *Ueber die Bedeutung der Zirbeldrüse*, Zeitschr. f. wiss. Zool., Bd. xl., 1884.
- Amaldi, P.**, *Contributo all'anatomia fina della regione peduncolare, &c.*, Rivista sperimentale di freniatria, Vol. xviii., 1892.
- Bechterew, W.**, *Experim. Untersuchungen ü. d. Kreuzung d. Sehnervenfasern im Chiasma*, Neurol. Centralbl., 1883; *Ueber den Verlauf der Sehnervenfasern, &c.*, *ibid.*; *Ueber die nach Durchschneidung der Sehnervenfasern im Innern der Grosshirnhemisphären (in der Nachbarschaft des hinteren Abschnittes der inneren Kapsel) auftretenden Erscheinungen*, Neurol. Centralbl., 1884; *Degenerationen des Hirnschenkels*, Arch. f. Psych., xix., and Neurol. Centralbl., 1885, 1886, and 1887.
- Bellonci, G.**, *La terminaison centrale du nerf optique chez les mammifères*, Arch. ital. de biologie, t. vi., 1885; also in Zeitschr. f. wissensch. Zool., Bd. xlvii., 1888.
- Beraneck, E.**, *Ueber das Parietalauge der Reptilien*, Jenaische Zeitschr. f. Naturw., Bd. xxi., 1887.
- Bernheimer, S.**, *Ueber die Entwicklung u. d. Verlauf der Markfasern im Chiasma, &c.*, Wiesbaden, 1889; *Ue. d. Sehnervenwurzeln des Menschen*, Wiesbaden, 1891; and Verhandl. d. 10ten internat. Congress, Berlin, 1890.
- Burdach, F.**, *Zur Faserkreuzung im Chiasma und in den Tractus nervorum opticorum*, Archiv f. Ophthalmologie, Bd. xxix., 1883.
- Cattie, J. Th.**, *Recherches sur la glande pinéale des plagiostomes, &c.*, Arch. de biologie, t. iii., 1882.
- Cionini, A.**, *Sulla struttura d. ghiandola pineali*, Riv. sperim. di freniatria, 1885 and 1888.
- Darkschewitsch, L.**, *Zur Anatomie d. Corpus quadrigeminum*, Neurol. Centralbl., 1885; *Ueber die hintere Commissur des Gehirns*, *ibid.*, 1885; *Einige Bemerkungen ü. d. Faserverlauf in d. hinteren Commissur*, *ibid.*, 1886; *Zur Anatomie der Glandula pinealis*, Neurol. Centralbl., 1886; *Ueber die Pupillarfasern d. Tractus opticus*, Abstract from the Russian in Neurol. Centralbl., 1887; *Ueber die sogenannten primären Opticus-centren u. ihre Beziehung zur Grosshirnrinde*, Arch. f. Anat. u. Physiol., Anat. Abth., 1886; *Ueber d. Kreuzung der Sehnervenfasern*, Arch. f. Ophth., Bd. xxxvii.; *Ueber den oberen Kern des N. oculomotorius*, Archiv f. Anat. u. Physiol., Anat. Abth., 1889.
- Darkschewitsch, L.**, und **Pribytkow, G.**, *Ueber die Fasersysteme am Boden des dritten Hirnventrikels*, Neurol. Centralbl., 1891.
- Dostoiewsky, A.**, *Ueber den Bau der Vorderlappen des Hirnanhanges*, Archiv f. mikr. Anatomie, Bd. xxvi., 1886.
- Duval, M.**, *Le troisième œil des vertébrés*, Journal de Micrographie, 1888.
- Edinger**, *Ueber einige Fasersysteme des Mittelhirns*, Neurol. Centralbl., 1890.
- Flechsig, P.**, *Weitere Mittheilungen ü. d. Beziehungen d. unt. Vierhügels zum Hörnerven*, Neurol. Centralbl., 1890.
- Flesch**, *Ueber den Bau der Hypophyse*, Tageblatt der 57 Versamml. deutsch. Naturf. u. Aerzte in Magdeburg, No. 4, 1884; *Ueber die Hypophyse einiger Säugthiere*, Tagebl. d. Naturforscherversammlung in Strassburg, 1885.
- Forel, A.**, *Einige hirnanatomische Betrachtungen u. Ergebnisse*, Arch. f. Psych., Bd. xviii., 1887.
- Fürstner**, *Weitere Mittheilung über den Einfluss einseitiger Bulbuszerstörung auf die Entwicklung der Hirnhemisphären*, Archiv f. Psychiatrie, Bd. xii., 1882.
- Ganser**, *Ue. d. periphere u. centrale Anordnung d. Sehnervenfasern u. ueber d. Corpus bigem. anterius*, Archiv f. Psychiatrie, xvi., 1882; *Vergleichend-anatom. Studien ü. d. Gehirn des Maulwurfs*, Morph. Jahrb., Bd. vii., 1882.
- de Graaf, H. W.**, *Zur Anatomie und Entwicklung der Epiphyse bei Amphibien und Reptilien*, Zoolog. Anzeiger, 1886; *Bijdrage tot de kennir van den bouw en de ontwikkeling der epiphyse bij Amphibien en Reptilien*, Leiden, 1886.
- von Gudden**, *Ueber die Kerne der Augenbewegungsnerve; Ueber den Nervenfaserverlauf im Opticus und in der Retina*, Deutsche Naturforscherversammlung zu Salzburg, 1882; *Ueber das Corpus mamillare und den sog. Schenkel der Fornix*, Allg. Zeitschr. f. Psychiatrie, Bd. xli., 1885; *Ueber*



die Sehnerven, die Sehtractus, &c., Tagebl. d. deutsch. Naturforscherversammlung, 1885 (Neurol. Centralbl.); also in *Gesammelte Abhandlungen*.

**Hamilton, D. J.**, *On the cortical connexions of the optic nerves*, Proceedings of the Royal Soc. of London, Vol. xxxvii., 1884.

**Hebold, O.**, *Der Faserverlauf im Sehnerven*, Neurol. Centralbl., 1891.

**Held, H.**, *Der Ursprung des tiefen Markes der Vierhügelregion*, Neurol. Centralbl., 1890.

**Henschen**, *Experimentelle u. patholog. Untersuchungen ü. d. Gehirn*, 2 vols., Upsala, 1890 and 1892.

**Hensen und Voelckers**, *Ueber den Ursprung der Accommodationsnerven, n. Bemerkungen über d. Function d. Wurzeln d. Nervus oculomotorius*, Arch. f. Ophthalm., Bd. xxiv., 1878.

**Honegger, J.**, *Vergleich.-anatom. Untersuchungen über den Fornix, &c.*, Recueil zool. suisse, t. v., 1890.

**Jatzow, R.**, *Beitrag zur Kenntniss der retrobulbaren Propagation des Chorioidealsarkoms und zur Frage des Faserverlaufs im Sehnervengebiet*, Archiv f. Ophthalmologie, Bd. xxxi., 1885.

**Julin, Ch.**, *De la signification morphologique de l'épiphyse (glande pinéale) des vertébrés*, Bullet. scientifique du Nord de la France et de la Belgique, 1887.

**Köppen**, *Ue. d. hintere Längsbündel*, Tagebl. d. deutsch. Naturforscherversamml. in Heidelberg, 1890.

**Leydig, F.**, *Das Parietalorgan der Wirbelthiere*, Zoolog. Anzeiger., 1887.

**Lothringer, S.**, *Untersuchungen an der Hypophyse einiger Säugethiere und des Menschen*, Archiv f. mikr. Anat., Bd. xxviii., 1886.

**Marchand**, *Beitrag z. Kenntniss der homonymen bilateralen Hemianopsie u. d. Faserkreuzung im Chiasma*, Archiv f. Ophthalm., Bd. xxviii., 1882.

**Marchi, V.**, *Sulla struttura dei talami ottici*, Rivista sperim. di freniatria, 1884 and 1887.

**Mingazzini, G.**, *Sur la fine structure de la substantia nigra Soemmeringii*, Archives ital. de biologie, xii., 1889.

**v. Monakow**, *Experimentelle und pathologisch-anatomische Untersuchungen über die Beziehungen der sogenannten Schpähre zu den infra-corticalen Opticocentren und zum N. opticus*, Archiv f. Psychiatrie, Bde. xiv., xvi., xx., xxii., xxiii., xxiv.; and Arch. f. Anat. u. Physiol., Physiol. Abth., 1885.

**Nussbaum, J.**, *Ueber die wechselseitigen Beziehungen zwischen den centralen Ursprungsgebieten der Augenmuskelnerven*, Wiener med. Jahrb., 1887.

**Onodi, A. D.**, *Ueber die Verbindung des Nervus opticus mit dem Tuberculum cinereum*, Internat. Monatsschr. f. Anat. u. Histol., iii., 1886.

**Parinaud, H.**, *Des rapports croisés et directs des nerfs optiques avec les hémisphères cérébraux*, Comptes rendus de la Soc. de la biol., 1882.

**Pemberton, H. R.**, *Recent investigations on the structure and relations of the optic thalami*, Journal of Comp. Neurology, i., 1891.

**Perlia**, *Die Anatomie des Oculomotoriuscentrums beim Menschen*, Archiv f. Ophthalmol., Bd. xxxv., 1889.

**Richter**, *Zur Frage der optischen Leitungsbahnen des menschlichen Gehirns*, Arch. f. Psychiatrie, Bd. xvi., 1885.

**Ritter, W. E.**, *The parietal eye in some Lizards, &c.*, Bull. of the Museum of Comp. Zool. at Harvard College, xx., 1891.

**Singer, J. u. Münzer, F.**, *Beitr. zur Kenntniss der Sehnervenkreuzung*, Wiener Denkschriften, Abth. iii., Bd. lv., 1888.

**Spencer, W. Baldwin**, *Preliminary Communication on the Structure and Presence in Sphenodon and other Lizards of the Median Eye described by von Graaf in Anguis fragilis*, Proceedings of the Roy. Soc., vol. xl., 1886; *On the Presence and Structure of the Pineal Eye in Lacertilia*, Quart. Journ. of Micr. Science, Oct., 1886.

**Spitzka, E. C.**, *Contrib. to the Anatomy of the Lenniscus*, The Medical Record, 1884; *Vorläufige Mittheilung ü. einige Resultate, hauptschl. d. Commissura posterior betreffend*, Neurol. Centralbl., 1885.

**Staufenglie, C.**, *Contrib. alla ricerca d. decorso n. fibre d. chiasma ottico*, R. Instit. Lombardo di sci. e lettere, xvi., 1891.

**Stilling, J.**, *Untersuchungen über den Bau der optischen Centralorgane, I. Theil; Chiasma und Tractus opticus*, 1882.

**Tartuferi, F.**, *Sull' anatomia minuta d. eminenze bigemine anteriori dell' uomo*, Mem. prem. d. R. Istituto Lombardo di Milano, 1885; *Sull' anatomia minuta delle eminenze bigemine anteriori dell' uomo*, Archivio italiano per le malattie nervose, 1885.

**Tartuffi**, *Tratto ottico en corpi genicolati*, Rivista sperimentali di freniatria, 1882.

**Westphal, C.**, *Ueber einen Fall von chronischer progressiver Lähmung der Augenmuskeln nebst Beschreibung von Ganglienzellengruppen im Bereiche des Oculomotorius-Kernes*, Archiv f. Psychiatrie, B.l. xviii., 1887; *Ueber Ganglienzellengruppen im Niveau des Oculomotorius-Kernes*, Neurol. Centralbl., 1887.

**Williamson, R. T.**, *The changes in the optic tracts and chiasma in a case of unilateral optic atrophy*, Brain, 1892.

**Zacher, Th.**, *Beitr. zur Kenntniss d. Faserverlaufs im Pes Pedunculi, &c.*, Arch. f. Psych., Bd. xxii., 1891.

THE LATERAL VENTRICLES AND THE PARTS OF THE BRAIN  
DEVELOPED IN CONNEXION WITH THEM: CORPORA STRIATA:  
CEREBRAL HEMISPHERES (PROSENCEPHALON).

**The lateral ventricles; ventricles of the cerebral hemispheres.**—An aperture (foramen of Monro) which has been already mentioned as opening out of the anterior part of the third ventricle (see p. 97) leads on each side into the corresponding ventricle of the cerebral hemisphere or lateral ventricle (figs. 88, 89). Each lateral ventricle is an irregularly curved cavity, extending in the substance of the corresponding hemisphere for about two-thirds of its entire length, and lined by a prolongation of the ciliated epithelium which characterises the inner surface of the true brain-ventricles. It may be described as consisting of a *body*, an *anterior horn*, a *posterior horn*, and a *middle, lateral, or descending horn*. The anterior horn curves from the foramen of Monro somewhat outwards, with a slight inclination downwards into the frontal lobe; the body comprises that part of the cavity which extends from the foramen of Monro to its bifurcation into posterior and descending horns opposite the splenium of the corpus callosum, and is separated anteriorly from its fellow of the opposite hemisphere by a thin septum, the *septum lucidum*; the posterior horn passes backwards, with a bold curve convex outwards, into the occipital lobe; and the descending horn passes forwards and slightly downwards also in a bold curve with its convexity outwards, into the temporal lobe, and extends to about an inch from the apex of that lobe. The anterior horn is directly continued from the body of the ventricle, and may therefore be described along with it.

The **body and anterior horn of the ventricle** are roofed over by the corpus callosum, with its lateral extension into the substance of the hemisphere. In examining the ventricles from above it is usual to slice the brain horizontally down to the level of the callosum, and then to cut through this commissure a short distance on each side of the middle line, and remove it sufficiently to expose the interior of the ventricle. The following parts are thereby brought to view, from within, outwards, or laterally: (*a*) The edge of the **fornix** (figs. 88, 89, *f*), a flattened tract of white matter with longitudinal fibres, which lies immediately under the callosum, broadening behind as it passes under the splenium, and bifurcating in front into two cylindrical bundles, each of which passes over the foramen of Monro, and in front of that foramen into the mesial part of the subthalamie tegmentum. (*b*) If the callosum and fornix are removed, a layer of pia mater is seen underneath. This is the **velum interpositum** (fig. 94), and its edge projects as the **choroid plexus of the lateral ventricle** from beneath the margin of the fornix in the form of a vascular fringe (figs. 88, 89, *pl. ch.*), which extends from the foramen of Monro (at the back of which it is continuous with the corresponding plexus of the opposite side as well as with those of the third ventricle) over the surface of the thalamus, as far as the descending cornu, into which it projects along the whole length of the horn (mesial border). (*c*) Lateral and anterior to the choroid plexus two masses of grey matter, separated by an obliquely-placed white stria, form the floor of the ventricle. The mesial and narrower of these is a part of the dorsal surface of the thalamus (fig. 88, *th. opt.*); it extends from the foramen of Monro to the posterior limit of the body of the ventricle and is covered with a thin layer of white matter. The white stria is the *tænia semicircularis* or *stria terminalis* (fig. 82, *St.*). A vein (*vein of the corpus striatum*) runs superficial to the tænia, and passes in front, at the foramen of Monro, into the vein of Galen of the velum interpositum. Close to the ependyma and lying over this vein of the corpus striatum is a small greyish band, containing longitudinally running nerve-fibres: this has been named the *lamina cornea*. The lateral mass of



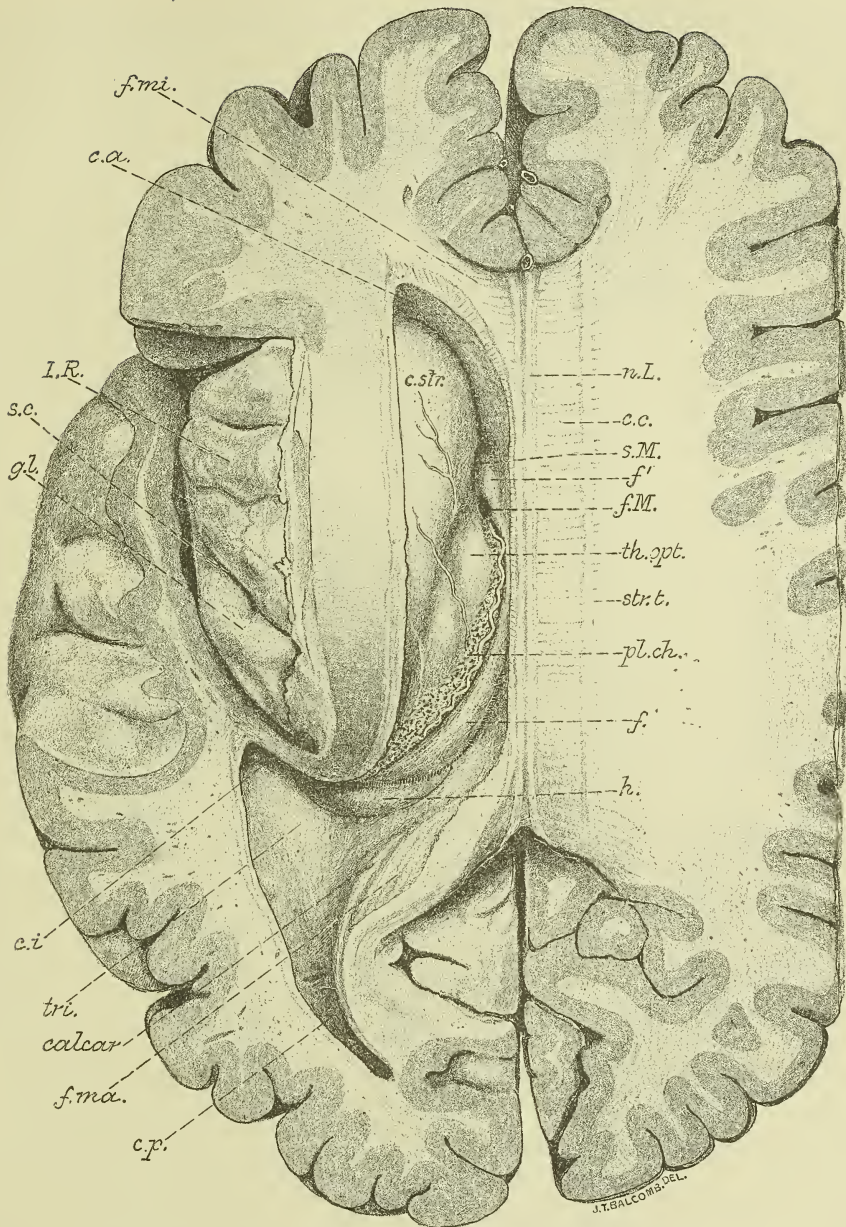


Fig. 88.—VIEW OF THE LATERAL VENTRICLE FROM ABOVE. Natural size. (E. A. S. and G. D. T.)

The preparation was made with the brain *in situ* (hardened). The skull cap and membranes having been removed, the brain was sliced down to the level of the corpus callosum. The left lateral ventricle was then opened by cutting away its roof, and the island exposed by slicing away the opercula. The drawing is made from a photograph.

*I.R.*, insula Reilii (the line points to the middle of the three gyri breves); *s.c.*, sulcus centralis insulae; *g.l.*, gyrus longus insulae; *c.c.*, corpus callosum; *n.L.*, nerves of Lancisi; *str.t.*, stria tecta; *f.mi.*, forceps minor; *f.ma.*, forceps major; *c.a.*, cornu anterius of ventricle; *c.p.*, cornu posterius; *c.i.*, entrance to cornu inferius; *f.M.*, foramen Monroi; *s.M.*, sulcus leading backwards to the foramen Monroi; *c.str.*, corpus striatum; *th.opt.*, thalamus opticus, anterior tubercle; *pl.ch.*, plexus choroides; *f.*, fornix; *f'*, its anterior pillar; *h.*, posterior end of hippocampus major; *tri.*, trigonum ventriculi; *calcar*, calcar avis.



grey matter is the *nucleus caudatus of the corpus striatum (c. str.)* It is pear-shaped, with the larger end projecting into the floor of the anterior horn, and the smaller tapering posterior end (tail) extending to the origin of the descending horn, and then curving downwards and forwards along the dorsal part of this horn, in which it forms a long, narrow, rounded eminence. The **posterior horn** (figs. 88, 89, *c.p.*), which is curved around the parieto-occipital fissure, its concavity therefore being directed inwards, passes, as before said, into the occipital lobe. It is roofed by the fibres of the corpus callosum which are passing to the temporal and occipital lobes : part of these fibres also form its lateral wall. At the upper part of its mesial wall there is a bundle of fibres (forceps major) sweeping round from the splenium of the callosum to enter the occipital lobe. This produces a projection into the cavity of the horn, which is known as the *bulb of the posterior horn*. Below it is another curved eminence, which extends from the base of the horn backwards for a variable distance, to end in a pointed extremity : this is termed, from its resemblance to a cock's spur, the *ergot* (Morand), or *calcar avis* (also *hippocampus minor*). It corresponds with the calcarine fissure on the mesial surface of the hemisphere.

The hippocampus minor is not peculiar to the human brain as was at one time thought, but is found in the brains of quadrumana. In the human subject the posterior horn varies greatly in size, and the hippocampus minor is still more variable in its development, being sometimes scarcely to be recognised, and at others proportionally large. It is usually most developed where the posterior horn is longest ; but the length of the posterior horn, and prominence of the hippocampus minor, are by no means in proportion to the dimensions of the hemisphere.

The **middle, lateral, or descending horn** (fig. 89) is directed at first backwards and outwards from the posterior end of the body of the ventricle ; it then passes downwards and forwards with a bold sweep (at about the plane of the parallel sulcus), being finally curved inwards, and ending about an inch from the apex of the temporal lobe, where it abuts against the amygdala. The dorso-lateral boundary (roof) is formed by the fibres of the callosum, which are arching over it into the temporal lobe, forming the so-called *tupelum*. The tail of the nucleus caudatus and the tænia semicircularis are prolonged into the roof. Extending along the floor of the horn is an eminence known as the *hippocampus major* or *cornu Ammonis* (fig. 89, *h*), which becomes enlarged as it descends, and being notched, its edge here presents a certain resemblance to an animal's paw (*pes hippocampi*). This eminence corresponds with the hippocampal fissure externally, which thus indents the floor of the cornu, and the grey matter at the bottom of the fissure being separated from the cavity of the ventricle by a thin layer of white substance (covered with ependyma), shews through and gives a bluish-white appearance to the hippocampus. Mesial to the hippocampus is the white band known as the fimbria (fig. 89, *fi*), prolonged from the posterior pillar of the fornix ; and over the fimbria, at the angle which the floor of the horn here forms with its roof, the choroid plexus projects into the cavity from the external pia mater ; the plexus is, however, covered by the epithelial lining of the cavity which extends over it in passing from roof to floor. If the pia mater is pulled away it drags along with it this covering layer of epithelium, and the cornu is made to open on the mesial surface of the brain. A cleft-like opening is thus produced, which has been called the *inferior fissure of the cerebrum*, being the lower part of the so-called *transverse fissure*, which follows the plane of the velum interpositum (see p. 184) over the thalamus and third ventricle, and emerges over the corpora quadrigemina. It is along this fissure that the choroid plexuses of the pia mater are invaginated into the ventricles, covered by the ventricular epithelium, which is pushed in before them. It is only when the choroid plexuses are dragged away that an actual fissure is formed in the hemisphere-wall between the fornix and fimbria on the one side and the optic thalamus on the other ; but with the

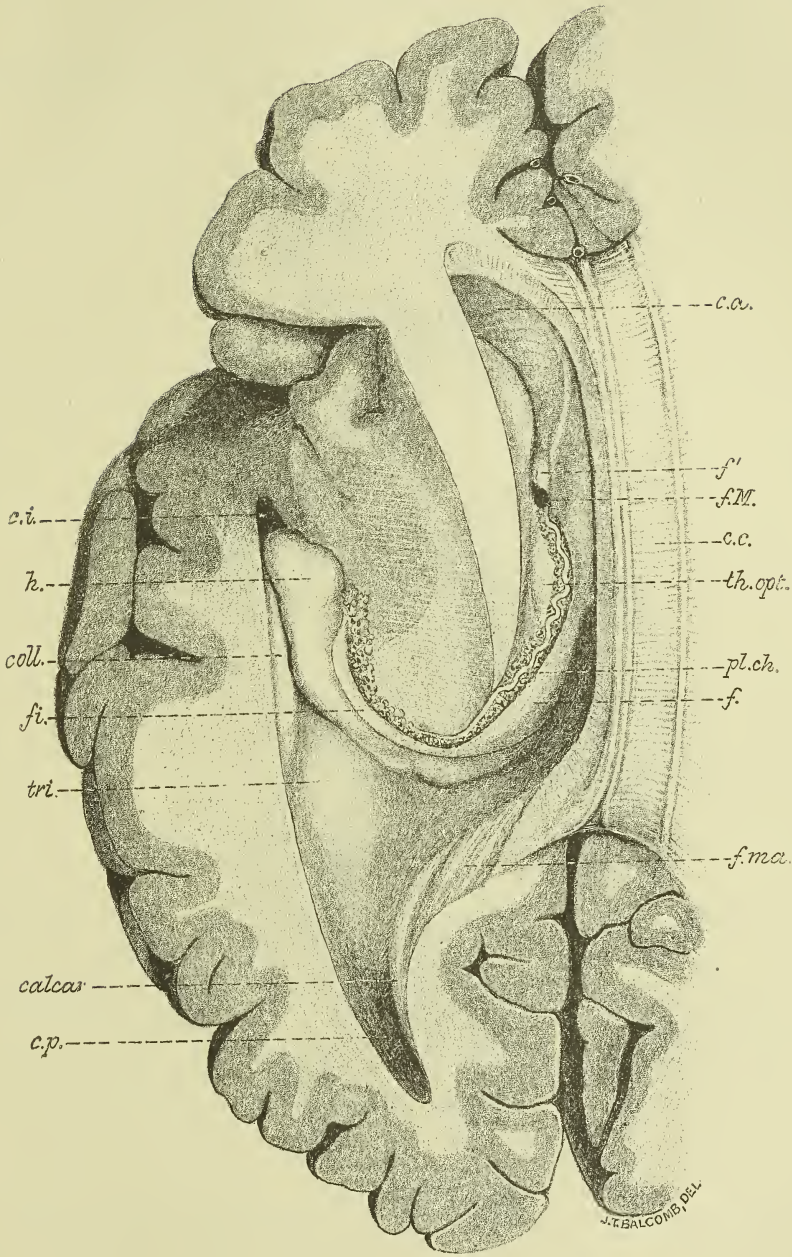


Fig. 89.—VIEW FROM ABOVE AND THE SIDE OF THE WHOLE LEFT LATERAL VENTRICLE.  
 Natural size. (E. A. S. and G. D. T.)

This is a further dissection of the preparation shown in fig. 88. The insula has been sliced away and the middle or descending cornu, *c.i.*, exposed. Within this are seen the following parts: *f'*, fimbria, continued from the fornix; *h*, the hippocampus major; *coll.*, the eminentia collateralis. The other lettering as in fig. 88.

plexus *in situ* it is a deep sulcus, *i.e.*, an invagination only, of the thin hemisphere-wall (here formed of the ventricular epithelium alone). It is known as the *choroidal fissure*, and appears at an early period of embryonic development.

Merkel and Mierzejewsky have described an actual cleft in the pia mater along the descending horn which effects a communication between the ventricle and the subarachnoid space, analogous to the foramen of Majendie and the lateral apertures in the fourth ventricle. This observation has not hitherto been confirmed.

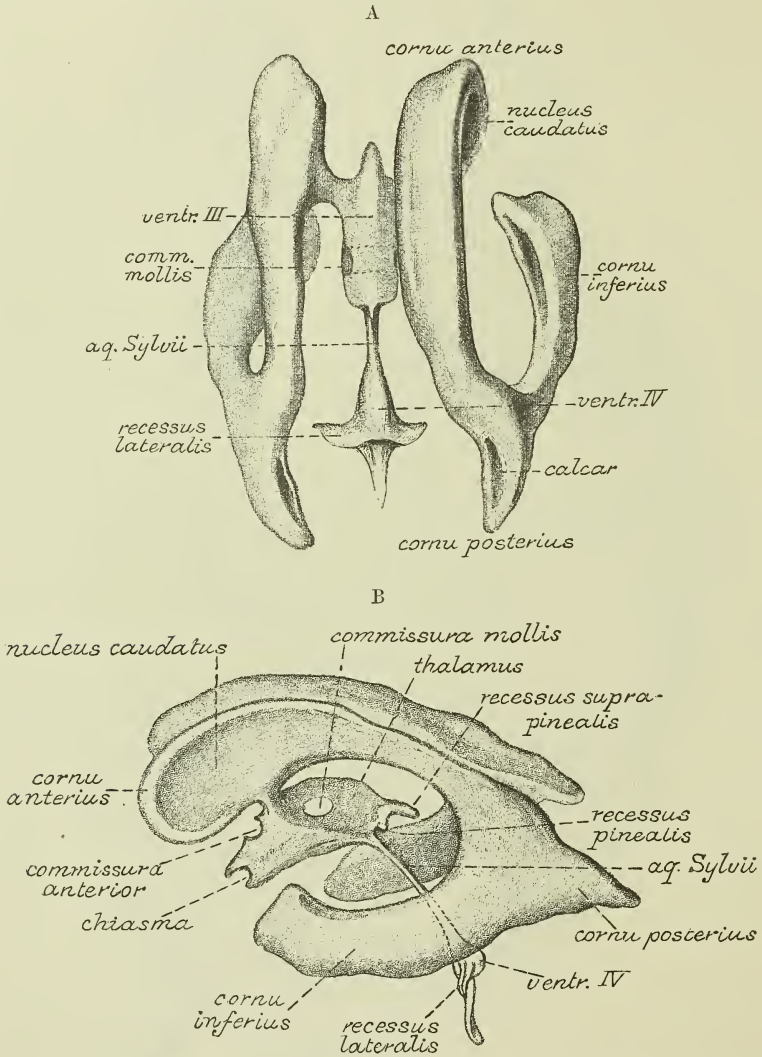


Fig. 90.—Two views of a PLASTER CAST OF THE CAVITIES OF THE CEREBRAL VENTRICLES. (After Welcker.)

A, from above; B, from the side. The projections into the cavities of the structures which bound the ventricles are seen as impressions upon the cast.

At the junction of the descending with the posterior cornu, and occupying the angle between the hippocampus major and the calcar, is a triangular space, the floor of which is mainly occupied by a smooth, somewhat raised surface, which extends backwards into the posterior cornu, and is often continued downwards into a longitudinal eminence which passes for some distance in the inferior horn alongside



of and lateral to the hippocampus major. This eminence corresponds with the collateral fissure externally, and is known as the *eminencia collateralis* or *pes accessorius* (fig. 89, *coll.*); this term is also by some authors used to include the smooth eminence at the junction of the cornua. The triangular space at this junction is termed by Schwalbe *trigonum ventriculi*.

The shape of the ventricles is best shown in a cast of the cavities, which can be made in plaster of Paris. The appearance of such a cast, viewed respectively from above and from the side, is given in the accompanying figure (fig. 90, A, B).

The **corpus callosum** or **great commissure** (*trabs cerebri*) (figs. 91, 92, 102), a white structure, about 10 centimeters long, which connects the two hemispheres throughout nearly half their length, approaches closer to the front than the back of

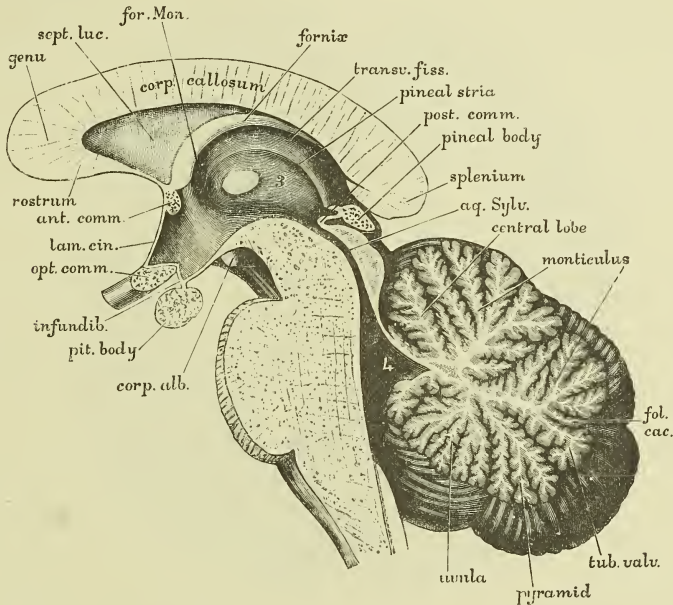


Fig. 91.—PORTION OF A MEDIAN SECTION OF THE BRAIN, SHOWING THE CORPUS CALLOSUM, THIRD VENTRICLE, AQUEDUCT AND FOURTH VENTRICLE, PONS, CEREBELLUM, ETC. (G. D. T.)  $\frac{3}{4}$ .

the hemispheres. It is about 20 mm. in width behind, and somewhat narrower in front. Its thickness is greater at the ends than in the middle, and is greatest behind (8 mm.). It is arched from before backwards, its lower surface being concave and its upper surface convex. Its upper surface is distinctly marked by transverse furrows, which indicate the direction of the greater number of its fibres. It is also marked in the middle by a longitudinal furrow (*raphe*), which is bounded by two white tracts, placed close to each other, named the *mesial longitudinal stria* or *nerves of Lancisi* (fig. 88). On each side, near the margin, are seen other longitudinal lines (*grey* or *lateral longitudinal stria*). The lateral striæ lie within a fissure (*callosal fissure*) which separates the upper surface of the commissure from the gyrus fornicatus (by which convolution they are entirely covered in: hence the name, *tenie tectæ*, which is often applied to them). Both the mesial and lateral longitudinal striæ are traceable, when well developed, into the gyrus dentatus posteriorly. The morphological value of these structures will be afterwards referred to (p. 155).

In front, the corpus callosum is reflected downwards and backwards, forming a

bend named the *genu* (fig. 91). The inferior or reflected portion, which is named the *rostrum*, becomes gradually narrower as it descends, and is connected with the lamina cinerea by a thin white layer, the *commissura baseos alba* of Henle. It gives off also two bands of white substance, the *peduncles of the corpus callosum*, which, diverging from one another, run backwards across the posterior margin of the anterior perforated space on each side to the tip of the temporal lobe, where they meet the inner olfactory roots. These peduncles traced upwards around the genu are found to be continued into the mesial longitudinal striæ.

Behind, the corpus callosum terminates in a free thickened border, named the *splenium*, but this term is sometimes restricted to the under part of this thickened border, which appears as if rolled round under the rest (*splenium proper*, Beevor).

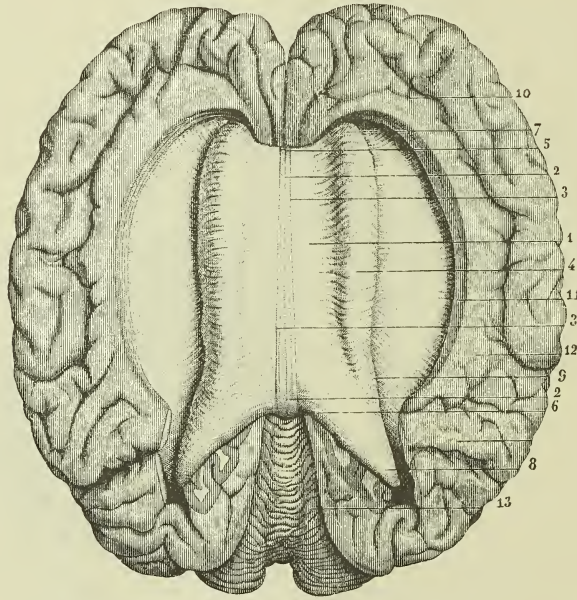


Fig. 92.—VIEW OF THE CORPUS CALLOSUM FROM ABOVE (from Sappey after Foville).  $\frac{1}{2}$

The upper surface of the corpus callosum has been fully exposed by separating the cerebral hemispheres and throwing them to the side; the gyrus fornicatus has been partly detached, and the transverse fibres of the corpus callosum traced for some distance into the cerebral medullary substance.

1, the upper surface of the corpus callosum; 2, median furrow or raphe; 3, longitudinal striæ bounding the furrow; 4, swelling formed by the transverse bands as they pass into the cerebrum, arching over the side of the lateral ventricle; 5, anterior extremity or knee of the corpus callosum; 6, posterior extremity; 7, anterior, and 8, posterior fibres proceeding from the corpus callosum into the frontal and occipital lobes respectively; 9, margin of the swelling; 10, anterior part of the gyrus fornicatus; 11, fissure between the corpus callosum and this convolution opened out; outside 12, is the termination of the calloso-marginal fissure, and before 13 is the parieto-occipital fissure; 13, upper surface of the cerebellum.

The mesial part of the under surface of the corpus callosum is connected behind with the fornix, and in the rest of its length with the septum lucidum, a vertical partition between the two lateral ventricles, which is included in the anterior bend of the corpus callosum. On the sides the corpus callosum roofs in the body and anterior horn of the lateral ventricles. The enlarged posterior part or splenium lies over the mesencephalon, with pia mater between. The transverse fibres of the corpus callosum pass in a radiating manner, interlacing with those of the internal capsule, through the medullary centre to the cortex of each hemisphere. Those in front which sweep round into the prefrontal region form the so-called *forceps minor*.

Those from the body and the upper part of the splenium which curve over the lateral ventricle form the *lapetum*, whilst a large mass of fibres from the splenium proper curves round into each occipital lobe and is known as the *forceps major*.

The **septum lucidum** (fig. 91, *sept. luc.*), a thin double partition, separates the anterior part of the two lateral ventricles. It is composed of two distinct laminæ, having an interval between them (*ventricle of the septum*) which contains fluid probably of the nature of lymph. It occupies the interval between the corpus callosum above and in front, and the anterior part of the fornix behind (fig. 91); and gradually tapers backwards to end over the middle of the third ventricle, from which it is separated by the fornix and velum interpositum. Antero-inferiorly it extends downwards in an angle which reaches the anterior commissure.

The laminæ of the septum are formed of a part of the mesial wall of the hemispheres which has remained free, while the surrounding parts have become united by the development of the corpus callosum above and in front and the fornix below and behind. The ventricle of the septum was therefore originally a part of the great longitudinal fissure, and has no connection with the internal ventricular cavity of the brain. Accordingly we find that it is not lined by ciliated epithelium, but each lamina consists of a thin layer of grey matter next to the cavity, and homologous with the grey matter of the cerebral cortex, and a thicker layer of white matter continuous below on either side with the general white matter of the hemisphere. Externally, next to the lateral ventricle, is a layer of ependyma, and covering this the epithelium which lines the lateral ventricle; internally is a layer of connective tissue, homologous with the pia mater.

The **fornix** (fig. 91, *f*) is an arched longitudinal white tract consisting of two lateral halves, which are separated from each other in front and behind, but in the intermediate part are joined together in the median plane. The two parts in front form the *anterior pillars* (*columnæ fornicis*); the middle conjoined part is named the *body*; and the hind parts, which are again separated from each other, form the *posterior pillars* (*crura fornicis*).

The *body* of the fornix is triangular in shape, being broad and flattened behind, where it is adherent to the under surface of the callosum, and narrower in front, where it is attached to the septum lucidum. Its lateral edges are free and are seen projecting into the lateral ventricles just above the choroid plexuses. Its under surface rests upon the velum interpositum, which separates it from the optic thalami and the third ventricle (fig. 94).

Beever distinguishes (in the monkey) two sets of fibres in the body of the fornix. Of these, the mesial set, when traced backwards, appear to turn dorsally and pierce the corpus callosum just in front of the splenium; above the corpus callosum they may perhaps join the posterior fibres of the cingulum (see p. 158), but their actual destination has not been certainly followed out.

The *anterior pillars* (fig. 82, *Cf*), cylindrical in form, can be traced downwards, slightly separated from each other, in front of the foramina of Monro, of which they form the anterior boundaries, and through the grey matter on the sides of the third ventricle, curving backwards to the corpora albicantia. There each column turns upon itself, making a twisted loop which forms the white portion of the corpus albicans, and from this it appears to be continued, as the *bundle of Vicq-d'Azyr*, upwards into the anterior nucleus of the optic thalamus (fig. 93). Each pillar is connected near the foramen of Monro with the stria pinealis (*tænia fornicis*), and with the *tænia semicircularis*, and it gives fibres to the septum lucidum (for other connections of the anterior pillar, see p. 158).

According to the experiments of Gudden and Forel the fibres of the anterior



pillars find a termination in the grey matter of the corpora albicantia, and are not directly continuous, as in dissected preparations they seem to be, with the bundle of Vicq-d'Azyr.

The *posterior pillars* or *crura* of the fornix (fig. 94, 13) are the diverging posterior prolongations of the two flat lateral bands composing the body. At first

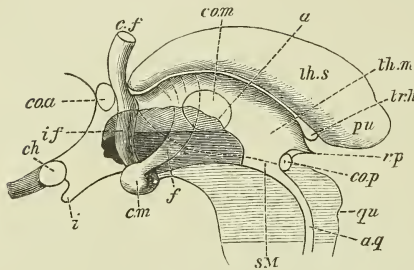


Fig. 93.—SKETCH SHOWING THE ORIGIN AND CONNECTIONS OF THE ANTERIOR PILLARS OF THE FORNIX. (Schwalbe.)

A median section has been made through the third ventricle, and the superficial grey matter removed at its anterior and lower part as far as *a*. *th.s*, upper part of the thalamus; *th.m*, its mesial surface: between the two is the medullary stria, leading from the pineal gland and trigonum habenule, *tr.h*, to the anterior pillar of the fornix, *c.f*; *f*, bundle of Vicq-d'Azyr; *cm*, corpus mamillare; *i.f*, fibres of the inferior peduncle of the thalamus diverging in its substance; *co.a*, anterior commis-

sure; *co.m*, middle commissure; *ch*, chiasma; *i*, infundibulum; *r.p*, stalk of pineal body; *qu*, corpora quadrigemina; *aq*, aqueduct.

they adhere to the under surface of the corpus callosum, then, curving outwards and downwards over the pulvinar of the optic thalamus, each crus enters the descending horn of the lateral ventricle, where some of its fibres are distributed on the surface of

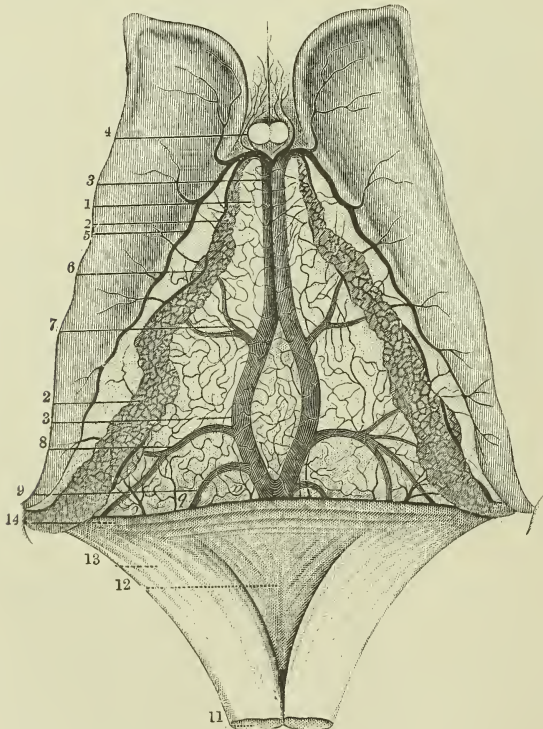


Fig. 94.—VIEW OF THE UPPER SURFACE OF THE VELUM INTERPOSITUM, CHOROID PLEXUSES, AND CORPORA STRIATA. (From Sappey after Vicq-d'Azyr.)  $\frac{3}{2}$

1, fore part of the tela choroidea or velum interpositum; 2, 2, choroid plexus; 3, 3, left vein of Galen partly covered by the right; 4, anterior pillars of the fornix divided in front of the foramen of Monro; on either side are seen small veins from the front of the corpus callosum and the septum lucidum; 5, vein of the corpus striatum; 6, convoluted marginal vein of the choroid plexus; 7, vein rising from the thalamus opticus and corpus striatum; 8, vein proceeding from the inferior cornu and hippocampus major; 9, one from the posterior cornu; 11, fornix divided near its middle and turned backwards; 12, lyra; 13, posterior pillar of the fornix; 14, the splenium of the corpus callosum.

the great hippocampus and the remainder are prolonged as the narrow band of white matter known as the *tenia hippocampi* or *fimbria* (fig. 89, *fi*).

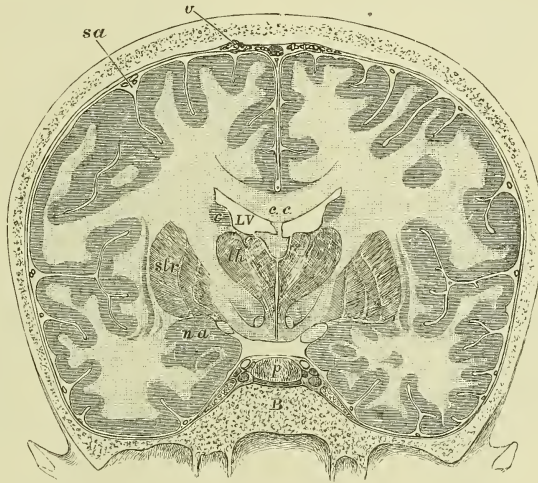On examining the under surface of the conjoined posterior parts of the fornix and corpus callosum, the splenium of the latter with its thickened edge and the diverging halves of the fornix appear to enclose between them a triangular structure, marked with transverse, longitudinal, and oblique lines. To this part the term *lyra* has been applied

(fig. 94, 12). This contains a few fibres which pass across from one posterior pillar of the fornix into the other, and are considered to form a commissural connexion between the two hippocampal regions of opposite sides. This connexion is denied by Beevor (in the monkey).

The **tænia semicircularis** is a band of white matter which lies in the groove separating the ventricular surface of the nucleus caudatus from that of the optic thalamus. It extends from the extremity of the descending horn of the lateral ventricle, where it passes into the nucleus amygdalæ, to the anterior part of the body of the ventricle, as far as the foramen of Monro, having a curved course corresponding with that of the ventricle. Its anterior connexions are somewhat obscure, but, according to Schwalbe and Testut, it divides anteriorly into two parts, one of which is continued into the anterior pillar of the fornix, and the other passes over and in front of the anterior commissure to become lost in the grey matter which

Fig. 95. — CORONAL SECTION THROUGH THE BRAIN AND SKULL MADE WHILST FROZEN. (Key and Retzius.)

*c, c*, corpus callosum; below its middle part the septum lucidum, and below that again the fornix; *LV*, lateral ventricle; *th*, thalamus; between the two thalami the third ventricle is seen; below the thalamus is the substantia innominata; *str*, lenticular nucleus of the corpus striatum; *c*, caudate nucleus of the same; between *th* and *str* is the internal capsule; outside *str* is the thin grey band of the claustrum, and outside this again the island of Reil at the bottom of the Sylvian fissure; *n, a*, nucleus amygdalæ; immediately within this is the optic tract seen in section; *p*, pituitary body; *B*, body of the sphenoid bone; *sa*, subarachnoid space; *v*, villi of the arachnoid.



intervenes between the septum lucidum and the anterior end of the nucleus caudatus: some fibres perhaps penetrating into that nucleus. According to Foville, each extremity is ultimately traceable into the anterior perforated space.

The **corpora striata** (*ganglia of the cerebral hemispheres*), situated in front and to the outer side of the optic thalami, are two large ovoid masses of grey matter, the greater part of each of which is embedded in the white substance of the hemisphere (extraventricular portion), whilst a part becomes visible in the body and anterior horn of the lateral ventricle (intraventricular portion). The corpus striatum derives its name from the streaked appearance it presents, especially in its anterior part, when cut into, an appearance which is due to the passage through it of bundles of white fibres of the internal capsule to the frontal lobe of the hemisphere.

The **nucleus caudatus** (*intraventricular portion of the corpus striatum*) (fig. 82, *Cs.*; fig. 88, *c.str.*), is of pyriform shape, its larger end being turned forwards and appearing in the floor and partly in the lateral wall of the anterior horn. This enlarged anterior extremity projects into the white matter of the frontal lobe, where it is bounded by the fibres which pass from the genu of the callosum. Its narrow end is prolonged backwards and outwards along the body of the ventricle and into the roof of the descending horn, passing nearly to the extremity of the latter. The caudate nucleus is separated from the thalamus by the tænia semicircularis. Where it lies in the lateral ventricle (superior surface) the nucleus caudatus is covered by a



layer of ependyma and over this by the ciliated ventricular epithelium. The ganglion is itself composed of a reddish grey substance like that of the outer zone of the lenticular nucleus (see below). On the deeper side, that turned towards the internal capsule, the nucleus receives from this a number of bundles of medullated fibres which are traceable from the crusta. According to Wernicke it is doubtful if any of these pass on to the white matter of the hemispheres, nor do they come from the

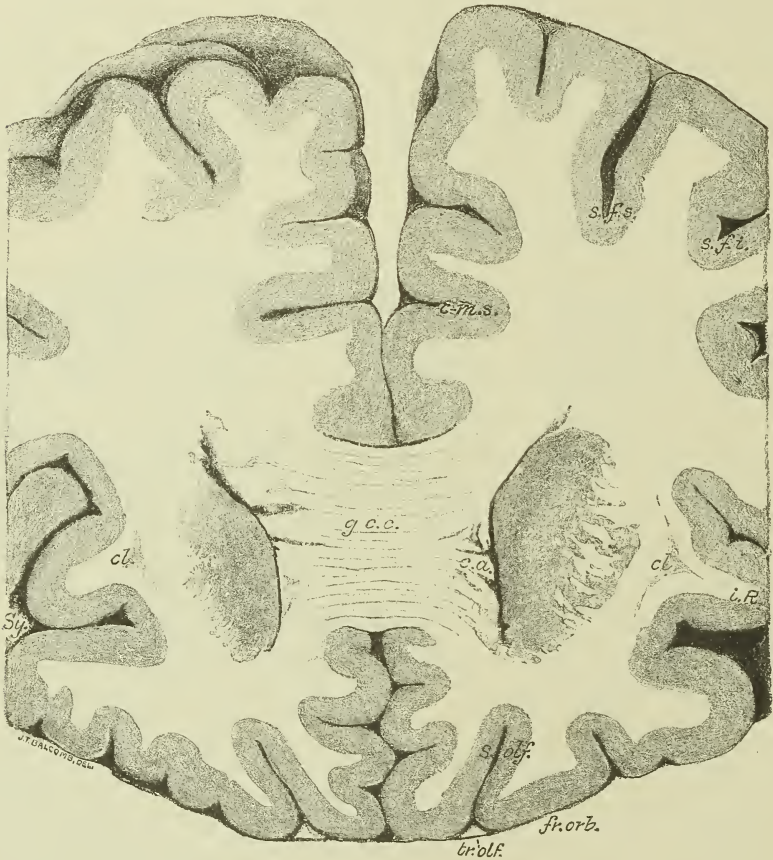

Fig. 96.—VIEW FROM BEHIND OF A FRONTAL SECTION OF THE HEMISPHERES PASSING THROUGH THE GENU OF THE CORPUS CALLOSUM. (E. A. S.) From a photograph.

*g.c.c.*, genu corporis callosi; *c.a.*, cornu anterius of lateral ventricle bounded laterally by the grey mass of the corpus striatum; *cl.*, claustrum; *i.R.*, insula; *Sy.*, Sylvian fissure; *c-m.s.*, sulcus callosomarginalis; *s.f.s.*, sulcus frontalis superior; *s.f.i.*, sulcus precentralis; *s.olf.*, sulcus olfactorius; *fr.orb.*, orbital surface of frontal lobe; *tr.olf.*, tractus olfactorius in section.

The section passes a little more anteriorly through the left hemisphere than through the right.

crusta directly, but only after traversing the medullary laminae of the lenticular nucleus (see below).

The nerve-cells of the nucleus caudatus are multipolar, and, in the adult, pigmented. Some are moderately large, but most small, belonging to Golgi's second type, with short axis-cylinder process (Marchi). Their nerve-processes pass in various directions, some into the internal capsule. In addition, peculiar spheroidal cells containing two or more nuclei were described by Henle.

The **nucleus lenticularis** (*extraventricular portion of the corpus striatum*) is separated in the greater part of its extent from the intraventricular part by a layer



of white substance (*internal capsule*), but is united with it in front, where it is pierced, as just stated, by the fibres passing to the frontal lobe. The lenticular nucleus is only seen in sections of the hemisphere. Its horizontal section (fig. 99, *n.l*)

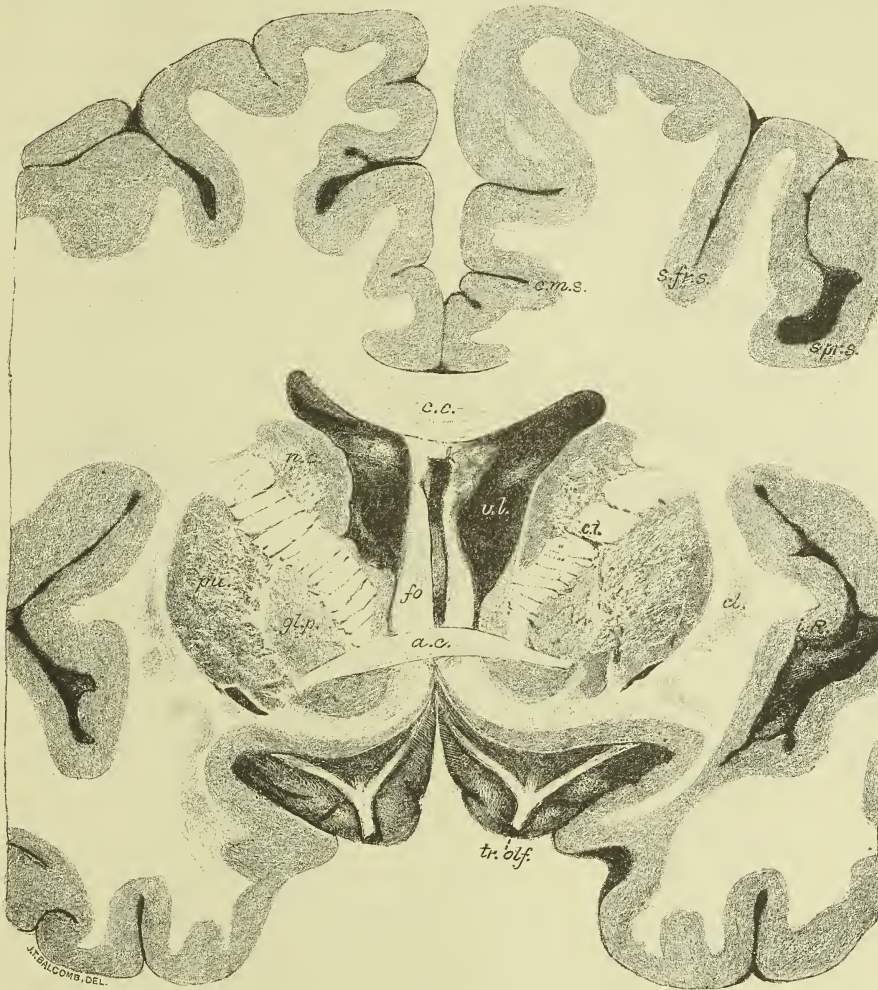


Fig. 97.—VIEW FROM BEHIND OF A FRONTAL SECTION OF THE HEMISPHERES PASSING THROUGH THE MIDDLE OF THE ANTERIOR COMMISSURE. (E. A. S.) From a photograph.

*c.c.*, corpus callosum; *fo.*, anterior pillars of the fornix with the anterior extremity of the third ventricle between them; *v.l.*, lateral ventricles; *a.c.*, anterior commissure; *n.c.*, nucleus caudatus; *gl.p.*, globus pallidus and *pu.*, putamen, of nucleus lenticularis; *c.l.*, between the nucleus caudatus and nucleus lenticularis, the internal capsule; *cl.*, claustrum; *i.R.*, insula; *c.m.s.*, sulcus callosomarginalis; *s.fr.s.*, sulcus frontalis superior; *s.pr.s.*, sulcus precentralis superior; *tr.olf.*, tractus olfactorius passing to the anterior perforated space and giving off its mesial, lateral, and middle roots.

somewhat resembles that of a biconvex lens, being wider in the centre than at either end, but larger anteriorly than posteriorly. It is less extensive than the caudate nucleus, which projects beyond it at either end. The antero-posterior diameter corresponds closely with that of the central lobe of the hemisphere, or island of Reil, and the greatest width is opposite the anterior edge of the optic thalamus. On a

transverse vertical section through the middle (figs. 97 and 98), this nucleus appears triangular, having a *lateral*, a *mesial* and an *inferior surface*, facing respectively the external capsule, the internal capsule, and the base of the brain. Two white lines (*medullary laminae*), parallel to the lateral border, divide it into three zones, of which the outer (*putamen*, Burdach, figs. 97, 98, *pu.*) is the largest and of a dark

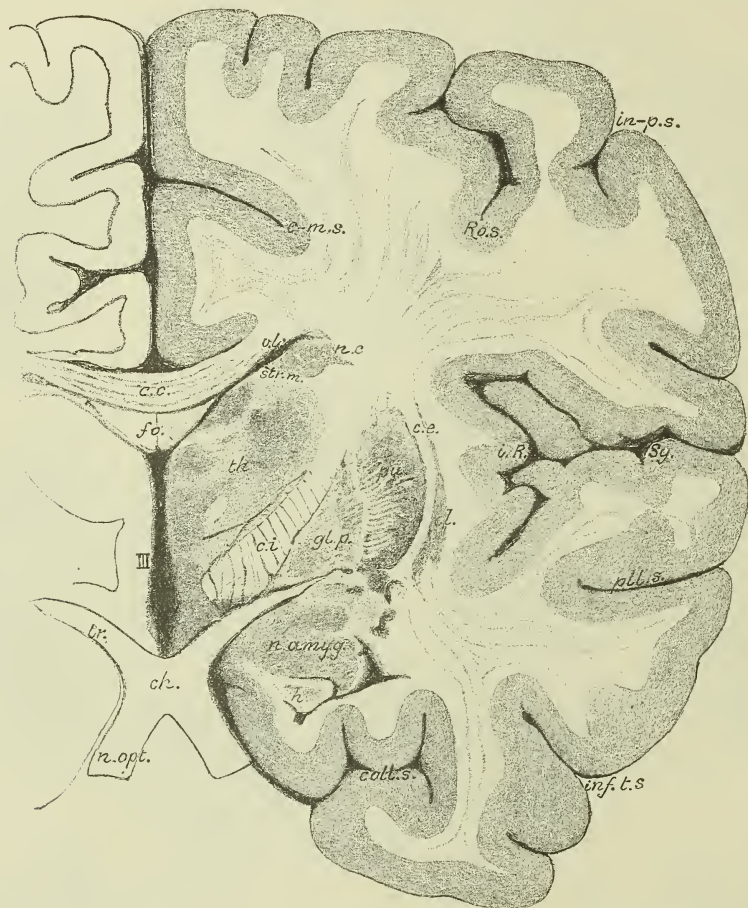


Fig. 98.—VIEW FROM BEHIND OF A FRONTAL SECTION THROUGH THE RIGHT HEMISPHERE TAKEN JUST BEHIND THE OPTIC CHIASSMA. (E. A. S.) From a photograph.

*c.c.*, corpus callosum; *fo.*, body of fornix; *III*, third ventricle; *v.l.*, lateral ventricle; *n.c.*, nucleus caudatus; *str.m.*, stria medullaris; *th.*, thalamus; *c.i.*, internal capsule; *gl.p.*, globus pallidus; *pu.*, putamen; *c.e.*, external capsule; *cl.*, claustrum; *i.k.*, insula; *n.amyg.*, nucleus amygdalæ; *h.*, anterior end of hippocampus major projecting into the descending cornu of the lateral ventricle; *tr.*, optic tract; *ch.*, optic chiasma; *n.opt.*, optic nerve; *c-m.s.*, callosomarginal sulcus; *Ro.s.*, Rolandic sulcus; *in-p.s.*, intraparietal sulcus; *Sy.*, Sylvian fissure; *pll.s.*, parallel fissure; *inf.t.s.*, second temporal sulcus; *coll.s.*, collateral sulcus.

reddish colour marked with fine radiating white striæ, whilst the inner two, known conjointly as the *globus pallidus* (*gl.p.*), are yellowish in tint. On its outer side is a grey lamina, termed the *claustrum* (*cl.*), which is separated from the lenticular nucleus by the stratum of white substance named the *external capsule* (*c.e.*). The internal capsule (continuation of the crusta) separates it in the greater part of its extent from the caudate nucleus and thalamus, but anteriorly the two nuclei of the corpus striatum are united at their bases. Where it is widest (fig. 97) the lenticular

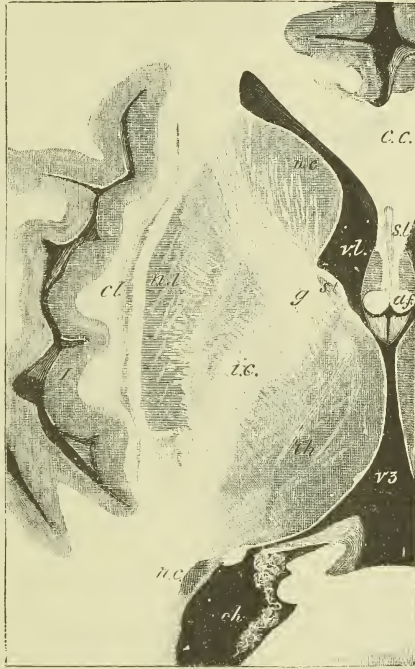


nucleus is continuous below with the superficial grey matter forming the anterior perforated lamina, into which the base of the claustrum also passes, and further back it comes in contact below with the nucleus amygdalæ (fig. 98); through these structures it is continuous with the grey cortex of the hemisphere.

All three zones of the nucleus lenticularis are pervaded by bundles of white fibres, but they are most conspicuous in the outer zone. The grey matter between the fibres contains many cells with yellow pigment in them. The cells on the whole resemble those of the caudate nucleus, but there are more in proportion belonging to the first type of Golgi (cells with a long nerve-process). Fibres pass directly from the inner zone into the adjacent part of the inner capsule (*i.e.*, into the peduncle of the cerebrum), while others from the substantia innominata below the optic thalamus,

Fig. 99.—HORIZONTAL SECTION THROUGH PART OF THE CEREBRAL HEMISPHERE. (E. A. S., after a preparation by Mr. S. G. Shattock.) Natural size.<sup>1</sup>

The section is viewed from below; *v.l.*, lateral ventricle, anterior cornu; *c.c.*, corpus callosum; *s.l.*, septum lucidum; *a.f.*, anterior pillars of the fornix; *v.3*, third ventricle; *th.*, thalamus opticus; *st.*, stria terminalis; *c.*, nucleus caudatus, and *n.l.*, nucleus lenticularis of the corpus striatum; *i.c.*, internal capsule; *g.*, its angle or genu; *n.c.*, tail of the nucleus caudatus appearing in the descending cornu of the lateral ventricle; *cl.*, claustrum; *I.*, island of Reil.



curve outwards around the mesial edge of the peduncle and enter the lower part of the lenticular nucleus as a distinct bundle (*ansa lenticularis*, p. 112) and passing into its medullary laminae are distributed in the middle and outer zones.

Other fibres connect the caudate with the lenticular nucleus, and others again pass from this nucleus into the corona radiata or white substance of the hemispheres and thence to the cortex, but few fibres emerge from or enter the lateral surface of the lenticular nucleus, which is sharply marked off from the external capsule.

The **external capsule** is formed of fibres which are not directly connected with the lenticular nucleus but are derived partly from the anterior commissure, and in part from a portion of the *ansa lenticularis*.

The **claustrum** (figs. 96 to 100, *cl.*) is a thin lamina of grey matter which is smooth next to the outer capsule but ridged and furrowed externally, the ridges and furrows corresponding to the gyri and sulci of the central lobe, with the white substance of which the claustrum is in immediate relation. According to Meynert the claustrum is to be looked upon as a separated part of the grey cortex of the central lobe. In transverse sections of the hemisphere the claustrum is seen to taper to a fine thread superiorly (apex) and to expand below (base), having the shape of an elongated triangle.

In the claustrum the cells are for the most part small and spindle-shaped, and arranged parallel with the surface, resembling those which are met with in the

<sup>1</sup> This figure shows the narrowed connections of the island of Reil with the rest of the hemisphere (mantle). These narrow connecting parts have been termed by Guldberg *isthmi (anterior et posterior) lobi centralis*.



deepest layer of the grey cortex of the hemispheres. Most of the cells contain yellow pigment.

The **internal capsule** (Burdach) (figs. 97 to 100, *c.l.* and *i.c.*) is a lamellated tract of white fibres which lies between the nucleus lenticularis laterally and the nucleus caudatus, stria terminalis, and optic thalamus mesially. It is somewhat interrupted, especially in front, by strands of grey matter which unite the caudate and lenticular nuclei. In front, behind and above it is continuous with the white substance of the hemispheres, its fibres diverging in a fan-like manner towards the cortex (*corona radiata* of Reil). Below it passes directly into the crusta, of which it is the immediate continuation. In horizontal sections (fig. 99) the internal capsule shows a bend (*genu*) opposite the stria terminalis, the anterior third forming an angle of about 120° with the posterior two-thirds; these two parts are known as the *anterior* and *posterior segments* respectively. In vertical sections (fig. 100) it appears to take a straight course, upwards and outwards from the crus cerebri to the

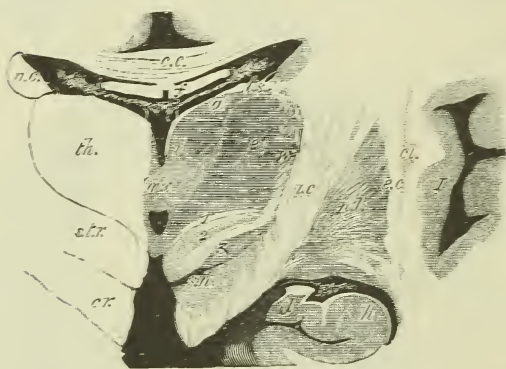


Fig. 100.—SECTION ACROSS THE OPTIC THALAMUS AND CORPUS STRIATUM IN THE REGION OF THE MIDDLE COMMISSURE. (E. A. S., after a preparation by Mr. S. G. Shattock.) Natural size.

*th.*, thalamus; *a, e, i.* its anterior, external and internal nuclei respectively; *cr.* its latticed layer; *m.c.*, middle commissure: above and below it is the cavity of the third ventricle; *c.c.*, corpus callosum; *f.*, fornix separated from the third ventricle and thalamus by the velum interpositum. In the middle of this are seen the two veins of Galen and the choroid plexuses of the third ventricle: and at its edges the choroid plexuses of the lateral ventricles; *t.s.*, tænia semi-

circularis; *cr.*, forward prolongation of the crusta passing laterally into the internal capsule, *i.c.*: *s.t.r.*, subthalamic prolongation of the tegmentum, consisting of (1) the dorsal layer, (2) the zona incerta, and (3) the nucleus of Luys; *s.n.*, substantia nigra; *c.c.*, nucleus caudatus of the corpus striatum; *n.l.*, nucleus lenticularis; *c.c.*, external capsule; *cl.*, claustrum; *I.*, island of Reil.

*corona radiata*. It has been determined as the result of experimental observations in animals, and from pathological and clinical observations in man, that the fibres which course in the middle third of the internal capsule (*i.e.*, which are opposite the globus pallidus of the lenticular nucleus) are connected with the part of the cerebral cortex excitation of which gives rise to movements in the various parts of the body (Rolandic region of cortex), whilst those of the anterior third are connected with the prefrontal region, and those of the posterior third with the occipito-temporal region.

Besides these fibres which connect the cortex of the hemisphere with the crusta, the internal capsule contains others derived from various sources, viz., from the caudate and lenticular nuclei, the optic thalamus, and sub-thalamic region, and also, through the corpus callosum, from the cortex of the opposite hemisphere (Hamilton). The exact localization within the internal capsule of most of these fibres has not as yet been determined.

## EXTERNAL CONFORMATION OF THE CEREBRAL HEMISPHERES.

The **cerebral hemispheres** together form an ovoid mass, flattened on its under side, and placed in the cranium with its smaller end forwards, its greatest width being opposite to the parietal eminences. The hemispheres are separated in a large part of their extent by a deep fissure, the *great longitudinal fissure*. On opening this fissure by drawing asunder the two hemispheres, it is seen, both before and behind, to pass quite through to the base of the cerebrum; but for 10 centimeters in the middle it is interrupted at a depth of about 30 mm. at the front to 40 mm. at the back by a large transverse mass of white substance, named the *corpus callosum*, which connects the two hemispheres together. While the brain is within the skull, the longitudinal fissure is occupied by a vertical process of the dura mater—the *falx cerebri*—which dips down between the two hemispheres, not quite reaching to the *corpus callosum* in front but touching it behind.

Each cerebral hemisphere has an outer, convex surface, in contact with the vault of the cranium; an inner or mesial, flat surface, which forms one side of the longitudinal fissure; and an irregular under surface, in which is a deep cleft, the *vallecula Sylvii*. In front of this cleft the under surface (orbital division) rests in the anterior fossa of the base of the skull, behind it in the middle fossa (temporal division), and further back still, on the *tentorium cerebelli* (occipital division). The surfaces pass into one another at the borders, which are also three in number, viz.: two mesial (superior and inferior) and one lateral. The anterior extremity of each hemisphere is known as the *frontal pole*, the posterior as the *occipital pole*.

The surface of the hemispheres is composed of grey matter, and is moulded into numerous smooth and tortuous eminences, named *convolutions* or *gyri*, which are marked off from each other by *fissures* or *sulci* of varying depth.

The convolutions are covered closely throughout by the vascular investing membrane, the *pia mater*, which sends processes down to the bottom of the sulci between them, while the arachnoid membrane passes from one convolution to another, without dipping between them. In general, the height of a convolution exceeds its width; and its width at the surface is somewhat greater than at its base. The convolutions present considerable variations of position, direction and complexity in the brains of different individuals, and even in the two sides of the same brain, but they are usually recognizable without much difficulty. It is far easier, however, to trace the more important fissures and convolutions on the brain of a monkey, where they are much less obscured by tortuosities and secondary sulci.

Since the external grey or cortical substance is continuous over the whole surface of the cerebral hemispheres, being found alike within the sulci and upon the gyri, it is obvious that a far greater extent of grey matter is thus provided for with a given size of the brain, than could have been the case had the hemispheres been plain and destitute of convolutions; indeed, it is calculated that the extent of "sunken" surface is twice that of "exposed" surface (*cf.* pp. 176, 177).

The sulci between the convolutions vary greatly in depth, being in some parts quite shallow, in others as much as 25mm. (1 inch) or more deep. The average depth is about 10mm. or 12mm. Certain well-marked sulci can easily be recognized, and these serve as guides to the position of others which may at first be less readily detected.

It may be well in the first instance to describe the six chief or "interlobar" fissures, so-called because they are used to mark the hemisphere off into lobes; the lobes themselves, with the convolutions and fissures which are included within them, can then conveniently be taken in order.









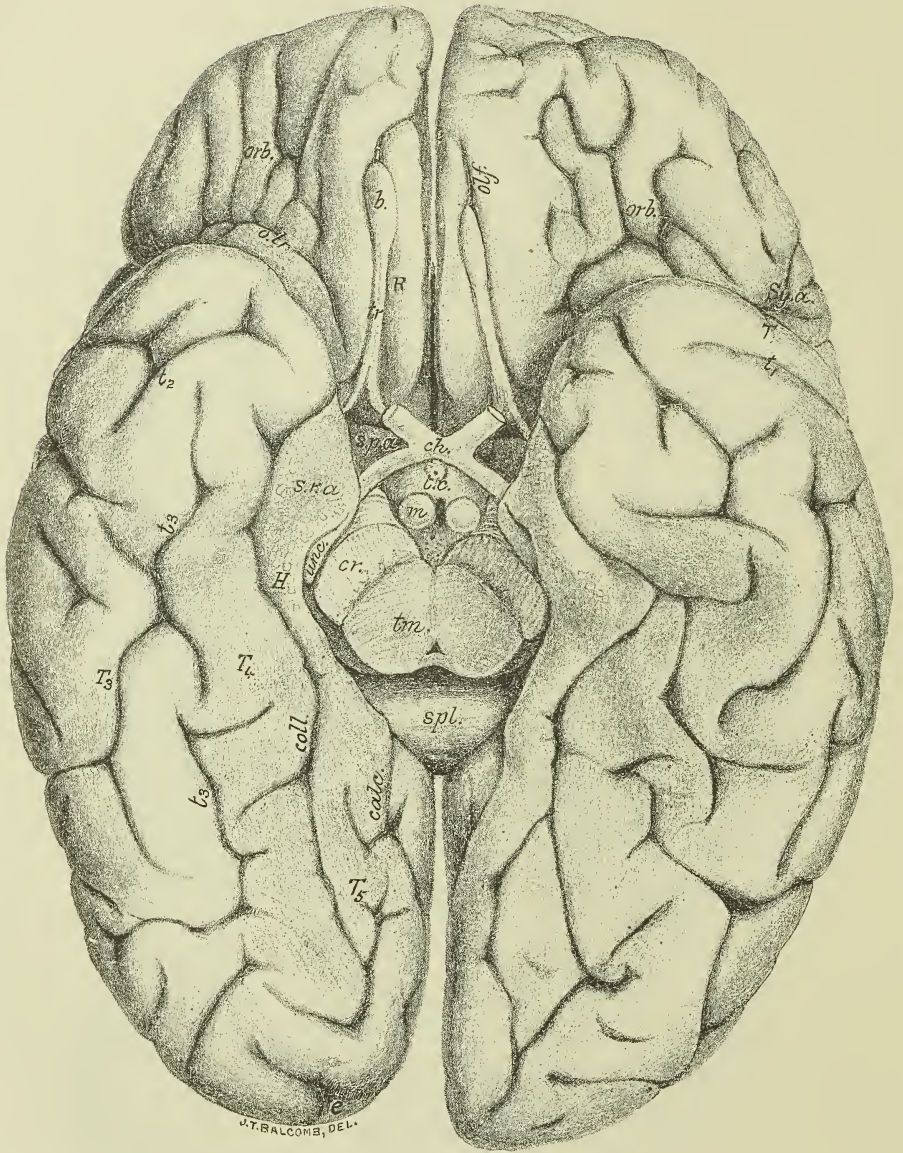


Fig. 103.



Fig. 101.—VIEW, FROM THE SIDE AND SLIGHTLY FROM ABOVE AND BEHIND, OF THE RIGHT HEMISPHERE OF A SIMPLY CONVOLUTED EUROPEAN BRAIN. (E. A. S.)

Fig. 102.—MESIAL ASPECT OF THE LEFT HEMISPHERE OF A SIMPLY CONVOLUTED EUROPEAN BRAIN. (E. A. S.)

Fig. 103.—UNDER SURFACE OF A SIMPLY CONVOLUTED EUROPEAN BRAIN. (E. A. S.)

The above are depicted nearly of the natural size. They have been drawn from photographs, and are all taken from different specimens.

The sulci are marked with small italic letters; the gyri with italic capitals. The corresponding parts are marked similarly in the three figures.

Fig. 101.—Sulci—*Ro.*, Rolandic or central; *g*, its superior genu; *Sy. a.*, anterior limb of Sylvian (*x*, ascending part, *y*, horizontal part); *Sy. p.*, posterior limb of Sylvian; *Sy. p. asc.*, ascending ramus of posterior limb; *f<sub>1</sub>*, superior frontal; *f<sub>2</sub>*, inferior frontal; *f<sub>3</sub>*, middle frontal; *f<sub>4</sub>*, paramesial frontal; *d*, diagonal, placed in this instance rather low down, and communicating with the Sylvian; *p. c. inf.*, inferior precentral; *p. c. i. ant.*, its anterior ramus; *p. c. sup.*, superior precentral; *p. c. m.*, mesial precentral; *p. c. tr.*, transverse precentral; *rtc. tr.*, transverse retro-central; *i. p. inf.*, intra-parietal, pars inferior (inferior postcentral); *i. p. sup.*, intraparietal, pars superior (superior postcentral); *i. p. post. s. hor.*, intraparietal, pars posterior seu horizontalis; *i. p. post.*, intraparietal, pars posterior (paroccipital of Wilder); *i. p. pr. asc.*, an ascending branch of the intraparietal; *p. o.*, parieto-occipital; *occ. ant.*, anterior occipital; *occ. lat.*, lateral occipital; *calc.*, posterior end of calcarine; *t<sub>1</sub>*, first temporal or parallel; *t<sub>1</sub> asc.*, its posterior ascending extremity, detached; *t<sub>2</sub>*, second temporal; *t<sub>2</sub> asc.*, its posterior ascending extremity joined to and apparently continuous with the first temporal.

Gyri—*F<sub>1</sub>*, *F<sub>2</sub>*, *F<sub>3</sub>*, first, second and third (superior, middle, and inferior) frontal; *a*, posterior part of third frontal; *b*, middle part (pars triangularis); *c*, orbital part; *A. F.*, ascending frontal; *A. P.*, ascending parietal; *T<sub>1</sub>*, *T<sub>2</sub>*, *T<sub>3</sub>*, first, second, and third temporal.

Fig. 102.—Sulci—*Ro.*, upper end of Rolandic; *p. c. m.*, mesial precentral; *f<sub>5</sub>*, mesial frontal; *c. m.*, calloso-marginal; *pr. l.*, prelimbic (anterior end of calloso-marginal); *pr. l. asc.*, an ascending branch of the prelimbic; *paracentr.*, paracentral (posterior end of calloso-marginal); *p. l.*, post-limbic; *ro.*, rostral; *ro. inf.*, inferior rostral; *p. o.*, parieto-occipital; *calc. ant.*, stem of calcarine; *calc. post.*, posterior part of calcarine; 1, 2, 3, 4, places where annectent gyri occur in calcarine and parieto-occipital fissures; *t<sub>3</sub>*, third temporal; *coll.*, collateral or fourth temporal; *h* (placed on the fascia dentata) has the hippocampal fissure just below it.

Gyri—*F<sub>1</sub>*, marginal part of first frontal; *C*, callosal (gyrus fornicatus); *H*, hippocampal; *unc.*, its uncus; *h*, dentate; *T<sub>4</sub>*, fourth temporal (fusiform lobule); *T<sub>5</sub>*, fifth temporal or infracalcarine (lingual lobule).

*c. c.*, corpus callosum; *spl.*, its splenium; *g*, its genu; *r*, its rostrum; *fo*, fornix; *fi.*, fimbria.

Fig. 103.—Sulci—*orb.*, orbital (sagittal rami); *o. tr.*, transverse orbital; *olf.*, olfactory; *t<sub>1</sub>*, *t<sub>2</sub>*, *t<sub>3</sub>*, first, second, and third temporal; *coll.*, collateral (fourth temporal); *calc.*, calcarine.

Gyri—*R*, gyrus rectus; *T<sub>1</sub>*, *T<sub>3</sub>*, *T<sub>4</sub>*, *T<sub>5</sub>*, first, third, fourth and fifth temporal; *H*, hippocampal; *s. r. a.*, substantia reticularis alba; *unc.*, uncus.

*ch*, chiasma; *s. p. a.*, substantia perforata antica; *t. c.*, tuber cinereum; *m*, corpora mamillaria, accidentally separated from one another in the preparation; *cr*, crista; *tm*, tegmentum; *spl.*, splenium of callosum.

**Fissure of Sylvius.**—The most distinct fissure in the adult brain, and also the first one to make its appearance in the development of the embryo, is the *fissure of Sylvius*. This deep and conspicuous fissure is seen at the base of the brain, opening out as the *vallecula Sylvi* (Broca) on to the anterior perforated space. From this origin the fissure passes transversely outwards to the lateral surface of the hemisphere, where it presently gives off a short *horizontal branch* (about 2 centimeters long), and a rather longer *ascending branch* (about 3 centimeters), the fissure being then continued nearly horizontally as the *posterior limb* for a considerable distance (8 or 9 centimeters) obliquely backwards and upwards in the direction of the parieto-occipital fissure, having a slightly curved course. It ends at about the junction of the middle and posterior thirds of the lateral surface (midway from superior to lateral border), usually by bifurcating, one branch passing obliquely upwards, the other backwards and somewhat downwards. If the lips of the Sylvian fissure are separated, the island of Reil is seen at the bottom of the sulcus. In section this fissure, together with the limiting sulcus of the island, forms a T-shaped figure (fig. 95). Its bounding convolutions are folded over the island of Reil, and the upper bounding convolutions which belong partly to the parietal, partly to the frontal lobe, form the *operculum* of Burdach.



The anterior horizontal and anterior ascending limbs of the fissure subdivide this operculum into three unequal parts, an upper or *fronto-parietal* (pars fronto-parietalis), a middle or *frontal* (pars triangularis, "cap" of Broca), and a lower or *orbital* (pars orbitalis) (fig. 101, *a, b, c*). All these are now often spoken of as opercula. The convolution bounding the Sylvian fossa below is also spoken of as the *temporal* operculum, so that four opercula are thus enumerated. They are formed in the embryo by the manner in which the mantle comes to overlap the central lobe. The temporal and fronto-parietal appear first, above and below the Sylvian fossa of the embryo: the frontal and orbital develop much later. The meeting of the four opercula determines the formation of the three limbs of the Sylvian fissure (fig. 104).

The Sylvian fissure is usually longer in the left than in the right hemisphere; the difference being due to the greater development of the frontal operculum on the left side (fig. 106)

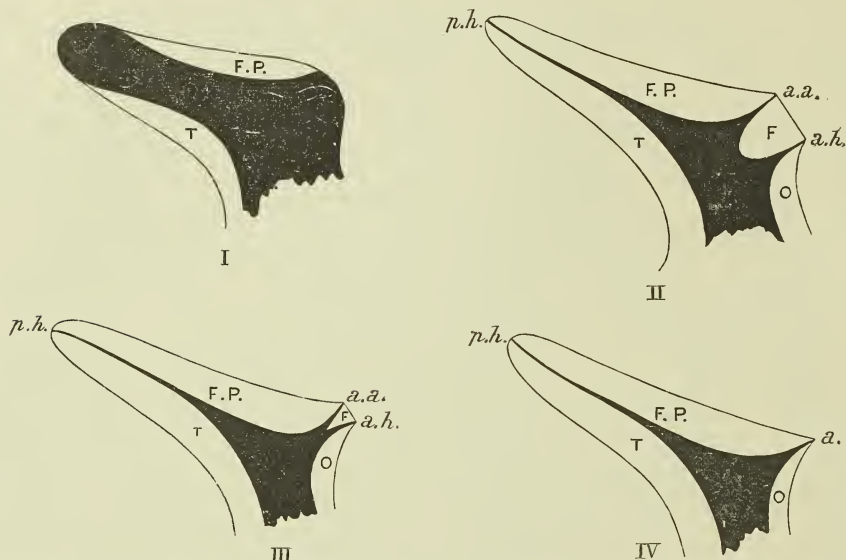


Fig. 104.—DIAGRAMS ILLUSTRATING THE MANNER IN WHICH THE INSULAR REGION IS COVERED IN BY THE VARIOUS OPERCULA. (Cunningham.)

The part printed black represents uncovered part of the Sylvian fossa of the embryo, the unshaded portions represent the different opercula.

F.P., fronto-parietal operculum; T., temporal operculum; F., frontal operculum (pars triangularis of third frontal gyrus); O, orbital operculum; *p.h.*, posterior limb of fissure; *a.a.*, anterior ascending limb; *a.h.*, anterior horizontal limb.

In I, the fronto-parietal and temporal opercula are beginning to grow over the fossa; in II, the formation of all four opercula is advanced, the pars triangularis being well marked, and the anterior limb U-shaped. In III, the pars triangularis is only slightly developed, and the anterior limb is a Y; in IV the pars triangularis is absent and the anterior limb is simple (I-form).

(localisation of speech centre, Broca). The horizontal and ascending limbs of the anterior branch of the Sylvian fissure often arise from a common stem (Y-condition, fig. 101 and fig. 106, right side), the pars triangularis being then less developed than usual. This part may even not form a distinct opercular projection, in which case the anterior limb of the Sylvian fissure is undivided (I-condition).

The anterior and ascending limbs arose by a common stem from the main fissure (Y form), in 32 p. c. of the hemispheres examined by Cunningham; independently (V and U form) in 37.5 p. c.; and as a single limb (I form) in 30 p. c. There are sometimes two secondary extensions of the Sylvian fissure on to the orbital lobe (orbital limbs), but these are less deep and have not the same morphological importance as the others.

The posterior limb about corresponds in the adult to the level of the squamous suture, but in children younger than fifteen years it is rather above this level. The angle which the direction of the posterior limb forms with a line perpendicular to the superior border of the hemisphere (Sylvian angle), varies considerably, but is more acute on the whole in the child than in the adult (Cunningham).

In the brain of some monkeys, the posterior limb of the Sylvian fissure joins (superficially) the parallel fissure, which it gradually approaches, and the two are continued as an apparently

conjoined fissure almost as far as the upper margin of the hemisphere; this conjunction is sometimes found in the human subject.

**Fissure of Rolando.**—The *fissure of Rolando*,<sup>1</sup> or *central sulcus* (Huschke) (fig. 101, *Ro.*; and figs. 105, 107 (monkey)), extends across the lateral convex surface of the hemisphere interrupting the general longitudinal course of the gyri and sulci. The parallel convolutions which bound it are named respectively the *ascending frontal* and *ascending parietal convolution* or the *central gyri*. It begins above, near the vertex or highest point of the hemisphere, somewhat behind the middle of the great longitudinal fissure, and passes downwards and forwards to end near the middle of the fissure of Sylvius, the posterior limb of which it sometimes (but rarely) joins. The junction is effected by the medium of a small sulcus, *precentral transverse sulcus* (figs. 101, 106, *p. c. tr.*), the *inferior transverse sulcus* of Eberstaller, which is usually separated from the lower end of the Rolandic fissure by an annectent gyrus joining the two central convolutions. The Rolandic fissure usually reaches the superior border of the hemisphere, but sometimes stops short of that line; it often exhibits a hook-like backward inclination at this extremity. As just mentioned, it passes obliquely downwards and forwards, but not in a perfectly straight course, for it has certain well-marked curves. At about the junction of its upper and middle thirds it is generally curved with the concavity forwards; just below its middle third it has a second bend with the concavity backwards, while in the lowest part its direction is nearly vertical, with a tendency of the lowermost end to curve backwards. The upper curve sometimes forms a very distinct bend (superior genu, fig. 101, *g*), representing a deep bay which is here found in the brain of the anthropoid apes (fig. 105). The middle part of the fissure is then nearly horizontal. It is very rarely interrupted in its course, although on separating its lips it may often be seen that there is a tendency to the appearance of an annectent gyrus about the level of the superior genu, and it is here that the interruption is liable to occur. The fissure of Rolando appears early (end of fifth month), being laid down in two parts, an upper shorter, and a lower longer portion (Cunningham). In this double mode of origin it resembles the precentral and postcentral sulci.

The acute angle which the slope of the fissure of Rolando forms with the superior border of the hemisphere is known as the Rolandic angle. According to Cunningham it averages 71.7°. The two Rolandic fissures form therefore when looked at from above, a wide V, open forwards and forming an angle of 143°. The length of the fissure is about  $\frac{2}{3}$ ths of the whole length of the hemisphere. It is relatively longer and more curved in the anthropoid apes than in man.

This fissure has once been found duplicated, the two fissures replacing it being separated by a gyrus (*g. Rolandicus*) along their whole length (Giacomini). The condition was present in both hemispheres of the same brain.

**Parieto-occipital fissure.**—The *parieto-occipital fissure* is best marked on the mesial surface of the hemisphere, where it appears as a deep cleft (fig. 102, *p.-o.*), extending downwards and a little forwards from the margin of this surface to near the posterior extremity of the corpus callosum, where it usually joins the calcarine fissure, the two together forming a Y which encloses a wedge-shaped portion of the occipital lobe (*cuneus*). On the convex surface the fissure is continued transversely outwards for a variable distance, generally only a few millimeters (*external part of the parieto-occipital fissure* (fig. 101, *p.-o.*)). This fissure is here taken as the division between the parietal and occipital lobes. The size of its external portion depends (inversely) on the size of the annectent gyrus which curves round its outer extremity and connects the parietal with the occipital lobe. In *Quadrumania* (figs. 105, 107) the external portion of this fissure is concealed within a deep transverse cleft (*Affenspalte*)

<sup>1</sup> Although thus named by Leuret (*Anatomie comparée du système nerveux*, 1839), from attention having been directed to it by Rolando a few years previously, this fissure was noticed and figured by Vicq-d'Azyr (*Traité d'anatomie et de physiologie*, 1796).

which intervenes between the parietal and occipital lobes, the cleft tending obliquely backwards, so that the occipital edge somewhat overlaps the parietal (*occipital operculum*). This "Affenspalte." is not represented in the adult human brain, but it is apparently represented by a temporary fissure which is seen in the foetus during the fifth and sixth months (*external perpendicular fissure* of Bischoff).<sup>1</sup> The parieto-occipital fissure appears about the fourth or fifth month on the mesial surface. It is about on a level with the *lambda* (see Vol. II., p. 83), or a little in front of the level of that spot : more so in the child than in the adult (Cunningham).

The **calcarine fissure** (Huxley).—This is seen on the mesial surface of the hemisphere (fig: 102). It is a deep fissure, extending from near the posterior

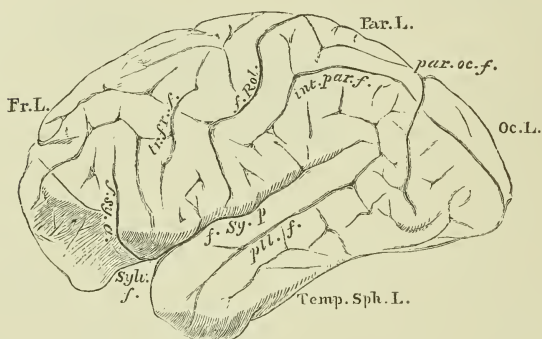


Fig. 105.—BRAIN OF CHIMPANZEE.  
(From Gratiolet.)

Fr. L., frontal lobe ; Par. L., parietal lobe ; Oc. L., occipital lobe ; Temp. Sph. L., temporo-sphenoidal lobe ; *Sylv. f.*, fissure of Sylvius ; *f. Sy. a.*, *f. Sy. p.*, its anterior and posterior limbs ; *f. Rol.*, fissure of Rolando ; *tr. fr. f.*, transverse frontal (pre-central) fissure ; *int. par. f.*, intra parietal fissure ; *par. oc. f.*, parieto-occipital fissure.

extremity of the brain, where it usually begins in a T-shaped fork, in a course curved at first upwards and then downwards, and ending below the splenium of the corpus callosum. The forked posterior extremity near the occipital lobe is sometimes cut off from the rest of the fissure, and appears as an independent sulcus (*sulcus extremus* of Schwabe). In many *Quadrumana* the anterior extremity appears to be continued into the hippocampal fissure, but this is usually superficial only, and occurs but rarely in the human brain.

The anterior part of the calcarine fissure is by far the deepest part, and it is this part which indents the posterior horn of the lateral ventricle and forms the calcar avis. A short distance from its anterior extremity the calcarine receives the internal parieto-occipital fissure, although in the depth of the latter fissure there is usually a small gyrus, passing from the apex of the cuneus to the isthmus of the gyrus fornicatus (opposite 1. fig. 102) (*cuneo-lingual annectent gyrus*). This sometimes comes to the surface and shuts off the continuity of the two fissures, which otherwise form a Y-shaped figure, the stem of the Y being formed by the anterior part of the calcarine, the limbs by the parieto-occipital and posterior part of the calcarine respectively. This posterior part of the calcarine is developed independently of the stem, which is a direct representative of one of the total fissures of the foetal hemisphere, while the posterior part of the calcarine (*posterior calcarine* of Cunningham) is formed much later by two depressions, which ultimately run together and into the true calcarine. The original independence of these parts is indicated by the existence of two annectent gyri (*anterior and posterior cuneo-lingual*) concealed within the posterior part of the calcarine : one at its junction with the stem of the Y, and the other near the hinder end. The places of these annectent gyri are indicated by 2 and 3 in fig. 102.

The parieto-occipital fissure is frequently interrupted in its depth by two annectent gyri. One of these is the cuneo-lingual annectent gyrus already mentioned (fig. 102, 1), the other, placed higher, may be termed the *cuneo-quadrate annectent* (fig. 102, at 4).

The parieto-occipital is preceded in the foetus by a fissure occupying about the same situation, but this usually disappears before the permanent fissure makes its appearance.

The **collateral fissure** (Huxley).—This is seen on the inferior surface, where it lies below and parallel to the anterior part of the calcarine (figs. 102, 103, *coll.*). It extends forwards towards the tip of the temporal lobe, but does not reach the

<sup>1</sup> According to some authorities, the anterior occipital sulcus of the adult brain (see p. 152) represents the Affenspalte of *Quadrumana*.



extremity of the lobe. The middle part of this fissure, which mainly causes the projection of the collateral eminence in the lateral ventricle (see p. 125), is formed independently of the two extremities.

The **calloso-marginal fissure** (Huxley) is an extensive fissure of the mesial surface, which begins below the rostrum of the corpus callosum close to the anterior perforated space, and sweeping round the genu of the callosum runs parallel to that body, separated from it by the gyrus fornicatus, as far as a little behind the middle of the hemisphere, where it turns obliquely upwards, and ends at the upper margin of the hemisphere a short distance behind the commencement of the fissure of Rolando (fig. 102). Both the anterior and the posterior parts of this fissure are developed independently of and are often permanently distinct from the middle part. The anterior part or *prelimbic fissure* (fig. 102, *pr.-l.*) sweeps round the genu of the corpus callosum, and when distinct from the middle part passes obliquely upwards towards the upper margin of the hemisphere. In any case it usually sends a well-marked ascending branch towards the margin (fig. 102, *pr.-l. asc.*). The posterior part of the calloso-marginal (*paracentral fissure* of Wilder, fig. 102) hooks round the inflected end of the fissure of Rolando, and is curved round the paracentral lobule, which it bounds behind, below, and in front: the last by an ascending ramus, which comes off at the junction of the posterior with the middle part of the calloso-marginal fissure.

The six fissures which have been described are used by anatomists to map out the surface of the brain into regions to which the name of "lobes" has, not very appropriately, been applied. In all, seven lobes are enumerated, viz., the *frontal, parietal, occipital, temporal, and limbic*, the *island of Reil*, or *central lobe*, and the *olfactory bulb and tract*, or *olfactory lobe*. It must, however, be understood that these so-called lobes have by no means an equal morphological value, nor do they correspond precisely with the functional differentiations of the hemisphere which can be made out as the result of experiments on animals, and clinical and pathological observations in man.<sup>1</sup> The distinction is further artificial because the so-called lobes are in many places not marked off from one another otherwise than by imaginary lines. Nevertheless it is found convenient for purposes of anatomical description to consider the surface of the brain as thus constituted, and they will accordingly be here described in the order in which they have been above enumerated.

**THE FRONTAL LOBE.**—The fissure of Rolando, passing obliquely downwards from the upper margin of the brain towards the Sylvian fissure, marks off the anterior part of the hemisphere—constituting in man nearly one-third of the whole—as the *frontal lobe*. This term, however, includes not only the part of the external surface which is thus marked off, but the corresponding adjacent part (marginal convolution) of the mesial surface, as far as the calloso-marginal fissure, and also the under or orbital surface of this anterior part of the brain. In the description of the fissures and convolutions within the lobe, these three surfaces will be separately considered.

**SULCI AND GYRI OF THE EXTERNAL SURFACE.**—The **precentral sulcus** (*pre-Rolandic sulcus* of Broca) (fig. 101, *p.c.inf.*, *p.c.sup.* and *p.c.m.*) has a direction parallel with that of the fissure of Rolando, from which it is separated by the ascending frontal gyrus. It is sometimes complete, but more usually is subdivided into two or three separate portions by annectent gyri, which connect the ascending frontal with the superior and middle frontal respectively; a third annectent gyrus passes below the lower end of the fissure, and unites the ascending frontal with the third frontal. The uppermost portion (*sulcus precentralis mesialis*, fig. 101, *p.c.m.*) cuts the upper border of the hemisphere, and appears on the mesial surface (fig. 102, *p.c.m.*) often as a well-marked vertical fissure, which

<sup>1</sup> Certain of them it is true, such as the olfactory and the occipital lobe and to a less marked degree the temporal lobe, appear to have a localized association with the functions of certain special sense organs.

occasionally runs into the calloso-marginal, to which it has sometimes been regarded as belonging (Schwalbe<sup>1</sup>). The next portion (*sulcus precentralis superior*), is very often continued forwards into the first frontal sulcus ( $f_1$ , fig. 101). Its middle part is opposite the upper genu of the fissure of Rolando. The inferior portion (*sulcus precentralis inferior*) is by far the best marked. It separates the ascending frontal from the third frontal gyrus, and usually gives off a well-marked branch anteriorly into the middle frontal gyrus (which may, as in fig. 101, *p.c.t.ant.*, be the main continuation of the fissure). After giving off this branch the fissure is usually prolonged upwards for some distance, but this is not shown in the brain figured, where the superior precentral extends unusually low down. The inferior precentral sulcus is often joined to the Sylvian fissure, either directly or through the intermediation of the sulcus precentralis transversus (*see* p. 143), or of the sulcus diagonalis (*see* p. 148), but there is usually, perhaps invariably, an annectent gyrus concealed in the depth of the fissure even in these cases. The inferior frontal sulcus sometimes appears to spring from the inferior precentral, either near its middle, or, as in the brain figured, from its anterior branch, but the two are probably more frequently separated by an annectent gyrus which here joins the middle and inferior frontal gyri.

Two well-marked sagittal sulci (*superior and inferior frontal*) course over the external surface of the frontal lobe in front of the precentral fissure; they subdivide this part of the lobe into three sagittal gyri, *superior, middle and inferior*. Besides these constant sulci, there are certain others which are less constant in their occurrence, and in the extent to which they are developed as connected fissures, viz., one running along the middle of the superior frontal gyrus, which we will term from its position near the upper border, the *paramesial sulcus* (fig. 101,  $f_4$ ), (*s. mesialis* of Cunningham), and one running along the centre of the middle frontal gyrus (*sulcus frontalis medius* of Eberstaller), (fig. 101,  $f_3$ ). Both of these are not only inconstant in their occurrence, but when present are frequently interrupted, and then appear to consist of a series of separate parts, which are often united here and there with the other frontal sulci.

The midfrontal sulcus (*s. frontalis medius*) usually bifurcates in front, and becomes transverse (*s. transversus anterior, fronto-marginal sulcus* of Wernicke).

The **superior frontal sulcus** ( $f_1$ ) is developed after the inferior, and along with the upper part of the precentral, with which it is usually in direct continuity. This sulcus is often interrupted by superficial annectent gyri passing obliquely from before backwards from the first to the second frontal convolution. Anteriorly, the superior frontal often passes into the mid-frontal sulcus (Cunningham). This is the case in the brain figured (fig. 101). Posteriorly, its line may be continued by a branch from the superior precentral sulcus passing across the ascending frontal gyrus. This was also the case in the brain here figured.

The **inferior frontal sulcus** ( $f_2$ ) usually curves forwards from the middle of the inferior precentral sulcus towards the frontal pole of the hemisphere. Several small secondary furrows pass from it above and below, and it is sometimes subdivided by superficial annectent gyri into three portions. Anteriorly it bifurcates, forming a transverse piece, which may develop separately. At the apex of the lobe, in front of and sometimes forming part of this fissure, are one or two transverse sulci forming the *sulcus radiatus* and *lateral fronto-marginal sulcus* of Eberstaller.

**Gyri.**—Four convolutions are described upon this surface, three of which run antero-posteriorly, while the fourth takes a direction obliquely across the brain, and parallel with the fissure of Rolando. The three antero-posterior convolutions are termed respectively the *superior, middle and inferior*, or *first, second, and third frontal*

<sup>1</sup> Schwalbe has termed it the "sulcus paracentralis," but this is not to be confounded with the fissure to which that name has been given by Wilder (p. 145).

*gyri*. They are separated from one another by the upper and lower longitudinal frontal sulci, and from the fourth or ascending frontal gyrus by the precentral sulcus, which runs parallel to the fissure of Rolando.

The **first frontal gyrus** ( $F_1$ ), which is much the longest, runs parallel with the upper margin of the hemisphere, over which it is continuous with the marginal convolution of the mesial surface, the two, in fact, really forming a single convolution to which the name first frontal is frequently applied. This convolution reaches the frontal pole of the hemisphere in front; behind it is partly continued into the upper end of the precentral or ascending frontal gyrus, partly separated from that gyrus by the upper end of the precentral sulcus; below it is marked off from the middle frontal by the irregular and somewhat interrupted superior frontal sulcus. It is sometimes subdivided by a longitudinally coursing sulcus (paramesial, s. *frontalis mesialis* of Cunningham) into two parts, but less often than the second gyrus. This subdivision is rarely found in the brain of the negro.

The **second frontal gyrus** ( $F_2$ ), runs below and parallel to the first. It is separated from the precentral by the precentral sulcus, the course of which is, however, here usually interrupted by a well-marked annectent gyrus. The inferior frontal sulcus separates it from the third gyrus. It is also often subdivided by a longitudinally coursing sulcus (midfrontal sulcus) into two parts, an upper or lower, which are sometimes described as distinct convolutions.

The **third frontal gyrus** ( $F_3$ ), the smallest of the three, is curved around both the anterior and the ascending limbs of the Sylvian fissure, which deeply indent the

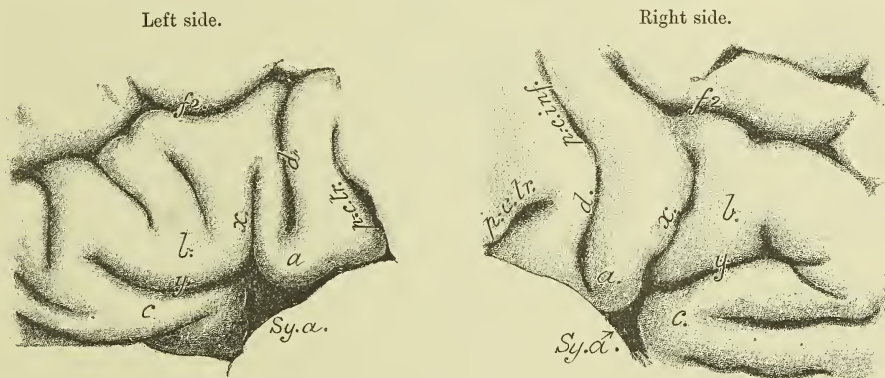


Fig. 106.—VIEWS OF THE THIRD FRONTAL GYRUS OF THE RIGHT AND LEFT HEMISPHERES OF THE SAME BRAIN. NATURAL SIZE. FROM PHOTOGRAPHS. (E. A. S.)

$f_2$ , inferior frontal sulcus; *p.c. inf.*, lower end of inferior precentral, very short, and not lettered on the left side, and continuous on the right side with  $d$ , diagonal sulcus (on the left side  $d$  joins  $f_2$ ); *p.c. tr.*, transverse precentral; *Sy.a.*, anterior limb of Sylvian fissure;  $x$ , ramus ascendens,  $y$ , ramus horizontalis;  $a$ , posterior part of third frontal (divided by the diagonal sulcus into two parts, viz., pars basilaris behind, and pars ascendens in front);  $b$ , middle part of third frontal or pars triangularis, partly subdivided on the left side by secondary sulci;  $c$ , orbital part of third frontal.

gyrus, and subdivide it into three parts, *anterior* (pars orbitalis), *middle* (pars triangularis), and *posterior* (pars basilaris). It is more developed on the left side of the brain than on the right—correspondingly with the localization of the speech-centre on the left side (Broca). This increased development chiefly affects the triangular middle part which lies between the anterior and ascending limbs of the Sylvian fissure (“cap” of Broca). When well developed, the triangular part entirely separates these two limbs (fig. 106, left side), when less marked, they are confluent below (fig. 106, right side); if the triangular part is absent they are entirely confluent (see also fig. 104 and p. 142). This inferior frontal gyrus is connected at its lower and



posterior end by an annectent gyrus with the lower end of the precentral, while at its anterior end it passes round to the orbital surface of the lobe.

This gyrus is usually regarded as being bounded posteriorly by the inferior precentral sulcus, but it is, for many reasons, more convenient to regard the transverse precentral as the posterior limit.

It is occasionally subdivided into two by a longitudinal sulcus concentric with the inferior frontal (Giacomini).

The pars basilaris is subdivided into two parts (anterior and posterior divisions) by an oblique fissure, the *sulcus diagonalis* of Eberstaller (figs. 101, 106, *d*). This is usually distinct, but sometimes joins the inferior precentral (fig. 106, right side), the inferior frontal (fig. 106, left side), or even the Sylvian fissure. The last is the case in fig. 101. The pars triangularis is also often scored by secondary sulci (figs. 101, 106).

According to most modern authorities the third frontal gyrus is almost or quite rudimentary in all primates excepting man. Cunningham points out, however, that although it is true that the opercular part of this convolution is not present in the apes, the same remark does not apply to the non-opercular part, and he believes that the inferior frontal sulcus, which is

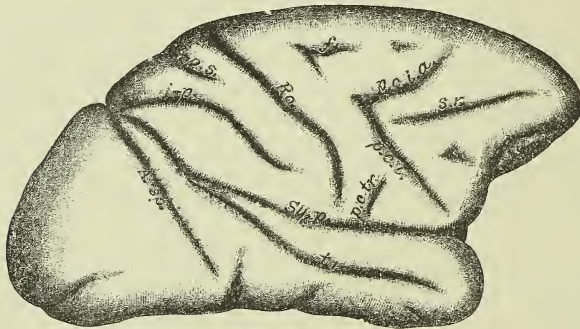


Fig. 107.—BRAIN OF MACAQUE MONKEY. Natural size. (E. A. S.)

Sulci. — *A.sp.*, "Affenpalte;" *i.p.*, intraparietal; *i.p.s.*, superior part of intraparietal; *Ro.*, Rolandic; *Sy.p.*, Sylvian, posterior limb; *f<sub>1</sub>*, superior frontal; *s.r.*, sulcus rectus (inferior frontal); *p.c.i.*, precentral inferior; *p.c.i.a.*, its anterior ramus; *p.c.tr.*, transverse precentral; *t<sub>1</sub>*, parallel.

regarded by most authorities as not represented in the apes, is, in fact, represented in them by the well-marked sagittal furrow (*sulcus rectus quadrumanorum*, fig. 107, *s.r.*) which runs forwards from near the angle of the inferior precentral sulcus to the apex of the hemisphere. This view, which was that taken by Gratiolet (*Mémoire sur les plis cérébraux de l'homme et des primates*, 1854), gives a well-developed third frontal gyrus to the ape brain, whereas if the sulcus in question be regarded as the superior frontal (Schwalbe, Mingazzini), or as the sulcus frontalis medius (Eberstaller, Hervé) of the human brain, the sulcus frontalis inferior must be absent in the ape, or at most represented by a small fronto-orbital sulcus which is sometimes present at the lowermost limit of the lobe (see fig. 107). But the superior frontal sulcus of man is represented in the monkey by one or more deep indentations of the cortex lying in a sagittal line near the margin and sometimes partly confluent (fig. 107, *f<sub>1</sub>*), and in some apes there is also a distinct mid-frontal sulcus besides the sulcus rectus; moreover, the study of the development of the inferior frontal sulcus in man is also in favour of Gratiolet's view. For a full discussion of this question the student is referred to Prof. D. J. Cunningham's memoir, "The Surface Anatomy of the Primate Cerebrum," Dublin, 1892.

The **anterior central, precentral, or ascending frontal gyrus** (fig. 101, *A.F.*) lies between the fissure of Rolando and the precentral sulcus, and extends from the superior margin of the hemisphere (where it is continuous with the posterior part of the marginal gyrus on the mesial surface) to the Sylvian fissure. It is narrowest in the middle, enlarging somewhat above and below. It is usually connected, as just mentioned, with each of the three longitudinal frontal convolutions by an annectent gyrus, the precentral sulcus being thereby considerably interrupted. There is a similar connection by a curved annectent gyrus below the fissure of Rolando, with the ascending parietal convolution.

**SULCI AND GYRI OF THE MESIAL SURFACE.**—On the mesial surface of the hemisphere there is only one convolution which is considered to belong to the frontal lobe, viz., the **marginal gyrus** (fig. 102, *F<sub>1</sub>*). This, as above explained, is continuous over the upper border with the superior longitudinal of the external surface. It is separated from the callosal or fornicate gyrus of the limbic lobe by the calloso-marginal

fissure, and is partially interrupted by the ascending branches of that fissure. Besides these, there is often, but not constantly, a sagittal fissure running along the middle of the convolution. This fissure (*sulcus frontalis mesialis s. marginalis*) subdivides the middle of the gyrus into superior and inferior parts. The antero-inferior part of the marginal gyrus is marked by two or three sulci which are curved concentrically with the prelimbic part of the calloso-marginal sulcus. These have been termed by Eberstaller the *rostral sulci* (*supra-orbital* of Broca) (fig. 102, *ro.*, *ro. inf.*) Below the genu of the callosum the marginal gyrus is continuous with the limbic lobe by one or more broad *fronto-limbic annectent gyri*. Other annectents are found between the several parts of the calloso-marginal sulcus, when this is subdivided; when it is not subdivided they are concealed in its depth. At its posterior end the marginal gyrus becomes continuous with the two central gyri on either side of the upper extremity of the fissure of Rolando. But this posterior part of the marginal gyrus is nearly cut off from the rest of the gyrus by the anterior ascending part of the paracentral sulcus, and is distinguished as the **paracentral** or **oval lobule** (fig. 102).

**SULCI AND GYRI OF THE ORBITAL SURFACE.**—The **orbital sulcus** (H-shaped sulcus, triradiate sulcus) is a complex of sulci, which extends over the greater part of the flattened orbital surface of the frontal lobe. It consists of a posterior part (*sulcus orbitalis transversus* of Weisbach, fig. 103, *o.tr.*), which curves round from near the anterior Sylvian fissure laterally, in an arch convex forwards, to end mesially near the lateral root of the olfactory tract; and of three or four sulci having a general sagittal direction (*sulci orbitales sagittales*), and usually communicating posteriorly with the transverse orbital. These sagittal sulci vary greatly in their number and extent, and in the number and direction of the secondary and tertiary sulci, which come off from them, and they frequently produce, with the transverse sulcus, the figure of an H, K or X. Weisbach has endeavoured to connect these variations with racial and sexual differences, but there does not seem to be any foundation for such connexion, and in fact (as is well shown in fig. 103), two entirely different types may be found on opposite hemispheres of the same brain.

Three convolutions are described as lying in front of the transverse orbital sulcus, named, according to their position, the **inner**, **middle**, and **outer orbital gyri**. The last of these is continuous at the side with the inferior frontal, the first and second are the continuations of the superior and middle frontal convolutions.

On the inner gyrus is seen the **olfactory sulcus** (*s.olf.*) in which the olfactory tract and bulb lie. It has a straight course nearly parallel with the great longitudinal fissure, but somewhat inclining towards it. The part of the inner gyrus between the olfactory sulcus and the mesial border is sometimes known as the *gyrus rectus* (*R*). Behind the transverse orbital sulcus, between it and the anterior limiting sulcus of the insula, is a fourth gyrus, the **posterior orbital**, which is also continuous with the inferior frontal.

The continuity of the convolutions of the external with those of the orbital surface is often interrupted by a sulcus which crosses their direction, extending across the front of the lobe from the anterior end of the Sylvian (*sulcus fronto-orbitalis*, Giacomini; *fronto-marginalis lateralis*, Eberstaller).

**PARIETAL LOBE.**—This lobe lies behind the frontal, in front of the occipital, and above the temporal lobe. It is bounded in front by the fissure of Rolando, behind by the parieto-occipital and anterior occipital fissures (p. 152), laterally and below by the posterior limb of the fissure of Sylvius as far as this preserves its horizontal direction, and then by a line connecting this with the lower end of the anterior occipital, but it is here freely continuous with the temporal lobe. Above and mesially it extends within the great longitudinal fissure and appears on the mesial side of the hemisphere, as the quadrate lobule.

**SULCI AND GYRI OF THE PARIETAL LOBE.**—The **intraparietal sulcus**



(Turner) (fig. 101) arches through the parietal lobe, commencing in its anterior inferior angle, where it is sometimes, though rarely, continued into the fissure of Sylvius. It ascends at first parallel to the fissure of Rolando (*pars ascendens inferior s. postcentralis inferior*), and then turns backwards horizontally to the back of the lobe (*pars horizontalis s. posterior*), extending nearly to the termination of the parieto-occipital fissure, past which it is continued (*pars occipitalis, paroccipitalis* of Wilder) to join the anterior occipital. Its horizontal portion divides the parietal lobe into two parts, the superior and inferior parietal lobules, and it is frequently bridged across by annectent convolutions connecting those lobules. One or two well-marked rami pass into the superior parietal lobule from the upper side of the *pars horizontalis*, and as many shallow sulci extend from its lower concave side into the inferior parietal lobule.

Above the *pars ascendens inferior* and often separated from it by an annectent gyrus connecting the superior parietal lobule with the ascending parietal gyrus is a short vertical fissure (*postcentralis superior*), which is termed by Cunningham the *pars ascendens superior*, since in a large number of instances it is directly continuous with the *pars ascendens inferior* (the bridging gyrus being then absent), and the two conjoined parts then constitute a sulcus which runs parallel to the fissure of Rolando, and is termed the *postcentral sulcus* (Ecker).

Although the condition with a detached *pars ascendens superior* is to be regarded as typical of this sulcus as shown both by its occurrence in most of the Quadrumana and the course of its development in the human embryo, it is by no means the most common in the adult human brain, the most usual condition being that here figured (fig. 101) in which there is a complete postcentral sulcus from which the horizontal arm passes off backwards at an oblique angle towards the occipital lobe, although generally interrupted near the anterior limit of that lobe by an annectent gyrus. An arrangement of this character was met with by Cunningham in 56 p. c. of his cases. In 16 p. c. a more or less complete postcentral sulcus was present, and was cut off from the horizontal part of the fissure by an annectent gyrus. Occasionally the postcentral sulcus communicates above, and sometimes also below, with the fissure of Rolando. Three deep annectent gyri partially interrupt the horizontal part of this fissure and join the superior and inferior parietal lobules (Eberstaller); these have been supposed to be a human characteristic, but they occur in the Chimpanzee and occasionally in the Baboon (Cunningham).

In rare cases the *pars ascendens inferior* of this fissure is cut off from the *pars horizontalis*, and the latter is continuous with the *pars ascendens superior* alone. In other and also rare instances all the parts of the fissure are separated from one another by bridging convolutions, so that the fissure appears as four distinct parts, viz., the two portions of the postcentral sulcus (lower and upper), the *pars horizontalis* and the *pars occipitalis*.

The occipital continuation of the intraparietal fissure is sometimes separated from the rest of the fissure (*paroccipitalis fissure* of Wilder). It usually terminates posteriorly by joining a sulcus which is nearly vertical to its direction, the *sulcus transversus occipitalis* of Ecker (*sulcus occipitalis anterior*, fig. 101). This will be further noticed in connection with the occipital lobe. In the monkey's brain the occipital termination is concealed within the deep cleft (Affenspalte) formed by the occipital operculum.

Below the postcentral sulcus and cutting into the margin of the fronto-parietal operculum, is a small oblique sulcus (*s. retro-centralis transversus* of Eberstaller) (fig. 101, *rtc. tr.*). This sometimes serves to prolong the intraparietal fissure into the fissure of Sylvius.

The intraparietal fissure is usually developed in the foetus in four segments (Cunningham), which appear in the following order, viz., inferior postcentral, horizontal, occipital, and superior postcentral. It is better developed, i.e., more continuous and deeper, in apes than in man; but the superior postcentral part is either not developed or is rudimentary in them (fig. 107). The so-called horizontal part is not truly horizontal, but has an upward inclination which is more marked in the male human brain than in the female.

The **posterior central, postcentral, or ascending parietal convolution** (fig. 101, *A.P.*) lies behind the fissure of Rolando, between this and the postcentral sulcus, and parallel to the ascending frontal convolution, with which it is usually continuous below the fissure of Rolando. Above, it is connected by a broad annectent gyrus with the superior parietal convolution, and is continued on to the mesial surface by a narrow annectent which unites it with the posterior part of the marginal gyrus (paracentral lobule).



The **superior parietal convolution** or **superior parietal lobule** (fig. 101) is that part of the parietal lobe which lies above the pars horizontalis of the intraparietal sulcus, and behind the upper part of the last described convolution, from which it is imperfectly separated by the upper part of the postcentral sulcus. Its posterior limit is the boundary of the parietal lobe, viz., the parieto-occipital fissure, round the extremity of which an annectent convolution connects this lobule with the occipital lobe (*upper parieto-occipital annectent gyrus*). The superior parietal is continuous on the mesial surface of the hemisphere with the quadrate lobule. It is often deeply cut into by an ascending branch of the intraparietal sulcus.

The **quadrate lobule** (precuneus, fig. 102) is the part of the parietal lobe which is seen on the mesial surface of the hemisphere. It is bounded in front by the posterior limb of the paracentral fissure, and behind by the parieto-occipital fissure, and is incompletely separated from the posterior portion of the limbic lobe by the postlimbic fissure. Its surface is indented by one or two furrows which cut the margin of the hemisphere, and extend a variable distance over the surface of the lobule (*precuneate sulci*).

The **inferior parietal lobule** is embraced within the curve of the intraparietal sulcus. It is bounded behind by the lower limb of the anterior occipital fissure. It is divided into three gyri, viz.: the supramarginal, the angular, and the postparietal (fig. 101). The **supramarginal convolution** lies behind and below the anterior part of the intraparietal sulcus, beneath the lower end of which it is continuous with the ascending parietal convolution. It arches round the upturned extremity of the fissure of Sylvius, to become continuous with the superior temporal convolution below, and with the angular behind. The **angular gyrus**, connected in front with the supramarginal, bends over the end of the parallel (first temporal) sulcus, and is continued below into the first and second temporal gyri. Behind, it is separated from the postparietal gyrus by a shallow vertical sulcus, which may be absent. The **postparietal gyrus** curves round the upturned end of the second temporal sulcus. (In the brain figured this appears like a continuation of the first temporal sulcus.) It is continued below into the second and third temporal gyri.

**OCCIPITAL LOBE.**—This lobe is very well marked off in *Quadrumania* by the deep cleft (*Affenspalte*) before mentioned (p. 144); but in man the line of demarcation between it and the adjacent parietal and temporal lobes is less distinct. It is relatively much larger in *Quadrumania*, especially in the lower monkeys, than in man.

The lobe is of pyramidal shape, lying behind the parietal and temporal lobes. In the adult its length, as compared with that of the whole hemisphere, is about as 21 to 100 (occipital index, Cunningham). It has two free surfaces, an external or lateral, and a mesial. It occupies the superior fossa of the occipital bone. On the external surface it is bounded in front by the parieto-occipital fissure, by the anterior occipital sulcus, and by a line connecting the lower end of this sulcus with the posterior extremity of the calcarine fissure. The line in question mainly corresponds with a horizontally-directed sulcus, which is termed by Eberstaller the *lateral occipital*: this sulcus may therefore be regarded as the lower boundary of the occipital lobe on the lateral surface. On the mesial surface of the hemisphere the lobe is marked off by the parieto-occipital fissure from the quadrate lobule, and by the posterior calcarine from the temporal lobe (fig. 102).

In assigning the above limits to the occipital lobe I have followed Eberstaller, and have departed from the usual description which includes in the lobe all the parts behind the plane of the parieto-occipital fissure, and therefore the posterior parts of the parietal and temporal lobes as here described. It seems to me, however, that Eberstaller's definition, although it confines the occipital lobe in man to relatively small limits, has the advantage of assigning well-marked anatomical boundaries to it and to the adjacent lobes, thus rendering a description of this part of the brain more easy.

**EXTERNAL SURFACE.**—The bounding sulci of the external surface of the occipital lobe are, as we have seen, the external part of the parieto-occipital, the anterior occipital, and the lateral occipital. The parieto-occipital has already been described (p. 143). The **anterior occipital sulcus** (**transverse occipital** of Ecker) is a transverse furrow, which is laid down as a distinct sulcus in the fœtus, but is later almost invariably joined by the horizontal part of the intraparietal, of which it then appears to be the bifurcated posterior end (p. 150). In *Quadrupedia* it is concealed by the occipital operculum, but on drawing this aside it may still be seen at the bottom of the “*Affenspalte*.” It approaches the mesial border of the hemisphere above, behind the parieto-occipital fissure, from which it is separated by an annectent gyrus which joins the occipital lobe with the superior parietal lobule. Its lower end, which is often curved forwards, is usually separated from the lateral occipital by the *inferior parieto-occipital annectent gyrus* uniting the occipital lobe with the postparietal gyrus. In the brain figured (fig. 101), this second occipito-parietal annectent lies deeply, and the two fissures are superficially joined.

The **lateral occipital sulcus** runs somewhat obliquely upwards and backwards from a short distance below and in front of the lower end of the anterior occipital towards the occipital pole of the hemisphere. But before reaching the pole it generally bifurcates in a Y, one branch curving upwards into the occipital lobe, the other downwards towards the posterior end of the calcarine; it may be embraced by the bifid extremity of the latter. Around its end a *lateral occipito-temporal annectent gyrus* curves, uniting the occipital lobe with the third temporal gyrus. Within the limits of the occipital lobe as here defined there are usually two or three small sulci of varying extent. These are, however, not constant enough in position and direction to serve for marking out this surface into distinct gyri.

The external surface has usually been described (*e.g.*, in previous editions of this work) as having three gyri, a *superior*, *middle* and *inferior*. But this description does certainly not hold good for most brains, and if any division is to be made it must be into *anterior* (between the anterior occipital sulcus and the upturned end of the lateral occipital) and *posterior* (behind the upturned end of the lateral occipital).

**MESIAL SURFACE.**—The mesial surface of the occipital lobe is occupied by a well-marked gyrus termed the **cuneate lobule** (*cuneus*) (fig. 102). This is of a triangular shape, and is bounded in front by the parieto-occipital fissure, and below by the calcarine, while above and behind it reaches the margin of the hemisphere and is continuous with the external surface. It is indented by two or three shallow vertical sulci.

The parieto-occipital and calcarine fissures which bound the mesial surface have already been described, as well as the deep annectent gyri which pass across them and connect the cuneus with the adjacent lobes (see p. 144).

The superior longitudinal venous sinus in passing downwards causes an impression on the inner side of the occipital pole of the hemisphere (Bastian). This impression is generally found on the right side, but sometimes on the left.

According to the usual description, which has been followed in previous editions of this work, the occipital lobe has a tentorial surface, comprising the lingual gyrus and posterior part of the occipito-temporal gyrus (*fusiform lobule*), which run in a sagittal direction, and are separated from one another by the posterior end of the collateral fissure. But by confining the occipital lobe to the limits above assigned, these gyri and sulci become entirely included in the temporal lobe, along with which they will accordingly be described.

**TEMPORAL LOBE.**—The *temporal* or *temporo-sphenoidal lobe* is bounded above for two-thirds of its length at first by the stem and afterwards by the posterior limb of the fissure of Sylvius, which separates it from the frontal and part

of the parietal. Behind and above it is continuous with part of the parietal lobe. Behind, it is separated from the occipital lobe by the lateral occipital sulcus. It is somewhat pyramidal in shape, having three surfaces, viz., lateral, superior and inferior, the superior concealed within the fissure of Sylvius. The under surface adjoins the limbic lobe, being separated from the hippocampal gyrus of that lobe by the collateral fissure. The rounded apex of the pyramid is free, is directed forwards, and lies underneath the orbital surface of the frontal lobe, from which it is separated by the broad commencement of the Sylvian fissure.

**GYRI AND SULCI OF THE UPPER SURFACE.**—The upper surface of this lobe, directed towards the insula and fronto-parietal operculum, is marked by two or three **transverse temporal gyri** (Heschl). On the nearly smooth part of the surface in front of these are three short gyri (*m*, fig. 108) separated by shallow sulci, which are directed from the gyrus longus insulæ towards the tip of the temporal lobe.

**SULCI AND GYRI OF THE LATERAL AND UNDER SURFACES.**—On these surfaces there are four sulci with an antero-posterior direction. The **first** or **superior temporal sulcus**, also termed from its relation to the Sylvian fissure the *parallel fissure* (fig. 101, *t*<sub>1</sub>), is an important furrow, appearing in the sixth month, and being constant in the Primates. In many monkeys it is more extensive than in man, nearly reaching the parieto-occipital fissure at the margin of the hemisphere. The angular gyrus curves round its extremity. Both this and the second temporal turn upwards as they pass back. The upturned extremity of the second sulcus may appear as a continuation of the parallel, as in the brain here figured (fig. 101). The fissure is sometimes interrupted by a small gyrus connecting the convolutions above and below it. The **second temporal sulcus** (*t*<sub>2</sub>) runs parallel to and below the last, but is less constant in extent and direction. It is often interrupted by one or more vertical connecting gyri. The postparietal gyrus curves round its extremity. The **third temporal sulcus** (*t*<sub>3</sub>) is seen on the under surface of the lobe, extending behind nearly to the occipital pole. It is often interrupted near its anterior and posterior ends, and sometimes also about the middle by annectent gyri. In front it generally fails to reach the extremity of the lobe, which forms a smooth "pole" from which most of the sulci diverge. A **fourth temporal sulcus** (*t*<sub>4</sub>) is formed by the collateral fissure, which has already been noticed (p. 145) (figs. 101, 103).

On the lateral surface of the lobe three convolutions can usually be distinguished. The **first** or **superior temporal gyrus** (fig. 101, *F*<sub>1</sub>) bounds the posterior limb of the Sylvian fissure below, and is continuous behind with the supramarginal and to a less extent with the angular convolution of the parietal lobe. The **second temporal gyrus** (*T*<sub>2</sub>) is continuous with the angular and postparietal gyri. The **third temporal gyrus** (*T*<sub>3</sub>) is continuous with the occipital lobe by the annectent gyrus which passes between the calcarine and lateral occipital sulci. On the under surface of the lobe is the **fourth temporal gyrus**, lying between the third temporal sulcus and the collateral fissure. The second and third gyri are convolutions of some thickness, and are a good deal interrupted by transverse and oblique secondary sulci. The fourth, which was formerly known as the first occipito-temporal, is narrower, and more sharply marked off by its bounding sulci. Its posterior part, which has been termed the *fusiform lobule*, is usually described as belonging to the occipital lobe (see previous page). Lastly, between the posterior part of the collateral and the calcarine fissure is a **fifth temporal gyrus**, which was termed by Huschke the *lingual lobule*, but it is better termed *infracalcarine gyrus* (*subcalcarine gyrus* of Wilder). This is continuous in front with the hippocampal gyrus of the limbic lobe (see below). It is joined by two deep annectent gyri, which pass across the posterior calcarine fissure, connecting this gyrus with the cuneus (fig. 102, 2 and 3).

The temporal lobe lies in the middle fossa of the skull, and its posterior part overlies the tentorium.



**THE CENTRAL LOBE OR ISLAND OF REIL.**—This lobe is entirely concealed in the adult human brain within the fissure of Sylvius, the margins of which form opercula (see p. 142) which overlap the lobe. The central lobe corresponds with the corpus striatum on the interior of the hemisphere (fig. 88), and probably in consequence of its close connection with this mass of grey matter, which appears early as a thickening of the lateral wall of the vesicle of the cerebral hemisphere (vide Embryology, Vol. I., p. 69), this particular part of the hemisphere does not keep pace with the general expansion which the hemisphere-vesicles undergo, and hence in consequence of that expansion it becomes overlapped and concealed by the rest of the hemisphere. On account of this early fixation and the close topographical relation between it and the largest of the basal ganglia, the central lobe (along with the basal ganglia and the continuation of the peduncles between them) is frequently spoken of as the *stem* (German, *Stammtheil*) of the hemisphere, the remainder of the cerebrum, which covers it in, being known collectively as the *mantle*.

To see the island it is necessary to cut away the opercula (fig. 108). It then appears as a triangular surface somewhat bulged outwards, the base of the triangle

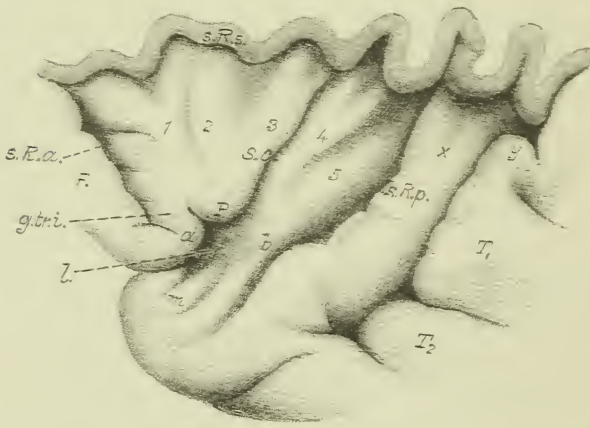


Fig. 108.—ISLAND OF REIL EXPOSED BY CUTTING AWAY THE UPPER OPERCULUM AND DRAWING ASUNDER THE ORBITAL AND TEMPORAL OPERCULA. (Eberstaller.)

*s.c.*, sulcus centralis insulæ; 1, 2, 3, gyri breves; 4, 5, gyrus longus; *s.R.a.*, *s.R.s.*, *s.R.p.*, anterior, superior, and posterior limiting sulci; *l.*, limen insulæ; *F.*, orbital part of third frontal gyrus; *T<sub>1</sub>*, *T<sub>2</sub>*, first and second temporal gyri; *x, y*, upper transverse temporal gyri; *g.t.r.i.*, gyrus transversus insulæ, passing at *a*, into the orbital part of the third frontal; *b*, connection of gyrus longus insulæ with apex of temporal lobe; *m*, short gyri on the upper surface of the temporal pole.

being directed upwards and the apex being at the vallecula Sylvii. This surface is marked out by shallow sulci, which have a fan-like arrangement converging from the base towards the apex of the triangle, into several straight gyri having a similar convergent course. One of these sulci, which is deeper and appears earlier than the rest, and is also more constant in lower Primates, has been termed the **sulcus centralis insulæ** (Guldberg) (fig. 108, *s.c.*), and this serves to subdivide the lobe into two parts, a *precentral* and *postcentral lobule*. Since the line of direction of this sulcus nearly corresponds with that of the fissure of Rolando in the mantle, the pre- and post-central parts of the island similarly correspond to the frontal and parieto-temporal lobes of the mantle; and they are in fact in continuity with the parts of those lobes which form the opercula. The island is, however, separated from these adjacent parts by a sulcus (**sulcus limitans insulæ**) which almost entirely surrounds it, and which is itself formed of an anterior, a superior, and a posterior part (fig. 108). The anterior and posterior parts of the limiting sulcus are, however, deficient near the apex of the lobe, so that there here occurs a direct continuity (by a small convolution, the *gyrus transversus insula* of Eberstaller) between the orbital part of the third frontal convolution as it dips round the margin of the Sylvian fossa, and the precentral lobule on the one hand, and between the limbic lobe and the extremity of the postcentral lobule on the other hand.

The **precentral lobule** of the insula is formed of a few short convolutions (*gyri breves*) (fig. 108. 1. 2. 3) converging from the base of the triangle but falling short of the apex of the lobule, which is smooth and forms a slight prominence (*pole of the island, p*). These convergent gyri are usually three in number (anterior, middle, and posterior), being subdivided in this manner by secondary and somewhat shallow sulci, having the same direction. The most marked of these sulci lies between the middle and posterior gyri breves, and has been named *sulcus precentralis insulae*. A fourth small gyrus is described by Eberstaller as lying deeply underneath the orbital operculum. This he has termed the *gyrus brevis accessorius*. This accessory gyrus, and usually also the anterior of the three gyri breves, look forwards, lying upon an *anterior surface* of the insula, which is sometimes nearly at a right angle with the lateral or general surface, in other brains hardly marked off from it. Its grey matter is continued over the anterior limiting sulcus into that of the orbital gyrus. The grey matter of the rest of the precentral lobule is continuous superiorly with that of the frontal lobe, inferiorly with that of the anterior perforated space. The inferior transitional part has been termed the *threshold of the island (limen insulae, Schwalbe)*.

The **postcentral lobule** (*gyrus longus insulae* of Giacomini (fig. 108, 4. 5)) is also often subdivided at its upper end by a longitudinal furrow (*sulcus postcentralis insulae*) into two parts, anterior and posterior. Its grey matter is continuous below with the tip of the hippocampal gyrus, laterally with that of the first temporal gyrus, above and posteriorly over the limiting sulci with the grey matter of the parietal and temporal opercula.

The three principal furrows of the insula (*sulcus centralis, s. precentralis, and s. postcentralis insulae*), which radiate from the vallecule Sylvii, have been compared with the three similarly radiating fissures of the mantle, viz., the fissure of Rolando, the precentral fissure, and the intraparietal fissure. They are not, however, directly continuous with those, being arrested at the *sulcus limitans insulae*. Sometimes the fissure of Rolando is continued by a small sulcus (transverse precentral) almost into the *s. centralis insulae*. Below and anteriorly the *sulcus centralis insulae* comes into close relationship with the extremity of the callosomarginal sulcus.

**LIMBIC LOBE.**—The *callosal gyrus*, with its continuation the *hippocampal gyrus*, were separated by Broca, on morphological grounds, from the other parts of the hemisphere, as a distinct lobe, intimately united in front and below with the olfactory lobe; and the name of *grande lobe limbique* was given by him to these combined lobes. To this lobe of Broca, Schwalbe added the other central parts of the mesial wall of the hemisphere, viz., the *lamina septi lucidi* and the *dentate convolution*, as well as the *fornix*; looking upon these as representing an inner encircling convolution concentric with the gyrus fornicatus and uncinatus, and naming the whole lobe thus reconstituted, the “falciform lobe,” the olfactory lobe being, however, excluded.

To the parts included by Schwalbe there must now be added a rudimentary *supracallosal gyrus* (represented in man principally by the longitudinal striæ of the corpus callosum), which is continuous with the dentate convolution posteriorly, and with the rudimentary *gyrus geniculi* (see p. 158) anteriorly. The lobe must further include the peduncles of the corpus callosum (see p. 127), which appear to represent a rudimentary gyrus (*gyrus subcallosus, Zuckerkandl*), and also another rudimentary gyrus underneath the corpus callosum, partly imbedded in and intimately connected with the fornix, to which the name of *gyrus infracallosus* or *gyrus fornicis* may be applied.

As thus constituted the limbic lobe is bounded circumferentially mainly by two important fissures, the callosomarginal above, and the anterior part of the collateral below, while the less constant postlimbic sulcus separates it behind from the parietal lobule, and the anterior end of the calcarine cuts into it just below the splenium.

The circumferential boundary is least distinct opposite the quadrate lobule, from which it is only separated by the small postlimbic sulcus, which in man is only occasionally continued into the callosomarginal. But in many animals the fissure which forms the external boundary is uninterrupted or nearly so, and forms the *limbic fissure* of Broca. This might perhaps more appropriately be termed the *outer limbic fissure*, since the callosal sulcus and the hippocampal fissure form together a second crescentic fissure within the limbic lobe, which may be distinguished as the *inner limbic fissure*. The internal limit of the lobe is formed by the *fissura choroidea* (Schwalbe), through which the choroid plexus is invaginated into the



lateral ventricle. The lobe is pierced by the great commissure of the hemispheres (the corpus callosum) and also by the anterior commissure. It is connected by annectent gyri with the lingual gyrus of the temporal lobe (see p. 153), with the cuneus of the occipital lobe (by a

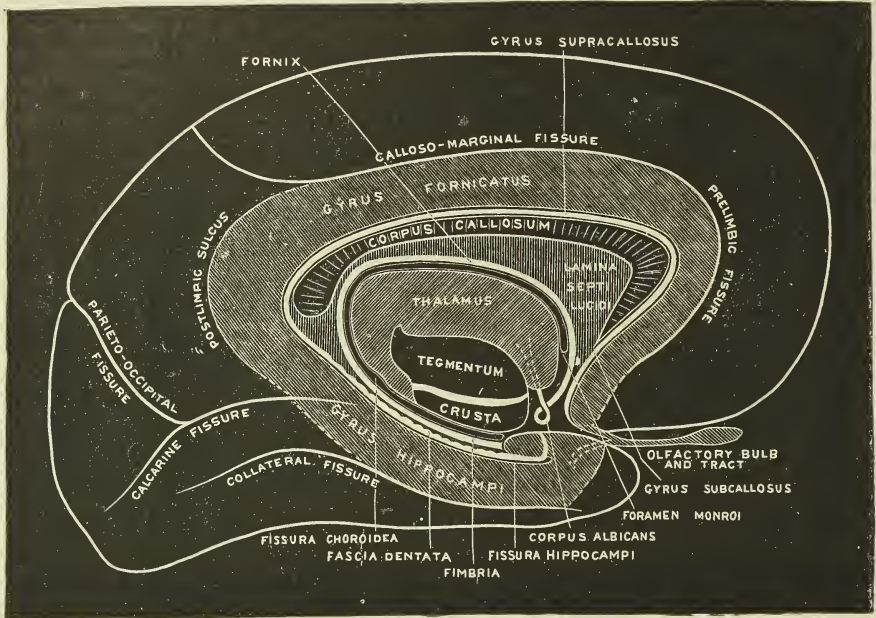


Fig. 109.—DIAGRAM OF THE LIMBIC LOBE.

gyrus hidden within the internal parieto-occipital fissure), with the quadrate lobule, with the orbital part of the frontal lobe, with the anterior part of the temporal lobe, and with the post-central lobule of the insula.

Each end of this crescentic lobe is connected with one of the roots of the olfactory tract, viz., the commencement of the gyruS fornicatus with the mesial root and the termination of the hippocampal gyruS with the lateral root.

CONVOLUTIONS AND FISSURES IN THE LIMBIC LOBE (fig. 102).—**GyruS fornicatus, gyruS cinguli, callosal gyruS.** This is an extensive convolution which lies between the marginal gyruS of the frontal lobe and the quadrate lobule of the parietal lobe above and the corpus callosum below. The convolution sweeps round the corpus callosum, beginning below its rostrum, where it abuts on the subcallosal gyruS, and ending a little below the level of the splenium by becoming continuous with the posterior end of the hippocampal gyruS. Where it passes into that gyruS it is much narrowed (isthmus).<sup>1</sup> It is separated from the corpus callosum by a fissure which is termed the *callosal sulcus*.

The **hippocampal gyruS** (*subiculum cornu ammonis*), also known, together with the infracalcarine, as the **uncinate gyruS**, is continued from the isthmus of the callosal convolution, and passes forwards above the anterior part of the collateral fissure towards the apex of the temporal lobe (figs. 102, 103). It ends before reaching this, however, becoming considerably thickened, and forming a recurved projection which looks backwards and inwards, and is known as the *uncus*. The hippocampal gyruS is covered superficially by a well-marked reticular layer of white fibres (*substantia reticularis alba*, Arnold (fig. 103, *s.r.a.*)).

The **dentate gyruS** (*fascia dentata Tarini* (fig. 102, fig. 110, *f.d.*)) lies above the hippocampal gyruS, from which it is separated by the *hippocampal* or *dentate fissure* (*f.h.*).

<sup>1</sup> By some authors the term gyruS fornicatus is made to include the hippocampal gyruS.



It is a narrow convolution having a peculiarly toothed or notched appearance at its free border, hence the name dentate. Above and overlapping it is the fimbria, from which it is separated superficially by a shallow sulcus (*fimbrio-dentate, f.f.-d.*), narrow in front

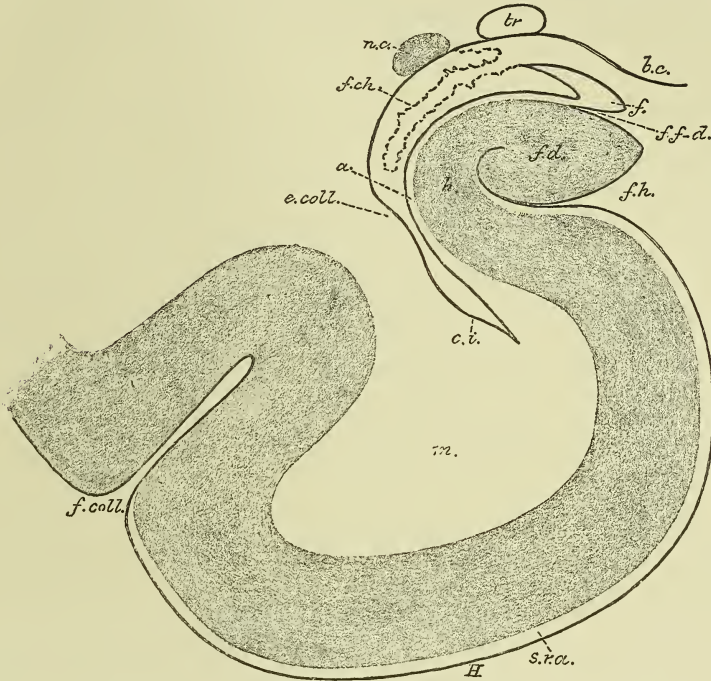


Fig. 110.—DIAGRAM OF A SECTION THROUGH THE LEFT HIPPOCAMPAL REGION (E. A. S.)

*b.c.*, basis cerebri; *tr.*, tractus opticus; *n.c.*, nucleus caudatus; *f.ch.*, fissura choroidea; *f.*, fimbria; *f.f.-d.*, fissura fimbrio-dentata; *f.d.*, fascia dentata; *f.h.*, fissura hippocampi; *h.*, hippocampus major; *a.*, alveus; *e.coll.*, eminentia collateralis; *c.i.*, cornu inferius ventriculi; *H.*, gyrus hippocampi; *m.*, its medullary centre; *s.r.a.*, substantia reticularis alba; *f.coll.*, fissura collateralis.

but broadening out behind, where it forms a triangular depression below the splenium of the callosum. The gyrus dentatus begins posteriorly just behind and above the splenium by a fine curved lamina (fasciola cinerea), which is continuous with the longitudinal striæ (both lateral and mesial) of the corpus callosum (p. 127). From here it bends downwards, lying along the isthmus of the gyrus fornicatus and then along the upper border of the hippocampal gyrus; here the posterior pillar of the fornix passes to its upper border in continuity with the fimbria (see p. 130). Anteriorly it is continued into the cleft between the hippocampal gyrus and its uncus, where it becomes lost to view. But if this cleft be opened out (fig. 111) the dentate gyrus is seen to exhibit a sharp curve within it, and in continuity with the curved end a greyish band emerges from the cleft and passes transversely over the uncus to disappear on the ventricular surface of that gyrus (Luschka, Giacomini).

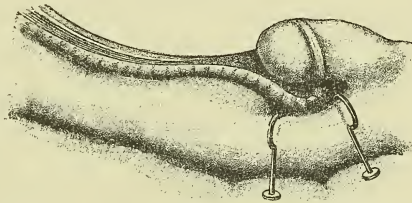


Fig. 111.—HIPPOCAMPAL GYRUS AND FASCIA DENTATA, SHOWING THE CONTINUITY OF THE LATTER WITH THE BAND OF GIACOMINI PASSING OVER THE UNCUS. (Testut.)

The part of the gyrus dentatus which lies below the splenium is sometimes much more developed than usual, and shows strongly marked folds or dentations which recall the broad

and secondarily convoluted gyrus dentatus which covers the under surface of the splenium in some mammals (G. Retzius).

Hidden beneath the posterior part of the callosal gyrus, between this and the subsplenial part of the gyrus dentatus, a small projection of the cortex is usually to be found, about 1 cm. long and 2 mm. to 4 mm. broad, marked by 1 to 4 semicircular eminences. This has been described (by A. Retzius originally, and more recently and fully by Zuckerkandl) under the somewhat misleading name of *callosal gyrus* (Balkenwindung), but is not to be confounded with the gyrus cinguli which has long been so denominated. It is best developed in osmatic mammals.

The **fimbria** (fig. 102, *fi*) represents the white matter of the hemisphere, which here comes to the surface along the side of the dentate gyrus. It is continuous with the alveus which covers the hippocampus major within the lateral ventricle, and this is continuous with and forms part of the central white matter. The fimbria itself, however, appears to be actually formed of fibres which are prolonged into it posteriorly from the pillars of the fornix: anteriorly it is continued into the white matter of the uncus. In section the fimbria appears as a somewhat club-shaped expansion of the alveus, exhibiting a hook-like mesial prolongation (fig. 110, *f*). This is the section of a thin lamina (*tenia fimbriæ*), continuous with the epithelium covering the choroid plexuses which here invaginate the ventricular epithelium.

The only sulcus within the limbic lobe which remains to be described (the *callosal sulcus* and the *fimbrio-dentate sulcus* having been already noticed) is the **hippocampal** or **dentate fissure** (fig. 102, *h*). This begins as a shallow furrow just above the posterior end of the splenium corporis callosi, between the fasciola cinerea and the end of the gyrus fornicatus, it then lies between the remainder of the dentate gyrus above and the isthmus gyri fornicati and hippocampal gyrus below, and becoming deeper as it passes forwards ends in the bend between the hippocampal gyrus and its uncus. This fissure causes the elevation of the hippocampus major or cornu Ammonis in the descending horn of the lateral ventricle (fig. 110).

**Gyrus fornicis.**—The **fornix** which has already been in the main described (p. 129) also belongs to the limbic lobe as here defined. It contains an association-bundle uniting the hippocampus major with the olfactory lobe. This bundle, the *olfactory bundle of the cornu Ammonis* (Zuckerkandl), best developed in osmatic mammals, is contained within the body of the fornix, but leaves the anterior pillar to pass in front of the anterior commissure and then to run in the subcallosal gyrus to the vallicula Sylvii. Here it divides into two parts, one (pars olfactoria) passing by the anterior circumference of the lamina perforata anterior to the inner root of the olfactory tract, and the other (pars temporalis) at the hinder border of the anterior perforated lamina to the point of the hippocampal gyrus. This is the band which has been described (by F. Arnold and Broca) as continuing the peduncle of the corpus callosum with the hippocampal gyrus.

In the monkey there is a band of grey matter running along the upper surface of the fornix, on each side near the middle line, wedged in between it and the corpus callosum. This closely resembles the supracallosal gyrus above the callosum (see below), and appears to be part of another rudimentary gyrus which may be termed *gyrus infracallosus*, or, including certain patches of grey matter which occur here and there in the substance of the fornix, *gyrus fornicis*.

The **cingulum**, which also belongs to the limbic lobe, is a tract of association-fibres running in the gyrus hippocampus and gyrus fornicatus. The bundle has for the most part a longitudinal course within the white matter of these gyri; but the fibres probably commence in the cortex, and since they constantly tend, as the whole bundle courses longitudinally, to diverge into the adjacent white matter of the hemisphere, it appears probable that they connect the hippocampal and callosal gyri with the cortex of the outer surface of the hemisphere (Beever). A bundle of fibres having a somewhat similar course in the anterior descending part of the gyrus fornicatus is usually described as part of this tract; but according to Beever it is doubtful if these fibres can be considered to belong to the cingulum; at all events, their continuity with the remainder of that tract could not be traced.

**Gyrus limbicus.**—The longitudinal striæ of the corpus callosum (p. 127) belong to a thin lamina of grey matter which extends over the surface of the corpus callosum from the lower edge of the gyrus fornicatus, and is much better developed in osmatic mammals than in Primates (Valentin, Jastrowitz). The striæ, together with this grey matter, represent a degenerated convolution (*supracallosal gyrus*, Zuckerkandl), which is continuous posteriorly with the fasciola cinerea, *i.e.*, with the dentate gyrus. Together with another degenerated gyrus in front, which is represented only by the prolongation of the stria medialis (*gyrus geniculi* of Zuckerkandl) these



form a rudimentary gyrus (*bordering gyrus, gyrus marginalis*,<sup>1</sup> Germ. *Randwindung*), which is curved around the brain-stem and the central parts of the hemisphere, lying within and concentric with the larger and well-developed gyrus formed by the fornicate and hippocampal gyri. The lamina of the septum lucidum, and the so-called peduncle of the corpus callosum (gyrus subcallosus of Zuckerkandl) also belong to this bordering gyrus, but have become separated from the supracallosal part by the development of the corpus callosum; and the gyrus infracallosus (where this exists) and the fornix and fimbria may also be considered to form part of it.<sup>2</sup>

**OLFACTORY LOBE.**—This lobe (fig. 112) lies at the ventral aspect of the frontal lobe. It is rudimentary in man and other Primates, and in the seals, and is lacking in Cetacea, but in all other mammals (osmatic mammals, Broca), and in vertebrates generally, it is well developed and forms a distinct portion of the cerebral hemisphere, enclosing an extension of the ventricular cavity. In some mammals (*e.g.*, horse) this extension remains throughout life in free communication with the anterior horn of the lateral ventricle, in others (*e.g.*, dog) the communication is lost. In the human fœtus of from two to four months, it appears as a hollow projection of the fore-brain, but as the walls of this projection thicken by the development of nervous tissue within them, the cavity becomes gradually obliterated, and is ultimately entirely occupied by a mass of neuroglia (central neuroglia of the olfactory tract and bulb). Compare Vol. I., pp. 71 and 79.

Anteriorly the olfactory lobe is connected with the olfactory cells of the olfactory mucous membrane, posteriorly it is connected with the two extremities of the limbic lobe.

The olfactory lobe may be described (His) as composed of two parts or lobules, an anterior and a posterior. The *anterior olfactory lobule* comprises (1) the *olfactory bulb*, which rests on the cribriform plate of the ethmoid bone, and receives the fibres of the olfactory nerves, which originate in the cells of the olfactory mucous membrane, (2) the *olfactory tract*, which lies in the olfactory sulcus of the frontal lobe, and posteriorly bifurcates into two roots, mesial and lateral, which diverge as they pass backwards and enclose (3) a space, the *trigonum olfactorium*, which is also known as the middle or grey root of the tract, (4) the *area of Broca* (His), a portion of grey matter lying between the mesial root and the peduncle of the corpus callosum, and continuous with the commencement of the callosal gyrus. This area is separated from the posterior part of the gyrus rectus of the frontal lobe by an oblique sulcus (*fissura serotina*, His).

The *posterior olfactory lobule* is marked off from the anterior by a curved fissure (*fissura prima*, His). It is formed by the portion of brain cortex, which appears on the surface at the anterior perforated space, and is bounded mesially by the peduncle of the callosum (gyrus subcallosus of Zuckerkandl), anteriorly by the fissure just referred to, whilst laterally it is continued into the vallecule Sylvii, and is concealed by the temporal lobe which overlaps it. The continuation of the lateral root of the olfactory tract courses lateralwards and backwards over the surface, as it passes towards the anterior end of the hippocampal gyrus.

The **olfactory bulb** (figs. 103, 112) is oval in shape and of a reddish-grey colour when viewed from the ventral aspect. It is nearly a centimeter long and about a third of this in width; from its posterior extremity the olfactory tract emerges. Its dorsal surface, which is in contact with the frontal lobe, is white and is directly prolonged into the tract. This surface presents a longitudinal ridge which fits into the anterior end of the sulcus olfactorius of the frontal lobe.

The **olfactory tract**, sometimes erroneously spoken of as the olfactory nerve, is a band of white matter, flattened on the ventral aspect but ridged along the dorsal

<sup>1</sup> Not to be confounded with the gyrus marginalis on the mesial surface of the frontal lobe (see p. 148).

<sup>2</sup> Zuckerkandl describes two bordering gyri, an outer and inner, the outer being formed by the dentate gyrus, the gyrus supracallosus and the gyrus geniculi, and continued into the inner root of the olfactory tract; the inner by the fimbria, fornix, lamina septi lucidi, and gyrus subcallosus.



aspect (where it fits into the olfactory sulcus), and therefore triangular in section. It measures about 2 centimeters in length and  $2\frac{1}{2}$  millimeters in breadth, being narrowest anteriorly where it passes out of the bulb, and broadening posteriorly as it bifurcates to form the roots. As already stated it encloses a central grey substance formed of neuroglia.

The **trigonum olfactorium** and the **area of Broca** are in fact parts of one and the same area of grey matter which forms the base of the anterior olfactory lobule, and is traversed by the roots of the olfactory tract. This area is separated from the peduncle of the callosum and the posterior olfactory lobule by the fissura prima, and the mesial root of the olfactory tract in passing over its ventral surface subdivides it superficially into its two parts. Of these the area of Broca receives many fibres from the mesial root as this passes over the surface, whilst the trigonum olfactorium receives others which are directly prolonged into it from the posterior

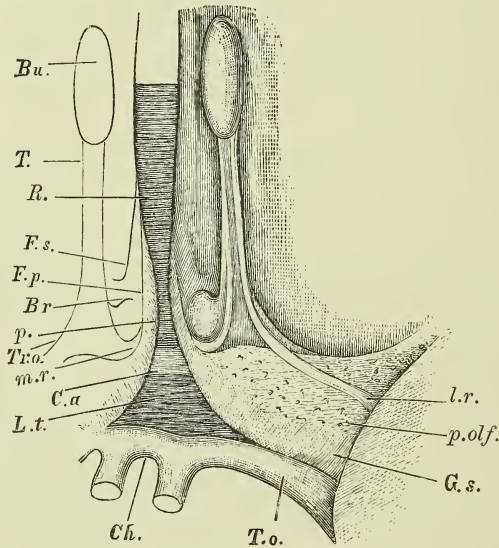


Fig. 112.—OLFACTORY LOBE OF THE HUMAN BRAIN (His).

*Bu.*, olfactory bulb; *T.*, tract; *Tr.o.*, trigone; *R.*, rostrum of corpus callosum; *p.*, peduncle of corpus callosum, passing into, *g.s.*, gyrus subcallosus (diagonal tract, Broca); *Br.*, Broca's area; *F.p.*, fissura prima; *F.s.*, fissura serotina; *C.a.*, position of anterior commissure; *L.t.*, lamina terminalis; *Ch.*, optic chiasma; *T.o.*, optic tract; *p.olf.*, posterior olfactory lobule (or anterior perforated space); *m.r.*, mesial root; *l.r.*, lateral root of tract.

end of the tract, and which sometimes form a distinct middle root of the tract. The ultimate destination of these fibres which pass into the trigone is not accurately known, but some appear to join the anterior commissure and to be conducted by this into the posterior part of the temporal lobe, and others, according to Meynert, may pass across in this commissure to the temporal lobe and hippocampal region of the opposite side, an "olfactory chiasma" being thereby produced. The evidence in favour of this crossed connexion is, however, at present insufficient. Fibres from the posterior end of the olfactory tract also pass directly into the white matter of the frontal lobe: these have been named the *upper* or *dorsal* root of the olfactory tract (Henle).

The *outer* or *lateral* root passes as already stated over the outer part of the substantia perforata anterior, and becomes lost to view in the depth of the vallicula Sylvii. In osmatic mammals it can be traced without difficulty into connection with the anterior part of the hippocampal gyrus, and, according to Luys, with the nucleus amygdalæ. The *inner* or *mesial* root is recurved sharply around the posterior limit of Broca's area, and its fibres pass partly into this, partly into the callosal gyrus. The olfactory tract has thus a relation to the limbic lobe which has been compared to that of the handle of a tennis-racquet to the ring of the blade, the two extremities of the curved limbic lobe being continuous respectively with the inner and outer roots of the olfactory tract (fig. 109). The combined olfactory and limbic lobes may be spoken of collectively as the *rhinencephalon*; it is marked off from the rest of the hemisphere by the combined callosal-marginal, postlimbic and collateral fissures forming together the limbic fissure, and in its development it varies directly with that of the olfactory organ. This co-relation in development applies more

especially to the hippocampal convolution, which in many smooth-brained osmatic mammals forms a considerable proportion of the hemisphere (*lobus hippocampi*).

The term rhinencephalon is limited by Turner to the olfactory and hippocampal lobes, but there seems no sufficient reason for excluding the remainder of the limbic lobe, the several parts of which are all closely inter-related. At the same time it must be pointed out that the limbic lobe unquestionably subserves other functions beside that of a central organ for the olfactory sense, since it is present even in those mammals (*Delphinidæ*) which are devoid of an olfactory sense, and in which the olfactory lobe proper is entirely absent. The results of experiment seem to indicate an association of parts of the limbic lobe with the perception of tactile sensations. (Consult on the comparative development of the rhinencephalon and the mantle in mammals, "The Convolution of the Brain, a Study in Comparative Anatomy," by Professor Sir W. Turner, *Journal of Anatomy*, October, 1890.)

ON THE VARIATIONS WHICH OCCUR IN THE DISPOSITION OF THE FISSURES AND CONVOLUTIONS IN INDIVIDUALS OF DIFFERENT AGE, SEX, INTELLECTUAL DEVELOPMENT, AND RACE.

Very considerable variations are found in the course and relative development of the fissures and convolutions, and this not only in different individuals, but also on opposite sides of the same brain. Even the principal fissures, under which term may be included both those which occur as complete folds of the hemisphere-wall (*Sylvian*, *hippocampal*, *calcarine*, *parieto-occipital*, and *collateral*), and those which are the first to make their appearance (about the sixth month of foetal life) as indentations of the smooth surface of the mantle (*precentral*, *Rolandic*, *intraparietal*, *parallel*, *olfactory*, *calloso-marginal*), are very subject to modification, as may partially be inferred from the detailed accounts which have already been given. Although a considerable amount of attention has been paid by several observers to these variations, and of late years especially by Pansch, Sernoff, Huschke, Rüdinger, Giacomini, Eberstaller, and Cunningham, it cannot be considered as proved that there is any constant relationship between any of the variations which are found to occur, and either the age, sex, occupation, or even the race of the individual. Various attempts have from time to time been made to determine in particular a sexual distinction, but it has invariably appeared that the inferences which had been drawn from an insufficient number of observations are not borne out by a more extended series. It is more probable that certain racial differences may ultimately be established when a sufficient number of brains belonging to individuals of other than European races shall have been carefully examined, but up to the present the materials for such comparison have not been abundant enough. In brains of individuals belonging to lower races which have been described (*Bushmen*, *Fuegians*, *Lapps*, and others), it has not appeared that there is any distinct lack of complexity in the convolutions as compared with ordinary European brains, but it is probable that if a large number were to be examined the average complexity in such races would be below that of the average European brain. This is in fact stated by Parker to be the case for the brain of the negro, but the number examined were not sufficient to be considered conclusive. There is apparently, however, more distinct evidence to show that complexity of convolution generally goes hand in hand with intellectual development of the individual, for in many cases in which the brains of men of known intellectual capacity have been examined, the complexity, due partly to the greater development of secondary and tertiary sulci, partly to the more curved course taken by the principal sulci, has been decidedly, in some instances extraordinarily, marked. Indeed, in some cases a relationship seems to have been apparent between a particular type of mental development and a special part of the brain; thus it was found that the brain of the great French orator, Gambetta, showed an especial degree of complexity of the third left frontal convolution. In skilled artisans it might be expected that the part of the brain which is connected with the voluntary movements of the hands and fingers might be found to be especially developed, and in one or two individual cases this has been noticed, but the material for a general statement regarding such relationship is insufficient. Benedikt, from the examination of the brains of a large number of individuals belonging to the criminal class, was of opinion that there exists amongst these an undue tendency to the formation of four antero-posterior convolutions in the frontal lobe, or in other words, an undue tendency to the appearance of the *paramesial* and *middle frontal sulci*. Although apparently supported by a few observations by other anatomists, this supposition has not borne the test of more extended observation; and, indeed, the so-called "criminal" type was actually less frequent in the brains of convicts examined by Giacomini than in those of ordinary persons.



## ON THE CAUSATION OF THE GYRI AND SULCI OF THE BRAIN.

Various explanations have been offered to account for the convoluted form of the cortex. These are based partly on mechanical considerations, *e.g.*, the resistance offered by the larger blood-vessels and undue growth of the brain as compared with that of its enclosing skull-capsule, partly on physiological or physiologico-mechanical considerations, which suppose that there is a relative increase of functional activity of certain parts as compared with others, resulting in an increased growth of those parts, and hence their projection in the form of gyri. These theories, however, are quite insufficient to account for the convoluted formation, since it can be shown (1) that the blood-vessels for the most part do not correspond with the fissures, nor do they lie in the depth of the fissures, when they happen to coincide with them; (2) that the brain does not fill the skull at the time the permanent fissures make their appearance; (3) that in the animal series there is no direct relationship between intellectual development and cerebral convolution. Further, it may be stated that no theory which will not also account for the fissures and laminae of the cerebellum as well as the convolutions of the cerebrum can be regarded as satisfactory.

It has, however, lately been pointed out by Jelgersma that a simple mathematical explanation exists for the existence of a convoluted surface. The one feature which mammals with smooth brains have in common is smallness of body; whereas those mammals which possess convoluted brains are invariably found to be of relatively large size (Dareste). In other words, small mammals have smooth brains, however high they may be on the animal ladder, and in spite of their possessing a high degree of intelligence (*e.g.*, certain monkeys), whilst large mammals have convoluted brains, although their intellectual development may be relatively low (*e.g.*, cetaceans). "The grey cortex of the brain, which in members of the same species maintains a tolerably constant thickness, increases by surface extension. Further, with every advance in the growth of the grey matter, there must be a proportionate increase of the subjacent white matter. The geometrical law involved is simply this—that in the growth of a body the surface increases with the second, but the interior with the third power of the radius. From this it is evident, seeing that the proportion of internal white matter and external grey matter is in all cases a uniform one, that in the evolution of a large animal out of a small animal a disproportion between the grey capsule and the white core of the cerebrum must result. This is compensated for by the extended cortex placing itself in folds or puckers. Jelgersma further points out that the extent of the cerebral surface depends upon two factors, namely, (1) the absolute quantity of the grey matter, and (2) the thickness with which this is spread over the surface. The absolute quantity of grey matter present is determined by the bulk, or by the psychical endowments of the animal, or by both of these factors together. On the other hand, although the thickness of the grey cortex is very much the same in the same species, it differs considerably in different animal groups; and it follows from the theory which he has advanced that the more sparsely the grey substance is spread over the surface of the white matter, the richer will be the convolution type. In the cetacean cerebrum the grey cortex is exceedingly thin, and it is due to this that the surface shows such an extreme condition of complexity."<sup>1</sup>

Cases in which there is a congenital absence of the corpus callosum are characterized by a peculiar type of convoluted surface, the fissures and convolutions showing a strong tendency to radiate from the Sylvian fossa. This is partly due, according to Cunningham, to a retention of certain of the primitive fissures which appear about the third or fourth month, are due to unfoldings of the whole thickness of the cerebral wall, and are mostly quite transitory; but they cannot all be thus accounted for. There is often in these cases an intricacy of pattern displayed which is comparable to that of the cetacean hemisphere, and may be very possibly produced in a similar manner.

The same law by which the formation of the cerebral convolutions is accounted for, likewise explains the development of the cerebellar folia, and of the wavy outline of the corpora dentata of the cerebellum and olives.

Jelgersma's theory is not complete in so far that it does not explain why the convolutions should tend to assume certain patterns in certain groups. It is not improbable that these differences may be determined by variations in the relative functional importance of different parts, producing a corresponding variation in the extent of grey matter which has to be provided for, and relative increase of this can only be obtained by local puckering (Cunningham). There is no doubt, however, that the formation of the various cerebral patterns, fairly constant for the same species, is scarcely susceptible of any very simple explanation, and that for the present we must rest satisfied with the statement of the fact.

<sup>1</sup> D. J. Cunningham, Address delivered at the opening of the section of Anatomy and Physiology at the annual meeting of the British Medical Association, 1890.



## INTIMATE STRUCTURE OF THE CEREBRAL HEMISPHERES.

## STRUCTURE OF THE WHITE MATTER.

The cerebral hemispheres, like the rest of the encephalon, are composed of white and grey substance, the white pervading nearly the whole of the middle of each hemisphere, where it forms what is known as the *medullary centre*, and extending into the convolutions; the grey forming a covering of some thickness over the whole surface of the convolutions (*cortex*), and occurring also at the base of the hemisphere in the form of the so-called basal ganglion (*corpus striatum*).

The white matter consists of medullated fibres, varying in size in different parts, but in general smaller than those of the cord and bulb. They are arranged in flattened bundles separated by neuroglia; the bundles have a somewhat rod-like appearance in transverse section.

The fibres of the medullary centre, though forming many different groups, may be referred to three principal systems, according to the general course which they take, viz.:—1. *Projection-fibres*, which pass from the isthmus encephali to the hemispheres, or *vice versa*. These fibres increase in number in passing the optic thalami and corpora striata, beyond which they spread in all directions into the hemispheres. 2. *Transverse or commissural fibres*, which connect the two hemispheres together. 3. *Association-fibres* (Meynert), which, keeping on the same side of the middle line, connect near or distant parts of the same hemisphere.

1. The **projection fibres** in each hemisphere are continuous in part with the fibres of the crusta, in part with those of the tegmentum, the latter probably indirectly through the corpus striatum and optic thalamus. They are in great measure, if not wholly, direct prolongations of the axis-cylinder processes of cells of the cortex (see diagram, fig. 20, p. 23).

*a. The fibres which are continuous with those of the crusta* pass in the internal capsule, between the optic thalamus and nucleus caudatus mesially, and the nucleus lenticularis laterally, probably giving off collateral fibres to those ganglia. Beyond the internal capsule the fibres diverge into the general white matter of the hemispheres, forming part of the system of radiating fibres known from its fan-like arrangement as the *corona radiata* (Reil) or *fibrous cone* (Mayo), the latter term being derived from the way in which the assemblage of radiating fibres is curved round in the form of an incomplete hollow cone as it emerges from below the nucleus caudatus, which follows the curve of the lateral ventricle.

Although it is probable that most of the fibres of the crusta pass directly into the medullary centre and through this to the grey cortex, without entering the basal ganglia of the hemispheres, this has only been definitely ascertained for one or two of the tracts of fibres which run in the crusta. The best known of these is the *pyramidal tract*, which is traceable through the inner capsule (opposite the middle of the lenticular nucleus) and corona radiata to the grey cortex of the ascending frontal and ascending parietal convolutions and to the posterior parts of the first and second frontal gyri. This is of interest in connection with the fact that physiological experiment indicates the grey matter of these particular convolutions as especially concerned in governing the action of the chief groups of muscles of the body (kinæsthetic or psycho-motor centres).

Another group of projection-fibres is the so-called *direct sensory tract*, which passes from the external or lateral part of the crusta through the posterior part of the internal capsule into the white matter of the occipital and temporal lobes of the hemisphere (centres for special senses).

The projection-fibres from the prefrontal region pass downwards in the anterior part of the internal capsule.

A few of the fibres of the crusta (those nearest the inner or mesial side) do not pass into the inner capsule and corona radiata, but are collected into the bundle known as *ansa lenticularis* and pass outwards underneath the thalamus into the nucleus lenticularis (see p. 112).

*b. The fibres which pass to the cerebrum in the tegmentum*, are originally constituted by the longitudinal bundles of the formatio reticularis of the medulla oblongata. They are reinforced as they pass upwards by sets of fibres derived from the superior peduncle of the cerebellum, and perhaps the middle peduncle; from the fillet; from the deeper parts of the corpora quadrigemina, and from the nerve- and other nuclei in the parts which they traverse. They become lost for the most part in the subthalamic tegmental region and in the thalamus, but on the other hand, from the outer side of the thalamus fibres stream outwards (see p. 111), and joining the general system of the corona radiata, diverge to nearly every part of the hemisphere. Other fibres, apparently continuous with this same system, pass from the posterior part of the thalamus into the optic tract.

From the lower part of the thalamus anteriorly fibres emerge forming the bundle known as the inferior peduncle of the thalamus, and curving round below the nucleus lenticularis, pass into the white substance of the external capsule.

2. The **transverse** or **commissural fibres** which connect the hemispheres together include—*a. The transverse fibres of the corpus callosum.* *b. The fibres of the anterior commissure.*

The fibres of the corpus callosum are derived from the cells of the grey cortex, being either the direct prolongations of their axis-cylinder processes or collaterals passing off from the projection fibres before mentioned (fig. 20, *call.*). When, therefore, a portion of cortex is removed or destroyed, certain fibres in the corpus callosum undergo degeneration. By this means it may be determined that the anterior portions of the callosum contain chiefly fibres derived from the frontal lobes, the posterior chiefly fibres from the occipital lobes, and the middle portion from the intermediate parts of the mantle. The fibres from a limited part of the cortex are not, however, entirely limited to one part of the callosum, but show a tendency to scatter, so that not only similar but also dissimilar parts of the two hemispheres are connected through this commissure (Sherrington). A certain number of projection fibres also pass across the callosum to the other hemisphere, and then turn downwards in the internal capsule (Hamilton). Hence, after removal of certain parts of the cortex on one side of the brain, some degenerated fibres are found in the pyramidal tract which is mainly connected with the other side (see p. 31).

The **anterior commissure** (fig. 113) is composed of a bundle of transverse fibres, which chiefly connects the temporal lobes of the two hemispheres. The bundle is most compact in the middle line, which it crosses at the front of the third ventricle just in front of the pillars of the fornix: in a median section of the brain it presents an oval section of 5 mm. long diameter, with its long axis from above down. From this point it passes laterally as a twisted bundle of fibres curving backwards and somewhat downwards through the ventral part of the globus pallidus, and below the putamen of the lenticular nucleus. Its fibres then diverge in a fan-like manner into the temporal lobe; whether any pass by means of the external capsule to the insula has not been satisfactorily determined.

The fibres of the anterior commissure which pass into the temporal lobe form by far the greater part of the commissure in man, and constitute what has been termed by Ganser the *pars temporalis*. Besides these fibres, there are others which are derived from the lobus olfactorius (see p. 160), and which appear to connect the olfactory tract of one side with the hippocampal gyrus of the opposite side. These form the *pars olfactoria* of Ganser: this part is very slightly developed in man.

The anterior commissure forms the segment of a circle, with the convexity

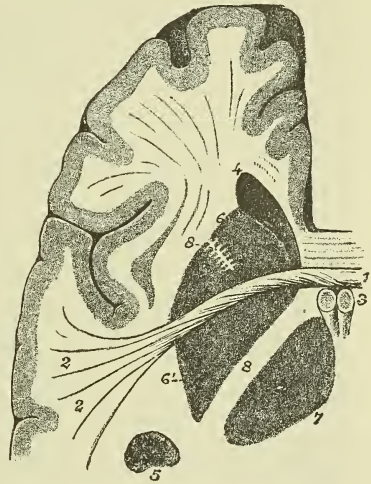
directed forwards. It is the principal cerebral commissure in all vertebrates below mammals : the corpus callosum first making its appearance in the lowest mammals and becoming developed proportionately with the increase of the mantle.

The rope-like twist of the anterior commissure is associated by Hill with a rotation of the cerebrum, which has occurred in the course of its development (Appendix A to English Translation of Obersteiner's "Anatomy of the Central Nervous Organs").

3. The **association-fibres** which connect different parts of the same hemisphere are either short or long. The *short association-fibres* (*fibræ propriae*, Meynert ;

Fig. 113.—HORIZONTAL SECTION OF THE LEFT HEMISPHERE, SHOWING THE COURSE OF THE ANTERIOR COMMISSURE. (Testut).

1, 2, anterior commissure ; 3, pillars of fornix ; 4, lateral ventricle, anterior horn ; 5, lateral ventricle, descending horn ; 6, 6', corpus striatum, caudate and lenticular nuclei ; 7, thalamus ; 8, internal capsule ; 8', anterior segment of internal capsule.



*lamina arcuata gyrorum*, Arnold) (fig. 114, s.), serve to connect adjacent convolutions, passing round below the grey matter at the bottom of the fissures. The *long association-fibres* are mostly collected into definite bundles, which can be traced for a considerable distance between the bundles of commissural and projection-fibres, or which run free for a certain part of their course. The principal bundles or tracts of long association-fibres are the following :—

(a) *Superior association-bundle* (superior longitudinal fasciculus, fasciculus arcuatus, Burdach).—This consists of sagittal fibres, which run below the grey matter of the convex surface of the hemisphere, between the frontal and occipital lobes, and between the frontal lobe and external part of the temporal lobe (fig. 114, f.l.s.).

(b) *Inferior association-bundle* (temporo-occipital bundle, inferior longitudinal fasciculus).—This is a bundle of fibres which lies close to the outer wall of the posterior and inferior cornua of the lateral ventricle and connects the temporal and occipital lobes (f.l.i.).

(c) *Anterior association-bundle* (uncinate fasciculus).—Under this name is described a white bundle, seen on the lower aspect of the hemisphere, passing across the bottom of the Sylvian fissure at the limen insulæ, and connecting the frontal with the temporal lobe (f.u.). The fibres of this bundle expand at each extremity, and the more superficial of them are curved or hooked sharply between the contiguous parts of the two lobes,—from which circumstance it has derived the name uncinata. Its fibres appear especially to connect the third frontal gyrus with the temporal lobe and with the anterior part of the limbic lobe.

(d) *Cingulum (ci.)*.—This forms the principal association-bundle of the gyrus fornicatus, its fibres coursing immediately above the transverse fibres of the corpus callosum, and passing from the anterior perforated space in front, curve round the splenium of the callosum behind, and pass in the gyrus hippocampi as far as its anterior extremity. Some of the fibres diverge, as they pass backwards, into the white matter of the hemisphere, and probably reach various parts of the cortex. The constitution of this bundle and its connections have been already dealt with (see p. 158).

(e) The *perpendicular fasciculus* (Wernicke), which runs vertically immediately



in front of the occipital lobe and connects the inferior parietal lobule with the fusiform lobule (*f.p.*).

(*f*) *The fornix*.—This (*fo.*), by means of its continuation, the fimbria (*fi.*), connects the hippocampal region of the limbic lobe with the corpus albicans, which again is connected through the bundle of Vicq d'Azyr (*v.d'A.*) with the thalamus

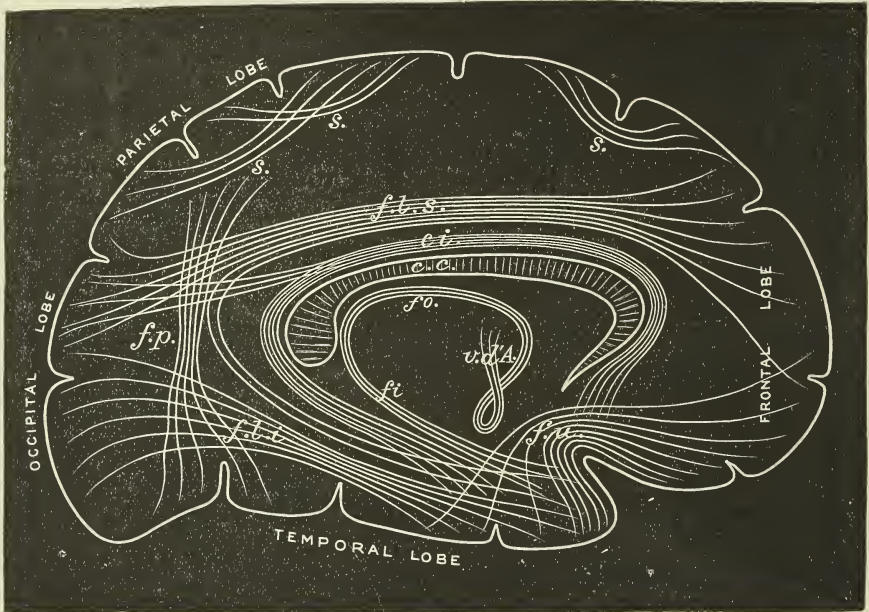


Fig. 114.—DIAGRAM OF THE ASSOCIATION-FIBRES OF THE CEREBRAL HEMISPHERE.  
(E. A. S., after Meynert.)

*s.*, short association-fibres, connecting adjacent gyri; *f.l.s.*, fasciculus longitudinalis superior; *ci.*, cingulum; *f.p.*, fasciculus perpendicularis; *f.l.o.*, fasciculus longitudinalis occipitalis; *fo.*, fornix; *fi.*, fimbria; *v.d'A.*, bundle of Vicq d'Azyr.

opticus. The course and relations of the fornix have already been described (pp. 129, 158).

The arrangement of the fibres in the white matter has been studied by H. Sachs, who finds that the fibres in the occipital lobe (the only part as yet fully investigated by him) are arranged in four layers or series, from within out, as follows:—1. Those which are prolonged from the corpus callosum (forceps major), which occupy the central parts nearest the ventricle. 2. Next to these a layer composed of projection-fibres, passing to the internal capsule. They are finer than the callosal fibres. 3. Another layer of larger fibres which surrounds the projection-layer, and is composed of long association-fibres. 4. A layer of short association-fibres, nearest the cortex. It will, of course, be understood that the peripheral layers are constantly pierced by the fibres which are passing from the cortex to join the more centrally-situated layers.

#### STRUCTURE OF THE GREY MATTER.

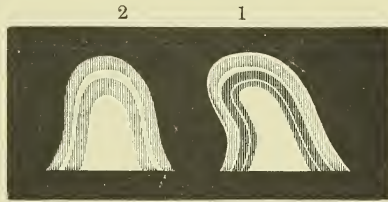
The grey matter on the convoluted surface of the cerebrum forms a continuous layer indistinctly divided into two or three strata by interposed thin layers of paler substance.

In examining a section macroscopically from without inwards (fig. 115, 1), we meet with—1. A thin coating of white matter situated on the surface, which on a section appears as a faint white line, bounding the grey surface externally. This superficial white layer is not equally thick over all parts of the cortical substance, but becomes thicker as it approaches the borders of the convoluted surface; it is

accordingly less conspicuous on the lateral convex aspect of the hemispheres, and more so on the convolutions situated in the longitudinal fissure which approach the white surface of the corpus callosum, and on those of the under surface of the brain. It is especially well marked on the hippocampal gyrus, and it has been there described under the name of the *reticulated white substance*. 2. Immediately beneath the white layer just described, is found a layer of grey or reddish grey matter, the colour of which, as indeed of the grey substance generally, is deeper or lighter according as its very numerous vessels contain much or little blood. 3. A layer, appearing in section as a thin whitish line (line of Vicq d'Azyr, outer line of

Fig. 115.—SECTIONS OF CEREBRAL CONVOLUTIONS  
(after Baillarger).

The parts are nearly of the natural size. 1, shows the six layers ordinarily seen in the cerebral cortex when carefully examined with the naked eye; 2, the appearance of a section of a convolution from the neighbourhood of the calcarine fissure.



Baillarger). 4. A second grey stratum. 5. A second thin whitish layer (inner line of Baillarger). 6. A yellowish grey layer which lies next to the central white matter of the convolution. In some convolutions, especially those bordering on the calcarine fissure, the line of Vicq d'Azyr is very distinct, but the inner line of Baillarger is not visible (fig. 115, 2).

Medullated fibres radiate from the white centre of each convolution in all directions into the grey cortex, having a course for the most part perpendicular to the free surface. In passing through the grey substance they are arranged in bundles about  $\frac{1}{1500}$ th of an inch in diameter, and thus separate the nerve-cells into elongated groups, and give the section a columnar appearance (fig. 116). The direction of the fibres varies according to the part of the convolution in which they occur, whether near the summit or the base, and the radiating direction is somewhat lost in the sulci between the convolutions, where the arched fibres which connect the adjacent convolutions seem to obscure the radiating bundles.

**Layers of cells in the cortex.**—The form and arrangement of the cells vary at different depths of a convolution, and in this way several layers are distinguished, having more or less definite characters, but not sharply marked off from one another. Their relation to the stratification distinguishable by the naked eye is not everywhere clearly made out. The most common type is that which is seen in the convolutions of the parietal lobe. In this most observers agree with Meynert in recognising five layers as follows (fig. 116):—

1. *Superficial or molecular layer.*—This, the most external layer, is narrow, and forms about  $\frac{1}{10}$ th of the whole thickness of the grey cortex. It is composed chiefly of neuroglia, but contains some nerve-cells. A few medullated nerve-fibres occur in it, forming a thin superficial white stratum almost immediately underneath the pia mater.

As already intimated these fibres are much more developed in the hippocampal region than in other parts of the cortex. The layer also contains non-medullated fibres, which ramify in it, and most of which are derived from the peripherally-directed processes of the pyramidal cells of the deeper layer.

The neuroglia-cells of the superficial layer are mostly elongated and set perpendicularly to the surface, where a principal process of each cell usually terminates in a foot or enlargement (fig. 117).

The nerve-cells of the layer are small. They vary in shape, many being fusiform and set parallel with the surface. Both their dendrites and their axis-cylinder processes, which give off numerous collateral branches, are for the most part confined to this layer. Many of them have two or three axis-cylinder processes, and these

frequently come off from the dendrites, instead of, as is usual, from the body of the cell (Cajal).

2. *Layer of small pyramids.*—This layer, of nearly the same thickness as the




Fig. 116.—SECTION OF CEREBRAL CONVOLUTION (Meynert).

1, Superficial layer, with scattered cells; 2, layer of small pyramidal cells; 3, broader layer of pyramidal cells, separated into columns by the radiating nerve-fibres; 4, narrow layer of small irregular cells; 5, layer of fusiform and irregular cells in medullary centre.

last, is characterized by containing a large number of small nerve-cells, mostly pyramidal, with dendrites extending mainly into the superficial layer, and an axis-cylinder process, which starts from the base of the cell and after giving off a few collaterals, passes downwards to the white centre, possibly to the corpus striatum as a projection-fibre. Some of the axis-cylinder processes do not, however, reach the white matter, but end in arborisations between the cells of the next layer.

3. *Layer of large pyramids.*—The third layer is of paler tint and much greater thickness. It contains pyramidal branching cells, some large others smaller, arranged with the pointed extremities towards the surface of the convolution, and separated into groups by the bundles of radiating nerve-fibres. The innermost portion of the layer, in which the cells are larger and the separation into groups more distinct, is sometimes described as a separate layer. The axis-cylinder processes of these cells give off 7 or 8 collaterals, which become medullated and end by ramifying in the adjacent grey substance. The axis-cylinder is then continued on into the white matter as a medullated fibre.

4. *Layer of polymorphous cells.*—The fourth layer is narrower, and contains many small, irregularly-shaped corpuscles, with numerous dendrites and a single axis-cylinder process. The axis-cylinder processes of most of these cells tend towards the white centre, but some pass peripherally, and reach the molecular layer where they become continuous with some of the nerve-fibres of that layer.

5. *Layer of fusiform cells.*—The fifth layer, of greater width than the last, and blending more or less with it, is com-



posed of fusiform and irregular cells. The fusiform corpuscles have a definite arrangement, being placed for the most part vertically at the summit of a gyrus; but parallel to the surface in the sulci, where they correspond in direction to the arcuate fibres passing from one convolution to another; they are said to be connected with these fibres.

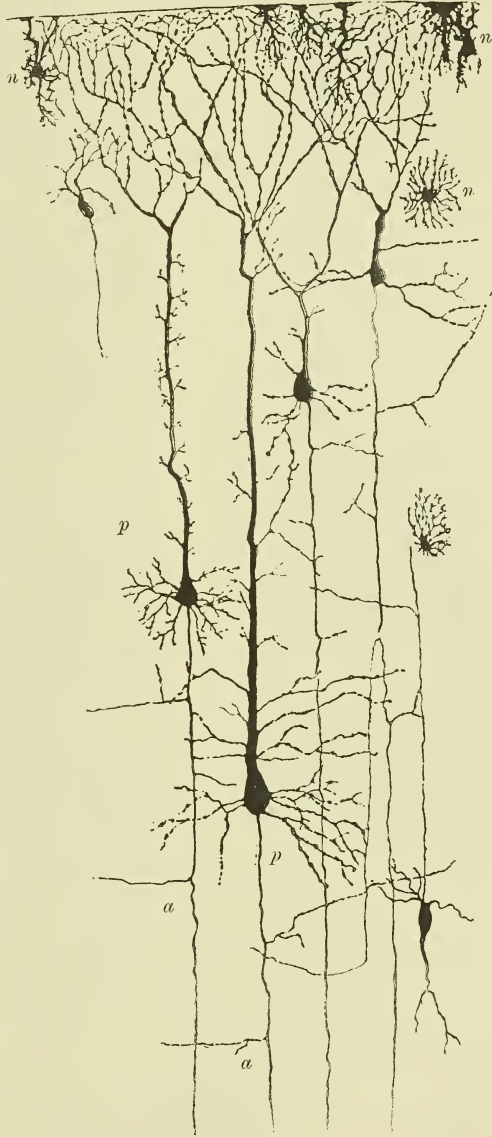Fig. 117.—CELLS FROM THE CEREBRAL CORTEX, SHOWN BY GOLGI'S METHOD. (G. Retzius.)

*n, n*, neuroglia-cells; *p, p*, pyramids; *a, a*, axis-cylinder processes of pyramids giving off collaterals.

Beneath the last layer is the medullary centre, with which it gradually blends. The fibres of the white substance, as they radiate into the grey matter, become finer. They are mostly continuous with the axis-cylinder processes of the pyramidal cells, the collaterals of those forming two plexuses of medullated fibres which lie, the one at the base of the 3rd layer, the other between this and the 2nd layer. These plexuses (inner and outer white plexuses of W. Krause) are probably the cause of the lines of Baillarger seen with the naked eye in a section of the grey cortex of a fresh brain.

In the Sylvian fissure the fusiform cells are more abundant than elsewhere, and from their number in the claustrum the fifth layer has been termed by Meynert the "claustral formation." They are also very abundant in the amygdaloid nucleus, which is indeed chiefly formed by a thickening of the deepest layer of the cerebral cortex. The cornu ammonis on the other hand is formed almost exclusively of the large pyramidal cells, and the layer in which these occur (third layer) has, in like manner, been termed the "formation of the cornu ammonis."

The axis-cylinder processes of the pyramids when they reach the medullary centre, pass either as association-fibres to other parts of the cortex of the same hemisphere, or as commissural fibres to the corpus callosum, and through this to the opposite hemisphere, or as projection-fibres to the corpus striatum and optic thalamus, or by way of the internal capsule to the midbrain, bulb and spinal cord. The junction with fibres of the association-bundles may be T-shaped, in other words they may bifurcate and pass in opposite directions underneath the cortex. Eventually they turn into the cortex again and end by free arborisation amongst its cells. More-



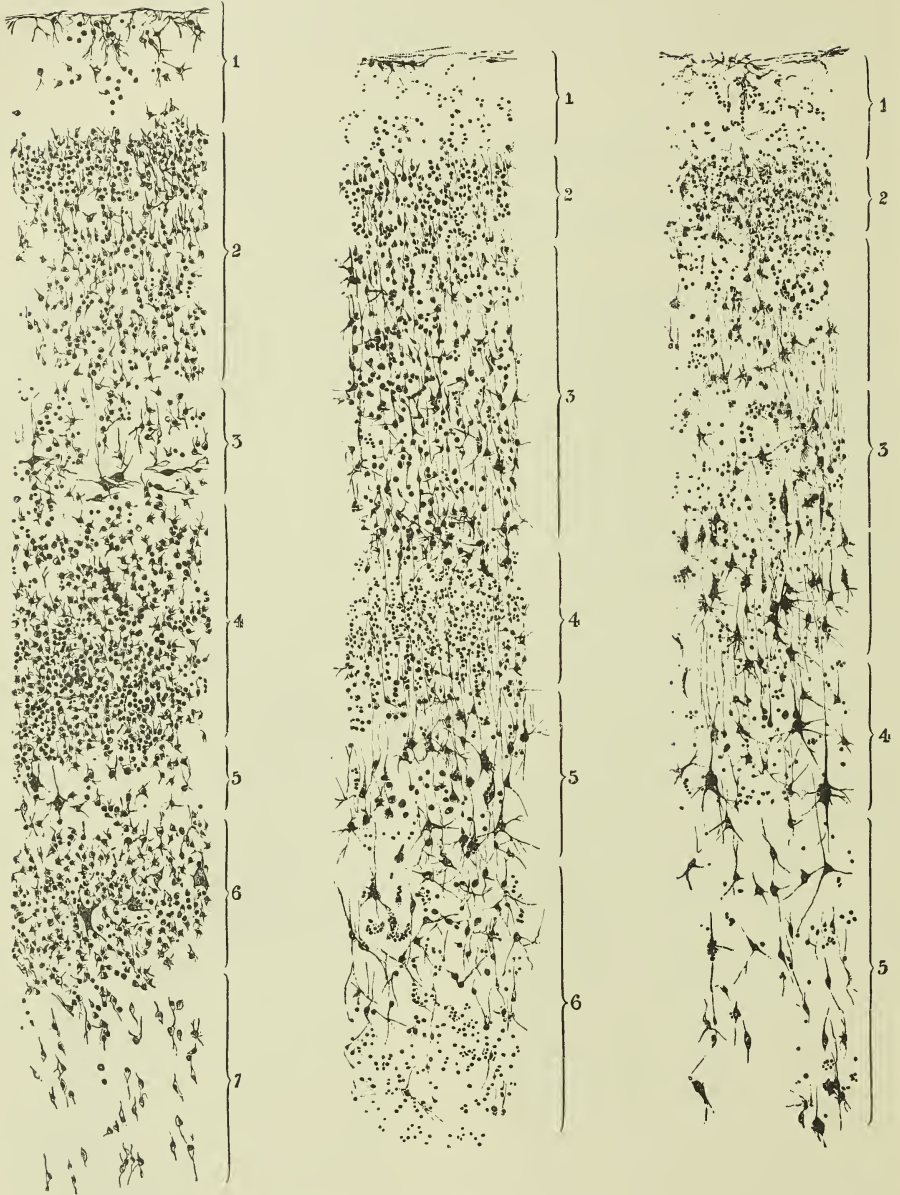


Fig. 118.—SECTION OF CORTEX OF OCCIPITAL LOBE.

1, superficial layer ; 2, layer of small pyramids ; 3 to 5, layer of large pyramids, with numerous small "granule" cells at 4 ; 6, polymorphous cells ; 7, spindle-cells.

Fig. 119.—SECTION OF CORTEX OF TEMPORAL LOBE.

The numbers denote the same layers as in fig. 118.

Fig. 120.—SECTION OF CORTEX OF FRONTAL LOBE.

1, 2, as in fig. 118 ; 3, 4, large pyramids ; 5, polymorphous and spindle-cells.

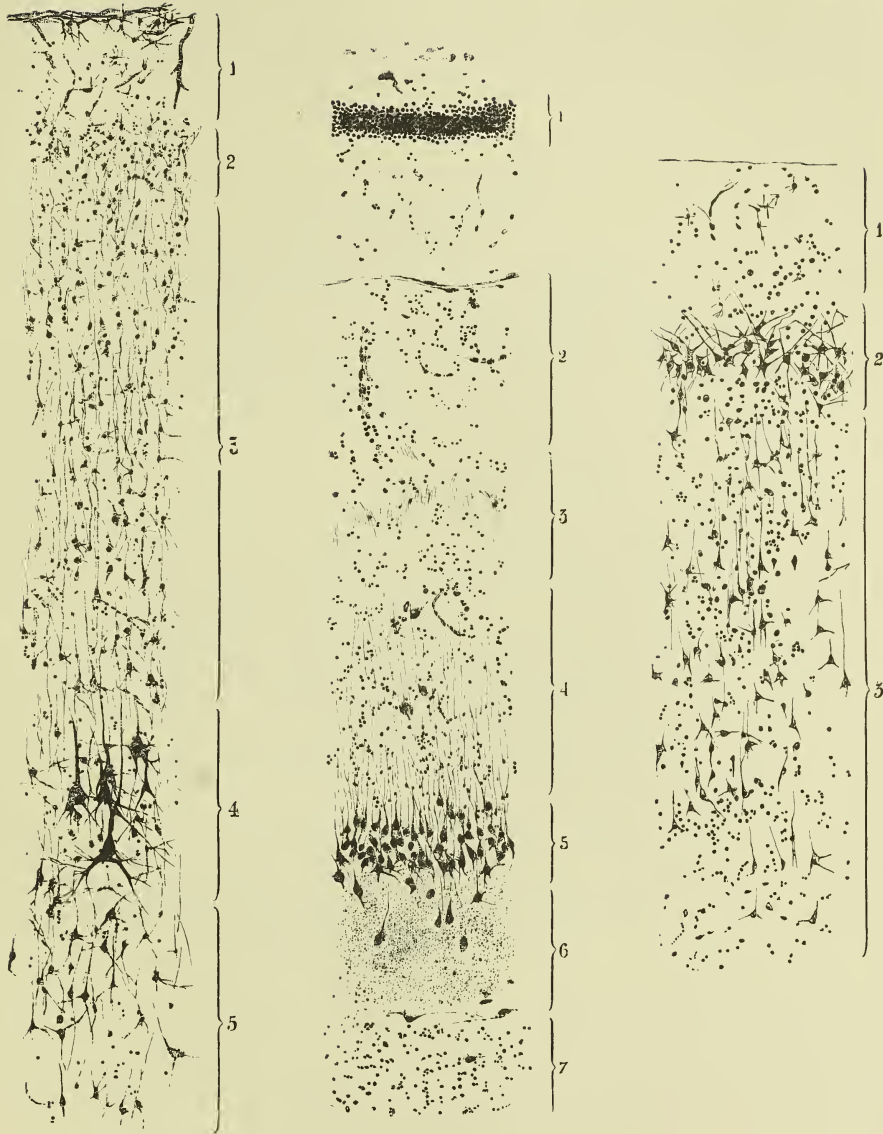


Fig. 121.—SECTION OF CORTEX OF MOTOR AREA.

The numbers denote the same layers as in fig. 120.

Fig. 122.—SECTION OF HIPPOCAMPUS MAJOR.

1, granular stratum of fascia dentata ; 2, superficial layer of cortex ; 3, stratum lacinosum ; 4, stratum radiatum ; 5, large pyramids ; 6, neuroglia-matrix (stratum moleculare) ; 7, alveus.

Fig. 123.—SECTION OF CORTEX OF GYRUS HIPPOCAMPI.

1, superficial layer ; 2, short pyramids ; 3, long pyramids.



over, in their longitudinal course they give off collaterals here and there to intermediate parts of the cortex. The commissural fibres, after passing through the corpus callosum, have a longer or shorter course in the white matter of the opposite hemisphere, and end by terminal arborisations in its cortex. In their course they also give collaterals to other parts of the cortex. Some of the commissural fibres are themselves collateral branches of the projection-fibres (fig. 20, p. 23).

The projection-fibres pass for the most part into the internal capsule. Both before reaching this and as they pass through it they give off collaterals, some of which enter the basal ganglia and ramify amongst the cells, whilst others pass towards the corpus callosum. The main fibres ultimately end by arborisation in the grey matter of the lower nerve-centres: those of the pyramidal tract amongst the cells from which the motor nerve-fibres originate. The projection fibres are mainly derived from the middle-sized and larger pyramids, and from some of the polymorphous cells of the fourth layer.<sup>1</sup>

**Differences of structure in different parts.**—Considerable variety occurs in different parts of the cerebral cortex in the size and regularity of shape of the nerve-cells and in the relative thickness of the several layers. It is especially worthy of notice that in the “psycho-motor” region, and particularly in the upper part of the ascending frontal convolution, some of the deeper pyramidal cells are very large (fig. 121, 4), and are arranged in more or less defined groups or nests (Betz, Bevan Lewis). On the other hand, in the neighbourhood of the calcarine fissure, large cells are very scanty, their places being for the most part taken by smaller ones (fig. 118). Again, in many parts a six-laminated cortex is produced by the intercalation of a layer of small angular cells in the middle of the layer of large pyramids (figs. 118, 119).

These differences in the size and arrangement of the cells in different parts of the cortex are well illustrated in the accompanying figures (118 to 123) by Bevan Lewis of sections from various regions.

The most remarkable differences of structure occur at the margin of the hemisphere in the region of the hippocampus, and in the olfactory lobe. These will now be specially considered.

**Structure of the hippocampus major or cornu ammonis.**—The hippocampus it will be remembered corresponds to the hippocampal fissure externally; this fissure separating the uncinatate or hippocampal convolution below from the fascia dentata above. The uncinatate convolution (fig. 123) has the ordinary structure of the cerebral gyri, being composed of a grey cortex and a thick white centre. The cortex generally is, however, thin, but the superficial layer is relatively thick, and contains many medullated fibres. The cells of the second layer are relatively large as compared with other parts of the cortex. The cortex is prolonged around the hippocampal fissure, forming the main part of the hippocampus (figs. 110, 124); the white centre is also prolonged over the projection of the hippocampus into the ventricle, but becomes very thin in this situation where it is known as the *alveus*. It is covered by the epithelium and ependyma of the ventricle.

Above the hippocampal fissure the grey matter of the hippocampus swells out into the notched lamina known as the *fascia dentata* (dentate convolution, fig. 124, *F d*). The white matter of the alveus is in like manner prolonged over this, but not quite as far as its free border; it becomes thickened and is continuous with the white band known as the *fmbrina* (*Fi*), which thus represents a free edge of the medullary centre of the hemisphere.

The projection of the hippocampus (into the ventricle) is thus produced by the

<sup>1</sup> Most of the above details relating to the destination of the axis-cylinder processes are derived from the observations of Ramón y Cajal, made upon specimens prepared by Golgi's method.

invagination of the cortex as the hippocampal fissure. According to Golgi and Sala there is a second invagination into the fascia dentata : this must however be looked upon as quite incomplete.

The greater part of the grey matter of the hippocampus is occupied by several rows of moderately large pyramidal cells (fig. 122, 5 ; fig. 124, 3) with long apical processes, which lie embedded in a neuroglia-matrix, and confer upon this, especially

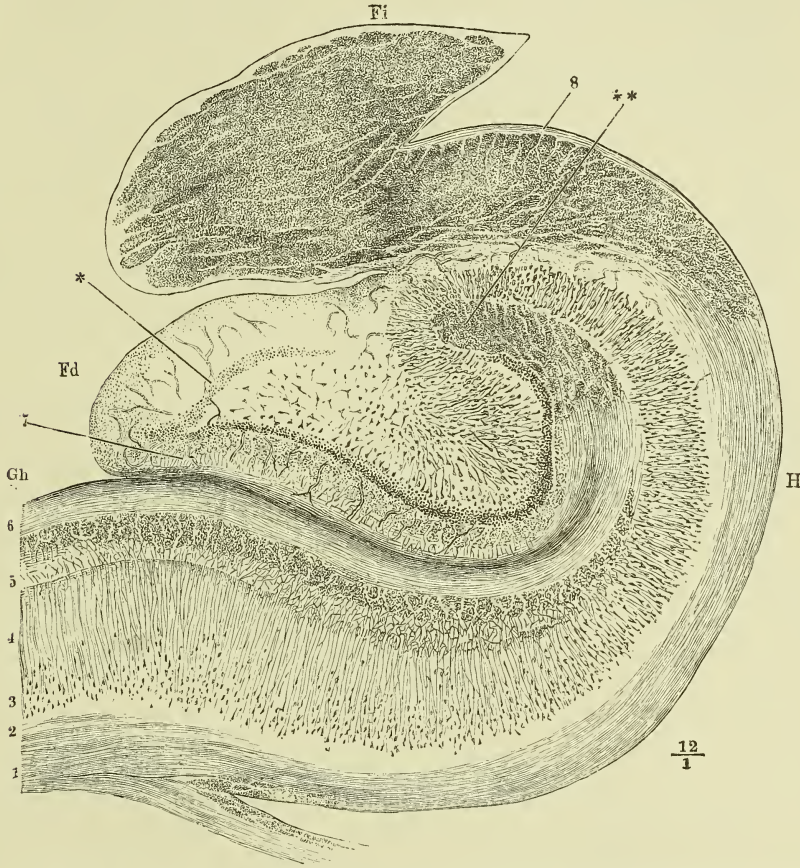


Fig. 124.—SECTION ACROSS THE HIPPOCAMPUS MAJOR, DENTATE FISSURE, DENTATE FASCIA AND FIMBRIA (after Henle).

*Gh*, part of the gyrus hippocampi or uncinata convolution ; *Fd*, fascia dentata or dentate convolution ; between them is the dentate fissure ; *Fi*, fimbria, composed of longitudinal fibres here cut across ; 1, 2, medullary centre of the hippocampal gyrus prolonged around the hippocampus, *H*, as the so-called alveus, into the fimbria ; 3, layer of large pyramidal cells ; 4, stratum radiatum ; 5, stratum lacinosum ; 6, superficial medullary lamina, involuted around the dentate fissure ; \*\*, termination of this lamina, the fibres here running longitudinally ; 7, superficial neuroglia of the fascia dentata ; \*, stratum granulosum.

in its outer part, a striated aspect ; hence the name of *stratum radiatum* sometimes used to distinguish this part of the layer (4). By their bases the cells rest upon the white layer or alveus, into which their axis-cylinder processes pass, but there is in some parts a layer of grey matter intervening (fig. 122, 6).

Superficial to the *stratum radiatum*, the processes of the pyramidal cells form an arborisation, the branches of which are closely interwoven (*stratum lacinosum*, 5). Superficial to this are a large number of small cells which give a granular appear-



ance to the layer they occupy (*stratum granulosum*). Superficial to this again is a well-marked layer of medullated fibres continuous with the reticulated white substance of the uncinata convolution (see p. 156). It is known as the *involved medullary lamina* (fig. 124, 6), and represents an increased development of the thin layer of white fibres which is ordinarily found in the molecular or superficial layer of the grey matter.

In the fascia dentata the large pyramidal cells are placed in the centre and are irregularly arranged: they are surrounded by an incomplete ring of closely packed small pyramidal cells (*stratum granulosum*, fig. 124, \*), outside which is a very broad superficial layer of neuroglia with a few scattered cells.

**Minute structure of the olfactory lobe.**—The peculiar structure of this part of the brain can best be understood by a reference to its mode of development. It is formed as a hollow outgrowth from the vesicle of the cerebral hemisphere (after-

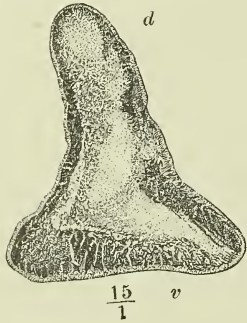

Fig. 125.—SECTION ACROSS THE MIDDLE OF THE OLFACTORY TRACT (Henle).

*c*, ventral surface; *d*, dorsal ridge. From without in are seen successively: (1) a thin superficial layer of neuroglia; (2) a (darkly shaded) layer of transversely-cut medullary fibres, of very unequal thickness in different parts; (3) the central grey matter projecting up into the dorsal ridge and here and there extending to the surface and partially interrupting the medullary layer.

wards the lateral ventricle), and in most of the lower animals (in which it is much more developed than in man), it exhibits even in the adult condition a central cavity (lined with ciliated epithelium), and in some, as already stated, this retains throughout life its connection with the lateral ventricle. The walls of the hollow outgrowth become thickened and differentiated into a central layer of neuroglia next to the cavity, a well-marked intermediate layer of white substance outside this, and a peripheral layer of grey matter surrounding the whole. In man and apes the same changes occur, but the cavity becomes completely obliterated and in its stead we find nothing but central neuroglia, which forms for the most part a tract flattened out laterally, and containing but few cells. The white or medullary substance around this appears in section in the form of a flattened ring consisting of longitudinal white fibres (fig. 125). In the olfactory tract the peripheral layer of grey matter is very thin and inconspicuous, so that the white substance almost everywhere shows through it, except along the dorsal ridge where there is an accumulation of the grey substance, extending into and partly interrupting the medullary ring (fig. 125, *d*). In the bulb on the other hand this dorsal accumulation of grey matter is not seen; but upon the ventral side of the flattened medullary ring (fig. 126, 1, 2, 3) in place of the thin scarcely visible layer of grey substance in the corresponding situation in the tract, a thick layer of grey matter is found and forms indeed the greater part of the thickness of the bulb, what was originally the central cavity being consequently now placed near the dorsal surface. This grey matter as seen in section exhibits the following parts (fig. 126, 4 to 8):—

(1.) A *granule layer* of considerable thickness (fig. 126, 4, 5, 6) lying next to the medullary ring, and characterised by the presence of numerous small cells, like those found in the deeper or granule layer of the grey cortex of the cerebellum. The layer is not entirely composed of these cells however, for there are present in addition a number of reticulating bundles of medullated fibres which separate the “granules” into groups, and other medullated fibres which pass vertically between the medullary ring and the next layer. There are also a number of large nerve-cells, having for the most part a conical shape (*mitral cells*, fig. 127, *m.c.*), the axis-cylinder processes

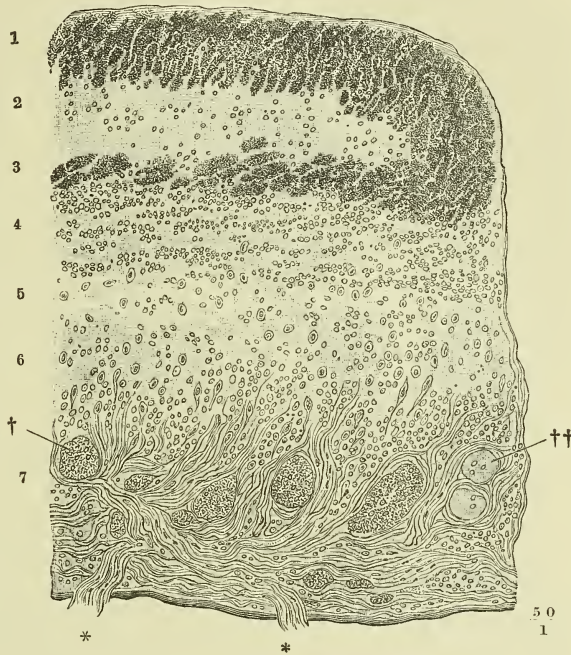


of which pass upwards through the granule layer, while most of their protoplasmic or dendritic processes enter the next stratum.

(2.) *The layer of olfactory glomeruli* (7). The remarkable bodies which

Fig. 126.—SECTION ACROSS A PART OF THE OLFACTORY BULB (Henle).

1, 3, layers of very fine transversely cut nerve-fibres, passing round into one another at the side, and forming the flattened medullary ring, enclosing the central neuroglia, 2; 4, 5, 6, granule-layer; 7, layer of olfactory glomeruli, †, ††; 8, layer of olfactory nerve-fibres, bundles of which are seen passing at \* \* to the olfactory mucous membrane.

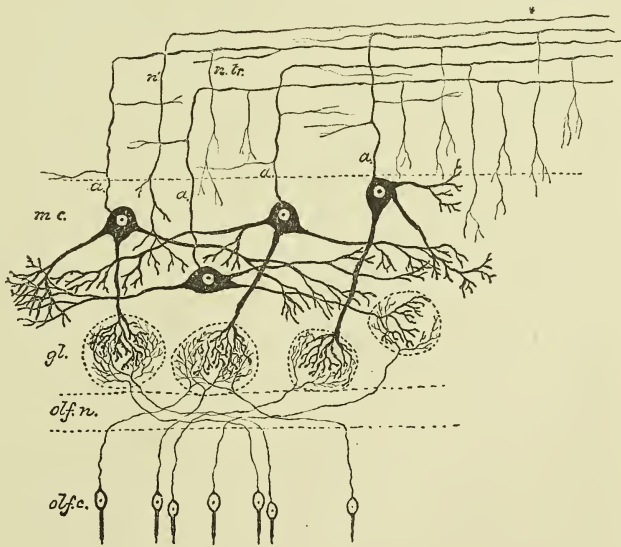


characterize this stratum were first described by Leydig in elasmobranchs and by Lockhart Clarke in mammals. They are rounded bodies which are formed of a dense interlacement of nerve-fibres derived on the one hand from the dendrites of the mitral cells, on the other from the olfactory fibres of the next layer. They also include a few small cells, which are probably neuroglial.

(3.) *The layer of olfactory nerve-fibres* (8). This, the deepest layer of the bulb,

Fig. 127.—DIAGRAM OF THE CONNECTIONS OF CELLS AND FIBRES IN THE OLFACTORY BULB. (E. A. S.)

*olf.c.*, cells of the olfactory mucous membrane; *olf.n.*, deepest layer of the bulb composed of the olfactory nerve-fibres, which are prolonged from the olfactory cells; *gl.*, olfactory glomeruli, containing arborisations of the olfactory nerve-fibres and of the dendrites of the mitral cells; *m.c.*, mitral cells; *a*, their axis-cylinder processes passing towards the nerve-fibre layer, *n.tr.*, of the bulb to become continuous with fibres of the olfactory tract: these axis-cylinder processes are seen to give off collaterals, some of which pass again into the deeper layers of the bulb; *n'*, a nerve-fibre from the olfactory tract ramifying in the grey matter of the bulb.



consists entirely of bundles of non-medullated nerve-fibres, which here form a dense plexus the fibres of which on the one hand pass through the perforations in the

cribriform plate of the ethmoid bone to the olfactory mucous membrane, and on the other hand into the glomeruli, where they ramify and form arborisations, which interlace with those of the dendrites of the mitral cells.

The relations of cells and fibres in the olfactory bulb have recently been reinvestigated by Golgi, Ramón y Cajal, v. Gehuchten, and others, by the aid of Golgi's silver nitrate method. The result of these investigations has been to show that the olfactory nerve-fibres take their origin in the olfactory cells of the Schneiderian membrane, which are therefore to be regarded as peripheral nerve-cells, and that they terminate in the arborisations already mentioned as occurring in the olfactory glomeruli. To these same glomeruli protoplasmic processes of the mitral cells also pass and end in arborisations which intimately interlace with those of the olfactory fibres. (Some of the protoplasmic processes of these cells do not, however, pass to the glomeruli, but end in free arborisations in the deeper parts of the granule layer.) On the other hand the axis-cylinder processes of the mitral cells pass upwards from the rounded apex of the cell, and passing between the "granules" reach the white fibres of the medullary ring. Turning sharply backwards nearly at a right angle they then become continuous with the fibres of the ring (see fig. 127), ultimately reaching the olfactory tract, along which they are conducted to the base of the brain. As they pass upwards and also in their horizontal course, they give off collateral fibres to adjacent parts of the bulb: these collaterals end after a shorter or longer course in free arborisations in the grey matter.

#### MEASUREMENTS OF THE BRAIN.

**Dimensions.**—The length of the cerebral hemispheres, measured from the frontal to the occipital pole, varies in the larger proportion of cases between 160 mm. and 170 mm. for the male brain; and between 150 mm. and 160 mm. for the female brain. The greatest transverse diameter of the whole brain for both sexes is about 140 mm. and the greatest vertical measurement of each hemisphere about 125 mm. (Huschke). The brains of dolichocephalic individuals are naturally longer than those of brachycephalic: in the latter there is a tendency to a breaking up of the longitudinal gyri by transverse fissures, thereby increasing the amount of surface and hence of grey cortex in proportion to the whole brain.

**Extent of grey cortex.**—The attempts hitherto made to measure or estimate the relative proportions of the different convoluted parts of the cerebrum to each other and to the degree of intelligence, either more directly or by the cranioscopic methods, have been attended with little success. Such researches as those of Rudolph Wagner give, however, some promise, when fully carried out, of affording more definite results. These researches had for their object to institute an accurate comparison between the brains of certain persons of known intelligence, cultivation, and mental power, and those of persons of an ordinary or lower grade. As examples of brains of men of superior intellect he selected those of Professor Gauss, a well-known mathematician of eminence (æ. 78), and Professor Fuchs, a clinical teacher (æ. 52); and as examples of brains of ordinary persons, those of a woman of 29 and a workman.

The careful measurement of all the convolutions and the intervening grooves in the four brains above mentioned was carried out by H. Wagner, by covering the cortex everywhere with gold-leaf, and determining the extent of surface by the amount employed. The result of these measurements is partly given in the accompanying table, the numbers indicating square millimeters of surface.

It will be seen that although there are undoubtedly differences in the brains examined, these are by no means so striking as might have been expected. Indeed it may be stated that the general result of these and similar observations has been

hitherto inconclusive, for although there have been observed several notable instances in which superiority of intellect has been found to be accompanied by increased size or complexity of the cerebral surface, in many other cases no such relation has been noticed.

*Comparative measurement of the extent of surface of the cerebral convolutions.*

	SURFACE OF EACH LOBE SEPARATELY.					FREE AND DEEP SURFACES OF CONVOLUTIONS.		Whole surface of Cerebrum.
	Frontal.	Parietal.	Occipital.	Temporal.	Central.	Free surface.	Deep surface, including surface of insula.	
1. Gauss .....	89,545	45,493	38,286	44,062	2,252	72,650	146,988	219,638
2. Fuchs .....	92,380	44,783	37,927	43,468	2,447	72,100	148,905	221,005
3. Woman ...	84,318	41,838	32,851	42,982	2,126	68,900	135,215	204,115
4. Workman..	72,890	40,142	32,490	39,880	2,270	62,750	124,922	187,672

It will be seen from the above that the total surface, exposed and sunken, is about 200,000 square mm., and that there is about twice as much sunken as exposed surface. With this estimate the determinations made by subsequent observers mostly agree. Baillarger, who dissected off and unfolded the cortex, and then measured its whole extent, obtained only an area of 170,000 sq. mm. as the mean of the brains thus treated. Paulier, by a modification of the method of Wagner, obtained a result similar to that of Baillarger for the whole surface, and, further, found the sunken surface to measure but little more than the exposed surface, and the extent of surface to bear no relation to the weight of the brain. Calori measured 41 brains (Italians), and obtained the following average results (in sq. mm.) for the total surface:—Male, brachycephalic, 243,773. Male, dolichocephalic, 230,212. Female, brachycephalic, 211,701. Female, dolichocephalic, 198,210.

Danilewsky attempted to determine the area of the whole cortex by a comparison of the weight of the brain, its specific gravity (1038), the specific gravity of the grey matter (1033), and white matter (1041), and the average thickness of the grey matter, which he estimated at 2.5 mm. He obtained in this way a result of about 33 per cent. as the weight of the grey cortex, giving for a brain weighing 1324 grm., a total surface of 169,200 sq. mm. De Regibus made similar calculations from estimation not of the specific gravity but of the amount of water in the whole brain and in its two component substances. His estimates of the total area of the cortex of both hemispheres are higher than those of Danilewsky, varying from about 217,472 to 278,940 sq. mm. (*vide* Donaldson "On the Brain of Laura Bridgman," in the American Journal of Psychology, vols. iii. and iv.)

**Thickness of cortex.**—It is clear that a measurement of surface alone without taking into account the thickness of the cortex, may be entirely misleading as to the amount of grey matter in the brain. This has been recognized by various observers, who have accordingly endeavoured to form an estimate both of the average thickness of the cortex generally, and also its thickness in special localities. The results have been tabulated by Donaldson in the paper above referred to, and from them it would appear that the thickness may vary from 1.55 mm. to 3.5 mm., or even somewhat more than this, the average in normal brains being 2.9 mm. If a section be made across a gyrus it will be found that the cortex is thickest at the summit of the gyrus and thinnest at the bottom of the bounding sulci, so that it is necessary to take a mean between these two measurements in order to arrive at the



average thickness for any locality. But beyond the fact that the cortex is somewhat thinner near the hemisphere-poles, and especially the occipital pole, than in the intermediate parts, no definite statement regarding the relative thickness of different parts can at present be made. Females have a very slightly less thickness of cortex than males (less than 1 per cent.), and the right hemisphere less than the left: the difference may amount to 7 per cent. (Donaldson).

**Weight.**—The results obtained by Sims, Clendinning, Tiedemann and J. Reid showed the maximum weight of the adult male brain, in a series of 278 cases, to be about 1810 grammes (64 oz.), and the minimum weight about 960 grammes (34 oz.). In a series of 191 cases, the maximum weight of the adult female brain was 1585 grammes (56 oz.), and the minimum 880 grammes (31 oz.). In a very large proportion the weight of the male brain ranges between 46 oz. and 53 oz., and that of the female brain between 40 oz. and 47 oz. Similar statistics have been published by Peacock, R. Wagner, Bischoff, Huschke, Boyd, Weisbach and others. The mean weight at from 20 to 40 years of age was found by Boyd to be 48 oz. (1360 grammes) for the male, and 43½ oz. (1230 grammes) for the female brain. Although many female brains exceed in weight particular male brains, as a general fact it may therefore be affirmed that the adult male encephalon is on an average heavier by 4 oz. or 5 oz. than that of the female (or about 9 per cent.).

The appended table, which has been compiled from the observations of R. Boyd (Phil. Trans. 1860), shows in grammes the mean weights at different ages in the two sexes.

	MALES.	FEMALES.		MALES.	FEMALES.
Children stillborn at term ...	393	347	From 14 to 20 years.....	1,374	1,244
Children born alive at term .	330	283	From 20 to 30 years.....	1,333	1,237
Under 3 months .....	493	451	From 30 to 40 years.....	1,364	1,220
From 3 to 6 months.....	602	560	From 40 to 50 years.....	1,351	1,212
From 6 to 12 months .....	776	727	From 50 to 60 years.....	1,343	1,220
From 1 to 2 years.....	941	843	From 60 to 70 years.....	1,313	1,208
From 2 to 4 years.....	1,095	990	From 70 to 80 years.....	1,288	1,168
From 4 to 7 years.....	1,138	1,135	Over 80 years .....	1,283	1,125
From 7 to 14 years .....	1,301	1,154			

It would appear from the above that the brain is absolutely heavier between 14 and 20 years of age than at any other period of life, and that at the age of 80 it has lost about 90 grammes, or rather more than 3 ozs., *i.e.*, about  $\frac{1}{3}$  of its whole weight.

The figures obtained by Broca are somewhat higher than these, *e.g.*, between the ages of 30 and 35, in the male, an average of 1421 grammes (50 oz.); in the female, 1269 grammes (45 oz.). According to the same statistics, the weight of the brain attains its maximum, not before the age of 20, as found by Boyd, but between 25 and 35 in the male and a little earlier in the female. This agrees with the results of Peacock.

The two hemispheres of the same brain, although hardly ever of exactly the same weight, show no constant difference, the one half preponderating just about as often as the other, and the average difference being only about 5 grammes (Braune). There is no evidence that the right hemisphere is the heavier in left-handed people.

It has frequently been found that the brains of distinguished men have a brain-weight above the average, sometimes markedly so, but the rule has many exceptions. The converse is by no means true.

The *relative weight of the encephalon to the body* is liable to great variation; nevertheless, the facts to be gathered from the observations of Clendinning, Tiedemann, and Reid, furnish the following general result. In a series of 81 males, the average proportion between the weight of brain and that of the body at the ages of twenty years and upwards, was found to be as 1 to 36·5; and in a series of 82 females, to be as 1 to 36·46. The results of Bischoff's observations give 1 to 35·2 in

the female. In these cases the deaths were the result of more or less prolonged disease; but in six healthy individuals dying suddenly from disease or accident, the average proportion was 1 to 41.

The proportionate weight of the brain to that of the body is much greater at birth than at any other period of extra-uterine life, being, according to Tiedemann, about 1 to 5·85 in the male, and about 1 to 6·5 in the female. From various observations, it further appears that the proportion diminishes gradually up to the tenth year, being then about 1 to 14. From the tenth to the twentieth year the relative increase of the body is most striking, the ratio of the two being at the end of that period about 1 to 30. After the twentieth year the general average of 1 to 36·5 prevails, with a further trifling decrease in advanced life.

*Influence of stature on brain weight.*—According to J. Marshall, the proportion of entire brain (in ozs.) to each inch of stature, is for the male sex 0·708; in the female 0·688. This relative preponderance in the male is due entirely to preponderance of *cerebral* development; the average stature-ratio for cerebrum alone being 0·0619 oz. in the male per inch of stature, and 0·599 oz. in the female, whilst the stature-ratios of cerebellum, pons and medulla oblongata, are similar in the two sexes.

The following tables have been compiled by Marshall from the data furnished by the observations of R. Boyd upon the brains of 1150 sane persons, viz. :—598 males and 552 females. They show the average weights in ozs. of the encephalon and its several parts at certain periods of life and in individuals having certain differences of stature :—

## M A L E S.

Total number of cases.	Ages.	STATURE 69 INCHES AND UPWARDS.				STATURE 68—66 INCHES.				STATURE 65 INCHES AND UNDER.			
		Whole Brain.	Cerebrum.	Cerebellum.	Pons and Med. Obl.	Whole Brain.	Cerebrum.	Cerebellum.	Pons and Med. Obl.	Whole Brain.	Cerebrum.	Cerebellum.	Pons and Med. Obl.
146	20—40	49·72	43·43	5·29	1	47·99	41·9	5·09	1	46·95	41·15	4·9	·9
337	40—70	48·15	42·1	5·09	·96	47·08	41·01	5·1	·97	45·74	39·88	4·96	·9
115	70—90	46·92	41·19	4·8	·93	46·	40·1	4·9	1	44·15	38·6	4·65	·9
598	20—90	48·40	42·34	5·09	·97	47·13	41·08	5·06	·99	45·61	39·84	4·87	·9

## F E M A L E S.

Total number of cases.	Ages.	STATURE 64 INCHES AND UPWARDS.				STATURE 63—61 INCHES.				STATURE 60 INCHES AND UNDER.			
		Whole Brain.	Cerebrum.	Cerebellum.	Pons and Med. Obl.	Whole Brain.	Cerebrum.	Cerebellum.	Pons and Med. Obl.	Whole Brain.	Cerebrum.	Cerebellum.	Pons and Med. Obl.
133	20—40	44·64	39·14	4·7	·8	42·98	37·23	4·85	·9	42·26	36·78	4·64	·84
299	40—70	42·67	37·21	4·63	·83	42·75	37·29	4·56	·9	42·49	37·08	4·54	·87
120	70—90	41·13	35·77	4·52	·84	39·84	34·45	4·55	·84	39·59	34·36	4·36	·87
552	20—90	42·76	37·32	4·62	·82	42·37	36·84	4·64	·89	41·53	36·17	4·5	·86

It will be seen from these that although there is an increase of brain-weight with body-stature, this increase does not keep pace, *pari passu*, with the stature. That is to say, taller persons, although they have absolutely more brain substance, have relatively less than shorter persons. This is true for either sex. Nevertheless the proportion of brain to the stature remains larger in the male both at the mean height of both sexes, and at nearly corresponding heights.

Marshall further finds from a minute analysis of these results of R. Boyd, that in the case of males of mean height, the weight in ounces of the cerebrum may be obtained by simply dividing the number of inches of height by 1.6, or in grammes by multiplying the number of centimetres of height by 7.

For females, the same formula as that employed for the male can be used, but the result must be multiplied by  $\frac{30}{31}$ .

Thus—

$$\begin{aligned} \text{Weight in ozs. of the mean male cerebrum} &= \frac{\text{Height in inches}}{1.6} \\ \text{“ “ “ female cerebrum} &= \frac{\text{Height in inches}}{1.6} \times \frac{30}{31} \\ \text{Weight in grammes of the mean male cerebrum} &= \text{Height in centim.} \times 7 \\ \text{“ “ “ female cerebrum} &= \text{Height in centim.} \times 7 \times \frac{30}{31} \end{aligned}$$

The weights as calculated from these formulæ are found by Marshall to correspond very nearly with the observed weights for definite statures as recorded in Boyd's tables. The correspondence is most complete for statures near the mean, the observed weights being slightly defective at the higher, and excessive at the lower statures.<sup>1</sup>

Most of the estimates of brain weight in different races have been obtained as the result of measuring the cubic contents of the skull cavity (compare Vol. II., p. 83, and Manouvrier, *loc. cit.*). In this way it is estimated (Davis), that the Chinese have an average brain weight of about 1330 grammes (approaching that of the European); the Sandwich islanders one of 1300 grammes; the Malays and North American Indians one of 1265 grammes; the negro 1245 grammes; the native Australians 1185 grammes. The Hindus have also a small brain weight (probably in relation to the small prevailing stature), viz.: 1190 grammes. Amongst Europeans the Latin races have a somewhat less brain weight than the Teutonic and Slavonic races; here also in all probability the influence of stature is apparent.

**Weight of the several parts of the encephalon.**—The proportionate weight of the cerebellum (inclusive of the pons and the medulla oblongata) to that of the cerebrum is, in the adult, as 13 to 87 (Huschke). The cerebellum is both absolutely and relatively somewhat heavier in the male than in the female.

In the new-born infant the ratio of the weight of the cerebellum to that of the whole brain is strikingly different from that observed in the adult. Huschke found the weight of the cerebellum, medulla oblongata, and pons together in the new-born infant, as compared with that of the cerebrum, to be in the proportion of 7 to 93.

Meynert found the proportions between the frontal, parietal, and conjoined occipital and temporal lobes to be 41.5 : 23.4 : and 35.1 (in both the male and female).

**Weight of the spinal cord.**—Divested of its membranes and nerves, the spinal cord in the human subject weighs from 1 oz. to  $1\frac{3}{4}$  oz. (average 30 grammes, Schwalbe). Its proportion to the encephalon is about 1 to 43.

<sup>1</sup> For further discussion of the proportion of stature to brain weight, the reader is referred to a paper by le Bon in the *Revue d'Anthropol.*, 1879, and to one by the late Prof. J. Marshall, F.R.S., in the *Journal of Anatomy and Physiology*, July, 1892.



## THE MEMBRANES OF THE BRAIN AND SPINAL CORD.

The cerebro-spinal axis is covered by three *membranes*, named also *meninges*. They are:—1. An external fibrous membrane, named the *dura mater*, which lines the interior of the skull, and forms a loose sheath in the spinal canal; 2. An internal areolar and vascular tunic, the *pia mater*, which closely covers the brain and spinal cord; and 3. An intermediate non-vascular membrane, the *arachnoid*, which lies over the *pia mater*, the two being in some places in close connection, in others separated by a considerable space.

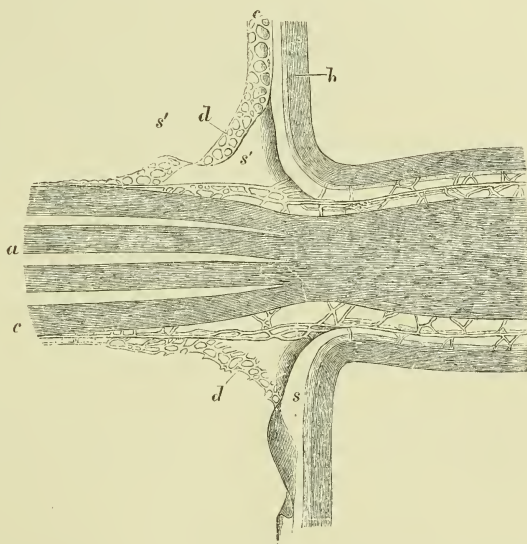
Some authors describe only two meninges, considering the arachnoid and *pia mater* to constitute one (*leptomeninges*), and the *dura mater* the other (*pachymeninges*).

## THE DURA MATER.

The *dura mater* is a very strong dense inelastic fibrous tunic of considerable thickness (.5 mm. or more in the cranium, less in the spinal canal). Its inner surface, turned towards the brain and spinal cord, is smooth and lined with

Fig. 123.—SECTION THROUGH THE PLACE OF EXIT OF A SPINAL NERVE-ROOT THROUGH THE DURA MATER. (Key and Retzius.)

*a*, bundles of the nerve-root becoming collected into a single bundle as they emerge; *b*, *dura mater*; *c*, *arachnoid*; *d*, a reticular lamella of the *arachnoid* reflected along the nerve-root; *s*, *subdural space*; *s'*, *s'*, *subarachnoid space*.



epithelium (endothelium), which was formerly regarded as a parietal reflection of the arachnoid membrane, this having been generally looked upon as a serous membrane. The space between the *dura mater* and *arachnoid* was formerly in like manner regarded as the sac of the *arachnoid*, but is now conveniently termed the *subdural space*. The outer surface of the

*dura mater* is connected with the surrounding parts in a somewhat different manner in the cranium and in the spinal canal.

In the cranium it adheres to the inner surface of the bones, and forms their internal periosteum. The connection between the two depends, in a great measure, on blood-vessels and small fibrous processes, which pass from one to the other; and the *dura mater*, when detached and allowed to float in water, presents a flocculent appearance on its outer surface, in consequence of the torn parts projecting from it. The adhesion between the membrane and the bone is more intimate opposite the sutures, and also at the base of the skull, which is uneven, and perforated by numerous foramina, through which the *dura mater* is prolonged to the outer surface, being there continuous with the pericranium. The fibrous tissue of the *dura mater* becomes blended with the areolar sheath of the nerves at the foramina which give exit to them.

In leaving the skull, the *dura mater* is intimately attached to the margin of

the foramen magnum, and below this to the cervical vertebræ as far as the third. Above the atlas it has an orifice on each side for the passage of the vertebral artery. Within the rest of the vertebral canal it forms a loose sheath around the cord (*theca*), and is not adherent to the bones, which have an independent periosteum. Towards the lower end of the canal, a few fibrous slips proceed from the outer surface of the dura mater to be fixed to the vertebræ; one such being especially well marked at the lower end, and seeming to join the anterior surface of the dura mater to the posterior common ligament of the vertebræ (anterior ligament of the dura mater, Trolard). The theca ends opposite the second sacral vertebra in the adult (see p. 6). The space intervening between the wall of the canal and the dura mater (*epidural space*) is occupied by loose fat, by areolar tissue, and by a plexus of spinal veins.

Opposite each intervertebral foramen the dura-matral theca has two openings, placed side by side, which give passage to the two roots of the corresponding spinal nerve. It is continued as a tubular prolongation on each nerve (fig. 128), and is lost in its sheath. Besides this, it is connected with the circumference of the foramen by areolar tissue.

The fibrous tissue of the dura mater, especially within the skull, is divisible into two distinct layers, and at various places the layers separate from each other and leave intervening channels, called *sinuses*. These sinuses, which have been elsewhere described (Vol. II.), are channels for venous blood, and are lined with a continuation of the endothelium of the veins. The division into two layers is most complete at the base of the skull, in the middle fossa, and in the neighbourhood of the cavernous sinus; on the outer side of this the Gasserian ganglion is included in a space (*cavum Meckelii*) between the two layers. Between the two cavernous sinuses the pituitary body is received into a depression of the membrane, which closely surrounds the organ in question, except where the infundibulum enters it. There is further a fissure immediately over the orifice of the aquæductus vestibuli, and here the prolongation of the membranous labyrinth of the ear, known as the saccus endolymphaticus, is received between the two layers.

The dura mater also sends inwards into the cavity of the skull three strong membranous *processes* or *partitions*. Of these, one descends vertically in the median plane, and is received into the longitudinal fissure between the two hemispheres of the cerebrum. This is the *falx cerebri*. The second is a sloping vaulted partition, stretched across the back part of the skull, between the cerebrum and the cerebellum, named the *tentorium cerebelli*. Below this, another vertical partition, named *falx cerebelli*, of small extent, passes down between the hemispheres of the cerebellum. Lastly, the portion of dura mater which stretches over the sella turcica, and pierced by a small hole for the infundibulum, covers the pituitary body, is sometimes spoken of as the *operculum* or *tentorium of the hypophysis*.

The **falx cerebri** (fig. 129, 1) is narrow in front, where it is fixed to the crista galli, and broader behind, where it is attached to the middle of the upper surface of the tentorium, along which line of attachment the straight sinus is attached. Along its upper convex border, which is attached to the middle line of the inner surface of the cranium, runs the superior longitudinal sinus. Its under edge is free, and reaches to within a short distance of the corpus callosum, approaching nearer to it behind. This border contains the inferior longitudinal sinus.

The **tentorium cerebelli**, or **tent** (fig. 129, 8), is elevated in the middle, and declines downwards in all directions towards its circumference, thus following the form of the upper surface of the cerebellum. Its inner border is free and concave, and leaves in front of it a shield-shaped opening, through which the isthmus encephali extends. It is attached behind and at the sides by its convex border to the horizontal part of the crucial ridges of the occipital bone, and there encloses the lateral sinuses. Farther forward it is connected with the upper edge of the petrous portion

of the temporal bone—the superior petrosal sinus running along this line of attachment. At the point of the pars petrosa, the external and internal borders meet, and may be said to intersect each other—the former being then continued inwards to the posterior, and the latter forwards to the anterior clinoid process.

The **falx cerebelli** (falx minor, fig. 129, 13) descends from the middle of the posterior border of the tentorium, with which it is connected, along the vertical

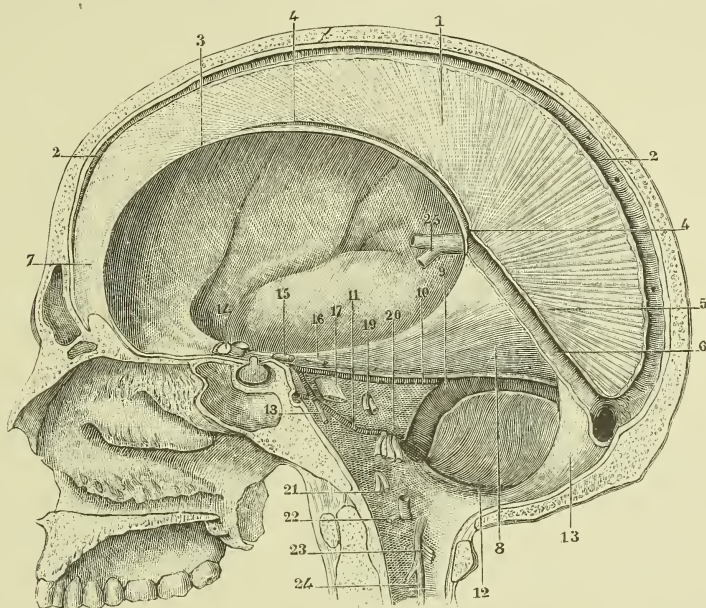


Fig. 129.—THE CRANIUM OPENED TO SHOW THE FALX OF THE CEREBRUM AND TENTORIUM OF THE CEREBELLUM, AND THE PLACES OF EXIT OF THE CRANIAL NERVES. (Sappey.)  $\frac{1}{2}$

1, falx; 2, superior longitudinal sinus; 3, concave border of the falx; 4, inferior longitudinal sinus; 5, base of the falx; 6, straight sinus; 7, anterior part of the falx; 8, right side of the tentorium cerebelli, seen from below; 9, lateral sinus; 10, superior petrosal sinus; 11, inferior petrosal sinus; 12, posterior occipital sinus; 13, falx cerebelli; 14, 15, 16, 17, 18, second, third, fourth, fifth, and sixth cranial nerves; 19, seventh and eighth nerves; 20, ninth, tenth, and eleventh nerves; 21, twelfth nerve; 22, 23, first and second cervical nerves; 24, upper end of the ligamentum denticulatum.

ridge named the internal occipital crest towards the foramen magnum, bifurcating there into two smaller folds. Its attachment to the bony ridge marks the course of the occipital sinus or sinuses.

**Structure.**—The dura mater consists of white fibrous and elastic tissue, arranged in bands and laminae, those of the two layers crossing each other obliquely for the most part in the cranial dura mater. In the falx and tentorium the bundles are arranged radially. It is not uncommon to find the cranial dura mater ossified in parts: most commonly in the falx cerebri. In the spinal dura mater the bundles have a nearly longitudinal arrangement. A layer of flattened endothelial cells covers its inner surface, and also its outer surface between the places of adherence to the bones and sutures. A similar layer of cells also covers both sides of the spinal dura mater. The cranial membrane is traversed by numerous blood-vessels which are chiefly destined for the bones, but there is a wide-meshed capillary network with peculiar ampullary enlargements, distributed near the inner surface of the cranial dura mater, and another network near the outer surface. The spaces between the fibrous trabeculae contain flattened connective tissue corpuscles which



frequently have an epithelioid arrangement : these spaces, like those of connective tissue generally, doubtless serve for the passage of lymph. They can be injected from the epidural space where this exists, and the injecting fluid can be forced along them through the thickness of the dura mater into the subdural space. They can also be filled by inserting the injecting cannula into the substance of the membrane. Minute nervous filaments, derived from the fifth, tenth, and twelfth cranial nerves, and from the sympathetic, enter the dura mater of the brain to be distributed chiefly to the blood-vessels and to the bone, but partly perhaps to the membrane itself. Nervous filaments have likewise been traced into the dura mater of the spinal column.

The arteries of the cranial dura mater are derived from various sources ; the principal are three in number, viz., the anterior, derived from the ethmoidal branch of the ophthalmic ; the middle, by far the largest, a branch of the internal maxillary ; and the posterior meningeal, a branch of the vertebral. There are also others derived from the ascending pharyngeal and occipital arteries. Their course and relations have already been described (see Vol. II.). Veins accompany these arteries, but others, mostly small ones, run independently and open into the venous sinuses. One sinus-like vein which accompanies the anterior branch of the middle meningeal artery, communicates superiorly with the superior longitudinal sinus, and passes inferiorly either into the veins of the orbit, or into the diploic veins, or into the sinus cavernosus (Merkel). Communicating with the superior longitudinal sinus from its anterior end as far back as the beginning of the occipital region are a number of diverticula, from 0.5 to 3 cm. long, which form a series of venous lacunæ (*lacunæ laterales* of Key and Retzius) receiving the independent meningeal veins, and some veins from the diploë, and are invaginated by Pacchionian granulations (see p. 190). These venous lacunæ are not entirely confined to the region of the superior sinus, but some may occur in the neighbourhood of other sinuses, especially the lateral and straight sinus.

**Subdural space.**—The space between the dura mater and the arachnoid, which was formerly, when the latter was considered to be a serous membrane, known as the cavity of the arachnoid, is now more usually known under the above title. It is in most parts a narrow capillary cleft, containing but very little fluid, which is probably of the nature of lymph. Its contained fluid finds exit chiefly around the arachnoid villi (Pacchionian granulations) into the sinuses of the dura mater, but partly by way of the lymph-clefts in the sheaths of the issuing nerves, cranial and spinal (Key and Retzius). In animals it has been shown (by Schwalbe) that the space is also in communication with the deep lymphatic vessels and glands of the neck and loin. Coloured fluids injected into the subdural space are never found to pass into the subarachnoid space, the arachnoidal limiting membrane being everywhere a closed one. Nevertheless, coloured fluids can be made to pass from the subarachnoid space through the arachnoid villi into the prolongations of the subdural space which surround those villi within the venous sinuses and lacunæ, and thence into the sinuses themselves. This passage may, however, take place by filtration.

#### THE PIA MATER.

The pia mater is a delicate, fibrous, and highly vascular membrane, which immediately invests the brain and spinal cord.

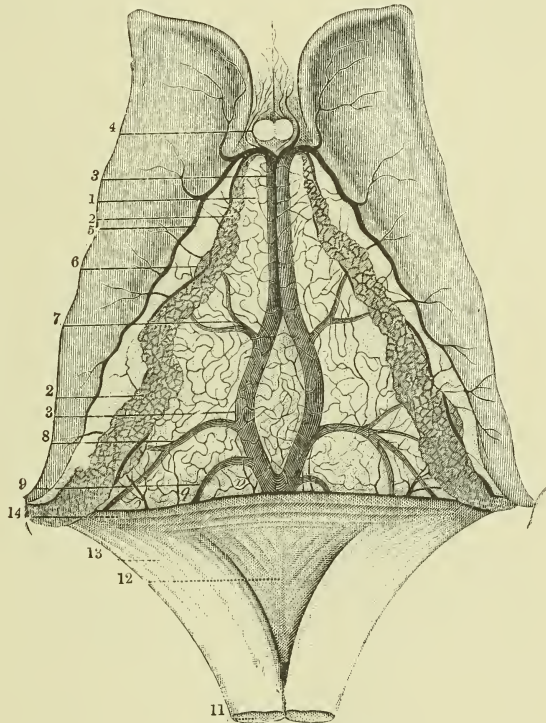
Upon the hemispheres of the brain it is applied to the entire cortical surface of the convolutions, and dips into all the sulci, most of which thus contain a double layer. From its internal surface numerous small vessels pass into the substance of the brain, and hence this inner surface is very flocculent, and is named *tomentum cerebri*. On the cerebellum a similar arrangement exists, but the membrane is finer,

and the double fold only distinct in the larger sulci. The pia mater also at the transverse fissure is invaginated into the lateral ventricles and over the third ventricle (covered however by the epithelium of those cavities), and there forms the velum interpositum or tela choroidea superior and choroid plexuses. It is also prolonged over the posterior wall or roof of the fourth ventricle, where it forms the so-called tela choroidea inferior and choroid plexuses of that ventricle.

The **velum interpositum**, or **tela choroidea superior**, is a triangular fold of pia mater, between the two layers of which arachnoidal tissue and blood-vessels are contained, which lies immediately underneath the fornix, and can therefore only be properly seen when this structure is cut through and raised (as in fig. 130). The velum interpositum is then seen to cover in the third ventricle and to extend over

Fig. 130.—VIEW OF THE UPPER SURFACE OF THE VELUM INTERPOSITUM, CHOROID PLEXUSES, AND CORPORA STRIATA (from Sappey after Vicq-d'Azyr).  $\frac{2}{3}$

1, fore-part of the tela choroidea or velum interpositum; 2, 2, choroid plexus; 3, 3, left vein of Galen partly covered by the right; 4, anterior pillars of the fornix divided in front of the foramen of Monro; on either side are seen small veins from the front of the corpus callosum and the septum lucidum; 5, vein of the corpus striatum; 6, convoluted marginal vein of the choroid plexus; 7, vein rising from the thalamus opticus and corpus striatum; 8, vein proceeding from the inferior cornu and hippocampus major; 9, one from the posterior cornu; 11, fornix divided near its middle and turned backwards; 12, lyra; 13, posterior pillar of the fornix; 14, the splenium of the corpus callosum.



the adjacent upper surface of the optic thalamus on each side as far as the oblique groove which marks that surface (p. 110, and fig. 82). The base of the triangle is

continuous with the general pia mater at the back and sides of the brain, the apex ends just behind the anterior pillars of the fornix (at the foramen of Monro). Each side of the triangle is bordered by a choroidal plexus which projects from under the edge of the fornix into the respective lateral ventricle; behind, these plexuses are continued along the mesial border of the descending cornu of the ventricle, where they are invaginated into the choroidal fissure, projecting over the fimbria; in front they converge, becoming gradually smaller, to the foramina of Monro, between which they become united. From this united part two other smaller plexuses pass backwards along the under surface of the velum interpositum, close to the middle line in front, but diverging behind (choroid plexuses of the third ventricle).

The choroid plexuses are covered where they project into the cavities by the epithelium of the ventricles, as is also that part of the velum interpositum which roofs in the third ventricle. Along the choroid plexuses a prominent vein, the choroid vein (fig. 89, p. 125), courses from behind forwards to join the vein of the corpus striatum and form the corresponding vein of Galen at the foramen of Monro:

the two veins of Galen pass forwards from this point in the middle of the velum interpositum, diverging somewhat behind, but again converging and ultimately becoming united into a common trunk (*vena magna Galeni*, fig. 130, *a*) which opens into the straight sinus. In this course they receive several tributaries from the optic thalami and other parts.

**Tela choroidea inferior.**—This name has been given to the layer of pia mater which, prolonged from the medulla oblongata, overlies the inferior half of the fourth ventricle and is reflected at the margin of the velum medullare inferius on to the under surface of the cerebellum. Like the velum interpositum, this also has two sets of choroid plexuses, mesial and lateral, which are continuous with one another in front. The mesial plexus extends forwards along either side of the middle line from the foramen of Majendie (p. 188) to where the tela is reflected along the edge of the inferior medullary velum; here the mesial plexuses are continued into the lateral plexuses on either side, and these extend to the apertures (in the pia mater) of the lateral recesses of the ventricle (p. 48).

On the spinal cord the pia mater has a very different character from that which it presents on the encephalon, so that it has even been described by some as a different membrane under the name *neurilemma of the cord*. It is thicker, firmer, less vascular, and more adherent to the subjacent nervous matter: its greater strength is owing to an external fibrous layer, which is arranged in longitudinal glistening bundles. A fold of this membrane dips down into the anterior fissure of the cord, and serves to conduct blood-vessels into that part. A thinner process passes into the greater part of the posterior fissure. At the roots of the nerves, both in the spine and in the cranium, the pia mater becomes continuous with their connective tissue sheaths.

The pia mater of the cord is thickened by a conspicuous fibrous band, running down in front over the anterior median fissure. This was named by Haller, *linea splendens*.

**Structure.**—The pia mater of the cord consists of two layers, the outer one being composed of interlaced bundles of connective tissue, which are for the most part parallel and longitudinal, and the inner or intima of peculiar stiff bundles bending suddenly and enclosing somewhat angular interspaces. Both surfaces of this inner layer are covered with endothelial cells, and there is a network of fine elastic fibres near the surfaces. On the cord pigmented cells are sometimes scattered among the elastic fibres. The outer and inner layers are separated here and there by cleft-like lymphatic spaces communicating on the one hand with the subarachnoid space and on the other with the perivascular canals immediately to be mentioned. In the pia mater of the brain only the inner of the two layers of the pia mater of the cord is represented.

The choroid plexuses are beset with a large number of highly vascular villous prolongations of the pia mater (choroidal villi), the larger of which are from 1 mm. to 2 mm. long, but are subdivided into smaller secondary or even tertiary villi. Each larger villus has an afferent artery and efferent vein which open into a capillary network lying close to the surface. The free surface of the villi and of the depressions between them is covered everywhere by a simple flattened or cubical epithelium, which is ciliated in lower vertebrates, but in mammals is said to possess cilia only in embryonic life. Each cell very commonly contains a yellowish fat globule.

The pia mater contains great numbers of blood-vessels, which subdivide in it before they enter the nervous substance. In the pia mater of the cord they lie between its two layers, but in that of the brain on the surface of the membrane, either projecting freely or covered by subarachnoid trabeculæ. Further each vessel is enclosed by a sheath composed of a more dense arrangement of the fibres of the



membrane (perivascular sheath). The diameter of the (lymphatic) canal thus formed may be considerably larger than that of the contained vessel. A similar sheath, derived from the pia mater, accompanies the vessel into the substance of the brain. At its commencement it is loose and funnel-shaped and can be injected from the subarachnoid cavity. On the cerebrum the inner layer of the pia mater is more closely adherent to the cortical substance of the convolutions, than on the cerebellum, where a distinct space traversed by fibres exists between the two.

**Nerves.**—Purkinje described a retiform arrangement of fine nerve-fibres in the pia mater; these are derived, according to Kölliker and others, from the sympathetic, and from the third, fifth, sixth, facial, pneumogastric, glossopharyngeal, and accessory nerves. Most of the fibres are destined in all probability for the blood-vessels.

The spinal pia mater is supplied by nerves from the grey rami communicantes of the sympathetic.

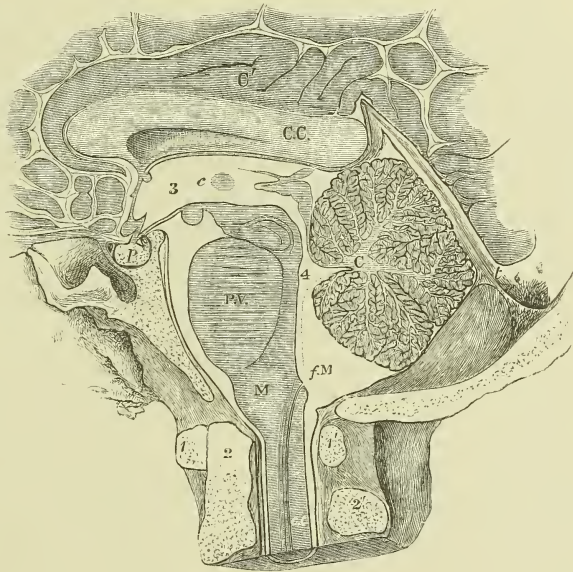
#### THE ARACHNOID MEMBRANE.

The arachnoid is a delicate membrane which is situated outside the pia mater, and invests the brain and spinal cord much less closely than that membrane. It passes over the various eminences and depressions on the cerebrum and cerebellum,

Fig. 131.—SECTION OF THE POSTERIOR AND LOWER PARTS OF THE BRAIN WITHIN THE SKULL, TO EXHIBIT THE SUBARACHNOID SPACE, AND ITS RELATION TO THE VENTRICLES. (After Key and Retzius.)

The section was made in the frozen state, the cavities having been previously filled with injection.

1, 1', atlas vertebra; 2, odontoid process of the axis, 2', 3, third ventricle; 4, fourth ventricle; *C. C.*, corpus callosum; *C'*, gyrus fornicatus; *C*, cerebellum; *t*, tentorium; *p*, pituitary body; *c.c.*, central canal of the cord; *f.M.*, in the cerebello-medullary part of the subarachnoid space, is close to the foramen of Magendie by which that space communicates with the fourth ventricle.



without dipping down into the sulci and smaller grooves. Beneath it, between it and the pia mater, is a space (subarachnoid space) in which is a considerable quantity of fluid (subarachnoid fluid), and in which are seen the larger blood-vessels passing obliquely towards the brain.

The **subarachnoid space** is larger and more evident in some places than in others. Thus, in the longitudinal fissure, the arachnoid does not descend to the bottom, but passes across, immediately below the edge of the falx, at some distance above the corpus callosum. In the interval thus left, the arteries of the corpus callosum run backwards along that body. At the base of the brain and in the spinal canal there is a wide interval between the arachnoid and the pia mater. In the base of the brain, this subarachnoid space extends in front over the pons and the interpeduncular recess as far forwards as the optic nerves, and behind it forms

The **subarachnoid space** is larger and more evident in some places than in others. Thus, in the longitudinal fissure, the arachnoid does not descend to the bottom, but passes across, immediately below the edge of the falx, at some distance above the corpus callosum. In the interval thus left, the arteries of the corpus callosum run backwards along that body. At the base of the brain and in the spinal canal there is a wide interval between the arachnoid and the pia mater. In the base of the brain, this subarachnoid space extends in front over the pons and the interpeduncular recess as far forwards as the optic nerves, and behind it forms

a considerable interval between the cerebellum and the back of the medulla oblongata (fig. 131). In the spinal canal, where it surrounds the cord, it is of considerable extent. It is occupied, in both brain and cord, by trabeculæ and thin membranous extensions of delicate connective tissue, connected on the one hand with the arachnoid, and on the other with the pia mater. This tissue is most abundant where the space between the two membranes is least. It is dense in the neighbourhood of the vessels, and is continuous with the tissue of their walls. In several places therefore the arachnoid is separated by larger intervals than at other parts from the pia mater.

The spaces which are thereby produced are termed *cisternæ arachnoidales* (reservoirs of subarachnoid fluid). They have been studied especially by Key and Retzius, and by Duret. The principal are situated at the base of the brain. The largest (*cisterna cerebello-medullaris*) lies between the middle part of the cerebellum and the medulla oblongata, and is directly continued from the subarachnoid space of the cord. Others lie in front and at the sides of the medulla oblongata and pons (*c. pontis media s. basilaris* and *c. pontis lateralis*), below the interpeduncular space (*c. interpeduncularis*), over the cerebral peduncles (*c.c. peripedunculares*), behind the optic chiasma (*c. chiasmatis*), in front of the chiasma (*c. lamina cinerea*), in the fossæ Sylvii (*c.c. fossæ Sylvii*), and over the corpus callosum (*c. corporis callosi*). These are all in free communication with one another, being only partly separated by imperfect septa of arachnoid tissue. They receive the subarachnoid clefts (*fumina*) which follow the course of the great fissures (Rolandic, Sylvian, parallel, &c.), and which themselves receive the clefts which follow the course of the secondary and tertiary fissures (*rivi* and *rivuli* of Duret).

The subarachnoid space communicates with the ventricles of the brain by means of the foramen of Magendie (fig. 131, *fM*), an opening into the lower part of the fourth ventricle, through the pia-matral expansion (tela choroidea inferior) which covers the ventricle; through apertures in the lateral recesses, one on each side, behind the upper roots of the glossopharyngeal nerve, in the pouch-like extension of the membrane beneath the flocculus; and perhaps also at the clefts described by Merkel in the descending cornua of the lateral ventricles (see p. 126).

The cerebro-spinal fluid is lodged in the subarachnoid space in the meshes of the trabecular tissue, and since this space communicates with the ventricles of the brain, the fluid within these must be regarded as of the same nature. It differs in many respects from ordinary lymph (compare Halliburton, Cerebrospinal Fluid, Journal of Physiology, Vol. X.).

The spinal subarachnoid space (fig. 132, *k, l*) is divided by an imperfect fibrous septum on either side termed the ligamentum denticulatum (*g*) into anterior and posterior portions. As was pointed out by Magendie there also exist a sort of septum dividing the subarachnoid space at the back of the cord (*septum posticum*) (*c*), the relations of which have been carefully studied by Axel Key and G. Retzius. It is a thin membranous partition, which passes in the median plane from the pia mater covering the posterior median fissure of the cord to the opposite part of the loose portion of the arachnoid membrane. It is most perfect in the cervical region, being incomplete below. It consists of numerous fine lamellæ, enclosing between them small spaces, within which run the larger blood-vessels. Subarachnoid trabeculæ also connect the nerve-roots with the inner surface of the arachnoid, and in the dorsal region fine membranous trabeculæ extend between the posterior nerve-roots and the posterior septum. In most parts however the subarachnoid trabeculæ are far less developed in the spinal canal than in the cranium.

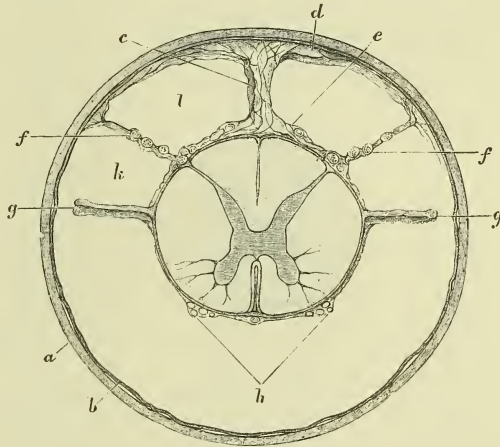
The nerves as they pass from the brain and spinal cord receive their perineural covering from the pia mater, and, in addition, two looser sheaths, an outer from the dura mater, and an inner from the arachnoid (fig. 128). Upon the optic nerve these sheaths remain distinct and separate, so that the space which each encloses may be injected, the outer from the subdural, the inner from the sub-arachnoid space. On the other nerves the arachnoidal sheath soon ceases, and the single sheath eventually

blends with both the epineurium and perineurium of the nerves. Accordingly it is found that injection driven into either the subdural or the subarachnoid space passes readily along the nerves even as far as the limbs. There thus exists a continuity between the ventricles of the brain, the subarachnoid space, and the lymphatic spaces within the nerve-sheaths.

**Structure.**—When examined under the microscope, the arachnoid membrane is found to consist of distinct riband-like bundles of fine fibrous tissue interlaced with one another. The intervals between these bundles are filled up by delicate membranes, composed of expanded cells, the nuclei of which persist and are scattered over the structure. Several layers of this tissue, arranged in a complex way,

Fig. 132.—SECTION OF THE SPINAL CORD WITHIN ITS MEMBRANES (UPPER DORSAL REGION). (Key and Retzius.) Magnified.

*a*, dura mater; *b*, arachnoid; *c*, septum posticum; *d*, *e*, *f*, subarachnoid trabeculae, those at *f*, *f*, supporting bundles of a posterior nerve-root; *g*, ligamentum denticulatum; *h*, sections of bundles of an anterior nerve-root; *k*, *l*, subarachnoid space.



constitute the arachnoid membrane proper. The subarachnoid trabeculae consist of bundles of similar fine fibrillar tissue, each of which is surrounded by a delicate nucleated sheath, also composed of cells, and continuous with the intertrabecular cell-

membranes of the arachnoid itself. The finer trabeculae when swollen by acetic acid very frequently show the well-known ring-like constrictions. The subarachnoid membranous expansions have a similar structure. In the spinal arachnoid the fibril-bundles have for the most part a longitudinal direction.

Volkman described a rich plexus of nerves in the arachnoid membrane of certain ruminants. Kölliker failed to detect their presence; but they have been again described by Bochdalek, who traces them to the portio minor of the fifth, the facial, and accessory nerves; and they have likewise been followed by Luschka.

**Ligamentum denticulatum.**—This is a narrow fibrous band which runs along each side of the spinal cord in the subarachnoid space, between the anterior and posterior roots of the nerves, commencing above at the foramen magnum, and reaching down to the lower pointed end of the cord (fig. 133, 9, and fig. 132, *g*). By its inner edge this band is connected with the pia mater of the cord, while its outer margin is widely denticulated; its denticulations are attached by their points to the inner surface of the dura mater, and thus serve to support the cord along the sides, and to maintain it in the middle of the cavity. The first or highest denticulation is fixed opposite the margin of the foramen magnum, between the vertebral artery and the hypoglossal nerve (shown in fig. 182 of Vol. II.); the others follow in order, alternating with the successive pairs of spinal nerves. In all, there are about twenty-one of these points of insertion, but the lower six or seven are less regular. The points of the lower denticulations are prolonged into threads, and ascend slightly to their attachments. At the lower end, the ligamentum denticulatum may be regarded as continued into the terminal filament of the spinal cord, which thus connects it to the dura mater at the extremity of the sheath. The free edge, in the intervals between the denticulations, is slightly thickened, and in many



parts is closely applied to the inner surface of the arachnoid, with which it is often directly connected by fine trabeculæ. The denticulations do not perforate the arachnoid but receive from it funnel-shaped sheaths, which accompany them to the inner surface of the dura mater (Axel Key and Retzius).

In structure the ligament consists of white fibrous tissue, mixed with many exceedingly fine elastic fibres. Several layers of fine connective tissue trabeculæ may be traced; they are surrounded by sheaths, which are composed of delicate

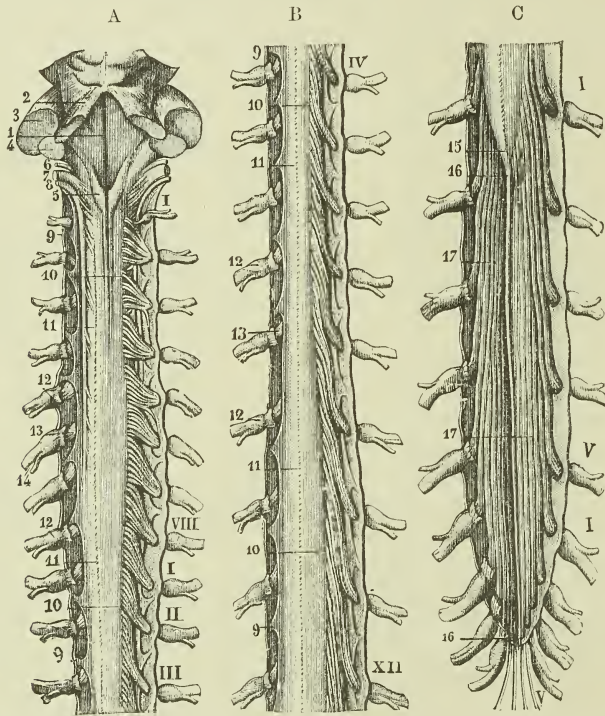


Fig. 133.—VIEW FROM BEHIND OF THE MEDULLA OBLONGATA AND SPINAL CORD, WITH THE THECA. (Sappey.)  $\frac{1}{2}$ .

The dura-matral sheath has been opened by a median incision and is stretched to either side. In the upper and middle parts (A and B) the posterior nerve-roots have been removed to show the ligamentum denticulatum. 1, fourth ventricle; 2, 3, 4, cerebellar peduncles; 5, clavus; 6, 7, 8, roots of glossopharyngeal, vagus, and accessory nerves; 9, points of ligamentum denticulatum; 10, line of entrance of posterior roots into spinal cord; 11 (in B), posterior median fissure; 12, ganglia; 13, cut anterior roots; 14, mixed nerve; 15, 16, filum terminale; 17, cauda equina.

nucleated cells, and here and there expand into membranes. Its tissue is continuous on the one hand with that of the pia mater, and at the apices of the denticulations with that of the dura mater.

**Glandulæ Pacchionii or arachnoidal villi.**—Upon the external surface of the dura mater, in the vicinity of the longitudinal sinus, are seen numerous small pulpy looking elevations, generally collected into clusters, named glands of Pacchioni (fig. 134). The inner surface of the calvaria is marked by little pits, which receive these prominences. Similar excrescences are seen on the internal surface of the dura mater, and upon the pia mater on each side of the longitudinal sinus, and also projecting into the interior of that sinus (*s*). Occasionally they are found also in other situations.

On a careful examination of the connections of these bodies it will be found that

the elevations found on the outer surface of the dura mater and within the longitudinal sinus, in no instance take origin in those positions, but that they are grape-like bodies which are attached more deeply, and in their growth have invaginated the dura mater. Their precise origin and nature were long the subject of conflicting opinions, but it has been satisfactorily shown by Luschka that they are villi of the arachnoid. On each side of the sinus, and communicating with it, are large venous spaces in the dura mater (*lacunæ laterales*, see p. 184); into these the villi project even in new-born animals, and those which appear to perforate the dura

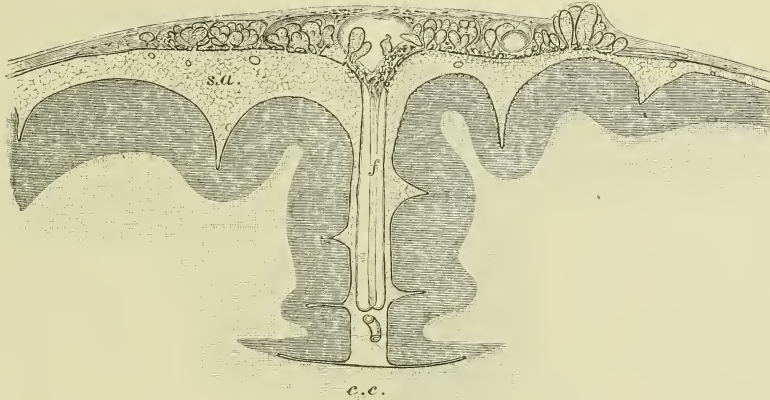


Fig. 134.—SECTION OF THE UPPER PART OF THE BRAIN AND MENINGES TO SHOW THE RELATIONS OF THE ARACHNOID VILLI. (Key and Retzius.) Magnified.

*c.c.*, corpus callosum; *f*, falx cerebri; *s.a.*, subarachnoid space, pervaded by a network of fine trabeculae; from it the fungiform villi are seen projecting into the lateral lacunæ of the dura mater. Some are projecting into the superior longitudinal sinus, *s*.

mater and appear on the surface have their inner parts in these spaces. Each villus is covered by a membrane, continuous with the arachnoid. Outside this is another fine membranous sheath, derived from the dura mater, and the interval between the two is continuous with the subdural space. Within the villus is a spongy trabecular tissue, continuous with the subarachnoid tissue, and of similar structure (Key and Retzius).

Fluid injected into the subarachnoid space passes freely into the Pacchionian bodies, and is found after a time to filter through their walls and thus to get into the subdural space, although there does not appear to be any open communication between the interior of these bodies and the prolongation of the subdural space which surrounds them. Moreover, if the injection is continued it can be driven even into the interior of the venous sinuses and lacunæ which are found in connection with them, especially into the superior longitudinal sinus, into which the arachnoid villi project. So that these villi seem to afford a means of passage of the cerebrospinal fluid from the subarachnoid space into the venous sinuses, when the fluid pressure in the subarachnoid space becomes from any cause increased above the normal.

#### BLOOD-VESSELS OF THE BRAIN AND SPINAL CORD.

**Blood supply of the spinal cord.**—The arteries of the spinal cord are (1) the *anterior spinal*, double above where it is derived from the vertebrals, but single and median below where it is reinforced by a series of small vessels derived from the vertebral, intercostal, lumbar, and other arteries, and passing to the cord along

the anterior roots, and (2) the paired *posterior spinal arteries*, similarly derived from the vertebrals, intercostals, and other arteries, and running just in front of the line of attachment of the posterior roots. Another small longitudinal anastomotic chain formed by branches of the posterior spinal runs along just behind the line of the posterior roots.<sup>1</sup> The branches of these vessels ramify in the pia mater investing the cord, communicating with one another to form transverse anastomoses, and from the main vessels and their ramifications vessels pass in to supply both the grey and white substance.

The small entering branches may be described as forming two systems, a centrifugal and a centripetal. The first is composed of a series of arterioles, (*central arterioles*, Ross), 200 to 300 in number, which pass from the anterior spinal

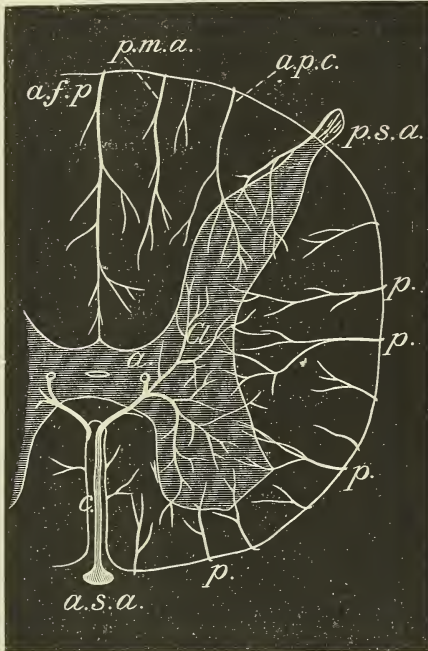

Fig. 135. —SEMIDIAGRAMMATIC REPRESENTATION OF THE ARTERIES IN THE INTERIOR OF A SEGMENT OF THE SPINAL CORD. (Obersteiner.)

*a.s.a.*, anterior spinal artery; *c*, a central arteriole; *a*, an anastomotic branch uniting it with another arteriole of an adjacent segment; *cl*, branch to Clarke's column; *a.p.f.*, artery of posterior fissure; *p.m.a.*, posterior mesial artery; *a.p.c.*, artery of posterior cornu; *p.s.a.*, branch of posterior spinal artery passing into gelatinous substance; *p*, other peripheral or centripetal arterioles passing through white substance of cord.

artery into the anterior median fissure, penetrating to the anterior commissure. Here each one passes either to the right or left, and divides into smaller arteries and capillaries for the central parts of the corresponding crescent of grey matter; but a considerable ascending and descending ramuscule is also given off, and these overlap in their distribution the corresponding longitudinal branches of the adjacent central arterioles.

Although mainly distributed to the central parts of the grey matter the central arterioles may also send branches to join the capillaries of the white matter.

The second or centripetal set has a converging or radial arrangement, passing in from the periphery. Some of these simply form capillary loops, which supply the superficial layers of the cord. Others are distributed to the white matter, where they form comparatively large-meshed longitudinal plexuses. But the most considerable of the centripetal arteries penetrate to the grey matter, and pour their blood into the close capillary network which pervades it, supplying the parts not served by the centrifugal vessels. The capillaries of the substantia gelatinosa are less numerous than in the rest of the grey matter, and their meshes are mostly longitudinal.

Special mention may be made of a series of small median arterial branches which enter the posterior fissure, penetrating in it to the posterior commissure, and giving off branches which supply the adjacent parts of the posterior white columns and Clarke's column, where this is found; and of the vessels which enter the grey matter with the bundles of the anterior and posterior nerve-roots, and are distributed to the corresponding cornua. It would appear however that no one part is supplied by only one set of arterioles, nor is any one set of arterioles confined in its distribution to

<sup>1</sup> For the origin and course of the spinal arteries see Vol. II., pp. 421 and 422.



any one white column or group of cells in the grey matter. At the same time it should be noted that within the cord itself (as within the brain), all the arteries are "terminal arteries," in Cohnheim's sense, that is to say, they do not anastomose with other arteries, but each one terminates in its own capillary area, and supplies no other. There is however much variation in the extent of the capillary area supplied by any of the arterial branches, and no definite statement can be made concerning the exact region supplied by any set of arterioles (Kadyi).

The origin and course of the veins of the spinal cord have been described in Vol. II., pp. 533, 534. The most considerable are two longitudinal median vessels, one running along the anterior median fissure along with the anterior spinal artery, and another over the posterior median fissure, unaccompanied by any considerable artery. Both of these median veins have a tortuous course, and the posterior one is frequently broken up into a kind of venous plexus, with longitudinal meshes, which extends over the whole posterior surface of the cord. There is also a less perfect lateral anastomotic chain lying behind the line of exit of the anterior nerve roots. All these vessels communicate freely with one another by lateral offsets. They receive the venous blood from the cord on the one hand, and on the other hand carry it away by veins which accompany, at frequent intervals, the nerve roots. In the upper part they join the veins of the cerebellum and pons, and the venous sinuses around the foramen magnum. Within the cord their branches anastomose frequently. The vein accompanying the anterior spinal artery receives, like that vessel, very numerous tributaries from the anterior median fissure (*central venules*): these carry away a large part of the blood from the grey matter; the *peripheral venules*, which enter the veins of the pia mater which covers the general surface of the cord, chiefly carry away the blood from the capillaries of the white matter.

**Blood-supply of the brain.**—The origin and course of the vessels which supply the brain have already been described in the section *Angeiology*, Vol. II. pp. 411 to 415 (arteries), and 519 to 524 (veins). In passing to their distribution the several arteries, having passed across the subdural space, enter the subarachnoid space and then divide and subdivide into branches, which, in their further ramification on the nervous centres, are supported by the pia mater, and, it may be remarked, are more deeply placed in the various fissures and sulci than the small veins, which do not accompany the arteries, but pursue a different course, and are chiefly seen upon the surface of the pia mater. From the arteries in the pia mater of the hemispheres very numerous small branches pass vertically into the grey matter of the convolutions. Most of these (*cortical arteries*) at once break up into a close plexus of capillaries for the grey matter; but others (*medullary arteries*), larger but less numerous, pass through the grey matter, giving off only a few small branches to it, and penetrate for some distance into the medullary centre, where they divide into a long-meshed capillary network. The smaller branches of arteries anastomose together to a certain extent in the pia mater before penetrating into the superficial grey matter (Huebner), but the branches which pass to the chief ganglia, such as the optic thalamus or corpus striatum, do not anastomose with one another.

Moreover, it is to be observed that, whilst the main branches of the arteries are situated at the base of the brain, the principal veins tend towards the upper surface of the hemispheres, where they enter the superior longitudinal sinus, most of them looping forwards as they pass into the sinus, and often entering the dura mater a short distance from the sinus, but more usually having a free course, sometimes of considerable length, through the subarachnoid space in passing from the pia into the dura mater. The veins of Galen, coming from the lateral ventricles and choroid plexuses, run backwards to the straight sinus, in the subarachnoid tissue which lies between the two layers of the velum interpositum.

It may be convenient here to recapitulate the sources of the blood supply to the several parts of the encephalon.

The **medulla oblongata and pons Varolii** are supplied by branches from the

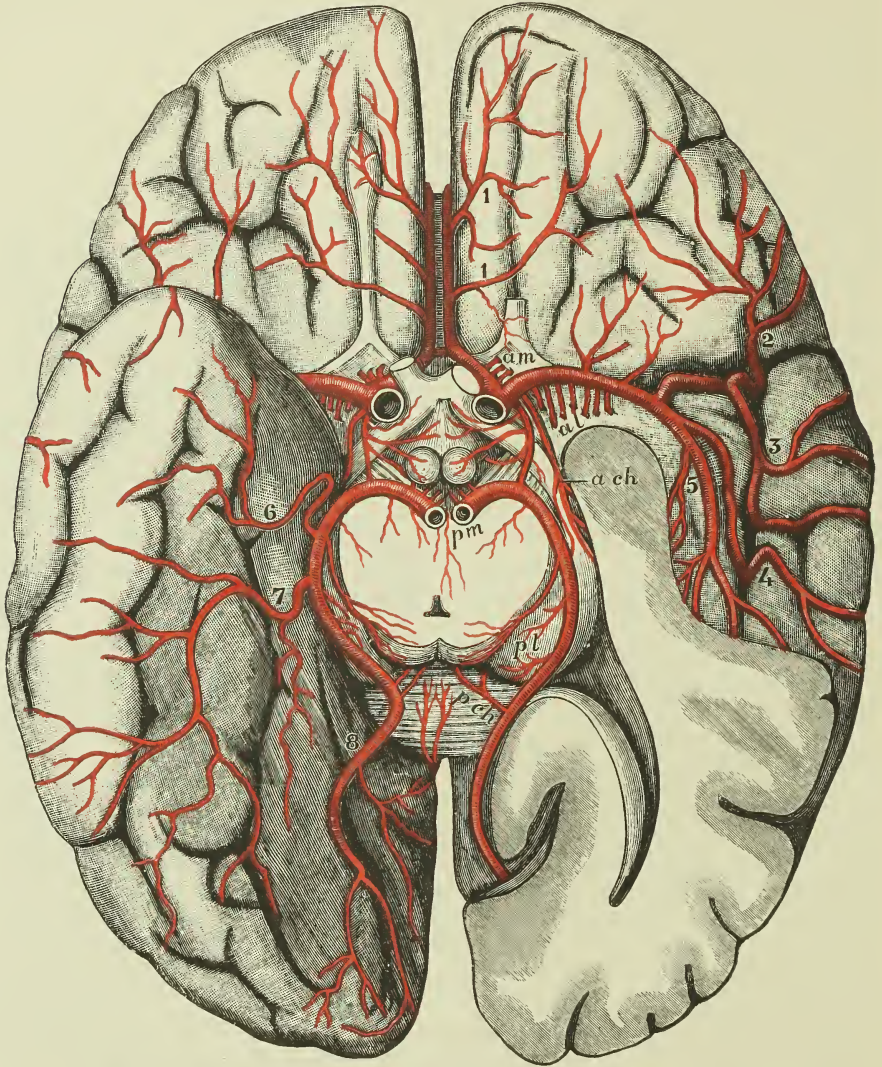

Fig. 136.—THE ARTERIES OF THE BASE OF THE CEREBRUM. (G. D. T., after Duret, and from nature.)

On the left side of the brain the temporal lobe is cut away so as to open the inferior and posterior horns of the lateral ventricle. The mid-brain is divided close above the pons and the posterior cerebral arteries are cut at their origin from the basilar.

*Central arteries* (to the basal ganglia): *am*, antero-mesial group arising from the anterior cerebral; *al*, antero-lateral group, from the middle cerebral; *pm*, *pl* (on the optic thalamus), postero-mesial and postero-lateral groups, from the posterior cerebral.

*Choroidal arteries*: *ach*, anterior, from the internal carotid; *pch* (on the splenium), posterior, from the posterior cerebral.

*Peripheral arteries*: 1, 1, inferior internal frontal, from the anterior cerebral; 2, inferior external frontal; 3, ascending frontal; 4, ascending parietal, and 5, temporo-parietal, from the middle cerebral; 6, anterior temporal, 7, posterior temporal, and 8, occipital, from the posterior cerebral.

anterior spinal, the vertebral, the basilar, and the posterior cerebral arteries. The branches enter the pons and medulla oblongata in two sets, lateral or radicular



(following the roots of the nerves), and median,—the latter passing in the raphe to the grey matter on the posterior surface. The valve of Vieussens and the superior peduncle of the cerebellum receive twigs from the superior cerebellar arteries. The choroid plexuses of the fourth ventricle are supplied by the inferior cerebellar arteries.

**Cerebellum.**—The *under surface* is supplied by the inferior cerebellar arteries from the vertebral, and the anterior from the basilar. The *upper surface* is supplied chiefly by the superior cerebellar arteries from the basilar: its posterior portion from the inferior cerebellar.

The **crura cerebri** derive their blood supply from the posterior communicating and the posterior cerebral arteries. Branches of the latter, and also others from the end of the basilar, enter the posterior perforated space.

The **corpora quadrigemina** and **corpora geniculata** are both supplied by the posterior cerebral artery, but branches of the superior cerebellar arteries pass to the inferior corpora quadrigemina.

The **optic thalamus** is supplied above and on the outer, inner and posterior

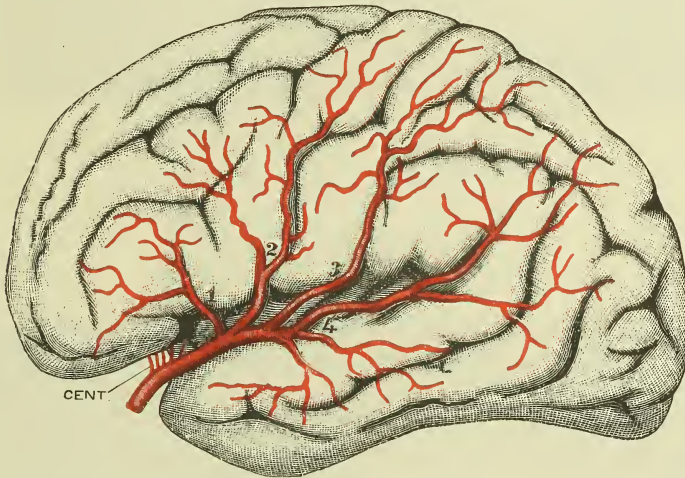


Fig. 137.—CORTICAL DISTRIBUTION OF THE MIDDLE CEREBRAL ARTERY. (G. D. T., after Charcot.)  
Diagrammatic.

CENT., antero-lateral group of central arteries: 1, inferior external frontal artery; 2, ascending frontal artery; 3, ascending parietal artery; 4, parieto-temporal artery.

sides by branches of the posterior cerebral artery, but its anterior and inner portion receives twigs from the posterior communicating arteries of the circle of Willis and its anterior and outer portion from the middle cerebral.

**Cerebral hemispheres.**—*Frontal lobe.*—The superior frontal and anterior two-thirds of the middle frontal convolution, with the upper extremity of the ascending frontal, are supplied by the anterior cerebral. The inferior frontal convolution, the posterior extremity of the middle frontal, and the greater part of the ascending frontal convolutions are supplied by the middle cerebral. The orbital surface is supplied, outside the orbital sulcus, by the middle cerebral: within that sulcus (including the olfactory bulb) by the anterior cerebral.

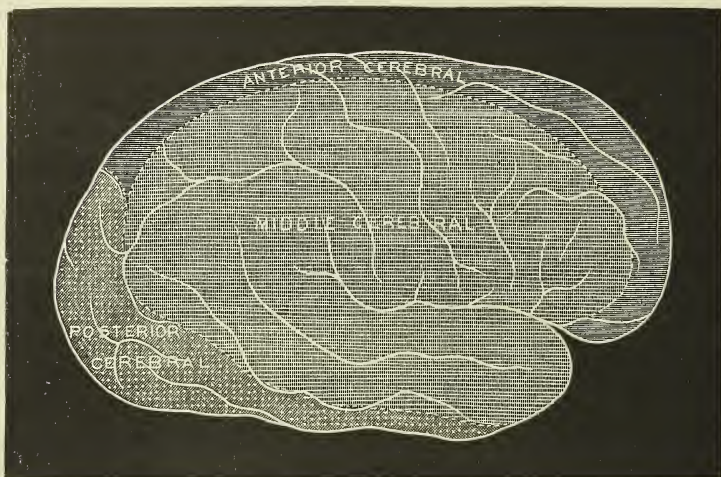
*Parietal lobe.*—All the convolutions of the parietal lobe are usually supplied by the middle cerebral artery.

*Occipital lobe.*—This lobe is supplied entirely by the posterior cerebral artery.

*Temporal lobe.*—The superior and upper parts of the middle temporal convo-



A



B

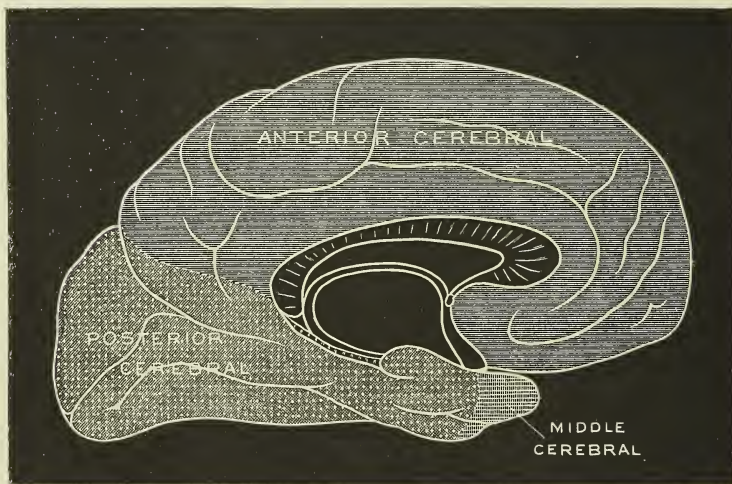


Fig. 138.—DIAGRAMS SHOWING THE AREAS OF CORTICAL DISTRIBUTION OF THE ANTERIOR, MIDDLE, AND POSTERIOR CEREBRAL ARTERIES RESPECTIVELY. (E. A. S.)

A, lateral ; B, mesial aspect ; C, basal aspect.

The area supplied by the middle cerebral frequently extends to the upper border of the hemisphere in the region of the parietal lobe, and therefore somewhat further than is represented in A.

lutions are supplied by the middle cerebral artery. The lower portion of the lobe by the posterior cerebral.

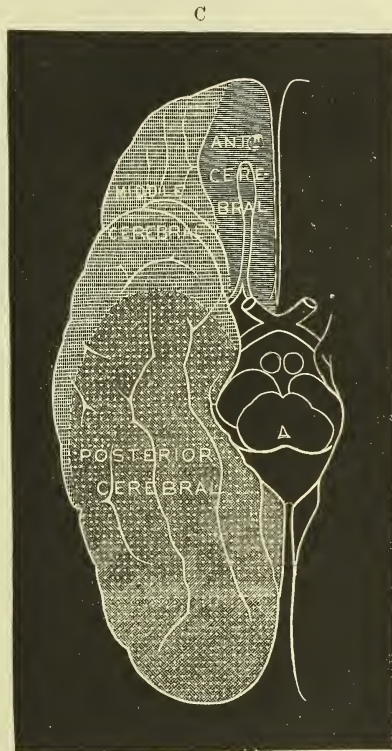
*Inner surface of the hemispheres.*—The whole anterior and upper portion, as far back as the parieto-occipital fissure, is supplied by the anterior cerebral artery; the cuneate lobule and the occipito-temporal region by the posterior cerebral.

The distribution of arteries to the several parts of the cerebral cortex is illustrated in the accompanying diagrams (fig. 138).

The *corpus callosum* is chiefly supplied by the anterior cerebral.

The *grey substance at the base* of the cerebrum is supplied by small twigs from the adjacent vessels of the circle of Willis, or from the roots of the cerebral vessels which pass off from the anastomosis.

*Central parts—corpus striatum.*—Both nucleus caudatus and nucleus lenticularis



are supplied almost exclusively by the middle cerebral artery, the numerous branches to these parts entering through the foramina in the anterior perforated space (fig. 136). They are divided by Duret into *lenticular*, *lenticulo-striate*, and *lenticulo-optic* (lenticulo-thalamic). These pass directly to their destination without anastomosing with one another, and traverse the zones of the lenticular nucleus and the internal capsule, to terminate finally in the caudate nucleus and optic thalamus (fig. 139). One in particular of the lenticulo-striate arteries which passes through the outer part of the putamen is very frequently the seat of hæmorrhage, and it has accordingly been termed by Charcot the "artery of cerebral hæmorrhage" (fig. 139, *x*).

The anterior part of the caudate nucleus is also supplied by the anterior cerebral,

and its upper surface receives fine twigs from the lateral choroidal branch of the posterior cerebral.

The *choroid plexuses of the lateral ventricles* are supplied (1) by the anterior choroid branch of the internal carotid which passes obliquely backwards and outwards, and enters the choroid plexus at the anterior end of the descending cornu, supplying two-thirds of the plexus of the lateral ventricle; (2) by the postero-lateral choroid artery, a branch of the posterior cerebral, which supplies the remaining third of the plexus. The *choroid plexus of the third ventricle* is supplied by a branch (postero-mesial) of the posterior cerebral. The *velum*

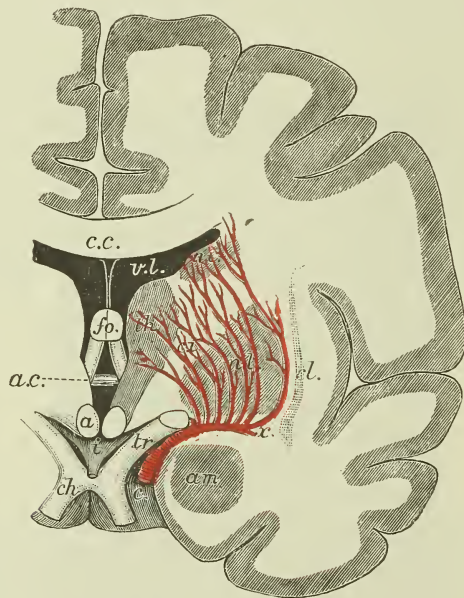


Fig. 139.—FRONTAL SECTION OF THE BRAIN, SHOWING THE MODE OF ORIGIN AND DISTRIBUTION OF THE LENTICULO-STRIATE AND LENTICULO-THALAMIC ARTERIES. (E. A. S.) Diagrammatic.

*c.c.*, corpus callosum; *fo.*, fornix; *a.c.*, anterior commissure; *a.*, corpus albicans; *i.*, infundibulum; *ch.*, chiasma; *tr.*, optic tract; *v.l.*, lateral ventricle; *n.c.*, nucleus caudatus; *n.l.*, nucleus lenticularis; *th.*, thalamus; *c.i.*, internal capsule; *cl.*, claustrum; *am.*, nucleus amygdalæ; above *x.*, artery of hæmorrhage. (The plan of the section is copied from Merkel.)

*interpositum* is also supplied by the two last-named branches of the posterior cerebral. The *parts in the quadrilateral space* at the base of the brain including the chiasma, the infundibulum and the corpora mamillaria receive branches directly from the circle of Willis.

For further details on the subject, which derives importance from the relation of different local pathological conditions to the vascular distribution, the reader is referred to a series of articles by Duret in the *Archives de Physiologie* for 1873 and 1874, to a paper by Huebner in the *Med. Centralblatt*, 1872; and to a work entitled "Die luetische Erkrankung der Hirnarterien," Leipzig, 1874, by the same author.

**Lymph-paths of the brain and spinal cord.**—Neither the brain nor the spinal cord possesses true lymphatic vessels. The lymph finds its way out of these organs by means of perivascular spaces in the tunica adventitia of the blood-vessels; these perivascular spaces communicate with the subarachnoid space at the surface of the brain and cord (Key and Retzius).



RECENT LITERATURE OF THE BRAIN.<sup>1</sup>

## GENERAL LITERATURE.

- Bastian, H. C.**, *The Brain as an organ of Mind*; and *Paralyses, cerebral, bulbar and spinal*, 1886.
- Dalton, J. C.**, *On the form and topographical relations of the corpus striatum*, Brain, vol. iii., 1880; *Topographical Anatomy of the Brain*, Atlas, 1882.
- Edinger, L.**, *Untersuchungen über die vergleichende Anatomie des Gehirns: I. Das Vorderhirn*; II. *Das Zwischenhirn*, Frankfurt-a.-M., 1892; *Zwölf Vorlesungen, &c.*, 3rd edition, 1892.
- Ferrier**, *The Functions of the Brain*, 2nd edition, 1886.
- Gavoy**, *L'encéphale, structure et description iconographique*, 1886.
- Gowers, W. R.**, *Diseases of the Nervous System*: Vol. I., *Diseases of the Spinal Cord*; Vol. II., *Diseases of the Brain*.
- Henle, J.**, *Handbuch der Nervenlehre*, Braunschweig, 1879.
- Hill, A.**, *The plan of the central nervous system*, Cambridge, 1885.
- Luys, J.**, *Recherches sur le système nerveux cérébro-spinal*, Paris, 1865; *Iconographie photographique des centres nerveux*, 2me édition, Paris, 1890.
- Mendel, Gehirn**, *Anatomisch*, Eulenburg's Real-Encyclop. der Gesammt. Heilkunde, vii., 1886.
- Meynert**, *Psychiatry*, translated by Sachs, 1885; *Article "Brain"* in Stricker's *Histology*, Sydenham Society's translation, vol. ii.
- Obersteiner, H.**, *The Anatomy of the Central Nervous Organs in health and in disease*, trans. by Alex. Hill, London, 1890, and German 2nd edition, 1892.
- Spitzka, E. C.**, *Architecture and Mechanism of the Brain*, Journ. of Nerv. and Ment. Diseases, 1878 et seq.
- Schwalbe, G.**, *Lehrbuch der Neurologie*, 1881.
- Testut, L.**, *Traité d'anatomie humaine. T. ii. fasc. 2. Neurologie*. Paris, 1891.
- Wernicke, C.**, *Lehrbuch der Gehirnkrankheiten*, vol. i., 1881.
- Wilder, B. G.**, *Article "Brain—Gross or Macroscopic Anatomy,"* Reference Handbook of the Medical Sciences, viii., 1889; and *"Malformations of Brain,"* Ibid.
- Wundt, W.**, *Grundzüge der physiologischen Psychologie*, Leipzig, 1880.

## SURFACE MORPHOLOGY OF THE HEMISPHERES.

- Bastian, H. C.**, and **Horsley, V.**, *Arrest of development of the upper limb in association with an extremely small right ascending parietal convolution*, Brain, vol. iii., 1880.
- Beer**, *On the development of the Sylvian fissure in the human embryo*, Journal of Anat. and Phys., 1890.
- Beevor, C. E.**, and **Horsley, V.**, *A minute analysis of cortical centres in the monkey*, Phil. Trans., 1887 and 1888.
- Benedikt, M.**, *Der Raubthierotypus am menschlichen Gehirne*, Vorläufige Mittheilung, Centralblatt für die medicinischen Wissenschaften, 1876; *Der Hinterhauptslappen der Säugethiere*, Ibid., 1877; *Anatomische Studien an Verbrecher-Gehirnen*, Wien, 1879; *Zur Frage des Vierwindungstypus*, Centralblatt f. d. med. Wissenschaften, 1880; *Beiträge zur Anatomie der Gehirn-Oberfläche*, Wiener Jahrbücher, 1888, s. 39; *Ueber die Fissura callosa-marginalis*, Verh. d. internat. Congress, Berlin, 1890, Bd. ii.; *Some points on the surface-anatomy of the brain*, Journ. of Anatomy, vol. xxv., 1891.
- Bischoff, Th. L. W.**, *Die Grosshirnwindungen des Menschen*, Abhandlungen der k. bayer. Akademie d. Wissensch., München, 1868; *Ueber das Gehirn eines Gorilla und die untere oder dritte Stirnwindung*, Sitzungsberichte der k. bayer. Akademie der Wissenschaften, München, 1877.
- Broca, A.**, *Anatomie descriptive des circonvolutions cérébrales*, Gaz. hebdom., T. xxxviii., 1891.
- Broca, P.**, *Anatomie comparée des circonvolutions cérébrales. Le grand lobe limbique et la scissure limbique dans la série des mammifères*, Revue d'anthropologie, 1878; *Recherches sur les centres olfactifs*, Ibid., 1879; *Description élémentaire des circonvolutions cérébrales de l'homme d'après le cerveau schématique*, Ibid., 1883 and 1884; *Mémoires sur le cerveau de l'homme et des primates*, Paris, 1888.
- Cunningham, D. J.**, *The complete fissures of the human cerebrum, and their significance in connection with the growth of the hemisphere*, Journ. of Anatomy and Physiology, xxiv., 1890; *On cerebral anatomy*, Brit. Med. Journ., Aug., 1890; *The surface anatomy of the primate cerebrum*, Cunningham Memoirs of the Royal Irish Academy, No. VII., 1892.
- Debierre, C.**, *Sur les anomalies des circonvolutions du cerveau de l'homme*, Comptes rendus de la société de biologie, 1891.
- Dercum**, *A note on the "pli de passage inférieur interne" in the human brain*, Journ. of nerv. and mental disease, 1889; *A description of two Chinese brains*, Ibid.
- Donaldson, H. H.**, *Nervous System. Report of 6 lectures on cerebral localization delivered in Boston*, Amer. Journ. of Psychol., vol. iv., 1891.
- Duval, M.**, *La corne d'Ammon*, Arch. de neurol., 1881-2.
- Dwight, T.**, *Remarks on the brain of a distinguished man*, Proc. Amer. Acad., vol. 13, 1887.

<sup>1</sup> For literature of Cerebellum, see p. 95; for Mid-brain and Interbrain, see p. 120.

- Eberstaller, O.**, *Zur Oberflächenanatomie der Grosshirn-Hemisphäre*, Wiener med. Blätter, 1884; *Zur Anatomie u. Morphol. der Insula Reilii*, Anat. Anz. ii., 1887; *Das Stirnhirn*, &c., 1890.
- Ecker, A.**, *Die Hirnwindungen des Menschen*, Braunschweig, 1869 and 1883.
- Fraser, A.**, *A guide to operations on the brain*, London, 1891.
- Giacomini, C.**, *Variétés des circonvolutions cérébrales chez l'homme*, Arch. ital. de biologie, t. i., 1882; *Benderella dell' uncus dell' hippocampo*, &c., Giorn. d. R. acad. d. Torino, 1882, and in Arch. ital. de biologie, t. ii., 1882; *Fascia dentata del grande hippocampo*, Ibid.; *Varietà d. circonvol. cerebrali nell'uomo*, 1884; *Guida allo studio delle circonvoluzioni cerebrali dell'uomo*, 1884 and 1891; *Sur le cerveau d'un Chimpanzé*, Arch. ital. de biologie, vol. 3, 1890, and in Atti d. R. acad. d. sci. di Torino, 1889; *Les cerveaux des microcéphales (avec 1 pl.)*, Arch. ital. de Biol., t. 15, 1891; *I cervelli dei microcefali*, Torino, 1890.
- Gowers, W. R.**, *The brain in congenital absence of one hand*, Brain, vol. i., 1878.
- Gratiolet, Mémoire sur les plus cérébraux de l'homme et des primates, Paris, 1854.**
- Guldberg, Bidrag til Insula Reilii's Morphologie, Christiania, 1887, and Anat. Anzeiger, 1887.**
- Hatch, J. Leffingwell**, *Some studies upon the Chinese Brain*, Intern. Monatsschr. f. Anat. u. Phys., Bd. viii., 1891.
- Hervé, La circonvolution de Broca, Thèse, Paris, 1888.**
- Heschl, Die Tiefenwindungen d. menschl. Gehirns, &c.**, Wiener med. Wochenschr., 1877; *Ue. d. vordere quere Schläfenwindung*, Wien, 1878.
- Horsley, V., and Schäfer, E. A.**, *A record of experiments upon the functions of the cerebral cortex*, Phil. Trans., vol. 179, 1888.
- Howden, R.**, *Variations in the hippocampus major and eminentia collateralis in the human brain*, Journ. of Anat. and Phys., xxi., 1888.
- Huxley, T. H.**, *On the brain of Ateles paniscus*, Proc. Zool. Soc., 1861.
- Jelgersma, G.**, *Ueber den Bau des Säugethiiergehirns*, Morph. Jahrb., 1888; *Das Gehirn ohne Balken, ein Beitrag zur Windungstheorie*, Neurol. Centralbl. ix., 1890.
- Jensen, J.**, *Die Furchen und Windungen der menschlichen Grosshirn-Hemisphären*, Zeitsch. f. Psychiatrie, 1871.
- Kowalewsky, P.**, *Das Verhältniss des Linsenkerns zur Hirnrinde*, Sitzungsber. d. Wiener Akad. d. Wiss., Bd. 86.
- Lussana, Ph.**, *Circumvolutionum cerebralium anatomes humana et comparata*, Editio 2da. Patavii, 1888.
- Marchand, F.**, *Beschreibung dreier Microcephalen-Gehirne, &c.*, Nova acta k. Leop. Carol. Akad., 1889 and 1890; *Ueber Microcephalie mit bes. Berücksichtigung der Windungen des Stirnlappens u. der Insel*, Marburg Sitzungsber., 1892.
- Marshall, J.**, *On the brain of a Bushwoman, &c.*, Phil. Trans., vol. 154.
- Mendel, E.**, *Ueber die Affenspalte*, Neurol. Centralbl., 1883.
- Mingazzini, G.**, *Ueber die Entwicklung der Furchen und Windungen des menschlichen Gehirns*, Moleschott's Untersuchungen, Bd. 13, 1888.
- Pansch, A.**, *Die Furchen und Wülste am Grosshirn des Menschen*, Berlin, 1879; *Ueber die typische Anordnung der Furchen und Windungen auf den Grosshirn-Hemisphären des Menschen und der Affen*, Archiv für Anthropologie, 1869, Bd. III.
- Parker, A. J.**, *Cerebral convolutions of the negro*, Proc. of the Philadelphia Academy, 1878.
- Passet, Ueber einige Unterschiede des Grosshirns nach dem Geschlecht, Archiv für Anthropologie, 1883.**
- Pitres, A.**, *Sur les atrophies partielles des circonvolutions cérébrales, consécutivement aux amputations, &c.*, Gaz. méd., 1877.
- Retzius, G.**, *Notiz ü. d. Windungen an der unteren Fläche des Splenium corporis callosi*, Arch. f. Anat., 1877.
- Richter, Ueber d. Entstehung d. Grosshirnwindungen, Arch. f. path. Anat., 1887.**
- Rohon, J. V.**, *Zur Anatomie der Hirnwindungen bei den Primaten*, München, 1884.
- Rüdinger, N.**, *Vorläufige Mittheilungen über die Unterschiede der Grosshirnwindungen nach dem Geschlecht beim Fötus und Neugeborenen, mit Berücksichtigung der angeborenen Brachycephalie und Dolichocephalie*, München, 1877; *Ein Beitrag zur Anatomie der Affenspalte und der Interparietalfurche beim Menschen nach Race, Geschlecht und Individualität*, 1882; *Ein Beitrag zur Anatomie des Sprachencentrums*, 1882.
- Schnopfhagen, F.**, *Die Entstehung der Windungen des Grosshirns*, Jahrb. d. Psych., ix., 1891.
- Seitz, J.**, *Zwei Feuerländer-Gehirne*, Zeitschrift f. Ethnologie, Berlin, 1886.
- Tenchini, Sopra alcune varietà della scissura di Rolandi, Rivista sperimentale di freniatria, &c., 1883.**
- Trolard, De l'appareil nerveux central de l'olfaction, Arch. de neurol., 1890, 1891.**
- Turner, W.**, *The convolutions of the human cerebrum*, Edinburgh, 1866; *A human cerebrum imperfectly divided into two hemispheres*, Journal of Anatomy, 1878; *The convolutions of the brain*, Verh. d. internat. Congress, Berlin, 1890, Bd. ii., and Journal of Anat. and Phys., vol. xxv., 1890; *Human cerebrum with a remarkably modified fronto-parietal lobe*, Journal of Anatomy, vol. xxv., April, 1891.
- Valenti, G.**, *Contributo allo studio delle scissure cerebrali*, Soc. toscana di sc. nat., vol. xi., 1891.
- Vanhersecke, G.**, *La morphologie des circonvolutions cérébrales*, Lille, 1891.
- Waldeyer, Die Hirnwindungen des Menschen, Verh. d. internat. Congress, Berlin, 1890; *Das Gibbon-Hirn*, Virchow-Festschrift, 1891; *Ueber die "Insel" des Gehirns der Anthropoiden*, Corr.-Bl. d. deutsch. Gesellsch. f. Anthrop., 1891.**



**Weisbach, A.**, *Die Supraorbital-windungen des menschlichen Gehirns*, Wien. med. Jahrb., 1870.  
**Wilder, Burt G.**, *Human cerebral fissures, their relations and names and the methods of studying them*, American Naturalist, October, 1886; *The Paroccipital, a newly recognized fissural integer*, Journal of Nervous and Mental Disease, vol. xiii., 1886; *The morphological importance of the membranous or other thin portions of the parietals of the encephalic cavities*, Journ. of Comp. Neurol., 1891.

**Zilgien**, *Étude d'un cerveau sans circonvolutions chez un enfant de onze ans et demi*, Journal de l'Anatomie et de la Physiologie, 1891.

**Zuckerkindl, E.**, *Beiträge zur Anatomie des menschlichen Körpers, IV. Ueber den Einfluss des Nahtwachstums u. der Schädelform auf die Richtung der Gehirnwindungen; V. Ueber Defecte an der Sprachwindung nebst einigen Bemerkungen zur normalen Anatomie dieses Windungszuges*, Wiener medicinische Jahrbücher, 1883; *Ueber das Riechcentrum*, Stuttgart, 1887.

## COURSE OF WHITE TRACTS AND COMMISSURES.

**Bechterew, W. v.**, *Zur Frage ü. d. äusseren Associationsfasern der Hirnrinde*, Neurol. Centralbl., 1891.

**Beevor, C. E.**, and **Horsley, V.**, *Arrangement of the excitable fibres in the internal capsule of the Bonnet monkey*, Phil. Trans., 1890.

**Beevor, C. E.**, *On the course of the fibres of the cingulum, and the posterior parts of the corpus callosum and fornix in the Marmoset monkey*, Phil. Trans., 1891.

**Bruce, A.**, *On the absence of the corpus callosum in the human brain*, Proc. Roy. Soc. of Edinburgh, and Brain, 1889 (contains earlier literature of subject).

**Dejerine**, *Contribution à l'étude de la dégénérescence des fibres du corps calleux*, Soc. de Biologie, Bull. médical, 1892.

**Edinger, L.**, *Zur Kenntniss des Faserverlauf im Corpus striatum*, Neurol. Centralbl., 1884.

**Flechsig, P.**, *Die Leitungsbahnen im Gehirn u. Rückenmark*, Leipzig, 1876; *Plan des menschl. Gehirns*, Leipzig, 1883.

**France, E. P.**, *On the descending degenerations which follow lesions of the gyrus marginalis and the gyrus fornicatus in monkeys*, Phil. Trans., vol. 180, B., 1889.

**Ganser**, *Ueber die vordere Hirncommissur der Säugethiere*, Arch. für Psychiatrie, vol. ix., 1878.

**Gudden, B. v.**, *Gesammelte und hinterlassene Arbeiten*, 1889.

**Hamilton, D. J.**, *On the corpus callosum in the adult brain*, Journal of Anatomy, vol. xix., 1885; *On the corpus callosum in the embryo*, Brain, 1885.

**Honegger, S.**, *Vergleichend-anatom. Untersuchungen über den Fornix, etc.*, Zurich, 1891.

**Hösel (u. Flechsig)**, *Die Centralwindungen ein Centralorgan der Hinterstränge*, Neurol. Centralbl., 1891.

**Langley and Grünbaum**, *On the degenerations resulting from removal of the cerebral cortex and corpora striata in the dog*, Journ. of Physiol., 1891.

**Luys**, *Nouvelles recherches sur la structure du cerveau et agencement des fibres blanches cérébrales*, L'Encéphale, 1884.

**Popoff**, *Zur Frage vom Ursprungsgebiete der Fasern der vorderen Commissur*, Neurol. Centralbl., 1886.

**Sachs, H.**, *Das Hemisphärenmark des menschlichen Grosshirns, I. Der Hinterhauptlappen*, Leipzig, 1892.

**Sherrington**, *Nerve tracts degenerating secondarily to lesions of the cortex cerebri*, Journ. of Physiology, 1890; *Further note on degenerations following lesions of the cerebral cortex*, Journ. of Physiol., 1890.

**Zacher**, *Beitr. z. Kenntniss des Faserverlaufs im Pes Pedunculi, sov. ü. d. corticalen Beziehungen d. Corpus genic. int.*, Arch. f. Psych., Bd. 22.

**Zuckerkindl**, *Ue. d. Riechbündel des Cornu Ammonis*, Anat. Anzeiger, iii., 1888.

## MINUTE STRUCTURE.

**Berkley, H. J.**, *The medullated cortical fibres, etc.*, Medical Record, New York, 1892.

**Betz**, *Ueber die feinere Struktur d. menschl. Gehirnrinde*, Med. Centralbl., 1881.

**Blumenau, L.**, *Zur Entwickl. u. feineren Anatomie des Hirnbalkens*, Arch. f. mikr. Anat., Bd. 37, 1891.

**y Cajal, S. R.**, *Sobre la existencia de células nerviosas especiales en la primera capa de las circunvoluciones cerebrales*, Gaceta catal., Barcelona, 1890; *Textura de las circunvoluciones cerebrales de los mamíferos inferiores*, Gaceta sanitaria, Barcelona, 1890; *Estructura fund. de la corteza cerebral de los batracios reptiles y aves*, Trabajos del laboratorio histológico, Barcelona, 1891; *Sur la structure de l'écorce cérébrale de quelques mammifères*, La Cellule, tom. vii., 1891.

**Conil, C.**, *Des résultats obtenus par la méthode de Golgi appliquée à l'étude du bulbe olfactif*, Mém. de la soc. de biologie, 1892.

**Exner**, *Zur Kenntniss vom feineren Bau der Grosshirnrinde*, Wiener Sitzungs., Bd. 83, 1881.

**Geluchten, v.**, et **Martin**, *Le bulbe olfactif chez quelques mammifères*, La Cellule, t. vii., 1892.

**Golgi**, *Sulla fina struttura d. bulbi olfattori*, 1875; *Origine du tractus olfactorius et structure des lobes olfactifs*, Arch. ital. de biologie, t. i., 1882; *Sulla fina anatomia degli organi centrali del sistema nervoso*, Rivista sperim. di freniatria, 1883.



- Kölliker, v.**, *Ue. d. feineren Bau des Bulbus olfactorius*, Sitzungsber. d. Würzburg phys.-med. Gesellschaft, 1892.
- Lewis, Bevan**, *On the comparative structure of the cortex cerebri*, Brain, vol. i., 1878.
- Lewis, Bevan, and Clarke**, *On the cortical lamination of the motor area of the Brain*, Proc. Roy. Soc., 1878.
- Major, H. C.**, *Histology of the Island of Reil*, West Riding Asylum med. Reports, vol. vi.; and Monthly Microsc. Journal, 1877.
- Marchi**, *Sulla fina anatomia dei corpi striati*, Rivista sperim. di freniatria, &c., 1883.
- Martinotti, C.**, *Beitrag z. Studium d. Hirnrinde u. d. Centralursprung der Nerven*, Monthly Int. Journ. of Anatomy and Physiology, vii., 1890.
- Meynert, Th.**, *Article "Brain,"* in Stricker's Histology, 1872.
- Richet, C.**, *Structure des circonvolutions cérébrales*, Paris, 1878.
- Sala, L.**, *Zur feineren Anatomie des grossen Scepfendefusses*, Zeitsch. f. wiss. Zool., Bd. 52, 1891; *L'anatomie fine de la fascia dentata Tarini*, Verhandl. d. x. internat. med. Congresses, Berlin, 1890.
- Schaffer, K.**, *Beitrag zur Histologie der Ammonshornformation*, Arch. f. mikr. Anat., xxxix., 1892.
- Spitzka, E. C.**, *Article "Brain, Histology,"* Ref. Handbook of the Medical Sciences, viii., 1889.
- Valpius, O.**, *Ue. d. Entwickl. u. Ausbreitung der Tangentialfasern in der menschlichen Grosshirnrinde*, Arch. f. Psych., Bd. 23, 1892.
- Weigert**, *Bemerkungen ü. d. Neurogliaegerüst*, Anat. Anzeiger, 1890.

## BRAIN-MEASUREMENTS.

- Baistrocchi**, *Sul peso specifico dell'encefalo umano, &c.*, Rivist. sperim. di frenatr., 1884.
- Bastian, H. C.**, *Ue. d. specif. Gewicht verschiedener Theile d. menschl. Gehirns*, Arch. f. Heilkunde, 1866.
- Bischoff, Th. L. W. v.**, *Das Hirngewicht des Menschen*, 1880.
- le Bon, G.**, *Recherches sur les lois des variations du volume du cerveau, &c.*, Revue d'Anthropol., 1879.
- Braune, Wilh.**, *Das Gewichtsverhältniss der rechten zur linken Hirnhälfte beim Menschen*, Archiv für Anat., 1891.
- Buchstab**, *Beitr. z. Frage v. d. Gewichts- u. Grössenverhältnissen des Gehirns*, Abstr. in Neurol. Centralbl., 1885 (from a Russian dissertation, 1884).
- Calori**, *Del cervello nei due tipi brachicephalo e dolichocephalo italiani*, Bologna, 1875.
- Clapham, C.**, *On the weight of the brain in the insane*, West Riding Asylum Medical Reports, vols. iii. and vi.; *The brain-weights of some Chinese and Pelew Islanders*, Journ. of the Anthropol. Institute, 1878.
- Conti, A.**, *De l'épaisseur de l'écorce du cerveau humain*, Internationale Monatsschrift für Anatomie u. Physiologie, vol. i., 1884.
- Crichton-Browne, J.**, *On the weight of the brain and its component parts in the insane*, Brain, vols. i and 2, 1879.
- Danilewsky, B.**, *Die quantitativen Bestimmungen der grauen und weissen Substanzen im Gehirn*, Centralblatt f. d. medicinischen Wissensch., 1880.
- Davis, B.**, *Contributions towards determining the weight of the brain in different races of man*, Phil. Trans., 1869.
- Donaldson, H. H.**, *Anatomical observations on the brain and sense organs of the blind deaf-mute Laura Bridgman*, Journal of Psychology, vols. 3 and 4, 1890 and 1891.
- Huschke, E.**, *Schädel, Hirn und Seele des Menschen und der Thiere nach Alter, Geschlecht und Race*, 1854.
- Jensen, J.**, *Untersuchungen über die Beziehungen zwischen Grosshirn und Geistesstörung an sechs Gehirnen geisteskranker Individuen*, Archiv f. Psychiatrie, vol. v., 1875; *Unters. ü. 453 nach Meynert's methode getheilten u. gezogen Gehirnen, &c.*, Ibid., xx., 1889.
- Krause, W.**, *Ueber Gehirngewichte*, Allgem. Wiener med. Zeit., 1888, and Internat. Monatschr. f. Anat. u. Phys., V., 1888.
- Major, H. C.**, *A new method of determining the depth of gray matter of the cerebral convolutions*, West Riding Lunatic Asylum Med. Reports, 1872.
- Manouvrier**, *De la quantité dans l'encéphale*, Mém. de la société de l'anthropologie, t. iii., 1888.
- Marshall, J.**, *Relations between the weight of the brain and its parts and the stature and mass of the body in man*, Journal of Anatomy and Physiology, July, 1892; *The brain of the late George Grote, with comments and observations on the human brain and its parts generally*, Ibid., Oct., 1892.
- Meynert, Th.**, *Das Gesamtgewicht u. die Theilgewichte des Gehirnes, &c.*, Vierteljahrsschr. f. Psych., 1867; *Ue. d. Methode der Gehirnwägungen*, Mittheil. d. Wiener anthropol. Gesellsch., Bd. 1, 1870.
- Mercier, A.**, *On the weight of the brain in the insane with reference to the hemispheres, lobes, brain-stem and cerebellum*, Journ. Mental Sc., vol. xxxvii., 1891.
- Paulier, A. B.**, *Recherches sur la notion de surface en anatomie. Determination de la surface du cerveau, &c.*, 1892.
- Snell, O.**, *Die Abhängigkeit des Hirngewichts von dem Körpergewicht und den geistigen Fähigkeiten*, Archiv f. Psychiatrie, Bd. xxiii., 1891; *Das Gewicht des Gehirnes, &c.*, Münchener medic. Wochenschr., 1892.
- Topinard**, *Le poids de l'encéphale*, Mém. de la société de l'anthropologie, t. iii., 1888.
- Vierordt, H.**, *Anatomische, physiologische und physikalische Daten und Tabellen*, 1888.

- Wagner, H.**, *Maassbestimmungen der Oberfläche des grossen Gehirns*, Inaug. Diss., Göttingen, 1864.  
**Wagner, R.**, *Vorstudien zu einer wissenschaftlichen Morphologie und Physiologie des menschlichen Gehirns als Seelenorgan*, 1860, 1862.  
**Weisbach, A.**, *Die Gewichtsverhältnisse d. Gehirns österreichischer Völker*, Arch. f. Anthrop., I., 1886.

## MEMBRANES AND VESSELS OF THE BRAIN AND CORD.

- Adamkiewicz, Albert**, *Die Blutgefässe des menschlichen Rückenmarkes ; I. Theil : Die Gefässe der Rückenmarkes-Substanz*, Sitzungsberichte der k. Akad. d. Wiss. in Wien, Bd. lxxxiv., 3 Abth., 1881 ; *II. Theil : Die Gefässe der Rückenmarkes-Oberfläche*, Ibid., Bd. lxxxv., 3 Abth., 1882 ; *Die Arterien des verlängerten Markes*, Denkschr. d. Wiener Akademie, 1890.  
**Browning**, *The veins of the brain and its envelopes*, Brooklyn, 1884 ; *Article "Vessels of the Brain,"* Ref. Handbook of the Medical Sciences, viii., 1889 ; *The arrangement of the supracerebral veins in man, as bearing on Hill's theory of a developmental rotation of the brain*, Journal of Nervous and Mental Diseases, vol. 18, 1891.  
**Duret, H.**, *Sur la distribution des artères nourricières du bulbe rachidien*, Archives de Physiologie, 1873 ; *Recherches anatomiques s. l. circulation de l'encéphale*, Ibid. 1874.  
**Hédon, E.**, *Étude anatomique sur la circulation veineuse de l'encéphale*, Thèse, 1888 ; abstract in International Monthly Journal of Anatomy and Physiology, 1889.  
**Huebner**, *Zur Topographie der Ernährungsgebiete d. einzelnen Hirnarterien*, Centralbl. f. d. med. Wissen., 1872 ; *Die luetiche Erkrankung der Hirnarterien*, Leipzig, 1874.  
**Kadyi, H.**, *Ueber die Blutgefässe des menschlichen Rückenmarkes*, 1889.  
**Key u. Retzius**, *Studien in der Anatomie des Nervensystems*, Stockholm, 1876.  
**Kolisko**, *Ue. d. Beziehung d. art. chor. ant. zum hinteren Schenkel der inneren Kapsel*, Wien, 1891.  
**Labbé, C.**, *Note sur la circulation veineuse du cerveau*, Archives de Physiologie, 1879 ; *Étude sur les granulations de Pacchioni, &c.*, Thèse, Paris, 1882.  
**Mierzejewsky, J.**, *Die Ventrikel des Gehirns*, Centralbl. f. d. med. Wissensch., 1872.  
**Ross, James**, *Distribution of the Arteries of the Spinal Cord*, Brain, April, 1880.  
**Roszbach u. Lehrwald**, *Ueber die Lymphwege des Gehirns*, Centralbl. f. d. med. Wissensch., 1888.  
**Sée, M.**, *Sur la communication des cavités ventriculaires de l'encéphale avec les espaces sous-arachnoïdiens*, Revue mensuelle, 1878 & 1879.  
**Sperino, G.**, *Circolazione venosa del capo*, Torino, 1884.  
**Symington, J.**, *On the valvular arrangements in connection with the cranial venous circulation*, Brit. Med. Journal, 1882.  
**Trolard**, *Recherches sur l'anatomie du système veineux de l'encéphale et du crâne*, Thèse, 1868, and in Archives générales de médecine, 1870 ; *Les granulations de Pacchioni*, Journ. de l'anatomie et de la physiol., t. 28 ; *De quelques particularités de la dure-mère*, Ibid., 1890.  
**Valenti, G., e Abundo, G.**, *Sulla vascularizzazione cerebrale, &c.*, Atti d. soc. toscana di sci. natur., vol. xi., 1890.  
**Windle, B. C. A.**, *On the arteries forming the circle of Willis*, Journ. of Anat. and Phys., xxi., 1888.

## ADDENDUM TO LITERATURE OF SPINAL CORD. (See pp. 34 to 37.)

- Sherrington, C. S.**, *Notes on the arrangement of some motor fibres in the lumbo sacral plexus. Section IV. Relation of the limb to cell-groups in the spinal cord*, Journal of Physiology, vol. xiii., No. 6, 1892.





# INDEX AND GLOSSARY TO VOL. III. PART I.

- ABDUCENT NERVE. *See* NERVE, SIXTH.  
 Aberrant bundle of medullary striæ, 50  
 Accessory auditory nucleus, 55, 60  
     cuneate nucleus, 53  
     flocculi, 76  
     nucleus, 20, 55  
     olivary nuclei, 57  
     vagal nucleus, 55  
 Acervulus cerebri (dim. of *acervus*, heap), 114  
 Acoustic tubercle, 50  
 Affenspalte (German, ape-fissure), 143, 150, 151  
 Age, influence of on brain-weight, 178, 180  
 Ala cinerea (grey wing), 50  
     lobuli centralis, 71, 73, 82  
 Algieri on tracts of Burdach, 32  
 Alveus (trough), 158, 172, 173  
 Amygdala cerebelli (*amygdala*, tonsil), 74, 76, 82  
 Amygdaloid nucleus, 124, 131, 135, 160, 169  
 Amygdalo-uvular lobe, 76  
 Angle, Rolandic, 143  
     Sylvian, 142  
 Angular gyrus, 151, 153  
 Annectent (connecting) gyri, 143, 144, 145, 146,  
     147, 148, 149, 150, 151, 152, 153, 156  
 Ansa (loop) lenticularis, 103, 112, 114, 135, 164  
     peduncularis, 112  
 Anterior column of cord, 9, 12, 22, 65  
     commissure of brain, 38, 98, 131, 135, 156,  
         160, 164  
         of cord, 6, 7, 10, 18  
     marginal bundle, 25  
     pillars or columns of fornix, 97, 113, 116,  
         129, 131, 158  
     pyramidal tract, 24, 31, 32, 45  
     roots of spinal nerves, 19, 32, 94  
 Antero-lateral ascending tract, 24, 25, 32, 34,  
     65, 85, 103, 104  
     descending tract, 24, 25, 32, 86, 93, 94  
     ground bundle, 26, 32  
     white columns, 9, 24, 31, 32, 64, 86, 95, 104  
 Apex cornu posterioris, 8  
 Aqueduct, nucleus of, 65  
     Sylvian, 96  
         central grey matter, 96, 98  
         epithelium of, 96  
 Arachnoid (*ἀράχνη*, spider or spider's web) mem-  
     brane, 1, 3, 137, 181, 187  
 Arachnoidal villi (*villus*, tuft of hair), 184, 190  
 Arbor vitæ (from resemblance to shrub so  
     called) cerebelli, 71, 74, 76, 78  
 Arched or arcuate fibres, external or superficial,  
     44, 45, 58, 59  
     internal or deep, 53,  
         58, 93, 95, 104  
 Arcuate sulci of cerebellum, anterior, middle  
     and posterior, 75, 77  
 Area of Broca, 159, 160  
 Areas of medulla oblongata, anterior, 43, 45  
     lateral, 43, 45  
     posterior, 41, 43  
 Arteries, cortical, 193  
     of dura mater, 184  
     lenticular, 197  
     lenticulo-optic (lenticulo-thalamic), 197  
     lenticulo-striate, 197  
     medullary, 193  
     of spinal cord, 191  
 Arterioles, central, 192  
 Artery of "cerebral hæmorrhage," 197  
 Ascending auditory fibres, 63  
     cerebellar tract. *See* CEREBELLAR TRACT.  
     degeneration, 24, 27  
     frontal gyrus, 148, 163  
     parietal gyrus, 143, 148, 150, 151, 163  
     root of fifth nerve, 52, 63  
     tracts, 25, 26  
 Association-bundle, anterior, 165  
     inferior, 165  
     superior, 165  
     fibres, 158, 163, 165, 169  
         of cerebellum, 84  
 Auditory nerve. *See* NERVE.  
     nucleus, 104, 106  
         accessory, 55, 60  
         inner or dorsal, 56, 62  
         outer or superior, 56, 62  
         ventral, 56, 63  
         connections of, 103, 104, 106  
 Auerbach on degeneration in spinal cord, 34  
 Australians, brain-weight of, 180  
 Axis, cerebro-spinal, 1  
  
 BAILLARGER on grey cortex, 177  
     lines of, outer and inner, 167  
 Band, furrowed, 76  
 Basal ganglia, 163, 172  
     optic ganglion, 116, 120  
 Basis pedunculi, 100  
 Basket cells, 89, 91  
 Bechterew on connections of upper olive, 60  
     fillet, 65  
 Beever on cingulum, 158  
     fornix, 129  
     lyra, 131  
 Bellonci on optic lobes of birds, 107  
 Benedikt on brain of criminals, 161  
 Bergmann's fibres, 87  
 Bigeminal bodies, 106  
 Birds, cerebellum of, 69  
     optic lobes of, 107  
 Bischoff on brain-weight, 178  
 Biventral lobe of cerebellum, 74, 76, 82  
 Blood-vessels of brain and cord, 191  
 Bochdalek on nerves of arachnoid, 189  
 Body of fornix, 129, 158  
 Body-weight, relation of brain-weight to, 178  
 Bordering gyrus, 159  
 Borders of cerebral hemisphere, 137  
 Boyd on brain-weight, 178

- Brachial enlargement of cord, 5  
 Brachium conjunctivum (connecting arm), 103  
   of quadrigeminal body, 105, 110, 111, 117  
 Brachycephalic (*βραχύς*, short; *κεφαλή*, head)  
   persons, brains of, 176, 177  
 Brain, 1, 38. *See also* CEREBRUM, CEREBELLUM, PONS, and MEDULLA OBLONGATA.  
   blood-vessels of, 191, 193  
   commissures of, 1, 38  
   dimensions of, 176  
   divisions of, 38  
   literature of, 199  
   lymphatics of, 198  
   measurements of, 176  
   membranes of, 1, 181  
   ventricles of, 38, 47, 96, 97, 122, 188, 189  
   weight of, 178  
 Brain-sand, 114  
 Broca, area of, 159, 160  
   on brain-weight, 178  
   on grande lobe limbique, 155  
 Bulb. *See* MEDULLA OBLONGATA.  
   of fornix, 115  
   olfactory, 145, 159, 174, 195  
   of posterior horn of lateral ventricle, 124  
 Bulbus rhachiticus (*ράχης*, backbone), 38  
 Bundle, olfactory, of cornu Ammonis, 158  
   posterior longitudinal, 58, 65, 66, 86, 93, 94, 95, 99, 102, 109, 114, 119  
 Burdach, tract of, 26, 28, 32, 44
- CACUMINATE (*cacumen*, tip) lobe, 74, 77, 82  
 Cajal on collateral fibres, 21  
   on moss-fibres, 91  
   on optic lobes of birds, 107  
   on spongioblasts and neuroblasts, 14  
   on zone of superficial granules, 92  
 Calamus scriptorius (writing pen), 47  
 Calcar avis (bird's spur), 124, 144  
 Calcarine fissure, 124, 143, 144, 172  
   posterior, 144  
 Callosal fissure or sulcus, 127, 156  
   gyrus, 155, 156, 158, 160  
 Calloso-marginal fissure, 145, 146, 148  
 Calori on grey cortex, 177  
 Canal, central of cord, 9, 10, 19  
 Capsule, external, 134, 135, 164  
   internal, 100, 101, 104, 111, 114, 119, 128, 131, 132, 133, 135, 136, 163, 166, 169, 172, 197  
 Caput cornu (head of horn), 8, 51, 52  
 Cat, ganglion cells of anterior nerve-roots of, 3  
   pyramidal tract of, 25  
 Cauda equina (horse's tail), 3  
 Caudate (*cauda*, tail) nucleus, 124, 131, 134, 135, 136, 197  
 Causation of gyri and sulci, 162  
 Cavum (a hollow) Meckelii, 182  
 Cell-columns of cord, 14  
   of anterior horn, 14  
   Clarke's, 16, 34, 86  
   lateral, 16  
   middle, 17  
   of posterior horn, 17  
   posterior vesicular, 16  
 Cells, degeneration of, 24  
   of Deiters, 13  
   outlying, 17  
   solitary, 17
- Central arterioles, 192  
   canal of cord, 9, 10, 19  
   grey matter of mid-brain, 65, 96, 98  
   gyri, 143, 148, 149, 150  
   ligament of cord, 2, 5  
   lobe of cerebral hemisphere, 133, 135, 145, 154, 177  
   cerebellum, 71, 73, 77  
   nucleus, oculomotor, 99  
   sulcus, 143  
   tract of tegmentum, 60  
   venules, 193  
 Centre, medullary, of cerebral hemisphere, 163  
 Centres, kinæsthetic, 163  
   psychomotor, 163, 172  
   for special senses, 163  
   visual, connection with cord and bulb, 119  
   inter-connection of, 119  
   connection with oculomotor nuclei, 119  
 Centrifugal arteries of cord, 192  
 Centripetal arteries of cord, 192  
 Cerebellar notch, anterior and posterior, 70  
   tract, antero-lateral descending, 24, 25, 32, 86, 93, 94  
   ascending bulbar, 86  
   direct, 24, 25, 32, 34, 44, 65, 85, 86  
   dorso-lateral ascending, 24, 25, 32, 34, 44, 65, 85, 86  
   ventro-lateral ascending, 24, 25, 32, 34, 65, 85, 103, 104  
 Cerebellum (dim. of *cerebrum*, brain), 38, 69  
   arbor vitæ of, 71, 73, 74, 76, 78  
   blood supply of, 195  
   commissures of, 84  
   connection with cortex cerebri, 86  
   fibres of crusta, 101  
   fourth nerve, 86  
   optic tract, 120  
   sixth nerve, 86, 93  
   third nerve, 86  
   cortex of, 87  
   crura of, 46, 84  
   degenerations following lesions of, 32, 93  
   divisions of, 69  
   fibres from posterior longitudinal bundle to, 103  
   fissures of. *See* FISSURES.  
   hemispheres of, 69, 70, 78  
   laminae of, 71, 72, 86  
   literature of, 95  
   lobes of, 71, 74, 77  
   of lower animals, 69  
   nuclei in white matter of, 83  
   peduncles of, 38, 46, 84  
   inferior, 69, 83, 86, 93, 95, 118  
   middle, 67, 70, 83, 85, 93, 94, 164  
   superior, 67, 69, 82, 83, 84, 93, 94, 100, 103, 164, 195  
   situation of, 69  
   size of, 71  
   sulci of, 71, 75, 78  
   surfaces of, 71, 74  
   weight of, 179, 180  
   white matter of, 71, 78, 87, 91  
   worm (vermiform process) of, 69, 71, 73, 74, 77, 78, 94  
 Cerebral hemispheres. *See* HEMISPHERES.  
 Cerebro-spinal fluid, 1, 3, 188

- Cerebrum (brain), 38  
 comparison between male and female, 179  
 cortex of. *See* CORTEX.  
 crura of, 38, 96, 100, 118, 195  
 fissures of. *See* FISSURES.  
 peduncles of, 96, 100, 135  
 rotation of, 165  
 weight of, 179  
*See also* HEMISPHERES.
- Cervix cornu (neck of horn), 8, 52
- Cervical enlargement of cord, 3, 5  
 nerves, effect of section of posterior roots, 28  
 nucleus, 16  
 region of cord, 10
- Cetaceans, brain of, 162
- Chiasma (χιάσμα, mark with letter X), olfactory, 160  
 optic, 96, 117, 198
- Chinese, brain-weight of, 180
- Choroid (correctly chorioid, from χόριον, membrane) plexuses of fourth ventricle, 50, 185, 186, 195  
 of lateral ventricles, 122, 124, 155, 185, 198  
 of third ventricle, 98, 185, 198  
 vein, 185
- Choroidal fissure, 126, 155  
 villi, 186
- Ciliary muscle, origin of nerve-fibres to, 99
- Cingulum (girdle), 129, 158, 165
- Cisterna (reservoir) cerebello-medullaris, 188  
 chiasmatis, 188  
 corporis callosi, 188  
 fossæ Sylvii, 188  
 interpeduncularis, 188  
 laminae cinereæ, 188  
 peripeduncularis, 188  
 pontis lateralis, 188  
 media s. basilaris, 188
- Cisternæ arachnoïdales, 188
- Clarke's column, 16, 53, 86  
 effects of destruction cells in, 34
- Clastrum (rampart), 134, 135, 169
- Clava (club), 143
- Clendinning on brain-weight, 178
- Clivus (slope), 70, 73, 79  
 lobe of, 74, 77  
 monticuli, 71
- Cochlear root of auditory nerve, 63
- Collateral eminence, 127, 145  
 fibres of, 21, 65, 88, 163, 164  
 fissure, 127, 144, 153
- Columnæ fornicis, 129
- Columns, white, of cord, 8, 14, 22  
 anterior, 9, 12, 22, 65  
 antero-lateral, 9, 24, 31, 32, 64, 86, 95, 104  
 lateral, 9, 12, 64  
 of Lissauer, 20, 26, 29  
 posterior, 9, 26, 27, 29, 32, 53, 63  
 postero-lateral, 7, 28, 44  
 postero-mesial, 7, 10, 28, 43  
 fornix, anterior, 97, 113, 116, 129  
 posterior, 124, 129, 130  
 medulla oblongata, 40, 41, 104
- Comet cells, 17
- Comma tract, 26, 29, 32
- Commissura (uniting band) basos alba, 128
- Commissural fibres of cerebellum, 84  
 of cerebrum, 163, 164, 169, 172  
 between hippocampi, 131
- Commissures, 1  
 anterior, 98, 135  
 of cerebellum, 84  
 of cerebrum, anterior, 38, 98, 131, 135, 156, 160, 164  
 middle, 38, 96, 97, 111, 113  
 posterior, 38, 98, 104, 109, 114, 117, 119  
 of cord, 1, 6, 7, 10, 18, 34  
 great, 127  
 inferior, of Gudden, 117, 118  
 of Meynert, 120  
 middle or soft, 38, 96, 97, 111, 113  
 optic, 117  
 posterior, 98, 104, 109, 114, 119
- Conarium (κωνος, pine-cone), 114
- Conducting tracts of cord, 22
- Cone, fibrous, 163
- Conus medullaris, 5
- Convolutated brains, 162
- Convolutions. *See* GYRI.
- Cord. *See* SPINAL CORD.
- Cornu Ammonis (from its resemblance to the horns on the statue of Zeus-Ammon), 124, 158, 169, 172
- Cornua of grey matter of cord, 8, 10, 32, 51, 52, 53, 58, 104  
 cell-columns of, 14
- Cornucopia (horn of plenty), 50
- Corona radiata, 107, 109, 119, 135, 136, 163
- Corpora albicantia (white bodies), s. mamillaria (*mamilla*, nipple), 96, 98, 111, 113, 115, 129, 166, 198  
 amylicea (ἄμυλον, starch), 14  
 bigemina (two), 38, 106  
 geniculata (*genu*, knee), 105, 109, 111, 117, 118, 119, 195  
 quadrigemina (four), 38, 96, 104, 109, 110, 117, 119, 164, 195
- Corpus callosum (*callosus*, hard), 38, 122, 127, 130, 137, 156, 164, 166, 197  
 absence of, 162  
 peduncles of, 128, 155, 158, 159
- Corpus trapezoides, 73, 78, 79, 82
- Cortex (bark) cerebelli, 87  
 cerebri, 163  
 cells of, 167  
 connection with cerebellum, 86  
 crusta, 101, 136  
 hippocampal and callosal gyri, 158  
 internal capsule, 136  
 lower olives, 86  
 upper fillet, 104  
 degenerations after lesions of, 31, 86, 164  
 occipital region of, 110, 136  
 prefrontal region of, 136, 163  
 Rolandic region of, 136  
 visual area of, 110
- Cortical arteries, 193
- Course of fibres in cord, 22  
 of cord through medulla oblongata and pons, 63
- Cranial nerves, 93, 95
- Crescentic lobes of cerebellum, 71, 73, 74, 82
- Criminals, frontal lobe of, 161
- Crossed pyramidal tract, 24, 31, 32, 51, 64  
 root of fifth nerve, 62
- Crura (*crus*, leg) ad cerebrum, 84  
 medullam, 86  
 pontem, 85



- Crura—*continued*.  
 cerebri, 38, 96, 100, 118, 195  
 fornicis, 129, 130  
 Crural enlargement of cord, 5  
 Crusta (rind) connection with cortex, 101, 136  
 mesial bundle of, 67  
 pedunculi, 100, 111, 114, 115, 132, 136,  
 163, 164  
 Culmen (summit) monticuli, 70, 71, 73, 79  
 Cuneate funiculus, 44  
 lateral, 44  
 lobule, 152, 197  
 tubercle, 44  
 Cuneo-limbic annectent gyrus, 144  
 Cuneo-lingual annectent gyrus, 144  
 Cuneo-quadrate annectent gyrus, 144  
 Cuneus (wedge), 143, 152, 153, 156  
 Cunningham on cerebral convolutions, 162  
 inferior frontal sulcus, 148  
 intraparietal sulcus, 150  
 Rolandic angle, 143
- DANILEWSKY on grey cortex, 177  
 Darkschewitsch on Gudden's commissure, 118  
 optic tract, 117  
 posterior commissure, 109  
 Decussating commissural fibres of cerebellum, 84  
 Decussation of fillet, 53  
 pyramids, 46  
 Degeneration of nerve-cells, 24  
 nerve-tracts in spinal cord,  
 ascending, 24, 27  
 descending, 24, 27  
 secondary, 24  
 tertiary, 24  
 in spinal cord from lesions in cerebellum,  
 32, 93  
 in cerebrum, 31  
 long, 32  
 short, 32
- Deiters, cells of, 13  
 on formatio reticularis, 58  
 nucleus of, 56, 62  
 Dentate fissure, 156, 158  
 gyrus, 127, 155, 156, 158, 172  
 De Regibus on grey cortex, 177  
 Descending cerebellar tract, antero-lateral, 24,  
 25, 32, 86, 93, 94  
 degeneration, 24, 27  
 horn of lateral ventricle, 122, 124, 130  
 root of fifth nerve, 65, 100  
 tracts, 24, 26, 94  
 Dimensions of brain, 176  
 Direct cerebellar tract, 24, 25, 32, 34, 44, 65, 85, 86  
 lateral, 25  
 pyramidal tract, 24, 31, 32, 45  
 sensory tract, 163  
 Dolichocephalic (δολιχός, long; κεφαλή, head),  
 persons, brains of, 176, 177  
 Donaldson on grey cortex, 177  
 Dorsal cell-group of anterior horn, 14  
 column of medulla oblongata, 40  
 longitudinal bundle, 58, 65, 66, 86, 93,  
 94, 99, 102, 109, 114, 119  
 nucleus, 16  
 oculomotor nuclei, 99  
 olfactory root, 160  
 part of mid-brain, 104  
 region of cord, 10  
 Dorso-lateral ascending cerebellar tract, 24, 25,  
 32, 34, 44, 65, 85, 86  
 cell-group of anterior horn, 14
- Dura mater (*dura*, hard; *mater*, in the sense of  
 that which produces or nourishes: trans-  
 lated from the Arabic), 1, 3, 181  
 anterior ligament of, 182  
 Duret on arteries of brain, 197, 198  
 cisternae arachnoidales, 188  
 Duval on connection between third and sixth  
 nerves, 63, 99
- EDINGER on fillet, 65, 103, 104  
 and Westphal, nucleus of, 99  
 Eighth nerve. *See* NERVE, AUDITORY.  
 Elasmobranch fishes, pineal body of, 45, 115  
 Eleventh nerve. *See* NERVE, SPINAL ACCES-  
 SORY.  
 Eminencia cinerea (grey eminence), 50  
 collateralis, 127, 145  
 teres (rounded, cylindrical), 51  
 Encephalon (*ἐν*, in; *κεφαλή*, head). *See* BRAIN.  
 Enlargements of cord, 3, 5  
 Ependyma (*ἐνδύμα*, clothing), 62, 98, 110, 132  
 Ependymal fibres, 96  
 Epidural (*ἐπί*, upon; *dura mater*) space, 182  
 Epiphysis (*ἐπιφύω*, grow upon) cerebri, 114  
 Ergot (French, spur), 124  
 Exposed surface of cortex, 137, 177  
 Extent of grey cortex, 176  
 External capsule, 134, 135, 164  
 geniculate body, 105, 109, 111, 117,  
 119, 195  
 perpendicular fissure, 144  
 Extraciliary fibres, 85  
 Extraventricular portion of corpus striatum, 132  
 Eyes, effects of extirpation, 110, 118, 119
- FACIAL nerve. *See* NERVE.  
 nucleus. *See* NUCLEUS.  
 Falciform lobe, 155  
 Falx (*falx*, sickle) cerebelli, 182, 183  
 cerebri, 137, 182  
 minor, 183  
 Fascia dentata (toothed bundle) Tarini, 156, 172,  
 174  
 Fasciculus (small bundle) arcuatus, 165  
 longitudinal, inferior, 165  
 superior, 165  
 perpendicular, 165  
 retroflexus, 113  
 (or funiculus) teres, 50, 53, 63  
 uncinata, 165  
 Fasciola (small bandage) cinerea, 157, 158  
 Fibres, collateral, 21, 65, 88, 163, 164  
 ependymal, 96  
 Fibrae propriae, 165  
 rectae, 59  
 Fibrous cone, 163  
 Fifth nerve. *See* NERVE.  
 nuclei of. *See* NUCLEUS.  
 Fillet, 53, 65, 66, 93, 109, 164  
 decussation of, 53  
 lateral or lower, 66, 103, 105  
 mesial, 67, 101, 103  
 tract of, 103  
 upper, 104, 107, 114, 119, 120  
 upper nucleus of, 104  
 Film (thread) terminale, 2, 5, 189  
 Fimbria (fringe), 124, 130, 157, 158, 159, 166,  
 172  
 Fimbrio-dentate sulcus, 157  
 First nerve. *See* NERVE, OLFATORY.  
 Fishes, pituitary body of, 116  
 segmentation of spinal cord in, 16

- Fissura choroidea, 155  
 prima, 159  
 serotina (late), 159
- FISSURES (*see* SULCI) of cerebellum, 71, 75, 78, 79  
 antero-superior, 71, 73  
 great horizontal, 71, 75, 79, 82  
 intraculminate, 82  
 intralobular, 72  
 midventral, 77  
 postclival, 71, 73, 79, 82  
 postero-superior, 71, 73  
 postnodular, 75, 79  
 postpyramidal, 75, 79  
 preclival, 71, 73, 79, 82  
 prepyramidal, 75, 79
- of cerebrum, 137  
 calcarine, 124, 143, 144, 172  
     posterior, 144  
 callosal, 127, 156  
 calloso-marginal, 145, 146, 148  
 choroidal, 126, 155  
 collateral, 127, 144, 153  
 dentate, 156, 158  
 external perpendicular, 144  
 great longitudinal, 129, 137  
 hippocampal, 124, 156, 158  
 inferior, 124  
 limbic, 155, 160  
 paracentral, 145  
 parallel, 153  
 parieto-occipital, 124, 143, 144  
 paroccipital, 150  
 prelimbic, 145  
 of Rolando, 143, 150, 154, 155  
 of Sylvius, 141, 143, 146, 147, 148, 150  
 transverse, 124  
 variations in, 161  
     *See also* SULCI.
- of medulla oblongata, 40  
 or furrows of spinal cord, 6, 7
- Fleischig on fillet, 65
- Flocculus (dim. of *floccus*, flock of wool), 74, 75, 82  
 accessory, 76
- Fluid, cerebro-spinal, 1, 3, 188  
 subarachnoid, 187
- Flumina (rivers), 188
- Folia (*folium*, leaf) of cerebellum, causation of, 162
- Folium caecuminis (of the tip), 71, 74, 79
- Foramen cæcum, 40  
 of Majendie, 48, 188  
 of Monro, 97, 122, 129
- Forceps (pincers) major, 124, 129, 166  
 minor, 128
- Forel on Meynert's bundle, 114  
 tegmentum, 114  
 tract of fillet, 103  
 pillars of fornix, 129
- Formatio reticularis, 51, 52, 58, 60, 65, 100, 101, 102, 103, 114, 164  
 alba (white), 58, 65  
 grisea (grey), 58
- Formation of cornu Ammonis, 169
- Fornix (arch or vault), 122, 128, 129, 155, 158, 159, 166  
 bulbs of, 115  
 pillars or columns of, anterior, 97, 113, 116, 129, 131, 158  
     posterior, 124, 129, 130, 157, 158
- Fossa rhomboidalis, 47  
 Sylvian, 142  
 Tarini, 115
- Fourth nerve. *See* NERVE.  
 nucleus of. *See* NUCLEUS.  
 ventricle, 47, 73  
     floor of, 50
- Fovea (pit) inferior, 50  
 superior, 50
- Foville on tænia semicircularis, 131
- Frænulum (*frenum*, bridle) veli, 104
- Frænulum lingulæ, 73
- Freud on solitary cells of lamprey, 17
- Frontal convolution. *See* GYRUS.  
 lobe, 112, 145, 156, 160, 161, 164, 165, 177, 180, 195  
 operculum, 142  
 pole of hemisphere, 137, 147  
 sulci. *See* SULCI.
- Fronto-limbic annectent gyrus, 149
- Fronto-marginal sulcus, 146  
 lateral, 146, 149
- Fronto-parietal operculum, 142
- Fuchs, brain of, 176
- Funiculus cuneatus (wedge-shaped cord), 44  
 lateralis, 44  
 gracilis (slender), 43  
 of Rolando, 44, 52  
 solitarius, 55  
 (or fasciculus) teres, 50, 53, 63  
     nucleus of, 54, 65
- Furrowed band, 76
- Fusifiform lobule, 153, 166
- GALEN, veins of, 185
- Gambetta, brain of, 161
- Ganglia or ganglion (γάγγλιον, swelling), basal, 163, 172  
 basal optic, 116, 120  
 of habenula, 103, 113, 117  
 of hemispheres, 131  
 interpeduncular, 103, 114  
 optic, 109  
 radialis cochlearis, 55  
 of roof, 108  
 of spinal nerve-roots, 3
- Ganser on quadrigeminal bodies, 107
- Gauss, brain of, 176
- Gehuchten on collateral fibres, 21  
 olfactory bulb, 176
- Geniculate body, external, 105, 109, 111, 117, 119, 195  
 internal, 105, 109, 118, 195
- Genu (knee) of corpus callosum, 128  
 of fissure of Rolando, 143  
 of internal capsule, 136
- Giacomini on brains of criminals, 161  
 gyrus Rolandicus, 143  
 dentatus, 157  
 longus insulæ, 155
- Gland, pineal, 96, 97, 104, 114
- Glandulæ Pacchionii, 190
- Globus pallidus (pale sphere), 134, 164
- Glomeruli (dim. of *glomus*, clue of thread),  
 olfactory, 175, 176
- Glosso-pharyngeal nerve, origin of, 40, 54, 55  
 nucleus, 55
- Golgi on classification of nerve-cells, 17  
 collateral fibres, 22  
 fascia dentata, 173  
 olfactory bulb, 176

- Goll, tract of, 26, 28, 32, 34, 43  
 Graaf, de, on pineal body, 115  
 Gracile nucleus, 53, 86  
 Grande lobe limbique, 155  
 Granule-layer of cerebellar cortex, 87, 89, 90  
   of olfactory bulb, 174  
 Great commissure of cerebrum, 127  
   horizontal fissure of cerebellum, 71, 75, 79, 82  
   longitudinal fissure, 129, 137  
 Grey commissure of cord, 7  
   matter, central, 65, 98  
   of aqueduct, 96, 98  
   of cord, 7, 13  
     connection with visual centres, 119  
     effect of destruction, 34  
     ganglionic or cell-columns of, 14  
     horns or cornua of, 8  
     intermediate grey substance of, 8  
     intermedio-lateral tract of, 8  
     microscopic structure of, 13  
     processus reticularis of, 8  
     proportion of, to white matter, 7, 10  
   of hemispheres, structure of, 160  
   of medulla oblongata, connection with  
     visual centres, 119  
   olfactory root, 159, 160  
 Grooves or sulci of medulla oblongata, 40, 41  
 Ground-bundle, antero-lateral, 26, 32  
 Gudden, commissure of, 117, 118  
   on connection between cerebellum and olive,  
     57  
     optic fibres, 118  
     pillars of fornix, 129  
 Guinea-pig, optic chiasma of, 118  
   pyramidal tract of, 25  
 GYRUS or GYRI (*γῦρος*, ring), 137  
   angular, 151, 153  
   annectent, 143, 144, 145, 146, 147, 148, 150,  
     151, 152, 153, 156  
   bordering, 159  
   breves insulæ, 155  
   brevis accessorius insulæ, 155  
   callosal, 155, 156, 158, 160  
   causation of, 162  
   central, 143, 148, 149, 150  
   of central lobe, 154  
   cinguli, 156  
   cuneo-limbic annectent, 144  
   cuneo-lingual annectent, 144  
   cuneo-quadrate annectent, 144  
   dentatus, 127, 155, 156, 158, 172  
   forniceatus, 156, 158, 165  
     effect of removal, 32  
   fornicis, 155, 158  
   frontal, 143, 146, 147, 148, 150, 154, 161,  
     163, 165, 172, 195  
   fronto-limbic annectent, 149  
   geniculi, 155, 158  
   hippocampal, 153, 155, 156, 158, 159, 160,  
     161, 164, 165, 167  
   infracalcarine, 153  
   infracallosus, 155, 158, 159  
   limbicus, 158  
   lingual, 156  
   longus insulæ, 155  
   marginal, 145, 146, 148, 150, 159  
   occipital, 152  
   occipito-temporal annectent, 152  
   orbital, 149  
   parietal, 143, 148, 149, 150, 151, 163  
   parieto-occipital annectent, 151, 152  
   postcentral, 150
- GYRUS or GYRI—*continued*.  
 postparietal, 151, 152, 153  
 precentral, 147, 148  
 rectus, 149  
 Rolandicus, 143  
 subcalcarine, 153  
 subcallosus, 155, 158, 159  
 supracallosal, 155, 158  
 supramarginal, 151, 153  
 temporal, 151, 152, 153, 155  
 transverse temporal, 153  
 transversus insulæ, 154  
 uncinate, 156, 172  
 variations in, 161
- HABENULA (dim. of *habena*, thong or rein), 111  
 ganglion of, 103, 113, 117  
 Hemixtirpation of cerebellum, 93  
 Hemisection of spinal cord, 33, 104  
 Hemispheres of cerebellum, 69, 70, 78  
   connection with cerebral cortex, 86  
   of cerebrum, 38, 122, 137  
   blood-supply of, 195  
   commissures of. *See* COMMISSURES.  
   dimensions of, 176  
   fissures of. *See* FISSURES.  
   ganglia of, 131  
   grey matter, structure of, 166  
   intimate structure of, 163  
   lobes of, 137, 145  
   mantle of, 135, 142, 154  
   stem of, 154  
   ventricles of, 122  
   weight of, 178  
   white matter, structure of, 163  
 Hensen on oculomotor nucleus, 99  
 Heubner on arteries of brain, 198  
 Hill on rotation of cerebrum, 165  
 Hindus, brain-weight of, 180  
 Hippocampal fissure, 124, 156, 158  
   gyrus, 153, 155, 156, 158, 159, 160, 161,  
     164, 165, 167  
 Hippocampus (from fancied resemblance to limb  
 of fabulous animal thus named) major,  
 124, 130, 131, 158, 172  
 minor, 124  
 His on funiculus solitarius, 55  
   origin of neuroglia- and nerve-cells, 14  
 Hoche on ganglion-cells in anterior nerve-roots, 3  
 Horizontal fissure, great, of cerebellum, 71, 75,  
 79, 82  
   sulcus, lower or lesser, 75, 77  
 Horns of grey matter of cord. *See* CORNU.  
   lateral ventricle, 122, 124, 130  
 Horse, olfactory lobe of, 159  
 H-shaped sulcus, 149  
 Huschke on brain-weight, 180  
 Hypoglossal nerve. *See* NERVE.  
 Hypophysis (*ὕψος*, under; *φύω*, grow) cerebri, 97,  
 116
- INCISURA marsupialis (pouch-shaped notch), 70  
 semilunaris, 70  
 Index, occipital, 151  
 Inferior fissure of cerebrum, 124  
 Infracalcarine gyrus, 153  
 Infundibulum (funnel), 96, 97, 98, 116, 198  
 Innervation of orbital muscles, 99, 119  
 Intellectual development, influence of, on dimen-  
 sions of brain, 176  
   on fissures and convolutions, 161  
 Inter-brain, 96



- Intercentral connections of visual apparatus, 119  
 Interlobular fissures of cerebrum, 137  
 Intermediate grey substance of cord, 8  
   process, 8  
   sulcus, anterior, 24  
     posterior, 7  
 Intermedio-lateral tract, 8  
 Internal capsule, 100, 101, 104, 111, 114, 119,  
 128, 131, 132, 133, 135, 136, 163, 160,  
 169, 172, 197  
   medullary lamina, 112, 114, 134  
 Interolivary layer, 63  
 Interpeduncular ganglion, 103, 114  
 Intraciliar fibres, 85  
 Intraculminate fissures, 82  
 Intralobular fissures of cerebellum, 72  
 Intraparietal sulcus, 149, 155  
 Intra-ventricular portion of corpus striatum, 131  
 Involuted medullary lamina, 174  
 Island of Reil, 133, 141, 145, 154, 164  
 Isthmi lobi centralis, 135  
 Isthmus of brain, 38  
   of gyrus fornicatus, 156  
 Iter a tertio ad quartum ventriculum, 96
- JELGERSMA'S theory of causation of cerebral  
 gyri, 162
- KEY on cisternæ arachnoidales, 188  
   septum posticum of cord, 188
- Kinæsthetic (*κίνησις*, motion; *αἴσθησις*, percep-  
 tion) centres, 163
- Kölliker on collateral fibres, 21  
   nerves of arachnoid, 189
- Krause, W., white plexuses of, 169
- LABORDE on connection between third and sixth  
 nerves, 63, 99
- Lacunæ laterales (lateral hollows), 184, 191
- Lamina (layer), anterior and posterior perfo-  
 rated. *See* PERFORATED SPACE.
- Laminae arcuatæ gyrorum, 165  
   cinerea (grey), 96, 98, 117  
   cornea, 122  
   medullary, inner, 112, 114, 134  
     involuted, 174  
     outer, 111, 114, 134  
   quadrigenina, 96  
   septi lucidi, 155, 159  
   of cerebellum, 71, 72, 86  
   transversales inferiores, 77
- Lamprey, solitary cells of, 17
- Lancisi, nerves of, 127
- Lateral area of medulla oblongata, 43, 45  
   cell-column of cord, 16  
   cell-group of anterior horn, 14  
   column of cord, 9, 12, 64  
     medulla oblongata, 40  
   cuneate funiculus, 44  
   fillet, 66, 103, 105  
   horn of grey matter, 8, 10, 32, 52  
     lateral ventricle, 122, 124  
   nucleus. *See* NUCLEUS.  
   pyramidal tract, 24, 31, 32, 51, 64  
   recess, 47, 48, 49, 188  
   sinus, 182, 184  
   sulcus, 100  
   ventricle, 97, 122
- Latin races, brain-weight of, 180
- Latticed layer of thalamus, 112
- Lemniscus (ribbon), 53
- Lenhossék on basal optic ganglion, 116
- Lenticular arteries, 197  
   nucleus, 101, 112, 114, 120, 132, 136, 164,  
 197
- Lenticulo-optic (lenticulo-thalamic) arteries,  
 197
- Lenticulo-striate arteries, 197
- Leptomeninx (*λεπτός*, thin; *μήνιγξ*, membrane),  
 181
- Lesions of cerebellum, effects of, 32, 93  
   cortex cerebri, effects of, 31, 86, 164  
   optic thalamus, effects of, 85  
   spinal cord, effects of, 32
- Lesser horizontal sulcus, 75, 77
- Ligament, anterior, of dura mater, 182  
   central, of cord, 2, 5
- Ligamentum denticulatum (*denticulus*, dim. of  
*dens*, tooth), 3, 188, 189
- Ligula (dim. of *lingua*, tongue), 49, 50
- Limbic (*limbus*, surrounding border) lobe, 145.  
 149, 154, 155, 159, 160, 161, 165, 166  
   fissure, 155, 160
- Limen insulæ (threshold of island), 155
- Line of Baillarger, inner and outer, 167  
   Vieq d'Azyr, 167
- Linea splendens (brilliant), 186
- Lingual gyrus, 156  
   lobule, 153
- Lingula (dim. of *lingua*, tongue), 48, 71, 73, 82
- Lissauer's column or tract, 20, 26, 29
- Literature of brain, 199  
   cerebellum, 95  
   medulla oblongata and pons, 67  
   mid-brain, 120  
   spinal cord, 34
- Lizard, posterior longitudinal bundle of, 102
- LOBE or LOBES, amygdalo-uvular, 76  
   biventral, 74, 76, 82  
   central, of hemispheres, 133, 135, 145, 154,  
 177  
     of vermiform process, 71, 73, 77  
   of cerebellum, 71, 74, 77  
   of clivus, 74, 77  
   crescentic of cerebellum, 71, 73, 74, 82  
   falciform, 155  
   frontal, 112, 145, 156, 160, 161, 164, 165,  
 177, 180, 195  
   of cerebral hemispheres, 137, 145  
   inferior semilunar, 74, 77, 82  
   limbic, 145, 149, 154, 155, 159, 160, 161,  
 165, 166  
   occipital, 112, 119, 145, 151, 153, 163, 164,  
 165, 166, 177, 180, 195  
   olfactory, 145, 158, 159, 164, 174  
   optic, 38  
     of birds, 107  
   parietal, 112, 145, 149, 153, 177, 180, 195  
   of pituitary body, 116  
   postero-superior of cerebellum, 71, 74, 82  
   posterior of cerebellum, 74  
   of pyramid, 77  
   quadrilateral of cerebellum, 74  
   slender, 74, 77  
   temporal, 112, 145, 149, 152, 156, 160,  
 163, 164, 165, 177, 180, 195  
   temporo-sphenoidal, 152  
   of under surface of cerebellum, 75  
   of upper surface of cerebellum, 73  
   of vermiform process, 77.
- Lobule, cuneate, 152, 197  
   fusiform, 153, 166

- Lobule, lingual.** 153  
 olfactory, anterior, 159, 160  
     posterior, 159  
 oval, 149  
 paracentral, 149, 150  
 parietal, inferior and superior, 150, 151,  
 152, 166  
 postcentral, 154, 155, 156  
 precentral, 154, 155  
 quadrate, 149, 151, 156
- Lobulus gracilis, anterior and posterior.** 75
- Lobus sacularis,** 74, 77, 82  
 centralis, 77  
 olivæ, 73, 74, 77  
 calcaris, 73, 77  
 gracilis (slender), 77, 82  
 hippocampi, 161  
 infundibuli, 116  
 linguæ, 77  
 lunatus (crescent-shaped) anterior, 73  
     posterior, 74  
 noduli, 75, 76, 77  
 pyramidis, 76, 77  
 tuberculi, 75, 77  
 uvulae, 76, 77
- Loeus cereuleus (dark-blue place),** 51, 98
- Perforatus posticus,** 115
- Long association fibres,** 165  
 degenerations, 32
- Longitudinal bundle, posterior or dorsal,** 58, 65,  
 66, 86, 93, 94, 99, 102, 109, 114, 119  
 fissure, great, 129, 137  
 sinus, inferior, 182  
     superior, 152, 182, 184, 191
- Longitudinal striae, lateral or grey,** 127, 155,  
 157, 158  
     mesial, 127, 128, 155, 157, 158  
 sulcus of midbrain, 104
- Lower stalk of thalamus,** 112
- Lumbar enlargement of cord,** 3, 5  
 region of cord, 10
- Luschka on arachnoidal villi,** 191  
 on nerves of arachnoid, 189
- Lays, nucleus of,** 114, 120  
 on outer olfactory root, 160
- Lymphatics of brain and cord,** 198  
 pituitary body, 116
- Lymph-spaces of dura mater,** 184  
 nerve-sheaths, 189  
 pia-mater, 156
- Lyra (lyre),** 130
- MAGENDE, foramen of,** 48, 185
- Malaya, brain-weight of,** 180
- Mantle,** 135, 142, 154
- Marchi on lesions of cerebellum,** 32, 93  
 tract of Burdach, 32
- Marginal bundle of nerve-fibres,** 8, 25  
 gyrus, 145, 147, 148, 150, 159  
 effects of lesion, 31
- Marrow, spinal,** 2
- Marshall on brain-weight,** 180
- Measurements of brain,** 176
- Medulla oblongata (medulla marrows: oblonga,**  
 greater in length than breadth, oblong,  
 areas of, 41, 43, 45  
 blood-supply of, 194  
 columns of, 40, 41, 104  
 external characters of, 38  
 fissures of, 40  
 form of, 39  
 grooves or sulci of, 40, 41
- Medulla oblongata—continued.**  
 internal structure of, 51, 53  
 literature of, 67  
 measurements of, 39, 179  
 origin of nerve-roots from, 40  
 situation of, 38  
 structure of, 40, 51
- Medulla spinalis (spinal marrow),** 2
- Medullary arteries,** 193  
 centre of cerebral hemispheres, 163  
 lamina, external, 111, 114, 134  
     internal, 112, 114, 134  
 involuted, 174  
 striae, 50, 59, 94  
 aberrant bundle of, 50  
 velum, inferior, 48, 70, 76, 78  
     superior, 47, 70, 79, 82, 85, 98,  
     103, 104
- Membranes of brain and cord,** 1, 3, 181
- Mendel on origin of facial nerve,** 61  
 superior cerebellar peduncle, 85
- Meninges (meninges, membrane),** 181
- Merkel on cleft in descending cornu,** 126, 188
- Mesencephalon (mesos, middle; ἐντέφαλον, brain),**  
 96
- Mesial bundle of crista,** 67, 115, 164  
 cell-group of anterior horn, 14  
 fillet, 67, 101, 103  
 longitudinal striae, 127, 128, 155, 157, 158
- Meyner on brain-weight,** 180  
 bundle of, 103, 113  
 commissure of, 120  
 on claustrum, 135  
 cortical cell-layers, 167  
 nucleus fastigii, 84  
 olfactory chiasma, 160  
 posterior commissure, 109  
 stratum dorsale, 114  
 intermedium, 101
- Microscopic structure of cord,** 12  
 cerebellar laminae, 86  
 cerebral cortex, 166
- Midbrain,** 38, 96  
 dorsal part of, 104  
 literature of, 120  
 transition from pons to, 65
- Middle cell-column,** 17  
 cerebellar peduncle, 38, 46, 67, 70, 83, 85,  
 93, 94, 164  
 horn of lateral ventricle, 122, 124  
 or soft commissure, 38, 96, 97, 111, 113
- Midfrontal sulcus,** 146, 147
- Midgracile sulcus,** 75
- Midventral fissure,** 77
- Mitral cells,** 174, 176
- Mole, posterior longitudinal bundle of,** 103  
 quadrigeminal bodies of, 105, 110
- Molecular layer of cerebellar cortex,** 87  
 cerebral cortex, 167
- Monakow on anterior brachium,** 107
- Monkey, fornix of,** 129  
 parallel fissure of, 153  
 pyramidal tract of, 25, 31  
 Sylvian fissure of, 142  
*See also QUADRUMANA.*
- Monro, foramen of,** 97, 122, 129
- Monticulus (dim. of mons, mountain) of cerebellum,** 71
- Moss-fibres,** 91
- Motor cell-column,** 14  
 nucleus of fifth nerve, 61  
 region, effects of removal, 31

- Mott on cells of Clarke's column, 16  
 section of nerve-roots, 27
- Mouse, optic chiasma of, 118  
 pyramidal tract of, 25, 31
- Munzer on degeneration in spinal cord, 34  
 on tract of Burdach, 32
- Muscles, orbital, innervation of, 99, 119
- Myelin-sheath, development of, in cord, 22
- NATES, 105
- Negro, brain-weight of, 180  
 first frontal gyrus of, 147
- NERVE or NERVES (*νεῦρον*, nerve), abducent.  
*See* NERVE, SIXTH.
- of arachnoid membrane, 188
- auditory, 95, 106  
 ascending root of, 56  
 cochlear root of, 63  
 connection with inferior quadrigeminal body, 106  
 restiform body, 86  
 nuclei, *see* NUCLEUS  
 origin of, 55
- cranial, 93, 95  
 of dura mater, 184
- eighth. *See* NERVE, AUDITORY.
- eleventh. *See* NERVE, SPINAL ACCESSORY.
- facial origin of, 40, 55, 61, 63  
 degeneration in, after cerebellar lesions, 93
- fifth, central tract of, 62  
 degeneration in, after cerebellar lesions, 93  
 origin of, 40, 51, 61, 65, 98  
 trophic fibres of, 51  
 roots of, ascending, 52, 63, 93  
 degeneration after section, 53  
 crossed, 62  
 descending, 65, 100  
 raphe, 62
- first. *See* NERVE, OLFACTORY.
- fourth, 98, 102, 103  
 connection with cerebellum, 86  
 sixth, 66
- glosso-pharyngeal, 40, 54, 55
- hypoglossal, 93, 95  
 origin of, 41, 53, 57
- of Lancisi, 127
- ninth. *See* NERVE, GLOSSO-PHARYNGEAL.
- oculomotor. *See* NERVE, THIRD.
- olfactory, 159, 175,  
 origin of, from medulla oblongata, 40  
 spinal cord, 3, 19
- optic, 93, 118  
 connection with anterior quadrigeminal bodies, 105
- phrenic, 16
- of pia mater, 187
- pneumo-gastric. *See* NERVE, VAGUS.
- second. *See* NERVE, OPTIC.
- seventh. *See* NERVE, FACIAL.
- sixth, connection with cerebellum, 86, 93  
 fourth, 66  
 third, 63, 66, 99  
 origin of, 42
- spinal accessory, 16, 20, 40
- tenth. *See* NERVE, VAGUS.
- third, 93, 95, 98, 99, 102, 103  
 connection with cerebellum, 86  
 sixth, 63, 66, 99
- roots of, 100
- trigeminal. *See* NERVE, FIFTH.
- Nerve or nerves—*continued.*  
 trochlear. *See* NERVE, FOURTH.  
 twelfth. *See* NERVE, HYPOGLOSSAL.  
 vagus, 40, 54, 55
- Nerve-cells of cerebellum, 87  
 of cord, 10, 13, 14, 34  
 of cortex cerebri, 167  
 degeneration of, 24  
 of medulla oblongata, 53, 56, 58  
 of optic lobes, 108
- Nerve-fibres of cerebral hemispheres, 163  
 of cord, course of, 22  
 degeneration of, 24, 27  
 size of, 12  
 traced through bulb and pons, 63
- Nerve-roots, spinal, 3, 11, 20, 94  
 anterior, 19, 32, 43, 93  
 ganglia of, 3  
 posterior, 20, 29  
 collateral fibres of, 21  
 degeneration following section of, 27  
 relation to spines of vertebræ, 3  
*See also* NERVE.
- Neurilemma (*νεῦρον*, nerve; *λέμμα*, peel or skin)  
 of cord, 186
- Neuroglia (*νεῦρον*; *γλία*, glue), 12, 62, 87, 92,  
 96, 98, 100, 159, 167, 174
- Nidus avis (bird's nest), 76
- Ninth nerve. *See* NERVE, GLOSSO-PHARYNGEAL
- Nodule, 74, 75
- North American Indians, brain-weight of, 180
- Notch, cerebellar, anterior, 70  
 posterior, 70
- NUCLEUS (kernel) or NUCLEI, ambiguous, 55  
 amygdalæ, 124, 131, 135, 160, 169  
 of aqueduct, 65  
 auditory, 104, 106  
 accessory, 55, 60  
 inner or dorsal, 56, 62  
 outer or superior, 56  
 ventral, 56, 63
- caudatus (tailed), 124, 131, 134, 135, 136,  
 197
- centralis, 58
- cervical, of cord, 16
- of corpus albicans, 115
- of Deiters, 56, 62
- dentatus, 82, 83, 84, 85
- dorsal, of cord, 16
- of Edinger and Westphal, 99
- emboliformis, 83
- facial, 61  
 connection with oculomotor, 103
- fastigii (roof), 83, 84
- of fifth nerve, motor, 61  
 sensory, lower, 62  
 upper, 61
- of fourth nerve, 98, 102
- of funiculus cuneatus, 53, 86  
 external or accessory, 53
- of funiculus gracilis, 53, 86  
 teres, 54, 65
- globosus (spherical), 83
- glosso-pharyngeal, 55
- hypoglossal, 53
- lateral, of cord, 17  
 of medulla oblongata, 52  
 of thalamus, 112
- lateralis, 52
- lenticular, 101, 112, 114, 120, 132, 136,  
 164, 197
- of Luys, 114, 120



NUCLEUS or NUCLEI—*continued.*

- oculomotor, 98, 102, 109, 114, 117, 118  
 central, 99  
 connection with facial, 103  
 dorsal, 99  
 ventral, 99
- olivary, 56  
 accessory, 57  
 connections of, 56, 86  
 superior, 47, 60
- of optic thalamus, 112, 113, 114, 129
- pontis, 60, 86, 93, 101
- pyramidal, 57
- of quadrigeminal bodies, 105
- red, 103, 114
- of roof, 84
- sacral, of cord, 16
- of sixth nerve, 63  
 atrophy of, 100
- spinal accessory, 20, 55
- of superficial arched fibres, 59
- tegmental, 93, 94, 103
- of third nerve. *See* NUCLEUS, OCULOMOTOR.
- upper, of fillet, 104
- vagus, 55  
 accessory, 55
- of white matter of cerebellum, 83
- OBEX (bolt), 50
- Occipital gyri, 152  
 index, 151  
 lobe, 112, 119, 145, 151, 153, 163, 164,  
 165, 166, 177, 180, 195  
 effect of removal, 32
- operculum, 144
- pole of hemisphere, 137, 152, 178
- region of cortex cerebri, effect of removal,  
 110
- sinus, 183
- sulcus, anterior, 144, 152  
 lateral, 151, 152  
 transverse, 150, 152
- Occipito-temporal annectent gyrus, 152  
 region of cortex, 136
- Ocular muscles, innervation of, 99, 119
- Oculomotor nucleus. *See* NUCLEUS.  
 sulcus, 100
- Olfactory bulb, 145, 159, 174, 195  
 bundle of cornu Ammonis, 158
- cells, 176
- chiasma (χιάσμα, mark with letter X), 160
- glomeruli (*dim.* of *glomus*, clue of thread),  
 175, 176
- lobe, 145, 158, 159, 164, 174
- lobule, anterior, 159, 160  
 posterior, 159
- nerves, 159, 175
- nerve-fibres, layer of, 175, 176
- root, inner or mesial, 128, 156, 158, 159, 160
- outer or lateral, 156, 159, 160
- middle or grey, 159, 160
- upper or dorsal, 160
- sulcus, 149
- tract, 145, 156, 158, 159, 160, 164, 174
- Olivary body, 41, 45, 85
- nucleus. *See* NUCLEUS.
- peduncle, 56
- Olive, inferior, 41, 45, 86, 93, 94, 118  
 connection with cerebral cortex,  
 86
- superior, 47, 60

- Operculum (cover or lid) of Burdach, 141  
 frontal, 142  
 fronto-parietal, 142  
 of hypophysis, 182  
 occipital, 144  
 orbital, 142  
 temporal, 142
- Optic lobes, 38  
 of birds, 107
- chiasma, 96, 117, 198
- commissure, 117
- ganglion, 109  
 basal, 116, 120
- optic nerve, 93, 118, 188
- radiations, 112
- recess, 97
- thalamus, 93, 96, 97, 110, 122, 136, 163,  
 164, 166, 195, 197  
 effect of lesion, 85
- inferior peduncle of, 164
- tract, 96, 105, 107, 110, 111, 112, 114, 117,  
 164  
 connection with cerebellum, 120
- Orbital gyri, 149  
 limbs of Sylvian fissure, 142
- muscles, innervation of, 99, 119
- sulcus, 149
- surface of cerebral hemisphere, 145, 148,  
 149, 195
- Origin of nerves from medulla oblongata, 40  
 spinal nerves, 3, 19
- Osmatic (ὀσμώδεις, smell) mammals, 158, 159,  
 160, 161
- Outlying cells of cord, 17
- Oval lobule, 149
- PACCHIONIAN glands, 190  
 granulations, 184
- Pachymeninx (παχύς, thick; μήνιγξ, membrane),  
 181
- Paracentral fissure, 145  
 lobule, 149, 150
- Parallel fissure, 153
- Paramesial sulcus, 146, 147, 161
- Parietal convolutions, 151  
 ascending, 143, 148, 150,  
 151, 163
- foramen, 115
- lobe, 112, 145, 149, 155, 177, 180, 195
- lobules, 150, 151, 152, 166
- Parieto-occipital annectent gyrus, 151, 152  
 fissure, 124, 143, 144
- Parkes on brain of negro, 161
- Paroccipital fissure, 150
- Pars ascendens inferior s. postcentralis inferior  
 of intraparietal sulcus, 150  
 superior of intraparietal sulcus,  
 150
- basilaris of third frontal gyrus, 147, 148
- fronto-parietalis of operculum, 142
- horizontalis s. posterior of intraparietal  
 sulcus, 150, 152
- intermedia of facial nerve, origin of, 55
- occipitalis of intraparietal sulcus, 150
- olfactoria of olfactory bundle, 158, 164
- orbitalis of operculum, 142  
 of third frontal gyrus, 147
- temporalis of olfactory bundle, 158, 164
- triangularis of operculum, 142  
 third frontal gyrus, 147
- Partitions of dura mater, 182
- Paulier on grey cortex, 177

- Peacock on brain-weight, 178
- Peduncle (*pedunculus*, foot-stalk of leaf) or peduncles, of cerebellum, 38, 46, 84  
 inferior, 69, 83, 86, 93, 95, 118  
 middle, 38, 46, 67, 70, 83, 85, 93, 94, 164  
 superior, 67, 69, 82, 83, 84, 93, 94, 100, 103, 164, 195  
 of cerebrum, 96, 100, 135  
 of corpus albicans, 115  
 of corpus callosum, 128, 155, 158, 159  
 olivary, 56  
 of pineal body, 113, 114, 117  
 of thalamus, inferior, 164
- Peduncular tract, 65
- Pedunculus conarii, 114  
 flocculi, 76, 82
- Perforated space or lamina, anterior, 112, 131, 135, 141, 155, 158, 159, 165, 197  
 posterior, 96, 98, 115, 195
- Perineural sheaths, 188
- Peripheral venules, 193
- Perivascular sheath, 186, 187
- Perpendicular fasciculus, 165  
 fissure, external, 144
- Pes (foot) accessorius, 127  
 hippocampi, 124  
 pedunculi, 100
- Petrosal sinus, superior, 182
- Phrenic nerve, origin of, 16
- Pia mater (*pia*, translation of Arabic word, meaning properly thin; *mater*, see Dura mater), 1, 3, 100, 114, 122, 137, 181, 184
- Pillars of fornix, anterior, 97, 113, 116, 129, 131, 158  
 posterior, 124, 129, 130, 157, 158
- Pineal (*pineæ*, pine-cone) body or gland, 96, 97, 104, 114  
 peduncles of, 113, 114, 117  
 eye, 115  
 recess, 97  
 stria, 98, 114, 129
- Pituitary body, 96, 97, 116
- Plexuses, choroid, of fourth ventricle, 50, 98, 185, 186, 195  
 of lateral ventricles, 122, 124, 155, 185, 198  
 sand of, 114  
 of third ventricle, 98, 185, 198  
 white, of cerebral cortex, 169
- Pneumo-gastric nerve. See NERVE, VAGUS.  
 nucleus. See NUCLEUS, VAGUS.
- Pole of hemisphere, 137, 147, 152, 178  
 of island, 155  
 of temporal lobe, 153
- Polymorphous cells, layer of, 168
- Pons (bridge) Varolii, 38, 46, 100, 101, 118, 179  
 blood-supply of, 194  
 dimensions of, 40  
 external characters of, 38, 46  
 internal structure of, 60  
 literature of, 67  
 nuclei of, 60, 86, 93  
 structure of, 47  
 transition to mid-brain from, 65
- Ponticulus (dim. of *pons*), 46
- Postcentral gyrus, 150  
 lobule, 154, 155, 156  
 sulcus of cerebellum, 71, 73, 79, 82  
 of cerebrum, 143, 150
- Postclival fissure, 71, 73, 79, 82
- Posterior area of medulla oblongata, 41, 43  
 calcarine fissure, 144  
 central gyrus, 150  
 columns of cord, white, 9, 26, 27, 29, 32, 53, 63  
 vesicular, 16  
 of medulla oblongata, 41, 104
- Commissure of cerebrum, 38, 98, 104, 109, 114, 117, 119  
 of cord, 7, 18
- Cuneo-lingual annectent gyrus, 144
- Descending tract, 29
- Horn or cornu of cord, 8, 10, 52, 53, 104  
 of lateral ventricle, 122, 124
- Intermediate septum of cord, 7
- Limb of Sylvian fissure, 141, 142
- Lobe of pituitary body, 116
- Longitudinal bundle, 58, 65, 66, 86, 93, 94, 95, 99, 102, 109, 114, 119
- Olfactory lobule, 159
- Orbital gyrus, 149
- Pillars of fornix, 124, 129, 130, 157, 158
- Segment of internal capsule, 136
- Septum of cord, 7, 188
- Spinal artery, 192
- Tubercle of optic thalamus, 110
- Postero-lateral column of cord, 7, 28, 44
- Postero-mesial column of cord, 7, 10, 28, 43
- Postgracile sulcus, 75
- Postnodular fissure, 75, 79
- Postparietal gyrus, 151, 152, 153
- Postpyramidal fissure, 75, 79
- Precentral gyrus, 147, 148  
 lobule, 154, 155  
 sulcus of cerebellum, 71, 73, 79  
 of cerebrum, 143, 145, 146, 148, 155  
 transverse, 143, 146, 155
- Preclival fissure, 71, 73, 79, 82
- Precuneate sulci, 151
- Precuneus, 151
- Prefrontal region of cortex, 136, 163
- Pregracile sulcus, 75
- Prelimbic fissure, 145
- Prepyramidal fissure, 75, 79
- Pre-Rolandic sulcus, 145
- Primates, third frontal gyrus of, 148
- Process, intermediate, 8  
 vermiform, 69, 71, 73, 74, 77, 78  
 effects of removal, 94
- Processes of dura mater, 182
- Processus reticularis, 8
- Projection fibres, 163, 164, 169, 172
- Prosencephalon (*πρός*, before; *εγκέφαλον*, brain), 122
- Psychomotor (*ψυχή*, mind; *motio*, motion) centres, 163, 172
- Pulvinar (cushion), 110, 117, 119
- Purkinje, corpuscles or cells of, 87, 88, 91, 93  
 on nerves of pia mater, 187
- Putamen (husk), 134, 197
- Pyramid of worm, 74, 76, 79
- Pyramids, anterior, 43, 45  
 decussation of, 46  
 large and small, layers of, 168  
 posterior, 44
- Pyramidal bundles, 67, 93

- Pyramidal nuclei, 57  
tract, 93, 100, 101, 163, 164, 172  
  anterior or direct, 24, 31, 32, 45  
  of isthmus, 65  
  lateral or crossed, 24, 31, 32, 51, 64  
  section of, 31
- QUADRATE lobule, 149, 151, 156  
Quadrigeminal bodies, 38, 96, 104, 109, 110,  
117, 119, 164, 195  
Quadrilateral lobe of cerebellum, 74  
Quadrumana, anterior occipital sulcus of, 152  
  calcarine fissure of, 144  
  intraparietal sulcus of, 150  
  occipital lobe of, 151  
  parieto-occipital fissure of, 143  
  third frontal gyrus of, 148  
  *See also* MONKEY.
- RABBIT, pyramidal tract of, 25  
Racial variations in gyri and fissures, 161  
Randwindung (German, bordering convolution),  
159  
Raphé (*ράφή*, seam) of bulb and pons, 59, 60  
  of corpus callosum, 127  
  of midbrain, 100  
Raphé-root of fifth nerve, 62  
Rat, pyramidal tract of, 25  
Recess, lateral, 47, 48, 49, 188  
  optic, 97  
  pineal, 97  
  suprapineal, 97  
Recti muscles of eye, innervation of, 99  
Red nucleus, 103, 114  
Reid, J., on brain-weight, 178  
Reid, R. W., on relation between vertebral  
  spines and nerve-origins, 3  
Reil, island of, 133, 141, 145, 154, 164  
Relative weight of encephalon to body, 178  
Reptiles, pineal body of, 115  
  posterior longitudinal bundle of, 103  
  segmentation of spinal cord of, 16  
Restiform (*restis*, rope) body, 44, 69, 85, 86  
Reticular formation, 51, 52, 58, 60, 65, 100,  
101, 102, 103, 114, 164  
Reticulated white substance, 167  
Retina, 107, 118, 119  
Retinal fibres, 110  
Retzius, on cisternæ arachnoidales, 188  
  on septum posticum, 188  
Rhinocephalon (*ῥίς*, *ῥίς*, nose; *ἐγκέφαλον*,  
  brain), 160, 161  
Ridge, connecting, of pyramid, 76  
Rivi (streams) and rivuli, 188  
Rolandic angle, 143  
  gyrus, 143  
  region of cortex, 136  
Rolando, fissure of, 143, 150, 154, 155  
  funiculus of, 44, 52  
  substantia gelatinosa of, 8, 10, 13, 44  
    cells in, 17  
  tubercle of, 44, 52, 62  
Roller on auditory nerve-roots, 56  
Roof, ganglion of, 108  
Roots, of auditory nerve, 56, 63  
  of facial nerve, 63  
  of fifth nerve. *See* NERVE.  
  olfactory, inner or mesial, 128, 156, 158,  
    159, 160  
    middle, 160  
    outer or lateral, 156, 159, 160
- Roots—*continued*.  
  olfactory, upper or dorsal, 160  
  of optic tract, 117  
  of spinal nerves. *See* NERVE-ROOTS.  
  of third nerve, 100  
Rostral sulci, 149  
Rostrum (beak), of corpus callosum, 128  
Rust-coloured layer of cerebellar cortex, 87
- SACHS on medullary centre of occipital lobe, 166  
Sacral nucleus, 16  
Sacro-coccygeal region of cord, 10  
Sacro-lumbar nerves, effect of section of posterior  
  roots, 27  
Sagittal sulcus of midbrain, 104  
Sala on fascia dentata, 173  
Sandwich islanders, brain-weight of, 180  
Schwalbe on falciform lobe, 155  
  on tænia semicircularis, 131  
Slavonic races, brain-weight of, 180  
Sclerosis (*σκληρός*, hard), 24  
Second nerve. *See* NERVE, OPTIC.  
Secondary degeneration of nerve-fibres, 24  
Section, effects of, of fillet, 53  
  of nerve-roots, dorsal and cer-  
    vical spinal, 28  
  sacro-lumbar  
    spinal, 27  
  sensory of fifth  
    nerve, 53  
  of pyramidal tract, 31  
  of spinal cord, 32
- Segment of spinal cord, 3, 16  
Semicircular fibres, 85  
Semilunar lobe, inferior, 74, 77, 82  
Sensory nuclei. *See* NUCLEUS OF FIFTH NERVE.  
  root of fifth nerve, 53  
  tract, direct, 163  
Septa of cord, 7, 9, 12  
Septum lucidum (clear partition), 122, 128, 129,  
155, 159  
  posterior intermediate of cord, 7  
  posticum of cord, 7, 188  
Seventh nerve. *See* NERVE, FACIAL.  
  nucleus of. *See* NUCLEUS, FACIAL.  
Sexual differences in brain-weight, 178, 179, 180  
  variations in gyri and sulci, 161  
Sheath, perineural, 188  
  perivascular, 186, 187  
Sherrington on degeneration after cortical lesions,  
32  
  on outlying cells of cord, 17  
Short association fibres, 165  
  degenerations, 32  
Siliqua (capsule) olivæ, 45  
Sims on brain-weight, 178  
Singer on degenerations in spinal cord, 34  
  on section of nerve-roots, 27  
  on tracts of Burdach, 32  
Sinus (hollow) lateral, 182, 184  
  longitudinal, inferior, 182  
    superior, 152, 182, 184, 191  
  occipital, 183  
  petrosal, superior, 183  
  straight, 182, 184  
Sinuses of dura mater, 182  
Sixth nerve. *See* NERVE.  
  nucleus of, 63  
Size of body, influence of, on convolutions, 162  
Slender lobe, 74, 77  
Smooth brains, 162



- Soft commissure, 97  
 Solitary bundle, 63  
   cells, 17  
 Solly on fibres of anterior column, 65  
 Space, epidural, 182  
   perforated, anterior, 112, 131, 135, 141,  
     155, 158, 159, 165, 197  
     posterior, 96, 98, 115, 195  
   subarachnoid 3, 186, 187, 198  
   subdural, 3, 181, 184  
 Special senses, centres for, 163  
 Speech-centre, 147  
 Spencer on pineal eye, 115  
 Sphincter pupillæ, innervation of, 99  
 Spinal accessory nerve, 16, 20, 40  
   nucleus, 20, 55  
 Spinal arteries, 191, 192  
 Spinal bulb. *See* MEDULLA OBLONGATA.  
 Spinal cord or marrow, 1, 2  
   blood-supply of, 191  
   cell-columns of. *See* CELL-COLUMNS.  
   central canal of, 9, 10, 19  
   central ligament of, 2, 5  
   columns of, white. *See* COLUMNS.  
   commissures of, 1, 6, 7, 10, 18, 34  
   conducting tracts of, 22  
   connective tissue of, 9  
   course of nerve-fibres in, 22  
   degenerations in, 27  
   dimensions of, 2, 3  
   distribution of nerve-cells of, 14  
   enlargements of, 3, 5  
   features of different regions of, 10  
   fibres of, traced through bulb and pons, 63  
   fissures or furrows of, 6, 7  
   form of, 3  
   grey matter of, 7, 13  
     *See also* GREY MATTER.  
   internal structure of, 7  
   lesions of, 32  
   lymphatics of, 198  
   membranes of, 1, 3, 181  
   microscopic structure of, 12  
   neurilemma of, 186  
   neuroglia of, 12  
   origin of nerves from, 3, 11  
   proportions of grey and white matter in, 7, 10  
   relation of to vertebrae, 2  
   segments of, 3, 16  
   septa of, 7, 9, 12, 188  
   veins of, 193  
   weight of, 180  
   white matter of, 9, 12  
 Spinal nerves, 3, 11, 19, 94  
 Spitzka on mesial fillet, 101  
 Splenium (*σπληνιον*, *pad*), 128  
 Stalk of thalamus, anterior, 112  
   lower, 112  
 Stammtheil (German, stem-part), 154  
 Starr on oculomotor nucleus, 99  
 Stature, influence of, on brain-weight, 179  
 Stem of hemisphere, 154  
 Stieda on optic lobes of birds, 107  
 Stilling on decussating fibres of cerebellum, 84  
   on optic tract, 118  
   on restiform body, 85  
 Straight sinus, 182, 184  
 Stratum albo-cinereum (white-grey layer), infe-  
   rius, 107  
   superius, 107  
   cinereum, 107  
   dorsale, 114  
 Stratum—*continued*.  
   granulosum, 174  
   intermedium, 101  
   laciniosum (jagged), 173  
   lemnisci, 107  
   opticum, 107  
   radiatum, 173  
   zonale, 98, 107, 111  
 Stria (furrow, streak) alba tubercis, 116  
   medullaris, of mid-brain, 98  
   pinealis, 98, 114, 129  
   terminalis, 110, 122  
 Striæ, longitudinal, lateral or grey, 127, 155,  
   157, 158  
   mesial, 127, 128, 155, 157,  
   158  
   medullares seu acusticæ, 50, 59, 94  
 Subarachnoid fluid, 187  
   space, 3, 186, 187, 198  
 Subcalcarine gyrus, 153  
 Subdural space, 3, 181, 184  
 Subiculum (support) cornu Ammonis, 156  
 Substantia ferruginea (colour of iron-rust),  
   51, 65  
   gelatinosa of Rolando, 8, 10, 13, 44, 62  
     cells of, 17  
     centralis, 18  
   innominata, 112, 135  
   interansalis (between the loops), 112, 114  
   nigra (black), 114  
   reticularis alba, 156  
   spongiosa, 13  
 Subthalamic tegmental region, 112, 113, 122,  
   136, 164  
 SULCUS (furrow) or SULCI (*see* FISSURES), causa-  
   tion of, 162  
   of cerebellum, 71, 75, 77  
     arcuate, anterior, middle and posterior,  
       75, 77  
     horizontal, great, 71, 75, 79, 82  
       lower or lesser, 75, 77  
   midgracile, 75  
   postcentral, 71, 73, 79, 82  
   postgracile, 75  
   postnodular, 75, 79  
   postpyramidal, 75, 79  
   precentral, 71, 73, 79  
   pregracile, 75  
   prepyramidal, 75, 79  
   valleculæ, 75, 76  
   of cerebral hemispheres, 137, 145, 149, 151,  
     153, 154, 156  
     callosal, 127, 156  
     central, 143  
     centralis insulæ, 154  
     diagonalis, 146, 148  
     extremus, 144  
     fimbrio-dentate, 157  
     frontalis inferior, 146, 148  
       medius, 146, 147, 161  
       mesialis, 149  
       (of Cunningham), 146, 147  
       superior, 146, 148  
     fronto-marginalis, 146  
       lateralis, 146, 149  
     fronto-orbitalis, 149  
     H-shaped, 149  
     inferior transverse, 143  
     intraparietal, 149, 155  
     limitans insulæ, 154  
     marginalis, 149  
     occipitalis anterior, 144, 150, 152

SULCUS or SULCI—*continued.*

- of cerebral hemispheres—*continued.*  
 occipitalis lateralis, 151, 152  
     transversus, 150  
 olfactory, 149  
 orbitales sagittales, 149  
 orbitalis, 149  
     transversus, 149  
 paramesial, 146, 147, 161  
 postcentralis, 143, 150  
 postcentralis insulæ, 155  
 postcentralis superior, 150  
 postlimbic, 155  
 precentralis, 143, 145, 155  
     inferior, 146, 148  
     insulæ, 155  
     mesialis, 145  
     superior, 146  
     transversus, 143, 146, 155  
 precuneati, 151  
 pre-Rolandic, 145  
 radiatus, 146  
 rectus (straight) Quadrumanorum, 148  
 retrocentralis transversus, 150  
 rostral, 149  
 supraorbital, 149  
 temporal, 153  
 transversus anterior, 146  
     inferior, 143  
     occipitalis, 150  
     orbitalis, 149  
     precentralis, 143, 146, 153  
     retro-centralis, 150  
 triradiate, 149  
 of mid-brain, lateralis, 100  
     longitudinalis, 104  
     oculomotorii, 100  
     sagittalis, 104  
     transversus, 104  
 of spinal cord, intermediate, 7, 24  
 Sunken surface of cortex cerebri, 137, 177  
 Superficial arched fibres, 44, 45, 58, 59  
 Superior commissure of cerebellum, 84  
     fovea, 50  
     medullary velum, 47, 70, 73, 79, 82, 85,  
     98, 103, 104  
     olive, 47, 60  
     petrosal sinus, 183  
     worm, 69  
 Supracallosal gyrus, 155, 158  
 Supramarginal gyrus, 151, 153  
 Supraorbital sulcus, 149  
 Suprapineal recess, 97  
 Surfaces of cerebellum, 71, 74  
     cerebral hemispheres, 137, 197  
     orbital, 145, 147, 148, 149, 195  
 Sylvian angle, 142  
     aqueduct, 96  
     fissure, 141, 143, 146, 147, 148, 150  
     fossa, 142
- TABLE of parts of cerebellar worm and hemispheres, 78  
 Tænia (*ταῖνια*, band) of medulla oblongata, 49  
     fimbriæ, 158  
     fornicis, 98, 110, 114, 129  
     hippocampi, 130  
     pontis, 115  
     semicircularis, 122, 124, 129, 131  
 Tæniæ tectæ (concealed), 127  
 Tapetum (carpet), 124, 129
- Tartuferi on quadrigeminal bodies, 106  
 Tegmental nucleus, 93, 94, 103  
 Tegmentum (covering), 98, 100, 102, 112, 114,  
     115, 163, 164  
     subthalamic, 112, 113, 122, 164  
 Tela choroidea (choroid web) inferior, 185, 186,  
     188  
     superior, 185  
 Temporal division of cerebral hemisphere, 137  
     gyri, 151, 152, 153, 155  
     lobe, 112, 145, 149, 152, 156, 160, 163,  
     164, 165, 177, 180, 195  
     operculum, 142  
     sulci, 153  
 Temporo-occipital bundle, 165  
 Temporo-sphenoidal lobe, 152  
 Tent of dura mater, 182  
     fourth ventricle, 78  
 Tenth nerve. *See* NERVE, VAGUS.  
 Tentorium (tent) cerebelli, 182  
     of hypophysis, 182  
 Terminal arteries, 193  
     filament of cord, 5, 189  
 Tertiary degeneration of nerve-fibres, 24  
 Testes, 105  
 Testut on tenia semicircularis, 131  
 Teutonic races, brain-weight of, 180  
 Thalamencephalon (*thalamus*, bed; *ἐγκέφαλον*,  
     brain), 96  
 Thalamus, optic. *See* OPTIC THALAMUS.  
 Theca (sheath), 3, 182  
 Thickness of cerebral cortex, 177  
 Third nerve. *See* NERVE.  
 Third ventricle, 96, 97  
 Threshold of island, 155  
 Tiedemann on brain-weight, 178  
 Tomentum (flock of wool, hair, &c.) cerebri, 184  
 Tonsil of cerebellum, 74, 76  
 Tooth on origin of facial nerve, 61  
 Trabs (beam) cerebri, 127  
 Tract or tracts, antero-lateral ascending, 24, 25,  
     32, 34, 65, 85, 103, 104  
     of antero-lateral column, 24  
     antero-lateral descending, 24, 25, 32, 65,  
     85, 86  
     bulbar ascending cerebellar, 86  
     of Burdach, 26, 28, 32, 44  
     central, of fifth nerve, 62  
     of tegmentum, 60  
     comma, 26, 29, 32  
     conducting, of cord, 22  
     crossed or lateral pyramidal, 24, 31, 32,  
     51, 64  
     direct pyramidal, 24, 31, 32, 45  
     sensory, 163  
     cerebellar, 24, 25, 32, 34, 44, 65, 85, 86  
     dorso-lateral ascending, 24, 25, 32, 34, 44,  
     65, 85, 86  
     of fillet, 103  
     of Goll, 26, 28, 32, 34, 43  
     intermedio-lateral, 8  
     of Lissauer, 20, 26, 29  
     olfactory, 145, 156, 159, 160, 164, 174  
     optic, 96, 105, 107, 110, 111, 114, 117, 164  
     connection with cerebellum, 120  
     peduncular, 65  
     posterior descending, 29  
     of posterior white columns, 26  
     pyramidal, 24, 31, 32, 45, 93, 101, 163,  
     164, 172  
     of isthmus, 65  
 Tractus transversus pedunculi, 118

- Transition from pons to mid-brain, 65  
 Transitional tegmental region, 114  
 Transverse fibres of cerebral hemisphere, 163, 164  
   fissure, 124  
   gyri. *See* GYRUS.  
   sulcus, inferior, 143  
     of mid-brain, 104  
     occipital, 150, 152  
     precentral, 143, 146, 155  
     temporal gyri, 153  
 Trapezium, 47, 104  
 Trapezoidal body, 73, 78, 79, 82  
 Trigeminal nerve. *See* NERVE, FIFTH.  
 Trigonum (triangle) acustici, 50  
   habenulae, 111, 113, 114  
   hypoglossi, 50  
   interpedunculare, 100  
   olfactorium, 159, 160  
   vagi, 50  
   ventriculi, 127  
 Triradiate sulcus, 149  
 Trochlear nerve. *See* NERVE, FOURTH.  
 Trophic fibres of fifth nerve, origin of, 51  
 Tuber (swelling) annulare, 39  
   cinereum, 96, 98, 111, 116  
   posticum, 74, 77, 79  
   valvulae s. posticum, 74, 77, 79  
 Tubercle, acoustic, 50  
   cuneate, 44  
   of optic thalamus, anterior, 110  
     posterior, 110  
   of Rolando, 44, 52, 62  
 Tuberculum laterale s. acusticum, 50  
 Türk, column of, 24  
 Turner, W. A. on origin of facial nerve, 61  
 Turner, Sir W. on rhinencephalon, 161  
 Twelfth nerve. *See* NERVE, HYPOGLOSSAL.
- UNCINATE GYRUS, 156, 172  
   fasciculus, 165  
 Uncus (hook), 156, 158  
 Uvula (from resemblance to uvula of soft palate),  
   74, 76, 79
- VAGAL nucleus, accessory, 55  
 Vagus (wandering) nerve. *See* NERVE.  
 Vallecula (dim. of *vallis*, valley), 70  
   sulci of, 75, 76  
   Sylvii, 137, 141, 158, 159  
 Valve of Vieussens, 47, 70, 195  
 Variations in gyri and sulci, 161  
 Vein, choroid, 185  
   of corpus striatum, 122, 185  
   of Galen, 185  
 Veins of dura mater, 184  
   of spinal cord, 193  
 Velum (sail or curtain) interpositum, 98, 114,  
   122, 129, 185, 198  
   medullary, inferior, 48, 70, 76, 78
- Velum—*continued.*  
   medullary, superior, 47, 70, 73, 79, 82, 85,  
     98, 103, 104  
 Vena magna Galeni, 186  
 Ventricles of brain, 38, 47, 96, 97, 122, 188, 189  
   of cerebral hemispheres, 122  
     fourth, 47, 73  
       floor of, 50  
       tent of, 78  
     lateral, 97, 122  
     of septum, 129  
     third, 96, 97  
 Ventro-lateral cell-group of anterior horn, 14  
   tract, ascending, 24, 25, 32, 34, 65, 85, 103  
     104  
     descending, 24  
 Venules, central, 193  
   peripheral, 193  
 Vermiform (*vermis*, worm) process. *See* WORM.  
 Vicq-d'Azyr, bundle of, 113, 115, 129, 166  
   line of, 167  
 Vieussens, valve of, 47, 70, 195  
 Villi (*villus*, tuft of hair), choroidal, 186  
   arachnoidal, 184, 190  
 Visual area of cortex cerebri, 110  
   centres, connection with cord and bulb, 119  
     oculomotor nuclei,  
       119  
     interconnection of, 119  
 Voelckers, on oculomotor nucleus, 99  
 Volkmann, on nerves of arachnoid, 189
- WAGNER on grey cortex, 176  
 Weight of brain, 178  
   spinal cord, 180  
 Weisbach on orbital sulcus, 149  
   weight of brain, 178  
 Wernicke on nucleus caudatus, 132  
 Westphal and Edinger, nucleus of, 99  
 White columns of cord. *See* COLUMNS.  
   commisure of cord, 6, 10  
   matter of cerebral hemispheres, structure  
     of, 163  
     cord, 9  
     microscopic structure of, 12  
     proportion of to grey, 7, 10  
   plexuses, 169  
   substance of cerebellum, 71, 78, 87, 91  
     commissural fibres in, 84  
     nuclei in, 83
- Worm, 69, 71, 73, 74, 77, 78  
   effects of extirpation, 94
- ZONA incerta, 114  
 Zuckerkandl on bordering gyri, 159  
   olfactory bundle, 158  
   gyrus geniculi, 158  
   supracallosus, 158  
   subcallosus, 159

END OF PART I.















