


Presented by
Harriet L. Connor, D. O.



COLLEGE OF OSTEOPATHIC PHYSICIANS
AND SURGEONS • LOS ANGELES, CALIFORNIA



Digitized by the Internet Archive
in 2007 with funding from
Microsoft Corporation

GYNECOLOGICAL DIAGNOSIS

GYNECOLOGICAL DIAGNOSIS

BY

WALTER L. BURRAGE, A.M., M.D. (HARV.)

Fellow of the American Gynecological Society; Member of the Obstetrical Society of Boston; Consulting Gynecologist to St. Elizabeth's Hospital; Formerly Visiting Gynecologist to St. Elizabeth's and the Carney Hospitals; Electro-Therapeutist and Surgeon to Out-Patients, Free Hospital for Women; Clinical Instructor in Gynecology, Harvard University, and Instructor in Operative Gynecology in the Boston Polyclinic

WITH TWO HUNDRED AND SEVEN TEXT ILLUSTRATIONS



NEW YORK AND LONDON
D. APPLETON AND COMPANY

1910

COPYRIGHT, 1910, BY
D. APPLETON AND COMPANY

PRINTED IN NEW YORK, U. S. A.

“Find out the cause of this effect—
Or rather say, the cause of this defect,
For this effect defective comes by cause.”

—*Hamlet*, Act ii, Scene 2.

24
~~D~~
1910

3-10-54
Carron J. O
Supt. H. Austin

P R E F A C E

SOME years ago a prominent surgeon who had been attending one of my clinics, remarked when the clinic was over: "I think I understand the treatment and I know how to do most of the gynecological operations, but where I find great difficulty is in the diagnosis."

At the present time the medical profession is devoting an ever-increasing amount of attention to diagnosis, and it seems fitting to describe at length this somewhat blind subject, gynecology, for the benefit of those who have not had an opportunity to study it in the special hospitals and clinics.

A practical text-book, embodying simplicity of technique and concise statement of essentials, has been the aim. The methods of procedure of the pathological and bacteriological laboratories have been omitted because of the assumption that the physician in making a diagnosis has always at his command the services of a trained pathologist and bacteriologist, or can consult text-books devoted exclusively to these subjects. The attempt has been made to keep in the background the rare diseases which are of so much interest to the specialist and to give prominence to the common affections usually met by the general practitioner. While the book is written entirely from the clinical point of view, the salient points of the anatomy and the latest views of the pathology have been summarized at the beginning of each chapter, and the literature has been scanned for new ideas of value to the practitioner.

The differential diagnosis is entered into extensively and is summarized in many places in the form of tables of parallel columns.

Particular attention has been paid to the diagnosis of the diseases of the bladder and of the rectum because of my belief that these organs are too often neglected. A chapter on diseases of the breast has been included because the breast is a part of the reproductive system in women and has intimate relationship with the uterine organs. The importance of the recognition of uterine disease in early life, which, when undiscovered, frequently causes disastrous results later, has led to the writing of the chapter on the gynecological affections of infancy and childhood. In the preparation of this chapter I have been fortunate in having the assistance of my friend, Dr.

John Lovett Morse, who kindly revised the manuscript. The chapter on the menopause is an attempt to shed light on this important but little understood period of woman's life.

An original feature of the book is an alphabetical index of illustrations—of which there are two hundred and fifteen—in the front. Thus the reader can find any desired figure without laboriously going through the entire list. The attempt has been made to place each figure next to the text it illustrates and all references to figures, as well as to subjects cited in other parts of the book, are accompanied by page numbers. Every chapter is headed by a résumé of its contents with page references, and all the illustrations, as well as the titles of the subject-matter, are also included in a very full index at the end.

The views here expressed and the methods described are those that have found favor in my practice, and they are put forward not with the feeling that they are new, original, or all-inclusive, but that having proved useful to me they may help others also to unravel the knotty problems of gynecology.

My thanks are due to Dr. Howard A. Kelly, Dr. E. C. Dudley, and the other authors who have kindly loaned illustrations from their works; to Dr. Henry T. Hutchins for revising the chapter on malignant diseases of the uterus and the section on the collection of the discharges and tissues for microscopic examination; to Dr. Howard W. Beal for assistance with the section on indirect cystoscopy; to Miss Florence L. Spaulding and Miss Ruth O. Huestis for original drawings; and especially to Messrs. D. Appleton and Company, who have shown never-failing courtesy and who have assisted in every possible way in the making of the book.

WALTER L. BURRAGE.

BOSTON

CONTENTS

PART I

GENERAL CONSIDERATIONS

	PAGE
CHAPTER I. INTRODUCTION	3
CHAPTER II. THE CLINICAL HISTORY	5
CHAPTER III. THE INTERPRETATION OF THE CLINICAL HISTORY . .	9
CHAPTER IV. THE PHYSICAL EXAMINATION	23
I. The preparation of the patient.—II. The preparation of the examining table.—III. The examination: 1. Preparation of the physician and placing the patient on the table. 2. Inspection of the external genitals. 3. Palpation.	
CHAPTER V. THE PHYSICAL EXAMINATION (<i>Continued</i>)	43
III. The examination (<i>continued</i>): 3. Palpation (<i>continued</i>). 4. Odor as a diagnostic sign. 5. The collection of the discharges and tissues for microscopic examination.	
CHAPTER VI. THE PHYSICAL EXAMINATION (<i>Continued</i>)	64
III. The examination (<i>continued</i>): 6. Inspection of the abdomen. 7. Palpation of the abdomen. 8. Percussion of the abdomen.	
CHAPTER VII. THE PHYSICAL EXAMINATION (<i>Concluded</i>)	77
III. The examination (<i>continued</i>): 9. Instruments and their use in diagnosis.	
CHAPTER VIII. THE INVESTIGATION OF THE URETHRA, BLADDER, AND URETERS	99
CHAPTER IX. THE INVESTIGATION OF THE RECTUM	121
CHAPTER X. THE SIGNIFICANCE OF THE CHIEF SYMPTOMS OF PELVIC DISEASE	127

PART II

SPECIAL DIAGNOSIS

	PAGE
CHAPTER XI. THE DIAGNOSIS OF ENDOMETRITIS, INCLUDING GONORRHEA AND EROSIONS OF THE CERVIX UTERI	165
CHAPTER XII. THE DIAGNOSIS OF PELVIC INFLAMMATION (PELVIC PERITONITIS AND PELVIC CELLULITIS)	187
CHAPTER XIII. THE DIAGNOSIS OF CONGENITAL ANOMALIES OF THE UTERUS, LACERATION OF THE CERVIX UTERI, AND DISEASES OF THE UTERINE LIGAMENTS	197
CHAPTER XIV. THE DIAGNOSIS OF MALPOSITIONS OF THE UTERUS	215
CHAPTER XV. THE DIAGNOSIS OF FIBROID TUMORS OF THE UTERUS	244
CHAPTER XVI. THE DIAGNOSIS OF MALIGNANT DISEASES OF THE UTERUS	266
CHAPTER XVII. THE DIAGNOSIS OF DISEASES OF THE OVARIES	284
CHAPTER XVIII. THE DIAGNOSIS OF DISEASES OF THE FALLOPIAN TUBES	324
CHAPTER XIX. THE DIAGNOSIS OF EXTRA-UTERINE PREGNANCY	340
CHAPTER XX. THE DIAGNOSIS OF DISEASES OF THE VAGINA	354
CHAPTER XXI. THE DIAGNOSIS OF DISEASES OF THE VULVA	388
CHAPTER XXII. THE DIAGNOSIS OF UTERINE PREGNANCY, ABORTION, AND HYDATIDIFORM MOLE	417
CHAPTER XXIII. THE DIAGNOSIS OF DISEASES OF THE URETHRA	444
CHAPTER XXIV. THE DIAGNOSIS OF DISEASES OF THE BLADDER	457
CHAPTER XXV. THE DIAGNOSIS OF DISEASES OF THE URETERS	486
CHAPTER XXVI. THE DIAGNOSIS OF DISEASES OF THE RECTUM	494
CHAPTER XXVII. THE DIAGNOSIS OF DISEASES OF THE BREAST	531
CHAPTER XXVIII. THE DIAGNOSIS OF THE GYNECOLOGICAL AFFECTIONS OF INFANCY AND CHILDHOOD	555
CHAPTER XXIX. THE MENOPAUSE AND OLD AGE	587
INDEX	627

LIST OF ILLUSTRATIONS

	FIG.	PAGE
ABDOMEN, cavity of, shape of	86	221
division of, into quadrants and indication of bony landmarks	18	65
organs of, origin of tumors in	129	304
Anal canal	191	495
cast of	192	496
Anal region, diagram of	195	515
Applicator, uterine	37	93
Ascites, abdomen of, seen in profile	131	307
cross section of, dorsal position	132	310
lateral position	133	311
BARTHOLIN'S gland, cyst of left	174	409
Bartholin's glands, abscess of	176	411
abscess of ducts of	175	410
Bladder, ballooned by air, patient in knee-chest position	54	112
base of, showing diverticula	185	458
normal, laid open from in front	51	106
overdistended	84a	217
papilloma of	190	482
stone in	186	463
tuberculosis of ureteral orifice in	187	469
varix of	188	474
Bladder phantom, for practising cystoscopy	58	118
Blood vessels, uterine and ovarian	8	47
Body, vertical median section of	6	44
of childbearing woman	84	216
Breast, diffuse bilateral hypertrophy of	201	541
dissection of lower half of, showing milk ducts	198	534
division of, into quadrants	200	538
lymphatics of	199	535
right, vertical section of	197	533
scirrhus cancer of	202	547
CALBRATOR, meatus, Kelly	44	101
Caruncle myrtiformes	165	397
Catheter, bladder, long silver	43	101
ureteral, Kelly	48	103
Cervix, adeno-carcinoma of canal of, early stage	111	268
cancer of, early stage	110	267
erosion of, with lacerations	69	185
fibroid of	108	254
hypertrophic elongation of	88a	225

	FIG.	PAGE
Cervix, laceration of, bilateral, with erosions	79	205
crescentic	81	207
stellate	80	206
unilateral (diagram)	83	209
with eversion of lips (diagram)	82	209
prolapse of	88	224
squamous-celled cancer of, early stage	110	267
supravaginal, elongation of	88	224
Controller, current, for use with electric cystoscope	57	117
Curette, uterine	31	90
Cylinder, vertical, filled with fluid, representing abdominal cavity	7	45
Cystocele	148	367
diagram of	148a	368
Cystoscope, bladder, Kelly	49	104
ureter, Nitze	56	116
Cystoscopy, modified knee-chest position used in	53	111
removing urine from bladder in, by suction apparatus	55	113
DECIDUA, uterine, in extra-uterine pregnancy	143	345
Depressor, vaginal, Hunter	29	89
Dilator, urethral, double-ended, Kelly	45	102
uterine, Wathen	34	92
uterine, Hanks	33	91
ENDOMETRIUM, normal	65	167
Enteroptosis, body pose in	19	67
Evacuator, bladder, Kelly	46	102
wash-bottle, Kelly	55	113
Extra-uterine pregnancy, ampullar, early	140	341
mole and fetus removed	141	342
ampullar, late	145	350
isthmal, section of uterus of	146	352
FALLOPIAN tubes, development of, in fetus	71	198
Fissure in ano	194	504
Fistula in ano, blind internal	196a	517
complete	196	517
Fistula, genital, scheme of, after Dudley	189	476
after Gilliam	155	385
Forceps, bladder, alligator	50	105
curette, Emmet	30	89
rectal, alligator	62	125
uterine dressing, Bozeman	23	83
vulsellum	25	84
GAUZE records of abdominal tumors	20	75
Genital organs, development of, five diagrams illustrating	158	162 395
external, at beginning of third month	157	392
Gland, Bartholin's, cyst of left	174	409

	FIG.	PAGE
Glands, Bartholin's, abscess of	176	411
abscess of ducts of	175	410
HAND, examining, showing protective sleeve	2	31
Hegar's method of palpating pedicle of ovarian tumor	126	301
sign, bimanual palpation for	179	425
Hematocele, pelvic	142	343
Hematocolpos, diagram of	171	398
Hematometra, diagram of	172	398
Hematosalpinx	139	335
diagram of	173	399
Hemorrhoids, types of	193	499
Hydatidiform mole	182	442
Hydrosalpinx	138	334
Hymen, different forms of	163-170	397
INTERSTITIAL pregnancy	144	346
Irrigator, uterine, Bozeman-Fritsch	35	92
Isthmial tubal pregnancy, section of uterus of	146	352
LIGAMENTS, utero-sacral, course of, in intraligamentous tumor	135	317
in retroperitoneal tumor	134	316
MATURITY, precocious, case of	207	565
"Milk line,"	200	538
Os, external, parous	66a	169
virginal	66	168
Ovaries, infantile	117	286
Ovary, cyst and tumor regions of	120	290
cyst of, adherent, arrangement of peritoneum in	124	292
intraligamentous, arrangement of peritoneum in	123	292
pedicle, arrangement of peritoneum in	122	292
very large, showing emaciation and "facies ovarina"	125	294
normal, pedicle, arrangement of peritoneum in	121	292
of mature woman	118	287
senile	119	289
tumor of, cross section of body of	127	302
tumors of, Hegar's method of determining relation of, to uterus	126	301
pedicle, formation of (4 diagrams)	121-124	292
Ovary and tube seen from behind	116	285
PAROVARIUM, large cyst of, seen in profile	128	303
Pelvimeter	42	98
Pelvis, contents of, from above	9	48
female, normal	9a	50
showing accessibility of contents to palpation	10	52
with hand in position as for vaginal examination	4	37
floor of, diagram showing structures of	150	373
of new-born child, longitudinal median section of	204	558

	FIG.	PAGE
Perineum, laceration of, complete median	151	374
partial lateral	152	375
Peritoneum, reflections of folds of, in pelvis	70	189
Position, dorsal	3	32
knee-chest	13	56
bladder, vagina, and rectum ballooned by air in	54	112
modified for cystoscopy	53	111
side-view, showing vertical thighs	14	57
lithotomy	15	58
raised pelvis	16	59
Sims	11	53
diagram of	12	54
standing	17	60
Precocious maturity, case of	207	565
Pregnancy, extra-uterine. See Extra-uterine pregnancy		
interstitial	144	346
tubal, early ampullar, abortion in	140	341
mole and fetus removed from tube	141	342
isthmal, uterus of	146	352
late ampullar, four months'	145	350
section of uterus, showing decidual modification in	146	352
Probe, uterine	22	82
Procidencia	87	223
Proctoscope, long	61	124
short	60	123
Pyosalpinx	137	333
RECTOCELE	149	369
diagram of	149a	370
Rectum, ballooned by air, patient in knee-chest position	54	112
lower part of, diagram of	195	515
SALPINGITIS, tuberculous	136	331
Searcher, ureteral, Kelly	47	102
Sound, uterine	21	78
Separator, urine, Luys	59	119
Speculum, bivalve. See Speculum, vaginal, Brewer and Graves		
rectal, Sims	63	126
uterine, Burrage	36	93
vaginal, Brewer	26	87
Edebohls	32	91
Graves	27	87
Sims	28	88
TABLE, examining	1	27
Tenaculum, uterine	24	83
Touch, bimanual, diagrammatic drawing	5	38
Tubercles of bladder wall	187	469

	FIG.	PAGE
URETER, orifice of, jet of urine spurting from	52	107
Urethra, caruncle of	184	454
mucous membrane of, prolapse of	183	449
Uterine organs of an infant at birth seen from above	205	562
Uterus, anteflexion of, in the little girl	90	230
pathological	91	231
bicornis	74	199
bicornute, one external os, two uterine cavities	78	201
bipartitus	72	199
body of, adeno-carcinoma of, early stage	112	269
horizontal section of upper part of	67	171
sarcoma of	113	279
cavity of, Kelly's methods of exploration of, exploring with finger	41	97
incising anterior wall	39	95
transverse incision anterior to cervix	38	94
laid open	40	96
chorioepithelioma of posterior wall of	114	281
development of, in fetus	71	198
didelphys	73	199
double, with double vagina	147	358
fibroids of, interstitial and submucous	104	248
intraligamentous	105	249
large tumor filling pelvis and simulating pregnancy	109	256
multiple	102	246
polyp in vagina, large	107	252
submucous, large, showing distortion of uterine cavity	106	250
simulating inversion	101	245
pedunculated, simulating inversion	99	241
simulating partial inversion	95	241
subserous, side view of abdomen containing large tumor	103	247
tumor of cervix	108	254
fundus of, height at various weeks of pregnancy	130	306
inversion of acute puerperal	93	239
complete	98	241
with pedunculated subserous fibroid of abdominal evolution	100	241
partial	97	241
caused by submucous fibroid	296	241
of left horn	94	241
normal, position of	6	44
pregnant, enlargement of, in late pregnancy	181	428
pregnant at sixth week, diagrammatic side view, during contraction	178	423
during relaxation	177	422
section of	178	424
prolapse of	87	223
partial	89	227
reconstruction of, showing shape of uterine cavity and cervical	64	166
canal	91	231
retroposition with anteflexion	92	235
retroversion of	92	235
caused by overdistended bladder	84a	217

	FIG.	PAGE
Uterus, sarcoma of	113	279
section of, in isthmal tubal pregnancy	146	352
transverse longitudinal	68	172
septus	75	199
unicornis	76	199
with accessory cornu	77	199
VAGINA, ballooned by air, patient in knee-chest position	54	112
chorioepithelioma of, metastatic	115	282
cyst of anterior wall of	154	381
cyst of posterior wall of	153	380
development of, in the fetus	71	198
double, with double uterus	147	358
infantile, examination of, with cystoscope	205	559
longitudinal section of, showing S-shaped curve	85	219
prolapse of	88	224
Vulva, at beginning of third month of fetal life	157	392
diagram of	156	389
infantile	203	556

PART I
GENERAL CONSIDERATIONS

CHAPTER I

INTRODUCTION

DIAGNOSIS, the foundation of gynecology, is elusive. The consultant frequently hears it said by the attending physician, "Doctor, I know how to do this operation, but what puzzles me is to know when it is indicated."

The educated touch is the keystone of the diagnostic arch; symptomatology, sight, instrumentation, microscopic findings, are but accessories. To train the touch requires time and application. As in learning any handicraft, the beginning is of great importance. Those who neglect to perfect themselves in the proper technique at the start, who never acquire "good form" as they say in athletics; never progress beyond a moderate degree of excellence. The practitioner who persists in making the bimanual examination with the patient in bed or on a yielding surface, or neglects to incommode her to the extent of causing to be loosened all clothing about the waist, never becomes a good diagnostician. The reasons for this will appear later.

There is no department of medicine in which the patient is less able to judge from her own observation of the correctness of the diagnosis than in gynecology. Unlike the dermatologist, for example, the gynecologist does not have trained upon his work the critical eye of his patient.

She is unable, also, to judge of the nature of the treatment employed. It is especially easy for a physician who has made an error in diagnosis to persist in a chosen line of treatment without discovering his mistake, for the relations between cause and effect are often most shadowy; also, consultations are relatively infrequent in this department of medicine. Because of the delicate nature of the confidences called for, and the sensitive portion of the anatomy involved, the patient shrinks from subjecting herself to repeated examinations at the hands of different physicians.

We have to do in this book with the question of diagnosis alone and it will be my endeavor to point out how best to make it. More stress will be laid on the interpretation of symptoms and signs in the light of experience than is usual in text-books on gynecology because it is thought thereby to help the practitioner.

That pathological conditions may exist without any symptoms at all should never be forgotten. For instance, a woman may have a double uterus, detected for the first time at the gynecological examination which follows labor, or a patient may have a small dermoid tumor of the ovary, discovered only when she comes to the physician to learn why she has never had children.

A judicious combination of the deductive and inductive methods seems to be the most practical way of presenting the subject; a result accomplished by describing the steps of the examination and the processes followed in arriving at a diagnosis, as nearly as may be, as they occur in actual practice.

Particular attention is paid to the minutiae of the history-taking, the management of the patient, and the smallest details of the examination, because of my belief that matters which seem trivial to many are in reality the solid groundwork of a correct diagnosis.

Mistakes in diagnosis are unavoidable even in the experience of the most expert. To make a mistake because an inadequate examination was made or no examination at all is an unpardonable sin. Experience teaches that finality in diagnosis is not always a possibility in gynecology, and even after the most painstaking history, analysis of the symptoms, and physical examination, we may fail to distinguish between two or three possible conditions. Our object is to reduce the uncertain cases to a minimum.

CHAPTER II

THE CLINICAL HISTORY

Method of getting the history, p. 5. Case-record systems, p. 6. Form for case records, p. 6.

METHOD OF GETTING THE HISTORY

MANY busy practitioners slight the clinical history, the taking of which should precede every physical examination. This is a mistake which carries its own retribution in the form of a slipshod diagnosis. A clear and exhaustive history not only serves as a guide in making the physical examination, but also develops symptoms which otherwise may be overlooked. There are few cases which are not better diagnosed by a careful preliminary questioning of the patient. The physician gains his patient's confidence, so necessary for a successful physical examination. If she becomes prolix or strays from the important point, a question will often bring her back. It is well to note especially, perhaps by underlining, the symptoms that seem most important to her, so that in subsequent interviews these may be under special observation. It is generally better to talk with the patient alone when getting the history, as there are important facts which will be suppressed if a third person, whether a nurse or a relative, be present. Sometimes it happens, however, that important facts are to be obtained from the husband, and, in the case of a young girl, from the mother. A desirable practice is to review the history after the physical examination in the light of the facts brought out by the examination and to cross-question the patient as to the truth. Avoid, as far as possible, asking leading questions and assenting too readily to the answers. Be sure that the answers represent the truth.

CASE-RECORD SYSTEMS

A good method for case records is the envelope, card-catalogue system. A filing cabinet with several drawers is obtained. Large, ungummed envelopes, and also a set of cards just fitting into the envelopes and the drawers as well, are procured. For use at the bedside it has been my custom to carry in a leather pocket-case a block of prescription blanks, six by four inches, which fit the envelopes of my filing cabinet. At the office I use cards of the same size. Every card and envelope is marked on the left-hand top corner with the patient's name and filed alphabetically in the cabinet. One advantage of the envelope system is that additional memoranda, such as notes on treatment and other data, may be filed in the same envelope, and it is not necessary to copy the notes taken at the bedside before filing them.

Many gynecologists have printed case sheets, either in a book or as loose pages or cards. It is well to have some schedule to follow so that the same order may be observed in all cases and important facts may not be omitted. To the beginner a printed form is invaluable, but to the physician of experience it is hardly worth while to take up desirable room on the cards with printing which may be of no use in many of the cases. The object is to get a schedule in mind, rather than to have it printed before you.

FORM FOR CASE RECORDS

Date :

Name in full :

(In the case of a married woman both own first name and husband's first name for purposes of future identification.)

Address :

Nationality :

Occupation :

Age :

Social Condition : Single.

Married. (how many years)

Widow : (how many years)

Children : (how many and ages)

Miscarriages or abortions : (number, and at what weeks or months of pregnancy.)

Diagnosis:

Family History.—General predisposition to cancer, lung trouble, heart disease, kidney disease, or rheumatism. If the parents are dead, what were the causes of death. Early or late occurrence of the first menstruation and of the menopause, or the occurrence of dysmenorrhea or uterine disease in sisters or female relatives.

Previous History.—Special reference to gynecological affections; as attacks of vulvar inflammation, or smarting with micturition, as indicating gonorrhoea; "inflammation of the bowels," as indicating pelvic inflammation; lack of control over the bowels or bladder, showing injury of the sphincter ani or of the pelvic floor; the account of any operation which may have been performed on the genital organs. The infectious diseases may point to inflammatory affections of the vulva and vagina in childhood.

Menstruation.—Age at which first menstruation occurred; whether normally established, the subsequent rhythm, duration, quantity, and quality of the flow; whether accompanied by pelvic pain, if so, the situation, character, and duration of the pain, also whether before, during, or after the flow; whether disturbances of other functions at the time of menstruation, as nausea, headache, depression of spirits; any recent irregularities in the rhythm, quantity, or character of the flow; intermenstrual pain, if so, exact dates of beginning and end of pain. Is menstruation accompanied by leucorrhoea, or not.

Vaginal Discharge.—Character, amount, when most in quantity, duration.

Pain.—Other than menstrual, situation, duration, character.

Confinements, Miscarriages, and Abortions.—Labors normal, rapid, tedious, or instrumental; whether injuries received or symptoms suffered; convalescence normal or not; stitches taken, fever following. Miscarriages or abortions, dates of occurrence and at what weeks of pregnancy; supposed cause or causes; attended by much flowing or fever; convalescence, good or bad.

Bladder Symptoms.—Frequency of micturition by day and by night; smarting on urination; control of urine on laughing and coughing and on standing and walking; pain in region of bladder on micturition; color and quantity of urine passed.

Present Illness.—Duration; particulars as to present symptoms such as pain, situation, character; leucorrhoea, when first noticed,

character, as thin, glairy, thick, purulent, bloody, or offensive; whether constant, or before and after menstruation.

Date of the Beginning of the Last Menstruation.

Abdominal Swelling.—When first noticed, progressive increase in size, stationary or smaller, painful or not.

Bowels.—Regular movement every day or constipated; full action or scanty; liquid, semi-solid, or solid stools; offensive odor; gas in bowels; blood, mucus, or pus with the stools; painful defecation.

General Health.—Appetite, digestion, sleep; whether an increase or decrease in body weight; headache; backache.

The General Appearance of the patient should be noted as regards height, approximate weight, complexion, color of lips, peculiarities of form, if any.

Analysis of Urine.

Treatment Advised.

CHAPTER III

THE INTERPRETATION OF THE CLINICAL HISTORY

The address, nationality, and occupation, p. 9. Age, p. 9. Social condition, p. 10. Dyspareunia, p. 11. Children, 11. Family history, p. 12. Previous history p. 12. Constitutional diseases, p. 12. Chief complaint and present illness, p. 13. Menstruation, p. 13; Puberty, p. 14; The menopause, p. 16; The atrophic changes in the genital organs and the body alterations of the menopause, p. 17. Vaginal discharge, p. 18. Pain, p. 18: Backache, p. 18; Muscular rheumatism, p. 19; Coccygodynia, p. 19; Pains in the groins, p. 19. Abdominal swelling, p. 20. Bladder symptoms, p. 20. The bowels, p. 21. Present illness, p. 22.

THIS is a chapter of probabilities; not instructions how to make an offhand diagnosis, but a sifting of the evidence as it is presented, the diagnosis being held in reserve until after the physical examination, and until after any supplementary evidence has been elicited in the way of answers to questions which may be suggested by the examination.

A knowledge of the normal conditions is essential, if the value of the abnormal symptoms is to be estimated correctly.

The Address.—This is important not only as a matter of business but as showing the possible effect on the patient's health of a healthy or an unhealthy locality.

Nationality.—The colored race is especially prone to fibroids. Cancer is seldom found in a negress.

Occupation.—Confinement in poorly lighted and ventilated workshops, long working hours, heavy lifting, insufficient food and prolonged standing on the feet aggravate, if they do not cause, pelvic disorders. On the other hand, a sedentary life with no real exercise may act as a contributory cause of pelvic disease.

Age.—The age of the patient suggests the special disturbances found in the various epochs of life. In infancy malformations and inflammations of the lower genital tract are to be expected. At this time the infections are generally limited to the vulva and vagina, and tumors, displacements, and traumatisms seldom exist. Vulvo-vaginitis is not uncommon in little girls.

Failure of the menses to appear previous to the sixteenth year should excite no apprehension: after that it is apt to indicate underdevelopment of the uterine organs.

During the period of sexual maturity nearly all of the lesions of the genital organs may be found. The effects of gonorrhœa are seen most often between the ages of twenty and thirty. Tumors of the breast are most frequently malignant between the ages of forty and sixty. Under the age of thirty-five a large abdominal tumor is more likely to be ovarian; after that age it is more apt to be a uterine fibroid.

A patient suffering from uterine hemorrhage more probably has endometritis or a polypus if under twenty; a polypus or some condition resulting from gestation, from twenty to thirty; fungous endometritis, polypus, or fibroids from thirty to forty; fibroids and malignant disease from forty to fifty. After fifty, malignant disease is the probability.

Social Condition.—Congenital malformations may be brought to the patient's attention for the first time after marriage. Certain inferences may be drawn from the single or the married state of a patient as regards the cause of menorrhagia or metrorrhagia, as shown by the tables on pages 137 and 139, Chapter X., also as regards leucorrhœa, as found on pages 144–146. Pregnancy is always to be considered if the patient is not a virgin. An early question as to the patient's social state, whether single, married, or a widow, may obviate embarrassing queries as to sexual relations and may throw light on the possible causes of her complaints. For instance, a recently married woman, always a sufferer with dysmenorrhœa, finds the symptom aggravated and unbearable since her marriage. A periodic pelvic congestion, due to malposition or malformation of the uterus, has been accentuated by the congestion which attends sexual relations. A recently married woman complains for the first time of smarting on urination, and leucorrhœa. Suspicion of infection with the gonococcus at once arises in the physician's mind. The possibility of pregnancy or venereal infection should never be lost sight of, notwithstanding the patient's statement that she is single or a widow, great caution and tact being exercised, however, in making inquiries. The final question as to the truth or falsity of the suspicion should be left until after the physical examination in any event, and in many

cases can not be made at all without causing serious and unjustifiable trouble in the family of the patient.

Dyspareunia.—Dyspareunia dating from the time of marriage indicates smallness of the introitus vaginæ or urethral caruncle, if the pain is at the beginning of coitus. If the pain is experienced after the penis has been introduced into the vagina the cause is apt to be pelvic inflammation or a tender cervix or ovary.

Children.—*Sterility.*—The absence of children may be important, for if a patient has been married many years and has not been pregnant, the inference is that the cause of the sterility rests with her and not with her husband, the latter being in good health, and we may expect to find some underdevelopment or malformation of the sexual organs. If there is any doubt as to the husband's virility a specimen of his semen should be examined for spermatozoa before subjecting the wife to gynecological treatment. (See Chapter X., page 147.)

Carcinoma of the cervix, common in parous women, is rare in nulliparæ, whereas cancer of the body of the uterus is more apt to occur in women who have not borne children. Complete or relative sterility is often found in women suffering with fibroids.

Number of Children.—The number of children a woman has had is important because child-bearing without a sufficient interval of recuperation between the labors frequently results in some sort of pelvic ailment. Therefore, note the ages of the children. The history of each confinement is of the greatest service in determining the origin of a pelvic inflammation, a misplacement of the uterus, or lacerations. A difficult forceps delivery followed by fever and a tedious convalescence may mean all three, though not necessarily.

Miscarriages and Abortions.—A history of each miscarriage or abortion should be secured with reference to the birth of children; if before, the interruption of labor can not be due to injuries received at labor: if subsequent to a difficult and complicated confinement, an abortion may well be caused by the labor. The probable cause of an abortion in the patient's estimation, whether attended by hemorrhage or fever and how long the patient was confined to her bed, are points to be ascertained. These facts often reveal the starting point of an attack of pelvic inflammation, or anemia and subsequent debility due to loss of blood. If repeated

abortions have occurred they may indicate syphilis, tuberculosis, or a deeply lacerated cervix.

Family History.—How much of a rôle heredity plays in the etiology of pelvic disease is not determined. Cancer and tuberculosis are found occasionally in members of the same family. It sometimes happens that several sisters will all have a similar lesion of uterine underdevelopment. I have seen three sisters, each suffering from marked pathological ante flexion. A premature or delayed occurrence of the menopause is frequently a family characteristic. So is the symptom of dysmenorrhœa. Family history, as a rule, does not have an important influence on diagnosis.

Previous History, on the other hand, is of great importance. We have noted how an abortion may be the starting point of an attack of pelvic inflammation to be followed, perhaps years later, by serious lesions of the pelvic organs. So a history of "inflammation of the bowels," without assignable cause, may mean pelvic inflammation, the nature of the treatment employed at the time of the attack throwing some light on the probable diagnosis.

An attack of soreness of the vulva associated with a purulent discharge, with or without smarting on urination, may well mean gonorrhœa.

Adhesions of the labia minora, and of the prepuce to the clitoris, and even imperforate hymen, may be caused by inflammation of the vulva in childhood due to diphtheria, scarlet fever, measles, or gonococcus infection. Nocturnal enuresis is caused, sometimes, by adhesions of this sort. Therefore, when possible, the mother of the patient should be questioned whether her daughter had vulval soreness and discharge when a child.

A lack of control over the bowels when loose, during the months following a labor, leads us to expect to find injury of the sphincter ani, also inability to control the urine when standing, or on laughing and coughing, make us look for injury of the vaginal wall and perineum and dislocation downward of the urethra.

Injury of the pelvic floor is present if the patient complains of the noisy escape of air from the vagina when she suddenly changes the position of her body, or strains.

Constitutional Diseases.—All general constitutional diseases have a bearing both as causative agents and aggravating influences on pelvic disorders; therefore they should be inquired into in getting

the history. It so often happens that a woman in her usual good health is not seriously incommoded by a pelvic lesion and when pulled down by a long illness is overwhelmed by uterine symptoms. The physician should move slowly in drawing conclusions as to cause and effect, and also in judging of the weight to be attached to the uterine disease.

It should never be forgotten that the whole is greater than any one part and that general constitutional diseases take precedence over gynecological affections. It is the sick woman we are to treat.

Chief Complaint and Present Illness.—It is very easy for the enthusiastic specialist to bend his energies to the making of a new ostium to a diseased Fallopian tube, or to the resection of a diseased ovary, quite forgetting for what the patient consulted him; that because he has found an abnormality of the pelvic organs, this must of necessity be the cause of the symptoms. He loses sight of the symptoms and doesn't always make a proper effort to relieve them, being led away on a futile hunt for anatomical perfection. Note, then, your patient's chief complaint, and when you have finished with the case, turn to your notes, refresh your memory, and see whether this complaint has been relieved.

The duration and character of the present symptoms should be noted, such as pain, leucorrhœa, abdominal swelling, and symptoms relating to the bowels or bladder, and do not slight the indications of the state of the general health as shown by the amount and character of the sleep, the state of the digestion, and the strength to accomplish customary daily tasks.

Menstruation.—Menstruation may be defined as a discharge of bloody fluid which takes place from the uterus at stated periods throughout the time of sexual activity in the life of women. The causation of the discharge is still in doubt.

Fränkel ("Die Function des Corpus luteum," *Archiv für Gyn.*, LXVIII., 1903, 438) considers that the corpus luteum in the ovary has a determining influence on menstruation. It is plain that the ovaries have something to do with this function because, when they are removed, menstruation ceases. As menstruation occurs only in human beings and some of the higher apes, it is difficult to settle the relation of menstruation to ovulation and to the normal or abnormal corpus luteum by animal experimentation.

The mechanism of menstruation consists of a diapedesis of

blood through delicate capillaries, newly formed in a thickened and congested endometrium, the vessels for the arterial supply being more capacious than those for the venous return. Some of the capillaries rupture and the blood flows out.

The flow at first is mucus streaked with blood, during the height of menstruation it is blood mixed with a little mucus, and toward the end it becomes more mucous in character. Menstrual blood is dark in color, alkaline in reaction, and, because of the mucus it contains, does not clot unless the mucus happens to be deficient. The mucus renders it more watery than ordinary blood. It has a peculiar odor given to it by the sebaceous glands of the vulva which are especially active during menstruation.

Puberty.—The average age at which menstruation is established, in temperate climates, is fourteen years. Variations of a year or two from this type occur within normal limits. It occurs earlier in the city girl who is subjected, perhaps, to intimate association with the other sex and to sexual temptations, than it does in the country girl, or in a girl carefully brought up in comparative seclusion. This rule applies to the lower animals. If a bull is placed in the pasture with a herd of heifers, heat appears earlier in the heifers than it does when they are segregated. In women of strong sexual passion the function of menstruation is established earlier and lasts longer than common.

The discharge of ova from the Graafian follicles of the ovary has been known to take place before menstruation is established, and it may continue after the menopause. The functions of menstruation and ovulation are not directly dependent one on the other, but both appear to be governed by the same portion of the sympathetic nervous system. Cases of precocious menstruation are occasionally reported, and it has been known to occur as early as a few days after birth. There are many cases on record of menstruation at a few weeks or months of age. Development of the external genital organs and the breasts, increase in body size, and often the growth of hair on the pubes goes with precocious menstruation. The diagnosis is not established unless the loss of blood recurs at monthly intervals and a physical examination of the child shows evidences of premature development.

It is unusual for menstruation to be established before the twelfth year. On the other hand its appearance is seldom delayed beyond

the eighteenth year. A case is on record, however, where a woman married at thirty-four, menstruated for the first time at forty-five, and bore a child at forty-six. According to the investigation of Rossi-Doria, an Italian physician, who recorded the data in over thirty thousand women, delayed menstruation goes hand in hand with pelvic disease. He found 39.21 per cent of pelvic malformations in women who had not menstruated until twenty years or over.

The normal rhythm of menstruation is a lunar month of twenty-eight days. A woman may enjoy perfect health in every respect and yet vary many days from the normal rhythm. Many women menstruate every three weeks, others every five weeks, with perfect regularity. In getting a history of the menstrual function it is necessary to specify the rhythm of the flow as well as the regularity. It is well to remember also that some women are regular at times and irregular at other times.

The duration of the flow is from four to seven days. Here also a variation within normal limits of two days either way is to be noted. The greatest amount of blood is lost in the first two days. A discharge of mucus before and after the flow is common. The average amount of blood lost at a single menstruation is from four to six ounces. It is impracticable to measure this exactly and we are forced to resort to the inexact method of counting the number of napkins used. As the napkins vary in size, are used to the point of saturation by some women and barely stained by others, no definite information can be obtained. Inquiry on these points, however, will give the physician an approximate estimate which should be recorded in detail in his notes. About two well-saturated napkins a day may be considered as being normal.

Whether menstruation is excessive in any given case depends in a certain measure on the physique of the patient; a full-blooded, plethoric woman may menstruate eight or nine days, using three or more well-saturated, large napkins a day: while an anemic, thin woman may be depressed by the amount of blood lost in a period of four days, using two napkins a day.

The character of the flow is of importance. Note clotting, an acid reaction, a bright arterial color, and any change in odor.

Attendant disturbances of other functions, before, during, and after menstruation, such as nausea, headache, depression of spirits,

variations in the action of the bowels or bladder, are very commonly observed, and should be chronicled.

Menstruation is generally attended with a greater or less degree of a sense of fulness and weight in the region of the pelvis; oftentimes a certain amount of pain is to be considered as not abnormal. The menstrual period is a time of instability of the circulation and of the nervous system. The body temperature is slightly elevated, the thyroid gland is enlarged, and the tonsils and vocal cords may be swollen so as slightly to impair the singing voice; so also, in some cases, there are salivation and swelling of the mucous membrane of the turbinate bones at this time. There is increased vascular tension and increased secretion of the sweat glands and of the sebaceous glands, especially those of the external genitals. Some women are affected by skin diseases at their catamenia, notably herpes, or small macular ecchymoses about the flexures of the elbows or knees.

A rhythmical wave of all the physiological processes has been demonstrated by Von Ott. The greatest activity is manifest just before the appearance of the flow, shown by increase of muscular strength, tendon reflexes, lung capacity, and heat production. The least activity is during the flow, the lowest point being reached on the fourth day. There is a slight reaction in the week following the cessation of the flow, an intermenstrual equilibrium of two or three days, to be followed by a gradual rise to a maximum two days before the next flow, and so on from month to month.

The Menopause.—The climacteric or cessation of the flow usually occurs from the forty-fifth to the fiftieth year, the discharge at this time becoming less and less in amount and of irregular occurrence, gradually stopping altogether in from six months to two years. Menstruation may stop short without any period of irregularity and there may be no disturbance of the nervous system, although the latter is more common.

If a woman begins to menstruate early the menopause is apt to be late, and vice versa. It is a family characteristic sometimes to have the menopause early or late. In case of fibroid tumors of the uterus the menopause is commonly delayed until the fiftieth year or later, and in subinvolution and chronic metritis the menopause comes late.

Vasomotor disturbances are to be looked for during the meno-

pause. The monthly rhythm which has existed since the fourteenth year is to be done away with, the sexual organs are to atrophy and become functionless. If the woman is in perfect health we shall expect nature to accomplish the change gradually as it was established, and without an upsetting of the general health. Too often, for one reason or another, the health is not rugged, then ensue hot flashes, sweating, palpitation, headaches, nervous irritability, and derangements of function in many organs, more especially those most closely controlled by the sympathetic nervous system.

It is a mistake to consider uterine hemorrhage as a part of the normal menopause. It seldom occurs unless there is a definite local cause in the shape of a fibroid tumor, a cancer, chronic subinvolution with hyperplastic endometritis, misplacement of the uterus, or other lesion. These uterine diseases may have caused no symptoms, though existent for many years. Search should always be made for them.

The Atrophic Changes in the Genital Organs and the Body Alterations of the Menopause.—The changes in the genital organs and in the body consist of (a) shrinking of the uterus in size. The muscular tissue becomes less thick and gradually the uterine cavity is shortened or even obliterated, the mucosa becoming thinned and the glands reduced in number. The epithelial cells grow smaller and lose their cilia. The vaginal portion of the cervix shrinks and does not project into the vagina. (b) The vagina is shortened and narrowed and its walls lose their elasticity and the mucous membrane its rugæ. (c) The ovaries shrink to small knobs of fibrous tissue, the Graafian follicles disappear, and the Fallopian tubes become mere cords. (d) The fat disappears from the vulva, the labia majora become flabby, and the mons veneris loses its prominence. (e) The pubic hair turns gray after the hair of the head has lost its color. (f) The breasts also atrophy and become flabby, and (g) the body weight is increased.

The menstrual flow may cease prematurely at an early age, even as early as the twenty-fourth year, the causes being general or local. As to the general causes not much is known beyond that they have to do with the nutritive and vascular systems.

The local causes are diseases which destroy the ovaries, as chronic infective inflammation, and removal of the ovaries by operation. It is worthy of remark that when functioning ovaries have been

removed the distressing nervous symptoms of the climacteric are much more severe than when the menopause occurs with the ovaries in place. (The menopause is discussed fully in Chapter XXIX.)

Vaginal Discharge.—Any discharge from the vulva is popularly referred to as leucorrhœa or whites. A certain amount of moisture is normal and is made up of the secretions of the sebaceous and sweat glands of the vulva, the lubricating mucus secreted by the glands of Bartholin lying in the posterior portion of the labia majora, —most active during times of sexual excitement,—and by the secretions of the uterus.

The vagina has no secretion proper and no glands, the vaginal secretion, so-called, being that poured out of the uterus together with epithelium and bacteria made acid by a bacterium which flourishes in the vagina under normal conditions. The fluid is milky and small in amount. The secretion from the cervix is tenacious, transparent, and thick; that from the endometrium of the uterine cavity is clear, transparent, and thin. Both have an alkaline reaction.

Skene's glands at the orifice of the urethra also secrete a mucus, which is thought to protect the meatus urinarius during coitus. Under normal conditions the combined discharge should not soil the clothing except just before and just after the menstrual periods, when all the secretions are increased in amount and may necessitate wearing a napkin.

Abnormal constituents of the vaginal discharge, such as pus or blood, should be noted, also a bad odor or irritating qualities. (This subject is discussed at greater length in Chapter X., page 143.)

Pain.—Pain in gynecological affections is generally situated in the inguinal and lumbo-sacral regions.

Backache.—Backache is not characteristic of any special uterine disease and it may have no relation at all to the pelvic contents. All we can say is that it is very often present in women suffering with gynecological diseases. Backache is very common in women between the ages of thirty and fifty who are in a nervously run-down condition. One sort of backache due to *sacro-iliac subluxation* as described by Joel E. Goldthwait (*Boston Med. and Surg. Journal*, 1905, Vol. 152, 593) must be differentiated from rheumatism of the muscles in the lumbo-sacral regions. The sacro-

iliac articulations are true joints and there is increased mobility in them as well as in the symphysis pubis in women during pregnancy and during menstruation. In certain women, especially those having spinal curvature who are the victims of subluxation, only one sacro-iliac joint is tender to pressure, and the displacement is the cause of backache as well as referred pains in the hip, leg, and ankle on the same side as the loose joint, caused by pressure on the sciatic nerve. These symptoms are not limited to the time of pregnancy and labor, though exaggerated then. The symphysis pubis is generally a loose joint also in these cases and may be painful to the touch, especially during menstruation. The mobility and tenderness of all three joints should be tested in any case of backache.

Muscular rheumatism is detected by tenderness on pressure of the following muscles:—the erector spinæ,—the longissimus,—the sacro-lumbalis, or the quadratus,—and by pain caused by the use of any of these muscles. When a patient with lumbo-sacral rheumatism starts to straighten up, there is great pain, which abates after a few minutes' use. A patient with this affection sits or lies preferably with the body bent forward.

Coccygodynia is a painful affection of the coccyx and is characterized by pain between the folds of the buttocks and by tenderness on pressure applied to the tip of the coccyx. (See page 159.)

Pain in the groins is common in uterine diseases. In acute pelvic inflammation it is generally pronounced, especially when the peritoneum is involved. In chronic uterine disease it may, or it may not, be present. If existent it is generally a dull, continuous pain. If on the right side it is to be differentiated from the sharp intermittent pain of appendicitis, and the pain and tenderness on deep pressure in this situation, in cases of uterine disease, are, as a rule, lower down than in appendicitis.

A bearing-down feeling, or a sense of weight in the pelvis, is a very frequent complaint. If, in answer to your question, the patient states that she has pain, ascertain where it is situated; the point of greatest intensity; whether it is constant or intermittent, fixed or radiating; what sort of a pain, dull, sharp, or stabbing. Describe it in the patient's own words as far as possible. The relation between the pain and menstruation, if any, should be inquired into; also the effect of exercise. The situation of the pain often shows

the nature of the lesion. Thus, pain in the sacral region may mean rectal disease, and pain above the pubes, disease of the bladder. This is not always the case, as is shown by the fact that disease of one ovary is often referred to the opposite side of the abdomen, therefore we must be on the lookout for referred pain.

Abdominal swelling, indicating a tumor of any sort, is to be asked for. If present, when was it first noticed,—what is its exact situation,—has it increased in size since it was first detected, and if so how much and how fast,—whether or no there has been pain in the swelling or tenderness on pressure.

In the case of a suspected ovarian tumor, ask whether there has been a loss of flesh about the chest and shoulders coincident with the increase in the size of the abdomen. The occurrence of jaundice in connection with a tumor in the upper abdomen, as indicating disease of the liver or gall-bladder, is to be noted, also the relation between a tumor in the flank and impaired function of the kidneys, pointing toward tumor of the kidney.

A swelling of the abdomen in a woman of child-bearing age may mean pregnancy, however improbable such a diagnosis may seem,—therefore ask always the date of the last menstruation. Bear pregnancy in mind even if the probable diagnosis is fibroid, ovarian cyst, or other tumor; pregnancy, intra- or extrauterine, may coexist as a complicating condition. It has happened several times in the author's experience that a surgeon of high reputation has discovered pregnancy in the course of an abdominal operation, undertaken for "abdominal tumor" without a more exact diagnosis.

Bladder Symptoms.—The fact should be borne in mind that women, as a rule, urinate at less frequent intervals than men. In obtaining a history it is important to inquire as to the patient's habit as regards micturition, before drawing conclusions as to the abnormality of the symptoms. The occurrence of bladder affections is rarer in women than in men.

Frequency of urination on standing or exertion, with inability to hold the urine, may mean a stone in the bladder, whereas constant desire to urinate may be due to cystitis or urethritis; therefore it is necessary to inquire whether the frequency is by day or by night. Smarting on urination indicates some irritation of the vulva or urethra. Inability to control the urine at all shows a fistula from

the bladder into the vagina, either directly, or by way of the uterus; lack of power over the bladder on laughing, sneezing, and coughing means lack of support to bladder or urethra from injury to the pelvic floor or to the anterior vaginal wall. These are samples of the class of facts which should be learned. (The subject is considered at length in Chapter X., page 151.) Ask:—How often the patient urinates? How frequently at night? How much pain in the act? When the pain is most intense? How long the pain lasts? Is it possible to control the urine when the desire to urinate occurs? Is the trouble getting better or worse? Is it affected by menstruation? Is it better or worse when the bowels are free? When did the difficulty begin? What is the supposable cause? Is the trouble the same now as at the beginning? What treatment, if any, has been used?

The Bowels.—Constipation is the rule in a large proportion of women suffering with gynecological affections. At least a third of all such patients are so affected, according to reliable statistics. The statement, however, that a woman is constipated does not describe the condition with sufficient minuteness. Many women pay little attention to their bowels, considering defecation as a troublesome function to be disregarded as long as possible. Therefore, it is necessary to make careful inquiries to determine that constipation really exists. The amount of fecal matter passed depends, of course, on the amount and character of food ingested. People of irregular habits as regards their food should be expected to pass a variable amount of fecal matter; four to eight ounces is said to be the normal amount passed in twenty-four hours if the patient is living on a mixed diet. The amount is more if the diet is vegetable rather than if animal. Habits of a lifetime have a controlling influence on defecation, and a person may evacuate the bowels regularly every other day or twice a day and yet be within the limits of the normal. We must inquire whether the bowels move regularly, *i.e.*, without medicine, enema, or artificial aid of any kind, at stated periods of time, and what those times are; whether the action is full, or scanty, and the stools solid, semisolid, or liquid; whether there is pain on defecation at the time (hemorrhoids) or lasting after the movement (fissure of the anus); whether the stools are ribbon-like (stricture of the rectum); whether offensive (decomposition); containing blood, mucus, or pus (hemorrhoids or fistula in ano);

whether there is escape of gas involuntarily (some injury of the sphincter, or fistula in ano).

In some cases of injury of the pelvic floor the patient finds that the only way she can evacuate the rectum is by making digital pressure in the vagina. Prolapse of the rectum on straining at stool is to be borne in mind in getting the history.

Inquiry should be made as to the length of time constipation has existed, whether it is habitual or intermittent, and whether, in the patient's mind, there is any assignable cause. The physician should consider a pelvic tumor, rupture of the pelvic floor, a stricture, or malignant disease of the intestine as possible causes of constipation. (See Chapter X., page 156.)

Present Illness.—Under this heading we group together the symptoms which go to make up the complaint for which the patient consults the physician. They consist of the data as to the functions of the different organs. Appetite, digestion, and sleep receive consideration in the detail justified by their importance in any given case, also any symptoms indicating derangement of the heart, lungs, kidneys, or other organs.

Variations in the body weight are important as showing changes in the nutrition. Other things being equal, a greater weight shows increased vigor and strength: such a statement being susceptible of modification in the case of very fat people.

In this portion of the history the physician has an opportunity to show his ability as an internist and by his knowledge of the science and art of medicine to keep his patient, if possible, on the main line of practice instead of shunting her on to the sidetrack of specialism.

It is always wise to note the exact date of the last menstruation before finishing the history. A habit of doing this will go a long way toward preventing awkward mistakes.

Finally, as a matter of record, make a memorandum of the patient's peculiarities of form and figure.

CHAPTER IV

THE PHYSICAL EXAMINATION

I. The preparation of the patient, p. 23.

II. The preparation of the examining table, p. 26. Care of the instruments, with list of a full kit, p. 28.

III. The examination: 1. Preparation of the physician and placing the patient on the table, p. 31; The dorsal position, p. 33. 2. Inspection of the external genitals, p. 33. 3. Palpation, p. 34: (a) The vaginal touch, p. 34; (b) The combined vaginal and abdominal touch, p. 38.

HAVING taken the history as outlined in the preceding chapter, the next procedure is the physical examination. It is not necessary to follow exactly the same routine in all cases; nevertheless it is most essential to have a definite system and to proceed according to it in all but exceptional instances, because in this way, and in this way only, are sources of error, the omission of important signs, reduced to a minimum.

First let us consider I. *the preparation of the patient*, then II. *the preparation of the examining table and the instruments*, and lastly III. *the examination itself*.

So much does a good diagnosis depend on careful preliminaries and on a multitude of little things that no apology is necessary for the space devoted to them.

I. THE PREPARATION OF THE PATIENT

It is absolutely essential that the rectum should be empty in order that the physician may make a satisfactory bimanual examination, also, in the case of abdominal palpation, if the bowels are distended by feces or gas the ability of the examiner to appreciate the condition of the abdominal contents will be interfered with. Therefore the patient, if there is need and if time serves, should be instructed to take a cathartic the day before the examination or an enema immediately before.

If a patient presents herself with the statement that the bowels have not moved for several days it is better not to make an examination until they are solvent, except in cases of emergency.

Unless there is some suspicion of disease of the urinary organs the bladder is to be emptied just before the examination. In certain urinary cases, where it is desired to obtain a catheter specimen of urine at the examination, the patient should be asked not to empty her bladder before the examination.

As a rule it is better to have no douche or special wash given before the examination, because the examiner wishes to form an opinion as to the character of the discharge, if present. It is a simple matter for him to wipe away the discharge later with sterile cotton or some antiseptic solution.

The most important matter in connection with the preparatory treatment of the patient and the one most often overlooked is the loosening of all constricting clothing about the waist. Simply to loosen the corsets and leave the drawers buttoned about the waist is not sufficient. So often women come to the examining table with corsets and skirts loosened, and investigation reveals one or two tight, constricting bands still left. Closed drawers should be removed. The union suit is a foe to an accurate diagnosis and should be removed. If the patient considers her condition of ill health important enough to consult a physician she should be ready to offer no hindrance to a proper examination.

With any encircling girdle about the upper abdomen it is manifestly impossible to compress the abdominal walls and to palpate the contents of the abdomen and pelvis. Such palpation is difficult enough with all conditions favorable, therefore do not handicap it by omitting to have all clothing loosened.

If the patient is in bed she should be prepared by having her put on a fresh pair of stockings. Should the Sims position be used an extra towel will serve for covering the right thigh.

Much depends on the physician's tact and the manner in which he goes about the preparation for the physical investigation. Women do not mind an examination which they consider necessary if the physician shows proper consideration for their feelings and knows how to go about the examination. If the matter is treated as disagreeable and to be put through as quickly as possible, the

result is apt to be that the physician's frame of mind will be reflected in the patient and she will be ill at ease and consequently will not give herself up to the investigation, not relaxing the abdominal muscles and thus limiting the facts which may be gleaned through the tactile sense.

The patient should be made to feel that the examination is to be conducted with as little pain and discomfort as is possible and that this is an important consideration to the examiner. She may be told a fact too often lost sight of, that pain, caused by roughness or vigorous handling, makes unconscious resistance and rigidity of the abdominal muscles, thereby dulling the sense of touch in the doctor's hands and preventing him from reaching deep-lying structures—consequently the examination is less successful. Often it is inadvisable to make a thorough investigation and a complete diagnosis at one sitting. Sometimes it is necessary to examine the patient on several different occasions before all the conditions have been found favorable and all the facts have been brought out. Therefore do not be led to express an opinion on the case prematurely.

In the case of young girls it is generally advisable to use an anesthetic before making a local examination, although it is not always necessary, much depending on the nervous temperament of the patient. In making an examination of a virgin in whom menstruation has been established an anesthetic is seldom required if great tact and gentleness are used. It is far preferable to make the first examination without ether if possible, because often facts of importance, such as regions of tenderness, brought out during the examination, are lost in an ether examination, to say nothing of the unfavorable after-effects of the anesthetic on the patient. Should the first investigation show the need, another examination with ether can be made.

Too much can not be said of the importance of the tactful handling of the patient previous to the examination. To see one skilled nurse in a large hospital clinic put forty women on the table for examination during the course of an afternoon, no complaints, no objections, and one following the other with military precision, is an object lesson of no mean value. Few nurses acquire such expertness, and to few is it needful. Much may be learned by studying, when the opportunity offers, the way it is done.

The local examination should be made during the intermenstrual period. Only in the case of hemorrhage and unusual conditions is it necessary to examine during menstruation.

II. THE PREPARATION OF THE EXAMINING TABLE AND THE INSTRUMENTS

Some hard surface on which the patient is to lie is a necessity for a proper examination. A soft bed or couch into which she sinks takes away all space under the buttocks for the unused fingers of the examiner's hand in the vaginal examination. Besides, most beds and couches are so low that the physician is in an uncomfortable position while examining and so many of his muscles are tense that he can not concentrate his entire attention on what his fingers are feeling. Furthermore, with the patient on a low couch the physician cannot get his eyes on a low enough level to look into the vagina unless he sits on the floor in an awkward and constrained position.

A table, the size, shape, and height of an ordinary kitchen table, is on the whole the best surface on which to put the patient. Portable or fixed supports for the feet are a useful addition and also a movable slide projecting from the right-hand lower corner of the table is a convenient adjunct. My table is stoutly built of walnut, has large casters on all four feet, and is of the following dimensions:—Length, 44 inches; breadth, 24 inches; height at bottom end, 33 inches; height at head end, 31 inches.

It is to be noted that the foot or examining end is higher than the head end. This is to cause the viscera to gravitate away from the pelvis and to allow of more pillows for the head without inclining the trunk downward toward the pelvis.

The table is covered with a hair pillow one inch thick, encased in a dark-colored, enameled canvas cover. This cover is buttoned to the under edge of the table top, as the removable sides of a carriage are fastened on.

Fixed or portable rests for the feet are an advantage, because with the feet slightly elevated above the surface of the table and at a short distance beyond the table's edge the abdominal muscles are more thoroughly relaxed and the patient is more comfortable

than she is with heels close to the buttocks, and slipping off the table.

In private houses the kitchen table is always available or, if it is best in occasional instances to examine the patient in bed, an ironing board or bread board may be placed on the mattress under the patient's hips, which should be at the edge of the bed, the feet resting in two chairs. A folded blanket, or two thicknesses of a comforter, should be laid on the table or board to take away the hardness. In this way the patient is reasonably comfortable during

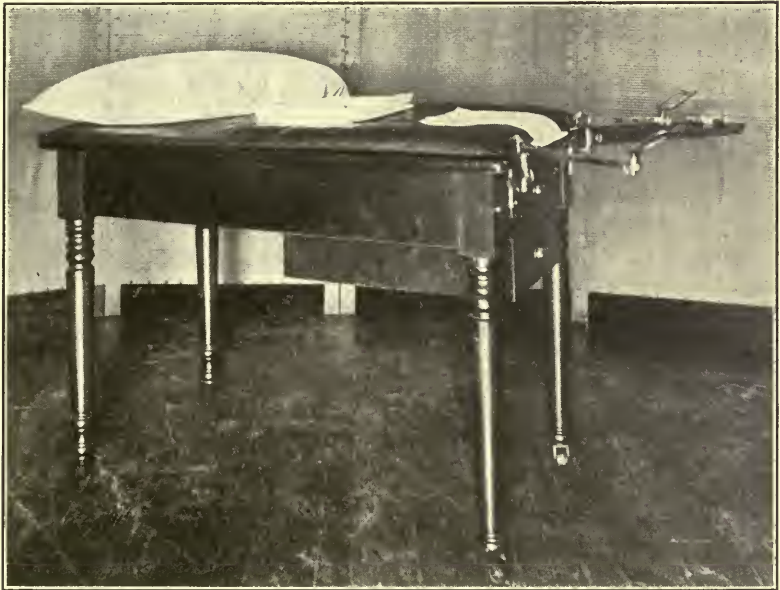

FIG. 1.—The Examining Table.

the short time occupied by the examination and the physician can do his work to the best advantage.

There are few points of superiority and many disadvantages in the complicated and costly tables sold in the instrument shops. The patient is not at ease on an unstable surface and she does not like to feel that by the pressure of levers she may be tilted into all sorts of positions; she is not in a state of mind to appreciate the beauty of the ingenious mechanism concealed in the table, and would rather lie on a solid, warm wooden table than on a hard, cold one, made of glass and iron.

The ordinary vaginal examination need not be a strictly aseptic operation, and it calls for clean, not aseptic furniture.

Suppose we have the table placed with its end toward a good light. We cover it with a folded comforter and a sheet, unless it is already provided with a permanent cushion. When the patient lies on her back with hips and heels at the edge, the only portion of the table which will come in contact with the region about the vulva and anus is a narrow part of the middle of the end, some two inches wide and six inches long. Therefore for every patient a fresh towel is opened just as it comes from the laundry and a newspaper is folded into it so that the original folds of the towel are reproduced. This towel, about six inches wide and a foot long, is now placed in the middle of the examining end of the table and one end tucked under the comforter or cushion. The surface to sit upon is thus some six by nine inches, according to the size of the towel. In this way each patient sits on an absolutely fresh towel, and the table is protected from the vaginal discharges or solutions used by the physician, by the newspaper which has been folded into the towel.

It is seldom necessary to soil the sheet or cushion. If by any chance it is soiled, as in case of hemorrhage, the sheet or towel is removed and the enameled canvas surface of the cushion is washed and a fresh sheet or towel put on. A pillow for the patient's head is placed at the head end of the table.

CARE OF THE INSTRUMENTS

Very few instruments are necessary for the routine gynecological examination. A uterine dressing forceps, a sound, and a small-sized bivalve speculum are frequently all that will be required.

It is best to keep all instruments out of the patient's sight, because she does not admire them nor look at them from the same point of view as the doctor, and it is not at all reassuring to feel that all the bright instruments of seeming torture may be used on her.

My full kit contains the following instruments:

Flexible uterine sound;

Uterine probe;

Bozeman uterine dressing forceps;

Uterine tenaculum, single;

Uterine tenaculum, double, or vulsellum;
Uterine scissors;
Silver uterine probe;
Small-size Brewer bivalve speculum;
Graves bivalve speculum;
Smallest size Sims speculum, also No. 4 size;
Edebohls speculum (included in the kit for cases in which
curetting or removal of a piece of tissue is necessary for diagnosis);
Hunter vaginal depressor;
Emmet curette forceps;
Bozeman-Fritsch uterine douche;
Two uterine applicators;
Uterine sharp curette with flexible shaft;
Set of Hanks metal uterine dilators;
Warthen uterine dilator;
Silver female catheter;
Kelly meatus calibrator;
Set of Kelly double-ended steel urethral sounds;
Kelly cystoscopes, Nos. 8, 10, 12;
Alligator bladder forceps;
Two Kelly ureteral catheters;
Kelly proctoscopes, two sizes;
Kelly ureteral searcher, and rubber bulb and tube for suction;
Head mirror;
Stethoscope;
Pelvimeter.
Added to these are:
Two sterile two-ounce bottles;
Compressed tablets of cocaine hydrochlorate;
Sterile absorbent cotton;
Sterile gauze;
A bottle of ereolin;
Cover glasses.

A collapsible tube of a sterile, soluble lubricant sold under the names of Lubrichondrin, Glycerine Emollient, Mucosol, or K-Y Jelly.

It is my practice to have one set of instruments in a drawer within easy reach of my right hand as I sit in front of my examin-

ing table; another set is in a bag ready to be carried to consultations at the patients' homes.

After use the instruments are scrubbed with soap, hot water, and a nail brush, rinsed with boiling water, dried at once, and put away clean. In cancer cases and those in which infectious matter is pretty surely present the instruments are boiled in soda as well as scrubbed with soap and water before being put away. Before use, the instruments which it is thought will be used, are placed in a shallow enameled iron tray and boiled for five minutes in a one-per-cent solution of washing soda in water; the soda solution is then poured off and hot water substituted. No instruments are ever let lie for any length of time after use without being washed. Until cleansed they are always kept immersed in water so that discharges and blood can not dry on.

III. THE EXAMINATION

1. Preparation of the physician and placing the patient on the table.
2. Inspection of the external genitals.
3. Palpation: (a) The vaginal touch. Dorsal position.
 - (b) The combined bimanual vaginal and abdominal touch, including points in the anatomy and the findings on palpation.
 - (c) The rectal touch.
 - (d) The bimanual recto-abdominal touch.
 - (e) Positions of the patient used in gynecological examinations other than the dorsal; the Sims position; the knee-chest position; the lithotomy position; the raised pelvis position; the standing position.
4. Odor as a diagnostic sign.
5. The collection of the discharges and tissues for bacteriological examination.
6. Inspection of the abdomen.
7. Palpation of the abdomen.
8. Percussion, auscultation, and mensuration of the abdomen.
9. Instruments and their use in diagnosis.

1. PREPARATION OF THE PHYSICIAN AND PLACING THE PATIENT ON THE TABLE

The physician prepares himself by washing his hands carefully and if they are cold by warming them, and by pulling up the sleeves of his coat and his cuffs so that they will not come in contact with the patient. As to rubber cots and rubber gloves, they interfere with the tactile sense, however used, and should be employed only in exceptional instances, as in cases of suspected gonorrhœa and of fetid discharge, also in rectal examinations. They serve to protect

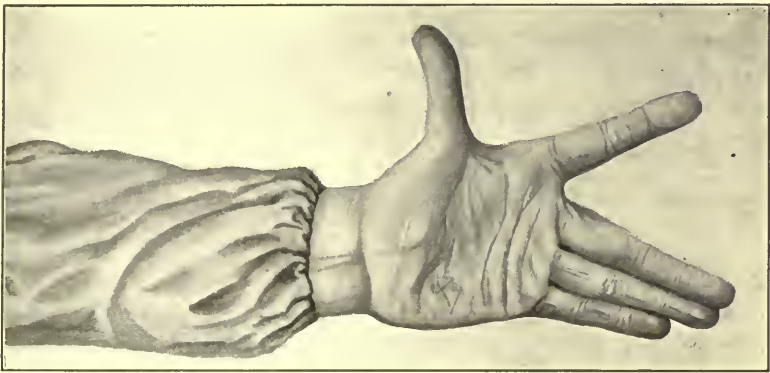

FIG. 2.—The Examining Hand, Showing Protective Sleeve.

coming patients and also the physician from contamination, as inoculation with syphilis, and favor the cause of asepsis. The physician who is personally neat and washes his hands carefully before as well as after a vaginal examination, need have no fear of carrying bacteria from patient to patient. The examination can not be so well made with cots or gloves as without them, therefore do not use them unless necessary.

As to protecting the sleeves, it is a good plan to wear sleeves made of "Stork sheeting" or thin rubber, with elastics at the wrists and elbows, pulled on over the coat sleeves. These rubber sleeves can be frequently cleansed and they prevent carrying infection from one patient to another. They obviate the necessity of removing the coat, a procedure which is undesir-

able because it seems to indicate to the patient formidable undertakings.

Of the importance of washing the hands before the examination too much can not be said. One never knows what bacteria he may have on his hands and under his finger nails. Every one necessarily washes his hands after the examination; how much more essential, from the standpoint of the patient's safety, is the preliminary wash. He who would practice gynecology must have the handwashing habit.

It is my custom to prepare a basin full of warm creolin solution,



FIG. 3.—The Dorsal Position.

one per cent, and place it on the instrument table within reach of my right hand. As before stated, the examination is not and need not be a strictly aseptic operation; therefore some antiseptic, which does not coagulate the albumen of the discharges, has an odor of its own, does not corrode instruments, nor irritate the tissues, is indicated. Any table will serve on which to lay the pan of instruments, basin, and sterile cotton. A low table is preferable to a high one. Its surface should be covered with a fresh towel.

The usual position employed in gynecological examinations is

the dorsal position. The Sims position, the knee-chest position, the elevated pelvis position, the lithotomy position, and the standing position will be described later.

The Dorsal Position.—Everything being in readiness, the patient steps into a hard-bottomed chair placed at the foot of the table and raises all her skirts behind, the physician meanwhile standing in front of her and holding up a sheet, so that she is screened from him as she sits on the little folded towel on the edge of the table. She lies down and puts her feet in the supports. To prevent straining the back it is well to ask the patient to draw up her knees as she lies down, otherwise her back will reach the cushion while her feet are still in the chair, putting her into a sort of Walcher position, one of great discomfort.

The sheet is now thrown over the recumbent woman so that she is entirely covered. Holding the lower edge of the sheet in the left hand the physician raises the patient's skirts in front with his right hand under the sheet. Then by carrying the middle point of the sheet upward to the pubic region both thighs are draped and only the vulva and anal regions are exposed. A woman does not object to an exposure of the genitals that is manifestly necessary so long as the surrounding parts and the body are covered up. This method of covering with the sheet is applicable to every sort of a case, and should be employed always unless the patient is anesthetized.

If the examination is at the patient's home the table is prepared in a good light in her room and she either walks to the examining table, or, if unable to walk, is carried from the bed.

2. INSPECTION OF THE EXTERNAL GENITALS

There is no valid objection to an inspection of the vulvar region; in fact, a proper diagnosis can not be made without it. The physician seats himself in the chair used by the patient to get upon the table, and spreads a fresh towel over his knees. By placing the fingers of each hand on the labia majora the labia are drawn gently apart and he notes the condition of the hymen, whether with one or more openings, unbroken or broken; the amount and character of the vaginal discharge; the appearance of redness about the orifices of Bartholin's glands or Skene's glands.

If redness appears about the orifices of Skene's glands, the well-anointed finger should be introduced for an inch into the vagina, pressing backward toward the sacrum with the dorsum of the finger as it is slipped into the vagina, and gentle pressure made with the tip of the finger along the course of the urethra from above downward to express pus from the glands.

He notes further the condition of the meatus urinarius, whether closed or open; the prepuce, whether adherent to the glans clitoridis or not, and injuries of the perineum. The surface of the perineum between the fourchette and the anus should present a convexity; if it is flat or concave it means an injury to the pelvic floor or perineum.

Palpation is to be combined with inspection in determining the nature and extent of injuries in this region. (See Chapter XX, page 372.) One must be on the lookout for skin affections. Pediculi are occasionally found among the poorer classes; and all sorts of anomalies of the external genitalia are to be looked for. Inspection of the vagina will be taken up in the chapter on the use of instruments.

3. PALPATION

Palpation includes the vaginal touch, the combined bimanual vaginal and abdominal touch, the rectal touch, and the combined bimanual recto-abdominal touch. The examination of the abdomen will be considered in another chapter.

(a) **The Vaginal Touch.**—The physician has washed his hands with care, his nails are always trimmed short and are clean, and his hands are warm. He stands facing the patient, who is in the dorsal position on the examining table. Now comes the question which hand to use for the vagina. I prefer the left hand for the reasons that the left hand is less frequently used for ordinary purposes than the right; therefore, the skin covering the terminal phalanx of the left forefinger is softer and capable of higher training of the tactile sense; less strength is required of the examining hand at the vagina than of the hand on the abdomen, which is engaged in gross manipulations, the right hand is usually the stronger except in the case of left-handed persons; the left hand is generally a trifle more flexible than the right hand, an important

consideration with reference to stowing away the unused fingers, and finally, using the left finger for the examination leaves free the highly trained right hand for the delicate manipulation of instruments.

Whichever finger is chosen, that one should be used in all but unusual cases, because it is desirable to educate one finger to feel correctly. It is the exceptional physician who can become ambidextrous.

Having decided on the left forefinger, it should be lubricated because the external genitals are dry, and pushing in the external parts causes the patient discomfort; it is the skin which is in need of lubrication rather than the vagina, which is supplied normally with a lubricating medium, therefore anoint the external labia and these in turn will lubricate the finger. The best lubricant is something of the nature of lubricichondrin, sold under the name of "mucolubricans" or "K-Y," prepared from cartilage treated with heat, a mildly antiseptic jelly containing eucalyptol or gaultheria, or some other substance to give it a pleasant odor. It is soluble in water. It is kept in a sterile, collapsible tube and is free from all danger of contamination. The oils and vaseline are peculiarly ill suited for lubrication because they cling to the finger and instruments and are well adapted to receive, retain, and distribute pathogenic organisms. Soaps are irritating to many patients, particularly in inflammatory conditions of the external genitals. The physician squeezes from the tube an ample quantity of lubricichondrin on to the dorsal aspect of his forefinger, anointing only the terminal and second phalanges. By bringing the hand downward until the little and ring fingers touch the table just under the cleft of the buttocks, the tip of the anointed forefinger seeks the perineum. When it is reached the back of the bent forefinger is drawn upward over the fourchette, thus lubricating the labia and the vestibule, the knuckle falling into the depression at the introitus vaginae. A second sweep with the finger, it is straightened, and the tip settles into the vagina. It is to be noted that the lubricant has been put only where it is needed and that there is none on the unused hand and on the patient's linen.

In introducing the finger into the vagina one bears in mind the condition of the hymen as noted at the previous inspection. If the hymen is tight great gentleness should be used and sufficient

time allowed for dilatation. Room in the vagina is always to be gained by pressing backward toward the sacrum, as the perineum and pelvic floor are dilatable in this direction only. The structures which hug the under surface of the pubic arch, the clitoris, vestibule, anterior vaginal wall, and urethra should be avoided as far as possible, as in that region sensation is most acute.

The examining finger may be likened to a small speculum as it carries down the perineum and opens the vagina. In many cases it is possible to use the finger in the place of a speculum.

As soon as the middle knuckle of the examining finger has passed the hymen the hand is turned so that the thumb is upward. The three unused fingers are carried behind the anus in the cleft of the nates and the thumb is moved to the left or right of the median line out of the way of the clitoris. The perineum and pelvic floor can be pushed in to a variable extent by the web between the index and middle fingers and thus the examining finger reaches farther. It is seldom necessary to employ two fingers for the vaginal examination, although there are cases where more may be learned with two than with one. The palmar surface of the last phalanx of the forefinger is the chief seat of the trained tactile sense. As a rule, particularly in virgins, two fingers cause the patient a great deal of discomfort and therefore accentuate the disagreeable features of the examination, tending to distress of mind and body and consequently preventing the relaxation so essential for a successful investigation of the contents of the pelvis. The scope of the vaginal touch depends, in a measure, on the anatomical peculiarities of the examiner's hand. A physician having thick, chunky hands with short fat fingers can not hope to be as good a gynecological diagnostician as one having a slim hand with long, tapering fingers. In women of spare build who have borne children, practically the entire inner surface of the pelvic cavity may be palpated by a long finger or fingers introduced into the vagina. It is not unusual to touch the promontory of the sacrum and the sacro-iliac synchondroses, besides all parts of the pelvic floor, not to mention the structures occupying the pelvis. (See Fig. 4.)

The examining finger as it enters the vagina notes the following points:—The state of the hymen, whether with large opening or small, whether rigid or easily dilatable; the vaginal walls, whether

with rugæ or smooth, whether of normal temperature, or hot, as in the case of inflammatory affections of the pelvic organs, or in fevers; whether the walls of the vagina are in apposition, or lax or separated; the amount of secretion, a dry vagina giving an entirely different sensation from a moist one; the condition of the pelvic floor and perineum; in the case of a parous woman search for a groove in either sulcus or the middle line, remembering the normal conformation of the perineum, that is to say, a convex surface in the vagina as well as on the skin outside; sometimes it is well to introduce the well-anointed forefinger of the right hand in the anus and palpate the tissue lying between the two

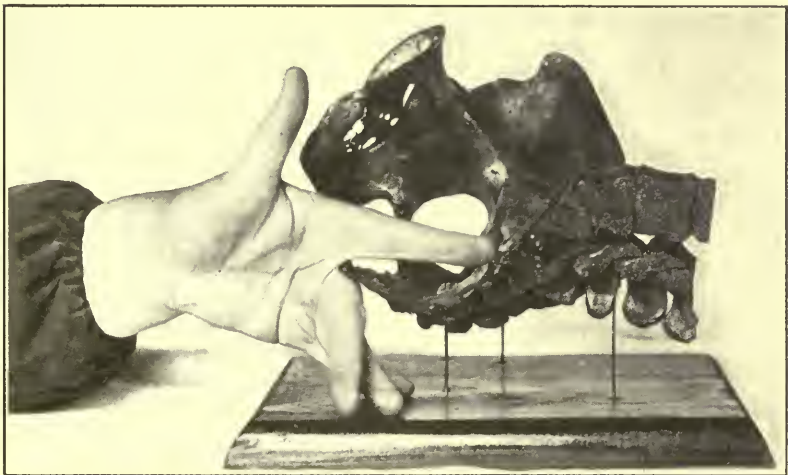


FIG. 4.—Half a Female Pelvis, with Hand in Position as for Vaginal Examination.

fingers in order to get a correct idea as to injuries which may be present. The vaginal touch informs us as to the contents of the rectum, whether empty or containing hard fecal masses, semi-solid feces, or dilated by fluid or gas; also whether or no the bladder is distended.

In order to practice this sort of palpation successfully requires a long experience and a thorough familiarity with the normal conditions, also the variations of the normal in different individuals.

Abnormalities of the vagina are to be detected by touch; such are cysts, partial septum, narrowing of the lumen by cicatrices,

the sequelae of old inflammatory action, or from congenital defects of development; also roughness, as in granular vaginitis.

On palpating the anterior wall of the vagina the urethra is felt, and thickening or sensitiveness of this structure—evidences of inflammation—are detected. So also the base of the bladder is to be touched to determine thickening or points of tenderness, in-

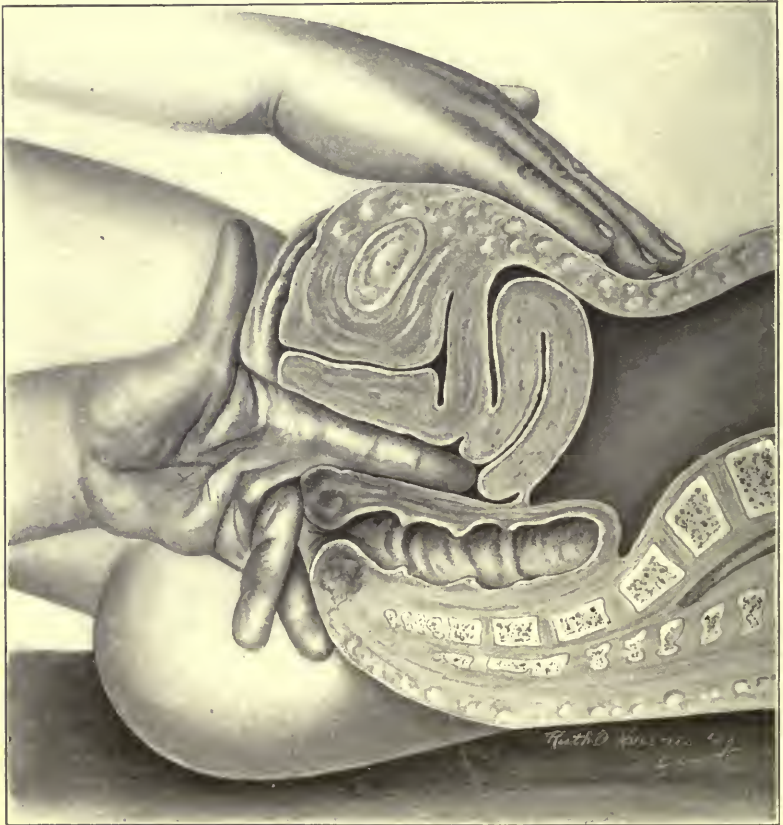


FIG. 5.—Diagrammatic Drawing, Illustrating the Bimanual Touch.

dicating the situation of ulcerated areas in the bladder mucosa. The ureters when thickened are easily palpable running from the bladder base toward the sacro-iliac synchondroses. The upper course of the pelvic portion of the ureters can be best detected by rectal examination.

(b) **The Combined Bimanual Vaginal and Abdominal Touch.**—When the tip of the examining finger reaches the posterior

fornix of the vagina the physician's right hand is laid gently on the lower abdomen, palm down with the heel of the hand just above the symphysis pubis. Very gentle and slowly applied pressure is made with this abdominal hand, all sudden movement being avoided as calculated to excite pain and consequently resistance of the abdominal muscles. The balls and not the tips of the fingers are used. The pelvic organs are carried down by the pressure above until they are within reach of the finger in the vagina, and conversely they are raised by the finger below until within touch from above. In the case of the bimanual vagino-abdominal touch we hold between our hands (the finger in the vagina and the hand on the abdomen) the contents of a box, the cavity of the pelvis.

It is sometimes a help in making the bimanual examination for the physician to rest the elbow of the hand making the vaginal touch on the knee of the corresponding leg, his foot being placed on the chair which is close to the table.

Factors outside of the condition of the bowels and rectum limiting what can be felt by the bimanual touch are, the amount of adipose tissue present, and the rigidity or laxity of the muscles of the abdominal walls. A rigid perineum has been referred to already as lessening the amount of invagination of the pelvic floor that may be made by the web between the fingers of the hand at the vulva.

In fat women both the vaginal and bimanual touch are interfered with. Other things being equal, it is impossible to make as accurate a diagnosis in a fat woman as in a thin woman. The fat in the perineal region reduces the scope of the vaginal touch. A greater hindrance is the fat in the abdominal walls; with two or three inches of fat in the panniculus adiposus the tactile sense is much blunted. It is like feeling through six or eight thicknesses of blankets. Naturally, then, we do not hope to make as good a diagnosis as when the abdominal walls contain little fat.

A rigid abdomen is a bar to diagnosis by touch. One can feel very little through a stiff sheet of pasteboard. If there is present peritonitis or great sensitiveness of the abdomen from any cause we expect to find rigidity. Many patients become rigid through anxiety and fear of painful manipulations by the physician, others

reflexly because of the discomfort caused by the laying on of the hands. Therefore, not only is the utmost gentleness imperative, but also it is a matter of supreme importance not to arouse the patient's fears by brusque behavior, or by the uncalled-for display of instruments.

As to gentleness, the flat hand on the lower abdomen makes light pressure and the physician inquires whether it causes pain. Distracting the patient's attention by a question or two often prevents rigidity. Next, the hand is arched by flexing slightly all the fingers so that the balls of the fingers press in deeply. It is very essential not to make the tips of the fingers press, the same rule holding here as in massage. Make pressure with the palmar surface of the last phalanges, for the tips of the fingers and the finger nails cause pain, and, also, less can be felt with the tips.

Ask the patient to take a long breath; as she does so, gently hold the abdominal wall in. Repeat the process and the examiner's hands are brought nearer and nearer together with each expiration. Judgment is necessary in performing this maneuver because too rapid or too forcible pressure will cause the abdominal muscles to contract, thus defeating the objects of the examination. Assistance is gained in some rare cases by drawing down the cervix with a tenaculum held by an assistant. In this way the back of the uterus and the broad ligaments are reached and also tumors and other attachments are made out.

The bimanual or conjoined examination is the keystone of the gynecological diagnostic arch. Nothing takes the place of the trained touch, and it is doubtful whether, in the march of progress, any form of investigation will supplant it.

Specula for the vagina, the bladder, and the rectum, bacteriology, and the microscope with its findings as to the nature of the blood and tissues, and the *x*-rays, detecting a stone in the bladder, ureter, or kidney, all have their uses. The bimanual touch is the most important.

The finger in the vagina notes, first, the situation, size, conformation, consistency, and sensitiveness of the cervix; lacerations, their location and extent; whether or no the tissues of the cervix are of normal consistency, or soft as in septic conditions or after labor, or indurated as in chronic metritis. The friable, bleeding

cervix of cancer is rarely mistaken for any other condition, except possibly a sloughing, pedunculated fibroid.

Cysts of the Nabothian follicles can be diagnosticated as shot-like bodies; a stringy, tenacious plug of mucus in the os can be differentiated from a thin discharge; in rare cases the cervix may be out of reach, being forced upward into the abdomen by a tumor in the pelvis so that it may lie on a level with the upper border of the symphysis pubis; the different situations of the cervix in the various malpositions and malformations of the uterus will be considered in the chapter devoted to these diseases. The long conical cervix found especially in pathological ante-flexion, so called, is readily distinguished from its opposites, the apparently short cervix—one in which the vagina has been stripped by childbearing from its attachments to the portio, or from the really short senile cervix.

The pinhole os is differentiated by touch from the os tinæ. By the vaginal touch we detect a polypus projecting from the os uteri. In the case of large polypi we detect the location and size of the pedicle by sweeping the finger about the tumor and noting where and how it is attached. Sensitiveness of the cervix to light pressure indicating endocervicitis is to be sought for. A prolapsed ovary or tube may be felt on one side of the cervix and an excursion to one of the sacro-iliac joints may, in rare cases, detect tenderness and induration there.

Palpating the normal ovary by the bimanual touch is a difficult matter unless all the conditions are favorable. These are, a patient with thin and relaxed abdominal walls and an injured perineum. Under such circumstances the ovary may be rolled between the fingers of the examiner's hands. Whenever the ovary is enlarged from any cause its palpation is rendered easier. In the case of rigid abdominal walls, large deposits of fat in these structures, a tight hymen and unyielding perineum, the palpation of the ovary becomes difficult. Often only the under surface can be felt, and sometimes only by a rectal examination. Note the sensitiveness to pressure of the normal ovary and in the case of a diseased ovary inquire of the patient if the pain caused by pressure is the same as that suffered at other times.

The Fallopian tube can not be felt by bimanual examination unless it is thickened or enlarged by disease. In this event it

may be mapped out with varying degrees of exactness according to the condition of abdominal wall and perineum.

An abscess in the pelvis, whether originating in the tube, the ovary, the vermiform appendix, the sacro-iliac joint, or coming from above in the psoas muscle, may be mapped out by the bimanual touch and a point of fluctuation found if it exists.

CHAPTER V

THE PHYSICAL EXAMINATION (*Continued*)

III. The examination (*continued*) — 3. Palpation (*continued*): Anatomy of the pelvic contents, p. 43. Barriers to infection, p. 43. Mobility of the uterus, p. 44. The uterine ligaments, p. 44. Mechanics of the pelvic and abdominal contents, p. 44. The pelvic circulation, p. 46. The normal position of the uterus, p. 49. Structures to be distinguished by palpation, p. 49. Inferences to be drawn from palpation, p. 50. (c) The rectal touch, p. 50. (d) The recto-abdominal touch, p. 53. (e) Gynecological positions other than the dorsal position, p. 53: The Sims position, p. 54; The knee-chest position, p. 56; The lithotomy position, p. 57; The raised pelvis position, p. 58; The standing position, p. 59.

4. Odor as a diagnostic sign, p. 60.

5. The collection of the discharges and tissues for microscopic examination, p. 61: Bartholin's glands, p. 61. Skene's glands, p. 61. The cervical canal, p. 62. The preservation of tissue, p. 63.

III. THE EXAMINATION (*Continued*)

3. PALPATION (*Continued*)

BEFORE describing further the pathological conditions which may be diagnosed by the bimanual touch, it will be well to review some points in the anatomy, physiology, and mechanics of the pelvic organs. No attempt will be made to give a complete description such as may be found in text-books of anatomy.

Think of the pelvis as a box, closed below by a flexible diaphragm, the pelvic floor, and open above into the abdominal cavity. Direct communication between the pelvic cavity and the outside world is established through the lumen of the Fallopian tubes, the uterine cavity, and the vagina. The barriers to the entrance of infective bacteria to the peritoneum are (1) the narrowings of the canals at the isthmus of the tube, the internal os of the uterus, and the hymen, and (2) the downward current of the secretions, partially maintained by the cilia of the lining epithelial cells, partly by peristalsis of the tube, and also by coughing and straining.

The uterus occupying the center of the pelvic cavity is suspended with its long axis coinciding with the long axis of the pelvis and at right angles to the long axis of the vagina. An important point to remember is that it is suspended and oscillates every time its owner coughs, sneezes, laughs, or moves about. It is held in place by certain ligaments to which it is attached, by its connection with the vagina, by the pelvic floor supporting the vagina, and by the pressure of the abdominal contents.

The ligaments are folds of peritoneum containing connective tissue, vessels, and nerves, and, in the case of the round and utero-

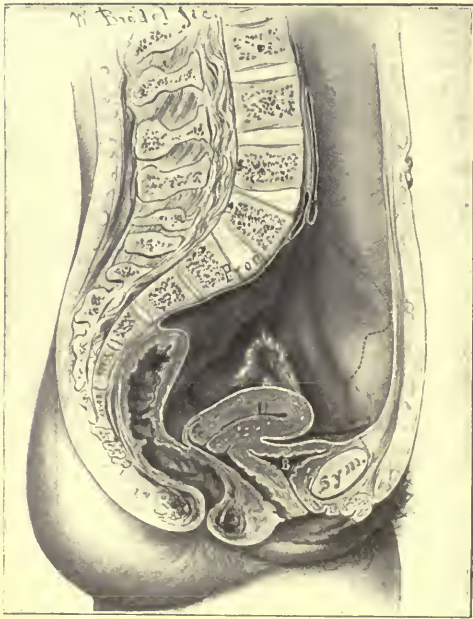

FIG. 3.—Vertical Median Section of Body. (Kelly.)

sacral ligaments, a few muscle fibers. The broad ligaments are on both sides with long attachments to the sides of the uterus, thick at their lower portions, reaching from the cervix nearly to the fundus and attached at their other ends to the sides of the pelvis. At the back are the utero-sacral ligaments, attached to the posterior surface of the uterus at the region of the internal os and extending to the back wall of the pelvis at the level of the second or third piece of the sacrum. The utero-vesical connective tissue is in front and also the round ligaments, which begin as large fleshy cords

just in front of each horn of the uterus and extend to the internal abdominal rings, becoming smaller and smaller as they approach their insertion in the fat of the pubes.

It is to be noted that when a woman is in the erect position (see Fig. 6) the insertions and origins of the round ligaments lie practically in the same horizontal plane, therefore these ligaments act rather as steadying guys than as supports to the uterus. In the case of the broad ligaments they are thick and strong in their lower portions and really support the cervix. So also the uterosacral ligaments support the lower uterine segment and through it the upper vagina. The attachments of the vagina to the cervix serve to steady this portion of the organ and keep it in its proper relation to the pelvic floor. The supporting action of the pelvic floor will be found described in more detail in the section on prolapse, Chapter XIV, page 220.

The abdominal cavity may be likened to an upright cylindrical vessel filled with water and closed at both ends by an elastic membrane. The weight of the water causes the bottom membrane to bulge outward and the pressure of the atmosphere the top membrane to sink inward.

In the case of a living woman, standing erect, the diaphragm represents the top membrane, the pelvic floor the bottom membrane, the walls of the abdomen the vessel, and the liver, stomach, spleen, kidneys, pancreas, intestines, and uterine organs the fluid. The posterior wall of the abdomen is practically immovable like the walls of the tube, but the anterior wall is elastic and capable of varying within wide limits, not only the capacity of the abdominal cavity, but the pressure exerted on its contents.

The contents of the abdominal cavity are solid, fluid, and gaseous, and the different structures are stowed so closely together that there is no waste space between them. The pressure which can be exerted on a solid organ in the abdominal cavity such as the liver, has no effect other than to compress it slightly or cause it to move within the limits permitted by its suspending ligaments.



FIG. 7.—A Vertical Cylinder closed at either End by an Elastic Diaphragm and Filled with Fluid.

According to a law of physics, pressure on the fluid contents of a closed vessel is transmitted with equal intensity in all directions. Pressure on the gaseous contents has no other effect than slightly to lessen their volume. The abdominal organs are supported by their ligaments and mesenteries, by each other, by the abdominal walls,—the upper ones by the ribs,—by the anterior projecting lumbar spine, and by the shelf of the false pelvis covered by the psoas muscles. (See Fig. 86, page 221.) Therefore, when the woman is in the erect posture the weight of the abdominal contents, minus what is assumed by the mesenteries and the abdominal walls, rests on the anterior face of the lumbar spine and the slanting brim of the false pelvis, on the lower anterior abdominal wall, and also on the posterior surface of the uterus and the broad ligaments and through them on the pelvic floor. Increased pressure due to contraction of the abdominal walls, straining; or downward excursion of the diaphragm, coughing and sneezing; is transmitted to the fluid contents in all directions. The posterior walls of the abdomen are rigid, the anterior walls are rigid when contracted, the bony wall of the pelvis is rigid, the pelvic floor is elastic, therefore it bulges downward, like the membrane on the bottom of the vessel in the figure.

If instead of being in the erect posture the woman is in the knee-chest position, the conditions are reversed. Now the weight of the abdominal contents comes on the diaphragm and the upper front walls of the abdomen, the pelvic floor is depressed inward like the upper membrane covering the vessel; when the vagina, rectum, or bladder is opened, air rushes in to replace the negative pressure, thus maintaining the equilibrium of the atmosphere, fifteen pounds' pressure to the square inch exerted in all directions.

In this connection the pelvic circulation is to be considered. Emmet pointed out long ago (*Trans. Amer. Gyn. Soc.*, 1887, Vol. XII., p. 65) that the veins of the pelvis are without valves, and to overcome the effect of gravity their course is extremely tortuous. "Moreover, this provision is necessary that undue traction be not made upon the vessels with the change of position, and with the increasing bulk of the uterus depending upon gestation." He noted the fact that if we draw down a healthy uterus to a certain point near the floor of the pelvis and hold it there, the cervix and vaginal mucosa become congested very soon, as evidenced by the

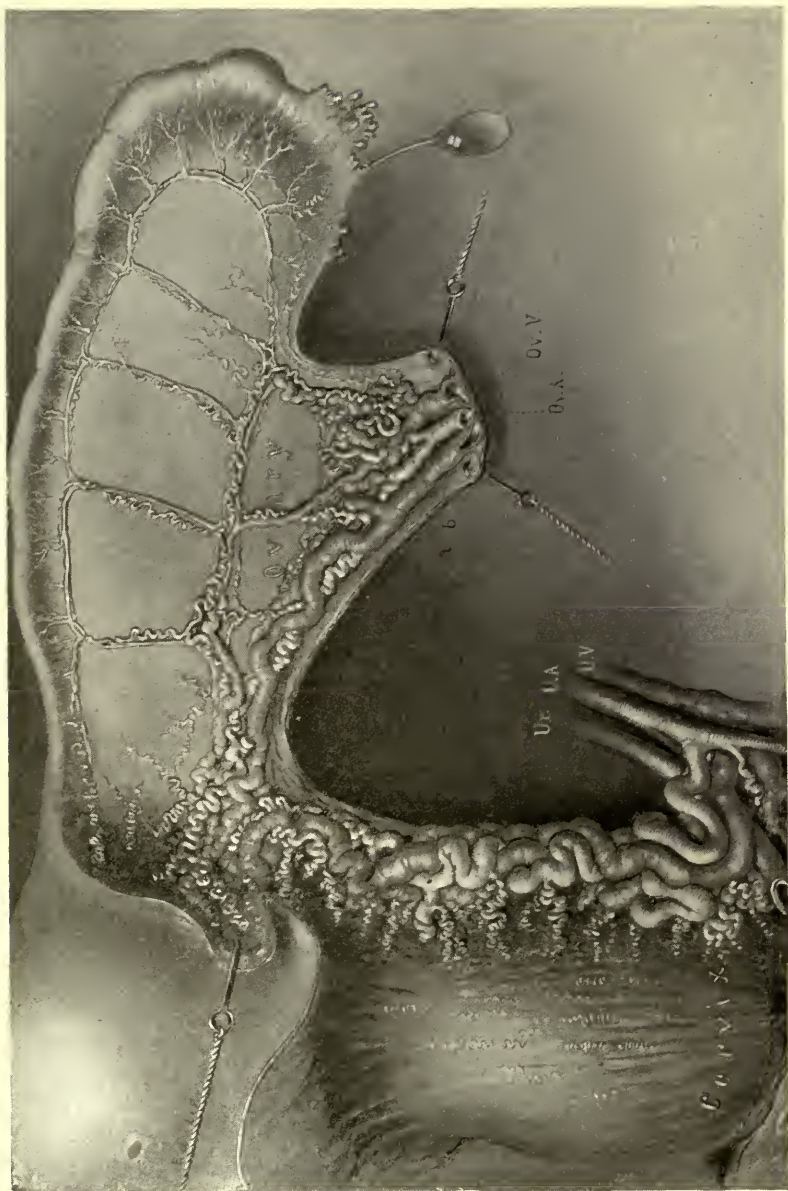

FIG. 8.—The Uterine and Ovarian Blood-Vessels. (Kelly.)

movements of the uterus, broad ligaments, and the abdominal contents.

The bladder, when filled, pushes the uterus and the ovaries and the tubes backward, tending to cause retroversion. The rectum, occupying the left posterior portion of the pelvis, when distended tends to raise the uterus and also makes for retroversion, because limiting the backward excursion of the cervix.

It is plain, then, that the normal position of the uterus varies somewhat according as the woman is standing or is lying down, it being somewhat more anteverted in the former and less anteverted in the latter, because of the effect of gravity and the varying pressure of the abdominal contents on the fundus. Also its position as well as its mobility varies according to the state of fullness of the bladder and the rectum.

In practicing bimanual palpation the following structures are to be felt: the symphysis pubis; the promontory of the sacrum; the uterus; the ovaries; the Fallopian tubes, when diseased so that they are thickened or enlarged; the appendix vermiformis, very exceptionally and only when thickened or enlarged by disease; the rectum and bladder, only, as a rule, when their walls are thickened.

In rare cases having lax and thin abdominal parietes a thickened ureter may be palpated at the point where it crosses the pelvic brim just outside the internal iliac artery and the sacroiliac joint. A thickened ureter may be felt always for two inches or so after it leaves the bladder. In favorable cases the normal ureters may be palpated per vaginam, but this is a fine point and not an accomplishment of many physicians.

On making downward pressure on the abdomen the promontory of the sacrum is felt just below the level of the umbilicus. Midway between the promontory and the symphysis pubis, or a trifle nearer the symphysis, the fundus uteri, if normally placed, is to be made out. In the erect posture the external os uteri is on a level with the upper margin of the symphysis pubis; in the recumbent attitude the os is slightly higher.

Steadying the cervix with the vaginal finger the examiner moves the uterus up and down and from side to side, thus gaining an idea of the mobility, whether normal or limited by past or present inflammatory action in the surrounding tissues, or by a tumor or a full bladder.

The uterus may be displaced as a whole downward in the axis of the pelvis (prolapse), or backward (retroposition), or exceptionally upward. Alterations in the axis constitute retroversion (often made to include retroposition) and anteversion. Lateral versions are of little importance.

Besides the situation, axis, and mobility of the uterus, one notes its form (abnormalities, flexions, and tumors), its size (atrophic or hypertrophic), and its density (soft in pregnancy and septic conditions and hard in chronic inflammation and in many tumors).

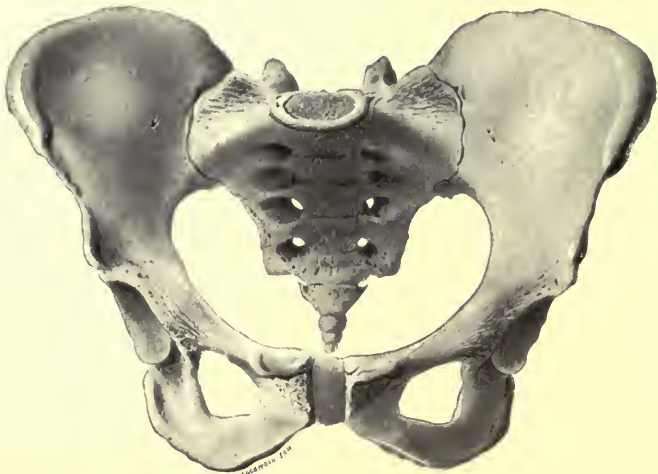


FIG. 9a.—Normal Female Pelvis.

Pressure on the uterine body eliciting tenderness denotes endometritis; and tenderness of the cervix, endocervicitis.

Tumors anywhere in the pelvis are to be placed accurately, and their size, form, consistency, and sensitiveness to pressure determined, also their relation to the pelvic organs. This relation is established often by moving the tumor and noting if the uterus moves, or vice versa.

In acute pelvic inflammation the abdominal walls are apt to be rigid because of the peritonismus which is generally present. Under these conditions little can be learned except by the vaginal touch.

Exceptionally it is best to combine instruments with the bimanual touch as described in Chapter VII.

(c) **The Rectal Touch.**—This method of examination is resorted to in order to gain a slightly higher reach in the pelvis and also in

cases where it is inadvisable to make the vaginal touch, as in young girls, a virgin with a rigid hymen, the case of a narrow, shallow vagina, or a congenital or acquired atresia of this organ.

In making a rectal examination it is desirable to use a large amount of lubricant because of the tightness of the anus. The digital examination of the rectum causes much more discomfort to most women than the digital examination of the vagina. Therefore, every reasonable device should be employed to lessen the discomfort, and also, unless the finger is well lubricated, the anus will grasp it so tightly as to interfere with its tactile sense. It is well to use a thin rubber cot for the rectum, removing it as soon as this part of the examination is over. Before making the examination the anal region is smeared freely with muco-lubricans and the left forefinger is thoroughly anointed as well.

Sometimes in patients who are annoyed by an accumulation of gas in the rectum it is well to let this gas out before making the examination, by passing a catheter through the anus before introducing the finger. As a rule, however, the presence of gas in the rectum facilitates the examination. The vaginal touch, if it has preceded the rectal touch, will give an inkling as to the condition of the rectum. The presence of fecal matter calls for an enema.

In passing the finger through the anus, note the tonicity and strength of the sphincter ani. In the case of hemorrhoids or fissure, where there has been long-standing irritation with consequent increased muscular action, the sphincter will be found in many cases to be hypertrophied. The sphincter may be weak and insufficient because of injury received during childbirth or by overstretching at the hands of a surgeon, or in cases of rectal prolapse or atrophic catarrh.

A fissure by presenting a localized point of sensitiveness, hemorrhoids by giving a feeling of lumps in the rectal wall, and also polypi by their feeling of pedunculation, may be detected by touch. The situation of the opening of a fistula in ano into the bowel can not be determined without the aid of a probe. Through the thin anterior rectal wall the examining finger makes out the cervix, the bases of the broad ligaments, and the utero-sacral ligaments. By raising the uterus, these ligaments are put on the stretch and an idea may be obtained as to their relative length

and thickness. The posterior wall of the uterus is very accessible through the rectum.

The ovaries and tubes if prolapsed may be palpated advantageously by the rectal touch.

Through the posterior wall of the rectum the coccygeal and sacral vertebrae may be felt, and fractures and dislocations of the coccyx determined. Pain caused by pressure on the coccyx may mean coccygodynia. (See Chapter X., page 159.)

Infiltrations or new growths in the recto-vaginal septum are to be mapped out, as to size, situation, consistency, and sensitive-

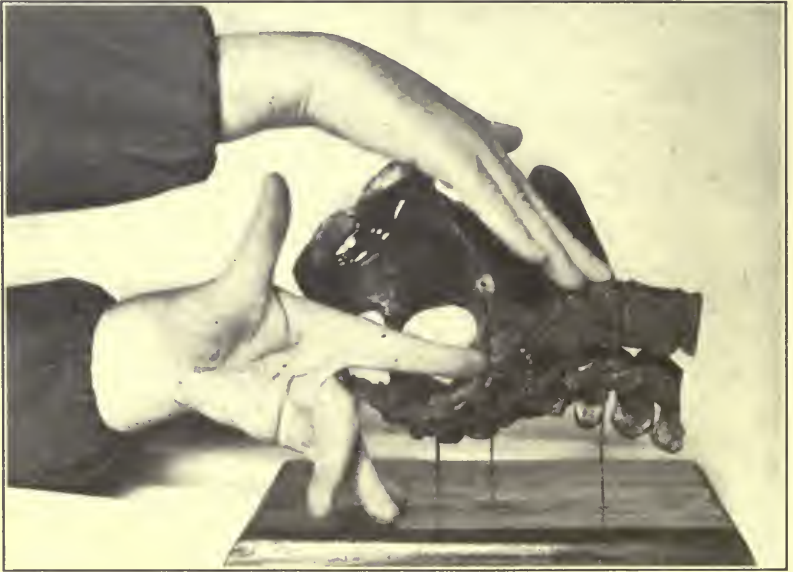


FIG. 10.—Half a Female Pelvis, Showing Accessibility of Contents to Palpation.

ness, by combined vaginal and rectal touch, the finger of one hand being in the vagina, and the forefinger of the other hand in the rectum. The presence of new growths and strictures in the rectum is diagnosed by the rectal touch.

Too great care can not be exercised in washing the hands before changing from a rectal to a vaginal examination and vice versa, because of the danger of transferring infective matter from one organ to the other. In the case of acute infective inflammation of the vulva and vagina, it is wiser not to examine the rectum at all. Often the rectal examination may be deferred as well to a later date.

By the rectum it is possible to palpate the branches of the sacral plexus of nerves where they course along the sides of the pelvis, and also to palpate a psoas abscess or disease of the sacro-iliac articulation.

(d) **The bimanual recto-abdominal touch** is the same as the bimanual vagino-abdominal touch as regards the structures which are reached, except that greater opportunity is generally afforded

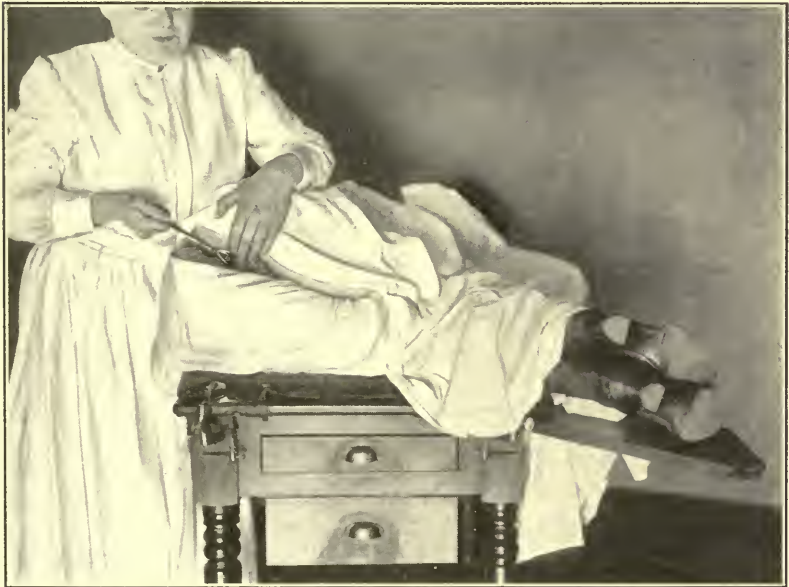

FIG. 11.—The Sims Position.

for exploration of the cul-de-sac of Douglas and its contents, than by the bimanual vagino-abdominal touch.

Digital exploration of the bladder is an unjustifiable procedure, as all the information obtained by touch may be gained by a speculum examination and by vaginal and rectal touch. The danger of incontinence of urine is too great to justify introducing the finger through the urethra, no matter how small the finger may be.

(e) **Gynecological Positions other than the Dorsal Position.**—Besides the dorsal position which has been described already, there are several other positions into which the patient is put for purposes of examination.

They are:—the Sims, the knee-chest, the lithotomy, the raised pelvis, and the standing positions.

The *Sims position* is not so frequently used now as in the years following the invention of the Sims speculum. Still, it is of great service both for the use of the speculum and other instruments, for practicing the bimanual touch, and for examination of the anus and rectum. For some reason not altogether clear, the illustrations introduced into all but one or two text-books on gynecology to show this position, do not figure it correctly as it was devised

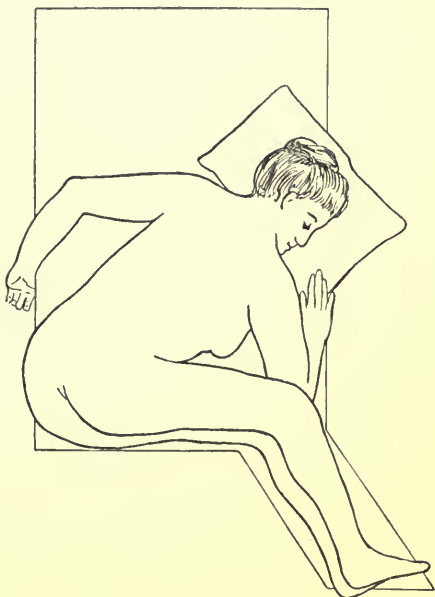

FIG. 12.—Diagram of the Sims Position.

by Sims or as it is used in the hospital where he did his work, the Woman's Hospital in the State of New York. As commonly shown, the patient is lying on her left side with thighs only partly flexed on the abdomen, in the middle of a long table; her head is generally on the left side of the table, her hips in the middle, and so far from the bottom edge that the genitals are entirely inaccessible for examination.

Suppose we have finished with the dorsal position and wish to put our patient in the *Sims position*. Pulling the sheet off and holding it in front of her we give her a hand and ask her to stand in the chair at the foot of the table. Then we pull out the little slide for a foot rest in the right-hand lower corner of the table and place the pillow for the head diagonally about midway along the right edge of the table. Now we ask her to raise her skirts and to sit on the left-hand corner of the table, sitting as far over to the left as she can and turning on her left side and drawing up her knees as she lies down. Throw the sheet over the hips as soon as she gets down. Next ask her to put her left arm over the left edge of the table and help her to do it.

See that her head is on the pillow on the right side and that she is, as it were, doubled up like a jack-knife. Then the physician stands on the left of the table facing the patient's hips, pulls them (asking at the same time for the patient's assistance) to the left, until the back of the sacrum is even with the left edge of the table, and the lower margin of the buttocks corresponds with the lower edge of the table. The feet are now on the foot rest, or, in default of this, on the back of a chair padded with a folded blanket, or on a table. The upper, the right knee is advanced a little beyond its fellow, and the inner edge of the sole of the right foot rests on the instep of the left foot.

A fresh towel opened out is made to cover the lower buttock and thigh by tucking one end into the drawers behind, and carrying the other end between the thighs in front. The free end below is tucked under the covering of the table. The upper buttock and thigh, the legs and feet, and the rest of the body are covered by the sheet.

In this position the pelvis is inclined at a slight angle to the table, the abdominal contents fall away from the pelvis, leaving the pelvic organs free from pressure; the abdominal walls are relaxed and the vagina, ballooned by air admitted by the speculum, can be most easily inspected.

It is difficult to put very stout women, or patients with large abdominal tumors, in this position and in these cases the Sims position is of less value than in thinner subjects.

The important points are to get the patient's back on a level with the left edge of the table and the head on the right edge of the table. Unless the patient is put in the correct position it is of no value whatever. Unless the thighs are sharply flexed on the abdomen and the hips are at the edge of the table, the physician can neither look into the vagina nor make manipulations to advantage.

The bimanual vagino-abdominal or recto-abdominal touch is made with the patient in the Sims position by introducing the left forefinger in either vagina or rectum and the right hand between the thighs, asking the patient to raise her right thigh until the hand is in place and then letting it drop again.

The Sims position is useful also for palpating uterine and ovarian tumors; with the patient in this position, relaxation of the

abdominal walls may be obtained often, when it can not be with the patient in the dorsal position.

The knee-chest position, or knee-elbow position, as it is sometimes called, is another gynecological position commonly wrongly figured in the text-books. The patient stands in the chair at the foot of the examining table facing the table. She raises her skirts in front and places one knee near one corner of the table, the other

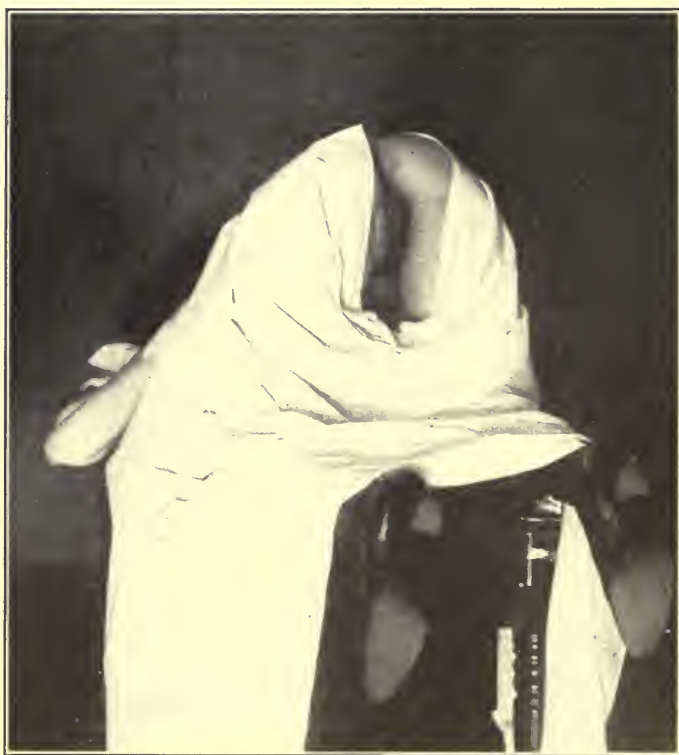

FIG. 13.—The Knee-Chest Position.

knee follows and takes its place at the opposite corner of the table. Then she bends forward and places her hands in the middle of the table while the physician throws the sheet over her. The feet and legs are left projecting over the table's edge, but the position is not uncomfortable, for all the weight comes on the knees and hands. Now the patient is on her hands and knees on the table. The physician folds a good-sized pillow once and

places it in the middle of the table. The patient is asked to place her head and chest on the pillow with her face to one side, letting herself down on to her elbows as she does so. The physician next goes to the foot of the table, throws the skirts above the hips under the sheet and drapes each thigh with the sides of the sheet. Note now whether the thighs are vertical. They are apt not to be, as the patient generally throws her chest too far forward, thus slanting the thighs. If they are not vertical they are easily made so by asking the patient to move her chest back a little as the pillow is moved for her in the same direction.

The knee-chest position is most useful for speculum examina-

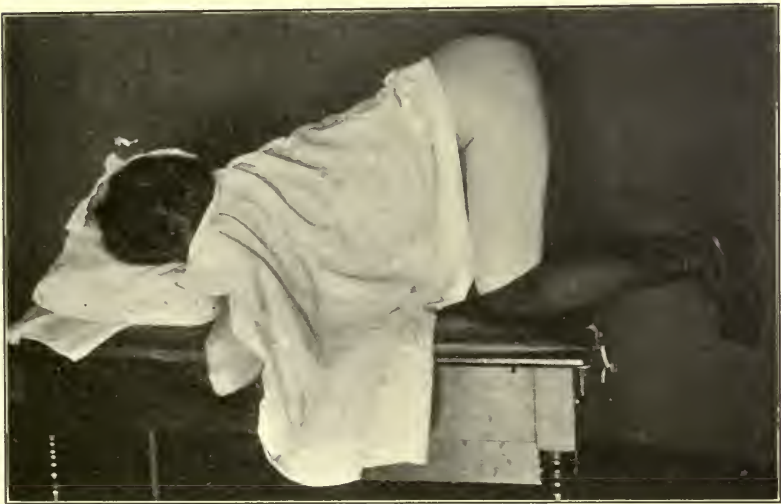

FIG. 14.—The Knee-Chest Position. Side View, Showing Vertical Thighs.

tions of the vagina, bladder, and rectum, the abdominal pressure being removed, and the viscus in which the speculum is placed being ballooned by the atmospheric pressure admitted by opening the external orifice.

To replace a retroverted or retroflexed incarcerated uterus, or an incarcerated tumor of the pelvis, often necessary to establish a diagnosis, the knee-chest position is invaluable.

The lithotomy position is the dorsal position with the thighs flexed on the abdomen. The position is maintained by leg holders, of the Von Ott, Robb, or the Clover's crutch patterns, by different forms of slings holding the flexed thighs to the shoulders of the

patient with straps, or by leg holders attached to the operating table. The patient is placed in the lithotomy position just as in the dorsal position, with the addition that the thighs are kept flexed by some device. Without any apparatus whatever it is possible, and often convenient, especially in short operations, such as curetting, for one assistant to hold both legs with one hand and have the other hand free to assist the physician. To do this, the assistant, generally a nurse, places herself on the left side of the table (the patient's right side), facing the physician, who

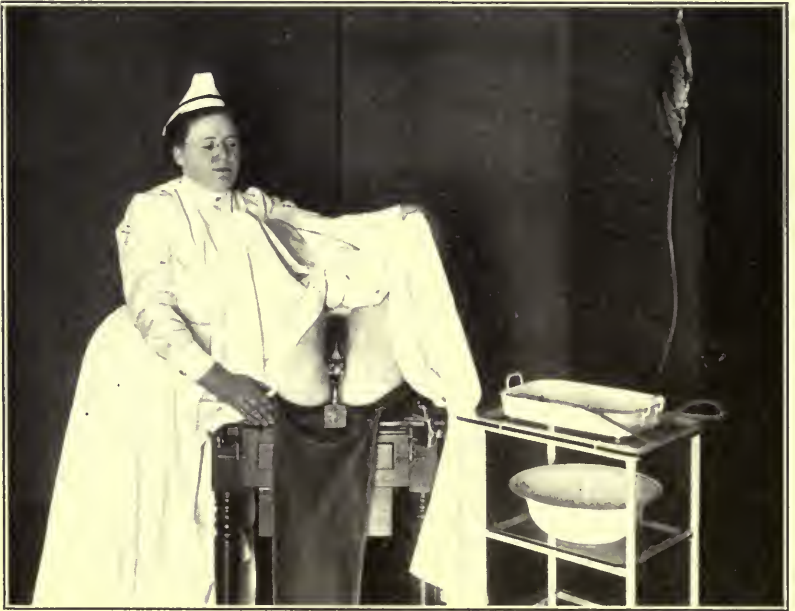

FIG. 15.—The Lithotomy Position.

is seated in the chair at the foot of the table. She reaches across the patient's flexed limbs with her left arm, letting the right knee rest in her left axilla and grasping the left leg with her left hand. Thus her right hand is free to hold instruments for the doctor.

The lithotomy position is used for examinations under ether, for operations, and for investigations where it is necessary to scrub up and asepticize the vulva and surrounding regions.

The raised pelvis position, used only in cystoscopic examinations, is an exaggerated lithotomy position. It is best obtained on a table which has a mechanism for the Trendelenburg posture,

but may be secured by placing a hassock or hard cushions covered with towels under the sacrum, so that the pelvis is elevated about ten inches above the level of the table, the legs being held by a Robb leg holder or by an assistant standing on a stool or box. This position tilts the pelvis backward and removes abdominal pressure from the bladder.

The standing position is of occasional use in determining the degree of prolapse of the uterus and vaginal walls when full abdominal pressure is exerted, also the axis of the uterus under these conditions, and the holding power of a pessary.

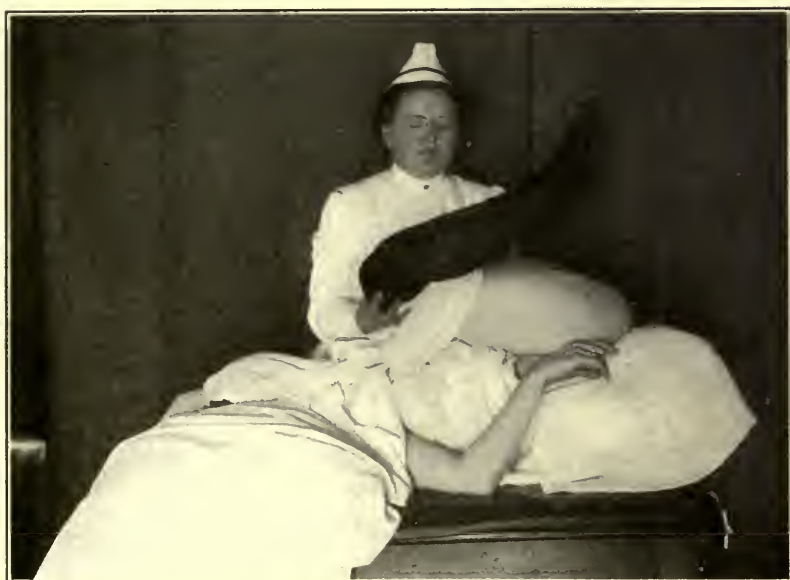

FIG. 16.—The Raised Pelvis Position.

The patient stands facing the physician with her right foot resting on a round of a chair eight or ten inches from the floor. The physician kneels on his left knee in front of her, or sits in a low chair resting his left elbow on his left knee. He anoints his left forefinger, and steadying himself with his right hand on her left hip, finds the vulva by sweeping the anointed middle finger of his left hand over the anal region, and then introduces the forefinger, just as in the vaginal examination in the case of the dorsal position. Having the patient bear down or cough gives an idea as to the excursion of the uterus with forced expiration.

4. ODOR AS A DIAGNOSTIC SIGN

The sense of smell is sometimes an aid to diagnosis, as in detecting the characteristic odor of the vaginal discharge from uterine cancer, and the odor of urine or feces in the vaginal discharges in the case of urinary or fecal fistulae. Menstrual blood has a different odor from other blood. Certain vaginal discharges have a pecu-

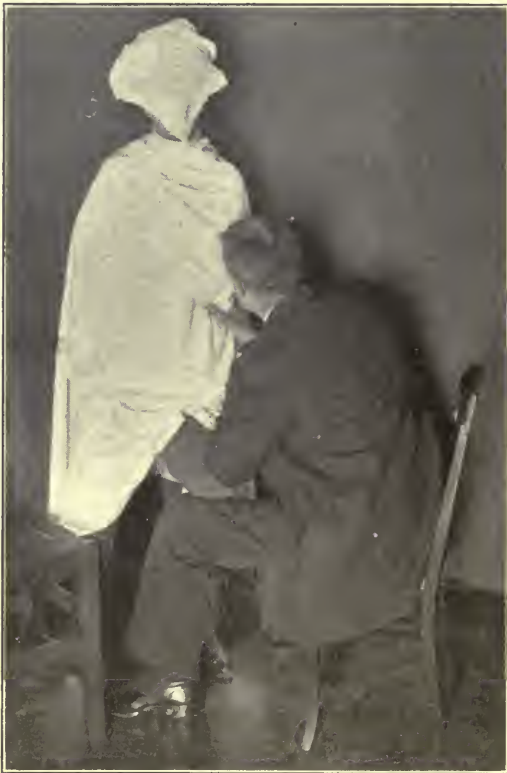

FIG. 17.—The Standing Position.

iarly foul odor. The odor exhaled by a patient suffering with septicemia is characteristic, although, like other odors, not capable of definite description. Diabetic urine has a sweet smell and urine may be distinguished from other discharges by administering spirits of turpentine or asparagus to the patient by the mouth and noting the odor of violets or asparagin in the urine.

Acetonemia, a form of intoxication with acetone occurring in diabetes, in infectious fevers, in intestinal fermentation, in general sepsis, and sometimes following gynecological operations, may be distinguished by the sweetish odor of the breath, described as like that of a pippin apple.

5. THE COLLECTION OF THE DISCHARGES AND TISSUES FOR MICROSCOPIC EXAMINATION

Materials Needed.—1. Half a dozen absolutely clean cover glasses. 2. A few culture tubes of hydrocele agar or blood serum (furnished by the pathologist). 3. Platinum wire loop. 4. Alcohol lamp. 5. Long-handled sharp knife. 6. Long-handled sharp-pointed scissors. 7. Uterine tenaculum. 8. Uterine dressing forceps. 9. Needle-holder, curved needle, and catgut. 10. Gauze packing. 11. Small bottle of ten-per-cent formalin.

Bartholin's Glands.—If the discharge from the glands of Bartholin is to be collected for examination for gonococci or tubercle bacilli, the labia are separated and the vulva is wiped dry with sterile cotton pledgets. Grasp the gland to be investigated between the thumb and forefinger, make gentle pressure, and transfer the discharge, which exudes from the mouth of the gland's duct, to a cover glass by means of a platinum wire loop or uterine applicator which has been passed previously through the flame of an alcohol lamp. Place a clean cover glass upon the first one, press the two gently together to spread the discharge evenly, slide the two apart, and allow to dry. The dry cover glasses may then be reapplied face to face and held together by an elastic band. They are then placed in an envelope which is labeled as follows:—

Name of patient:

Date:

Source of material:

Examine for (organism):

Sent by Dr.——

The preparation properly labeled is then sent to the pathologist for examination.

Skene's Glands.—The orifice of the urethra and the introitus vaginae are wiped dry with sterile cotton pledgets. Introduce the finger into the vagina and make gentle pressure from above down-

ward along the course of the urethra. As the ducts of Skene's glands open into the urethra just inside the urethral labia, any discharge from these ducts will contain a certain admixture of urethral discharge also. The urethra can hardly become infected without accompanying infection of Skene's glands, but this mixture with urethral discharge is unimportant from a clinical standpoint. If it is essential to examine the discharge from Skene's glands apart from that from the urethra, then the latter canal must be walled off with a small cotton pledget and pressure made only over Skene's gland. Transfer the discharge obtained to cover glasses as described under Bartholin's glands.

The Cervical Canal.—The patient is placed in the Sims position by preference, although the procedure may be successfully carried out in the dorsal position. A speculum is introduced and the vagina cleansed with sterile cotton and water and then dried with dry cotton. A good exposure of the cervix can usually be obtained without the use of a tenaculum. The use of a tenaculum is often accompanied by bleeding which may contaminate the cervical discharge. Sometimes it is necessary to draw the cervix down with a tenaculum. In this case the instrument should be firmly fixed at the first attempt and held in place. A sterile tampon screw is most useful in obtaining cervical discharge. The instrument is introduced into the cervical canal not beyond the internal os and twisted until some of the discharge has been caught in the threads of the screw. Whether obtained with the screw or with the platinum wire loop the smear is made as described in the case of the glands of Bartholin and Skene.

Cultures.—If cultures for the purpose of obtaining a bacterial growth from a discharge are to be made, the culture tubes are used. Collect a drop of the discharge on the sterile small wire loop which comes with the tube and smear it over the slanting surface of the material in the tube. Replace stopper, label carefully, and return to the pathologist. It is possible to introduce the small wire loop into most cervical canals without dilatation, and it is much better to take the culture or smear without dilating the canal, because in the process of dilating the discharges are partly removed and mixed with blood and tissue.

Removal of Tissue from the Cervix for Examination.—The Sims position usually offers the best exposure of the cervix for the

removal of pieces of tissue for examination. In removing a suspicious piece of tissue for microscopic examination it is wise to cut out some of the apparently healthy tissue as well as the diseased portion, for it occasionally happens that the pathologist receives nothing but necrotic tissue and can form from it no diagnosis whatever. A raw surface left by removal of tissue should be closed by suture or tamponed until all bleeding has been checked. Tissues removed by the curette, scissors, or knife for the purpose of diagnosis, are to be plunged intact and immediately into a ten-per-cent solution of formalin in water; then they are properly labeled, and sent to the pathologist.

CHAPTER VI

THE PHYSICAL EXAMINATION (*Continued*)

III. The examination (*continued*): 6. Inspection of the abdomen, p. 64. Method of performing it, p. 65. Appearances to be noted, p. 65. Enteroptosis, p. 67.

7. Palpation of the abdomen, p. 68. Method of performing it, p. 69. Points to be determined by palpation, p. 69. Palpation of the kidneys, p. 70.

8. Percussion of the abdomen, p. 71 : Auscultation of the abdomen, p. 72 : Mensuration of the abdomen, p. 74 ; Gauze records of abdominal tumors, p. 74; The X-rays in diagnosis, p. 76.

III. THE EXAMINATION (*Continued*)

6. INSPECTION OF THE ABDOMEN

ATTENTION will be directed to the abdomen to a greater or a less degree according to the nature of the disease present in any given instance. In the case of late pregnancy, and of tumors of abdominal evolution, whether originating in the pelvis or not, investigation of the abdomen is of chief importance.

In suspected uterine disease the vaginal and bimanual examinations usually precede the examination of the abdomen. In the case of a large abdominal swelling the abdomen is first inspected.

For the examination of the abdomen it is not so necessary that the patient should lie on a hard surface as in the case of the vaginal examination. However, the table is most convenient for the physician because he can stand up and make his inspection, palpation, percussion, and mensuration when in a position comfortable to himself; not, as in the case where the patient is on a low bed or couch, with bent back and strained muscles, conditions which are not conducive to most careful investigation. The patient on a table is comfortable enough for the brief time required for the examination.

All the patient's clothing has been loosened and the corsets

removed, as previously described. The sheet covers the legs, thighs, and pubic region. The raised skirts cover the chest, or, if the skirts have been removed, another sheet is used for this purpose.

To investigate the abdomen to the best advantage the patient's head should be raised a little on a pillow and the thighs should be slightly flexed. Too much flexing of the thighs or raising the head and thorax high will decrease the portion of the abdomen available for examination.

For purposes of description the abdomen may be divided

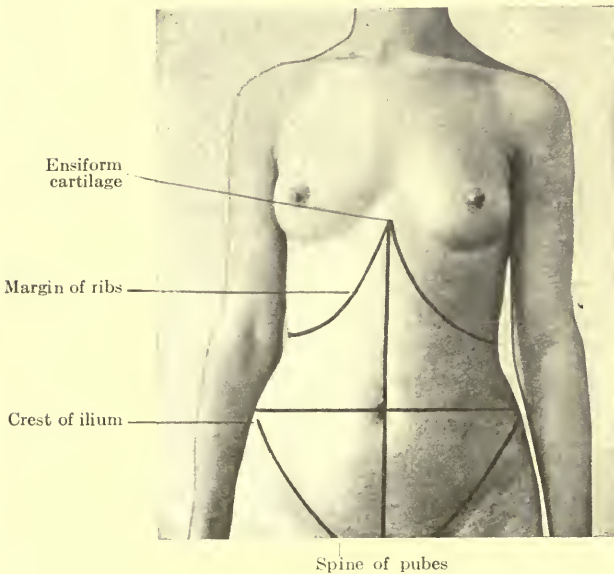


FIG. 18.—The Abdomen Divided into Quadrants and the Bony Landmarks Indicated.

arbitrarily into four regions, by two lines, one a vertical line passing through the ensiform cartilage, the umbilicus, and the symphysis pubis, and the other passing through the umbilicus at right angles to the vertical line. The four regions so made may be called the right upper quadrant, the right lower quadrant, the left upper quadrant, and the left lower quadrant.

On observing the abdomen one notices symmetry or asymmetry, distention or retraction, increased or diminished motion of the abdominal walls on respiration, and the appearance of the skin.

To detect symmetry, stand at the foot of the examining table and look at the abdomen from below. Tumors of the ovary as well as tumors of the kidney are apt to cause asymmetrical enlargement of the abdomen; whereas, tumors of the uterus and ascites more commonly produce symmetrical enlargement. One notes bulging in the flanks and a flattening of the anterior aspect of the abdomen due to ascites, or to lax abdominal walls, with or without an abnormal amount of fat in the panniculus adiposus.

A tumor rising from the pelvis, unless of great size, is usually outlined by the abdominal walls. In ovarian cysts the abdomen is irregularly ovoid in shape with its point of greatest protuberance below the umbilicus, and there is no bulging in the flanks. In the case of multilocular cysts the loculi may be distinguished by sight in exceptional cases through a thin abdominal wall, so nodules of a malignant growth in an ovarian cyst can sometimes be distinguished by the eye. Large multiple fibroids also show occasionally through the skin as lumps of irregular shape; an interstitial fibroid forms a protuberance of a smoother outline that is generally situated in the median line.

Observe the movements of the abdominal walls. The normal movements on inspiration and expiration extend over the entire surface from ensiform to pubes. In cases of large tumors springing from the pelvic cavity the movement is confined to the epigastric region if the distention is great, also if there are adhesions between the tumor and the parietes there may be motion only in this region. Sometimes, when there are no adhesions present, the abdominal wall can be seen to glide up and down over the surface of a tumor of moderate size.

Waves of peristalsis in the intestines may be noted in a patient with thin flaccid walls and retracted abdomen, also pulsations of the abdominal aorta. In pregnancy the situation of greatest intensity of fetal movements may be observed.

Separation of the recti, due to distention of the abdomen during previous pregnancies, often leaves a ventral hernia through which a tumor, the pregnant uterus, or the abdominal contents may protrude. Palpation of the abdominal and pelvic organs is rendered most easy in these cases.

The appearance of the skin of the abdomen is of interest as showing discolorations from blisters and counterirritants, indica-

tions of previous treatment, also the presence of edema or skin diseases. Enlargement of the superficial veins indicates pressure on the deeper vessels. Excessive distention of the abdomen renders the skin white and glossy in appearance, whereas, when the walls are lax, the skin has a shriveled or puckered look.

The lineæ albicantes, red and purple when recent, and white and glistening when old, are to be looked for especially over the flanks. They indicate previous stretching of the skin, but are not pathognomonic of pregnancy, as they occur in virgins who have grown rapidly and then lost subcutaneous fat.

Pigmentation of the linea alba (linea nigra) and increase of pigment about the umbilicus and lower abdomen occur in some women during a first pregnancy. This pigmentation persists, but is of no diagnostic importance in a subsequent pregnancy.

When the patient is sick in bed with peritonitis, the characteristic way in which she holds herself, with knees drawn up to relieve all strain on the abdominal parietes, is to be noted.

Enteroptosis.—In some cases it is advantageous to put the patient in the standing position for the purpose of inspecting the abdomen; especially is this desirable in suspected ptosis of the abdominal viscera, a condition often associated with uterine disease.

Here we must inspect not the abdomen alone, but the entire trunk. The patient stands, first, facing the physician, entirely nude except for a sheet held by a nurse draping the lower limbs and pubic region. Then she stands so that he sees her in profile. In typical enteroptosis one notes a long, narrow thorax, with flat and sunken epigastric region. The waist is long, the abdomen is prominent, the shoulders are rounded, and when seen in profile the lower back is nearly flat instead of presenting, as normally, a forward curve, with shoulders and hips well back and spine bent forward in the lumbar region. There is generally an absence of adipose tissue in these patients and the muscles are apt to be slender and flabby.

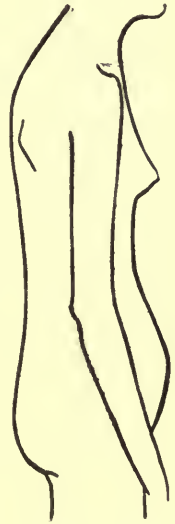

FIG. 19.—The Body Pose in Enteroptosis.

7. PALPATION OF THE ABDOMEN

To palpate the abdomen successfully, the patient should be prepared as for inspection, that is, in the dorsal position with the head slightly raised on a pillow, all clothing loosened, the feet supported, and the pubic region, thighs, and legs covered by a sheet. The physician, standing on the patient's right, places both hands, warmed, and with finger nails cut short, on the abdomen. No abrupt or rapid movements should be made, and, for the purpose of distracting the patient's attention and thus favoring relaxation, it is advisable at this juncture to ask some question as to the health, not directly referable to the abdomen.

By care and patience the tendency of the abdominal muscles to contract when stimulated by manipulation may be overcome. Oftentimes more than one sitting is necessary to accomplish this result, and in this event the diagnosis must be held in abeyance until after a second examination. It is better to make two or more attempts, except in urgent cases, rather than resort to an examination under an anesthetic, because with increasing experience the physician learns an added amount from each palpation, and having gained the patient's confidence and treating every case according to her individuality, he is able more frequently to dispense with an anesthetic.

The utmost gentleness should obtain always. The harder the pressure, the greater the resistance of the abdominal walls and the greater the blunting of the physician's tactile sense. Furthermore, it has happened several times in the experience of the writer, that a student novice has ruptured a thin-walled or necrotic ovarian cyst or a circumscribed collection of peritonitic fluid, by too vigorous palpation.

A thin, relaxed abdominal wall permits of palpation of the promontory of the sacrum, and the pulsations of the abdominal aorta are to be felt distinctly. The anterior superior spines and the crests of the ilia, the symphysis pubis and the borders of the ribs, body landmarks, are always to be made out. Thick and tense abdominal walls interfere with palpation.

It is well to have a definite system to follow in palpating the

abdomen. Begin with the lower quadrants and proceed to the upper quadrants. (See Figure 18, page 65.) By making firm but gentle, deep pressure, the patient at the same time taking a deep breath, the hands, flat on the abdomen, are brought together and a fold is grasped between them so that an estimate is formed of the thickness of the abdominal walls and their degree of tension. Avoid as far as possible digging into the flesh with the tips of the fingers, using instead the palmar surfaces of the last phalanges, the location of the trained tactile sense.

We may learn by palpation, of the presence of a tumor, also its situation, size, shape, mobility, consistency, and point of attachment. We determine a point of tenderness on pressure, indicating localized peritonitis. In a majority of cases we may palpate the normal kidneys, more easily if they are enlarged or displaced. We palpate the edge of the normal or enlarged liver, and a displaced liver, as in enteroptosis, also a distended gall bladder, or an enlarged spleen. A loop of bowel distended with feces and also the distended urinary bladder may be made out by palpation.

Suppose a tumor is present; first we determine its situation by making gentle, firm pressure with both hands, noting in which quadrant or quadrants of the abdomen it is situated. The abdominal walls should move with the hands over the underlying organs or the tumor. Tumors situated in the structures of the abdominal wall move with the wall on inspiration and expiration over the organs underneath. Tumors of the abdominal and pelvic organs that are adherent to the abdominal parietes limit the motion of the walls on respiration. Exceptionally, in cases where the walls are lax and the tumor is not excessively large, the physician is able to pick up the abdominal wall and determine if it is adherent to the tumor beneath. All the abdominal organs normally move more or less during respiration,—those organs nearer the diaphragm, as the liver and kidneys, moving the most, while those in the bottom of the abdomen are less affected. The size of the tumors can be learned only approximately. It is to be borne in mind that some tumors vary in size at different times: for instance, an ovarian cyst is smaller after there has been free catharsis from the bowels, and a fibroid tumor of the uterus is larger just before the catamenia and smaller just after.

The shape of the tumor is made out by palpating it in several

directions. To this end the examiner shifts his position to the left side or to the foot of the examining table.

The mobility of the tumor is ascertained by grasping it between the two hands and moving it about. Changing the patient's position to the lateral position may cause the tumor to fall by gravity to the dependent side. Ovarian tumors tend to gravitate into the abdominal cavity if the patient is put in the knee-chest position. The excursions of a movable tumor show us something as regards adhesions and the point of attachment and length of the pedicle. Traction on the pedicle generally causes pain referred to the situation of the pedicle.

The consistency of a tumor is often a difficult matter to pass on. Waves of fluctuation are made out by a combination of palpation and percussion. The hand of an assistant is placed, ulnar edge down, in the longitudinal axis of the abdomen and firm pressure is made. This is to eliminate the wave which may be transmitted by the fat of the abdominal wall. The physician taps one side of the abdomen and notes with the other hand, placed on the opposite side, oscillations which may be transmitted through the fluid. If a cyst is filled so that the fluid is under great pressure and if the cyst walls are thick, the fluid waves may be indistinguishable. So also, if the fluid is of a thick consistency, fluctuation may be absent.

Peristaltic contractions of a piece of intestine are sometimes to be distinguished and also the rhythmical contractions of a pregnant uterus. To determine either of these it is necessary to let the hand rest gently on the abdomen for a considerable length of time.

The point of attachment of a tumor may be learned by moving the tumor while the hand is held on a neighboring organ and noting whether the organ moves too, or by moving the organ and noting the behavior of the tumor.

Palpation of the Kidneys.—Palpation of the kidneys is best done with the patient in the dorsal position. The physician stands at the patient's side facing toward her head, his left hand is placed under the flank and his right hand over the flank, while the patient takes a deep breath. This process is repeated, the hands coming together a little more with each expiration. Time, gentleness, and gradual movements are important factors in this manipulation.

The right kidney, being a little lower than the left, is more accessible to palpation. With practice it will be found that there are comparatively few cases,—and these patients having very stout and rigid-walled abdomens,—in which the lower poles, at least, of the kidneys can not be felt.

In the case of movable kidney, generally the entire kidney can be outlined, especially where it is enlarged. Pressure on a tuberculous or hydronephrotic kidney will frequently force turbid urine through the ureter into the bladder. If the bladder has been emptied by catheter previous to the examination and clear urine obtained, such a procedure assists materially in establishing the diagnosis, for a second catheterization following palpation draws off cloudy urine.

To determine the extent of the downward excursion of a misplaced kidney the flank is palpated either in the sitting or in the standing position. In the sitting position the patient sits on the foot of the table with her feet in a chair, and bends forward slightly. In the standing position she stands facing the table and about a foot from it. Placing both hands on the table she leans forward so that part of her weight is taken on the hands; thus the abdominal muscles are relaxed. This manipulation can be executed best with the assistance of a nurse or another woman, because the patient can not hold up her loosened clothing and bear part of the weight on her hands at the same time. Personally, I have learned to place the chief reliance on the dorsal position for palpation of the kidneys, except to make out the amount of extreme downward excursion, when sometimes the standing, and at others the sitting, position gives the better result.

8. PERCUSSION, AUSCULTATION, AND MENSURATION OF THE ABDOMEN

The combination of palpation and percussion for the detection of fluid waves in the abdomen has been described in the discussion of palpation.

Percussion is best practiced with the patient in the dorsal position. By it we determine the situation of the lower margin of the liver-dullness, the area of stomach and colon tympany, splenic dullness, the dullness due to fecal accumulations in the bowels or urine in

the bladder, and the dullness caused by free fluid in the peritoneal cavity or by the fluid or solid constituents of a tumor.

Unfortunately we have no standard of comparison in percussion. We can not compare the percussion note of one side of the abdomen with that of the other, and the conditions are constantly varying, due to changeable quantities of fluid, solid and gaseous matters in the stomach and bowels, and the encroachment of one organ on another. Also, there are to be considered the variations caused by the normal mobility of the abdominal organs.

Nevertheless, percussion is a valuable adjunct to palpation. Its chief use in gynecological diagnosis is in differentiating between ascites and a cystic ovarian tumor. In the case of ascites, the flanks, being the dependent portion of the abdominal cavity and therefore occupied by fluid, are dull to percussion. The intestines, filled more or less by gas, float on top of the fluid, and give an area of resonance in the umbilical region. Shifting the position of the patient to one side sends the fluid (unless by chance it is walled off by adhesions) to the dependent side, and the resonance is to be found on the upper side and flatness below. In rare cases, when the ascitic fluid greatly distends the abdomen, there may be no change in the area of dullness on shifting the position of the patient.

In the case of a large ovarian cyst, the resonance is in the epigastric region, the intestines having been forced there by the tumor and the dullness is over the area occupied by the tumor. Change of posture does not alter the areas of dullness and resonance. (See Figures 132 and 133.) If the gut has a short mesentery, the intestinal resonance may be in the upper parts of the flanks, or, in case the intestine is occupied by fluid or solid fecal matter, there may be little or no resonance, the entire abdomen being dull or flat to percussion. A large deposit of fat in the omentum may cause dullness in any situation.

In gastropotosis one detects the displaced stomach by inflating it with gas by giving the patient a dram of bicarbonate of soda in half a glass of water, followed by half a dram of tartaric acid in another half-glass of water. Percussion is performed with the patient in the dorsal position and also in the standing position. The lower margin of the liver is percussed in these two positions and the differences of level noted.

Auscultation is of value chiefly in diagnosing pregnancy. The

detection of the fetal heart-sounds, with a rate entirely different from that of the maternal pulse, is one of the absolutely distinctive signs of pregnancy. They are seldom discernible before the twentieth week, although certain observers report having heard them as early as the twelfth week. After the twenty-eighth week they should almost always be heard, if the child is alive, at any rate after repeated examinations. Hydramnios or thick abdominal walls may prevent the sounds from being transmitted to the ear. The sounds are usually heard over the child's back. Therefore, since left positions of the occiput are the most common, the heart-sounds are generally to be heard on a line drawn from the umbilicus to the left anterior superior spine of the ilium.

If they are not heard in this region the entire abdomen should be auscultated carefully. Changes in the position of the child may make the sounds audible at one time and inaudible at another, so that, should there be a failure to hear them, more than one examination is to be made. Occasionally the child's position may be changed by manipulation for purposes of auscultation, so that its back comes against the abdominal parietes of the mother. Some physicians prefer direct auscultation, with the ear applied to the abdomen, to the mediate auscultation of the stethoscope.

The binaural stethoscope is the best means for detecting the fetal heart-sounds. Its mouth should be moistened to do away with the noise generated by the slipping of the stethoscope on the skin. Generally the lightest possible pressure of the stethoscope on the skin is advisable, and to this end it is best to let it rest by its own weight and not to hold it with the fingers. The beating of the fetal heart (130 to 140 beats a minute) has been likened to the ticking of a watch under a pillow. To make the diagnosis sure, the rate should be counted for a minute, and thus it is differentiated from the maternal pulse, which is counted by the physician's finger on the mother's radial artery.

The uterine souffle, or bruit so called, is an intermittent blowing sound synchronous with the patient's pulse. It occurs not only in pregnancy but also in fibroids of the uterus and in other uterine and even ovarian tumors, and is probably due to increased circulation in enlarged blood-vessels. It is of no special diagnostic importance. The noises made by gas in the stomach and intestines are to be detected by auscultation.

In cases of peritonitis, one may determine by this means whether the peristaltic movements of the intestines are still present. Friction sounds made by the rubbing together of roughened surfaces of tumors and adjacent structures may sometimes be heard, also the murmur transmitted from an abdominal aneurysm.

Mensuration is a means of determining the rate of growth of an abdominal tumor. Exact measurements are impracticable because of the varying state of the bowels as to distention or relaxation, and also because of the yielding nature of the tissues and the mobility of the tumors. Nevertheless, much may be learned, in cases of chronic enlargement of the abdomen, by making careful measurements at repeated examinations several weeks or months apart. These are made partly with a tape measure and partly with a pelvimeter, and, for purposes of comparison, all subsequent measurements should be made under as nearly similar conditions as to time of day, time after menstruation, state of the bowels, etc., as possible. They should always be made with the patient in the same position and with all clothing loosened. Very light contact pressure with the tape or pelvimeter on the skin is best.

The measurements to be taken are:—the greatest circumference; the circumference at the umbilicus; the distance from the ensiform cartilage to the symphysis pubis; from the umbilicus to the anterior superior spine of the ilium on each side; and the greatest diameter of the abdomen as measured with the pelvimeter, the patient standing, one point of the pelvimeter being placed over the most prominent portion of the abdomen, and the other over the spinous process of some definite counted sacral vertebra.

Dr. Howard A. Kelly ("Medical Gynecology," p. 17) has devised a method for making permanent gauze records of abdominal tumors and displaced viscera. The patient being in the dorsal position, the physician outlines the tumor and the landmarks, such as anterior superior spines of the ilia, margins of the ribs, symphysis, and umbilicus, on the skin of the abdomen with an aniline pencil. If the skin does not take the pencil marks well, wet it with a little alcohol. Lay a plate of glass over the abdomen and on it place a piece of stiffened gauze (*suisse*, *nainsook*, or *organ-die*). The skin markings are visible through the glass. Reproduce them with a crayon pencil on the gauze. File away the gauze, labeled with the patient's name and the date, for future reference.

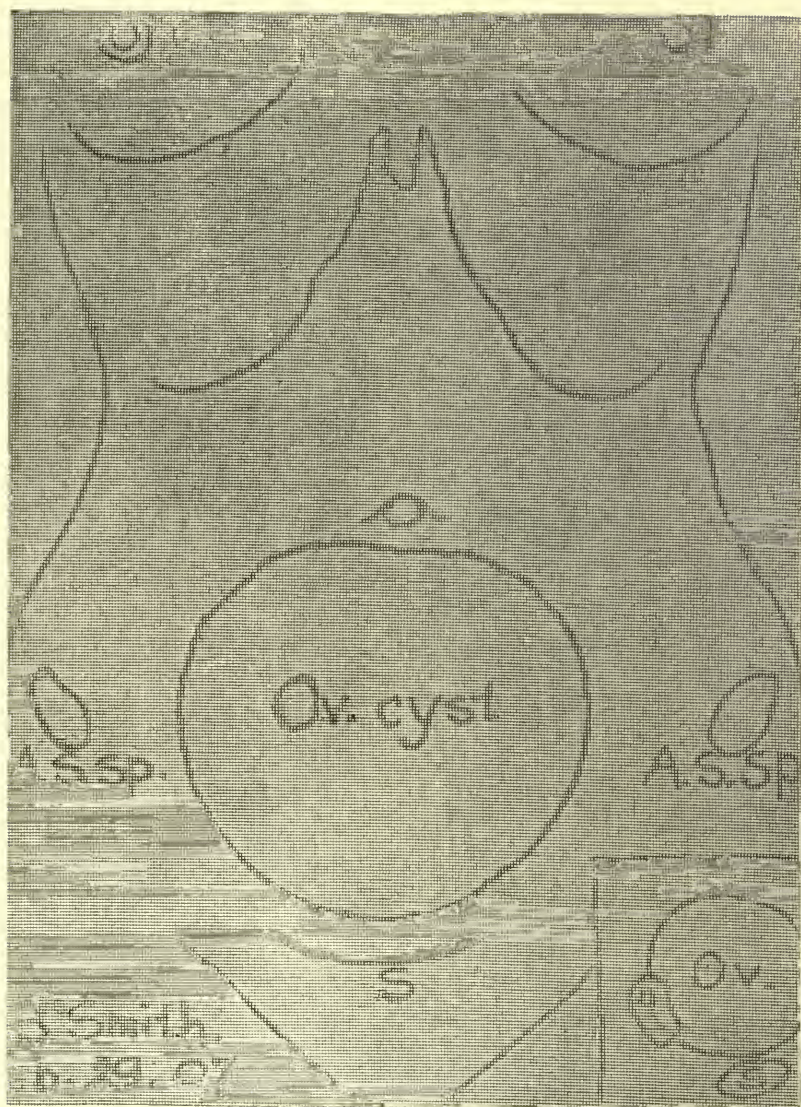


FIG. 20.—A Permanent Gauze Record of an Abdominal Tumor. (Kelly.)

The X-rays in Diagnosis.—The X-rays are of supplementary diagnostic value in detecting stone in the ureter or kidney, and in determining ptosis of the stomach and intestines when these organs are filled with bismuth in suspension, also the presence of bone in tumors,—conditions important for the gynecologist to recognize. One skilled in the use of the Roentgen rays should be called in, as the neophyte is apt to be misled by the appearances seen in the photographic plates, and to put a wrong interpretation on their showings.

CHAPTER VII

THE PHYSICAL EXAMINATION (*Concluded*)

III. The examination (*concluded*): 9. Instruments and their use in diagnosis, p. 77: General remarks, p. 77. The uterine sound, p. 78: When to pass it, p. 78; Methods of passing, p. 79; Facts to be determined by the use of the sound, p. 80; Cautions, p. 82. The uterine probe, p. 82. The uterine dressing forceps, p. 83. The uterine tenaculum, p. 84. The vulsellum, or double tenaculum forceps, p. 84. The vaginal speculum, p. 85: The bivalve, or duckbill speculum, p. 85; The Neugebauer bivalve speculum, the Ferguson speculum, the Simon speculum, and the Edebohls speculum, p. 86; The Sims speculum, p. 87. The Hunter depressor, p. 88. The Emmet curette forceps, p. 89. The uterine curette, p. 90. Curetting, p. 90: Dangers of curetting, p. 93. Digital exploration of the uterine cavity, p. 94. Pelvimetry, p. 95: External or Baudelocque's conjugate diameter, p. 96; The oblique conjugate diameter, p. 97; The transverse diameter, p. 98; The transverse diameter of the outlet, p. 98. The capacity of the pelvic cavity, p. 98; The oblique diagonal diameters, p. 98.

THE EXAMINATION (*Concluded*)

9. INSTRUMENTS AND THEIR USE IN DIAGNOSIS

In a majority of gynecological diseases the diagnosis is made without the use of instruments. They are not the most important part of the physician's equipment. No matter how ingeniously constructed, and be they ever so well adapted to their uses, instruments in these days can not take the place of the educated touch. The physician, particularly the American physician, with his native mechanical bent, although mindful of the revolutionizing of gynecology by the speculum (which his countryman, J. Marion Sims, gave to the world), should forswear the wiles of the instrument-maker and devote his attention to training his touch, leaving instruments to the last.

The immediate followers of Sims and Emmet were so pleased with the newly discovered vaginal speculum and with their ability to inspect the vagina by its skillful use, that they were quite content

to rest their diagnoses of uterine disease on what they saw through the speculum. Hence it followed that for the time other means of investigation were slighted and only in recent years has the profession escaped from the thrall of the speculum.

Out of a number of instruments each examiner and operator will have his personal preference for those which seem best to serve his needs. My full kit of instruments is to be found in Chapter IV., page 28.

The Uterine Sound.—The uterine sound, although employed less and less as skill in the bimanual touch increases, is on the whole the most valuable of the instruments used in diagnosis. In the days of Peaslee, Simpson, and Sims, the use of the sound was much abused, as the other means of diagnosis had not been perfected at that time. The student was taught to pass the sound in nearly all cases of uterine disease, and, as aseptic methods were unknown, the results to the patient were too often disastrous. Not only was the sound passed into the uterine cavity, but malpositions of the uterus were forcibly corrected by this means, thus adding trauma to infection. At the present time the sound is employed to confirm a diagnosis made by the bimanual touch, and in certain rare conditions to make a diagnosis where the touch can not be used.

The sound is to be preferred to the probe because the slightly larger end of the sound will slip over irregularities in the mucous membrane lining the cavities of the cervix and the body of the uterus, while the tip of a probe will catch in them. A sound of small caliber made of flexible copper, with a knob at the distal end, one side of the handle being rough and the other smooth, should be chosen. One side of the handle is made rough so that the operator may be informed as to the direction taken by the point of the bent instrument when sounding a deep and tortuous uterine cavity or sinus. The sound may be graduated in inches or centimeters, according to the preference of the physician. It is easier to keep it clean if it has no notches. The measurements are taken by marking the depth to which it has entered the uterus, by means of the finger tip held against the sound, or the dressing forceps grasping



FIG. 21.—
The Uterine
Sound.

the sound at the external os and then, on withdrawing it, comparing the measurements with a measured scale on the table on which the instruments are placed.

Before passing the sound the vagina must be cleansed in every case. We do not know what bacterial growth may be present in the vagina. Assuming that there are no pathogenic organisms present under normal conditions, some are introduced from the external genitals in the course of the vaginal touch, which always precedes the use of the sound. To cleanse the vagina, swab it out several times with pledgets of absorbent cotton held in the uterine dressing forceps and dipped in a warm solution of creolin and water (one per cent).

The sound may be passed (1) bimanually, the patient being in the dorsal position. To do this the physician seizes a piece of absorbent cotton in the uterine dressing forceps held in his right hand, and carries it through the warm creolin solution; now depressing the patient's perineum with his left forefinger in the vagina, he swabs out the entire vagina, repeating the process several times. Laying down the dressing forceps he takes up the sound. The situation of the external os is determined with the tip of the left forefinger, and the knob-like end of the sound is carried along the left forefinger until it enters the os. The further manipulations are directed by the information as to location, axis and shape of the uterus, gained by the bimanual touch. It is customary to bend slightly the distal two inches of the sound toward the roughened side of its handle. The sound is held lightly in the right hand and allowed to slide in by its own weight. Forceful movements are absolutely contraindicated and unnecessary. The physician who uses force thereby demonstrates that he has failed in his bimanual touch. If the sound does not pass readily it should be withdrawn and the end bent at a different angle and reintroduced. Remember that the barriers to the introduction of the sound are at the external and internal ora. The internal os is always closed except when blood is passing out of the uterine cavity, after labor, or in certain pathological states.

In some cases where the uterus is sharply flexed, and when it is high in the pelvis, the cervix may be grasped with a tenaculum and drawn toward the vulva to facilitate the introduction of the sound. The tenaculum should be a single one, introduced into the

cervical canal, not a double tenaculum, which makes two holes in the cervix and may start a hemorrhage and cause pain.

The sound may be passed (2) by sight. For this purpose the patient is in the dorsal, the Sims, or the knee-chest position. If in the dorsal position the bivalve speculum is introduced and the vagina cleansed. The cervix is steadied with the tenaculum and the sound inserted in the uterine cavity. If in the Sims position the Sims speculum is introduced, and the manipulations are as in the dorsal position. If in the knee-chest position, the Sims speculum is introduced and the vagina balloons with air, the uterus falling forward toward the abdomen. In this position it will be found necessary generally to seize the cervix with a tenaculum and raise it before the sound will enter.

The uterine sound shows the depth and direction of the uterine canal, the size of the external and internal ora, the shape of the uterine cavity, situation of lacerations of the cervix, irregularities of the mucosa, the situation of the pedicle of a uterine polyp or submucous fibroid, the tonicities of the uterine walls, and, by bimanual touch with the sound in the uterus and the hand on the abdomen, the thickness of the uterine walls.

In passing the sound one measures the distance from the external os to the internal os where the tip of the sound catches, and thus estimates the length of the cervical canal. The remaining distance from the internal os to the fundus gives the depth of the uterine cavity proper. In this way are distinguished the uterus of the little girl, the so-called infantile uterus with its long cervix and short body, and hypertrophic elongation of the cervix, an exaggeration of the infantile uterus; the atrophic uterus of old age with small body and shortened cervix; lactation atrophy, and the uterus deprived of its cervix by amputation.

The uterine cavity, as a whole, is increased in size in pregnancy, subinvolution, hypertrophic elongation of the cervix, and new growths. It is diminished in atrophic conditions,—either failure of development or acquired atrophy,—in inversion, and in new formations encroaching on the cavity.

In investigating the direction of the uterine canal it must be borne in mind that the cervical canal may extend in one direction while the uterine cavity is at an angle to it, as in ante flexion and retro flexion. Inflammatory exudate or new growths in the neigh-

borhood of the uterus, by causing displacement, may alter the direction of the canal.

Stenosis of the external os is common in certain forms of ante-flexion where we find the so-called "pinhole os," in senile atrophy, and following improperly performed operations on the cervix. False stenosis of the internal os is apparent in many cases of anteflexion, the sound passing when the uterus has been straightened by traction on the cervix with a tenaculum. True stenosis is found after injuries of the internal os due to too vigorous curetting or to steaming; from inflammation in the tissues in this neighborhood, as in cases of cancer of the cervical canal (adenocarcinoma); in senile atrophy; and it may be congenital, as in hematometra.

Both the internal os and the external os may be enlarged in subinvolution and as a result of laceration.

It is important to determine whether the internal os also is lacerated in cases where there are lacerations in the external os. This is done by the sense of touch communicated through the sound. The situation and extent of laceration are determined partly by recognizing the landmarks in the mucosa of the cervical canal in the form of the arbor vitæ and by trying to reconstruct the cervix in its original form by rolling the everted edges together with tenacula, also by placing the sound over the arbor vitæ with its tip at the middle of the fundus and noting whether a laceration is on one or both sides of the sound. (See Chapter XIII., p. 209.) The sound gives a good idea of the shape and size both of the cervical canal and of the uterine cavity proper.

The physician while passing the sound should keep in mind always the shape of the normal uterine cavity (see Figures 64, 67, and 68, pp. 166, 171, 172), an isosceles triangle, having as boundaries front wall, back wall, fundus, and internal os. There are no side walls, but in their place are the two furrows formed by the meeting of the front and back walls, beginning below at the internal os and ending above in the orifices of the Fallopian tubes.

The internal os being relaxed or dilated, the properly bent sound is passed lightly and methodically over anterior wall, posterior wall, fundus, and lateral furrows, detecting fungosities or inequalities in the mucosa, or a pedunculated growth. The last is very difficult to do, and is not possible in all cases. It is surprising, however, how much may be learned by training the sound-touch.

By sound-touch the firm, elastic resistance of the healthy uterus may be differentiated from the sclerosed tissues of subinvolution or the soft tissues of the septic uterus.

With the sound in the uterus and the fingers on the abdomen or with a finger in the rectum, it is possible sometimes to estimate the thickness of the uterine walls.

Cautions.—The greatest caution is to be exercised in passing the sound in infectious cases, especially in gonorrhœa, because the sound will carry the infective bacteria beyond the natural barriers at the external and internal ora. Also in cases of septicemia and advanced cancer, the sound should be used with circumspection because of the danger of perforation which is most easily made under these conditions, the uterine structure often being so soft as to offer practically no resistance to the passage of the sound through it. Perforation occurs occasionally under such conditions in the hands of the most careful. Never pass the sound into the uterine cavity without first asking the patient the date of her last menstruation. Make this an invariable rule, and, not forgetting the possibility of prevarication, and also having fresh in mind the result of the bimanual examination,—the invariable precursor of the use of any instrument,—you will avoid making that most serious of all gynecological mistakes, the sounding of the pregnant uterus.



FIG. 22.—
The Uterine
Probe.

The misplaced uterus should never be replaced with the sound, a practice much in vogue twenty years ago. If the uterus is freely movable, not held by adhesions, it can always be replaced by bimanual manipulation together with traction by a tenaculum in the cervix, making use of one or more of the various gynecological positions. One attempt should not discourage. More favorable conditions may obtain at another time.

Besides its use in the uterus the sound may be used to investigate the bladder—its situation, as in prolapse of the uterus and in tumors: also the situation of sensitive areas and the presence of stone or phosphatic deposits in the bladder.

The Uterine Probe.—The uterine probe has the same uses as the

surgical probe, and besides having a handle and a long shaft, it can be used to investigate the interior of small uterine canals, and may be bent to conform to tortuous uterine interiors or long sinuses. The probe supplements the sound, but as an aid to diagnosis should not supplant it.

The Uterine Dressing Forceps.—My preference for a dressing forceps is one made on the scissors principle, as this seems best to supplement the hand in uterine manipulations. The forceps known as Bozeman's,—detachable blades with double curve, catch, and serrated jaws,—makes one of the most useful instruments known to gynecological art. With it we not only grasp pledgets of cotton with which to wipe away the discharges and cleanse the vagina, but also remove a bit of stringy, tenacious discharge from the os uteri, or pieces of tissue from the os or vagina for microscopic or bacteriological examination.

By grasping with the forceps the uterine sound while in the uterus at a point where it projects from the external os, the depth of the uterine cavity is measured on a clean towel when the sound is withdrawn.

The curves in the blades of the instrument permit of its entering the uterine cavity or a sinus while the hand which holds it does not obstruct the operator's view. Being made on the scissors principle, levers of the first class with the fulcrum some distance from the jaws, one is able often to open the jaws in a cavity (uterine cavity or sinus), after passing through a narrow opening (internal os), or skin entrance,—something that a forceps made



FIG. 24.—
Uterine Tenaculum.

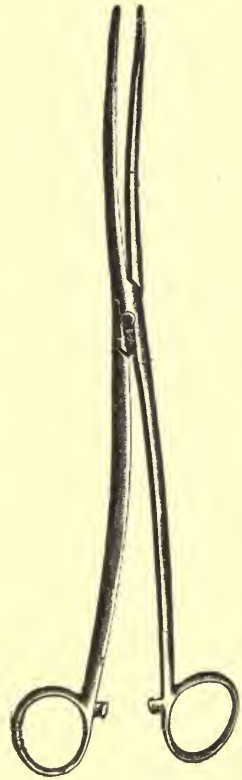


FIG. 23.—Uterine Dressing Forceps.

on the principle of the Sims uterine dressing forceps, levers of the third class, will not do.

In an emergency the Bozeman dressing forceps may be used as a hemostatic forceps. The jaws may be wound with absorbent cotton and thus used to make applications to the interior of the uterus or a sinus, and the forceps may be used also to hold nitrate-of-silver pencils for cauterizing granulations.

The Uterine Tenaculum.—This is to-day a neglected instrument. When used in days gone by to manipulate silver wire, the tenaculum was indispensable. The form of tenaculum devised by Emmet and Sims for shouldering silver wire is the best for general use—*i.e.*, one with a right-angled end, instead of a hook, for the reason that it holds the tissues at the point where it is introduced,—is less likely to tear not only the tissues of the patient but the operator's finger, and it is more readily withdrawn from the tissues when desired. It should be introduced into diseased tissue when possible and does less damage and stays in place better in the hard resistant mucosa of the cervical canal than in the friable mucous membrane covering the vaginal portion of the cervix.



FIG. 25.—Vulsellum Forceps.

Although the double tenaculum forceps, or vulsellum, holds more firmly than the single tenaculum, the single one makes but one puncture, causes less pain and no hemorrhage, and is to be preferred in the routine of examinations.

Tenacula are of immense benefit in diagnosis, in steadying and drawing down the cervix both for the bimanual examination and for inspection, in rolling together the lips of a torn cervix to estimate the situation and extent of the tears, to reconstruct the lacerated perineum by hooking the landmarks and drawing them together, and in seizing and fixing a portion of cervical tissue to be removed for the purpose of microscopical diagnosis. The slender tenaculum does not bruise the tissues as does the tissue forceps.

The Vulsellum or Double Tenaculum Forceps.—In choosing an instrument of this sort one should aim at having it not too heavy and yet with steel enough to prevent the blades springing apart. The so-called American bullet forceps with two points, and having a check on one blade that prevents the blades crossing, is excellent and most useful. Vulsella made after the principle of Museaux's forceps (four points), or the French heavy vulsella (four or more points), are useful in the morcellation of fibroid tumors and the removal of cancer, but have no place in diagnosis. The double tenaculum forceps is useful in holding the cervix during dilatation when it is necessary to have a firmer hold than the single tenaculum will give, and in seizing pedunculated tumors in the vagina, also for holding and drawing down the uterus while practicing the bimanual touch to determine the relation of a tumor to this organ. (See Figure 126.)

The Vaginal Speculum.—As has been said previously, most of the diagnosis in uterine diseases is made by the sense of touch. The vaginal speculum offers us a view of the vagina and vaginal portion of the cervix. Of the multitude of different forms of specula to be had of the instrument makers, the most generally useful are the bivalve and the Sims. The *Edebohls* speculum with weight attached is for use in curetting and manipulations performed with the patient anesthetized. In children a good view of the vagina may be obtained through a Kelly cystoscope, using as large a one as will go through the vaginal introitus without injuring the hymen, the patient being in the knee-chest position.

The Bivalve or Duckbill Speculum.—There are many good forms of this speculum on the market. The writer prefers those called by the names of Brewer and Graves, because of their simplicity and usefulness under varying conditions. More than one speculum should be in every kit for the reason that vaginae vary so in size. With a girl having a narrow vagina and a not easily dilatable hymen, a small speculum is called for, whereas, for a woman having extensive injuries of the pelvic floor and perineum and lax and redundant vaginal walls, a large speculum is a necessity. The patient is in the dorsal position. To introduce the bivalve speculum the left forefinger is anointed with lubricichondrin and both valves of the speculum are smeared with it. The forefinger is introduced into the vagina as in making the digital examination, the perineum

is depressed, and the speculum introduced, the slit between the blades being vertical. Before the speculum has reached its deepest point of entrance it is turned so that the short blade is above and the long blade behind. By means of the lever connected with the handle of the speculum the blades are separated until the cervix is engaged between their ends, then they are held in place by the set-screw on the handle. Some bivalve specula, such as the Graves, are provided with a second set-screw with which to hold the separated bases of the blades, thus increasing the spread of the speculum at the introitus vaginae, and adding to its usefulness in cases of roomy vaginae.

Care must be exercised, in handling the bivalve speculum, not to pinch folds of the vagina and the labia minora between the bases of the blades. This is most easy to do when the vagina is lax and the labia minora long. One objection to the bivalve speculum is that its blades cover both the anterior and posterior walls of the vagina, thereby obscuring them from view. This defect may be overcome in some cases by turning the speculum, first having loosened the lever holding the blades, so that the blades are on either side of the vagina. The cervix is to be brought into view, if it does not readily present, by hooking a tenaculum in the os and drawing the cervix downward.

The Neugebauer bivalve speculum and the Ferguson cylindrical speculum are used by some gynecologists. The latter covers the entire vagina and is of little value in diagnosis. The former requires much skill in handling to prevent pinching the vagina or labia, and when in place has no advantage over the duckbill speculum.

There are various specula for use with the patient in the dorsal position that depress the perineum and posterior wall without covering the anterior wall, such as

The Simon speculum, which is one-half of a Sims speculum. These specula are chiefly useful in operative procedures where the patient is anesthetized and is not called upon to endure the discomfort caused by prolonged traction on the perineum. For operative procedures the simplest and best speculum of this class is *the Edenhols speculum* with a solid flattened weight weighing about a pound and fitted with a hook, instead of the little pail usually sold with the speculum. The weight is made flat so

that it does not take up useful space at the end of the operating table. A weight may be improvised easily out of a piece of lead pipe hammered flat and perforated to take a hook made out of a piece of stout iron wire.

The Sims Speculum.—This, when given to the profession a generation and a half ago by J. Marion Sims, transformed the art of gynecology, and is to be used only with the patient in the Sims position or in the knee-chest position.

The orthodox method of passing the Sims speculum is as follows:—The operator holds the speculum by the unused blade in his left hand and places the well-anointed forefinger of the right hand, along the blade which is to be used, with the palmar surface of the finger fitting the concavity and the tip projecting




FIG. 26.—Brewer Bivalve Speculum.

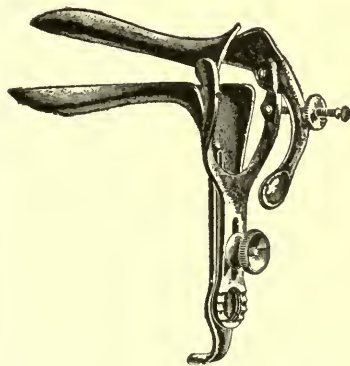


FIG. 27.—Graves Bivalve Speculum.

just beyond the end of the blade. The tip only of the finger enters the vulvar cleft, and while the back of the forefinger protects the sensitive anterior wall of the vagina and introitus, the blade is pushed into the vagina by pressure from the thumb of the right hand on the base of the blade, the unused blade being at the same time transferred from the operator's left hand to the right hand of an assistant.

Another and preferable way is to anoint the left forefinger as for a vaginal examination, except that the palmar as well as the dorsal surface of the finger is smeared with the lubricant, then, hooking the finger about the blade of the speculum, anoint it from base to tip. Finally, pass the same

finger over the vulvar cleft, introduce its tip into the vagina, and carry back the perineum far enough to allow the tip of the speculum to enter. In pushing the speculum home the direction of the vagina is to be borne in mind, its axis being not straight upward in the axis of the patient's body, but directed backward toward the sacrum.

The use of the Sims speculum necessitates an assistant, except for a most cursory examination. The assistant stands on the left side of the table at the patient's back and faces squarely the physician, who is seated in the chair; with all the fingers of the left hand the assistant raises the labium majus on the upper, right side, holding it against the buttock with the hand flat, not with the ends of the fingers dug into the flesh. The assistant's left arm rests on the patient's right thigh. The right hand receives the



FIG. 28.—Sims Speculum.

unused blade of the speculum after the other blade has been settled in the proper place in the vagina. The simplest method of holding the speculum, and the easiest for the novice to learn, is to grasp the unused blade with four fingers of the right hand, the palm of the hand being upward. (See Fig. 11, page 53.)

With the speculum in position air enters the vagina and the pelvic contents gravitate toward the abdomen. Nothing but the posterior wall of the vagina being covered, a nearly unobstructed view of the vagina is afforded. By moving the speculum in or out or turning the tip from side to side, all parts of the vagina may be brought into view. If the vaginal walls are redundant some sort of a depressor will be found useful. For this purpose the best instrument is

The Hunter Depressor.—It should have a flexible copper shank, and a large and a small end, and should be silver-plated. With it

one pushes out of the field of vision the obstructing folds of the vagina. The Hunter depressor has an advantage over the Sims ring-shaped depressor in that its polished silver surface reflects light and therefore aids the speculum in illuminating the deep recesses of the vagina. In many cases the uterine dressing forceps, grasping a small piece of cotton, may be substituted



FIG. 29.—Hunter Vaginal Depressor.

for the depressor. The smallest speculum which will give a good view should be chosen because the small instrument does not stretch the hymen and introitus so much laterally, and thus a longer antero-posterior slit is opened in which the smaller speculum may be moved about freely. It is a mistake to use a large speculum in the case of a tight hymen or narrow vagina, because with it much less of the vagina can be seen and the patient is caused unnecessary suffering. The opening into the vagina should be oblong, not circular, and additional room is obtained only by carrying the posterior wall of the vagina backward.



FIG. 30.—Emmet Curette Forceps.

Looking into the vagina one confirms by sight the information gained by touch and gains additional data. The rugæ are seen, if present, conditions of inflammation are noted, also the caliber, length, and dilatibility of the canal and abnormalities of shape and new growths. The character and amount of the discharge with its reaction, acid or alkaline; the cervix, its shape, size, location, whether lacerated, and if so, the situation and extent of the lacerations as determined both by sight and by use of the sound and tenacula, also the cervical discharge, its character, amount, and reaction are all noted. Cover-glass specimens

and cultures from the discharge may be made if necessary.

The Emmet Curette Forceps.—This is one of the most valuable of the instruments used in diagnosis. With it one removes pieces of tissue from the uterine cavity for examination under the micro-

scope. It has many advantages over the curette, especially in cases of pedunculated growths which often are not caught by the curette. This instrument can not damage the uterine walls, as it does nothing more than pinch the bits of tissue which project above the surface of the endometrium. In selecting a curette

forceps care should be exercised to have the jaws ground true so that they fit accurately together. Many of the instruments on the market are absolutely useless because the jaws have rounded edges which do not fit accurately one to the other over their entire length. In consequence the tissue which is engaged between them slips out and is not pinched tightly and removed as it should be.

Except after labor or abortion the cervical canal must be dilated to a moderate degree with Hanks dilators in order to admit the closed jaws of the forceps. When once in the uterine cavity the jaws are separated and then brought together again. Then they are removed from the uterus and the contents washed off in sterile water. The process is repeated until the anterior and posterior walls of the cavity have been gone over thoroughly and systematically.

The Uterine Curette.—One curette is sufficient for all purposes of diagnosis. This is a sharp loop of medium size, the shaft of the instrument being made of flexible copper so that it may be made to conform to a bent uterine canal. Also with a flexible shaft the danger of doing damage by too forcible curetting is lessened. Following abortion or delivery and when there is flowing, the curette, and often the curette forceps also, may be introduced through the cervical canal without dilatation, except under such conditions

where dilatation is necessary. Curetting should only rarely be performed without an anesthetic.

Curetting.—*Instruments Needed.*—Sound, vulsellum forceps, Edebohls speculum, Hanks dilators, Wathen dilator, curette, curette forceps, two uterine applicators, Bozeman's uterine douche with irrigator bag and tube.



FIG. 31.—
Uterine Curette.

The patient is anesthetized with ether, either preceded by nitrous

oxide or not, according to the preference of the operator. She is placed in the lithotomy position on a Kelly pad with buttocks at the edge of the examining table, the legs being held by an assistant or by portable or fixed leg holders. The bimanual touch is practiced. The vulva, vagina, and surrounding regions are washed thoroughly with several washings of soap and hot water, then with alcohol, and finally with sterile water. Observe that the bimanual touch is made before the washing up. This is because the tactile sense is less interfered with when the vagina is lubricated by the natural secretions. After irrigation and swabbing with alcohol, and especially with solutions of corrosive sublimate, the vagina is dry and clings to the finger, sometimes to such a degree that the sense of touch is very



FIG. 32.—Edebohls Vaginal Speculum.

much blunted. Sterile towels are placed about the field of operation and an Edebohls weighted speculum, previously sterilized with the other instruments, is introduced into the vagina. The anterior lip of the cervix is seized with a double tenaculum forceps and the sound is passed. (For facts to be learned by the passing of the sound see page 80.) The cervix is dilated by passing the graduated Hanks metal dilators. These are safer than the branched steel dilator, which, if carelessly used, makes rents in the uterine walls, more especially in the neighborhood of the internal os. These rents are not always recognized by the operator.



FIG. 33.—
Hanks Uterine Dilator.

If the cervix is rigid it is well to follow the Hanks dilators with a steel branched dilator. The Wathen dilator is one of the best of these. After it has been introduced the blades are to be separated by approximating the handles by manual pressure, not by turning the set-screws, as is so often done. The reason for this is that when using the screw the operator can not judge of the force he employs, whereas, by manual pressure, he can estimate it accurately. When sufficient power

has been applied the screw is turned until the handles are held in place. After the uterine muscle is tired the handles are brought

a little nearer together and the screw takes up the slack,—thus relieving the operator's hands. Fifteen minutes are necessary for dilatation, more if the dilatation is to be excessive, as in cases where it is best to insert the finger into the uterine cavity for purpose of exploration. Dilatation being accomplished, the curette is introduced and the walls of the uterine cavity are gone over systematically, anterior wall, posterior wall, lateral sulci, fundus, and region of the internal os. The curette forceps always supplements the curette and many are the polypi which have escaped the curette that are seized by the curette forceps. The curetting should be stopped when the curette grates on the firmer submucous tissue of the uterine wall. The feeling imparted to the curette is characteristic. The pieces of tissue obtained are collected from the vagina on swabs of wet sterile gauze held in the dressing forceps and transferred at once to a ten-per-cent formalin solution, in which they are preserved for the pathologist. The uterine cavity is irrigated freely with hot sterile water or hot salt solution and swabbed dry with gauze wound around a uterine applicator. Bozeman's uterine douche is as good as any for purposes of irrigating the

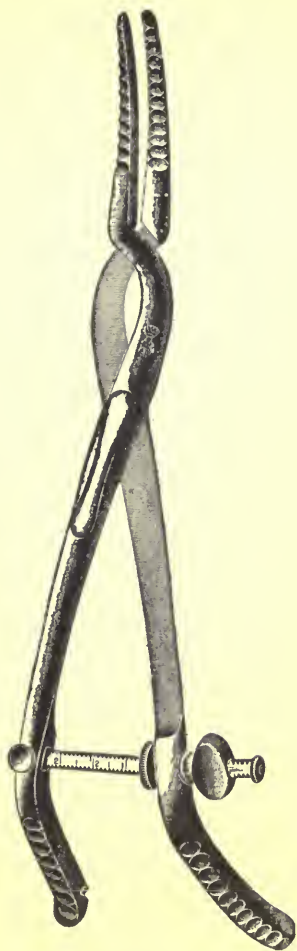

FIG. 34. Wathen Uterine Dilator.



FIG. 35.—Bozeman-Fritsch Uterine Irrigator.

Bozeman's uterine douche is as good as any for purposes of irrigating the

uterine cavity, though in cases of long and rigid cervix, the Burrage uterine speculum is useful both for irrigation and for swabbing the uterine interior. For packing the uterine cavity with gauze, a procedure sometimes necessitated in obstinate hemorrhage, this latter instrument is invaluable, for the gauze slips easily through the metal tube of the speculum into the uterine cavity instead of clinging to the tissues of the cervical canal.

The vagina is now protected by placing a pledget of sterile gauze in the posterior vagina under the cervix, and the uterine cavity is swabbed out with a uterine applicator wound with gauze and dipped in pure carbolic acid. This swabbing serves a triple purpose:—it antiseptifies the uterine cavity, thus providing for possible errors in technique; it mildly cauterizes the uterine interior, thus checking hemorrhage; and it destroys the little islands of tissue which have been missed by the curette. By studying the interior of uteri which have been removed by hysterectomy—a previous curetting without swabbing having been done—it has been my experience to find that there are nearly always present at least one or two bits

FIG. 37.—
Uterine Ap-
plicator.

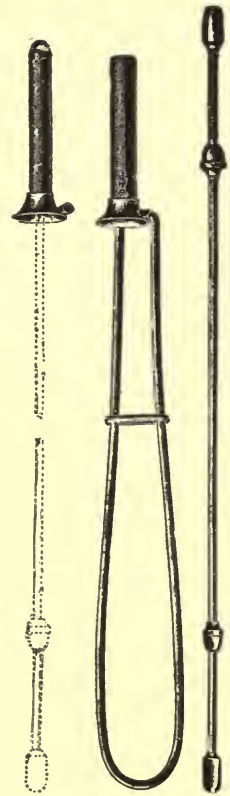


FIG. 36.—Burrage
Uterine Speculum.

of adventitious tissue left behind by the curette. *The Dangers of Curetting.*—These are: (1) perforation of the uterus, a very considerable danger in septic conditions and after labor; (2) hemorrhage, especially after labor or abortion when the uterine sinuses are large; (3) the removal of the entire endometrium and submucous layer preventing regeneration and causing the formation of scar tissue and subsequent sterility; and (4) septic infection from the inocula-

tion of the endometrium with septic matter already there or introduced from without. Perforation is avoided by using the greatest gentleness in curetting septic cases and in using the curette forceps or the finger instead of the curette wherever possible.

If hemorrhage occurs, the uterine cavity is to be irrigated with very hot water (120° F.), and, this failing, it is to be packed with gauze. For this purpose a Burrage uterine speculum and forked

pusher will be found most useful. The removal of the entire endometrium and submucous layer is avoided by observing the directions already given, and the production of septic infection by observing strict asepsis and by not operating during acute attacks of pelvic inflammation.

Digital Exploration of the Uterine Cavity.—This is practiced ordinarily for complete investigation in cases of doubt. The dilatation is effected by means of the Hanks dilators, followed by the Wathen

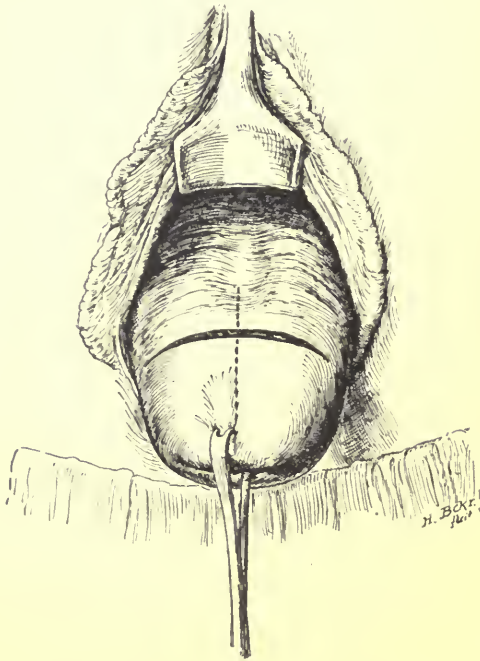


FIG. 38.—Transverse Incision Anterior to Cervix. (Kelly.)

dilator. The Bossi uterine dilator or large steel rectal dilators are useful for the extreme stages of the dilatation. The bare finger should be employed for the exploration because thus the full benefit of the tactile sense is to be obtained. In exceptional cases, those with rigid cervixes where danger of rupture of the tissue is great, a valuable method of exploring the uterine cavity is that described most fully in Dr. Howard A. Kelly's "Operative Gynecology," Second Edition, Vol. I., page 596. An anterior colpotomy is performed, the transverse incision being used. After the vagina

and bladder have been separated from the uterus by blunt dissection, the cervix is steadied by two vulsella and the anterior lip of the cervix is divided between them with scissors to a point beyond the internal os. The digital examination of the uterine interior completed, the divided uterine walls are brought together with sutures and the vagina is then replaced and sutured. In my experience, a certain amount of preliminary dilatation of the cervix facilitates this operation. (See Figs. 38—41.)

The remaining instruments in the examiner's kit, namely, those for the investigation of the urethra, bladder, and ureters, and those for the examination of the rectum, will be described in the succeeding chapters devoted to these subjects.

Pelvimetry.—The gynecologist is frequently consulted by women who wish to know whether they have any pelvic deformity that would be a hindrance to their having children, also

by those who are already pregnant with the same query, therefore it seems best to describe the measurement of the pelvis. B. C. Hirst ("Diseases of Women," p. 419) thinks that deformed pelvis occur in about seven per cent of the white women of large American cities, but that they are comparatively infrequent among the upper classes and in the rural agricultural districts, while frequent among negroes. A general practitioner in a city can hardly hope to avoid seeing cases of pelvic deformity. For the many forms of pelvic deformities the reader is advised to consult a

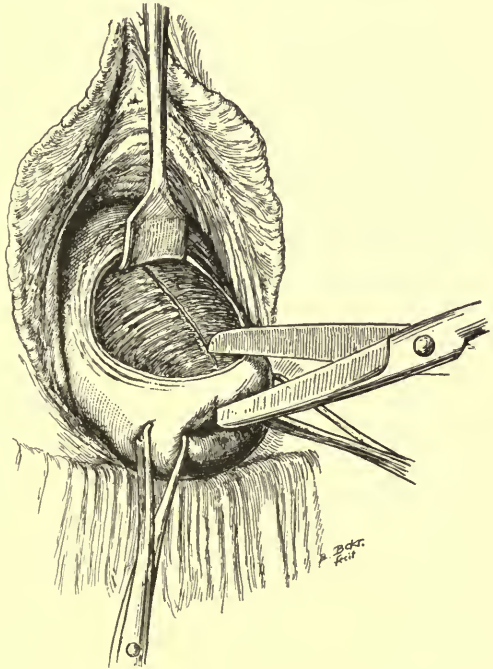


FIG. 39.—Incising the Anterior Wall of the Cervix. (Kelly.)

modern text-book on obstetrics. The commonest forms are simple flat pelvis, generally equally contracted pelvis (justo-minor), and generally contracted flat pelvis. These are all due to faulty development of the skeleton. The other rarer forms are caused by disease of the pelvic bones and anomalies in the sacro-iliac and pubic joints.

To practice pelvimetry successfully one must have a reliable tape measure and a pelvimeter. The latter is a large pair of calipers with a scale divided into centimeters and inches. The measurements to be made are the antero-posterior diameter of the superior strait, the capacity of the pelvic cavity, and the transverse diameter of the pelvic outlet. In exceptional cases of obliquely contracted pelvis it may be necessary to measure the oblique diagonal diameters of the pelvic inlet. The patient must be prepared as for a vaginal examination and should be inspected first in the standing position to note the posture, shape of the back, and inclination of the pelvis.

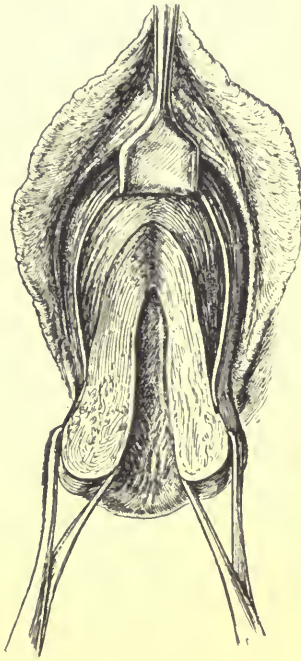


FIG. 40.—Uterine Cavity Laid Open. (Kelly.)

External or Baudelocque's Conjugate Diameter (8 inches, or 20.5 centimeters).—On inspecting the standing woman from behind, one sees in some cases, not in all, Michaelis' rhomboid, a lozenge or diamond-shaped surface on the skin at the base of the spine. The four points making the diamond are:—on the sides, a depression at each upper corner of the sacrum; at the bottom, the notch between the buttocks; and at the top, the depression over the spine of the fifth lumbar vertebra. If this depression can not be seen, the spines of the vertebræ are felt by the finger from above downward until the last one is reached. The tip of the pelvimeter, guided into place by the physician's finger, is placed in the depression just below the last spine. The other point of the pelvimeter is placed on

the anterior upper margin of the symphysis pubis, exactly in the middle line. Firm pressure is made and the reading on the scale of the pelvimeter is taken. The true conjugate can not be estimated accurately from the external conjugate because of the uneven thickness of the pelvic bones in different individuals, and also because of the varying obliquity of the pubic bone. An external conjugate of $6\frac{1}{2}$ inches, 16 centimeters, or under, means surely an antero-posterior contracted pelvis, anything over 8 inches, 20.5 centimeters, is normal or large.

The *oblique conjugate diameter* ($5\frac{1}{8}$ inches, or 12.8 centimeters), or the distance from the promontory of the sacrum to the under margin of the symphysis pubis, may be measured by examining the woman in the dorsal position. Two fingers of the left hand are introduced into the vagina and the middle of the promontory of the sacrum reached with the tip of the middle finger. Be careful not to mistake the last lumbar for the first sacral vertebra and be gentle and not too rapid in performing this manipulation. With the tip of the forefinger of the right hand, mark the point at the base of the thumb of the left hand touched by the lower edge of the symphysis.

After the hand has been removed, the distance between the tip of the middle finger and this point is measured by the tape measure. Subtract from this $\frac{3}{4}$ of an inch, or 1.75 centimeters (representing the thickness of the symphysis), to obtain the true conjugate. The

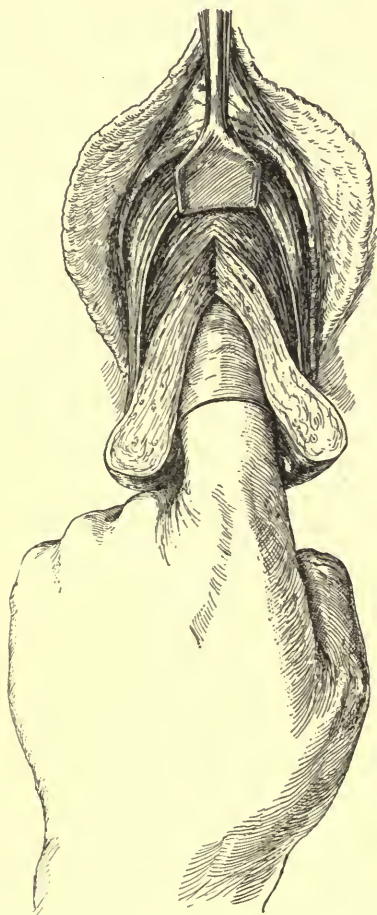


FIG. 41.—Exploring Uterine Cavity with Finger. (Kelly.)

measurement of the normal *true conjugate* is $4\frac{3}{8}$ inches, or 11 centimeters.

The transverse diameter ($5\frac{3}{8}$ inches, or 13.5 centimeters).—This diameter is inferred from measurements of the iliac bones. The distance between the anterior superior spinous processes of the ilia in well-formed women is $10\frac{1}{4}$ inches, or 26 centimeters; the distance between the crests of the ilia at their widest points is $11\frac{1}{2}$

inches, or 29 centimeters; the distance between the trochanters is $12\frac{1}{8}$ inches, or 31 centimeters. In making these measurements the patient is in the dorsal position, but with the thighs extended.

The Transverse Diameter of the Outlet ($4\frac{3}{8}$ inches, or 11 centimeters).—This is the distance between the tuberosities of the ischia and is measured with the patient in the lithotomy position, the pelvimeter being employed as in the other external measurements.

The Capacity of the Pelvic Cavity.—This is an estimate formed by vaginal examination with two fingers in the vagina. When the

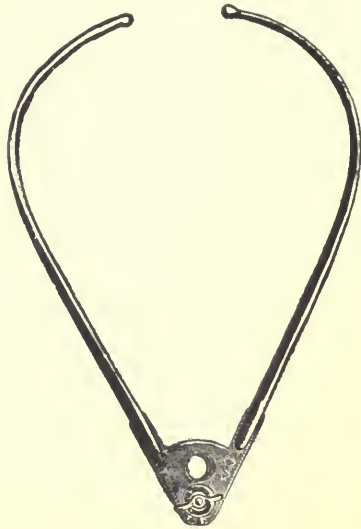


FIG. 42.—The Pelvimeter.

oblique conjugate is being measured the opportunity should be seized to palpate the interior of the pelvis and form an idea of its capacity, as well as a search made for abnormalities in the shape of new growths, old fractures, caries, or necrosis.

The Oblique Diagonal Diameters ($8\frac{3}{4}$ to $9\frac{1}{8}$ inches, or 22 to 23 centimeters).—These are measured by the pelvimeter with the patient lying first on one side and then on the other. One end of the pelvimeter is placed on the posterior superior iliac spine on one side and on the anterior superior iliac spine on the other. The right oblique diagonal is generally a trifle longer than the left. The posterior superior spinous processes are often marked by distinct dimples on the woman's back.

CHAPTER VIII

THE INVESTIGATION OF THE URETHRA, BLADDER, AND URETERS

Instruments used, p. 99.

Anatomy, p. 100. The urethra, p. 100. The bladder, p. 101. Landmarks in the bladder, p. 102. The ureters, p. 104.

The examination, p. 107. Catheterization of the bladder, p. 108. Searching the urethra and the bladder, p. 108. Direct endoscopy and cystoscopy with air distended urethra and bladder, p. 110. Catheterization of the ureters, p. 115. Indirect cystoscopy with water distended bladder, p. 117. Chromocystoscopy, p. 119.

In this chapter we will consider only direct urethroscopy and cystoscopy by means of a simple tube (the Kelly cystoscope) and reflected light, as a means for the inspection of the urethra and bladder, for it has been found in the author's experience, to meet satisfactorily the gynecologist's requirements for diagnosis. Moreover, the method is easily learned and simpler than cystoscopy with a Nitze cystoscope or instrument of that class, by which an electric lamp is introduced into the water-distended bladder. As indirect, electric cystoscopy is applicable occasionally where the air-distended bladder method cannot well be used, and as many physicians prefer it as a method of diagnosis, I have added as an appendix a description of the steps of this sort of cystoscopy as I have seen it employed in competent hands.

INSTRUMENTS USED

Silver female catheter, long.

Kelly meatus calibrator.

Kelly steel urethral sounds, one set.

Kelly cystoscopes, Nos. 8, 10, and 12.

Kelly ureteral searcher.

Two Kelly ureteral catheters.

Rubber bulb and tube for suction.

Alligator bladder forceps.

Uterine applicator.

Sims speculum.

Head mirror.

To this list of instruments are added:

A sterile ten-per-cent solution of cocaine hydrochlorate in water.

A sterile four-per-cent solution of boric acid.

Absorbent cotton.

A sterile eight-ounce bottle with stopper.

Two sterile two-ounce bottles with stoppers.

A two-quart fountain syringe, and a

Collapsible tube of lubriehondrin, or K-Y jelly.

Not every woman who complains of urinary symptoms is to be subjected to a cystoscopic examination. For instance, frequency of micturition associated with early pregnancy, although not precisely normal, generally represents increased congestion of the upper urethra and the neck of the bladder, due to the pregnant state, and is to be disregarded, unless the symptoms are so severe that they undermine the health by interfering with rest and sleep. Only when urinary symptoms are persistent as well as severe, are the urinary organs to be investigated.

Before proceeding to the examination let us review the salient features of the anatomy of the urethra, bladder, and ureters.

ANATOMY

The Urethra.—The urethra is a membranous canal varying from an inch and a quarter to an inch and a half in length (3 to 3.5 centimeters) extending from the meatus urinarius to the neck of the bladder. It lies under the arch of the pubes, its lower extremity being separated from the pubic bone by about four-tenths of an inch (1 centimeter). It is parallel with the vagina and is embedded in its wall, its course being slightly curved, the concavity directed forward and upward. Its diameter when undilated is about a quarter of an inch (6 millimeters).

The meatus urinarius opens into the vestibule just above the opening of the vagina.

In virgins the meatus is a vertical slit about a fifth of an inch long, formed by two little lips which close the orifice and protect it from infection. In old women these lips are lacking.

The wall of the urethra consisting of three coats, muscular, erectile, and mucous, is about one-fifth of an inch thick and is dilatable to a considerable degree, the meatus being the most resistant part. It is not safe, however, to dilate the urethra beyond twice its normal diameter, *i.e.*, beyond half an inch (12 millimeters), because of the danger of permanent incontinence of urine.

When the urethra is not distended the mucous coat is thrown into longitudinal folds, one of which, placed along the floor of the canal, resembles the verumontanum in the male urethra. The canal is lined with stratified epithelium, which becomes transitional near the bladder. In the floor of the urethra are two little tubular glands, half an inch long and about a thirty-second of an inch in diameter, placed length-wise, with their orifices at the meatus, just within or upon the labia urethrae. These are Skene's glands. It is thought that the function of these glands is to secrete a lubricating mucus to protect the meatus from trauma during coitus.

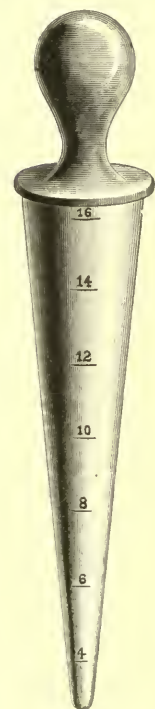


FIG. 44.—Kelly Meatus Calibrator.



FIG. 43.—Silver Female Catheter.

The Bladder.—The bladder, a musculo-membranous sac embedded in connective tissue, when quite empty and contracted is cup-shaped, and on vertical median section its cavity, with the adjacent portion of the urethra, presents a Y-shaped cleft, the stem of the Y corre-

sponding to the urethra. When slightly distended the bladder has a rounded form and is still contained within the cavity of the pelvis; when greatly distended it is ovoid in shape, rises into the abdominal cavity, and may reach as high as the umbilicus. Its capacity is about a pint.

For purposes of description the bladder may be divided into a superior, an antero-inferior, and two lateral surfaces, also a base or fundus, and a summit or apex.

The superior, or abdominal surface, is free toward the peritoneal cavity and is covered with peritoneum; the antero-inferior portion looks toward the posterior surface of the symphysis pubis and is uncovered by peritoneum; the lateral surfaces are covered by peritoneum except in their lower portions where they come in contact with the broad ligaments; the fundus or base of the bladder is directed downward and backward and is partly covered by peritoneum and partly uncovered. It is connected with the anterior aspect of the cervix and with the anterior wall of the vagina by areolar tissue, the union between the bladder and vagina being closer than that between the bladder and cervix.

The upper portions of the bladder are more movable than the lower and when viewed through the cystoscope may be seen to move with respiration.

The so-called neck of the bladder is the point of beginning of the urethra, but it is not a true neck, as there is no tapering part. A tonic contraction of the muscular fibers in

the bladder wall at this point prevents the escape of urine.

The bladder is composed of four coats: serous, muscular, submucous, and mucous.



FIG. 45.—The Kelly Double-ended Urethral Dilator.



FIG. 46.—Kelly Evacuator.

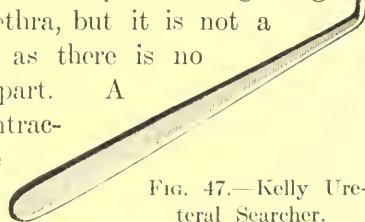


FIG. 47.—Kelly Ureteral Searcher.

The serous coat is derived from the peritoneum and is therefore partial; the muscular coat is made up of three layers of unstriped muscular fibre, two of them being longitudinal, and one, circular in direction; the submucous coat is the areolar tissue which connects the muscular with the mucous coat. The mucous coat is thin, smooth, and of a pale rose color, and is thrown into folds or rugæ when the bladder is empty. There are no true glands in the mucous membrane.

Landmarks in the Bladder.—When the bladder is distended with air it forms a hollow sphere. The internal orifice of the urethra or neck of the bladder is a definite landmark to be recognized by the observer looking through the cystoscope as the first portion of mucous membrane which rolls into the lumen of the cystoscope as its end is withdrawn through the urethra. The ureteral orifices are two minute openings situated in small elevations of the mucous membrane of the bladder (mons ureteris), an inch apart, one on each side of the median line and each three-quarters of an inch (2 centimeters) from the internal orifice of the urethra. These three points mark out the trigone of the bladder.

There is sometimes seen the interureteric ligament, a distinct fold elevated above the level of the surrounding mucosa connecting the ureteral orifices.

The location of lesions in the bladder is described by means of these landmarks and by the natural divisions of the bladder already given.

The Ureters.—The ureters are two cylindrical membranous tubes lying in the loose connective tissue behind the abdominal and pelvic peritoneum, about three-sixteenths of an inch (6 millimeters) in diameter and twelve inches (30 centimeters) long, extending from the pelvis of the kidneys to the bladder. The length of the ureters depends in some measure on the length of the trunk. A patient having a long trunk will have correspondingly long ureters. Different




FIG. 48.—
Kelly Ureteral Catheter.

authorities give the length of the ureters all the way from ten to sixteen inches (25 to 40 centimeters). The left ureter is a little longer than the right because of the higher position of the left kidney. The ureter is funnel-shaped as it leaves the pelvis of the kidney and then the lumen has a diameter of an eighth of an inch (2 millimeters), until the ureter reaches its termination in the bladder wall, where there is a narrowing, which becomes a complete closure when the bladder is distended. This closure

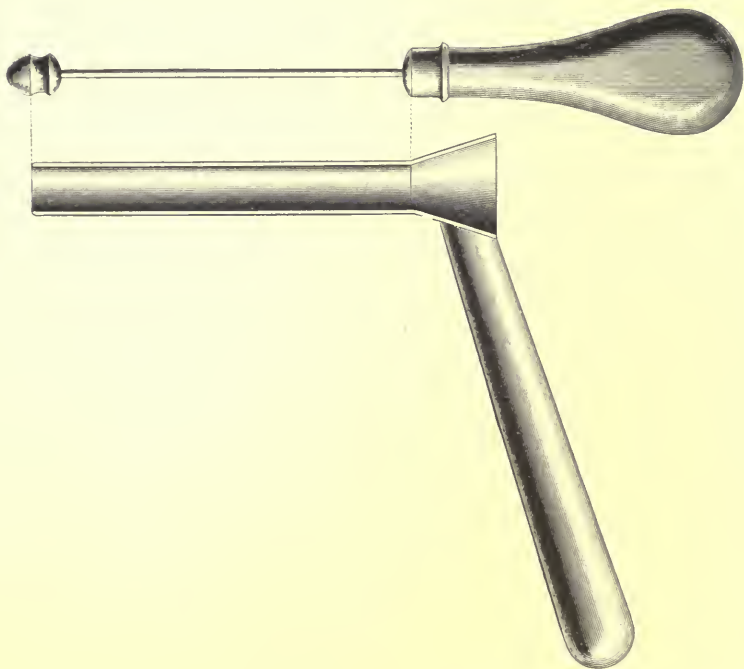


FIG. 49.—Kelly Cystoscope with Obturator.

is effected by the oblique insertion of the ureter in the bladder wall, the mucosa and anterior portion of the bladder wall forming with the upper side of the ureter a wedge-shaped valve, the apex of the wedge being at the ureteral orifice.

The ureter lies on the psoas muscle throughout its abdominal course, at the brim of the pelvis it lies on the common iliac artery. Within the pelvis it runs downward just outside the internal iliac artery, and then, turning forward and crossing under the uterine artery, it passes half-way between the pelvic wall and

the cervix, at a distance of about half an inch from the latter, under the base of the broad ligament to the bladder. The ureter is composed of three coats, fibrous, muscular, and mucous. The fibrous coat is continuous with the capsule of the kidney above and is lost in the bladder wall below; the muscular coat of the ureter proper is made up of three layers: external, internal longitudinal, and middle circular; the mucous coat is smooth and has a few longitudinal folds. It is continuous with the mucosa of the bladder below and the pelvis of the kidney above, and is composed of several layers of cells.

The ureters transmit the urine from the kidneys to the bladder intermittently by means of peristaltic waves traveling the length of the ureter. Through the cystoscope the urine may be seen to issue from the ureteral orifices in little spurts and the ureteral orifices may be seen to expand and contract, the spurts being more forcible and more frequent with greater activity of the kidneys, the normal rate being all the way from one spurt every ten seconds to a spurt every sixty seconds.

Observations have been recorded which tend to prove that the movements of the orifice are less frequent when the kidney on that side is functionally inactive. Infection travels from the bladder up the ureter only when the valve-like arrangement at the orifice in the bladder has been destroyed, or when infective material has been introduced into the ureter, as on a ureteral catheter or bougie.

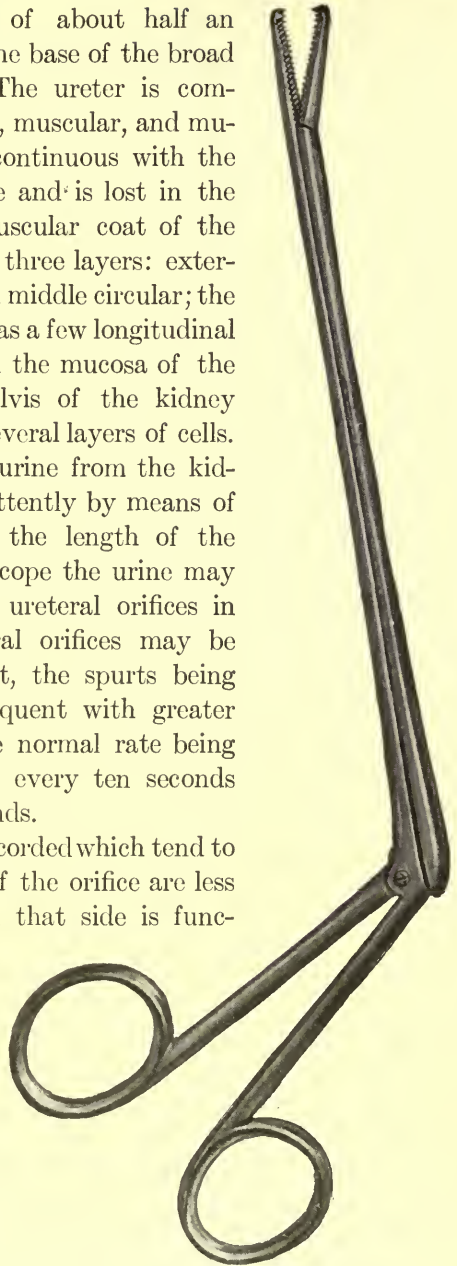


FIG. 50.—Alligator Bladder Forceps.

THE EXAMINATION

Suppose a woman presents herself complaining of marked pain or difficulty with urination, or she has noticed pus or blood in the urine. The examination is conducted as follows: The patient is instructed not to pass her urine, if she is able to hold it. She is placed on the table in the dorsal position (see page 33). The

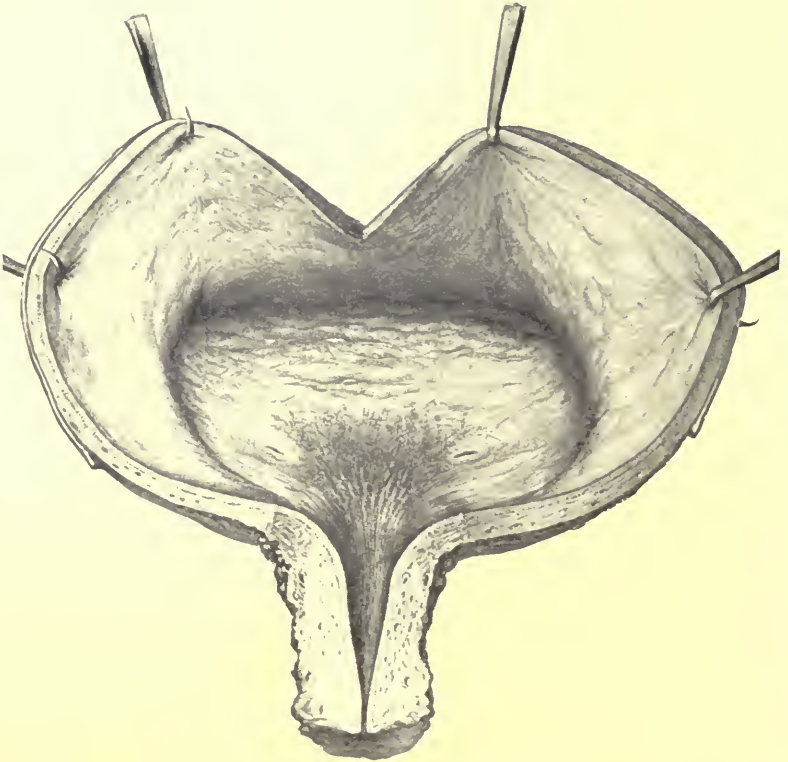


FIG. 51.—The Normal Bladder. Laid Open from the Front. (Kelly.)

external genitals are inspected and a sharp lookout is exercised for evidences of gonorrhœa, for eczematous skin lesions, or abnormalities of the meatus.

Redness about the meatus and the orifices of the glands of Skene and Bartholin, with the possibility of expressing a drop or two of pus from the urethra by stroking its course through

the wall of the vagina, makes gonorrhœa most probable. Gonorrhœa being suspected, no instrument should be passed beyond the bladder neck for fear of carrying infection into that organ.

Inspection shows whether the labia urethræ, which normally close the meatus in virgins, are in apposition or separated; shows the presence of a urethral caruncle or prolapse of the mucous membrane of the urethra or a tumor in the urethra projecting through the meatus. Inspection also shows eczema of the vulva caused by the urine of diabetes mellitus.

Palpation by the left forefinger in the vagina reveals thickening of the urethra and tenderness at any portion of its course, also a

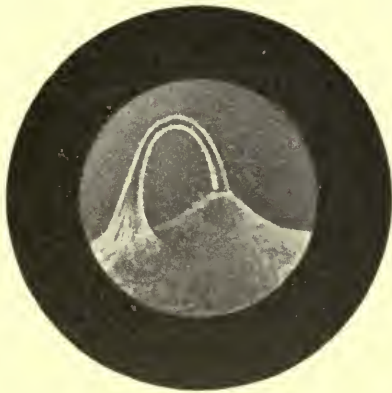


FIG. 52.—Urine Spurting from Ureteral Orifice, as Seen through Cystoscope. (Knorr.)

suburethral abscess or tumor, and the bimanual touch reveals thickening of the bladder walls, a stone in the bladder, points of tenderness, a distended bladder, or a vesico-vaginal fistula. Percussion over the pubes determines an area of dullness corresponding to a distended bladder. The bimanual touch may reveal tenderness of the pelvic portion of the ureter or thickening of the ureter in this part of its course, or a stone in the ureter.

To reach the upper portion of the pelvic portion of the ureter the recto-abdominal bimanual touch is best. Thin and relaxed abdominal walls are a necessity for success in this field of investigation, although a thickened ureter may be palpated in the lowest two inches of its course by a digital vaginal examination, and, exceptionally, a thickened ureter may be seen as a ridge in the

vaginal mucous membrane on speculum examination of the vagina. Palpation having furnished what information it will, the next step is the passage of the silver catheter.

Catheterization.—I prefer a long catheter of small caliber, because it may be used both as a searcher of the urethra and bladder as well as a catheter. The meatus, vestibule, and inner surfaces of the nymphæ are sponged with three or four pledgets of cotton soaked in sterile water or weak creolin solution, each pledget being thrown away as soon as it has been used once. That is, a piece of cotton is never dipped a second time in the water. Normally the urethra, as in the case of the vagina, except just inside the external opening, is free from bacteria. Well lubricated, the sterile catheter is passed gently into the bladder, the direction of the urethra being borne in mind, at first backward parallel with the axis of the vagina until the bladder neck is reached, and then forward. Care should be taken not to touch the outer end of the catheter before the urine is collected, and the lubricating should be done directly from the collapsible tube without the intervention of the physician's fingers.

The urine from the bladder is collected in the sterile eight-ounce bottle for analysis, note being made of the character of the urine as it flows from the catheter, whether clear, cloudy, or bloody. Blood at the beginning indicates that its source is the ureter or kidney. Also whether the last part is cloudy, showing residual pus; and the force of the stream, increased in distended bladder and in cases of pressure on the bladder by tumors or straining, decreased in atonic bladder. Suprapubic pressure may be necessary to empty such a bladder.

Searching the Urethra and Bladder.—After the urine has been withdrawn the catheter is used as a searcher, the greatest gentleness being employed. The bladder walls are gone over systematically and points of tenderness noted. With a finger in the vagina and the searcher catheter in the bladder the thickness of the bladder wall at the base is estimated: a stone, foreign body, or phosphatic deposits are detected by a gritting sensation transmitted to the catheter, or, in the case of a stone, by a metallic click; sometimes a tumor is diagnosed in this way. In cases of cystitis it is not wise to sound the bladder at the same time that a cystoscopic examination is to be made because the slightest trauma will cause bleeding.

The discharge of blood through the catheter at the end of catheterization is a diagnostic sign of cystitis.

If there is suspicion that the bladder is contracted, its capacity may be measured by injecting with the fountain-syringe tube attached to the catheter, warm, sterile, one-per-cent boric-acid solution until the patient has a strong desire to urinate. Then disconnect the syringe tube and collect and measure the water issuing from the catheter. In cases of cystitis it is wise to irrigate the bladder with boric-acid solution before ending the examination. For this purpose the process just described is repeated several times. It is to be noted that the catheter has not been removed from the bladder since it was introduced, thus a minimum of trauma is inflicted on the urethra and vesical neck.

The bladder searching being finished, the catheter is withdrawn slowly; clonic spasm of the bladder walls is noted in some cases, indicated by a drumming of the movable upper portion of the bladder on the less movable base. If the bladder is irritable or the muscular fibres hypertrophied, the catheter is seized with greater firmness at the bladder neck as it is withdrawn.

When the end of the catheter reaches the urethra one notes: points of tenderness, pouches in the mucous membrane or abnormal size in the lumen, also stricture, by no means rare, its situation and relative size. With a finger in the vagina and the end of the catheter in the urethra one determines the thickness of the walls of the urethra, the extent of any pouching of the mucous membrane, due to rupture of the walls from trauma during delivery, and also dislocation of the urethra downward. This is a common deformity and one often overlooked. To detect it the investigator observes whether the urethra is in close relation with the under surface of the arch of the pubes as it should be normally, or far away from it, as it is when dislocated. In cases of prolapse of the uterus the urethra, together with the bladder, is commonly dislocated to a variable degree. Suppose the upper third of the urethra is dislocated downward with the bladder. The catheter is passed into the urethra most gently until it meets the obstruction of the downward bend of the urethra. The point of the catheter is noted by palpation by a finger in the vagina and thus the situation of the beginning of the dislocation is determined.

In the case of procidentia, if the bladder is dislocated a curved

uterine sound is to be substituted for the catheter and the situation of its point, as felt by the finger, marks the lower limits of the bladder in the prolapsed mass.

Having gained all the facts possible by the use of the catheter, the next proceeding is inspection of the urethra and bladder.

Direct Endoscopy (*Inspection of the Urethra*), and **Direct Cystoscopy** (*Inspection of the Bladder*).—The patient is in the dorsal position. The bladder has been emptied of urine. The tip of the meatus calibrator is passed into the urethra and the size of the undilated meatus is read on the scale of the calibrator. Suppose it reads 6 millimeters. A No. 10 cystoscope may be used and the meatus must be dilated a little. This should be done by gentle pressure on the conical calibrator and twisting it, care being taken that the lubrication is ample. If the tissues about the meatus prove to be rigid it is wise not to make all of the dilatation at one sitting, for the patient's confidence will be lost if she is hurt too much. If there is a stricture of the urethra it must be dilated with the double-ended steel dilators, and the dilatation should occupy several sittings. The meatus being stretched to 10 millimeters without laceration or excessive pain to the patient, the next step is the cocainization of the urethra. Sometimes, if the meatus is sensitive, it will be found best to use the cocaine before dilating the meatus.

To cocainize the urethra wet the terminal two inches of the uterine applicator and wrap it, using a sterile rubber glove to handle the cotton, with a thin layer of absorbent cotton so that the diameter of the wrapped applicator is about three-sixteenths of an inch (4 millimeters). Soak this in sterile ten-per-cent cocaine solution gently insert the applicator into the urethra, hold the cotton at the meatus with two fingers while the applicator is withdrawn with the other hand, leaving the cotton in the urethra.

It is well not to pass the tip of the applicator beyond the neck of the bladder, because if this is done ardor urinæ is likely to be evoked and, the cotton acting as a wick, urine will drip from the end projecting from the meatus, thus diluting the cocaine and soiling the patient's clothing while she is being put in the knee-chest position for the cystoscopy.

A knee-chest position, modified from that described on page 56, is the one commonly employed for cystoscopic examinations.

In this case the thighs are not vertical as in the correct knee-chest position, the knees being nearer the chest. In very stout patients and in certain operative cases the raised pelvis position (page 58) is employed. By the time all the instruments are ready, the room is darkened, and the patient is well settled in the correct knee-chest position (four or five minutes), the cocaine should have produced sufficient anesthesia of the urethra to permit us to proceed with the cystoscopy.

Artificial light is necessary for cystoscopy. An electric light, gas light, or a kerosene lamp is to be chosen in the order named. The ordinary sixteen-candle-power electric lamp is sufficient, a

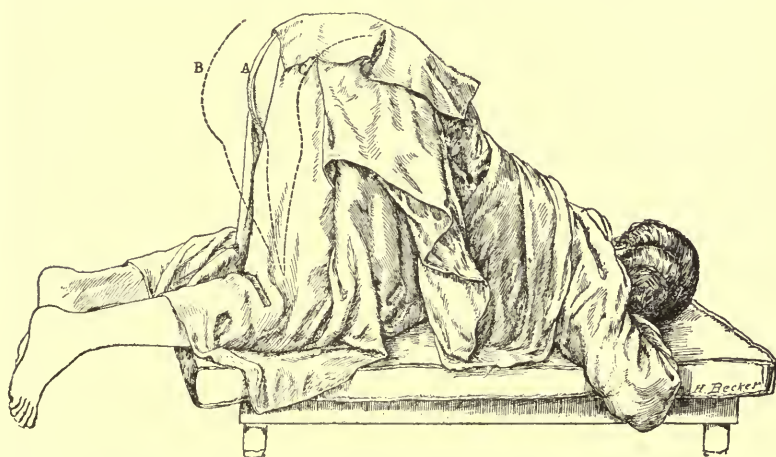


FIG. 53.—Modified Knee-chest Position Used in Cystoscopy. *B.* Is position of Buttocks in the Modified Position.

thirty-two-candle-power lamp with a tin reflector is better. An argand burner makes the best gas light, but a Welsbach light is good. A kerosene lamp must have a circular burner so as to give a large flame. Any lamp should have the shortest possible stand so that the source of light may be as near to the patient's sacrum as possible, in order that the angle formed at the mirror on the operator's forehead between the rays from the source of light and the reflected rays going into the bladder may be as acute as possible. It should be remembered that the electric light, if held near the uncovered skin for any length of time, will cause a serious burn. If the patient is anesthetized this is a very important fact to bear in mind.

Light reflected by a head mirror from an ample source is far better as an illuminant of the bladder than light from a small

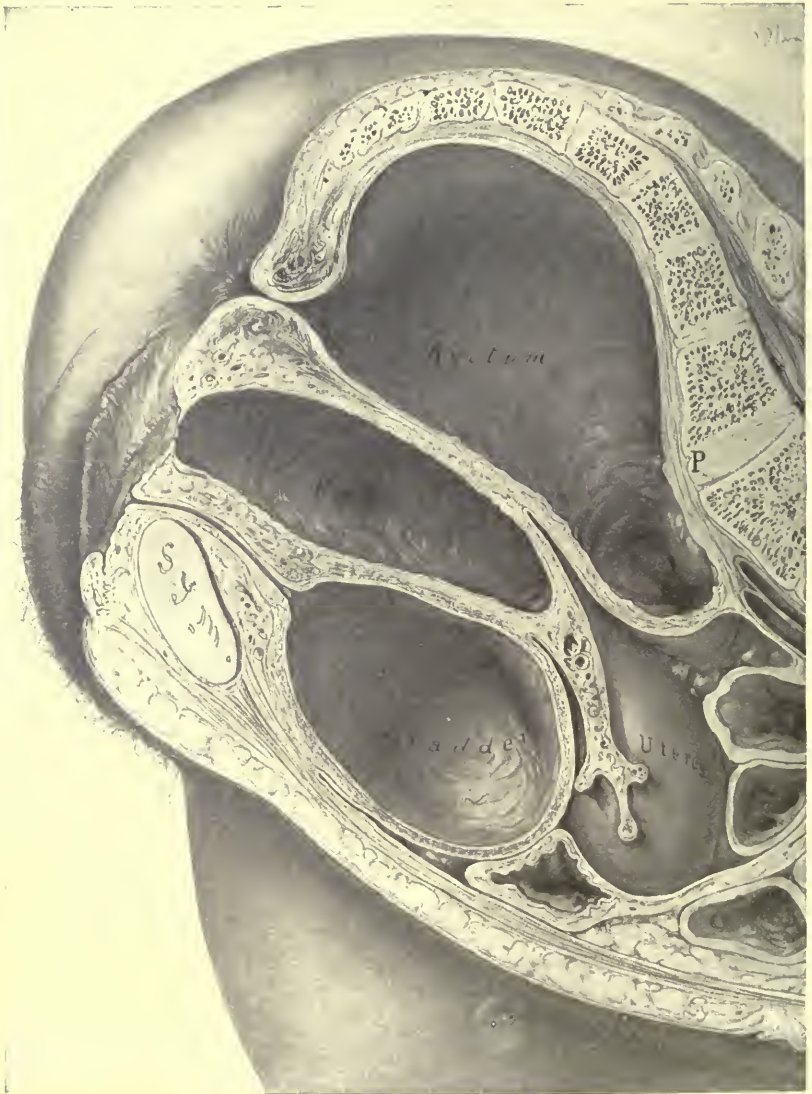


FIG. 54.—Bladder, Vagina, and Rectum Ballooned by Air Admitted with Patient in Knee-chest Position. (Kelly.)

electric headlight, because it is difficult to keep the field illuminated with the small light, every motion of the head deflecting the rays.

Any form of illumination introduced into the bladder obstructs the view, the wires for the lamp cutting off a part of the lumen of the urethra, besides the risk of burning the bladder by the heat generated by the lamp.

All being in readiness, the pledget of cocaine-soaked cotton is removed from the urethra and a well-lubricated No. 10 cystoscope with its obturator in place is passed into the urethra and bladder. If air does not enter the vagina it is well to open the introitus

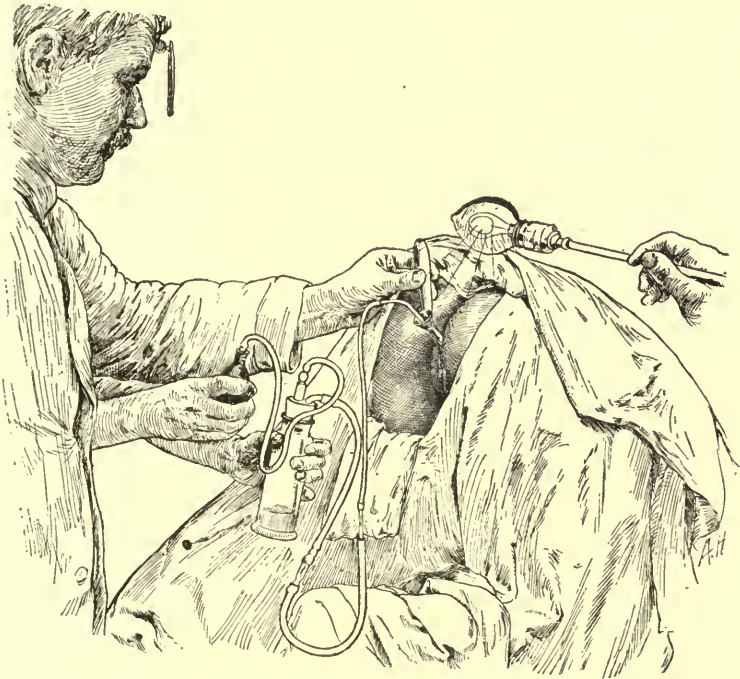

FIG. 55.—Suction Apparatus in Use for Removing Urine from Bladder. (Kelly.)

vaginae with one finger. If the bladder does not balloon at once, the silver catheter, previously cleaned and lubricated, is passed through the sphincter ani, thus letting air into the rectum, and permitting the trigone of the bladder to come more into view through the cystoscope.

The operator sits on a high stool and looks through the cystoscope, which should be practically horizontal if the patient is in the proper position.

If urine has collected in the superior portion of the bladder, or if it collects during the examination, it is to be removed by the bent tube introduced through the cystoscope, suction being applied by means of the bulb and rubber tube attached to the tube in the bladder. The greatest care should be exercised to have the bulb and tubes sterile, so that infection may not be introduced, and to this end the bulb should be squeezed and held collapsed while the end of the tube is rinsed in sterile water before it is introduced. A modified chemical-laboratory wash-bottle may be used for removing the urine, as shown in figure 55.

In cystoscopy with the patient in the elevated-pelvis position the collection of urine at the fundus of the bladder is much more troublesome than it is when the patient is in the knee-chest position, for in the latter position the urine falls into the capacious superior part of the bladder behind the pubes.

The different landmarks of the bladder are sought for, the ureteral orifices inspected. Bits of tissue may be removed from ulcerated areas or new growths with the alligator forceps; cultures taken, or the ureters catheterized. Of the last, more shortly.

A culture is taken by bending the handle of a sterile cotton-tipped uterine applicator so that the applicator will pass through the cystoscope without obstructing the view. After the desired area in the bladder has been swabbed with the cotton, the latter is drawn over the surface of the slant agar tube, hydrocele agar being used when gonococcus infection is suspected.

To find the ureteral orifices first determine the situation of the internal opening of the urethra. This is done by noting the point at which the urethral mucous membrane begins to roll into the lumen of the speculum. The trigone, which is more injected than the rest of the bladder, is the space between the two ureteral orifices and the opening of the urethra. It is small; therefore, the ureteral orifice is near at hand. If a V is marked on the external upper part of the cylinder of the cystoscope, with its point toward the bladder end and the sides of the V separated by an angle of thirty degrees, the ureteral orifice on one side may be found by bringing an arm of the V parallel with the axis of the urethra, when the cystoscope will point toward the ureteral orifice on the same side. The ureteral opening is a little slit situated on the *mons ureteris*, a slight eminence.

Inspection of the urethra, endoscopy, is practised as the cystoscope is withdrawn. The neck of the bladder is recognized as the first part of the rolling-in rim of mucous membrane coming into the lumen of the cystoscope as the latter is being withdrawn. Then in succession follow the different portions of the urethra, the meatus being last. After the patient has been restored to the dorsal position following cystoscopy in the knee-chest position, it is essential to pass the silver catheter into the bladder to let out the air which has accumulated. If the physician remembers to do this the patient will be spared the ardor urinæ and the discomfort which attend a distended bladder. Occasionally the endoscope of Skene or the urethral bivalve speculum recommended by him are of great service in viewing the interior of the urethra, especially in investigating new growths. These instruments have not been included in the list of instruments necessary for the investigation of the urethra, because the cystoscope generally answers every purpose of diagnosis, and simplicity of technique is aimed at in this book.

Catheterization of the Ureters.—If the bladder is the seat of infective inflammation the physician should debate seriously the advisability of catheterizing the ureters, more especially if he has reason to believe that the ureters are not infected. If it is a question of unilateral gonococcus or tuberculous infection of kidney and ureter with enlarged kidney and thickened ureter, the diseased ureter should be catheterized, the healthy ureter should not be catheterized, because of the great danger of introducing septic matter into a sound ureter, the problem being similar to that of passing the catheter through the neck of the bladder in cases of gonorrhœa of the urethra, or of introducing instruments beyond the internal os uteri in infections of the vagina and cervical canal. Nature has set up well-defined barriers against infection, and the physician should be assured of good results to follow before breaking them down.

The ureteral orifices are found by depressing the handle of the cystoscope and carrying it to one side while the tip is raised toward the patient's sacrum. The dimensions of the trigone are borne in mind and the orifice shows in the proper place as a minute opening from which a drop of urine spurts every few moments. The rapidity of the flow of urine is dependent on the activity of the

kidney, on the amount of fluids the patient has recently taken, and on the state of the nervous system. Sometimes it is advisable to regulate these factors before proceeding with a cystoscopy. Both orifices should be found before a catheter is passed, because in some cases the orifice may be displaced by uterine malpositions, by pelvic inflammation, or by other abnormalities of the pelvic organs.

The ureteral orifice being found, the ureteral searcher is passed into it to make sure that it is the ureter and not a pocket in the mucous membrane. Then the catheter is passed and the cystoscope is withdrawn over it. The cystoscope with its obturator in place is reintroduced beside the catheter and the opposite ureteral orifice is found and catheterized in similar fashion.

Now the patient is gradually lowered into the dorsal position, the physician guarding the ends of the catheters as she moves.




FIG. 56.—Nitze's Model of Ureter Cystoscope for Catheterizing Both Ureters.

The sterile two-ounce bottles collect the urine from each ureter, the amount of urine and the time of flow being noted on each bottle as well as the ureter from which the urine came. Great care is to be taken to mark the bottles correctly, and to this end it is best to stick a gummed label on each bottle before the catheterization, and to mark the bottles at once after they are used.

In exceptional cases something may be learned as to stone in the ureter or stricture of the ureter by passing ureteral bougies. Wax-tipped bougies have been used with success in diagnosing stone in the kidney, but much skill, gained by long experience in this field, is necessary to produce results.

Catheterization of the ureters with the patient in the elevated-pelvis position, a more convenient position when an anesthetic is used, is conducted much as in the knee-chest position. The light is held close to the patient's pubes and the operator stands looking downward, through the cystoscope to the trigone. When

the catheters are in place the patient's pelvis is lowered to the table.

It should be remembered that the cystoscopic appearances and the situation of the ureteral orifices are altered by malpositions and tumors of the uterus and by other pelvic tumors. For instance, in prolapse folds appear in the bladder mucosa after reposition of the uterus and the cystocele.

Indirect Cystoscopy with Water-Distended

Bladder.—The instruments necessary are:—a Nitze cystoscope with wires and electric-light connection, a current controller and source of electricity, such as the street current or a storage battery, irrigating bag and one-per-cent boric-acid solution, urethral calibrator, urethral catheter, uterine applicator, absorbent cotton, and cocaine. The bladder should have a capacity of at least five ounces and the fluid should be clear; if it is not, an irrigating cystoscope must be employed. The patient is in the dorsal position; the meatus urinarius is dilated with the urethral calibrator (cocaine being used if necessary as described in direct cystoscopy, page 110) until it will admit a No. 25 French sound, the usual diameter of most cystoscopes. If there is a stricture of the urethra it must be dilated. No bleeding should accompany the introduction of the cystoscope, because it will spoil the view in the bladder. Before introducing the cystoscope fill the bladder with boric-acid solution and allow it to run out until the water is clear, then from five to seven ounces are injected and the catheter withdrawn. The cystoscope is connected with the source of light and the lamp tested. Then the current is turned off and the instrument is smeared with lubrichondrin and introduced, care being taken to depress the handle as the curve passes the neck of the bladder.

The following are the appearances of the bladder as seen through the cystoscope according to Casper ("A Text-Book of Genito-Urinary Diseases"). The normal mucous membrane of the bladder varies from light yellow to pink, being redder at the base than in




FIG. 57. — Current Controller for Use with Electric Cystoscope.

other parts. In the course of a prolonged examination urine is poured out into the bladder by the ureters and the color of the mucosa becomes redder because of the yellowness of the medium through which it is seen, also if the brightness of the light diminishes the color becomes redder, therefore the light should be bright

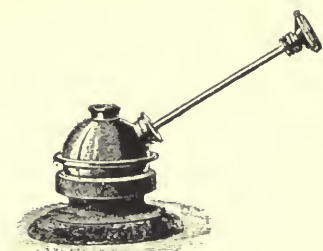


FIG. 58.—Bladder Phantom for Practising Cystoscopy.

and white. The delicate ramifying blood-vessels, especially well marked at the fundus, are similar to the vessels seen with the ophthalmoscope at the fundus of the eye. Bundles of muscle fibers, parts of the detrusor vesicæ, make little ridges in the bladder walls, especially in the superior and lateral portions. Exaggerations of these ridges become the "trabecula" in the cases of hypertrophy of

these muscles when increased work has been thrown upon them, as in stricture of the urethra. Between the trabeculae may be diverticula, which look like deep excavations in the bladder wall. A shadow will cover a part of the circular field of vision if the cystoscope is withdrawn from the middle of the bladder. This is due to the fact that a part of the prism in the cystoscope is covered by the sphincter vesicæ muscle. Carrying the beak of the instrument downward brings the base of the bladder into view, and pushing it a little backward and to one side brings the opposite ureteral elevation into the field. If the ureteral eminence is watched for a little time it will be seen to swell up suddenly, make a convulsive movement, and at the same time an eddy will be observed in the bladder fluid. This is the periodic discharge of urine. If the urine is discolored the bladder fluid will have to be renewed either by irrigation through a catheter or an irrigating cystoscope. Often the urine from one ureter will be clear and from the other cloudy.

This form of cystoscopy, like the direct form, should not be used in the presence of acute inflammation of the bladder and it can not be employed in the case of a contracted bladder. In chronic catarrhal cystitis the mucous membrane appears to be puffy, velvety, and red, and is coated with secretion. The vascular network is no longer visible, the surface of the bladder looking

cloudy and dull. Scales and flakes of secretion are found floating free in the fluid or on the bladder wall. Tuberculous cystitis shows nodules surrounded by a red border situated mostly on the floor of the bladder, and in advanced cases distinct ulcers are visible. Tumors of the bladder give especially good pictures with this form of cystoscope and so do vesical calculi. Foreign bodies can be distinguished and their size and shape determined, and a ureteral catheter, introduced into a ureter, may be seen disappearing through the ureteral orifice and throwing a shadow below it on the base of the bladder.

To those who are interested in this form of cystoscopy the following books are recommended: "Die Cystoskopie beim Weibe," Dr. Richard Knorr; "Handbuch der Cystoskopie," Dr. Leopold




FIG. 59.—Luys Urine Separator. It Divides the Bladder into Halves by a Removable Diaphragm and the Urine from Each Half is Collected by a Separate Tube.

Casper; "Handatlas der Cystoskopie," Dr. Otto Kneise; "A Handbook of Clinical Cystoscopy," E. Hurry Fenwick.

Chromocystoscopy.—Chromocystoscopy is a method of investigating the functional capacity of each kidney that has been used abroad for the past six years with success. It consists of cystoscopy with water-filled bladder. Fifteen minims of a five-per-cent aqueous solution of methylene blue are injected into the buttock. In five minutes, more or less in individual cases, the urine is rendered blue and can be seen through the cystoscope spurting from the mouths of the ureters. The urine from the two ureters is compared as regards the following points:—The interval before its appearance, the intensity of the color, the number of jets to the minute, and the force of the jet. If one ureter eliminates dark blue urine while there is no trace of stain in the urine from the other

kidney, there may be obstruction by a stone in the ureter giving colorless urine, or compression of this ureter so that the passage of the urine is delayed, or such extensive destruction of the kidney tissue on this side that the stain has not been excreted. The method is said to obviate the necessity for ureteral catheterization in many cases and to give a reliable indication of the functional capacity of each kidney, besides affording a means of finding an otherwise hidden ureteral orifice.

CHAPTER IX

THE INVESTIGATION OF THE RECTUM

Inspection of the anus, p. 121. Anatomy of the rectum, p. 121. Digital examination, p. 123. Proctoscopy, p. 124. Stretching the sphincter and speculum examination of the rectum with an anesthetic, p. 126.

THE frequent association of rectal and gynecological affections makes the diagnosis of the former important, also symptoms in gynecological disease are so often referred to the rectum that it becomes most necessary to eliminate rectal disease.

Of course the rectum should be empty before an examination is made, an enema being given if there is any doubt on this point, and it should be given always in cases where the rectum is to be investigated with the proctoscope. In those cases in which there is protrusion of the bowel only at stool, the patient should go to the closet before the examination.

Inspection of the Anus.—The best position for both visual and digital examination is the Sims position. Inspection of the anus may show external hemorrhoids, and internal hemorrhoids after the patient has just been to the closet, external fistulæ, ulcerations, pin worms, abscess, fissure, and skin diseases, such as eczema and venereal warts. If the buttocks are separated by the hands and the patient bears down, a fissure may be brought into view.

Some points in the diagnosis have been obtained already from the vaginal examination. Tumors can be ruled out by the vaginal touch. The sphincter ani is now everted by a finger in the vagina pressing the rectal wall out through the anus, thus affording an opportunity for study and a search for hemorrhoids, polypi, ulcerations, fissures, or fistulae. This procedure can not, however, be executed in virgins with unstretched perineæ, a reasonable amount of injury or elasticity of the perineum being a necessity.

Before taking up the digital examination let us review a few points in the anatomy and physiology of the rectum.

Anatomy of the Rectum.—The rectum is about eight inches long, merging above into the sigmoid flexure of the descending colon at

the left sacro-iliae articulation, there being no distinct point of separation between the two. The upper portion, four inches long, is almost completely surrounded by peritoneum. The peritoneum is reflected from the anterior surface of the middle portion or ampulla, which is three inches long, at a point about two and a quarter inches from the anus to pass on to the posterior wall of the vagina. As the anterior and posterior walls of this part of the rectum are in apposition when it is not distended by feces or gases, it appears in sections as a transverse slit. The third portion, or anal canal, an inch long, is the part surrounded by the internal sphincter above and external sphincter below, and supported by the levatores ani muscles. When empty this part is seen in a vertical median section as a longitudinal slit. It is to be borne in mind that the long axis of the canal of the anus is nearly horizontal when the patient is in the erect posture and is at approximately a right angle to the long axis of the two upper portions of the rectum,—therefore the anus discharges the fluid fecal contents not downward in the axis of the body, but backward. The soiled state of the rear boards of a country privy bears testimony to this fact in anatomy. When solid fecal masses are passed the anal canal is taken up much as the cervix uteri is taken up during labor, and the feces are extruded downward. This obliquity of the anal canal to the main lumen of the rectum lessens the direct strain on the sphincter made by accumulations of fecal matter and gases.

The rectum is composed of four coats,—serous, muscular, areolar, and mucous. It is similar in structure to the rest of the large intestine, except that the semilunar folds of the mucous membrane to be found higher up in the bowel are here strongly developed, so that they form shelves projecting into the lumen of the gut. These shelves or valves (valves of Houston) are generally three in number, two high up, are on the sides of the rectum, a third and the largest, is in front opposite the base of the bladder. When a fourth is present it is in the ampulla on the posterior wall about an inch above the anus. These valves are disposed alternately. When the rectum is empty they overlap each other so that it is difficult to pass a bougie or other foreign body by them. Their function is probably to support the weight of fecal matter and prevent it from impinging on the anus where its presence is sure to excite a desire

for defecation. Just above the internal sphincter the mucous membrane is thrown into three or four longitudinal folds on each side. These are known as the columns of Morgagni. Between them are little pockets, or valves.

The vessels of the rectum lie in the loose areolar tissue between the muscular and mucous coats, and, receiving no support from the muscles, varicosity is favored. Moreover, the veins pierce the muscular coat, run superficially in a longitudinal direction, and are apt to be constricted when the muscle contracts; also there are no valves in the superior hemorrhoidal veins, and hardened feces are likely to press on them and stroke the blood downward, away from the heart. The mucous membrane is thick and loosely connected to the muscular coat beneath, thus favoring prolapse,




FIG. 60.—Short Proctoscope.

especially in the child, where the rectum is straighter than in the adult.

The reflex contractions of the sphincter prevent healing of a fissure and are a source of pain. They also prevent an ischio-rectal abscess from closing and convert it into a fistula. Because overdeveloped by its activity in such cases, the sphincter is especially strong; therefore it must be thoroughly stretched to the point of temporary paralysis before any operative procedure can be undertaken with the hope of a successful outcome.

Digital Examination.—The well-anointed left forefinger is passed into the anus, the direction being first forward toward the vagina and then backward. If the patient bears down as the tip of the finger passes through the anus, the sphincter is relaxed and the anal canal is straightened. Thus the discomfort is lessened while the finger is introduced gradually with a boring motion. The an-

terior and side-walls of the ampulla are palpated. A lesion on the anterior wall is felt between the left forefinger in the rectum and the right forefinger in the vagina. The strength of the sphincter ani is estimated, spasm, due to long-continued irritation, areas of induration, ulceration, or narrowing of the caliber of the gut, and the presence of tumors are determined. A general smoothness and absence of folds indicates atony.

The right forefinger, in like manner, is used to palpate the posterior wall of the ampulla. The presence of internal piles is very hard to diagnosticate by touch. The proctoscope must be used for these. In making the digital examination it is well to pass the unused fingers of the examining hand between the nates, or over the vulva and the thumb beside the vulva or between the




FIG. 61.—Long Proctoscope.

nates, for in this way a greater distance can be reached in the rectum than by shutting the unused fingers on the palm of the hand. If, after the digital examination, the diagnosis is still in doubt, the Kelly proctoscope should be used.

Proctoscopy.—A good light, preferably an electric light and a head mirror, are necessary, just as in cystoscopy. The patient is put in the knee-chest position. Something as to the condition of the anal canal may be learned by the use of the smallest-size Sims vaginal speculum in the anus and some physicians report good results with it. Personally, I have not found it valuable as a means of diagnosis unless the sphincter has been first stretched. The Sims rectal speculum is adapted only for use with the patient anesthetized.

Two proctoscopes are sufficient for diagnostic purposes. The shorter one, three inches (7.5 centimeters) long by seven-eighths

inch (2.3 centimeters) in diameter, is passed first. It is thoroughly anointed and introduced slowly while the patient bears down. The physician keeps in mind the direction of the anal canal and the rectum proper; the tip of the proctoscope with its obturator in place is pointed first downward toward the pubes, then inward in the axis of the body after the sphincter has been passed, and then upward toward the sacrum. Remember the situation of the valves of the rectum and work the tip of the proctoscope by them gradually. Removing the obturator air rushes in, balloons the rectum, and permits a view of the lower part of this organ. The alligator forceps are useful to remove bits of fecal matter or to wipe away secretion with cotton pledgets, or to obtain tissue for microscopic examination. As the proctoscope is withdrawn the internal and external sphincters are inspected as they roll into the lumen of the proctoscope. The longer proctoscope, five and a

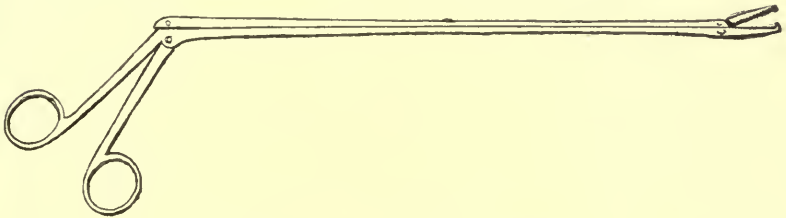


FIG. 62.—Long Alligator Forceps.

half inches (14 centimeters) long by seven-eighths inch (2.3 centimeters) in diameter, is of value to inspect the upper rectum. The sigmoidoscope is a dangerous instrument, for although by its use, in favorable cases, a glimpse of the sigmoid may be obtained, it is likely to injure the bowel.

In introducing the longer proctoscope it is advisable to remove the obturator after the sphincter has been passed and to **carry** the instrument higher in the rectum by sight. The semilunar valves can be seen and avoided by the advancing edge of the proctoscope. Remember that the empty rectum is normally contracted—that is to say, its walls are in apposition—therefore this state must not be mistaken for stricture. The air sometimes does not separate the walls of the upper rectum, although it does those of the ampulla.

The mucous membrane of the rectum is studded by branching vessels and the openings of little glands may be seen. Inflammation is marked by a diffuse velvety injected appearance of the

mucosa, together with the disappearance of the normal branching vessels; ulcerations are easily distinguished, polypi may be seen hanging from the rectal wall, or the bleeding surface of a carcinoma may obstruct the lumen of the proctoscope. If there is stricture of the bowel because of syphilis, or cancer, a smaller proctoscope should be used. A large-sized Kelly cystoscope will often serve instead of a proctoscope in such cases, also in the examination of the rectum in children.

Stretching the Sphincter and Speculum Examination of the Rectum.

In exceptional cases it is necessary to give an anesthetic in order to make a complete diagnosis of rectal disease. In such an event, after the patient is thoroughly anesthetized she is placed in the

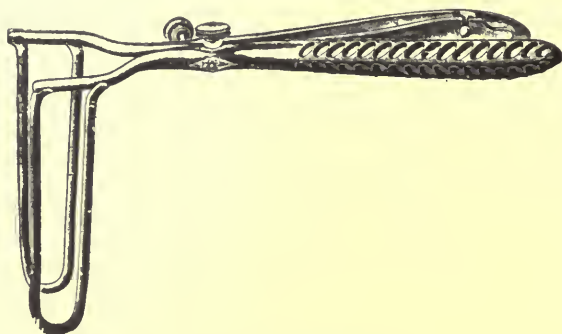


FIG. 63.—Sims Rectal Speculum.

Sims position; the operator anoints both thumbs and inserts them through the anus. By means of the fingers grasping both buttocks gentle but firm traction is made on the sphincter ani. A good deal of time should be devoted to the stretching of the sphincter, some fifteen minutes. Rapid and forcible stretching is very apt to result in rupture of the muscle followed by partial or complete permanent incontinence of feces or in fissure of the mucous membrane. Thorough stretching of the sphincter is an essential for any instrumentation of the rectum except proctoscopy. After the preliminary stretching the sphincter muscle is fixed between the thumb and forefinger of the left hand and successive portions of its periphery are stretched by the thumb and forefinger of the right hand. The Sims rectal speculum is passed and light is reflected into the rectum by the head mirror, the alligator forceps and pledgets of cotton being used to wipe away discharges and feces.

CHAPTER X.

THE SIGNIFICANCE OF THE CHIEF SYMPTOMS OF PELVIC DISEASE.

Dysmenorrhœa, p. 128: Frequency, p. 128; Menstrual molimina, p. 128. I. Dysmenorrhœa associated with pelvic lesions, p. 129: Congenital malformations, Retroposition with anteflexion, Pelvic inflammation, Fibroids, p. 129. II. Dysmenorrhœa where no pelvic lesion can be found, p. 130: Neurotic dysmenorrhœa, Dysmenorrhœa due to poor general health, p. 130. Membranous dysmenorrhœa, p. 130.

Intermenstrual pain, p. 132: Description, p. 132. Etiology, p. 133.

Menorrhagia and Metrorrhagia, p. 134: I. Constitutional causes, p. 135. II. Local causes, p. 135: 1. The patient is a virgin, p. 136; Table of menorrhagia and metrorrhagia in virgins, p. 137; 2. The patient is not a virgin and (*a*) has never been pregnant, p. 137, (*b*) has been pregnant, p. 138; (*c*) is pregnant, p. 138; Table of menorrhagia and metrorrhagia in married women, p. 139.

Amenorrhœa, p. 139: 1. Primary amenorrhœa, p. 139: Due to (*a*) Failure of growth, p. 139; (*b*) Atresia of the hymen or of the vagina, p. 140. 2. Secondary amenorrhœa, p. 141: Due to (*a*) Pregnancy and lactation, p. 141; (*b*) Atrophy of the ovaries, p. 141; (*c*) Constitutional diseases, p. 141; (*d*) Exhaustion and shock, p. 142; (*e*) Retention of menses from acquired atresia of the genital canal, p. 142.

Leucorrhœa, p. 143: Character of the discharge, p. 143: White discharge, p. 143; Yellow discharge, p. 143; Watery discharge, p. 144; Fetid discharge, p. 144; Bloody discharge, p. 144. Occurrence of leucorrhœa, p. 144: Leucorrhœa in children, p. 144; Leucorrhœa in virgins, p. 145; Leucorrhœa in married women, p. 145; Leucorrhœa in old women, p. 146.

Dyspareunia, p. 146: 1. Psychological causes, p. 146. 2. Anatomical causes, p. 146.

Sterility, p. 147: Absolute, p. 147; Secondary, p. 147; Facultative, p. 147. Sterility in the male, p. 148. Sterility in women, p. 148: Age as a factor, p. 148; Other factors, p. 149, Anomalies and diseases of the uterine organs, p. 150; Conditions of the uterine organs that cause interruption of pregnancy, p. 150. Constitutional diseases and general causes, p. 151.

Vesical symptoms, p. 151: 1. Dysuria, p. 151; General causes and local causes, p. 152. 2. Too frequent urination, p. 153. 3. Incontinence of urine, Enuresis, p. 154: Local causes, p. 154; General causes, p. 155; Nocturnal enuresis, p. 155. 4. Retention of urine, Ischuria, p. 155. 5. Suppression of urine, Anuria, p. 156.

Rectal symptoms, p. 156: Pain, p. 156. Hemorrhage, p. 157. Rectal discharge, p. 157. Fecal accumulation, p. 157. Difficulty in defecation, p. 158. Protrusion from the anus, p. 158. Character of the feces, p. 158.

Coccygodynia, p. 159: Etiology and pathology, p. 159. Symptoms, p. 159. Diagnosis, p. 160.

Pruritus vulvae, p. 160. Caused by: 1. Irritating discharges from the vagina or bladder, p. 160; 2. Diseases of the vulva, p. 161; 3. Neuroses, p. 161.

DYSMENORRHEA

THE term dysmenorrhœa (from *δυσ*, difficult, *μήν*, month, and *ῥέειν*, to flow) signifies painful menstruation, and is used to define suffering of whatever kind associated with the performance of the function of menstruation. In spite of the many theories advanced to explain the occurrence of pain accompanying, preceding, or following the monthly flow, we are still ignorant of the cause. Authorities are not agreed as to the frequency of pain among normal women. Theoretically the woman should be conscious of menstruation only by the discharge of blood from the vulva; as a matter of fact a considerable proportion of women have some sort of discomfort. Marie Tobler (*Monatsschr. für Geburts. und Gyn.*, 1905, Vol. XXII., p. 1) investigated this question in the case of one thousand and twenty women and found that twenty-six per cent had local pain, general discomfort, malaise, weakness, or mental disturbance at menstruation. Some writers place the percentage of local or general discomfort as high as sixty or seventy per cent of all women. It is to be remembered, however, that most of the data come from investigators who have to do with women afflicted with uterine disease and not with normal women.

Menstrual molimina are the local and general disturbances that are supposed to be normal to menstruation; they are:—a certain amount of pain in the pelvis extending through the back and thighs, also nervous depression, resulting in lassitude, headache, nervous instability, and derangement of the function of different organs.

Some of the last are: eye strain, skin eruptions—such as urticaria and acne,—pains in the joints, and loosening of the sacro-iliac joint in the case of sacro-iliac disease, and various sorts of “neuralgias.” They are often spoken of as “reflex symptoms.” Exaggeration of the menstrual molimina constitutes dysmenorrhœa, although the term is more often applied to the actual pain which is referred to the pelvis than to the more distant manifestations.

Dysmenorrhœa may be classified as of two sorts, (1) that associ-

ated with definite discoverable lesions of the uterine organs, and (2) that in which no abnormality of those organs can be determined.

1. DYSMENORRHEA ASSOCIATED WITH PELVIC LESIONS

This includes dysmenorrhea occurring in the case of (1) Congenital malformations of the uterine organs, (2) retroposition with ante flexion, (3) pelvic inflammation, and (4) fibroids.

1. Congenital Malformation of the Uterine Organs.—A woman having an infantile uterus or a congenitally ante flexed uterus is apt to suffer with dysmenorrhea, so also, in the case of atresia of the vagina or of the uterus where the ovaries are at the same time well developed, pain recurring at regular intervals is apt to be a constant symptom.

2. Retroposition with Ante flexion.—Dysmenorrhea is the rule with this affection, especially in the case of the unfruitful. The pain in these cases generally begins with the appearance of the flow, it is cramp-like, and is relieved after the flow has become well established. Frequent and painful micturition is often associated with this malposition, whatever the cause may be.

This is a sort of uterus in which the so-called *obstructive dysmenorrhea* was supposed by Marion Sims and his followers to occur. This theory is that the escape of the menstrual discharges is impeded by the flexing of the uterine canal by a stenosis either of the internal or the external os, by an intra-uterine polyp acting like a ball-valve, or by clots of blood. At the present time the best authorities are agreed that actual obstruction seldom exists.

3. Pelvic Inflammation.—Pelvic inflammation includes endometritis, and also pelvic peritonitis, salpingitis, ovaritis, and a certain amount of cellulitis. In the acute stages of pelvic inflammation dysmenorrhea is a fairly common symptom—perhaps in from a third to a half of all cases. In the chronic stages it causes uterine malposition and chronic endometritis, which are more directly causative of painful menstruation. The pain is apt to antedate the beginning of the flow and lasts through the entire period.

4. Fibroids.—Dysmenorrhea is a fairly constant accompaniment of submucous and interstitial myomata. It is rare in the subperitoneal sort. The size of the tumor bears no definite relation

to the amount of the pain experienced; often the pain is most severe in the case of very small tumors. The pain in the uterus itself must be differentiated from the more or less constant pain due to pressure by large tumors on the surrounding nerves in the pelvis. The pain in the uterus, according to Kelly and Cullen ("Myomata of the Uterus"), is most severe at, or just before, the menstrual period. The pain from pressure is apt to be in the legs and feet and may be mistaken for rheumatism.

II. DYSMENORRHEA WHERE NO PELVIC LESION CAN BE FOUND

Dysmenorrhea often exists in women who, apparently, have perfectly normal uterine organs. In this event the painful menstruation is (1) neurotic, or (2) due to poor general health.

1. Neurotic Dysmenorrhea.—Neurotic dysmenorrhea appears to be due to excessive sensitiveness of the endometrium. The uterine contractions occurring during menstruation cause abnormal pain, something like the after-pains of labor. The formation of clots in the uterine cavity, exciting expulsive contractions and pain, has been assumed to be the cause in some cases, but there are no facts to substantiate this theory. Dysmenorrhea is often observed in cases of neurasthenia and sometimes in patients with this disease who previously had not had painful menses. The physician is often left in doubt which is cause and which effect in the investigation of neurasthenia and dysmenorrhea.

2. Dysmenorrhea Due to Poor General Health.—Dysmenorrhea is observed frequently in girls under twenty who are the subjects of anemia or chlorosis. There are no satisfactory theories among the many that have been advanced to explain this association of menstrual suffering with these two diseases.

Membranous Dysmenorrhea.—Membranous dysmenorrhea is characterized by severe cramp-like pains in the lower abdomen and back, resembling labor pains, occurring at the time of menstruation and followed by the expulsion of a more or less incomplete cast of the cavity of the corpus uteri in the shape of a sac, triangular in form, gray in color, and having a rough surface. When floated

in water and laid open, the interior of the sac is smooth. With the aid of a magnifying glass this smooth surface is seen to be studded with minute openings which represent the mouths of the utricular glands. If the sac is reasonably complete—it is seldom entire—the openings of the Fallopian tubes may be distinguished in the upper corners. The membrane is from one to three millimeters thick and under the microscope shows much the appearance of exudative interstitial endometritis, although the pathological characteristics of the membrane are not constant; therefore membranous dysmenorrhea is not a definite disease but a condition which exists in the presence of different pathological processes.

The etiology of this disease is shrouded in mystery. As far as known, endometritis precedes membranous dysmenorrhea in a large proportion of cases. In certain cases menstruation is normal and regular until infection occurs following abortion or labor; then membranous dysmenorrhea develops in the course of a few months. In another class of cases, many of them being unmarried women, menstruation is normal and regular and the painful menstruation with the expulsion of a membrane develops without any apparent cause. Following the expulsion of the membrane there is generally a profuse flow of blood.

In making a diagnosis of membranous dysmenorrhea we must exclude (a) decidual endometritis and (b) exfoliative vaginitis.

(a) In the case of *decidual endometritis* there is a history of pregnancy, also some of the signs of pregnancy or extra-uterine pregnancy should be present (see Chapters XXII and XIX). Hemorrhage following the expulsion of the membrane, or parts of it, generally lasts longer and is more profuse than is the case with membranous dysmenorrhea. The cast of the uterine cavity is larger and more vascular than in the case of the membrane of dysmenorrhea, and chorionic villi should be visible when the specimen is examined under the microscope.

(b) *Exfoliative vaginitis* may accompany membranous dysmenorrhea, the exfoliation of the vagina being a part, apparently, of the same pathological process which causes the casting off of the endometrium. Such an association, although authoritatively reported, must be considered as very rare. Exfoliative vaginitis occurring as a result of inflammation or from treating the vagina with strong caustics, such as nitrate of silver (see Chapter XX, page

364), is a not uncommon disease, and if the lining mucosa is thrown off at the time of a menstruation which is accompanied by cramps, the physician must be able to distinguish between a cast from the vagina and one from the uterine cavity.

A vaginal cast when floated in water does not present a triangular shape and no tubal openings are to be seen. However, as all casts are often expelled in pieces, these features may be absent in both cases. On examining a vaginal cast with a magnifying glass it will be seen to have a surface that is relatively rough and there are no openings of glands in it. Microscopic examination shows it to be made up of stratified vaginal epithelium and the characteristic glandular structure of the endometrium is absent.

INTERMENSTRUAL PAIN

Intermenstrual pain, or "Mittelschmerz," is the name given to pain similar to the pain of dysmenorrhœa, occurring on a definite date between two menstrual periods, often midway between, but not always.

This affection is by no means uncommon and every gynecologist of wide experience has met with several cases. Dr. H. A. Kelly ("Medical Gynecology") has collected sixty-four cases from his own experience and the literature, and I will summarize his conclusions from an analysis of these cases.

As a rule intermenstrual pain does not begin with the first menstruation, but is generally noted during the period of full sexual activity, that is, between the years of twenty and thirty-five. In a majority of cases it is associated with sterility, but in a large proportion of the child-bearing women who are the subjects of this pain, pregnancy seems to stand in a causal relation to the intermenstrual pain.

Three cases of intermenstrual pain have been reported in which, pregnancy supervening, the pain ceased entirely during pregnancy and during lactation, only to return on the reestablishment of menstruation.

The pain always occurs about the middle of the intermenstrual period and extends into the second half of it, and the date of the intermenstrual pain seems to depend on the date of the beginning

of the following menstrual period and not on that of the preceding period.

Exact data as to the beginning of regular menstruation and the beginning of the intermenstrual pain should be made in every case for record. The character of the pain varies in individual cases, it may be dull or it may be sharp; it is seldom paroxysmal. It is situated in the pelvic region, just as in dysmenorrhea. The pain lasts from a few days, up to the entire time from its beginning until the next menstruation. It generally lasts three or four days.

Intermenstrual pain may be present during all of a woman's menstrual life. We have no assurance that it will cease short of the menopause. It does not seem to be associated with dysmenorrhea, although precise information on this point is lacking, as it is on the question of its association with regularity and irregularity of menstruation. There is a very great probability that many cases rated as irregularity of painful menstruation would, if analyzed carefully, be found to be cases of intermenstrual pain.

In a majority of cases of intermenstrual pain the suffering is accompanied by a vaginal discharge, either as a watery leucorrhœa, or a yellowish or blood-stained discharge. Often, a uterine lesion, such as endometritis, a polyp, or a submucous fibroid will be found to explain the leucorrhœa. As a rule, no definite relation has been established between pelvic lesions and intermenstrual pain.

As regards the causation of this affection, Kelly is inclined to agree with Sir William Priestly, who first reported four cases of the disorder in 1871 (*Brit. Med. Jour.*, Vol. II., p. 683). His theory is that under normal conditions previous to menstruation, one or both ovaries become congested, the congestion persisting through menstruation and for a few days after. This congestion is attended by no signs. Under abnormal conditions, because of changes in the ovaries not understood, the congestion begins earlier than usual and is attended by pelvic pain. Therefore the pain has relation to the coming period and not to that which has preceded the pain. In the cases observed clinically such a relation is found to exist.

Physicians are urged to report cases of intermenstrual pain with exactness so that data may be in hand as to this interesting and neglected affection. Besides the patient's age and social condition, the following points should be noted:—(1) Day of the month on

which the last menstruation began. (2) Date at which intermenstrual pain began. (3) Date at which the following catamenia began. (4) Length of time the pain lasts, and its character. (5) Date when intermenstrual pain was first noted. (6) Full details of a normal menstruation, *i.e.*, exact interval between beginning of each two catamenia, duration of the flow in days, amount of flow in napkins each day, occurrence of pain and leucorrhœa. (7) Whether or not intermenstrual pain is attended by a vaginal discharge, and if so, its amount and character. (8) If a pelvic examination has been made, note the findings.

MENORRHAGIA AND METRORRHAGIA

Menorrhagia (monthly bleeding, from $\mu\eta\sigma\epsilon\sigma$, menses, and $\rho\upsilon\sigma\sigma\upsilon\upsilon\alpha\iota$, to burst forth) an excessive loss of blood at the menstrual periods, and metrorrhagia (uterine bleeding, from $\mu\eta\tau\epsilon\rho\alpha$, womb, and $\rho\upsilon\sigma\sigma\upsilon\upsilon\alpha\iota$, to burst forth) a loss of blood independent of menstruation, are two terms which frequently can not be used with discrimination because the two conditions so often coexist. That is to say, a metrorrhagia becomes a menorrhagia when the menstrual period arrives, and menorrhagia, as in the case of a submucous fibroid, in the course of time becomes a metrorrhagia. Therefore it will be convenient to consider the two symptoms together, bearing in mind the fact that menorrhagia may be due to constitutional disease, whereas metrorrhagia is always due to disease of the pelvic organs. *Menorrhagia* is a relative term, for what is a moderate flow for one woman would be rated as excessive by another. Therefore, before pronouncing that menorrhagia exists in any given case, the physician must inquire minutely as to the patient's normal habit of menstruation, getting the number of days that the flow lasts, and the number and size of the napkins used, and whether they are well saturated or not. As a rule, under normal conditions, most of the flow occurs during the first two or three days. Find out whether this is the case. Supposing that it is, a loss of blood of a like amount, lasting through five or six days, would constitute menorrhagia. If the flow is increased during the normal menstrual time it is one type of menorrhagia, and a menstruation unduly prolonged in point of time is another.

Only painstaking questioning, or the results of observation by a nurse, will establish the facts.

In investigating a case of menorrhagia the constitutional causes should be considered first, then the local causes. Only the habit of excessive menstruation—not for one or two periods only—should necessitate a diagnosis, and, particularly in the case of unmarried girls and women, constitutional diseases must be eliminated carefully before proceeding to local examination. The establishment of menstruation at puberty is frequently attended by menorrhagia for several periods. Family tendencies are to be borne in mind. In some families it is the habit for the women to flow freely, and in others the reverse holds true.

I. CONSTITUTIONAL CAUSES OF MENORRHAGIA

The following blood conditions are known to be attended by menorrhagia:—hemophilia, purpura, scurvy, leukemia, the uremia of nephritis, and severe cholemia or jaundice. The various infectious diseases, such as small-pox, scarlet fever, cholera, typhoid fever, influenza, and malarial fever, often have excessive menstruation as a symptom. Menorrhagia is not uncommon in the early stages of pulmonary phthisis, although amenorrhœa is the rule in this disease. It also occurs in syphilis and in the chronic poisonings of alcohol, lead, or phosphorus, and in organic heart disease and in cirrhosis of the liver. An excessive menstrual flow is apt to attend the initial stages of any acute constitutional disease. Heart disease favors climacteric hemorrhage,—a feeble or an insufficient heart making for pelvic congestion with consequent menorrhagia or metrorrhagia.

II. LOCAL CAUSES OF MENORRHAGIA AND METRORRHAGIA

Having ruled out the constitutional causes of menorrhagia, the physician should make a careful vaginal examination in all cases of persistent uterine hemorrhage, whether occurring at the menstrual periods or not.

The local causes may be enumerated as follows:—

Uterine congestion.

Endometritis.

Polypi.

Abortion.

Extra-uterine pregnancy.

Subinvolution of the uterus.

Submucous fibroids.

Cancer of the cervix.

Cancer of the fundus.

Sarcoma.

Chorio-epithelioma.

Inversion of the uterus.

Backward displacements of the uterus.

Inflammation of the tubes and ovaries.

Small cystic degeneration of the ovaries.

Ovarian cyst with twisted pedicle.

Arterio-sclerosis of the uterine blood-vessels.

Vaginitis and injuries of the vulva and vagina.

It may be well here to point out the probable diagnosis to be obtained from the patient's age, whether or not she is a virgin, or whether or not she has ever been pregnant.

The following affections are common to the virgin, the married woman, and the multipara:—ovarian tumors, fibroids, and cancer and sarcoma.

Arterio-sclerosis of the small blood-vessels of the uterus has been described by Henri Arnal, Palmer Findley, and others. It is essentially a disease of the senile uterus, although cases have been reported in the uteri of women between thirty and forty years of age. As yet we do not know how often this condition, which seems to be not very uncommon, is the cause of hemorrhage.

1. The patient is a virgin, and (a) is under the age of twenty-five. Increase in the amount of menstrual flow is most often due to uterine congestion, perhaps brought on by exposure, or over-exertion during a menstrual period, or it may be due to a glandular polyp. In the latter case, the polyp generally produces metrorrhagia as well as menorrhagia, and thus we may distinguish between hemorrhage due to congestion and that due to a polyp. Uterine congestion is the direct cause of all uterine hemorrhage, the more remote causes, such as displacements and inflammation of the tubes and ovaries.

being many. Chronic endometritis, formerly thought to be the common cause of uterine bleeding, is now regarded as relatively rare, with the exception of the polypoid and the hyperplastic varieties.

(b) Menorrhagia may be due to backward displacement of the uterus at any age before the menopause. From twenty-five to thirty-five uterine fibroids of submucous evolution are an important cause of both menorrhagia and metrorrhagia. Cancer, especially cancer of the fundus, is to be thought of as a cause of metrorrhagia after the age of thirty-five. A watery vaginal discharge accompanies the flow very often in the case of cancer of the fundus; sometimes also in fibroids.

The facts may be summarized in the following table:—

MENORRHAGIA AND METRORRHAGIA IN VIRGINS.

AGE.	MENORRHAGIA.	METRORRHAGIA.
Under twenty-five.	{ Uterine congestion. Backward displacements. Constitutional diseases.	{ Uterine polyp. Rarely, submucous fibroid.
Twenty-five to forty.	{ Uterine congestion. Endometritis. Backward displacements. Submucous fibroid.	{ Uterine polyp. Submucous fibroid. Rarely, cancer or sarcoma of the body of the uterus.
Over forty.	{ Submucous fibroid. Endometritis. Uterine congestion. Backward displacements.	{ Submucous fibroid. Uterine polyp. Cancer or sarcoma of the body of the uterus. Rarely, cancer of the cervix.

2. The patient is not a virgin, and (a) has never been pregnant. When a patient has been married a short time and gives a history of gonococcus infection with purulent vaginal discharge and smarting on urination, the probability is that if she has menorrhagia she is suffering with gonorrhoeal endometritis and perhaps with pyosalpinx also. If gonococcus infection is not present menorrhagia in such a patient probably means uterine congestion due to excessive

sexual intercourse. It may mean, however, a tear of the hymen from violent coitus, or a bleeding urethral caruncle.

If there are any symptoms of pregnancy, such as a preëxisting amenorrhea with sharp pain in one groin and tenesmus, irregular metrorrhagia might indicate extra-uterine pregnancy. In this case look for decidual membrane in the blood passed (see Chapter XIX., page 344), or it might mean an early abortion. The differential diagnosis of these two conditions will be found in Chapter XXII., page 441.

In the absence of the signs and symptoms referred to, metrorrhagia points to a uterine polyp.

Menorrhagia becoming gradually metrorrhagia in a woman over thirty-five years of age suggests a submucous fibroid, and metrorrhagia occurring after forty, always should arouse suspicion of malignant disease; sterile married women and virgins being more prone to cancer of the body of the uterus than to cancer of the cervix, and parous married women to the latter.

(b) *The patient has been pregnant.* If a pregnancy is not very distant in the past, metrorrhagia is probably due to subinvolution; if metrorrhagia also is present, there may be retained products of conception, or inversion. Metrorrhagia coming on six weeks or so after labor may mean chorio-epithelioma. If pregnancy was in the distant past, endometritis in various forms, uterine displacements, fibroids, or cancer of the cervix must be thought of. Metrorrhagia beginning after the menopause has become well established almost invariably means cancer.

(c) *The patient is pregnant.* Uterine hemorrhage beginning after one, two, or three months of amenorrhea, with the occurrence of some of the symptoms of pregnancy, points toward threatened abortion, and if regular rhythmic pains, like labor pains, are present also, to inevitable abortion. (See Chapter XXII., page 439.)

Irregular hemorrhage, perhaps with the passage of decidual membrane, accompanied by pain in one groin and bearing down, with any symptoms of pregnancy may mean extra-uterine pregnancy. (See Chapter XIX., page 351.)

In the later months of pregnancy hemorrhage may be due to placenta previa or, rarely, to carcinoma of the cervix.

The following table summarizes the facts as regards uterine hemorrhage in married women:—

MENORRHAGIA AND METRORRHAGIA IN MARRIED WOMEN.

	MENORRHAGIA.	METRORRHAGIA.
<i>Multiparæ.</i>	{ Uterine congestion. Inflammation of tubes and ovaries. Submucous fibroid.	{ Uterine polyp. Sub-mucous fibroid. Extra-uterine pregnancy Ruptured hymen. Cancer or sarcoma of the body of the uterus. Rarely, cancer of the cervix.
<i>Following Pregnancy.</i>	{ Sub-involution. Endometritis. Submucous fibroid.	{ Retained products of concep- tion. Cancer of the cervix. Inversion. Senile endometritis. Chorio-epithelioma. Rarely, cancer of the body of the uterus.
<i>During Pregnancy.</i>	{ Rarely, menstruation during pregnancy.	{ Threatened abortion. Inevitable abortion. Placenta prævia. Extra-uterine pregnancy. Rarely, cancer of the cervix.

AMENORRHEA

Amenorrhea, or absence of the menstrual flow (from *â*, privative, μήν, month, and *ῥέειν*, to flow), may be classified as follows:—(1) Primary amenorrhea, or *emansio mensium*, in which menstruation has failed to appear at the usual age; and (2) secondary amenorrhea, or *suppressio mensium*, in which menstruation has ceased after it has been established.

1. **Primary Amenorrhea.**—Primary amenorrhea is due to (a) failure of growth of the uterine organs, perhaps coincident with lack of general bodily growth, perhaps not, or to (b) atresia of the hymen or of the vagina. The last condition, called *cryptomenorrhea*, is, strictly speaking, not amenorrhea at all, but a retention of menstrual fluid. As we are considering the symptom of absence of menstruation, it is convenient to include *cryptomenorrhea* in this place.

(a) *Failure of Growth.*—A girl having a stunted physique may have tardy growth of the uterine organs also, and menstruation

may appear later than normal. This, however, is not so often the case as it is to find a good physique and abnormal uterus and ovaries. The uterus which exhibits faults of development, such as uterus didelphys, uterus bicornis, and uterus bipartitus (see Chapter XIII., page 199), does not ordinarily have amenorrhea as a symptom, although rudimentary uterus, when associated with atresia of the vagina, generally does. Arrests of growth, on the other hand,—infantile uterus and congenital atrophy of the uterus,—are commonly attended by amenorrhea. *Infantile uterus* is a relatively common condition. The uterus is narrow in proportion to its length, has a long cervix and a short body, and is situated well back and high in the pelvis at the end of a long vagina. The cervix is conical and anteflexed, and the os a "pin-hole os." The patient's figure, breasts, hair, and voice are generally of the feminine type. *Congenital atrophy of the uterus* is a rare condition. Here all the dimensions of the uterus are reduced while the normal proportions are retained. The condition has been found in dwarfs and cretins, and in early tuberculosis and chlorosis. It is supposed that in these cases the uterus attained a proper growth to the virgin type, and that atrophy followed.

Both of these conditions are generally associated with anomalies of the ovaries. (See Chapter XVII., p. 285.) Congenital absence of both ovaries is extremely rare. It is of course accompanied by absolute amenorrhea. Absence of one ovary does not affect menstruation. Faulty growth of the ovaries accompanies both infantile uterus and rudimentary uterus. The ovaries are small and amenorrhea may exist.

(b) *Atresia of the Hymen, or of the Vagina.*—Cryptomenorrhea may be caused by imperforate hymen (see Chapter XXI., page 396), or by the different varieties of atresia of the vagina (see Chapter XX., pages 357, 359). In these cases the ovaries are functionally active. Menstrual molimina are present and may be attended by severe cramp pains, and there may be vicarious menstruation from the nose or other mucous-membrane-lined cavities. The menstrual fluid collects behind the obstruction, which may be situated anywhere from the hymen to the internal os, though it is usually in the vagina, and by distending first the vagina, then the uterus, and finally the tubes, causes the conditions known as hematoocolpos, hematometra, and hematosalpinx, respectively.

The patient, who has passed the usual time for puberty, presents a normal figure and has normal feminine breasts, hair, and voice. She complains of absence of menstruation and suffers with menstrual molimina—generally severe cramps in the lower abdomen.

2. Secondary Amenorrhea.—The following causes besides the menopause may be enumerated as accounting for the cessation of menstruation after it has been established:—(a) pregnancy and lactation, (b) atrophy of the ovaries, (c) constitutional diseases, (d) exhaustion and shock, and (e) retention of menses from acquired atresia of the genital canal. Cessation of menstruation may be temporary or permanent; if the latter, it constitutes the menopause.

(a) *Pregnancy and Lactation.*—Pregnancy must be considered the chief cause of amenorrhea and the physician will do well to bear this constantly in mind, even in the cases where the probability of its being present seems to be small. It is to be remembered that menstruation may occasionally occur during pregnancy (see Chapter XXII., page 419). The menses are usually absent during lactation, though not always. Prolonged lactation may induce lactation atrophy of the ovaries with consequent amenorrhea.

(b) *Atrophy of the Ovaries.*—Not much is known about the conditions which cause atrophy of the ovaries. When atrophy has taken place the oöphoron of the ovary, the egg-bearing zone, is smaller and harder than normal, and becomes transformed into a layer of dense fibrous tissue.

Ovarian atrophy has been reported in women who have nursed their children a very long time, and also in the following diseases:—the exanthemata, myxedema, marked anemia, and diabetes. We are justified in supposing that cessation of function of the ovaries is the direct cause of amenorrhea in the

(c) *Constitutional Diseases.*—Whether demonstrable degenerative tissue changes occur ordinarily when amenorrhea is present we do not know. There is no doubt that the ovaries show a decrease in size under such conditions.

Suddenly acquired obesity is often attended by amenorrhea, so also are the early stages of pulmonary phthisis. In the former case it is apparently due to anemia and over-nutrition, and in the latter to anemia and malnutrition. Other instances of the latter

cause are: tuberculosis of the kidney, diabetes, chronic nephritis, malaria, chronic mercury, lead, or alcohol poisoning, leukemia, and the morphine habit.

If amenorrhea is not directly dependent on the blood state it is related to the condition of the nervous system.

(d) *Mental overwork* in schoolgirls is sometimes responsible for the absence of the menstrual flow. Sudden grief, worry, or fear, or grave hysteria, melancholia, or some of the other psychoses, are often attended by amenorrhea.

(e) *Amenorrhea from retained menstruation due to atresia of the genital canal* is comparatively rare. Necrosis of the vagina or cervix following prolonged and difficult labors, the wearing of neglected pessaries, or injury of the vagina from caustics, occasionally cause cicatricial stenosis to the extent that the secretions of the uterus are dammed up. In this event the absence of menstruation will be attended by crampy pains and menstrual molimina.

If a girl does not menstruate after she has passed her sixteenth year, the physician should inquire into the state of her general health, making whatever physical examination is necessary to arrive at a diagnosis of systemic disorder. The blood should be examined both as regards the number of red corpuscles and the percentage of hemoglobin. Failing to find any constitutional cause for the amenorrhea, a local examination should be made, and except in the rare cases of phlegmatic girls of good sense, with the aid of an anesthetic.

Should the patient experience menstrual molimina without a flow, local examination should be made without a previous inquiry into the constitutional state.

Neglect to investigate has resulted in serious harm in the cases of retained menstruation from imperforate hymen or atresia, through dilatation of the uterus and tubes with rupture of the latter into the abdominal cavity.

In women who have been exposed to sexual intercourse, pregnancy should always be in the physician's mind as a probable cause of amenorrhea, and after the fortieth year the possibility of the beginning of the menopause should be considered.

In every case of amenorrhea the general physical condition of the patient should first engage the physician's attention,—the nervous system and the blood state being thoroughly investigated.

LEUCORRHEA

Leucorrhœa, or "whites" (from λευκός, white, and ροία, flow), is the generic name commonly given to any discharge from the vulva, other than blood.

Under normal conditions the inner surface of the vulva is simply moist during the intermenstrual time, except just before and just after menstruation, when the discharge may be enough to necessitate wearing a napkin. The normal moisture is made up of elements from four different sources, in varying amounts, namely: secretion from the uterine cavity proper, secretion from the cervical canal, epithelium from the vagina, and secretions from the vulva. The secretion from the uterine cavity is a clear, transparent fluid, small in amount, and having an alkaline reaction; that from the cervical canal is tenacious, transparent, and thick like the white of an egg. The epithelium cast off from the vagina is mixed with the uterine secretions to form a milky fluid which is generally small in amount.

The sweat and sebaceous glands of the vulva make a secretion of considerable amount, forming smegma, which is found in the folds about the nymphæ and under the prepuce. Besides this there is the glairy mucus secreted by the glands of Bartholin and Skene.

CHARACTER OF THE DISCHARGE IN LEUCORRHEA

We will now consider the discharges under abnormal conditions, taking up first the different characters of the discharges and then the probable meaning of the various discharges occurring in girls and women of different social conditions.

White Discharge.—It is white, creamy or curdy, or viscid and clear. It stiffens the linen but does not stain it. It may mean pelvic congestion, endometritis, or laceration of the cervix, with or without uterine malposition.

Yellow Discharge.—It is light yellow (muco-purulent), markedly yellow (purulent), or greenish yellow (gonococcus infection). It may mean purulent endometritis, a pelvic abscess discharging through the vagina, pyometra associated with cancer of the cervix, and, most frequent of all, gonococcus infection of vagina, cervix, urethra, or the vulval glands.

Watery Discharge.—This is a clear, colorless fluid that does not stiffen the linen. It may have color enough to stain the linen. It may mean uterine congestion, endometritis, intermittent hydrosalpinx, submucous fibroids, or cancer of the uterus, especially cancer of the body. Under watery discharge must be included leakage of urine from a urinary fistula or incontinence. Here the odor of urine is apparent.

Fetid Discharge.—Foul-smelling discharge may be purulent or watery in character and results from necrosis of tissues. It may be caused by a neglected, retained pessary, by a sloughing submucous fibroid or polyp, by decomposed products of conception, and, most frequent of all, by cancer of the uterus, especially cancer of the cervix; the discharge in the last case having a characteristic odor.

Bloody Discharge.—A discharge tinged with blood, occurring during the intermenstrual period, stains and stiffens the linen. It may be due to endometritis, laceration of the cervix, submucous fibroid, polyp, vaginitis, or cancer. *A scanty brownish discharge lasting for several weeks may indicate a disintegrating uterine decidua in the case of ruptured tubal pregnancy (see Chapter XIX., page 353),* or it may mean the slow breaking up of a blood clot within the uterine cavity.

OCCURRENCE OF LEUCORRHEA

Leucorrhœa in Children.—The immediate cause of leucorrhœa in children is vulvitis. A white discharge occurs sometimes in poorly nourished children, and intestinal worms, dirt, and struma have been assigned as causes. Just how these are factors, and why some children affected by them have leucorrhœa and others do not, has not been explained. One author has assigned the staphylococcus as a cause and others have found a large variety of bacteria in these cases. Masturbation is undoubtedly a cause of vulvitis and therefore of leucorrhœa with a white discharge, never of leucorrhœa with a purulent discharge. The practice is by no means infrequent among neurotic children. (See Chapter XXVIII., page 574.) Purulent vulvitis is due to gonococcus infection in a majority of cases. Recent bacteriological investigations of epidemics of this disease in institutions, public baths, and elsewhere prove that the gonococcus

is present in nearly all of the cases and that the disease is most frequent in children under five years of age. There occurs rarely in little girls a vulvo-vaginitis with purulent discharge, perhaps due to the staphylococcus. Vaginitis is generally associated with vulvitis, and salpingitis develops in a certain proportion of the cases. The disease leaves disabling traces not only in closure of the tubes but also in the form of adhesions of the nymphæ to the prepuce and to each other. (See Chapter XXI., page 394.)

Leucorrhœa in Virgins.—Transitory leucorrhœa in a virgin may be due to a pelvic congestion. The discharge under these conditions is generally either white and curdy, or clear and viscid, or a mixture of the two. Sometimes the leucorrhœa if of the viscid type is from the secretion of the glands of Bartholin caused by sexual feelings. In only exceptional instances can a male physician ascertain the facts in this respect, so that if such a state of affairs is suspected the patient should be referred to a woman physician. Persistent leucorrhœa in a virgin is due to pelvic congestion or endometritis in the young, or, in the old, may be due to cancer of the body of the uterus or to a submucous fibroid. Menorrhagia is generally an attending symptom. A local examination should be made because in this way only can an intelligent opinion be formed of the condition of the uterine organs. After the examination has been made the state of the general health should receive careful attention in the way of correcting anemia, whether or not local treatment is employed in conjunction with it.

Leucorrhœa in Married Women.—In women who are accustomed to sexual intercourse a white discharge may mean simple pelvic congestion. This is not an unusual condition in the recently married, the congestion of the pelvic organs being excessive because of intemperance in coitus. So also, a leucorrhœa may result from habitual incomplete coitus, part of the discharge coming from the uterine cavity and part from Bartholin's glands. "Whites" are a symptom of laceration of the cervix, erosions, endometritis, and uterine misplacements. A yellow discharge is found in the various sorts of vaginitis (see Chapter XX., page 361). Vaginitis following infection during or after confinement is very common, and also gonorrhœal vaginitis. The gonorrhœal sort is apt to date from marriage or intercourse and to be accompanied by frequent and smarting micturition. A vulvo-vaginal abscess or a bubo may

have complicated the disease. Parous women are more apt to have cancer of the cervix than nulliparæ. This disease is attended by a yellow or bloody vaginal discharge. Retained products of conception cause a bloody discharge, as a rule, and sloughing fibroids or polypi a foul, purulent discharge, while a submucous fibroid causes a thin, watery leucorrhœa. A persisting brownish discharge may mean extra-uterine pregnancy.

Leucorrhœa in Old Women.—Women who have passed the menopause should have no vaginal discharge if their uterine organs have atrophied in a normal manner. If there is a white discharge it may be due to senile endometritis, caused by old-standing uterine lesions. A yellow or bloody discharge means either senile vaginitis or cancer, and so often the latter that no time should be lost in investigating the condition of the uterine organs as soon as the symptom is reported.

DYSPAREUNIA

Dyspareunia, from the Greek *δυσπάρεισος*, ill-mated, is the name given to pain or difficulty in sexual intercourse.

Difficulty in accomplishing the sexual act may be due to (1) psychoneurological, or to (2) anatomical causes. Of (1) the psychoneurological causes, we may enumerate repulsion or aversion on the part of the wife. Cases are on record where women have refused to let their husbands touch them throughout a long series of years of married life because of repulsion, or the husband's awkward manner of approach. Another of the psychoneurological causes is *vaginismus* (see Chapter XX., page 378), a spasmodic reflex contraction of the levator ani and other muscles about the vulva excited by the slightest touch. This affection may be associated with actual smallness of the vagina or an irritable hymen, or it may be due entirely to an irritable condition of the nervous system.

(2) Anatomical causes of both difficult and painful intercourse are (a) those situated in the vulva or lower vagina—a rigid hymen, a small vagina, either from faulty growth or from cicatricial stenosis, chronic vaginitis, urethral caruncle, vulvitis, a vulvo-vaginal abscess, chancres or chaneroids of the vulva, and kraurosis vulvæ; and (b) deeper-seated conditions, of which the chief are,—metritis,

lacerations of the cervix with tender cicatrices, prolapsed and tender ovaries, and masses of pelvic inflammatory exudate. It is unnecessary to consider here the acute inflammations of vulva, vagina, uterus, ovaries and tubes, or pelvic peritoneum because, of necessity, intercourse could not take place in the presence of such conditions.

Disproportion between the size of the penis and the caliber of the vagina, or a deficiency in the lubricating fluids secreted by the prostate in the male and Bartholin's glands in the female, may be causes of dyspareunia.

In getting a history of pain during intercourse the physician must inquire whether the pain is at the beginning, or after the penis has entered the vagina. If at the beginning, the cause is probably to be sought in vaginismus or in class (a) of the anatomical causes; if after the penetration of the male organ the cause is in class (b). Inquiry should be made whether the pain has been present with coitus since the beginning of married life, or has been noted following the occurrence of any of the symptoms of pelvic disease.

Physical examination will reveal all of the anatomical causes and also vaginismus.

STERILITY

Sterility, from the Latin word *sterilis*, barren, meaning, when applied to a woman, that she has not borne a living child,—not that she is unable to,—is classified as *absolute (primary) sterility* where no child has been borne and no miscarriage, or no abortion has taken place, as *relative (secondary) sterility* where one or more pregnancies have occurred, followed by a period of unfruitfulness, or *facultative sterility*, infertility caused by the prevention of conception.

Sterility may be due either to the husband or to the wife, possibly to both, therefore no physician should submit a woman to local treatment for sterility without first assuring himself that the husband's organs of procreation are functioning normally. This is done by questioning, by an examination of the penis and testicles, and by a microscopical examination of semen spent into a glass vial, which is then corked and kept warm at the body temperature, by placing it in warm water. Questioning, not in the presence of the wife, will determine whether the man thinks that coitus is

performed normally, or whether he has noticed any abnormality of his generative organs, or has had gonorrhœa. Examination of the penis and testicles by the physician may detect some anomaly that the patient had not suspected:—it may show a gleetly urethral discharge. Microscopical examination of the semen on a warm slide will show whether it contains living spermatozoa or not. Care must be exercised not to heat the bottle containing the semen too much or to let it get cold, or the spermatozoa may be killed.

STERILITY IN THE MALE

The frequency with which the fault lies with the husband in cases of sterility is obviously a matter difficult to determine. Sän-ger, and Lier and Ascher (quoted by Kelly, "Medical Gynecology") have studied this matter in a number of cases. Of 242 husbands of sterile marriages examined by these authors, 104, or 43 per cent, showed absence of living spermatozoa, or deficiency of semen and impotency, the proportions being, respectively, 79 cases, and 25 cases. Further, 55 of the men had infected their wives with gonorrhœa, producing, as the authors assume, *indirect sterility*.

A fair inference from these statistics, by three competent observers, is that in something over half of the sterile marriages the fault lies with the husband, hence the importance of investigating the man as well as the woman.

STERILITY IN WOMEN

Age as a Factor.—As pointed out by Matthews Duncan and shown in the following table, the age at marriage is the chief factor in the expectation of sterility.

Age at Marriage.	15-19	20-24	25-29	30-34	35-39	40-44	45-49
Percentage of wives bearing a child within two years	43.7	90.5	75.8	62.9	40.9	15.4	4.3

From this it will be seen that fecundity is greatest in women who have been married between the ages of twenty and twenty-four, and decreases progressively until the menopause.

Duncan has shown also by his statistics that of the wives married between the ages of twenty and twenty-four who were all fertile, only six and two-tenths per cent began to bear after three years of marriage. In other words, when the expectation of fertility is greatest the question of probable sterility is soonest decided.

The age of the wife has a bearing on sterility, for, according to this same author's statistics, the following percentages were observed:—

Age of Wives at Marriage.	15-19	20-24	25-29	30-34	35-39	40-44	45-49	50 and over.	Total.
Number of wives observed	700	1,835	1,120	402	205	110	46	29	4,447
Sterile wives	51	0	311	151	109	100	44	29	725
Percentage sterile	7.3	0	27.7	37.5	53.2	90.9	95.6	100	16.3

Other Factors.—The factors essential for procreation, as far as the woman is concerned, are, the presence of a living ovum, a healthy endometrium upon which the ovum may develop, permeability of the genital tract so that the spermatozoon may reach the ovum, and secretions of the genital tract that are not inimical to the life of the spermatozoon, or that do not bar its upward progress to the ovum.

Entrance of the penis into the vagina is not necessary to produce conception, for cases are on record where pregnancy has occurred, and women have come to labor even, with an unruptured hymen which presented only a minute opening; therefore deposition of semen on the vulva is all that is necessary in some cases. Also, sexual feeling is not a necessity, for women have conceived after intercourse while unconscious from intoxication and other causes, and artificial insemination has produced conception. Still, conception is more likely to occur if the penis enters the vagina and if sexual feelings with an orgasm are present, the spermatozoa, in all probability, finding a more ready entrance to the uterine cavity during the orgasm.

Leaving out of account the question of age, already considered, the following may be enumerated as causes of sterility in women:—

(1) Bars to conception in the form of anomalies and diseases of the uterine organs. (2) Conditions of the uterine organs causing interruption of pregnancy and death of the fertilized ovum or fetus

(abortion and extra-uterine pregnancy), and (3) Constitutional diseases and general causes acting either in preventing conception, or in terminating it after it has begun.

1. *Anomalies and Diseases of the Uterine Organs.*—The following is a list of the pelvic diseases commonly found associated with sterility, beginning with the vulva and ending with the ovaries:—

Imperforate or rigid hymen (preventing penetration).

Tumors of the vulva (preventing penetration).

Urethral caruncle (dyspareunia).

Absence or atresia of the vagina (preventing penetration).

Vaginismus (preventing penetration).

Vaginitis (destruction of spermatozoa by discharges, especially gonorrhœa).

Rupture of the pelvic floor (allowing semen to run out).

Inversion of the vagina with uterine prolapse (preventing insemination).

Infantile uterus (lack of normal endometrium).

Anteflexion of the uterus (mechanical obstruction, together with endometrial discharges).

Endometritis and polypi (abnormal endometrium and discharge).

Erosions of the cervix (spermatozoa barred, or killed by discharge).

Lacerations of the cervix (spermatozoa barred, or killed by discharge).

Cancer of the cervix and body (spermatozoa barred, or killed by discharge).

Fibroids of the uterus (unknown direct cause).

Hyperinvolution of the uterus (abnormal endometrium).

Nodular and obliterating salpingitis (very frequent cause, especially of one-child sterility. Canal of tube obstructed by nodules or closed by adhesive inflammation).

Under-development or atrophy of the ovaries (oöphoron of ovary affected, so that healthy ova are not produced, or are not thrown off).

Ovarian tumors (all of functioning oöphoron destroyed, or ova can not reach tubal ostium).

Adhesions about the ovaries (same as ovarian tumors).

2. *Conditions of the Uterine Organs that Cause Interruption of Pregnancy.*—The chief local causes of abortion are:—

Pelvic congestion from excessive coitus.

Endometritis (abnormal endometrium).

Retrodisplacements of the uterus (preventing the progressive enlargement of the uterus).

Lacerations of the cervix (through endometritis and lack of protection of the ovum or fetus).

Syphilis of the placenta or decidua.

Introduction of foreign bodies, such as catheters, into the uterus.

Follicular salpingitis (furnishing diverticula for the development of extra-uterine gestation).

3. *Constitutional Diseases and General Causes.*—The chief constitutional affections that either cause failure to conceive, or interrupt pregnancy are:—

The acute diseases, especially the infectious diseases, such as acute rheumatism, scarlatina, and typhoid fever.

Alcoholism and morphinism.

Syphilis (frequent cause. From syphilis of placenta and decidua, or transmitted from father through semen).

Excessive obesity, occurring rapidly.

Anemia, associated with chronic heart disease, kidney disease, diabetes, or tuberculosis.

The psychoses (mental diseases or sudden nervous shocks).

Inbreeding (marriage of cousins).

Masturbation (chronic pelvic congestion from conjugal onanism, simple masturbation, or douches).

VESICAL SYMPTOMS

The chief symptoms of disease or derangement of function of the urinary organs are:—

(1) Difficult, retarded, or painful urination, *dysuria*.

(2) Too frequent urination, *frequent micturition*.

(3) Incontinence of urine, *enuresis*.

(4) Retention of urine, *ischuria*.

(5) Suppression of urine, *anuria*.

1. *Dysuria*, from the Greek words, *δυσ*, ill, and *ουρον*, urine, signifies an inability to start the stream and to empty the bladder, and also pain attending the act of micturition. When the urine is passed drop by drop with spasmodic pain the condition is known

as *strangury* (from *στράγγειν*, a drop and *ὄρουρον*, urine). It is found in cystitis, especially in those forms of cystitis that are due to poisoning by cantharides or turpentine.

Painful or difficult urination is a very common symptom complained of by women who suffer with gynecological affections. Some authors estimate the number of such women who have vesical symptoms as high as one-half of all the cases applying to the physician for relief. A greater or less degree of dysuria almost invariably accompanies pelvic inflammation and also gonococcus infection, but more of this later.

The physician will do well to rule out first the general constitutional causes of dysuria. Pain and burning during urination may be due to a too acid or too concentrated urine. This is the case in patients who habitually ingest a small quantity of fluids and also in lithemic women. Sometimes this symptom is indicative of acute nephritis, because then the urine is concentrated. The ingestion or absorption, through the lungs or skin, of turpentine may cause dysuria, and in the same manner cantharides, mustard, and pepper, when taken internally or applied to the skin, may be attended by this bladder symptom.

The local causes of dysuria, beginning at the meatus urinarius, are, *urethral caruncle* (see Chapter XXIII., page 453). Here the pain may be so severe that the nervous system is upset and the patient becomes melancholic. The pain is described as "scalding," "stabbing," "shooting," or "cutting," and is felt while the urine is passing over the caruncle and for some little time afterward. The pain is apt to be aggravated during the menstrual period, and the dread of the pain is often so great that urination is deferred as long as possible, so that retention may result. In many of these cases there is a constant pain in the vulva as well as the pain which attends micturition, the constant pain being aggravated by walking.

Dyspareunia generally accompanies dysuria in these cases, and there may be bleeding on coitus.

Urethritis is due in a great majority of cases to gonorrhoea and is a common cause of dysuria. Anything that increases the congestion of the pelvic organs, such as menstruation or pregnancy, exaggerates the inflammation of the urethra, and therefore increases the severity of the symptom of difficult or painful micturition. (See Chapter XXIII., page 450.)

Downward dislocation of the urethra is a not infrequent cause of difficulty in passing urine, and so is *stricture of the urethra*, one of the results of urethritis. *Suburethral abscess* generally causes difficulty in urination. It is a subacute disease and is attended by pain, fever, dyspareunia, and the intermittent discharges of pus.

The causes of dysuria that are situated in the bladder are:—

(a) *Calculi and foreign bodies*, which are usually attended by cystitis; (b) cystitis in its various forms (see Chapter XXIV., page 462); and the (c) *new growths of the bladder*, the most frequent of which are *papilloma* and *cancer*.

2. Too Frequent Urination.—The time-worn term “irritable bladder” has given way to a more rational and more exact description of both the symptoms and the pathological conditions present. To establish the fact of too frequent urination, the physician must inquire as to the patient’s habit as regards emptying the bladder. Many women are accustomed to void urine only at long intervals of time, perhaps once or twice a day. Perhaps they ingest very small quantities of fluids. Under the influence of excitement, of taking more fluids, or of cold, the amount of urine may be larger, and the desire to pass it consequently more pressing and more frequent. On the other hand, a small amount of fluid taken by the mouth and abundant perspiration will diminish the amount of urine secreted, and therefore the necessity for passing it.

Inquiry into too frequent urination should deal with the custom of the individual under ordinary conditions of health. How many times by day, and how many times by night. Too frequent urination must be differentiated from incontinence, and this will be taken up in the section on incontinence.

Most conditions which make micturition painful also cause it to be too frequent. This is the case with the inflammations of the pelvic organs. Here we are considering only the affections which are chiefly distinguished by abnormal frequency.

During pregnancy the urethra and the neck of the bladder partake of the congestion of all the pelvic organs at this time. Why this congestion of the neck of the bladder is attended by too frequent micturition in some pregnant women and not in others we do not know.

The statement may be made that, as a general rule, micturition is more frequent during pregnancy, especially during early preg-

nancy, than at other times. Women who suffer with uterine disease may have too frequent micturition only at the time of menstruation because of the additional congestion of the neck of the bladder at that period.

The ingestion of large quantities of fluids, especially of those which have a diuretic effect, like tea, coffee, and beer, is followed by frequent micturition, so also are diabetes mellitus, diabetes insipidus, and hysteria, because of the secretion of an abundant supply of urine in these diseases.

Urethritis and stricture of the urethra are causes of frequency,—even congenital smallness of the meatus may cause frequency. *Contracted bladder*, by not permitting any considerable quantity of urine to accumulate, causes frequency, and so do tumors of the bladder situated in the neighborhood of the vesical trigone.

Cystitis is attended by increased frequency of micturition, in fact it is a cardinal symptom, but there are no data in hand to show that increased frequency is due to ureteral or kidney disease where the bladder is not at the same time affected, although put from a suppurating kidney, in the same manner as concentrated urine,—perhaps containing crystals,—may stimulate the bladder neck and cause frequency of urination, also the passage of a renal calculus along the ureter may cause a reflex desire to urinate. The bladder is so frequently involved in cases of pyelitis and ureteral calculus, however, that frequency of urination may be considered a symptom of these diseases.

3. Incontinence of Urine (*Enuresis*).—1. *Local Causes*.—Inability to control the escape of urine from the bladder, or the passing of it unconsciously, may be due first of all to an *overdistended bladder*. In this event the urine escapes a little at a time and the patient may not realize that the bladder is overfilled: her complaint being only that her clothes are wet or that she can not control the urine, permanent incontinence exists in vesico-vaginal fistula, also in vesico-uterine and uretero-vaginal, or uretero-uterine fistula. (See Chapter XXIV., page 474.)

Incontinence is a feature in epispadias, downward dislocation of the urethra, and in some cases of prolapse of the uterus, and in cystocele. In the latter cases the urine may escape only when the intra-abdominal pressure is increased in laughing, coughing, sneezing, or straining.

2. *General Causes.*—*Nocturnal enuresis* is a form of incontinence found in children. Here large quantities of urine are voided, quite unconsciously, at night only, the affection being supposed to be caused by an over reflex excitability of the nervous mechanism of the bladder. Rarely a local abnormality, such as an adherent prepuce, may act as a cause.

Incontinence may be due to a disorder of the brain itself (*a*), or (*b*) to some affection of that portion of the spinal cord which puts the brain into communication with the vesical centers in the sacral segments of the cord.

(*a*) The conditions which inhibit conscious cerebral activity are: coma, from whatever cause, as alcohol, epilepsy, or cerebral hemorrhage; some insanities: sunstroke; shock, and the poisons of some of the infectious diseases, as diphtheria and typhoid fever.

(*b*) The lesions which interfere with the conduction between the brain and the vesical centres in the lower cord are: myelitis, injuries and tumors of the cord, spinal meningitis, and locomotor ataxia.

If the reflexes are entirely abolished total paralysis of the bladder with retention and dribbling of urine ensues; if the paralysis is partial, there will be partial retention, with occasional voiding of urine and its involuntary escape after voluntary urination is finished. The last happening is a frequent occurrence in locomotor ataxia.

4. **Retention of Urine** (*Ischuria*).—The urine may be retained in the bladder and the patient unable to void it in the same diseases of the brain and spinal cord as in the case of incontinence just noted. It is a pretty constant symptom of multiple sclerosis. Retention often alternates with incontinence in cases of coma and the typhoid state. Retention is common in *hysteria*, and in order that overdistention of the bladder may be avoided, the physician should palpate and percuss the lower abdomen of the hysterical woman to detect a full bladder. Retention is not uncommon during *late pregnancy*, and, whatever the cause, may result in a lack of expelling power and atony of the bladder. Retention is to be expected in *incarceration of the retroflexed pregnant uterus*, and may occur, rather infrequently, in fibroids and ovarian tumors. Retention has occurred because of blocking of the urethra by a suburethral abscess, or by cancer of the urethra. Temporary re-

tion has been caused by the occluding of the urethra by a calculus or a pedunculated tumor of the bladder, and lodgment of a stone in the ureter may produce retention by causing spasm of the sphincter vesicae.

5. **Suppression of the Urine** (*Anuria*).—If urine is not secreted, or if secreted does not reach the bladder, the condition is known as suppression of urine, or anuria. The catheter must be passed and the bladder found empty before anuria may be said to be present.

Anuria, a rare condition, may occur in hysteria, in uremia, during the terminal stage of chronic nephritis, in acute nephritis, or in poisoning by turpentine, lead, phosphorus, or cantharides. Suppression of urine has been noted in yellow fever, typhoid fever, and the late stages of acute yellow atrophy of the liver, and in sunstroke.

In hysterical anuria the diagnosis is established by passing the catheter and then repeating the procedure after a definite interval of time,—say two hours, when the patient does not expect it,—thus obviating conscious or unconscious malingering. If both ureters are obstructed by disease within, or by pressure from without (see Chapter XXV., page 489), so that no urine reaches the bladder, the condition is known as *obstructive anuria*. This is a rare condition, the diagnosis being made by cystoscopy and ureteral catheterization.

RECTAL SYMPTOMS

In taking the history, certain facts pointing toward rectal disease are to be noted; among them are the occurrence of slight morning diarrhea, continuing over a long period of time and alternating with attacks of constipation, a sense of weight in the pelvis, dull pain in the region of the sacrum, and pain or swelling of the left lower limb.

Pain.—As to pain, ask when it was first noticed, the exact situation, how long the attack usually lasts, what effect has defecation upon it, and how severe it is. The most probable cause of pain occurring over a long period of time is fissure. When of recent occurrence, pain may be due to fissure, complete fistula, blind internal fistula, or prolapsed internal piles. If the pain is in the anus the chances are that the lesion is there, whereas if it is in the region of the sacrum the lesion is probably in the rectum proper.

If the pain lasts after defecation for several hours, the probable diagnosis is fissure or blind internal fistula, or complete fistula with a large internal opening. Pain ceases after defecation in the case of stricture, but in the case of piles the pain persists as long as the piles are outside the sphincter.

Pain following defecation indicates fissure, blind internal fistula, prolapsed internal piles, or a protruded polypus or tumor. Pain accompanying constipation and relieved only by emptying the rectum, is probably due to impaction of feces, ulceration, or stricture. Pain or itching, coming only after the patient has gone to bed, may mean external piles or eczema about the anus.

Hemorrhage.—Hemorrhage from the rectum is either (*a*) associated with defecation, or (*b*) it is independent of defecation.

(*a*) Bleeding internal piles and fissure cause loss of blood with the stools. When the feces passed are only smeared with a little blood, the diagnosis may be ulcer of the rectum. Profuse hemorrhage sometimes accompanies defecation in the case of internal piles, a slight hemorrhage being more usual in cases of prolapse, polyp, or villous tumor.

(*b*) Hemorrhage independent of defecation occurs in some cases of internal piles, cancer, and, in the case of prolapsed growths, in prolapse of the mucous membrane, in internal piles, and in polyp. Continuous hemorrhage seldom lasts more than twenty-four hours and, as a rule, hemorrhage in rectal disease is intermittent. Blood may come from the skin around the anus in the case of eczema, fissures, external piles, or tuberculosis in that region.

Rectal Discharge.—Besides blood, there may be discharged from the rectum, mucus, muco-pus, and serous fluid. An increase in the amount of the rectal mucus is found in proctitis, in internal piles, in prolapse, and in stricture with invagination of the rectum.

In the case of chronic hypertrophic proctitis the amount of mucus passed per anum, often involuntarily, is so great that the patient is forced to wear a napkin. Pus is due to an abscess which has ruptured into the bowel, or to a fistula-in-ano. Muco-pus is generally found in ulceration, whether malignant or simple.

Serous fluid is passed in cases of villous tumor, often in large quantities and involuntarily. Besides making inquiry on these points the patient's linen should be inspected.

Fecal Accumulation.—The rectum is almost always found filled

with feces in cases of fissure, internal piles, eczema of the anus, and hypertrophy of the external sphincter from whatever cause. In the case of stricture of the rectum the accumulation of feces will be found above the stricture, not below. The symptoms of this condition may be nothing more than a sense of fulness in the rectum, or there may be no symptoms. Digital examination makes the diagnosis. The physician should have the probabilities in mind before making the examination.

Difficulty in Defecation.—With this condition there is present a more or less constant desire to empty the bowel, and defecation is not attended by relief. It is not the same as constipation. If the dread of going to stool is due to pain caused by the act, the probable diagnosis is fissure, or ulcer, or a partly torn off polyp, causing spasm of the sphincter. If there is a tightness of the sphincter, the muscle will be found hypertrophied and non-dilatable. If there is much pain with straining before and during defecation and disappearing entirely after defecation, leaving a sense of only partial relief, a stricture is probably present.

Character of the Feces.—Diarrhea is not a true diarrhea unless it consists of a frequent discharge of fecal matter, whether solid, semi-solid, or fluid. True diarrhea is not frequently met with in rectal disease. If the feces are passed in short pieces of small caliber, with a little mucus and blood, or pus and blood, a stricture is probably present. If there is much blood and the feces are not in small pieces, cancer is to be suspected. In prolapse or invagination of the rectum, the feces are apt to be scybalous.

Protrusion from the Anus.—This occurs in internal piles, polyp, and pedunculated tumors, including villous tumors and cancer. If the protrusion is associated with defecation, the tumor returning to the rectum spontaneously soon after,—the probable diagnosis is internal piles, a polyp with short pedicle, a moderate degree of prolapse, or a villous tumor. When the protrusion remains down for several hours, the probable diagnosis is internal piles which have become pedunculated, a polyp with long pedicle, a marked degree of prolapse, or a villous tumor, and also, if protrusion occurs on standing or straining, it is probably due to an extreme degree of any of these. The affections referred to in the preceding section will be found described at length in Chapter XXVI., pages 498, and 523–525.

COCCYGODYNIA

The term coccygodynia (from *κόκκυξ*, coccyx, and *ὀδύνη*, pain) is the name given by Sir James Y. Simpson to pain in the region of the coccyx, an affection occurring almost entirely in women and generally due to injury of the coccyx during labor. Some time previous to May, 1844, Dr. J. C. Nott, of Mobile, Alabama, removed the last two coccygeal bones in a young unmarried woman for "neuralgia of the coccyx," due to caries of the coccyx, following injury from a fall. This is the first recorded instance of coccygodynia, which is very commonly associated with gynecological affections.

Coccygodynia may occur in men when due to injury, but it is extremely rare. As in Nott's case, the disease in woman may be associated with caries of the bone; this is, however, rare, and the pathological appearances of the specimens removed by operation show most often disease of the joint between the first and second coccygeal bones. The three lower bones are generally ankylosed in adults so that forcing them backward,—as in labor,—or forward, as in a fall on the buttocks when the thighs are flexed, places the strain on the only movable joint, that between the first and second pieces. Besides injury to the joints the coccyx may be fractured. The etiology of the pain is obscure and some authors attribute it to rheumatism of the muscles in the neighborhood of the coccyx, others to sprains of the ligaments, and still others to some affection of Lushka's coccygeal gland, which has a rich nerve supply.

The symptoms consist of continuous pain in the region of the coccyx aggravated by sitting down and by rising from a sitting posture. A hard seat causes especially severe pain and pain is exaggerated by defecation and by coitus. Mild cases are fairly common, but severe ones are infrequent. In the bad cases there may be constant pain along the entire length of the spinal column; the patient may get up from a sitting posture by placing the palm of one hand upon the seat of the chair and the other on any convenient support, and pushing the body up by the arms as much as possible, so as to avoid contracting the muscles of the pelvic floor and the glutei. The bad cases are usually the victims of neurasthenia.

In making the diagnosis, tenderness of the coccyx to light pressure, both from the skin surface and by a finger in the rectum, is the chief feature. If there is dislocation the lower bones of the coccyx, grasped between the finger in the rectum and the thumb in the crease of the nates, may be thrown out of line with the upper bone, or bones. A fracture may be felt as a ridge on the surface of the coccyx.

Tenderness over the coccyx by both vaginal and rectal digital examination may be found in proctitis (see Chapter XXVI., page 506), therefore in establishing the diagnosis of coccygodynia this disease must be ruled out.

PRURITUS VULVÆ

Pruritus vulvæ, or itching of the vulva, is a symptom which may be the source of a great deal of misery to its victim, and may lead to serious derangement of the health from loss of sleep and constant nervous irritation. In the severe grades it is often accompanied by evidences of impairment of the nervous system, such as frequency of micturition, indigestion, irritability of temper, and instability of disposition. It is a symptom and is undoubtedly due to a certain sort of irritation of the terminal filaments of the nerves in the skin of the vulva, but the pathology is, as yet, unknown. The causes of pruritus may be divided into: (1) irritating discharges from the vagina or bladder, (2) diseases of the vulva, and (3) neuroses.

1. **Irritating discharges from the vagina** are, (a) leucorrhœa from chronic endometritis. Leopold holds that this is a very common cause of pruritus; also leucorrhœa from vaginitis, as in gonorrhœa, is a not uncommon cause of itching.

(b) The urine of diabetes is a frequent cause of pruritus. The patient complains of great thirst, drinks large quantities of water, and is hungry most of the time. Examination of the vulva shows slight redness about the orifice of the urethra, redness and perhaps induration of the labia, and excoriations from scratching. The urine has a sweetish smell and on examination is found to contain sugar. Pruritus is often the first symptom which leads to the diagnosis of diabetes.

(c) The urine of cystitis, or nephritis, may cause pruritus, but this is not a common happening and usually yields readily to treatment for the urinary difficulty.

2. **Diseases of the vulva** causing pruritus are, first, (a) congestion of the vulva and varix of the vulva, both commonly found in pregnancy, in uterine or ovarian tumors, or in any obstruction to the venous return of the blood in the pelvis,—such as intra-abdominal pressure on the vena cava. Even the congestion of the menstrual period may be accompanied by itching.

(b) Vulvitis and kraurosis vulvæ are attended by more or less pruritus, the latter, generally by intense itching.

(c) *Pediculus pubis* is a cause of itching. On careful inspection of the hairs of the vulva the parasites or their nits are readily seen and are destroyed by shaving the parts and anointing with a ten-per-cent solution of carbolic acid and olive oil.

(d) Thrush of the vulva is a cause of pruritus, and in little girls (e) simple uncleanliness seems to operate as a cause. (f) Eczema of the vulva is nearly always attended by severe itching.

3. **Neuroses.**—Under this head we may include, (a) masturbation, although it is doubtful whether the itching is not the cause of the masturbation, rather than the reverse. There can be no doubt, however, but that constant handling and irritation of the clitoris and vulva make for hypersensitiveness and therefore exaggeration of a predisposition to pruritus.

(b) *Oxyuris vermicularis*, or pin-worms, found in the rectum in children, cause itching not only about the anus but of the vulva also. In pruritus vulvæ in a child this cause, as well as uncleanliness, should be always sought for.

(c) Pruritus is common at the menopause without discoverable lesions of the vulva, and is observed sometimes also in (d) women having a rheumatic diathesis.

PART II
SPECIAL DIAGNOSIS

CHAPTER XI

THE DIAGNOSIS OF ENDOMETRITIS, INCLUDING GONORRHEA AND EROSIONS OF THE CERVIX UTERI

Anatomy and physiology of the endometrium, p. 166.

Pathology, p. 169.

Anatomico-pathological classification, p. 170.

Endometritis from a clinical point of view, p. 173: Acute non-gonorrhœal endometritis, p. 173; Etiology, p. 173; Symptoms, p. 174; Signs, p. 176. Chronic non-gonorrhœal endometritis, p. 176; Varieties, p. 176, (1) Of puerperal origin, or post-abortum, p. 176, (2) Those varieties which are not preceded by a known acute stage, p. 177; Etiology, p. 177; Symptoms, p. 177; Signs, p. 178. Gonorrhœal endometritis and gonococcus infection, p. 179. Acute gonorrhœal endometritis, acute gonorrhœal endocervicitis, p. 180; Symptoms, p. 181, Diagnosis, p. 181, Differential diagnosis, p. 181; Chronic gonorrhœal endometritis, p. 182; Latent gonorrhœa in women, p. 182; Differential diagnosis of chronic gonorrhœal endometritis, p. 183. Senile endometritis, p. 183. Endocervicitis, p. 184. Erosions of the cervix uteri, p. 184; Characteristics, p. 184; Diagnosis, p. 185; Differential diagnosis, p. 186.

ALTHOUGH endometritis is a part of the inflammatory process called Pelvic Inflammation, it may exist without involvement of the periuterine structures. As pelvic inflammation is most often caused by infection introduced through the vagina and uterus, so endometritis is generally a beginning stage of pelvic inflammation. The term *endometritis* will be used to define inflammation of the endometrium.

Endocervicitis is the name given to the inflammatory process when it is limited to the cervix. The differentiation of endocervicitis from endometritis of the body has a practical importance in the acute infections, especially in gonococcus infection, and also in the chronic form of inflammation where the disease is apt to be situated chiefly in the cervical canal. An inflammatory process situated in the endometrium may extend to the muscular structure of the uterus, and then the process may be defined more exactly as a metritis.

In practice the diagnosis of metritis aside from endometritis

is an academic affair and of no practical significance even when it is possible to diagnose one without the other; therefore, little will be said of metritis, with the understanding that in the severe grades of endometritis there is present also metritis.

ANATOMY AND PHYSIOLOGY OF THE ENDOMETRIUM

A word as to the anatomy and physiology of the endometrium before taking up the consideration of the different manifestations of inflammation. The following description applies to the unimpregnated uterus of the healthy adult woman between menstrual periods. It will be noted that the mucosa of the cervical canal is anatomically and physiologically different from the mucosa of

the uterine cavity proper, therefore we are justified in considering the word endometrium as applying to the latter only.

The interior of the uterus is divided into two cavities: the cavity of the body, and the cavity of the neck, which are separated from each other by the constricting ring of muscular tissue about the internal os. The shape of these cavities has been referred to elsewhere, the cavity of the body being represented by an inverted isosceles triangle with the two angles of the base in the uterine cornua and the third angle at the internal os. The anterior and posterior walls of the uterus

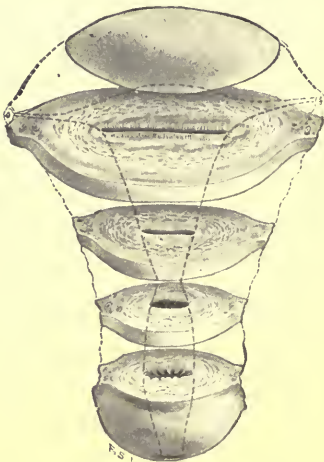


FIG. 64. — Reconstruction of Uterus, Showing Shape of Uterine Cavity and Cervical Canal. (Williams.)

meet at the sides at an acute angle so that there are no lateral walls proper, therefore the uterine cavity is flattened from before backward. The cervical cavity is fusiform in shape, largest in the middle and contracted at the internal and external ora.

Under resting conditions the cavity of the body is closed against infection from below at the internal os and from infection from above by the muscular constrictions at the isthmuses of the Fallopian tubes. The cavity of the cervix in like manner is protected from

infection from above by the narrowing at the internal os, and from below in the nulliparous uterus more, and in the parous uterus less, by the constriction at the external os.

The wall of the uterus is made up of three layers, the thin, serous, peritoneal layer, the thick muscular layer—composing most of the structure of the uterus—and the medium thick mucous layer. The mucous layer, the endometrium, consists of the utricular glands, connective tissue, blood-vessels, nerves, and lymphatics. It is covered by a single layer of ciliated columnar epithelium—which also lines the glands—and is continued through the Fallopian tubes.

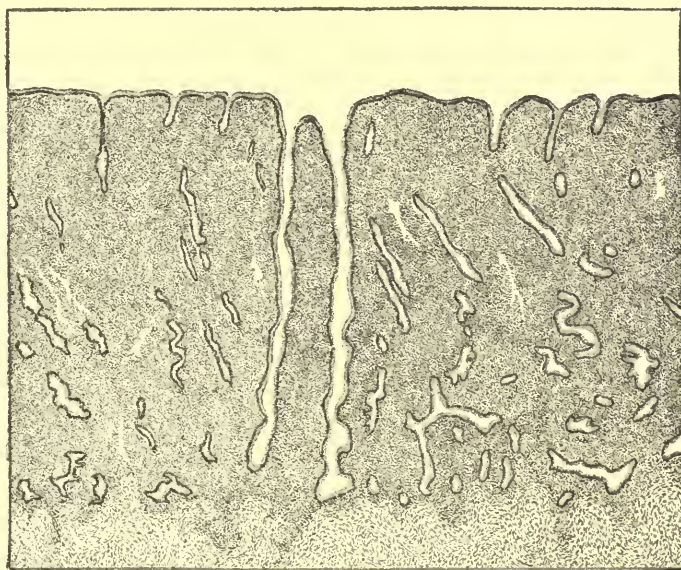


FIG. 65.—Normal Endometrium. (Williams.)

The endometrium is essentially a glandular structure. The glands are tubular and branching, several opening often by one mouth. They extend into the muscular layer and all open into the uterine cavity. In the body of the uterus the endometrium is closely united to the muscularis, whereas in the neck it is freer. In the cervix uteri the lining epithelium shades into pavement epithelium at the external os. In this cavity the mucous membrane is thrown into oblique ridges which diverge from an anterior and posterior longitudinal raphe, presenting an appearance which has received the name of arbor vite.

The normal secretion of the uterine glands is a clear, watery fluid, having an alkaline reaction, that of the glands of the neck is clear and viscid; it is also alkaline. Throughout the cervical mucosa are found a variable number of little cysts, presumably glands, which have become occluded and distended with retained secretion. They are called the ovula Nabothi, or Nabothian follicles.

The endometrium shows normally many differences in structure from infancy to old age and during the intermenstrual and menstrual cycles.

Before puberty it is relatively thin and undeveloped, nearly all of it having the character of the cervical mucosa.

Our views as regards the normal histology of the endometrium have of recent years undergone a considerable change, due to the important observations of Hitschmann and Adler (*Monatsschrift für Geburts. und Gynaekol.*, 1908, XXVII., 1), confirmed by several subsequent investigators.

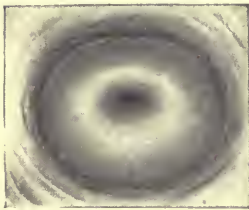


FIG. 66.—Virginal External Os. (Williams.)

Hitschmann and Adler, after a painstaking study of the uterine mucosa from fifty-eight women at various periods of the menstrual cycle, found that the endometrium from the cessation of one menstrual flow to that of the next, presents a constantly changing histological picture. This cycle of changes they divide into four phases; postmenstrual, interval, premenstrual, and menstrual. At the height of the menstrual flow the mucous membrane diminishes in thickness and the glands pour out their secretion, becoming narrow and straight. The surface epithelium is frequently lost, but this is not an invariable rule. After the period there takes place a very rapid cell growth in both the epithelium and connective tissue. The glands become larger and wider, although still quite narrow and straight. The epithelium is low and in a condition of rest. By about the fifteenth day the cell growth of the epithelium has progressed to such an extent that the glands become somewhat tortuous, and often assume a spiral or corkscrew-like appearance. Finally, six or seven days before the beginning of menstruation, the glands rapidly enlarge and become tortuous, the cells bulge into the lumen, the epithelium

becomes higher and broader, and the lumen is filled with a mucous secretion. These gland changes are much more marked in the deeper portion of the mucosa than in the superficial, so that there is produced a well-marked differentiation into a superficial compact and a deep spongy layer. In this respect there is a marked similarity to the appearance of the young decidua, the resemblance being increased by the fact that the interglandular stromal cells in many cases assume an appearance very similar to or approaching that of decidual cells.

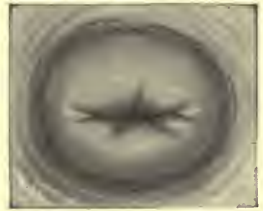

FIG. 66a.—Parous External Os. (Williams.)

During pregnancy the mucosa of the corpus uteri is enormously congested. Its function is the formation of the decidua—the connective-tissue cells of the endometrium going to make the decidual cells of pregnancy.

Following the menopause there is an atrophy of the endometrium coincident with the shrinking of the uterus so that in the old woman the uterine glands are found almost entirely obliterated, and there is apt to be partial or complete closure of the uterine canal at the internal os.

PATHOLOGY

It is probable that all forms of endometritis are due to bacterial invasion of the endometrium. The endometrium under normal conditions is sterile, and bacteria in small numbers introduced from without are promptly destroyed. Although chemical irritation and trauma may cause congestion and favor bacterial growth, the idea that these influences and “constitutional taints” do anything more than provide a fertile soil for the microorganisms has gone the way of many older theories.

The following bacteria have been found in the endometrium in cases of endometritis—seldom in pure cultures, generally in mixed infections:—

Staphylococcus pyogenes albus, citreus, and aureus.

Streptococcus pyogenes.

Gonococcus.

Colon bacillus.

Tubercle bacillus.

Diphtheria bacillus.

Typhoid bacillus.

Pneumococcus.

Bacillus *aërogenes* capsulatus.

Spirochæta pallida of syphilis.

In many forms of endometritis the bacterium reaches the endometrium from without by way of the vagina; in a smaller number of varieties it comes from the Fallopian tubes or abdominal cavity through the lumen of the tubes; and in still other varieties it comes through the lymphatics and veins of the uterine wall from near-by sources of infection in peritoneum, rectum, or bladder; and rarely it reaches the endometrium from distant sources through the blood current.

The classification of endometritis has long been a stumbling block to the gynecologist. A recent writer on the subject gives a pathological classification containing eleven different forms, according to the macroscopic or microscopic appearances of the different varieties, and a clinical classification of ten different sorts of chronic endometritis.

A bacteriological classification will ultimately be the one chosen as a guide to diagnosis. At present, not enough facts are known to justify its use. As it is impossible to diagnose the different varieties according to the pathology, except by examination of scrapings from the endometrium, and, according to the present state of our knowledge of the pathology of the endometrium, the differentiation of the varieties has no bearing on the treatment, we shall consider the subject from the clinical point of view. Suffice to mention the forms of endometritis which have been recognized as a result of the microscopic examination of scrapings and of uteri removed by operation.

ANATOMICO-PATHOLOGICAL CLASSIFICATION

Hypertrophic endometritis, in which the endometrium is thickened and soft. If the glands are increased in size only, it is called *hypertrophic glandular endometritis*, if they are increased in number it is called *hyperplastic glandular endometritis*.

F. Hitschmann and L. Adler (*Zeit. f. Geb. u. Gyn.*, 1907, LX., 63) state that endometritis glandularis hypertrophica and endometritis glandularis hyperplastica have nothing whatsoever to do with inflammation. The first is not even a pathological condition of the uterine mucosa but corresponds to the premenstrual state of the normal lining of the uterus; the latter consists partly of the normal premenstrual condition, and partly of variations in the number of glands within physiological limits; in addition it includes cases in which there is a glandular hypertrophy of the uterine mucous membrane, but this also is a change which is entirely independent of inflammation.

There is, according to these investigators, but one variety of inflammation of the uterine mucosa, endometritis interstitialis, or, as it is usually called, endometritis. The diagnosis is made by demonstrating the cells of infiltration, so-called plasma cells.

If the inflammatory process affects chiefly the interglandular connective tissue the process is known as *interstitial endometritis*. This form has an acute and a chronic stage, the acute being characterized by diffuse or circumscribed infiltration of the stroma by small round cells with congestion of the blood-vessels and a serous exudate in the spaces of the connective tissue (exudative interstitial endometritis).

The chronic stage is characterized by newly formed connective tissue resulting in compression of the utricular glands, and, in the later stages in atrophy of the endometrium, the so-called *atrophic endometritis*.

Retention cysts may be formed in the interglandular spaces of the connective tissue and *cystic interstitial endometritis* results, or the glands may be obstructed by the pressure of the connective tissue at their mouths, *cystic glandular endometritis*. *Fungous endometritis* is the term applied when the mucosa is thrown into folds; *villous endometritis*, when it is covered with shaggy villousities; and

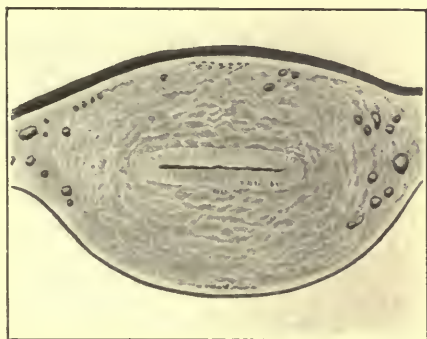


FIG. 67.—Horizontal Section of the Upper Part of the Body of the Uterus.

polypoid endometritis, when one or more mucous polyps are present. When a layer of necrotic tissue, composed of degenerated epithelium, blood, leucocytes, microorganisms, and fibrin is found on the surface of the endometrium—as in certain infections following labor and abortion—the condition is known as *pseudodiphtheritic endometritis*, and when true ulcers form in the endome-

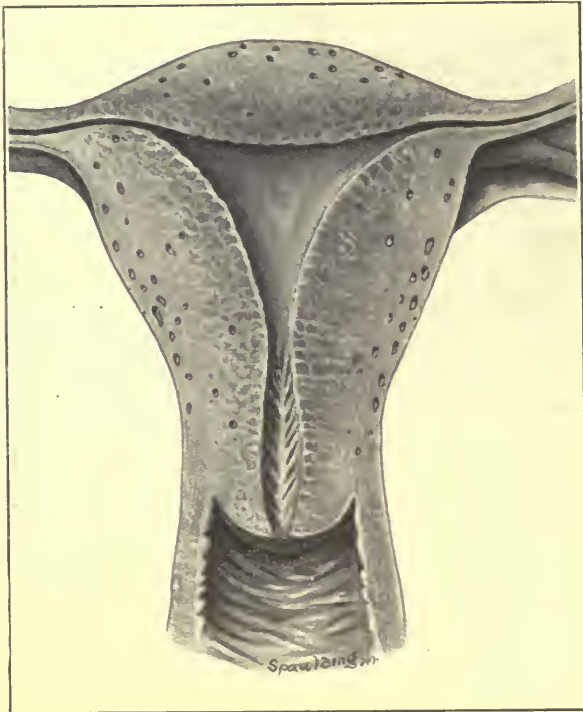


FIG. 68.—Transverse Longitudinal Section of the Uterus.

trium—as in carcinoma and tuberculosis—the process is called *ulcerative endometritis*.

Decidual endometritis is the name given to inflammation of the endometrium during pregnancy. It is diagnosed definitely by microscopic examination of the decidua after expulsion of the fetus. Evidences of inflammatory action are present. The symptoms may be hydrorrhœa uteri gravidi, or pains in the uterine region during pregnancy.

A rare condition is *exfoliative endometritis*, so-called *membranous dysmenorrhœa*. It consists of the discharge from the uterus of a

more or less incomplete cast of the cavity of the corpus uteri, in the shape of a sac, triangular in form, gray in color, and of a rough surface. Floated in water and laid open, its interior is smooth. When examined under a magnifying glass it is seen to be studded with minute openings which represent the mouths of the utricular glands. When the sac is reasonably complete the openings of the Fallopian tubes may be distinguished at the upper angles of the sac. The membrane is from one to three millimeters thick and under the microscope shows much the appearances of *exudative interstitial endometritis*, although the pathological appearances vary in different cases.

Tuberculous endometritis, relatively rare, is a sequel often of primary tuberculosis of the tubes. Rarely it is primary in the cervix. Tuberculous infection may reach the endometrium also from without by coitus, or by instrumental or digital interference. Occurring in the late stages of general tuberculous infection of the genito-urinary system, it has no clinical importance, because the other manifestations of the disease are of overshadowing seriousness. It is characterized by the presence of giant cells, tubercles, and tubercle bacilli found microscopically in scrapings made from the endometrium. The tubercle bacilli may be detected in the uterine discharges. Many cover-slip preparations should be studied before affirming the absence of the bacillus.

Not much is known of the forms of endometritis occurring after the acute infectious diseases—typhoid fever, diphtheria, scarlet fever, measles, and smallpox—nor of the endometritis which attends syphilis.

Gonorrhœal endometritis will be considered separately under the clinical classification.

ENDOMETRITIS FROM A CLINICAL POINT OF VIEW

The subject is best divided into *acute* and *chronic endometritis*, with special consideration of *gonorrhœal endometritis*, *senile endometritis*, and *endocervicitis*.

ACUTE NON-GONORRHEAL ENDOMETRITIS

Etiology.—This is an inflammation due to invasion of the endometrium by septic microorganisms, more especially the staphylococcus and the streptococcus. It is a grave form of en-

endometritis as contrasted with a majority of the chronic forms of endometritis, which are of a mild type and have no recognizable acute stage.

Its chief causes are: (1) infection following labor and abortion; (2) the use of uncleanly fingers or instruments in making office treatments; (3) operations which are not aseptic, and (4) sloughing intra-uterine tumors.

(1) Infection following labor and abortion is the most frequent cause of acute endometritis. It can not be entirely avoided even with the most scrupulous care. Retained membranes may decompose and cause it. Too often the physician is to blame.

Bacteria brought to the vagina on carelessly washed hands, lack of thoroughness in the preparations for the immediate repair of the injuries of the pelvic floor and perineum following labor, the unnecessary use of forceps, or too frequent vaginal examinations, to say nothing of too much douching—thereby washing away the normal secretions of the vagina, which, according to Döderlein destroy pathogenic bacteria—all play an important part. The great danger of so-called septic endometritis, which attends criminal abortion, is too well known to require extended comment.

(2) The general practitioner of medicine, realizing the necessity of washing his hands after an examination, is careless about washing them before making a vaginal examination or instrumental treatment. The practice of making intra-uterine office treatments is dangerous even with strict asepsis, besides being useless as a therapeutic measure. Passing the sound into the uterine cavity should be done only under strict aseptic precautions and with the utmost gentleness to avoid trauma.

(3) Minor operations may cause as great harm as major ones and too commonly do so because the preparations for the lesser procedures are not as carefully made.

(4) Sloughing of a uterine polyp, of a pedunculated submucous fibroid, or of an inverted uterus sometimes results in septic endometritis unless prompt operative measures are instituted.

Symptoms.—The symptoms of acute endometritis with septic absorption, *acute septic endometritis*, manifest themselves within twenty-four to forty-eight hours after infection, although they may be delayed for several days. Their severity depends upon the form of infection. A septic intoxication which is due to the absorption

into the system of ptomaines,—the product of decomposition set up by bacteria,—is called *sapremia*; that which is due to the absorption of the bacteria themselves with their toxins is known as *septicemia* proper. As yet we have no means of determining which form of infection is present in any given case. We know that the form caused by the streptococcus is the more grave, that the streptococcus may be diffused very rapidly throughout the system, and that in death resulting from this form there may be found few pathological changes in the pelvic organs. The staphylococcus, on the other hand, is more apt to produce marked local reaction and pus formation. The severity of the symptoms will vary according to the continued presence of the source of infection and the rapidity of its absorption. Although the endometrium is the point of entrance of the infective material into the system and endometritis is the first manifestation of the poisoning, the disease is a general one almost from the first. In the later stages of the disease the involvement of tissues neighboring to the endometrium—the uterine muscle, pelvic cellular tissue, the Fallopian tubes, and peritoneum—produces complications which overshadow the endometritis. The symptoms are ushered in by a severe chill, followed by elevation of temperature (103° – 104° F. or higher), and a rapid pulse (110–120 or higher). If the disease follows labor or abortion the lochial discharge is diminished in amount at first and then increased, becomes dark in color, then purulent, and generally, though not in the streptococcic form, has an offensive odor. If the disease does not follow labor or abortion a bloody, purulent, usually offensive uterine discharge is a constant symptom after the initial chill. Intermittent uterine pains—becoming continuous and severe if the inflammatory process reaches the peritoneum—nausea, constipation, and frequent and painful micturition are early symptoms.

Irregularly recurring chills, high temperature, rapid and feeble pulse, a sense of well-being and apathy, the characteristic undescribed odor of sepsis, diarrhea, and failing strength, are symptoms of the advanced stages of the disease.

Acute endometritis without sapremia or septicemia, is attended by comparatively slight constitutional disturbances and the symptoms are limited to elevation of temperature—generally preceded by a chill—pain of moderate severity in the lower abdomen, frequent and painful micturition, nausea, and disturbance of menstruation,—

either suppression or menorrhagia. The symptoms abate in a few days.

Signs.—In all forms we find on physical examination,—the uterus enlarged and soft, tender to light pressure in all parts; the vagina hot and dry; the uterine discharge wanting at first and later increased in amount. The os is patulous. Rigidity and tenderness of the abdominal muscles, called peritonismus, is to be expected if the peritoneum is involved in the inflammatory process, otherwise not. Acute endometritis without complications is uncommon.

If the case is seen early an anesthetic should be given because of the great pain caused by manipulation. Thorough aseptic precautions are observed. A sound is passed into the uterus and retained membranes, or sloughing tumors, polypi, or fungosities are detected by sound-touch. In cases of doubt the cervix should be dilated until it will admit the operator's finger, and the interior of the uterus explored by touch, all adventitious tissue being removed either with the finger, curette, or curette forceps, and preserved in a ten-per-cent formalin solution for microscopic examination.

CHRONIC NON-GONORRHEAL ENDOMETRITIS

Varieties.—Chronic endometritis may be divided into: (1) those forms of acute endometritis that have terminated in a chronic form, and (2) the varieties which present no acute stage demonstrable by clinical methods.

(1) *The forms of acute endometritis which have become chronic are commonly of puerperal origin, or post-abortum.* Some of the pathological varieties are,—pseudodiphtheritic, decidual, and ulcerative endometritis. A chronic endometritis resulting from an acute septic endometritis generally has as complications one or more of the following affections:—metritis, cellulitis, peritonitis, pelvic abscess, or salpingitis. When the inflammatory process is centered chiefly in one of the situations just enumerated, the inflammation of the endometrium is less active and the physical signs indicate that in the endometrium the fire has, as it were, burned out, leaving only smouldering embers. Microscopic examination of the endometrium reveals one or more of the different stages of glandular and interstitial endometritis as described on pages 170 and 171.

If septicemia is present the symptoms are those of chronic septicemia; fluctuating elevations in the temperature, rapid and feeble pulse, dry skin, diarrhea, the odor of sepsis, malnutrition, and anorexia.

There being no septicemia the symptoms are leucorrhœa, uterine hemorrhages, menstrual disturbances, dyspareunia, sterility, and abortion, and symptoms referable to the digestive and nervous systems.

Leucorrhœa is the only constant symptom. The discharge is profuse,—though varying in amount in individual cases. It is purulent in character and may be mixed with blood. It is, as a rule, odorless unless it has been retained on the vulva and has decomposed because of the patient's uncleanly habits.

A history of an acute attack of septic infection and the character of the leucorrhœa—especially if septic microorganisms can be found in it upon microscopic examination of cover-glass preparations—serve to distinguish this form of endometritis from

(2) *The large number of varieties of chronic endometritis which are not preceded by a known acute stage.* They may be enumerated as:—fungous, villous, polypoid, exfoliative, and tuberculous.

The endometritis of the infectious diseases—typhoid fever, diphtheria, scarlet fever, measles, small-pox, and syphilis—all are of a mild type.

Etiology.—Predisposing causes of chronic endometritis are:—uterine displacements, uterine malformations (especially ante-flexion), subinvolution of the uterus, extensive lacerations of the cervix, tumors of the pelvis, sexual excesses, chronic constipation, the infectious diseases, and certain constitutional diseases,—anemia, chlorosis, rheumatism, and lithemia.

The pathological processes present are glandular and interstitial endometritis as described on pages 170 and 171.

Symptoms.—The chief symptom is *leucorrhœa*. The patient does not remember when she first noticed a vaginal discharge, so gradual is its beginning. It is due to the secretion of the utricular glands plus that of the vulvo-vaginal glands. The amount depends on the condition of the endometrium,—more when it is hypertrophied and in the glandular variety of endometritis, and less in the atrophic variety. In the fungous and polypoid forms the leucorrhœa is apt to be bloody, and, if there is decomposition of tissues, purulent. In

most of the varieties of chronic endometritis the discharge is thin and serous in character.

When the secretion from the cervical canal exceeds in amount that from the body of the uterus the discharge is thick and viscid in consistency. It is without odor and is unirritating as a rule, although in patients of uncleanly habits it may have a foul odor.

The amount of discharge varies from a staining of the linen to several well-soaked napkins a day; it is increased for a day or two just before and just after each menstrual period because of the normal congestion of the genital organs at these times.

Hemorrhage at the menstrual period or excessive menstrual flow—styled menorrhagia—is to be expected in the hypertrophic form of endometritis; scanty flow in the atrophic forms. Painful menstruation—dysmenorrhea—is a pretty constant symptom, although it occurs in such great variety of manifestations and at such variable times with reference to the flow that it is impossible to dogmatize about it. Irregularity in the occurrence of menstruation also is to be expected, variations of a few days before or after the normal time being common.

Sterility and abortion are more often observed in patients suffering from chronic endometritis than in women with normal uterine organs. Symptoms of general ill health usually accompany chronic endometritis, although it is not always easy to determine whether the ill health is due to the endometritis or the endometritis to the ill health.

Signs.—The physical examination reveals a uterus enlarged, but not necessarily to a marked degree, and more or less sensitiveness of the uterus to light pressure when it is squeezed between the examiner's fingers during the combined vagino-abdominal or recto-abdominal touch. If the uterus is occupied by polypi it will be felt to be fatter than normal, and often a polypus, having been elongated and driven down by the uterine pressure, presents at the external os.

On speculum examination a discharge is seen to be issuing from the external os. Its character is noted. A tough stringy mucus is the characteristic of the secretion of the glands of the cervix; a thin, watery discharge is from the glands lining the cavity of the corpus uteri. The alkalinity of the discharge should be tested

with a piece of litmus paper. In endometritis the reaction is often neutral or even acid. The condition of the neck of the uterus is noted,—whether lacerated or eroded or not.

On passing the uterine sound the cavity of the uterus is generally found to be enlarged. In anteflexion with endometritis the internal os is tight, but the operator will find that by straightening the canal by traction on the cervix with a tenaculum it is always possible to pass a sound of small caliber. Previous to passing the sound an accurate idea should be obtained as to the probable direction of the uterine canal by means of the bimanual touch. Great gentleness is essential.

If the sound is passed with the greatest care and blood flows after its withdrawal and the cavity is tender, endometritis may be diagnosed. Fungosities and polypi are to be detected in favorable cases by the tactile sense transmitted through the sound, *i.e.*, when the canal is widely open and reasonably straight. Points of tenderness in the endometrium and their definite situations are determined by the sound.

GONORRHEAL ENDOMETRITIS AND GONOCOCCUS INFECTION

Gonorrhœal endometritis merits special consideration because it is a very common disease and has serious sequelæ.

As to its frequency authors do not agree. It is undoubtedly more common in the public clinics and among prostitutes than in private practice. Zweifel estimated that ten per cent of his private gynecological cases suffered from gonorrhœa. Different writers place gonorrhœa as the cause of acute inflammation of the uterus and tubes in from one-half to two-thirds of the patients seen in the dispensary services of the large cities. This estimate includes some of the puerperal cases, which form a considerable number of the total acute infections, for the gonococcus, as well as the staphylococcus and the streptococcus, is the cause of puerperal infection.

The gonococcus, a diplococcus discovered by Neisser in 1879, finds a favorite habitat in the deeper portions of the mucous membranes which are covered with cylindrical epithelium. It also grows readily under pavement epithelium, but can not penetrate the squamous epithelium as easily as the columnar.

Its favorite homes in the female generative apparatus when once

introduced are, in order of frequency:—(1) the urethra and Skene's and Bartholin's glands; (2) the mucosa of the cervical canal; (3) the upper portion of the vagina; (4) the endometrium of the corpus uteri; (5) the mucosa of the Fallopian tubes.

Although the squamous epithelium of the vagina of adults, bathed in its acid secretions and protected by its normal bacterial flora, resists the invasion of the gonococcus, the tender vaginal mucosa of children, although covered by squamous epithelium, is easily penetrated by it, whence the frequency of vulvo-vaginitis among children.

The gonococcus is speedily destroyed by other bacteria and their toxins in the case of a secondary infection in the process of abscess formation, as attested by the rarity with which it is found in the contents of a chronic pyosalpinx; on the other hand it may remain alive in the mucosa of the cervical canal or in Skene's glands for a series of years. As a rule gonorrhœal infections are uncomplicated by mixed infections with other bacteria unless trauma accompanies the infection.

The diplococcus is always introduced from without—in little children by the contaminated fingers of an adult infected with the disease and by soiled linen or bath sponges—in adults, as a rule, by coitus.

Gonorrhœal endometritis invariably begins in the cervical canal. It may be limited to the cervix uteri if the internal os is well closed,—as in virgins and in ante flexion. In multiparous women it is prone to spread to the corpus uteri. Sometimes the gonococcus is carried from the cervix to the corpus uteri by the physician's sound or uterine applicator. The disease is acute or chronic.

Acute Gonorrhœal Endometritis

The disease is limited to the cervix, *acute gonorrhœal endocervicitis*. The mucosa of the cervical canal is reddened, swollen, and bathed in pus, which sometimes has a greenish tinge. The neck is swollen, soft, and tender to the touch. Examined histologically the mucosa shows loss of epithelium in places; the uterine glands show hypertrophy and hyperplasia, and the interglandular tissue is enormously infiltrated with round cells and polymorphonuclear leucocytes. The blood-vessels are increased in number and size.

On staining for the gonococcus it is found lying in groups between the epithelial cells and also in the subepithelial tissue. The gonococci may also be found in the pus. They seldom penetrate the uterine muscle by way of the lymphatics as do the streptococci, and when gonorrhoeal inflammation reaches the peritoneum it does so by way of the mucosa of the corpus uteri and of the Fallopian tubes.

Symptoms.—The symptoms of acute gonorrhoeal endocervicitis are generally marked by the symptoms of coincident inflammation in the urethra, vulvo-vaginal glands, and vagina. There is a history of infection. The symptoms are ushered in by a chill followed by an elevation of temperature and a rapid pulse. The patient complains of pelvic pain, painful micturition and defecation, nausea and vomiting, and, in the course of a few hours, there is a leucorrhoea,—at first mucous in character, soon becoming purulent and sometimes mixed with blood. The symptoms are not so severe as in acute septic endometritis, and last not over a week. They are more pronounced if the inflammation has extended to the body of the uterus, and still more so if to the Fallopian tubes. In these cases one looks for greater pelvic and abdominal pains.

Diagnosis.—The diagnosis rests on (1) the history of a suspicious intercourse, which was followed by a purulent vaginal discharge, and by preceding frequent and painful micturition, *i.e.*, an acute urethritis, strong presumptive evidence of gonorrhoea; (2) the symptoms just enumerated; (3) the physical signs. The cervix is swollen and tender, and pus flows from the os. If the mucosa of the corpus uteri is also involved—acute gonorrhoeal endometritis—the entire uterus is enlarged and tender to bimanual touch; (4) the microscopic examination of the pus shows the presence of the gonococcus.

Differential Diagnosis.—The acute form of gonorrhoeal endometritis may be mistaken for acute septic endometritis. In the gonorrhoeal form the local and constitutional symptoms are less severe, there is lacking a cause for sepsis in the form of post-puerperal infection or intra-uterine treatment, and on the other hand there may be present a history of a suspicious intercourse. The urethra, Skene's glands, and the vulvo-vaginal glands are involved; there may be enlargement of the lymphatic glands of the groin—adenitis, bubo—finally the gonococci are found in the discharge.

Chronic Gonorrhœal Endometritis

Chronic gonorrhœal endometritis may result from a well-marked acute gonorrhœal endometritis. More commonly the history of an acute stage is wanting. The history of frequent and painful micturition, either following marriage or in a woman suspected of having loose habits, whether married or single, should lead the physician to consider the possibility of gonorrhœa.

The onset of the disease is generally insidious; the symptoms and physical signs are those of the varieties of chronic endometritis due to the saprophytic and pyogenic bacteria.

The leucorrhœa in gonorrhœal endometritis is generally most abundant; it loses the purulent character of the acute stage and is mucous in character. The diagnosis depends on finding the gonococcus in the discharge from the cervix. Some authors claim that it is necessary to make cultures in order to identify surely the microörganism, but this view is not held by most. Many slides should be examined. Negative findings do not rule out gonorrhœa, and this brings us to the consideration of latent gonorrhœa.

Latent Gonorrhœa in Women.—Certain experiments by Wertheim of Vienna (*Archiv. für Gyn.*, 1892, XLI., No. 1), and clinical observations by a number of investigators, go to show that the gonococcus loses its virulence after a time—weeks or months—that when it is planted in new ground, *i.e.*, when another individual is infected, the microörganism recovers its former vitality, and that when reintroduced into the original host all the symptoms and signs of an acute attack of gonorrhœa are manifested. For example, a man has acute gonorrhœa which ends in a chronic gleet. He infects his wife and later is reinfected by her and has another acute attack of gonorrhœa. In the course of time each becomes tolerant of the gonococci of the other. The husband has intercourse with a prostitute, suffers a fresh attack and reinfests his wife. This explains why the gonococcus, even after years of apparent cure, may regain its full virulence. Such authorities as Wassermann (*Berl. Klin. Woch.*, 1897, No. 32, p. 685), Maslovski, DeChristmas, and Jullien agree that there is no immunity in gonorrhœa, one attack giving no exemption from the disease in the future. It argues for repeated examinations of a gleetly urethral discharge in the male before advising marriage.

The cervical canal and Skene's glands in the floor of the urethra are the chief lurking places for the gonococcus in the female genital apparatus.

Differential Diagnosis of Chronic Gonorrheal Endometritis.—Chronic gonorrheal endometritis may be mistaken for the simple forms of endometritis. A gonorrheal origin of an endometritis may be suspected from the history of the case;—an acute attack with purulent discharge and painful micturition following a suspicious intercourse. Occasionally there is a history of the patient having had a bubo or gonorrheal inflammation of the joints. More commonly no such history is obtainable. It is seldom advisable to institute too minute inquiries in this direction in the case of married women because of the risk of causing trouble between husband and wife,—trouble which can not be cured by the physician.

Tubal disease is found in conjunction with all forms of endometritis, but more commonly with the septic and gonorrheal forms.

In most cases repeated bacteriological examinations of the discharge from the cervix are the only way of distinguishing to a certainty the cause of the inflammatory process. The results of the examinations are so often negative that we are left with only a probable diagnosis founded on the history alone.

SENILE ENDOMETRITIS

Senile endometritis is an atrophic form of endometritis occurring in women who have passed the menopause, occurring particularly in poorly nourished subjects. It is due to the infection of the atrophying mucosa, but what causes the infection is not known. Pathologically the endometrium is found thinned, the glandular elements are wanting, and many times the endometrium is entirely replaced by connective tissue. There may be stenosis of the uterine cavity from adhesion of the walls, and, from the same cause, the retained secretions may form a senile pyometra or hydrometra. The latter is very rare. The symptoms have an insidious onset, a thin, purulent, often offensive and irritating vaginal discharge being the chief symptom. Pruritus vulvæ is common, also vulvitis. Sometimes the discharge is tinged with blood. There may be symptoms of mild sepsis if the discharges are retained, and in this case pelvic pains are to be expected.

The physical signs show the uterus to be small (unless there is pyometra), and the cervix uteri is atrophied. An attempt to pass the sound will reveal partial or complete atresia of the uterine canal. If the canal is patent the discharge is seen issuing from the os. The disease, coming as it does after the menopause and attended as it is by a foul discharge, may be mistaken for carcinoma of the cervical canal or body of the uterus. Dilatation and euretting, with an examination of the tissue removed, will settle a doubt.

ENDOCERVICITIS

Endocervicitis is a chronic inflammation of the mucosa of the cervical canal. It is called also cervical catarrh and cervical endometritis. The disease is confined to the cervix uteri,—there is no extension to the mucosa of the corpus uteri. This is a common affection. The gonorrhœal form has been described under chronic gonorrhœal endometritis. Lacerations of the cervix are a frequent cause. When the cervix is torn the lips become everted and are subjected to trauma from (1) pressure on the posterior wall of the vagina by scybalous masses in the rectum resting on the unyielding sacrum, or (2) from excessive coitus. Another common cause of endocervicitis are polypi originating either in the mucosa of the cervix or corpus.

The cervical tissues in endometritis become hypertrophied, the mucosa is eroded, and cystic degeneration develops. Infection is difficult to dislodge as the bacteria occupy the glandular crypts.

EROSIONS OF THE CERVIX UTERI

Characteristics.—Erosions of the cervix uteri are characterized by a dark red or purplish color of the tissues immediately around the external os uteri. Having the appearance of ulceration they were formerly believed to be true ulcers.

In an erosion there is no inflammatory action accompanied by destruction of the epithelium as in ulceration. The surface squamous epithelium, which normally covers the cervix, is removed,—it is eroded,—and the underlying columnar epithelium is hypertrophied.

(1) *A simple erosion* presents a uniformly smooth, velvety surface

with sharply defined edges. On microscopic examination it is seen to consist of a single layer of columnar epithelium with little or no formation of new glands.

(2) A *papillary erosion* has an irregular projection of its livid red surface and has been called "cock's-comb granulations." Here the microscope shows deep invaginations of the columnar epithelium to form glands, alternating with elevations made up of newly formed connective tissue and round cells. The glands secrete a viscid mucus.

(3) A *follicular erosion* is one in which retention cysts—the so-

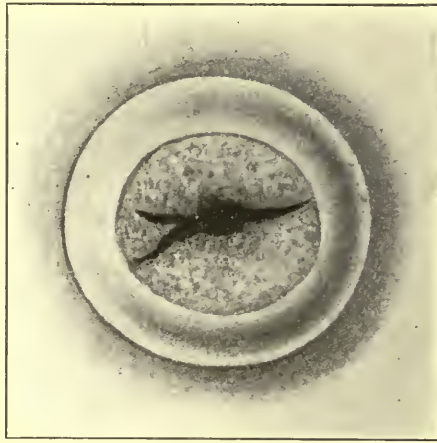


FIG. 69.—Erosion of the Cervix with Lacerations.
(H. Macnaughton-Jones.)

called Nabothian follicles—are present in considerable number. These cysts are formed by the occlusion of the newly formed glands referred to in the description of the papillary erosion. They are filled with inspissated mucus and vary in number. There may be half a dozen, or the cervix may be fairly riddled with them. In size they vary from a B.B. shot to an English walnut in extreme cases. They are usually not larger than a pea. To the examining finger the retention cyst feels like a shot; to the eye it appears as a little rounded elevation of a bluish-white or yellow color.

Diagnosis.—Leucorrhœa is the constant symptom of endocervicitis. The diagnosis is made by digital and speculum examinations. The finger detects lacerations, the soft velvety surface of the

erosion, the stringy plug of mucus in the os, shot-like retention cysts, and tenderness of the tissues of the cervix. The speculum shows the scars of the lacerations and thus their extent, the dull red roughened surface of the erosion, the plug of mucus in the os, polypi, and retention cysts, if they exist. The fact that erosions are found in the virgin and even in the infant (see Chapter XXVIII., page 563) must be borne in mind. The determining factor in the causation of this condition seems to be the exposure of the columnar epithelium with which the canal of the cervix is lined to the conditions which obtain in the vagina where the mucous membrane is paved with squamous epithelium.

Differential Diagnosis.—The differential diagnosis concerns itself with the exclusion of ulceration due to (1) an ill-fitting pessary, (2) to tuberculosis; (3) to chancre or chancroid, and (4) to carcinoma. All forms of true ulceration are rare,—erosions are common.

(1) *Ulceration from an Ill-fitting Pessary.*—If an ill-fitting pessary has been removed and the ulceration does not promptly heal under appropriate treatment a piece of tissue should be excised under cocaine anesthesia and examined microscopically.

(2) *Tuberculous Ulcer.*—Evidences of tuberculosis elsewhere in the body, a history of tuberculosis, and microscopic examination of the discharge and a piece of excised tissue, will establish the diagnosis.

(3) (a) *Chancre.*—The history is an important consideration. A definite period of incubation of the disease is present and the symptomatology and signs are those of syphilis. Chancre is seldom seen in the initial stage, *i.e.*, before ulceration. When ulcerated it is a single ulcer. The ulcer heals under antisymphilitic treatment. The differentiation of the *Spirochaeta pallida* in a piece of tissue removed for microscopic examination makes the diagnosis certain.

(b) *Chancroid.*—Here one finds multiple ulcers appearing soon after a suspicious intercourse and no symptoms of syphilis.

(4) *Carcinomatous Ulcerations.*—These are generally attended by much thickening of the surrounding tissues and bleeding. A piece of tissue should be excised and sent to the pathologist for microscopic examination.

CHAPTER XII

THE DIAGNOSIS OF PELVIC INFLAMMATION

(Pelvic Peritonitis and Pelvic Cellulitis)

Definitions, pelvic peritonitis and pelvic cellulitis, p. 187. Routes of infection in pelvic inflammation, p. 187.

Pelvic peritonitis, p. 188: Anatomy, p. 188. Etiology, p. 189. Varieties, p. 190; Acute pelvic peritonitis, p. 190. Chronic pelvic peritonitis, p. 191; Tuberculous peritonitis, p. 191.

Pelvic cellulitis, p. 192: Anatomy, p. 192. Etiology and pathology, p. 192; Pelvic abscess, p. 193. Symptoms, p. 193. Diagnosis, p. 194.

Table of differential diagnosis of pelvic inflammation, p. 195.

Definition.—The term pelvic inflammation signifies broadly inflammatory action situated in any of the structures occupying the pelvis. It will be used in this chapter to mean inflammation in the peritoneum which covers the pelvic organs, and in the underlying cellular connective tissue of the pelvis.

The inflammatory process when confined to the pelvic peritoneum constitutes a pelvic peritonitis, and when in the pelvic cellular tissue a pelvic cellulitis.

Pelvic Peritonitis.—This is a very common affection and accompanies inflammatory affections of the ovaries and tubes, as well as inflammation of the peritoneum of the entire peritoneal cavity. The inflammation extends to the cellular tissue from propinquity and therefore the two processes are often combined.

Pelvic Cellulitis.—This, on the other hand, is a rare affection following labor or abortion and exhibits less tendency to extend to the peritoneum and to the overlying structures. It is often impossible to differentiate between the two varieties of pelvic inflammation, especially in the later stages. An attempt will be made to describe both forms, beginning with the more important: first, saying something of the routes of infection and the character of the structures involved.

Routes of Infection in Pelvic Inflammation.—Infection may reach the pelvic peritoneum and cellular tissue (1) from the outside, through the lumen of the vagina, uterus, and tubes, or (2) from the blood current and the lymphatics.

1. It is possible for infection to travel through the vagina, uterus, and tubes without leaving traces behind it. Often, at the time the patient first comes under observation, the inflammatory processes in these structures have burned themselves out.

2. The blood or lymph vessels may bring infection to the pelvis from distant organs, though this is rare. Generally the infective microorganism is near at hand either in the uterus, tubes, bladder, or rectum, rarely in an infected ovarian cyst, a suppurating appendix vermiformis, or the large or the small intestine.

Occasionally infection comes to the pelvis in a psoas abscess or other abscess of distant origin, such as an abscess about the sacro-iliac or hip joints. The following bacteria have been found in cases of pelvic inflammation, generally in mixed culture, and they may be classed as causative of the inflammation:—

Gonococcus.

Colon bacillus.

Streptococcus pyogenes.

Staphylococcus pyogenes albus, aureus, and citreus.

Tubercle bacillus.

Diphtheria bacillus.

Typhoid bacillus.

Pneumococcus.

Actinomyces.

PELVIC PERITONITIS

ANATOMY

The pelvic peritoneum covers the concave surface of the floor of the pelvis. Beginning on the anterior wall of the abdomen behind the pubes and passing downward and backward, it covers first the posterior surface of the bladder. In this situation it is loosely adherent and has more or less cellular tissue under it. From the bladder it reaches the uterus just below the level of the internal os and thence rises over the anterior aspect of the body of the uterus. This lowest portion forms the so-called vesico-uterine pouch. Passing over the fundus of the uterus, where it is closely adherent, the peritoneum is continued on the posterior surface of the body of the uterus to a point a little below the level of the internal os where it leaves the uterus to dip down deep in the pelvis

to form the cul-de-sac of Douglas. Its lowest point in the cul-de-sac varies, but averages half an inch or so below the attachment of the vagina to the cervix. Rising from the cul-de-sac of Douglas, the peritoneum reaches first the anterior part of the middle portion of the rectum. Higher up it reaches the sides of this viscus and still higher the posterior portion of the first part of the rectum. At

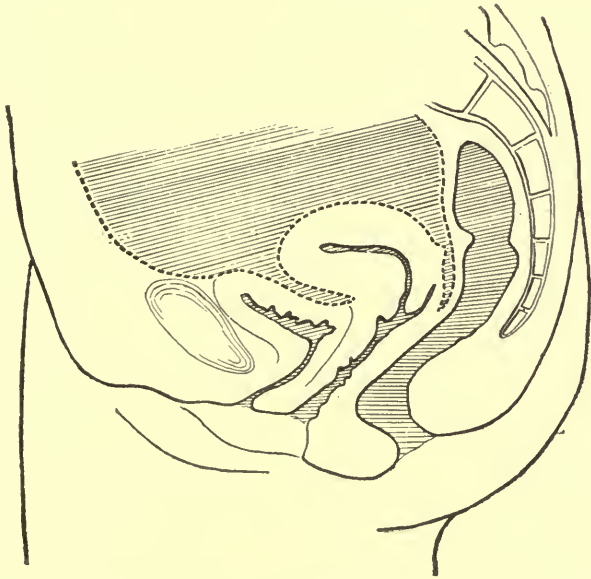


FIG. 70.—Reflections of the Folds of the Peritoneum (Dotted Lines).

the sides of the uterus the folds of the peritoneum form the broad ligaments. Above they cover the Fallopian tubes and the posterior surfaces of the ovaries.

ETIOLOGY

Pelvic peritonitis, the more common of the two sorts of pelvic inflammation, is almost always secondary to salpingitis. It may follow the escape of pus or even menstrual blood or injected fluid from the ostium abdominale of the Fallopian tube, or it may follow septic metritis, cystitis, proctitis, perforation of the uterus, appendicitis, or psoas abscess.

The gonococcus and streptococcus are, as far as we know, the bacteria most frequently the cause of pelvic peritonitis.

VARIETIES

The disease is acute or chronic.

Acute Pelvic Peritonitis.—This is manifested by sharp pains in the lower abdomen and pelvis, rigidity of the abdominal muscles, tenderness to examination both of the abdomen and the vagina, fever, rapid pulse, nausea, vomiting, constipation, and nervous depression.

The greater the tendency of the peritonitis to become a general peritonitis, the more pronounced are the symptoms. If the resisting power of the individual is great, *i.e.*, a high opsonin index is present, and the virulence of the infecting bacteria little, or the dose small, the inflammation may subside, leaving behind it adhesions between the opposing folds of peritoneum. Thus the tubes become glued in the cul-de-sac frequently, and coils of intestine are fastened to the tubes. In the severer grades of inflammation the omentum helps to wall off the process from the general cavity of the peritoneum. It applies itself to an inflamed tube in an almost intelligent manner. If resolution does not occur because of the great virulence of the infective material or lessened resistance of the patient, a chronic pelvic peritonitis, or a pelvic abscess, results. Without treatment such a pelvic abscess most commonly opens into the rectum, although it may find exit into the bladder or through the abdominal wall. It very rarely opens into the uterus or vagina.

The diagnosis is established by the presence of the symptoms above noted and by the physical signs, which are:—on bimanual examination the vagina is hot, denoting increased body temperature; the uterus is fixed and there is a sense of resistance in the tissues occupying the pelvis, a board-like feeling. This induration of the pelvic tissues, coupled with the rigidity of the abdominal walls and great tenderness to light pressure, make it impossible to map out the contents of the pelvis with exactness. A tumor mass, if present, is high up in the pelvis. The uterus may or may not be misplaced according to the situation of the greatest amount of exudate. If there is an abscess present a point of softening is to be searched for. Abscess, however, is generally rare and, if present, occurs in the later stages of pelvic peritonitis. Speculum examination aids little in the diagnosis of this affection. The uterine

discharges are diminished at the onset and increased in the later stages. The detection of a vaginitis may show the origin of a pelvic peritonitis and the isolation of an infective bacterium may show its nature. So also, examination of the rectum or bladder, should symptoms point the way, may help us to find the route taken by the infecting agent in reaching the pelvic peritoneum. Examination of the blood generally shows an increase in the number of white cells, although this is not an invariable concomitant.

Chronic Pelvic Peritonitis.—This begins with an acute attack, although the symptoms may be of inconsiderable moment, so as to escape the patient's notice. Often there will be a history of a series of acute attacks separated by intervals of months or years. The symptoms are pain of a dull character in the pelvic region, backache, constipation and painful defecation, disturbance of bladder function, and poor health. Physical examination reveals a larger or smaller amount of exudate and limitations of the mobility of the uterus, tubes, and ovaries due to adhesions. These organs are apt to be displaced as well as enlarged. Tenderness in the chronic stage is not a prominent factor as in the acute form.

Pelvic abscess may result in the course of a chronic pelvic peritonitis. This will be described more in detail under pelvic cellulitis, as it is more often found in the latter affection.

Tuberculous Peritonitis.—Tuberculous peritonitis is one variety of chronic pelvic peritonitis. Here the disease, as seen clinically, is seldom limited to the pelvis, being an affair of the general peritoneum.

The disease begins in the Fallopian tubes in a vast majority of instances, and is sometimes seen and diagnosed before it has reached the general peritoneal cavity. It is characterized by a gradual onset, by fever recurring every evening and disappearing in the morning, rapid pulse, sweating, particularly at night, loss of weight, loss of strength, and anorexia. As the disease progresses there is enlargement of the abdomen due to the presence of plastic exudate or to the accumulation of fluid. Early in the disease nothing characteristic can be made out. An enlargement of a tube, with surrounding exudate, increasing in size when examined at repeated intervals, coupled with a family history of tuberculosis, previous tuberculosis in some other organ, and the symptoms just enumerated, make a probable diagnosis of tuberculous pelvic per-

itonitis. Elimination of the other causes of salpingitis, such as gonorrhoea, may be of assistance. The disease is found most often in virgins. In chronic pelvic peritonitis we do not expect to find leucocytosis, even if an abscess is present, although it may occur.

Pelvic peritonitis leaves behind it many disabling lesions in the shape of adhesions and displacements. It is the cause of a large portion of the diseases peculiar to women, and therefore should receive most careful attention at the hands of the physician.

PELVIC CELLULITIS

ANATOMY

The cellular tissue of the pelvis lies under the peritoneum. In it pass the blood-vessels, arteries and many large veins, and the lymphatics. It is most abundant in the bases of the broad ligaments and between the peritoneum of Douglas' pouch and the vagina and lower rectum. Therefore, these are the situations where the cellulitis occurs most often. The peritoneum is pretty closely attached to the uterus, Fallopian tubes, and ovaries. That is to say, very little cellular connective tissue is present under the peritoneum in these regions. It is less closely attached to the bladder.

ETIOLOGY AND PATHOLOGY

Pelvic cellulitis is a relatively rare affection. In more than two-thirds of the cases it is of puerperal origin, and is generally due to infection by the common pus-producing cocci which enter the pelvic cellular tissue from the uterus. Infection may come from the vagina, rectum, or bladder, or from unclean instrumentation or septic manipulation. The trauma incident to parturition opens the way for the entrance of bacteria. The common situations of the inflammation have been foreshadowed in the description of the situations in the pelvis where cellular tissue is most abundant. The lymph vessels and veins are affected first. A lymphangitis or a phlebitis may be limited by the plugging of a vessel by a thrombus, and in such a case infection goes no farther.

In pelvic cellulitis the infective process extends to the tissue about the vessels, the cellular tissue, and we have a cellulitis.

The infective inflammation may go through all three of the initial stages of inflammation, *i.e.*, congestion, effusion, and suppuration, or only the first, or the first two. The process, from a pathological point of view, is not so different from that of a furuncle, namely, infection conveyed into a connective-tissue area.

Pelvic Abscess.—If the process goes on to suppuration the pus is evacuated in time spontaneously into the vagina or other pelvic viscera, often doing a good deal of damage before this issue is attained. Should the abscess open into the bladder or rectum, it is unlikely to heal and the patient becomes septic and dies from septicemia after a long illness. This is frequently the result even if most thorough drainage is made, provided intervention has been postponed until the abscess has burrowed extensively into the tissues of the pelvis and the resisting powers of the patient have been reduced to low limits. Early surgical intervention and drainage of the abscess into the vagina result in speedy healing, just as in the case of a boil, with nothing left behind except malposition of the uterus, tubes, and ovaries, and rarely dislocation of the bladder, or stricture of the rectum or urethra.

There is no tendency to recurrence and no chronic process as in the case of pelvic peritonitis, where the inflammation originates in the Fallopian tube, which is lined with mucous membrane. It is a well-known fact that infection tends to lurk in mucous membranes, and it does not remain in the cellular tissue. Forms of chronic cellulitis have been described, such as the chronic atrophic cellulitis of Freund, also an edematous form. It is a question, however, whether such processes really originate in the cellular tissue.

A pelvic abscess may result from a rupture of a pyosalpinx into the cellular tissue of the broad ligament or of the retro-uterine space. In this case one would expect that the healing process would be more protracted, and such is generally the case. So also in severe grades of cellulitis originating in the uterus, the overlying tubes and ovaries become infected by extension and have to be reckoned with in the treatment and prognosis.

SYMPTOMS

The symptoms of pelvic cellulitis are (*a*) general, those common to infections, *i.e.*, fever, rapid pulse, chills, prostration; and (*b*) local,

severe pain in the pelvis, sensitiveness to light touch, both of the abdomen and the vagina, also dysuria and painful defecation. The local symptoms abate quickly, even if the process goes on to suppuration, and most rapidly if resolution occurs.

DIAGNOSIS

By conjoined manipulation there is found a tumor in the pelvis occupying the region of the broad ligament on one side, or the retro-uterine space behind. The recto-abdominal touch is especially useful in diagnosing this affection. If the mass is in the usual situation in the base of the broad ligament, the uterus is crowded to the opposite side, the tumor, which is hard or boggy to the feel, bulges into the vagina. If the tumor is in the retro-uterine space the lumen of the vagina is encroached upon and the bladder and cervix are crowded forward against the pubes and anterior abdominal wall. In the acute stage there is rigidity of the abdominal muscles, as well as sensitiveness, so-called peritonismus. This soon subsides. In the later stages when there is abscess formation it is difficult to find the situation of the uterus without the aid of a sound. There is a mass in the pelvis that may occupy nearly the entire cavity. The pus generally burrows into the retro-uterine space. Rectal examination will often show the upper limits of the tumor; combined rectal and vaginal examination is always of value in mapping out the size and form of the sort of cellulitis that begins in the retro-uterine cellular space. In some cases there is marked edematous thickening in the space between the upper and middle portions of the vagina and the rectum. This is palpated with great exactness by one finger in the rectum and another in the vagina. The detection of fluctuation in a pelvic abscess is not easy because thick walls of lymph are effused and encompass a collection of pus of any considerable size.

Often an effusion of blood in the peritoneal cavity, a pelvic hemothecle of several weeks' standing, simulates a pelvic abscess. The hemothecle should have a boggy feeling, not unlike feces of pasty consistency, but on account of the wall of organized lymph with which it is surrounded and the tension of the contents of the sac there may be no boggy feeling. The history of the beginning

of the attack, if obtainable, will throw light on the diagnosis, hœmatocele being ushered in by severe pain and rectal tenesmus, and with prostration but no fever. Pelvic cellulitis always begins with fever.

The sequelæ of pelvic cellulitis are not so serious as those of pelvic peritonitis. Neglected cases may leave crippling traces because of the involvement of ovaries, tubes, rectum, ureter, or bladder. Cases which end in speedy resolution, either spontaneously or because of prompt surgical interference, often leave no other traces than a cicatrix, or a small area of induration in the vagina.

DIFFERENTIAL DIAGNOSIS OF PELVIC INFLAMMATION

The following table of the differential diagnosis of pelvic inflammation has been modified from that in E. C. Dudley's "Text-book of Gynecology":

Pelvic Peritonitis.

- A. Exudate surrounds uterus and is apt to be high in pelvis.
- B. Uterus fixed wherever it happens to be.
- C. Pain severe and paroxysmal in acute stage.
- D. Tendency to suppuration not marked.
- E. Frequently results in general peritonitis.
- F. Constitutional symptoms more severe. Apt to be nausea and vomiting.

Pelvic Peritonitis in Douglas' Cul-de-sac.

- A. Tumor mass has a sharp outline and is relatively high in pelvis.
- B. Uterus is displaced forward.

Pelvic Cellulitis.

- A. Tumor usually at one side of uterus and low in pelvis.
- B. Uterus displaced laterally, not necessarily fixed.
- C. Pain less severe and more continuous.
- D. Tendency to suppuration marked.
- E. Seldom results in general peritonitis.
- F. Constitutional symptoms less severe. No nausea and vomiting.

Retro-uterine Cellulitis.

- A. Tumor mass of indefinite outline is situated in the space between rectum, vagina, and uterus in pelvic floor and is flattened in form.
- B. Cervix uteri alone bent forward or to the side, not the body and fundus.

Pyosalpinx.

- A. Mass on one or both sides of uterus and back of it, not bulging into the vagina.
- B. Mass of sharp outline and sausage-shaped.
- C. Mass partly movable.

Chronic Pelvic Hematoecle.

- A. History of tubal pregnancy with symptoms of sudden internal hemorrhage. May be repeated light attacks.
- B. No chill or fever.
- C. Relatively rapid increase in size of tumor.
- D. Tumor doughy and elastic.

Appendicitis with Abscess.

- A. Onset with severe symptoms and nausea and vomiting.
- B. Tenderness over appendix region.
- C. Exudate high up in pelvis. Reached by vaginal or rectal examination only with difficulty.

Psoas Abscess.

- A. History and symptoms of tuberculosis.
- B. Evidences of Pott's disease.
- C. No history of acute onset.
- D. Limitation of motion and pain in thigh.

Subserous Myoma.

- A. No history of infection.
- B. No history of acute onset.
- C. Contour of the tumor rounded, sharply defined, and tumor intimately connected with the uterus.

Pelvic Cellulitis.

- A. Mass on one side of uterus only and low in the pelvis, bulging into the vagina.
- B. A diffuse swelling.
- C. Mass fixed.

Pelvic Cellulitis.

- A. History of infection.
- B. Chills and fever.
- C. Slow development of tumor.
- D. Tumor hard until suppuration.

Pelvic Cellulitis (Right Side).

- A. Onset with less severe symptoms; no nausea and vomiting.
- B. No tenderness over appendix region.
- C. Exudate low in pelvis in base of broad ligament or in retro-uterine space. Easily palpated through vagina and rectum.

Pelvic Cellulitis.

- A. History of non-tuberculous infection.
- B. No evidences of Pott's disease.
- C. History of acute onset.
- D. No limitation of motion or pain in thigh.

Pelvic Cellulitis.

- A. History of infection.
- B. History of acute onset.
- C. Tumor of indefinite outline and not so intimately connected with the uterus.

CHAPTER XIII

THE DIAGNOSIS OF CONGENITAL ANOMALIES OF THE UTERUS, LACERATION OF THE CERVIX UTERI, AND DISEASES OF THE UTERINE LIGAMENTS

Diagnosis of congenital anomalies of the uterus, p. 197: I. Anomalies due to arrest of development, p. 198: Absence of the uterus, p. 198; Rudimentary uterus, p. 198; Uterus bipartitus, p. 200; Uterus didelphys, p. 200; Uterus bicornis, p. 200; Uterus septus, p. 200; Uterus unicornis, p. 200; Diagnosis, p. 201; Differential diagnosis, p. 202. II. Anomalies due to arrest of growth, p. 202: Infantile uterus, p. 202; Congenital atrophy, p. 203; Puerperal atrophy, p. 203; Non-puerperal atrophy, p. 203.

Diagnosis of laceration of the cervix uteri, p. 204: Anatomy, p. 204. Etiology, p. 204. Mechanism and pathology, p. 205. Results of laceration, p. 206: Subinvolution, p. 207; Diagnosis of laceration, p. 208: Recent lacerations, p. 208; Old lacerations, p. 209. Differential diagnosis, p. 210.

Diagnosis of the diseases of the uterine ligaments, p. 210: The broad ligaments, p. 211: Parovarian cysts, p. 211; Varicocele of the broad ligament, p. 212. The round ligaments, p. 212: Tumors, p. 212; Hydrocele of the canal of Nuck, p. 213. The utero-sacral ligaments, p. 213. The utero-ovarian ligaments, p. 214.

CERTAIN points in the anatomy and mechanics of the uterus have been considered in Chapter V., page 44, and others will be described in Chapter XIV., on the diagnosis of malpositions of the uterus, pages 222-224. The endometrium has been described in Chapter XI. on Endometritis, page 166. In the present chapter we will take up the arrests of development, lacerations of the cervix, and diseases of the uterine ligaments.

DIAGNOSIS OF CONGENITAL ANOMALIES OF THE UTERUS

The uterus, which in the virgin measures three inches in length, two inches in breadth at the fundus, and nearly an inch in thickness, is developed from the coalescence of the two Müllerian ducts in the embryo. This coalescence takes place from the eighth to the twelfth weeks of fetal life. The development should be complete, with the septum between the two ducts absorbed and the

uterus completely formed, by the twentieth week, and after this time the question is one of growth, and not of development. The period of growth extends to the twentieth year of life. Therefore, in seeking the cause of uterine anomalies we have to consider two factors—arrested development and arrested growth.

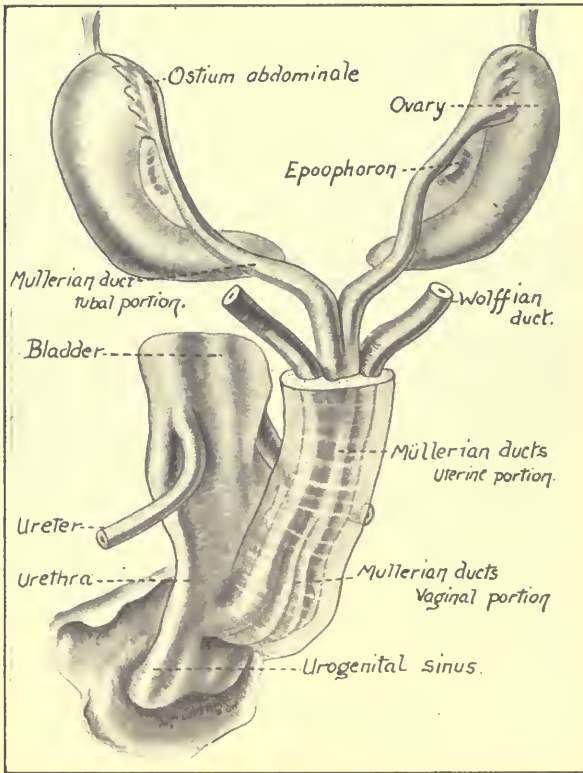


FIG. 71.—The Development of the Tubes, Uterus and Vagina in the Fetus. The Vaginal Portions of the Müllerian Ducts Are Here Still Separate. (After J. Kollmann.)

I. ANOMALIES DUE TO ARREST OF DEVELOPMENT

Absence of the Uterus.—Complete absence of the uterus, *i.e.*, those cases in which there is present not even a knob of tissue at the upper end of the vagina to represent a uterus, is an affair only of non-viable fetal monstrosities or pseudo-hermaphrodites.

Rudimentary Uterus.—Rudimentary uterus, on the other hand,

is not so uncommon. A goodly number of cases have been reported in the literature and they generally appear under the caption of "absence of the uterus" because the diagnosis is so difficult during life. In these cases there is present, in the situation usually occupied by the uterus, a knob of connective tissue of variable

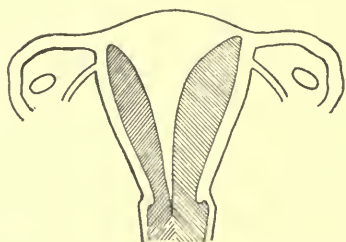


FIG. 72.—Uterus Bipartitus.

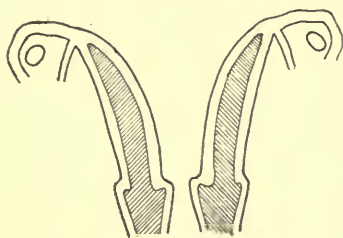


FIG. 73.—Uterus Didelphys.

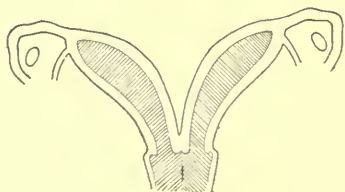


FIG. 74.—Uterus Bicornis.

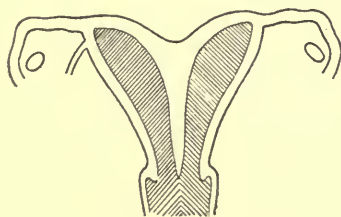


FIG. 75.—Uterus Septus.

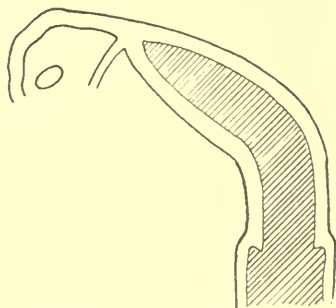


FIG. 76.—Uterus Unicornis.

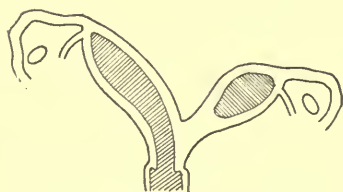


FIG. 77.—Uterus Unicornis with Accessory Cornu.

size and there is partial or complete absence of the vagina. The tubes are absent and the ovaries may or may not be absent. If they are present the patient suffers from molimina. Patients with this abnormality of development are generally well-formed women with normal external genitals, breasts, hair, and voice, who consult

the physician because of the absence of menstruation. The case of a married woman reported by me,—“Congenital Absence of Uterus and Vagina” (*Amer. Jour. of Med. Sci.*, March, 1897), came under observation because of the absence of a vagina.

The diagnosis is made by recto-abdominal examination with the patient under an anesthetic,—also by examination with a large sound in the bladder and the finger in the rectum. An absolute diagnosis can be made only by an abdominal section or by a post-mortem examination.

Uterus Bipartitus.—Uterus bipartitus consists of a poorly developed cervix continuous with two rudimentary united cornua which are usually solid cords, but may be provided with pervious canals as in the figure. The ovaries are generally present in an undeveloped state. Here only the lower part of Müller’s ducts have succeeded in coalescing to form a cervix, failing to unite in their upper portions.

Uterus Didelphys.—This is rare. It consists of two separate uteri, each with one horn, and two separate vaginae. Sometimes the lower extremity of one vagina is occluded at some point above the vulva and may contain retained secretions. (See Congenital atresia of the vagina, Chapter XX., page 357.)

Uterus Bicornis.—Uterus bicornis is a relatively common condition. In it Müller’s ducts have united to form a cervix with two canals and two ora, but are ununited above, so that there are two long cornua representing a uterine body. Sometimes the union has progressed to a point a little higher up in the cervix and we have one external os and one cervical canal below, and two cervical canals above, or the condition known as *Uterus bicornis uncollis*. (See Fig. 78.)

Uterus Septus.—Uterus septus is the coalescence of the ducts to form a uterus which appears to be normal externally but within, its cavity is divided longitudinally into two cavities by a persistence of the septum.

Uterus Unicornis.—Uterus unicornis results from the development of only one cornu, the other being entirely absent or rudimentary. The corresponding Fallopian tube is generally absent. If secretions accumulate in the rudimentary cornu, there being no outlet, a distended sac will be formed; but fortunately this is a rare happening. Pregnancy may occur in a rudimentary horn.

also in uterus didelphys, and, of course, in uterus septus. (See Chapter XXII., page 433.)

Diagnosis of Uterine Anomalies Due to Arrest of Development.—

The diagnosis of uterine anomalies due to arrest of development rests on the symptoms in the rare cases where accumulation of secretions forms a sac that presses on the bladder or rectum, or causes cramps; or cases in which menstruation does not occur at the normal age. As regards the latter it should be remembered that menstrual blood may flow from one half of a uterus while it is collecting in the other half. Abortion and premature labor are more frequent in the case of double uterus, and the presence of a septum makes delivery difficult and involution slower. A decidua

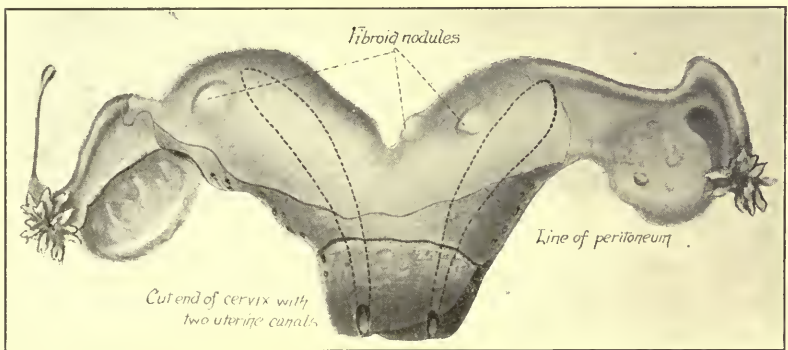


FIG. 78.—Bicornute Uterus, One External Os, Two Uterine Cavities. Removed from Single Woman 31 Years old, Jan. 27, 1903, for Rebellious Dysmenorrhea.

forms in the empty half of a septate pregnant uterus or in a rudimentary horn just as it forms in the uterus in the case of tubal pregnancy.

By examination the presence of two vaginal canals is a definite indication of a double uterus. If the vagina is single the two ora of a didelphys uterus may be palpated by the examining finger and may be seen through the speculum. Two uterine horns, or a divided fundus, may be felt by bimanual examination if the conditions are exceptionally favorable, that is, a thin and lax abdominal wall and absence of much fat. If the uterus feels normal to the bimanual palpation except for the presence of two ora in the cervix, two sounds are passed simultaneously, one into each os, and an attempt made to make them meet in the uterus.

If they do not meet, the case is one of uterus septus. If the septum does not reach to the external os the diagnosis is more difficult, and in this case the lower edge of the septum may possibly be felt with the tip of the sound. If the bimanual touch shows that there is a depression in the fundus we have to do with a case of uterus didelphys or uterus bicornis, the latter being much more frequent. The halves of a uterus bicornis are commonly closely adherent well above the level of the internal os and can not be moved independently, whereas in the case of uterus didelphys the two halves are well separated and can be so moved. They may lie even at some distance from each other, and the point of separation may be felt by rectal palpation, and if the conditions for palpation are favorable, an ovary attached to each horn may be palpated.

The diagnosis of the one-horned uterus is not easy. The fundus is found to one side of the pelvis, it is tapering, and only one ovary can be made out. Hematometra or pyometra may be present, and are to be diagnosed as swellings occupying a portion of the uterus. The diagnosis is difficult and is seldom made exactly without opening the abdomen.

Differential Diagnosis.—It is important to distinguish pregnancy in a detached cornu of an anomalous uterus from a fibroid tumor. The occurrence of irregular hemorrhage from the uterus and the absence of the signs and symptoms of pregnancy, together with hardness and irregularity of the surface of the tumor, serve to point toward a fibroid.

II. ANOMALIES DUE TO ARREST OF GROWTH

These are *infantile or puerile uterus*, in which the uterus of the adult remains of the type found at birth,—and *congenital atrophy* of the uterus, in which the organ, though of the type of the adult, is atrophied as a whole. These two sorts of malformations are not very uncommon. The condition known as retroposition with antelexion (see page 231) would seem to be closely allied to the infantile uterus.

Infantile Uterus.—This is a relatively common condition. The infantile uterus is narrow in proportion to its length, has a long cervix and a short body, and the uterus is situated well back and

high in the pelvis at the end of a long vagina, there being at the same time more or less anteflexion. The os is a "pinhole os" and the cervix is conical. Menstruation is usually absent in these cases, but the breasts, figure, hair, and voice may be perfectly normal; sexual desire is absent and the patient is necessarily sterile. The diagnosis is made by the bimanual recto-abdominal touch and by passing the sound. The situation of the internal os, where the tip of the sound or probe catches, is well up in the total length of the uterus and is characteristic, and the relatively large and long cervix, and short and slender body, can be made out easily. The ovaries are apt to be small in these cases. Help in the diagnosis is obtained often if the uterus is drawn down by a tenaculum held by an assistant while the bimanual touch is practiced.

Congenital Atrophy.—The congenital atrophic uterus is a rare condition. Here the diagnosis is made by finding a well-proportioned uterus which is small in all of its diameters. This anomaly is associated with lack of body growth, absence of pubic hair and sex characteristics. We must suppose that the individual attained a proper growth of the uterus to the virgin type followed by atrophy. The condition has been found in dwarfs and cretins and in cases of early tuberculosis and chlorosis.

Puerperal Atrophy.—The opposite of subinvolution is puerperal atrophy, superinvolution. Vineberg of New York has added to our knowledge of lactation atrophy. (*Amer. Medico-Surg. Bull.*, N. Y., 1895, VIII., 1518.) It is a shrinking of the uterus in size symmetrically below the virgin type, following prolonged lactation, and is due probably to overstimulation of the uterus due to nursing. It is not a permanent condition, the uterus returning to its normal size two or three months after nursing has been discontinued. It would appear that a certain amount of atrophy is normal during the puerperium irrespective of lactation, therefore superinvolution is a distinctly pathological state.

Non-puerperal Atrophy.—This occurs even more rarely than puerperal atrophy, in chronic wasting diseases, as in tuberculosis, and in the acute infectious diseases, such as scarlatina. I have seen one case following steaming of the uterine cavity. Non-puerperal atrophy may or may not be permanent. The exact causes are not known.

DIAGNOSIS OF LACERATION OF THE CERVIX UTERI

The credit for a proper understanding of laceration of the cervix uteri is due to Thomas Addis Emmet, of New York, who published his first paper on the subject, "Surgery of the Cervix Uteri," in the *American Journal of Obstetrics* in February, 1869. Previous to this the effects of lacerations were treated under the name of ulcerations of the womb, coxcomb granulations, or erosions of various sorts.

In a large proportion of cases the cervix is torn during labor, the few cases where it is injured by forcible dilatation or incision at the hands of the physician being disregarded here, although it happens not at all infrequently that the upper portion of the cervix is injured by the two-branched steel dilators employed in dilatation for curetting.

ANATOMY

The normal cervix in the virgin is slightly conical and projects into the vagina from a half to five-eighths of an inch (1 to 1.5 centimeters). The os is round or oval in shape and about a sixteenth of an inch in diameter. In women who have borne children the os is more of a transverse slit (see Figs. 65 and 66) and may be irregular from lacerations, and the cervix is rounder and less conical than in the virgin. To the feel the tissues are firm, but not hard, and seen through the speculum are of a yellowish pink color. The wall of the cervical canal presents anteriorly and posteriorly a longitudinal column from which proceed a number of oblique columns, giving the appearance of branches from the stem of a tree. This is called the uterine *arbor vite*. These columns become more indistinct after the first labor, but they are not obliterated.

ETIOLOGY

The causes of laceration may be enumerated as: (1) A rapid second stage of labor, (2) A large child and a small cervix, (3) A rigid cervix, as in abortion, or from diminished elasticity of the tissues, (4) Instrumentation, as from the forceps or instruments used in embryotomy, or in dilatation, (5) Friability of the tissues of

the cervix due to prolonged pressure by the presenting part, or to disease of the cervix.

MECHANISM AND PATHOLOGY

In the virgin uterus the canal of the cervix at its widest part, *i.e.*, midway between the external os and the internal os, is about one-fifth of an inch in diameter. During delivery this must be dilated to the diameter of the child's head, some four and a half inches. The muscular fibers of the cervix become stretched excessively and it is not surprising that lacerations occur, especially if insufficient time is given for the dilatation. Lacerations may occur in any direction or in several directions, that is, they may be unilateral, bilateral, or stellate, and anterior or posterior. They are most often lateral. Extensive tears which involve the cervix above the attachment of the vagina are apt to result in infection of the perimetrium (cellulitis). During pregnancy the cervix together with the rest of the uterus is enlarged to accommodate the growing fetus. The rhythmical contractions of the uterus during the entire pregnancy reach their climax in labor when the major part of the hypertrophied uterine muscle acts as an expellent force, while the small portion of the uterus, the lower part of the cervix, acts a passive rôle and is dilated. This lower part of the cervix may be likened to the sphincter ani muscle. After receiving an excessive stretching as a preliminary to an operation for hemorrhoids, or other operation on the rectum, the sphincter ani does not recover its tone and is unable to contract for forty-eight hours, more or less—in fact it has been stretched for this very purpose. So in the case of the lower cervix after labor. It is a flabby, soft ring that has no power of contracting. Under normal conditions, and when not lacerated, it contracts to the

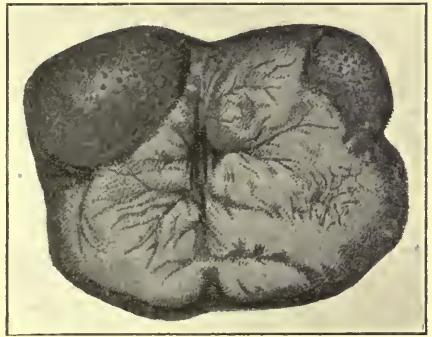

FIG. 79.—Bilateral Lacerations of the Cervix with Erosions.

After receiving an excessive stretching as a preliminary to an operation for hemorrhoids, or other operation on the rectum, the sphincter ani does not recover its tone and is unable to contract for forty-eight hours, more or less—in fact it has been stretched for this very purpose. So in the case of the lower cervix after labor. It is a flabby, soft ring that has no power of contracting. Under normal conditions, and when not lacerated, it contracts to the

dimensions of a parous, normal cervix in the course of a few days. When torn the lips are turned out into the vagina by the weight of the large uterus above and the contracting power of the cervix is thus lost. (See Fig. 82.) The intracervical tissues are everted into the vagina, the uterine circulation is interfered with, the tissues become engorged and remain swollen—therefore there is no longer room for them within the uterine canal. Infection of the rolled-out mucosa adds to the trouble and erosions, endometritis and cystic degeneration result, with ultimate thickening of the torn lips from subinvolution. Because of the downward excursion of the heavy

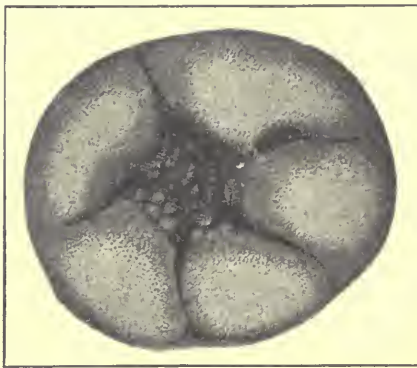


FIG. 80.—Stellate Lacerations of the Cervix.

uterus the cervix projects relatively farther into the vagina and the attachments of the latter organ to the cervix appear to be higher up on the uterus, although in reality they are not, and thus the torn cervix seems to be larger than it is. Subinvolution, or chronic metritis, keeps the uterus heavy and in this manner accentuates the eversion. Lacerations of not great extent

unite readily in the absence of infection. If pelvic inflammation is present lacerations are apt not to heal so soon, if at all, and extensive lacerations may involve the vagina and even the bladder or rectum, leaving fistulae behind them. It often happens that the laceration is in the canal of the cervix and that the external os is little, if at all, involved.

RESULTS OF LACERATION

The immediate results of laceration of the cervix are hemorrhage, or the production of a fistula. The later results are endometritis, subinvolution of the uterus, cystic degeneration and erosion of the cervix (see Chapter XI. on endometritis, page 184), thus furnishing a favorable soil for the growth of cancer, cellulitis

(see Chapter XII. on pelvic inflammation, page 192), cicatricial stenosis of the uterine canal, and a tendency to sterility and abortion. As regards the last, Dr. Emmet's tables ("Principles and Practice of Gynecology," 3rd edition, pages 447, 448) show that following lacerations of the cervix 71.34 per cent of his 164 cases were sterile, and of the 47 who became pregnant, 51 per cent aborted one or more times. These were in the preaseptic days and infection as a sequence to injury was undoubtedly more frequent than now.

Endometritis is considered in Chapter XI., page 165.

Subinvolution.—This may be defined as a failure of the physiological hypertrophy of pregnancy to subside after labor. It is due not only to laceration of the cervix but to malposition of the uterus from weakening of the uterine ligaments and too long a stay in bed, with general debility following confinement.

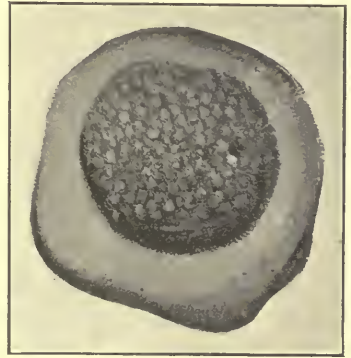

FIG. 81.—Crescentic Lacerations of the Cervix.

After the early stages of subinvolution infection plays a rôle in most cases and there is present an interstitial metritis, formerly called *areolar hyperplasia*. In this disease the connective-tissue elements in the uterine wall are increased and the muscular elements diminished. In the acute stages there is a round-celled infiltration; the uterus is large and feels softer. In the later stages the uterus is large but the tissues are indurated. This is the time when the connective-tissue elements predominate and a pathological involution takes place. The lymph and blood vessels are diminished in size, crowded out by the connective tissue; the muscle atrophies and the uterine tissues become pale and indurated. Such a state of affairs is found in uteri which have been many years the seat of chronic metritis, not in recent cases, *i.e.*, generally not before four or five years after the receipt of injury or misplacement. Subinvolution or chronic metritis may be associated with arterio-sclerosis of the uterine vessels in the later years of life.

DIAGNOSIS OF LACERATION

The symptoms of laceration of the cervix are the symptoms of the pathological conditions resulting from this lesion. Immediate hemorrhage following labor calls for prompt diagnosis. The specific nervous symptoms, such as pain in the suboccipital region, headaches of the vertex and neuralgia, considered by Dr. Emmet to be due to a "cicatricial plug" in the angle between the lips of old tears of the cervix, are now generally thought by the profession to be due to a deterioration of the nervous system caused by pelvic disease in general.

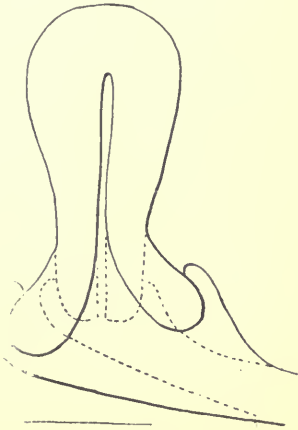


FIG. 82.—Diagram Showing Bilateral Laceration of the Cervix with Eversion of the Lips.

The diagnosis of lacerations is not an easy matter, as becomes evident when we reflect that the diagnosis was not made until Emmet showed the way in 1862. The results of lacerations so obscure the landmarks that at the time when most lacerations come under the physician's observation—several years after their receipt—he is at a loss to determine the exact situation and extent of the injury.

(a) **Recent Lacerations.**—In the case of recent tears of the cervix the only bars to an exact diagnosis are the tumefaction of the parts and the exhausted condition of the patient. If there is excessive hemorrhage following delivery the diagnosis must be made at once. In other cases it may be made in a few hours or days, depending on the patient's condition. The woman should be in the dorsal position on a table in a good light. The perineum being retracted by a large Sims speculum in the hands of an assistant, the cervix is seized with a double tenaculum and drawn down and search is made for solution in continuity in the circle of the enlarged os. Tears can be repaired at this time by suturing. Some operators prefer to do this in an intermediate time, *i.e.*, four or five days after labor, perhaps scraping the edges of the tear with sterile gauze before uniting

them. The injuries must be followed carefully to their limits, whether they be confined to the cervix, or if they extend to the vagina, or even to the rectum or the bladder.

(b) **Old Lacerations.**—If every woman were submitted to a careful uterine examination after child-bearing, and injuries of the cervix, as well as those of the pelvic floor, found and repaired, there would be comparatively little for the gynecologist to do. It happens, however, that most of the lacerations of the cervix come under the physician's notice for the first time some years after their receipt. At this time the diagnosis is difficult because of enlargement and distortion of the cervix, eversion of the lips, and cystic degeneration of the Nabothian follicles and erosion. The trained vaginal touch after a little practice detects all of these features even to the erosion. For inspection the Sims position is best. Search first for the arbor vitæ and thus determine the situation of the cervical canal. The passage of the sound helps to define the situation of this canal, but the physician must be on his guard not to be misled by the malpositions of the uterus found in cases of unilateral tear as pointed out by Emmet. (See Fig. 83.) In this event the sound passed to the

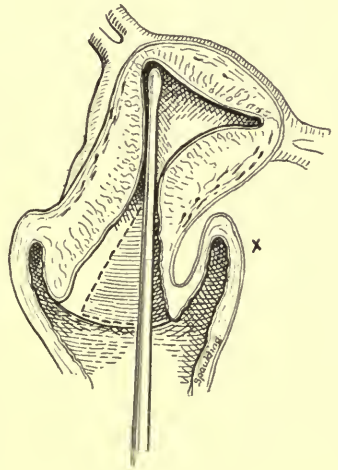


FIG. 83.—Unilateral Lacerations of the Cervix, Producing Obliquity of the Long Axis of the Uterus. (After Emmet.) The Reduplication of the Vagina is shown at W.

cornu opposite to the seat of the laceration may appear to be in the canal (see figure), but because of the tilting of the fundus toward the laceration the sound occupies the laceration and not the normal cervical canal. Here a search for the arbor vitæ will help to set us right and the bimanual touch will also assist. Putting the patient in the knee-chest position, thus permitting the uterus to fall toward the abdomen high in the pelvis, straightens its axis and also pulls out the reduplication of the vagina on the side where the laceration is situated. In all lacerations of severe grade it is well to study the conditions as seen through the specu-

lum when the patient is in this position, because in the dorsal position the weight of the uterus—usually increased in cases of laceration—drives this organ downward so that the intravaginal portion of the cervix seems to be longer, especially if the upper vagina has become stretched. Therefore, there is present in extensive lacerations of the cervix apparent hypertrophy and elongation of the cervix beyond what really exists. This reduplication of the vagina is shown at X in the figure. Next, with the patient in the Sims position, hook a tenaculum into the crown of each lip of the cervix and bringing the two tenacula together, try to reconstruct the cervix. If there is much induration of the tissues this feat is difficult of accomplishment. By palpation with the tip of the finger or the sound, determine the situation and extent of cicatricial tissue in the angle of the tear, pressure on the tissue causing pain. With the tip of the sound a laceration within the canal of the cervix may be appreciated, for in that situation the sound falls into an opening in the otherwise smooth mucosa of the wall of the canal. The internal os will be found abnormally large should the laceration involve this region, permitting the sound to be moved freely about after it has been passed through. When the arbor vitæ has been made out the situation of the laceration with reference to it is determined.

DIFFERENTIAL DIAGNOSIS OF LACERATIONS

Cancer of the cervix is the disease most often mistaken for lacerated cervix. The differential diagnosis is considered under cancer of the cervix, Chapter XVI, page 272. Carcinoma is attended by much induration of the tissues and ulceration, also cancer bleeds easily and the superficial portions are friable. Endocervicitis and erosion is a coincident condition in laceration, but may exist in the absence of laceration. The diagnosis is based on the absence of the signs of laceration. Eversion of the mucous membrane of the cervical canal may be present without laceration and it is well to bear this fact in mind. The cervix in such cases is of normal contour and there are no evidences of laceration.

DIAGNOSIS OF DISEASES OF THE UTERINE LIGAMENTS

The uterine ligaments are the broad ligaments, the round ligaments, the utero-sacral ligaments, and the utero-ovarian ligaments.

THE BROAD LIGAMENTS

These become stretched in prolapse of the uterus so that they no longer support that organ. Under normal conditions they have enough elasticity, together with the utero-sacral ligaments, to restore the uterus to its normal situation after it has been drawn down forcibly. Certain tumors originate in the broad ligaments, notably parovarian cysts, fibromata and lipomata, also dilatation of the veins, varicocele. The solid tumors are extremely rare, lipomata are seldom seen, and fibromata only occasionally, the latter being not large as a rule and arising in the unstriped muscle fiber between the folds of the ligament. Sarcoma and carcinoma of the broad ligament are secondary to malignant disease of the uterus.

Parovarian Cysts.—These originate in Gärtner's duct, Kobelt's tubules, or in the parovarium proper. Small pedunculated cysts may develop from one of these structures, or the cysts may be sessile and large. These large cysts, so called, develop between the layers of the broad ligament and are of slow growth. They are seldom larger than a child's head. The cyst has no pedicle, the Fallopian tube is stretched over its surface, and the cyst pushes the uterus to the opposite side of the pelvis. Adhesions are rare because the cyst is covered by peritoneum. The wall of the cyst is thin, transparent, and of a greenish-yellow hue, the contents are a thin, colorless fluid of a non-irritating character having a specific gravity of 1002 to 1008. Upon rupture the cyst is apt not to refill, in this respect differing from an ovarian cyst. A parovarian cyst may be rarely the seat of papilloma and in this case the contents are opaque, the walls are thick, and the cyst is like a papillomatous cystoma of the ovary. The diagnosis is made by vagino-abdominal and recto-abdominal palpation, if necessary having the uterus drawn down by a vulsellum while the palpation is being practiced. (See Fig. 125, page 294.) The cyst is on one side of the pelvis, in close relation with the uterus. Its mobility is distinctly limited; it is ovoid in shape and has smooth walls; fluctuation is distinct, being felt through the vault of the vagina; there is no pedicle, but a groove between the cyst and the uterus can be distinguished. The differential diagnosis is considered in Chapter XVII, on ovarian tumors, page 297.

Varicocele of the Broad Ligament.—This is not a very rare disease. It consists of dilated veins running transversely in the upper part of the broad ligament and forming a tumor that may be as large as a small hen's egg, though generally much smaller. Varicocele is found more often on the left side. Perhaps this is because the left ovarian vein is valveless and opens into the renal vein at a right angle. It is possible to make a diagnosis by recto-abdominal palpation by finding a doughy-feeling tumor in the broad ligament, but as such a tumor is not tense except when the patient is in the erect posture, the diagnostician would be likely to miss it during the usual examination made with the patient in the dorsal position. If there are varicosities elsewhere in the body varicocele of the broad ligament should come into the physician's mind and he should examine the patient in the standing position. The characteristic symptom of varicocele of the broad ligament is a dull aching pain in the pelvis or back.

THE ROUND LIGAMENTS

The round ligaments vary much in size and in length in different individuals, therefore their ability to steady the uterus as guys is a variable quantity. The muscular fibers are situated in the inner two-thirds of the ligament and sometimes the ligaments are nothing but the slenderest of cords. Fibroma, fibromyoma, adenomyoma, fibromyxoma, and sarcoma of the round ligament have been described. The tumor is generally unilateral but may be bilateral. These tumors are thought by some writers to be associated with fibroids of the uterus. They may be found in any portion of the course of the ligament,—in the abdominal cavity, the inguinal canal, or in the labium majus,—and they develop slowly, but may be stimulated to more rapid growth by the presence of pregnancy. The tumors are hard and generally pedunculated.

Diagnosis of Tumors of the Round Ligament.—If a tumor is situated within the peritoneal cavity it is felt by bimanual palpation in the front of the pelvis on one side. If it is in the inguinal canal or labium majus the tumor is felt from the outside in the course of the canal or in the labium. It must be differentiated from omental or ovarian hernia, hydrocele of the round ligament, a cyst of Bartholin's gland, or enlarged inguinal lymphatic glands. There is no

impulse on coughing or straining and the enlargement can not be reduced by taxis. An ovary in the inguinal canal is very sensitive to pressure, and swells and is painful at the time of menstruation. A cyst of Bartholin's gland will present fluctuation, and enlarged inguinal glands are generally separate glands, *i.e.*, they are multiple tumors and are situated to the outside of the inguinal canal.

Hydrocele of the Round Ligament or of the Canal of Nuck.—In the fetus the peritoneal covering of the round ligament projects as a tubular process into the inguinal canal. This tube is called the Canal of Nuck and it sometimes persists through life. If fluid collects in this canal and the abdominal end of the canal is obliterated there is found a cystic, translucent, oval tumor which may extend downward even into the labium majus. In size the tumor may be as large as a hazelnut or even attain the proportions of a cocoanut. It can not be pushed up into the abdomen, it fluctuates, and has an impulse on coughing if situated in the inguinal canal. In rare cases the cystic tumor may communicate with the peritoneal cavity and in this event the fluid may be forced out of it by gentle pressure. Hydrocele is not tender like an ovarian hernia; it is of gradual development and often there is difficulty in distinguishing a hydrocele from hernia. In the case of encysted hydrocele the elastic, translucent character of the tumor that can not be reduced with the patient recumbent, serves to distinguish it. The hydrocele that connects with the peritoneal cavity can not be differentiated from hernia without an operation. In the case of an inflamed hydrocele the differentiation from a strangulated hernia is made by the absence of severe constitutional symptoms, and of symptoms of intestinal obstruction. As a matter of fact such tumors have generally been operated on for strangulated hernia.

THE UTERO-SACRAL LIGAMENTS

The utero-sacral ligaments contain, besides connective tissue and peritoneum, as do the round ligaments, a certain amount of muscle fibers. When the uterus is drawn down forcibly there is elasticity enough in the ligaments to pull the uterus back again. The ligaments are much overstretched in prolapse of the uterus and are abnormally short in retroposition with anteflexion, in the latter case being almost of a cicatricial hardness. Naturally liga-

ments of this character limit the downward or forward excursion of the uterus. The diagnosis of shortening is made by the bimanual vagino-abdominal and recto-abdominal touch. The uterus is raised and at the same time the ligaments are palpated to detect shortening and thickening, or the uterus is brought down by traction with a tenaculum while the rectal touch is practiced. Shortened ligaments are easier to make out than lengthened ones. In the infant, the uterus being very high in the pelvis, the utero-sacral ligaments course from their origins at the second piece of the sacrum to their insertions on the uterus in the form of an arch and may be felt in this shape by rectal palpation. The operator should not lose the opportunity afforded, during abdominal operations when the cul-de-sac of Douglas is in view, to inspect as well as to palpate these ligaments from above.

THE UTERO-OVARIAN LIGAMENTS

The following tumors have been found in these ligaments: fibroma, sarcoma, and carcinoma. The last two must be regarded as extensions of the disease from the uterus; the former, fibroma, is very rare. These tumors can not be distinguished from ovarian tumors without opening the abdomen. In some cases the ovarian ligaments are very long, thus favoring prolapse of the ovaries.

CHAPTER XIV

THE DIAGNOSIS OF MALPOSITIONS OF THE UTERUS

General considerations, p. 215.

I. Malpositions of the uterus as a whole, p. 218: 1. Ascent, p. 218. 2. Descent (prolapse), p. 218; Pathology, p. 218; Mechanism, p. 219; Symptoms and course, p. 226; Diagnosis, p. 226; Differential diagnosis, p. 228. 3. Anteroposition, p. 229. 4. Lateroposition, p. 229. 5. Retroposition, p. 230: Retroposition with anteflexion, p. 231; Diagnosis of retroposition with anteflexion, p. 232. 6. Hernia of the uterus, p. 233.

II. Abnormalities of the axis and form of the uterus, p. 234: 1. Retroversion, p. 234: Retroversio-flexion, p. 234; Diagnosis of retroversio-flexion, p. 236. 2. Anteversion, p. 238. 3. Anteflexion, p. 240. 4. Inversion, p. 240; Diagnosis, p. 240; Differential diagnosis, p. 240. 5. Torsion, p. 243.

GENERAL CONSIDERATIONS

IN considering the subject of malpositions of the uterus it must be understood that displacement of the uterus carries with it more or less change in the position of other pelvic organs at the same time. For instance, it is manifestly impossible to place the uterus in a condition of complete prolapse without altering the position of the tubes, ovaries, bladder, and vagina.

We shall consider in each instance the dislocation of the most important organ, noting the complications. The normal position of the uterus and the factors which determine its situation in the pelvis and limit its mobility under the varying conditions of health have been described in Chapter V., page 43.

When pregnant or under conditions of disease the uterus is subject to certain displacements as a whole, and its long axis may be turned or verted in one of several directions. Theoretically we have to do with two distinct classes of displacements. The uterus may be likened to a telescope upon a stand in a room. The telescope may be in the middle of the room (the pelvis), or it may be placed against the wall (retro-position), or it may be raised (ascent), or lowered (prolapse). Also it may be tilted in one of many direc-

tions (version) although its position as a whole with reference to the walls, floor, and ceiling of the room has not been changed.

Alteration of the position of the uterus generally but not necessarily implies change in its axis, and often in its form. For instance, retroversion generally means a certain degree of retro-position and often retroflexion; prolapse presupposes retroversion

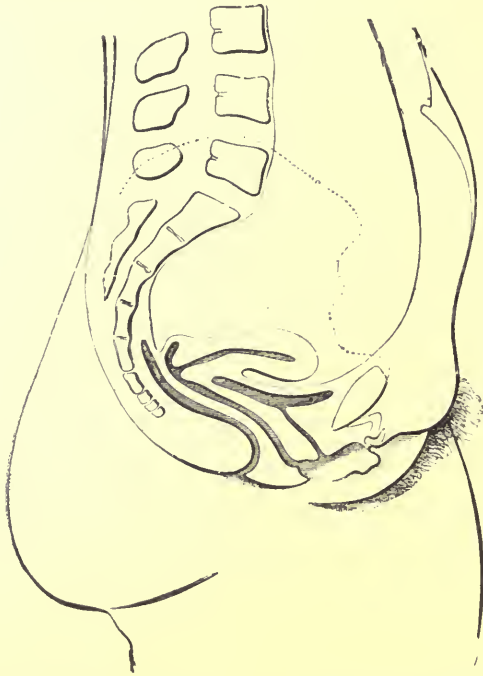


FIG. 84.—Median Section of the Body of a Woman Who has Borne Children. Bladder Empty. (Schultze.) Note Anteversion of Uterus.

in the early stages of the descent of the uterus; inversion is a form of prolapse.

The lesion that is supposed to be the important one from a pathological standpoint gives the name to the displacement, although—as before stated—several lesions are involved. The classification here used is a practical rather than a theoretical one.

In describing the pelvic circulation, Chapter V., page 46, it has been stated that the blood-vessels of the uterus and broad ligaments are convoluted, valveless, and capable of great distention, depending for their normal tone on absence of constricting influ-

ences in the way of pressure from tumors or pelvic inflammatory masses, or stretching due to malposition of the uterus.

We know how much a prolapsed uterus is reduced in size after it has been replaced in a normal position in the pelvis and maintained there for a few hours even. We know that a normal uterus, displaced downward mechanically, becomes congested. It is fair to assume that this is due to a straightening of the tortuous valve-

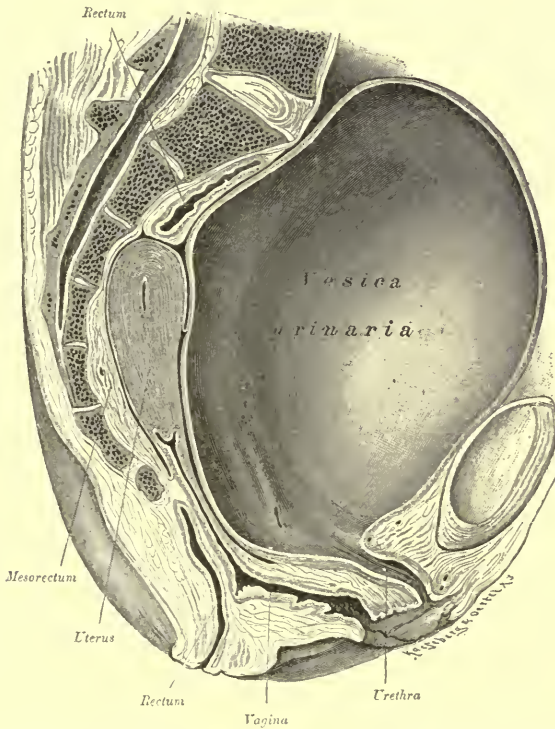


FIG. 84a.—Longitudinal Median Section of a Pelvis with Overdistended bladder. (Zuckermandl.) Note Retroversion of Uterus.

less veins, thus lessening the resistance of their walls to an increased pressure delivered by the less convoluted arteries.

It is the view of the author that uterine malpositions have a direct mechanical effect on the pelvic circulation, therefore displacements of the uterus as a whole are of more importance than changes in the axis (version), or changes in form (flexions, torsions, or tumors).

I. MALPOSITIONS OF THE UTERUS AS A WHOLE

1. Ascent. 2. Descent (prolapse). 3. Antero-position. 4. Latero-position. 5. Retroposition. 6. Hernia of the uterus.

1. ASCENT

The uterus is in a position of ascent in the later months of pregnancy; when it is displaced upward by a tumor developing from the lower part of the pelvis; when oversupported by a pessary; and when it has been attached to the abdominal wall by a ventral suspension or fixation operation. The diagnosis is established by bimanual palpation. The cervix uteri is far removed from the normal situation and in some cases can not be reached by the tip of the examiner's finger. The fundus may be palpated through the abdominal walls. According to our present knowledge ascent is not an important displacement. The only symptom directly traceable to ascent is an irritability of the bladder, seen occasionally, and thought to be due to traction on the vesical neck. Prolapse, on the other hand, is extremely important as well as of common occurrence.

2. DESCENT OR PROLAPSE

The extent of the descent varies from a slight "falling of the womb" to the complete escape of the uterus through the vulvar orifice.

When the uterus remains within the body the displacement is spoken of as an incomplete prolapse, or *descensus uteri*; when it is outside the body it is known as complete prolapse, or *prociidentia*. This form of displacement is generally of slow development—a matter of months and years.

Acute prolapse, due to violence or sudden straining when the uterus is large and heavy, the ligaments weak, and the retentive power of the abdominal walls diminished—as after labor—has been observed as a rarity.

Pathology.—The pathology of prolapse includes the morbid anatomy of all the pelvic organs involved. The circulation is obstructed by traction on the vessels and all the displaced organs

become congested; the nerves also are stretched or even sundered. The displaced vagina becomes swollen and congested and may be ulcerated; there may be hernia of the cul-de-sac of Douglas, and the rectum may occasionally send an offshoot into the hernia; the bladder is frequently displaced and is subject to catarrh; and the endometrium is the seat of endometritis—the uterus being, as a rule, much congested.

Mechanism.—To understand the mechanism of the production of prolapse one must consider three factors. (a) The pelvic floor. (b) The uterine ligaments and attachments of the uterus to surrounding structures. (c) The variations of pressure exerted by the abdominal contents.

(a) The pelvic floor is a muscular and tendinous diaphragm closing the outlet of the pelvis. Through this diaphragm runs the vagina transversely and obliquely as a slit. In the erect woman the vagina is at an angle of about 60° with the horizon, terminating above at the neck of the womb, which in turn has its long axis placed at a right angle to the long axis of the vagina.

The vagina in its course from the cervix to the introitus vaginae shows an S-shaped curve when seen in a median longitudinal section of the body, the forward bulging portion of the S being in its lower portion opposite the under edge of the symphysis pubis. (See Fig. 85.) This prominent portion of the vagina is made by the presence at this point of the chief muscle masses of the levator ani and smaller muscles and fasciæ making up the pelvic floor. It is the so-called “perineal body” of the older gynecologists. By reference to the diagram (Fig. 84) it will be seen that this key-stone to the arch of the pelvic diaphragm lies about midway between the lower border of the symphysis and the coccyx. Injury to the muscles here naturally destroys the sigmoid curve of the vagina, opens its outlet, and diminishes the support to the structures lying above. The vagina, instead of being a flattened ribbon-like canal with walls in apposi-

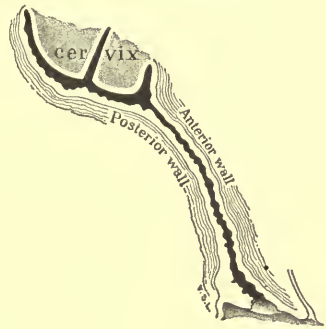


FIG. 85.—S-shaped Curve and Inclination of Vagina. Note that the Walls Are in Apposition. (Skene.)

tion and running almost transversely from the cervix to the hymen, now becomes a straighter open tube, leading almost directly downward from the cervix to the introitus.

The pelvic floor, according to Hart and Barbour, may be divided up into an anterior and a posterior segment. The anterior segment is a relatively movable one, the posterior is relatively fixed. The anterior or pubic segment consists of anterior vaginal wall, urethra, and bladder, all attached loosely to the symphysis pubis by retropubic deposits of fat. The posterior or sacral segment is made up of posterior vaginal wall, the muscles and fasciæ of the perineum, and the rectum, all firmly bound to the sacrum and coccyx. During labor the anterior segment is drawn up; the posterior segment is driven down. In the formation of prolapse the anterior segment, because of the injury of the posterior segment, swings downward and backward—the retropubic fat giving way with consequent dislocation of bladder and urethra. It is plain that a tipping back of the uterus on its axis, so that it may get into the same axis as the vagina, is a requisite to the descent of that organ, and that this tipping backward is made possible by injury of the posterior segment of the pelvic floor and dislocation of the anterior segment, so that the cervix—not stayed from behind and having no firm tissue in front of it—swings forward until its long axis coincides with the long axis of the vagina. This subject will be made clearer when we consider the different directions in which under varying conditions the intra-abdominal pressure is applied to the fundus uteri.

(b) The uterine ligaments and the attachments of the uterus to the surrounding structures.

The ligaments, described in Chapter V, page 44, consist of three pairs of ligaments proper—the broad, the round, and the utero-sacral; and the attachments are—the utero-vesical connective tissue, the vagina, and the retro-uterine cellular tissue. In considering the causation of prolapse we must think of the woman being in the erect position, because it is in this attitude that the great strain is brought to bear that causes sacro-pubic hernia. By reference to the diagram (Fig. 84) on page 216 it will be seen that the origins and insertions of all the ligaments lie in nearly the same plane. As a matter of fact, the pubic ends of the round ligaments are a little lower than their insertions into the horns of

the uterus, therefore the round ligaments can not support the uterus except in cases of extreme prolapse. On the other hand, the attachments of the utero-sacral ligaments to the pelvic wall near the second piece of the sacrum are a trifle higher than their insertions into the uterus at the level of the internal os. They are normally firm and strong and act as true supports.

The broad ligaments check lateral motion and limit the uterine

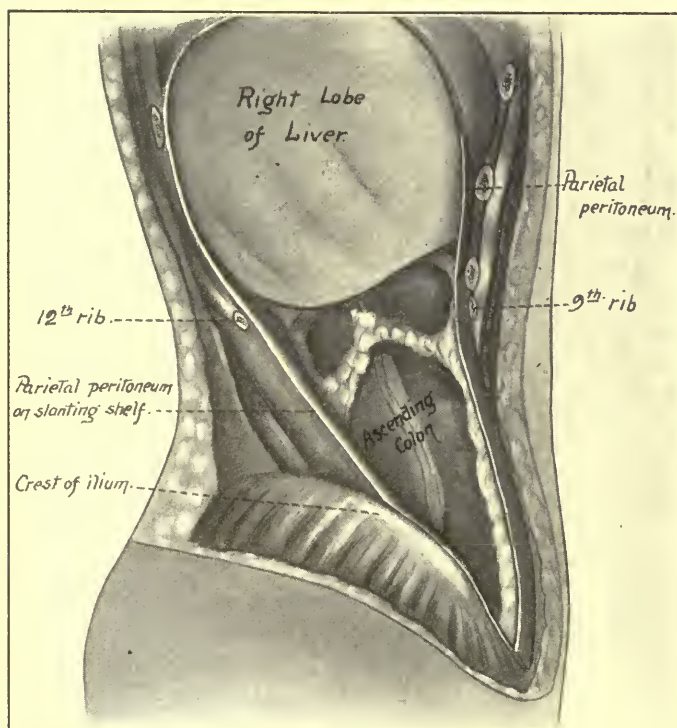


FIG. 86.—Right Side of Abdominal Wall Has Been Removed, Showing Funnel Shape of Abdominal Cavity, which Is Wide Above and Narrow Below, also the Slanting Shelf which Gives Partial Support to the Viscera. (After Corning.)

movements largely to forward and backward excursions. The intra-abdominal pressure is exerted on the posterior aspect of their broad surfaces and thereby they assist either in retaining the uterus in anteversion, or, if the axis of the uterus has been changed from anteversion to retroversion, the pressure being on their posterior aspects, they assist in keeping the womb in that position and in aiding prolapse. The thick bases of the broad ligaments

intimately joined with the uterus form strong connecting and supporting structures between the uterus and pelvic walls. Prolapse can not occur unless the attachments of the ligaments or the ligaments themselves are severed or stretched. The utero-vesical connective tissue, when torn asunder by labor or when weakened by the atrophy of the triangular mass of subpubic fat, promotes retroversion and also prolapse by lessening the resisting power of the structures connecting the uterus with the symphysis and indirectly diminishing the distance between the cervix and the pubes.

One of the common results of a difficult labor is to loosen the attachments of the vagina to the cervix. As seen through a speculum with the patient in the Sims or knee-chest position, there appears to be little or no intra-vaginal portion to the cervix. In these cases the mobility of the uterus is increased and, other things being equal, descensus is favored. The attachments of the vagina to the cervix serve to steady the uterus and keep it in its proper relation to the pelvic floor.

The retro-uterine cellular tissue has probably very little influence on the position of the uterus unless it is the seat of inflammatory thickening; in which case it fixes the organ. It sometimes happens that women who are the subjects of pelvic inflammation are relieved of preëxisting prolapse only to suffer with it again when the exudate has been absorbed.

(c) The variations of pressure exerted by the abdominal contents. The reader is referred to Chapter V., page 45, for a partial exposition of this subject. Here it is sufficient to say that we have to do with (1) downward pressure exerted by (a) increased weight of the uterus itself, (b) the weight of the intestines filled with a varying amount of solid, fluid, or gaseous matter, and (c) the weight of dislocated organs, such as the stomach or kidneys, or the weight of a tumor; and (2) additional pressure transmitted to the abdominal contents by the walls of the abdomen and by the diaphragm in coughing, laughing, straining, jumping, and riding.

The downward pressure spends itself under normal conditions mostly on the lower anterior wall of the abdomen. By consulting Fig. 6, page 44, it is apparent that the long axis of the abdominal cavity falls at nearly a right angle to the long axis of the pelvic cavity, and that the pelvic viscera are protected in a measure from

pressure directed downward from above by the forward lumbar curve of the spine, which, in the normal standing posture of the individual, must take some of the weight of the contents of the abdomen. A transverse section of the body of the adult virgin through the fifth lumbar vertebra shows that at this situation the depth of the abdominal cavity from before back is very much less than it is in the upper portion of the abdomen. For instance, it represents only a little over a third of the entire thickness of the body if measured in the median line from the anterior face of the lumbar vertebra to the skin surfaces of the front and back of the body. At the level of the twelfth dorsal vertebra, on the other hand, the abdominal cavity takes up over a half of the thickness of the trunk if measured in the same way and occupies a major part of the cubic contents of the body at this point.

When the back is flattened and the forward lumbar curve is more or less obliterated—as happens in the case of the flat-chested, slouchy body posture so often seen in women—more of the weight of the viscera will fall on the inlet of the pelvis.

Under normal conditions there is present a thrust directed forward, inward, and downward from the slanting surface of the brim of the false pelvis (60° with the horizon) that throws the abdominal pressure on to not only the lower abdominal wall, but also on to the posterior surface of the anteverted uterus and the backs of the wide expanses of the broad ligaments. Thus is the uterus maintained normally with its long axis at a right angle at least with the long axis of the vagina. As has been stated previously, the axis of the uterus must be changed to retroversion before prolapse can occur. Such a change in axis is brought about by relaxation of the uterine ligaments, by

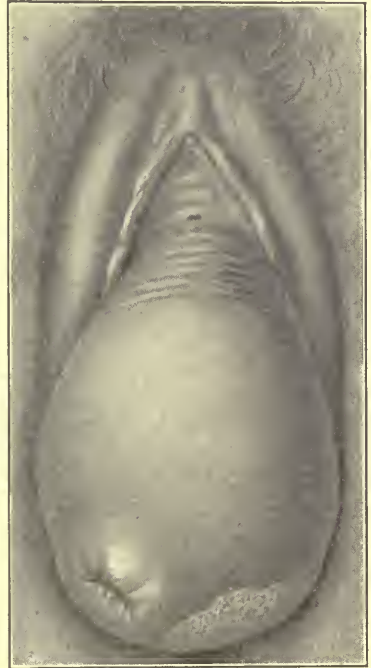

FIG. 87.—Complete Prolapse or Procidentia. (After Huguier.)

chronic distention of the urinary bladder, chronic fulness of the rectum, sudden jar, etc. (see Retroversion, page 234). When once the axis has been changed, the intra-abdominal pressure is exerted against the anterior face of the uterus and the broad ligaments, and increased pressure accentuates the retroversion, and at the same time pushes down the uterus, now in the same axis as the vagina. Factors which make for greater downward pressure, such as a persistent cough or violent straining because of chronic

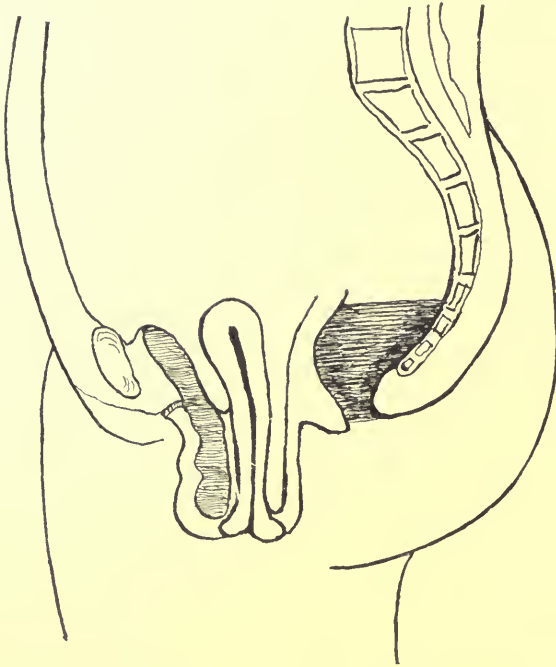


FIG. 88.—Prolapse of the Vagina and Cervix, with Elongation of the Supra-vaginal Cervix.

diarrhea, tend to cause descensus uteri. Constant straining is an important factor in the causation of prolapse; therefore prolapse is found most frequently among women of the working classes. These women are apt to get up and begin work soon after confinement when the uterus is large and heavy and retroverted.

Inversion of the vagina may take place without actual descent of the uterus because of the elasticity of the vagina, and, prolapse may be simulated by elongation of the lower uterine segment.

True hypertrophic elongation of the cervix, a lengthening of the cervix and the lower segment of the uterus, is by no means an uncommon condition. In such a case, should the utero-sacral ligaments, which ordinarily limit the amount of the descent of the uterus, prove to be strong and not susceptible of stretching, the fundus uteri may remain nearly at its normal level while the external os presents at the introitus vaginae. A typical case of true hypertrophic elongation of the cervix was reported by Huguier ("Mémoire sur les Allongements Hypertrophiques du Col de l'Utérus,"

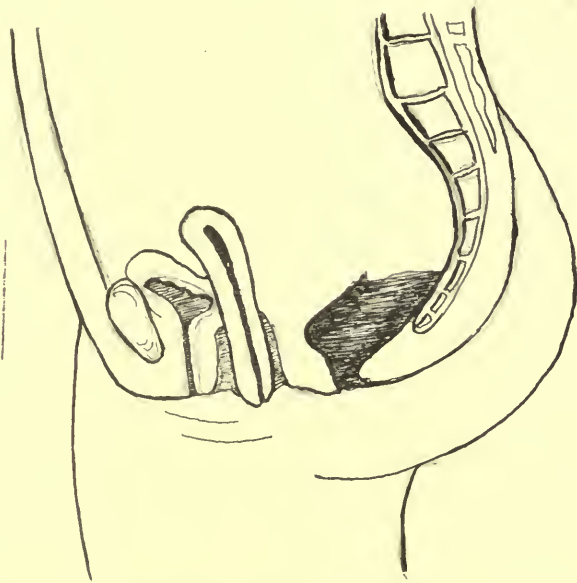


FIG. 88a.—Hypertrophic Elongation of the Cervix in the Virgin.

1860, p. 40) as long ago as 1860. A woman twenty-three years of age, of poor general health and physique, married two years but never pregnant, presented herself for treatment because of pains in the abdomen, dyspareunia, and a tumor in the opening of the vagina. Catamenia began at thirteen and she noticed the projection at the vulva at fourteen and a half years. It came out while she was standing or straining and was reduced on lying down. Examination showed the vagina only a little shortened and occupied by the enlarged cervix; fundus uteri only a trifle below its

tions (version) although its position as a whole with reference to the walls, floor, and ceiling of the room has not been changed.

Alteration of the position of the uterus generally but not necessarily implies change in its axis, and often in its form. For instance, retroversion generally means a certain degree of retro-position and often retroflexion; prolapse presupposes retroversion

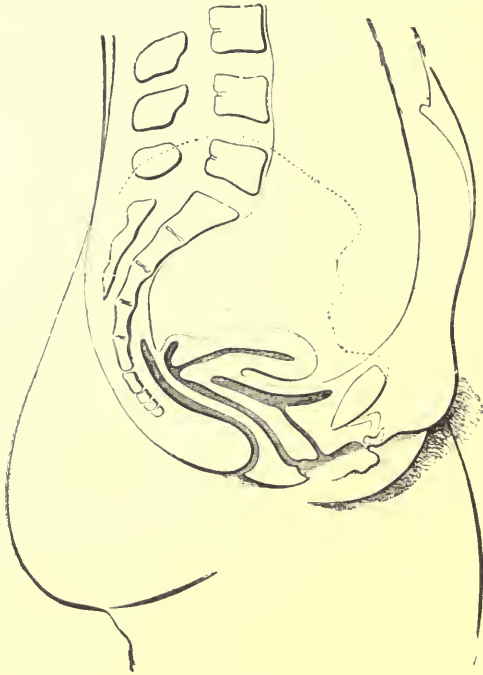


FIG. 84.—Median Section of the Body of a Woman Who has Borne Children. Bladder Empty. (Schultze.) Note Anteversion of Uterus.

in the early stages of the descent of the uterus; inversion is a form of prolapse.

The lesion that is supposed to be the important one from a pathological standpoint gives the name to the displacement, although—as before stated—several lesions are involved. The classification here used is a practical rather than a theoretical one.

In describing the pelvic circulation, Chapter V., page 46, it has been stated that the blood-vessels of the uterus and broad ligaments are convoluted, valveless, and capable of great distention, depending for their normal tone on absence of constricting influ-

impulse on coughing or straining and the enlargement can not be reduced by taxis. An ovary in the inguinal canal is very sensitive to pressure, and swells and is painful at the time of menstruation. A cyst of Bartholin's gland will present fluctuation, and enlarged inguinal glands are generally separate glands, *i.e.*, they are multiple tumors and are situated to the outside of the inguinal canal.

Hydrocele of the Round Ligament or of the Canal of Nuck.—In the fetus the peritoneal covering of the round ligament projects as a tubular process into the inguinal canal. This tube is called the Canal of Nuck and it sometimes persists through life. If fluid collects in this canal and the abdominal end of the canal is obliterated there is found a cystic, translucent, oval tumor which may extend downward even into the labium majus. In size the tumor may be as large as a hazelnut or even attain the proportions of a cocoanut. It can not be pushed up into the abdomen, it fluctuates, and has an impulse on coughing if situated in the inguinal canal. In rare cases the cystic tumor may communicate with the peritoneal cavity and in this event the fluid may be forced out of it by gentle pressure. Hydrocele is not tender like an ovarian hernia; it is of gradual development and often there is difficulty in distinguishing a hydrocele from hernia. In the case of encysted hydrocele the elastic, translucent character of the tumor that can not be reduced with the patient recumbent, serves to distinguish it. The hydrocele that connects with the peritoneal cavity can not be differentiated from hernia without an operation. In the case of an inflamed hydrocele the differentiation from a strangulated hernia is made by the absence of severe constitutional symptoms, and of symptoms of intestinal obstruction. As a matter of fact such tumors have generally been operated on for strangulated hernia.

THE UTERO-SACRAL LIGAMENTS

The utero-sacral ligaments contain, besides connective tissue and peritoneum, as do the round ligaments, a certain amount of muscle fibers. When the uterus is drawn down forcibly there is elasticity enough in the ligaments to pull the uterus back again. The ligaments are much overstretched in prolapse of the uterus and are abnormally short in retroposition with ante flexion, in the latter case being almost of a cicatricial hardness. Naturally liga-

of bladder, urethra, and rectum—also the ovaries and tubes—and the amount of prolapse and the condition of the vagina. In most cases of prolapse the vagina becomes thickened to a marked degree and takes on the characteristic of skin, and ulceration may develop in its structures. These items are to be noted carefully because upon them depends the form of treatment employed and its success.

A conjoined recto-abdominal examination determines the situation of the fundus uteri. A sound passed into the uterine cavity shows its depth, size, and shape, and whether or not any polypi are situated there. The cleansed sound passed into the urethra shows the direction of the canal and whether any portion of it is dislocated downward and, if so, how much. It also shows the limits of the bladder in the prolapsed mass by noting the situation of the point of the sound on the vagina both by sight and touch. (See high light in Fig. 89, marking tip of sound in bladder.) A finger hooked through the anus shows whether the rectum has been dislocated downward. It may be possible to palpate the whole of the uterus outside the vulva through the walls of the inverted vagina, but in most cases, for the purposes of diagnosis, it is best to reduce the prolapse. This is done by covering it with mucolubricans and making gentle upward pressure, at the same time squeezing the mass a little, and in some cases it may be necessary to place the patient in the knee-chest position before resorting to this measure. When the mass has been reduced a bimanual examination is made with the patient in the dorsal position and the size and shape of the uterus mapped out anew. It is now possible to determine true hypertrophic elongation of the lower segment of the uterus, fibroid nodules, the location of the ovaries, etc. If the vaginal walls are much thickened the tactile sense of the examiner's finger will be blunted. In this event a recto-abdominal examination will prove to be more satisfactory.

Differential Diagnosis of Prolapse.—An *inverted uterus* may be mistaken for a prolapse. The absence of a distinct ring having a sharp edge completely surrounding the prolapsed mass, and the fact that at no point can a sound be passed into the tumor, serve to distinguish the two. If the abdominal walls happen to be extremely thin a cup-shaped depression in the abdominal aspect of an inverted uterus may be made out by bimanual touch.

True hypertrophic elongation of the lower uterine segment (Fig. 88a) has been spoken of as a part of prolapse. It is diagnosed by distinguishing unusual length of the lower part of the uterus by bimanual touch, by finding a fundus placed relatively high in the pelvis, and increased length of the cervical canal, as disclosed by measuring the sound passed only to the internal os,—the point where the tip meets an obstruction. When the patient is placed in the knee-chest position the cervix is not obliterated, as under normal conditions. True hypertrophic elongation occurs only in sterile women; false hypertrophic elongation, occurring in the parous, is described in the chapter on laceration of the cervix, page 209.

A pedunculated fibroid or polypus is sometimes mistaken for a prolapse. In this case a sound can be swept about in the uterine cavity at any point in the circumference of the collar of the cervix except at the side where the polypus is attached to the uterine wall. There is no cavity in the polypus, and recto-abdominal touch reveals the presence of the fundus uteri in its normal position.

3. ANTEROPOSITION

Anteroposition of the uterus, or a uterus placed as a whole too near the symphysis pubis, is due to retro-uterine tumors, such as a pelvic hematocoele, dermoid ovarian tumor, or tumor of the rectum, or even an overloaded rectum. As far as we know, this position of the uterus is of no significance from a pathological or clinical point of view. The diagnosis is established by the bimanual touch; noting that the uterus is not in its normal situation but close against the pubic arch.

4. LATEROPOSITION

The uterus may be displaced to the right side or to the left side by a tumor or an inflammatory mass, the uterus being pushed to the opposite side of the pelvis to that occupied by the tumor mass. Cicatricial contraction following an effusion in one broad ligament may draw the uterus to that side of the pelvis. Such a malposition is to be noted for the purpose of removing its cause and has significance only because of the pathological condition producing it.

Varicocele of the Broad Ligament.—This is not a very rare disease. It consists of dilated veins running transversely in the upper part of the broad ligament and forming a tumor that may be as large as a small hen's egg, though generally much smaller. Varicocele is found more often on the left side. Perhaps this is because the left ovarian vein is valveless and opens into the renal vein at a right angle. It is possible to make a diagnosis by recto-abdominal palpation by finding a doughy-feeling tumor in the broad ligament, but as such a tumor is not tense except when the patient is in the erect posture, the diagnostician would be likely to miss it during the usual examination made with the patient in the dorsal position. If there are varicosities elsewhere in the body varicocele of the broad ligament should come into the physician's mind and he should examine the patient in the standing position. The characteristic symptom of varicocele of the broad ligament is a dull aching pain in the pelvis or back.

THE ROUND LIGAMENTS

The round ligaments vary much in size and in length in different individuals, therefore their ability to steady the uterus as guys is a variable quantity. The muscular fibers are situated in the inner two-thirds of the ligament and sometimes the ligaments are nothing but the slenderest of cords. Fibroma, fibromyoma, adenomyoma, fibromyxoma, and sarcoma of the round ligament have been described. The tumor is generally unilateral but may be bilateral. These tumors are thought by some writers to be associated with fibroids of the uterus. They may be found in any portion of the course of the ligament,—in the abdominal cavity, the inguinal canal, or in the labium majus,—and they develop slowly, but may be stimulated to more rapid growth by the presence of pregnancy. The tumors are hard and generally pedunculated.

Diagnosis of Tumors of the Round Ligament.—If a tumor is situated within the peritoneal cavity it is felt by bimanual palpation in the front of the pelvis on one side. If it is in the inguinal canal or labium majus the tumor is felt from the outside in the course of the canal or in the labium. It must be differentiated from omental or ovarian hernia, hydrocele of the round ligament, a cyst of Bartholin's gland, or enlarged inguinal lymphatic glands. There is no

them. The injuries must be followed carefully to their limits, whether they be confined to the cervix, or if they extend to the vagina, or even to the rectum or the bladder.

(b) **Old Lacerations.**—If every woman were submitted to a careful uterine examination after child-bearing, and injuries of the cervix, as well as those of the pelvic floor, found and repaired, there would be comparatively little for the gynecologist to do. It happens, however, that most of the lacerations of the cervix come under the physician's notice for the first time some years after their receipt. At this time the diagnosis is difficult because of enlargement and distortion of the cervix, eversion of the lips, and cystic degeneration of the Nabothian follicles and erosion. The trained vaginal touch after a little practice detects all of these features even to the erosion. For inspection the Sims position is best. Search first for the arbor vitæ and thus determine the situation of the cervical canal. The passage of the sound helps to define the situation of this canal, but the physician must be on his guard not to be misled by the malpositions of the uterus found in cases of unilateral tear as pointed out by Emmet. (See Fig. S3.) In this event the sound passed to the

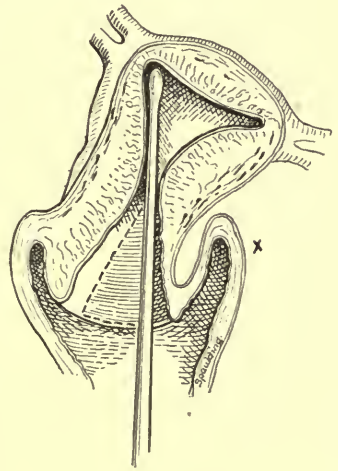


FIG. S3.—Unilateral Lacerations of the Cervix, Producing Obliquity of the Long Axis of the Uterus. (After Emmet.) The Reduplication of the Vagina is shown at W.

cornu opposite to the seat of the laceration may appear to be in the canal (see figure), but because of the tilting of the fundus toward the laceration the sound occupies the laceration and not the normal cervical canal. Here a search for the arbor vitæ will help to set us right and the bimanual touch will also assist. Putting the patient in the knee-chest position, thus permitting the uterus to fall toward the abdomen high in the pelvis, straightens its axis and also pulls out the reduplication of the vagina on the side where the laceration is situated. In all lacerations of severe grade it is well to study the conditions as seen through the specu-

with the addition, in the case of retroposition with ante flexion, of adhesions limiting the mobility of the uterus.

Anteflexion may be acquired, however, as in the case of a uterus with softened tissues having a fibroid in the anterior wall of the fundus. Excessive straining at stool tends to bend the cervix forward and at the same time to fold the fundus and body of the uterus forward and downward, provided the forward excursion of the region of the internal os is limited. Thus a flexed uterus becomes more flexed. The uterine canal is obstructed mechanically at the internal os by excessive flexure, therefore we should expect these patients to suffer with blood stasis and endometritis, the results of a damming up and decomposition of the uterine discharges, and this is usually the case.

Vesical symptoms are due to the backward traction of the cervix on the vesical neck and to the interference offered by the forward flexed fundus uteri to the filling of the bladder. Of the two the former is the more important cause.

I have previously called attention to the frequency of retroposition with ante flexion ("Division of the Utero-Sacral Ligaments and Suspensio Uteri for Immobile Retroposition with Anteflexion," *Amer. Gyn. and Obstet. Jour.*, Jan., 1898, and "Further Experience with the Operative Treatment of Anteflexion," *Amer. Gyn. and Obstet. Jour.*, Jan., 1900). The condition has not been recognized generally by the profession, having been classed broadly as retroversion.

Diagnosis of Retroposition with Anteflexion.—The diagnosis is made by finding the uterus as a whole in the extreme back part of the pelvis. This is done by practising the bimanual vaginal-abdominal or recto-abdominal touch. The cervix is in the axis of the vagina, the anterior lip is flattened and short, the crown of the cervix being in extreme cases practically continuous with the front wall of the vagina. The cervix, in the axis of the vagina, is not so long, as a rule, as in the case of the puerile cervix, but it is long as compared with the fundus, representing two-thirds of the entire length of the uterus. Its tissues are generally indurated and more or less tender; there is a cervical discharge from a pin-hole os. The fundus is flexed forward and may be grasped between the forefinger in the vagina and the fingers of the hand on the abdomen. It may be enlarged or it may not, and tenderness

on pressure and induration are not necessarily present. Shortened utero-sacral ligaments or extraligamentous adhesions—these latter rarely present—limit the forward excursion of the uterus as determined by making forward traction with the examining hands. Rigidity of the tissues at the angle of flexion is determined by manipulating the uterus. Downward pressure on the fundus by the hand on the abdomen moves the cervix backward, and upward pressure on the fundus by the finger in the vagina moves the cervix forward. It is impossible to change the relation of cervix and fundus to each other by separating two fingers placed between them in the vagina.

As a rule it is not necessary to pass the sound in order to verify the diagnosis. In fat women, however, with thick and rigid abdominal walls, this procedure may be necessary. Select a flexible sound of small caliber. This is better and safer than a probe, the tip of which will catch in pockets of the lining mucous membrane. Bend the sound so that it corresponds to the bent uterine canal as determined by palpation; fix the cervix with a tenaculum and make gentle traction, thus straightening the uterine canal as much as possible. Pass the sound tentatively, withdraw and rebend, until the tip will slip through the internal os. Note the point of sensitiveness in the uterine canal, if any, the distance of the internal os from the external os, and the total depth of the uterine cavity. Note thus the relation that the length of the cervical canal bears to the length of the uterine cavity proper; also consider the tightness of the internal os, the capacity of the uterine cavity, and the amount and character of the discharge. If blood follows the gentle passing of the sound and tenderness is present, one may diagnose endometritis.

6. HERNIA OF THE UTERUS

Hernia of the uterus through the inguinal or the crural canal is a rare anomaly. The diagnosis is established by determining the absence of the uterus from its normal situation and its presence in the hernial sac. The latter is a most difficult matter and most of these cases have been operated on for strangulated hernia, when the diagnosis was made. Congestion or tumefaction of the hernial tumor containing a uterus should be looked for at the time of

chronic distention of the urinary bladder, chronic fulness of the rectum, sudden jar, etc. (see Retroversion, page 234). When once the axis has been changed, the intra-abdominal pressure is exerted against the anterior face of the uterus and the broad ligaments, and increased pressure accentuates the retroversion, and at the same time pushes down the uterus, now in the same axis as the vagina. Factors which make for greater downward pressure, such as a persistent cough or violent straining because of chronic

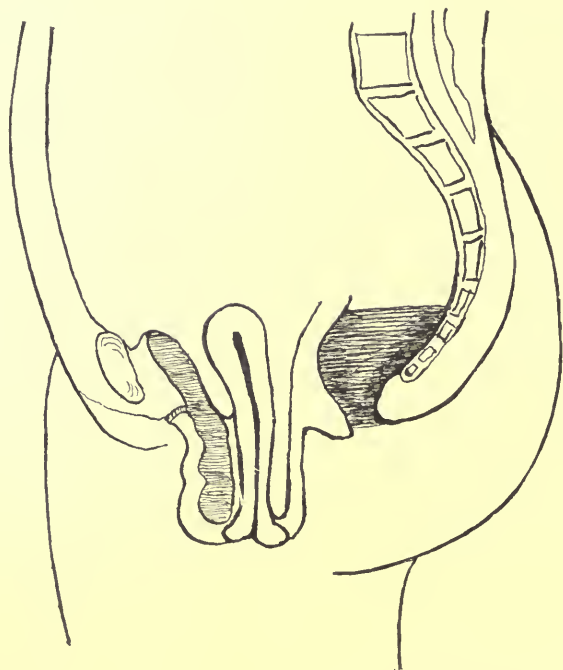


FIG. 88.—Prolapse of the Vagina and Cervix, with Elongation of the Supravaginal Cervix.

diarrhea, tend to cause descensus uteri. Constant straining is an important factor in the causation of prolapse; therefore prolapse is found most frequently among women of the working classes. These women are apt to get up and begin work soon after confinement when the uterus is large and heavy and retroverted.

Inversion of the vagina may take place without actual descent of the uterus because of the elasticity of the vagina, and, prolapse may be simulated by elongation of the lower uterine segment.

the uterus, therefore the round ligaments can not support the uterus except in cases of extreme prolapse. On the other hand, the attachments of the utero-sacral ligaments to the pelvic wall near the second piece of the sacrum are a trifle higher than their insertions into the uterus at the level of the internal os. They are normally firm and strong and act as true supports.

The broad ligaments check lateral motion and limit the uterine

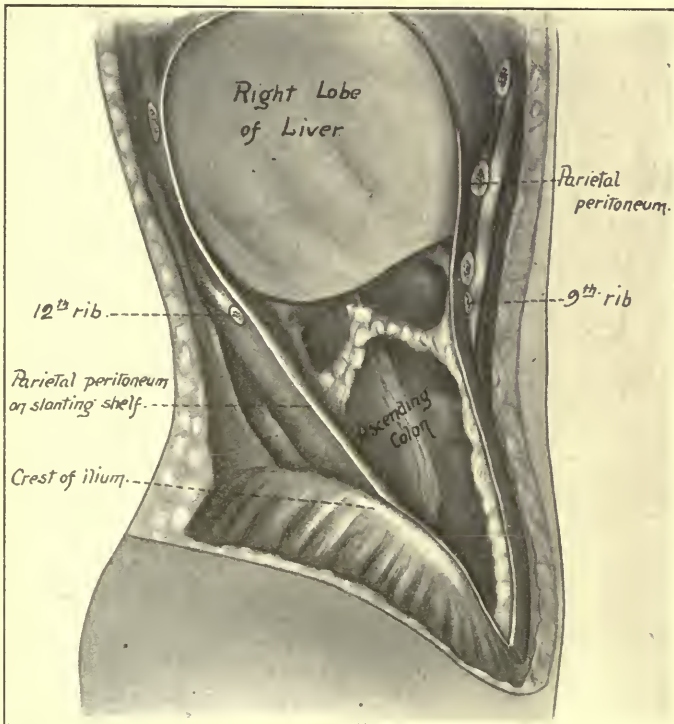


FIG. 86.—Right Side of Abdominal Wall Has Been Removed, Showing Funnel Shape of Abdominal Cavity, which Is Wide Above and Narrow Below, also the Slanting Shelf which Gives Partial Support to the Viscera. (After Corning.)

movements largely to forward and backward excursions. The intra-abdominal pressure is exerted on the posterior aspect of their broad surfaces and thereby they assist either in retaining the uterus in anteversion, or, if the axis of the uterus has been changed from anteversion to retroversion, the pressure being on their posterior aspects, they assist in keeping the womb in that position and in aiding prolapse. The thick bases of the broad ligaments

ried women. Possibly habitual constipation and overdistention of the bladder and faulty posture may have something to do with it. The symptoms of retroversio-flexion are not distinctive and there may be no symptoms. If present, they are: a sense of weight in the pelvis or bearing-down feeling, irregularities of menstruation, uterine catarrh, constipation, frequency of micturition, and abortion and sterility. In the case of retroflexion, if pregnancy occurs in the retroflexed fundus there is less likelihood of spontaneous reposition than in retroversion, and therefore abortion is more likely to occur. The bladder and rectal symptoms are apt to be more pronounced in retroflexion than in retroversion because in the former there is more dragging on the neck of the bladder and a sensitive fundus impinges more directly upon the lower rectum. The degree of retroversion is a variable quantity. Formerly it was customary to define the amount of tipping of the uterine axis with great exactness and the retroversion was said to be in the first, second, or third degree, according as it was tipped backward so that its long axis pointed, respectively, at the promontory of the sacrum, in the axis of the vagina, or it exceeded the last amount of tilting. Now we consider the old first degree to be within normal limits. It is well, however, to preserve these distinctions for purposes of description.

Diagnosis of Retroversio-flexion.—The bimanual touch shows the fundus to be absent from its normal situation and the cervix in the axis of the vagina. If the abdominal walls are thin and relaxed it is possible often to palpate the fundus bimanually, even though it is retroflexed. In less favorable cases the hand on the abdomen determines the absence of the fundus in its normal position. The finger in the vagina notes a sense of resistance in the cul-de-sac, or in the case of retroflexion, a rounded body in that situation. Rectal touch is of great assistance in the diagnosis of both retroversion and retroflexion, for by the rectum the examiner's finger can reach a higher point in the pelvis than by the vagina. One of the most important facts to determine is the mobility of the uterus; therefore attempt to dislodge it. To do this, make an upward pressure on the fundus by the left forefinger—protected by a cot—in the rectum while the cervix is pushed backward by the right forefinger in the vagina, the patient being in Sims position. If this is unsuccessful, hook a tenaculum into the cervix and make down-

ward traction while the rectal finger pushes the fundus up. If the fundus has been displaced from the hollow of the sacrum by these manipulations the tenaculum is removed from the cervix, the left forefinger—the cot having been removed—is transferred to the vagina, the right hand is passed between the patient's thighs to the abdomen and the uterus rocked into place by the bimanual touch. The knee-chest position and traction on the cervix with a tenaculum will often accomplish the reposition of an obstinate retroversion or an incarcerated pregnant fundus. Sometimes the displaced fundus is held between the utero-sacral ligaments. When the uterus is raised in the pelvis these ligaments are relaxed and the fundus may be pushed up through them. In some cases, especially in virgins with tense, well-developed abdominal walls, nothing short of an anesthetic will permit reposition of a retroflexed uterus even though free from adhesions. During the manipulation the physician gains a knowledge, through his sense of touch, of the other pelvic organs. He detects salpingitis or thickenings denoting adhesions. He notes points of tenderness, and these warn him against vigorous attempts at reposition. When the Peaslee rigid uterine sound was first invented it was customary for the practitioner of that day to pass it into the uterine cavity and forcibly pry the uterus into place, and the trauma, together with the lack of asepsis which prevailed at that time, produced most disastrous results in the form of acute pelvic inflammation, salpingitis, or even pelvic abscess.

Suppose the fundus has been freed from its abnormal position, the next procedure is to hold the cervix backward while you reach for the fundus with the fingers of the right hand on the abdomen, working them behind it by gradual and repeated pressure as the patient takes deep inspirations. Backward pressure on the cervix and forward rocking on the fundus restore the uterus to its normal position. The bimanual touch practiced in the Sims position is most useful for this procedure. Always be sure that the bladder is empty before beginning the manipulations. If the uterus comes up do the ovaries also assume a normal position? Note their size as well as their mobility. In exceptional cases the aseptic sound may be passed to confirm a diagnosis, especially in cases of retroflexion. Here it is generally necessary to pass a sound to differentiate from a fibroid in the posterior uterine wall. It is necessary

tion and running almost transversely from the cervix to the hymen, now becomes a straighter open tube, leading almost directly downward from the cervix to the introitus.

The pelvic floor, according to Hart and Barbour, may be divided up into an anterior and a posterior segment. The anterior segment is a relatively movable one, the posterior is relatively fixed. The anterior or pubic segment consists of anterior vaginal wall, urethra, and bladder, all attached loosely to the symphysis pubis by retropubic deposits of fat. The posterior or sacral segment is made up of posterior vaginal wall, the muscles and fasciæ of the perineum, and the rectum, all firmly bound to the sacrum and coccyx. During labor the anterior segment is drawn up; the posterior segment is driven down. In the formation of prolapse the anterior segment, because of the injury of the posterior segment, swings downward and backward—the retropubic fat giving way with consequent dislocation of bladder and urethra. It is plain that a tipping back of the uterus on its axis, so that it may get into the same axis as the vagina, is a requisite to the descent of that organ, and that this tipping backward is made possible by injury of the posterior segment of the pelvic floor and dislocation of the anterior segment, so that the cervix—not stayed from behind and having no firm tissue in front of it—swings forward until its long axis coincides with the long axis of the vagina. This subject will be made clearer when we consider the different directions in which under varying conditions the intra-abdominal pressure is applied to the fundus uteri.

(b) The uterine ligaments and the attachments of the uterus to the surrounding structures.

The ligaments, described in Chapter V, page 44, consist of three pairs of ligaments proper—the broad, the round, and the utero-sacral; and the attachments are—the utero-vesical connective tissue, the vagina, and the retro-uterine cellular tissue. In considering the causation of prolapse we must think of the woman being in the erect position, because it is in this attitude that the great strain is brought to bear that causes sacro-pubic hernia. By reference to the diagram (Fig. 84) on page 216 it will be seen that the origins and insertions of all the ligaments lie in nearly the same plane. As a matter of fact, the pubic ends of the round ligaments are a little lower than their insertions into the horns of

ences in the way of pressure from tumors or pelvic inflammatory masses, or stretching due to malposition of the uterus.

We know how much a prolapsed uterus is reduced in size after it has been replaced in a normal position in the pelvis and maintained there for a few hours even. We know that a normal uterus, displaced downward mechanically, becomes congested. It is fair to assume that this is due to a straightening of the tortuous valve-

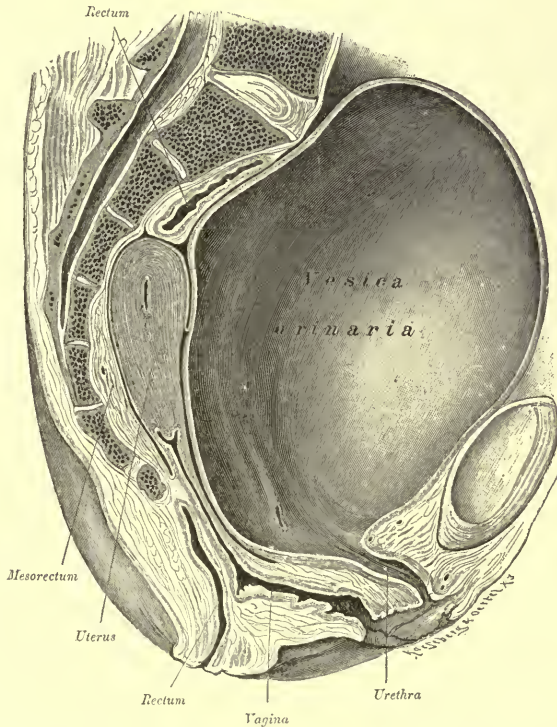


FIG. 84a.—Longitudinal Median Section of a Pelvis with Overdistended bladder. (Zuckerkindl.) Note Retroversion of Uterus.

less veins, thus lessening the resistance of their walls to an increased pressure delivered by the less convoluted arteries.

It is the view of the author that uterine malpositions have a direct mechanical effect on the pelvic circulation, therefore displacements of the uterus as a whole are of more importance than changes in the axis (version), or changes in form (flexions, torsions, or tumors).

3. ANTEFLEXION

Anteflexion has been described at length under Retroposition with Anteflexion. It is to be understood that this malformation of the uterus does occur without the posterior malposition. What has been said of the combined disorder applies equally to the flexion alone.

4. INVERSION

Inversion of the uterus is a partial or complete turning of the organ inside out. It is of three sorts: (1) acute puerperal inversion, (2) chronic puerperal inversion, and (3) inversion caused by uterine tumors. The first sort concerns the obstetrician. The second is the more usual of the remaining two forms that are seen by the gynecologist.

Puerperal inversion is due to relaxation of the uterine muscles at the time of the delivery of the placenta. Coughing or sneezing may invert a relaxed uterus; too much traction on the cord and an adherent placenta are the direct causes in some cases. The uninverted part of the uterine wall may seize the inverted part so that the uterus looks like the bottom of a wine bottle, and the contraction of the unrelaxed portion may continue to push the fundus downward until the uterus is completely inverted. The process may start in the lower uterine segment, which is inverted first, and is followed by the fundus. The tubes follow necessarily into the cup of the inverted fundus and sometimes also loops of intestines, but these structures are seldom adherent. The everted mucosa of the uterine cavity is dark red and bleeds easily, and in cases of long standing inversion it shows regions of ecchymosis and ulceration. Cases have been reported where there were adhesions between the partially inverted fundus and the cervix. If inversion is due to downward traction on the uterine wall by a submucous fibroid there is apt to be present a foul uterine discharge, for the fibroid is generally in a state of necrosis. The usual symptoms of chronic inversion are: pelvic pain, hemorrhage, leucorrhœa, frequency of micturition and dysuria, and difficulty in walking and standing.

Diagnosis of Inversion.—In favorable cases where the abdominal walls are relaxed and the patient is not fat, the bimanual touch will

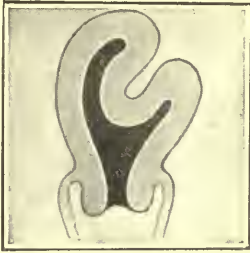

FIG. 94.—Partial Inversion of the Left Horn of the Uterus.

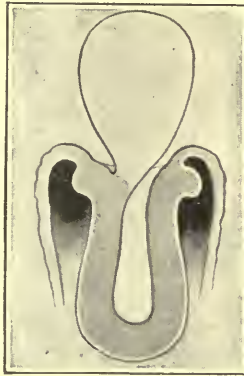

FIG. 100.—Complete Inversion Complicated by a Subperitoneal Fibroid which Resembles the Uterus.



FIG. 95.—Pedunculated Submucous Fibroid Simulating Partial Inversion.

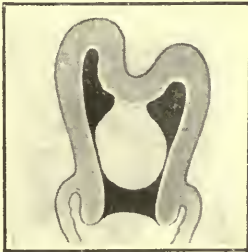

FIG. 96.—Partial Inversion Complicated by and Caused by a Submucous Fibroid.

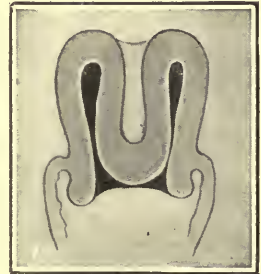

FIG. 97.—Partial Inversion.

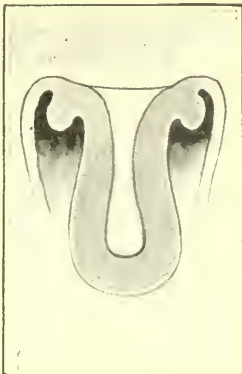

FIG. 98.—Complete Inversion.

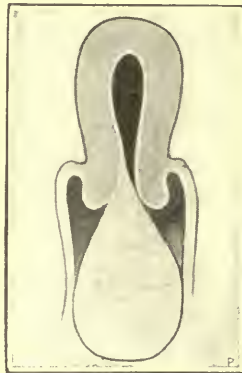

FIG. 101.—Submucous Fibroid Filling the Vagina with Normally Situated Uterus Above Simulating Condition in last Figure.

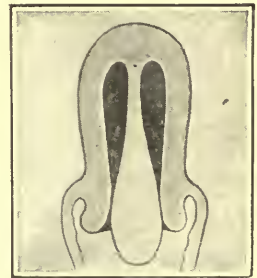

FIG. 99.—Pedunculated Submucous Fibroid Projecting from the External Os, Resembling an Inverted Uterus.

show the absence of the uterus in its customary situation. Rectal touch is of great use, also the recto-abdominal touch, and the rectal touch with a sound in the bladder. In extremely favorable cases the depression of the inverted cup may be made out by the abdominal hand. By vagina the partial or completely inverted uterus is felt and seen, and occasionally the orifices of the Fallopian tubes can be demonstrated in the inverted fundus. The ring of the cervix can be felt by the finger swept about the inverted fundus. The difficult point in diagnosis is to differentiate complete inversion from submucous myoma.

By reference to the figures on page 241, it will be seen that a myoma may spring from the fundus, body, or cervix. It may be sessile, or have a short pedicle or a long one. Fig. 100 shows an unusual condition: a pedunculated subperitoneal fibroid attached to the cervical region—the uterus being in a state of complete inversion—and the fibroid tumor presents to the examiner's touch the size and shape of a uterus in a normal situation. In such a case it would be extremely difficult to tell the uterus from the tumor. Detection of the orifices of the Fallopian tubes and also the ring of the cervix would be the distinguishing features. Complete prolapse can be differentiated from an inversion by finding in the prolapse the external os uteri; the extruded mass is wider above and narrower below; and the vagina is everted to a greater or less degree, as shown by the fact that the point of a sound introduced into the bladder can be felt in the hernia. In the case of inversion, on the other hand, there is no external os, the orifices of the tubes may be seen, and a sound in the bladder goes upward, except very rarely when the vagina also is inverted.

Differential Diagnosis of Inversion.—The following is a tabulated statement of the differential diagnosis between complete inversion and pedunculated fibroid in the vagina, and incomplete inversion and intra-uterine submucous fibroid.

Complete Inversion.

1. Sweeping finger and sound about tumor shows it to have no point of attachment.

2. Sound will enter ring of cervix but a short distance.

Pedunculated Fibroid in Vagina.

1. Tumor is attached at one point by a broader or narrower attachment. Verify location and size of attachment by the sound.

2. Sound goes to fundus a distance of $2\frac{1}{2}$ inches (six centimeters), at least.

*Complete Inversion.**(continued)*

3. Uterus absent in abdomen to bimanual examination.
4. Hernia mass is symmetrical, larger below and narrower above.
5. Orifices of the Fallopian tubes are often demonstrable.

Incomplete Inversion.

1. Uterine cavity is shallow as measured by sound.
2. Cup-shaped depression in uterus felt bimanually.
3. Symptoms date from parturition.

*Pedunculated Fibroid in Vagina.**(continued)*

3. Uterus present in abdomen.
4. Mass may be asymmetrical.
5. No orifices of the Fallopian tubes.

Intra-Uterine Submucous Fibroid.

1. Cavity deep.
2. No cup-shaped depression.
3. Symptoms do not date from parturition.

5. TORSION OF THE UTERUS

Torsion, or twisting of the uterus on its own long axis, may be complete or it may be partial. In the former the entire uterus is twisted to one side or the other, generally not more than half a turn, as in the cases of anteflexion or retroflexion where one utero-sacral ligament is shortened. In the case of tumors growing from one side of the pelvis, however, the uterus may be twisted several times on its own axis. Torsion of the uterus occurring with a fibroid of subserous evolution, or an ovarian tumor having a short pedicle, is generally partial. The cervix uteri, being steadied by the insertions of the broad ligaments, is not so apt to participate in the twist and the uterus is twisted on itself, the fundus and body alone taking part in the twist.

Torsion is especially apt to be found in the case of double uterus or uterus bicornis.

The diagnosis is made by determining by the bimanual touch the position of the ovaries and also the situation and direction of the transverse axis of the fundus with reference to the cervix. In the event of complete torsion of the uterus the transverse axis of the external os may be seen through the vaginal speculum to be turned away from the normal.

CHAPTER XV

THE DIAGNOSIS OF FIBROID TUMORS OF THE UTERUS

Definition, p. 244. Pathology, p. 244. Classification, p. 245. Situation, p. 248. Frequency, p. 248. Etiology, p. 250. Course and Development, p. 251. Degenerations, p. 252. Complications, p. 255. Effect on neighboring organs, p. 257. Effect on distant organs, and on the system, p. 258. Relation of fibroid tumors to heart disease, p. 259. Dangerous to life, p. 260. Symptoms, p. 260. Symptoms of adenomyoma, p. 262. Diagnosis and differential diagnosis, p. 262. Subserous fibroids, p. 262. Intraligamentous fibroids, p. 263. Interstitial fibroids, p. 263. Submucous fibroids, p. 264.

DEFINITION

FIBROID tumor, also called myoma, fibromyoma or fibroma of the uterus, is a nodular growth developing from some portion of the uterus, usually, but not always, above the cervix, varying in size from a minute speck to a mass or masses filling the pelvic and abdominal cavities.

PATHOLOGY

The largest fibroid which I have found recorded was one removed at autopsy from a single woman fifty-three years of age by S. H. Hunt of Long Branch, N. J. (*Amer. Jour. Obstet.*, 1888, XXI., p. 62.) It weighed one hundred and forty pounds and the cadaver after the removal of the tumor weighed ninety-five pounds.

The tumors are generally round in shape, with smooth surface, but may be pear-shaped, kidney-shaped, mulberry-shaped; may be molds of the pelvic cavity, or, very rarely, may resemble a fetus. They are single or multiple, as many as one hundred and fifty tumors having been found in the uterus by Bland-Sutton. (*Brit. Med. Jour.*, April 6, 1901.) They are of a hard consistence, though a predominance of muscular tissue in their structure, or degenerative changes, may render them softer. They are classed

as benign tumors because they do not "eat up" the surrounding tissues by extending into their substance, and they do not cause destruction by metastases. They are composed of the same tissues as the uterus, namely, unstriped muscle fibers and connective tissue. On section a fibroid tumor is of a glistening white, or whitish-yellow color and is seen to be made up of a disorderly intertwining of muscular and connective-tissue fibers. In the larger masses, however, these are grouped in more or less well-defined whorls (see Fig. 106) which somewhat resemble knots in a piece of wood. Between the groups of fibers run arteries, veins, and lymph channels derived from the normal vessels of the uterus, ramifying at first beneath the capsule of the tumor and then plunging directly into its interior. As a rule these tumors are poorly nourished because they derive their blood from the surrounding constricted uterine tissue. Occasionally they are supplied by large vessels through adhesions to surrounding organs.

CLASSIFICATION

Fibroid tumors may be classified according to their situation with reference to the uterus. They are—

1. Subserous,
 - (a) Intraligamentous.
 - (b) Tumors of the cervix.
2. Interstitial.
3. Submucous.

They are described further by defining their number and size, and by noting any special kind, as adenomyoma. For instance, in Fig. 102 we see a specimen of a multiple fibroid uterus: an interstitial fibroid of the anterior uterine wall, a subserous fibroid springing from the fundus uteri, and an interstitial tumor of the posterior wall. All fibroids originate in the uterine muscle, therefore all are interstitial in the beginning. If the tumor develops in the outer wall of the uterus and grows from the uterus under the peritoneum, it is called an adenomyoma.

Adenomyoma is a special variety of myoma characterized by the presence of glands similar to those found in the uterine mucosa. Thomas S. Cullen ("Adenomyoma of the Uterus," 1908) found

73 cases of adenomyoma among 1283 cases of myoma examined microscopically in the Johns Hopkins Hospital Surgical-Pathological Laboratory during thirteen years, or 5.7 per cent of all fibroids. These tumors are diffuse and may or may not be definitely encapsulated.

1. **Subserous Fibroid Tumor.**—Such tumors have the greater part of their periphery outside the uterine wall and have no considerable covering of uterine tissue. (See Fig. 102, upper tumor.) The

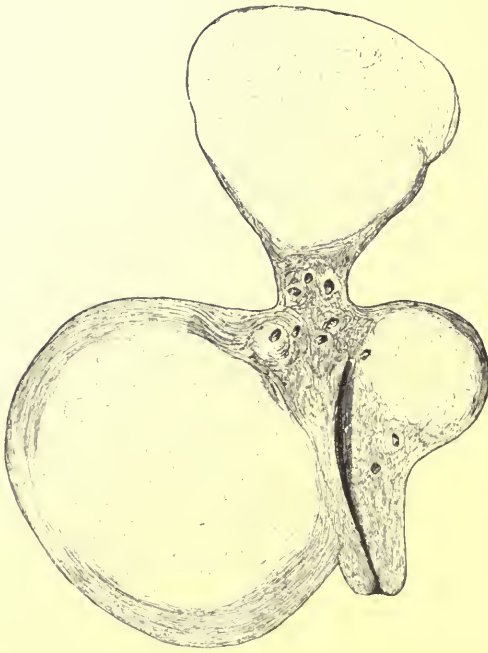


FIG. 102.—Multiple Fibroids, One Subserous and Two Interstitial. (Winter.)

greater the size of the subserous tumor the more it is separated from the uterus, as a rule. It may be relatively small or large. If, instead of developing under the serosa, the tumor separates the folds of the broad ligament and distorts the viscera to a greater or less degree, it is called an

(a) *Intraligamentous Fibroid Tumor.* (See Fig. 105.)—These tumors have the greater part of their circumference outside the uterus and are not covered by uterine tissue. Noble ("Gynecology and Abdominal Surgery," H. A. Kelly and C. P. Noble, 1907, p. 669)

found this form of tumor in 3.5 per cent of the 2,274 cases of fibroid tumor he studied. The same characteristics belong to

(b) *Tumors which originate in the lower posterior segment of the uterus and grow into the cervix and then into the posterior pelvis, or those rare tumors which originate in the cervix itself and develop away from the uterus.* (See Fig. 108.) The cervix, to be sure, has no covering of peritoneum. As the tumor increases in size and rises in the pelvis it pushes the peritoneum before it. Therefore, this class of tumors may be included among the sub-

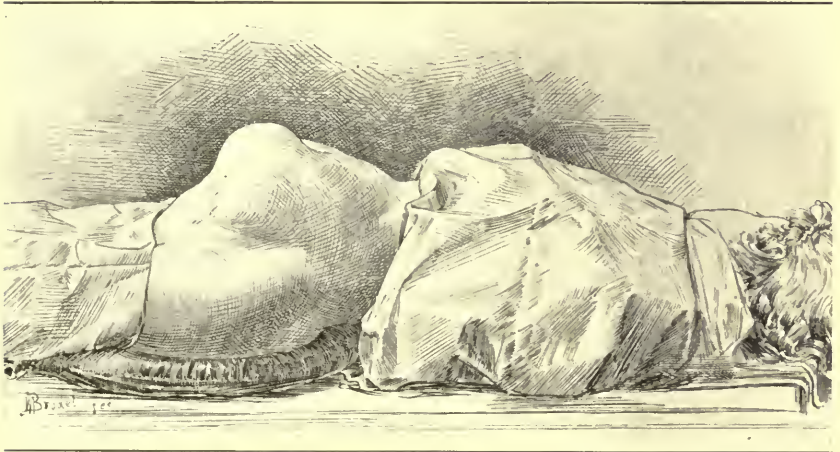

FIG. 103.—Large Multinodular Subperitoneal Fibroid with Thin Abdominal Walls. Seen in Profile. (Kelly.)

serous. In subserous fibroids the uterine cavity is altered little if at all in length or shape.

2. **Interstitial (intramural, intraparietal) fibroid tumors** are those which are situated in the wall of the uterus and are surrounded by a covering of uterine musculature. (See Figs. 102 and 104.) They may or they may not alter the contour of the uterus. The uterine cavity is almost always lengthened, and it may be broadened and made asymmetrical in shape by this form of tumor.

3. **Submucous Fibroid Tumors.**—These are the tumors which develop into the uterine cavity and are covered with mucous membrane and with little, if any, of the uterine musculature. (See Figs. 104 and 106.) Of all the three varieties these cause the greatest changes in the form of the uterine cavity. These are

the bleeding fibroids. The pressure exerted by the tumor on the nervous mechanism of the uterus sets up reflex uterine contractions producing a gradual delivery of the tumor. At first the tumor becomes pedunculated; then the pedicle is elongated until the internal os has been dilated. Finally, in favorable cases, the tumor is delivered. More often necrosis of the tumor sets in before the delivery is accomplished, and we have a *Sloughing Fibroid*.

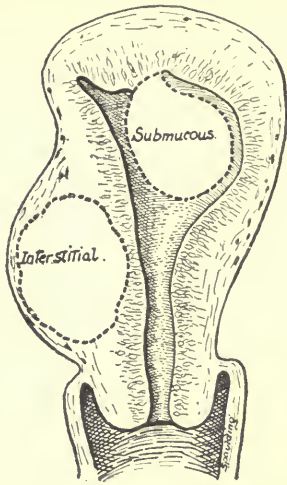


FIG. 104.—Interstitial and Submucous Fibroids.

A pedunculated submucous fibroid, if of small size, is called a *fibroid polyp* (see Fig. 107), and is to be distinguished from a *mucous polyp*, one of the manifestations of glandular endometritis. In all forms of fibroids, more especially in the submucous and the interstitial, the mucous membrane of the corpus uteri may show evidences of glandular and interstitial endometritis.

Kelly and Cullen ("Myomata of the Uterus") state that the mucous membrane of the uterine cavity is generally normal, but that cervical endometritis is relatively frequent when a sloughing submucous myoma exists, otherwise it is rare even if there be present evidences of an old inflammatory process in the ovaries and tubes. Therefore they point out that the surgeon may open the uterine cavity with impunity in the absence of vaginal discharge and signs of tubal disease.

SITUATION

Fibroid tumors always originate in the substance of the uterine wall. They almost always develop in the body rather than in the neck of the uterus, and they are more commonly found in the posterior than in the anterior or lateral walls.

FREQUENCY

Fibroid tumors are the most prevalent of all neoplasms affecting the uterus. As regards their frequency among women, most

authors quote Bayle (S. H. Bayle, "Dict." en 60 vol., Paris, 1813, t. VII., p. 73) who stated as long ago as 1813 that 20 per cent of all women over thirty-five years of age have fibroids; but as other authors have arrived at different results (Klob, for instance, asserting that 40 per cent of the uteri of women who die after the fiftieth year contain fibroid tumors), and as Bayle's opinion has not been confirmed, we may state that the exact frequency of the tumors is yet to be determined. They are met with mostly during the period of sexual maturity, between the ages of thirty and fifty years, being rare before twenty and after fifty-five. Gusserow, out of 919 cases of fibroids, found only 15 under twenty years of age and only 17 over

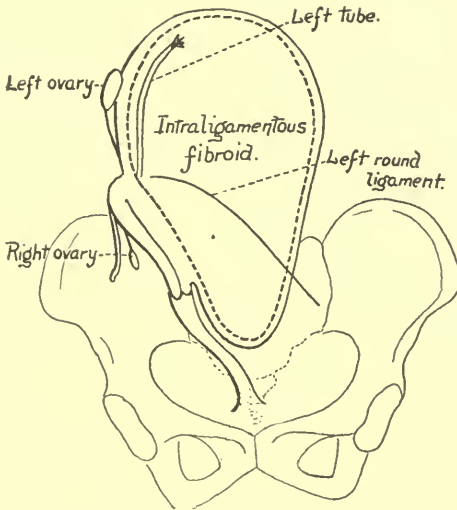


FIG. 105.—Diagram Showing an Intraligamentous Fibroid.

sixty years of age. The highest percentage, 38.8, was between the ages of thirty and forty, and the next highest, 36.7, was between forty and fifty. Fibroids are undoubtedly very frequent in the negro race. The autopsy statistics of the Johns Hopkins Hospital show, according to Kelly and Cullen ("Myomata of the Uterus," 1909), that out of 742 autopsies on white and black women, over twenty years of age, 20 per cent had fibroids in their uteri, and of these, 33.7 per cent of the black women had uterine myomata, and 10 per cent of the white women were affected in this way. It is not yet determined whether fibroids are more common among the

single than the married. Bayle and other authors thought that they were, while Gusserow, Dupuytren, West, and others, hold that they are not.

ETIOLOGY

The causation of these tumors is even now unknown, although the problem has been studied assiduously by many noted investi-

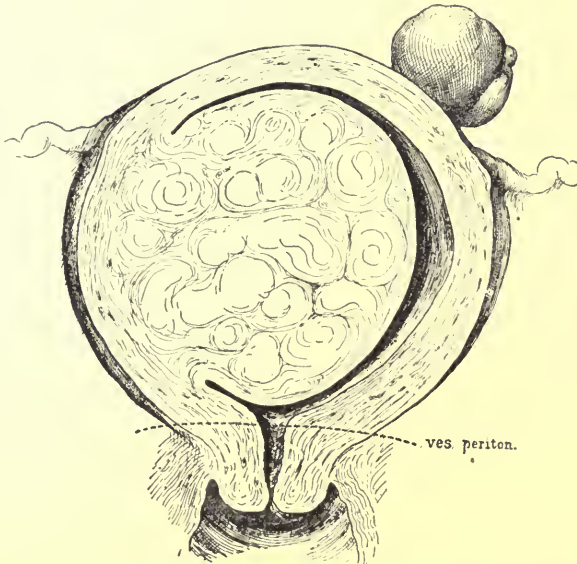


FIG. 106.—Large Submucous Fibroid showing Distortion of the Uterine Cavity. (Kelly.)

gators during the last fifty years, and many hypotheses have been advanced, but so far none has been proved correct. An ingenious theory is that advanced by A. Claisse (Thèse de Paris, 1900). He thinks they are due to infection of the uterine mucosa; subacute inflammatory lesions of the mucosa, especially about the little blood-vessels of the muscular wall, causing proliferation of round cells, which are transformed into fibrous tissue. Heredity has been supposed to play a part in the causation of fibroids; Hofmeier, Veit, Kleinwächter, and others considering it a predisposing cause. It is doubtful whether this assumption is well founded, however, and we must regard the occurrence of fibroid tumors in members

of the same family—a not uncommon happening—as coincidences rather than examples of heredity.

Sexual irritation, such as masturbation or abnormal sexual practices, has been assigned as a cause of myoma by Veit. While the chronic congestion which is due to undue irritation of the genital organs may assist the growth of a fibroid, it is difficult to see how it could originate one. It is probable that many fibroids are of congenital origin, perhaps due to a fetal misplacement of tissue according to Cohnheim's theory, but, as already stated, this has not been proved. The tumors do not attain any considerable size until the late child-bearing period; therefore age must be considered a factor in the etiology.

COURSE AND DEVELOPMENT

The development of a fibroid is a slow affair, generally a matter of years. H. A. Kelly has cited a case which was under medical observation for twenty-five years before operation and two years after. ("Operative Gynecology," 1907, Vol. II., p. 347.) A large interstitial tumor, with a uterine cavity measuring eight or nine inches, became larger and subperitoneal and pedunculated so that at operation it was found attached to a small uterus by a pedicle 1 centimeter long and 3 centimeters broad. It weighed 59 pounds.

I have spoken of the direction of the growth in describing the different kinds of tumors. Upon the course taken by the tumor in its growth depends often its subsequent fate. For instance, if it grows subserous it may become pedunculated and in time may be separated entirely from the uterus, receiving its nourishment through adhesions to surrounding structures. Such cases are rare, but are met with occasionally. If, on the other hand, the tumor grows toward the uterine cavity, it is apt to be extruded through the external os. In either case the blood supply to the tumor is interfered with and there is a tendency to necrosis and degenerative changes. If the tumor remains in the substance of the uterus, as in the case of an interstitial fibroid, its nourishment is established on a surer footing. It is possible for all tumors, and for small tumors especially, to remain in a quiescent state for an indefinite period. Bland-Sutton ("Tumours Innocent and Malignant," 4th Edition, 1906, p. 187) calls attention to the *latent seedling*

fibroids, in regard to which he says: "If a number of uteri be examined from women between the twenty-fifth and fiftieth years by the simple means of sectioning them with a knife, in a large proportion of these uteri a number of small rounded fibroids, resembling knots in wood, will appear, their whiteness being in strong contrast with the redness of the surrounding muscle tissue. These discrete bodies, in many instances no larger than mustard seeds, are in histologic structure identical with the fully grown tumours."

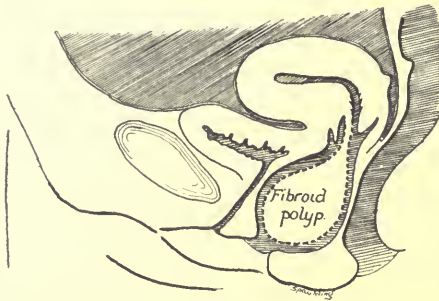


FIG. 107.—Pedunculated Fibroid Originating in the Cervix that has been Expelled into the Vagina. (After Auvad.)

When removing fibroids by operation one can never be sure that all tumors have been removed; therefore, a patient can not be assured that the fibroids will not grow. On the other hand, tumors may increase rapidly in size. Soft tumors grow faster than hard ones, as a rule. Fibroid tumors grow during pregnancy and diminish in size markedly after delivery. They increase in size just before each menstrual period and diminish after the flow has ceased. In many instances they lessen in size after the menopause, but not always. All these facts must be kept in mind when examining a patient at different times to determine the relative bulk of a tumor.

DEGENERATIONS

There are certain alterations of structure occurring in fibroids, the causes of which we do not know, except that sometimes they can be explained by the presence of arteriosclerosis and a diminished blood supply. Degenerations in fibroids are observed frequently following pregnancy. An increased formation of fibrous and hya-

line tissue occurs in practically all myomata and, when the process is extensive, necrosis of the center occurs, with a resulting cyst cavity with walls of irregular outline.

Softening of a fibroid tumor may be due to several causes. Among them we may enumerate hyaline, colloid, and fatty degeneration.

Hyaline degeneration was noted in 3.1 per cent of 2,274 cases of fibroid tumors collected by Noble from the literature ("Gynecology and Abdominal Surgery," H. A. Kelly and C. P. Noble, 1907, p. 669). Often these tumors become progressively indurated, especially after the menopause.

Colloid or Myxomatous Degeneration.—This is characterized by the effusion of mucous material between the muscle bundles, the mucin and proliferation of round cells in the interstitial tissue distinguishing it from edema. Noble found myxomatous degeneration in 3.4 per cent of his 2,274 cases.

Small, hard tumors are found at autopsies on old women, their presence not having been detected during life.

Fibro-cystic Tumors.—These tumors result from the breaking down and liquefaction of areas of degeneration in fibroids and the fusion of different foci by the absorption of the dividing partitions. The degenerated areas are separated, not by distinct walls, but by portions of the fibrous structure of the tumor. These tumors are not, as formerly thought, a separate class of tumors.

Dolérís (*Archiv. de tocologie*, janv. et fév., 1883, pp. 1 and 364), noted a proliferation of connective tissue becoming colloid in a fibroid tumor during pregnancy. After delivery it is supposed that the diminution in the size of a fibroid is due to fatty degeneration.

Calcification.—This is rather a rare transformation which Noble (*loc. cit.*) found in 1.7 per cent of his cases. Deposits of phosphate and carbonate of lime are found near the periphery or the center of the tumor and make either a bony framework—not true bone, however—or a shell. Rarely is the tumor solidified to make the so-called "uterine stone." Small areas of calcification are not uncommon.

Fatty Degeneration.—Gusserow ("Die Neubildungen des Uterus," 1886) has called attention to the fact that fatty degeneration of a fibroid tumor has been determined microscopically in only three

cases—those of Freund, A. Martin, and Brunings—where there has not been resulting diminution in the size of the tumor as well. There is a form of fibroid tumor called *lipomyoma* in which a portion of the tumor is composed of fatty tissue.

Edema.—Edema is often present in fibroids and may be considered a beginning stage of necrosis. It most often affects the subserous tumors.

Amyloid Degeneration.—A single case of amyloid degeneration

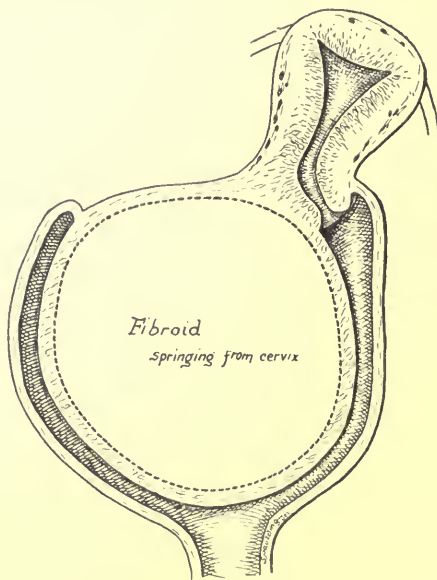


FIG. 108.—Fibroid of the Cervix Distending the Vagina. (After Dartigues.)

of a fibroid polypus has been observed by Stratz. (*Zeit. f. Geburts. u. Gyn.*, 1889, Bd. XVII., II. 1, p. 80.)

Suppuration.—This is the result of the infection of the tumor with bacteria derived from the intestinal canal, the genital tract, or the blood. Prolonged pressure of a tumor on the bowel, or an appendix vermiformis adherent to the tumor, may permit easy penetration of microorganisms. Instrumental or digital invasion of the uterine cavity for exploration or curetting may infect a fibroid, especially a submucous myoma.

Gangrene.—Gangrene may result when a tumor is undergoing degeneration, or when there is torsion of its pedicle. Micro-

organisms may or may not play a part in the necrobiotic process. The mechanism of the process is obscure. Extreme torsion of a tumor, causing stasis of the blood supply and necrosis or gangrene, is a rare complication of fibroid tumors. Zangemeister thought that the fibroid uterus when rotated showed commonly (21 times to 3) a torsion to the right side.

Thrombosis.—Thrombosis of the blood-vessels of a fibroid may occur. It is probable that the tumor is tolerated in the body for a long time after the blood supply is cut off before it becomes infected, just as in cases of neglected extra-uterine pregnancy in the late months.

Sarcomatous Degeneration.—This occurred in two per cent of the cases collected by Noble (*loc. cit.*), and Winter (*Zeits. für Geburts. und Gynäkol.*, Bd., LVII., H. 1, 1906, p. 19) found sarcoma in 4.3 per cent of 253 cases of fibroid tumor in which sections were taken systematically from different parts of all tumors.

COMPLICATIONS

Carcinoma occurs as an associated lesion in fibroid tumors, not as a degeneration, for we know that the two processes are distinct histologically, with the exception of a few cases of adenomyoma where cancer has been described as springing direct from the glands within the tumor. In a study of 4,880 consecutive cases of fibroid tumor, Noble (*loc. cit.*) found that cancer was present in 2.8 per cent. In his personal experience with 337 fibroids, cancer of the corpus was present in 2.6 per cent, and cancer of the cervix in 1.4 per cent; hence, as women not the subject of fibroid tumor have cancer of the cervix ten times to one for cancer of the corpus uteri, he concluded that there is a causal relation between fibroma and cancer of the body of the uterus (adeno-carcinoma of the endometrium).

Metastases.—Fibroid tissue can be invaded and destroyed by an epithelial growth. The most frequent combination is occurrence of carcinoma of the body of the uterus coincident with fibro-myoma. Sometimes a fibroid tumor includes in its tissues glandular elements derived from the ducts of Müller or Wolff, and these elements are subject to a carcinomatus transformation. X. Bender and G. Lardenmois (*Bull. Soc. Anat.*, 1904, No. 8, Octobre) have shown

that uterine fibroids may be invaded by metastases from cancer of some distant organ.

Diseases of the Tubes and Ovaries.—These diseases, due to infection, are not infrequent complications of fibroids. Daniel studied this subject in Pozzi's clinic (C. Daniel, *Rev. de gyn. et de chir. abd.*, 1903, pp. 25 et 193). In most cases either the ovaries, or the tubes and ovaries together were diseased, rarely the tubes

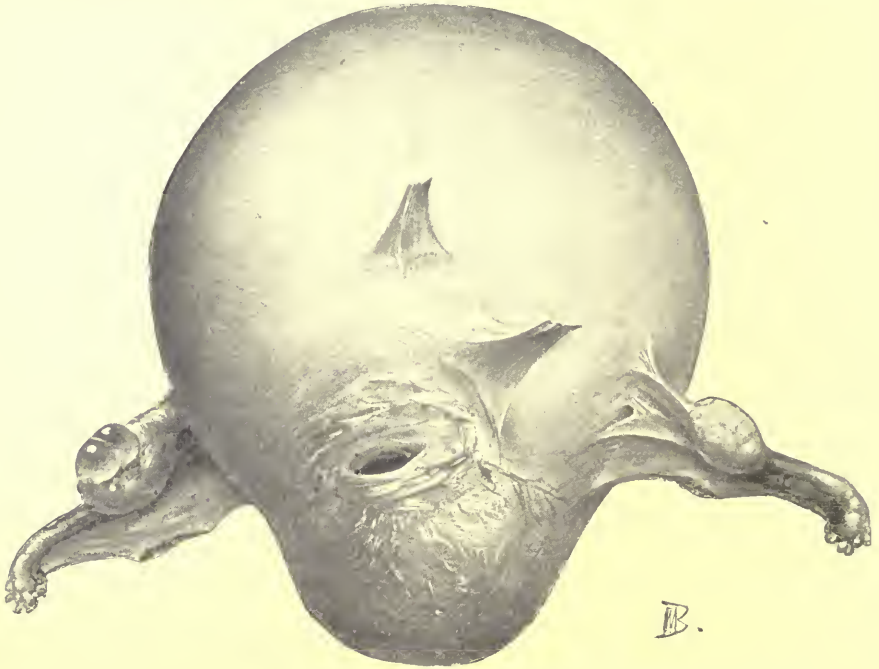


FIG. 109.—Large Globular Fibroid, the Lower Part Filling the Cavity of the Pelvis, Simulating Pregnancy at Term. (Kelly.)

alone were affected. Among 139 cases gathered from the literature in addition to his own cases he found lesions of the tubes 32 times, alterations of the ovaries alone 79 times, and tubo-ovarian disease 28 times. Among 70 cases observed in Pozzi's clinic the most common lesions were catarrhal salpingitis, purulent salpingitis, hematosalpinx, and cystic degeneration of the ovaries. In Noble's 2,274 cases of fibroid tumor (*loc. cit.*, p. 668), complications in the uterine appendages or in the pelvis existed in 37 per cent. In Pozzi's clinic lesions of the tubes and ovaries occurred in 59 per cent of the myoma cases.

In the analysis of these statistics it is not to be forgotten, however, that these large percentages were among women whose fibroid tumors required surgical treatment; they had entered the hospital for operation. It is hardly fair to assume that all fibroids are subject to complications to the same extent; in fact, this is an objection to most of the statistics which have to do only with fibroid tumors causing symptoms of a severe grade.

EFFECT OF FIBROID TUMORS UPON NEIGHBORING ORGANS

The uterus, being attached to the vagina, to the uterine ligaments, and to the peritoneum, is more or less limited in its movements. If a fibroid tumor develops in its substance, the uterus may displace the bladder or press the rectum, urethra, or ureters against the bony framework of the pelvis. In the case of a fibroid of the posterior uterine wall, the cervix may press on the urethra and cause retention. But this is a rarity. The bladder is extremely tolerant to misplacement by a tumor. However, retention is sometimes caused in this way, and congestion of the vesical mucosa, which exists in the case of fibroids as determined by Zukerkandl through cystoscopic examinations (A. Vénot, *Annales de gyn. et d'obstet.*, 1907, 2 s., IV., 287-310), furnishes a favorable soil for the growth of bacteria that may be introduced by a catheter. Injury of the ureters and kidneys from pressure on the ureters is much more frequent than thought formerly. Knox has reported a series of cases of compression of the ureters observed during operation on fibroids at the Johns Hopkins Hospital. Of the different varieties intraligamentous growths and tumors developing from the cervix are most apt to compress the ureters and also to displace them upward.

It is difficult to say even approximately just what is the frequency of renal disease because of ureteral compression by fibroid tumors. J. C. Webster found renal complications due to fibroids in 30 per cent of 100 cases—on the other hand, Haultain in 120 cases had never met renal complications. Cullingworth met hydro-nephrosis due to compression in 2 out of 100 cases: Sarwey, 1 in 430 cases: Knox, 3 in 400. A. Vénot points out that the compression of the ureter is probably intermittent, due to the motion

of the fibroid; therefore symptoms due to the compression are not present with any definite regularity.

Interference with defecation due to pressure on the rectum by a fibroid tumor is a common complication.

Tumors situated low cause the greatest degree of interference with the enlargement of the uterus during pregnancy and with delivery. Fibroids, then, are a cause of abortion. Lefour (Thèse d'agrég. de Paris, 1880), out of 307 cases of pregnancy complicated by myomata, noted 39 abortions (12.7 per cent), the mother dying in 14 cases. Nauss (Thèse de Halle, 1882), out of 241 cases, found that abortion took place in 47, or 15 per cent. The tumors situated low in the pelvis obstruct delivery; if situated elsewhere in the substance of the uterus they generally interfere with involution and are the cause of post-partum hemorrhages. Although the presence of a fibroid is by no means a bar to the occurrence of pregnancy, it is a frequent cause of sterility. Ols-hausen gathered the statistics of nine different observers, including Seanzoni, von Winkel, Schroeder, and Hofmeier, and found that out of 1,731 married women with fibroid tumors 520, or 30 per cent, were sterile. He considers this figure too high, however, because many women with fibroids come under a physician's observation only because of sterility, and those who become pregnant often do not consult a physician at all.

EFFECT ON DISTANT ORGANS AND ON THE SYSTEM

Anemia from prolonged and repeated hemorrhages is one of the most common results of fibroid tumors. The hemoglobin may be reduced as low as thirty per cent or even less and the red cells to 1,000,000. The affection is a serious one and difficult to correct often, even after the drain of blood has been stopped. Acute hemorrhage in fibroid cases seldom proves fatal, but the continued loss of blood produces a condition of lowered vitality, and a disposition to thrombosis, embolism, and phlebitis that counter-indicates in many cases an operation for the removal of a tumor. Many authors state that the hemoglobin should be at least fifty per cent before a hysterectomy is undertaken. Kelly and Cullen however, (*loc. cit.*, pp. 453 and 454), report twenty-two cases of operation for the removal of myomata in which the hemoglobin was

forty per cent or less, with a mortality of three cases. It often happens that several years elapse before a profoundly anemic patient regains good health after the cause of the loss of blood has been removed.

RELATION OF FIBROID TUMORS TO HEART DISEASE

The frequency of cardiac palpitation in fibroid tumors has been referred to by me. (*Amer. Jour. Obstet.*, Vol. XXIX., No. 3, 1894.) The symptom appears to be quite independent of actual cardiac disease, there being no evidences of enlargement of the heart or of adventitious murmurs. It is possible that palpitation may be due to anemia, in which event one expects to find hemic murmurs, and some influence must be assigned to the menopause in patients who are in this time of life. (See Chapter XXIX., page 613.) The exact relation of these tumors to heart disease is not known. Certain degenerative changes in the heart and in the blood-vessels, such as brown atrophy, fatty degeneration, fatty infiltration of the heart muscle, also chronic endocarditis, and arteriosclerosis of the arteries have been noted by students of this question, notably by Hofmeier, Fenwick, Strassman and Lehmann, Boldt, Pellanda, Winter, and Fleck, as quoted by Noble (*loc. cit.*, p. 671). Winter found the heart perfectly normal in 60 per cent of 266 cases examined with reference to this point; valvular disease was found in but 1 per cent, and dilatation and hypertrophy in but 6 per cent, the examinations being made in every case by a specialist in internal medicine.

It is difficult to understand how lesions of the heart can be caused by tumors. I think we may agree with Winter that, in the present state of our knowledge, we must attribute almost all of the cardiac symptoms in cases of fibroid tumors to anemia, and consequent derangement of the nervous system. It is well to remember, however, that heart disease not infrequently accompanies fibroids, although not necessarily in a causal relation.

DANGEROUS TO LIFE

Fibroid tumors may be a direct menace to life. Pellanda (C. Pellanda, "La Mort par Fibromyomes Utérins," Paris, 1905), in a study of 171 cases of death from fibromyomata without operation, states that in 6.4 per cent of the fatal cases death was due to hemorrhage.

Acute abdominal emergencies due to torsion and infection of a tumor are by no means unknown. Rupture of the uterus, due to fibroids obstructing labor, has occurred. As a rule, however, these tumors endanger life indirectly through their degenerations and complications, through interference with the function of other organs, and by their effect on the general health—anemia and its consequences.

SYMPTOMS

The symptoms of fibroid tumors are hemorrhage, anemia, pain, and leucorrhœa, also constipation, frequency of micturition, retention of urine, and dysuria; the last four being the result of pressure on rectum, ureters, urethra, or bladder.

Hemorrhage.—Hemorrhage may be of the type of menorrhagia or of metrorrhagia, more often the former. It is a symptom met with in the submucous tumors, occasionally in the interstitial, and not at all in the subserous. As most fibroids are multiple it is not always easy to say which form predominates in any given case. The submucous varieties cause hemorrhage by enlarging the surface of the endometrium, the total number of square inches being increased many times in the case of large tumors.

Diapedesis of red blood cells through the walls of the capillaries of the endometrium takes place to a greater extent the larger the surface involved, but venous congestion caused by the pressure of the tumor on the thin-walled veins is supposed to be at the root of the mechanism of hemorrhage in fibroid tumors; the arteries, with their thicker, elastic walls, being able to withstand better the pressure. The flowing may be only slightly increased over normal or it may amount to an excessive hemorrhage requiring active treatment. The size of the tumor bears no relation to the amount of the flow, the small tumors often having the greatest flowing,

It is a curious fact that some women with fibroids flow more when they are lying down than they do when up and about; therefore the treatment in such cases is not rest in bed. This peculiarity should be looked for in getting the history. An active acute hemorrhage is generally not so serious in its effects on the system as a lesser bleeding lasting over months and years.

Anemia.—Anemia exists so frequently in fibroid tumors that the physician should be on the lookout for a pale face, lips without much color, eyes a pearly white, muscles rather flabby, pulse bounding, but soft and compressible, with increased rapidity on the slightest excitement. Besides palpitation a feeling of faintness and breathlessness and languor accompanies anemia. In some cases there is swelling of the ankles. The red blood cells may fall to one-fifth or less of the normal number (1,000,000 per cubic millimeter), and the hemoglobin to thirty per cent. Hemic heart murmurs are usually present.

Pain.—Pain may or may not be present in fibroid tumors, and when it does occur is variable in amount. It is either referred to the uterus or to other organs when due to pressure on surrounding structures. It assumes several forms, occurring as a dull, constant pain situated in one or both groins or across the abdomen, as a bearing-down pain, or as a backache, and these varieties may exist separately or conjointly. It may be referred to the thighs or the legs in consequence of the pressure of the tumor on the sacral plexus of nerves. Pressure on a ureter may cause pain, but the rectum and bladder are generally tolerant of pressure so far as pain is concerned, their disturbance when pressed upon showing itself in derangement of function. Dysmenorrhea occurs in about twenty per cent of the cases of fibroid tumors, the cramp-like pain being often severe. It must be remembered, however, that an uncomplicated fibroid rarely gives rise to much pain, and therefore the presence of pain, especially if severe, indicates an inflammatory complication, such as salpingitis or adhesions. A rapidly growing tumor is apt to cause pain which is referred to the uterus. Expulsive pains are found when a submucous tumor becomes pedunculated and can be extruded either in part or wholly at the external os. Kelly and Cullen found that tumors of moderate size caused the most pain.

Leucorrhœa.—A vaginal discharge is rare in fibroids except in

the submucous variety. In this form it is common as a white discharge, and if the tumor is necrotic the discharge is muddy, watery, and malodorous. A profuse watery discharge associated with fibroids should always excite suspicion of cancer.

Symptoms of Adenomyoma.—According to Cullen this variety of myoma is most prevalent between the thirtieth and sixtieth years and does not tend to cause sterility. Lengthened menstrual periods are the first symptoms and the flowing gradually assumes the proportion of hemorrhages. There is pain with the period that is referred to the uterus; it may be grinding in character. There is no intermenstrual vaginal discharge and microscopical examination of scrapings shows the uterine mucosa to be normal.

DIAGNOSIS AND DIFFERENTIAL DIAGNOSIS

The diagnosis of large fibroid tumors is a comparatively easy matter, but the diagnosis of small ones is often difficult. The symptoms are not of much assistance, except that painful menstruation becoming profuse and protracted, and a history of sterility or early miscarriages, are suggestive of fibroids. The chief reliance is the bimanual palpation; and the passage of the uterine sound is most useful. The first point to determine is the relation of the tumor mass to the body of the uterus.

Subserous Fibroid Tumors.—If the tumor is a single mass bimanual palpation shows that it is connected with the uterus. To determine this point place the tip of the forefinger in the vagina on the cervix. On moving the tumor with the other hand on the abdomen, note whether the cervix moves at the same time. Outline the growth as exactly as the laxity and thinness of the abdominal walls will permit. In some cases of small-sized tumors in women with thin parietes, it is possible to map out the ovaries, and an attempt should be made to do this in every case. If the tumor is pedunculated it must be differentiated from an *ovarian cyst*. This is done by detecting fluctuation in a cyst. Making firm pressure against the tumor with the finger in the vagina, taps with the finger of the hand on the abdomen are transmitted to the finger in the vagina as waves. The pedicle of a pedunculated myoma may be palpated by drawing down the cervix with a

vulsellum, which is passed to an assistant to hold while the bimanual recto-abdominal touch is practised. (See Fig. 126, page 301.) If the contents of the cyst are thick and semisolid, as in the case of dermoid cysts, the fluid waves will be absent. Some ovarian cysts are as hard as some fibroids, especially soft fibroids. As a rule the fibroids are multiple and there is more than one nodule to be reckoned with; not only that, but the nodules are usually of a stony hardness. If the fibroid tumor or tumors are large enough to distend the abdomen the uterus is drawn up in the pelvis. This upward excursion of the uterus does not take place in the case of an ovarian tumor.

Fibroma of the ovary has been mistaken for a pedunculated subserous fibroid. Here only an abdominal operation can clear up the diagnosis. The sound should be passed. Fibroids are so often multiple that a lengthened canal may indicate a submucous or an interstitial fibroid and therefore indirectly point to a subserous tumor. Before passing the sound observe strict antiseptic precautions and always inquire as to the date of the last menstruation.

Pelvic inflammatory exudate may complicate a fibroid tumor, but is seldom mistaken for it. The mass in inflammation is brawny and fills in the chinks of the pelvis. There is a history of fever, even if it is not present at the time, as shown by the thermometer.

Cancer of the pelvis, originating in the uterus or ovaries, may be mistaken for fibroid tumor, but is differentiated by the fixity of the infiltration, and the lack of definite outline of the tumor.

Ascites is occasionally present in large tumors. Change of position of the patient changes the situation of the fluid, which is mapped out by its flatness to percussion.

The contour of the abdomen in the case of large fibroids is dome-shaped if the fibroid is globular and single, nodular if multiple. The tumor stands out sharply on all sides when seen in profile. (See Fig. 103.) Ascites, if it is present in excess, modifies the contour.

Intraligamentous Fibroid Tumors.—An intraligamentous fibroid is situated at one side of the uterus, the sound showing the situation of the latter if it can not be palpated. This sort of tumor is low in the pelvis, often it can be felt projecting into the vagina. Its mobility is limited because of its attachments and its situation.

Interstitial Fibroid Tumors.—The uterine canal is commonly

lengthened in cases of interstitial fibroids, and hemorrhage is likely to occur in these tumors. In this variety the enlargement of the uterus may be symmetrical, or it may be asymmetrical. In the latter, the diagnosis is easier to make; in the former, one must rule out *pregnancy*. To do this it is important to get the history most carefully, having regard to amenorrhea and nausea. The elastic feel of the pregnant uterus is to be sought for, also the softening of the cervix and the bulging of the anterior segment early in pregnancy and ballottement later. (See Chapter XXII., p. 423.) Breast changes are to be looked for, and if the tumor is large an attempt should be made to auscult the fetal heart sounds. Another examination a month later will confirm a diagnosis of pregnancy.

A fibroid rarely becomes cystic before it has attained the size of a three months' pregnancy; therefore, an elastic tumor of less than this size is probably not a fibroid. The sound is not to be passed if there is the slightest suspicion of pregnancy. Examination under ether is advisable if the abdominal walls are tense or the conditions for examination are not entirely satisfactory.

Sarcoma may develop in a fibroid. In this event the tumor has grown rapidly. Only operation makes a positive diagnosis of sarcoma.

Submucous Fibroid Tumors.—A history of hemorrhage is present in almost all submucous fibroids. Here the diagnosis is established by the sound and, if necessary, by digital exploration of the uterine cavity. Bimanual palpation determines an increase in size of the uterus. This is true even in the case of small growths. The sound shows enlargement and distortion of the uterine cavity. If the tumor is at the fundus nothing but digital exploration will settle the question whether it is sessile or pedunculated. Something may be learned often by the tactile sense transmitted through the exploring sound. To make a digital exploration of the uterine cavity the cervix is to be dilated by a series of dilators: the Hanks, followed by the Wathen or by large Simon dilators, plenty of time being taken so that rupture may not occur. In cases of hard, resistant cervixes it is best to adopt the method of incision of the anterior wall of the cervix described in Chapter VII., page 94, repairing the cervix by suture after the exploration is finished. A sessile submucous fibroid of the fundus uteri may be mistaken for

adenoma or adeno-carcinoma. A piece removed and submitted to microscopic examination is the only means of distinguishing the two. A pedunculated tumor presenting at the external os may be mistaken for *inversion* and, if sloughing, for *cancer of the cervix*. It is distinguished from cancer by learning that the sound may be made to sweep entirely around the tumor, thus making sure that the cervix itself is not the seat of the disease; and from inversion by noting, by bimanual recto-abdominal touch under ether, that the fundus uteri is in its normal situation. An inverted uterus is usually very sensitive to touch, although not invariably so.

Cancer of the body of the uterus and chorioepithelioma are to be excluded by the examination of tissue removed from the uterine cavity by curetting or by digital exploration, and, in the case of chorioepithelioma, by the history of a previous labor, abortion, or hydatidiform mole having occurred within a few weeks.

CHAPTER XVI

THE DIAGNOSIS OF MALIGNANT DISEASES OF THE UTERUS

Cancer, Sarcoma, and Malignant Chorioepithelioma

Cancer of the uterus, p. 266: Definition, p. 266. Varieties, p. 266. Diagnosis of cancer of uterus in general, p. 270. Diagnosis of cancer of the cervix, p. 271; Differential diagnosis of cancer of the cervix, p. 272. Diagnosis of adeno-carcinoma of the cervical canal, p. 275; Differential diagnosis of the adeno-carcinoma of the cervical canal, p. 276. Diagnosis of cancer of the body of the uterus, p. 276; Differential diagnosis of cancer of the body of the uterus, p. 277.

Sarcoma of the uterus, p. 278: Frequency and definition, p. 278. Varieties, p. 279.

Malignant chorioepithelioma, p. 280: Definition, macroscopic and microscopic appearances, p. 280. Course of the disease, p. 281. Ectopic malignant chorioepithelioma, p. 282. Diagnosis, p. 283.

THE DIAGNOSIS OF CANCER OF THE UTERUS

By cancer of the uterus we understand a malignant new growth the essential elements of which consist of epithelial cells having a characteristic arrangement. The cancer cells may proliferate and directly invade the surrounding tissues or they may be transported by the lymphatics to distant sites and there proliferate and form metastatic growths.

VARIETIES

The mucous membrane of the uterus may be divided into three types: (1) That covering the vaginal portion of the cervix, extending from the vaginal vault to the external os, and composed of squamous-celled epithelium. (2) That lining the cervical canal from the external os to the internal os, and composed of high cylindrical epithelial cells; and (3) That lining the uterine cavity proper from the internal os to the fundus, and composed of low

cylindrical or cuboidal epithelial cells. Cancer of the uterus always originates in the mucous membrane, and the type of cancer is determined by the character of the cells of the mucous membrane in which it originates.

We have then three kinds of cancer of the uterus:

1. Squamous-celled cancer of the cervix.
2. Adeno-carcinoma of the cervical canal.
3. Adeno-carcinoma of the body of the uterus.

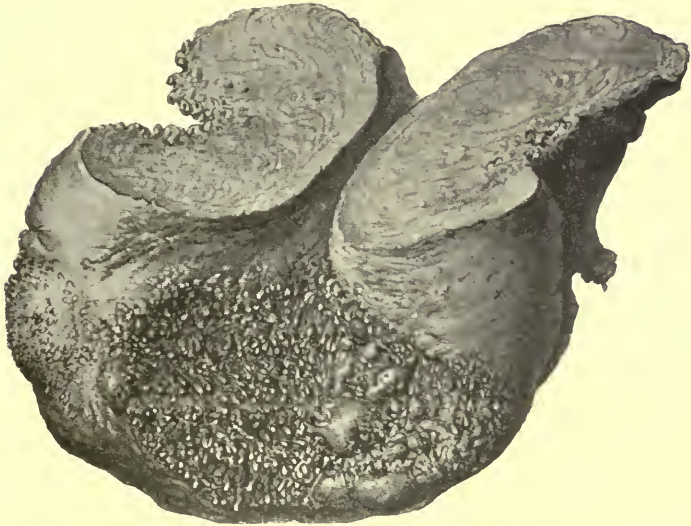


FIG. 110.—Early Stage of Squamous-celled Cancer of the Cervix. The Cauliflower Mass has been Cured away. (Cullen.)

Very rarely there is present a squamous-celled cancer of the body of the uterus.

1. *Squamous-celled cancer of the cervix* begins at or near the junction of the cervical and vaginal mucous membranes at the external os. Clinically, three types are recognized: (a) The everting or cauliflower growth, in which there is marked proliferation of the cancer, the growth spreading to and involving by direct extension the vault of the vagina. (b) The infiltrating type, in which the external contour of the cervix may remain normal, the growth extending internally deep into the wall of the cervix. (c) The ulcerative type, in which ulceration with loss of cervical tissue takes place early and proceeds until the entire cervix is eroded.

The squamous-celled type of cancer of the cervix is usually of rapid growth and it soon involves the surrounding tissues and organs—the bladder, the ureters, and rectum. The lymph glands of the parametrium and the iliac glands receive the cancer by means of the lymph channels and themselves take up the disease.

Microscopically the squamous-celled type begins as an hypertrophy of the pavement squamous epithelium of the cervix. The cells themselves hypertrophy and have large round or oval vesicular nuclei with many mitotic figures. These cells invade the

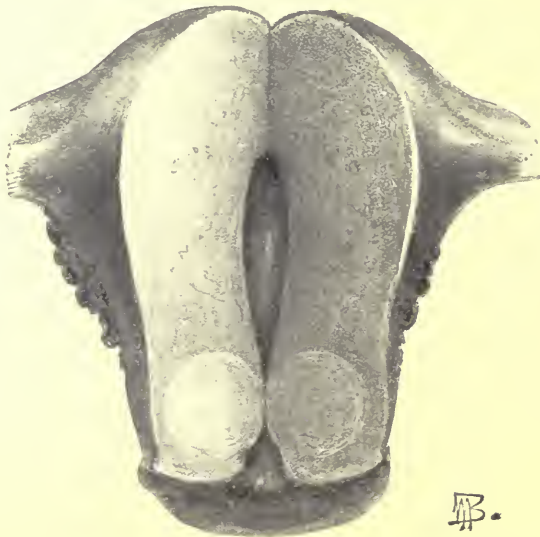


FIG. 111.—Very early Adeno-Carcinoma of the Cervical Canal. (Cullen.)

cervical tissue in all directions and without any typical arrangement.

2. *Adeno-carcinoma of the cervical canal* originates in the high cylindrical epithelial cells lining the cervical canal and the glands of the cervical canal. This type of cancer of the cervix spreads perhaps less rapidly than the squamous-celled variety, although necrosis takes place rather early. The squamous-celled variety seldom spreads beyond the level of the internal os, but the adeno-carcinoma frequently reaches to the fundus. The cervix may be reduced to a mere shell by the necrosis of the latter form of cancer and yet the external contour of the cervix remains unchanged. Metastasis to the surrounding organs, the bladder and rectum,

takes place usually by direct extension of the growth. The iliac glands are involved sometimes early and sometimes late, as is the case with the squamous-celled variety.

Microscopically adeno-carcinoma of the cervix is recognized as a proliferation of the cylindrical cells of the cervical mucous membrane, these cells preserving their alveolar or glandular arrangement. There is distinct loss or crowding out of the interglandular stroma, the proliferating alveoli lying close to one another.

3. *Adeno-carcinoma of the body of the uterus* originates in the low columnar epithelium lining the uterine cavity and the glands

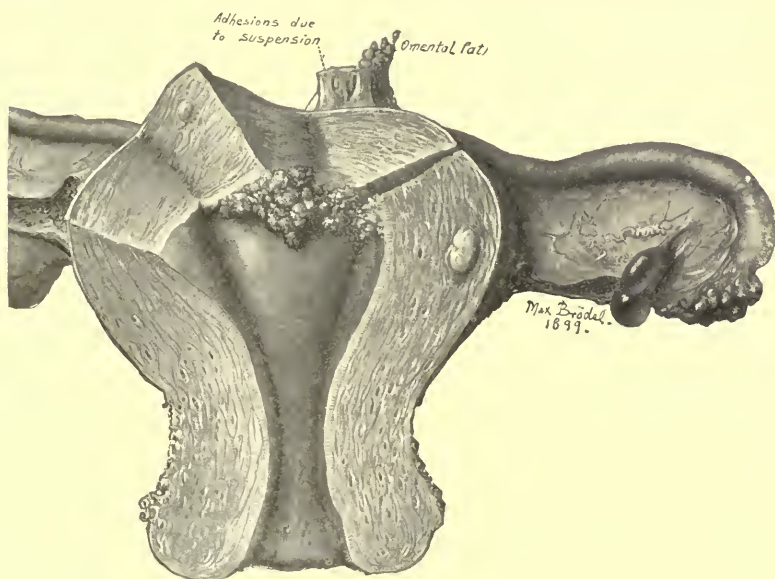


FIG. 112.—Early Adeno-Carcinoma of the Body of the Uterus. (Cullen.)

of the endometrium. It usually starts at the fundus or in one cornu as a circumscribed area of proliferation of the endometrium. From this point it may spread until it involves the entire uterine cavity. The growth may proliferate, forming actual outgrowths of endometrium into the uterine cavity, as well as invade the uterine muscular wall. The growth may ulcerate its way through the uterine wall and appear in the peritoneal cavity and form peritoneal metastases. This is generally a late process of a long-existing cancer. The ordinary benign uterine polyp, being covered by endometrium, may become carcinomatous. Adeno-carcinoma

of the body seldom extends beyond the internal os, although adenocarcinoma of the body and cervix may coexist.

Glandular metastasis from this form of cancer is late.

Microscopically adenocarcinoma of the body is recognized by the proliferation of the low cylindrical cells of the endometrium of the fundus, these cells preserving their glandular arrangement with distinct loss of interglandular stroma. The cells lining the new glands are from two to four layers deep or possibly entirely fill the alveolus.

DIAGNOSIS OF CANCER OF THE UTERUS IN GENERAL

It is important to keep in mind that cancer is always a local disease in the beginning and that prompt removal of the diseased tissues effects a permanent cure; therefore early diagnosis is especially important. A failure to make a correct diagnosis is followed surely by the death of the patient in from six months to a year and a half. Late operations, except in the case of cancer of the body, are of value only in prolonging life a few months or a year or two, and in lessening suffering. The view commonly held by the laity, and, sad to relate, by too many of the medical profession, that cancer is an incurable disease is not true, provided that it can be recognized and removed before it has gained a good headway.

It appears that progress is being made in getting patients to submit to examination at earlier periods of the disease. G. Winter's works in spreading a propaganda, both among the physicians and the laity, in East Prussia, is most encouraging (*Zentralblatt für Gynäkologie*, 1904, No. 14, p. 441). It is a fact, however, that at the present time a large proportion of the sufferers from this dread disease are permitted to get into an absolutely hopeless state, then to go through the awful months of suffering until a lingering death releases them.

The *symptoms of uterine cancer* are by no means pathognomonic; they are suggestive and are as follows: Bleeding, particularly in women who have passed the menopause; and hemorrhage or a show of blood after coitus, also a persistent or recurring sero-sanguinolent vaginal discharge. Neither of these is a symptom of the normal menopause, as has been maintained in the past. The

menopause has no local symptoms if the uterine organs are normal. Bleeding or a vaginal discharge occurring at the time of change of life should lead at once to a vaginal examination to determine the cause. Pain and cachexia are symptoms of the advanced, hopeless stages of the disease, only at this time one does not have to be a physician to make a diagnosis. Although the disease occurs most commonly in women who are between the fortieth and fiftieth years it may occur at any age between eight and seventy-six.

Clinically, heredity seems to play a rôle, though this has been disputed.

The disease is relatively rare in the colored race.

It is more frequent among women who have borne children than in nulliparæ.

The diagnosis varies with the progress of the disease, and the variety of cancer present; the early stages, while the normal tissues are being replaced by cancer cells, show only a slight local thickening or proliferation; the later stages, when the tissues are breaking down and degenerating, show ulceration, bleeding, and detritus with foul odor.

As has been pointed out in describing the different forms which cancer assumes, the disease advances in different manners and at different rates of speed in individual cases. It may progress to a fatal termination in a year; on the other hand, I have had a patient who had the erosion type of cancer of the cervix where there was every indication that the disease had existed for twenty years. The tissues may be brittle and easily disintegrating, or tough and hard. The tissues most commonly invaded by the different kinds of cancer have been noted, therefore in making a diagnosis the routes of extension of the disease must be taken into account. We employ both touch and sight in making a diagnosis, as well as microscopic examination of tissues removed.

DIAGNOSIS OF CANCER OF THE CERVIX

This, of all forms of uterine cancer, is the easiest of diagnosis because the lesions can be detected by both touch and sight.

(a) The *cauliflower growth* is the simplest, growing as it does as a polyp-like mass projecting from the cervix into the vagina. In the early stages this appears as an indurated, reddened area raised

above the surrounding mucous membrane. In its later progress one expects to find a larger tumor, reddish-gray in color, with softened, disintegrated tissue. The sound perforates it with ease, and any manipulation causes hemorrhage.

(b) If the *infiltrating* sort is present the tissues are indurated and the contour of the cervix may be altered or not. If the vaginal mucous membrane overlying the growth is intact the diagnosis is difficult. In all suspicious cases a wedge-shaped piece of tissue should be removed and submitted to the pathologist for microscopic examination.

(c) *The ulcerating variety* is distinguished by an ulcer of excavating tendency. There is much loss of substance; the edges of the ulcer are rough and irregular; the base is necrotic; the underlying tissues are hard to the feel. If portions of the deeper parts of the edge of an ulcer crumble on pressure by the finger or sound the condition is suspicious of cancer; also, if the edge of the ulcer has a porky consistency and is of a yellowish-gray color. In all doubtful cases a piece of tissue must be removed for microscopic examination. To do this fix the cervix with a double tenaculum just outside the diseased area and let an assistant hold the tenaculum. If the cervix proves to be sensitive inject into the sound tissue surrounding the diseased area, in several places, a few minims of two-per-cent sterile solution of cocaine with a hypodermic syringe. Wait five minutes. With a single tenaculum and a scalpel or scissors cut out a good-sized piece of the diseased tissue in the shape of a wedge. Be prepared to place a catgut stitch with a curved needle should there be much bleeding. Often an application of tincture of iodine and carbolic acid followed by a dry tampon will be sufficient to stop all bleeding. The patient should not be dismissed until it is known that the bleeding has been controlled.

Differential Diagnosis of Cancer of the Cervix

(a) **Cauliflower Form.**—The *cauliflower form* of cancer of the cervix must be differentiated from:

- (1) Follicular hypertrophic polyp.
- (2) Mucous polyp.
- (3) Papillary tuberculosis.

(4) Myoma of the cervix.

(5) Condylomata acuminata.

(1) The *follicular hypertrophies* of the cervix produce discrete tumors, in some cases similar to polypi. They are soft, of a red color, and show the rounded, yellow, shot-like, dilated Nabothian follicles in their substance, the condition being not unlike that in the tonsil. The follicles may be seen and felt also in the surrounding normal mucous membrane of the cervix. There is lacking the crumbling consistency, the sharp edges, and the indurated base of the cauliflower cancer. The microscope will confirm the diagnosis.

(2) *Mucous polypi*, especially if multiple and having a lumpy appearance, may be mistaken for cancer. Polypi are covered everywhere with mucous membrane, they are soft, and the sound will detect the position and size and shape of their pedicles.

(3) *Papillary tuberculosis*, although relatively rare, may simulate closely polypoid carcinoma in its early stages. The external os may be surrounded by a papillary excrescence. It is possible in favorable cases to determine the presence of the little glassy tubercles the size of a millet seed lying in the greasy, cheesy substance characteristic of broken-down tuberculous tissue. In tuberculous disease of the cervix the ulcerated form is more common than the papillary. The diagnosis must be made by the microscope.

(4) *Myoma of the cervix* is rare. A cervical myoma is covered with a smooth mucous membrane, it disintegrates by ordinary gangrene, and has a firm and not a crumbly consistency.

(5) *Pointed condylomata* may simulate papillary cancer, especially during pregnancy. They form a circumscribed tumor of irregular surface; but they have no infiltrated base and no real ulceration, only a papillary surface with thick epithelium. They are of a reddish-white color. As a rule they occur in more than one situation at the same time, *i.e.*, on the wall of the vagina or on the vulva.

(b) **Infiltrating Cancer.**—Infiltrating cancer is confused most often with inflammatory diseases of the cervix occurring in connection with tears, especially when the tissues are indurated and nodular, as they often are. As a rule the inflammatory process involves the entire cervix, the consistency is not so hard as in cancer, and the external mucous membrane is not involved. If the cervix is riddled with diseased Nabothian follicles the similarity of the two

conditions is often great. But here the cancer is limited, whereas the inflammatory affection is universal. In all cases a piece of tissue should be removed for examination.

(c) **Ulcerating Form.**—The ulcerating form of carcinoma must be differentiated from:

1. Erosion.
2. Simple ulcer; as in prolapse.
3. Tuberculous ulcer.
4. Chaneroids.
5. Syphilitic ulcer.

1. If there is very little infiltration and induration a cancerous ulceration may simulate a *simple erosion*, especially in those cases where the erosion has a thick, roughened surface. The characteristics of the malignant ulceration are to be borne in mind. Also, the erosion as seen through the speculum presents a bright red, shining appearance, while the cancerous ulceration shows loss of substance and a dull red or yellowish-gray color.

The erosion has no sharp edge, but shows a gradual transition of the pavement epithelium of the normal mucous membrane to the erosion by a border of irregular outline, and there are apt to be islands of normal mucous membrane in the erosion. If there is infection of the erosion, sear formation results. In doubtful cases the microscope must be brought in.

(2) *Simple Ulcers.*—These occur in prolapse; they are generally not situated at the external os, while the carcinomatous ulcers are more apt to be in that situation. They are apt to have a light yellow base and show cicatrization about the periphery, and there are islands of mucous membrane in the central portions. After the prolapsed uterus has been replaced for a day, all traces of infiltration of the tissues under such ulcers disappear and evidences of repair at the edges can be seen. As a rule there is little or no thickening of the tissues under these ulcers. This is the case also with ulcers caused by an ill-fitting pessary. They heal readily.

(3) *Tuberculous Ulcer.*—This, although rare, is very similar to carcinomatous ulcer. Both are generally situated around the external os; the base of the tuberculous ulcer is yellow in color, nodular but not infiltrated. Yellow, miliary tubercles may be seen in the mucous membrane in the neighborhood of the ulcer.

There is apt to be present also tuberculosis of the endometrium and of the tubes. The microscope settles the diagnosis.

(4) *Chancroids* are generally small in size and multiple; their base has a diphtheritic, grayish appearance, and is not indurated, and the edges are indented and raised. Similar lesions are to be found generally in the vagina and vulva.

(5) *Syphilitic ulcer* may occur on the cervix in three forms: (a) as an ulcerated initial lesion, (b) as broken-down papules, or (c) as a degenerated gumma.

(a) The *initial lesion* is solitary and of great hardness. The ulcer has a sharp edge and is of a dirty reddish-brown color; its discharge being of a greasy consistency. It may extend into the cervical canal in the case of a parous woman with open os externum.

(b) *Ulcers from papules* are generally multiple and are elevated above the surrounding surface of the normal mucous membrane. Their surface is covered with disorganized white or yellowish tissue. Near them are to be found non-ulcerated papules, especially on the walls of the vagina and vulva.

(c) *Gummata of the cervix* are very rare. They are described by Neumann (Winter's "Lehrbuch der Gynäkologischen Diagnostik," iii. Auf.) as occurring about the os externum and on either or both the anterior and posterior lips of the cervix. The ulcers are elliptical in shape with sharply defined edges, shallow or deep, generally with yellow purulent covering. Good-sized fungous granulations are apt to be found on the surface. These ulcers are to be differentiated from cancerous ulcerations by their irregular and sinuous borders, their rapid disintegration, and the crater-like excavations of their tissues. Syphilitic lesions elsewhere in the body assist in making the diagnosis, the microscope being the court of last resort.

DIAGNOSIS OF ADENO-CARCINOMA OF THE CERVICAL CANAL

In this form the diagnosis is of necessity difficult. Palpation will show usually thickening of the cervix and perhaps a nodular feeling. If the external os is normal, a nodular thickening and the detection of a bloody discharge from the os may be all of the suspicious signs.

If the os is open because of tears, ulcerated and indurated areas in the canal may be both palpated by the finger in the canal and

seen with a uterine or bladder speculum. With the aid of a sharp, stiff-shanked curette, tissue is removed for microscopic examination.

In the infiltrating variety where there is no ulceration, palpation having shown localized thickening of the tissues, the external os should be dilated under ether and a piece of tissue excised for a microscopic examination.

In curetting the body and fundus of the uterus it is very easy to overlook this situation. The physician should bear in mind always that the cervical canal is one of the points of origin of cancer.

Differential Diagnosis of Adeno-carcinoma of the Cervical Canal

This form of cancer of the uterus is to be differentiated from *interstitial myoma*, and *chronic cervical endometritis in old women*.

As to the former, the infiltration of the tissues surrounding the center of the disease distinguishes carcinoma from myoma. In the case of the latter the mucous membrane of a chronic endocervicitis is more normal to sight, although not necessarily so to the touch, and the curette carries away little tissue. Tissue is removed and the microscope tells the last word.

DIAGNOSIS OF CANCER OF THE BODY OF THE UTERUS (ADENO-CARCINOMA)

The symptoms are the chief guide to a diagnosis of cancer of the body of the uterus. Bleeding alternating with a watery discharge, occurring in a woman who is past the menopause, and the exclusion of fibroids and of cancer of the cervix, make cancer of the body probable. Cancer of the body of the uterus is more common in nulliparæ than in women who have borne children. There is sometimes a characteristic odor to the uterine discharge in cancer. It can not be described, however. A recurrent pain, similar to labor pains, coming on regular days and of several hours' duration, the so-called Simpson symptom, has been described as characteristic of cancer of the body. This sort of pain is found also in myoma of submucous evolution and must be interpreted as the result of the stimulation of the uterus by a foreign body which it is trying to expel. There is nothing characteristic in the uterine discharge of cancer to distinguish it from the discharge from myoma, except

that on microscopic examination cancer elements may be distinguished in it. A uterine discharge occurring in a woman past forty should lead to an investigation.

So, also, palpation gives no characteristic feeling. There should be slight enlargement of the body; there may be tenderness. In patients with very thin or lax abdominal walls it may be possible in exceptional cases to make out a localized tumor in the body of the uterus. This is unusual.

The diagnosis is established by exploration of the cavity of the uterus, first with the sound and then with the curette forceps or the finger. The sound will detect friable tissue, the curette forceps will remove it for microscopic examination. Every part of the uterine cavity must be reached by the curette, as the initial lesion may be very small and easily overlooked.

The curette forceps are especially valuable in this case, for they pinch off and remove tissue without tearing it to pieces. The finger introduced to the fundus can recognize beginning cancer of the mucous membrane.

In order to examine with the finger ether must be administered and the cervix dilated with steel branched dilators and large Hegar dilators. A method devised by H. A. Kelly, consisting of an anterior colpotomy and division of the anterior wall of the cervix (see page 94), is of value often in exploring the interior of the uterus. As in the other forms of uterine cancer, the microscope is the means of a sure diagnosis.

Differential Diagnosis of Cancer of the Body of the Uterus

The differential diagnosis is a matter of the microscopic examination. The physician should remember that sarcoma of the endometrium, necrotic myoma, mucous polypi, the products of conception, or hydatidiform moles may be found in the uterine cavity. The characteristics of cancer of the fundus have been referred to already (page 269).

Before leaving the subject of uterine cancer it is well to draw attention to the great difficulty often experienced in determining whether a thickening in the broad ligaments is of inflammatory or of cancerous origin. It is well to bear in mind that most thickenings are the result of old pelvic inflammation. Cancer may super-

vene, however, and then it may be assumed that all of the induration is due to the cancerous infiltration. The history of the case is of some assistance in differentiating the two.

If there has been pelvic inflammatory disease, it will be shown by a history of difficult and infected labors and abortions and a history of old attacks of "inflammation of the bowels." We have seen what are the usual routes of infection of the surrounding tissues in the different forms of uterine cancer, both as to the cellular tissue and the glands. Then we know that cancer of the body seldom extends to the broad ligaments and to the lymphatic glands except in the late stages of long neglected cases, whereas cancer of the cervical canal extends to the surrounding tissues relatively early.

THE DIAGNOSIS OF SARCOMA OF THE UTERUS

Sarcoma of the uterus is of very rare occurrence. It is most often found between the ages of forty and sixty. W. A. Edwards (*Amer. Jour. Med. Sci.*, July, 1909) has recently collected 16 cases of sarcoma of the uterus in children who were fifteen years of age or younger. It forms about 4.8 per cent of all malignant growths and 2 per cent of all uterine tumors. (E. Hurdon, Kelly and Noble, "Gynecology and Abdominal Surgery," Vol. I., p. 151.) It is a disease originating from connective-tissue elements as contrasted with epithelial elements from which carcinoma arises. There is to be noted in sarcoma not only a numerical increase in the number of cell elements, a hyperplasia, but also a change in the original type, heteroplasia. The small round or spindle cells acquire large nuclei, many times larger than the nuclei of the original cells of the connective tissue. There is great proliferation of the cells into the surrounding tissues and later metastases by the blood-vessels to distant organs. The proliferation is not everywhere uniform; larger and smaller cells lie together, so that the distinguishing characteristics of sarcoma are the change in the type of the cells and the dissimilarity of their arrangement. In sarcoma the tumor parenchyma is richly vascularized, carrying its own blood supply; whereas in cancer the blood-vessels are contained only in fibrous septa. Therefore sarcomata are full of blood and are not so apt to be found in a degenerated condition.

Three varieties are recognized by pathologists: spindle-celled sarcoma; giant-celled sarcoma; and small round-celled sarcoma. The last is the most difficult to diagnose microscopically, especially if only small pieces are furnished from a curetting. The disease may originate in any of the structures of the uterus where connective tissue is found, in the interglandular connective tissue of

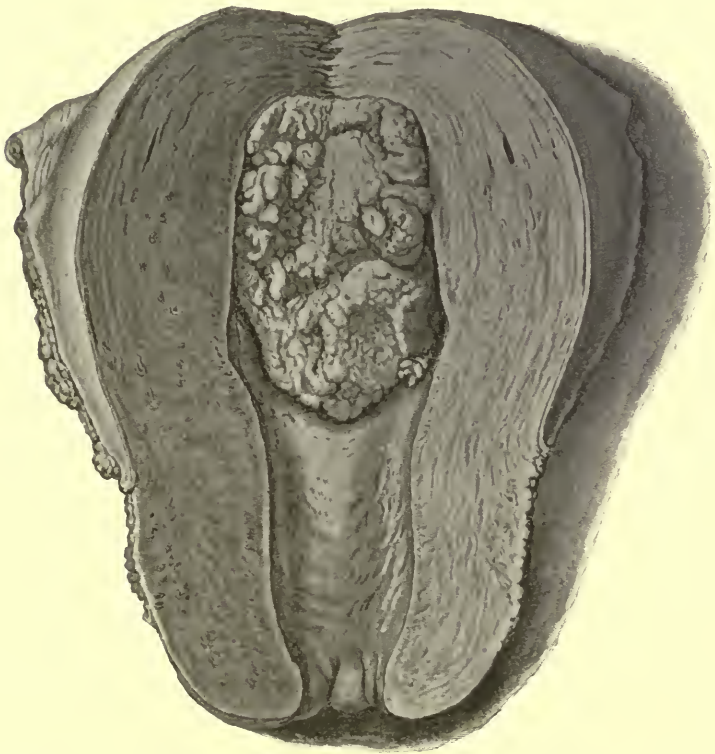

FIG. 113.—Round-celled Sarcoma of the Body of the Uterus. (Cullen.)

the endometrium, in the connective tissue of the myometrium, or about the blood-vessels. One of the most frequent seats is a preëxisting myoma of submucous or interstitial development; the next most frequent is the body of the uterus, and the least frequent is the cervix.

In *sarcoma of the body of the uterus*, if the disease originates in the endometrium, there is a diffuse thickening and infiltration of the endometrium, accompanied often by more or less definitely

circumscribed outgrowths. The growth is soft and friable, consisting of a homogeneous brain-like substance very well vascularized.

Sarcoma of the muscular wall usually occurs as a circumscribed, nodular growth and rarely as a diffuse infiltration.

Sarcoma of the cervix occurs in two forms, a polypoid tumor of soft consistency and smooth surface, attached by a broad base, or a tumor made up of many little blebs of tissue of different sizes, racemose in character, something like a hydatidiform mole or the grape-like vaginal sarcomata of infants. These latter tumors are sometimes called myxosarcomata.

The diagnosis of sarcoma can not be made without the aid of the microscope. Metastases by way of the blood current occur in about a fourth of the cases of sarcoma of the endometrium, according to G. Winter. They are in the lungs, intestine, and peritoneum. The lymph glands are very seldom involved. Metastases from sarcomata of the uterine wall or myomata invaded by sarcoma are more frequent, being found in the lungs, liver, and intestine.

THE DIAGNOSIS OF MALIGNANT CHORIOEPITHELIOMA

Sänger in 1889 (M. Sängcr, "Ueber Deciduome," *Centralb. f. Gyn.*, 1889, Bd. 13, p. 132) reported a case of decidosarcoma: a tumor developing in the uterine cavity after pregnancy and followed by metastases to distant organs. Soon other observers reported similar tumors under the names, Deciduoma malignum, Decidosarcoma, Placentoma, Syncytioma malignum, Malignant hydatidiform mole, or other names.

Marchand (F. Marchand, "Ueber das maligne Chorionepitheliom nebst Mittheilung von zwei neuen Fällen," *Zeitschr. f. Geb. u. Gyn.*, Bd. 39, p. 173) in 1895 and the following years showed that the tumor originates in the epithelial cells covering the chorionic villi, and is of a fetal rather than a maternal (decidual) source, hence the name Chorionepithelioma, which has since been generally adopted by the many authors reporting cases.

The disease consists of a tumor without sharply defined border developing in the mucous membrane of the body of the uterus (very rarely in the Fallopian tube or the vagina) and invading the

mucous structure. It is dark red in color, of soft consistency, and abundantly supplied with blood. It has a tendency to become gangrenous and in that case has a foul odor.

The surface is apt to be unevenly lobulated. On cross section, the structure is seen microscopically to be made up of fibrous septa and large spaces filled with extravasated, clotted blood, or placental tissue. Larger or smaller nodules are to be seen in the uterine muscle, which becomes often very thin when the disease has nearly penetrated to the peritoneum. The metastases show

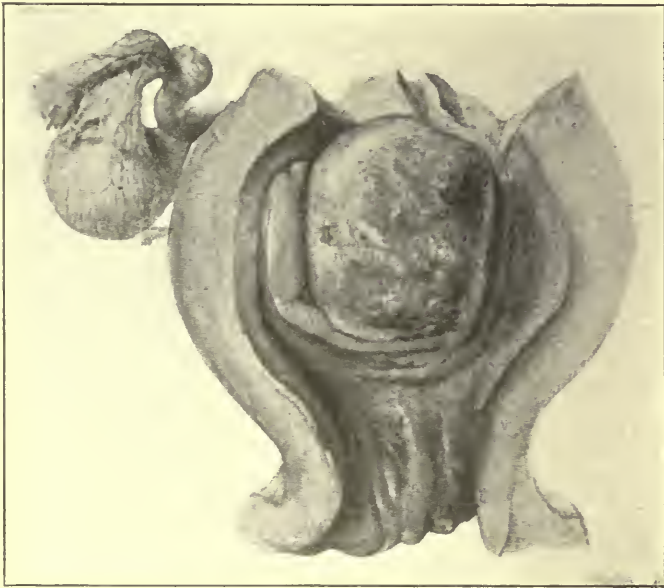

FIG. 114.—Chorioepithelioma of the Posterior Wall of the Uterus. (Winter.)

the same characteristics. In the later stages there are numerous metastases from the growth, not only in the neighborhood of the uterus but in distant organs, most commonly in the lungs, and the disease proves fatal in a majority of cases.

The disease never occurs except after pregnancy, most often after hydatidiform mole and abortion. It generally occurs only a few weeks after the pregnancy, but may be delayed several months.

The usual chain of happenings in the case of chorioepithelioma

is as follows: hemorrhages occurring after abortion or the delivery of a hydatidiform mole, curetting and the removal of tissue without stopping the bleeding, quickly developing anemia, and signs of metastases in the lungs (pain, hemoptysis, and rise of temperature). It is plain that prompt hysterectomy is indicated in order to save life. In exceptional cases the ovum which has grown a chorioepithelioma is (*a*) in the Fallopian tube and not in the uterus, and in still rarer cases (*b*) in the wall of the vagina.

These cases are called *Ectopic malignant chorioepithelioma*. In the first, (*a*) the symptoms are those of extra-uterine pregnancy, and in the second, (*b*) they are the same as in the uterine variety. The primary disease in the vagina being more accessible to sight

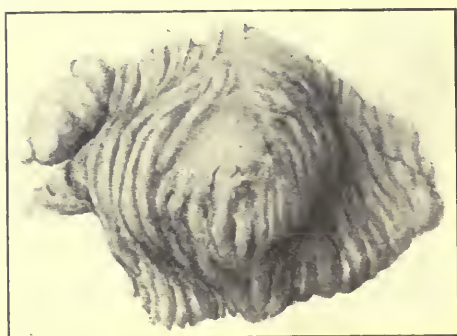


FIG. 115.—Metastasis in the Vagina from Chorioepithelioma of the Uterus. (Winter.)

and touch, the diagnosis should be made more promptly than when it is in the uterus.

According to J. Veit ("Das maligne Chorioepitheliom," *Handbuch d. Gyn.*, ii. Auf., Bd. 3, 1908) microscopic study of the tissues shows that syncytium, Langhans' layer, and connective tissue of the chorion, when all present in the same case, are found primarily in the veins of a uterus that has been pregnant, and especially after hydatidiform mole. If the epithelial cells of the chorionic villus proliferate rapidly in the veins, being well nourished, the process is malignant. The factor which determines the malignancy of the growth is the proliferating power of the epithelial cells and not the invasion of the veins by the connective tissue of the chorion.

If by chance the proliferating epithelial cells of the villus get

into other tissues than the veins, as, for instance, into the peritoneum, the process ceases. A non-malignant form of the disease has been reported, and at the present time authorities are not agreed as to the reason for the two forms or as to their differentiation before the specimen reaches the pathological laboratory, therefore it is safe to assume that every case of chorioepithelioma is malignant and treat it accordingly.

DIAGNOSIS

The diagnosis depends on the apparent recurrence of a placental polyp after abortion or a hydatidiform mole, with hemorrhage, and a watery, foul discharge. Rapidly developing anemia under such conditions is a suspicious symptom, as the anemia develops more rapidly in this than in any known disease. Tissue removed by the curette or curette forceps is submitted to microscopic examination. Better still the cervix is dilated until the canal will admit the physician's forefinger and digital exploration demonstrates the presence of a soft tumor.

The tissue of a chorioepithelioma is much more friable and softer than that of a placental or other polypus. The uterus is found to be somewhat enlarged when the bimanual touch is practiced. In most cases it is not sensitive.

In cases of hydatidiform mole the physician should keep his patient under observation for several weeks after the mole has been delivered and should bear in mind the possibility of the development of a chorioepithelioma. Early removal of a chorioepithelioma is attended by lasting cure.

CHAPTER XVII

THE DIAGNOSIS OF DISEASES OF THE OVARIES

Anatomy and age changes, p. 284.

Anomalies, p. 285. Atrophy, p. 285.

Displacements, p. 286: Undescended ovary, p. 286. Prolapse of the ovary, p. 286. Hernia of the ovary, p. 288.

Inflammations (Ovaritis), p. 288: Acute ovaritis, p. 288; Diagnosis of acute ovaritis, p. 288. Chronic ovaritis, p. 290. Diagnosis of chronic ovaritis, p. 290.

Tumors of the ovary, p. 291: Modes of development, p. 292. Classification, p. 293. Malignancy, p. 293. Etiology and symptoms, p. 293. Diagnosis in general, p. 295. Diagnosis of small ovarian tumors, p. 296; Differential diagnosis of small ovarian tumors, p. 296. Diagnosis of large ovarian tumors, p. 301; Differential diagnosis of large ovarian tumors, p. 305. Tables, pp. 308, 309.

Complications of ovarian tumors, p. 315: 1. Adhesions and incarceration, p. 315. 2. Intraligamentous development, p. 316. 3. Torsion of the pedicle, p. 317. 4. Infection and suppuration, p. 318. 5. Degenerative processes, including malignancy, p. 318. 6. Rupture, p. 319. 7. Association with pregnancy, p. 320.

Diagnosis of the different pathological varieties of ovarian tumors, p. 321.

ANATOMY AND AGE CHANGES

At birth the ovary is an elongated body, lying parallel with the Fallopian tube and resembling in shape a flattened cucumber. (See Fig. 117.) Its surface is smooth, its borders may be crenate, and it may have a longitudinal furrow. At puberty it has become transformed into a smooth olive-shaped gland, grayish-pink in color, $1\frac{1}{2}$ inches long (4 cm.), $\frac{3}{4}$ to 1 inch broad (2 to 2.5 cm.), and $\frac{1}{2}$ inch thick (1 to 1.5 cm.) and weighing about 2 drams (6 grams).

From puberty to the menopause it maintains the same size and shape, but the smoothness of its surface is marred by scars, the results of repeated lacerations caused by the rupture of the ripe Graafian follicles. (See Fig. 118.)

After the menopause the ovary shrinks and becomes wrinkled and atrophic, and at the age of seventy weighs about one gram. (See Fig. 119.)

ANOMALIES

Congenital absence of both ovaries is rare and is associated with defective development of the uterus and partial or complete absence of the vagina. Absence of one ovary usually accompanies deficiency of the corresponding half of the uterus and the Fallopian tube, and absence or misplacement of the kidney on the same side of the body. There is on record no reliable description of a supernumerary ovary; the bodies described as such being corpora fibrosa, small myomata of the ovarian ligament, or partially detached tubes

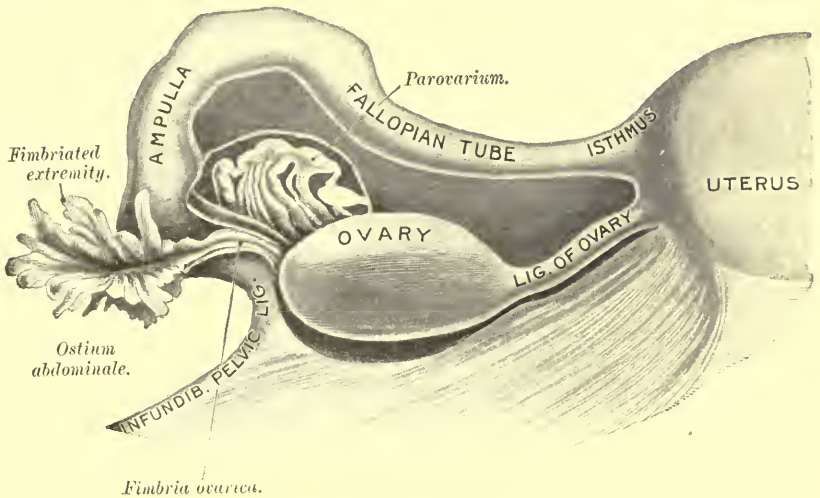


FIG. 116.—The Ovary and Tube Seen from Behind. (Henle.)

of the parovarium. Faulty growth of the ovary is commonly associated with the uterine condition known as infantile uterus, also with rudimentary uterus.

Atrophy of the ovaries occurs normally at the menopause. They become smaller and harder and the oöphoron (the egg-bearing zone on the outside of the ovary) is transformed into a layer of dense fibrous tissue. *Lactation atrophy* is a shrinkage in the size of the ovary occurring sometimes in women who have nursed their children for a long time. Ovarian atrophy has been reported in the exanthemata, myxedema, marked anemia, and in diabetes. It is supposed to occur in connection with rapidly acquired obesity.

At all events young women who have suddenly become fat frequently suffer with amenorrhœa. On account of the increase in fat in the abdominal walls it is not easy to determine a decrease in the size of the ovaries in these patients, but in certain cases atrophy has been definitely made out.

In 1900 I opened the abdomen in a case of absolute amenorrhœa of eight months' duration following steaming of the uterine cavity at the hands of another practitioner. The woman was twenty-eight years old, the mother of two children. The ovaries were found to be partially atrophied as well as the uterus.

DISPLACEMENTS OF THE OVARY

(a) Undescended ovary, (b) Prolapse of the ovary, (c) Hernia of the ovary.

(a) **Undescended Ovary.**—The ovaries are in close relation with the kidneys in the embryo and they gradually move downward

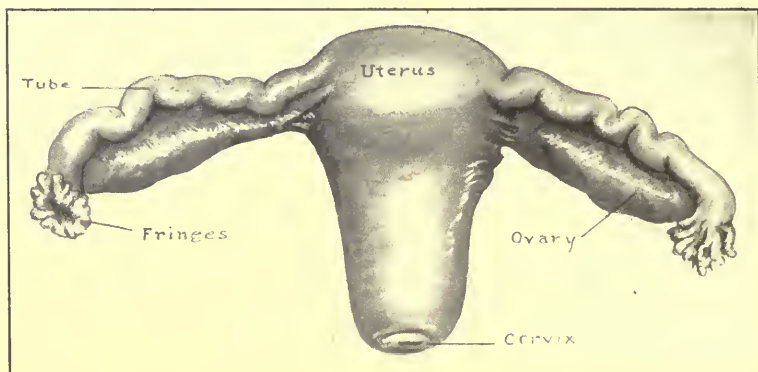


FIG. 117.—Uterus, Tubes, and Ovaries of an Infant One Month Old.

to the pelvis, at birth lying on the psoas magnus muscle in close relation with the internal abdominal ring. They get to their normal situation in the adult soon after birth. It may happen in very rare instances that an ovary may remain in the neighborhood of the kidney and may retain its infantile shape. If it is the right ovary that has failed to descend the cœcum also generally remains high up, in its fetal position.

(b) **Prolapse of the ovary** may occur when from repeated preg-

nancies the ovarian and broad ligaments have been stretched and subsequently not properly involuted, permitting the ovary to sag back into Douglas' cul-de-sac. Also when an ovary is enlarged for any reason and thus gravitates of its own weight to the pelvic floor. Misplacements of the uterus, such as retroversion and retroflexion, are commonly associated with prolapse of the ovaries.

Prolapsed ovaries may be tender to touch, when we may assume that they are the seat of inflammation, *ovaritis*. In this event

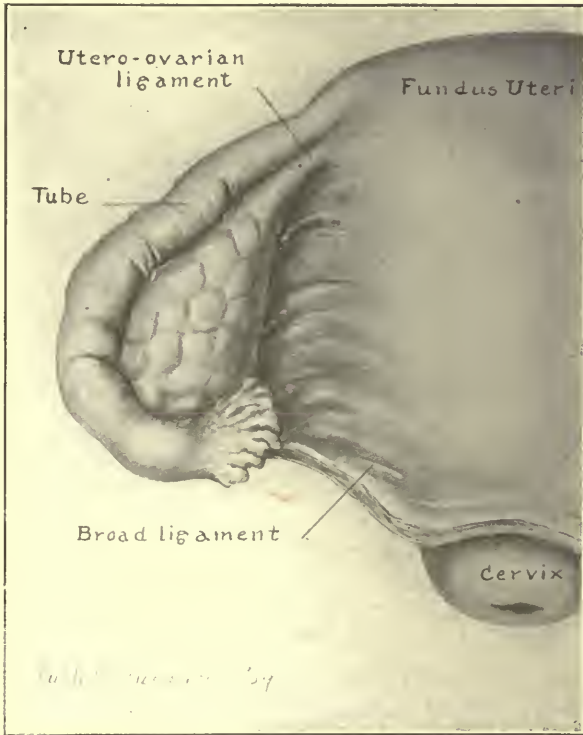


FIG. 118.—Ovary and Tube of a Woman during Sexual Maturity.

they may cause suffering when pressed on during the act of defecation, especially the left ovary, or during coitus. The diagnosis is established by the bimanual touch. Absence of the ovary in its normal situation and its presence at the base of the broad ligament as determined by rectal touch are the diagnostic points. It is often difficult to differentiate a prolapsed ovary from a small scybalous mass in the rectum. In order to do this successfully,

thoroughly cleanse the rectum by enema, and examine a second time. In some cases it is well to use the proctoscope to be sure that the upper rectum is free. If the ovary is tender distinguishing it is easier.

(c) **Hernia of the ovary** is comparatively rare in adults but occurs not infrequently in infants under a year and a half old. It may occupy a hernial sac either alone or accompanied by its Fallopian tube. Ovarian hernia is more apt to occur as an inguinal than as a femoral hernia. Congenital hernia of the ovary is very rare, but it may occur in the early months of infancy because the ovaries and tubes at this time normally lie in close proximity to the abdominal ends of the inguinal canals. (See Fig. 206.) Many cases reported as hernia of the ovary are hydroceles of the canal of Nuck. Hernia of the ovary may occur at any age up to the seventy-third year. The diagnosis can be made definitely only by operation. It is difficult to be sure of the absence of the ovary on one side. A hernia—preferably an inguinal hernia—having a tender body in it, while at the same time the ovary on that side can not be palpated in its normal situation, makes a probable diagnosis.

INFLAMMATIONS OF THE OVARY

Ovaritis may be acute or chronic. The **acute form** occurs in infections following labor or abortion, gonorrhœa, typhoid fever, miliary tuberculosis, the acute exanthemata, or mumps. The ovary is enlarged and congested, the oöphoron or the paroöphoron being involved, or both. The tissues are infiltrated with serum, leucocytes which have escaped from the blood-vessels, and sometimes with blood. If there is a large collection of blood, a *hematoma of the ovary* is formed. *Abscess of the ovary* may be the result of severe grades of inflammation and a tumor which reaches the size of an egg may eventuate. There are apt to be adhesions to the surrounding structures, such as the Fallopian tubes and intestines. The abscess may rupture into the intestine, bladder, or vagina. It has been known in rare cases to break into the general peritoneal cavity, causing fatal peritonitis.

Diagnosis of Acute Ovaritis.—Pelvic pain aggravated by move-

ment of the body or by defecation, and tenderness on pressure in the ovarian regions, are characteristic of a mild attack of ovaritis. Chills and marked elevation of the body temperature are to be expected if suppuration occurs. If there is peritonitis of any extent there will be rigidity of the abdomen and a rapid and small pulse and increased pain. If it is possible to palpate the ovary it will be found enlarged and exquisitely tender. Commonly the rigidity of the abdominal walls prevents exact differentiation of the structures involved. An abscess is usually fixed in a mass of exudate. Fluctuation may be made out by rectal palpation, but

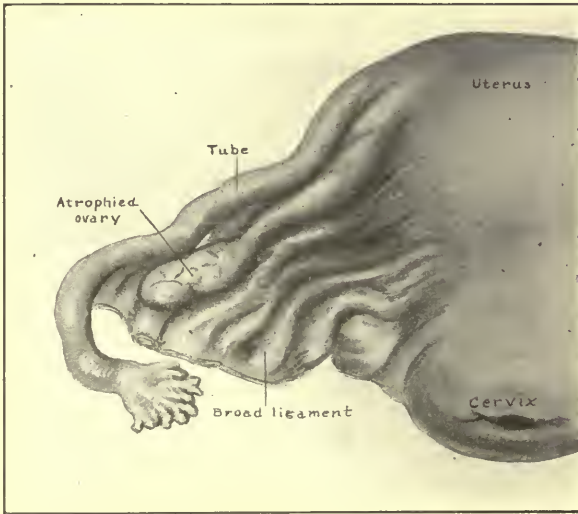


FIG. 119.—Senile Ovary and Tube.

often the wall of the abscess is so thick that this is impossible. In the case of acute ovaritis it is impossible to distinguish exactly between ovaritis and salpingitis. If the disease is right-sided we must, if possible, eliminate appendicitis. The history of the onset is the important point in distinguishing the two. Acute pelvic inflammation is generally preceded by a vaginal discharge or other uterine symptoms such as dysmenorrhea, whereas in appendicitis there is a history of digestive disturbances, such as diarrhea alternating with constipation, or of previous attacks of pain in the right lower abdomen. The pain of pelvic disease is dull and steady and is situated deep in the pelvis, pressure over Poupart's ligament

occasioning great suffering. The pain of appendicitis is sharp and colicky and is higher in the abdomen and is more diffused.

If the appendix happens to be in the pelvis or if there is much peritonitis it is impossible to distinguish the two affections.

Chronic ovaritis may follow an acute ovaritis or it may originate in an infection of the uterus, especially in gonorrhœa. It is also found in the presence of fibromyomata and large ovarian tumors of the opposite side, although the disease is generally bilateral.

The oöphoron is usually affected, the Graafian follicles often becoming enlarged and causing atrophy of the stroma because of their size. Such a condition is called *small cystic degeneration*. In certain cases the entire cortical region of the ovary (oöphoron) is transformed into little cysts containing a clear fluid, the ovum having dis-

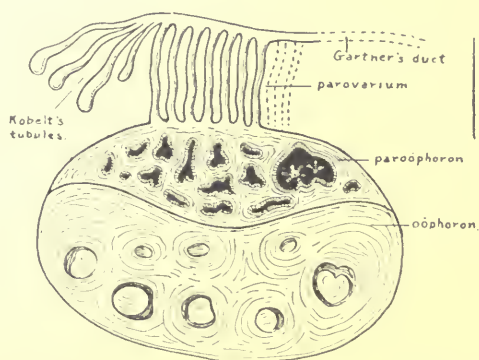


FIG. 120.—Diagram Showing the Cyst and Tumor Regions of the Ovary.
(After Bland-Sutton.)

appeared. Now and then a few normal follicles may be found. In some cases of chronic ovaritis, the stroma and not the follicles is involved. In the late stages of this disease the ovary is found small and scirrhotic with a puckered, uneven surface, as from many scars.

Diagnosis of Chronic Ovaritis.—There is nothing pathognomonic in the symptoms of this disease. There is apt to be pain in the ovarian regions, and scanty menstruation if the ovarian stroma has been destroyed, also dysmenorrhœa. The ovaries may be tender to the touch; often they are not. The bimanual touch may determine follicular enlargement or a nodular feel. In only exceptional cases when all the factors are favorable, more especially at an examination under an anesthetic, can a small cirrhotic ovary be diagnosed.

OVARIAN TUMORS

We have considered already certain states of the ovary that strictly may be classed as tumors, for instance, "small cystic degeneration" and inflammatory conditions with enlargement.

Let us now take up ovarian tumors proper, counting as tumors all enlargements of the ovary greater in size than a hen's egg, using Pfannenstiel's classification based on the origin of the tumor. (Veit's "Handbuch," J. Pfannenstiel, "Die Erkrankungen des Ovarium.")

A. NON-PROLIFERATING CYSTS.

(Follicular cysts; Cysts of the corpus luteum.)

B. NEW FORMATIONS.

I. *Parenchymatogenous Tumors.*

(Tumors arising from germinal or follicular epithelium, or from the ovum.)

1. Epithelial New Formations.

(a) Cystoma serosum simplex.

(Simple cyst.)

(b) Cystadenoma	}	Pseudomucinosum. (Multilocular cysts.) Serosum. (Papillary cysts.)
-----------------	---	---

(c) Carcinoma.

2. Embryomata.

(Tumors springing from the ovum.)

(a) Dermoid cysts.

(b) Teratomata.

II. *Stromatogenous Tumors.*

(Tumors arising from the connective tissue.)

1. Fibroma.

2. Sarcoma.

3. Peri- and Endothelioma.

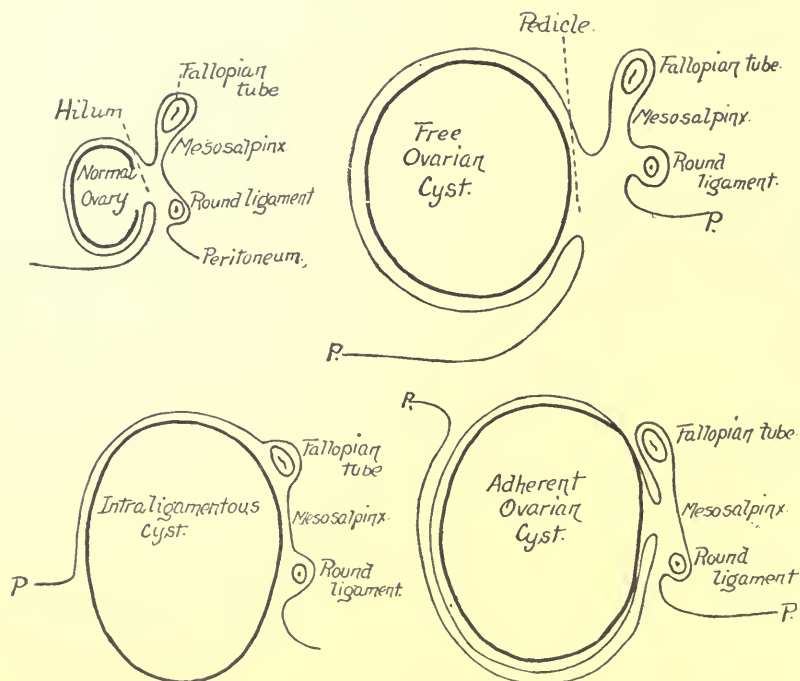
C. MIXED TUMORS.

(Various combinations of the tumor processes enumerated.)

Fig. 120 shows diagrammatically the different portions of the ovary affected by neoplasms.

MODES OF DEVELOPMENT OF OVARIAN TUMORS

The accompanying diagrams indicate the method of development of the pedicle of a tumor and the arrangement of the peritoneum in the case of the normal ovary, a free ovarian cyst, an intraligamentous cyst, and an adherent ovarian cyst. It is plain that the broad ligament, the Fallopian tube, the round ligament,



FIGS. 121-124.—Four Diagrams Showing the Method of Formation of the Pedicle in the Different Sorts of Ovarian Tumors.

and the ovarian ligament are included in varying degrees in the pedicle of a large non-adherent ovarian tumor. Commonly the Fallopian tube is much elongated and spread over the surface of the tumor, the round ligament comes on to the anterior face of the tumor, and the ovarian ligament is much enlarged and lengthened. In the case of tumors developing between the layers of the broad ligament, or of adherent ovarian tumors, the conditions are as shown in the diagram. A parovarian cyst may lie free in the

pelvis attached only by a pedicle formed from the broad ligament, and it is not unusual to find such a cyst as a complication of a small ovarian tumor.

CLASSIFICATION

Ovarian tumors have been generally classified as solid or cystic, and benign or malignant. As will be seen from the classification of Pfannenstiel, such a division is arbitrary and many of the tumors are both solid and cystic, and also benign and malignant. This is shown by careful microscopic examination in the pathological laboratory where a unilocular cyst will be found often to have small cysts in its walls, or trabeculæ in the cyst walls, denoting former subdivisions. Some of the multilocular cysts show papillary masses in certain regions, while in other places small dermoid cysts may be discovered, and even areas of cancerous degeneration.

MALIGNANCY

A *benign tumor* is one which does not tend to recur when extirpated, as well as one which does not implant itself elsewhere or invade the tissues.

A *malignant tumor* signifies a growth which tends to destroy life by invasion of the surrounding tissues as well as one which distributes its elements by metastasis to other parts of the body.

In a general way one may say that the cystadenomata (multilocular cysts), the parovarian cysts, the fibroids of the ovary, and the dermoid cysts are benign; the carcinomata and sarcomata are malignant, and the papillary tumors are on the border land. That is to say, the papillary cystadenomata tend to implant their elements on the surrounding structures, there to grow, but they do not invade the underlying structures as do the carcinomata and sarcomata.

ETIOLOGY AND SYMPTOMS

Ovarian tumors are found most often during the time of sexual activity in the life of women, but may occur at any age. Chiene

and F. B. Lund have each removed an ovarian cyst from a child three months old, and Thornton operated successfully on a woman ninety-four years of age.

It is supposed that the germ of most tumors exists from fetal life and that when the proper stimulant comes the tumor develops.

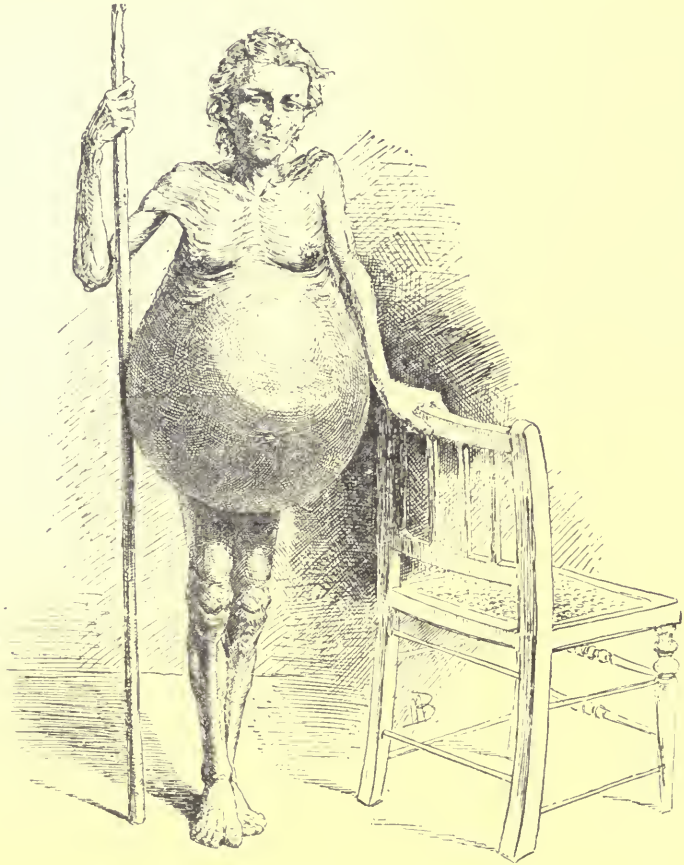


FIG. 125.—Very Large Ovarian Cyst with Characteristic Emaciation about the Chest and "Facies Ovarina." (Kelly.)

The controlling factors are unknown. The symptoms consist, during the early stages of the growth of an ovarian tumor, in the usual *syndromata of uterine disease*, and may be of little moment to the patient, so that her attention is not directed to the pelvis. They are menstrual disturbances,—such as dysmenorrhœa, menor-

rhagia, or scanty menstruation,—a sense of weight in the pelvis, or, if there is peritonitis, pain. When the tumor attains a considerable size, so that it fills the pelvis or rises out of it into the abdomen, there are *pressure symptoms*. These are vesical or rectal tenesmus, frequent micturition, and constipation; in the case of large tumors, edema of the vulva and of the lower extremities caused by pressure on the iliac veins; also hemorrhoids. In rare cases there have been noted albuminuria and suppression of urine from hydronephrosis caused by pressure on the ureters. Other symptoms are jaundice from occlusion of the bile ducts, ascites from pressure obstruction to the portal system, dilated veins in the skin of the abdomen, the occurrence of the white lines in the skin known as *lineæ albicantes*, occasional umbilical hernia, and derangements of digestion and dyspnea.

Pain in the abdomen is a symptom of adhesions, as a rule, and great care should be observed in taking the anamnesis to get the exact situation, character, and duration of the pain. Pain is caused also by traction or torsion of the pedicle and by secondary changes in the contents of the cyst involving adhesions to the sensitive parietal peritoneum.

The facies ovarina is a peculiar facial expression that is pathognomonic of the late stage of large ovarian tumors. It consists of an anxious, careworn look; the face is pale and shriveled, there being wrinkles in the cheeks, and it looks longer; the nostrils are wide and the lips thin, the space between the eyelids and the bony margin of the orbits is sunken. The face does not have that yellowish hue characteristic of the late stages of cancer, nor yet the full appearance of the face of the pregnant woman.

There is also to be noted in large ovarian tumors a loss of flesh over the chest and shoulders, probably of a piece with the atrophy of the face just described.

DIAGNOSIS IN GENERAL

In considering the diagnosis of ovarian tumors it is convenient to divide them into *small tumors*, those that lie wholly within the pelvic cavity proper, and *large tumors*, those that lie for the most part in the abdominal cavity. We will discuss the diagnosis and

the differential diagnosis of each, then take up the complications of ovarian tumors, and finally say something of the diagnosis of the different pathological varieties of tumors, as far as they can be distinguished without operation.

The important factor in the diagnosis of all ovarian tumors is to determine the relation of the tumor to the uterus.

If it can be shown that moving the tumor moves the uterus, or, conversely, that changing the position of the uterus moves the tumor, there is a probability that the tumor is ovarian. On account of adhesions and intraligamentous development, all ovarian tumors are not movable. The tumors of medium size, those that have risen out of the pelvis but have not yet distended the abdominal walls to excessive degree, are easiest to palpate with reference to their connection with the uterus. To perform the palpation to the best advantage, use is made of the bimanual vagino-abdominal touch.

With the forefinger against the cervix, push the tumor in the abdomen or pelvis to one side with a quick movement of the hand on the abdomen. At the same moment the cervix will be felt to move because of the pull on the pedicle of the tumor. Sometimes, but not often, a quick push on the uterus by the finger in the vagina will be transmitted to the tumor, as detected by the hand on the abdomen.

To palpate the pedicle the cervix is grasped by a double tenaculum held by an assistant while the physician practices the bimanual recto-abdominal touch, with two fingers in the rectum. (See Fig. 126, page 301.)

In this way it is possible sometimes to get a good idea of the situation, size, and length of the pedicle of a tumor. As pointed out by John A. Sampson ("Surgery, Gynecology and Obstetrics," 1907, Vol. IV., p. 685), traction on the pedicle of an ovarian tumor causes pain. Also twisting of the pedicle, as determined by operations performed on patients by the aid of local anesthesia, causes pain which is referred to the pelvis on the side on which the pedicle is situated.

DIAGNOSIS OF SMALL OVARIAN TUMORS

Those tumors, which lie entirely within the cavity of the true pelvis, are diagnosed by the bimanual touch, both vagino-abdominal

and recto-abdominal. In the case of the small tumor it is difficult to make out the characteristics of the pedicle. One determines this in some cases as described above. We try to ascertain the position, size, form, and density of any given pelvic tumor; then its relation to the uterus. If the tumor is small there is a likelihood that the uterus can be placed and its size and shape defined by touch. In the larger tumors, those filling the pelvis, such palpation is difficult or impossible. In this event the sound must be passed to determine the location and relative size of the uterus. As a rule, ovarian tumors are round. This is always the case with the cysts, the solid tumors being generally, but not invariably, round. A fluctuating consistency can be made out in most cases of cysts. A small-sized ovarian cyst is to be looked for in the situation of the ovary, and is movable (rarely adherent); an intra-ligamentous cyst lies to one side and behind the uterus, and is immovable. A cyst may lie in front of the uterus, rarely, and, of course, there may be two ovarian tumors, one on each side.

Differential Diagnosis of Small Ovarian Tumors

We must rule out.:

1. Ovaritis.
2. Subperitoneal fibroid.
3. Parovarian cyst.
4. Hydrosalpinx, hematosalpinx, and pyosalpinx.
5. Encapsulated peritonitis, or inflammatory exudate.
6. Echinococcus cyst.
7. Extra-uterine pregnancy.
8. Early normal pregnancy, or cornual pregnancy.
9. Distended urinary bladder.

1. **Ovaritis.**—Tumors of the chronic form of ovaritis are seldom larger than a pigeon's egg, but the acute form resulting in abscess may be of considerable size. Here there is fever, and the tumor is of recent occurrence, an acute affair. The tumor is tender, and there is pelvic peritonitis in varying degree of intensity as evidenced by rigidity of the abdominal walls. Also there is generally a history of infection.

2. **Subperitoneal Fibroid.**—The differentiation in this case is often

a difficult matter and depends entirely on the findings from palpation. The consistency of an ovarian cyst is softer than that of a subserous fibroid. As a rule, the fibroid is more intimately allied with the uterus, and in many cases the pedicle is short and thick or the growth is sessile. It helps in the diagnosis if other fibroid nodules can be distinguished in the substance of the uterus, for fibroids are apt to be multiple. The coexistence of ovarian cyst and fibroid is not an uncommon occurrence.

In the case of an *interstitial fibroid* the uterus should be enlarged and menorrhagia is apt to be a symptom; the passage of the sound will show an increased depth of the uterine cavity.

If, by any chance, both normal-sized ovaries can be palpated, the tumor is a uterine fibroid.

3. Parovarian Cyst.—Parovarian cysts are generally relatively small in size, therefore they are put here. They may be large, however. The cyst arises from the epoöphoron, is generally unilocular, and has a thin wall, with clear serous contents. It is situated between the tube and ovary and is intra-ligamentous in growth; therefore, when the cyst has developed the tube is on its upper surface and the ovary below it. In extremely rare cases the ovary may be palpated by the finger in the vagina on the under surface of the cyst. As a rule, the differential diagnosis can not be made.

4. Hydrosalpinx, Hematosalpinx, and Pyosalpinx.—The accumulation of serous fluid, blood, or pus in the Fallopian tube gives it a more or less characteristic shape. This is a strong diagnostic point. A pyriform swelling with its small end at the uterine horn is indicative of a dilated tube. In the case of hydrosalpinx and hematosalpinx there is, as a rule, no complicating peritonitis, therefore the diagnosis is easier than in the case of pyosalpinx, which is apt to be surrounded by exudate. Hydrosalpinx and hematosalpinx never reach the great size of exceptional cases of pyosalpinx. It is unusual for any variety to be more than an inch and a half (3 cm.) in diameter or five inches (12 cm.) long. The hydrosalpinx has a thin wall, and fluctuation can be determined without much difficulty; pyosalpinx has thick walls because of inflammatory action in the tube and also in the peritoneum surrounding it, and it is not easy to make out fluctuation.

5. Encapsulated Peritonitis.—If a quantity of serous or purulent

exudate in the case of pelvic peritonitis, or a quantity of ascitic fluid becomes encapsulated by peritoneal adhesions, the condition may be mistaken for a cystic tumor of the ovary. Such a condition is relatively rare, however. Generally there is evidence of tuberculosis or carcinosis or actinomycosis of the peritoneum and the manifestations of the disease in the general cavity of the peritoneum overshadow those in the pelvic cavity. Such circumscribed collections of fluid in the pelvic cavity have an irregular shape and are not often round. Also fluid is apt to be present in other portions of the peritoneum.

6. Echinococcus Cyst.—Echinococcus cyst of the pelvis is rare. Primary echinococcus disease of the ovary is unknown, but it occurs in the following situations in the pelvis: (a) the uterus, (b) the mesometrium, (c) the pelvic bones, (d) the omentum, and (e) the Fallopian tubes. Also downward extension of hydatid disease of the liver may reach the pelvis. Echinococcus cyst is round and fluctuates; but, as a rule, is more distended and has thicker walls than an ovarian tumor, and it is generally densely adherent to the surrounding structures. Bland-Sutton ("Surgical Diseases of the Ovaries and Fallopian Tubes," 1891, p. 183) says that a "peculiar sign—hyatid fremitus—can sometimes be obtained by placing the palm of the left hand upon the tumor and sharply percussing with the finger of the right. It is a peculiar tremor or thrill, only felt over a hyatid cyst." In this country hydatid disease is very rare.

7. Extra-Uterine Pregnancy.—This gives a history of pregnancy. Before rupture there is a boggy fluctuating or elastic tumor at the side and back of the uterus. It is the shape of a distended tube. Look for purple discoloration of the vagina with increased discharge, and for changes in the breasts together with uterine enlargement and softening of the cervix, also pain on moving the cervix. About the time of intra-abdominal rupture of the pregnant sac the endometrium casts off a modified decidua of pregnancy with more or less uterine hemorrhage. At the time of rupture the symptoms are those of intra-abdominal hemorrhage and are urgent. There is a fulness in the cul-de-sac with abdominal distention, rapid, feeble pulse, severe pain in the abdomen, and collapse. If in a chronic case a hemocele has formed, there is a boggy mass in the cul-de-sac, generally filling the pelvis, the uterus being in

front. There may be a history of repeated attacks of pain recurring at irregular periods.

8. Normal Pregnancy.—Early normal pregnancy, particularly if the pregnancy begins in one horn of the uterus, may be mistaken for ovarian cyst. It should not be forgotten that the two conditions frequently coexist. First, the history indicates pregnancy. Inquire for amenorrhœa and morning nausea and whether there has been coitus. The uterus in pregnancy is anteflexed, there is bulging of the lower uterine segment anteriorly, the uterine tissues have a peculiar elastic feel and are compressible by bimanual touch (Hegar's sign; see Fig. 178). The cervix is soft and there are increased vaginal discharge and purplish discoloration of the anterior vaginal wall and introitus vaginae, noticeable as early as the sixth week in some instances, though usually not quite so early. The breasts are full, the veins showing in the skin; the areolæ are pigmented and show enlargement of the follicles. There may be secretion from the breasts. In the case of pregnancy in one horn of a bifurcated uterus the history of pregnancy is to be obtained. There is no bulging of the lower uterine segment, but the other signs of pregnancy are the same. There is no fluctuation in the pregnant uterus until the stage of "ballottement." This is not available as a diagnostic sign until the twenty-first week of pregnancy when there is sufficient fluid in the amnion and the fetus is heavy enough to give the characteristic feeling as the fetus bobs about when jostled by the sudden impact of the examiner's finger in the vagina.

9. A Distended Urinary Bladder.—If the rules for the preparation of the patient for an examination have been observed (see Chapter IV., page 23) it will have been learned that the patient has been unable to urinate, and therefore a catheter has been passed. It sometimes happens that a patient is unable to speak the language or is unconscious, and the question of ovarian tumor arises. It is safe to pass the catheter if there is the slightest doubt that the bladder is empty. Upon palpation the full bladder is not so movable as an ovarian cyst, as a rule, and the uterus is retroverted under the bladder. Dribbling of urine is apt to be a symptom of an overfilled bladder.

cian may be able to distinguish the situation and characteristics of the pedicle. (See Fig. 126, page 301.)

Inspection.—Inspection of the abdomen of a woman having a moderately large ovarian tumor will show the enlargement most pronounced on the side from which the tumor has sprung. This is not the case with very large tumors. As a rule the enlargement is in the lower portion of the abdomen. B. C. Hirst (“Diseases of Women,” Second Edition, p. 539) has seen three cases in which an ovarian tumor was in the upper abdomen—twice due to tight lacing and once to the fact that the tumor was elevated in preg-

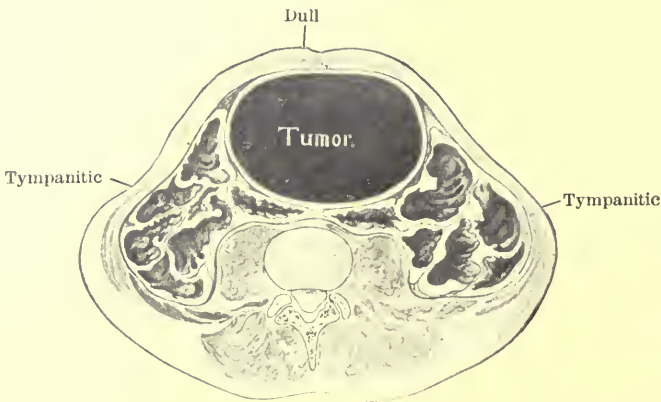


FIG. 127.—Diagram of a Cross Section of the Body in the Case of an Ovarian Tumor.

nancy, became adherent to the liver, and did not descend with involution of the uterus.

When the tumor has been long existent we expect to find the *facies ovarina* and loss of flesh about the chest and shoulders. Unless ascites is present or the tumor is excessively large, there is no bulging in the flanks.

Palpation.—Palpation usually shows a fluctuating tumor, more distinctly felt on the affected side. The elasticity will depend on the sort of tumor present, and on the tenseness of the cyst. If the tumor is very tense it may feel like a solid mass. It is rare for solid tissues to predominate in ovarian tumors. Nodules may be felt and loculi of a multilocular tumor if the abdominal walls are thin. If the walls are very tense or thick it is necessary often to

administer an anesthetic before a satisfactory examination can be made. The mobility of the tumor depends on the length of its pedicle, the relation between the size of the tumor and the size of its abdomen, and the presence of adhesions.

By means of the bimanual vagino-abdominal or recto-abdominal touch it may be possible to determine that the uterus is not enlarged and is separate from the tumor, and the pedicle may be mapped out by traction on the uterus. Also the connection of the tumor may be made plain by moving the tumor suddenly, the im-

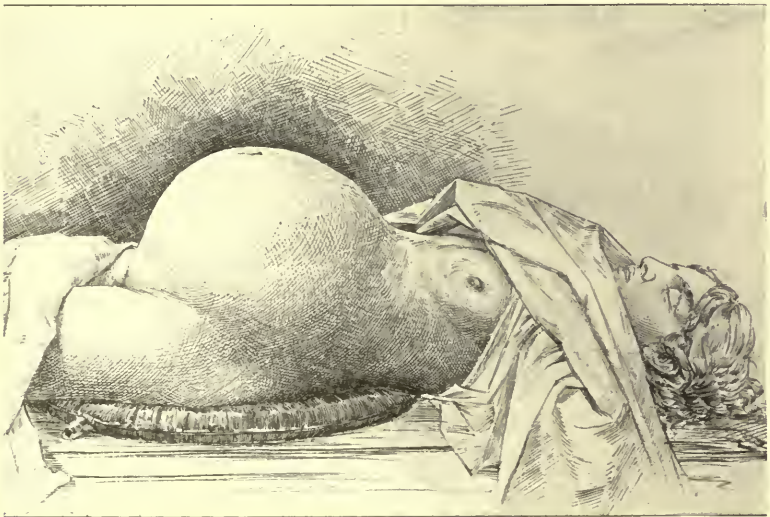


FIG. 128.—Large Parovarian Cyst Seen in Profile. (Kelly.)

pulse transmitted to the uterus being appreciated by the finger in the vagina or rectum.

Percussion.—With the patient in the dorsal position the tumor occupies the lower anterior portion of the abdomen. The intestines, held by their mesentery, are nearer the diaphragm and at the sides of the tumor; therefore tympanitic resonance is found in the epigastrium, flatness over the tumor, and dullness or modified resonance in the flanks. These areas of resonance, flatness, and dullness do not change with change in the position of the patient, as regards the side position or the standing position. If the tumor contains fluid, a *percussion wave* may be elicited by placing a hand on each side of the abdomen and then tapping with the finger of

one hand. A vibration will be felt by the opposite hand. If the abdominal walls are very fat the fat may transmit a wave by itself; therefore, to eliminate this fat wave have an assistant place a hand with the ulnar edge down along the middle line of the ab-

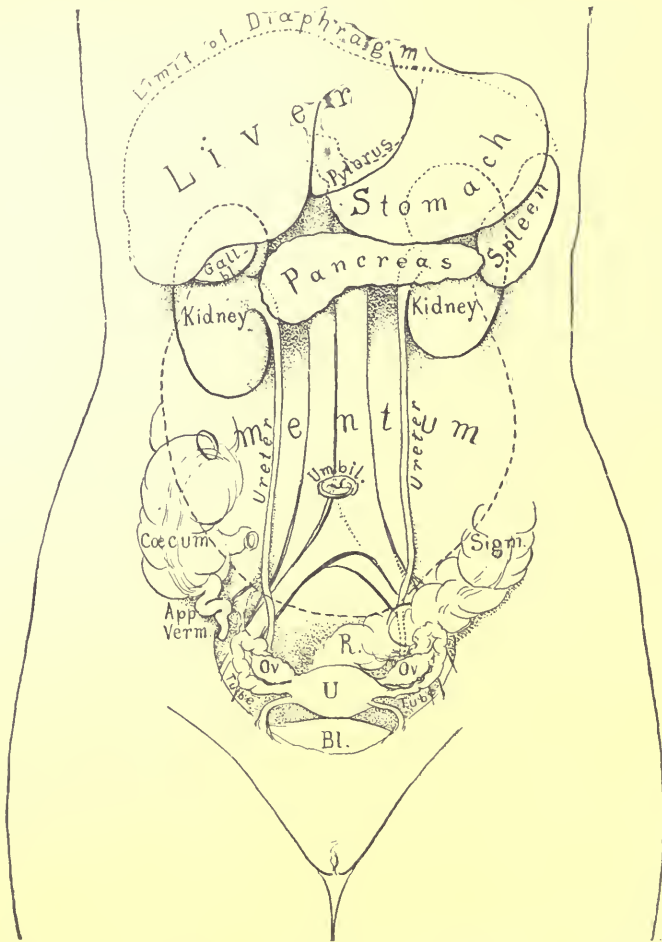


FIG. 129.—The Various Abdominal Organs from Which Tumors May Arise. (Kelly.)

domen and press firmly. If the fluid in the cyst is thick, as in dermoids, the percussion wave may be slight or absent.

Measurements.—Measurements of the abdomen show an increase or decrease in the size of a tumor from time to time. They are

made with a tape measure at some definite point, as about the body at the umbilicus, or at the anterior superior spines of the ilia. Other measurements are, the distance from the tip of the ensiform cartilage to the upper margin of the symphysis pubis and a measurement made with the pelvimeter, the patient being in a standing position, from the upper apex of Michaelis' rhomboid area on the back over the sacrum, to the most prominent point of the tumor. These measurements must be taken each time with the patient in exactly the same position, whether standing or on the side and always with the bowels free.

Aspiration or tapping an ovarian tumor is never justifiable as a means of diagnosis, and *exploratory incision* is to be practiced only when it is impossible to make a diagnosis and all the preparations have been made for a complete operation.

Differential Diagnosis of Large Ovarian Tumors

We must rule out:

1. Pregnancy.
2. Ascites.
3. Fibroids.
4. Accumulations of gas or fecal matter in the intestines.
5. Fat or tumors in the abdominal walls, including "Phantom Tumor."
6. Cyst of the pancreas.
7. Tumors of the spleen, liver, and kidneys.
8. Cyst of the omentum.
9. Echinococcus cysts.
10. Dilated stomach.
11. Distended urinary bladder.

1. Pregnancy.—It should be assumed, until the contrary has been proven, that every abdominal enlargement in a woman is due to pregnancy. In this way many embarrassing mistakes will be avoided. The diagnosis of early pregnancy has been considered in treating of the small ovarian tumors. Advanced pregnancy is to be excluded by the history. It is possible to have amenorrhea in ovarian tumor, especially where both ovaries have become dis-

organized by the disease affecting them, but it is unusual. Morning nausea and vomiting during the early months, or salivation and heartburn and swelling of the breasts, are characteristic of pregnancy. Sometimes these symptoms have occurred at a given time with previous pregnancies. Ask whether they have been observed this time since the patient first noticed the enlargement of the abdomen.

Quickening is usually noticed at the end of the sixteenth week of pregnancy. The signs of pregnancy in the later months are

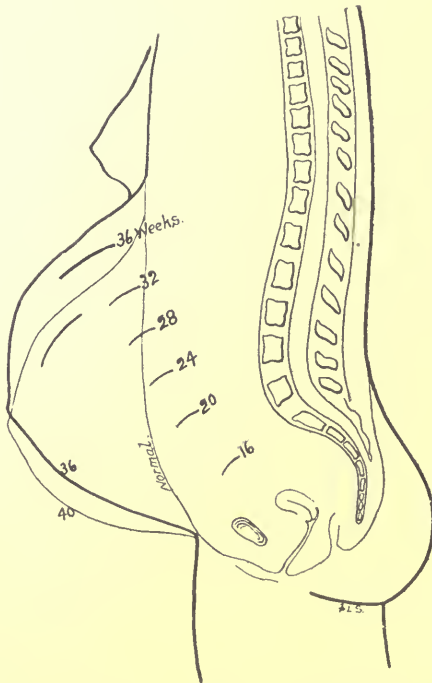


FIG. 130.—The Height of the Fundus Uteri at the Various Weeks of Pregnancy (After Zweifel.)

softening of the cervix, increased vaginal discharge, ballotement after the twenty-first week. Fluctuation in the uterus is very indistinct unless the liquor amnii is in excess and the uterine walls are thin from any cause. By careful palpation the intermittent rhythmical contractions of the pregnant uterus may be felt as early as the fourth month. A good deal of patience, gentleness, and skill are necessary to get this sign. Purplish discoloration

of the vulva and anterior wall of the vagina are to be made out from the sixth to the twelfth week. If milk or colostrum can be squeezed from the breasts it is an important indication of pregnancy.

Fetal heart sounds can be heard after the twentieth week, and fetal movements can be felt after the sixteenth week unless the fetus is dead. The tumor has developed relatively rapidly; there is pigmentation of the areolæ of the nipples, and of the linea alba in some cases; edema of the ankles is not uncommon after the

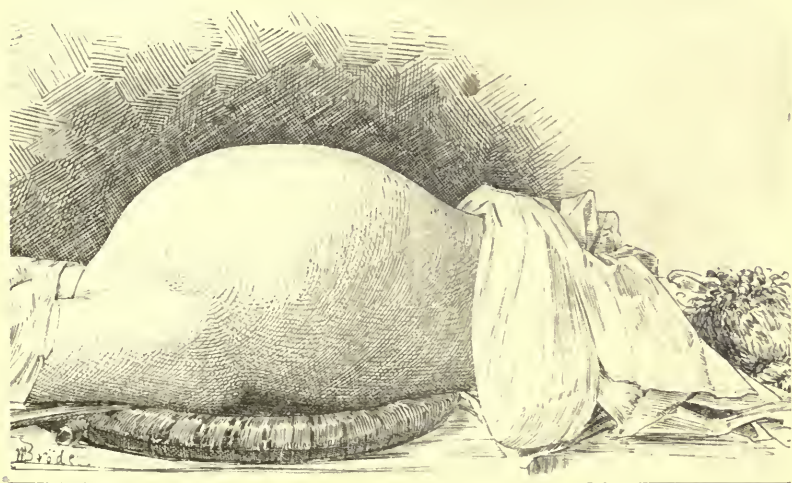

FIG. 131.—The Abdomen of Ascites Seen in Profile. (Kelly.)

seventh month; the face shows sometimes the facies uterina, a fullness about the eyes and front of the cheeks.

In the case of an ovarian tumor there is no softening of the cervix; the tumor is distinct from the uterus and is of gradual development; there is no ballottement and there are no fetal heart sounds or movements; also there is absence of pigmentation of the areolæ and the linea alba; edema of the ankles is rare, except after a tumor has existed several years; the superficial veins of the abdomen are enlarged, and the facies ovarina is present in the case of long-existing tumors.

Hydrammios, an excess of amniotic fluid, has led many a surgeon to diagnose ovarian cyst. A careful study of the history, symptoms and signs of pregnancy and ovarian tumor ought to make

differentiation relatively easy and sure. In ovarian cyst the tumor is of less rapid development, there is no ballottement, and the tumor is more on one side than the other, and, most important, it is distinct from the uterus.

2. **Ascites.**—An accumulation of fluid in the peritoneal cavity may accompany an ovarian tumor, and in such a case the diagnosis is difficult, and may be settled exactly only at the operation undertaken for the removal of the tumor.

The following table, taken from Dudley's "Gynecology," with modifications, gives the points which serve usually to distinguish ascites from ovarian cyst.

<i>Ascites.</i>	<i>Large Ovarian Cyst</i>
1. Previous history of disease of kidneys, heart, or liver, or peritoneum.	1. No such history
2. Enlargement comparatively sudden.	2. Gradual.
3. Face puffy; color waxy; early anemia.	3. <i>Facies ovarina</i> , anemia relatively late.
4. With patient in dorsal position symmetrical enlargement of abdomen, bulging in flanks and flat on top.	4. Asymmetrical until tumor is very large, peaked on top.
5. With patient sitting the abdomen bulges below.	5. No change.
6. Navel prominent and thinned.	6. Navel unchanged usually.
7. Fluctuation decided and diffuse throughout abdomen, but is absent in the highest parts. Modified on change of position.	7. Less distinct and limited to the cyst. Not modified by change in position of patient.
8. Intestines float on top of liquid, therefore percussion gives a tympanitic note in the upper portions and flatness in the flanks when patient is on her back. Change in position changes position of intestines and of resonance to the highest part of the abdomen.	8. Intestines occupy same position all the time. No change in percussion with change in position of patient, <i>i.e.</i> , flat over cyst and resonant above it and to one side, the side opposite to that from which the cyst sprung.
9. Vaginal palpation shows bulging into the posterior cul-de-sac.	9. No bulging into the cul-de-sac.
10. Uterus prolapsed, but size and mobility unchanged.	10. Uterus displaced by the cyst, mobility limited by the tumor.

Encysted ascites, or fluid confined to a limited part of the abdominal cavity by adhesions, may give the same areas of dullness and resonance as an ovarian cyst.

3. **Fibroids.**—There is considerable danger of confusing a large fibromyoma of the uterus with a large ovarian cyst. The following table, compiled from several authors and from my own experience, points out the chief features in the differential diagnosis:

Large Uterine Fibroid.

Large Ovarian Cyst.

1. Menorrhagia or metrorrhagia common where the growth is interstitial in part.

2. General health not necessarily impaired, except anemia from loss of blood or debility from pain. Palpitation of heart common.

3. Rarely occurs in early life.

4. Slow growth.

5. Apt to be asymmetrical and nodular; tumors commonly multiple.

6. Consistency firm, elastic, or hard.

7. Uterus large and cavity enlarged if growth is interstitial. Tumor a part of uterus or connected by a short and thick pedicle.

8. Uterine bruit by auscultation in half of the cases.

9. No change in facial expression unless pale from hemorrhage.

10. Superficial veins of abdomen not enlarged.

1. Menstruation unchanged or diminished in amount.

2. General health impaired early. No pain except in the case of adhesions, or other complications. Palpitation uncommon.

3. May occur in infancy.

4. More rapid growth.

5. Symmetrical; may be lobulated.

6. Fluctuating.

7. Uterus not enlarged. Tumor connected with it only by pedicle, which is apt to be relatively long.

8. Absent.

9. Facies ovarina and loss of flesh about neck and chest.

10. Veins enlarged.

It must not be forgotten that because of degenerative processes in a uterine fibroid there may be fluid in the tumor and fluctuation will be found, and that in some of the ovarian tumors with solid contents fluctuation may be absent. As stated before, it is never justifiable to tap a tumor, a procedure once much in vogue for the purpose of diagnosis, because some of the fluid is almost sure to escape into the peritoneal cavity and to cause peritonitis of a grade and severity depending on the character and amount of fluid extravasated.

4. **Accumulation of Gas or Fecal Matter in the Intestines.**—Tympanites has been mistaken for ovarian cyst. Accumulated gas gives a tympanitic note on percussion, the gurgling of gas in the bowels may be heard by auscultation, and there is an absence of a fluid wave on palpation. By the vaginal touch there is an

absence of the firm elasticity communicated by a fluid or solid tumor. In the case of fecal accumulation there is a history of chronic constipation and the distended bowel will pit on pressure by abdominal or vaginal touch. Active catharsis removes the tumor.

5. Fat or Tumors in the Abdominal Walls, including "Phantom Tumor."—A thick panniculus adiposus may simulate an ovarian tumor and, strange as it may seem, well-known surgeons have operated for tumor under such conditions. Grasping the abdominal walls in the hands, it is possible in most cases to determine that the fat is in the substance of the wall rather than in the abdominal cavity. Edema of the abdominal walls sometimes simulates

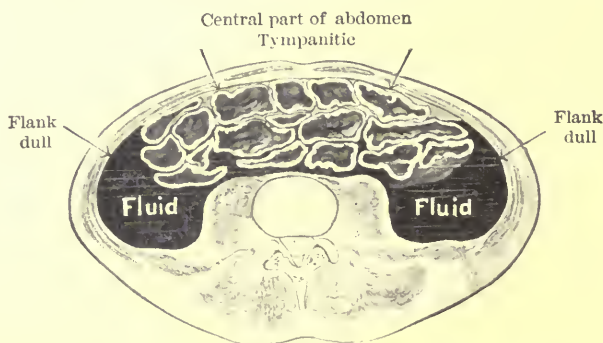


FIG. 132.—Diagram of a Cross Section of the Abdomen of Ascites, Dorsal Position.

tumor. In this case we expect to find pitting on pressure and evidences of edema elsewhere.

Tumors of the anterior abdominal walls consist of fibromyoma of the rectus muscle and cysts of the urachus. They are of uncommon occurrence.

Fibromyoma of the Rectus.—Two instances of this have fallen under my observation. Both patients were twenty-nine years of age and mothers of families. One was seen with Dr. F. W. Johnson, of Boston, in consultation, March 18, 1892, and operated upon by him the same day in my presence. Here there was a tumor of soft consistency, the size of a Florida orange, in the left epigastric region. The other was a patient operated upon by me October 23, 1896. In this case there was a somewhat smaller tumor of harder consistency in the right rectus muscle, just below the level of the umbilicus.

Both were entirely extraperitoneal and were pronounced by the pathologist to be fibromyoma.

Cysts of the urachus develop in the normally impervious cord which runs from the bladder to the umbilicus. Like the bladder itself, a cyst of the urachus represents a persistent portion of the allantois. A cyst as large as the urinary bladder, or larger, may form in the course of the urachus. Such a cyst is situated between the fascia and the peritoneum on the inside of the abdominal parietes, in the median line. It is to be differentiated from an ovarian cyst by its absence of connection with the uterus or its appendages, by the greater area in the abdomen of, intestinal

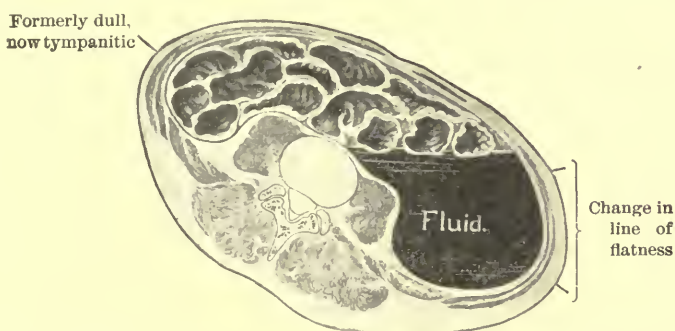


FIG. 133.—The Same as Fig. 132. Lateral Position, Showing Change in Situation of Areas of Dullness and Tympany.

resonance, and by the absence of the other signs and symptoms of ovarian cyst.

“*Phantom Tumor.*”—Phantom tumor occurs occasionally in hysterical women who have the power of contracting the muscles of the abdomen so as to form a mass that simulates an abdominal tumor. The muscular contraction can be overcome sometimes in these cases by firm pressure of the hands and the tumor then disappears. There is exaggerated tympany over the tumor because the intestines, held by the muscles, form the tumor. In many cases it is impossible to make an exact diagnosis without etherization, and accordingly it is well to etherize a doubtful case of phantom tumor or tumor in the abdominal wall.

6. **Cyst of the Pancreas.**—The situation of the tumor is of great importance in differentiating cyst of the pancreas from ovarian cyst. The former develops under the margin of the ribs on the left

side and grows from above downward. If the cyst is large the liver and stomach may be displaced upward, while the transverse colon is depressed under the tumor, the cyst reaching the pelvis only exceptionally in the case of very large tumors. Therefore a pancreatic cyst can be confused only with high-lying ovarian cyst. Pancreatic cysts generally are thin-walled and the fluid is thin, consequently fluctuation is marked. The greatest convexity of the abdomen is in the neighborhood of the umbilicus. The history given by the patient is that the tumor was high up under the ribs when first noticed, and bimanual examination of the pelvic organs shows that there is no connection between the uterus and the tumor and that the ovaries are not enlarged.

7. Tumors of the Spleen, Liver, and Kidneys.—*Tumors of the spleen* originate, of course, in the left hypochondrium, have an oblique position, and a peculiar elastic consistency. Under the influence of degenerative processes or the presence of an echinococcus cyst there may be fluid in a splenic tumor. Such a condition must be regarded as very unusual, however. In the case of *wandering spleen* the tumor may be in the iliac fossa, and may be mistaken for an ovarian tumor or a kidney. Careful palpation of such a tumor with the aid of an anesthetic will show one or more notches in the anterior border and perhaps a vertical slit at the hilum. Palpation of the kidney regions will show the presence of the kidneys in their normal situation. It has been suggested by H. A. Kelly (Kelly and Noble, "Gynecology and Abdominal Surgery," Vol. II., p. 597) that by passing a renal catheter and injecting the kidney with enough fluid to produce a mild renal colic, the pain will be referred to the lumbar region and not to the splenic tumor. Examination of the pelvic organs ought to exclude uterus, tubes, and ovaries from participation in the tumor. A wandering spleen has been known to become lodged in the pelvis and there to obstruct the intestine (case of Körte, cited by J. Bland-Sutton, *Brit. Med. Jour.*, 1897, p. 132), and J. C. Webster (*Jour. Amer. Med. Assn.*, 1903, Vol. XL., p. 887) has reported a case of wandering spleen that occupied the right iliac fossa.

Tumors of the liver may be confused with ovarian tumors if they reach downward to the pelvis, or if during late pregnancy an ovarian tumor has become fixed to the liver by adhesions, so that upon involution of the uterus the tumor remains in the upper

abdomen. The firm, hard consistency of the liver is more or less characteristic, also its sharp lower border, which is placed obliquely to the ensiform cartilage and is indented with a notch for the gall bladder. Also, all liver tumors move more or less on deep respiration, except accessory lobes, very large tumors, and echinococcus disease. The pelvic organs are investigated and the relation of the tumor to the liver tested by moving the tumor about and noticing if the liver is moved also.

Tumors of the kidney are not of frequent occurrence. The most common are: hypernephroma and papillary cystoma. Malignant tumors affect especially the young and the old. Hematuria is present in almost all malignant tumors of the kidney; pain in the region of the kidney is a less common symptom. *Hypernephroma* is a tumor arising from adrenal tissue but involving the kidney in practically all instances. The tumor is lobulated and extends toward the median line. It is malignant and has metastases, most commonly in the lungs and liver.

Polycystic disease of the kidney consists of a cystic degeneration of the kidney parenchyma, and the tumor is like a bunch of grapes. Many of these tumors are congenital. Congenital kidney disease is apt to be associated with disease of the ovaries, as the two develop together in fetal life. Echinococcus cysts develop in the kidney in 5.8 per cent of all cases of hydatid disease. The tumor grows slowly and forms a smooth, round, movable mass.

A movable kidney may get as low as the pelvis. Its shape is characteristic. Hydronephrosis may accompany renal tumor and in this case the urine will show abnormal constituents.

Cystic tumors or simple cysts of the kidney arise in the outer part of the cortex, and may attain great size. Such a cyst is to be differentiated from an ovarian cyst by its location in the flank, its relative immobility, and by its not being connected with the uterine organs as proved by the bimanual examination. If the uterine organs are normal the differentiation is easier than if they are diseased.

8. Cyst of the Omentum.—Cysts of the omentum are mostly flat and shield-shaped; they are very freely movable, and can be rotated so that in some cases the posterior portion of the cyst may be palpated. They are of infrequent occurrence, and it is generally easy to determine that the cyst has no connection with the uterine organs.

9. **Echinococcus Cysts.**—Echinococcus disease may be confused with ovarian tumor especially if it involves structures in the pelvis. It has been referred to as occurring in the liver, spleen, and kidneys. In the pelvis it occurs in the following situations according to Bland-Sutton ("Diseases of Women," Bland-Sutton and Giles, p. 388): (a) The uterus; (b) the mesometrium; (c) the pelvic bones; (d) the omentum; (e) the Fallopian tubes. There is no authentic case on record of primary echinococcus cyst of the ovary. Large tumors may develop in any of the structures named. As a rule, they form part of a general invasion of the subperitoneal tissues. The colonies are apt to communicate with the vagina, bladder, or rectum and the characteristic vesicles escape with the urine or feces. Bland-Sutton says, "The clinical recognition of echinococcus cysts in the pelvic organs, mesometrium, or bones is sometimes made by a sort of 'lucky guess' when other and more common diseases can with certainty be excluded. Occasionally when a patient seeks advice for pelvic trouble, and brings 'vesicles' which have escaped by the rectum, vagina, or urethra, much speculation is spared. When the bones are eroded and swellings form under the skin, they are punctured, and characteristic fluid with vesicles and hooklets escapes, and so the diagnosis is established. When the cysts suppurate the physical signs are those of abscess."

10. **Dilated Stomach.**—Careful percussion of the stomach area, auscultation of the abdomen while the patient swallows a mouthful of water, the appreciation of a gurgling sound all over the region occupied by the stomach, and the situation of the maximum of enlargement of the abdomen above the umbilicus, ought to determine the presence of a dilated stomach. If there is a doubt administer an effervescent mixture and practice percussion when the stomach is distended with gas.

11. **Distended Urinary Bladder.**—The bladder may rise as high as the umbilicus when overdistended and may present the appearance of an ovarian cyst. (See Fig. 85, page 217.) The bladder tumor is in the median line, close held to the back of the arch of the pubes; it bulges into the vagina, distending the anterior wall; there is almost continuous overflow of urine, and generally hypogastric distress, except where the patient is unconscious or the distention has existed a long time. Passing the catheter removes all doubt.

DIAGNOSIS OF THE COMPLICATIONS OF OVARIAN TUMORS

The complications to which ovarian tumors are subject are:

1. Adhesions and incarceration.
2. Intraligamentous development.
3. Torsion of the pedicle.
4. Infection and suppuration.
5. Degenerative processes, including malignancy.
6. Rupture.
7. Association with pregnancy.

1. Adhesions and Incarceration.—Adhesions between an ovarian tumor and its surrounding structures make the diagnosis much more difficult, especially in the case of small ovarian tumors, those lying wholly within the cavity of the pelvis. The history of attacks of inflammation may give a clew to the presence of adhesions, as the occurrence of pain. It is a well-known fact that the parietal peritoneum rather than the visceral peritoneum is the seat of pain. This fact has been demonstrated during abdominal operations performed under local anesthesia. Therefore we should expect adhesions to the parietal peritoneum to cause more pain than those to the viscera. Extensive adhesions may occur without any pain whatsoever.

Fixation of a tumor to a greater or less degree indicates adhesions as a rule. The exception is the rare condition of *incarceration without adhesions*. A tumor may become incarcerated in the pelvis, thus causing obstruction of the bowel, or abortion as in the case of the retroflexed pregnant uterus.

An attempt should be made to dislodge an ovarian tumor fixed in the pelvis, by putting the patient in the knee-chest position, letting air into the vagina by means of the Sims speculum, and by making traction on the cervix with a tenaculum. Upward pressure on the tumor, the patient being in the dorsal position, through either the vagina or rectum will, in many cases, dislodge a non-adherent tumor. After reposition the bimanual palpation and the mapping out of the pedicle proceed with greater facility. Sometimes the shape and character of adhesions in the pelvis can be made out by touch, also adhesions to the abdominal walls in the case of large tumors can be determined in a smaller proportion of

cases. Adhesions to the intestines, omentum, liver, or spleen can not be diagnosed with certainty.

2. **Intraligamentous Development.**—If a tumor has grown between the layers of the broad ligament it is immovable and can not be displaced into the abdominal cavity by bimanual manipulation. It gives the impression of being closely united with the uterus and the examiner may receive the impression that he has to do with a fibroid tumor of the uterus. Intraligamentous tumors are generally cystic, however; they have no pedicle and sometimes may be differentiated from parovarian cysts by this characteristic.

If the physician can decide that an immovable cystic tumor in the pelvis is connected not only with the uterus but with *the side*

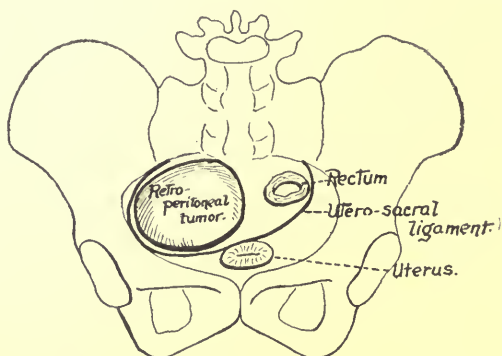


FIG. 134.—Diagram Showing the Course of the Utero-sacral Ligaments in the Case of a Retro-peritoneal Tumor.

of the uterus the tumor is probably an intraligamentous ovarian cyst. This may be done sometimes by grasping the uterus and palpating it separately from the tumor. The uterus is commonly displaced laterally to the side of the pelvis opposite to that occupied by the tumor. Occasionally the ovary with its long Fallopian tube stretching to it as a cord may be made out lying on the top of the tumor, and now and then the round ligament can be palpated as a round cord coming over the surface of the tumor to the internal abdominal ring.

To distinguish a tumor developing under the peritoneum in the back of the pelvis from an intraligamentous tumor one tries to palpate the utero-sacral ligaments. If these are in front of the tumor it is a retro-peritoneal growth, whereas if the ligaments

are behind the tumor it is an intraligamentous neoplasm. (See Figs. 134 and 135.)

3. Torsion of the Pedicle.—Rotation of an ovarian tumor on its long axis causing twisting of its pedicle is by no means an uncommon happening. It presupposes the absence of adhesions to surrounding fixed structures such as the pelvic walls or the parietes of the abdomen. It is more apt to occur in tumors of medium size. To detect a twisting by palpation of the pedicle where all the conditions are most favorable is a possibility. Ordinarily torsion is diagnosed only by its results. The twisting may be gradual, in which case the tumor adjusts itself to the lessened blood supply caused by the constriction of its pedicle, or it may be rapid.

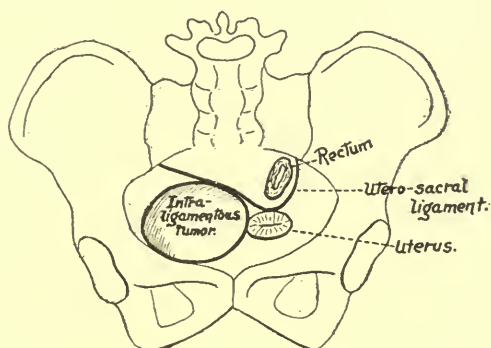


FIG. 135.—Diagram Showing the Course of the Utero-sacral Ligaments in the Case of an Intra-ligamentous Tumor.

Whether gradual or rapid there comes a time when the blood supply is cut off, then ensue in the cyst edema, enlargement, suppuration, or even gangrene. Atrophy has been known to occur in the case of very small tumors and complete separation of the cyst from its pedicle in rare instances. Torsion is apt to be followed by adhesions, especially adhesions to the bowels.

Symptoms of the chronic stage of torsion may be entirely wanting, or a patient may complain of pains in the abdomen especially at the time of the catamenia when congestion of the pelvic organs is normally greatest. These pains may be associated with nausea and vomiting and are apt to follow violent exertion or trauma. If the twisting is sufficient to cause blood stasis the symptoms are those of general peritonitis and there is present an acute abdominal

emergency. Acute abdominal pain, rapid, feeble pulse, vomiting, elevation of temperature, and a rigid abdomen occurring in a woman known to have an ovarian tumor are symptoms calling for immediate operation.

Twisting of a pedicle of an ovarian tumor has been mistaken for *appendicitis*. Bimanual examination will reveal the presence of the ovarian tumor; the pain caused by torsion is not of the colicky character of the pain of *appendicitis*. Finally the history reveals no similar attacks of pain and no history of digestive disturbances and irregularity of the bowels as in the case of *appendicitis*.

4. Infection and Suppuration.—Infection of ovarian tumors with streptococcus, typhoid bacillus, or bacterium coli communis, is transmitted by the blood current, or from the intestine, urinary bladder, or the Fallopian tube. Formerly, when it was the custom to tap ovarian cystomata, infection was introduced very frequently in this way. Ovarian cysts become infected following an attack of typhoid fever, and in this case the bacilli, in all probability, gain entrance through the blood. A patient known to have an ovarian cyst should be watched carefully for evidence of infection of the cyst following an attack of typhoid fever. The symptoms are chills, elevation of temperature, rapid pulse, pain, and tenderness in the abdomen.

The Fallopian tube is a very frequent carrier of infection to an ovarian tumor. This is to be inferred because it is about the fimbriated end of the Fallopian tube that the densest adhesions are to be found during operation for the removal of infected cysts. It is probable that infection following puerperal fever reaches a tumor by this channel. In the case of an inflamed bladder or intestine or vermiform appendix the organ may become adherent to a tumor and the inflammatory process be carried to the growth by continuity. The inflammatory process, however transmitted, may go on to *suppuration*. In this case there are to be noted sudden enlargement of the cyst, severe pain and tenderness, rapid and weak pulse, and chills, high temperature, and exhaustion. Prompt operation alone will prevent rupture or general peritonitis and death. Gas may be formed in the cyst and then a tympanitic note will be given to the percussion over it.

5. Degenerative Processes Including Malignancy.—The following secondary changes may take place in an ovarian tumor, although

none of them can be diagnosed with certainty. On account of the necessity of speedy operation indications of malignancy require special attention, however.

(a) Calcareous degeneration.

(b) Fatty degeneration.

(c) Myxomatous degeneration.

(d) Changes in the fluid contents from straw color—with specific gravity of from 1010 to 1050—to thick or semisolid, of various colors and consistencies.

(e) Malignant degeneration. Carcinoma, sarcoma, endothelioma, and teratoma are the malignant processes affecting ovarian tumors. Suspicion of malignity attaches to double-sided tumors, *i.e.*, tumors of both ovaries, and to partial development in the broad ligament. Ascites is common in the case of malignant tumors, and is apt to be small in amount except in the late stages of the disease. Malignant tumors, except sarcoma, are most apt to occur in old rather than in young women, and cachexia is found in the later stages only. Early edema of the legs in the case of small tumors is said to be a sign of malignancy. When the disease has attacked the surface of the tumor hardness of the tissues and a nodular feeling by both abdominal and vaginal palpation is most characteristic. The nodules or lumps may be large or small. The surface is irregular. It should not be forgotten that cancer of the ovaries is very often metastatic and that the primary seat of the disease should be sought in the stomach or intestine.

6. Rupture.—Rupture of an ovarian cyst is of unusual occurrence, especially in these days of relatively early operation on women who have tumors. In the older, preaseptic days, when the danger of operation was great, many cysts ruptured and filled again or caused peritonitis as it happened. The physician and also the nurse should remember that a thin-walled cyst or one having weak places in its walls because of degenerative processes may be ruptured by a too vigorous bimanual examination or by preparations for an abdominal operation. Both of these accidents have occurred in my experience. In the case of a multilocular cyst only one loculus may rupture and the rupture may be into the main cyst cavity, into another loculus, or into any one of the following structures: peritoneal cavity—most frequent—and bladder, vagina, or rectum. Rarely rupture has occurred into the small intestine, or

Fallopian tube, and very rarely through the abdominal wall or into the stomach. The causes of rupture are, degenerations of the cyst wall; papillomatous growths penetrating the wall; torsion of the pedicle, causing hemorrhage or suppuration in the cyst with increased tension; and trauma, such as blows on the abdomen, careless handling, already referred to, or contractions of the abdominal walls in labor. Parovarian cysts when once ruptured may not refill. In the case of ovarian cysts the wall continues to secrete fluid after rupture and the cyst may refill or the fluid may be poured into the organ into which the opening has been made. If the fluid is clear and serous it may cause little irritation of the peritoneum; if, on the other hand, it is colloid or dermoid in character it is apt to set up a lively peritonitis. The gravity of rupture depends then, in large measure, on the character of the cyst contents. This being unknown, the complication must be regarded as serious and treated by immediate operation, for rupture of an infected cyst into the peritoneal cavity is usually fatal.

The symptoms are severe pain in the abdomen, faintness, rapid pulse, perhaps subnormal temperature. Examination shows absence of the tumor and free fluid in the peritoneum, or discharge of fluid from bladder, vagina, or rectum, or other viscus. If only one loculus has been ruptured the tumor will be diminished in size only by so much.

7. Association with Pregnancy.—Small or medium-sized tumors are more often found in association with pregnancy. Because of the danger of rupture and torsion of the pedicle, the diagnosis of pregnancy in these cases is of the greatest importance. In the early months it is a question of determining the presence of more than one growth in the pelvis or a tumor on each side, one being the uterus and the other the ovarian tumor. The signs of pregnancy are referred to in Chapter XXII., p. 420. If physicians would make it a rule to examine all pregnant women under their care from time to time with reference to the detection of tumors and other abnormalities, many of the tragedies of the puerperium would be avoided. In cases of doubt it is advisable to administer ether in order to make a diagnosis.

DIAGNOSIS OF THE DIFFERENT PATHOLOGICAL VARIETIES OF OVARIAN TUMORS

The different kinds of ovarian tumors according to their pathological characteristics are shown in the list on page 291. Prognosis and treatment depend in a measure on the kind of tumor present; therefore, certain probabilities may be stated as to the different tumors. The following description is taken with few changes from Winter's "Gynaekologischen Diagnostik," p. 303.

1. Follicular cysts never occur larger than a base-ball. They are unilocular, have thin walls, and are not tightly distended, so that fluctuation can be elicited easily. They are generally unilateral and do not cause pain.

2. Cysts of the corpus luteum are not larger than a base-ball; they have thick walls, and are unilateral.

3. Simple cysts have thin walls and thin fluid contents, and are differentiated clinically from follicular cysts only by their greater size.

4. Multilocular cysts are the most common kind of ovarian tumors. They vary in size from very small to enormous. In the beginning such a tumor is round, but becomes irregular in shape by the development of several cysts within the parent cyst. Therefore, the surface becomes lobulated and in some cases the large and small daughter cysts can be palpated. The consistency varies according to the fluid contents. Hard portions are apt to be found in the walls where there has been no cystic degeneration. The small or multilocular tumors are fairly movable; the larger ones are limited in motion by adhesions, which are common, especially to the omentum, bowel, and abdominal wall, seldom to the uterus or other pelvic organs. These tumors are usually unilateral and have a well-marked pedicle. Ascites is generally absent; when present it is in small amount.

5. Proliferating papillary cysts are seldom larger than a man's head. They are not often perfectly round in shape and have an uneven, lumpy surface. In the situations where the papillary masses occur the consistency is not so fluid as elsewhere. The tumors are apt to affect both ovaries—double tumor; they are of intraligamentous development, at least on one side, and are often

partially, but not entirely, in the broad ligament. When the papillary masses have pierced the wall of the tumor there are metastases in different parts of the abdomen, especially in Douglas' cul-de-sac. Ascites is common.

6. **Primary carcinoma**, when small, retains the form of the ovary; when large, the tumor has a surface that is very rough because of knobs and excrescences. Small tumors are hard, large ones are cystic because of degenerative processes inside. The pedicle is for the most part short, and the tumor may be intraligamentous. The tumors are generally double and ascites is commonly present. Early edema of the legs is to be looked for in the case of small tumors, and cachexia in the late stages. Metastases occur early. Secondary carcinoma attacking a cyst has the same characteristics.

7. **Dermoids** are seldom larger than a man's head and most often between a hen's egg and a Florida orange in size. They are round and oval in shape and are seldom double, having for contents thick fluid, fat, bone, and hair; fluctuation is not marked. Sometimes bone may be felt in the wall of the cyst, and often there are portions of solid tissue in dermoid cysts. These cysts are of slow development and occur most often in young persons. Adhesions are common and occasionally the tumor adheres so closely to the intestine that there is gas in the tumor. The x-rays may show the bone in a tumor.

8. **Teratomata** are apt to be the size of a man's head and occur mostly in young subjects. Their consistency is solid, often hard, and they may contain nodules of varying consistency. If the tumor is malignant there are metastases and ascites. The clinical diagnosis can seldom be made.

9. **Fibroma** of the ovary is a round or oval tumor, very hard, with smooth surface and generally unilateral. It may be as large as a man's head and ascites is usually present. Often cystic cavities develop in such tumors, and the ascites does not return after the tumor has been removed. Fibroma can not be distinguished clinically from fibrosarcoma.

10. **Sarcoma** of the ovary occurs as *fibrosarcoma* (spindle-celled sarcoma) and as *round-celled sarcoma*. The former is generally double, has a smooth surface and a hard consistency, and ascites is present. It is benign, and no metastases are formed. The *round-celled sarcoma*, on the other hand, occurs as a soft, medullary

tumor with tolerably smooth surface. It is generally unilateral and ascites is often present and the tumor may be of considerable size. The tumor elements perforate the surface early and infiltrate the neighboring organs, especially the abdominal cavity.

II. Peri- and endothelioma have the same characteristics as round-celled sarcoma.

CHAPTER XVIII

THE DIAGNOSIS OF DISEASES OF THE FALLOPIAN TUBES

Anatomy and age changes, p. 324.

Congenital Anomalies, p. 326: Absence of the tubes, p. 326. Accessory tubes and ostia, p. 326. Diverticula from the tube, p. 326. Hernia of the tube, p. 326. Displacement and elongation of the tube, p. 326. Cyst of Morgagni, p. 327.

Salpingitis, p. 327: Acute, p. 327. Chronic, p. 329. Gonorrheal, p. 330. Tuberculous, p. 330. Actinomycotic, p. 332. Echinococcus infection, p. 332. Syphilitic, p. 332.

Retention tumors (Sactosalpinx), p. 332. Pyosalpinx, p. 332. Hydro-salpinx, p. 333. Hematosalpinx, p. 334. Diagnosis of Sactosalpinx, p. 335.

Differential diagnosis of Appendicitis and Salpingitis, p. 336.

New Growths, p. 337: Polypus, p. 337. Papilloma, p. 337. Embryoma, p. 338. Myoma and fibroma, p. 338. Fibromyxoma, p. 338. Carcinoma, p. 338. Sarcoma, p. 339. Chorioepithelioma, p. 339.

ANATOMY AND AGE CHANGES

THE Fallopian tubes are developed from the portion of Müller's ducts lying above the round ligaments, and as they come from the same structures as the uterus and vagina they are continuous with these organs and their canals, and are parts of one long tube, branching, when it reaches the uterine horns, into two tubes. (See Fig. 71, page 198.)

Each tube occupies the free border of the broad ligament. It has an average length of four inches (10 centimeters) but may vary; sometimes one tube is longer than its fellow. The inner third of the tube is narrow and is from one-sixteenth to one-eighth inch (2 to 4 millimeters) in diameter; it is called the *isthmus*. The outer two-thirds is larger in diameter, three-eighths inch (7 to 8 millimeters), is called the *ampulla*, and ends in the *infundibulum*, or trumpet-shaped depression, in the center of which is the *ostium abdominale* surrounded by the *fimbriae*, or fringes. These fringes are extensions of the reduplicated mucous membrane lining the tube and are of uneven length. Running from the abdominal

ostium to the ovary is the *tubo-ovarian ligament*, traversed by a furrow so that it appears to be a long fimbria. This represents the uppermost portion of Müller's duct that has been opened out, instead of remaining as a closed tube. The tube is convoluted, the isthmus is directed outward and slightly upward; while the ampulla arches over and descends, so that the infundibulum is directed toward the ovary and the fimbriæ are in contact with that gland. (See Fig. 116, p. 285.)

The lumen of the tube varies from the diameter of a bristle at the isthmus to a quarter of an inch (some 5 millimeters) in the ampulla. It is lined with mucous membrane, and covered with columnar ciliated epithelium, which is reduplicated and thrown into longitudinal folds. These folds become thicker as they approach the infundibulum and on the abdominal side of the ostium are continuous with the fimbriæ. The tube is composed of unstriped muscle fiber, continuous with that of the uterus, and arranged in an outer longitudinal layer and an inner circular layer. Outside the longitudinal layer is loose connective tissue between it and the peritoneum, which covers two-thirds of the circumference of the tube and is terminated by a sharp edge at the ostium abdominale.

The function of the tubes is to carry the ova to the uterus. It has been shown by Hofmeier and Mandl (J. Whitridge Williams, "Gynecology and Abdominal Surgery," Kelly and Noble, Vol. II, p. 132) that there is a current of fluid from the peritoneum, or secretion from the tubal mucosa, promoted by the cilia of the tubal epithelial cells, from the abdominal ostium of the tube to the internal os of the uterus. It has been proved by experiments on animals and a few observations on human beings that a few hours after coitus spermatozoa can be found in the outer portions of the tubes and even on the ovaries, so that it would appear that the spermatozoa get into the tubes in spite of the current against them, and that the tube is the normal place of impregnation rather than the uterus. Under normal conditions the fertilized ovum is passed along by the cilia to the uterus where it becomes embedded in the uterine mucosa. Under abnormal conditions it is arrested in the tube and a tubal pregnancy results.

At the menopause the Fallopian tubes atrophy, becoming shorter and narrower and the epithelial elements disappear, so that in the

old woman they are nothing but slender cords, often having no lumen. (See Fig. 119, p. 289.)

CONGENITAL ANOMALIES

Absence.—Complete absence of both tubes is exceedingly rare and occurs only in connection with failure or rudimentary development of the uterus. Absence of one tube is found in cases of failure of development of the corresponding uterine horn. Partial development of the tube is more common than complete absence, the tube being represented by a narrow, impervious cord, or a portion of the tube only may be implicated, and the isthmus may be normal while the ampulla is undeveloped or atypical, or vice versa. The diagnosis can not be made without an abdominal operation.

Accessory tubes have been described not infrequently. Probably many of them are not true cases of extra tubes but accessory ostia, a much more common condition. Three reporters at least have given instances of true double tubes, and Nagel (Veit's "Handbuch," Bd. I.) found a double Müllerian duct in a human embryo.

Accessory ampullæ communicate with the main lumen of the tube, usually entering near the attachment of the mesosalpinx. Each has its own infundibulum and fimbriæ. As many as six accessory ostia have been reported; one or two are not uncommon.

Diverticula of the walls of the tube appearing as herniæ occur occasionally, and, like the supernumerary ostia, are of importance because they may be lodging-places for fertilized ova, and thus a cause of tubal pregnancy. This anomaly, as also the preceding, can not be diagnosed except at operation.

Hernia.—The tube is found sometimes with the ovary in a hernial sac. Such herniæ are generally of the inguinal variety and unilateral. The condition is not susceptible of diagnosis before operation.

Displacement and elongation of the tube may be congenital or acquired. The tube is displaced to a greater or less degree with displacements of the ovary and uterus, and also, in the case of large ovarian tumors and large tumors of the broad ligament, it is both displaced and elongated. In pregnancy it becomes lengthened enormously as the uterus approaches its size at full term and after labor the tube involutes with the uterus to regain its normal size.

Sometimes, where the conditions for examination are most favorable, *i.e.*, very thin abdominal walls or separation of the recti, it is possible to palpate an elongated Fallopian tube coursing over a tumor or at the side of a pregnant uterus. Generally the diagnosis can not be made.

The cyst or hydatid of Morgagni is a small cyst rarely larger than a pea, attached by a stalk one to one and a half inches (some 2 to 6 centimeters) long, to the fimbriæ or to the tube itself. It is entirely harmless and has no clinical importance.

SALPINGITIS

Salpingitis is the chief disease of the Fallopian tubes of interest to the practising physician.

The classification of salpingitis from an etiological standpoint is difficult because it is impossible to distinguish the different sorts of bacteria that serve as exciting causes. The streptococcus and the gonococcus are the two most important microorganisms. It is probable that in those cases where the pus in the tubes is sterile the inflammation was originally of streptococcic origin but that the organism has died out. These organisms are transmitted to the tubes through the uterus, an endometritis being an almost invariable precursor of a salpingitis. The tubercle bacillus is a not infrequent cause of salpingitis, and rare causes are actinomycosis, eelinoecoccus disease, and syphilis. Hemorrhagic salpingitis may accompany the exanthemata, and there is a mild catarrhal form of salpingitis and perisalpingitis of unknown origin that occurs as a complication of uterine tumors.

It is possible for fluids injected into the uterus to pass into the tubes, especially when the tubes have been hypertrophied by pregnancy and when the normal tonus is not present, and thus set up a salpingitis, though this is an academic affair. The lumen of the isthmus of the tube is very small and the irritation caused by foreign fluids sets up a contraction of the circular fibers so that it is seldom that fluid can be made to pass through.

Salpingitis may be divided clinically into acute and chronic.

Acute Salpingitis.—*Pathology.*—In the case of *catarrhal salpingitis*, in the early stages of an acute attack the mucous membrane is

swollen so that the redundant folds fill the lumen of the tube. The muscular and peritoneal coats are involved to a greater or less degree and the entire tube is reddened; the tissues are edematous and soft. According to the character of the infecting agent the inflammatory process extends or does not to the ovary and neighboring structures of the peritoneum through the ostium abdominale. Apparently sometimes the swelling of the mucosa in the tube is sufficient to close the ostium and the disease is limited to the tube itself. In the tube accumulates a certain amount of serous fluid, drainage into the uterus being interfered with by the swelling of the mucosa in a very small canal.

In the case of *purulent salpingitis* all the processes are intensified. The mucous membrane is more swollen and injected; the entire tube is much enlarged and there is pus in its canal. The peritoneal covering of the tube is involved, and, either by direct extension of the inflammation through the wall of the tube, or because of the action of the pus that escapes from the ostium of the tube, adhesions of the ampulla to surrounding structures,—bowel, omentum, bladder, or uterus, are formed. The mesosalpinx and broad ligament are infiltrated so that they have a board-like feeling.

Symptoms.—The symptoms of *acute catarrhal salpingitis* are so slight that they are overshadowed by the symptoms of the co-existing endometritis. (See page 174.) The symptoms of *acute purulent salpingitis*, on the other hand, are often severe, consisting of abdominal pain, fever, rapid pulse, uterine hemorrhage, dysuria and painful defecation, and purulent vaginal discharge. According to the amount of localized peritonitis are the symptoms more urgent. Where the infection involves the ovary and a tubo-ovarian abscess results the symptoms and signs are those of pelvic abscess. (See page 193.)

Diagnosis.—The history is that of endometritis (see page 174) and preceding infection. In the *catarrhal* form palpation by the bimanual touch may reveal tenderness of the tube, but this is a fine point in diagnosis. In the *purulent* form, not only tenderness but thickening of the tube may be evident. It is especially to be cautioned that the utmost gentleness be used because of the danger of expressing pus from the ostium of the tube into the peritoneal cavity.

Evidences of endometritis are also present. If there is much

distention of the tube in the subacute stage the tube may be made out as a sausage-, club-, or retort-shaped body, and it is apt to be in the cul-de-sac of Douglas. (See Pyosalpinx.) Acute purulent salpingitis is a very common affection and the attempt should be made to diagnose the disease early in its course.

Chronic Salpingitis.—*Pathology.*—Chronic salpingitis results from an acute salpingitis. The tube is usually closely adherent to the ovary and surrounding structures; it is apt to be in the cul-de-sac of Douglas; it shows marked convolutions and twists. The walls of the tube are generally thickened and indurated. Sometimes the thickening is in the isthmus, and at others in the ampulla. Now and then one finds nodules the size of a small pea in the structure of the wall of a tube (salpingitis nodosa), these being found generally in the isthmus. On section they show a dense fibromuscular structure containing glandlike spaces, which sometimes represent the lumen of the tube. Tubes containing these nodes are apt to be impervious. The condition is not to be confused with nodular tuberculosis of the tube.

The ostium of the tube is commonly closed by peritonitic adhesions or exudate in cases of chronic purulent salpingitis, but often on separating the adhesions it will be found that the fimbriæ are free and the ostium is patent. It is probable that these are the cases in which, upon the subsidence of the inflammation and the absorption of the exudate in the peritoneum, the ostia become pervious again. In many cases, especially those due to gonococcus infection, the fimbriæ are found adherent and there is true occlusion of the ostium.

In the case of chronic salpingitis infection from the tube may be transmitted to the ovary, and a tubo-ovarian cyst or tubo-ovarian abscess may result, or the process may be limited to the tube, salpingitis proper.

Symptoms and Diagnosis.—The symptoms are pains in the groins, a sense of weight in the pelvis, exacerbations of fever, irregularity of menstruation, dysmenorrhœa, and vaginal discharge. The diagnosis is made by palpating enlarged tubes, by the presence of preceding and coincident endometritis, and by symptoms of pain and fever not accounted for by the endometritis.

Salpingitis due to the streptococcus is less apt to affect both tubes than is the gonorrhœal variety.

Gonorrheal Salpingitis.—As a rule it is a long time, months or years, before the gonococci of an endometritis reach the tubes, although they have been found in the tubes within two weeks after the initial infection; therefore the disease is generally described as being subacute or chronic from the start.

The disease is usually bilateral and may be ushered in by a chill, fever, and local tenderness and pain. In the more chronic stages the amount of tenderness is variable and may be wanting, there is generally no fever, and the patient may be in fair health except for anemia and debility; but during the menstrual periods there are dysmenorrhea, local tenderness, irregularities of menstruation, and increased vaginal discharge as troublesome symptoms. Acute attacks of inflammation are apt to occur in the history of chronic gonorrheal salpingitis and whenever a drop of pus escapes into the peritoneal cavity there is inflammatory reaction.

As previously stated, the ostia of the tubes are more apt to be closed by gonorrheal than by streptococcic inflammation, thus accounting for the sterility of prostitutes.

Diagnosis.—Unless the gonococci can be found in the discharges from the uterus there is no way of distinguishing this form of salpingitis from any other. The probabilities may point in this direction from a history of gonococcus infection, from the occurrence of gonorrheal joint affections, or from evidences of past inflammation in the vaginal or inguinal glands.

Tuberculous Salpingitis.—The Fallopian tube is the most frequent site of genital tuberculosis in the female. Where careful routine microscopical investigations have been made of all the clinical material furnished by the operating-rooms of hospitals it has been found that from five to ten per cent of all the inflammatory affections of the tubes are tuberculous. Without painstaking investigations it is impossible often to distinguish tuberculous from simple salpingitis.

The disease may be primary in the tubes (it is generally bilateral) or secondary to a lesion or lesions at a distance, as in the lungs, or in a contiguous organ, such as a tuberculous ulcer of the intestine. The tubercle bacillus may come to the tube from the vagina by way of the uterus, or from the blood current. The infection may be limited to the tubes, or both uterus and tubes are involved.

It is possible, and not a very uncommon happening, for the gonococcus to be associated with the tubercle bacillus.

Pathology.—Tuberculosis of the tubes appears in three forms, *miliary*, *caseous*, and *fibrous*. The appearances of the tube vary according as the disease began in the mucous membrane lining its cavity or in the peritoneal coat. The tube may be atrophied or much enlarged and tortuous and a part or the entire tube may be affected. Microscopically tuberculous nodules are found. These consist of a central giant cell surrounded by epithelioid cells and an outer zone of small round cells. Caseous foci are common and the folds of the mucosa are thickened and adherent. The lumen of the tube may be closed by a hyperplastic process affecting the mucosa just as in the swelling which accompanies infections by

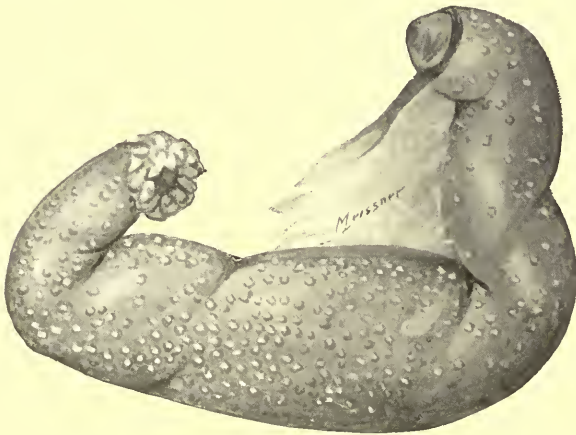

FIG. 136.—Tuberculous Salpingitis. (Dudley.)

other organisms. The disease generally is progressive, but may be arrested, the tube being represented in such cases by a thin, impervious, fibrous cord. If the disease progresses one expects to find tuberculosis of the peritoneum.

Diagnosis.—Tuberculous salpingitis is seldom seen in an early stage when the diagnosis can be only that of salpingitis. A tuberculous history or tuberculosis elsewhere in the body leads one to suspect the etiological significance of a salpingitis and sometimes in the later stages fluid in the peritoneum calls attention to tuberculosis. Pyrexia, recurring every evening and disappearing

every morning, loss of weight and strength, rapid pulse, sweating, particularly at night, are symptoms of tuberculosis.

Actinomycotic salpingitis is secondary to actinomycosis elsewhere, besides being very rare. The tubes are converted into abscesses in which the characteristic yellow or brownish-black, sago-like granules are readily recognized. Under the microscope the actinomyces is recognized in the characteristic granulation tissue.

Echinococcus infection is extremely rare also, and is secondary to hydatid disease in the broad ligament or elsewhere in the pelvis. Sometimes, but not always, pelvic hydatids are secondary to hydatid disease of the liver or other abdominal organ. Cases have been reported of tubes enormously distended by hydatids. The diagnosis would rest on the discovery of the disease in some neighboring organ or the passage of cysts from the vagina, rectum, or bladder.

Syphilitic salpingitis must be regarded as a very rare disease. It has been found in the new-born and extremely rarely in the adult. The tubes contain miliary gummata in their walls, and the folds of the mucosa are adherent. In one case in an adult, gummata the size of hazelnuts were found. The diagnosis is made probable by finding evidences of syphilis in other situations in the body, by the history of syphilis, and by the presence of an enlarged tube.

RETENTION TUMORS OF THE TUBE, OR SACTOSALPINX

Pyosalpinx is a Fallopian tube distended with pus. The tube varies in size and shape. With moderate distention it is club-shaped, having a number of convolutions; with more distention it is retort-shaped with the stem of the retort at the uterine horn; here the convolutions are more or less eliminated. With extreme distention the tube becomes an oval sac. These large tubes are uncommon. The largest ones I remember having met were in the case of a woman twenty-three years old, upon whom Dr. Clement Cleveland operated with my assistance January 20, 1890. The patient had been married one year and had not been pregnant. She had very few symptoms. The right tube measured six inches in length, and three inches in diameter at its outer end, and one and three-fourths inches at its inner end. Three inches of the

isthmian end of the tube were not enlarged. This tube had comparatively few adhesions about it. The left tube measured four inches in length, and three inches in diameter, and the surrounding adhesions were dense. Each was ovoid in shape and showed no convolutions.

As a rule a pus tube is surrounded by adhesions, because its peritoneal surface is enveloped in an inflammatory membrane. The pus is sterile in over half of all cases. This fact is explained by the dying out of the microorganisms which have caused the inflammation and are always to be found in the acute and subacute cases. The walls of a pyosalpinx are generally thick, but they may be thin.

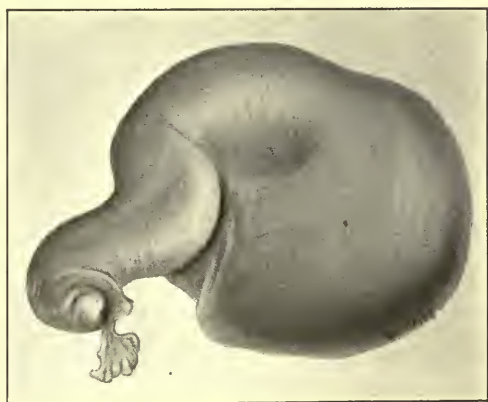


FIG. 137.—Pyosalpinx.

In the older cases the epithelial lining of the tube has been replaced by granulation tissue. Rupture into the peritoneal cavity is an accident which has occurred, although not very commonly. C. W. Bonney (*Surgery, Gynecology, and Obstetrics*, Nov., 1909, p. 542) collected forty-five cases, including the cases from the literature and a case of his own. In most instances there was no assignable cause for the rupture. Whenever infection has set up an abscess of the ovary as well as a pyosalpinx the condition is known as a *tubo-ovarian abscess*. This has been described under Pelvic Abscess. (See Chapter XII, page 193.)

The diagnosis of pyosalpinx will be considered with the diagnosis of hydrosalpinx and hematosalpinx.

Hydrosalpinx is an accumulation of serous fluid in the tube. It

presupposes complete closure of the ostium abdominale, but not necessarily the lumen of the isthmus of the tube, and is the result of a preëxisting salpingitis. In *intermittent hydrosalpinx* there is a temporary obstruction to the uterine outlet of the tube caused by kinks in the isthmus, that is, a mechanical stenosis exists. In such cases there is a periodic discharge of watery fluid through the uterus. The shapes of tubes, the seat of hydrosalpinx, are the same as those of pyosalpinx, but the walls are thinner and on microscopic examination are seen to be practically normal, except in the case of *follicular hydrosalpinx*, in which there are evidences

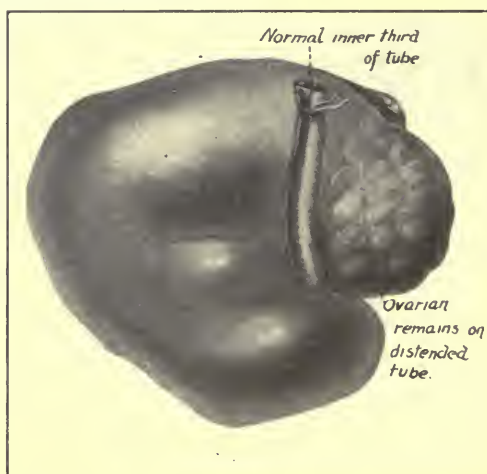


FIG. 138.—Hydrosalpinx, Two-thirds Actual Size. (Author's Case).

of endosalpingitis. Hydrosalpinx is seldom larger than a Bartlett pear, although cases have been reported the size of a child's head. The ampulla of the tube is dilated with fluid more often than the isthmus. If an ovarian cyst connects with a distended tube by an adventitious opening not the ostium abdominale, the condition is known as a *tubo-ovarian cyst*. These cysts are by no means uncommon, and can not be distinguished clinically from hydrosalpinx, except in those rare cases of hydro salpinx in which the normal ovary can be palpated by bimanual touch.

Hematosalpinx is a Fallopian tube distended with fluid blood. Hemorrhage occurring into a hydrosalpinx forms a hematosalpinx. It is now believed that a majority of cases of hematosalpinx are

the result of tubal pregnancy and incomplete abortion. (See Tubal Pregnancy.) Hematosalpinx presupposes closure of the ends of the tube just as in the case of pyosalpinx and hydrosalpinx. Hemorrhage into the tube may take place as a result of torsion of the tube and it occurs as a complication of fibroids of the uterus. It is found also in cases of imperforate hymen with accumulation of menstrual blood in the uterus (hematometra).

Hematosalpinx resembles hydrosalpinx as to size and shape, but is of a dark reddish-brown color. The walls are thick, but

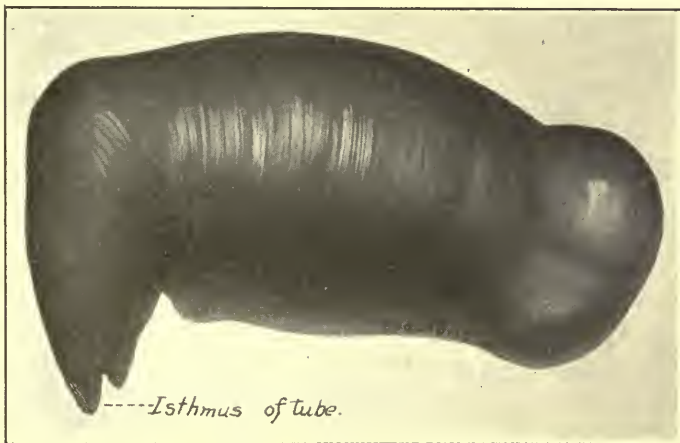

FIG. 139.—Hematosalpinx, Actual Size, Caused by Acute Torsion of Right Tube. Twist of Two Turns to the Right at the Isthmus. (Author's Case).

friable, and covered by adhesions. On microscopic examination it is seen that the mucosa is degenerated and destroyed, the muscular tissue is swollen and infiltrated, while the peritoneal coat shows thrombosed vessels and deposits of blood pigment.

DIAGNOSIS OF SACTOSALPINX

The diagnosis of pro-, hydro-, and hematosalpinx rests on the determination by palpation of a tumor of the shape of a dilated tube connected with, but not a part of the uterus. If the normal ovary can be distinguished separate from the tumor so much the better. In the cases where the tube is not very large the characteristic shape—club-shaped, pyriform, or retort-shaped—can be

made out with clearness. Also in these cases the isthmus of the tube connecting the tumor with the uterine horn may be palpated. With the larger tubes no characteristic shape can be learned by palpation. If both tubes are enlarged it is a strong diagnostic point in favor of retention tumors because these are generally bilateral.

Pelvic peritonitis with adhesions is an almost universal accompaniment of these tumors, therefore they are more or less fixed. There is no means of knowing previous to operation the contents of a dilated tube, whether pus, serum, or blood. Aspiration is not justifiable because by puncturing the tumor its contents may contaminate the peritoneum, thus complicating needlessly an operation for removal, which is indicated in all cases.

The diagnosis of rupture of a retention tumor is the same as that of rupture of an ovarian tumor (see page 319).

Torsion to the point of strangulation is evidenced by acute stabbing abdominal pain, vomiting, and the signs of a tender tumor in the situation of the tube. Torsion without strangulation has been reported in only three cases. Storer in 1906 (*M. Storer, Boston Med. and Surg. Jour.*, March 15, 1906, page 285) reported a case of bilateral torsion and collected sixty-two cases of torsion of the tube in the literature since Bland-Sutton first called attention to the condition in 1890.

DIFFERENTIAL DIAGNOSIS BETWEEN SALPINGITIS AND APPENDICITIS

Right-sided salpingitis is often mistaken for appendicitis. It should be remembered that the two affections may co-exist, and in this case which was in the beginning the exciting cause and which is the chief factor at the present time, are shown by the clinical history of the onset of the attack. Acute salpingitis is usually preceded by endometritis, by a vaginal discharge, and by menstrual disturbances, often by dysmenorrhea. In the case of appendicitis there is a history of digestive disturbances, of irregularity of the bowels, or of previous attacks of pain in the right side. Rovsing has made use of a method of reproducing the pain of appendicitis that is of value sometimes in the differential diagnosis. He strokes the descending colon from below upward, and the transverse colon from left to right, thus forcing gas back into the cecum and appen-

dix, distending these structures and reproducing a pain similar to that from which the patient has suffered.

In salpingitis the pain is more steady, less intense, and radiates into the pelvis, while in appendicitis it is colicky and more general.

Dr. Robert T. Morris (*Jour. Amer. Med. Asso.*, January 25, 1908, Vol. L., page 278) has directed attention to two points of tenderness, called *Morris' points*, which he considers of great assistance in distinguishing between chronic salpingitis and chronic appendicitis. One point is situated one and a half inches from the umbilicus on a line drawn from the umbilicus to one anterior superior spinous process of the ilium, and the other point is in a similar situation on the opposite side. These points are approximately over the lumbar lymph glands which receive the lymph vessels from the Fallopian tubes, ovaries, uterus, and broad ligaments, and also from the appendix. McBurney's point is on this same line on the right side one and a half inches from the spinous process. The right Morris' point is tender on pressure in the case of chronic appendicitis not involving the Fallopian tube, sometimes even when McBurney's point is not tender. In the case of salpingitis either unilateral or bilateral both Morris' points are tender. Several physicians have reported satisfactory results from the use of this means of diagnosis and it may be regarded as an accessory to other methods of diagnosis in chronic cases.

NEW GROWTHS

Primary new growths of the Fallopian tubes are relatively rare. They originate in the mucosa, or in the walls of the tube, and are benign or malignant. The benign growths are, polypus, papilloma, embryoma, myoma and fibroma, and fibromyxoma. The malignant growths are carcinoma, sarcoma, and chorioepithelioma.

Polypus of the mucosa is rare. It consists of simple inflammatory thickening of the mucous membrane or a polypus similar to a uterine polypus originating from placental tissue left attached to the tubal wall by a tubal pregnancy.

Papilloma is thought to be a result of an old salpingitis rather than a neoplasm proper. E. Hurdon ("Gynecology and Abdominal Surgery," Kelly and Noble, Vol. I, p. 174) has collected fourteen

eases from the literature. According to this authority the disease consists of a cauliflower papillary mass which originates in the mucous lining of the tube and distends the lumen without invading the wall. "Small peritoneal papillomata may develop, but metastases do not occur. Like the ovarian papillomata the tubal growths often produce an ascites. If, however, the abdominal ostium is closed, there is no ascites and the fluid is either retained in the tube or is discharged through the uterus (hydrops tubæ profluens)." Papilloma of the tube is generally unilateral.

Embryoma.—There have been at least four authentic cases of dermoid tumor of the tube reported in the literature, occurring in patients between the ages of twenty-five and forty-eight. One of the cases was an oval tumor the size of a hen's egg, which on section showed a tumor mass free in the tubal canal and having only a superficial attachment to the mucosa.

Myoma and fibroma, occurring as small nodules in the tubal walls, are not to be confused with the *salpingitis nodosa* of gonorrhœa or with the nodules occurring in tuberculosis of the tubes. Bland-Sutton says ("Surgical Diseases of the Ovaries and Fallopian Tubes," page 286): "I have satisfied myself that when there is a general myomatous enlargement of the uterus, the muscle tissue of the tubes also participates in the change, becoming thick and hard."

A true fibromyomatous nodule similar in every respect to uterine fibromyomata and the size of a walnut has been described as occurring in the tube. Even larger tumors have been reported. They are extremely rare.

Fibromyxoma.—One case of fibromyxoma of the tube has been reported in the literature, the tumor being about the size of a fist.

Carcinoma.—Hurdon refers to seventy cases of primary carcinoma of the tube in the literature. The disease usually affects one tube, though it may be bilateral. It occurs most often in women who are between forty and sixty years of age and chronic salpingitis is thought to stand in an etiologic relation to the disease. It originates in the epithelial covering of the mucosa and develops in the form of a papillary tumor. The diseased tube is converted into a large cylindrical pear-shaped tumor, which may reach the size of a child's head, but is usually about the size and shape of a retention tumor of the tube. The disease may advance by direct extension to the surrounding structures or by metastases.

Sarcoma.—There are only five cases of this disease in the literature, two round-cell, one spindle-cell, and one myxosarcoma. The tumor arises in the connective tissue of the mucous membrane or tube wall and presents a papillary or polypoid character.

Chorioepithelioma of the tube, as a sequence of tubal gestation, seems to be relatively as frequent as chorioepithelioma of the uterus following uterine pregnancy. Hurdon notes eleven cases that have been reported. In the place of the tube there is a large sac with thin, friable walls, which encloses a soft, spongy structure resembling placenta, and masses of bloody, fibrinous material. Histologically the findings are the same as in chorioepithelioma of the uterus.

The diagnosis of neoplasms of the tube can be only a probability. Fortunately they are very rare. After diagnosing a tumor of the tube by palpation, the possibility of its being a neoplasm should be borne in mind.

Tubal pregnancy will be considered in the next chapter under Extra-uterine Pregnancy.

CHAPTER XIX

THE DIAGNOSIS OF EXTRA-UTERINE PREGNANCY

Tubal pregnancy, p. 341: Frequency, p. 341. Etiology, p. 341. Pathology, p. 343. Uterine decidua, p. 344. Fate of the fetus, p. 344. Diseases of the ovum, p. 345.

Ovarian pregnancy, p. 345.

Symptoms and signs of extra-uterine pregnancy, p. 346: Pelvic hematocoele, p. 347. Multiple, combined, and repeated tubal pregnancies, p. 348.

Diagnosis, p. 348: Early extra-uterine pregnancy, p. 348. Late extra-uterine pregnancy, p. 350.

Differential diagnosis, p. 351: Early extra-uterine pregnancy before rupture, p. 351. Early extra-uterine pregnancy after rupture, p. 352. Late extra-uterine pregnancy, p. 353.

DEFINITIONS

By extra-uterine pregnancy we understand the development of a fertilized ovum at some point between the Graafian follicle in which it originates and the uterus.

The fertilized ovum may develop on the ovary itself, *ovarian pregnancy*, on the fimbria ovarica, one of the fringes at the ostium abdominale of the Fallopian tube that extends from the ostium to the ovary, so called *abdominal pregnancy*, or in the tube, *tubal pregnancy*.

It is possible, and cases have been reported, of a fertile ovum developing in a tubo-ovarian cyst, the fetal sac being made up partly of tubal and partly of ovarian tissue. Such cases are spoken of as being *tubo-ovarian pregnancies*. When a primary tubal (ampullar) pregnancy has grown in its development into the abdominal cavity it is called a *tubo-abdominal pregnancy*, and when, at the opposite end of the tube, a pregnancy beginning in the uterine end of the isthmus (interstitial pregnancy) develops into the uterus it is referred to as *tubo-uterine pregnancy*.

True abdominal pregnancy does not exist, the cases reported as such being those in which the growth of the fertilized ovum

began on ovarian or tubal structure and the subsequent development was in the abdominal cavity.

TUBAL PREGNANCY

A vast majority of extra-uterine pregnancies are tubal, and of these the ampullar form is probably the most common, though some authors assert that the isthmal variety has the precedence. The interstitial variety is the rarest.

Frequency.—It would appear that extra-uterine pregnancy is more frequent than formerly, but whether this is really so or seems

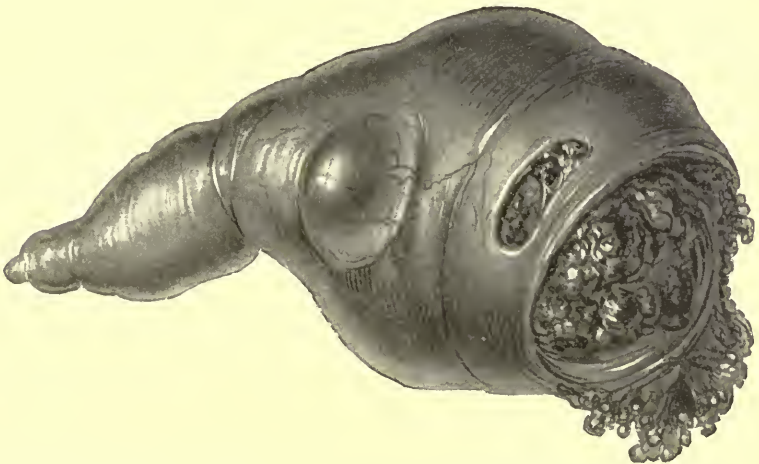


FIG. 140.—Early Ampullar Extra-uterine Pregnancy. Tubal Abortion. Natural Size. (Kelly.)

to be so because of better diagnosis and the more common practice of opening the abdomen, is not plain. In 1876 Parry was able to collect only 500 cases from the literature; to-day the literature teems with them. One prominent gynecologist in this country has reported recently having seen as many as 300 cases of extra-uterine pregnancy, another 200, and a third has operated on 154 cases. Still another operator says that operations for extra-uterine pregnancy form about four per cent of all his abdominal operations, and in my own experience such operations have been nearly five per cent of all my celiotomies.

Etiology.—As to the causation of tubal pregnancy we are still

in the dark. Dr. J. Whitridge Williams ("Extra-uterine Pregnancy," Kelly and Noble, "Gynecology and Abdominal Surgery," Vol. II., page 137), to whom I am indebted for much of the matter in this chapter, after reviewing at length the different theories which have been advanced to explain its occurrence, says of etiology: "In many instances the arrest of an ovum in a crypt resulting from follicular salpingitis, or in a diverticulum from the lumen of the tube, may afford a satisfactory explanation,



FIG. 141.—Same Case as Fig. 140. The Mole and the Fetus Have Been Removed from the Tube. (Kelly.)

though in a certain proportion of cases even the most careful history of the patient and thorough microscopic examination of the specimen will fail to reveal a tangible cause for the condition."

Any woman during the childbearing age may have extra-uterine pregnancy. It is more often observed in women who have been previously sterile or when there has been a long interval since the last pregnancy.

Pathology.—It appears that the ovum is embedded and the placenta is formed in the tube exactly as in the uterus. The tube wall is invaded by the fetal elements, its structures become degenerated and in part converted into fibrin so that they offer comparatively little resistance to the developing fetal cells. Shortly the latter are found just under the peritoneum. In a majority of cases early rupture of the tube is due to the erosion of a large blood-vessel with consequent hemorrhage and a giving way of the thin peritoneum.

Tubal pregnancy may terminate by abortion into the lumen

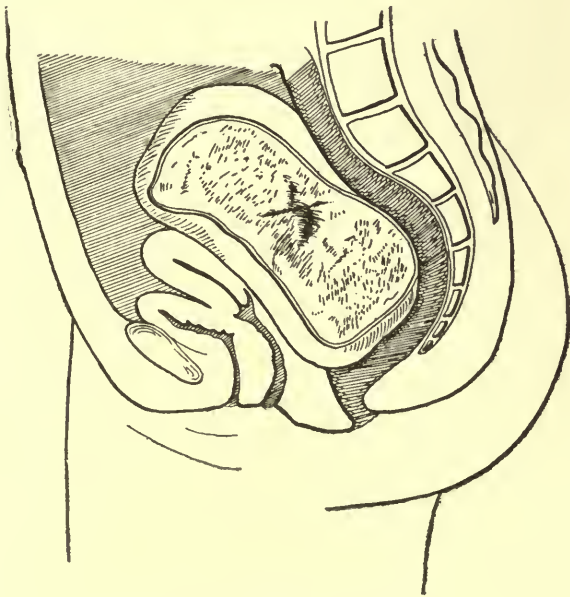


FIG. 142.—Pelvic Hematocoele.

of the tube, the most frequent issue; by rupture into the peritoneal cavity, both of these taking place during the first few weeks of pregnancy; or by development even to term. Rupture is more common in pregnancy in the isthmus, and abortion in ampullar pregnancy.

As far as the results go it makes little difference whether early rupture takes place through the capsular membrane into the lumen of the tube or through the wall of the tube. There is a hemorrhage in either case. The ovum with its membranes is (1)

separated completely from its bed and is expelled into the lumen of the tube and perhaps through the ostium, or (2) is expelled through the tubal wall directly into the peritoneal cavity or, (3) the separation is partial, the ovum remains, and the hemorrhage continues. The last, incomplete abortions, are the most frequent. When the ovum and its envelopes are extruded at once through the ostium abdominale the hemorrhage may cease; when, on the other hand, the separation of the ovum from the tubal wall is only partial, the ovum may increase in size because of infiltration with blood, and a *tubal mole* is formed. Under such conditions the hemorrhage continues as long as the mole remains in the tube and the blood trickles from the ostium and forms a pelvic hematocoele instead of free hemorrhage into the peritoneal cavity as in the case of complete abortion or tubal rupture.

Tubal rupture occurs more frequently in isthmal and interstitial pregnancy than in ampullar pregnancy. In interstitial pregnancy rupture may not occur until as late as the fourth month, whereas in isthmal pregnancy rupture generally occurs within the first few weeks of pregnancy, not infrequently before the patient is conscious that she is pregnant.

Rupture occurs near the placental site and is either into the peritoneal cavity or between the folds of the broad ligament.

Uterine Decidua.—A decidua, very similar in structure to the decidua of uterine pregnancy, is formed in the uterus coincident with the development of the ovum in the tube, and it is cast off soon after the death of the fetus either in small pieces, or, rarely, as a complete triangular cast of the uterine cavity. (See Fig. 143.) Hemorrhage from the uterus is apt to occur when the decidua comes away, but the membrane may be passed without the patient's knowledge. If portions can be obtained for microscopic examination, either from discharges or by curetting the uterus, they furnish a valuable diagnostic sign.

Fate of the Fetus.—The extruded ovum is always killed and is absorbed by the peritoneum unless it is advanced beyond the third month. It is highly improbable, as thought formerly, that the placenta can be attached to other structures in the abdominal cavity, at this time. The facts go to show that attachment is primary either on the ovary or tube and that any other adhesions are due to the later stages of the development of the fetus and

placenta. If the rupture is between the folds of the broad ligament, a rare happening, the fetus dies and a hematoma of the broad ligament is formed. Exceptionally when the placenta is not injured pregnancy may continue in the broad ligament or the broad ligament sac may rupture into the peritoneal cavity and a *secondary abdominal pregnancy* results.

If the fetus has developed beyond the third month it may be *mummified*, consisting of an absorption of the fluid portions so that there is nothing left but shriveled skin holding together the bones of the skeleton, or, rarely, it may form a *lithopedion*, a mummified fetus in which lime salts have been deposited. Sometimes the dead fetus and its membranes suppurate and an abscess is formed and very exceptionally this fetus becomes converted into *adipocere*, a sort of ammoniacal soap found occasionally in dead bodies.

Diseases of the Ovum.—The occurrence of tubal mole has been referred to already. (See page 344.) *Hydatidiform mole* has been found in the tube and differs in no respect from hydatidiform mole occurring in the uterus. In this situation it is followed by *chorioepithelioma* just as in the uterus.

In most cases of advanced tubal pregnancy there is a diminution in the amount of liquor amnii, but hydramnios has been observed. There are two cases on record of patients who had eclampsia during false labor.

OVARIAN PREGNANCY

J. Whitridge Williams has collected from the literature thirteen positive cases of ovarian pregnancy, in eleven of which the pregnancy had not progressed beyond the fourth month. In addition

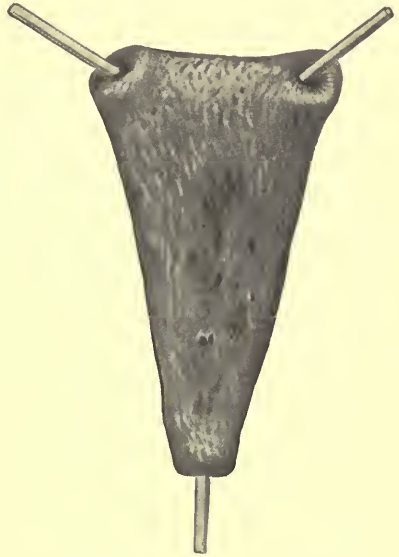

FIG. 143.—Uterine Decidua from a Case of Extra-Uterine Pregnancy. (Zweifel.)

he classed as highly probable or probable ovarian pregnancy, twenty-two other cases. In eleven of these thirty-five cases pregnancy had progressed to full term, so that the inference is that the ovary can accommodate itself more readily than the tube to the growing fetus. Early rupture is the rule, however,

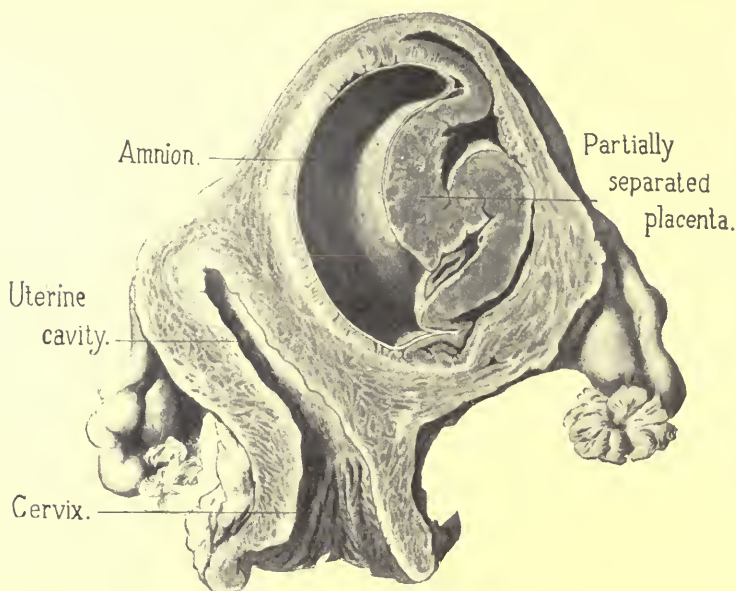


FIG. 144.—Interstitial Pregnancy. (Bumm).

in ovarian pregnancy, just as in tubal pregnancy. It is possible for the ovum to be destroyed early without rupture and *ovarian hematoma* may result. The implantation of the ovum on, or in, the ovary does not differ from the embedding in the uterus except that a definite decidua is wanting.

SYMPTOMS AND SIGNS OF EXTRA-UTERINE PREGNANCY

There are no symptoms to early unruptured extra-uterine pregnancy and its discovery is only a matter of chance. Slight pain in the ovarian region may be present. Amenorrhœa may be a symptom, but cases are recorded of rupture before it was time for another menstrual period, the patient having no idea she was pregnant. Suppression of menstruation is not as frequently a

symptom with extra- as with intra-uterine pregnancy, perhaps due to the presence of the uterine decidua, and if rupture or abortion takes place in the tube there is hemorrhage from the uterus. Sometimes the patient thinks herself pregnant and there may be present signs in the breasts, bluish discoloration of the anterior vaginal wall and the introitus, together with enlargement of the Fallopian tube on bimanual palpation.

It has been my experience that the patient has skipped one menstrual period and has some symptoms of pregnancy before the symptoms of rupture occur. These are sudden, severe, lancinating pain in the groin, bearing down, and rectal tenesmus, followed at once by faintness and sighing respiration with collapse, pallor, distention of the abdomen, a feeble rapid pulse, and subnormal temperature. Patients seldom die of this first hemorrhage, but after a few hours there is another attack of pain, followed by greater collapse, and if there is no surgical aid death may follow.

No two cases are alike, one will bleed rapidly and another slowly. Further, the amount of collapse does not seem to be in direct ratio to the amount of blood which has escaped into the peritoneal cavity, for upon operation it is found sometimes that when the abdomen is full of blood the symptoms have not been severe. In other cases most alarming symptoms follow the extravasation of a small quantity of blood.

Pelvic Hematocele.—If the blood has trickled out of the ostium of the tube, as in tubal abortion, or if for any reason the discharge of blood is intermittent, there will be a series of attacks of pain, perhaps a week or two apart. In these cases a *pelvic hematocele* is generally formed. The blood collecting in the pelvis is partly coagulated and is walled off by an organized membrane of peritonitic exudate. Such a collection may be a *solitary*, or a *diffuse hematocele*, the former term being applied to a smaller collection of blood in the neighborhood of the Fallopian tube.

Local examination shows a boggy mass, also softness of the cervix, and pain on moving it forward with the finger. Bluish discoloration of the vagina may be present. Colostrum in the breasts is an unreliable symptom. In some cases of early rupture there is a uterine discharge of a brownish color which may continue for weeks. This is due to the disintegration of the decidua in the uterine cavity.

The pelvic hematocoele is generally situated in the cul-de-sac of Douglas. If the uterus happens to be retroverted and the cul-de-sac obliterated the blood may be effused in front of the uterus and in that case the hematocoele will be found anteriorly. A fresh hematocoele is flaccid and fluctuates; an old one is hard and may be of uneven density.

If rupture does not result in death and there is no surgical interference pregnancy may continue and secondary abdominal pregnancy may follow. Then the symptoms will be those of pregnancy, with more pain and more suffering from the fetal movements than in uterine pregnancy. False labor sets in at term with uterine contractions and pain. The fetal sac contains so few muscular fibres that it can not contract to any great extent. The false labor may last a few hours or a number of days and is followed by the death of the child.

Multiple, combined, and repeated tubal pregnancies are reported in the literature. Twin tubal pregnancies occur occasionally, both embryos being in the same tube or one in each tube, and Sanger and Krusen, according to Whitridge Williams, have reported cases of triplet tubal pregnancy, all of the embryos being of the same age. Combined extra- and intra-uterine pregnancy is not very rare. Weibel in 1905 had collected 119 cases from the literature. This class includes only the combined pregnancies in which the embryos were of the same age, and not the cases of uterine pregnancy occurring in the presence of the remains of an old extra-uterine pregnancy.

There have been many cases on record of repeated tubal pregnancy in the same woman, and several cases of this have fallen under my observation.

DIAGNOSIS OF EXTRA-UTERINE PREGNANCY

EARLY EXTRA-UTERINE PREGNANCY

The positive diagnosis of early tubal pregnancy before rupture has been made and has been proved by operation. Such a diagnosis is based on the symptoms and signs of early pregnancy and the presence of a tender unilateral tumor of the tube and slight enlargement of the uterus, more especially if the woman has been

sterile, or a long interval has elapsed since the last pregnancy. A diagnosis under these conditions is only probable, however. Any patient presenting such a combination of symptoms and signs should be kept under continued observations until the diagnosis is made plain or an operation is performed. The death of the fetus, usually between the fourth and the ninth week of pregnancy, is signaled by the discharge of the uterine decidua and by more or less hemorrhage from the uterus. At this time the diagnosis is apt to be uterine abortion. Always carefully examine the ovaries and tubes in cases of abortion and if possible get shreds of extruded tissue for microscopic examination. In exfoliative endometritis a cast of the uterine cavity may be thrown off, and therefore the extrusion, in extra-uterine pregnancy, of the decidua in one piece, triangular in shape, is not proof positive of the existence of this disease, but may be classed as presumptive evidence. On the other hand, the cast-off decidua may be lost at an early date, perhaps without the patient's knowledge. A tubal tumor of a size corresponding to the length of time the supposed pregnancy has existed, a slightly enlarged uterus, a relaxed vagina with bluish discoloration, a vaginal discharge of blood and shreds of tissue, and pain caused by pulling the cervix forward with the finger in the vagina make the diagnosis of tubal pregnancy most probable.

The symptoms of rupture have been considered under the heading of symptoms, page 347. They are characteristic. Sudden faintness and collapse, together with severe pain in the region of the pelvis in a woman who has gone over her period, make a probable diagnosis of rupture of an extra-uterine pregnancy. If the patient recovers quickly the probabilities are in favor of its being tubal abortion. If there are recurrent attacks and a hematocoele can be made out—a boggy mass of indefinite outline—the diagnosis of tubal abortion is undoubted. If the patient goes from bad to worse, and there are rigidity of the abdomen, increasing abdominal pain, pallor, sighing respiration, subnormal temperature, and a thready pulse, the diagnosis is tubal rupture and the abdomen should be opened at once. After the first attack of collapse and pain, there is to be felt a mass in the pelvis.

LATE EXTRA-UTERINE PREGNANCY

In the later stages of extra-uterine pregnancy a correct diagnosis is seldom made until full term is reached. In the later months of pregnancy the diagnosis rests on finding the child lying outside

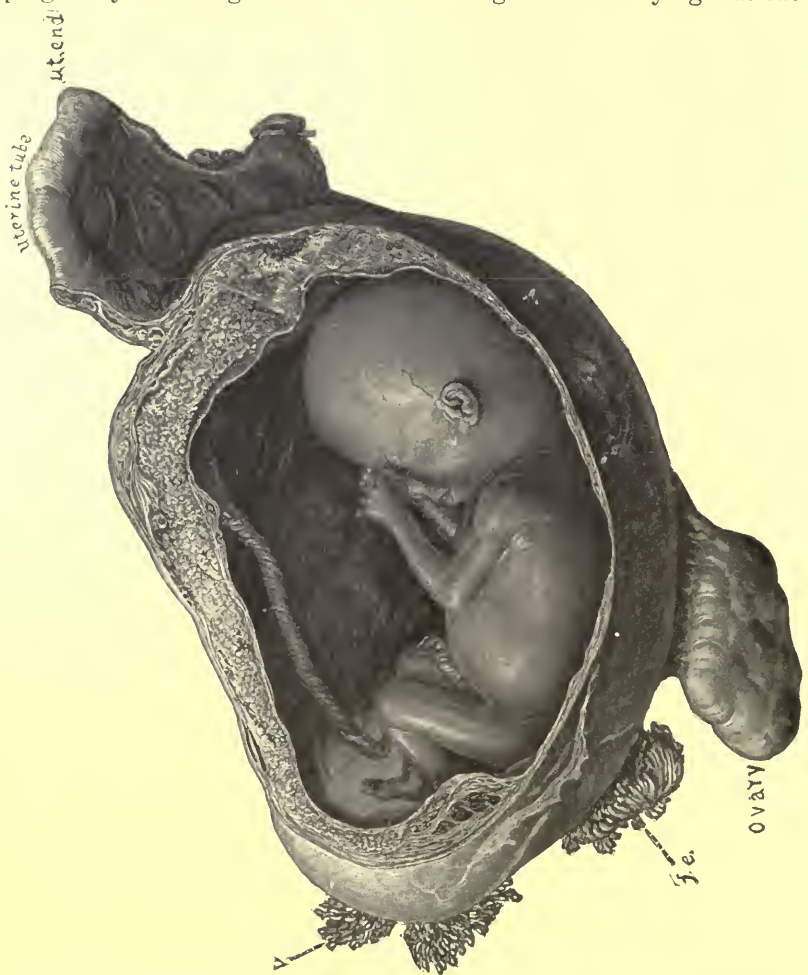

FIG. 145.—Unruptured Ampullar Extra-uterine Pregnancy, Four Months. (Williams.)

of the uterus, which is the size of a three months' pregnancy. The child can be palpated, the fetal heart sounds heard, and fetal movement felt, if the child is alive. The patient has had more

pain than is usual in normal pregnancy. The sound may be passed into the uterus to determine that it is empty.

At full term the diagnosis is made by a history of false labor followed by a gradual decrease in the size of the abdomen. The uterus is nearly normal in size and displaced by a large tumor either forward or backward. The child can be palpated and, if alive, the fetal heart sounds can be heard. The diagnosis at full term is easy to make, whereas previous to this time it is difficult.

The diagnosis of combined intra- and extra-uterine pregnancy is seldom made previous to labor or operation. Sometimes in the case of twins when a child has been born from the uterus and there is delayed birth of a second child, examination leads to the diagnosis of extra-uterine fetation. Also, operation for ruptured extra-uterine pregnancy with abdominal hemorrhage may show the co-existence of uterine pregnancy.

DIFFERENTIAL DIAGNOSIS OF EXTRA-UTERINE PREGNANCY

Early Extra-Uterine Pregnancy before Rupture.—Here any enlargement of tube or ovary not greater in size than a goose egg may be mistaken for an extra-uterine fetation. The presence of the symptoms and signs of early pregnancy (see Chapter XXII, page 418) and the fact that an extra-uterine sac is more apt to be tender, are the only distinguishing features.

Pregnancy in a retroverted uterus has been mistaken for extra-uterine pregnancy. A thorough examination, if necessary with an anesthetic, ought to remove all doubt. The symptoms which accompany retroversion of a gravid uterus should be borne in mind, viz., difficulty in micturition, retention of urine, pains in the pelvis, and constipation. If the bladder is overdistended it may be palpated. Passage of the catheter establishes the diagnosis. Uterine fibroids have been mistaken for a gravid tube, though this is rare. Fibroids are seldom single and the uterus is apt to be distorted by their growth.

Early Extra-Uterine Pregnancy after Rupture.—Symptoms and signs of early pregnancy with a paroxysm of severe abdominal pain, collapse, distention and rigidity of the abdomen, thready pulse and subnormal temperature, besides meaning ruptured

extra-uterine pregnancy, may indicate rupture of an ovarian cyst, or torsion of the pedicle of an ovarian cyst, rupture of a pyosalpinx or even of an appendiceal abscess, or rupture of a varicose vein, of the broad ligament. The treatment is the same in all of these conditions, immediate opening of the abdomen.

If the rupture has been into the folds of the broad ligament

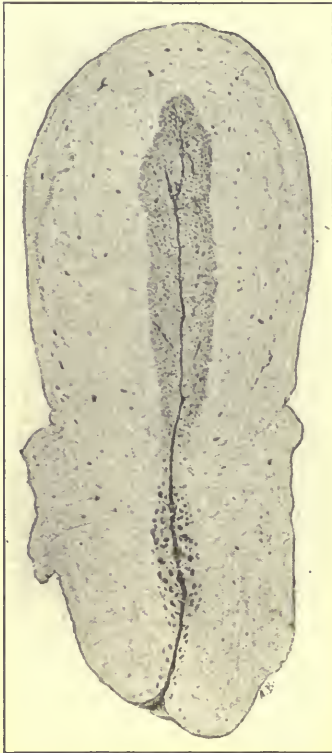


FIG. 146.—Median Section of the Uterus of a Case of Isthmial Tubal Pregnancy of about Two Months, Showing the Decidual Modification of the Endometrium. (Couvellaire.)

there will be a mass of irregular outline at the side of the uterus, of doughy consistency. It is to be differentiated from a pelvic inflammatory mass by its lack of hardness, by the absence of the history of infection, and by the absence of the signs of infection in vagina and cervix.

In the event of symptoms of acute rupture in conditions simulating extra-uterine pregnancy the history of the case will throw light on the diagnosis. In the case of an ovarian tumor the history will show the previous existence of a tumor, except in the case of a small one, and the uterus is not enlarged; in the case of pyosalpinx there is a history of genital infection and the temperature is apt to be elevated, also the symptoms of hemorrhage,—weak heart, pallor, sighing respiration, and syncope,—are absent. In the case of rupture of an appendiceal abscess, the same is true and in addition there is a history of digestive disturbances, constipation

alternating with diarrhoea, and, usually, previous attacks of right-sided pain. In cases of chronic rupture, those in which the symptoms are not severe and prolonged, uterine abortion is one of the conditions most apt to be mistaken for extra-uterine pregnancy. If there is any doubt at all that the case is one of uterine

abortion, ether should be given and a thorough bimanual examination made. The uterine hemorrhage in cases of extra-uterine pregnancy is generally of less amount than in cases of abortion and the clots are less frequently passed. The pain of rupture is a severe, agonizing sensation, one that can not be endured; in the beginning it is unilateral. The pain of abortion is that of labor, beginning as an aching, drawing pain in the lumbar region radiating toward the hypogastrium.

The changes in the size and consistency of the uterus are more marked in uterine than in extra-uterine pregnancy. In the case of acute pyosalpinx or an exacerbation of a chronic pyosalpinx there are no softening of the cervix and no pain when the cervix is moved forward as in the case of extra-uterine pregnancy. In the case of rupture of varicose veins of the broad ligament, a rare event, there is nothing to point toward a diagnosis unless the patient has been under observation previous to the rupture.

According to Baumgarten and Poffer (*Wiener klinische Wochenschrift*, 1906, No. 12) acetonuria is present in extra-uterine pregnancy. They examined the urine of one hundred patients and were able, by detecting acetonuria, to distinguish between extra-uterine pregnancy and other pelvic tumors.

Late Extra-uterine Pregnancy.—If the walls of a pregnant uterus are abnormally thin, and the walls of the mother's abdomen are also thin, the fetus may be so plainly felt that a uterine may be mistaken for an extra-uterine fetation. Careful bimanual palpation will determine that the fetus is in the uterus. So, also, a sacculated pregnant uterus may simulate extra-uterine pregnancy, as well as pregnancy in a bicorned uterus. In the latter case an ether examination may serve to differentiate.

A late extra-uterine pregnancy with an excess of hydramnios may simulate ovarian cyst. If the fetus can be outlined by palpation, or the fetal heart heard, the diagnosis is easy.

The consideration of pregnancy in abnormal uteri, such as bicorned and rudimentary, will be found in the chapter on pregnancy, page 432.

CHAPTER XX

THE DIAGNOSIS OF DISEASES OF THE VAGINA

Anatomy, p. 354: Vaginal discharge, p. 355. Age changes, 356.

Malformations of the vagina, p. 356: Congenital malformations, p. 356. Acquired stenosis and atresia of the vagina, p. 359.

Inflammations, p. 361: Acute vaginitis, p. 362. Chronic vaginitis, p. 363. Condylomatous vaginitis, p. 363. Emphysematous vaginitis, p. 364. Mycotic vaginitis, p. 364. Ulcerative vaginitis, p. 364. Senile vaginitis, p. 365. Tuberculous vaginitis, p. 365. Syphilitic vaginitis, p. 365.

Displacements of the vagina, p. 366: Cystocele, p. 366. Rectocele, p. 369. Hernia or enterocele, p. 371.

Injuries of the vagina, p. 371: Lacerations of the perineum and pelvic floor, p. 371. Other injuries, p. 372.

Foreign bodies in the vagina, p. 377. Gas in the vagina, p. 378.

Vaginismus, p. 378.

New growths of the vagina, p. 379.

Fistulae of the vagina, p. 384.

ANATOMY

THE vagina is a slit in the pelvic floor extending from the hymen to the cervix uteri and lying between the bladder in front and the rectum behind. It is nearly parallel to the plane of the brim of the true pelvis, and, with the patient in the upright posture, makes an angle with the horizon of about 60°. When seen in a median longitudinal section the slit of the vagina shows an S curve, the height of the first anterior protuberance of the S being at the summit of the perineal body. (See Figs. 6, p. 44 and 85, p. 219.) In horizontal section in its middle course it is seen as an H-shaped opening. (See Fig. 151, p. 374.) Like the cavity of the uterus it is funnel-shaped, being larger above and smaller below, and it has two walls, an anterior and a posterior, which are in apposition unless the vagina is distended.

The anterior wall extends from the hymen below, to the cervix above, the *anterior fornix* being the space formed between the intra-vaginal portion of the cervix and the upper portion of the anterior

wall. The length of the anterior wall is from two to two and a half inches (5 to 6 centimeters). In its lower portion it is closely united with the urethra, but higher up is surrounded by loose areolar tissue.

The posterior wall extends from the hymen to the cervix uteri. It is three inches (7.5 centimeters) long or nearly an inch longer than the anterior wall. The space between the vaginal portion of the cervix and the upper part of the posterior wall is called the *posterior fornix*. It is deeper than the anterior fornix.

The mucous membrane of the vagina is arranged in transverse folds or rugæ. In the lower part of the centre of each wall is a single or double longitudinal thickening about seven-eighths inch long, known as the *column of the vagina*. The anterior column is the larger.

The vagina is made up of three coats, the mucous membrane, the muscular coat, and the erectile tissue lying between the two. The arrangement of the mucous membrane in folds has been described. The epithelium covering the surface of the mucous membrane is of the squamous variety. There are no functioning glands, although the presence of gland tissue in the mucous membrane has been proved by von Herff and R. Meyer. The muscular coat consists of two layers, an external longitudinal, the stronger, and an internal, weaker, circular layer. The loose connective tissue uniting the mucous membrane with the muscular coat contains a plexus of veins which are arranged similarly to the veins in other erectile tissues. Because of its opening near the anus and the urethra, and its being invaded by the penis, the vagina is especially subject to infection from outside. Bacteria may be brought to it from the uterus and trauma may come from childbearing.

Vaginal Discharge.—Although under normal conditions possessing no functioning glands and therefore no secretion proper, the surface of the vagina is covered by cast off epithelial cells and also bacteria with moisture having an acid reaction. This has a white creamy color and is not enough in amount to attract the woman's attention. The acidity of the fluid may be due to the lactic acid bacterium of Döderlein, though authorities are not agreed on this point. Be that as it may, pathogenic bacteria, unless especially virulent, do not live long in a healthy vagina, not finding a good culture medium or being killed by the microorganisms

already there. Under pathological conditions an excess of alkaline secretion from a cervical catarrh may neutralize the acidity of the vagina and render it alkaline, thus furnishing an opportunity for the growth of disease-producing germs.

Age Changes.—In the child the vagina is narrow and there are many rugæ. Its walls are in close apposition. In the adult nulliparous married woman the vagina is more capacious, the widening being more in the upper than in the lower portion. After childbearing the vagina loses some of its folds, is larger, and may show alterations in shape because of its attachments being stripped from the cervix, or from laceration of the perineum.

With the onset of the menopause atrophic changes begin. The mucous membrane loses its rugæ and becomes smooth, and the vagina becomes contracted. In its upper portion the fornices are obliterated because of atrophy of the cervix and shrinking of the vaginal walls.

MALFORMATIONS OF THE VAGINA

Malformations of the vagina are *congenital* or *acquired*. As the vagina as well as the uterus is derived from the coalescence of Müller's ducts it partakes of the congenital malformations of the uterus.

Congenital Malformations.—These are: absence of the vagina, atresia of the vagina, septate vagina, double vagina, and persistence of a Müller's duct, also the persistence of Gärtner's duct.

Absence of the Vagina.—This is not a very uncommon malformation, instances of it appearing constantly in the periodical literature. It is associated with a greater or less degree of lack of development of the uterus, the uterus being represented generally by a small knob of tissue. The ovaries and tubes may or may not be present. If the ovaries are present the patient, otherwise perfectly formed as regards figure, external genitals, breasts, and hair, suffers from painful menstrual molimina, and an operation for the removal of the ovaries may be necessary. The anomaly occurs without assignable cause in well-nourished women in other respects fully developed.

The diagnosis is established by noting the absence of the introitus vaginae and by the bimanual recto-abdominal touch practised

with the patient under the influence of an anesthetic. Something is learned also by palpation through the rectum with a sound placed in the urethra and bladder. As a rule no vestige of the vagina can be found in these cases. The entire absence of the ovaries can not be determined surely without an abdominal section, but failure to find them in a case where all the conditions for examination are favorable, *i.e.*, lax and thin abdominal walls, together with the absence of menstrual molimina, makes the diagnosis reasonably certain.

Atresia of the Vagina (Congenital).—Vaginal atresia is due to the fact that the Müller's ducts fail to coalesce properly throughout their entire course, and the lower end of the vagina may fail to reach the hymen. As a rule there is some portion of the unoccluded vagina just under the cervix. In cases of congenital atresia of the vagina the vagina has been found dilated with secretion so that it bulged beyond the vulva, and has been known to cause retention of urine in the new-born because of pressure on the urethra.

Occlusion of the vagina is to be differentiated from imperforate hymen, the latter, being developed from the margins of the urogenital sinus, is not a complete obstructive membrane. It is likely that when the hymen is closed the closure is the result of adhesive inflammation. The hymen can generally be recognized as a separate structure below the introitus vaginae.

Any defect of the vagina that causes retention of the uterine secretions should be diagnosed at birth or soon after.

In the case of double uterus and vagina one vagina may appear as a blind sac running beside the well-formed vagina. It is thought now that most cases of atresia of the vagina owe their origin to inflammatory processes, perhaps during intra-uterine life, although there are cases, mainly those associated with uterine abnormalities, that are due to failure of development pure and simple.

The diagnosis is generally made by chance or by the occurrence of hematocolpos or hematometra due to retained secretions in the vagina or uterus.

Septate vagina and double vagina occur when the septum between the Müllerian ducts is partially or not at all absorbed. The partial form is more often observed, although all forms are rare. The septum may be placed diagonally so that it has the appearance of a transverse septum, thus partially occluding one side of the

vagina; it may extend a part of the length of the vagina, more often in the lower part, making two canals below and one above, or it may be only a ridge on the anterior or posterior wall of the vagina. If one Müller's duct persists in the upper part of the

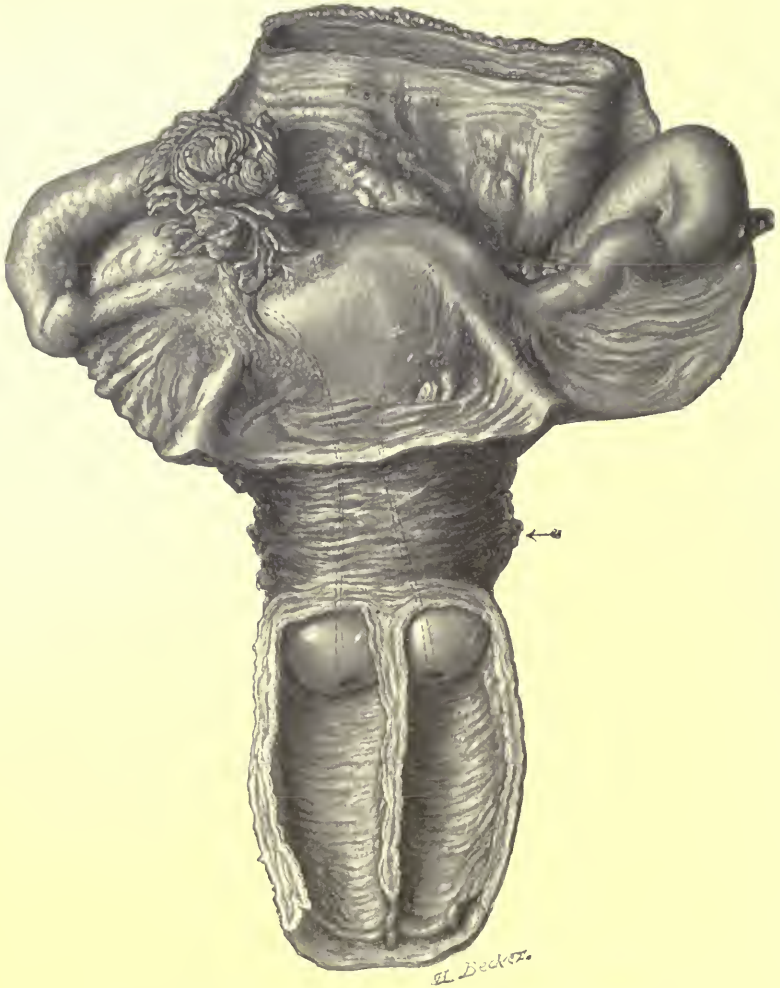


FIG. 147.—Double Uterus and Double Vagina. (Kelly.)

wall of a well-developed vagina and is connected above with a rudimentary supernumerary uterus while having no opening below, it may become dilated by retained secretions and appear as a cyst. Freund and others have reported such cases.

Several cases of double vagina have been reported, notably one of double vagina and double uterus reported by H. A. Kelly ("Operative Gynecology," 2nd edition, page 210.) (See Fig.147.)

Gärtner's duct, which in the embryo extends as a small canal through the side of the uterus or the broad ligament, the cervix, and the lateral or anterior wall of the vagina nearly to the introitus vaginae, may persist in the wall of the adult vagina. This may, rarely, give rise to cysts or even to an abscess.

Retention of secretions due to atresia of the vagina, hematocolpos, will be considered under acquired stenosis and atresia in the section on inflammations.

The diagnosis of malformations is made by inspection and by digital examination. A small speculum is necessary and sometimes a Kelly cystoscope serves well for a view of an undeveloped vagina. Bimanual recto-abdominal touch will determine the condition of the uterus and ovaries.

Acquired Stenosis and Atresia of the Vagina.—Stenosis of the vagina is a constriction or narrowing of the canal, while atresia is a complete closure or obliteration of it.

J. Veit ("Handbuch der Gynäkologie," Bd. III, 1908) thinks that most of the forms of vaginal atresia that cause retention of secretions as seen in the adult (hematocolpos) are to be classed as acquired, and assigns adhesive inflammation in the first years of life as a cause. This inflammation is not as a rule severe and has no symptoms often. We know of the frequency of gonorrheal vulvo-vaginitis in little girls, and also that inflammatory affections of the vagina are found in septicemia, scarlet fever, and diphtheria. Also, bacteria find ready entrance to the vagina in typhoid fever, dysentery, and similar affections. Taken in connection with the frequency with which traces of inflammatory action—for example, adhesions of the prepuce to the clitoris—are found in adults upon careful search, there seems to be ample ground for the theory that this sort of atresia originates in adhesive inflammation.

In adults the cause of cicatricial stenosis is inflammatory action involving the submucous and muscular layers, due to injuries following childbirth, to caustic applications to the vagina, to improperly performed operations on the vagina, to foreign bodies left in the vagina, such as neglected pessaries, and to vaginitis phlegmonosa disseccans. As a result there are found in the vagina

cresecentic folds, ring-like narrowings, transverse septa with minute openings, all being forms of stenosis, or there is a general shutting up of the entire canal, atresia. This atresia may be caused by a thin membrane, by a broad cicatrix several centimeters thick, or by the entire destruction of the vagina.

Atresia or stenosis results in difficulty in coitus and in labor. In the congenital form of atresia of the genital organs there is apt to be diminished desire for sexual intercourse, especially if the ovaries are undevelopd. Another result of atresia is *hematocolpos*, or accumulation of menstrual blood and uterine secretions in the vagina. These cases are generally first seen in girls who have passed the age of puberty without the appearance of the menstrual flow. They may experience pain in the abdomen. Examination shows a tumor behind the pubes that increases in size at each menstrual period and diminishes in the interval. On inspection of the vulva there is to be noted a bulging outward in the region of the introitus vaginæ of an elastic tumor. The hymen is to be distinguished as a separate membrane. If the septum of the vagina is thin the dark color of the retained blood may manifest itself through the membrane. The bimanual recto-abdominal touch determines the presence of a fluctuating tumor in the situation of the vagina.

If the accumulation of blood and uterine secretions has dilated the uterus, *hematometra*, it may be possible, with the aid of an anesthetic, to palpate the enlarged uterus. Dilatation of the Fallopian tubes from the same cause, *hematosalpinx*, sometimes results. In the latter event there may be an escape of fluid through the ostium abdominale of the tube into the peritoneal cavity with resulting peritonitis and symptoms of a severe grade. The danger of causing such extrusion of fluid should be borne in mind in making the bimanual touch and the amount of force used should be carefully limited. (See Chapter XXI, p. 398).

Diagnosis.—The diagnosis of stenosis and atresia of the vagina offers few difficulties. The examining finger detects folds and ridges and partial narrowings, also double vagina, if present. A small speculum is generally indicated, for with it the physician gets a better view of an abnormally narrowed vagina. An open canal with an elastic tumor by its side makes probable a dilated rudimentary vagina. Cyst of the vagina must be excluded, how-

ever, and this can be done by determining the normal state of the uterus, tubes, and ovaries, as rudimentary vagina is seldom found with the other uterine organs perfectly normal. In all cases it is important to investigate the uterus and tubes.

Differential Diagnosis.—Acquired stenosis and atresia must be differentiated from the congenital malformations, from vulvitis with atresia, and from vaginismus. The congenital malformations are of relatively rare occurrence and are associated with other defects of development in uterus, tubes, or ovaries, their salient characteristics having been referred to. In adhesive vulvitis there are apt to be traces of inflammatory action (adhesions) about the clitoris and nymphæ, as well as at the introitus vaginæ. There may be a history of gonorrhœa, in this case look for cicatrization or redness in the neighborhood of the vulvo-vaginal glands; or there may be a history of diabetes. Vaginismus is characterized by painful and spasmodic contractions of the muscles of the pelvic floor, especially those about the lower vagina. In cases of doubt the administration of an anesthetic will relieve all spasm.

INFLAMMATIONS OF THE VAGINA

(*Vaginitis or Colpitis*)

Infection of the vagina depends on the number and vitality of the pathogenic bacteria that have found their way into it; also on the state of health of the epithelium of the mucosa of the vagina. Any direct injury of the epithelium, or change in its character due to a uterine catarrh favors the development of infective organisms, and their entrance into the tissues. Just what bacteria are present as causative agents in any given case it is not always easy to determine; those that are most often found are the streptococcus, the staphylococcus, the colon bacillus, the tubercle bacillus, the gonococcus, and a gas-producing bacillus.

Vaginitis is relatively more common in children than in adults, probably because of the softer epithelium in childhood. In children vulvo-vaginitis of gonorrhœal origin is not uncommon, and vaginitis is a frequent concomitant of the acute infectious diseases. In adults vaginitis is a rare disease.

Etiology.—The following may be mentioned as predisposing

and exciting causes of vaginitis: Retained discharges from an insufficient opening in the hymen; irritation from excessive venery or masturbation; congestion from pregnancy or abdominal tumor, or organic disease of the heart, liver, or kidneys; gaping of the vulvo-vaginal orifice; douches of irritating substances, such as strong corrosive sublimate; foreign bodies, such as pessaries and tampons; oxyuris vermicularis; injuries received at labor and abortion, and recto- and vesico-vaginal fistulae.

ACUTE VAGINITIS

Pathology.—In the mild cases it is characterized by a reddened, swollen, granular mucosa which is bathed in an abundant thin purulent discharge. The entire vagina is usually involved. In the severe cases, swelling and hyperemia increase and excoriations and even necrosis may occur. In puerperal conditions and in the acute infectious diseases the mucosa may be covered with a whitish-gray or greenish deposit or by a false membrane made up of the necrosed upper portion of the mucosa—*pseudo-diphtheritic vaginitis*. Cases of true *diphtheritic inflammation*, due to the Klebs-Loeffler bacillus, have been described, though they are rare.

In certain extremely severe cases the inflammatory process extends to the tissues about the vagina and there is a *paravaginitis*. This is the case in an *erysipelalous vaginitis* similar to the erysipelas of the skin, a rare disease, and in *paravaginitis phlegmonosa dissicans*, which sometimes accompanies typhoid fever. In the phlegmonous variety the whole or the greater part of the tube of the vagina is cast off as a slough with subsequent stenosis.

Symptoms.—Burning pain referred to the vulva, a profuse leucorrhœal discharge, generally purulent in character and irritating to the vulva, smarting on urination if the vulva is involved and also if urethritis is present, as in the gonorrhœal form, a sense of fullness in the pelvis, and backache, are the usual symptoms. Vulvitis goes with vaginitis in many cases, especially in children. The constitutional symptoms are not marked, the temperature seldom going above 101° F., except in the streptococcic, diphtheritic, and paravaginitic forms.

Diagnosis.—The patient is placed in the Sims position and the labia are separated. The character and amount of discharge are

noted and a finger placed in the vagina finds that it is hot. In the gonorrhœal variety, which is relatively rare and is secondary to infection of Bartholin's glands, the urethra, and cervical canal, the discharge is generally of a greenish-yellow color. The smallest Sims speculum that will serve is used because the vagina is very sensitive. The mucous membrane shows some of the many characteristics described under the pathology of acute vaginitis. If the vaginal discharge originates from the uterus or an abscess discharging into the vagina instead of from the vagina itself, the speculum examination will settle this point.

CHRONIC VAGINITIS

Pathology.—Chronic vaginitis may succeed acute vaginitis, or, more often, may be of a chronic type from the beginning. It is apt to result from the irritation from pessaries or tampons, or other foreign bodies. In the gonorrhœal form it is usually secondary to gonorrhœal infection of the uterus, Bartholin's glands, or the canal of the cervix uteri.

The disease is generally confined to certain portions of the vagina rather than to the entire surface, as it is in the acute form. The affected portions are reddened, often mottled with slight ecchymoses, or they are brown in color from old deposits of blood pigment. The surface is granular, or glazed and smooth and free from rugæ. Microscopically it is seen that the surface epithelium is somewhat thinner than normal, whereas the submucous tissue is thick, dense, and infiltrated with small round cells; sometimes blood pigment shows in deposits in places. In granular vaginitis the granulations on the surface are crescent-shaped, small in size, and pretty generally scattered over the surface of the vagina. Certain special varieties of chronic endometritis are observed.

Gonorrhœal vaginitis should be mentioned as a variety, although it has few characteristics that distinguish it from simple vaginitis. It is generally secondary to gonococcus infection elsewhere and the discharge is apt to be of a greenish color.

Condylomatous Vaginitis.—Condylomata similar to those found about the vulva, but set not so close together, are to be found sometimes in vaginae that have been subject to long-continued irritations, as from gonorrhœal endocervicitis. The condylomata

may be scattered over a large or a small area in the vagina. They show under the microscope hyperplasia of the papillæ accompanied by secondary epithelial proliferation.

Emphysematous Vaginitis.—This variety occurs most often during pregnancy and occasionally during the puerperium, and is characterized by the presence in the vaginal walls of small cysts, generally not much larger than a pea, and containing gas. They may appear to be bluish in color due to the thinness of their walls. They are due to a gas-producing bacillus the exact nature of which has not been determined, and are developed in the connective-tissue spaces. Sometimes the cysts are as large as a filbert. On pressure with the finger the cyst disappears, and on opening it with a knife gas escapes.

Mycotic Vaginitis.—This is a form of vaginitis in which there is a growth of a fungus in the vagina, the *Oidium albicans*. The walls of the vagina are covered with large numbers of grayish-brown, slightly elevated masses which are easily detachable. Beneath them the mucosa is swollen and eroded. Under the microscope the masses are seen to be made up of epithelial cells and the spores and mycelium of *Oidium albicans*. It has been thought that the dark color is due to blood-coloring matter.

Ulcerative Vaginitis.—Ulcerative vaginitis is a term used to distinguish the form of the disease in which the mucosa has been destroyed by ulceration, as in the case of an ill-fitting pessary. Following the true form of ulceration in which the submucous tissue is involved a cicatrix results.

An interesting case of ulcerative vaginitis in a case of bacillary dysentery has been reported by M. M. Canavan (*Boston Med. and Surg. Jour.*, Nov. 11, 1909, page 705). In this case a woman fifty-one years old, an inmate of the Danvers State Hospital for the Insane for four years, was affected by bacillary dysentery during an epidemic of the disease in 1908. She died, just after a vaginal hemorrhage, on the fourteenth day of her illness. At the autopsy the following condition was found, to explain the hemorrhage and a bloody vaginal discharge which had been noted during the last six days of her illness. The surface of the vagina was dull brownish-gray in color and was covered with a tenacious pigmented exudate and there were clusters of deep-notched winding ulcers at the fornices of the vagina.

Senile Vaginitis.—In senile vaginitis, a form of vaginitis peculiar to women who have passed the menopause, the mucous membrane is atrophic and therefore poorly nourished. The irritation of the vagina from a uterine discharge is apt to proceed to the stage of ulceration, generally many small scattered ulcers being present. These enlarge, coalesce, cause hemorrhage by the erosion of small vessels, and form scar tissue. There may be adhesions between the walls of the vagina. The disease is a common one in women over sixty years of age.

Tuberculous Vaginitis.—This variety is practically always secondary to tuberculosis elsewhere, although a problematical case of primary tuberculosis of the vagina has been reported by Carl Friedlander and Olshausen. The disease, not a common one, occurs in the form of one or more ulcerations, generally situated in the neighborhood of the cervix. The ulcers are flat, circumscribed, with infiltrated hyperemic margins, the base covered with yellowish-gray material or studded with tubercles. Histologically the floor of the ulcer consists of granular, caseous material, beneath which the tissue is infiltrated with typical miliary tubercles or diffuse tuberculous tissue. The diagnosis is made by the microscope.

Syphilitic vaginitis needs only to be mentioned. Chancres, ulcers, or gummata may be found in the vagina. They are rare and are diagnosed by the characteristic lesions of the disease in other parts of the body, by the history of syphilis, and by the detection of the spirochaeta pallida in the discharge.

Symptoms.—The symptoms of chronic vaginitis are vaginal discharge, generally purulent in character, a sensation of fullness in the pelvis, perhaps itching of the vulva with smarting on urination if the vulva also is affected. The general health may suffer as a result of the irritation and consequent loss of sleep, but there are no characteristic constitutional symptoms. Leucorrhœa may be the only symptom.

Diagnosis.—The patient is in the Sims position. A Sims speculum is employed. It is noted that the vagina is not sensitive as in the acute stage and does not feel hot to the examining finger. The mucous membrane is thickened and is of a dark red or bluish color; in places it is smooth and in others it is roughened and the discharge is thinner and less purulent than in the acute stage.

It is to be remembered that the vagina may be simply a canal which conducts purulent or other fluids from the uterus or the surrounding organs to the vulva; therefore be sure that the inflammatory process is primary in the vagina. In the case of gonococcus infection, as pointed out already, the process is secondary to infection in the urethra, Bartholin's glands, and the cervical canal; consequently those situations should receive attention.

The special varieties of vaginitis just enumerated should be borne in mind and their characteristics recognized. Cultures and smears are made from the discharges and pieces of tissue removed for microscopic examination in all doubtful cases.

DISPLACEMENTS OF THE VAGINA

In this section we shall consider cystocele, rectocele, and the rare condition known as true hernia of the vagina.

CYSTOCELE

Cystocele is a prolapse downward of the anterior wall of the vagina together with the base of the bladder. It would appear that in some cases the muscular wall of the vagina has given way and the bladder wall in the cystocele is covered only by vaginal mucosa. If the urethra alone is dislocated downward the condition is called *urethrocele*. In this case the urethra may be detected as a thickened ridge, and passage of the sound together with palpation shows the situation of the urethra.

Etiology and Frequency.—The chief cause of cystocele is child-bearing, the anterior movable segment of the pelvic floor, that portion lying between the arch of the pubes and the uterus (see Chapter XIII, Etiology of Prolapse, page 223) being dislocated and stretched. Injuries of the perineum, actual tears of the anterior vaginal wall, and subinvolution of the vagina are contributory causes. Rupture of the perineum and consequent lack of support to the anterior wall of the vagina is an important factor in the causation. Cystocele is most often met with in working women who have less careful obstetric supervision than the women of the upper classes, and get on their feet before involu-

tion of the uterus, vagina, and perineum have been completed. As injuries of the perineum and pelvic floor are the chief cause of subinvolution it behooves the physician to diagnose and repair these injuries promptly and thus prevent the occurrence of cystocele, which may not develop for months or years after the receipt of the injuries.

Symptoms.—The symptoms depend on the extent of the prolapse. They are, a sensation of fullness in the orifice of the vagina, and the feeling that something projects in that situation on straining, the bulging cystocele being mistaken for uterine prolapse; also dragging and weight in the pelvis, in the case of large cystocele and prolapse, and inability to empty the bladder easily. If the urethra is dislocated (urethrocele) there is more or less incontinence on coughing,

laughing, and straining. There may be residual urine in a dislocated bladder with consequent cystitis. This is rare.

Diagnosis.—There may or may not be evidence of bulging of the anterior wall of the vagina when the introitus vaginæ is inspected with the patient in the dorsal position. Straining brings the anterior wall into view, however. A curved sound introduced through the urethra shows the situation of the base of the bladder as determined by palpation of its tip under the anterior vaginal wall. The extent of the prolapse may be estimated by examining the patient in the standing position and asking her to strain while the examination is made. In the knee-chest position the cystocele disappears. In large cystoceles the vaginal wall is thickened and has the appearance of skin. In prolapse of the uterus it may be ulcerated.

Differential Diagnosis.—We must distinguish cystocele from cyst or other tumor of the vagina, hypertrophy of the bladder

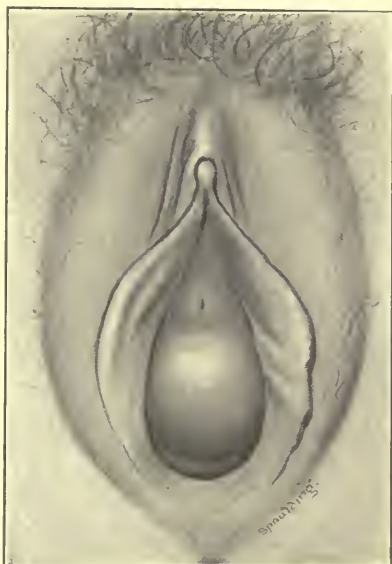

FIG. 148.—Cystocele.

wall in chronic cystitis, sub-urethral abscess, and true intestinal hernia of the vagina. *Tumor of the anterior vaginal wall* does not increase in size or tension on straining and coughing, it does not disappear on pressure or on putting the patient in the knee-chest position, filling the bladder has no effect on the size or elasticity of the tumor, and palpation of a sound in the bladder shows that there is something besides the walls of the bladder and vagina between the tip of the sound and the examiner's finger in the vagina.

Hypertrophy of the bladder wall in chronic cystitis to the extent of forming a tumor in the vagina is rare. The diagnosis of cystitis by means of the cystoscope and examination of the urine, together

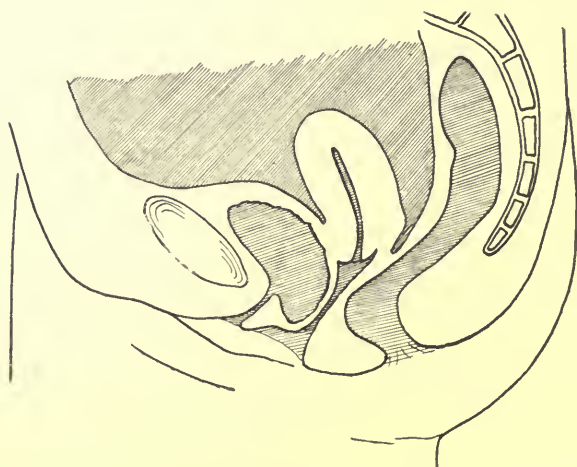


FIG. 148a.—Diagrammatic Representation of Cystocele.

with the symptoms of cystitis, point the way toward a differentiation. Palpation of the greatly thickened bladder by the finger in the vagina will settle the diagnosis.

Sub-urethral abscess is diagnosed by placing a sound in the urethra and palpating the tumor in the vagina on the sound. In this way it will be plain that the urethra is not involved in the tumor. Besides, there are present in the case of the abscess symptoms and signs of inflammation, and there is apt to be a minute opening of the abscess into the urethra through which pus may be forced on pressure.

Anterior intestinal vaginal hernia is a rare condition in which

coils of small intestine occupy a sac formed by a pouch of prolapsed peritoneum between the front of the uterus and the bladder. This pouch projects under the anterior vaginal wall in the same situation as a cystocele. On pressure a true hernia disappears with a gurgling sound, it disappears when the patient is in the knee-chest position, it is soft and doughy to the touch, and the coils of intestine may be palpated between a sound in the bladder and a finger in the vagina, thus showing a greater thickness of the intervening structures than in the case of cystocele.

RECTOCELE

Rectocele is a forward protrusion of the anterior rectal wall into the vagina, although the name is given to any bulging of the posterior vaginal wall, whether the protrusion contains the rectum or not. It is possible for the posterior vagina to become separated from the rectal wall, because of the loose connection of the two structures. As a rule the rectal wall is in the dislocated vagina. Rectocele is one of the concomitants of complete uterine prolapse.

Etiology and Frequency.—Rectocele is caused by rupture of the perineum and pelvic floor, by consequent subinvolution of the vagina, and by chronic overdilatation of the rectum by feces and scybalous masses.

The firm support ordinarily given to the anterior wall of the rectum during defecation, due to contraction of the levator ani muscle at this time, is lacking because of the injury of this muscle. Therefore the fecal mass covered by rectal and vaginal walls is pushed forward into the vagina. Constant straining accentuates the faulty condition. Like cystocele, the development of a rectocele is a matter of

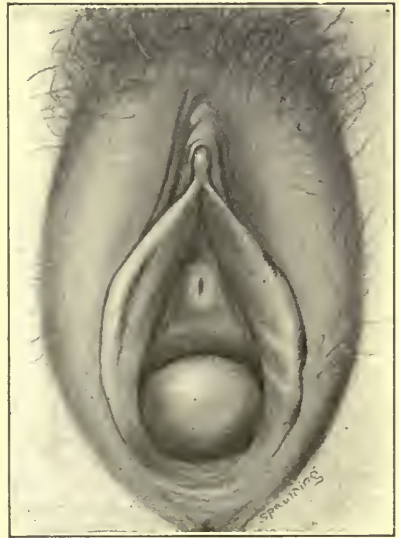


FIG. 149.—Rectocele.

months and years, and the disease is frequent among the working classes for the same reason as in the case of cystocele.

Symptoms.—The symptoms are a sense of fullness in, or protrusion from, the vulva, weight and dragging in the pelvis, and difficulty in defecation. Sometimes the woman is obliged to replace the rectocele with her fingers before she can empty the bowel, and in pronounced cases of rectocele there is apt to be rectal tenesmus and a feeling as if the rectum had not been emptied completely.

Diagnosis.—Bulging of the posterior vaginal wall may be visible

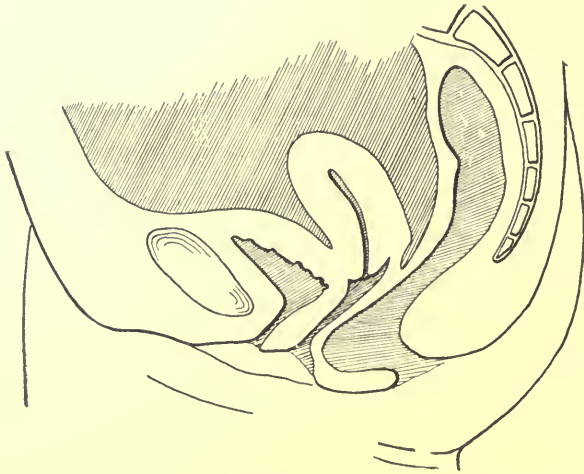


Fig. 149a.—Diagrammatic Representation of Rectocele.

on separating the labia when the patient is in the dorsal position. Straining brings the wall into view and it recedes again when the effort is over. The physician, passing a forefinger through the anus, hooks it forward into the rectocele. This makes positive the diagnosis and differentiates separation of the posterior vaginal wall from the rectum, from cases of true rectocele. We must rule out cysts and other tumors of the posterior vaginal wall and true posterior vaginal hernia or enterocele. Both of these are palpated between a finger in the rectum and another finger in the vagina. A cyst or tumor is fluctuating or hard, and is felt as a distinct mass between the two fingers, whereas in rectocele the rectum and vaginal walls alone are between the fingers.

In the case of enterocele the doughy feel of intestine with gurgling on pressure is to be made out, and, on placing the patient in the knee-chest position the tumor disappears.

HERNIA OR ENTEROCELE

True hernia or the descent of a loop of intestine in a pouch of peritoneum either into the recto-vaginal cellular tissue below Douglas' cul-de-sac, or into the cellular tissue between the uterus and the bladder, is a rare occurrence. It is sufficient to note that cases have been reported and that the diagnosis is made by palpating the tumor and eliciting the doughy feel characteristic of intestine, by noting gurgling noises in the tumor when it is pressed upon, and by observing that the tumor increases in size on straining, but disappears when the patient is placed in the knee-chest position. Such tumors must be differentiated carefully from rectocele, cystocele, or tumor of the vaginal wall. (See these sections.)

In very rare cases an enterocele has been known to find its way to the vulva. In this situation it must be distinguished from inguinal hernia that has reached the labium majus. Examination of the external abdominal ring will show whether the ring is free. Also it is to be differentiated from a cyst of Bartholin's gland or other tumor of the labium. In the case of the enterocele it has an origin from above, has an impulse on coughing, and disappears with the patient in the knee-chest position. A tumor of the labium has none of these characteristics.

INJURIES OF THE VAGINA

Injuries of the vagina may be due to (1) childbearing, to too rapid expulsion of the head, breech, or shoulders, or to pressure of the blades of forceps, (2) to coitus, where there is disproportion between the size of the penis and the vagina, and too great violence is used, (3) to unskillful instrumentation, and (4) to a fall on a sharp body such as a picket.

(1) **Childbearing.**—A majority of injuries due to childbearing consist of lacerations of the perineum, next in frequency are lacerations of the upper vagina, due to the extension of a tear of the cervix to the vagina. Sometimes a circular laceration in the

upper vagina may separate the cervix partially or wholly from the vagina. Generally the tears of the vagina are longitudinal in direction. On one occasion I repaired immediately after a version an extensive longitudinal laceration of the anterior vaginal wall not involving the cervix. Lacerations of the vagina are more apt to occur where the vaginal wall has been narrowed by cicatrices or its elasticity has been impaired by disease.

Lacerations of the Perineum and Pelvic Floor.—By this term is meant not only injuries of the perineal body so-called,—really not an anatomical entity,—but also damage to the structures composing the pelvic floor. These are the levatores ani,—sphincter vaginae, sphincter ani, and transversus perinei muscles, and the following fasciae: posterior layers of the triangular ligament,—called also the transverse perineal septum, a strong mass of connective tissue and elastic tissue in which the muscles are inserted, the anal fascia, the recto-vesical fascia, and the deep superficial fascia.

By conjoined recto-vaginal examination of a nullipara one determines that the tissues between the fingers are of the shape roughly of a triangle, with its slightly convex base the space on the skin between the anus and the fourchette, and its apex at the upper limit in the vagina of the lower anterior curve of the S formed by that canal in its course to the cervix. The tissues feel firm and elastic (the transverse perineal septum) and there is a distinct convexity upward (the patient being in the dorsal position) of the lower posterior vaginal wall.

An attempt to evert the rectum through the opening of the vagina will encounter much resistance and cause pain to the patient. If, now, the patient is asked to strain it is noted that the anterior and posterior walls of the vagina already in contact are pressed more firmly together and that the perineum,—the skin surface between the vagina and rectum,—bulges outward, and the distance between anus and fourchette is increased. If, on the contrary, the woman is told to draw in the muscles it will be found that the anus and the skin perineum are lifted inward and upward toward the posterior surface of the arch of the pubes.

By vaginal palpation pressure directed backward and on both sides of the middle line encounters definite elastic resistance (the levator ani muscles). If the patient is asked to contract the mus-

cles they are felt to become rigid. The significance of a laceration depends on the number of structures involved and on the extent of the injury.

In most first labors there is some injury of the fourchette in the median line. These superficial tears are of little practical importance because they do not involve the supporting structures of the pelvic floor. If the structures composing the perineum are

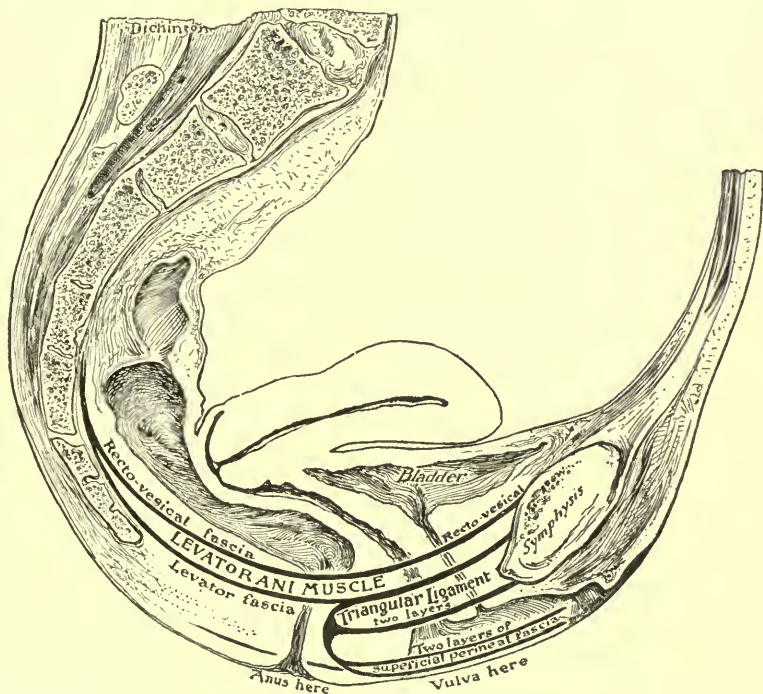


FIG. 150.—Diagrammatic Longitudinal Median Section of the Pelvis, Showing Structures of the Pelvic Floor. (Dickinson.)

rigid and non-clastic, as in the case of old primiparæ, the tear is apt to be deeper and therefore of more serious import.

Tears of the pelvic floor proper are of three sorts: (a) median, (b) lateral in one or both sulci, and (c) a combination of these two.

(a) Median tears, if of any considerable depth, are apt to involve the sphincter ani muscle to a greater or less degree. To put the case a little differently, a vast majority of the lacerations of the

sphincter ani are median tears. In the case of complete laceration of the perineum the pelvic floor proper is not injured to the extent that its supporting power is lessened, therefore we do not expect to find the results of laceration of the pelvic floor in the form of cystocele, retroversion, and prolapse.

Partial or complete loss of control over the bowels is to be expected after laceration of the sphincter ani. If only a portion of the fibers of the sphincter are injured the patient may be able to control her bowels if they are constipated, but not if they are loose; or the retentive power over gas may be lost.

Complete Laceration.—Suppose the laceration is complete. Inspection shows a gaping vulva with the retracted ends of the

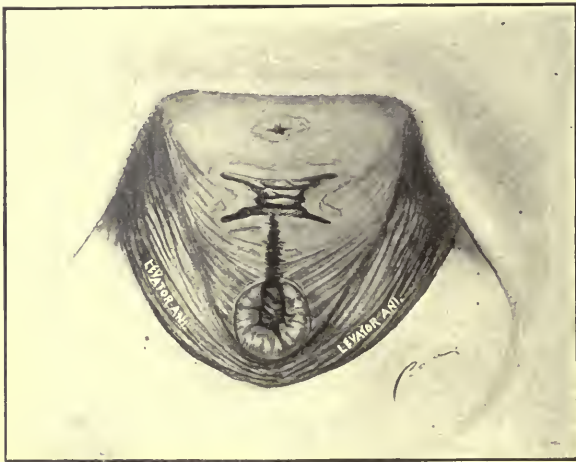


FIG. 151.—Complete Median Laceration of the Perineum. Levator Ani Muscles not Injured. (Gilliam.)

sphincter ani muscle showing as a minute dimple on each side of the anus at the ends of the contracted, crescentic muscle. The recto-vaginal septum, when not extensively torn, stretches above as a tense band across the open anus, in which the bright red corrugated mucosa of the rectum is seen. Unless the levator ani has been injured, the walls of the upper vagina are in contact. If the laceration has not been complete a finger inserted into the anus estimates the amount of damage to the sphincter by noting the strength with which it grasps the finger.

(b) and (c). Lateral tears in the sulci are the common forms

of injury to the pelvic floor. They are the important ones from the point of view of the dislocation and diseases of the pelvic organs which result if they are not repaired.

The lateral tears injure the levator ani muscle. After the injury the muscle ends contract and carry with them the torn fasciæ; some of the injured structures are replaced by connective tissue, and, in the case of tears reaching the surface, by cicatricial tissue. In the course of many years there may be marked atrophy of all the structures composing the pelvic floor. The exact kind of deformity that results in any given case is determined by the

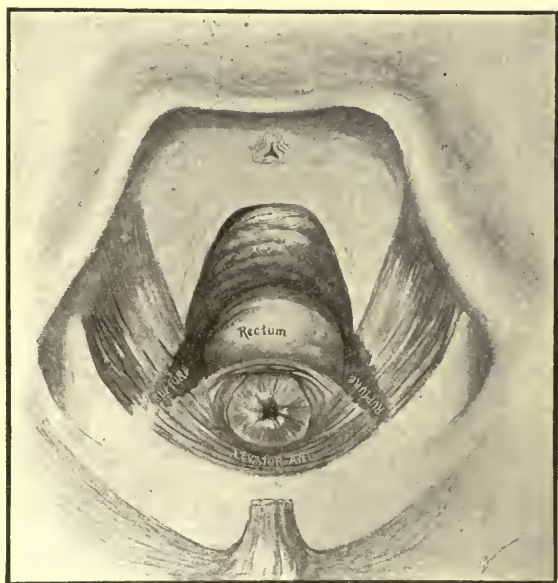


FIG. 152.—Perineum Lacerated in Both Sulci. Levator Ani Muscles Injured. (Gilliam.)

structures involved and the time which has elapsed since the receipt of the injury. Sundering the transverse perineal septum permits the transversus perinei muscles to contract and draw the edges of a wound to both sides of the vulva. At an examination of a fresh tear in the hours following delivery it is possible to get a fairly accurate idea of the structures involved, although the swelling and distortion of the tissues at this time render the determination not easy. By separating the labia and sponging

off the blood, the difference between the shining vaginal mucosa and the oozing raw tissue becomes apparent. The anterior vaginal wall should be held up against the pubes and the tears traced to their farthest limits. With a finger in the rectum the upper portions may be brought better into view. A good light and the patient on a table or on an ironing board on the edge of the bed are essentials to an exact diagnosis. After an interval of months and years we can not say exactly what has occurred at the time of injury. Dissection on the living, in the course of an operation undertaken for the purpose of repair, will not give us this information because of the abundant blood supply of the parts involved. Inspection of an old laceration in the sulcus shows a gaping vulva, vaginal walls apart, perhaps cystocele, rectocele, or prolapse, the perineum is flat and longer than normal because the rectum is displaced backward. When the patient strains the vaginal walls roll down instead of holding closer together, and the perineum between the fourchette and anus, instead of bulging, is concave. Palpation shows a groove in the sulcus and a lack of hardness here when the patient contracts the muscles of the pelvic floor. The perineal septum is always more or less injured in these cases, and palpation of the perineum with one finger in the vagina and the other in the rectum will make manifest that the convex summit of the perineal body, the top of the anterior S curve of the lower vagina, has disappeared and in its place is a depression. In many cases very little injury is apparent when the vulva is inspected because the skin has not been severed. The physician should be on the lookout for the "skin perineum" and not be deceived by it. By hooking a finger into the vagina the absence of the firm convex surface of the perineum will be apparent at once. A common form of laceration is a tear in one sulcus together with a tear in the median line.

By the former we assume that the levator ani is injured and by the latter the transverse perineal septum. Often both sulci are affected and there is also a tear in the median line below. Too much can not be said of the importance of making an exact diagnosis of the situation of the tear in every case of rupture of the pelvic floor, for in this way only can repair be intelligently carried out.

(2) **Injuries due to coitus** are not frequent. Sometimes the first

coitus causes a laceration of the hymen which extends to the vagina and there may be serious hemorrhage. Rape has caused severe and fatal injury of the vagina in children and also in women. In willing coitus whenever there is a large penis and a small vagina injury may occur if force is used.

(3) **Injuries due to unskillful instrumentation** are not very uncommon. The violence is done sometimes by the patient introducing sharp instruments into the vagina in an effort to produce abortion, and at others by the ignorant abortionist, also the unskillful use of the obstetric forceps or other instruments may cause laceration, often of serious import.

(4) **Falls on sharp bodies**, such as the picket of a fence or the handle of a pitchfork, have produced extensive and even fatal injuries.

Hematoma of the vagina is a rare condition. It occurs both as a result of trauma and following labor, the latter being by far the more frequent cause. There is a collection of blood just under the mucous membrane and the tumor is dark in color and fluctuates.

FOREIGN BODIES IN THE VAGINA

Little girls may introduce foreign bodies in the vagina, just as in the other accessible cavities of the body, from a spirit of inquisitiveness. Thus pebbles, seeds, fruit-stones, pencils, hairpins, and other objects have been removed from the vaginae of little girls. Older girls and women, especially the sexually perverted, have introduced the ends of candles, pencils, and other things for purposes of masturbation. Spools, rubber balls, sponges, pieces of cotton, and many other substances have been taken from vaginae in which they had been placed in the hope of preventing conception.

The vagina has served as a repository for smuggled and stolen property, such as jewelry, gems, and banknotes, and, in the case of the feeble-minded, a legion of strange articles have been secreted there. The foreign body most often found in the vagina is a neglected or forgotten pessary. As is well known, a hard-rubber pessary becomes incrustated with lime salts as soon as its polish is gone. The roughened surface chafes the mucous membrane until it ulcerates. Soft-rubber pessaries irritate the vagina more than the

hard-rubber variety, as a rule, but not being so firm do not cut so far into the tissues. Pessaries have been retained for a long series of years in reported cases, and sometimes with resulting stenosis of the vagina. Sometimes a vesico-vaginal or a recto-vaginal fistula is caused in this way. Pin worms and round worms may inhabit the vagina. There is a foul discharge from the vagina if ulceration is present. The diagnosis of a foreign body is an easy matter when digital and speculum examination are made, attention having been attracted by the vaginal discharge.

Gas in the Vagina (Garrulity of the Vagina.)—An accumulation of gas in the vagina that is expelled with a noise on straining or moving the body quickly from one position to another is a not very rare condition. Every gynecologist of experience has seen many cases. In the past it has been thought that such a condition was due exclusively to injuries to the pelvic floor, so that in certain positions of the body, as on the side, air entered, to be expelled later when the woman assumed the upright position. Although such a cause may be operative in some cases, the recent investigations of Kleinwächter, Taussig, and Veit (*“Handbuch der Gynäkologie,”* zweite Aufl., Bd. III, page 201) go to prove that the accumulation of gas in the vagina, a condition most often found in the puerperium, is due to a gas-forming bacterium. The disease is thought to be allied to vaginitis emphysematosa (see page 364) and has been classed by Veit as among the inflammations of the vagina.

When the disease is due to injury of the pelvic floor with subinvolution coupled with weakening of the abdominal walls, the diagnosis is not so difficult. If these conditions do not obtain, and it is due to a gas-forming organism, drying the vagina and packing it with dry tampons on which boric acid powder has been dusted will kill the organism and thus confirm the diagnosis. We must rule out recto-vaginal fistulae in these cases, for gas in the vagina may come from the rectum.

VAGINISMUS

Vaginismus may be regarded as a symptom rather than a disease. It consists of a hyperesthetic condition of the orifice of the vagina and is characterized by spasmodic and painful contractions of the levator ani and constrictor vaginae muscles. Sometimes the irri-

tability extends to the muscles of the thighs or other sets of muscles in the neighborhood of the vulva.

Vaginismus is a rare condition found, as a rule, in young, neurotic women and in the newly married. It may occur, however, in women who have borne children. It may be dependent on a local lesion, such as urethral caruncle or inflammation of the vulva. Masturbation, by overstimulation of the sexual organs, causes vaginismus in some instances. Ineffectual attempts at coitus produce in time erosions at the introitus and nervous excitability and dread of pain. A large penis and a small vagina may cause tonic spasms of the muscles of the pelvic floor. Cases are on record where the penis has become imprisoned in the vagina by vaginismus so that it was necessary to administer an anesthetic to the woman before the couple could be separated. The vagina may be very sensitive, so that the slightest touch or even taking a douche causes contraction of the muscles, and a vaginal examination is impossible without an anesthetic, or it may be caused only by violent intercourse. The nervous system suffers when vaginismus has existed for any length of time and various nervous stigmata may be present. A vaginal examination will determine the cause of the condition. If necessary a second examination with an anesthetic must be made. Vaginismus is one of the causes of dyspareunia,—painful coitus. (See Chapter X., page 146.)

NEW GROWTHS OF THE VAGINA

The new growths of the vagina are: (1) cysts, (2) myomata, (3) sarcomata, (4) carcinomata.

(1) **Cysts.**—Cysts of the vagina are the most frequent of the tumors found in this organ. As a rule, they are between the size of a pea and an English walnut, are single, and found on the anterior rather than on the posterior wall. Very large cysts may develop in exceptional instances, and in such cases the cyst develops in the broad ligament; very rarely a series of cysts is found. A cyst of the vagina appears as a bluish-white, rounded eminence in the pink mucous membrane of the vagina. It is elastic to the feel. If the cyst is situated superficially it projects more into the lumen of the vagina and is of a darker color because of its thin walls; if it

is situated deep in the vaginal wall it projects less prominently and is not so dark in color.

Cysts of the vagina are due to (a) inclusions of epithelial tissue during operations for the repair of lacerations of the perineum, or during spontaneous healing of such injuries; (b) vaginal gland

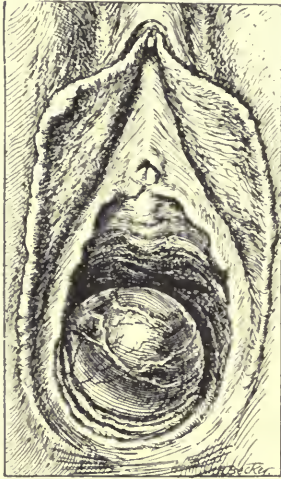


FIG. 153.—Inclusion Cyst of Vagina Occurring Three Years after Repair of a Perineal Tear. (Cullen.)

tissue, and (c) the remains of embryonic structures, such as Gärtner's and Müller's ducts. The inclusion cysts are generally found in the neighborhood of the perineum, in the posterior wall, low down. These are small, spherical in shape, have as contents mucus made turbid by desquamated epithelium, and are lined with a layer of stratified squamous epithelium. Not much is known about the cysts which arise from vaginal gland tissue. They are infrequent as compared with the other two varieties, however. Cysts originating in persistent Gärtner's ducts are comparatively frequent, and are situated in the lateral or anterior walls of the vagina. These cysts are more apt to be cylindrical in shape than perfectly globular, corresponding in their long axis to the axis of the duct, are filled with a clear straw-colored fluid, and are lined with cylindrical epithelium.

A persistent Müller's duct has been referred to in the chapter on anomalies. A blind end of a misplaced ureter has been known to form a cyst of the vagina.

A persistent Müller's duct has been referred to in the chapter on anomalies. A blind end of a misplaced ureter has been known to form a cyst of the vagina.

The diagnosis offers little difficulty. Cystocele, urethrocele, and rectocele must be ruled out, also other tumors of the vagina. An arterio-venous aneurism has been mistaken for a cyst of the vagina, also vaginal hernia, or collection of blood in a double vagina. A sound in the urethra or bladder will assist in excluding urethrocele and cystocele, and a finger in the rectum, rectocele.

A cystocele or rectocele should increase in density on straining, whereas a cyst does not. A vaginal hernia should transmit an impulse on coughing and has a characteristic doughy feel. It dis-

appears when the patient is placed in the kneec-chest position. An aneurism should have a thrill. The characteristics of double vagina have been described in the section on anomalies.

Echinococcus cysts of the vagina are very rare and are generally due to echinococcus colonies in the mesometrium burrowing in the recto-vaginal septum.

(2) **Myomata.**—Myomata or fibroids of the vagina are rare. Some seventy authentic cases have been reported in the literature, being found in most cases in women between forty and fifty years of age. They occur as small, spherical, hard, nodular tumors, seldom over two inches in diameter, projecting from the vaginal wall into its lumen. They are usually single, but may be multiple and are not associated with fibroids of the uterus, although a case where both existed in the same patient has been reported by Fabricius (*Zentralblatt für Gynäkologie*, 1908, No. 36, 1191) and another by Kelly and Cullen ("Myomata of the Uterus," page 440). The tumor is sessile and has a fibrous capsule of its own separating it from the surrounding tissues.

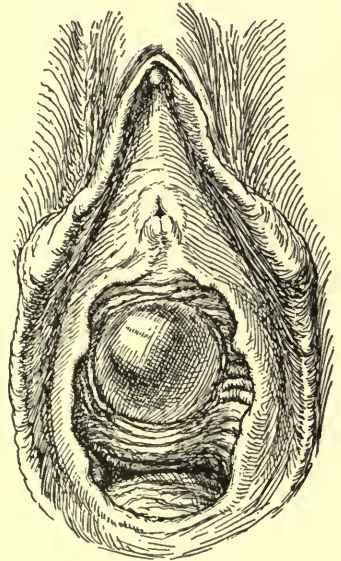


FIG. 154.—Cyst of Anterior Vaginal Wall Probably Due to Occlusion of Gärtner's Duct. (Cullen.)

The etiology of these tumors, just as in the case of fibroids of the uterus, is unknown. They are apt to be the seat of edematous degeneration.

The diagnosis is generally easy, the fluctuating character of a vaginal cyst serving to distinguish it from a myoma, and in the case of sarcoma and carcinoma the mucous membrane covering the tumor is involved, whereas in myoma it is not. The hard character of the tumor serves to distinguish it from cystocoele, rectocoele, or hernia.

(3) **Sarcomata.**—Sarcoma of the vagina is of two sorts, (a) sarcoma of the vagina in children, and (b) sarcoma of the vagina in adults.

(a) *Sarcoma of the vagina in children* is of doubtful etiology, but has been observed very soon after birth. It generally develops in the first year of life and is fatal within a year or two. In one case reported the child lived to be six years old. About forty cases of this disease are on record. The disease is characterized by the development of vesicle-like polypi of a dark red (hemorrhagic) and pinkish-gray (translucent) color, arranged in racemose clusters. In the beginning of the disease the first appearance is a polyp, usually attached to the anterior wall of the vagina. In five out of the sixteen of the twenty-six cases analyzed by Starfinger ("Sarcom der Vagina bei Kindern," 1900) however, the disease began on the posterior wall. Its surface is smooth and it resembles a mucous polyp of the uterus. From this polyp there develop in the course of time, weeks or months or even years, proliferations of cystic polypi until they fill the vagina and project through the vulva. The disease is apt to involve the bladder at an early date, then the cervix and uterus, and finally the peritoneum. Metastases are infrequent, the growth extending mostly by continuity and generally forward into the bladder and peritoneum and not backward into the rectum. Histologically the growth consists of round and spindle-shaped cells, also giant cells and striped muscle fibers. The diagnosis before the disease has progressed extensively is very difficult. A vaginal discharge in an infant should lead to a speculum examination, a Kelly cystoscope with a reflected light being the best instrument for this purpose.

(b) *Sarcoma of the Vagina in Adults*.—Fifty-two cases of this disease are on record. It is a disease of later adult life, few of the cases being under forty years of age. Here, as in the case of the child, the disease begins as a polyp most commonly, although instances of its starting as a diffuse infiltration are reported. It appears to lie latent for a considerable time, just as with the child. The primary lesion may be on either wall of the vagina, and it progresses in its development as a ring-like infiltration so that the vagina is narrowed, or it grows as a diffuse tumor of one wall. Ulceration occurs. The disease does not often penetrate the vesico-vaginal or recto-vaginal septa or extend largely, but metastases to other organs are formed relatively early. Histologically the tumor is made up of small round cells, spindle cells, and giant cells, but not striped muscle fibers. Melanotic sarcoma has been report-

ed in three cases. The appearance of a polyp situated on the vaginal wall, usually with a broad base and of firm consistency, should excite a suspicion of sarcoma. Microscopic examination of the removed polyp will distinguish sarcoma from myoma or carcinoma.

(4) **Carcinoma of the Vagina.**—Carcinoma of the vagina is secondary to cancer of the uterus, in which event it is relatively common, or it is primary, when it is comparatively rare. Schwarz observed 84 cases of primary cancer of the vagina among 35,807 gynecological patients, or something over two-tenths of one per cent. It forms about one per cent of all carcinomata of the generative organs. *Primary cancer of the vagina* is a disease of advanced life, but may occur as early as the twenty-sixth year; it occurs only in women who have borne children and is more often found in the posterior wall. When seen early it is a nodule an inch or an inch and a half in diameter. The edges are sharply defined, infiltrated, and injected. The surface soon becomes necrotic and ulcerated and may exhibit papillary elevations. The nodule is firmly embedded in the surrounding tissues after the very earliest stages. The disease extends extremely rapidly both superficially and deeply, and if the lower portion of the vagina is infected the inguinal lymph glands are involved. The disease tends to extend to the rectum more often than to the bladder and it may reach to the vulva; it originates in the squamous epithelium and has all the characteristics of squamous-celled cancer (see Cancer of the Uterus, page 267).

In getting a specimen of tissue for microscopic examination the deeper tissues must be excised because the superficial portions consist usually of inflammatory products only. The symptoms in the early stages are bleeding from the vagina, on coitus especially, also a watery vaginal discharge.

In making the diagnosis we must rule out secondary carcinoma of the vagina. This is done by discovering cancer of the cervix, cervical canal, or fundus uteri, or cancer of the rectum or bladder. Carcinoma in these situations must be rigidly excluded before pronouncing the disease primary in the vagina. Myoma is excluded by the physical appearances of myoma and by the microscope. If a primary cancerous area lies behind a stenosis of the vagina the diagnosis is more difficult. Inflammations of the vagina with ulcerations are differentiated by the absence of infiltration under the

abscess. If an ulceration caused by an ill-fitting or neglected pessary does not heal rapidly a portion should be excised for microscopic examination.

There have been reported a case or two of *primary chorioepithelioma of the vagina*, and *venereal warts* in conjunction with condylomata of the vulva occasionally occur.

FISTULÆ OF THE VAGINA

An opening between the vagina and the surrounding hollow viscera is called a fistula. Of such fistulæ there are five sorts:— (1) Vesico-vaginal, (2) Urethro-vaginal, (3) Uretero-vaginal, (4) Recto-vaginal, and (5) Entero-vaginal. The last is extremely rare. For the sake of completeness we must mention a communication between the vagina and a pelvic abscess, or the peritoneal cavity, openings made, as in the case of (5), fistula into the intestine, in the course of operations.

Vaginal fistulæ are caused by sloughing of the vaginal walls due to prolonged pressure of the child's head during labor, by injuries from obstetric instruments, by ulceration due to pessaries and other foreign bodies, or by ulcerations from foreign bodies in the bladder. They result also in the late stages of carcinoma of the cervix, vagina, rectum, and bladder, and following operations, especially hysterectomy. In the last case and also when a vesico-vaginal fistula has been formed by operation, nature closes the opening, generally in a short time.

Vesico-vaginal fistula is the most frequent of all the forms of vaginal fistulæ, although not nearly so often met with as in the olden days before the art of obstetrics had been perfected to its present high degree of excellence. The vaginal and bladder walls are involved in varying extent. Almost the entire base of the bladder may slough away, leaving the orifices of the ureters exposed in the edge of the fistula, or the opening between the bladder and vagina may be no larger than a pin's point. The symptoms are leakage of urine from the vagina, and, unless great care is maintained by the patient to keep dry, excoriation, redness, and soreness of the vulva, perineum, and thighs. The amount of urine lost will depend on the size of the opening and on the retentive power

of the vagina. Sometimes urine is retained in the vagina while the patient is recumbent, the pelvic floor being uninjured and the introitus small. Often when the fistula is small the patient may void a portion of the urine through the urethra and the rest will escape through the vagina.

The diagnosis is made by the history of incontinence and by the physical examination. The digital touch, if the fistula is large, will

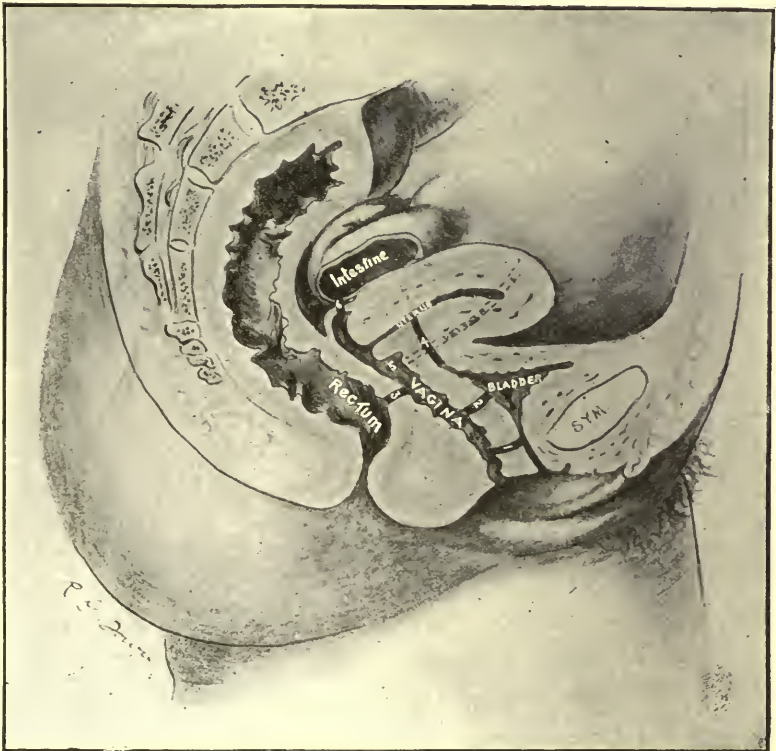


FIG. 155.—Scheme of the Different Sorts of Genital Fistulæ, not Including Fistula-in-Ano. (Gilliam.) 1. Urethro-vaginal. 2. Vesico-vaginal. 3. Recto-vaginal. 4. Vesico-uterine. 5. Uretero-vaginal. 6. Entero-vaginal.

indicate the size and situation of the fistula. The patient is placed in the Sims position and a Sims speculum introduced. Inspection shows the size, shape, and situation of the fistula. A sound or probe passed through the urethra may be made to appear through the opening in the vagina. In larger fistulæ the bladder wall is apt to be much injected (cystitis) and often incrustated with lime salts.

These must be removed gently. Vesico-vaginal fistula gives a fine opportunity to inspect the bladder and to catheterize the ureters. If the fistula is very small and there is doubt as to its situation, the patient is placed in the dorsal position and the bladder is filled with milk and water. Examination of the cleansed vagina through a duckbill speculum will show the point at which the white milk leaks through the fistula.

Uretero-vaginal fistula is detected in the same manner. The bladder is filled with milk and water and it is noted that clear urine and no milk collects in the vagina; measure the bladder urine and that which gathers in the vagina, and, if the two kidneys are secreting an equal amount, it is possible, by finding that the two quantities are the same, to decide that all the urine from one ureter escapes into the vagina. The sense of smell is a great help in detecting the presence of urine, for in some instances the differentiation of watery fluid coming out of the uterus or the peritoneal cavity from urine is not easy. To aid in distinguishing urine in cases of vaginal fistula it is sometimes of use to give the patient five drops of doubly distilled turpentine on a lump of sugar three times a day. It imparts the characteristic odor of violets to the urine. Methylene blue, one to two grains every four hours given by the mouth, renders the urine a bluish-green color. The colored urine may be seen to escape from a fistula.

Urethro-vaginal fistula is a rare variety of fistula due to syphilitic or malignant ulceration or operation on the urethra. The opening between the urethra and vagina is generally small and is situated in the upper course of the urethra. There is no incontinence of urine unless the fistula involves the neck of the bladder. The diagnosis is made by passing a probe into the urethra and through the fistula. For fistulae involving the bladder and ureters see also Chapters XXIV and XXV, pages 474 and 492.

Recto-vaginal fistula results in the late stages of cancer of the cervix and also in the case of neglected pessaries and imperfect union of a lacerated perineum. Rarely this fistula results from syphilitic or tuberculous lesion of the vagina. The opening is generally small in size.

The symptoms are the escape of flatus, and also more or less fluid feces, into the vagina. Vaginitis and vulvitis are apt to result from the irritation caused by the fecal matter.

The diagnosis is founded on the history, and on the examination. The patient is placed in the dorsal position and the anterior vaginal wall raised by a Sims speculum. If the fistula can not be seen a probe is passed in the most likely spots and if it enters an opening which connects with the rectum its point may be felt by a finger in that organ. Also, one may inject the rectum with milk and water and note its escape into the vagina.

Entero-vaginal fistula is rare. It results generally from a surgical operation. The presence of feces in the vagina, the exclusion of an opening into the rectum by means of inspection of the rectum through a proctoscope, the character of the fecal matter (chyme), and finding the opening of the fistula in the upper vagina on inspection and probing with the patient in Sims position, will establish the diagnosis. For fistula-in-ano see Chapter XXVI, page 516.

CHAPTER XXI

THE DIAGNOSIS OF DISEASES OF THE VULVA

Anatomy, p. 388: Age changes, p. 391.

Congenital Anomalies, p. 391: Malformations of the vulva as a whole, p. 391. Development of the external genital organs, p. 392. Anomalies, p. 393. Malformations of the clitoris, p. 393. Malformations of the labia majora, p. 394. Malformations of the labia minora, p. 394. Malformations of the hymen, p. 396. Imperforate hymen, p. 396. Hermaphroditism, p. 399.

Injuries of the vulva, p. 400.

Inflammation of the vulva, p. 402: Simple or catarrhal vulvitis, p. 402. Gonorrhœal vulvitis, p. 402. Diabetic vulvitis, p. 403. Thrush, p. 403. Elephantiasis, p. 404. Pruritus vulvæ, p. 404. Kraurosis vulvæ, p. 404. Edema and gangrene, p. 405. Varix, p. 405.

Venereal lesions of the vulva, p. 406: Chancre, p. 406. Chancroids, p. 406. Chancre, p. 406. Mucous patches, p. 407. Condylomata, p. 407. Gumma, p. 408. Tuberculosis of the vulva, p. 408.

Cysts of Bartholin's gland, p. 408: Abscess of Bartholin's gland, p. 409; Differential diagnosis of cyst and abscess, p. 412.

Labial Hernia, p. 412.

Benign tumors of the vulva, p. 413.

Malignant tumors of the vulva, p. 414: Cancer, p. 414; Differential diagnosis of cancer, p. 415. Sarcoma, p. 416.

ANATOMY

THE term vulva is applied collectively to the structures often called the external genital organs, and includes: the mons veneris, the labia majora and minora, the clitoris, the vestibule, and the hymen.

The Mons Veneris.—The mons veneris is the eminence in front of the symphysis pubis. It is formed by a collection of subcutaneous fat and is covered with coarse hair, generally of the same color as the hair of the head. The upper limit of the hair is a horizontal line, differing from the male pubic hair, which is continued upward along the linea alba in a V shape. Below, the hair is continuous with the hair on the outer surfaces of the labia majora.

The Labia Majora.—These are two thick, parallel folds of skin

extending from the mons veneris nearly to the anus. They are wider above and grow thinner as they approach the perineum where they are lost. Each fold is called a labium majus and the opening where the two meet in the middle line is called the pudendal slit (rima pudendi). The posterior limit of the slit is a transverse cutaneous fold called the fourchette, the depression between this and the base of the hymen being the fossa navicularis.

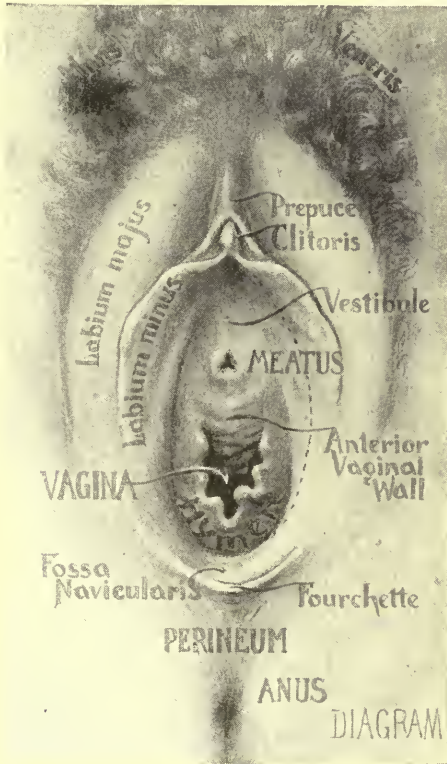


FIG. 156.—Diagram of the Vulva. (Dickinson.)

The labia majora are pigmented more than the surrounding skin and the outer surfaces contain sebaceous glands and are covered with more or less hair, the hair becoming scanty and short toward the posterior parts. The inner surfaces of the labia majora are smooth, and the thin skin covering them resembles mucous membrane in the virgin, but is harder in the parous woman. The outer ends of the round ligaments become lost in the upper por-

tions of the labia majora, which are made up of fat and connective tissue.

The Labia Minora, or Nymphæ.—These are two thin, pink, delicate folds of skin extending from the frenum of the clitoris above, downward to be lost on the inner surfaces of the labia majora at about the level of the opening of the vagina. They are developed from the margins of the genital cleft. They have no hairs but abundant sebaceous glands. Each fold is a labium minus, and the two labia may be asymmetrical. In the virgin the lesser labia are entirely covered by the greater labia, but under abnormal conditions the nymphæ may project beyond the labia majora, and in this case they are pigmented.

The Clitoris.—This is a rudimentary penis developed from the genital eminence, but it is without a urethra traversing it (see Fig. 157). It is situated between the labia majora and is concealed by the upper portions of these structures, it is about an inch and a quarter long, and arises from the pubic arch by two crura, which unite to form the body of the clitoris. At its tip is a glans, which is covered partially or wholly by a prepuce, that, coming from above and partially encircling the glans, is prolonged downward into the labia minora. The clitoris is made up of erectile tissue and the glans is covered by a very sensitive epithelium. At the base of the glans are sebaceous glands which secrete smegma.

The Vestibule.—The space between the clitoris above, the entrance of the vagina below, and the nymphæ on the sides is the vestibule. It is developed from the urogenital sinus, is, roughly, triangular in shape, and is pierced in its centre by the external orifice of the urethra, (meatus urinarius) which presents a longitudinal slit closed by two little lips (labia urethræ) which form a slight elevation above the surface of the vestibule.

The Hymen.—This is a thin, circular, white or light pink, perforated membrane which separates the vulva from the vagina. It is made up of connective tissue and elastic fibers and is covered on both sides with stratified epithelium. Its shape, thickness, and even its situation vary in different cases. The opening into the vagina (introitus vaginæ) is generally in the anterior part; it may be ring-shaped (annular), admitting the tip of the forefinger; this is the commonest condition, or it may be cribriform, fimbriate, horseshoe-shaped, septate or linear. The tissues of the hymen

may be tough and resistant, though generally friable and torn with the first coitus or even by vaginal examination, always by parturition. The remains of the torn hymen are called *carunculæ myrtiformes*. In the infant and embryo the hymen projects forward into the cleft between the labia in the form of two apposed longitudinal lips. (See Figs. 163 to 170.)

The Glands of Bartholin.—These glands furnish a clear, glairy, lubricating mucus for coitus and for the delivery of the child during labor. They are two in number, each is about the size of a large pea and is situated at the side of the posterior part of the vaginal canal in the sphincter vaginae muscle. The opening of the canal of the gland is a minute pin-point hole to be found in the posterior portion of the inner surface of the labium majus. In women who have borne children it is just outside the last and uppermost *caruncula myrtiformis*.

AGE CHANGES

Infancy.—In infancy there is no visible hair on the mons, and the labia majora are rounded and firm, the labia minora projecting between them as slightly elevated, pink folds. (See Fig. 203.)

Puberty.—At puberty hair grows on the mons and the outer surfaces of the labia majora, the latter becoming pigmented and increasing in size so that they conceal the nymphæ. The nymphæ may grow larger after puberty, and if they do, the exposed parts become pigmented and of coarser texture. Enlargement of the nymphæ has been ascribed to masturbation, and it is likely that such is sometimes the case, though this is not the only cause.

Old Age.—The hair on the mons and labia majora becomes gray and is shed soon after the hair of the head. After the menopause the mons loses its fat gradually and the labia shrink so that in old age the orifice of the vulva gapes. The hymen if unbroken shrinks, and the introitus vaginae is narrowed in any event.

CONGENITAL ANOMALIES

Malformations of the Vulva as a Whole.—True congenital anomalies of the vulva, such as complete atresia of the vulva, are very rare and occur for the most part in non-viable fetuses. There are

on record, however, one case of double vulva in an adult, and many cases of infantile vulva where the labia majora and minora were small and flat, the introitus narrow, and the mons veneris not prominent and poorly provided with hair. Such a condition is usually associated with poorly developed general physique. Precocious development of the vulva is found sometimes in conjunction with precocious menstruation in very young children. In these cases the breasts also show abnormal development. In the chapter on diseases of the vagina, page 356, I have referred to the not infrequent occurrence of a normal vulva and normal body form

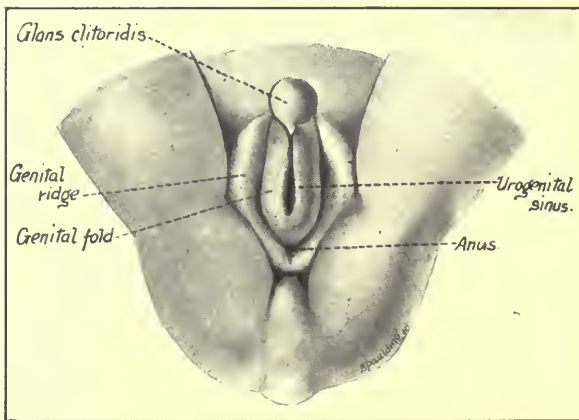


FIG. 157.—The External Genital Organs at the Beginning of the Third Month of Fetal Life. (After Keibel.)

associated with a rudimentary uterus and vagina. An appreciation of the steps in the development of the several parts of the urogenital system is a necessity for the proper understanding of the different congenital malformations of the external genitals.

Development of the External Genital Organs.—At the end of the first month of intra-uterine existence there is developed in the outer surface of the caudal region of the embryo a depression in the skin (Fig. 158), which grows deeper until it reaches the allantois and rectum to form the cloaca (Fig. 159). About this time appears the genital eminence above the cloaca, flanked on each side by a fold of skin. The genital eminence in the female becomes later the clitoris, and the folds of skin the labia majora, the nymphæ being developed on their inner surfaces. (See Fig. 157.) Figure

160 shows the differentiation of the bladder and rectum from the allantois and hind gut respectively, and the beginning of the formation of the perineum by the downward extension of the perineal septum between the rectum and the urogenital sinus, which has been formed by a union of the ducts of Müller and the cloaca. The proctodeum, the posterior portion of the invagination of the skin that is to form the anus, is now differentiated. In Fig. 161 the urethra has been formed and a septum divides the urinary from the genital tract. Figure 162 (at about the end of the fourth month) shows the vagina, although not yet with a canal, developed from the ducts of Müller and separated by the hymen from the vulva. The perineum has its mature shape and the anus now opens backward. The vestibule, the clitoris, and both sets of labia are already formed, although they do not assume their final shape until the fifth or sixth month. The external genital organs are at birth much more completely developed than the internal organs, which remain in a more or less rudimentary condition until the child is eight or ten years old.

Anomalies.—*Persistence of the Urogenital Sinus.*—This is most often met with as an opening of the anus into the vagina, “anus vaginalis” so called, in which there is incontinence of feces because of the absence of the sphincter ani muscle. There is met with rarely a *hypospadias*, or a connection of the urethra with the vagina high up, the vestibular canal being long. Another form of *hypospadias*, also rare, is the condition where there is no urethra and the bladder opens directly into the vestibular canal. In these cases there is of necessity incontinence of urine and the bladder opening can be seen in the anterior wall of the vagina.

Occasionally a case of *persistent cloaca* is met with, the perineal septum and the sphincter ani not being developed. Incontinence of feces exists in such cases.

Malformations of the Clitoris.—The clitoris may be absent, it may be small, it may be hypertrophied, it may be cleft, as in *epispadias*, or the prepuce may be adherent. Absence of the clitoris is an extremely rare occurrence, and so is cleavage of the clitoris, but the organ is found very small not infrequently, and large quite commonly. Sometimes the clitoris attains the size of a small puerile penis. Such a condition has no clinical significance and requires no treatment unless it interferes with coitus,—an unusual happening.

An adherent prepuce, on the other hand, may be the source of sexual irritation and conduce to masturbation, and in children may be the cause of enuresis, some writers even attributing the existence of symptoms of grave derangement of the general nervous system to this as a cause. All women who apply for gynecological treatment should be examined with reference to the adhesions of the prepuce. The prepuce should be pushed upward with two fingers until the glans can be distinguished. By the use of gentle pressure, aided if necessary by the flat end of a surgical probe, the prepuce may be separated from the glans. Hard, white specks of retained smegma not larger than a pin's point are generally found under the adherent prepuce. Some authors maintain that adhesion is a condition normal to the prepuce in both sexes. The number that are found to be adherent in girls and women, if every case coming under observation is examined for this condition, has been surprisingly large in my experience, and my own view is that adhesion of the prepuce in the girl and woman plays a much less important rôle in the causation of symptoms than in the boy and man.

Malformations of the Labia Majora.—The following malformations have been described, although all must be regarded as extremely rare. Absence of the labia, rudimentary labia, multiple labia, hypertrophy of the labia, and adhesions of the labia. The only ones that require comment are multiple and adherent labia. The former consists of longitudinal division of the labia into several folds of skin instead of one, and the latter is a part of apparent vulvar atresia. If the closure is complete the child is non-viable. Generally there is a small opening anteriorly through which micturition takes place.

Malformations of the Labia Minora.—The same malformations as in the case of the labia majora have been met with. The two that need description are hypertrophy of the labia and adherent labia. *Hypertrophy of the nymphæ* is by no means rare. It reaches a stage of extreme development in the "Hottentot apron," so-called, in which the labia extend downward some seven or eight inches between the thighs. This condition is unknown among the women of civilized races. A moderate degree of hypertrophy is not uncommon and is of no importance unless it interferes with coitus. *Adherent labia* represent inflammatory affections during

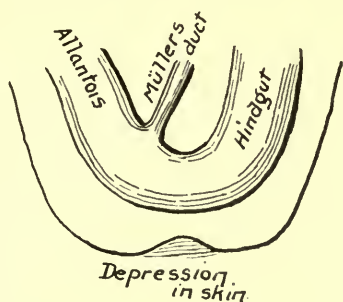


FIG. 158.—The Allantois, the Hindgut, Müller's Duct and the Depression in the Skin.

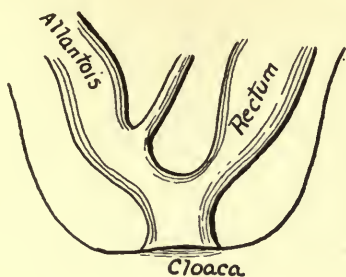


FIG. 159.—The Depression in the Skin Has United with the Allantois and Hindgut to Form the Cloaca.

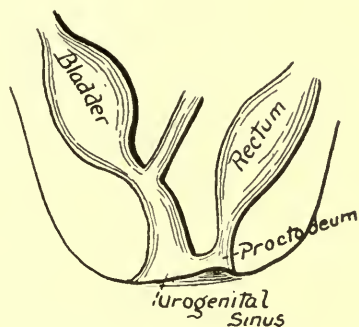


FIG. 160.—The Bladder Is Formed, also the Beginning of the Urethra and the Vagina, Both Opening into the Urogenital Sinus. The Rectum opens Separately into the Proctodeum.

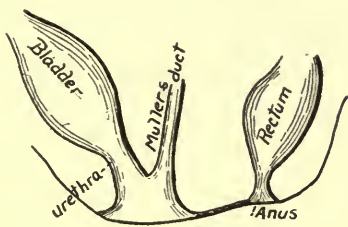


FIG. 161.—The Urethra is further Developed, the Opening of the Vagina Reaches nearer the Vulva, and the Perineum Is Formed.

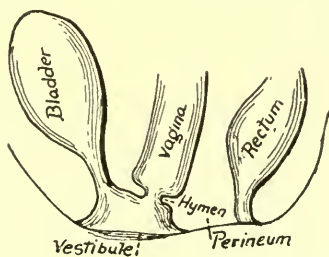


FIG. 162.—Complete Development. The Urogenital Sinus Has Become the Vestibule. The Hymen nearly Closes the Opening of the Vagina, which Has Become Enlarged. The Rectum is more Capacious and the Anus Opens Backward Posterior to the fully Developed Perineum.

fetal or infantile life. The union is generally incomplete and there is an opening through which urine can escape. Immediate division of the two labia is demanded if there is no opening when a child with this deformity is born, otherwise it is non-viable.

Malformations of the Hymen.—Authorities are divided as to the structures from which the hymen is developed. Pozzi's view of its development ("Traité de Gynécologie," quat. édit'n, p. 1383) seems as near the facts as any. It is that the hymen is developed in the fifth month from both the vagina above, after fusion of the Müllerian ducts, and from the vestibular canal,—a vestige of the urogenital sinus,—below. Gellhorn (*Amer. Jour. Obstet.*, Aug., 1904, p. 145), who has studied this question most carefully, thinks that the indications point to the hymen being derived from the Müllerian ducts exclusively.

The hymen has never been found absent by competent observers. As has been stated in describing the anatomy, the form of the hymen varies much in different individuals, also its thickness. Of the different forms in which the hymen is found, the fimbriate or, denticulate, the septate, the cribriform, the annular, the linear and the crescent, the annular and crescent-shaped hymens are the most common. The hymen may be so tough and resistant that it is not ruptured by attempts at sexual intercourse, on the other hand it may be so dilatible that it stretches to accommodate the penis without tearing. The rule is that it is generally torn by intercourse, and always by parturition. Cysts and solid tumors of the hymen have been described, but they are excessively rare.

Imperforate Hymen.—The opening in the hymen may be extremely minute and yet pregnancy may ensue. A case has been recorded by H. L. Horton (*Boston Med. and Surg. Jour.*, vol. 82, p. 33) of a patient who was in labor with a hymeneal opening measuring only one-sixteenth of an inch in diameter. From the most recent researches the view has gained ground that imperforate hymen is a misnomer, the condition being one really of atresia of the vagina, for in many of the cases recorded after the liberation of retained menses a hymen has been found outside the obstructing membrane. In other words, the lower end of the vagina, which is a solid structure in the early stages of development after the fusion of Müller's ducts and before the canal is formed,

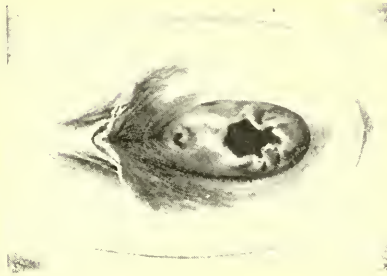

Fig. 163. — Annular Hymen of Virgin.

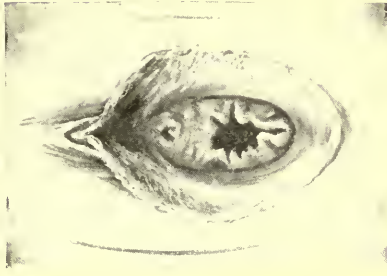

Fig. 164. — Annular Hymen which Has Been Dilated by Coitus.

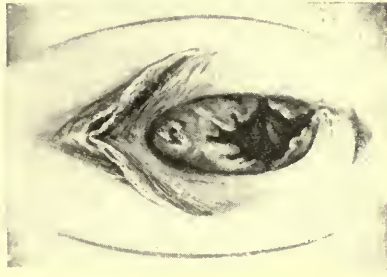


Fig. 165. — Carunculae Myrtiliformes.




Fig. 166. — Fimbriate Hymen.

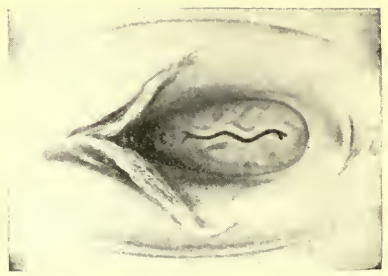


Fig. 167. — Hymen with Vertical Slit.

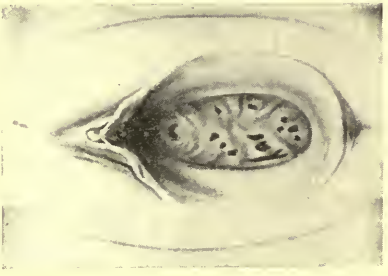


Fig. 168. — Cribriform Hymen.

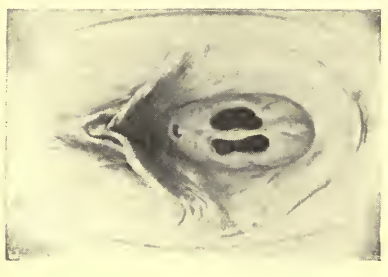


Fig. 169. — Hymen with Vertical Septum.

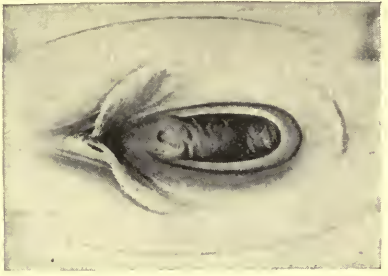


Fig. 170. — Horseshoe-shaped Hymen.

FIGS. 163-170. — EIGHT FIGURES SHOWING THE DIFFERENT FORMS OF THE HYMEN. (Dickinson.)

remains impervious in the adult. Be the cause what it may, the result is a damming up of the uterine secretions with resulting hemato-colpos, hematometra and even hematosalpinx.

The vulva of every female infant should be inspected by the obstetrician and the patency of the orifice of the vagina determined by passing into it a catheter. Most cases of imperforate hymen are not discovered until puberty, in rare instances the malformation has not been suspected until early marriage. There may be few symptoms, and these nothing more than a sense of weight and fullness in the pelvis. As the accumulated blood increases in amount the patient may experience colicky pains in the abdomen and interference with micturition and defecation. Amenorrhea, when the body shape and the psychic changes of puberty announce the presence of that state, should lead to a local examination, especially if there is a menstrual moli-

men.

FIG. 171.—Hemato-colpos, Caused by Atresia of the Vagina or Imperforate Hymen.

Diagnosis of Imperforate Hymen.—The diagnosis rests on the physical examination. Inspection shows a bulging in the region of the introitus vaginae which is of a bluish tinge. The urethral orifice is dilated. Recto-abdominal palpation reveals the presence of a fluctuating mass in the region of the vagina; if the case is an early one, the vagina alone may be dilated, if a later case the uterus, or the uterus and the tubes are enlarged (see Figs. 171, 172 and 173.) The utmost gentleness should be employed and it is wise not to make too exact a diagnosis because of the danger of rupturing the tubes, should they be distended. A more precise finding is gained after an anesthetic has been administered, and

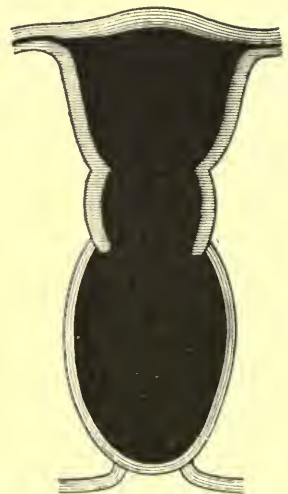
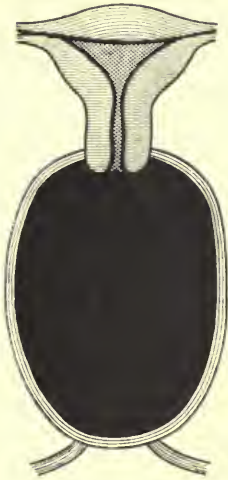


FIG. 172.—Hemato-colpos and Hematometra.

this could not be given until the preparations have been made for evacuating the fluid.

Hermaphroditism.—Hermaphroditism (Hermes and Aphrodite), the union of the two sexes in one individual, is a term generally used to describe a person whose external genital organs partake of the characteristics of both sexes. Every embryo is in the beginning potentially both male and female; some preponderating influence determining the development of the Wolffian or the Müllerian ducts, so that it is not strange that remnants of the undeveloped ducts should be found in the adult. The steps of the development of the sexual organs are indicated in Fig. 71, page 198 and in Figs. 158–162.

True Hermaphroditism.—A true hermaphrodite, according to Neugebauer, is an individual who can impregnate another and also can be impregnated itself by another individual; not only that, it may impregnate itself. According to this definition true hermaphroditism occurs in the lower animals, as in the cestopods. The gastropods, on the other hand, can fructify each other but not themselves. True hermaphroditism in the functional sense does not occur in man, but in the sense that an individual may have a genital gland which contains both ovarian and testicular tissue, an ovotestis, five undoubted cases have been reported, by V. Salén, Garré, Piek, and Schickele. One of Piek's two cases was that of a woman who had borne several children and Garré's case was that of a male hermaphrodite twenty years old. Therefore, true hermaphroditism, defined as the occurrence of a combination gland of both ovary and testicle in the same person, does occur. A preponderating number of the reported cases are instances of pseudohermaphroditism. Neugebauer in his exhaustive work has gathered together 1,886 cases of pseudohermaphroditism in addition to the five cases of true hermaphroditism.

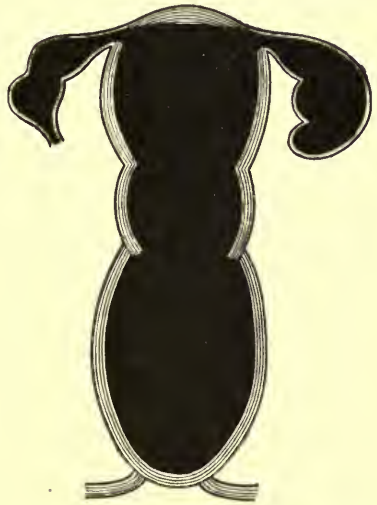


FIG. 173.—Hematocolpos, Hematometra and Hematosalpinx.

Pseudohermaphroditism.—Pseudohermaphroditism is more often of the male variety.

Male False Hermaphroditism.—Here the body form, stature, hair, and breasts are of the male type; testicles are always present, but the external genital organs are malformed. The penis is undersized and the glans imperforate, while the penile urethra is represented by a groove running into a cul-de-sac which corresponds to an incomplete vulva. The two halves of the scrotum have failed to unite in the median line, thus resembling the labia majora, and enclose a rudimentary vulvar orifice scarcely admitting a finger tip. One half of the scrotum may contain a testis, and the other testicle may be in the inguinal canal. It is a condition of hypospadias in the male. There are many varieties of this type. The cases are apt to be regarded as females and are brought up as girls until after puberty when they show sexual inclination toward females.

Female False Hermaphroditism.—This is less common than the male kind. The ovaries are always present, but may be in the labia majora. The body form, stature, and hair are of the female type, but the individual may have a beard and the breasts may be poorly developed. The clitoris is large, resembling a penis, the labia majora are fused in the median line so that they are like a scrotum, and the vagina is small.

For a complete exposition of this subject, with descriptions and illustrations of the many cases of hermaphroditism that have been reported, the reader is referred to Neugebauer's work ("Hermaphroditismus beim Menschen," 1908).

INJURIES OF THE VULVA

Injuries of the vulva may be divided into (a) those due to child-bearing, (b) those due to direct violence, and (c) those due to coitus.

(a) *Childbearing.*—The labia majora are apt to be bruised and lacerated, more often the former, by the obstetric forceps. Lacerations are generally superficial, but may involve the vulvo-vaginal glands. *Hematoma of the labium majus* occurs occasionally following difficult labor and may attain great size. It is especially liable to occur in patients who have suffered with varix of the vulva

during late pregnancy. Hematoma is diagnosed by a tense swelling of a dark color, due to the clotted blood showing through the skin of the labium, and it is very sensitive on pressure. Such a hematoma very seriously complicates labor. The nymphæ are torn now and then, but such wounds are seldom serious. The vestibule may be torn near the clitoris so that dangerous hemorrhage may result, but this is an unusual occurrence. Injuries of the hymen have been referred to under the malformations of the hymen, page 396, and lacerations of the perineum are treated in the chapter on diseases of the vagina, page 372.

(b) **Direct Violence.**—The vulva, because of its situation, is protected from the more common forms of injury, but may be injured by falls astride of a sharp object, or by kicks, or blows. The close proximity of the unyielding bony arch of the pubes and the abundant blood supply of the parts make wounds in this region more serious. Women have fallen astride of a chair, or a pitchfork, or the saddle of a bicycle, or a fence picket, with resulting wound of the vulva, generally attended by excessive bleeding. Blows or kicks are apt to take effect on the labia majora with resulting *hematoma*, generally of one labium, and sometimes of considerable size. The hematoma may suppurate, become gangrenous, or, if not of a severe grade, may be absorbed. The dark blood generally shows through the skin; the hematoma is not often larger than a closed fist, and of course is very sensitive. Children have been injured by splinters of wood penetrating the vulva while sliding down a board, or by being thrown on sharp objects while coasting.

(c) **Coitus.**—Injury of the hymen at the first intercourse often results in bleeding which has been known to be alarming in amount in very rare cases: usually the bleeding is of no moment. Severe injury of the vulva from rape upon young girls has been reported, the wound involving the perineum, labia, or even the recto-vaginal septum, there being cases on record where a recto-vaginal fistula resulted from brutal coitus. Disproportion in the size of the penis and the vagina in the case of young girls and old women has given rise to injuries, which must be considered as of infrequent occurrence.

INFLAMMATION OF THE VULVA: VULVITIS

The vulva, being covered by modified skin and hair, is affected by the same sort of skin diseases as the other hairy parts of the body. The forms of skin diseases that most frequently affect the vulva are, erythema, eczema, herpes, acne, tuberculosis, condylomata, kraurosis, elephantiasis, thrush, pediculus pubis, syphilis, erysipelas, diphtheria, and gonorrhœa. The last is the most frequent of the causes of inflammation of the vulva; other causes are, lack of cleanliness, irritating vaginal discharges, or irritating urine, as in diabetes mellitus, local irritation, as from scratching or an ill-fitting napkin, and, finally, any constitutional exhausting diseases that lessen the resisting power of the tissues.

Simple or Catarrhal Vulvitis.—Simple or catarrhal vulvitis is the most common form of vulvitis and may be due to want of cleanliness, pediculi pubis, excessive coitus, abnormal discharges from the uterus, fecal or urinary fistulæ, or malignant disease. In the acute form it is characterized by tenderness, burning and throbbing at the vulva, smarting on urination, and profuse, non-purulent discharge. In the chronic form itching and burning are noticeable symptoms, also a discharge that is thinner and less in quantity than in the acute stage of the disease. The vulva is congested and more or less swollen in its various parts and there may be excoriations or even ulcerations. In some cases the hair and sweat follicles are infected and the vulva is studded with papules and pustules. This follicular vulvitis is a rare form of vulvar inflammation seen mostly in the clinics of Europe. In diphtheritic vulvitis a characteristic gray membrane, composed of fibrin, is formed on the vulva, and a similar appearing membrane, but with little fibrin, also occurs in puerperal cases from the action of bacteria other than the Klebs-Loeffler bacillus, generally the streptococcus. The superficial inguinal glands take up infective matter from the vulva and even in the simple, catarrhal vulvitis may be enlarged. The disease has no tendency to invade the vagina or urethra and microscopic examination shows the absence of the gonococcus.

Gonorrhœal Vulvitis.—In this variety, by all odds the most frequent form of vulvar inflammation, the disease has a tendency to invade the neighboring organs, and we have vaginitis, endocervi-

citis, urethritis, and inflammation of Skene's and Bartholin's glands, as well as the vulvitis proper; the vulvitis, in fact, being the least important of the gonorrhœal processes. The discharge is purulent and of a yellow or greenish-yellow color; the disease affecting the urethra early, there is burning, and frequent micturition from the beginning. The inguinal glands may be involved and a "bubo" is developed in the course of a few days; also, the vulvo-vaginal glands are apt to be infected. The diagnosis rests on the severity of the inflammation following a suspicious intercourse, on the presence of urinary symptoms, on being able to express a drop of pus from the urethra or one of Bartholin's glands, and on finding the gonococcus in the discharge. Gonorrhœal vulvitis is not uncommon among infants and little girls, especially in institutions, and may lead to adhesions of the labia minora or even the labia majora. The entire vulvar cleft may be closed except a small opening either in front or behind through which the urine escapes. Lesser degrees of adhesions are by no means rare, and careful examinations of the women who present themselves in the out-patient clinics will reveal many cases of agglutination of portions of the nymphæ, or adhesions burying the glans clitoridis.

Diabetic Vulvitis.—Diabetic vulvitis is an inflammation of the vulva caused by the decomposition of the urine in diabetes mellitus by the *saccharomyces fungus*. Its symptoms are burning and intense itching, and tenderness of the vulva. On inspection the vulva is of a dull, reddish color and the surfaces of the labia and vestibule are parchment-like, corrugated, and dry. Excoriations from scratching are to be expected, or even the presence of small boils, and in time the disease affects the skin of the mons veneris and the insides of the thighs and the anal region. The diagnosis is made by finding sugar in the urine and by the appearance of the vulva, which is most characteristic.

Thrush of the Vulva.—This rare disease is caused by the *Saccharomyces albicans*, just as in the case of parasitic stomatitis. It is found most often in nursing women, in advanced diabetes, tuberculosis, cancer and in women who are exhausted physically. The parts affected are covered with slightly elevated, snow-white spots, which have a tendency to coalesce and leave shallow ulcers. The *saccharomyces fungus* in the form of mycelium and spores may be found in the discharges scraped from the surface.

Elephantiasis of the Vulva.—Elephantiasis is extremely rare except in tropical climates. It affects mostly the labia majora, but may involve the clitoris or the nymphæ. It occurs between the twenty-fifth and fiftieth years of life, and is characterized by thickening and enlargement of the tissues, sometimes forming a large tumor that has fissures and ulcerations on its surface.

Pruritus Vulvæ.—This is a symptom which may be due to a variety of causes, and consists of intense itching of the vulva. (See also Chapter X., page 160.) The various skin diseases such as eczema and pediculosis are characterized by itching, also the vulvitis due to diabetes, and the presence of *Ascaris lumbricoides* and *Oxyuris vermicularis*, especially in young subjects. Lack of cleanliness may cause itching and so may irritating discharges, as well as congestion of the vulva, as in varicose veins of the vulva and in pregnancy. Aside from these definite causes the terminal nerve filaments in the vulva may be affected so that itching results, as in the case of some old women and in certain nervous diseases, and we are ignorant of the causation. For the purposes of prognosis and treatment it is important to determine, as far as possible, a definite cause. Great sensitiveness of the vulva may be due to a neuritis affecting the nerves of this region, and the physician will do well to rule out this affection before resorting to local treatment.

Kraurosis Vulvæ.—Kraurosis vulvæ is a progressive atrophy and contraction of the tissues of the vulva of unknown cause, occurring mostly after the age of forty. The disease affects the nymphæ, clitoris, and vestibule and begins as small brown spots, of irregular shape and slightly depressed, on the surface of the labia minora and the vestibule. Soon the tissues of the vulva become tense, shining, white, and contracted; the meatus urinarius presents a reddened prominent appearance, and along the caruncule myrtiformes are small patches of subcutaneous hemorrhage. The nymphæ atrophy. The orifice of the vagina becomes contracted so that it will barely admit the tip of a finger without causing hemorrhage or great pain. The pubic hair has a peculiar stubbly appearance and may be broken or may come out. The labia majora are not much affected by the atrophic process, as a rule. Microscopic examination of the tissues shows small-round-celled infiltration and great development of fibrous tissue, with absence of

hair follicles and sebaceous glands. Left to itself the disease runs a chronic course of five or six years. The symptoms are great irritation, smarting on urination, and painful intercourse, which may cause lacerations, the parts being very friable; the lacerations being severe if pregnancy and labor occur. The symptoms may be entirely relieved when the atrophic process has reached its climax. The diagnosis is established by the appearance of the vulva.

Edema and Gangrene of the Vulva.—*Edema* of the vulva may occur as a result of vulvitis, but is more commonly the result of interference with the pelvic circulation by pressure on the pelvic veins by tumors, pelvic inflammatory masses, or the pregnant uterus, or it may form a part of a general anasarca. The nymphæ and the prepuce of the clitoris are the parts mostly affected, but in extreme cases the labia majora and even the mons veneris become enormously distended. Pitting of the tissues on pressure is the diagnostic sign to be looked for. *Gangrene* may follow excessive edema or erysipelas of the vulva, or as a complication of the exanthemata, also in dirty, underfed children, where it is analogous to noma, or as an epidemic puerperal disease, or an acute inflammation independent of contagion. The nymphæ are the portions of the vulva most affected by gangrene. It begins usually as a livid red, indurated swelling of one labium, soon breaking down into dirty gray or dull red ulcerations and followed by a greenish-black layer of gangrene.

Varix or Varicose Veins of the Vulva.—*Varix* is found often during the later months of pregnancy. The enlarged veins are in the labia majora, and one or both sides may be involved, the left more often than the right. The vulva being well supplied with blood-vessels and also with erectile tissue, it is not surprising that obstruction to the veins should result in varix. The dark veins may be seen through the skin of the labium, and to the touch present the characteristic feeling of a bag of worms, as in the case of varicocele of the scrotum. Similar varicosities are to be found in the veins of the upper and inner thigh, and also in the vagina.

Rupture of the veins of the vulva during delivery results in a hematoma of the vulva.

VENEREAL LESIONS OF THE VULVA

Venereal lesions include chaneroids, chanere, mucous patches, and condylomata lata and acuminata.

Chancroids are most often found on the fourchette, the inner surfaces of the labia majora, the nymphæ, and the vestibule; they are multiple as a rule, and are more common among the uncleanly. Secondary infection is usual and fresh chancroids keep appearing; and often some that seem to be healed break down and ulcerate anew. The lesion begins as a pustule that soon becomes an ulceration; the ulceration has a punched-out undermined edge, a soft, non-indurated base, which has a granular, uneven surface covered by a purulent discharge. This discharge is auto-inoculable. The sore is sensitive to touch. The chaneroid appears about forty-eight hours after an infecting coitus and develops rapidly. Secondary infection of the lymphatic glands of the groin (a bubo) involves commonly only one gland in a severe grade of inflammation, causing pain and often suppuration.

Chancre of the Vulva.—This is relatively rare, an extra-genital situation of the initial lesion of syphilis being more frequent in the female than in the male. Also, because of the inaccessibility of the parts and the trifling discomfort to which they commonly give rise, chaneres of the vulva often escape observation. The initial lesion of syphilis, if situated on the vulva, is generally to be found on the labium majus; the next most frequent situation is the fourchette, then the nymphæ, the clitoris, and the mons veneris in order of frequency. The chanere appears as a hard, red lump which soon ulcerates; the induration of its base being a characteristic feature, also the enlargement, in six to ten days after its appearance, of the individual lymphatic glands in most intimate connection with it. The chanere appears after an average period of twenty-six days from the time of inoculation, and is nearly always single, but may be multiple if several abrasions have been inoculated at the same time. The ulcer formed by the chanere has smooth edges, often elevated or sloping, never undermined, and the base is of smooth surface and indurated, and the secretion, which is serous and scanty, is not auto-inoculable. The infection of the lymphatic

glands of the groins, primary adenopathy, affects several glands in a painless enlargement.

Diagnosis of Chancre of the Vulva.—The diagnosis of chancre is often a matter of extreme difficulty. The discovery of the *Spirochaeta pallida* in the secretions or a smear from the chancre makes the diagnosis sure, but failing this the three most important points are, the long period of incubation of the disease, the induration of the base of the sore, and the enlargement of the individual lymphatic glands in the groin.

A recent writer on the diagnostic significance of the *spirochaeta pallida*, R. P. Campbell, *Jour. American Medical Association*, Vol. LIV, March 19, 1910, page 924), speaks as follows from a large clinical experience in Montreal: "It should be possible to find the *spirochaeta pallida* in approximately 100 per cent of chancres excluding those which are nearly healed, or have been actively treated, and some cases of mixed infection. In view of this fact, treatment should not be begun before the diagnosis is confirmed by finding the *spirochaete*."

Differential Diagnosis.—*Herpes of the vulva* is excluded by the appearance and the feel of the herpes: a superficial group of vesicles with a soft base disappearing after a short time. The crops of herpes may be multiple, while chancre is single.

Furunculosis of the vulva has been mistaken for chancre. Here the boils are apt to be multiple and run the usual course of a furuncle. The chief lesion that is confounded with chancre is the chaneroid, and the distinguishing characteristics of the two lesions have been touched upon in the two preceding pages.

Mucous Patches.—Mucous patches in the vulva are a frequent manifestation of secondary syphilis. They occur as moist papular syphilides and erosions, and have a discharge with a foul odor. The *Spirochaeta pallida* is abundant in scrapings from these patches and they are a most frequent source of syphilitic contagion. They are apt to be converted into *condylomata lata* or into a fusion of several papules to form cauliflower-like growths on the genitals, with fissures and ulcerations. *Condylomata accuminata*, occurring in cases of gonorrhoea and unclean persons with irritating vaginal discharge, are not the same as the *condylomata lata*. The acuminate variety are pointed, more wart-like, pedunculated, and of a branched, tree-like character. Their color may be that of the sur-

rounding skin, or, if the epithelium has been removed by friction or maceration, they are of a deep red hue. They have a foul discharge and may affect any portion of the vulva or the inner surfaces of the thighs, and may grow to the size of a fist.

Gumma.—A gumma as a manifestation of tertiary syphilis may develop as a round tumor in the labium majus. It has a tendency to break down by a sort of fatty degeneration, but not to suppurate.

TUBERCULOSIS OF THE VULVA

This is a rare affection, there being on record only some fifteen or twenty cases. The disease is generally seen in the ulcerative stage in women between twenty and forty years of age, the ulcers being of a grayish color, of varying size, with irregular edges, exhibiting in their bases tubercles in process of cheesy degeneration, and friable, poorly nourished granulations. The ulcers are situated in the vestibule or on the labia or perineum. The diagnosis is often difficult, numerous sections of the ulcerated tissues being made before tubercles and the tubercle bacilli are found. The inguinal glands are not affected in this disease; the ulceration proceeds slowly, having a course of from eight to ten years, and there is no marked induration of the tissues. The disease has been called also lupus vulvæ, and *esthiomène de la vulve*.

CYSTS OF BARTHOLIN'S GLAND

It is not surprising that the duct of the vulvo-vaginal gland, which is only half a millimeter in diameter at its exit, should become occluded as a result of infective inflammation, thus damming up the secretions. Gonorrhœal inflammation is supposed to be a cause for the obliteration of the duct of the canal and therefore a cause of the formation of a cyst. Be that as it may, cysts of Bartholin's gland are of sufficiently common occurrence. They are usually unilateral, vary in size from half a centimeter to four centimeters in diameter, and occur during the childbearing period of life. The smaller ones may be due to the occlusion of a secondary, branching duct, rather than the main duct.

A cyst gives little trouble as a rule, though the larger ones may interfere with coitus; they are rarely painful. The patient generally gives a history of old inflammation of the vulva. The diagnosis consists in detecting a fluctuating, not tender swelling in the situation of the vulvo-vaginal gland (see figures from Huguier).

Cysts of the secondary ducts and of the gland itself are situated

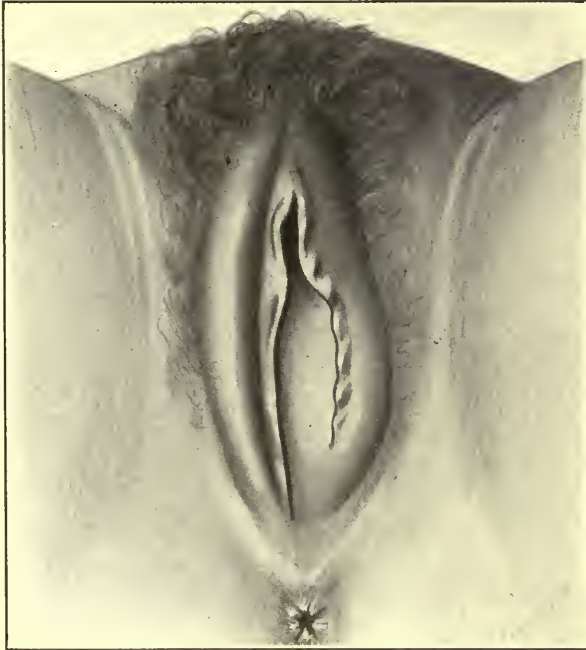

FIG. 174.—Cyst of the Left Bartholin's Gland. (After Huguier.)

deeper in the tissues and farther from the introitus vaginae than cysts of the main duct, and such cysts may be multilocular, whereas cysts of the main duct are always unilocular. When laid open cysts of Bartholin's gland are found to be filled with a glairy, colorless, white-of-egg mucus, and to be lined by a smooth membrane.

ABSCESS OF BARTHOLIN'S GLAND

Abscess of the vulvo-vaginal glands is very common and is due, in a large proportion of cases, to gonorrhœa. One gland at a time is affected, as a rule, more often the left, and the disease is generally

met with in women under thirty years of age, who are likely to have gonorrhœa, such as prostitutes and women of loose habits. The duct of the gland, or the gland itself, may be involved, Huguier having reported cases of the former. (See Fig. 175.)

In severe and neglected cases the gland becomes disorganized. Huguier thought that cysts of the duct or gland become infected and suppurate.

Suppuration in the gland or canal is apt not to come on until the

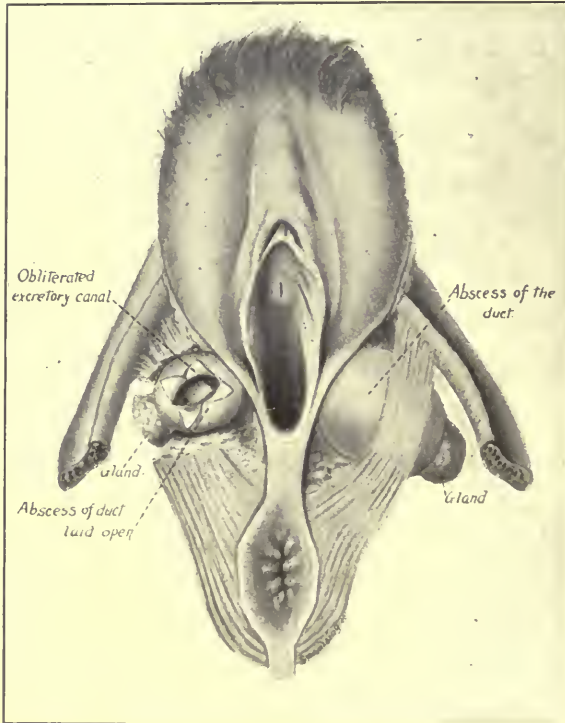


Fig. 175.—Abscess of the Ducts of Both Bartholin's Glands. (After Huguier.)

later stages of gonococcus infection. Then there is a recurrence of heat and burning in the vulva with sharp pains, slight elevation of temperature, and tenderness of the tissues, the symptoms being aggravated by standing, walking, and sitting even, the patient being most comfortable in the recumbent posture. There may be retention of urine, or the urine simply smarts. Examination shows swelling and edema of the labium and sometimes pus escapes

from the orifice of the duct on the inner surface, or the abscess may be evacuated spontaneously through openings below the orifice. The inguinal lymphatic glands are affected sometimes and a "bubo" results. After the subsidence of the acute inflammation the vulvo-vaginal gland is apt to remain in a state of chronic inflammation and a drop of pus, perhaps with a greenish tinge, or a muco-puru-

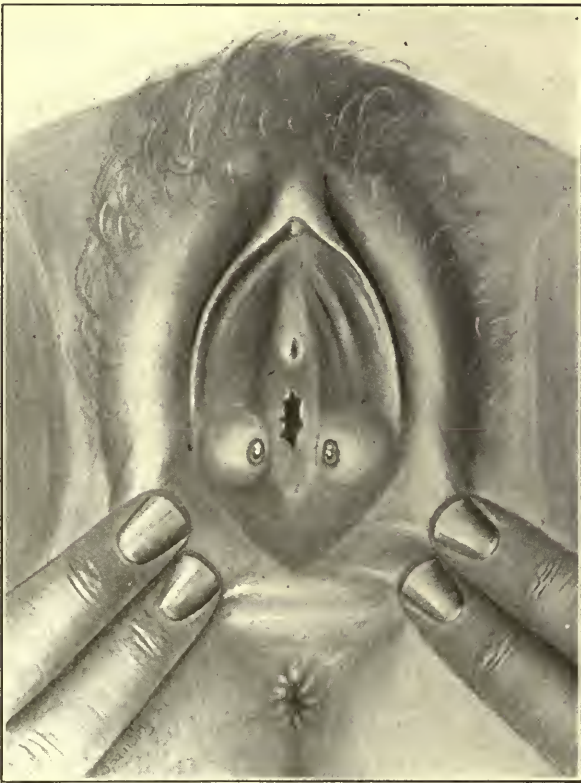

FIG. 176.—Abscess of Both Bartholin's Glands. (After Huguer.) A Drop of Pus is shown in the Orifice of Each Duct. Note Relation of Orifices to Introitus Vaginae.

lent discharge issues from the duct. At this stage the orifice is surrounded by a red areola which resembles a flea bite, the so-called *macula gonorrhoeica* of Sanger. It is in this stage that infection is apt to be transmitted to the male and light up in his urethra an acute gonorrhoea, or it may cause puerperal sepsis or ophthalmia neonatorum. Relapse is common in abscess of Bartholin's gland

and the opposite gland may become infected, therefore prompt surgical treatment is indicated. Smears should be made from the discharges and examined for the gonococcus.

DIFFERENTIAL DIAGNOSIS OF CYSTS AND ABSCESS

In cases of long-standing inflammation the tissues may be so thickened that malignant disease is simulated. Microscopic examination of tissue excised will establish the diagnosis. A rectal fistula discharging through the labium has been mistaken for an abscess of Bartholin's gland. Examination per rectum in such a case reveals brawny swelling, and the opening of the fistula in the bowel may be made out by means of the proctoscope and the probe. Hematoma of the labium makes a more uniform swelling than a cyst or abscess and feels doughy, also the skin is dark in the case of the hematoma and there is a history of injury or of recent parturition. Inguino-labial hernia appears in the upper part of the labium and tends to disappear when the patient lies down. There is an impulse on coughing, and in the case of hydrocele of the canal of Nuck the swelling is also in the upper part of the labium, but it is irreducible. Hydrocele of the Canal of Nuck is treated in the chapter on the diseases of the uterine ligaments. (See Chapter XII., page 213.)

LABIAL HERNIA

An inguinal hernia not infrequently finds its way into the labium majus and sometimes there is a double hernia of this sort. The hernia descends through the inguina canal and follows the course of the round ligament into the labium; this form of hernia being analogous to scrotal hernia in the male. The hernial sac may contain only omentum or it may hold intestine, the uterine tubes, the ovaries, or even the uterus. It is caused by the failure of the canal of Nuck to become obliterated. The patient complains of pains in the region of the hernia, especially on exertion, and is apt to suffer with dyspepsia and constipation. If the hernia is reducible the lump in the vulva disappears when the patient is in the recumbent posture.

If the sac contains omentum the swelling is irregular in feel, provided the fat over the tumor is not excessive in amount, thus obscuring the tactile sense. The percussion note is flat and there is no gurgling sound in it when reduced and very little impulse on coughing.

If the hernial sac contains intestine the swelling is smooth, regular, and elastic. It is increased in size and becomes more tense on coughing or straining, and if reducible disappears or becomes smaller when the patient lies down. As the hernia goes back into the abdominal cavity a gurgling sound is heard. The tumor of the labium is tympanic to percussion and an impulse is transmitted to it when the patient coughs.

Should an ovary be in the hernial sac pressure will cause pain similar to the pain experienced when the normal ovary is pressed between the fingers in a bimanual examination.

If the uterus is in the sac bimanual examination of the pelvis will reveal the absence of the uterus from its usual situation.

Differential Diagnosis.—Hernia into the labium must be differentiated from hydrocele of the canal of Nuck, from a tumor of the labium, or a cyst of Bartholin's gland. From the first it is distinguished by the fact that it is tympanitic, has an impulse on coughing, may have an irregular contour, is reducible, and has gurgling on reduction. Hydrocele is irreducible, is of smooth outline, has no impulse, and is flat to percussion. A solid tumor of the labium is generally of hard consistency; it projects from the surface, has no impulse on coughing and no gurgling. A cyst of Bartholin's gland is globular, has no impulse, is flat to percussion, and is situated in the lower part of the labium, whereas a hernia is oval, has an impulse, may be tympanitic, and is in the upper part of the labium.

BENIGN TUMORS OF THE VULVA

These are fibroma, myoma, myxoma, neuroma, angioma, lipoma, and cysts. They are rare. Most of them affect the labia majora. J. Bondi has found three sorts of cysts of the labia minora, of which the mucous cysts are the most frequent. He thinks they represent remains of the Wolffian bodies. They are situated in the upper part of the labium. Lipoma may grow from the fatty tissue of the

mons veneris or the labia majora, or even from the nymphæ, and may attain considerable size. The diagnosis of benign tumors can not be made exactly, short of removal and microscopic examination of the tissues of the tumor. Slow growth is the rule, and the only symptoms are interference with coitus and the discomfort attending the presence of the growth.

MALIGNANT TUMORS OF THE VULVA

These are cancer and sarcoma.

Cancer.—*Primary cancer of the vulva is rare.* It is a disease of advanced life, usually occurring between the ages of forty-five and sixty. Its most frequent point of origin is the groove between the nymphæ and the labium majus, but it may develop from the prepuce of the clitoris or any of the structures of the vulva. The cancer appears in one of three forms, as a circumscribed elevation, as a deep ulceration with infiltrated margins, or as a diffuse infiltration. The circumscribed growth is a firm tumor rising from the surface of the vulva and more or less movable on the underlying, infiltrated tissues. If the cancer has broken down it is a friable lobulated or warty mass, showing points of ulceration. The surface is granular, furrowed, and bright red in color, and the base is indurated. The carcinoma may invade the deeper tissues from the beginning, not forming a circumscribed growth on the surface. In this case the tissues become of a brawny hardness and are thickened over an area of considerable extent. This sort of growth may progress very slowly, and ulceration may not appear for several years. The tendency of the disease is to involve the structures of one side of the vulva and then to extend to the opposite side, perhaps by inoculation. The lymphatic glands of the groin are involved early, and the individual glands are to be distinguished as separate, hard lumps.

Cancer of Bartholin's gland occurs as a round, indurated tumor, often as large as a hen's egg, in the lower portion of the labium majus. The tumor is generally very vascular, and large vessels can be made out in the overlying skin.

Cancer of the vulva is of the type of squamous-celled carcinoma, and cancer "pearls," due to horny degeneration of the centers of

the epithelial nests, are abundant. Like cancer in other situations in the genital organs, this form of cancer has no symptoms which are peculiar to itself. Pain is a late symptom after the disease has extended and involved the larger nerve trunks. Ulceration causes local tenderness and a discharge.

Differential Diagnosis of Cancer.—In the early stages of cancer the following diseases must be excluded: tuberculosis, condylomata lata and acuminata, chancre, chancroids, and urethral caruncle. *Tuberculosis* occurs in younger women, *i.e.*, between twenty and forty years of age, and is of slower growth; the nodules are multiple and soft, the induration of the base being absent; tubercles may often be seen in the cheesy degenerated areas; and the inguinal glands are not involved. The microscope will settle a doubtful diagnosis. It is to be remembered that the two diseases are both present sometimes in the same case. *The two sorts of condylomata* are excluded by the history; in the case of condylomata lata there is a history of syphilis, and in condylomata acuminata, of gonorrhœa; also by the absence of ulceration and pain.

Chancre in its early stages may resemble cancer. In the former there is a history of infection followed by a definite period of incubation, twenty-six days. The initial lesion is not painful, its ulcer shows no tendency to spread to the surrounding tissues, and its discharge is scanty, muco-purulent, and thin, as opposed to the profuse purulent discharge of the cancerous ulcer. If the *Spirochæta pallida* can be found in smears from the surface the diagnosis of chancre is made certain. Also, the secondary symptoms of syphilis are developed within six weeks after the appearance of the initial lesion.

Chancroids are preceded by a history of infection two days or so before the development of the ulcers, which are generally multiple. Only one lymphatic gland at a time is involved as a rule in chancroids, and the gland tends to suppurate; in cancer several glands are affected and they do not suppurate. The chancroid ulcers are punched out, with undermined edges, and their bases are of smooth surface, and are not indurated. The ulcer from chancre is single, it has sloping edges, and a rough and indurated base. *Urethral caruncle* occasionally simulates beginning cancer. Caruncle is, however, of soft consistency. When ulcerated it should be removed promptly and subjected to a microscopic examination.

Sarcoma of the Vulva.—Primary sarcoma of the vulva is extremely rare and occurs in young subjects as a rule. The melanotic variety is the one most often found, but spindle-celled and round-celled forms have been reported. In the melanotic variety the lesions are multiple and appear as hard, round nodules several centimeters in diameter, of a black or brown color, and originating in warts, moles, or naevi. The nodules tend to coalesce and to become ulcerated, but do not attain great size. In the other varieties the nodules are generally single, grow rapidly, and may attain considerable proportions, even as large as a man's head. They do not ulcerate and the lymphatic glands are rarely affected.

CHAPTER XXII

THE DIAGNOSIS OF UTERINE PREGNANCY, ABORTION, AND HYDATIDIFORM MOLE

Diagnosis of normal uterine pregnancy, p. 417: During the first three months, p. 418; History, p. 418, Amenorrhea, p. 419, Nausea and vomiting, p. 419, Salivation and minor digestive disturbances, p. 420, Breasts, p. 420, Leucorrhœa, p. 420, Bladder disturbances, p. 420; Inspection and palpation, p. 420, Breasts, p. 421, Areola, p. 421, Inspection of the vulva and vagina, p. 421, Bimanual touch, p. 423. During the last six months, p. 426; History, p. 426, Quickening, p. 426; Inspection and palpation, p. 426, Gait, p. 426, Figure, p. 426, Breasts, p. 426, Secondary areola, p. 426, Vulva, p. 427, Bimanual touch, p. 427, Internal ballottement, p. 429, Abdomen, p. 427; Auscultation, p. 429, Tabular statement of symptoms and signs of pregnancy by months, p. 430. Differential diagnosis of normal pregnancy, p. 431; During the first three months, p. 431, Ante flexion, p. 431, Chronic subinvolution, p. 431, Fibroid in the anterior wall, p. 431, Retroflexion, p. 431, Extra-uterine pregnancy, p. 431; During the last six months, p. 432.

Diagnosis of abnormal uterine pregnancy, p. 432: Diagnosis of retroflexion and incarceration of the pregnant uterus, p. 432. Diagnosis of interstitial pregnancy and of pregnancy in a rudimentary horn of a bicornute uterus, p. 433. Diagnosis that pregnancy has occurred previously, p. 433. Diagnosis of multiple pregnancy, p. 434. Diagnosis of pernicious vomiting of pregnancy, p. 434.

Diagnosis of abortion, p. 436: Definitions, p. 436. Frequency, p. 437. Etiology, p. 437. Symptoms, p. 438. Diagnosis, p. 439; Diagnosis of threatened abortion, p. 439; Diagnosis of inevitable abortion, p. 439; Diagnosis of abortion partially or wholly completed, p. 440; Diagnosis of miscarriage, p. 440. Differential diagnosis, p. 440.

Diagnosis of hydatidiform mole, p. 441: Pathology, p. 441. Symptoms, p. 443. Diagnosis, p. 443.

THE DIAGNOSIS OF NORMAL UTERINE PREGNANCY

THE diagnosis of normal uterine pregnancy offers often many difficulties to the practising physician and is perhaps the most important department of diagnosis. Vander Veer collected seventy-seven instances of abdominal operations on supposedly pathological growths, some of the operators being men of note, where the patient was pregnant in each instance. Hirst mentions the fact

that a gynecologist on the staff of a large hospital has twice operated for fibroid tumors of the womb, and only after the amputation of the uterus found that it was pregnant, and not the seat of a fibroid tumor at all. Both patients died. I have seen the same thing happen in the experience of a prominent surgeon to one of the largest hospitals, although the subsequent fate of the patient was unknown. I have also known of a surgeon of large experience operating for ovarian tumor on the wife of a noted obstetrician, the diagnosis being made by the apprehensive husband and by an internist, the operation proving that there was no ovarian tumor, the excessive abdominal enlargement being due to pregnancy and hydramnios. Mistakes are so frequent that no excuse is necessary for occupying space in describing a subject which, by a strict interpretation, belongs in the domain of obstetrics.

The diagnosis of pregnancy depends on the history; on inspection of the face, neck, figure, breasts, abdomen, and vagina; on the bimanual examination, and, in the later months, on auscultation of the abdomen.

DURING THE FIRST THREE MONTHS OF PREGNANCY

The diagnosis of pregnancy before the fetal heart sounds are heard or fetal movements felt in the fifth or sixth month is not an absolute certainty; still, the strongest sort of a probability may be expressed if all the facts are taken into consideration. The demonstration of the changes in the genital organs due to the increased blood supply and the growth of the ovum form the basis of a diagnosis; contributory facts are the alterations in the breasts, the body form and carriage, and the effects on the nervous system.

History

To get the history of pregnancy is not always an easy matter, for patients not infrequently conceal the facts either because, in the case of the unmarried, they hope the physician may pass a sound into the uterus and cause abortion, or they are ashamed to acknowledge immorality, or, in the case of those pregnant for the first time, because of inaccurate observation. Patients who have been pregnant previously can say sometimes that pregnancy began with a particular coitus when especially pleasurable sensations

were experienced, also morbid cravings for special sorts of food or disturbances of digestion have been the same as with former pregnancies.

Amenorrhea.—Absence of menstruation is one of the chief symptoms of pregnancy. In questioning the patient the exact date of the beginning of the last menstruation should be obtained and also how long it lasted, and whether it was in all respects similar to the usual menstrual periods. Did coitus occur soon after this period? The end of the last catamenia is the date from which the beginning of pregnancy is usually reckoned. If the patient has been always regular in her menstruation, amenorrhea of two months is a most suspicious circumstance; if, on the other hand, she has been habitually irregular or if she is nursing a baby, so much importance can not be attached to it. Cases are on record where menstruation has occurred at irregular intervals during the entire pregnancy; in fact, one or two shows of blood during the first few months are by no means uncommon. About half of all nursing women menstruate during lactation, and as the number of pregnancies increase the tendency to menstruate while nursing increases also, therefore amenorrhea during lactation is not a constant sign. Baudelocque, Deventer, and others have reported instances of regular menstruation occurring only during gestation, but such cases are rare. Amenorrhea may occur in chlorosis, maldevelopment of the uterus, or the beginning of the menopause, in tuberculosis, obesity, acute constitutional diseases, prolonged lactation, chronic poisonings, particularly lead, or from change of climate, or profound mental disturbance. Amenorrhea is common in girls who have immigrated from a foreign country. A majority of the Irish girls seen in the out-patient clinics of Boston have amenorrhea for several months after arriving in this country. Acromegaly, occurring as it generally does in young subjects, is apt to have complete amenorrhea as one of its first symptoms, and tumors of the base of the brain, especially those involving the hypophysis cerebri, as pointed out by Harvey Cushing, have amenorrhea as a prominent symptom.

Nausea and Vomiting.—The morning sickness of pregnancy is a fairly common but by no means an invariable accompaniment of gestation. It varies from an occasional qualm to active nausea and vomiting occurring when first assuming the erect posture in

the morning. Some patients can not brush their teeth without being nauseated. The symptom does not manifest itself as a rule until the fourth or fifth week, but may begin as soon as ten days after conception. It occurs also in Bright's disease, gastritis, and chlorosis. These diseases must be ruled out, and if there has been a previous pregnancy, nausea and vomiting will probably have occurred with it. The symptom must be regarded as due to the enlargement and stretching of the uterine muscle fibers and nerves. The nausea may occur at other times than in the morning and may persist throughout pregnancy, although it generally ceases after the third month.

Salivation and Minor Digestive Disturbances.—An excessive flow of saliva, heartburn, eructations, and abnormalities in appetite such as longings for strange or unusual articles of food, are not unusual accompaniments of pregnancy. Occasionally patients are seen who enjoy better digestion and even better general health while they are pregnant than at any other time.

The Breasts.—A sensation of weight and fullness in the breasts, often accompanied by tingling sensations, is common to pregnancy, and patients who are observant note greater prominence of the nipples, and enlargement of the follicles in the darkened areolæ.

Leucorrhœa.—There is a marked increase in vaginal discharge during pregnancy. This is noted early with the occurrence of the engorgement of the genitals; but, of course, leucorrhœa may be due to other causes. It is seldom that the increase in the discharge in early pregnancy is enough to attract the patient's attention.

Bladder Disturbances.—Increased frequency of micturition is a most common accompaniment of early pregnancy, probably due to congestion of the vesical trigone coincident with the physiological hyperemia of the uterine organs.

Inspection and Palpation

Since the days of Hippocrates and Democritus certain changes in the face and neck have been observed in pregnant women. The eyes seem to be deeper set, and may have bluish circles under them: there are brownish-yellow blotches upon the skin of the cheeks, which are fuller than usual, and the neck seems larger than when the woman is not pregnant. Too much importance is not to

be attached to these signs, which may be entirely absent. Still, one or more of the changes will be found not infrequently if opportunity is afforded for careful observation of the patient both before and during pregnancy.

The Breasts.—*Enlargement.*—The breast enlargement of pregnancy presents a firm, irregular feeling on palpation, and not the smooth, soft swelling due to increase of fatty tissue. The hard, knotty sensation is due to the increase in the size and number of the lobules of the mammary gland. In the early months this change is to be distinguished most clearly at the outer edges of the gland.

The veins of the entire breast are enlarged, forming a blue tracery under the skin, most marked in the neighborhood of or in the areola. They show better in persons with white, thin skins.

The Areola.—The circular area upon which the nipple stands in the non-pregnant woman, of a pinkish or somewhat pigmented color according to the type of the individual, darker in brunettes and lighter in blondes, under the influence of gestation becomes darker in color. Even in the light blonde the customary pink color is deepened; in the brunette the areola becomes the color of the skin of a quadron. In fair women the areola may be elevated above the surrounding skin; this feature is brought into prominence by stretching the skin of the rest of the breast. When stimulated by a touch of the finger tip the surface of the areola will wrinkle up or pucker. The wrinkling brings into prominence the enlarged sebaceous follicles, some twelve to twenty in number, which project about a sixteenth of an inch above the surface of the areola.

The value of the mammary signs is greater in first pregnancies because many of the characteristics, such as enlargement and the appearances of the areola, persist after the termination of the first pregnancy. One must rule out previously existing uterine or ovarian disorders, or masturbation, because in these conditions the breast appearances are often the same as in pregnancy. The mammary signs are among the earliest of the indications of pregnancy and are especially valuable as indicative of the probable condition in the case of the unmarried where it is necessary for the physician to proceed with caution. A physical examination of the chest gives opportunity to inspect the breasts, and their showing sometimes warrants further investigation.

Inspection of the Vulva and Vagina.—On separating the labia the

vagina will be found to be abnormally moist and covered with whitish shreds of desquamated epithelium, and the anterior vaginal wall just under the urethra shows a dusky, purplish discoloration sometimes called Jacquemin's sign because first noted by this author in 1837. The discoloration is to be seen first in the bottoms of the furrows of the mucous membrane, therefore it is well to put the anterior vaginal wall on the stretch. This sign may be apparent as early as the end of the first month and is present in over half of

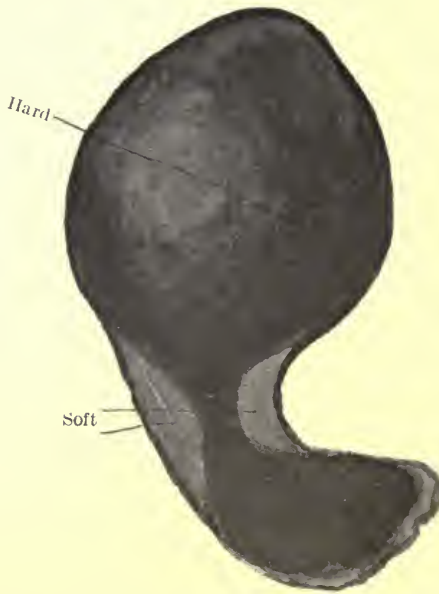

FIG. 177.—Diagrammatic Side View of the Pregnant Uterus of the Sixth Week, during Relaxation. (After Dickinson.)

all cases by the end of the third month. It is more distinct in multiparæ and is more apt to be absent in primiparæ.

Speculum examination of the upper vagina shows the cervix to be of a purplish color, soft to the feel, and in primiparæ the os tinæ becomes rounder. Erosions are of a deeper purple color than the surrounding tissues. Many observers consider the discoloration of the cervix an earlier and more constant sign than Jacquemin's sign. As congestion of vagina and cervix may be found in pelvic disease, such as large ovarian and uterine tumors obstructing the venous circulation, and in certain constitutional diseases, as heart

disease and cirrhosis, the physician must be on his guard. The typical discoloration of pregnancy is, however, limited to the lower anterior vaginal wall, about the lower urethra, and to the cervix; whereas in pelvic disease and constitutional disorders the congestion is general.

The Bimanual Touch.—This is practised with the patient in the customary dorsal position (see page 33). The finger notes a soft cervix. It is to be remembered that softening of the cervix is



FIG. 177a.—The same, during Contraction.

found also in septic conditions of the uterus, as in septic endometritis, so that a soft cervix is not pathognomonic of pregnancy. The uterus itself is a little lower in the pelvis than normal, and is enlarged by the growing ovum, which is usually attached to the endometrium in the neighborhood of the orifices of the tubes. The uterus grows faster than the ovum at first, and the ovum with its envelopes does not fill the uterine cavity until the end of the third month, when the decidua reflexa joins the decidua vera.

The first change in shape noted in the gravid uterus consists in a slight enlargement of its transverse diameter; then it becomes lengthened and fatter as the ovum increases in size, especially in

the anterior part of the body of the uterus; this anterior bulging being quite characteristic in many cases. Asymmetry is caused by the development of the ovum in one cornu, a not uncommon happening. Uterine enlargement may be detected by the practised hand as early as the sixth week; in the third month there can be no doubt about it, even to the tyro. The softening of the uterus varies in different individuals and at different times in the same individual. It is less in primiparæ than in multiparæ, but under

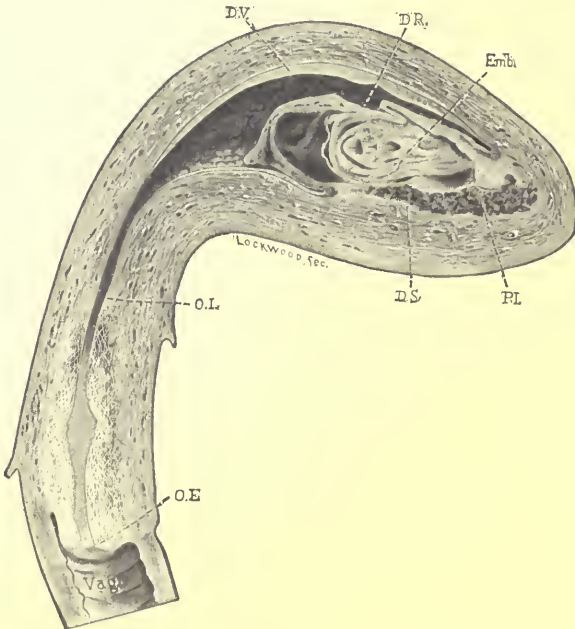


FIG. 178.—Six-weeks' Pregnant Uterus with Elongation of Cervix, Showing Extent to which its Cavity Is Occupied by the Ovum. *O.E.*, external os; *O.L.*, internal os; *D.V.*, decidua vera; *D.S.*, decidua serotina; *D.R.*, decidua reflexa; *Emb.*, embryo; *P.*, placenta. (Williams.)

the influence of pregnancy there is always an increase in elasticity of the organ. Even as early as the first weeks the rhythmical contractions which go on throughout pregnancy may be felt by patient bimanual palpation. They involve the entire uterus and are excited by any manipulation of the organ, therefore the bimanual examination should last from five to ten minutes so that sufficient time may be afforded for contractions to take place. Ellice McDonald (*Amer. Jour. Obstet.*, LVII., 1908) observed intermittent

contractions in 88 out of 100 cases of early pregnancy examined with reference to diagnosis. The lower uterine segment is the portion of the uterus where the softening is most manifest. The softening at this point is called Hegar's sign and can be determined only during uterine relaxation. The upper portion of the uterus, being occupied by the ovum, is tense and elastic; below the ovum the soft uterine tissues may be compressed between the finger in

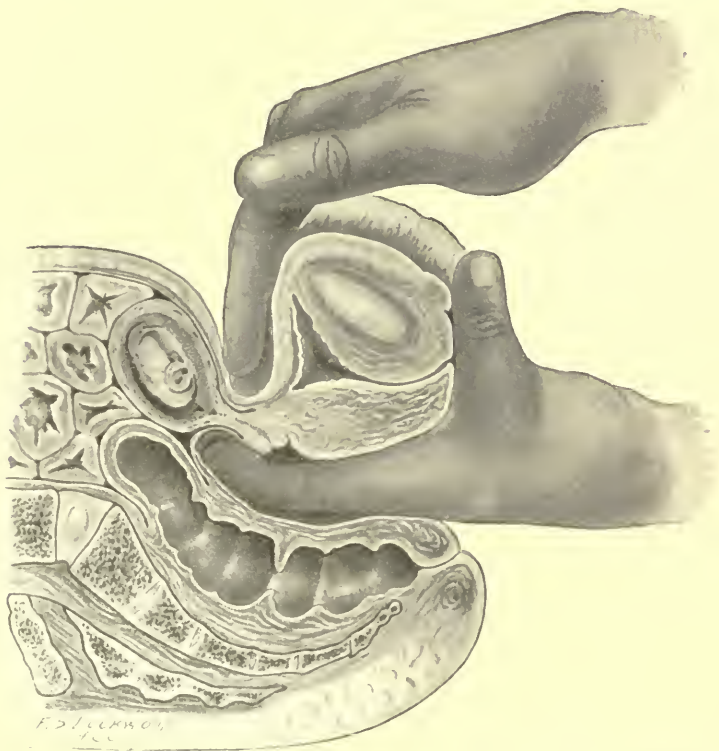

FIG. 179.—Bimanual Palpation of Early Pregnancy for Hegar's Sign. (Williams.)

the vagina and the fingers of the abdominal hand brought down either in front of the uterus or behind it, generally the latter. (See Fig. 179.)

Very early in pregnancy palpation with the abdominal hand in front of the body of the uterus and the vaginal finger behind the cervix is sometimes available, especially in cases of retroversion; later in pregnancy, when the uterus has become longer and more

anteflexed, the fingers of the abdominal hand are brought down behind the fundus, while the finger in the vagina is placed in front of the cervix. The softening of the tissues of the lower uterine segment makes this portion of the uterus more flexible than in the unimpregnated state. Downward pressure by the abdominal hand on the top of the fundus during a period of relaxation, while the vaginal finger under the crown of the cervix makes upward pressure, causes the uterus to bend in the weakest part, the softened area. McDonald found this increased flexibility in ninety-seven out of his one hundred cases.

DURING THE LAST SIX MONTHS OF PREGNANCY

History

The history is the same, except that nausea and vomiting and digestive disturbances cease after the third month, and the bladder symptoms are apt to be less. Abdominal enlargement is noticeable now, and the patient has to let out her dresses. *Quickening*, or the sensation caused by the fetal movements, is felt from the sixteenth to the eighteenth week of gestation, some women detecting it earlier than others.

Inspection and Palpation

The Gait.—In the later months the pregnant woman walks with a backward pose, the abdomen, more or less enlarged, being prominent in front. Ask her to walk up and down the office and note her gait. Also, the sacro-iliac and pubic joints of the pelvis are relaxed during later pregnancy; in women with sacro-iliac disease the motion is excessive, and the gait is decidedly wobbly; in other women the gait may be little if any affected.

The Figure.—The prominent breasts and protuberant abdomen will be noticeable if the physician has been acquainted with his patient previous to pregnancy.

The Breasts.—Besides the changes in the breasts noted as to be found during the first three months, there appears at the fifth month a *secondary areola* outside the primary areola which is next to the nipple, consisting of a network of pigment around light spots, each spot representing a circle round the opening of a sebaceous follicle. These light spots may extend all over the breasts, but are

most marked next to the primary areola. Skillful stroking of the breast toward the nipple will force *colostrum* from the nipple after the third month. This is a valuable sign of pregnancy, although milk has been found in the breasts of virgins and even in young children of precocious development.

The Vulva.—The vulva, vagina, and cervix have the same appearance as during the first three months, except that the engorgement of the tissues is now more marked. The vaginal discharge is increased in amount.

The bimanual touch detects the fetus by *internal ballotement* after the fourth month, for by this time the quantity of liquor

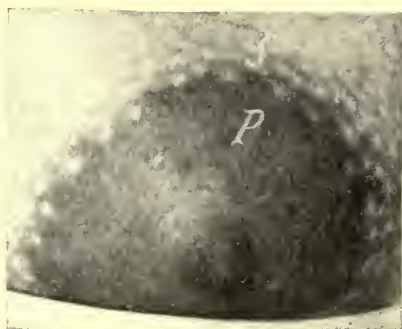

FIG. 180.—Primary and Secondary Areolæ in a Brunette. (“American Text-Book of Obstetrics.”)

amni is sufficient, and the fetus is large enough to permit the examiner to feel its bobbing about in the uterus. Ballotement may be practiced with the patient in the dorsal or in the standing position, preferably the latter. The physician introduces one or two fingers into the vagina and makes a quick, sharp, upward push against the uterus. In a moment the fetus, which is heavier than the fluid in which it is suspended, settles against the examining finger with a distinct tap. This sign is available during the fifth and sixth months. After that the fetus has grown so large that it can not be moved about freely. After the seventh month the cervix is very soft and the os is patulous.

The Abdomen.—Pigmentation of the linea alba of the abdomen is noticeable, especially in brunettes, after the third month. It consists of a dark line about half an inch wide extending from the

symphysis pubis around the navel to the tip of the ensiform cartilage. In the later months of pregnancy streaks of white or pink appear in the skin of the flanks, the breasts, and the lower abdomen, the so-called *lineæ albicantes*.

The protrusion of the abdomen in pregnancy after the fifth or sixth month is generally asymmetrical, being more marked on the right. The umbilicus is apt to protrude in the last two months.

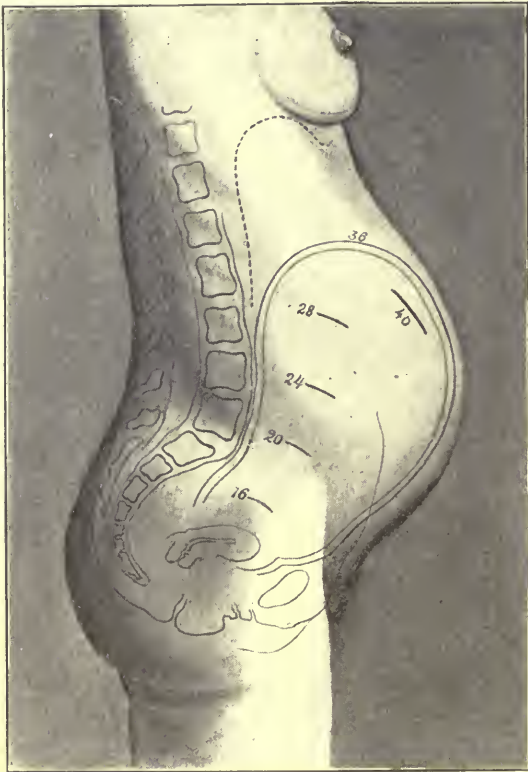


FIG. 181.—Enlargement of the Uterus at the Different Weeks of Pregnancy. (“American Text-Book of Obstetrics.”)

The fundus uteri is two or three fingers’ breadth above the symphysis at the end of the fourth month and reaches the umbilicus at the close of the sixth month.

The parts of the fetus may be felt in favorable cases by the twentieth week (the fifth month), being a most valuable sign of pregnancy. Excess of liquor amnii, a rigid and thick abdominal

wall, or tense uterine walls prevent the detection of the fetal parts. Fetal movements can be felt by the end of the sixth month with a fair degree of constancy and often much earlier. Placing the hand quietly on the abdomen it is allowed to rest there for several minutes. A very gentle throb is felt if in the sixth month, later the movements are stronger. During the sixth month *external ballotement* may be practised, a hand on each side of the abdomen being able to push the fetus to and fro; also intermittent uterine contractions, rhythmic and painless, occurring every five to ten minutes and lasting a minute or two, may be distinguished by placing the hand on the abdomen and waiting. A sudden motion with the hand or a cold hand will often cause a contraction. These contractions can be made out through the abdomen after the fourth month, but are to be felt by bimanual touch from the beginning of pregnancy. A uterus distended by retained menstrual blood or by an intra-uterine tumor has these same rhythmical contractions.

Auscultation

The fetal heart sounds are proof positive of pregnancy. Occasionally they may be heard toward the end of the fourth month, but as a rule are not available as a means of diagnosis before the end of the fifth month. The entire anterior surface of the uterus must be explored with the stethoscope because of the variable position of the fetus, but the most usual situation is between the umbilicus and the left anterior superior spine of the ilium, because the back of the child is situated there in the commonest position, left occipito-anterior. The heart beat has been likened to the ticking of a watch under a pillow; it is double and has a rate of 120 to 150 beats a minute, being increased by the activity of the child, by fever of the mother, and at the beginning of a uterine contraction, variations of twenty beats a minute being often observed in the same fetus. A *uterine souffle*, synchronous with the mother's pulse and heard best along the left side of the uterus, becomes audible during the fourth month and is a sign of an enlarged uterus, but not necessarily of pregnancy because it is heard also in large fibroids.

A summary of the symptoms and signs of pregnancy by months, modified from Dickinson, is appended.

SUMMARY OF SYMPTOMS AND SIGNS OF PREGNANCY BY MONTHS.

Calendar Months.	HISTORY.	BREASTS.	ABDOMEN.	PELVIS.	MISCELLANEOUS
1.	Amenorrhea throughout all months.
2.	Nausea. Swelling and tingling of breasts. Frequency of micturition.	Enlarged. Veins show. Areola pigmented. Follicles.	Leucorrhœa. Purplish discoloration vagina. Bulging anterior fundus. Compressibility of lower segment. Soft cervix.
3.	Ditto.....	Ditto.....	Ditto.....	Swelling of face and neck.
4.	Nausea ceases.	Colostrum...	Beginning enlargement. Pigmentation of linea alba.	Cervix softer. Fetal parts felt. More congestion of vagina.	Skin discolorations.
5.	Quickening ..	Secondary areola.	Fetal heart sounds heard. Fetal parts felt. Uterine contractions felt. Uterine souffle.	Internal ballotement.
6.	Ditto.....	Ditto.....	Fetal movements. Ext. ballotement. Lineæ albicantes. Fundus reaches umbilicus.	Ditto..... Cervix higher in the pelvis.	Gait unsteady. Backward pose. Prominent breasts and abdomen.
7.	Ditto.....	Ditto.....	Ditto.....	No ballotement.	Ditto.....
8. 9.	Abdomen progressively larger.	Cervix very soft and os patulous.

DIFFERENTIAL DIAGNOSIS OF NORMAL PREGNANCY

It has been my experience that in early pregnancy a malformation of the uterus or a tumor of the uterus is most often mistaken for pregnancy, whereas in the later months an ovarian tumor is frequently confused with the pregnant uterus. It may be well to mention some of the most common mistakes in diagnosis, although there are so many that the advice as to the later months to regard all enlargements of the abdomen as due to pregnancy until the contrary has been proven, is certainly safe to follow.

During the First Three Months

Anteflexion with retroposition may closely simulate early pregnancy, especially if there is congestion of the cervix and an endometrial discharge. In anteflexion the cervix is not soft, there is no purplish discoloration of the anterior vagina, the corpus uteri is not elastic, the lower uterine segment is not compressible, there are no rhythmical contractions, and menstruation still persists, though irregular. An examination several weeks later shows the signs to be the same as at the last examination, and, additionally, markedly anteflexed uteri are generally sterile.

Chronic subinvolution shows an enlarged uterus, but the tissues are firmer than normal, the body is not globular in shape or bulging anteriorly, and the lower uterine segment is not compressible. Purplish discoloration is absent. Menstruation, though scanty, is present.

Fibroid of the anterior wall is of hard consistency; menstruation is present, purplish discoloration is absent, rhythmical contractions may be present. Upon a second examination after an interval of two weeks or more, the sound may be passed and the situation and size of the fibroid determined.

Retroflexion.—The congested fundus may simulate a gravid uterus. The uterus should be replaced as described in Chapter XIV., page 237, and another examination made in the course of a few days.

Extra-uterine pregnancy is considered in Chapter XIX., page 340.

It is always wise not to hurry in making a diagnosis in doubtful cases and ask for another examination, if necessary with an anes-

thetic. Nothing is to be lost and often much gained by adopting such a course.

During the Last Six Months

In the case of enlargements of the abdomen due to other causes than pregnancy the rate of enlargement does not coincide with that of the gravid uterus; if amenorrhœa is present the duration of the absence of the menses does not correspond with the size of the tumor, supposing it to be pregnancy; and the distinctive signs of pregnancy are absent, namely, the fetal heart sounds, fetal parts felt, fetal movements felt, and internal and external ballottement. Menstruation usually persists. The differential diagnosis of ovarian cysts, fibroid tumors, phantom tumors, and fat in the abdominal wall, distended bladder, ascites, tympanites, and the very rare hematometra, will be found in the chapter devoted to those subjects as shown in the index and need not be repeated here. In cases of rigid abdominal walls more than one examination and, in very doubtful cases, an anesthetic is indicated.

THE DIAGNOSIS OF ABNORMAL UTERINE PREGNANCY

The Diagnosis of Retroflexion and Incarceration of the Pregnant Uterus.—This not uncommon condition is characterized by a tumor of elastic consistency filling the pelvis, the cervix being high up behind the arch of the pubes. The symptoms and signs of pregnancy are present and in addition there are apt to be pelvic pains and retention of urine. Before attempting to replace the uterus a careful investigation of the urinary function should be made and queries asked whether there has been stoppage of urine or whether any bits of tissue have been passed with the urine, or the patient has suffered with symptoms of cystitis. Krukenberg, who with Rivington collected twenty cases of rupture of the bladder occurring in cases of incarcerated retroflexed pregnant uteri, advises against replacement of the uterus whenever there have been passed by the urethra portions of necrotic bladder wall because of the danger of rupturing the bladder during replacement. He prefers to practice abortion. In any event the bladder should be thoroughly emptied by catheter before attempts at

replacement are carried out. These are done by placing the patient in the knee-chest position, making traction on the cervix with a tenaculum and at the same time rocking the fundus upward by the promontory of the sacrum by pressure on the uterus through the abdomen. Often the Sims position is more favorable for this procedure, and sometimes it will be necessary to pack the vagina with cotton tampons and make a second attempt after an interval of forty-eight hours. In my experience the administration of an anesthetic is seldom necessary.

The Diagnosis of Interstitial Pregnancy and of Pregnancy in a Rudimentary Horn of a Bicornute Uterus.—In Chapter XIII., page 198, are described the different sorts of anomalies of the uterus. E. Kehrer ("Das Nebenhorn des doppelten Uterus," 1899) collected eighty-two cases of pregnancy in rudimentary cornua. The diagnosis before operation in a majority of these cases lay between extra-uterine pregnancy, ovarian cyst and subserous myoma. The diagnosis of this condition *intra vitam* must always be considered extremely difficult. Kehrer cites five physicians who diagnosed the condition correctly and reports the cases in detail. The chief point of difference between tubal pregnancy and pregnancy in the rudimentary horn of a uterus bicornis is that in the latter there is a thick pedicle or even no pedicle at all between the uterus and the gravid tumor, whereas in extra-uterine pregnancy there is a long slim pedicle, longer in ampullar and isthmal tubal pregnancy and shorter in interstitial tubal pregnancy.

Interstitial pregnancy often simulates pregnancy in a rudimentary horn. The ovum developing in the uterine portion of the tube causes asymmetry of the uterus. Only when the conditions for examination are most favorable can the separation between the pregnant horn and the main fundus uteri be felt. The sound may be passed into the main uterine cavity to prove that it is empty. I have seen two cases of interstitial pregnancy that became normal uterine pregnancies in the course of the third month as the fetus and its envelopes grew into the uterine cavity from the tube. As a rule the interstitial pregnant tumor is separated from the uterus by a shorter pedicle than the pregnant rudimentary horn of a double uterus.

The Diagnosis That Pregnancy Has Occurred Previously.—In medical cases the physician may be called upon to give an opinion

whether or no a woman has ever borne a child. The answer will depend upon the physical examination alone. Following pregnancy the breasts are flabby and more or less pendulous, the changes in the nipples and areolæ previously described are to be sought, also lineæ albicantes on the breasts or about the lower abdomen or hips. A scar from a mammary abscess is good evidence of previous lactation unless other satisfactory explanation of its presence is forthcoming.

By vaginal examination the hymen will be found destroyed and in its place the caruncule myrtiformes, the vagina will show a certain amount of relaxation and absence of the rugæ; lacerations of the perineum or pelvic floor are proof of previous pregnancy. The uterus will be found a little enlarged and the os will be found round, not the os tincæ of virginity. A tear in the cervix is proof positive of child-bearing unless there is a history of instrumentation. Erosions with endocervicitis must not be mistaken for lacerations and their effects.

The Diagnosis of Multiple Pregnancy.—The diagnosis of multiple pregnancy rests on finding an unusually large uterus, a groove in the fundus separating the fetuses, hearing two fetal hearts, each with a different rhythm, and on the palpation of two heads or two breeches.

The Diagnosis of Pernicious Vomiting of Pregnancy.—Excessive vomiting of pregnancy or *hyperemesis gravidarum*, occurring most frequently between the third and the fifth week of pregnancy, is of three varieties, according to J. Whitridge Williams, reflex, neurotic, and toxemic. In the *reflex* variety, the vomiting is apparently directly attributable to the existence of some abnormality of the generative tract such as retroflexion or antelexion of the uterus, erosions or cicatrices of the cervix, or an ovarian tumor, and it ceases promptly upon the correction or removal of the abnormality. The fact, however, that in many pregnant women the presence of similar lesions is not associated with serious vomiting would apparently indicate that its reflex origin is quite exceptional, and is evidence that some other etiological factor is usually concerned in the production of the vomiting. The failure of suggestive treatment and the lack of evidence of serious changes in metabolism make it improbable that the affection is neurotic or toxemic in origin.

In the *neurotic* variety the vomiting is dependent upon the existence of a neurosis—more or less clearly allied to hysteria—which may occur in women who had manifested no signs of impaired nervous control previous to the occurrence of pregnancy. In such cases careful examination will fail to reveal the existence of a single physical condition which could account for the vomiting, while the most accurate chemical analysis of the urine will afford no evidence of serious metabolic disturbance; and, finally, characteristic lesions will not be found at autopsy in the rare cases which end fatally, as such patients die from starvation.

Cure frequently follows the employment of apparently useless measures and unphysiological procedures, such as a vigorous lecture on the part of the physician, dilating the cervix, applying leeches to the epigastrium, or the administration of an anesthetic. A rigorous rest cure or suggestive treatment also may bring relief.

Toxemic vomiting, on the other hand, is a very serious disease and is a manifestation of a profound disturbance in metabolism, of the exact origin of which we are ignorant. All that we know at present is that it usually ends in death, and sometimes leads to a fatal termination within a few days after the appearance of serious symptoms. In such cases the patient presents signs of a profound intoxication, and may die in coma without any evidence of starvation.

The urine, while diminished in amount as the result of the scanty intake of fluids, does not contain albumin or casts until shortly before death, and may apparently present a normal amount of urea, as determined by the Doremus method, so that its casual examination gives no clew to the gravity of the condition.

In reality, however, there is a decided decrease in the amount of nitrogen excreted as urea and a marked increase in the amount put out as ammonia. Accordingly, while the total nitrogen output may be practically normal, the percentage of nitrogen eliminated as ammonia is greatly increased, and this so-called "ammonia coefficient," instead of being 4 or 5 per cent as in normal pregnancy, may rise to 20, 30, or 40 per cent. Moreover, the proportion of amido-acids is increased, and sometimes the acetone content is abnormally large.

In making a differential diagnosis between the three varieties it is essential to eliminate the toxemic form by a careful urinary

analysis. If the ammonia coefficient exceeds 10 per cent the diagnosis of toxemic vomiting should be made. If the ammonia coefficient is approximately normal the probability of a serious toxemic condition can be eliminated and the diagnosis will be between the reflex and the neurotic varieties. Some manifest lesion in the generative tract makes the diagnosis reflex vomiting.

The suggestion has been put forward by F. P. Underhill and R. F. Rand (*Archiv. of Internal Medicine*, Jan. 15, 1910, Vol. 5, p. 61), that the changes observed in the urine in pernicious vomiting of pregnancy are induced by the inanition which accompanies the severe grades of the disease and that the urine shows nothing characteristic until a stage of great prostration has been reached. They think that the supply of carbohydrates to the system is the factor which determines the relative output of urea and ammonia and claim good results in the treatment of pernicious vomiting by the administration by enema of dextrose in solution.

THE DIAGNOSIS OF ABORTION

Definitions.—*An abortion* is the expulsion from the uterus of the products of conception before the placenta is formed, that is, during the first three months; *a miscarriage* is the emptying of the uterus of the fetus, the placenta and its membranes, from the beginning of the fourth month until the child is viable, at the end of six and three-fourths months; and *a premature labor* is the delivery of the child after it is viable, or between six and three-fourths months and term.

The word abortion is so frequently used to mean the expulsion of the products of conception at any time from the beginning of pregnancy up to the time of viability that it is convenient to so use it in this chapter.

A complete abortion is one in which the fetus and its membranes are cast off entire; *an incomplete abortion* is one in which the fetus is born, but the membranes and the placenta, if formed, remain behind; *a concealed or missed abortion* is one in which the embryo has perished but is not expelled; *spontaneous abortions* are those which occur without known cause; *induced abortions* are those which are caused artificially and intentionally, whether by the

administration of drugs or by the use of instruments, and *habitual abortions* are abortions repeated in successive pregnancies.

Frequency.—Obviously exact figures as to the frequency of abortions are difficult to obtain. Without doubt many occur during the first six weeks of pregnancy without attracting much attention, and many patients who have abortions are not under a physician's care. J. Clifton Edgar found 635 cases of interruption of pregnancy—abortion, miscarriage, or premature delivery—among 10,000 cases of labor treated in a dispensary service in New York City, or one in every 15.7. Some authors give the frequency of abortions as once in every five or six cases of labor.

Abortion proper is more apt to occur in multiparæ, while miscarriages and premature labors are found more commonly in primiparæ. This seems to be due to the frequency of uterine disease in multiparæ, so that with an increasing number of pregnancies the uterus becomes progressively less tolerant and expels its contents earlier with each successive pregnancy.

Etiology.—The causes of abortion may be grouped in three classes in the order of their frequency: (1) maternal, (2) fetal, and (3) paternal.

1. *The maternal causes* are (a) constitutional and (b) local. *a. Constitutional.* Under this heading are to be classed the infectious diseases, as typhoid fever, pneumonia, smallpox, scarlatina, cholera, especially if accompanied by high fever suddenly developed, and tuberculosis and syphilis. Syphilis in the mother is a very frequent cause of abortion, some authors going so far as to claim that it causes a quarter of all abortions.

Other causes of abortion are cardiac diseases, the toxemia of chronic nephritis, diabetes mellitus, lead or arsenic poisoning, anemia from sudden loss of blood, the use of oxytoxic drugs, as ergot, cotton-root bark, quinine, aloes, and tansy. *b. Local causes* are all those conditions that cause pelvic congestion, such as malpositions of the uterus, especially retrodisplacements, chronic endometritis, lacerations of the cervix, and excessive sexual intercourse.

2. *The causes in the ovum and embryo* are, anything that interferes with the nutrition or produces the death of the fetus. Many of them are secondary to pathological conditions in the mother's tissues. They are syphilis of the decidua or placenta, and low

situations of the placenta, also, less frequently, anomalies of the decidua and the other fetal envelopes or of the fetus itself, producing injury or death. Introducing foreign bodies into the uterus, such as catheters or hatpins, must be reckoned as local causes. When the fetus is dead it acts like a foreign body and the uterus expels it. In exceptional instances the fetus may be retained in the uterus as long as two weeks after its death.

3. *The causes due to the father* are chiefly syphilis transmitted by the spermatozoa. Sometimes there are syphilitic changes in the placenta and fetus where the mother shows no sign of the disease. Other causes are debility in the father, perhaps due to tuberculosis, perhaps to excessive indulgence in sexual intercourse. A French author has cited the instance of thirty cows who were served by the same bull within a short period of time. The fifteen that were served first went to full term, while the last fifteen aborted without an exception.

Symptoms.—In abortion during the first six weeks there are seldom any prodromal symptoms. The woman may think she has a delayed and profuse menstruation, and may not realize that she is pregnant. Much blood is lost and clots are passed, and there may be pains in the region of the uterus. If she thinks she is pregnant and observes the clots she will think that she has seen the fetus in the "fleshy mass" that she has passed. The ovum, as a matter of fact, is generally passed first of all and is lost with the blood and clots. In the case of a complete abortion all of the embryo and its envelopes are passed at once and there is very little hemorrhage, the process lasting from twenty-four to forty-eight hours from the first hemorrhage or pain until all symptoms cease. Abortions are more apt to be incomplete, portions of decidua being left behind, and, in this event, hemorrhage continues.

In abortion from the sixth to the twelfth week there are apt to be prodromal symptoms of fullness and weight in the pelvis and backache, indicating pelvic congestion. At this time uterine pains and hemorrhage are more severe and constitutional symptoms such as nausea, pallor, rigors, nervousness, and apprehension are often marked. After the third month the symptoms of abortion are more like those of labor at term. The three stages of labor can be distinguished, the uterine contractions are more marked, and there are strong involuntary bearing-down efforts.

Diagnosis.—The diagnosis of abortion depends on the determination that the patient is pregnant; on the character of the pain, indicating uterine contractions; on the amount and character of the hemorrhage; on dilatation of the cervix; and on the descent of the products of conception into or through the os uteri. Practically we are called on to distinguish between threatened abortion, inevitable abortion, and an abortion partially or wholly completed.

The Diagnosis of Threatened Abortion.—First we get the history to determine the probability of the existence of pregnancy. If it can be learned that the patient has missed a catamenia twice or even once, if she has been exposed to impregnation, if she has experienced any disorders of digestion, or will tell of swelling of the breasts, or frequency of micturition, we may get valuable clues. Pain, if it indicates uterine contractions, is of a rhythmical character, beginning in the flanks and extending to the pubic region. The distinct character of the pain is more clearly marked in miscarriages than in abortions proper and in the threatened abortion there is little or no pain. Hemorrhage is moderate in amount, bright in color, free from clots, and intermittent. Examination shows breast changes (see section on normal uterine pregnancy, p. 421), purplish discoloration of the vagina and cervix, the cervix soft, the os somewhat dilated. The uterus is enlarged, the fundus is bulging forward, the lower uterine segment is compressible, and uterine contractions are infrequent.

If, after a series of hours, the symptoms abate and the cervical canal does not dilate, the ovum does not descend, and uterine contractions are still of infrequent occurrence, the case may be said to be in the category of a threatened abortion.

The Diagnosis of Inevitable Abortion.—If, on the other hand, the hemorrhage increases in amount, is persistent, and contains clots and fragments of fetal structures, pain is considerable and increasing in severity, and local examination shows that the ovum has moved down in the uterus, as attested by the elimination of the angle of ante flexion between the large anterior fundus and the cervix, while the ovum can be felt by the tip of the examining finger through the dilated os as a soft bag, uterine contractions being frequent, the case is one of inevitable abortion.

An ovum may be differentiated from a blood clot by noting that it increases in size during a uterine contraction, becomes

smooth and tense, and advances, while the blood clot is not tense and does not advance; also, the ovum presents a convex surface and is elastic, while the blood clot is cone-shaped with its apex downward and is not elastic. All clots or tissue passed should be floated out in water and examined with a magnifying glass for decidua, fringe-like chorionic tissue, or bits of placenta, the tissue being examined subsequently under the microscope.

The Diagnosis of Abortion Partially or Wholly Completed.—To determine whether all or a part of the contents of the uterus have been expelled it is necessary to have everything which has been passed from the vulva preserved for careful inspection. To this end the napkins worn by the patient should be saved, and, before emptying the bladder or bowels she should sit on a chamber and strain so that the contents of the vagina may be expelled into the chamber for preservation. The ovum, being small and suspended in the liquor annii, is usually lost when the membranes are ruptured early in the course of an abortion, being passed from the vagina at stool. Parts of the decidua are more often left in the uterus than not. In very early abortions the pieces of tissue can be felt with the tip of the uterine sound palpating the uterine cavity. When there is any foreign substance in the uterus the cervical canal will be found open. In pregnancy exceeding three months' duration the finger can be passed into the uterine cavity and will feel the bits of fetal membranes or portions of placenta still adherent to the walls. The Emmett curette forceps will bring away tissue for examination. If the tissues appear to be in any respect abnormal they should be sent to the pathologist for examination. The finding of an intact ovum settles the question of a complete abortion. The disappearance of the secretion of the breasts is an important sign that an abortion is complete. If the abortion is completed the uterus will be found contracted and the uterine canal closed. In *missed abortion* the dead fetus may be retained in the uterus for some time; there are no pain and no hemorrhage, but the cervix remains soft and the os patulous.

The Diagnosis of Miscarriage.—The diagnosis of miscarriage is generally easier than that of abortion because the signs of pregnancy are definite and pronounced and the same may be said of the symptoms (see the diagnosis of normal uterine pregnancy, page 426).

Differential Diagnosis.—Abortion must be differentiated from

extra-uterine pregnancy and from menorrhagia, metrorrhagia, and dysmenorrhœa. In abortion the hemorrhage is generally greater in amount and the clots are more frequently passed than in early extra-uterine pregnancy after rupture; the pain is much less severe in abortion and is of the uterine contracture variety, that is, beginning as an aching in the flanks and radiating to the hypogastrium, whereas in extra-uterine pregnancy the pain is severe, agonizing, and in the beginning is unilateral. The changes in the uterus are more marked in abortion than in extra-uterine pregnancy, and in the latter some tumor of the adnexa can be determined. It is to be remembered that a uterine decidua is formed in the case of extra-uterine pregnancy and this is apt to be passed early.

Menorrhagia and metrorrhagia are excluded by the history, which excludes pregnancy, and by the absence of the symptoms and signs of pregnancy, also by determining some cause for the increased flowing, such as a fibroid tumor, endometritis, or cancer. Dysmenorrhœa is excluded by the past history of pain occurring at some definite interval of time before, after, or during the flow, and by the absence of the symptoms and signs of pregnancy.

THE DIAGNOSIS OF HYDATIDIFORM MOLE

Hydatidiform mole, also called vesicular or cystic mole, is a disease of the chorion consisting of a cystic formation at the ends of the villi, producing a mass that resembles a bunch of grapes. It is a rare disease occurring once in about three thousand cases of pregnancy and is found oftenest among multiparæ between the ages of twenty-five and forty. It is apt to be repeated in successive pregnancies in the same patient. The mole generally develops before the fourth month and causes the death of the fetus.

Pathology.—The cystic process which involves the chorion is, according to Marchand, an edematous degeneration in which the syncytium plays an important rôle. Large masses of syncytium and chorionic epithelium invade the decidua and the uterine walls just as in chorio-epithelioma, the process resembling this disease which follows hydatidiform mole in about half the cases. The translucent vesicles are similar in shape to the elements

of the chorion of the first two months, being fusiform, pyriform, or rounded, they contain a fluid that is similar to liquor amnii, and of the chorion of the first two months, being fusiform, pyriform, they range in size from a pin's head to a large grape. The mass of vesicles may grow to the size of a man's head, the myxomatous degeneration involving the entire surface of the chorion, or it may

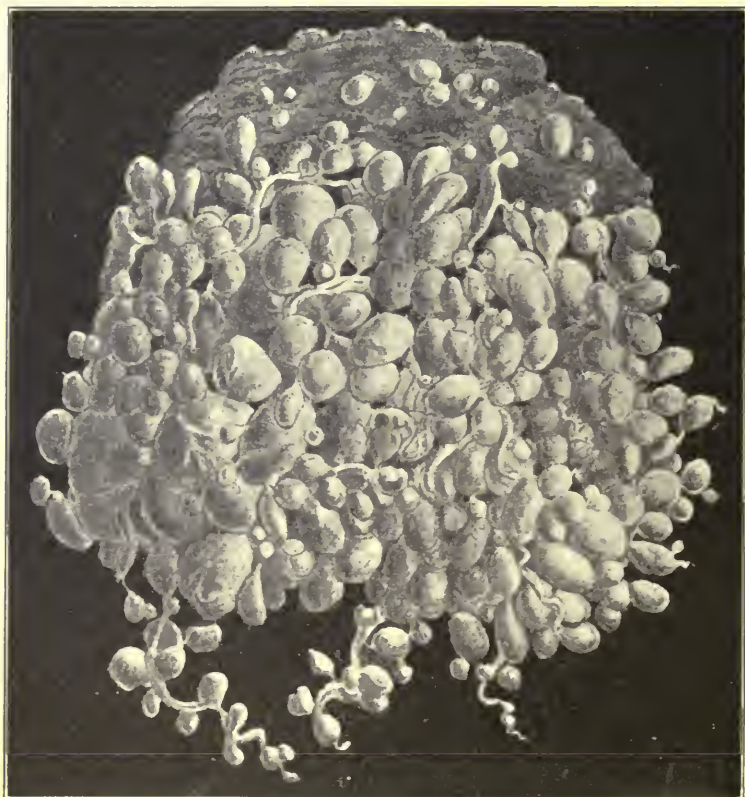

FIG. 182.—Hydatidiform Mole. (Bumm.)

be a small tumor involving only the placental portion of the chorion. The mass is expelled by the uterus as a rule in the fourth or fifth month with labor pains and hemorrhage, but portions of the cystic mass are apt to be closely adherent to the uterine wall so that some is apt to be left behind, necessitating a curetting. The fetus may be destroyed in cases of extensive disease, or it may be pre-

served in cases of minor involvement. It is generally killed early. Sometimes, when the uterine blood-vessels are eroded, the hemorrhage from hydatidiform mole may be excessive.

Symptoms.—In the first few weeks of pregnancy there is no means of distinguishing cystic disease of the chorion. As the pregnancy advances the uterus containing hydatidiform mole increases in size more rapidly than in the case of normal pregnancy, and hemorrhage occurs with a bloody, watery discharge, which is not unlike currant-juice in appearance.

Diagnosis.—The diagnosis rests on the symptoms and on a doughy feeling of the uterus on bimanual palpation, this being demonstrable after the third month when the rapid growth of the uterus becomes apparent. If the cysts are found in the vaginal discharge the diagnosis is certain. No fetal movements or heart sounds are heard and there is no ballottement.

The possibility of the development of chorio-epithelioma following hydatidiform mole should never be lost sight of, and every patient should be kept under close observation for at least a month after the expulsion of the mole.

CHAPTER XXIII

THE DIAGNOSIS OF DISEASES OF THE URETHRA

Anomalies, p. 444: Persistent urogenital sinus, p. 444. Hypospadias, p. 444. Partial defect of the external urethra, p. 444. Epispadias, p. 445. Atresia of the urethra, p. 445.

Displacements of the urethra and alterations in form, p. 445: Upward dislocation, p. 445. Downward dislocation, p. 446: Diagnosis, p. 446; Differential diagnosis, p. 447, Urethrocele, p. 447. Suburethral abscess, p. 447, Dilatation of the urethra, p. 447, Dangers attending dilatation, p. 447, Prolapse of the urethral mucosa, p. 448.

Inflammation of the Urethra, Urethritis, p. 450: Acute urethritis, p. 450. Chronic urethritis; (a) Diffuse; (b) Circumscribed, p. 451: Latent gonorrhoea, p. 452.

Stricture of the urethra, p. 451.

New growths of the urethra, p. 453: Urethral caruncle, p. 453. Polypus of the urethra, p. 455. Primary Cancer of the urethra, p. 455. Sarcoma of the urethra, p. 456.

THE anatomy of the urethra and the methods of examination and the technique of endoscopy will be found in Chapter VIII., page 100.

ANOMALIES

The congenital defects of the urethra are: absence of the urethra, hypospadias, dilated short urethra, epispadias, and atresia. The development of the urethra and bladder is shown in the diagrams from Schroeder in Chapter XXI., page 395. Where the urethra has failed entirely to develop the bladder opens directly into the vagina, and the case may be regarded as a *persistent urogenital sinus*. Several of these cases have been reported in the literature, but more common are the instances of lack of development of the lower portion of the urethra. If the part lacking is the posterior urethral wall the case is one of *hypospadias*, and if both anterior and posterior walls are absent in the lower course of the urethra it is a case of *partial defect of the external urethra*. In cases of absence of the vagina the urethra is commonly found *dilated and short*, in some cases being of large enough caliber to admit

the penis. Many authors have assumed that the large size of the urethra in such patients is due to forcible dilatation during coitus, but as the large urethra is found in unmarried women who are the subjects of absence of the vagina—in patients who could never have been subjected to sexual intercourse—the condition of the urethra must be regarded as due to a partial persistence of the urogenital sinus. Intercourse has undoubtedly taken place through such a urethra in many instances, but we must not regard the dilatation by the penis as the primary cause of the large caliber.

Epispadias is a defect of the upper wall of the urethra associated with separation of the labia minora and division of the clitoris. In extreme cases of epispadias there is also exstrophy of the bladder together with deficiency of the anterior bladder wall. The condition is rare, as is *atresia of the urethra*, which is supposed to be due to inflammatory affections late in intra-uterine life causing more or less complete occlusion of the urethral canal. There must be some avenue of escape for the urine even before birth or else the child has great distention of the abdomen from overfilled bladder, ureters, and kidneys. Partial atresia may be relieved soon after birth by passing a sound, as in the case reported by Mandl and cited by Kelly, in which a child two days old had vomiting and convulsions until the atresia of the urethra was broken down by a sound.

DISPLACEMENTS OF THE URETHRA AND ALTERATIONS IN FORM

UPWARD DISLOCATION OF THE URETHRA

Upward dislocation of the urethra may occur from dragging on the bladder and the urethra in the case of large tumors and in pregnancy. It is supposed that the traction on the neck of the bladder may be the cause of frequency of urination, which sometimes occurs in these cases; more often there are no symptoms at all. Rarely there is retention of urine, and the catheter, when passed, traverses a long route up behind the pubic bone. A soft rubber catheter is safer than a glass or silver one in such cases.

DOWNWARD DISLOCATION OF THE URETHRA

Downward dislocation of the urethra is a fairly common lesion resulting from child-birth. The entire urethra may be torn from its pubic supports, as in the case of procidentia, or only the upper portion may be freed from its fastenings. Not infrequently careful examination will reveal dislocation of the upper third of the urethra in cases where prolapse of the uterus is not present. We must suppose that in these cases the uterus and its ligaments have involuted and regained a normal state, while the sundered tissues under the pubic arch are unable to support the urethra in a normal situation. Downward dislocation of the urethra may be attended by no symptoms, or the patient may experience sudden stoppage of the urine during urination, or there may be partial incontinence. The tone of a dislocated urethra is apt to be below par, therefore such a urethra is more likely to become infected than is a normal one.

Diagnosis.—The diagnosis is established by palpation of the urethra with a sound in its canal and a finger in the vagina, also by inspection of the vagina while the sound passes through the urethra, the patient being in the dorsal position. For this purpose employ a sound that is about three-sixteenths of an inch in diameter or a Kelly urethral dilator of the same caliber (4 millimeters) so that this larger sound may occupy the entire lumen of the urethra, and thus indicate the true course of the organ, and not—as would be the case with a small sound—enter a diverticulum, if present. With this sound passed so that its tip is just below the neck of the bladder, tilt the point downward and note whether the urethra is held to the os pubis or goes downward into the vagina. Next substitute a uterine sound for the dilator, bend the terminal inch of the sound to an angle of thirty degrees, and introduce it with the point downward. If the upper third of the urethra is dislocated downward the point of the sound, following the course of the displaced urethra, may be seen and felt in the vagina.

In my private case records are the notes of fifteen cases of downward dislocation of the urethra not associated with uterine prolapse. In cases of uterine prolapse with accompanying dislocation of bladder and urethra, the course of the urethra in the prolapsed mass is mapped out with the bent sound in the urethra.

Differential Diagnosis.—We must differentiate *urethrocele*, which is a pocket in the lower wall of the urethra—generally in the middle third of its course—from downward dislocation of the urethra. This is done by noting the general course of the urethra by means of a large sound or Kelly dilator passed to the neck of the bladder. Withdraw the sound and pass a bent probe through the opening in the urethral wall into the urethrocele, following the point of the probe with a finger in the vagina. Next pass a cystoscope into the urethra and see the opening into the urethrocele, passing a probe through the cystoscope into the urethrocele to verify the diagnosis. Urine may collect in a urethrocele, decompose, and set up a urethritis. The urine is ejected during the act of coughing, laughing, or straining, and the patient complains of this sort of incontinence.

Dislocation of the urethra downward must be differentiated from *suburethral abscess*, an abscess occupying the urethro-vaginal septum, varying in size from a cherry to a hen's egg. Such an abscess has a chronic course and is supposed to originate in Skene's glands, in a diverticulum from the urethral canal, or in a suppurating cyst of the urethro-vaginal septum. It is the seat of pain and soreness during urination, defecation, and coitus, the latter often being impossible of accomplishment because of the tenderness of the vagina. The abscess generally opens into the urethra by a minute opening, and pressure on it through the vaginal wall causes the sac to collapse as it is emptied. In some cases the patient experiences periodic discharges of pus from the urethra. If the cystoscope is passed up to the vesical neck and withdrawn, a few drops of pus will be seen to gush into its lumen after the tip of the cystoscope has passed the opening into the abscess. A probe passed into the opening and palpated per vaginam establishes the diagnosis.

Dilatation of the Urethra.—Congenital enlargement of the urethra has been referred to in discussing the anomalies as a manifestation of the persistence of a urogenital sinus. Stricture or tumor of the urethra if situated near the meatus may cause dilatation of the urethra behind the stricture or tumor.

All of the structures of the urethra are hypertrophied during pregnancy and Skene thought that the urethra was dilated at that time. Artificial dilatation has been caused by coitus per

urethram and by introducing foreign bodies into the urethra for purposes of masturbation, and, also, dilatation of the urethra was formerly practiced by physicians for the purpose of digital exploration of the bladder for suspected stone or tumors of that organ. The urethra is extremely tolerant of dilatation and bladder stones as large as an inch in diameter have been passed spontaneously through the urethra, followed by only temporary incontinence. Nevertheless, forcible dilatation of the urethra to a diameter of more than half an inch (12 millimeters) is entirely unjustifiable, because permanent incontinence is very apt to be the result. Few physicians possess a forefinger whose knuckle at the end of the first phalanx measures less than three-quarters of an inch (18 millimeters) in diameter and most forefingers are much larger. The interior of the bladder can not be palpated unless this knuckle is passed into the urethra. Examination with the little finger is inadequate, although the lower portions of the bladder may be reached with its tip. Modern methods of cystoscopy do away with the need of digital exploration and we may subscribe to Dr. Thomas Addis Emmet's vigorous statement to his students in the old days at the Woman's Hospital, that the man who dilates a woman's urethra with his finger should be put in jail.

The diagnosis of a dilated urethra is made by observing pouting of the meatus, and a distinct ridge in the vagina corresponding to the course of the urethra. By touch per vaginam the enlarged urethra may be felt as an elastic, rolled-up, membranous tube, and on introducing a large Kelly dilator into the urethra, it slips easily into the bladder. Moving the tip of a uterine sound about in the urethra we determine an enlarged canal, and by palpating the sound per vaginam we learn the thickness of the tissues of the urethro-vaginal septum. The No. 12 cystoscope passes easily, and the larger sizes of the urethral dilators introduced successively will tell of the exact diameter of the urethra.

Prolapse of the Urethral Mucosa.—This rare affection consists of an eversion or turning out of the urethral mucous membrane through the meatus. For some reason the hypertrophied mucosa becomes loosened from its attachments and is extruded from the external orifice in the shape of a deep red or bluish tumor with the orifice of the urethra in its center. The extreme grade of this affection is most often found in debilitated old women and in

young children; a moderate amount of eversion may occur in any woman who has had children. In the pronounced grades the prolapsed mucous membrane may become edematous or even gangrenous. The diagnosis is made by discovering a deep red tumor in the situation of the vestibule, that is covered everywhere with easily bleeding mucous membrane, and has a slit in its center that gives access to the bladder. If only a portion of

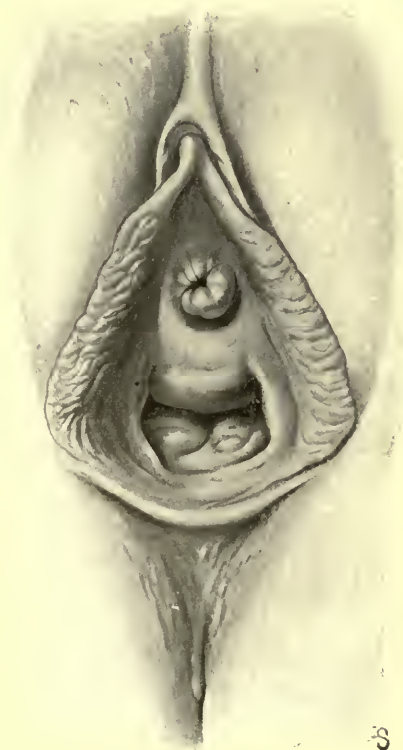

FIG. 183.—Prolapse of the Urethral Mucous Membrane. (Montgomery.)

the circumference of the urethra is involved in the prolapse the everted mucosa may be mistaken for a polypus, a urethral caruncle, or eversion of the bladder mucosa. If the prolapsed mucous membrane is seized with a delicate pair of forceps and drawn down it will be found to have a broad base and will be increased in size; in the case of a polypus or caruncle drawing the tumor down will show a pedicle, and no increase in size beyond the elongation due

to traction. In many cases the everted mucosa may be replaced in the urethra by the use of cocaine and taxis.

If the case is one of eversion of the mucosa of the bladder, the sound passed into the urethra can be made to sweep entirely around the tumor, and when passed further there is no bladder cavity to receive it. By taxis and pressure with a large-sized sound the prolapsed mucous membrane may be pushed into the bladder. Cystoscopy will show the distended bladder and the portion of the lining that had been prolapsed to be of a deep red color.

INFLAMMATION OF THE URETHRA: URETHRITIS

Urethritis is a common affection in women, though not so often diagnosed as in the male; "irritable bladder" and "cystitis," in the place of an exact diagnosis, often meaning urethritis. With the more general use of the endoscope we are learning more of this disease. It is most often due to the gonococcus, but may be due to an extension downward of a cystitis, to traumatism—as from injuries during childbirth or from the passage of a calculus—to urethral new growths, or to an extension upward of a vulvitis. The disease is limited to the mucous and submucous tissues, which are injected, swollen, and secrete pus; the upper and lower portions of the urethra being more often affected than the middle part. Urethritis occurs in two forms, acute urethritis, and chronic urethritis, the inflammatory process having a marked tendency to lurk in Skene's glands. This is true especially of the gonococcus form, which may be cured apparently, only to be lighted up anew into an acute attack when the gonococci have found fresh culture material in another individual.

Acute Urethritis.—Acute urethritis begins with burning and itching in the neighborhood of the urethra, followed in one or two days by painful micturition. The body temperature may be elevated and anorexia and lack of energy may be present for a short time. The patient notices that her linen is discolored by a purulent discharge and even by blood; for there may be bleeding in the most acute stage. The local examination should be made before the patient has urinated. The dorsal position is used. A drop of pus appears in the meatus and the mucosa at the orifice

of the urethra is injected, red, and swollen. Stroking the urethra from above downward by a finger in the vagina, pus issues from the orifice of the urethra. If it does not come from the urethra it may be expressed from the openings of the canals of Skene's glands, which are situated one on each side in the lower portion of the labia urethrae just inside the meatus. The finger in the vagina notes increased body heat and tenderness of the urethra. In this acute stage it is just as well not to use the endoscope because of the damage it must inflict on the inflamed mucosa. If it is used with the aid of a strong solution of cocaine, the mucous membrane is seen to be bright red and bleeding easily and pus issues from between the folds and from the minute glands, or there are to be seen linear ulcers two to four millimeters long and one millimeter broad, generally on the posterior wall. Great care should be exercised not to introduce the endoscope (Kelly Cystoscope No. 8) beyond the bladder neck, for fear of infecting the bladder. Smears should be made and examined for the gonococcus. Concomitant inflammation of one or both of Bartholin's glands indicates probable gonococcus infection.

Chronic Urethritis.—Chronic urethritis is the form of urethral inflammation most often seen by the gynecologist. It commonly follows acute urethritis, although the latter may have given very few symptoms and may not have been diagnosed.

The disease is diffuse or circumscribed.

(a) *Diffuse Chronic Urethritis.*—This generally follows acute urethritis. The longer the inflammatory process has existed the paler becomes the mucosa and the greater the thickening of the mucous and submucous tissues because of new formation of connective tissue. In the later stages of chronic urethritis the urethra is felt as a hard tube, only moderately tender to touch. The symptoms may be nothing more than itching or burning in the region of the urethra and perhaps frequency of micturition. There is some swelling and a gelatinous and granular condition of the mucosa at the external orifice. The mucosa pouts out into the lumen of the endoscope so that the canal appears closed; it is dull red in color, granular and soft, and the lacunæ, crypts, and openings of the glands show as deeper red spots, perhaps giving exit to pus. The disease is most often met with in prostitutes.

(b) *Circumscribed Chronic Urethritis.*—In this form one sees

through the cystoscope patches of pale, almost gray mucous membrane surrounded by the pale red, normal mucosa. Later the pale areas become whiter still as they represent scar tissue, and they sometimes form strictures of the urethra. When the speculum is passed through such cicatricial areas they show decreased elasticity and tear easily, causing bleeding. The chronic inflammation may be limited to the region of Skene's glands. In this case there will be reddening about the orifices of the ducts of the glands and pressure through the vagina will express a drop of pus or turbid serum from the gland. The discharge is apt to be thin and serous in the chronic cases, and gonococci are few. Careful search for this organism should be made. Skene's glands are among the chief lurking places of *latent gonorrhœa*, the other most frequent situations being the cervical canal and Bartholin's glands. If the gonococcus can be isolated from the discharge from either of the latter organs, even though it is absent in the urethral discharge, the inference is that gonococcus infection of the urethra is present also. Several microscopic examinations should be made from the discharges from each of the three situations before pronouncing that gonorrhœa is absent.

STRICTURE OF THE URETHRA

Van de Warker as long ago as 1887 called attention to the frequency and importance of strictures of large caliber in women. My own experience has taught me that such strictures are relatively frequent and are found by the physician who does a good deal of cystoscopic work. In my private records are the notes of nine cases that I have seen, and Pasteau (quoted by Knorr) saw twelve cases and had collected one hundred and twelve from the literature.

Strictures are caused by chronic gonorrhœal urethritis, by injuries of the urethra during labor, by cicatricial contracture of the anterior vaginal wall, due to a slough, or very rarely to cicatrization of a chancre, or carcinoma of the urethra. Stricture at the meatus sometimes results from kraurosis vulvæ.

The symptoms of stricture are: painful and difficult micturition, the urine being passed in a small stream. A small meatus is very commonly met with in women and is diagnosed by passing the

conical calibrator. Any measurement in the adult under 6 millimeters must be classed as small. A stricture is detected by passing the graduated urethral dilators and noting the situation and size of the point of resistance. Through the cystoscope one sees irregular rolling-in of the mucosa and asymmetry, the strictured portion being whiter than the surrounding mucosa, non-elastic, and bleeding if stretched.

NEW GROWTHS OF THE URETHRA

The new growths observed as occurring in the urethra are caruncle, polypi, cancer, and sarcoma.

Urethral Caruncle.—Urethral caruncle is the term used to denote a highly vascular tumor which projects from the urinary meatus. It is a common affection. Lange has described three forms according to their pathology; (*a*) granuloma, (*b*) papillary angioma, and (*c*) telangiectatic non-papillary mucous polyp.

a. The granuloma is characterized by infiltration of round cells and abundant capillaries, and is the result of a gonorrhœal lesion of the urethra. *b.* Papillary angioma is a highly vascular mucous polyp. It has a covering of pavement epithelium with nipple-like elevations, and is invaded by connective-tissue elements. *c.* The telangiectatic variety is characterized by an abundance of thin-walled capillaries, these being so dilated often as to give the tissue a cavernous character; they may even contain cysts. This tumor has no papillæ.

All three varieties are found with equal frequency in middle life, the granuloma is more often found in young women between twenty and forty, and the papilloma variety in women over forty. As a rule, urethral caruncle is observed late in the childbearing period of life, although it may be found at any age from childhood to old age. The symptoms are excessive pain on urination and sensitiveness of the vulva, even to the slightest touch, also frequency of micturition and derangement of the nervous system. Patients may hold their urine for long periods of time to avoid the pain experienced on passing it. Pains, which we may call sympathetic, radiate in all directions from the pelvis, just as in vaginismus. One of my patients complained of a spasmodic drawing up of one

thigh so that when she walked one leg seemed shorter than the other. Physical examination showed no difference in the length of the limbs and no abnormality in the locomotor apparatus. The symptom was entirely done away with by the removal of the caruncle. Coitus is painful or impossible. The patient with a caruncle is apt to be morose, depressed, anxious, or even hysterical. The diagnosis is established by the appearances. On separating

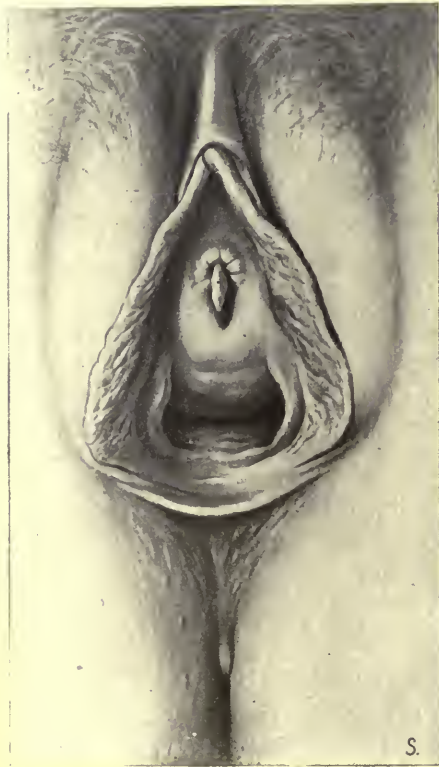


FIG. 184.—Urethral Caruncle. (Montgomery.)

the labia one sees a brilliant red growth projecting from the meatus. It may look like a cock's comb or a very small raspberry and varies in size from a BB shot to a cherry,—large ones being unusual. Its surface is generally smooth, but may be roughened like the surface of a raspberry. The growth generally springs from the posterior wall of the urethra just inside the meatus and is either pedunculated or sessile. With a few exceptions urethral caruncle

is exquisitely sensitive; now and then a non-sensitive tumor is seen. It bleeds easily, but does not, as a rule, bleed enough to soil the patient's linen, but a purulent vaginal discharge is a common accompaniment of these growths, perhaps because they are frequently of gonorrhœal origin. They are of slow growth and almost always recur when removed unless every bit of tumor tissue has been taken out; but the recurrent growth is like the first, and there is no tendency to malignancy or to extension beyond the original site. A thorough diagnosis can not be made often without cocaine or an anesthetic. The meatus must be dilated with the conical calibrator and the exact situation and extent of the base of the tumor determined by the aid of the cystoscope.

Polypus of the Urethra.—Certain forms of caruncle are polypi, as already stated in the consideration of caruncle. Mucous polypi situated in the middle and upper urethra are very rare. They cause few symptoms and are to be seen through the endoscope. A few cases of fibroma of the urethra have been described and one or two cases of myoma.

Primary Cancer of the Urethra.—This is a rare disease, there being on record in 1903 only nine authentic cases. Secondary cancer of the urethra, on the other hand, is not so uncommon. The primary disease is a disease of older women and seems to start in the tissues about the lower urethra more often than in the urethra itself and to invade the mucous membrane late. Strictly speaking, only the form of cancer beginning in the urethral tissues should be classed as cancer of the urethra, but after the mucous membrane has been destroyed the differentiation of the primary point of origin is necessarily difficult. The disease must be differentiated from caruncle, chancre, and tuberculosis. In caruncle the tumor is soft and does not increase in size; it is situated in the urethral canal, generally on the posterior wall. In the case of primary cancer the growth is hard and is seldom seen before it has involved a wide area. The ulcer of a chancre follows a suspicious intercourse with a definite period of incubation, twenty-six days. It heals in a short time, leaving a scar. The ulceration of cancer is of long duration, it extends to the surrounding parts, and the history of infection is absent. Perhaps the *Spirochæta pallida* can be isolated from the discharge. In the case of a tuberculous ulcer the cheesy matter and the tubercles, characteristic of tuberculosis, may be

seen by the naked eye, and there is little or no induration of the base of the ulcer as in the case of both cancer and chancre. In all doubtful cases a piece of tissue should be excised for microscopic examination.

Sarcoma of the Urethra.—This is a very rare disease, only four cases having been reported. Three of the cases were in women fifty years of age or older, and the fourth in a child of three. The symptoms are bleeding and the presence of a tumor in the situation of the urethra. The tumor is to be removed and examined under the microscope.

CHAPTER XXIV

THE DIAGNOSIS OF DISEASES OF THE BLADDER

Anomalies, p. 457: Absence of the bladder, p. 457. Double bladder, p. 458. Loculate bladder, p. 458. Epispadias and exstrophy of the bladder, p. 459.

Alterations in form, and displacements, p. 459: Distended bladder, p. 459. Rupture of the bladder, p. 460. Contraction of the bladder, p. 461. Upward displacement, p. 461. Downward displacement, p. 461. Lateral displacement, p. 462. Hernia of the bladder, p. 462. Eversion of the bladder, p. 462.

Foreign Bodies in the bladder, p. 462: Calculi, p. 462. Other foreign bodies, p. 463.

Cystitis, p. 465: Classification, p. 466: Etiology and pathology, p. 466: Catarrhal cystitis, p. 467; Ulcerative cystitis, p. 468; Exfoliative cystitis, p. 468; Tuberculous cystitis, p. 468. Certain rare forms of cystitis, p. 470. Symptoms of cystitis, p. 471. Diagnosis of cystitis, p. 471.

Varix of the bladder, p. 474.

Fistulæ of the bladder, p. 474: (1) Vesico-vaginal fistula, p. 474; Frequency, etiology and pathology, p. 474; Symptoms, p. 476; Diagnosis, p. 477; Differential Diagnosis, p. 478. (2) Vesico-uterine fistula, p. 479; Vesico-utero-vaginal fistula, p. 479. (3) Vesico-intestinal and other fistulæ, p. 479.

New Growths of the bladder, p. 480: Symptoms, p. 481. Diagnosis, p. 481. Benign tumors, p. 482; Papilloma, p. 482; Fibroma and Myoma, p. 483; Adenoma, p. 483. Malignant tumors, p. 483: Carcinoma, p. 483; Sarcoma, p. 484.

Functional Disturbances of the bladder, p. 485.

THE anatomy and technique of examination of the bladder have been described in Chapter VIII., page 107.

The diagnosis of diseases of the bladder is made by study of the history, by analysis of the urine, and by direct examination of the organ by means of palpation of its exterior and by inspection of its illuminated interior.

ANOMALIES

Absence of the bladder is a very rare malformation and is generally associated with a non-viable child. In these cases the ureters terminate in the urethra, the rectum, or the vagina.

Double bladder is another very rare malformation, which is apt to be associated with duplication of the other pelvic organs, as in a case reported by Suppinger, in which there was a double bladder and also double urethra, clitoris, hymen, and anus, each half of the pelvis containing a uterus unicornis, an ovary, and a tube.

Loculate bladder, or a bladder presenting congenital pockets or diverticula which project outward from the main cavity of the bladder, is not so rare, and the same may be said of a bladder partially divided by a median septum. The congenital loculate bladder is not to be confused with the bladder pocketed by calculi or by inflammatory disease, neither is it to be classed as an instance

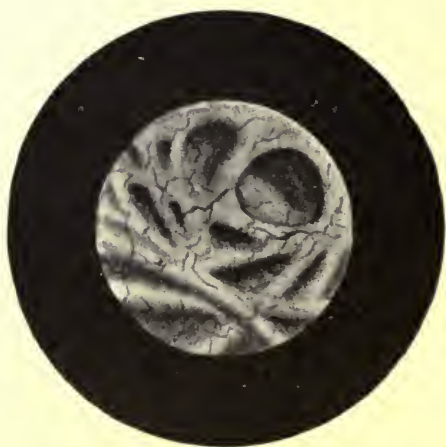

FIG. 185.—The Base of the Bladder showing Diverticula. (Knorr.)

of supernumerary bladders or double bladder, already mentioned. The diagnosis is established by observing the loculi through the cystoscope and noting that they are separated by ridges of mucous membrane, and not by scar tissue, the latter being hard and white, and the former soft and pink.

A. L. Chute (*Boston Medical and Surgical Journal*, March 22, 1906, p. 309) has called attention to a case in which a diverticulum of the bladder existed as the result of a previous suprapubic cystotomy, the pocket acting as a storehouse for organisms that had periodically reinfected the bladder. In the same paper he mentions a congenital diverticulum, diagnosed by the cystoscope, that acted apparently in the same way.

Hypospadias, a condition of persistent urogenital sinus, has been referred to under diseases of the urethra.

Epispadias and exstrophy of the bladder are rarer in the female than in the male and are very seldom met. There is a failure of development in early fetal life both of the anterior wall of the bladder and of the anterior abdominal wall over the bladder, and if the entire front wall of the bladder is wanting, the symphysis pubis is absent also. The posterior wall of the bladder appears as a bleeding, reddened, rounded mass where the symphysis should be, just above the orifice of the vagina, and in its surface the openings of the ureters can be seen spurting urine from time to time. The surface of the everted bladder wall is covered with mucus and urine, and the odor of decomposed urine is strong. The urethra is generally wanting in these cases, the clitoris is fissured, and the vagina and uterus are apt to be undeveloped, although several cases of pregnancy occurring in the subjects of exstrophy of the bladder have been reported. Many of these malformed individuals die in early childhood. Excoriations and ulcerations of the skin surrounding the ectropion are generally present because of the constant escape of urine, and infection of the ureters and kidneys is a common complication. The general health is impaired on account of the local discomfort, the complications, and the inability to perform the ordinary duties of life.

ALTERATIONS IN FORM, AND DISPLACEMENTS

Distended Bladder.—The shape of the distended bladder in the woman is determined by its surroundings. The uterus and broad ligaments behind limit its excursion in that direction, therefore its greatest diameter when moderately distended is not longitudinal, as in the male, but transverse. In extreme distention when the vault rises into the abdomen the long diameter is on a line drawn from the base of the bladder to the umbilicus. A distended bladder of this sort resembles an ovarian tumor rising from the pelvis. (See Fig. 84*a*, page 217.) Percussion of the anterior abdomen for a distance of a hand's breadth, more or less, above the symphysis, elicits a flat note, and fluctuation may be determined by bimanual palpation. The catheter must be passed in

all doubtful cases, and especially is this precaution necessary if there is a history of dribbling of urine. In the case of the overfilled bladder the desire to urinate ceases when the distention becomes extreme and the repeated involuntary loss of small quantities of urine may be the only symptom. If the bladder is very much distended the distress and pain in the lower abdomen which accompany the earlier stages of distention may be absent. Patients, strange as it may seem, are very apt not to realize that the bladder has not been emptied and to give the physician the impression that they have been passing their urine, only, perhaps, too frequently.

Rupture of the bladder may occur either by violence from without, as from blows or falls when the bladder is distended, or from excessive muscular efforts on the part of the patient herself, as in labor, or in the struggles of anesthesia. Rupture is more likely to occur if the bladder wall has been thinned by ulceration and sloughing, as well as by distention. It has been known to occur in extra-uterine pregnancy as well as from all sorts of trauma.

One of the most frequent causes seems to be retroversion of the pregnant uterus. Krukenberg and Rivington collected between them the reports of twenty cases of this sort. Krukenberg thinks that in cases of retroversion and incarceration of the pregnant uterus the physician should proceed with great caution in replacing the uterus, and if portions of gangrenous bladder wall have been passed per urethram, abortion should be performed rather than replacement, because of the danger of rupturing the bladder during the necessary manipulations. Rupture is commonly intra-peritoneal and uncommonly extra-peritoneal. The diagnosis of rupture depends on sudden abdominal pain and collapse. The sound passed into the bladder goes an indefinite distance up into the abdominal cavity through the rent in the bladder, while the catheter shows that the bladder is empty. In the event of extra-peritoneal rupture the symptoms are less severe and urinary extravasation appears in the course of a few hours. In such case the sound can not be passed such a long distance as when the opening is into the peritoneal cavity. Sterile salt solution injected into the bladder causes no swelling of the viscus as determined by bimanual palpation if the rupture is intra-peritoneal. Cystoscopy is out of the

question in these cases because of the grave condition of the patient. The abdomen should be opened at once.

Contraction of the bladder is generally due to cystitis, to inflammatory adhesions about the bladder, or to a habit of frequency of micturition. The symptom is frequency of urination. The diagnosis is established by injecting fluid until the patient has a strong desire to urinate or until the fluid is expelled. Measure the amount in a glass graduate. It may be only an ounce or two. By cystoscopy the bladder will not dilate well when air is admitted and the mucous membrane is wrinkled and corrugated; scar tissue will be seen if the contraction is due to old inflammatory processes in the bladder.

Upward displacement of the bladder not associated with distention is met with in the case of large fibroids of the uterus. The bladder is flattened out on the anterior face of the tumor and its fundus may even reach as high as the umbilicus. The relative infrequency of urinary symptoms in these cases has always been a source of surprise to me. Palpation of the tumor will show, provided the abdominal walls are lax and thin, an elastic swelling on the anterior aspect of the tumor. The passage of the sound into the bladder permits the mapping out of its confines. This procedure should never be omitted by the surgeon in the diagnosis of large fibroids, for the operator should know where the bladder is situated before he opens the abdomen, rather than cut into it by mistake in the course of an operation for the removal of a tumor—a not very rare happening.

Downward displacement of the bladder occurs whenever the anterior segment of the pelvic floor is displaced downward. It is generally associated with uterine prolapse and with rupture of the perineum and pelvic floor. When the base of the bladder projects into the anterior wall of the vagina the condition is known as cystocele. The diagnosis of this condition is to be found in Chapter XX., page 366 (see also Chapter V., *The Mechanics of the Pelvic Floor*) page 221. It is rare for the entire bladder to be in the sac of a complete uterine prolapse, a portion of the organ remaining in the pelvis in almost all cases. When a part of the bladder is prolapsed and a part is behind the pubic bone the organ may assume an hour-glass shape. Exceptionally, in the presence of procidentia, the bladder becomes detached from its connections with the vagina

and remains in its normal situation. The diagnosis of the situation of the bladder is established by means of the sound passed into the bladder. (See Fig. 89, page 227.) In cases where the base has been displaced the ureteral orifices are displaced also, although they always bear the same relation to the internal orifice of the urethra.

Lateral displacement occurs when an inflammatory mass or tumor occupies one half of the pelvis, the bladder being obliged to expand into the opposite half of the pelvis. Here the asymmetry may be determined with a sound, measurements being taken of the depth of the bladder in various directions.

Hernia of the Bladder.—The bladder wall may, very rarely, be pushed into the inguinal and femoral canals and form a part of a hernia.

Eversion of the bladder through a dilated urethra is a rare form of displacement. The entire thickness of the bladder wall is involved and the protruded mass appears as a bright red tumor projecting from the urethral orifice. The mechanism of the production of eversion appears to be as follows: Given, a large urethra, as in the congenital enlargement described on page 444, the patient strains excessively, perhaps because of constipation or diarrhea, and the posterior wall of the bladder is forced into the neck of the bladder and then into the urethra, to present, in the course of time, at the external orifice. In extreme instances the entire bladder has been found turned inside out through the urethra. Eversion is observed most frequently in young children, and in the very old. The diagnosis is made by noting the ureteral orifices in the prolapsed mass, by passing a sound introduced in the urethra round the tumor and finding that it is attached nowhere to the urethral wall, and by observing that the sound will not pass beyond the neck of the bladder. An anesthetic is necessary in order to reduce the eversion. When the bladder wall has been pushed back, the fact that the urethra is dilated will be apparent, and the bladder can be filled with fluid, and also inspected with a cystoscope.

FOREIGN BODIES IN THE BLADDER

Calculi.—The foreign body most frequently found in the bladder is a calculus or stone. This may have reached the bladder from the kidney through the ureter—in which case the stone is said to

be primary—or it may have formed in the bladder about some other foreign body, such as a silk ligature, or the products of inflammation. In the latter event it is a secondary stone. In-crustations of phosphates and urates on the bladder walls following inflammatory processes are the commonest forms of calculi. Small uric acid and oxalic acid calculi may come down from the kidney, stay in the bladder, and attain considerable size by the accretion of layers of deposit of urates and phosphates.

Calculi are most often found in children and in old women.

The female urethra is short and frequently small stones from the kidney are passed without causing severe symptoms. On the

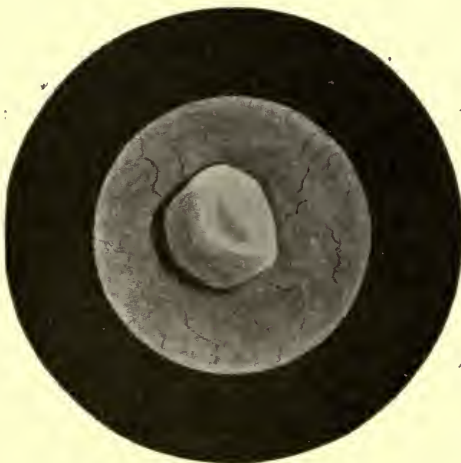

FIG. 186.—Stone in the Bladder. (Knorr.)

other hand, foreign bodies are introduced from without much more easily than in the male, therefore the presence of extraneous foreign bodies and consequently of some form of stone—for foreign bodies are usually encrusted after they have been in the bladder for any length of time—is more common in the female than in the male bladder.

Other Foreign Bodies.—Substances introduced through the urethra are: pieces of catheters which have broken off, pieces of rubber tubing, hairpins, seeds of cherries and other fruits. It is a rare but not impossible occurrence for a nurse to break off a glass catheter in the bladder. Many of the fenestrated glass catheters are weakened by the holes of the fenestrations being too near

together, and on this account the catheter is more apt to be cracked in this situation.

Once, ten years ago, I was performing an abdominal operation for retroversion in a private hospital. This operation had been preceded at the same sitting by a curetting and trachelorrhaphy, and the precaution of passing the catheter at the close of the vaginal operations had been neglected so that when the abdomen was opened the bladder was found to be full. A nurse was asked to pass the catheter. She did so, using a fenestrated glass instrument of the common pattern, and announced that there was no urine in the bladder. On withdrawing the catheter, however, one and a quarter inches of the end were missing. Removing my gloves, I passed another catheter and withdrew eight ounces of urine. I was then able to palpate by my finger in the vagina the broken catheter lying on the base of the bladder. Introducing an Emmet curette forceps through the urethra I succeeded in pushing the broken glass into the forceps by means of my finger in the vagina so that it lay in the long axis of the fenestration of the blades. The catheter end was removed through the urethra without injuring the bladder or urethra in the slightest degree. The broken piece exactly matched its fellow, but the bladder was irrigated to make sure that no spicule of glass was left behind. The operation was finished and the patient made a convalescence free from urinary symptoms. Since this accident I have discarded this form of glass catheter and use only the sort that has a single opening in the end or side.

Foreign bodies may enter the bladder from the vagina, the most common of these being a neglected pessary, which has ulcerated through; or from the abdominal cavity, as a silk ligature which was about the pedicle of an ovarian cyst, then became infected and reached the bladder by means of adhesive inflammation; or the contents of a dermoid or echinococcus cyst which has opened into the bladder. The bones of an extra-uterine fetus have been known to find their way into the bladder.

Foreign bodies which remain in the bladder a considerable length of time invariably set up a cystitis. This process may be limited to a portion of the organ, as in the case where the irritating foreign body, especially in the case of stone, is situated in a loculus. As a rule, the cystitis is general. Large foreign bodies have been

known to ulcerate through the bladder into the vagina or into the peritoneal cavity.

Symptoms.—The symptoms of foreign bodies are those of cystitis: there is frequency of micturition, pain in the region of the bladder, cloudy, perhaps bloody urine. A stone may be carried in the bladder for years without producing any more symptoms than a frequency of micturition. A freely movable stone causes exaggeration of symptoms on moving about, especially on riding and driving; it may be at these times only that the urine is bloody.

Diagnosis.—The diagnosis is made by palpation and inspection. Many foreign bodies may be felt by the finger in the vagina, the obstacles being a foreign body of small size and a thickened bladder wall. The base of the bladder should be palpated always. The sound introduced per urethram hits a stone or encrusted foreign body with a metallic click. Sometimes a stone in a loculus, or one covered with a thick layer of mucus, will not give this click and phosphatic deposits on an ulcerated area give a grating feeling to the sound similar to that of a round calculus. The drumming of the bladder wall on the end of the catheter—so-called “stammering of the bladder,” little taps being given to the catheter,—must not be mistaken for the metallic click. This drumming is a physiological affair and may occur in healthy bladders as far as we know at present. It occurs surely in the course of catheterization of patients who present no bladder symptoms. The exact diagnosis of stone is made by means of the cystoscope, the patient being in the knee-chest cystoscopic position. Unless the foreign body is adherent to the bladder wall it will drop to the most dependent part; in any event it may be seen through the cystoscope.

The electric cystoscope with water-distended bladder is well adapted for the inspection of small calculi and especially for those that are pocketed. (For electric cystoscopy see Chapter VIII., page 117.)

CYSTITIS

Inflammation of the bladder is much more infrequent in women than in men. It is a disease of adult life and is especially common at the times of excessive pelvic congestion, that is, during the menstrual periods, in pregnancy, during congestive pelvic disease,

and at the menopause. True cystitis is rare during childhood, but bacteriuria is not uncommon. (See Chapter XXVIII., page 579.)

Classification.—Cystitis may be classified as acute or chronic, circumscribed or diffuse, or according to the clinical manifestations. Some day a classification based on the bacteriology will be the standard. At present a clinical classification seems to be most available for diagnostic purposes. The symptoms of cystitis will be considered as a whole after the different clinical forms have been described.

Etiology and Pathology.—The immediate cause of cystitis is always a bacterium. Many sorts of bacteria are found in the bladder under conditions of health, just as in the cases of the other orifices of the body that are lined with mucous membrane. With an unimpaired *vis medicatrix naturæ* the microorganisms are short-lived, instance the Klebs-Loeffler bacillus in the nose; given impaired vitality and the germs find lodgment and flourish in the tissues. The following bacteria have been isolated from the bladder, almost always in mixed infections:

bacillus coli communis,	gonococcus,
streptococcus pyogenes,	typhoid bacillus,
staphylococcus pyogenes,	tubercle bacillus,
staphylococcus albus,	bacillus proteus,
staphylococcus aureus,	bacillus lactis aërogenes,
staphylococcus citreus,	bacillus pyocyaneus,
	urobacillus liquefaciens.

In other words, almost any bacterium may, under favorable conditions, enter the bladder and cause a cystitis. What are the avenues of entrance and what are the favorable conditions? The microorganism may reach the bladder (*a*) through the urethra, as in the case of the gonococcus, which, as far as known, always gets into the bladder by this channel, (*b*) through the ureter, as in the case of the tubercle bacillus, which usually descends to the bladder in this way, (*c*) by the blood current,—the typhoid bacillus may come in the blood, and (*d*) by direct extension through the tissues from an adjoining organ, as in the case of the bacillus coli communis entering the bladder through the walls of an adherent and inflamed bowel.

The favorable conditions—the predisposing causes—are: (1) local, or (2) general. 1. Local causes are injuries of the bladder, either direct trauma inflicted on its mucous membrane, or on the musculature of the wall, as instrumentation during difficult labor, rough catheterization with a hard catheter, or from stone or other foreign body in the bladder, or by displacements of the bladder, as from the injuries resulting from childbirth, from tumors, or from overdistention. Pregnancy and the catamenia must be regarded as local causes, for at these times the congestion of the pelvic organs is pronounced, and observation has shown that cystitis is more apt to begin then, and if it has existed previously exacerbations are more common both just before the menstrual periods and during pregnancy and the puerperium. Anything that excites and continues congestion of the pelvic organs must be regarded as a cause of cystitis, and therefore excessive venery or masturbation may have an etiological significance. Inflammation of adjacent organs is a local cause in many gynecological cases, as inflammation of the tubes, a pelvic abscess, or dermoid cyst discharging into the bladder, or uterine cancer.

2. Among the general causes are to be classed certain drugs taken by the mouth, as cantharides and turpentine, which cause congestion of the vesical mucosa and therefore are causes of inflammation, also alcohol taken in excess. Lowered vitality and anemia are caused by the wasting diseases, also by any acute disease. Skene said that he had noted that in measles and scarlet fever the mucous membrane of the bladder suffered like the mucous membranes elsewhere in the body in these diseases.

Chronic heart disease and cirrhosis of the liver produce engorgement of the pelvic organs; old age, by diminishing the tonicity of the bladder walls, favors retention and decomposition of urine; and paralysis, in the same way, may promote retention, overdistention, and decomposition. Major operations, by depressing the strength and powers of resistance of the system, may be reckoned among the causes. "Catching cold" must be regarded as a local congestion of unknown origin, which often is the only cause afforded by the history of the case.

Catarrhal Cystitis.—The mucous membrane of the bladder is of a deeper shade of pink than normal, and there is an increase in the number and the size of the visible blood-vessels. The condition is

an exaggeration of the hyperemia seen during menstruation and pregnancy. No one can say when hyperemia shades into inflammation, therefore very little will be said of hyperemia and local hyperemia of the trigone, for instance, and "trigonitis" will be classed as localized cystitis.

Ulcerative Cystitis.—With ulceration there is a loss of epithelium in the mucous membrane. An excavation can be seen lined by granulation tissue, which bleeds on the slightest touch. There may be pus, granular débris, or urinary salts on the surface of an ulcer, and, in the healing stage, ridges and irregular elevations are visible.

Exfoliative Cystitis.—This is a rare form of cystitis in which the mucosa is shed in part or as a whole, with subsequent regeneration. It is due, apparently, to the cutting off of the blood supply of the bladder caused most often by retroflexion of the pregnant uterus, or by protracted delivery. It is an ischemic necrosis, with or without bacterial infection. The detached mucous membrane is passed per urethram either in small pieces or in one large piece, and is apt to be covered by uric acid crystals and to be so much disorganized that the recognition of it as mucous membrane is not easy. In severe grades, as pointed out by Boldt, the muscular or even the peritoneal coats of the bladder may be involved.

Tuberculous Cystitis.—Tuberculous cystitis is a frequent affection and, in the vast majority of cases, is secondary to tuberculous disease of the kidney, the infection coming to the bladder through the ureter. Rarely it is primary in the bladder, and it may be a part of a general tuberculosis. If the disease is secondary to tuberculosis of the kidney the manifestations in the bladder are most marked in the neighborhood of the ureteral orifice on the side of the affected kidney, because in this situation the infected undiluted urine comes into most intimate contact with the mucosa. Tuberculosis of the kidney is generally unilateral in its earlier stages. The ureteral mons is puffy and swollen, and glistening opaque tubercles and ulcerations are seen in the mucosa surrounding the orifice. The disease is seldom seen before the ulcerative stage, although there is a catarrhal stage which precedes it. In the course of time caseation occurs and the tubercles break down, leaving a deep, ragged-edged ulcer; the urine containing pus, blood, and mucus. The disease may be confined to definite patches in

the bladder; the trigone, base, and posterior walls being most often involved; the ulcerations advance slowly in any event; in very bad cases the entire bladder may be ulcerated.

The disease runs a chronic course of many years' duration. In making the diagnosis of tuberculous cystitis the history is of aid, and if gonorrhoea can be ruled out in a patient having a distinct family history of tuberculosis, the probability is that the disease is tuberculous, especially if the cystitis occurs in a young woman. The appearances of the bladder are more or less characteristic: glistening, opaque tubercles on a reddened base, breaking down to form ulcers with irregular sharp edges and granulating bases.

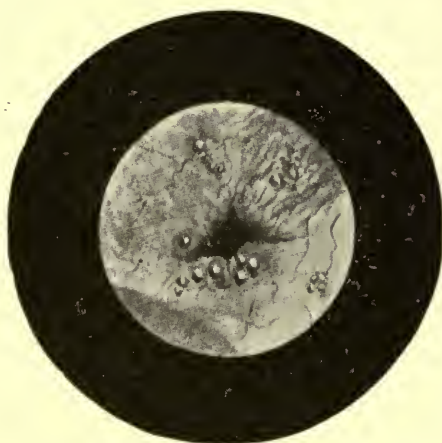


FIG. 187.—Tuberculosis of the Left Ureter and Bladder, Showing Crater-like Ureteral Orifice and Tubercles of the Bladder Wall. (Knorr.)

In the late stages the bladder shows contracted areas and ulcerations. Finding the tubercle bacilli in the urine makes the diagnosis positive. In the early stages of the disease they may be few in number and hard to find; later, there will be no difficulty, as abundant bacilli are in the urinary sediment.

Hunner and Casper have been able to find tubercle bacilli in eighty per cent of all their cases of tuberculosis of the urinary system. Hunner gives the following steps of his technique for finding the bacilli:—A catheterized specimen of urine is allowed to stand a few hours in a conical urine glass; 5 to 10 cubic centimeters are taken from the bottom with a pipette and centrifugalized. The heavy deposit is spread on two glass slides that have been pre-

viously cleansed of grease by alcohol, and are allowed to dry in the air or in the incubator. These slides, after fixing by heat, are stained in the usual manner by carbol-fuchsin, then they are decolorized with a three-per-cent nitric or hydrochloric acid alcohol solution, and counterstained with methylene blue. Half an hour is spent in the examination of each slide under the microscope.

Inoculation of a guinea-pig is an easy and sure way of establishing the diagnosis of tuberculous cystitis. By means of a hypodermic syringe suck up a little of the urinary sediment and inject it under the skin of the groin of a guinea-pig, having first washed and shaved the area. If tubercle bacilli are present the enlarged inguinal glands will be felt as distinct nodules in the course of two or three weeks. A gland removed, sectioned, and stained will show the characteristic lesions of tuberculosis and the tubercle bacilli.

In doubtful cases pick off a bit of tissue from the edge of the ulcerated area in the bladder, using the cystoscope and the alligator forceps, and stain and examine the tissue for tubercle bacilli.

Rare Forms.—*Certain rare forms of cystitis* have been described. Of these *vesicular cystitis* consists of the appearance of minute vesicles, the size of a pin's head, on a congested bladder mucosa. These vesicles may be arranged in bead-like strings on either side of the blood-vessels and are regarded as dilated lymphatics. Larger vesicles amounting to bullæ have been described as occurring in the bladder. The little vesicles are not to be confused with the tubercles of tubercular cystitis. The vesicles are shiny, translucent, and have no red base, as in the case of the tubercle. The tubercles are opaque and are never arranged in rows.

Several observers have noted the occurrence in the bladder of a patch of horny, epithelial cells arranged in layers, a cornification of the mucosa. A. T. Cabot (*Amer. Jour. Med. Sci.*, Feb., 1891) described a case in which a membrane of whitish-yellow color and hard to the touch, in size forty-five square centimeters and two or three millimeters in thickness, was removed by him from the posterior wall of the bladder of a man of forty by suprapubic cystotomy. The membrane was composed of epithelial cells arranged as they are on the surface of the skin. Virchow found a similar condition of the mucous membrane of the larynx that he called "pachydermia laryngis."

Gierke, according to Hunner, described two cases and found seven others in the literature with the following characteristics:—Soft nodules or plaques of a yellowish or yellowish-gray color situated in the mucous membrane and submucosa of the bladder presenting an appearance not unlike the Peyer's patches of the intestine in typhoid fever. They are round or oval, isolated or connected, and vary in size from one millimeter to two centimeters in diameter. The mucosa surrounding a plaque is reddened. They have no characteristic arrangement and their pathology and etiology are obscure.

Symptoms of Cystitis.—The chief symptom of cystitis is frequency of passing urine accompanied by pain, it being most marked when the seat of the disease is near the neck of the bladder. The frequency varies under differing conditions and at different times, from once an hour to every five minutes. There may be great straining on urination with the passage of only a few drops of urine at a time. This is known as strangury (from *στρογγύριον*, a drop, and *οἴρον*, urine). Patients of a nervous temperament suffer more acutely with a milder grade of bladder inflammation than do their thicker-skinned, more stoical sisters with a cystitis of severe type. Hyperemia of the trigone may be associated with frequency and even with painful micturition. An important factor in the symptomatology as regards its effect on the nervous system is the patient's fear that a toilet may not be accessible when the desire to urinate comes, therefore she stays at home, becomes a recluse, and is melancholic. Loss of sleep because of frequency of micturition is another important factor to consider in cases of cystitis in deciding as to the causation of nervous debility. More or less constant pain in the region of the bladder is a symptom of an ulcer of the base of the bladder. An ulcer or fissure may be painful only when the bladder is distended and the walls of the bladder are on the stretch and the surface of the ulcer or fissure is bathed in irritating urine. A rise of temperature may occur in acute cystitis, but in the chronic stages fever is generally absent. It may occur, however, in pyelitis, and irregular elevation of temperature should lead suspicions in that direction.

Diagnosis of Cystitis.—The diagnosis rests on the results of the examination of the urine and on the physical examination.

The Examination of the Urine.—The urine in cystitis is cloudy

and contains pus and large pavement epithelial cells. Other variable constituents are blood—normal and abnormal—urates, phosphates, crystals, and bacteria. To be sure that pus in the urine is from the bladder and not from the external genitals or the vagina it is necessary to procure a catheter specimen, and even then the point of origin of the pus may be the ureter or the kidney. If there are present casts, a large amount of albumin, and small epithelial cells, also if the passing of urine filled with pus alternates with the passing of clear urine, the indications point toward kidney disease. Kelly has called attention to the fact that when the bladder urine is alkaline from a proteus infection the pus cells become converted into mucoid substances and the urine is slimy and stringy, while no well-defined pus cells are found in the urine. The presence of abnormal blood in the urine signifies that the blood has been in the urine a considerable time, and therefore its origin is more likely to be the kidney than the bladder. If blood is effused rapidly, however, it will appear in the urine as normal blood, be its origin the bladder or the kidney.

In almost all cases of cystitis the urine is acid when freshly passed, but it quickly becomes alkaline on standing. In some cases the urine in the bladder is made alkaline by the bacillus proteus or other bacteria. This happens in cases of dislocated bladder where there is present residual urine. There is nothing distinctive about the specific gravity of cystitis urine, and many of the old views as to its characteristics must be revised in the light of our present knowledge of the bacterial origin of all forms of cystitis.

The odor of a cystitis urine is strong and may smell of decomposition even though the colon bacillus is present and the reaction is acid. There may be gas in the urine caused by the decomposition of diabetic urine due to the saccharomyces bacterium, or to the presence in the bladder of the gas bacillus, also in cases where there is a fistula connecting the bowels with the bladder.

Palpation.—Palpation of the bladder by the bimanual touch elicits areas of tenderness, especially if the cystitis is situated in its common location, the base of the bladder. Such areas may be mapped out by means of the catheter-sound in the bladder, the patient telling when the sensitive spot is touched. Thickening of the bladder wall is appreciated by palpating the base of the bladder with the finger in the vagina, and also by noting the

thickness of the tissues between the tip of the sound in the bladder and the vaginal finger; a contracted bladder may be felt as a hard, irregular lump. In acute cystitis vaginal palpation shows that the bladder is the seat of extreme tenderness, but further than that palpation is not available without an anesthetic.

Cystoscopy.—Cystoscopy may be employed in all cases of cystitis except in the most acute stages. Here it is wiser, generally, to make soothing treatments until the active symptoms of fever, strangury, and excessive tenderness have abated, before using the cystoscope. The use of cocaine in the urethra and the knee-chest position as described in Chapter VIII., page 110, best facilitate inspection of the interior of the bladder. In the case of trigonitis and the milder grades of bladder inflammation the artificial anemia caused by the high position of the pelvis, coupled with the air distention of the viscus, tend to do away with the characteristic signs, therefore in these cases the raised pelvis dorsal position should be used.

All parts of the bladder should be examined systematically in order. Free blood is wiped off the surface by minute pledgets of cotton held in the alligator forceps and thus is made plain the difference between blood on the surface of the mucosa and blood effused in the tissues. Collected urine is removed by the suction-tube and bits of urinary salts obstructing the view are taken away with the alligator forceps. If the disease is localized the congested, diseased areas of the bladder wall are contrasted with the paler, healthy parts. Cultures are made from ulcerated areas, the ureteral orifices are inspected, and the character of the fluid issuing from them is noted. It is never justifiable to pass a ureteral catheter into a presumably healthy ureter in the presence of acute or sub-acute cystitis, until the nature of the infection in the bladder is known, because of the great danger of carrying infection into the ureter, and until all other attainable facts as to the existence of kidney disease are in hand the physician should be content not to invade the ureters. In the presence of infection the bladder should be irrigated with sterile one-per-cent borie acid solution before ureteral catheters are passed and such an irrigation should be the last step in the cystoscopy.

VARIX OF THE BLADDER

Varicose veins of the bladder is a very rare condition, although from a priori considerations it should be common. It has been found in men associated with rectal hemorrhoids. Knorr shows in his book a beautiful plate of a varix in the neighborhood of the right ureteral orifice as seen through the electric cystoscope. Hem-



FIG. 188.—Varix of the Bladder near the Opening of the Right Ureter. (Knorr.)

orrhage from the bladder is the chief symptom, and difficulty of urination may be present. Cystoscopy affords the only opportunity for an exact diagnosis.

FISTULÆ OF THE BLADDER

A vesical fistula is an abnormal channel of communication between the bladder and an adjacent organ. Fistulæ are of three sorts:—1. Vesico-vaginal, 2. vesico-uterine, 3. vesico-intestinal and other fistulæ.

1. VESICO-VAGINAL FISTULA

Frequency, Etiology, and Pathology.—Vesico-vaginal fistulæ vary in size from a pin-point opening to a large hole involving the entire base of the bladder. The cervix may be involved, in which

case the fistula becomes vesico-uterine as well as vesico-vaginal. The opening is generally situated in the median line in the case of a fistula involving the cervix as well as the vagina, according to Thomas Addis Emmet ("Vesico-Vaginal Fistula," 1868). In other fistulæ the opening may be in any part of the vesico-vaginal septum. It is irregular in outline in the months following its formation and the edges are thickened and ulcerated; later, the opening is circular or oval and the edges are smooth, thin, and hard, the tendency of the fistula being to close by granulation and cicatrization. A clean-cut fistula formed artificially by operation for the purpose of draining the bladder in cases of cystitis will close spontaneously in a short time unless the operator takes the precaution to stitch the cut edges of the bladder mucosa to the edges of the vaginal mucous membrane. A small opening which has been caused by sloughing may close of itself, but, in many cases, these are the fistulæ that persist for years.

In the case of large fistulæ there may be present cicatricial bands radiating from the fistula over the bladder walls. Vesico-vaginal fistulæ are the most common of the fistulæ of the genital tract. They are not nearly so common as they used to be forty years ago. During the first twelve years of the Woman's Hospital in the State of New York up to the year 1868, Dr. Emmet had under his charge 296 cases of genital fistulæ, including in this number the cases of vesico-uterine and recto-vaginal fistula, the last, however, forming only about six per cent of the whole. At the present time I venture to say that few gynecologists having an active hospital service and a large private practice see more than two or three cases of vesico-vaginal fistula in the course of a year. A perusal of the recent annual reports of half a dozen metropolitan hospitals having large gynecological clinics reveals the fact that in no one hospital were more than three cases of vesico-vaginal fistula seen during any one year.

The cause of vesico-vaginal fistula is, in a vast majority of cases, ischemic necrosis of the vesico-vaginal septum due to impaction of the child's head in the pelvis during prolonged labor. Very rarely fistula may result from the use of the obstetric forceps. Emmet saw only three cases where this had occurred. It is possible that at the present time when forceps are used more frequently and women are neglected in labor less often, injuries from instruments

may occur with relatively greater frequency. If the forceps or other instruments cause the fistula there will be a discharge of urine immediately after labor, otherwise not until the slough has separated—in a week or ten days. In two cases that I operated on for extensive vesico-vaginal fistula there was a history of incontinence of urine following immediately after a difficult forceps

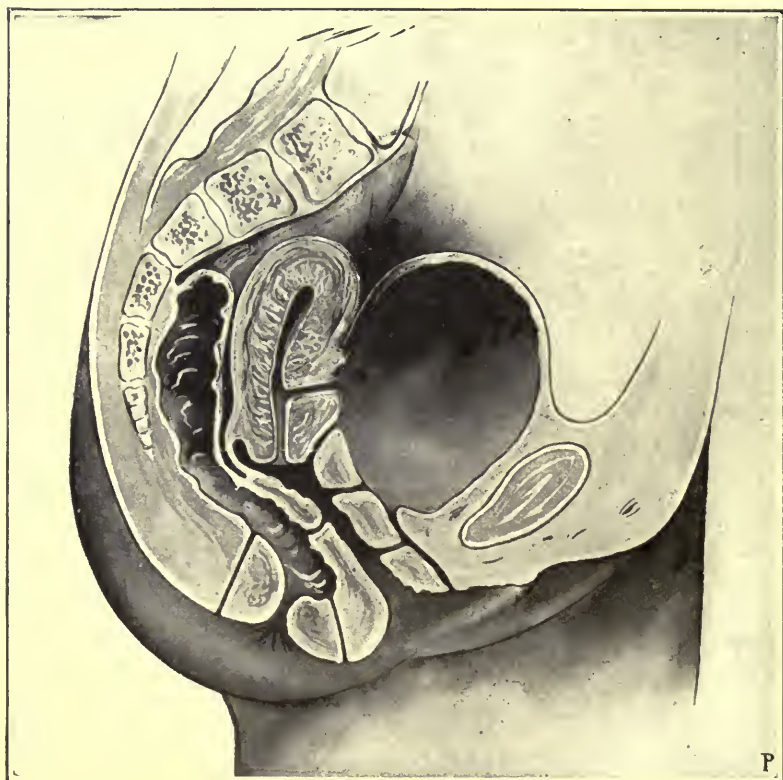


FIG. 189.—Diagrammatic Representation of the Different Sorts of Genital Fistulae. (Dudley.)

delivery in each instance. Embryotomy had been performed in one. Other causes of vesico-vaginal fistula are: sloughing resulting from cancer of the bladder, from a large vesical calculus or from an ill-fitting pessary, or the burrowing of a pelvic abscess.

Symptoms.—The symptoms of vesico-vaginal fistula consist of a constant dribbling of urine, beginning at once after the receipt of the injury if it is due to forceps or other obstetrical instruments

and in a week or ten days if due to a slough from prolonged pressure and ischemia of the vesico-vaginal septum. In the latter event we expect to find present a rise of temperature and a purulent vaginal discharge. The skin of the vulva, perineum, and the insides of the thighs is excoriated, reddened, and, in cases of long standing, thickened. The hairs of the vulva and the edges of the fistula are encrusted with urinary salts.

The patient suffers extremely from the irritation caused by the urine and from being constantly wet and deprived of proper rest, so that the nervous system is deranged and in many cases she becomes melancholic. The nutrition is impaired, and cachexia and poor health result.

If the vaginal outlet is uninjured, as occasionally happens, some patients with vesico-vaginal fistula are able to retain a considerable amount of urine in the vagina while lying down, the urine being passed when the patient assumes the erect posture. The subject of a vesico-vaginal fistula may become pregnant, an event that occurred in a patient who was under my observation, and Winckel has reported an instance of a woman with a vesico-vaginal fistula who became pregnant, was delivered at term, and subsequently the fistula healed spontaneously.

Diagnosis.—The patient should be placed first in the dorsal position. If there is dermatitis of severe grade it will be advisable to treat this condition before making an exact diagnosis. To this end the urinary salts should be removed carefully, the parts bathed in boric acid solution—one per cent—and thoroughly dried with soft lint, a pledget of cotton being placed temporarily in the vagina if necessary to prevent urine from coming out until the parts are dry. Then all the region of the vulva and insides of the thighs and also the introitus vaginae should be smeared with a freshly made ointment of oxide of zinc. This treatment should be repeated twice a day and the vulva should be constantly covered with soft napkins of washed cheese cloth or old linen, the attempt being made to keep the parts as dry as possible. Prolonged, hot six-quart vaginal douches should be given twice a day before the drying and the treatment with the ointment. Dr. Emmet always laid much stress on the douches and said that his good results with vesico-vaginal fistula depended in large measure on the faithfulness of the nurse. The urine should be kept diluted by giving

much fluid by the mouth—milk is especially valuable in these cases—and rendered unirritating and aseptic by the administration of urotropin, ten grains every four hours.

With the patient in the Sims position and with a Sims speculum in the vagina the fistula may be inspected, note being taken of its size, the condition of the edges, whether inflamed and thickened, or encrusted with salts, or cicatricial and thin. The situation of the ureteral orifices should be determined in every case so that they may not be included in the line of sutures when repair is undertaken. Also, if the opening is of sufficient size, the condition of the bladder wall may be seen, whether free from lime salts and how much inflamed and the openings of the ureters may be inspected directly. The capacity of the bladder, whether contracted or not, is determined by passing a sound through the urethra and, in the case of a large opening, by exploration with the finger passed through the fistula.

In the case of very small fistulæ nothing but a fine probe can be passed through the opening. In this event the probe is introduced into the bladder through the urethra and an attempt is made to cause its point to emerge in the vagina. In these cases it is well to put the patient in the elevated pelvis position and perform cystoscopy in an attempt to see the fistulous opening and probe it with the ureteral searcher. At the same time the condition of the bladder mucosa is inspected. In the case of minute fistulæ which can not be found with the probe, inject the bladder with milk and water or with aniline blue and water, the patient being in the dorsal position and a speculum in the vagina, and watch for the appearance of the colored fluid from the opening in the vaginal wall. Knowing the situation of the fistula a fine probe can almost always be passed through it. The amount of scar tissue in the vagina must be determined carefully because the repair depends on the amount of freely movable tissues at the disposal of the operator. The scar tissue is felt by the palpating finger as a hardened and roughened area. The finger introduced through a fistulous opening into the bladder feels the velvety mucous membrane of the bladder and also the rough lime salts, if they are present.

Differential Diagnosis.—A vesico-vaginal fistula must be differentiated from a *ureteral fistula into the vagina*.

In the latter event there will be a history of discharge of urine in the natural way and also of a more or less constant leaking. Injecting the bladder with milk and water and drying the vagina, search is made for an opening in the vaginal vault that gives exit to fluid having the odor of urine. If urine escapes from the os uteri, a vesico-uterine fistula is the diagnosis. In cases of doubt inject the bladder with milk and water and then see it issue from the os. Don't pass a ureteral catheter or probe into a suspected ureteral fistula nor into the ureteral orifice in these cases, because of the danger of infecting the ureter and causing ureteral and renal disease.

2. VESICO-UTERINE FISTULA

This form of fistula is not so common as vesico-vaginal fistula and is more often due to a direct tear from the uterus into the bladder during labor, than to sloughing following bruising of the tissues. The lower portion of the tear through the cervix generally heals, leaving a fistulous opening above. The symptoms are dribbling of urine more or less constantly. Some of the urine may be passed through the urethra and yet there may be a leaking. Filling the bladder with milk and water and noting that the white fluid comes from the os uteri establishes the diagnosis, also passing a sound or probe through the urethra, the end is passed through the bladder fistula into the uterus. Another sound passed into the uterine cavity through the cervical canal meets the first sound with a metallic click and imparts a sensation of contact to the first sound or probe.

Vesico-utero-vaginal fistula consists of an opening between bladder, cervix, and vagina resulting from extensive injury of the cervix. Emmet thought it of more frequent occurrence in women who have borne a number of children and have relaxed abdominal walls. The defect is apt to be found partially bridged over by granulation and cicatrization, or it may be entirely closed with the exception of a small fistula in the lower cervix.

3. VESICO-INTESTINAL AND OTHER FISTULÆ

Cases of communication between the bladder and the intestine have been reported but they are rare and most commonly follow

operative procedures. R. Harrison reported a case of fistula between the colon and the bladder in which bubbles of gas escaped through the urethra, and C. P. Noble published a case of rectovesical fistula following an ischio-rectal abscess, which had existed five years before. Gas and pieces of fecal matter were passed per urethram.

An abscess of the Fallopian tube or of the ovary may open into the bladder, and not very infrequently a suppurating dermoid tumor discharges in this way. The presence of cystitis and finding the contents of a dermoid, such as teeth, bone, or hair, in the bladder, or if passed from the urethra, points to the seat of fistula. Bone from a macerated extra-uterine fetus has been known to find its way into the bladder and to form the nucleus of a stone. The sudden appearance of a large amount of pus in the urine together with the symptoms of acute cystitis should lead to the suspicion that a tubo-ovarian or other pelvic abscess has discharged into the bladder. If the patient has been under previous observation and an abscess has been diagnosed, palpation will show it to be collapsed. Cystoscopy is the only sure means of making a diagnosis of fistula in such cases, the opening being found and probed by sight. Bimanual palpation shows the presence of an inflammatory mass adjacent to the bladder wall in this class of fistulae.

NEW GROWTHS OF THE BLADDER

Neoplasms of the bladder are either secondary to a malignant growth in an adjacent organ,—perhaps by direct extension, as in the case of carcinoma of the cervix, or perhaps by metastasis from cancer of a distant organ,—or they are primary in the bladder itself. Primary tumors of the bladder are relatively rare, being from three to five times less frequent in women than in men. They are most often observed between the ages of forty and sixty, but may occur at any age, though of very unusual occurrence before thirty. Nothing is known of their causation. They are to be classed as benign and malignant. The benign are: papilloma, fibroma, myoma, and adenoma; the malignant are: malignant papilloma, carcinoma, and sarcoma. The tumors may spring from

the mucosa, from the submucosa, or from the muscular layer, and they are more apt to be situated on the base or on the posterior wall, and show a tendency to be single rather than multiple. E. Hurry Fenwick, whose experience with bladder tumors has been extensive, says:—"Broadly speaking, the cystoscopist will encounter two well-marked varieties of vesical tumors: the villous-covered and the bald. Those clothed with villous processes may be benign or they may be malignant, but the smooth-surfaced groups are almost always malignant, more especially if they occur after the age of forty-five."

Symptoms.—The symptoms of bladder tumors in general are, sudden stoppage of the urine with resulting pain (in the case of pedunculated growths), and intermittent hemorrhage at the end of urination, or mixed with the urine. Renal pain in the kidney whose ureteric orifice is nearer the tumor in the bladder is a not uncommon symptom. Spontaneous coagulation of the urine in a vessel (fibrinuria) due to the excess of fibrin discharged with the blood in the urine has been observed only in the case of bladder tumors. Cystitis is a late manifestation. Frequent micturition is common, especially if the base of the bladder and the trigone are affected.

Diagnosis.—The diagnosis depends on the history, on palpation, on the cystoscopic appearances, and on the microscopic examination of shreds in the urine and tissue removed from the bladder. Malignancy is distinguished from benignity only by the greater preponderance of pain and induration of the tissues in the former. Certain distinguishing characteristic features will be taken up with each disease. Lincoln Davis (*Annals of Surgery*, April, 1906), from an analysis of forty-five cases occurring in the Massachusetts General Hospital, thinks that the important diagnostic feature of malignancy of bladder tumors is the infiltration of the underlying bladder wall, and that the recurrence of epithelial tumors does not mean necessarily that they are malignant. The electric cystoscope with water-distended bladder is especially well adapted to the inspection of bladder tumors and very beautiful pictures are obtained of the villi of a papillomatous growth floating in the bladder fluid like the tentacles of a sea anemone.

BENIGN TUMORS

Papilloma.—Papillomata are the most common of all vesical tumors. The name papilloma is given to pedunculated tufted tumors, but the shape does not necessarily indicate their pathological structure, so that it happens that papilloma, although commonly made up of submucous connective tissue—a fibroma, and therefore benign—may be an outgrowth of the epithelial tissue of the mucosa and therefore malignant. The benign papilloma is made up of a framework of connective tissue richly supplied

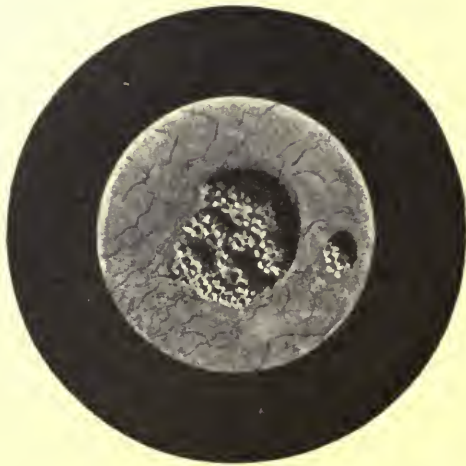


FIG. 190.—Papilloma (Fibroepithelioma) of the Bladder. (Knorr.)

with blood-vessels and covered with pavement bladder epithelium. It has a branching, villous appearance, the villi are often of extreme thinness and resemble chorionic villi, or they may be short and stunted and some may be covered with white phosphatic deposits. The villi may be so short that a papillomatous growth may appear through the cystoscope to be smooth on first inspection; in this event it looks white, differing from the smooth reddish or reddish-white surface of an epithelioma. These growths are generally single in their early stages and the base never reaches downward beyond the submucosa. They vary in size from a pea to a hen's egg, the latter being rare, and are more commonly found in the neighborhood of the ureteric orifice, outside the trigone. The mouth of the ureter

nearer the tumor is reddened and is converted into a furrow instead of being a little slit. The surrounding mucosa of the bladder is generally reddened and swollen. If the pedicle is long the growth will float about and is likely to plug the internal orifice of the urethra, and therefore cause retention. The more sessile the tumor and the further it is situated toward the posterior wall, the less likely is this result to occur.

The first symptom of papilloma is blood at the end of micturition; later the amount of blood lost may be alarming. An ache in the kidney on the side of the body on which the tumor is situated is a symptom of the advanced stages when the growth has increased in size. This ache is thought to be due to ascending infection of the ureter and kidney, with or without hydronephrosis. Impeded urination occurs if the tumor obstructs the urethral orifice, and cystitis may be a late result. The diagnosis rests on these symptoms, on the finding of a tumor by vaginal palpation of the bladder base, and on the cystoscopic appearances as described above. The microscopic examination of pieces of tissue passed in the urine or removed by the alligator forceps will alone settle the diagnosis of the sort of tumor present.

Fibroma and Myoma.—These benign tumors are of rare occurrence. A fibroma or fibroid polyp is made up of connective tissue, it is usually pedunculated and has a smooth or slightly lobulated surface. Its pedicle is well vascularized, but the tumor itself is not. The latter fact may be the reason that these tumors are apt to undergo myxomatous degeneration. Only a few cases of myoma of the bladder have been described. They begin in the muscular coat and develop into the cavity of the bladder either as a sessile or as a pedunculated growth. In one reported case the myoma was on the outside of the bladder.

Adenoma.—This is a rare benign epithelial tumor of the glandular type; it is sessile or stalked, and has a smooth, lobulated, or villous surface. The sessile growth, as in the case of the fibroid polyp, can be enucleated easily from the bladder wall.

MALIGNANT TUMORS

Carcinoma.—There are two sorts of primary cancer of the bladder, one squamous-celled, and the other cylindrical-celled. The disease begins as a small nodule either of the encephaloid, scirrhous, or

colloid type, and has a tendency to remain localized in the bladder for a long time. Later, multiple tumors are found, and ulceration, cystic degeneration, and gangrene occur. The bladder wall surrounding and under the tumor is indurated. The surface of the tumor may be covered with villi, which are more vascular than in the case of the benign growths; the growth is apt to be sessile. The disease extends from the base of the bladder, its usual situation, to the ureters, often closing one or both orifices and causing renal disease and it either forms a tumor in the bladder or infiltrates the bladder wall and the surrounding tissues. The symptoms are the same as in papilloma and the diagnosis is made in the same manner. Much induration of the tissues in the bladder base points toward carcinoma and constant pain in the region of the bladder, and frequency of micturition, are characteristic symptoms. Cystitis, with pain in other regions, as in the back and thigh, and emaciation, are late manifestations. The exact diagnosis is made by the microscopic examination of a portion of tissue either from the urine or removed from the bladder through the cystoscope.

Sarcoma.—Primary sarcoma of the bladder is extremely rare, although more frequent than in men. It may occur at any age. The tumors are of rapid growth, usually multiple. They are sessile and tend to grow out through the urethra. They are red or blackish in color and have a smooth surface.

FUNCTIONAL DISTURBANCES OF THE BLADDER

As has been pointed out already, any disease that interferes with the normal physiology of the trigone and neck of the bladder is apt to cause bladder symptoms, as, for instance, hyperemia of the trigone or trigonitis, and dislocation of the neck of the bladder. In these days of cystoscopy we find many instances of frequency of urination where the only discoverable abnormality is injection of the mucosa of the trigone. A concentrated urine from lack of sufficient ingested fluids, urine containing an excess of uric acid, crystals of oxalic acid, or turpentine, cantharides or other irritating substances, is a cause often of frequency of micturition. So also may be a urethra of caliber insufficient to drain the bladder freely and speedily.

Irritability of the bladder has been the term that has in the past cloaked a multitude of sins of omission in diagnosis. In *hysteria* the secretion of large quantities of limpid urine with consequent frequency of micturition alternates with scanty high-colored urine. Spasm of the detrusor fibers of the bladder with the involuntary discharge of urine occurs sometimes in this disease, and hysterical retention is frequent.

When there is spasm of the neck of the bladder in hysteria there may be great difficulty in starting urination. Incontinence may occur with an attack of epilepsy. In the case of *locomotor ataxia* there is lack of control over the bladder, beginning as a delay in starting micturition; after the flow has begun it stops suddenly, then starts again, and when the bladder seems to be emptied urine is passed into the clothes.

In this disease there may be also partial or complete retention with incontinence from overdistention, or vesical tenesmus.

Retention and incontinence occur in *Pott's disease* and in *injuries of the brain and spinal cord*, and also in *general paralysis of the insane*. Retention is noted as a constant symptom in *multiple sclerosis*.

Where the passing of large quantities of urine is due to mental influences, as in the case of *apprehension and worry*, and not to organic nervous disease, the frequency of micturition is limited to the day-time, for as a rule such a patient sleeps all night without rising to empty her bladder.

Incontinence of urine is of two sorts, that which occurs in overdistention of the bladder, the drop-by-drop kind, with incessant dribbling, and the incontinence in the form of intermittent evacuations of large quantities of urine. The first kind is due to any cause which distends the bladder with urine, the cause being found among the functional and organic diseases of the bladder; the second is supposed to be due to faulty innervation of that organ. The latter kind is most frequent in children. Many of these children are quite normal as to their urinary functions during the day and the incontinence is nocturnal only; others, a smaller proportion, not only wet their beds at night, but experience pressing calls to urinate during the day, and if not attended to at once, wet their clothes. (See Enuresis, Chapter XXVIII., page 578.)

CHAPTER XXV

THE DIAGNOSIS OF DISEASES OF THE URETERS

- Anomalies, p. 486: Double ureter, p. 486. Abnormal situation of ureteral orifice, p. 486. Cystic dilatation of an occluded ureter, p. 487. Ureteritis, p. 488. Stricture of the ureter, p. 489. Ureteral calculus, p. 490. Prolapse of the ureteral mucosa into the bladder, p. 491. Ureteral Fistulæ, p. 492: Uretero-uterine, p. 492. Uretero-vaginal, p. 492. Uretero-vesical, p. 492. Uretero-intestinal, p. 493. New growths of the ureter, p. 493.

THE anatomy and physiology of the ureters and the methods of examination will be found described in Chapter VIII., page 104.

ANOMALIES

Anomalies of the ureter are rare. One ureter has been found wanting, just as one kidney is sometimes absent. It is the rule that extreme degrees of ureteral malformations are associated with non-viable fetuses.

Double ureter is the anomaly most frequently observed. The duplication may start at the kidney from two separate pelves and then unite at some point below to form one canal to the bladder, or it may continue double and enter the bladder by two orifices, one behind the other. Cases are reported in which a double ureter was found on each side in the same patient. The anomaly has little if any clinical importance and is discovered in the course of cystoscopy, during operations on the kidney, or at autopsies.

Abnormal Situation of Ureteral Orifice.—The ureteral orifice has been found in one of the following situations: the vagina, the urethra, near the external meatus, and under the prepuce of the clitoris.

The patient suffers from persistent leakage of urine, but at the same time empties her bladder at regular intervals. The importance of finding out whether the abnormally placed ureteral orifice is the only outlet of a ureter or a supernumerary orifice is apparent.

The history of incontinence existing from birth in a virgin is a presumption in favor of abnormal congenital implantation, although the other causes of incontinence of urine (see Chapter X., page 154) must be investigated. If, on the other hand, the incontinence dates from a difficult labor, or the patient has been subjected to some operative interference, the probability is that an abnormal situation of a ureteral orifice has been artificially induced. If the orifice should be under the prepuce of the clitoris, drying the vulva with cotton and watching it will soon determine the source of the urine. If the orifice is in the urethra the urethra must be inspected through its entire length most carefully with a cystoscope in order to find the opening. If in the vagina, the vagina is dried with cotton after a speculum has been introduced, and search is made for the ureteral orifice. By placing a light packing of dry absorbent cotton in the vagina and removing it, one may fix approximately the situation of the opening by the situation of the spot of urine on the cotton. Does the wet cotton smell of urine? A fine probe may be used as a searcher. The bladder is injected with milk and water or aniline-blue solution to rule out this viscus as a source of the escaping urine. If none of the colored fluid escapes into the vagina the opening found in the vagina is a ureteral orifice. Cystoscopy is now performed and search made for both ureteral orifices in the bladder. If only one is found the inference is that the opening in the vagina is of the opposite ureter. A sterile ureteral catheter is passed into it and the catheter palpated by rectal examination. If two orifices are found in the bladder a ureteral catheter is passed into each and an attempt made to touch one of them with the tip of a probe introduced into the orifice in the vagina, thus determining a supernumerary orifice, and also on which side of the body, and with which kidney it is connected.

Cystic dilatation of an occluded ureter has been reported. In this anomaly the lower end of the ureter has failed to communicate with the bladder or with any other part of the genital tract. The reported cases have been in adults. In one instance the ureter ended in a cyst that was mistaken for a cyst of the vagina. Uterine anomalies are apt to accompany the blind ending of a ureter; sometimes the ureter may end without dilatation. In either event the corresponding kidney is the seat of hydronephrosis or it is atrophied.

In all ureteral diseases as well as in cases of suspected nephritis the physician must watch each ureteral orifice separately and note the character of urine issuing from it, whether clear, turbid, or bloody, the force with which the urine is ejected, and the rate of frequency of the spurts. It will be found that in the case of a diseased kidney of diminished functional capacity the rate of spurting from the ureteral orifice will be much diminished—perhaps only once in two minutes—while the orifice from the sound kidney spurts urine every twenty seconds. Where the kidney is atrophic there may be no discharge of urine from the ureter on that side.

URETERITIS

Inflammation of the ureter arises from extension of inflammation downward from the kidney, upward from the bladder, from some cause in the ureter itself—as from a calculus in the ureter—or from inflammation in the cellular tissue surrounding the ureter,—periureteritis, so-called. As a rule the disease is due to the tubercle bacillus, to the gonococcus, or to the colon bacillus, except in the cases of stone in the ureter; and ureteritis is secondary to disease of the kidney or bladder, therefore its symptoms are often overshadowed by the symptoms of those diseases. Pain in one groin extending up to the kidney on the same side, with frequent and painful micturition and pus in the urine, are the symptoms of ureteritis. The diagnosis is established by the symptoms and by the physical examination. Palpation of the base of the bladder and the lateral vaginal fornix will detect a tender, thickened cord coursing toward the posterior pelvis. This cord may be traced a little farther by rectal palpation. An acutely inflamed ureter is very sensitive. The abdominal course of the ureter may be palpated in patients who are not too fat by finding the promontory of the sacrum, and rolling the abdominal wall over a point situated two fingers' breadth to one side, for at this point the ureter crosses the brim of the true pelvis. If the ureter is inflamed at this point the patient will experience pain when it is pressed against the underlying bone.

Through the cystoscope the orifice of an inflamed ureter will generally be found in a puffy and swollen mass situated in an area of injected mucosa, and cloudy urine may be seen to issue from it.

STRICTURE OF THE URETER

Stricture or obstruction of the caliber of the ureter is much more common in women than in men. It may be due to (*a*) pressure from without, to (*b*) a foreign body in the canal, or to (*c*) localized contractions or narrowing of the lumen caused by inflammatory action or to valve formation in the walls of the ureter itself. *a*. Some of the causes of obstruction of the ureter from without are:—Ovarian and uterine tumors, cancerous infiltration of the broad ligaments, thickened bladder walls, and tumors of the bladder. *b*. The bodies that may obstruct the canal of the ureter are: a calculus, a blood clot, or an echinococcus cyst. *c*. The affections of the ureteral walls are: ureteritis, valve formation in the ureteral wall, cancer of the ureter, and gumma of the ureter.

The situation of obstruction is almost always in the pelvic portion of the ureter, rarely in the upper end near the pelvis of the kidney. Certain diseases of those mentioned are apt to cause obstruction of both ureters. They are: cancer of the cervix extending into the bases of the broad ligaments, thickened bladder walls from any cause, and subperitoneal fibroid tumors. In other cases the obstruction is apt to be unilateral.

The symptoms depend on whether the obstruction is of sudden or of gradual occurrence. In the former case there is pain in the course of the ureter; in the latter, there may be no symptoms at all. If the obstruction depends on ureteritis the symptoms will be those of ureteritis. Persistent pain in the course of the ureter and pus in the urine should lead to an investigation of the cause. The diagnosis is made by palpating the ureter by vagina, by rectum, and at the pelvic brim, as described in the diagnosis of ureteritis. Search should be made for tumors of the pelvis, or for exudates which may press on the ureter, remembering that it is in the pelvis that obstruction generally occurs.

Catheterization of the ureter through the cystoscope will show, first, that the catheter meets a sudden check, or after meeting a less pronounced obstruction it may pass by a narrowed part of the ureter, whereupon there is an immediate flow of an ounce or more of urine. Perhaps the catheter will be seized at the stricture and resist withdrawal.

In introducing a metal catheter into the ureter for searching purposes it is well to have the patient in the dorsal position, so that after the catheter is in place its further course may be guided by the finger in the rectum. In using the gum-elastic or renal catheter the examination is begun with the patient in the knee-chest position. After the catheter has been introduced the patient is lowered to the dorsal position and a bladder catheter passed to let the air out of the bladder. The point where the stricture is situated is noted by withdrawing the catheter until the eye has become engaged in the stricture. At this point the flow of urine stops. Measure from the outer end of the catheter to the meatus urinarius. After the catheter is out the difference between this measurement and the total length of the catheter is the distance of the upper part of the stricture from the meatus. To determine the distance of the stricture from the bladder, subtract from the last measurement the distance from the meatus to the ureteral orifice, as measured by the ureteral searcher passed through the cystoscope.

Graduated whalebone bougies have been used to determine the situation and size of strictures of the ureter by various investigators. I have had the best results with the Kelly gum-elastic renal catheters which contain stylets.

URETERAL CALCULUS

A calculus is much more often found in the renal pelvis or in the bladder than in the ureter. If the calculus has been lodged in the ureter for any considerable length of time it is apt to have a spindle shape. The calculus forms in the pelvis of the kidney and works down into the ureter; it may be about an inch (2.5 centimeters) long and a quarter of an inch (5 millimeters) in diameter, but smaller ones are most often seen. A calculus five inches (12.5 centimeters) long has been observed. Calculi generally lodge just below the pelvis of the kidney, at the pelvic brim, and in the pelvic floor. Severe pain in the course of the ureter,—often accompanied by chills and rigors, rapid pulse, and prostration,—is characteristic of the lodgment of a stone in the ureter. Paroxysms of pain come on intermittently at variable intervals as long as the stone is in the ureter. If the stone moves downward by irregular gradations

its movement may be traced by the appearance of blood in the urine. The stone, damming up the urine, causes hydronephrosis and by forming a ball valve in some cases permits the intermittent discharge of large quantities of urine. In the course of time the kidney is damaged by the back pressure of urine, by infection, or by both.

The diagnosis is established by the symptoms, by palpation, and by catheterizing the ureters. A stone in the pelvic floor may be palpated by vaginal and rectal palpation and at the pelvic brim by abdominal palpation. In the upper part of the true pelvis a stone may be felt by high rectal palpation. Through the cystoscope a stone may be seen projecting from the ureteral orifice or pushing the mons into the bladder; if not, it may be touched with the metallic ureteral catheter introduced in the ureter. To detect a stone high up in the ureter Dr. Kelly uses a flexible renal catheter tipped with a light coating of dental wax, noting, after the catheter has been withdrawn, the scratch marks made by the stone on the wax.

The X-rays may be used to detect the presence and situation of a ureteral calculus, a competent radiologist being employed to obtain a photograph, and also, if the calculus is in the upper portion of the ureter, an exploratory incision may be made either through the abdomen in the linea semilunaris, or extraperitoneally in the lumbar region, as for nephrectomy. If an incision is made plans should be perfected beforehand to proceed with an operation for the removal of a stone should palpation through the wound reveal its presence.

PROLAPSE OF THE URETERAL MUCOSA INTO THE BLADDER

Prolapse of the ureteral mucosa into the bladder has been found rarely in children and is probably congenital. It is thought to depend on stricture of the ureteral orifice causing the lower end of the ureter to project into the bladder in the form of a cystic tumor, the obstructed ureteral orifice being at some point on the circumference of the tumor. Cases of acquired prolapse of this sort have been reported and it is likely that the disease occurring in children has the same mechanism of causation.

URETERAL FISTULÆ

A ureteral fistula is an abnormal opening between the canal of the ureter and the surface of the body, or some part of the genital or alimentary tract. Ureteral fistulæ are congenital, as pointed out in the consideration of anomalies, page 486, or they are produced by trauma,—most commonly as a result of a difficult labor,—from injuries in the course of operations on the pelvic contents or on abdominal tumors, or they are caused by ulceration. They involve generally the pelvic portion of the ureter. Difficult labor may cause sloughing of the uterus or vagina and the ureteral wall, leaving a permanent *uretero-uterine* or *uretero-vaginal fistula*. The ureters have been cut in the course of hysterectomy many times,—sometimes when the cause of death has been set down as exhaustion or peritonitis. In cases where the patient has survived, the urine finds its escape through the drainage tract either in the abdominal wall or in the vagina. In one of my cases the ureter discharged through the canal of the cervix uteri, a supravaginal amputation having been performed for a large fibroid. The opening healed spontaneously in the course of a few weeks. This is the issue in many cases. Sometimes, however, the fistula is permanent.

A ureteral stone has been known to ulcerate through the walls of the ureter and bladder, finding its way into the latter viscus and forming a *uretero-vesical fistula*.

In making a diagnosis of ureteral fistula it is to be remembered that in the congenital forms the opening of the ureter is generally situated low down near the external genital organs, *i.e.*, under the prepuce of the clitoris, near the meatus urinarius, or in the lower vagina; in the acquired forms, on the other hand, the opening is more apt to be higher up near the base of the bladder, or in the vault of the vagina. The congenital fistulæ have a history of loss of urine since childhood, whereas the acquired date from some operation, a difficult labor, or from some definite date. If only one ureter is involved in the fistula, the usual happening, the patient passes urine by the urethra as well as experiencing the discomfort of more or less constant leakage. If the fistula is into a vagina closed by a tight hymen the loss of urine may occur only when the patient is in the erect posture.

The bladder is injected with aniline blue and water, or with milk and water, and if there is a fistula involving the bladder and the uterus, or bladder and vagina, the escape of the colored fluid will be noted. If there is a fistula in the lower pelvic course of the ureter a metal ureteral catheter passed into this ureter will go an inch or two but not beyond the situation of the fistula, whereas in the sound ureter it may be pushed gently well up into the pelvis, some three inches.

Uretero-intestinal fistula is apt to be the sequel of an operation, but may be congenital. If the ureter opens into the intestine infection commonly passes up the ureter to the kidney. This has been the result of artificially turning the ureters into the rectum because in this case there is no valve at the orifice to protect the ureter. The urine is generally irritating to the rectal mucosa and the patient when constipated feels a desire for defecation and passes urine without feces per anum. Cystoscopy shows only one ureteral orifice, or one orifice transmitting urine and the other functionless.

NEW GROWTHS OF THE URETER

Primary tumors of the ureter are rare. E. Garceau ("Renal and Ureteral Tumors," 1909) mentions fourteen cases of strictly localized primary ureteral tumors which he has analyzed, ureteral calculus being associated with two of these. The more usual forms are epithelial growths occurring in the varieties of papilloma, and papillary and non-papillary epithelioma.

One or two cases of mesodermal growths have been recorded. Ureteral tumors are practically all malignant. They originate generally in the upper ureter or in the pelvis of the kidney. Their symptoms are pain, hemorrhage, and the presence of a tumor, and the diagnosis has been made in only a very few cases without operation. The diagnosis may be made, however, in the presence of hematuria by isolating characteristic cells of the growth from the urine drawn from the pelvis of the kidney by the renal catheter.

CHAPTER XXVI

THE DIAGNOSIS OF DISEASES OF THE RECTUM

Anomalies, p. 494: 1. Arrest or irregular development of the hind gut, p. 496; Imperforate rectum, p. 496; Imperforate rectum with outlet into the urethra or bladder, p. 496; Imperforate rectum with outlet into the vagina, p. 497. 2. Arrest or irregular development of the proctodeum, p. 497; Imperforate anus, p. 497; Imperforate anus with anal canal ending in the vulva, p. 497; Anus well-formed, anal canal ending above in a cul-de-sac, p. 497; Abnormally small anus, p. 498.

Hemorrhoids or Piles: Frequency and etiology, p. 498. External hemorrhoids, p. 500. Internal hemorrhoids, p. 501.

Fissure in Ano, p. 503: Symptoms, p. 503. Diagnosis, p. 504. Differential diagnosis, p. 505.

Inflammation of the Rectum, Proctitis, p. 505: 1. Simple proctitis, p. 506; Acute catarrhal proctitis, p. 506; Chronic catarrhal proctitis, p. 507; Atrophic proctitis, p. 507; Hypertrophic proctitis, p. 508. 2. Specific proctitis, p. 510; Gonorrhoeal proctitis, p. 510; Syphilis of the rectum and anus, p. 510; Congenital syphilis, p. 510; Chanere, p. 511; Mucous patches, p. 511; Ulcerations, p. 512; Gummata, p. 512; Syphilitic stricture, p. 512; Chaneroids of the anus and rectum, p. 512; Tuberculosis of the anus and rectum, p. 513; Dysenteric proctitis, p. 513.

Abscess and Fistula in Ano, p. 514: Abscess, p. 514. Fistula, p. 516: Varieties, p. 516; 1. Complete, p. 516; Horseshoe fistula, p. 516; 2. Incomplete, p. 517; Blind external fistula, p. 517; Blind internal fistula, p. 517; Symptoms, p. 518; Physical examinations, p. 518.

Stricture of the Rectum, p. 518: Congenital strictures, p. 519; Strictures due to pressure on the rectum from without, p. 519. Inflammatory strictures, p. 519; Pathology, p. 519; Symptoms, p. 520; Physical examination, p. 520.

Prolapse of the Rectum, p. 521: Symptoms, p. 521. Physical examination, p. 522.

New Growths of the Rectum, p. 522: 1. Benign tumors, p. 522; (a). Tumors about the anus, p. 522, Papilloma, p. 522; Soft fibroma, p. 523; Lipoma, p. 523. (b). Tumors of the rectum, Polypi, p. 523; Adenoma or mucous polyp, p. 523; Fibro-adenoma, p. 523; Lymph-adenoma, p. 523; Glandular polypi, p. 524; Fibroma or fibrous polyp, p. 524; Myoma, p. 524; Villous tumor, p. 524; Myomatous polyp, p. 525. 2. Malignant tumors, p. 525; Cancer of the rectum, p. 525; Cancer of the anus, p. 526, Pathology, p. 526, Symptoms, p. 527, Diagnosis, p. 528, Differential diagnosis, p. 528; Sarcoma of the rectum, p. 529, Varieties, p. 529, Diagnosis, p. 530.

A SHORT sketch of the chief points in the anatomy and physiology of the rectum, as well as a description of the methods of examination,

will be found in Chapter IX., page 121. An analysis of the chief symptoms of rectal disease is given in Chapter X., page 156.

ANOMALIES

The different stages of the development of the rectum and anus are shown diagrammatically in the figures from Schroeder on page 395, Figs. 158–162, Chapter XXI. As it is not the general custom for obstetricians to examine carefully the anus and rectum of the new-born infant, many minor malformations pass unobserved. Where a careful examination is made some degree of malformation will be found not so infrequently. Starr has estimated

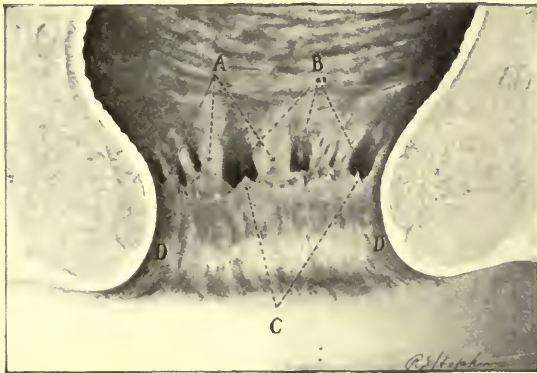


FIG. 191.—The Anal Canal. *A*, Columns of Morgagni; *B*, Semilunar valves or Crypts of Morgagni; *C*, Dentate Border Marking Upper Limits of Anus and surmounted by Papillae; *D*, Hilton's White Line. (Tuttle.)

that anal and rectal malformation occurs about once in ten thousand births. It is more common in girls than in boys, if we include anus vaginalis (see page 393, Chapter XXI.). As shown in the diagrams on page 395 the rectum and the anus are developed from entirely different structures of the blastoderm, the former from the hind-gut, and the latter from the proctodeum, a depression in the epi-blast opposite the lower end of the hind-gut, therefore malformation of the one does not necessarily imply abnormality of the other. As a matter of fact, if the rectum is malformed or displaced the anus is generally normal, and vice versa.

Malformation of either of these organs is likely to be associated with malformation in other portions of the body that are derived

from the same layer of the blastoderm. For instance, children with anomalies of the rectum are apt to suffer with cleft palate.

Many of the developmental defects are associated with non-viability and monstrosities. The following anomalies have been described:

1. ARREST OR IRREGULAR DEVELOPMENT OF THE HIND-GUT

Sir Charles Ball ("The Rectum, Its Diseases and Developmental Defects") reports the case of a child three months old, in which the rectum was entirely absent, also the entire colon, the ileum

opening in the center of an exstrophy of the bladder. The external genitals were also wanting. Children born with such defects must necessarily be short lived.

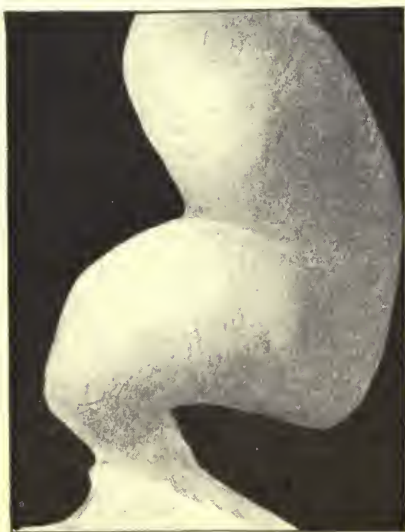

FIG. 192.—Cast of Rectum and Anal Canal. (Tuttle, after Quénu and Hartmann.)

Imperforate Rectum.—This is a common malformation, the bowel ending in an open tube on a level with the reflection of the peritoneum on the rectum, presumably due to the failure of the hind-gut to send out a bud, the post-allantoic gut, to meet the proctodeum. The condition may or may not be associated with imperforate anus. If it is, the condition is recognized at once by inspection; if not, the infant is generally

dosed with cathartics, and only when grave symptoms of obstruction supervene, is a thorough examination made. The physician should make it a rule to institute a thorough physical examination if an infant's bowels have not moved within the first twenty-four hours of life. If the anus appears to be normal externally, introduce the well-anointed tip of the little finger and determine whether the anal canal is patent.

Imperforate Rectum with Outlet into the Urethra or Bladder.—In

this anomaly there has been a persistence of the allantoic opening with failure of the rectum to end in the anus. If the opening is into the urethra (a condition usually found in the male) there is an escape of flatus and meconium from the urethra together with the urine; if, on the other hand, the opening is into the bladder the meconium and feces become mixed with the urine and sooner or later the individual succumbs to ascending infective ureteritis and kidney disease, even if the outlet is large enough to obviate intestinal obstruction.

Imperforate Rectum with Outlet into the Vagina.—This is a persistence of the urogenital sinus and is met with not infrequently. The opening may occur at any point in the vagina and is generally large enough to permit the passage of meconium or even solid feces. An imperforate hymen may obstruct the escape of the feces from the vagina, and in this case there is present a bulging, greenish membrane in the situation of the introitus.

The rectum has been known to be imperforate and to connect with the uterus, and also to open on the back near a spina bifida; and the rectum may open normally, but have connected with it ureters, uterus, or vagina. Also, diverticula in the lower rectum are sometimes found.

2. ARREST OR IRREGULAR DEVELOPMENT OF THE PROCTODEUM

Imperforate Anus.—There may be no trace of the anus, or its situation may be marked by a slight depression, or by a wart-like prominence; this constitutes entire absence of development of the proctodeum.

Imperforate Anus with Anal Canal Ending in the Vulva.—This is a very common anomaly and is confounded with imperforate rectum having a vaginal outlet. Women with this anomaly may have children and live to an advanced age without realizing that they are abnormal, as they may have perfect control over the vulvar anus. Incontinence of feces is common in these cases, however.

Anus Well Formed; Anal Canal Ending above in a Cul-de-sac.—In this malformation the proctodeum develops a normal anus, but the anal canal is imperforate above. The condition may be associated with imperforate rectum, but often the rectum is normal and only

a membranous septum separates its cavity from the anal canal. The child on straining may cause this septum to protrude from the anus.

Abnormally Small Anus.—The anus may be abnormally small (see Congenital Stricture of the Rectum, page 519), or it may be divided into two parts by a median longitudinal septum.

HEMORRHOIDS OR PILES

Hemorrhoids or piles are tumors composed chiefly of dilated blood-vessels or blood-clots, situated beneath the mucous membrane or skin of the anus or lower rectum. They are (*a*) *external*, when they are on the outside of the anus, either as exaggerations of some of the natural rugæ of the skin around the anus, or rounded or elongated venous tumors situated at the margin of the anus; or, they are (*b*) *internal*, tumors originating within the anal canal or in the ampulla, capable, perhaps, of being forced outside. Both sorts of piles may exist in the same patient. Histologically a pile is seen to be made up not only of the dilated veins, with thickened walls, but also of a considerable amount of connective tissue, the latter being more in evidence in cases of long duration.

The terms hemorrhoids and piles are used interchangeably, but the former (from the Greek *αἱμόρροια*, a discharge of blood) appears to have the better authority, perhaps because it appears in the Bible. In 1 Samuel, v. 9, we find:—"——the hand of the Lord was against the city with a very great destruction; and he smote the men of the city, both small and great, and they had emerods in their secret parts."

The term pile, signifying a ball (from the Latin, *pila*), would seem to be fully as descriptive as hemorrhoid, but having been used extensively by the quacks has fallen into disrepute.

Frequency and Etiology.—The disease is extremely common and few persons pass middle life without having suffered from it. It appears to be more common among men than women, although authors vary in their estimation of the relative frequency. Perhaps five men to three women is a fair statement.

Hemorrhoids are more often found in middle age, although cases are on record as young as six months, one author having reported

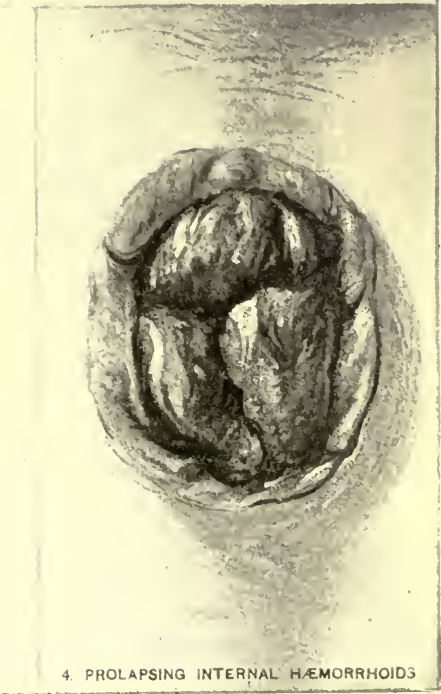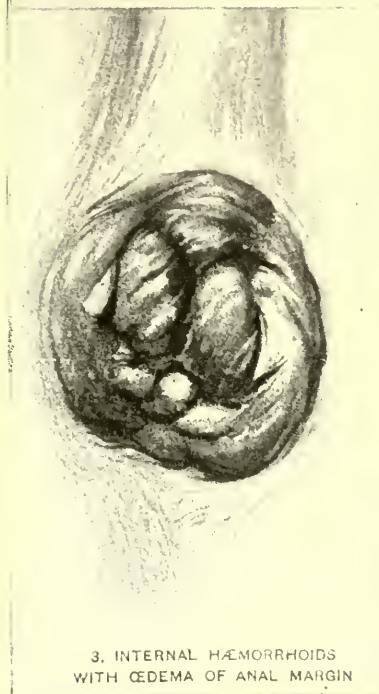
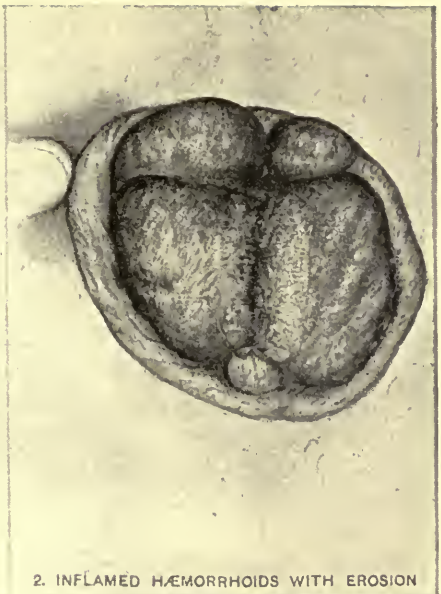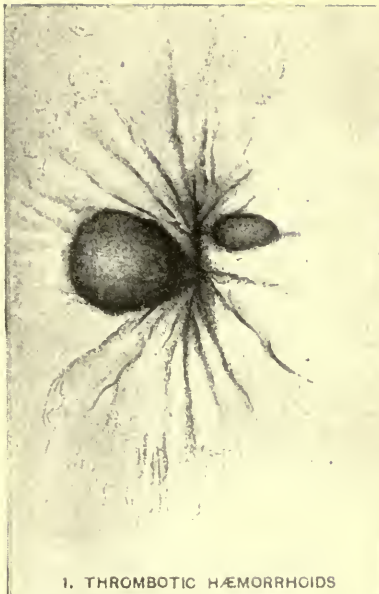


FIG. 193.—Types of Hemorrhoids. (J. P. Tuttle.)

thirty-nine children under the age of fifteen years who had hemorrhoids. Heredity seems to play a rôle in the causation, successive generations of a family suffering with the disease. The upright posture apparently has to do with the causation, for none of the domestic animals have hemorrhoids except, occasionally, very fat, over-fed dogs. It is supposed that the thin-walled, valveless veins of the rectum are unable to stand the constant pressure of a blood column of some fourteen inches in height, which they are subjected to when the human frame is in the upright position.

Exciting causes are, overeating, rich food, lack of exercise, and sedentary occupations. Violent straining, as in lifting heavy weights, or straining at stool, may cause a hemorrhoidal condition of the veins of the anus, and thrombotic hemorrhoids are nearly always caused in this way.

Heart disease, kidney disease, and cirrhosis of the liver must be classed as exciting causes, but chronic constipation with the passage of solid fecal masses along the rectum, stripping the venous blood away from the heart, is one of the chief direct causes. Uterine diseases are reckoned as causative of piles. Certain it is that the two are frequently associated.

External Hemorrhoids.—There are two varieties of external hemorrhoids, (*a*) redundant folds of the skin about the anal opening, and (*b*) venous tumors. (*a*) The normal corrugations of the skin surrounding the anus may be exaggerated and little tabs of skin and connective tissue result. These may be of little significance; on the other hand, they are capable of being inflamed, or even suppurating and of leaving behind more or less induration. Constipation is the direct cause. The piles may cause itching and, when inflamed, smarting, rendering sitting uncomfortable. If there is suppuration, the symptoms are those of abscess. Examination shows retained secretion or fecal matter between the rugæ and the pile will be found to be red, glistening, and perhaps excoriated. (*b*) The superficial veins of the margin of the anus become dilated and the condition may involve the entire circumference of the anus. The veins belong to the inferior hemorrhoidal plexus. The swelling may be limited to one, two, or three circumscribed tumors. In any event the swelling is marked during straining efforts and almost completely subsides soon after, leaving the skin loose and redundant when the straining has ended. There is no induration

or excoriation. The chief complaint is difficulty in defecation and also a feeling of fullness at the anus. The patient feels that her bowels should be emptied, but she can not accomplish it even by persistent straining and there is much soreness lasting after stool. In the case of this sort of piles there may be acute attacks of spasm of the sphincter attended by great burning and itching, very commonly just after the patient has gone to bed at night, or after defecation.

The patient being on her side and relaxed, examination shows the skin of the anus loose and redundant and the sphincter tightly closed. If the piles are thrombosed there will be small, oval or round tumors, varying in size from a pea to a walnut, situated just beneath the skin, the color being that of the normal skin, or varying from red to dark blue. This is the sort of pile that causes sudden symptoms of sharp, cutting pain when the thrombosis occurs.

On straining, the anal orifice forms the apex of a cone-like prominence, and flatus or a little rectal mucus may escape. When the finger is passed through the anus, the sphincter grips it tightly and hinders its easy introduction. The sphincters are abnormally strong and the rectum is apt to be dilated and contain flatus, or even feces. Sometimes a chronic condition of this sort is productive of rectocele.

Internal piles may complicate the external piles and should be sought for.

Many physicians, as well as the laity, assume that all piles originate in the rectum and have come down, and therefore urge their patients to replace them. Of course, replacement should not be attempted unless the piles are internal.

External piles should be handled gently, it being a mistake to squeeze the thrombosed hemorrhoids with the object of forcing out the clot, for at any time the tumor may become infected and trauma will assist in gaining entrance for the germs.

Internal Hemorrhoids.—Internal piles consist of a varicose condition of the veins of the lowest two and a half inches of the rectum. Not all of this region is affected in most cases, and the lower part, the anal canal, is the place where internal hemorrhoids are most often found. The internal pile is apt to be pear-shaped, because the vein (a branch of the superior hemorrhoidal plexus) issuing

from it, passes upward in the submucous tissue and soon loses its varicosity, the lower end only being bulbous. Generally there are several of these venous tumors placed parallel to one another. On dissection, this variety of hemorrhoid consists of a mass of dilated veins and connective tissue. In thrombosed piles there is a blood clot and more connective tissue. Constipation and heredity seem to play the chief rôles in the causation.

The symptoms are hemorrhage and the protrusion of the pile through the anus.

The amount of blood lost may be slight and occur only at stool, or it may be excessive and come on at irregular periods. It is difficult to judge, from the description of the patient, how much blood is lost, and one must always remember that blood lost per anum is not necessarily from the rectum, but may come from the stomach, duodenum, or ileum. If from the latter situations it will be dark colored and tar-like in consistency, whereas if from the rectum it will be less dark; it may be arterial and more or less mixed with mucus or feces. Generally blood from internal hemorrhoids is passed after stool.

Protrusion of the hemorrhoid does not come on until after the tumor has existed a considerable time and has attained a large size. At first the pile recedes spontaneously, but as it gets down farther, the sphincter contracts firmly and prevents its return. In bad cases, rest in bed, with the hips elevated, may be necessary before reduction can be accomplished, but, as a rule, the pile can be pushed up after it has been anointed.

An excess of mucus is generally associated with internal hemorrhoids and there may be a sense of weight, or aching in the sacral region, or even pain in the anus, when the pile is prolapsed.

Examination shows edema of the skin about the anus in the form of one or more soft elastic folds; this swelling is more marked if the piles are strangulated and is due to the obstruction of the venous return. The patient is asked to strain, and if the piles are well developed they come into view as purplish tumors, the anus being below its natural position. The finger inserted into the rectum detects the hemorrhoids as elastic tumors, perhaps pedicled, and hard if thrombosed.

Hemorrhoids of the anterior wall of the rectum may be inspected by everting the wall of the rectum, in the case of women who have

had children, by pressure with a finger in the vagina. In virgins, the pelvic floor is too rigid to permit of this procedure. The sphincters are hypertrophied except in long-standing cases, when they do not appear to have the normal contractile power.

By the use of the short proctoscope, piles may be seen as bluish tumors projecting from the mucous membrane.

FISSURE IN ANO

Anal fissure, or irritable ulcer, signifies a superficial ulcer situated in one of the sulci between the folds of the mucosa of the anal canal. It is almost always single, it is pear-shaped or triangular in form, is always in the long axis of the canal, and varies in length from three-eighths to seven-eighths of an inch (9 millimeters to 2.1 centimeters). It is from a quarter of an inch (6 millimeters) to half an inch (1.2 centimeters) broad, the wider part being generally below and in the skin of the anus. At the lower limit of the fissure, or just to one side of it, there is sometimes a small fold of skin called "a sentinel pile."

Fissure is most often found on the posterior surface of the anal canal, although it may be on any side. In cases of long standing the ulceration may reach in depth to the sphincter muscle; as a rule it is superficial.

The disease occurs in all ages and conditions of life, but is chiefly found in adult life and especially in women during the childbearing period.

Constipation is the cause of fissure; hard, dry, scybalous masses tearing the delicate mucous membrane while being voided.

Symptoms.—The symptoms are pain, muscular spasm, and occasional loss of blood. The pain seems to be out of all proportion to the size of the lesion and is described as a burning, aching, and throbbing sensation just within the anus. It begins while the feces are being passed (it may be delayed for half an hour) and lasts from half an hour to six or eight hours, to return when the next motion of the bowels takes place. The patient is induced to put off defecation because of the discomfort and thus the fissure is aggravated. The spasm of the sphincter causes great pain and also interferes with defecation, besides diminishing the diameter of the fecal mass.

Diagnosis.—Inspection shows a fissure, when the buttocks are widely separated, and the skin of the anus is apt to be redundant and thrown into exaggerated folds in these cases. The external sphincter is palpated to detect abnormal thickening or induration, and when the patient is asked to strain down, the amount of spasm of the sphincter may be estimated, the straining causing pain in the fissure. Discharge from the fissure, small in amount and

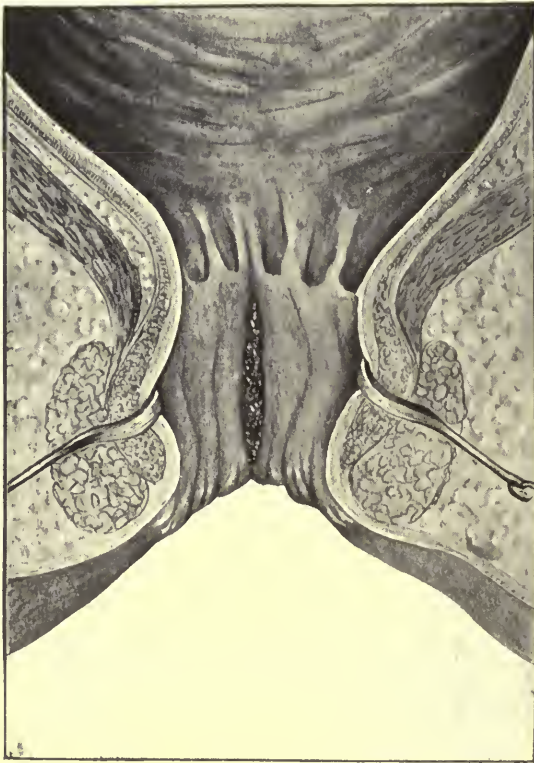


FIG. 194.—Fissure in Ano. (Tuttle.)

non-purulent, is to be looked for. Digital exploration of the rectum should be made, with an anesthetic if the pain is too severe, preparations being made at the same time to treat the suspected fissure, so that only one anesthetization may be necessary. The ulcer is felt as a roughened patch in the smooth mucosa of the anal canal.

If the situation of a fissure can be determined, the finger should

be pressed against the opposite wall to cause as little pain as possible. The spasmodic contraction of the sphincters and levatores ani is now apparent and feces are apt to be found in the rectum. The rectum should be cleared by enema and further examination made. The complications of anal fissure, such as polypi, piles, and blind internal fistula, are generally situated in the lowest part of the rectum. Unless the patient is anesthetized it is not wise to pass the proctoscope in the case of fissure, because of the great pain caused.

Differential Diagnosis.—Simple fissure must be differentiated from

Syphilitic Fissure.—The latter are generally multiple and are on the right or left of the anus, not in the middle line; they cause pain that begins during defecation but does not persist so long as in simple fissure and is apt to recur at night. The inguinal or the femoral lymphatic glands will be found to be enlarged individually, and there is a history of syphilis.

Blind internal fistula is attended by a history of continuous pain, which is accentuated by defecation but does not cease entirely. It is accompanied by a periodic discharge of pus, with the relief of pain, except during defecation. Pus can generally be seen issuing from the bowel in cases of blind internal fistula, and the finger introduced in the rectum will be found to be streaked with pus on its withdrawal, and instead of a roughened patch, as in fistula, the ball of the finger feels induration. Perhaps a depression can be felt and a bent probe can be passed into the fistula.

INFLAMMATION OF THE RECTUM—PROCTITIS

Inflammation of the rectum may be divided into

1. *Simple*, those inflammations of unknown bacterial origin, or
2. *Specific*, those inflammatory processes due to the bacteria of gonorrhoea, syphilis, tuberculosis, or dysentery.

An inflammation affecting the rectum generally involves the colon as well, because the two are similar structures anatomically and parts of one canal, therefore it is not always possible while considering proctitis to rule out colitis.

The absorptive power of the rectal mucosa is considerable, as

is attested by the rapidity with which fluids injected into the rectum are taken into the circulation. It is here that the fluid contents of the intestine are rendered semisolid or solid by the abstraction of their watery constituents, therefore it is not surprising that the bacteria from the feces, especially if the solid parts cause abrasions, should find lodgment in the walls.

As a matter of fact, the rectum, especially in its lower part, seems to be relatively immune to septic infection, just as in the case of the lips and mouth and the other openings of the body. The inflammatory process may be of mild grade, catarrhal proctitis, or it may progress to ulceration, ulcerative proctitis.

1. SIMPLE PROCTITIS

Simple catarrhal inflammation of the rectum is a common disease, especially in women who have uterine disease. It may be (a) acute, or (b) chronic.

(a) **Acute catarrhal proctitis** may be caused by pin-worms, impacted feces or foreign bodies, or by prolapse of the rectum. Other causes are: highly seasoned food; sitting on cold stone, wet seats, or the damp ground; irritating cathartics, such as jalap, aloes, gamboge, and podophyllin. Fermentation and putrefaction of the intestinal contents may be direct causes of acute proctitis.

Symptoms.—The symptoms are a sense of discomfort and fullness in the region of the rectum, with tenesmus, and the forcible ejection of fluid feces through an anus made small by irritation of the sphincter. There may be pain in the pelvis, radiating into the back and thighs. The patient has less discomfort while lying down than when erect and there may be slight fever.

Frequent desire for an evacuation of the bowels is a prominent symptom from the first, and defecation does not remove the desire, the straining even causing prolapse of the rectum sometimes in children.

The discharges are fluid and after the first twenty-four hours may be tinged with blood or pus. The process is confined to the mucosa, as a rule, in acute proctitis, though the inflammation may be so severe that portions of the mucous membrane are cast off and the deeper layers affected also. In the latter event, ulceration, abscess, fistula, or stricture may follow.

Examination shows great tenderness when an attempt is made to introduce the finger or speculum into the rectum and the sphincter is contracted. The mucous membrane feels hot, dry, and swollen in the very early stages, and later very moist. Through the proctoscope, at first, it is of a light red color throughout, or deep red in patches and lighter red elsewhere; later, the color is darker red and the surface is covered in places with opaque yellowish mucus. Slight trauma, even from wiping away the secretions, causes bleeding.

(b) **Chronic catarrhal proctitis** may follow acute catarrhal inflammation of the rectum, or, as far as we know, it may be chronic from the beginning. The latter is true of *atrophic catarrhal proctitis*, the most frequent type of catarrhal proctitis. *Hypertrophic catarrhal proctitis*, the other form, although generally chronic in course, may show an acute stage.

ATROPHIC PROCTITIS.—This consists of an atrophy of the mucous membrane and its glandular elements throughout the rectum. It is limited to the rectum; not, like the hypertrophic variety, affecting the colon also. The disease is found mostly in adult life and is probably due to sedentary occupation, the overeating of highly spiced food, chronic constipation, and the abuse of cathartics and enemata. The affection is not infrequently associated with syphilis, either acquired or hereditary. Sometimes it is associated with chronic pelvic inflammation. J. P. Tuttle has noted the association of this form of rectal catarrh with chronic catarrh of the nose, and C. B. Kelsey calls attention to the frequency with which gynecologists overlook this disease and the possibility, if an ulcerative stage has been reached, of its causing subsequent stricture of the rectum.

Pathological examination of the tissues of a rectum affected by *chronic atrophic proctitis* shows the mucosa to be granular, dry, inelastic, and adhering to it small masses of dry feces and perhaps shreds of exfoliated epithelium. Under the microscope the epithelium is found wanting in many places on the surface and there are granulations and ulcerated areas. The crypts of Lieberkühn are atrophied, the solitary follicles are enlarged and distended, and the connective tissue of the submucosa is increased in amount.

The symptoms are those of a mild irritation of the rectum. As the disease is apt to be complicated by fissure and hemorrhoids,

the symptoms are more directly caused by these affections. Long-continued constipation, with hard and lumpy stools and burning and discomfort in the rectum, may be the only symptoms, the latter being often mistaken for chronic disease of the ovaries or tubes. Pruritus ani is a common symptom.

Examination shows the skin of the anus relatively normal, and the mucous membrane of the rectum bright red and shiny, with small pieces of dry feces adhering to it in places. It does not bulge into the end of the proctoscope. To the examining finger, the mucosa feels dry and it sticks to the finger. In long-standing cases the rugæ seem to be obliterated and the valves of Houston stand out more prominently, while the ampulla is dilated. Erosion and ulceration are not uncommon. In such cases the stools may be smeared with blood or pus, and the eroded or ulcerated areas may be seen through the proctoscope.

HYPERTROPHIC PROCTITIS.—This is a chronic inflammation of the rectal mucous membrane, in which the mucosa and submucosa are thickened. The disease involves the colon as well as the rectum, being a part of an inflammatory process affecting the entire large intestine, and it generally follows an acute attack of proctitis or colitis. The affection is found most often in fat, flabby individuals who are the victims of chronic constipation, and occurs also in cases of chronic catarrhal appendicitis, uterine malpositions, abdominal tumors pressing on the intestine, and in movable kidneys, which slide up and down on the bowel.

Pathological examination of the rectal wall shows marked hypertrophy of all the elements of which it is composed, including the glands and the connective tissue of the mucosa and submucosa.

The symptoms are apt to be more general than local. Where the disease follows a well-marked acute attack, there will be a lessening in the severity of the symptoms. As chronic hypertrophic proctitis is a part of a colitis and a large area of intestine is involved, the symptoms are of more serious moment than is the case in atrophic proctitis. They are: diarrhea alternating with constipation, the stools being soft and mixed with pus, or hard and round, like sheep-droppings, and covered with muco-pus. Tenderness on pressure over the course of the colon in the abdomen, with swelling of the abdomen and griping pains, may be a feature of the case. In cases of a pronounced character, there may be tenesmus, occurring

periodically and accompanied by the discharge of a large quantity of thick glairy mucus or muco-pus. Mucus may escape involuntarily in these cases to such an extent that the patient is forced to wear a napkin. Pruritus is a common and a troublesome symptom. Constitutional symptoms are: flatulence, loss of appetite, coated tongue, yellow skin, offensive breath, and loss of weight and strength.

Examination shows redness of the skin and hypertrophy of the rugæ about the anus due to the irritation caused by abundant mucus coming from the anus. Dermatitis may exist in extreme cases, with much thickening of the skin. Condylomata acuminata, with their characteristic tree-like growth, are not uncommon in the skin about the anus.

By digital examination, the mucous membrane of the rectum feels doughy, and the cavity of the gut seems somewhat restricted; quite the opposite to the state of the case in atrophic proctitis.

Through the proctoscope, the flabby redundant mucosa bulges into the end of the proctoscope. It is pale red in color and covered with muco-pus. It does not bleed easily and neither ulceration, hemorrhoids, nor fissure is apt to complicate this form of proctitis, although prolapse may.

The following table shows the principal points in the differential diagnosis between the atrophic and the hypertrophic forms of proctitis:—

CHRONIC ATROPHIC PROCTITIS	CHRONIC HYPERTROPHIC PROCTITIS
1. Constipation is generally the rule.	1. Constipation alternating with diarrhea.
2. Secretions absent; peri-anal skin dry and relatively normal.	2. Secretions increased about the peri-anal region; acute dermatitis; moist eczema. Condylomata apt to be present.
3. Sphincters usually contracted and hypertrophied.	3. Sphincters generally relaxed.
4. Mucous membrane dry, stools adhesive, rectum readily distended and easy to examine.	4. Mucous membrane swollen and edematous, prolapses over the end of the proctoscope during examination.

CHRONIC HYPERTROPHIC
PROCTITIS
(continued)

5. Mucous membrane bleeds readily; light sponging produces considerable oozing.
6. Mucous membrane dry and of a bright red color.
7. Ulceration common.
8. Inflammatory process almost invariably confined to the rectum and sigmoid.
9. Hemorrhoids often present. Prolapse seldom seen.

CHRONIC ATROPHIC PROCTITIS
(continued)

5. Bleeding from the mucous membrane uncommon.
6. Mucous membrane moist and of a pale red or pinkish hue.
7. Ulceration rare.
8. Inflammatory process rarely limited to the rectum and sigmoid, the colon being involved as well.
9. Hemorrhoids an unusual complication. Prolapse more frequent.

2. SPECIFIC PROCTITIS

Gonorrheal Proctitis.—This disease is rarely diagnosed, though it probably is not so infrequent as formerly supposed by writers on venereal disease. It is undoubtedly more frequent in women than in men and is due to the extension of the disease from the vulva because of the introduction of the gonococcus on the finger or rectal tube, or it may be due to unnatural intercourse. The symptoms and anatomical appearances are those of simple proctitis and the diagnosis is made by the isolation of the gonococcus from the discharges.

Condylomata, fissure, and submucous fistula are found as complications.

Syphilis of the Rectum and Anus.—Syphilis manifests itself in the skin about the anus, in the anal canal, and in the rectum proper, in primary, secondary, and tertiary lesions. It may be congenital, or it may be acquired innocently, or by inoculation by unnatural coitus.

Congenital syphilis is almost always of the secondary type and occurs in young children, usually during the first two or three months of life. The lesions consist either of cracks in the skin about the anus, radiating from the anus, or smooth, flat, elevated

patches, from a quarter of an inch to half an inch in diameter, in the same situation. These lesions exude a very contagious discharge. The diagnosis is established by finding the *Spirochæta pallida* in the discharge or scrapings from the lesions, and in the appearance of syphilitic lesions elsewhere in the body.

As indicating the relative frequency of the different syphilitic lesions, the statistics of P. Sick, from the Hamburg General Hospital, may be quoted. Among 11,826 women and children treated there for venereal diseases, there were: mucous patches, 986; chancroids of the anus, 224; chancres of the anus, 12; strictures of the rectum, 10; rectal gunmata, 2; and anal gumma, 1.

Chancre, the initial lesion of syphilis, is not uncommonly found about the anus in women. Statistics have been published that go to show that among women who have syphilis chancre is found at the anus in about one in thirteen. The characteristics of the chancre in the skin about the anus are exactly the same as on the vulva. (See page 406.)

If the chancre is in the anal canal, or rectum proper, a rare occurrence, it is apt to escape detection. Digital and visual examination will detect a single, non-sensitive lesion, with an indurated base, and the individual glands in the groin will be found enlarged. Scrapings from the chancre will show the *Spirochæta pallida*.

Mucous Patches.—The anus is the most frequent seat of mucous patches next to the mouth and throat; they may begin on the vulva and spread to the anal regions. Mucous patches do not occur within the rectum, so far as known. They begin as a reddening of the skin between the folds of the buttocks, noticed sometimes before the initial lesion has healed; the chancre, in fact, merging into a mucous patch. As a rule the mucous patch is developed with the secondary lesions, at the same time as the macular eruption upon the skin of the rest of the body. The reddened area of skin is raised a little above the surrounding skin; the epithelium becomes macerated and is shed, leaving a shallow erosion. There is a scanty, thin discharge and there is no itching. Soon the surface of the erosion is covered by a grayish-white membrane slightly elevated above the surface of the skin. The patches vary in size and may be single, multiple, or coalescing, so that the entire circumference of the anus is involved.

When the papillæ of the mucous patches grow upward from the skin they may form flattened warty growths called *condylomata lata*, or vegetating mucous patches. They are accompanied by more or less discharge and are more commonly found in uncleanly syphilitics.

Ulcerations may result from the breaking down of mucous patches. *Syphilitic ulcerations within the rectum* are common. They present few symptoms and reach the chronic stage before they are recognized. They tend to spread, following the course of the blood-vessels and the lymphatics and are destructive in their tendencies, having been known to perforate the peritoneum. The lymphatic glands in the hollow of the sacrum become enlarged and may be palpated, but must not be mistaken for gummata.

When the ulcers cicatrize they leave behind them bluish-white, non-elastic tissue that forms a stricture.

Gummata.—Gummata of the anus are very rare and only a few cases of gumma of the rectum have been reported. The latter is described as a round, elastic, painless tumor, situated in the sub-mucous tissues. It is single or multiple and from the size of a pea to that of a small orange. The fact that a gumma does not suppurate, is not tender, and does not occur in chains, serves to distinguish it from enlarged lymphatic glands.

Syphilitic stricture of the rectum is considered under Stricture, page 519.

Chancroids of the Anus and Rectum.—This affection is rare in America, though not infrequent on the Continent abroad. The chaneroidal ulcer, being auto-inoculable, often extends from the vulva (see page 406), therefore we may regard chancroids of the anus as secondary in a vast majority of cases. Chancroids of the rectum are generally due to sodomy. The points of diagnosis and differential diagnosis of chancroids will be found in the chapter on diseases of the vulva, page 415. There is a form of chaneroid called phagedenic, characterized by an intense inflammatory process involving the deeper structures, with much destruction of tissue. This sort, if situated in the rectum, may cause stricture. It is rare, and occurs commonly in patients of debilitated constitution.

Chaneroids and chanere may coexist in the same patient, therefore the physician must be on the watch for the characteristic appearance of each lesion.

Tuberculosis of the Anus and Rectum.—Primary tuberculosis of the anus and rectum is extremely rare; the secondary affection, occurring in patients with advanced tuberculosis of the lungs or other organs, is not infrequent.

A *miliary variety of primary tuberculosis* in the skin about the anus has been described. In this form there are minute, shot-like bodies beneath the epidermis, that have developed in the sweat and oil glands of the skin. They are arranged in a crescentic or circular shape and soon break down to form shallow ulcers with ragged, indurated edges and giving forth a thin discharge of seropus.

An *ulcerative variety* is the common form in which tuberculosis is seen, both in the skin about the anus and inside the anal canal. The ulcerations are apt to involve both the anal margin and the mucous membrane inside the anal canal. They may be single, or on both sides of the anus; they are round or oval in shape, the borders are irregular in form, but undermined, and of a pale color, shading to the normal pink of the surrounding skin. There is induration around the ulcer, but the base is relatively soft, irregular in its surface, grayish in color, and the granulations do not bleed easily. Yellowish tubercles, the size of a millet seed, are scattered over its surface, and in the older parts of the base of the ulcer cheesy material may be found. The discharge is small in amount, sero-purulent, and mixed with blood.

These ulcerations are not especially painful: they do not tend to heal as they progress in all directions and do not, like other ulcers, assume the type of fissure when they invade the anal canal, but involve both the rugæ and the sulci.

Primary tuberculosis of the rectum proper is practically unknown, but the secondary type occurs. The ulcerations present the same appearance as in the anal canal, ulcerations here producing stricture as their late results.

The diagnosis is made by finding tubercle bacilli in scrapings made from the ulcer and by the characteristics of the ulcer itself.

Dysenteric Proctitis.—This is an inflammation of the rectum and sigmoid flexure of the colon occurring in sporadic dysentery, and caused by the ameba coli. In endemic and epidemic dysentery the entire colon and rectum are involved, but in this event the constitutional disease overshadows the affection of the rectum.

The inflammation of the rectum is generally of the catarrhal variety, but in chronic cases progresses to an ulcerative stage, the ulcerations being linear, punched-out, and like little grooves in the mucous membrane following the course of the blood-vessels. The purulent discharge is very profuse and the submucosa is destroyed to a greater extent than the mucosa, whence the undermined edges of the ulcers.

The symptoms of the acute stages of dysenteric proctitis are pain and heat in the pelvis and anal region, tenesmus, diarrhea, slight elevation of temperature, rapid pulse, and exhaustion. The diarrhea is attended by the frequent painful passage of, at first, partly solid and partly fluid stools, changing to watery stools and finally mucus, tinged with blood and pus. There is burning after stool and the frequency of defecation is very great. In the chronic stages the frequency is not so great and the symptoms are those of ulceration. The ulcers have the characteristic appearances of worm-tracks in wood, following the course of the blood-vessels. They sometimes result in stricture.

ABSCESS AND FISTULA IN ANO

Abscess.—The tissues immediately surrounding the anus and rectum are especially subject to infection and inflammation, because of the abundant lymphatic and blood supply of the parts, from the ample source of bacteria in the retained contents of the intestine, and from the obstruction to the circulation caused by hardened fecal masses.

The bacteria most frequently found in abscesses about the rectum are the tubercle bacillus, and bacterium coli communis, generally associated with staphylococcus or streptococcus.

The course of the abscesses is acute or chronic, only the deeper ones, the superior pelvi-rectal abscesses, being of severe grade and immediately dangerous to life. Abscesses in this region burrow in the path of least resistance, passing between the fascial planes and around the blood-vessels which are large enough and vigorous enough to resist thrombosis and gangrene.

Superficial abscesses, of the nature of acne pustules or furuncles, open on the skin; subcutaneous abscesses and deeper seated

suppurations, generally, besides opening through the skin, make their way between the internal and external sphincters, perforate the mucous membrane, and discharge into the anal canal, forming, in a large majority of cases, a fistula.

Those that enter the bowel alone form blind, internal fistulæ, while those that open both on the skin and into the gut are complete fistulæ.

The different sorts of abscesses in this region as enumerated by Goodsall and Miles ("Diseases of the Rectum," Part I.) are:—(a) subcutaneous, (b) ischio-rectal, (c) submucous, (d) pelvi-rectal,

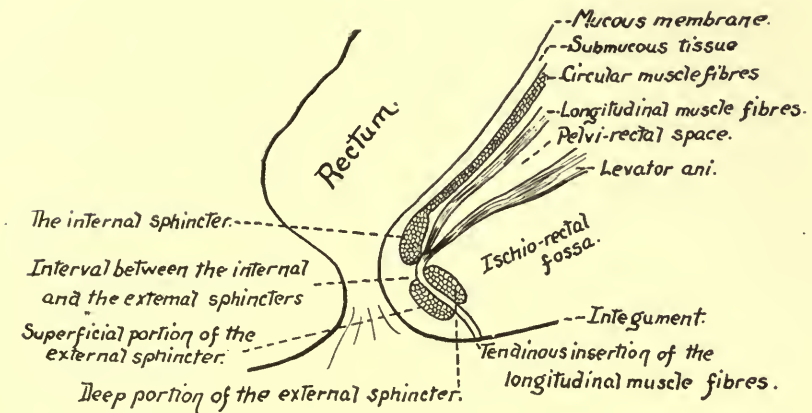


FIG. 195.—Diagrammatic Representation of the Lower part of the Rectum and its Immediate Surroundings. (After Goodsall and Miles.)

(e) labial. As has been said, the (b) *ischio-rectal abscess* opens not only on the skin, but also between the sphincters into the bowel.

The (c) *submucous abscess* originates in the submucous tissue, usually in the lowest three inches of the rectum, and is generally confined to one side of the bowel. It shows a tendency to burrow downward and to empty near the anus. The (d) *pelvi-rectal abscess* begins in the loose connective tissue between the levatores ani below, and the reflection of the peritoneum above. This space being continuous with the bases of the broad ligaments, septic inflammatory processes starting in these structures may spread to the pelvi-rectal space. Infection may come from the rectum, from malignant disease of the bowel, or ulcerations high up. Rarely, in the acute form of this disease, the pus may rupture through the

peritoneum into the abdominal cavity; in the chronic forms it is more apt to perforate the levators and form an ischio-rectal abscess. This sort of abscess is the cause of deep *horseshoe fistula*. The disease is generally attended by extensive cellulitis. (e) *Labial abscess* is an extension backward to the anal region of a vulvo-vaginal abscess. This is a rare sort of abscess.

The symptoms of abscess are pain in the rectum, with aching and throbbing especially on defecation, tenderness in the region of the anus, and constitutional symptoms in the acute stages. Examination shows great heat, tenderness, and induration of the tissues, with fluctuation at the seat of the abscess. The exact situation is determined almost entirely by palpation and the physician will search for the different sorts of abscesses according to the descriptions just given.

Fistula.—The word fistula is derived from the Latin fistula, something capable of being split, a hollow reed or pipe. Fistula in ano may be defined as an unobliterated abscess track which opens either in the skin near the anus, or into the rectum, or both. Fistula is comparatively rare in women, the average age at which it occurs being thirty-six years. It may be caused by a fissure, by ulceration of the bowel, by stricture, by polypoid growths, or by carcinoma.

As implied by the definition, an abscess always precedes a fistula, except in the very rare cases of fistula caused by traumatism. A fistula generally opens by one orifice in the bowel, but by several in the skin.

VARIETIES.—There are three sorts of fistulae, although all three may be combined in the same patient. They are (1) *complete*, when there is an opening through the skin and also an opening into the bowel, and (2) *incomplete*, including (a), blind external, when there is an opening into the skin alone, and (b), blind internal, when the only opening is into the rectum.

1. In the *complete fistula* the main track generally passes between the two sphincters into the rectum, but it may be subcutaneous throughout, and not go round the external sphincter.

From the main track branches go off to end in blind passages or to perforate the skin. Rarely the main sinus, after burrowing between the sphincters toward the mucous membrane of the rectum, may ascend above the internal sphincter before perforating into the

rectum, but as a rule the internal opening is in the anal canal between the sphincters. Complete fistulæ form about seventy per cent of all fistulæ.

2. Of *incomplete fistulæ* (a), the *blind external fistula* is an abscess

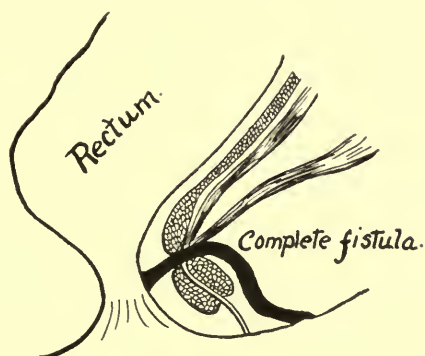


FIG. 196.—Diagram of Complete Fistula in Ano.

cavity having an opening in the skin, near the anus. The track may represent a previous existing complete fistula the internal opening of which has closed. In the case of (b), the *blind internal fistula*, there are three courses taken by the abscess track to its opening into the bowel: it may be subcutaneous and pass outside

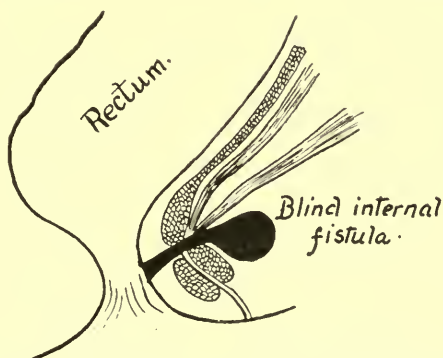


FIG. 196a.—Diagram of Blind Internal Fistula.

the external sphincter into the anus; it may be submuscular, passing through the external sphincter, or between the internal and the external sphincters; or it may be submucous, coursing entirely in the submucous tissue. The last form is often due to a preëxisting

fissure, is apt to be higher in the rectum than the others, and may be felt by a finger in the rectum as a cord, running in the rectal wall.

Goodsall and Miles have observed that fistulæ which have started posterior to a transverse line drawn through the anus, burrow more extensively than those that have started in front of this line.

SYMPTOMS OF FISTULA.—The symptoms of fistula are pus from the bowel, together with the history of a preëxisting abscess, or fissure, or other rectal disease. Flatus may escape from a complete fistula and also liquid feces and gas may distend a blind fistula so that it is painful. If the swelling due to inflation is of considerable size it is possible to obtain tympany on percussion. The pain of fistula is inconsiderable and bleeding is only an occasional symptom.

PHYSICAL EXAMINATION.—Examination will reveal the presence of an external or an internal opening, or both; the course and ramifications of the track of the fistula, and the presence, or absence, of complicating diseases.

If the abscess preceding the fistula has been opened, the opening in the skin is apt to be smaller than when the abscess has opened spontaneously. All the openings should be investigated thoroughly with a probe. The internal opening is found by proctoscopy and by passing a probe into it through the proctoscope. Palpation and the passage of the probe are the main reliances of diagnosis. Internal piles are the commonest local complication of fistulæ; fissure, ulcer, stricture, polypi, or carcinoma may also coexist.

If there is suspicion that a fistula is tuberculous, serapings of tissue should be examined for the tubercle bacillus rather than rely on evidences of tuberculosis elsewhere in the body. A tuberculous fistula has generally a discharge that is small in quantity and thin and white, and the fistula is surrounded by much induration.

STRICTURE OF THE RECTUM

Strictures of the rectum may be classified, according to their causation, as congenital, as due to pressure on the rectum from without, or as inflammatory. Obstruction of the lumen of the rectum by new growths of the rectum or by foreign bodies in the gut may be disregarded in a discussion of stricture, as may the

so-called *spasmodic stricture*, which was formerly thought to be very prevalent, but is now regarded by writers on diseases of the rectum as a rare curiosity and a temporary condition. Strictures may be further classified, according to their form, as annular, or as tubular.

Congenital strictures are generally found in the anal canal, either at the margin of the anus or just below the level of the internal sphincter. The condition of stricture is apt to be regarded as simple constipation and the patient does not consult the physician until puberty or after. There is no history of an inflammatory or ulcerative process of the rectum and a careful sifting of the evidence shows only a gradually increasing constipation. The stricture may consist of a band, or of a circular membrane with an opening in the center, being entirely distinct from the sphincter muscle, which may, or may not, be hypertrophied. Congenital hypertrophy of Houston's valves may constitute a virtual stricture.

Strictures due to pressure on the rectum from without are relatively common in women, as in the retroversion of an enlarged or gravid uterus, or a tumor wedged in the pelvis, or a pelvic inflammatory exudate. The rectum is surprisingly tolerant of interference of this sort and, beyond a constipation and a mild proctitis, there may be no evidences that the caliber of the bowel is very nearly shut off. As a rule the symptoms due to the encroaching body overshadow those due to obstruction of the rectum.

Inflammatory Strictures.—These constitute a majority of all strictures and are due to tuberculous ulceration, to syphilitic ulceration, and to ulceration of unknown origin. Most of them are situated not higher than two and a half inches (6 centimeters) from the margin of the anus. Occasionally a stricture of this sort is found as high as three and a half inches (9 centimeters) up the bowel.

Pathology of Inflammatory Strictures.—Ulceration of the mucous membrane is the macroscopic appearance in the early stages of inflammatory stricture. When the ulceration has healed there is a lack of elasticity of the rectal wall and it has a dry, leathery feel and a dull, non-shining appearance. Often the ulcerative process continues after the stricture has been formed, and in this case the rectum contains muco-purulent discharge. If cicatrization has taken place, the cicatrix appears as a bluish-white, dense, ligamentous structure. The ulcer is of the type of infection causing it;

that is, syphilitic, tuberculous, or simple. Syphilitic ulceration is apt to heal below, while, at the same time, it extends upward. Gummata may be found in the course of the arteries and veins, together with endarteritis. In the tuberculous stricture, the entire epithelial surface of the mucous membrane is destroyed and caseous nodules are found in the tissues of the submucosa.

Symptoms of Inflammatory Strictures.—The symptoms of stricture during the ulcerative stage are dull, constant pain in the region of the rectum, diarrhea, tenesmus, and the discharge of mucus, pus, and blood; during the obstructive stage they are, increased frequency in a desire for an action of the bowels, the passing of small quantities of feces with incomplete relief, and, after an interval of a few minutes, the repetition of the desire for defecation. As the stricture becomes smaller in caliber the feces are passed in small-sized, round, or flattened pieces, and, if ulceration is still present, pus or blood may streak the stools.

In the case of strictures of long standing the large intestine becomes chronically distended because of insufficient emptying, and, as a result, the abdomen is distended. The patient complains of distention and of flatulence, more particularly during the first two hours after taking food. Another symptom in these cases is swelling of the feet and legs, particularly on the left side, and, in extreme cases, emaciation, with cachexia from autointoxication, result.

Physical Examination.—Physical examination shows the anus to be normal in appearance, except that there may be present several folds of redundant skin, or scars, if the patient has suffered with complicating fistula. If the stricture happens to be at the anal orifice, the natural rugæ are absent and there is no redundancy, while cicatricial tissue takes the place of some of the skin at the anal margin. Straining on the part of the patient produces bulging, but no relaxation of the anus, and the finger feels a rigid ring about the opening. In the case of stricture within the rectum, the finger introduced into the rectum notes deficient contractile power of both sphincter muscles. The stricture, as has been said, is generally in the lowest two and a half inches of the gut. If the finger tip will pass through the stricture, the caliber and the shape and length of the stricture may be estimated; if not, the finger in the vagina will estimate the length of the inflammatory or cicatricial

mass. The short proctoscope passed through the anus permits a view of the stricture, and its size and length may be determined by passing through it olive-pointed bougies. Sometimes a smaller proctoscope, or a large Kelly cystoscope, may be passed through the stricture and a view of the rectum beyond the stricture thus obtained. The presence of much thickening about the rectum, with the escape of pus on digital examination, generally indicates the coexistence of an ischio-rectal or pelvi-rectal abscess.

In making the diagnosis, the history should be inquired into minutely and search made for the stigmata of syphilis or tuberculosis, the two most common causes of stricture.

PROLAPSE OF THE RECTUM

By prolapse of the rectum is meant the eversion of a part or the whole of the rectum through the anal orifice. It is *partial* when the mucous membrane alone is everted, and *complete* when all the coats of the rectum are involved. The disease is found most frequently in young children and in old women, especially in the women who have suffered from weakening of the sphincter ani muscle from childbearing. Laxity of the connections of the mucosa with its underlying structures and weakening of the tone of the sphincter muscle are predisposing causes. Exciting causes are obstinate constipation and chronic diarrhea, causing prolonged and repeated straining at stool, also extruded rectal polypi, or other rectal tumors, causing overstretching and relaxation of the sphincters.

Symptoms.—The symptoms are (*a*) loss of control over the bowels with the involuntary escape of rectal mucus as well as flatus and feces; (*b*) protrusion of the bowel, at first at stool only, followed by spontaneous reposition, then protrusion on coughing, or any sort of straining, and, finally, permanent prolapse unless reduced manually; (*c*) increased frequency in the action of the bowels; (*d*) pain of moderate or small amount as a result of long-continued irritation—pain is of an aching or throbbing character and persists as long as the part is protruded; (*e*) hemorrhage when the prolapsed mucous membrane is excoriated or ulcerated, not of large amount in any case.

Physical Examination.—The prolapse may involve the entire circumference of the rectum or only a part of it. There is no redundant skin about the anus in these cases and palpation determines that the mucosa moves freely on the muscular coat: the sphincters are relaxed and deficient in contractile power. The determination of the thickness of the wall of the prolapsed mass shows whether only the mucous membrane or the entire rectal wall is down. If the mucosa alone is extruded—*incomplete prolapse*—the mass is seldom more than two inches long, and one side is generally longer than the other. In *complete prolapse* the protrusion is generally equal on all sides and the mass measures some three or four inches in length. In *incomplete prolapse*, the opening into the lumen of the gut is circular, or oval, and centrally situated, whereas in *complete prolapse* the opening is slit-like and points backward because of the traction of the meso-rectum. In *incomplete prolapse* these are generally sulci anteriorly and posteriorly and the mucous membrane is smooth, whereas in *complete prolapse* there are no sulci and the mucous membrane is marked by several concentric furrows.

NEW GROWTHS OF THE RECTUM

New growths of the rectum are:—(1) benign, or (2) malignant.

1. BENIGN TUMORS OF THE RECTUM AND ANUS

Benign tumors are of infrequent occurrence, are of slow growth, they do not infiltrate the surrounding structures, and, when removed, do not show a tendency to recur. They may be divided into: (a) tumors about the anus, and (b) tumors of the rectum.

a. *Benign Tumors about the Anus*

These are papilloma, soft fibroma, and lipoma. They arise from the skin and subcutaneous tissue.

Papilloma.—Papilloma is due to hypertrophy of the papillary layer of the true skin. It occurs in young adults and appears to be due to want of cleanliness. The tumor consists of an enlarged papilla in the form of a bulb-shaped tumor about half an inch or three-quarters of an inch long, at the margin of the anus. Several tumors

are generally present in the same case and the pedicle of each is separated from its fellow by a strip of normal skin. Each tumor is made up of a central artery and vein in a connective-tissue stroma, which is covered by stratified epithelium. The surface of the papilloma is the same color as the surrounding skin, though it may become eroded and ulcerated. These simple tumors must be differentiated from carcinoma. In the latter there is no normal skin between the different parts of the tumor, and there is much infiltration of the surrounding skin and subcutaneous tissues. Condylomata lata have the appearances described on page 512 and condylomata acuminata those to be found on page 407. Hemorrhoids are of a deep purple color, and are soft and compressible, or, if thrombosed, very hard.

Soft Fibroma.—Soft fibroma is a pedunculated tumor of rare occurrence arising from the connective tissue of the submucosa. It contains besides connective tissue, muscular and glandular tissue, and is similar in structure to molluscum fibrosum. The tumor may attain great size and may weigh as much as a pound or more.

Lipoma.—Lipoma is a fatty tumor caused by hypertrophy of one or more lobules of fat. It is situated under the skin surrounding the anus, is soft, and is freely movable, in this respect being distinguishable from an inflammatory exudate or abscess. Occasionally a lipoma is pedunculated.

b. Benign Tumors of the Rectum—Polypi

These tumors originating in the rectum are generally pedunculated growths and therefore are classed as polypi. They are of the following pathological varieties: adenoma, fibroma, myoma, villous tumor, myxoma, and lipoma.

Adenoma.—Adenoma or *mucous polyp* is the most common form and is met with almost entirely in children under ten years of age. It consists of a hypertrophy of the crypts of Lieberkühn, and shows on section the tubules lined with columnar epithelium and surrounded by areolar tissue. If the connective-tissue elements predominate the tumor becomes a fibro-adenoma. Lymphoid tissue may form the basis of a tumor of this sort, due to hypertrophy of one of the solitary follicles of the rectum, and in this case the tumor is a *lymphadenoma*.

Glandular polypi are usually single, vary in size from a quarter of an inch to one inch in diameter, are round, and attached to the rectal wall by a long and slender pedicle. They generally arise in the lowest two inches of the rectum and may exist for a long time before the pedicle becomes enough elongated so that the tumor is passed through the anus at defecation. When it is, the diagnosis may be made. The probability is that many of these growths are torn from their pedicles and extruded during a movement of the bowels. The symptoms are hemorrhage from the anus after the growth has gotten within the grasp of the sphincters, and straining. The passage of blood from the rectum, in children, should always lead the physician to make a rectal examination. The examining finger is swept around the rectum and search made for the pedicle of the tumor. A view of the rectum and the tumor may be obtained through a Kelly proctoscope, No. 12. To make an accurate diagnosis an anesthetic will generally be necessary.

Fibroma or Fibrous Polyp.—A fibrous polyp is generally situated in the lowest two inches of the rectum; it is from a quarter of an inch to an inch in diameter, and is attached to the rectal wall by a short, thick pedicle. It occurs in adults and is usually single. It is made up of fibrous tissue and is covered with stratified epithelium when it springs from the anal canal, but has a complete mucous membrane over its surface if it originates higher up in the rectum. The tumor originates from the submucous connective tissue, a thrombosed internal pile, or from the nodules on the free edges of the valves of Morgagni, and is at first sessile.

There may be no symptoms until the growth becomes pedunculated, and then there will be rectal irritation or loss of blood. Digital examination will detect the polyp and its situation. If the pedicle has been torn by the violent action of the sphincter, there may be so much pain that an anesthetic may be necessary before a satisfactory diagnosis can be made.

Myomatous Polyp.—Myomatous polyp, a very rare sort of tumor, has the same characteristics as fibrous polyp, except that the tumor is made up of muscular tissue in excess of fibrous tissue.

Villous Tumor.—This rare sort of tumor in the rectum is described by Allingham ("Diseases of the Rectum") as "a lobulated, spongy mass, with long, villus-like groups studding its surface." Goodsall and Miles had collected thirty-five cases of villous tumors,

twelve in their own experience. The tumors appear to originate entirely from the mucous membrane of the upper rectum in patients who are beyond middle life. The growth is at first sessile and as it increases in size becomes pedunculated, the pedicle being band-like or poorly developed. If it is well developed the tumor has the appearance of being slung to the rectal wall as by a mesentery, attached obliquely. These tumors do not infiltrate the rectal wall, but may be the seat of carcinomatous degeneration. The symptoms consist of the escape from the anus of a thin, watery fluid. The frequent defecation caused by the tumor is described as diarrhea. There may be present dull pains in the region of the rectum and hemorrhage, also constipation alternating with diarrhea, and cachexia from loss of blood. The growth itself does not appear to bleed unless it is prolapsed through the anus. Internal piles are apt to complicate the disease. Anesthesia and the rectal speculum will be necessary in order to map out the situation, size, and character of the pedicle of a villous growth.

Myxomatous Polyp.—Myxomatous polyp is very rare in the rectum. A tumor made up of a combination of fibrous tissue and mucoid tissue, a *fibro myxoma*, is occasionally seen. Here, there are loose areolar-tissue spaces filled with a thick viscid fluid. The diagnosis is made as in the other forms of benign rectal tumors. There are no characteristic symptoms beyond an increasing difficulty in emptying the bowel satisfactorily.

2. MALIGNANT TUMORS

Malignant tumors of the rectum are cancer and sarcoma, the former being frequent, and the latter rare.

Cancer of the Rectum

Cancer of the rectum forms about five per cent of cancers of all parts of the body (combined statistics of 45,906 cancers by Heimann, Zeman, Krönlein, and De Bovis, "Diseases of the Rectum," J. P. Tuttle) and about fifty per cent of all cancers of the intestine (same statistics). The disease is more frequent in men than in women and is found most often between the forty-fifth and fifty-fifth years in both sexes, although it may occur at any age. The etiology is entirely unknown, except that it is found

more often in patients who have suffered previously with hemorrhoids, ulceration, or benign tumors of the rectum.

The most frequent situation of the disease is the upper rectum between the sigmoid flexure of the colon and the internal sphincter. The lower down in the rectum the disease is situated the greater the discomfort to the patient and the greater the likelihood, therefore, of an early diagnosis.

Cancer of the Anus

Cancer of the anus is infrequent. It may originate in the skin about the anus, in this case being a squamous-celled carcinoma, or in the anal canal with downward extension, an adeno-carcinoma. Squamous-celled carcinoma is rare and is most often met with in women over fifty years of age. An ulcer having an indurated base, bleeding easily, and extending into the margin of the anus is the appearance generally seen.

The lymphatic glands in the groin are the ones that are enlarged in cases of cancer about the anus. A piece of the ulcer and its base should be removed for microscopic examination.

Pathology and Course.—Pathologically, cancer of the rectum belongs to the class of adeno-carcinomata, the disease showing an atypical growth of glandular elements. If the connective-tissue elements predominate and the stroma is large in amount and dense, the tumor is called *scirrhus*; if, on the contrary, the glandular elements predominate and the tumor is soft in consistency it is called *medullary*. Colloid degeneration may affect the growth; then it is known as *colloid* cancer.

In the early stages adeno-carcinoma of the rectum is a sessile, rounded tumor, flattened on top, situated in the mucous and sub-mucous tissues and freely movable. As the tumor increases in size the cancerous outgrowths invade the muscular wall below, and the mucous membrane above, so that within a few months the tumor is ulcerated on top, fixed in the rectal wall, and of irregular outline. This is the condition usually found when cancer of the rectum in an early stage is first seen by the physician, although the less fully developed growth is occasionally detected during a routine examination.

Involvement of the lymphatic glands in the hollow of the sacrum appears to be a relatively early event.

The cancerous ulcer is excavated, with irregular, everted, and indurated edges, lying on a base that is of a porky hardness. When it has extended nearly round the circumference of the bowel stricture occurs, and by this time infiltration of the tissues surrounding the rectum takes place and the rectum is fixed. The ulceration may open into the vagina, bladder, or peritoneum in the late stages of the disease, and at this time the abdominal lymph glands are affected, and metastatic deposits occur in the liver and other organs.

Symptoms.—Goodsall and Miles have analyzed with great care the histories of their cases of cancer of the rectum, with a view to detecting any symptoms, however slight, that may excite the attention of the physician and suggest a probable diagnosis of this dreadful disease. The patient's condition is so uniformly hopeless in the later stages that any facts that may lead to early diagnosis must be sought with painstaking assiduity.

In the earliest stages before ulceration has taken place, the patient is apt to complain of a well-marked attack of constipation, having previously had regular movements without the use of laxatives; also there may be slight loss of weight, and after the attack of constipation is over there is frequency in the action of the bowels excited especially by the ingestion of hot fluids. The bowels at this time may act four or five times during the day and not at all at night. Goodsall and Miles insist that such a train of symptoms, occurring in women who have passed forty years of age, should lead to a thorough rectal examination, and I can not but agree with them, for any tyro can make a diagnosis in the advanced stages when it is too late for treatment to be of avail, and the patient's only hope lies in early detection.

When the ulcerative stage has been reached the symptoms are, increased frequency of defecation with difficulty of procuring a satisfactory evacuation of the rectum, the appearance of blood and mucus in the stools, pain in the rectum from constant straining, and progressive loss of weight.

In the later stages, when the rectum has become fixed, the symptoms are, the escape of blood, mucus, and pus without feces, deep-seated pain in the pelvis, over the sacrum, and extending down the thighs, and general cachexia.

If there is stricture nearly occluding the lumen of the rectum

the symptoms are, obstinate constipation alternating with diarrhea, intermittent hemorrhage, pain in the rectum and also in the abdomen, abdominal distention, emaciation, vomiting, and obstruction. The odor of cancer in the later stages is characteristic.

Diagnosis.—The diagnosis is founded on the symptoms and on the physical examination. The latter shows the anus relaxed, patulous, and darker than the surrounding skin, probably caused by obstruction to the venous circulation and constant straining. The usual situation of the disease has been referred to; the anal canal will be found free from disease. With the aid of the finger and the proctoscope an accurate conception must be obtained of the situation, size, color, consistency, and shape of the lesion.

The growth bleeds easily on the slightest touch, therefore digital examination will be followed by hemorrhage.

Palpation of the glands in the hollow of the sacrum is practiced by turning the right forefinger with its palmar surface toward the sacrum and feeling on both sides of the rectum for enlarged glands in that situation. The inguinal glands should be investigated also, especially if the disease is situated near the anus, and in late stages of the disease secondary deposits in the liver or other organs should be sought for.

Differential Diagnosis.—The following conditions must be excluded:—Tuberculous ulceration, extensive inflammatory exudate about a blind internal fistula, polypi, villous tumor, simple stricture, and gumma.

Tuberculous ulceration in the rectum is rare. It is attended by no distinct tumor, the ulceration does not bleed easily, its base is relatively soft, and its edges are not indurated. Tubercles and cheesy matter appear in the granulations of the floor of a tuberculous ulceration and the surrounding induration is less in amount than in cancer. The microscope will show the presence of the tubercle bacilli.

Extensive inflammatory exudate about a blind internal fistula will present the mucous membrane covering the induration intact, except where the fistula opens; the tumor is smooth in outline, there is a history of the discharge of pus, and digital examination produces a sudden gush of pus accompanied by a diminution in

the size of the swelling. Treatment of the fistula is followed by relief of the symptoms.

Polypi.—Adenomatous or mucous polypi occur almost exclusively in children under ten years of age. The surface of the growth is soft, it is seldom of great size, and is protruded at stool. The other sorts of polypi are discrete rounded tumors without induration surrounding them.

Villous tumor has a broad obliquely attached pedicle, it is soft and velvety to the feel, and is lobulated. It may cause as many as twelve actions of the bowels in twenty-four hours and it rarely bleeds unless prolapsed.

Simple stricture has a firm, even margin. It may be situated at the apex of an invagination of the rectum. There is absence of irregularity and induration of the tissues surrounding the stricture. The bleeding that follows a digital examination is always slight in amount and there is a purulent discharge.

Gumma of the rectum is very rare. There is a history of syphilis. The growth is round and smooth and elastic, and the mucous membrane over it is healthy. A gumma may become softened and fluctuate. Iodide of potash given by the mouth will cause a diminution in the size of the gumma.

Sarcoma of the Rectum

Sarcoma of the rectum is a disease of later life and occurs in growths of three pathological varieties:—spindle-cell, small round-cell, and giant-cell, any one of which may take on a melanotic change, converting the tumor into a melanotic sarcoma.

The tumors are single or multiple, they vary in size from half an inch in diameter to the size of an orange, and they are situated generally in the lowest two inches of the rectum. To the touch they are round, of irregular surface, and relatively hard in consistency, being especially dense in the case of the fibro-sarcomata. They appear of the color of the normal mucous membrane, but may be of a dark red or grayish color, or, in the melanotic kind, black. If there is more than one tumor the different tumors may not be alike in color.

Sarcomas of the rectum grow much more rapidly than do carcinomas, the lymphatic glands being involved relatively early. Metastases occur early also.

The symptoms of sarcoma are not characteristic. The disintegrating tissues have no characteristic odor. The attachment of a sarcoma to the wall of the rectum does not spread out like carcinoma, it is abrupt and clearly defined, and only in the late stages does it infiltrate the walls extensively.

Any rapid growing tumor of the rectum should be removed at once, and the microscope will make the diagnosis.

CHAPTER XXVII

THE DIAGNOSIS OF DISEASES OF THE BREAST

Anatomy, p. 532.

Age changes, p. 534: The infantile breast, p. 534. The breast at puberty, p. 535. Lactation hypertrophy, p. 535. The senile breast, p. 536.

Classification of diseases of the breast, p. 536.

Anomalies, p. 538: Complete absence of the breast, p. 538. Incomplete development of the breast, p. 538. Supernumerary mammae, p. 538.

Symptomatic lesions, p. 539. Pain, areas of induration, phantom tumors, p. 539.

Hypertrophies, p. 539: Infantile hypertrophy, p. 539. Galactocele, p. 539. Diffuse bilateral hypertrophy, p. 540. Senile parenchymatous hypertrophy, p. 540.

Inflammations, p. 542: Mastitis, p. 542; Acute mastitis, p. 542; Mammary abscess, p. 542; Submammary abscess, p. 542. Chronic mastitis, p. 543; Chronic interstitial mastitis, p. 543; Diffuse mastitis, p. 543; Lobular mastitis, p. 542; Tuberculous mastitis, p. 543; Actinomycotic and syphilitic mastitis, p. 544.

Benign tumors, p. 544: Fibro-epithelial tumors, p. 544. Epithelial tumors, p. 545.

Malignant tumors, p. 545: Carcinoma, p. 545; Adenocarcinoma, p. 546; Comedo, p. 546; Colloid, p. 546; Cystic, p. 546; Intra-cystic papillomatous varieties, p. 546; Medullary carcinoma, p. 546; Scirrhus carcinoma, p. 548; Cancer cysts, p. 548; Paget's disease of the nipple, p. 548, Sarcoma, p. 549.

Diagnosis of tumors of the breast in general, p. 549: History, p. 550. Age, p. 550. Duration of the tumor, p. 551. Situation of the tumor, p. 551. Mobility of the tumor, p. 552. Inspection and palpation, p. 552. Dimpling of the skin, p. 552. Retraction of the nipple, p. 553. Enlarged glands in the axilla, p. 553. Late signs of cancer, p. 553; Discharge from the nipple, p. 553; Ulceration of the skin, p. 553; Skin metastases, p. 553; Metastases in other organs, p. 553; Enlarged supraclavicular glands, p. 554; Cachexia, p. 554; Inadvisability of making exploratory incisions, p. 554.

ALTHOUGH diseases of the breast are commonly regarded as in the province of the surgeon, the breasts are distinctly a part of woman's reproductive apparatus and in intimate relationship through the nervous system with the uterus, as attested by the uterine contractions induced by suckling, by the development of the breasts and their functions coincident with the growth of the uterine organs, even under abnormal conditions, by the sexual

feelings caused by manipulation of the breasts, and finally, by the swelling and pain in the breasts associated with menstruation in the case of uterine disease; therefore we shall discuss here the diagnosis of the diseases of the mammae.

ANATOMY

The breasts consist of racemose glandular structures situated beneath the skin one on each side of the sternum. Each gland appears as a hemisphere projecting from the front of the thorax under the skin and covering a portion of the pectoralis major and a smaller portion of the serratus magnus muscles. The breast extends from the level of the second rib above to the level of the sixth rib below, and laterally from the margin of the sternum to the axillary line. The various lobes and lobules of which the gland is composed radiate from the nipple and extend to unequal distances in different parts of the breast, sometimes forming a prolongation of the gland tissue into the axilla, over the serratus magnus muscle, or toward the sternum. In the rare event of the occurrence of supernumerary mammae the glands are found on a line drawn from the anterior margin of the axilla downward through the nipple over the flank, the so-called "*milk line.*" (See Fig. 200.)

The nipple, cylindrical in shape and about half an inch in diameter, projects about half an inch from a point a little below and to the median side of the summit of the hemisphere. Its top is made rough by fissures and in the center is a depression in which are the openings of the milk ducts.

Surrounding the nipple is the areola, a circle of pigmented, wrinkled skin, in which are sweat glands and from a dozen to twenty little elevations formed by the sebaceous glands.

The mammary gland rests loosely upon the pectoral fascia, so loosely that the entire breast is freely movable. A sagittal section of the mamma shows it to be made up of gland tissue, all the ducts of which converge at the nipple; of fat, fibrous tissue, and skin. The gland tissue is firm in texture and of a pale reddish color. There are from fifteen to twenty excretory ducts, each one coming from a lobe, every duct having a spindle-shaped dilatation

as a reservoir for milk just before it emerges from the apex of the lobe into the nipple.

The lymphatic glands of the axilla receive the greater number of the lymphatic vessels of the breast and are disposed in three groups: the pectoral, at the outer margin of the pectoralis muscle;

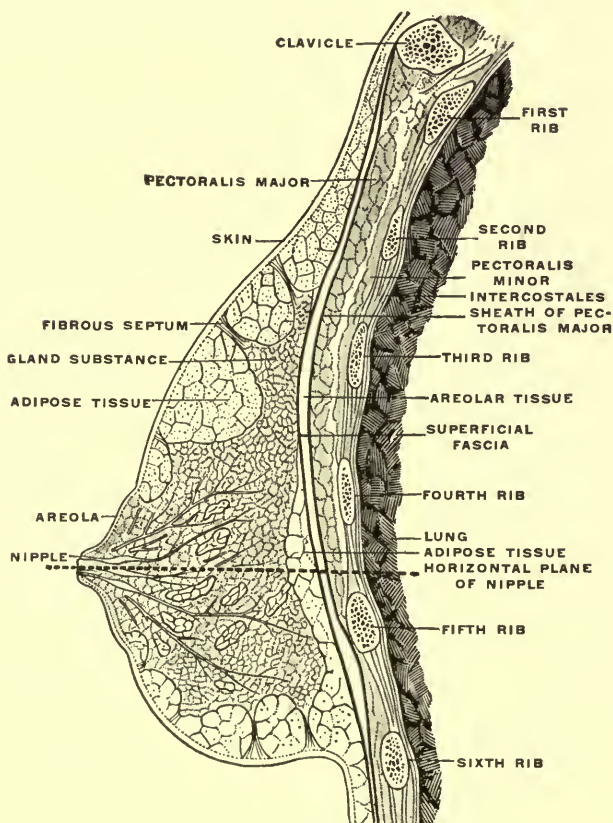


FIG. 197.—Vertical Section of Right Breast, Inner Surface of Outer Segment. (Testut.)

the axillary proper, in the loose adipose tissue of the axilla; and the subscapular, between the scapula and the posterior wall of the thorax. The anastomosis of the lymphatics of the breast is exceedingly free and it is easy to see how the skin may become involved early in cancer of the breast. The pectoral group of axillary lymphatic glands is the one usually first infected in this disease.

AGE CHANGES

The Infantile Breast.—The breast at birth consists of a nipple covered with epidermis, which differs from normal skin. The mamma is surrounded by a non-pigmented areola. On section the breast is seen to be made up of branching ducts surrounded by loose areolar tissue and fat.

Longridge, who studied the mammary glands of still-born

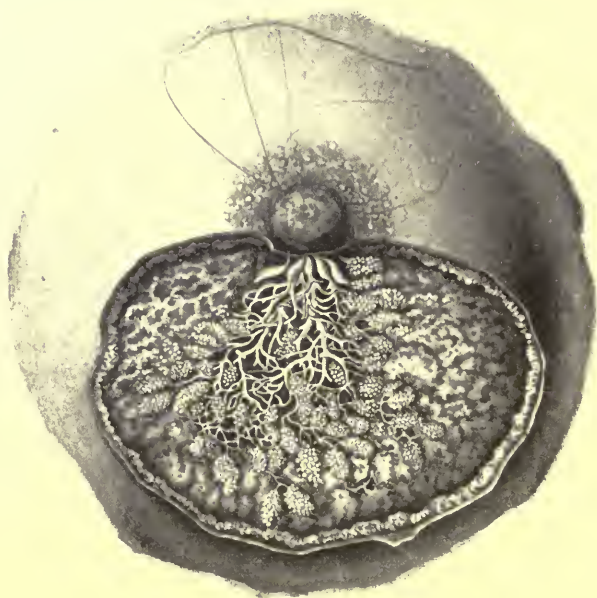

FIG. 198.—Dissection of the Lower Half of the Breast, Showing the Anatomical Arrangement of the Milk Ducts. (Jewett.)

infants, found that in large children with abundance of subcutaneous fat the breasts are usually well developed, irrespective of sex. The breast tissue can be felt distinctly as a solid mass lying below the primary areola, and on squeezing it a fluid, which on microscopic examination is indistinguishable from milk, can be expressed. Whatever the cause of the activity of growth in the breast of the new-born infant may be, and many theories have been advanced, such as the existence of a "chemical messenger" in the circulation,

or an internal secretion from the maternal placenta, the growth and the secretion cease soon after birth and the breast is quiescent until puberty approaches.

The Breast at Puberty.—At puberty the whole breast enlarges, the nipple becomes larger also, and is more sensitive; the areola increases in size and becomes pigmented to a moderate degree in brunettes. Acini lined with epithelium are formed by bulbous outgrowths from the ducts, and there is an increase both in the gland structures and the intralobar stroma.

Lactation Hypertrophy.—The breasts become fuller, the veins are

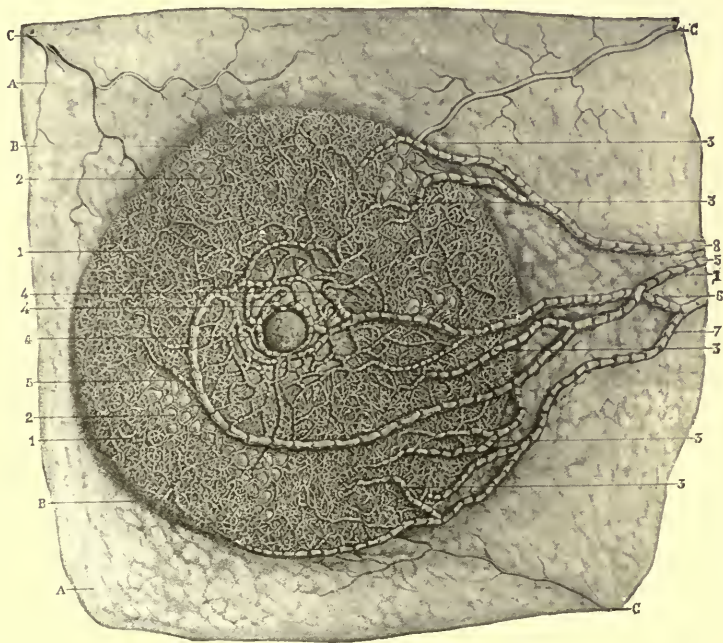


FIG. 199.—Lymphatics of the Left Breast. (Sappey.)

prominent, and the patient has a sensation of swelling of the breasts during the second month of pregnancy and later. The nipples become prominent and the areola pigmented. In the wrinkled skin of the latter, the enlarged sebaceous glands, twelve to twenty in number, stand up as little elevations. During the fifth month there appears a secondary areola outside the primary areola, consisting of a network of pigment around light spots, each repre-

senting a circle round the opening of a sebaceous gland. Colostrum may be pressed from the nipple by skillful stroking of the breast toward the areola after the third month of pregnancy. The secretion of milk is not established until the end of the second day of the puerperium. On section of a breast during lactation one notes that the gland structure is enormously hypertrophied, the intralobular connective-tissue stroma having, to all intents and purposes, disappeared, and the blood-vessels and lymphatics are much enlarged.

The Senile Breast.—Atrophy takes place early—between thirty and forty—in the case of women whose breasts have not undergone lactation hypertrophy. In the latter event the atrophy begins with the onset of the menopause. The gland structure shrinks, but, if the woman is well nourished, fat takes its place and the breast may retain its former size. When senile atrophy is well advanced the breast consists of bands of fibrous tissue, with occasional remains of a duct or an acinus lined with atrophic epithelial cells surrounded by fat and radiating from the nipple.

CLASSIFICATION OF DISEASES OF THE BREAST

The following classification is taken from J. C. Bloodgood's excellent article on diseases of the female breast in Kelly and Noble's "Gynecology and Abdominal Surgery," being based on a clinical and pathological study of 1,048 lesions of the breast, observed in the surgical pathological laboratory of the Johns Hopkins Hospital.

- I. *Anomalies.*
- II. *Symptomatic Lesions.*
 1. Pain (neuralgia of breast, mastodynia).
 2. Areas of congestion (phantom tumors).
- III. *Hypertrophies.*
 1. Infantile (duct ectasia).
 2. Puberty hypertrophy (normal).
 3. Lactation hypertrophy (physiological).
 4. Diffuse bilateral hypertrophy (pathological).
 5. Senile parenchymatous hypertrophy, with and without cyst formation.

IV. *Inflammations (Mastitides).*

1. Pyogenic, with abscess formation.
 - (a) Associated with lactation.
 - (b) Not associated with lactation.
2. Chronic interstitial, with parenchymatous atrophy and without cyst or abscess formation.
3. Tuberculosis.
4. Actinomycosis.
5. Syphilis.

V. *Benign Tumors.*

1. Fibro-epithelial tumors:
 - (a) Intracanalicular myxoma (periductal myxoma or fibroma-Warren).
 - (b) Adenofibroma.
2. Epithelial tumors:
 - (a) Adenoma (cystadenoma).
 - (b) Cysts with intracystic papilloma.
 - (c) Simple cyst, single or multiple (see senile parenchymatous hypertrophy).
 - (d) Galactocele (see lactation hypertrophy).
3. Miscellaneous rare tumors:—lipoma, enchondroma, lymphangioma, dermoid cysts, calcium deposits, encysted foreign bodies.

VI. *Malignant Tumors.*

1. Carcinoma.
 - (a) Adenocarcinoma.
 - (b) Medullary carcinoma.
 - (c) Scirrhous carcinoma.
 - (d) Cancer cysts.
2. Sarcoma.
 - (a) Secondary to intracanalicular myxoma.
 - (b) Non-indigenous.

Let us now consider briefly the different lesions of the breast that figure in the preceding classification before proceeding to a clinical diagnosis of tumors of the breast in general (see page 549).

I. ANOMALIES

Complete absence of the breast, usually affecting one breast only, has been described as a very rare anomaly and is due to lack of development in early embryonic life. Sometimes the ovary on the corresponding side is absent also.

Incomplete development of the breast, with or without absence of the nipple, is much more common than absence and is apt to be associated with anomalies of the uterine organs. When the nipple is wanting the areola is often imperfectly formed or absent altogether.

Supernumerary mammæ are not very rare. They are usually near

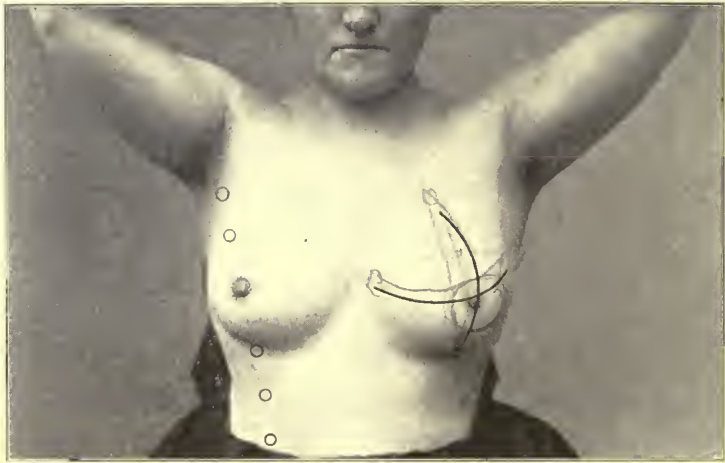


FIG. 200.—The “Milk Line” or Situation of Supernumerary Mammæ, also the Breast Divided into Quadrants. (Warren.)

the situation of the normal breast or in the “milk line,” (see page 532). Garré observed five developed mammæ, two on the thorax, one in each axilla, and one in the median line below the ensiform cartilage. Some authorities consider that seven pairs of mammæ existed originally in the human race, situated in the “milk line,” three above and three below the present normal pair, and that supernumerary breasts indicate a return to a primal type.

A remarkable case has been reported by Blum (*München. med. Wochenschr.*, May 21, 1907) of a girl seventeen years old who had

two well-developed mammæ in the normal situation and a third mamma in the region of the mons veneris the size of a goose egg and surmounted by seven nipples. The two normal mammæ had no secretion, but four of the seven nipples of the supernumerary breast secreted a copious amount of colostrum regularly just before and during the first day of each menstruation.

II. SYMPTOMATIC LESIONS

Pain in the breast associated with a localized swelling is not uncommon, especially in young childless married women at the time of menstruation. The painful swelling is firm, but disappears when menstruation is over. Sometimes gynecologists see areas of induration in the breasts of patients with uterine disease. In a doubtful case of a tumor which has existed for a long time the patient should be anesthetized and careful palpation will show whether the tumor is a *phantom tumor* or not. If a breast tumor is found to be real, the wisest course is to remove it at the same sitting, having, of course, already gained the patient's consent, and have the tumor examined by the pathologist. *Mammary neuralgia* may be due to pressure on the breasts from badly fitting corsets, or from traction in the case of excessively pendent breasts, and is commonly observed in neurotic women at the time of menstruation. It occurs also in anemic women and in sexually precocious girls. Only when the pain is present in one breast alone does the symptom call for careful investigation of the breasts.

III. HYPERTROPHIES

Infantile hypertrophy is a rare affection due to the abnormal distention of the ducts with desquamated, degenerated epithelium. The breast at this time is more apt to become infected and mastitis ensues often. Ordinarily the swelling of the breast subsides spontaneously.

Puberty and lactation hypertrophy have been considered on page 535.

Galactocele is a cystic tumor occurring during lactation and caused by the dilatation of a duct. The tumor is flask-shaped,

with the mouth of the flask at the nipple. Fluctuation is present and the skin and nipple are normal. In some cases there are several of these tumors in a breast. Absence of inflammatory thickening should distinguish a galactocele from a pyogenic mastitis.

Diffuse Bilateral Hypertrophy.—Excessive enlargement of the breasts due to abnormal growth of breast tissue, a sort of adenofibroma, found mostly in young unmarried women, is always a bilateral disease. The increase in size is slow, requiring from one to fourteen years to attain a considerable development, and the enlargement is first noticed between eleven and thirty years of age. Occasionally the progress of these cases is rapid, as in the one reported by Durston, where the two breasts weighed, after removal, sixty-four and forty pounds, respectively, the growth having taken place within four months. This, I think, is the largest case on record.

The enlargement begins in one breast and after a time the opposite breast also begins to grow. The breasts are at first full and firm, but later become flaccid. The areolæ are increased in diameter and the nipples become flattened by pressure. The great bulk of the breasts, which may reach nearly to the knees, may impede locomotion or even interfere with respiration. No cases of cancer occurring in diffuse bilateral hypertrophy have been recorded.

Senile Parenchymatous Hypertrophy.—This disease, forming a quarter of all the benign lesions and occurring during the cancer age, is the most important of the non-malignant tumors.

The etiology is not known. The pathology consists of an increase in the parenchyma, the epithelial cells proliferating and degenerating, associated with dilatation of the ducts and acini,—an adenomatous type. In the early stage there are no symptoms, unless, possibly, pain and tenderness associated with areas of increased density in the breast. With further distention of the ducts cysts are formed, the lining epithelium being destroyed in the course of time, or the dilated ducts, instead of being filled with fluid, contain proliferating epithelial cells,—the adenocystic type.

If one tumor is present it may feel like an area of induration without definite boundaries, or it may be a sharply circumscribed growth, in the latter event being at times large enough to involve an entire quarter of the breast.

Palpation will show a cystic character (the cyst being generally spherical) or perhaps a simple hard area. The nipple and the skin over the tumor are normal. If a quadrant of the breast is involved the normal contour will be altered. The adeno-cystic type of tumor grows rapidly, the tumor reaching a considerable size in a few days, but cases are on record where the growth had existed for several



FIG. 201.—Diffuse Bilateral Hypertrophy of the Breasts. (Warren-Gould.)

years. There may be a discharge from the nipple, and pain is a symptom of the early stages.

If there are two or more tumors present in one or both breasts, the diagnosis is made by finding one circumscribed cystic tumor and several smaller shot-like tumors, generally in the opposite breast.

On exploratory section a cyst has thin walls with smooth inner

surface and the contents are clear and fluid, never bloody, or thick as in the case of a cancer cyst.

IV. INFLAMMATIONS—MASTITIS

Mastitis may be due to the *Staphylococcus albus* or *aureus*, to the tubercle bacillus, to the *Spirochaeta pallida* of syphilis, and very rarely to the *actinomyces bacillus*. It is (a) acute, or (b) chronic.

a. **Acute mastitis** occurs almost without exception during lactation and generally before the fourth month of lactation. It is more often met with in primiparæ. It is probable that infection reaches the gland tissue through the nipple and the ducts in most cases, but may get there by way of the blood or from neighboring anatomical structures.

The early caking of the breast during the first few days of labor seldom leads to abscess formation. At any time after this, generally in the first four weeks, always before the fourth month of lactation, one or more areas of induration may be observed in one breast, attended by a rise of body temperature, a chill, and pain and tenderness in the breast. A crack in the nipple is often to be found in such a case. Resolution may take place without abscess formation if the breast is properly supported and passive hyperemia induced after Bier's method. If not, a *mammary abscess* results; the indurated area becomes reddened, the pain increases so that nursing is impossible, there are leucocytosis and a constant elevation of temperature, and fluctuation with adhesion of the skin to the indurated mass can be made out.

Abscesses are apt to be multiple and the breast may be riddled with them. Sometimes not only the parenchyma of the gland is infected, but the loose connective tissue between the breast and the pectoral muscle is involved and a *submammary abscess* is the result.

The important point in diagnosis is to recognize the beginning of pus formation, so that an early incision may be made and thus obviate destruction of breast tissue, sinuses, and a prolonged supuration with its deleterious effects on the system. Therefore the appearance of redness of the skin over an indurated area of gland

tissue, a union of the skin with the tissues underneath, continued elevation of temperature and leucocytosis, are indications that pus has formed, even though fluctuation can not be determined.

A rare form of "acute carcinoma" or "carcinomatous mastitis" developing rapidly in the course of mastitis has been described by Volkmann.

b. Chronic mastitis includes both suppurative and non-suppurative inflammations of the breast. The pyogenic variety may follow an acute mastitis, in which case the abscess wall, lined with granulation tissue, becomes thickened and the pus filling the abscess is of thin consistency.

Chronic interstitial mastitis is a chronic inflammation of the interstitial connective tissue of the gland. The connective tissue is increased in amount and crowds out the acini and ducts. In the later stages there is atrophy of all the structures and the breast on section shows a dull opaque white surface, with very few of the pink spots of secreting gland substance to be seen. The disease may be limited to individual lobules of the mamma, in this case being referred to as a *lobular mastitis*, or it may involve the entire gland—*diffuse mastitis*.

Chronic interstitial mastitis is found in women of middle age in the non-lactating breast, it has no distinctive symptoms, and must be differentiated from cancer.

Chronic mastitis generally affords a history of an acute attack of mastitis some time in the past, the lump in the breast has been stationary in size since it was first noticed, it is painful, and more tender than cancer, it does not involve the surrounding structures, either muscle below, or fat and skin over it, and the tumor is freely movable.

Tuberculous mastitis, forming six per cent of all benign lesions of the breast, is a form of chronic mastitis occurring between the ages of twenty-five and thirty-five, and occurring more often in the non-lactating than in the lactating breast. As a rule, it occurs after the fourth month of lactation and is unilateral.

There may be no family history of tuberculosis and there may be no other lesions of tuberculosis elsewhere in the body. The disease begins in an area of induration, generally in the region of the areola. The induration breaks down and an abscess is formed without acute symptoms of pain and fever, the abscess ruptures

spontaneously, leaving a sinus. At this time an exact diagnosis may be made by means of the microscopic examination of tissue removed from the abscess or sinus wall.

Actinomycotic and Syphilitic Mastitis.—These forms of mastitis, extremely rare, are diagnosed in the case of actinomycosis by the characteristic appearance of the tissues (see page 332). In the case of syphilis a primary lesion has been known to occur on the nipple. It has the characteristic appearance of chancre elsewhere (see page 406). Mucous patches have been observed both on the nipple and in the folds under a pendulous breast. Only a few cases of gumma of the breast, and diffuse syphilitic mastitis have been described. The diagnosis of syphilis rests on the history with the definite period of incubation of the disease, and on the appearance of the lesions, which are the same as in the vulva (see page 406).

Search should be made for the spirochæta pallida in excised tissue or the discharges.

It is thought that the tissue changes resulting from lactation mastitis furnish a predisposition to cancer and John Speese (*Annals of Surgery*, Vol. LI., Feb. 1910, p. 212) advises removal of all indurated areas from this cause occurring in the breasts of women who are near the menopause.

V. BENIGN TUMORS

1. FIBRO-EPITHELIAL TUMORS

These are intracanalicular myxomata and adenofibromata, the former being the more common, and both together forming 39 per cent of 333 benign tumors of the breast observed by Bloodgood. The tumors are single, or multiple (in about one-fifth of the cases), they occur in one or both breasts and in young women, the average age at which they are first noticed being less than twenty-five years.

Cancer has never been observed as a complication of this sort of tumor. The growth is slow. Most of the tumors are single and small and may be removed without sacrificing the breast.

Recurrence of a tumor of the fibro-epithelial type should be regarded as an instance of successive tumors developing at different periods of time from separate foci, rather than the growth of a new

tumor from elements of the first one, and as these tumors are multiple in a fifth of all cases, such a so-called "recurrence" might well be more common than it is. As a matter of fact these "recurrences" are very rare.

Large intracanalicular myxomata sometimes occur in older women—from thirty to fifty years of age. These have a tendency to develop into sarcoma and therefore call for a radical operation.

The adenofibroma is always relatively small in size, is spherical, hard and firm, even calcareous in some instances; the older the tumor the more fibrous tissue is present.

2. EPITHELIAL TUMORS

Cystic Adenoma.—This is a rare form of growth consisting of a small, encapsulated, freely movable tumor occurring in breasts of sterile women between the ages of thirty and fifty years.

Cysts with intracystic papilloma are also rare and constitute a form that can not be distinguished clinically from malignant cysts of the same characteristics. The chief symptom of the benign cyst is a discharge of blood from the nipple. The cyst is generally single, occurs in women between the ages of thirty and sixty, and its growth is generally slow. On account of the impossibility of making an exact diagnosis, such a cyst should be removed together with the entire breast and the pectoral muscle and axillary glands.

For a discussion of simple cysts and galactoceles see page 539.

VI. MALIGNANT TUMORS

CARCINOMA

The average duration of life in cancer of the breast from the first time the tumor is noticed until death is 3.77 years. In the case of atrophic scirrhus a patient has been known to live over nine years, but only in this form of cancer has life been prolonged so far. The disease is, then, of comparatively slow growth—nearly four years on the average—and the opportunities for early diagnosis and removal of the disease are therefore ample.

Cancer of the breast may be divided, for the purposes of diag-

nosis, into the following varieties:—adenocarcinoma, medullary carcinoma, scirrhous, and cancer cysts.

Adenocarcinoma.—Adenocarcinoma formed 14.4 per cent of the carcinoma cases seen in Halsted's clinic. In this species of cancer the inoperable cases were the fewest and the percentage of cures greatest; in other words, the disease progresses more slowly and involves the surrounding structures later than in the other forms of cancer. Bloodgood enumerates four varieties of adenocarcinoma, namely: the comedo, or duct cancer; the colloid; the adenocystic; and the malignant intracystic papilloma. Each may be pure, or any one may be combined with medullary or scirrhous cancer.

Comedo Adenocarcinoma.—This is the commonest type. The cut surface of a breast affected with this disease shows trabeculae of fibrous tissue in the meshes of which are round, granular areas from the center of which worm-like comedo bodies can be expressed, the appearance being characteristic. The tumor has no capsule. The disease begins as a small circumscribed tumor and may be shot-like, sometimes being multiple, and rarely occurring in both breasts.

Colloid Adenocarcinoma.—This differs from the preceding in having a thin capsule, and presenting on section—bulging between the fibrous trabeculae—pink gelatinous lobules which are pathognomonic.

Cystic Adenocarcinoma.—This may be either circumscribed or diffuse, the latter occurring generally during senile parenchymatous hypertrophy. The disease is characterized by the occurrence of cysts in an encapsulated tumor showing on section the characteristics of adenoma. Glandular involvement is late and a permanent cure following operation may be expected, even if the skin and muscles are involved.

Adenocarcinoma with Papilloma in the Cysts.—This is similar to the benign form (cystic adenoma, see page 545) except that the papilloma proliferates and becomes an infiltrating fungous growth resembling medullary carcinoma.

A discharge of blood takes place from the nipple just as in the benign form, the only difference being that the malignant type infiltrates and the fungous growth is different in appearance from the benign papilloma.

Medullary Carcinoma.—This formed three per cent of Halsted's

cases of cancer. It grows rapidly, but does not infiltrate as soon as scirrhus. It is the form of cancer most often found in the lactating breast. Beginning as a small, circumscribed, soft tumor, it soon becomes larger and begins to ulcerate. On section the fibrous stroma may be seen enclosing much granular, friable tissue, which may be forced out on pressure.

This form of cancer is frequently associated with adenocarcinoma

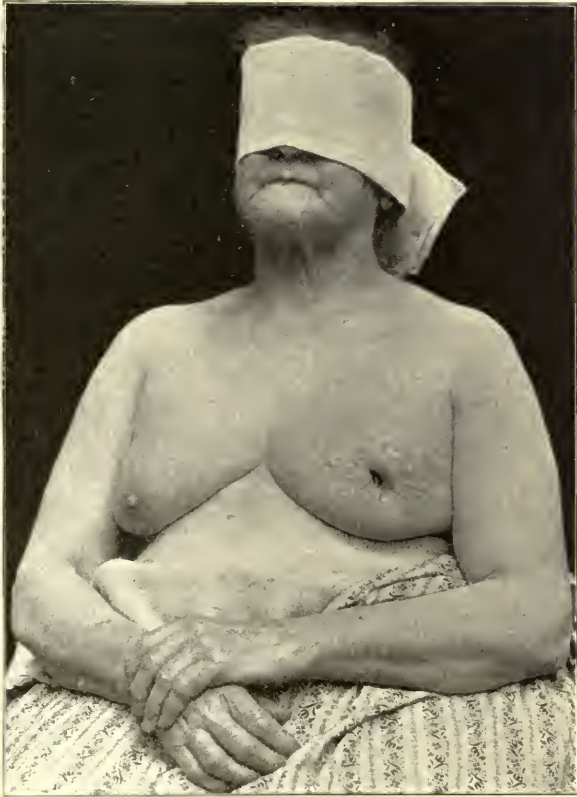

FIG. 202.—Scirrhus Cancer of the Left Breast. (Warren-Gould.)

both of the comedo and the cystic varieties. There is one type of medullary carcinoma, called the hemorrhagic, which is characterized by the occurrence of patches of old and fresh blood throughout the tumor, as seen when a section is made.

Medullary carcinoma often resembles sarcoma and pathologists are puzzled to differentiate them.

Scirrhus Carcinoma.—Scirrhus cancer may be divided into the circumscribed, the small infiltrating, and the large infiltrating scirrhus. On cutting a scirrhus tumor of whatever sort, the physician experiences a gritty sensation as the knife goes through the tough tissue and on feeling the cut surface with the finger it is lumpy and hard. To the eye it shows much white fibrous stroma with yellow dots and lines in the interstices. The disease infiltrates the surrounding structures relatively early and has all the marks of malignancy within twelve months of the first appearance of the tumor. Glandular involvement and metastases to other organs are common.

The large infiltrating scirrhus cancers are the most dangerous and furnish the largest proportion of the inoperable cases. According to Bloodgood's analysis of the cases in Halsted's clinic, 70 per cent of all the cancers were scirrhus, and of these 10 per cent were circumscribed, 29 per cent were large infiltrating, and 31 per cent were small infiltrating scirrhus.

The diagnosis rests on the presence of a hard tumor presenting all the characteristics of malignancy (see page 552).

Cancer Cysts.—These tumors are rare, forming only 2.7 per cent of all tumors of the breast. The diagnosis from benign cyst, before operation, is impossible.

On exploratory incision the cancer cyst contains blood, but no papilloma, or it contains a thick, grumous material formed from broken-down epithelial cells. A galactocele, on the other hand, has thin, smooth walls and is surrounded by lactating breast tissue; a circumscribed, chronic abscess has a thick wall and thin, clear or cloudy, serous contents; a papillomatous cyst generally contains blood and papillomatous material; and a malignant adenomatous cyst has an infiltrating fungous growth lying in bloody contents. True cancer cysts are extremely malignant and are generally fatal, whether operated upon or not.

Paget's Disease of the Nipple.—Chronic eczema of the nipple associated with ulceration of the nipple, occurring in women between forty and sixty, is now regarded as a secondary manifestation of cancer of the breast, the primary lesion being a malignant tumor of the breast, the nipple being involved by metastases along the ducts or lymphatics. Paget described the disease in 1874 and until very recently the lesions of the nipple and areola were thought to precede the formation of a tumor in the breast.

SARCOMA

True sarcoma of the breast is rare. Bloodgood found eighteen among five hundred and five malignant tumors. It occurs as primary sarcoma of the stroma of the breast, as sarcoma arising in intracanalicular myxoma, and as metastatic sarcoma from some other organ. The primary sarcoma presents on section soft, friable tissue lining the walls of cyst cavities; the intracanalicular myxomatous form has distinct lobulations and the characteristics of myxoma.

Sarcoma shows the manifestations of malignancy, the patients are between the ages of forty and fifty, and the growth of the tumor is rapid.

THE DIAGNOSIS OF TUMORS OF THE BREAST IN GENERAL

The importance of early diagnosis in diseases of the breast can not be insisted on too often. The operating surgeons constantly see cases where the probable diagnosis was not made until too late and as, at the present time, the only hope for the patient with cancer lies in its early removal, delay on the part of the general practitioner, who sees nearly all of the patients, seals the death warrant. In this connection M. H. Richardson says:—"The evils of wrong diagnosis need not be exemplified, but the evils of a too-positive opinion do need emphasis, especially those opinions which, if wrong, sacrifice health, or even life itself."

W. L. Rodman, from a large operative experience, estimates that it is impossible to make a diagnosis of cancer in an operable stage in about ten per cent only of all cases.

In other words, an early diagnosis of cancer can be made in ninety per cent of all cases of cancer. That such a percentage does not obtain at present we have only to glance at the operability record of a large clinic, such as Halsted's at the Johns Hopkins Hospital. Of 464 patients admitted with the diagnosis of primary carcinoma of the breast, in only 349, or 75.3 per cent, was the disease in an early enough stage of development to permit of a radical operation at the hands of zealous advocates of this sort of operating. In all probability the percentage would be much

lower among less enthusiastic hospital surgeons, and even less among general practitioners.

According to W. L. Rodman the three most important points to consider in the diagnosis of a tumor of the breast are, the age of the patient, the situation of the growth, and whether or not it is adherent to the surrounding tissues.

History.—The history that malignant tumors have occurred in the family of the patient may occasionally be obtained, but in at least three-quarters of the cases the family history is negative in this respect. This is the case also in tuberculosis of the breast, forming about six per cent of the benign lesions of the breast and occurring between the ages of twenty-five and thirty-five.

The history of syphilis in the patient may point toward the very rare lesion, gumma of the breast, and the fact that the patient has been exposed to the contagion of syphilis might lead to the detection of chancre of the nipple, an unusual disease.

Injuries or blows on the breast were formerly thought to be causative of tumors. Now we may say that nothing is known of the etiology of tumors except that the inflammatory lesions follow infection, which may sometimes be traced by the history.

Married women are more subject to breast cancer than the unmarried, and the fruitful more than the sterile.

The date when the tumor was first noticed must be carefully recorded, also whether it has grown larger, and the amount of pain or tenderness, both in the early stages of the tumor and during the time intervening between its beginning and the present consultation.

Age.—The only disease of the breast occurring in infancy is abnormal distention of the ducts (duct ectasia) with a discharge from the nipple, sometimes associated with pyogenic mastitis, therefore the breast is practically immune from disease until the hypertrophy of puberty. At this time and after, the fibro-epithelial tumors (adenofibroma and intracanalicular myxoma) may occur. During lactation an induration is generally due to pyogenic mastitis. Any of the inflammations may occur from puberty to the menopause, also any of the benign tumors.

Carcinoma is essentially a disease of the atrophic breast, but it may occur as early as nineteen (case of A. J. McCosh). Only a few cases, however, have been reported of the disease occurring earlier than twenty-five.

Rodman analyzed 5,000 cases of cancer of the breast, with reference to the age at which it was diagnosed, and found that a fifth of all the cases occurred in women under 40 years of age. Almost an equal number occurred in the two decades between 40 and 50, and between 50 and 60. After 60, cancer of the breast is infrequent. Therefore the age of greatest frequency is the time of the menopause and the succeeding years while the breast is undergoing atrophic changes.

Sarcoma, forming about three and a half per cent of all malignant tumors of the breast, is found in women who are in the neighborhood of 40 years of age. Bloodgood puts the age at 40 to 50, but says that sarcoma occurs as a complication in intracanalicular myxoma, which commonly is found in younger women. This may account for Gross' earlier statistics. In 35 of his cases of "cystic sarcoma" the average age was 33.7 years, and in 60 cases of "solid sarcoma," only 13 were in women over 40 years of age.

Even at the present time the differentiation of sarcoma from medullary carcinoma is often a difficult problem for the pathologist, and a second examination of the specimen not infrequently brings a change in the diagnosis.

To summarize, if the patient is under twenty-five the presumption is that a given tumor of the breast is benign; if over twenty-five it is either benign or malignant, with the probability of the latter increasing as the age of the patient becomes more advanced.

Duration of the Tumor.—A tumor which has been present a year or more and yet manifests no evidences of malignancy (see page 546) is generally benign; still, a scirrhus cancer may exist for as long as five years without involving the surrounding tissues to an appreciable extent.

Situation of the Tumor.—Cancer is more frequently found in the upper and axillary side of the breast, although it may be found in any portion; next in point of frequency is the region of the areola. Malignant tumors in this situation are apt to pull on the nipple and cause retraction more often than in the case of growths situated in the outer portions of the gland.

Benign tumors are more frequently found in the sternal half of the breast, and are very rare in the areola. Mastitis, with the exception of the tuberculous form, occurs chiefly in the outer, axillary side.

Cancer generally involves one breast only, but has been found in both breasts in about five per cent of all malignant tumors. If a benign tumor has been removed from one breast, another tumor occurring in the opposite breast would probably be benign also. As a rule, multiple tumors are benign.

Mobility of the Tumor.—*Inspection and Palpation.*—If a tumor is freely movable and not adherent to the skin it is not cancerous. If, on the other hand, it is fixed either to the muscle below or, more important, to the skin, causing dimpling,—and when situated in the region of the areola, retraction of the nipple,—the growth is almost certainly cancer. To determine the connection of the tumor with the skin, expose both breasts fully, place the palm of each hand flat on the center of each breast, and move the breasts alike to and fro in every direction until asymmetry is produced in the diseased one by the adhesion of the tumor to the skin. This procedure is especially valuable in deep-seated growths in large and fatty breasts.

In palpating the breast a malignant growth, if it has reached the surface, is hard and of irregular outline; if situated deeply its connection with surrounding tissues limiting its mobility or causing asymmetry must be the determining diagnostic features.

If the nipple is retracted it should be seized firmly and pulled out, comparing it with the nipple of the opposite breast. The physician should bear in mind that many women have ill-formed and retracted nipples from birth. Should both nipples show deformity the patient should be questioned as to their usual shape.

Atrophy of the subcutaneous fat, even if the tumor is not actually connected with the skin, is a strong indication of cancer.

To determine any union between the tumor and the subcutaneous areolar tissue or the reticular layer of the corium some surgeons pick up the skin over the tumor and thus demonstrate a shortening of the fibrous trabeculae of the subcutaneous tissue or corium, comparing this finding with the condition of the skin elsewhere in the breast; others use the test of moving both breasts about as just described. Another method is to grasp one breast with both hands, whereupon the skin intervening between the hands will show dimpling if cancer is present and a smooth bulging surface if a benign tumor is present.

In practising inspection and palpation the physician makes a

mistake if, to save the patient's feelings, he does not expose thoroughly both breasts, the chest being in a good light. The slightest amount of asymmetry should lead to a thorough investigation as described above.

Retraction of the nipple, as has been pointed out, is a sign of cancer in the early stages of malignant disease situated in the neighborhood of the areola.

Enlarged glands in the axilla, formerly thought to be an important diagnostic sign of cancer, are now found to be fairly constant signs of benign tumors and inflammations of the breast.

Pain in the breast is a common symptom of the last two lesions also, and appears in cancer only in the inoperable, late stages. Pain, unassociated with tumor, occurs also in neuralgia of the breast (mastodynia), a rare condition except where associated with menstruation or the menopause. In the latter event, it may be due to senile parenchymatous hypertrophy. Pain in the region of the breast may be due to rheumatism of the pectoral muscle. In this case it should be called forth by abducting the arms on the chest.

Late Signs of Cancer.—Late signs of cancer interest us only in so far as they indicate whether or no the disease has passed a stage where operation may be attempted with hope of a favorable result. They are: pain, a discharge of blood from the nipple, ulceration, skin metastases, metastases in other organs, enlarged supraclavicular glands, and cachexia.

Discharge from the Nipple.—Besides being found in late cancer, a discharge from the nipple is present in the following conditions:—during pregnancy and lactation, in the infantile breast, in senile parenchymatous hypertrophy, and in papillomatous cysts. In the last case it is apt to be bloody.

Ulceration of the Skin over the Cancerous Growth.—This is a very grave sign and few, if any, patients presenting ulceration have been cured by operation.

Skin Metastases.—Occasionally two or more shot-like bodies are found in the skin of the breast at a distance from the malignant tumor. These are metastases from the tumor and are of serious import, for no case of permanent cure where skin metastases were present has been reported.

Metastases in other Organs.—These are always an indication of the

hopelessness of radical operation. M. H. Richardson has recently called attention (*Jour. Amer. Med. Assn.*, May 15, 1909, Vol. LII., p. 1556) to the importance of making a complete physical examination in the case of mammary cancer, saying that he has twice opened the abdomen for abdominal tumors of doubtful diagnosis without examining the breasts; and in both cases there were extensive cancerous infiltrations, which were metastatic from the breasts. He says also that any persistent cerebral or spinal symptoms in cancer of the breast should lead to an examination of the nervous system for metastases in the cerebro-spinal axis, of which he has now seen many cases; and a persistent cough should call for an examination of the lungs to find metastases there.

Enlarged Supraclavicular Glands.—Palpable enlarged glands above the clavicle are of grave significance, the most favorable statistics showing only 7.5 per cent of cures following operation where the sign had been present. In the opinion of many operators, the presence of these enlarged glands places the patient in the list of the hopeless.

Cachexia.—When the disease has reached the point where the patient's health has failed and anemia, constipation, anorexia, loss of strength, a yellow color of the skin, and other symptoms of derangement of bodily function are present, there will be found also metastases, lack of mobility of the tumor,—because of the involvement of surrounding structures,—and ulceration, and the prognosis is absolutely bad.

In all cases of clinically doubtful diagnosis, it is not wise to make an exploratory incision into the tumor with the knife, or the hollow Mixter punch, because of the very great danger of autoinfection.

If a tumor is of doubtful diagnosis it should be removed, the pathologist in attendance at the operation deciding, by means of sections of the tumor, the need of radical extirpation of surrounding structures.

CHAPTER XXVIII

THE DIAGNOSIS OF THE GYNECOLOGICAL AFFECTIONS OF INFANCY AND CHILDHOOD

Importance of examining the genitals, p. 555. The examination, p. 556. Anomalies, p. 557: Adherent prepuce, p. 557. Labial hernia, p. 558. Hydrocele of the labium majus, p. 559. Imperforate hymen, p. 560. Imperforate rectum and anus, p. 561. Prolapse of the uterus, p. 562. Erosion of the cervix, p. 563. Precocious menstruation and precocious maturity, p. 564.

Diseases of the vulva and vagina, p. 566: Vulvo-vaginitis, p. 566; Simple vulvo-vaginitis, p. 566; Gonorrheal vulvo-vaginitis, p. 566, Symptoms, p. 568, Diagnosis, p. 568; Tuberculosis of the vulva, p. 568; Diphtheritic vulvitis, p. 569. Gangrene of the vulva, or noma, p. 569. Sarcoma of the vagina, p. 570.

Genital hemorrhages, p. 571: Hemorrhage from the vulva in the newborn, p. 572. Hemorrhage from the vulva in little girls, p. 572. Metrorrhagia of puberty, p. 573.

Masturbation, p. 574.

Malignant disease of the uterus, p. 576.

Diseases of the ovaries and tubes, p. 576: Diagnosis, p. 576.

Diseases of the bladder, p. 578: How to collect the urine in infants, p. 578. Peculiarities of urination, p. 578. Enuresis, p. 578. Bacteriuria, p. 579. Cystitis and stone in the bladder, p. 581. Primary tumor of the bladder, p. 582. Hematuria, p. 583.

Diseases of the rectum, p. 584: Prolapse of the rectum, p. 584. Proctitis, p. 585. Fissure in ano, p. 585. Incontinence of feces, p. 585.

WITH the march of progress the gynecological affections of children that were formerly thought to be so infrequent as to merit little attention, are now known to be not only not rare, but of considerable importance from the standpoint of prophylaxis, if from no other. Practically all the diseases found in the adult have now been observed in children. It is a well-known fact that the genitals of the female infant are not so carefully looked after by the physician and nurse as are those of the male child. Abnormalities of the prepuce in the latter are almost always noted, while the vulva of the little girl is not systematically inspected. Neglect of abnormalities and disease in the female infant—such, for instance, as an insufficient opening in the hymen, adhesions of the nymphæ, or vulvo-vaginitis—provide in later years for retained menses, or in-

fection of the genital tract, enuresis, masturbation, or salpingitis,—or for uterine malpositions, which are the result of previous pelvic peritonitis. The relatively frequent occurrence of sarcoma of the vagina in infants, its rapid and fatal course, make delay in diagnosis especially dangerous. Also, diseases of the urinary organs are by no means rare and deserve prompt attention.

EXAMINATION

The examination of the genital organs in children varies from that in adults in that the anatomical parts are very much smaller and the little patient's attention has to be distracted and her good-

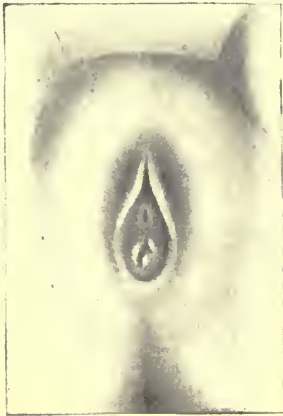

FIG. 203.—The Infantile Vulva. (Williams.)

will obtained in greater measure before the investigation can be carried through. The use of an anesthetic becomes necessary more often in the case of children than in adults, in order to secure the essential relaxation. A digital examination of the vagina should seldom be attempted in children. If the vagina is to be examined it must be inspected through a Kelly cystoscope of the largest size that will enter the vagina without rupturing the hymen; artificial light and a head mirror being employed as described in the chapter on the investigation of the bladder (Chapter VIII., page 110). The knee-chest position is the

best posture for the examination. (See Fig. 205.)

The recto-abdominal touch (see Chapter V., page 53) is the one to be employed in palpating the pelvic organs in children. For this an anesthetic is generally necessary in the case of very young children, but in older children, if their confidence can be gained, ether may not be required. The utmost gentleness and delicacy of touch must be employed in making palpation because of the relatively small size of the sphincter ani and the friable nature of the rectal wall in infants and children. The sad accident has occurred of the examining finger making a rent through the

rectum into the peritoneal cavity because too much force was used. Because of the relatively greater length of the examining finger and the small size of the pelvis and the close proximity of the abdominal organs, it is possible in little children to palpate the iliac, hypogastric, and umbilical regions through the rectum, and, in addition to the pelvic organs, in this manner to feel a diseased appendix or enlarged mesenteric glands. Be on the lookout for a full bladder, which is an abdominal organ in the child, and may simulate a cystic ovarian tumor or a collection of pus.

ANOMALIES

The development of the external genital organs is described in the chapter on the diseases of the vulva (Chapter XXI., page 392) and the reader is advised to consult this description and Figs. 158 to 162, page 395, also Fig. 71 (from Kollmann), page 198, showing the development of the ovaries, tubes, uterus, and vagina, before taking up the congenital affections seen in children. Fig. 204, page 558, after Webster, shows the anatomy of the pelvic organs in the new-born child. Note that the vagina is relatively long, the cervix is long compared with the body of the uterus, and the uterus is in a position of retroposition with anteflexion, besides being high in the false pelvis.

The congenital anomalies of the vulva, vagina, uterus, tubes, ovaries,—also of the bladder and rectum, are treated at length in the chapters devoted to these subjects. In the present chapter we will consider only those defects of the generative organs that cause symptoms during childhood and with which the practitioner must be familiar.

Adherent Prepuce.—Adhesion of the prepuce to the clitoris with retained smegma is a not uncommon condition in female infants and children. Some authors consider that the prepuce is adherent normally. W. A. Edwards (supplement to Keating's "Cyclopedia of Diseases of Children," p. 872) noted adhesions of the labia minora nine times in his private records of the births of two hundred and fifty female children. He says further that he has been accustomed to see several cases of adherent prepuce in children every year. It is doubtful whether adherent prepuce is often a cause of

grave nervous disease, but this acts sometimes as a cause of local irritation and of enuresis in children. In cases of wetting of the bed the genitals should be inspected carefully to rule out this abnormality. The irritation caused by the adhesion of the prepuce is thought to be a cause of masturbation,—at any rate the prepuce is often found adherent in masturbators.

Labial Hernia.—An inguinal hernia sometimes passes along the round ligament and appears in the labium majus. This condition

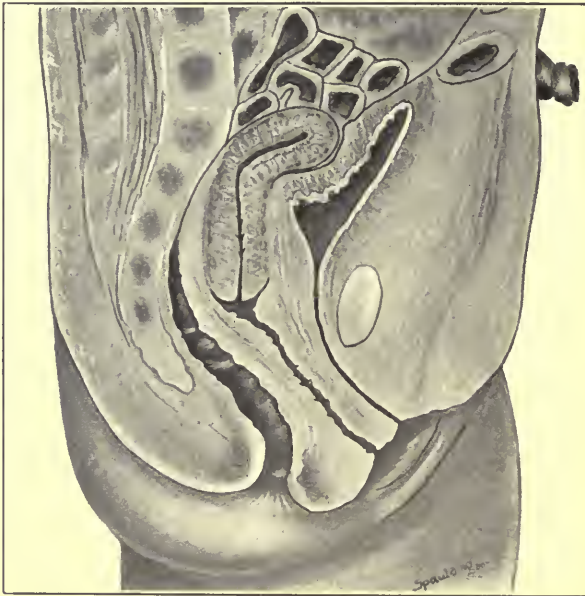

FIG. 204.—Longitudinal Median Section of the Pelvis of a New-born Child. (After Webster.) Showing relatively long cervix and vagina, retroposition with ante flexion, straight sacrum and cartilaginous coccyx.

is seen in late childhood occasionally, and not rarely in infants. The hernial sac may contain omentum, intestine, or ovary and tube. Hernia of the ovary, sometimes accompanied by its tube, has been met fairly often in female infants under eighteen months of age, it being due apparently to the normal position of the ovaries and tubes in infancy close to the internal openings of the inguinal canals (see Fig. 206), to a patent canal of Nuck, or a shortened round ligament. The protrusion can be traced to the external abdominal ring above, and is limited to the upper portion of the

labium. If it contains omentum it is irregular to the feel and flat to percussion, and if intestine it is smooth and has a tympanic note. The sac is generally reducible by taxis if the patient is recumbent unless it contains an ovary, when it is firmer, flat on percussion, tender, and can not be returned to the abdominal cavity. Labial hernia is to be distinguished from hydrocele of the labium majus and tumor of the labium.

Hydrocele of the Labium Majus.—Should the peritoneal invest-

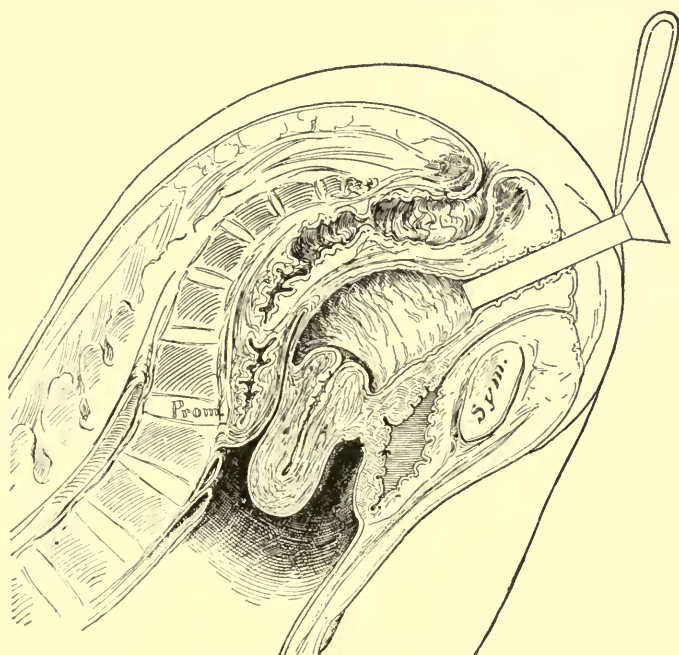


FIG. 205.—Examination of the Infantile Vagina and Cervix with a Kelly Bladder Speculum. (Kelly.)

ment of the round ligament extend downward nearly to the end of the ligament in the labium instead of terminating as normally in the inguinal canal, this sac of peritoneum (the canal of Nuck) may become filled with serum, thus forming a hydrocele. In this case there is a firm ovoid tumor in the labium with its smaller end upward. It can not be reduced, it is flat on percussion, and its upper pole is generally separated by an appreciable distance from the external abdominal ring. If the hydrocele is of large size, fluctua-

tion may be made out. The condition is a rare one and is distinguished from labial hernia in not being reducible and in presenting a flat percussion and fluctuation. The differentiation from a tumor of the labium may be impossible. Tumors are apt to be in the lower part of the labia and they are of even rarer occurrence.

Imperforate Hymen.—Imperforate hymen, as pointed out in Chapter XXI., page 396, is a misnomer, the condition being generally one of atresia of the lower part of the vagina. It is rare and generally causes no symptoms until menstruation is established. The results of not recognizing it until puberty are so deleterious to the patient that the obstetrician should satisfy himself by a careful examination of the genitals of every new-born girl, not only that the hymeneal opening is not closed, but that it is of sufficient size to afford proper drainage to the vagina. For, if it is not, infections and inflammations are more likely to occur in later years. This point can be determined easily by passing a catheter into the vagina. If the catheter will not pass, a proper opening into the vagina should be established by operation.

The physician will do well to bear in mind that atresia of the vulva and vagina arises in many cases from the infectious diseases and is not, as formerly taught, "congenital." An apparent trifling infection of the genitals in childhood, accompanied by minor symptoms, may result in closure of the vaginal opening or a gluing together of the nymphæ. Therefore, the physician should watch his female infants and girls who are suffering from typhoid fever, smallpox, scarlatina, and diphtheria, with great care, having this possibility in mind. As pointed out by Nagel in 1896, it is rare to find true congenital atresia of the vagina except in cases where there is also present some arrest of development of the uterus or ovaries.

L. Pincus (*Monatsschr. für Geb. und Gyn.*, 1903, XVII., p. 751) has maintained that a majority of cases of primary absence of the menses, supposed to be due to congenital obstruction of the vagina, are really caused by atresia of the vagina accompanying or following the infectious diseases, and he has reported cases which bear out his contention. According to him and contrary to common belief, typhoid fever is the most frequent cause of atresia, and H. A. Kelly ("Medical Gynecology," page 248) has collected nine

cases from the literature in which typhoid fever was the cause of vaginal atresia. Smallpox, as we might expect from the nature of the disease, comes next in frequency, and cases are reported of atresia following dysentery, pneumonia, erysipelas, cholera, scarlatina, and diphtheria. Attention has been called to this subject only in recent years so that the number of reported cases is not as yet large.

To overlook atresia in a child is an easy matter, therefore the importance of instituting a minute inquiry as to the presence of vulvar irritation or discharge in a female child suffering from an infectious disease is apparent, and in the presence of atresia in children of more mature years the mother should be questioned as to whether these symptoms had existed during or following infectious disease in the child in the past.

Imperforate Rectum and Anus.—Starr ("American Text-Book of Diseases of Children") has estimated that malformation of the rectum and anus occurs about once in ten thousand births and is more common in girls than in boys,—if we include anus vaginalis. As has been pointed out elsewhere (see Chapter XXVI., page 495) the rectum and anus are developed from entirely different structures of the blastoderm—the former from the hind-gut, the latter from the proctodeum—therefore malformation of one does not necessarily imply abnormality of the other, and observations show that where the rectum is malformed or displaced the anus is commonly normal, and vice versa.

Imperforate Rectum.—Imperforate rectum is comparatively common, the rectum ending in an open tube on a level with the reflection of the peritoneum on the rectum, due presumably to the failure of the hind-gut to send out a bud (the post-allantoic gut) to meet the proctodeum. The imperforate rectum may open into the vagina, and in this case, unless imperforate hymen is present also, there is an escape of meconium or feces by the vagina.

Imperforate Anus.—Imperforate anus, due to failure of development of the proctodeum, is a not uncommon anomaly. There may be no trace of the anus, or its situation may be marked by a slight depression or by a wart-like prominence.

Imperforate anus with anal canal ending in the vulva is common and is confounded with imperforate rectum having a vaginal outlet. Incontinence of feces is generally present in these cases.

Anus well formed and the anal canal ending above in a cul-de-sac is not uncommon. In this anomaly the child on straining causes the septum dividing the rectum from the anal canal to protrude from the anus.

The obstetrician should examine the anus of every new-born child with a view to discovering the abnormalities just described. His little finger well anointed and introduced through the sphincter ani will go a long way toward finding an anomaly before it has caused serious symptoms. A thorough examination must be

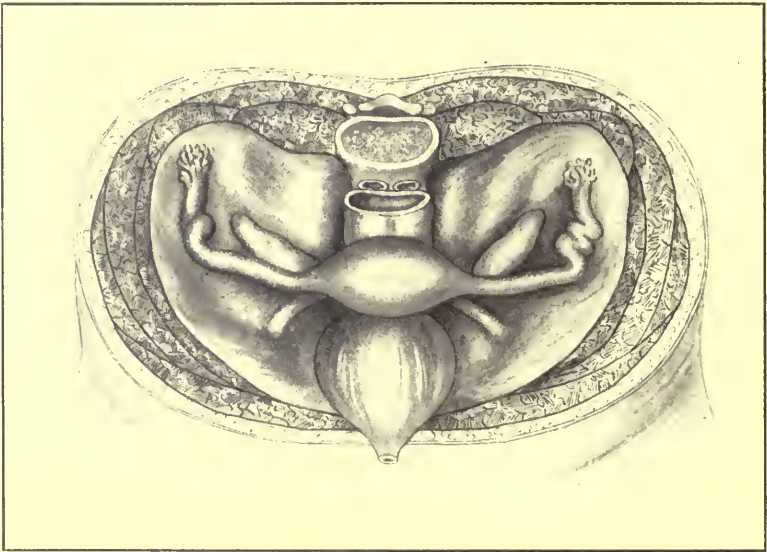


FIG. 206.—Pelvic Organs of a Female Infant at Birth. (After Bland-Sutton.) Showing elongated ovaries and the Fallopian tubes in close relation with the internal abdominal rings.

instituted in case a baby has not had a movement of the bowels within twenty-four hours after birth and in case there is incontinence of feces.

Prolapse of the Uterus.—Prolapse of the uterus in a new-born child is a rare condition. Ballantyne and Thompson (*Amer. Journ. Obstet.*, 1897, Vol. II., p. 35) reported eight cases from the literature and their own experience. The anomaly seems to be associated with lumbo-sacral spina bifida and rectal prolapse,—often with club-foot and sometimes with hydrocephalus, so that it may be

regarded as one of those congenital malformations that occur in children destined to have a short life. Two cases are on record of prolapse in girls of thirteen, due in one case to a persistent cough and in the other to carrying heavy burdens. I have myself seen a case of prolapse in a stout full-grown virgin due to a chronic diarrhoea with tenesmus.

Erosion of the Cervix.—Congenital erosion of the cervix is a condition that would hardly excite the attention of the general practitioner unless it were accompanied by a persistent vaginal discharge. In such an event it may be recognized by speculum examination of the vagina. Leopold first called attention to the occurrence of erosions in babies and children in 1872. Fischel (*Archiv. für Gynaekol.*, 1880, Bd. XVI., S. 192) found cervical erosions which he examined microscopically in four fetuses still-born at term, in two infants a few days old, in an infant fourteen days old, and in three infants three, four, and five weeks old, respectively. As a rule, the external os in these cases is found in the form of a narrow transverse opening amounting often to a split in the crown of the cervix. The opening is surrounded by a reddened, velvety area from three to four millimeters wide. Sometimes the eroded area extends higher up on the lateral surfaces of the cervix than on the anterior and posterior aspects, and in other cases the erosion is limited to the crown of the cervix where the cervix comes in contact with the posterior wall of the vagina. These observations of Fischel have been confirmed by later observers, notably, in our own country, by C. B. Penrose. He says ("Diseases of Women," sixth edition, p. 174):—"Erosion of this character has been found in a more or less marked degree in thirty-six per cent of new-born infants." It predisposes to erosion in the adult virgin and appears to be due to lack of proper development of the external os, so that the sharp line of demarcation between the squamous epithelium of the vaginal portion of the cervix and the cylindrical epithelium of the mucosa of the cervical canal is not formed, and the cervical mucosa appears on the crown of the cervix. The affection has no characteristic symptoms. In the girl of more mature years congenital erosion may cause a mucoid vaginal discharge, a sense of weight in the pelvis and perhaps backache. In this event the vagina should be inspected with a small Sims speculum, or a large Kelly cystoscope.

Precocious Menstruation and Precocious Maturity.—Genital hemorrhage in the new-born does not constitute precocious menstruation. A flow of one to five days' duration must recur at regular intervals and be attended by various feelings of discomfort analogous to those experienced by women at the catamenia, in order to be classed as *premature menstruation*. V. Gautier (*Rev. méd. de la Suisse romande*, 1884, IV., p. 501) reported twenty-four cases of this affection and Dr. John Lovett Morse (*Archives of Pediatrics*, 1897) had brought the number of reported cases up to thirty-five in 1897. In this series the first flow began all the way from one week after birth to the seventh year, and regular menstruation persisted from three months to five and a half years. Numerous cases have been reported since. *Precocious maturity* involves a rapid growth of the whole body in height and weight, also changes in the size and shape of the genital organs and mammary glands, the growth of hair about the genitals and in the axillæ, and regular menstruation. In older children who are instances of precocious maturity there is generally noted by the parents a marked predilection of the child for the opposite sex.

Menstruation is rarely the first symptom observed, in precocious maturity, but follows the changes in body development already noted. Gautier and Morse (*loc. cit.*) collected together fifty-seven cases of this condition and the literature has shown many instances since. Here is a case reported by C. Wischmann, of Norway (abstract in *Zentralbl. für Kinderheilk.*, 1904, 9, p. 46). The child was born September 4, 1899, and a discharge of blood from the genitals was first noted February 24, 1901. In the succeeding sixteen months twelve menstrual periods were observed. The child was large, the breasts were full, and the mammary glands well developed. There was hair on the mons veneris and in the axillæ. There were no evidences of rickets and there was no history of similar abnormalities in the family.

Dr. Morse, (*loc. cit.*) reported a case which I saw and examined for him on November 9, 1896, when the child was fourteen and a half months old. The facts in the case were briefly these:—The child was born August 29, 1895, and was said to have weighed fourteen pounds at birth. At that time her breasts were large and the baby was very fat in the neck. There was no history of early menstruation in the family except that the mother began to men-

struate at twelve. One previous child, a boy three years old, was normal in every respect. When two months old the mother noticed that the baby had the "whites" and that there was a little coarse hair on the vulva. On May 29, 1896, when exactly nine months old, a bloody vaginal discharge was noted. Weight then was twenty-eight and a half pounds,—breasts large, mons veneris prominent, and external genital organs well developed. A flow of three days, recurring each month, occurred regularly until she was examined November 9, 1896, and a leucorrhœa was noted

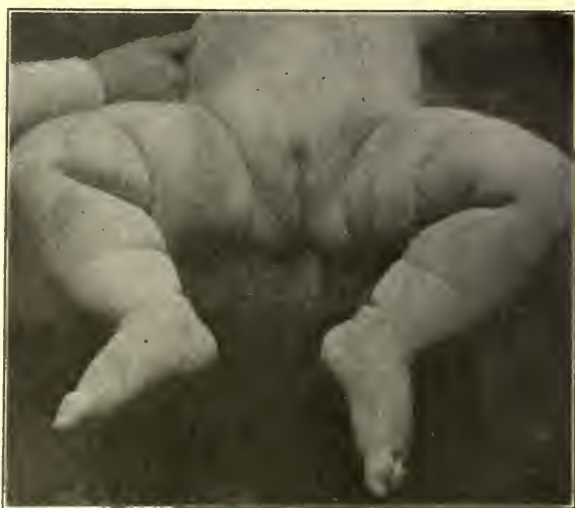

FIG. 207.—A Case of Precocious Maturity. Child fourteen and a half months old.

during the intermenstrual period. There were no evidences of immodesty or sexual feelings. Then her appearance was that of a child of three,—weight thirty-six pounds, height thirty-two and a half inches, two teeth, intelligence above the average, and could say several words distinctly and walked well,—a moderate growth of hair in the axillæ and on the back, breasts prominent and each contained a mass of gland tissue as large as a pigeon's egg, nipples well developed and surrounded by a dark areola and a little hair. Local examination showed: (I quote from my notes made at the time) "the labia majora well developed and meeting in the median line, a spare growth of light brown coarse hair on the

mons veneris and outer surfaces of the labia majora, labia majora well developed and of moderate size, clitoris normal, hymen with central opening dilatable, easily admitting my little finger, which is nine-sixteenths of an inch in diameter, for a distance of one and a half inches in the vagina, rugæ of vagina normal and cervix well formed, and of normal density. Vagina as large as that of a girl of six years."

DISEASES OF THE VULVA AND VAGINA

Vulvo-Vaginitis.—In discussing imperforate hymen and atresia of the vagina, vulvo-vaginal inflammation—more particularly the kinds of inflammation that attend the infectious diseases—has been referred to as a cause of atresia.

Simple Vulvo-Vaginitis.—Epstein has described a form of vulvo-vaginitis that is present in fetal life and continues after birth. It is characterized by an abundant, glairy mucoid and muco-purulent vaginal discharge, and by redness and excoriation of the genitals. In the secretion are found much epithelium, leucocytes, and many forms of bacteria,—notably the streptococcus and frequently the bacillus coli communis, but never the gonococcus. By the bacteriological examination this rare affection is distinguished from the common gonorrhæal vulvo-vaginitis. Many authors have described a non-gonorrhæal vulvo-vaginitis occurring in infants and children of all ages. It is due in some cases to masturbation. In these cases the discharge is more apt to be mucoid or muco-purulent than purulent—unlike the gonorrhæal form—and the disease is not so rebellious to treatment as in the case of gonococcus infection. Mendes de Leon (abstr. in *Jahrb. für Kinderheilk.*, 1908, Vol. 67, p. 253) thinks that the staphylococcus plays a rôle in the etiology of a simple vulvo-vaginitis in children and that this form of inflammation is contagious, as in the case of the gonococcus form.

Gonorrhæal Vulvo-Vaginitis.—Of late years, since the discharge coming from the genitals of children who are affected with inflammation in that region has been examined microscopically, the fact has become painfully apparent that a majority of the cases of vulvitis are caused by the gonococcus. Of course the gonorrhæal form is met more often in dispensaries and in hospital clinics than in private practice. Epidemics of the disease have occurred where

all cases started from one child, such as that in the Babies' Hospital in New York in 1902 reported by L. Emmett Holt (*New York Medical Journal*, 1905, Vol. 81, p. 521). Another evidence of indirect and accidental infection is an epidemic which occurred in the city of Posen, Germany, in 1890, when two hundred and thirty-six school girls aged from six to fourteen years, were taken ill with vulvo-vaginitis in from eight to fourteen days after using the same public bath-house, where, on account of limited accommodations, the children were required to bathe in the same tub. Sometimes the infection is intentional, due to the superstition prevalent among some of the ignorant classes, that a man may rid himself of gonorrhoea by giving it to a virgin.

According to the published statistics of dispensary services, the disease is most frequent in the new-born and during the first five years of life,—then it is frequent again just before puberty. There is reason to believe that in a good many cases the infection has been transmitted to the child intentionally. To show the frequency of vulvo-vaginitis among the children seen in out-patient clinics, we may cite those of the Mount Sinai Hospital in New York, as given by Sara Welt-Kakels (*New York Medical Journal*, 1904, Vol. 80, p. 689). During the ten years from 1893 to 1903 she saw 190 cases of vulvo-vaginitis, forming one and six-tenths per cent of all the children seen. In the Women's Venereal Department of the Johns Hopkins Hospital Dispensary, 139 cases of vulvo-vaginitis were seen among 1,366 patients, or ten and two-tenths per cent ("Medical Gynecology," p. 365). These, of course, were in venereal cases only. Most authors regard the frequency of vulvo-vaginitis among sick children as about one per cent.

The disease may be acquired from the mother during birth, and O. Heubner ("Lehrbuch der Kinderheilkunde," 1906, p. 502) has observed a case where an infant infected with gonorrheal ophthalmia subsequently became infected in the vulva, because of the carelessness of the nurse, and had a vulvo-vaginitis and a urethritis. This author thinks that in cases of vulvo-vaginitis in the child investigation will show that in many instances the mother will be found to have had a chronic leucorrhoea. The use of the same towels, linen, and sponges by several members of a family may be the means of spreading the infection and of course the soiled fingers of the nurse or the mother are accountable in many cases.

Symptoms of Vulvo-Vaginitis.—The symptoms of vulvo-vaginitis may excite little attention. In the case of a baby it may cry on passing water and an older child may complain of smarting on micturition. There may be itching or burning at the vulva so that the child scratches. In a few cases Bartholin's glands are swollen, but they do not suppurate. The inguinal glands may be swollen, but a bubo is not formed. If attention is called to the disease in its initial stage the body temperature will be found to be elevated. Often the mother brings the child to the physician because its linen is stained with yellow spots. In cases of long standing the child becomes pale and its general health suffers. The disease most often gets into the chronic stage before it is discovered and it runs a chronic course of weeks and months and is extremely rebellious to treatment. One author has reported finding gonococci in the discharges after the disease had existed for four years. W. J. Butler and J. P. Long (*Journ. Amer. Med. Assn.*, Oct. 17, 1908, p. 1301) state that in their experience in institutional epidemics of vulvo-vaginitis in children during ten years, the disease is quite as intractable to treatment as in adult women.

Diagnosis of Vulvo-Vaginitis.—On separating the labia the entire vulva is found to be red. It is wiped with a pledget of absorbent cotton and by pressure on the perineum from behind, pus—generally of a greenish color—comes from the vagina and the urethra. The physician should not introduce his finger into the rectum in cases of suspected infection of the genitals because of the very great danger of introducing infective matter in that organ. Cover glasses are prepared from the pus for microscopic examination as described on page 61. Usually the gonococci are easily demonstrated in the cells by the Gram method. The disease is differentiated from simple vaginitis by the bacteriological examination. Very rarely injuries of the vulva are found and only then are we justified in diagnosing rape. The inflammatory symptoms generally last from four to six weeks and the discharge changes from profuse purulent to scanty and mucoid as the disease progresses. The most frequent complication seems to be arthritis. Gonorrhoeal peritonitis has been reported as a sequel of gonorrhoeal vulvo-vaginitis by at least twelve different authors, therefore it may be regarded as a serious complication.

Tuberculosis of the Vulva.—Whether tuberculosis of the external

genitals is ever primary in those organs seems to be doubtful. Brüning, according to Langstein (Pfaundler and Schlossmann, "Diseases of Children"), collected forty cases in which the disease seemed to start in the tubes, and then affected in order,—the ovaries, uterus, vagina, and vulva. He is of the opinion that primary tuberculosis of the external genitals has not been proven because the diagnosis in the cases reported has been made clinically, whereas definite pathological proof of the absence of tuberculosis elsewhere in the body is necessary before deciding that the disease has originated in the vulva.

We are safe in saying that primary tuberculosis of the genital organs in children usually originates in the Fallopian tubes and from this situation is transmitted to the other organs of the genital tract. The disease is commonly secondary to tuberculosis of the lungs. In any event it is a rare affection. Secondary tuberculosis of the pelvic organs is seldom recognized in young children, the symptoms being masked by the symptoms of the primary pulmonary lesion. The appearances and the diagnosis are described in Chapter XXI., page 408.

Diphtheritic Vulvitis.—Diphtheria of the vulva, secondary to pharyngeal diphtheria, is an occasional disease of childhood. Several cases of primary diphtheria of the vulva have been reported. Jacobi (*Archives of Pediatrics*, Feb., 1891) reported firm occlusion of the vulva and vagina as a result of diphtheritic inflammation, and Hydrup-Pederson, according to W. A. Edwards, reported the case of a girl of fifteen, who during an attack of diphtheria passed a complete cast of the vagina. Later the child developed a marked atresia of the vagina which was cured by operation. Diphtheritic vulvitis is characterized by swelling, dark red discoloration, and the formation of a thick gray membrane covering, and adherent to the tissues. Constitutional symptoms of fever of moderate degree, anorexia, and pallor with loss of strength are present. The membrane separates from the underlying tissues in the course of a few days, leaving an ulcerated surface, and there is a foul-smelling vaginal discharge. The Klebs-Loeffler bacillus is found in the discharges or in smears made from the affected parts.

Gangrene of the Vulva, or Noma Vulvæ.—Gangrene of the vulva, a disease similar to cancrum oris, may attack the vulva (usually one of the nymphæ), in the case of dirty and underfed children,

or as a complication or sequela of measles, scarlatina, erysipelas, or typhoid fever. The disease is not so common as it was formerly, especially in hospitals, because of the improved hygienic surroundings and aseptic treatment. Noma of the mouth is often associated with noma of the vulva. For instance, Gierke reported thirteen girls in his hospital service in Stettin, with noma of the mouth, four of whom also had noma of the external genitals. Loeschner, in the babies' hospital in Prague, noted two cases of noma of the vulva among twenty cases of noma of the mouth. The disease begins usually as a livid red, indurated swelling of one labium, soon breaking down into dirty gray or dull red ulcerations and followed by a greenish-black layer of gangrene. The constitutional symptoms are severe and the disease, though rare, is a serious one.

Sarcoma of the Vagina.—Sarcoma of the vagina is by no means a rare affection in children. Although there are only forty or so authentic cases reported in the literature, there have been numerous cases of polyp of the vagina reported without microscopic examinations of the tumor. Now, polyp of the vagina is a morbid condition in children that is unknown to the pathologist. The known new growths of the vagina besides sarcoma are,—cysts, myoma, carcinoma, venereal warts, and the extremely rare primary chorioepithelioma. All of these except sarcoma occur almost always in adults, and this occurs in both adults and children. Pedunculated primary myoma of the vagina might be mistaken for sarcoma, but of the seventy cases of myoma reported only one or two occurred in the child. Edwards has been able to find no case of primary carcinoma in the child, but he cites two cases of primary chorioepithelioma of the vagina, in children thirteen and twelve years old, respectively. I think these should be viewed with suspicion as yet, until further observations have been made. Therefore we must consider the cases of vaginal polypi so frequently referred to in the literature as instances of sarcoma, until the contrary has been proven.

Sarcoma of the vagina in children generally develops in the first year of life and is fatal within a year or two. In most cases it appears to be present at birth. Demme-Gränicher (L. Pick, *Archiv für Gynaek.*, 1894, 46, 218) reported the case of an infant in whom a nodule the size of a pea was found in the vagina at the time of birth. This showed no signs of active growth until the sixth year,

when it increased rapidly and the child died in the seventh year, of fibrosarcoma of the vagina. Other instances go to show that the disease may be latent just as in this case, so that should a tumor of the vagina be discovered, the practitioner will err on the side of safety if he removes it and submits it to a microscopic examination.

Sarcoma of the vagina is characterized by the development of a mass of vesicle-like polypi of a dark red (hemorrhagic) and pinkish-gray (translucent) color, arranged in racemose clusters. The first evidence of the disease is what appears to be a polyp similar to a mucous polyp of the uterus. This generally springs from the anterior wall of the vagina, though a certain proportion (perhaps a quarter of the cases) have been found on the posterior wall. This primary tumor, when it grows, proliferates rapidly in the form of the racemose polypi and soon fills the vagina. The base of the tumor becomes broader and infiltrates the vaginal wall, the disease tending to invade the bladder early,—probably because it begins in close proximity on the anterior vaginal wall,—then the cervix and uterus,—next the parametrial cellular tissue with the uterus (causing hydronephrosis), and finally the peritoneum. The disease progresses rather slowly, seldom extends to the rectum, and metastases to distant organs are infrequent. Therefore, prompt recognition and removal offer a good chance for permanent cure. Histologically sarcoma of the vagina may represent all the different varieties of sarcoma.

The diagnosis before the disease has progressed extensively is very difficult. A vaginal discharge in an infant, or the presence of any tumor in the introitus vaginae, should lead at once to an examination with a Kelly cystoscope, followed by the prompt removal of adventitious tissue for microscopic examination.

GENITAL HEMORRHAGES

As previously stated, hemorrhage from the vulva does not constitute precocious menstruation. Hemorrhagic disease of infants or children, or *hemophilia*, is an inherited taint characterized by bleeding on slight trauma or spontaneously from any of the cavities of the body that are lined with mucous membrane,—the nose, the mouth, the intestines, the stomach, and other organs. It is

generally not manifest before the second year and an attack of bleeding is usually accompanied by fever, and hemorrhage takes place from several situations. In *purpura* also, hemorrhage may take place from the genitals as well as from other mucous membranes. This disease is apt to occur in cachectic, rachitic, or anemic children and is commonly observed between the second and the tenth year. Here also fever is present and the bleeding is from several sources. These diseases have nothing to do with the disease about to be described.

Hemorrhage from the Vulva in the New-born.—The occurrence of this affection in infants who were not the subjects of hemophilia or purpura, was observed thirty-five times in ten thousand female children by Schulkowski, and Cullingworth saw thirty-two cases in children under six years of age. J. Zappert (*Wiener med. Woch.*, 1903, No. 31) had observed occasionally a bloody mucoid discharge from the vulva in new-born girls from the fifth to the sixth day after birth. There were no attending symptoms such as pain, and the discharge was of short duration, did not recur, and seemed to be entirely harmless. Zappert was enabled to examine a portion of a uterus from a child who had typical hemorrhage of this kind. The genitals appeared to be normal and there had been no previous sepsis. Microscopic examination of the portion of the uterus showed only excessive vascularity of the submucous tissue and extravasation of blood corpuscles from the dilated vessels, but an intact epithelium of the mucous membrane and an absence of all traces of inflammation,—an analogous condition, in other words, to the histological picture of the endometrium of the menstruating uterus in the adult. Like the swelling of the mammary glands often noticed in the new-born, this hemorrhage may be due to some physiological stimulation of the uterine mucous membrane.

In Schulkowski's observations the hemorrhage did not appear until the fifth or sixth day after birth and he considers that the cause of the hemorrhage is a physiological hyperemia of all the abdominal organs that is present soon after birth.

Hemorrhage from the Vulva in Little Girls.—J. Comby (*Traité des Maladies de L'Enfance*, 1897, p. 554) insisted that a local cause was to be sought for vulvar hemorrhages in little girls, and this view is in accord with the facts as to the post-climacteric hemorrhages. Although in the latter case investigation of the

genitals is usually attended by less difficulty, we should not be deterred from instituting a thorough examination in infants in case the bleeding is persistent, or recurs. Comby has noted hemorrhage from the vulva in children who are the subjects of vulvovaginitis and he cites A. Broca, Pourtier, Henoeh, Heinricius, and Graefe, each as having found prolapse of the urethral mucous membrane a cause of genital hemorrhage in the new-born. The frequency of genital hemorrhage in the course of infectious diseases may well be due to inflammation in the vagina or uterus in these cases. Henoeh noted hemorrhage in the case of "papilloma of the vulva or vagina." By this we should understand now, sarcoma of vagina or vulva, or possibly angioma, which has been reported by Sanger and others. Angiomatous tumors are said to degenerate rapidly and, in this event, might well cause bleeding.

Although a case of lipoma of the vulva in a five-months-old child (Quinn, *Bull. Soc. de chir.*, 1890, Vol. 16, No. 1) has been reported, it seems improbable that such a tumor could be the cause of hemorrhage. Carcinoma of the vulva and vagina is unknown in new-born infants, although a few cases are on record of the disease in older children.

Congenital erosion of the cervix, prolapse of the urethra, vulvovaginitis and its sequelæ, also sarcoma of the vagina and prolapse of the mucous membrane of the urethra, should be kept in mind by the physician as possible causes of a bloody vaginal discharge.

Metrorrhagia of Puberty.—The hemorrhages from the genitals that occur at the time of puberty may be of varied causation according to P. Hours (*Thèse de Paris*, 1908) who reported fifteen cases. He enumerates the following as causes:—Fungous endometritis following infection from the vagina, uterine new growths, diseases of the heart, liver, or kidneys, chlorosis, hemophilia, purpura, the eruptive fevers, and finally and most frequent, the general infections and toxemias. The possibility that the nervous system, governor of the menstrual function, may not become adjusted at once and that hemorrhage as well as scanty menstruation may occur in girls at puberty without discoverable lesion of the genitals, should be in the physician's mind. But, on the other hand, he should not sit with hands folded and let "Nature" work out the problem unassisted. The rational procedure in all cases of vaginal hemorrhage is to make a local examination and try to find the

cause at first hand. Even if no local cause is found, the physician will treat his patient more understandingly with the knowledge that she has no manifest lesion of the genitals.

MASTURBATION

Masturbation (from the Latin, *masturbare*, to pollute one's self) is a much commoner condition in children than is generally thought by the profession. We must distinguish two sorts,—(1) that occurring in infants, called by B. K. Rachford "Pseudomasturbation," (*Archives of Pediatrics*, Aug., 1907, p. 561) and (2) true masturbation, occurring in older children.

(1) **Pseudomasturbation.**—This has been described under the titles,—“Thigh Friction,” and “Infantile Masturbation.” It is accomplished generally by the child lying on its back, the thighs are flexed, crossed, and pressed tightly together, closely embracing the genitals. In this position the infant rubs its thighs together or makes up and down movements with its body. Sometimes it rubs itself against its mother, or the corner of the crib, or other foreign objects, seldom using its hands. The movements are evidently attended by pleasurable sensations, with nervous tension, excitement, flushing of the face, staring eyes and large immobile pupils, followed in a few minutes by perspiration, relaxation, contentment or exhaustion, and sometimes by sleep. This sort of masturbation occurs as early as the fourth month and the average age was sixteen months in the table of fifty-two cases reported by Rachford. He explains its early occurrence by the fact that the external genital organs in the girl are practically fully developed and endowed with physiological function at birth, whereas the internal organs of generation do not attain their full growth until the child is ten years old. Partly on this account and partly because the infant can have no sexual thoughts, he thinks this sort of masturbation should be distinguished from the masturbation of older children and adults. Of the fifty-two cases collected by this author by eighteen different reporters, forty-eight were in female infants,—therefore the affection may be said to belong to the female sex. This can be explained on the ground of the proximity of the openings of the urinary and fecal canals to the sensitive vulva, and to the

fact that the clitoris, being less protected by the labia than in the adult, is more exposed to excitation and irritation by necessary handling in the interests of cleanliness. A hyperacidity of the urine existed in more than half of the reported cases. Therefore, this must be considered as a cause. Intestinal worms, proctitis, adherent prepuce, and uncleanness must be reckoned as causative also. Heredity in the form of a neurotic inheritance, meaning an unstable nervous system in a poorly developed body, existed in three-fourths of the cases and L. Emmett Holt, in forty-six cases in his private records, was struck with the great frequency of masturbation in mentally defective children.

(2) **Masturbation in Older Children.**—In older children the practice of masturbation is more commonly found in boys than in girls. The example of other children is an important factor in establishing the practice, and when the habit is once formed it is hard to break.

As regards its effect on the child most authorities are agreed that it is deleterious, but not very serious in most cases unless practiced to excess. The vice is thought to be present in the nervously or mentally defective, and to accompany such conditions as a result and not as a cause. O. Heubner has noticed derangement of the heart in masturbating children, especially idiopathic hypertrophy with dilatation,—particularly of the left ventricle,—and irregularity of action during violent exercise. Masturbating children with strong bodies show fewer symptoms than those with weak bodies. Edwards (*loc. cit.*) says that masturbating children often do serious damage to the sexual organs, citing Bokai's case in which a girl of ten, who for a long time had practiced masturbation, for the same purpose had ligated the clitoris so tightly with a thread that the organ swelled up to the size of an Italian hazel-nut. The thread was removed fourteen days later and it became necessary subsequently to remove the hypertrophied clitoris with the thermo-cautery.

Sometimes children introduce foreign bodies into the vagina for purposes of masturbation, but this practice is not so common as in the case of adults. J. P. West, who has reported several cases, says: "A number of children who do not thrive after every care and attention has been given for every disease or trouble that could be found, will prove to be masturbators. I have seen many

illustrations of this and have been deceived not a few times by parents who were unwilling to acknowledge the practice of this habit in their child."

If a child is addicted to this vice the diagnosis is established only by observing the practice. Abnormalities of the genital organs and of the urine should be excluded by a local examination and by urinalysis before measures of treatment are instituted.

MALIGNANT DISEASE OF THE UTERUS

Recent investigation of the literature by W. A. Edwards (*Amer. Journ. Med. Sci.*, July, 1909) shows twenty-three reported cases of malignant disease of the uterus in children between nine months and fifteen years of age. Sixteen of these were primary sarcoma and seven carcinoma, three of the latter being cancer of the cervix. There were many varieties of sarcoma reported and the cases of sarcoma of both uterus and vagina where the point of origin of the disease was in doubt have been excluded in my summing up,—so also have been culled out a case of cancer of the abdominal organs and an encephaloid cancer in a young woman of eighteen. Therefore in the future it behooves us to be on the lookout for malignant disease even in the very young.

DISEASES OF THE OVARIES AND TUBES

Ovarian tumors are fairly common in children, especially the embryomata and cystadenomata. Bland-Sutton over ten years ago had collected one hundred cases of ovariectomy performed on children under sixteen years of age and Olshausen among one thousand seven hundred and sixteen ovariectomies has operated on children sixty-one times. Ovarian tumors, although found in infancy, become more frequent as puberty is approached. W. A. Edwards (*loc. cit.*) has recently collected forty-eight cases of malignant disease of the ovary in children fifteen years old or younger, the youngest being a fetus seven months old. Sarcoma of various sorts, or carcinoma was found in every case, sarcoma being the more frequent. There are many cases in the recent literature of primary tuberculosis of the tubes in children, and

also of gonorrhœal salpingitis from extension upward of the infection of vulvo-vaginitis. Some of these last cases are attended by general peritonitis of a severe type.

After the infectious diseases, as pointed out by Lebedinski, Skobansky, and others, there is a degeneration of the Graafian follicles of the ovaries just as there is degeneration in the other parenchymatous organs after these diseases. Therefore, the function of the ovaries is, for a time at least, more or less impaired by scarlet fever, typhoid fever, and diphtheria. Massin (*Archiv für Geb. and Gyn.*, 1891, XL., p. 146) showed that the uterus exhibited endometritis after typhoid fever, pneumonia, dysentery, and "relapsing fever"; but Jung (*Zentralb. für Gyn.*, 1904, XXVIII., p. 991), after an exhaustive investigation of gonococcus infection, thinks that the gonococcus from vulvo-vaginitis seldom lurks in the cervical canal in children.

Symptoms and Diagnosis.—On account of the small size of the child's pelvis there is an early ascent of an ovarian tumor into the abdomen; in fact, the ovaries are abdominal organs in the infant. Therefore, pressure on the bladder and rectum is rarely present in the case of ovarian tumors in the child. On the other hand, a relatively small tumor, owing to the limited room for expansion, causes marked disturbances of digestion and respiration. The child is easily fatigued and, if old enough to call attention to her discomforts, may complain of pain in the abdomen. The watchful mother notices an undue prominence of the abdomen and that the child's appetite is impaired and her breathing short.

The diagnosis of diseases of the ovaries and tubes in children is made by the bimanual recto-abdominal touch. It is well to first put the child in the knee-chest position and admit air into the rectum by passing a cystoscope or catheter through the anus. Great gentleness should be used in making the bimanual touch. Owing to the small size of the pelvis and the straightness of the sacrum in the child, a comparatively small tumor of the ovary may appear to be high in the abdomen and springing from the liver or kidney because of the small amount of space in the child's abdomen. An anesthetic should be used for the examination, perhaps only a few whiffs of ether or chloroform being given. Find first the position of the long cervix and short uterine body. In comparison to the body the cervix appears at first to be unduly

large. It is high in the pelvis. (See Figs. 204 and 206.) The ovaries are like little cucumbers with their long axes corresponding with the long axis of the Fallopian tubes and they are close to the pulsating external iliac arteries; also, the uterus being so high, the utero-sacral ligaments are arched in the shape of a bow and may be felt as guides to the ovaries. In the case of an ovarian tumor one ovary of course will be wanting. The cervix may be drawn down with a double tenaculum held by an assistant while the bimanual touch finds and determines the length, breadth, and thickness of the pedicle of a tumor, just as in the adult. (See Fig. 126, page 301.)

A discussion of the different sorts of tumors both of the ovaries and of the Fallopian tubes will be found in the chapters devoted to these subjects. Suffice it to say here that sarcoma of the ovary and tuberculosis of the tubes are rather more frequent in children than many of the other affections.

DISEASES OF THE BLADDER

Practically all the diseases of the bladder found in the adult are met with in children. The anomalies will be found in Chapters XXIII., XXIV., and XXV., pages 444, 457, 486. Here we will refer to some of the commoner affections. Prolapse of the mucous membrane of the urethra has been referred to in the section on genital hemorrhages.

To collect the urine of a female infant place a small cup over the vulva and hold it in place with the napkin. If the infant is placed upon a chamber regularly every ten or twenty minutes for a few hours and a cold compress is placed over the bladder, urine may generally be obtained. Catheterization with a soft-rubber catheter under aseptic conditions is a certain and reliable means of getting a specimen of urine.

The twenty-four-hour amount of urine in infants is relatively greater than in older children and adults. The urine is passed as often as twice an hour during the waking hours of the first two years of life, while during sleep it is retained from two to six hours.

Enuresis.—The involuntary voiding of urine, especially at night, is a fairly common affection. The consideration of this subject belongs to the domain of neurology rather than gynecology, as

the affection is due in a majority of cases to derangement of the nervous system. (See Chapter X., p. 154.) The involuntary discharge of urine is normal in the young infant and it becomes voluntary only at a later age and is dependent largely on the child's training. In most children the urine is controlled during the waking hours after the first year, but while asleep it may be passed in the bed as late as the second year, or even the third year, so that the loss of control during sleep should not be regarded as abnormal until the end of the third year.

During five years at the Children's Dispensary of the University Hospital in Philadelphia, Ostheimer and Levi (*Journ. Amer. Med. Asso.*, Dec. 17, 1904) found eighty-five cases of enuresis among one thousand, six hundred and fifty-seven new patients, or about five per cent. Townsend had one case of rectal polyp in a girl suffering with incontinence in which a cure was effected by removing the polyp. Ostheimer and Levi had a similar case in which cure was not obtained by removing the polyp. Kerley (*Bost. Med. and Surg. Journ.*, Vol. CLV., pp. 172-174) noted the presence of urine of a high specific gravity and hyperacidity in the subjects of incontinence and assigned, as causative in some cases, contracted bladder, adhesions of the prepuce, vaginitis, and thread worms. Suffice it to say here that in case of enuresis the genital organs should be carefully examined to rule out abnormalities.

Bacteriuria.—For the substance of this section I am indebted largely to Dr. John Lovett Morse's excellent article, "INFECTION OF THE URINE AND THE URINARY TRACT BY *BACILLUS COLI* IN INFANCY" (*Amer. Journ. Med. Sciences*, Sept., 1909).

Bacteriuria is a disease characterized by the presence of bacteria in exceedingly large numbers in the freshly passed urine, and by the absence of marked symptoms of an inflammatory process in the mucous membrane of the urinary tract. It must be remembered that the presence of bacteria in the urine in the course of an infectious nephritis, or in a general infectious disease, does not constitute bacteriuria. Bacteriuria is most common in infancy and is almost always due to the *bacillus coli communis*. Dr. Morse has seen fifty cases, over sixty per cent of them being in girls. Escherich, who in 1894 first pointed out the frequency of bladder affections in girls, observed that the *bacillus coli* was present fifty-eight times among his sixty cases.

There are, as a rule, no severe general symptoms in bacteriuria. There may be slight elevation of temperature and malaise. Frequent and painful micturition are not uncommon, and older children who are the subjects of this disease, often suffer from incontinence. The urine is uniformly cloudy, having the appearance of a bouillon culture of bacteria. The odor is foul and the reaction acid.

Etiology.—Theoretically, infection of the urine and the urinary tract may occur in three ways: (1) Through the blood (the hematogenous, or descending theory); (2) Through the urethra, (the ascending theory), and (3) Through the tissues between the intestines, the home of the bacillus coli, and the bladder (the transparietal theory). Without going into a detailed analysis of these theories it is sufficient to note that they indicate that the route of infection is not always the same. It seems reasonable to conclude, however, that in the majority of the cases in girls the infection is through the urethra, in a fair proportion it is transparietal, while it is occasionally hematogenous. Infection of the bladder is impossible while the mucosa is normal; therefore some lesion or abnormality of this membrane is a contributory cause.

Pathology.—Reddening or swelling of the mucous membrane of a whole or a part of the urinary tract with some desquamation of the epithelium, and, in some cases, evidences of degeneration of the lower tubules of the kidney, are the only pathological changes that have been observed in bacteriuria. The disease may be secondary to disturbance of the intestinal tract; often the determination as to whether the internal disturbance is before, or after the bacteriuria, is a difficult matter to settle.

Symptoms and Diagnosis.—In a majority of cases the symptoms are: elevation of temperature, restlessness, drowsiness, fretfulness, and signs of discomfort. Anorexia is the rule, and disorder of function of the gastro-intestinal tract is especially common. Vomiting is not unusual and the movements of the bowels are abnormal. Frequent and painful micturition may be present if there is a cystitis or urethritis, or tenderness in the kidney region if the kidney is involved. Often the staining of the baby's napkins yellow, by the turbid urine, first calls attention to the condition.

Examination of the urine shows the urine to be pale and uniformly cloudy, the cloudiness being due in part to the bacteriuria and in part to the presence in the urine of large numbers of pus cells.

Sometimes the urine has a gelatinous appearance. The odor may be normal, but it is generally foul. The specific gravity is not abnormal and the twenty-four-hour amount varies only with the amount of liquids ingested. The reaction is almost invariably acid and not infrequently strongly acid. The *Bacillus coli* does not decompose urea and thrives in an acid medium, though preferring an alkaline or neutral medium. The acidity of the urine being hostile to the growth of other bacteria, the *Bacillus coli* is usually found in pure culture. The urine usually contains less than one tenth of one per cent of albumin and under the microscope the sediment is seen to be composed largely of pus cells,—usually single, sometimes in clumps. Caudate, small round cells, and squamous cells in small numbers are present in many cases, but squamous cells are never to be found in large numbers, as they are in purulent inflammation,—probably because of the absence of the ammoniacal products of the decomposition of urea, which are the cause of the destruction and desquamation of bladder epithelium in inflammatory affections of the bladder. Hyaline, or fine granular casts are seen occasionally,—blood almost never. The disease has been confused with typhoid fever and with malaria.

Cystitis and Stone in the Bladder.—Cystitis, a true inflammation of the bladder, is now known to be of relatively frequent occurrence in female infants and little girls, though extremely rare in male infants. It is most often observed in the first three years of life. Stone in the bladder, on the other hand, occurs twenty times in the male to once in the female child. This is due, probably, to the short urethra in the female, offering not only opportunity for infection from without, but an easy escape for calculi from the bladder. Since Escherich called the attention of the profession to the frequency of cystitis in 1894, cases have been reported in the literature with ever-increasing frequency; probably many of these being cases of bacteriuria, however.

The three theories as to the route of the infective bacteria in their course to the bladder, ascending, descending or hematogenous, and transperietal, have been referred to in the discussion of bacteriuria. Cystitis is due in a majority of cases, just as with the last disease, to (*a*) the *baecillus coli communis* which reaches the bladder by any of the three ways, but generally through the urethra. It may be due to (*b*) the tubercle bacillus, and in this event the

process is almost always a descending one, the disease originating in the kidneys, or it is transmitted through the blood from the lungs or other focus. (c) Gonococcus infection of the bladder is a process ascending through the urethra; so is (d) a diphtheritic cystitis following diphtheria of the vulva. The infections from (e) staphylococcus, or (f) streptococcus are generally secondary to suppuration in the kidney, but may come by either of the other two routes.

Cystitis is present in some degree in practically every case of stone in the bladder, because the calculus inflicts trauma on the mucous membrane and thus makes possible infection; for, as we have stated previously, bacteria can not live in a bladder which is lined with a normal mucosa.

Symptoms and Diagnosis.—The child is restless, cries a great deal, is pale and weak, has loss of appetite, and the temperature is elevated. There are increased frequency of micturition and difficulty in passing urine, also colic in the abdomen, with tenderness on pressure over the bladder. The urine is generally acid, cloudy, and of strong odor. The sediment under the microscope is seen to contain much pus, free and in clumps, and many squamous epithelial cells from the bladder, also blood and bacteria. Through the cystoscope the mucosa is seen to be reddened, swollen, and covered with mucus. It may be excoriated and show ulcerations and clotted blood. In the tuberculous form there are fibrinous deposits on the surface of the mucous membrane and cultures made from the deposit determine the sort of bacterium present.

STONE IN THE BLADDER.—As already pointed out, this is rare in the female. There are certain parts of the United States where it is relatively common, such as Kentucky, Tennessee, Ohio, Virginia, and North Carolina. The calculi are mostly composed of uric acid. Next in frequency are oxalate of lime, and sometimes there is found urate of ammonium combined with uric acid.

The symptoms are sudden stoppage of the stream of urine during micturition, vesical tenesmus, cloudy and strong-smelling urine, and, in older children, pain in the bladder region on jumping or playing violently. The diagnosis is made by passing the sound into the bladder and noting the metallic click caused by bringing it in contact with the calculus.

Primary Tumor of the Bladder.—G. Hüsler (*Jahrbuch für Kinderheilk.*, 1905, Vol. 62, p. 33) has collected from the literature

three primary tumors of the bladder in female infants aged, respectively four, nine, and seven months; the symptoms being a sudden retention of urine followed by cystitis with bloody urine. One of the tumors was a spindle-celled sarcoma, another fibroadenoma, and the third of unknown character. In the same list with these three cases were eleven instances of tumor of the bladder in boys, showing the relative frequency of this rare disease in the two sexes.

Hematuria.—By hematuria is meant the excretion of urine containing blood. This affection is to be distinguished from hemoglobinuria, the discharge of blood-coloring matter in the urine. In the latter,—a disease caused by the toxemias and found especially in scarlet fever, also in measles, typhoid fever, erysipelas, and malaria,—the red blood corpuscles are not found by the microscope in the urine.

Blood in the urine is purely symptomatic and may be due to local causes, such as stone in the kidney or bladder tuberculosis, or tumor of the kidney; or to general causes, such as a hemorrhagic diathesis; and most frequent of all, infantile scurvy. The vagina as a source of blood must be excluded always by a local examination. The presence of blood casts in the urine is a sure sign that the blood comes from the kidney and the presence of casts of other sorts and renal epithelium points toward the kidney as a source. In these cases the blood will be found to be intimately mixed with the urine and clots are rare.

As early as 1889, Gee (*St. Barthol. Hosp. Reports*, 1889, Vol. XXV., p. 85) first called attention to bloody urine as often the only sign of infantile scurvy, and more recently J. L. Morse (*Journ. Amer. Med. Assn.*, Dec. 17, 1904) has insisted on the importance of this symptom in scurvy, reporting seven cases seen by him in the course of three years. He considers that hematuria may be the earliest symptom of infantile scurvy and therefore, for a time, the only symptom, and it is the most common cause of uncomplicated hematuria in infancy. J. P. Parkinson (*Brit. Med. Journ. of Chil. Dis.*, Feb. 1907, p. 37) has reported a case of infantile scurvy in a child eleven and one-half months old, in which hematuria was the only obvious sign of the disease until closer examination showed other signs.

There are a few cases on record of hematuria due to the administration of salicylate of soda by the mouth, notably that of

Marshall, which appeared in the *Lancet* for February 2, 1907, where a girl of ten had hematuria following the taking of small doses of the salicylate. Chlorate of potash, rhubarb, and strawberries have been known to cause hematuria.

DISEASES OF THE RECTUM

Attention has been called to imperforate anus and rectum in infants in the consideration of the anomalies, page 561.

Practically all of the diseases of the rectum found in the adult are found also in the child since, more particularly in recent years, the pediatricists have studied the affections in children. We shall mention here only the more common ones.

Prolapse of the Rectum.—A portion or the whole of the rectum may be everted through the anal orifice. The prolapse is said to be *partial* when the mucous membrane alone is extruded, and *complete* when all the coats of the rectum are involved. Rectal prolapse occurs slightly more often in girls than in boys. According to Bokai's statistics of 360 collected cases, 163 were in male and 197 in female infants. The affection is most frequent in children during the second and third years of life, probably because at this time the child is put on the chamber and straining,—particularly in those conditions in which straining is excessive, such as dysentery,—brings the intra-abdominal pressure more directly on the loosely fixed rectum. This is brought about by the lack of curve in the sacrum in the infant, thus permitting of more direct abdominal pressure from above, and less protection for the rectum from below and behind by the cartilaginous coccyx than is the case in the adult where the lower rectum is protected by the strongly curved bony coccyx.

Predisposing causes are wasting diseases, such as rickets and diseases of the intestine. Enteritis and proctitis, obstinate constipation, stone in the bladder, and whooping-cough have been known to stand in causal relationship to prolapse.

Prolapse usually occurs during the act of defecation. The physician notes a bright red tumor, covered with mucus and the size of a walnut, at the anus. It is generally easily reduced, but returns with each movement of the bowels, gradually increasing

in size. Sometimes the application of cold to the prolapse will cause it to go back. In the more extensive grades of prolapse the tumor may be the size and shape of a small potato—conical in shape, with the dimple of the opening of the bowel at its apex, similar to the external os in the case of uterine prolapse. The symptoms of prolapse besides protrusion are, loss of control over the action of the bowels,—shown by the baby's napkins being always soiled,—increased frequency of the action of the bowels, and, in cases of a severe grade, bleeding of small amount from the prolapsed mucous membrane.

Proctitis.—Inflammation of the rectum occurs in children as a part of inflammation of the rest of the large intestine, but may occur (rarely) alone. The causes are chiefly local, the most frequent being the use of irritating injections or suppositories, either to combat constipation or for the administration of drugs. Proctitis accompanies thread-worms and is found in cases of gonorrhœal vulvo-vaginitis from extension of the infection from the vulva, either spontaneously or by the introduction of the nurse's or mother's finger, or a syringe tube through the anus during the course of this disease. Both simple catarrhal and specific proctitis have been observed. (See Chapter XXVI., page 506.)

Fissure in Ano.—This is not very rare in children and is caused by the passage of large, hard fecal masses, or by the maladroit use of the syringe nozzle. The result of the injury of the mucosa of the anal canal is an irritable ulcer situated in one of the folds of the mucous membrane, pear-shaped or triangular in form, with its long axis in the long axis of the anal canal. Pain on defecation is the constant symptom. The child cries and resists every effort to have the bowels move, so that chronic constipation results. The pain may be referred to other parts in the neighborhood. The ulcer is felt by the well-anointed finger passed into the anus as a rough spot and it is seen by introducing a large Kelly cystoscope (No. 12) through the sphincter and inspecting the surface of the mucous membrane as it rolls into the lumen of the cystoscope as the instrument is withdrawn.

Incontinence of Feces.—Incontinence of feces is a symptom of prolapse of the rectum. It is seen in cases similar to incontinence of urine in children who are over three years of age, and may be associated with the latter affection. Fowler (*Amer. Journ. Obstet.*,

1882, XV., p. 984) mentions the case of a girl of thirteen years in whom incontinence of feces had persisted from infancy. In this case the sphincter ani was decidedly relaxed. A. Rivière (*Médecine moderne*, 1898, Vol. IX., p. 308) reports the case of a girl of twelve years, where incontinence, beginning at nine years, was due to chronic overdistention of the rectum. The rectum in this case was found to be greatly distended.

The cause of this affection is generally clearly an affair of the nervous system, just as in the case of enuresis. According to the reported cases it occurs more frequently in boys than in girls.

Incontinence of feces is found in cases of chronic wasting diseases, epilepsy, myelitis, and in injury to the lumbar portion of the spinal cord; also in meningitis, and occasionally in typhoid fever. In all cases not of manifest central nervous origin the sphincter ani should be examined as to its tonicity, and also a proctoscopic examination of the rectum should be made to detect overdistention and relaxation of that organ.

CHAPTER XXIX

THE MENOPAUSE AND OLD AGE

The menopause, p. 587: General considerations, p. 588. Anatomical and physiological considerations, p. 592; Anatomy, p. 592. Atrophic changes in the uterine organs, p. 594; Physiology, p. 595. Age at which the menopause occurs, p. 597. Premature menopause, p. 598. Delayed menopause, p. 601. The dodging time, p. 611. Phenomena of the menopause in body and mind, p. 612; Cardio-vascular system, p. 612, Hot flashes, p. 612, Tachycardia and high arterial tension, p. 613; The nervous system, p. 613; Sexual feelings, p. 614; Mental diseases, p. 615; The alimentary canal, p. 615; The nutrition, p. 616; Rheumatism, p. 616; The skin, p. 617. Influence of uterine diseases on the menopause, p. 617; Hemorrhages, p. 617; (a) Fibroids, p. 617; (b) Subinvolution, p. 618; (c) Endometritis, p. 618; (d) Polypi, p. 618; (e) Cancer of the uterus, p. 619; Displacements of the uterus, p. 620; Cystocele and rectocele, p. 621; Vaginitis and injuries of the vagina from coitus, p. 621; Eczema or pruritus vulvæ, p. 621; Vesical symptoms, p. 621.

Old age, p. 622: General considerations, p. 622: Effects of old age on the ovaries, p. 623; On the Fallopian tubes, p. 623; On the uterus, p. 624; On the vagina, p. 625; On the vulva, p. 625.

THE menopause (*μηνες*, menses, and † *παύσις*, cessation) sometimes called the change of life, or climacteric, the time when the catamenia cease, marks not only the end of the reproductive period in the life of woman, but it means also a change in the psychical as well as in the bodily make-up of the individual. It occurs in temperate climates after a period of from thirty to thirty-two years of menstrual life, between the ages of forty-five and fifty years. Then ensues a period of rejuvenescence of ten or fifteen years in which the woman, freed from the annoyances and disturbing influences attendant on menstruation and childbearing, settles into a more staid and less emotional form of life, when she devotes herself to the duties and problems that confront her without the demands on her strength that reproduction or preparation for reproduction entail.

As regards old age it becomes necessary at the outset to distinguish between the general application of the term to the latter part of life and that portion of it in which there are present distinct evidences of degeneration of body or mind. Perhaps the latter time is more accurately defined by the term senility. That some individuals maintain vigor of both body and mind even to advanced years, is common observation, so that placing a mark in

number of years for the beginning of senility is a manifestly difficult proceeding. The ancients said,—“*Ætas non annis sed viribus aestimatur.*” Nevertheless, Hippocrates placed the beginning of senility at fifty-six years; Daubenton, who lived in the eighteenth century, at sixty-three, and Flourens (“*De la longévité,*” 1854), some hundred years later, at seventy. Most authors adopt a conventional age of sixty as the beginning of the retrogressive changes of old age, and we will follow their lead.

THE MENOPAUSE

GENERAL CONSIDERATIONS

The term menopause, although signifying only the cessation of the menses, is, on the whole, the best we have to describe a complex condition. Whether the catamenia cease suddenly or by irregularly recurring periods scattered over a number of months or years, the stopping of the menses is only one symptom attending changes not only in the reproductive organs, but also in many other organs and in the system at large, these changes having their origin in a cessation of the function of the ovaries. The symptoms consist roughly of the following:—On the part of the uterus, hemorrhages and leucorrhea; the heart, palpitation and irregular rhythm; the arteries, increased tension and hot flashes; the nervous system, neuralgias, insomnia, depression of spirits, and nervous instability; the alimentary tract, dyspepsia, gastro-enteritis, and constipation; the kidneys, renal insufficiency; the skin, dermatoses; and the general nutrition, obesity, rheumatism, and anemia.

Among the savages, who lead an out-of-door life and are the least removed in their mode of existence from the animals, it would appear that the menopause occurs without any symptoms except the cessation of menstruation. (A. Currier, *Amer. Gyn. Trans.*, Vol. 16, 1891.) Among the civilized races, however, the more artificial the life the more likely the occurrence of one or more of the symptoms enumerated. In fact, the absence of symptoms during the change of life may be regarded as abnormal among women of all classes and conditions of life in civilized communities to-day. This should not be construed as meaning that the menopause is a critical time of life or that the gloomy views about this

period that obtained in ancient times, or even thirty or forty years ago, should be held true at the present time. For instance, Kisch ("Das klimakterische Alter der Frauen," 1874, p. 109), writing in 1874, gives the following table of gynecological affections he found in 440 women who complained of symptoms referable to the uterine organs, among five hundred women investigated, in many cases several diseases being found in one individual:—

	Cases
Menorrhagia and metrorrhagia in.....	286
Chronic metritis.....	79
Leucorrhœa.....	327
Prolapsus uteri.....	65
Ante- and retroflexion of uterus.....	52
Pruritus vaginæ.....	46
Vaginismus.....	12
Carcinoma uteri.....	3
Uterine polyp.....	5
Tumor of the breast.....	8

Tilt ("The Change of Life," E. J. Tilt, 1882, p. 143) has an even longer list of uterine diseases found in five hundred women, as follows:—

	Cases
Floodings, in.....	138
Leucorrhœa.....	158
Remittent menstruation.....	33
Vaginitis.....	4
Follicular inflammation of the vulva.....	10
Inflammation of the labia.....	4
Ulceration of the neck of the womb.....	9
Hypertrophy and inflammation of the womb.....	2
Prolapsus of the womb.....	5
Uterine polypi.....	4
Uterine fibrous tumors.....	4
Uterine cancer.....	4
Ovarian tumors.....	3
Milky or glutinous secretion of the breasts.....	2
Irritation and swelling of the breasts.....	14
Tumor of the breast, non-malignant.....	2
Cancer of the breast.....	1
Habitual deposits in the urine.....	49
Pain and difficulty in passing urine.....	9
Incontinence of urine.....	4
Haematuria.....	1
Erectile tumor of the meatus urinarius.....	2
Perineal abscess.....	2

The earlier writers believed that many maladies of serious nature were necessarily due to the menopause and this view is still held by many, not only of the general public, but by members of the medical profession. The reason is to be found in the absence of accurate diagnosis in the past. For instance, take the uterine disease, fibroid tumor of the uterus. We know now that these tumors are the cause of a very large number of cases of flowing at the menopause, and further that, unless there is surgical interference, the cessation of the menses in these cases does not come for several years after the time observed in women who have no uterine disease. Fibroid cases were formerly included in the statistics of the menopause, whereas now they are treated surgically so often and are generally recognized as fit subjects for operative treatment, that no one thinks of leaving them to the kind offices of nature unassisted. The early recognition of uterine cancer was an unknown branch of diagnosis fifty years ago and instances of flowing caused by this dread disease were classed as natural concomitants of the climacteric. Now we know that cancer is found most frequently in both sexes between the ages of forty-five and fifty-five and there is reason to believe that the disease has some association with retrogressive changes in the tissues.

At all events this holds true in the case of cancer of the breast where the atrophy of the tissues of the breast at the menopause is associated with the development of cancer in that organ. It is more than probable that the same may hold true of the uterus. Fibroids and cancer of the uterus are, therefore, truly diseases of the menopause, although the causative relations of the climacteric to these diseases is by no means proved, consequently they should be always in the mind of the practitioner while considering the case of a woman who is passing through this period of life. The point to keep in mind in this connection is that it is the uterine disease that causes the patient's ill health and not the time of life during which the disease manifests itself, in the same measure as regards the constitutional diseases. Tilt mentions in his table forty-nine cases of "habitual deposits in the urine." Now we look for faults in metabolism and a diminished ingestion of fluids to explain such deposits.

In a study of the menopause for the purpose of gaining an insight into its true nature, one considers first the physiology of the

change of life in a normal woman and then the points of departure from the normal. If such a thing were possible we should utilize statistics of the symptoms manifested by women having normal uterine organs when they are passing through the period of the change. Most of the figures given by writers on this subject, such as Brierre de Boismont, Kisch, Kehrer, Tilt, and Börner, are made up largely of women suffering with uterine diseases. Normal women do not apply to physicians for advice, and whatever symptoms they experience are not a matter of record, or are not subjected to expert analysis; therefore, most of our ideas must come from study of abnormal women and chiefly from those who are affected with uterine disease. The many variations in general health exhibited by women who are undergoing the menopause complicate an investigation into the phenomena and therefore hinder the sifting of cause and effect.

During the last twenty years, since abdominal operations on the uterine organs have become so common, frequent opportunities have presented for more accurate study of the condition of these organs during and subsequent to the menopause. Moreover, our knowledge of the artificial menopause, induced by the removal of the ovaries, has become very minute of late years, because of the unfortunate practice which obtained in the eighties and nineties of removing the ovaries for the cure of a variety of diseases of the nervous system, and also, since the era of aseptic abdominal operating began, the frequent sprayings made necessary by ovarian disease have furnished many examples.

In this chapter I shall approach the subject of the menopause from the standpoint of the gynecologist, citing first the opinions of the most eminent authorities and then my own views formed by reading the literature and by an analysis of one hundred and fifteen cases taken from my private case records of women who were between the ages of forty-one and fifty-nine years, who had either passed by the menopause or were passing through it, all of the cases being women who consulted me for uterine disease. No cases of myoma or cancer are included except a few cases of small uterine polypi which may have been of myomatous origin, and a few cases of cancer of the uterus which were several years past the menopause.

ANATOMICAL AND PHYSIOLOGICAL CONSIDERATIONS

Anatomy.—The ovaries are developed in the embryo from epiblast and mesoblast on the inner surface of the Wolffian bodies in close relationship with Müller's ducts, which eventually form the Fallopian tubes, uterus, and vagina. Most of the ovary is composed of cortex, which is made up of primary ova enclosed in primary follicles which lie in a delicate connective-tissue framework. At birth there are some one hundred thousand of these primary ova present in an ovary, over half of them disappearing before puberty is reached, and the rest developing into ripened ova in their Graafian follicles to be constantly diminished in number during the thirty or thirty-two years of sexual maturity by the repeated discharge of ova through the surface of the ovary, leaving it, as the years go by, with an ever-increasingly corrugated appearance.

After the ovum has escaped from the Graafian follicle there is formed, on the inner surface of the walls of the follicle, the corpus luteum, a wrinkled yellow membrane made up of polygonal epithelioid lutein cells, the yellow color being due to the lutein. If pregnancy supervenes the corpus luteum persists for a long time; if it does not, connective tissue takes the place of the lutein cells, the yellow color disappears, and the corpus is gradually absorbed.

When the menopause has been established the cortical zone of the ovary is diminished in thickness, the ova and their follicles disappear, and the ovary becomes progressively smaller in size and more shrunken in appearance as the connective tissue, of which it is now mainly composed, atrophies with the advancing years.

The office of the ovary is to furnish ova, and in addition it has an important influence on various functions of the body, chiefly the circulation of the blood, the nervous system, and the nutrition. The theory has been suggested by various observers that the ovaries are ductless glands like the thyroid and suprarenal glands and that they furnish an internal secretion. More recently the view has gained ground that this internal secretion is produced by the corpus luteum. This is not the place to discuss the various theories and the facts advanced to substantiate them. Suffice it to say that as yet we know nothing more than probabilities and these seem to me to be that the ovaries exercise their influence on the

system chiefly through the circulation, an argument in favor of the theory of an internal secretion.

The function of the thyroid gland seems to have some relation to that of the ovary, both being in sympathy as essential to the development and preservation of the genital organs, and yet opposed in certain respects, as shown by the enlargement of the thyroid at the menopause. Thyroid feeding produces excellent results in cretinism and in infantilism, and ovarian extract ameliorates the symptoms of exophthalmic goitre. Vinay ("La ménopause," 1908, p. 60) points out that in parts of Switzerland where goiters are common, many women develop these tumors for the first time at the menopause, but not before or after. The suprarenal glands have been found hypertrophied, or the seat of tumor formation, in cases of sexual precocity; and atrophy has been found associated with insufficient development of the genital organs, so we are led to believe that these organs have an intimate relationship with the ovaries.

Hegar likened the tubes, uterus, and vagina to the duct of a gland, the ovary. Disappearance of this gland results, as in similar processes in other glands, in disappearance of the duct also. So in the developmental stage of the organism the growth of the duct is related to that of the gland, and when in anomalies the ovaries are found absent, the tubes and uterus or the vagina are generally either defective or wanting. At the time of the menopause the atrophy of the ovary is accompanied not only by a cessation of menstruation, but by a shrinking of the tubes, uterus, vagina, and external genitals, all a slow process requiring a variable amount of time in different individuals, but always, in all probability, a series of months or years.

In the following case reported by J. C. Dalton (*Trans. Amer. Gyn. Soc.*, 1878, Vol. 2, p. 134), the ovaries one year after the menopause showed Graafian follicles in a state of degeneration, and no corpora lutea:—"A woman, forty-three years of age, of average bodily development, who had had one child twenty-one years before, died at the Charity Hospital, New York, February 7, 1877, of cerebral meningitis. Menstruation had ceased within a few days of one year before death.

"The uterus was empty, of medium size, and normal in appearance except for a constriction of the os internum, which was reduced to

an orifice two millimeters in diameter. The uterine mucous membrane was generally smooth and pale, marked only with a slight arborization of fine blood-vessels. The ovaries were somewhat undersized, and loose in texture. They contained a number of collapsed, empty, degenerate Graafian follicles with slightly thickened walls, presenting the appearance of having been long in an inactive condition. One ovary contained ten or fifteen such bodies, the other from fifteen to twenty. In the ovarian tissue there were also a few small, blackish stains, without definite structure. There were no normal Graafian follicles anywhere, and no corpora lutea in either organ."

In contrast to this case Puech (cited by E. Börner, "Die Wechseljahre der Frau," 1886, p. 8) found the ovaries of normal size in a woman three years after the menopause. In my own list of cases (Case No. 17, see table on page 605) I removed atrophic ovaries from a single woman forty-one years of age before the menopause had become established, although the patient had been in the dodging time for two years; whereas in Case 60, that of a married woman of forty-six, the ovaries were normal in size and appearance at operation one year after the beginning of irregularity of the menses. As a rule I have found the ovaries atrophied at operations performed on patients who have passed the menopause (as in Case 108) except in cases where the ovaries with their tubes were the seat of a chronic inflammatory process.

Atrophic Changes in the Uterine Organs.—During and following the cessation of menstruation retrograde metamorphosis takes place in the ovaries, the Fallopian tubes, the uterus, the vagina, and the external genitals, the process of atrophy of these organs requiring a variable amount of time in different individuals and proceeding with the same rate of speed in the different organs in no two patients alike. In the absence of definite demonstrable pathological conditions the atrophic changes should proceed from the ovaries downward, involving in progressive sequence tubes, uterus, vagina, and external genitals, and this, I think, is the rule. The tubes lose their lining epithelium and finally their lumen is closed and they become mere cords; the uterus becomes smaller in all its dimensions, its walls grow thinner, and the internal os is contracted and is often obliterated. The cervix generally atrophies before the body of the uterus, becoming shorter and thinner, but in women

who have regular sexual intercourse this may not be the case, and of course, if the cervix is the seat of old lacerations and chronic metritis, it may be the last portion of the organ to show atrophic changes.

When the menopause is well established the vagina, which during the change is apt to be hyperemic, becomes pale,—perhaps only in patches, while the rest is dark red; it is narrower and shorter and assumes a conical shape because the contraction is greatest in the upper portion. It loses its elasticity and the mucous membrane gradually is deprived of its rugæ, so that the walls become more friable and the surface smoother. Sometimes coitus in the case of an atrophic vagina causes excoriation, pain, and bleeding, and may be the source of impairment of the nervous balance of the patient. Laxity of the tissues of the vagina with atrophy of the muscular walls at the menopause favors prolapse.

The changes in the external genitals consist in loss of subcutaneous fat and in a gradual shrinking, but these transformations are so closely bound up with the nutrition of the system as a whole, that, although having their origin at the menopause, they are generally not marked until old age. Therefore, we seldom note absence of fat under the mons veneris and the labia pudendi until old age sets in, even in the cases of premature and artificially induced menopause. The condition here is not dissimilar to that in the mammae which atrophy at the menopause, the gland tissue being replaced by fatty tissue, which is deposited in abundance throughout the entire body, especially in its upper portions, at this time.

Physiology.—To obtain an understanding of the physiology of menstruation it seems to me that the menstrual-wave theory developed by Mary Putnam Jacobi ("On the Question of Rest for Women during Menstruation," 1878) and by William Stephenson (*Amer. Journ. Obstet.*, 1882, Vol. XV, p. 287) offers the best explanation. It is that menstrual life is associated with a well-marked wave of vital energy manifested by variations in the body temperature, in the daily amount of excretion of urea, and in the arterial tension, as demonstrated by the investigations of these authors. The highest body temperature, the greatest daily excretion of urea, and the highest arterial tension as registered by the sphygmograph occur at a period of five or six days before menstruation, and the lowest point of all three of these indices of

the vital processes is just after the cessation of menstruation. In other words, the woman's system is prepared by a gradual rhythmic process for menstruation and reproduction. We know that at the menstrual period the uterus, ovaries, tubes, and vagina pass through a phase of increased functional activity and engorgement that necessitates an increased blood supply to these organs. Accordingly the tributary arteries dilate and the arteries of the rest of the body, in obedience to the law of compensation, undergo a vaso-constriction, whence the slight drop in arterial tension noted by Stephenson in the radial pulse just before and during menstruation. The blood in the pelvic circulation is forced at increased pressure through the capillaries of the uterus, with a result that there is hemorrhage from the endometrium.

It is plain that anything that profoundly upsets the balance of blood-pressure upon which menstruation depends may cause either an increase in the flow or a diminution, or even cessation. This upsetting may come through the nervous system, as in the case of nervous worry or shock, or it may come directly through the circulation. Dr. Francis Hare (*Clinical Journ.*, Aug. 29, 1906) has reported a case where the inhalation of amyl nitrite immediately checked a normal menstrual flow, and in the olden days when our forefathers employed venesection as a universal therapeutic measure it is reported that blood-letting, in the case of a menstruating woman, was followed by the same result. In one case the blood was removed from the pelvis by vaso-dilation of the systemic arteries, and in the other by abstraction from the general circulation. The tonicity of the blood-vessels, of the portal system, that great reservoir of the body, must have an important influence on menstruation, and in the future we may look to see results of investigations on the circulation conducted to determine the causes of greater or less congestion of the uterine organs at the catamenia.

We may regard the time between menstrual periods not as a period of rest from preparation for reproduction, but as a marshaling of the forces which reach their acme just before the molimen, then, after a brief period of slack water, to rise again to high tide, with ever-recurring regularity of rhythm until the stimulus ceases to emanate from the ovary and menstruation and the capacity for reproduction are no more.

AGE AT WHICH THE MENOPAUSE OCCURS

All the statistics found in the literature as to the age of the beginning of the menopause are unsatisfactory because they include chiefly women having all sorts of uterine diseases as well as those afflicted with various other bodily ailments. Many of the statistics include the cases of premature menopause. For these reasons the available statistics do not represent fairly the average age of the occurrence of the menopause, at least among women who are not the subjects of uterine disease, for it is my belief that uterine disease is the principal cause of prolongation of the menstrual function. As long ago as 1869 E. Krieger ("Die Menstruation," p. 171) gathered the statistics of six authors, of which the following is a summary:—

Two thousand two hundred and ninety-one cases reported by Mayer, Tilt, Guy, Brierre de Boismont, Courty, and Puech.

Between the years	No. of cases	Percentage of all
36-40.....	272.....	11.87
41-45.....	595.....	25.97
46-50.....	940.....	41.03
51-55.....	334.....	14.58
Before 35 or after 55.....	150.....	6.54

In this list the greatest number of cases were the women who ceased to menstruate between the ages of forty-six and fifty. Tilt (*loc. cit.*, p. 26) gives an average age of 45.7 among 1,082 women observed in London and Paris, including the cases of premature menopause.

As regards the influence of race or locality on the time of the menopause we know so little from what sort of women the statistics were gathered, and the figures of different observers are so much at variance, that the only conclusion we are justified in drawing is that the age is somewhat more advanced in the women of the higher latitudes than is the case in those living nearer the equator; and in the Jewish race the menopause occurs relatively early in whatever part of the world the women happen to live. As an example of the variability of statistics concerning neighboring races leading a similar mode of life, we may cite the following:—

In a study of the menopause among the American Indians

Andrew F. Currier (*Trans. Amer. Gyn. Soc.*, 1891, Vol. 16, p. 274) found an average age of 47.2 among twenty-five Sioux Indians, and 53.4 among ten of the Cheyenne and Arapahoe tribes. He states (*loc. cit.*, p. 277) that among the Quapaws the child-bearing period ends at thirty-five to forty, whereas among the Crows and Assiniboines (*loc. cit.*, p. 278) the child-bearing period frequently continues until the forty-fifth year. Tilt gives a table of the comparative dates of the cessation of menstruation in different countries as follows:—France, Paris, 44, Rouen, 48.7; England, 46.1 and 47.5; Central Germany, 47; Denmark, 44.8; Norway, 48.9; Lapland, 49.4; Russia, 45.9.

Something must be assigned to the influence of heredity in the matter of the age at which the menopause is established. It has been my observation that the climacteric appears at about the same age in mother and daughter; that a late or an early menopause is a common characteristic in the women of certain families. My personal experience as to the average age has to do with an analysis of the records of eighty-eight cases of women between the ages of forty-one and fifty-nine who consulted me in Boston or New England, for uterine disease. (See tables, pp. 604–611). All cases of myoma, cancer of the uterus which manifested itself previous to several years after the cessation of the menses, and, of course, artificially induced menopause, are excluded. The average age of the menopause in these cases was 46.78 years. This may be considered as a fair average for women with uterine disease exclusive of fibroids and cancer, who live in New England, although a larger number of cases, both of those afflicted with gynecological troubles and of more nearly normal women, should be gathered and analyzed before arriving at definite conclusions.

PREMATURE MENOPAUSE

The cessation of the menses previous to the normal average time is known as premature menopause, but as variations from the normal are so frequently seen it will be convenient to consider as cases of this abnormality those which occur before the fortieth year. The important point to bear in mind in establishing the diagnosis is to be sure that a reasonable time has elapsed since the last menstrual period to make its recurrence in the future

seem improbable. Apprehensive patients often think the change of life is at hand upon the occurrence of a transitory irregularity in the menses.

A direct cause for the cessation of the menses early is to be found sometimes in (a) a sudden blow or fall, extreme fright, anxiety, or grief acting through the nervous system; (b) serious constitutional diseases, such as cholera, septicemia, the acute exanthemata, or poisoning by alcohol, phosphorus, mercury, arsenic, or lead; (c) diseases affecting the uterine organs directly, such as excessive lactation-atrophy of the uterus, steaming of the uterine cavity after the method of Pincus (see p. 286), or inflammations and tumors of the ovaries. Other factors which seem to stand in a causal relationship to an early menopause are rapidly succeeding pregnancies beginning early in life, and excessive venery. Some authors consider that the southern races who mature relatively young have the menopause correspondingly early; but others do not agree to this view and consider that there is no relationship between the age at which menstruation begins and the time of its cessation. Obesity, especially that form which is rapidly acquired, is a cause of an early menopause both in the opinion of A. Currier (*Medical News*, 1888, p. 173) and myself.

Although any of these causes may result in a permanent disappearance of the menstrual flow, we are by no means sure, as pointed out by Börner (*loc. cit.*), that ovulation is also abolished and that true cessation of the reproductive function has been established, and we may agree with him in the statement that many of the reported cases of premature menopause are to be regarded with suspicion because the absence of the menses for a sufficiently long period of time has not been observed and because an accurate gynecological examination eliminating the common causes of amenorrhea has not been made.

How causes in class (a) act to produce amenorrhea we do not know. It is probable that the general constitutional diseases act directly on the ovaries. We know that the exanthemata cause changes in the ovaries, as shown by Lebedinsky's examinations of the ovaries from cases of scarlet fever. (See Chapter XVII., p. 285.) C. Vinay ("La ménopause," 1908) has called attention to the frequency with which sclerosis of the ovaries is found in tuberculous individuals, and Slavjansky, according to Börner, found paren-

chymatous inflammation of the ovary in cholera, recurrent fever, and septicemia.

The destructive diseases of the ovaries originating either in those organs or in the neighboring organs of the pelvis, may well cause the menopause. The surprising fact is that they so seldom do cause it, for in cases of large cystomata of both ovaries where at operation no sound ovarian tissue can be discovered by macroscopic examination, the patients generally report that menstruation has taken place with more or less regularity during the growth of the tumors. We must assume in such cases that some functioning ovarian tissue has been preserved, even though it can not be easily discovered. We know that in ovarian transplantation from one individual to another, menstruation and ovulation continue as long as ovarian tissue is present, even though this tissue is not in its usual situation with reference to the uterus, and it seldom happens that destructive inflammatory processes completely eliminate all of both ovaries.

A recent writer (M. M. Stark, *Surg., Gynecol., and Obstet.*, Jan., 1910, Vol. X., p. 40) has collected from the literature the following fifty-nine cases of premature menopause, occurring between the ages of seventeen and thirty, all reported by reliable authorities.

Menopause at	Reporter	No. of Cases
17	Kisch.....	1
18	Stark.....	1
19	Frazer, Stark, 1 each.....	1
20	Dalton, Kisch, Stark, 1 each.....	3
21	Sehalit 1, Boismont 2, Courty 1, Stark 1.....	5
22	Mayer 2, Stark 1.....	3
23	Krieger, Walter, Stark, 1 each.....	3
24	Boismont, Stark, 1 each.....	2
25	Mayer.....	2
26	Montgomery 1, Mundé 1, Boismont 1, Stark 2.....	5
27	Tilt, Guy, Boismont, 1 each.....	3
28	Foster, Currier, Guy, Boismont, Stark, Courty, 1 each .	6
29	Mayer, Boismont, Courty, Napier, 1 each.....	4
30	Mayer 5, Tilt 10, Guy 1, Felty 1, Napier 1, Stark 1. . .	19
		<u>58</u>

The number of cases occurring between thirty and forty years of age is, of course, the largest. Börner (*loc. cit.*, p. 39) gives the following as a genuine case of premature menopause of unknown causation: "Mrs. H., now thirty-nine years old, menstruated

regularly after twelve years of age. Married at thirty-four and aborted twice in the course of two years. When she was thirty-six her husband, who had been seriously ill and for whom she had cared constantly, died suddenly. Her menses ceased on the second day of her period and although she saw slight traces of a flow twice subsequently at intervals of four or five months, there had been absolutely no flow for the past two years. The only symptom was mental depression. On local examination the vagina was somewhat shortened and contracted; the cervix thin-walled, soft and small, with a tear (one of the abortions was a rapid one at six months), and the uterus as a whole very thin-walled and almost membranous. The ovaries, of practically normal consistency, were freely movable but small in size."

DELAYED MENOPAUSE

The menopause may be said to be delayed when menstruation is continued beyond the fiftieth year.

An important point in diagnosing this condition is to distinguish between irregular hemorrhages and menstruation. In many cases careful questioning of the patient is necessary to bring out the difference clearly.

Are ovulation and fertility prolonged with menstruation? There are many cases on record of both menstruation and childbearing late in life, some of them most sensational and far too large a proportion founded on hearsay evidence rather than on the personal observation of the reporters. One of the earliest cases is that recorded by Pliny the Elder, of Cornelia, of the family of Scipio, who at the age of sixty bore a son who was named Volusius Saturninus. Fordyce Barker ("The Age of Women When the Capacity for Childbearing Ceases," *Phila. Med. Times*, 1874) pointed out that the eldest child of Cornelia was born in the year 163 B.C. and that Pliny was born in the year 23 A.D. and his "Historia Naturalis" was published about the year 77; therefore, at least two hundred years must have elapsed from the time of this extraordinary birth to the time when Pliny wrote. Pliny gave no documentary evidence and, as he was something of a romancer at best, we may class the case as a tradition and not as an observed fact. In the same way, if the cases in the literature are examined carefully

and the sources of information sifted, the facts generally rest on hearsay evidence. Take the case of Ann Woods who is said by Dr. Benjamin Rush "to have given birth to a child after she was sixty years old." In this case the evidence of the truth of the story rests entirely upon the assertion of the old woman herself who claimed to be ninety-six years of age when she called at Dr. Rush's home "to beg for cold victuals."

Dr. Fordyce Barker (*loc. cit.*) reports the following authentic case of late childbearing: "May 6, 1852, I attended a case of labor in St. Mark's Place, New York City, in consultation with the late Dr. Robson, of this city. The labor was normal but tedious and our patient was delivered of a daughter by the aid of forceps. This lady had been married twenty-seven years and this was her first pregnancy. After the birth of the child, the husband showed to Dr. Robson and myself a family Bible, in which the birth of his wife was recorded as having been May 5, 1801. July 3, 1853, Dr. Robson having died, I attended this lady in her second confinement. The mother and both daughters (now married) are still living."

John Davies (*Lond. Med. Gazette*, 1847, Vol. 39, p. 950) reported the case of a woman proved to be sixty-three years old by her baptismal certificate, who had a child when fifty-five years old. The child, a girl eight years old, the youngest of eleven children, was brought to see Dr. Davies. The mother had not menstruated since the birth of her youngest child and she thought that menstruation had begun early, when she was twelve or thirteen years old.

More remarkable still is a case reported by W. J. Kennedy (*Trans. Edinburgh Obstet. Soc.*, 1881-82, Vol. VII., p. 77) of regular menstruation and a child born at sixty-two, to a thrice-married woman, the mother of twenty-one children. The facts in the case are well authenticated, Dr. Kennedy having known the woman for ten years and attended her in her last labor, in November, 1880. Her husband, when applying to the parochial board for relief in 1879, stated that his wife was then sixty years old. She was born in October, 1818, and was first married in 1838, her husband dying after one child was born. By her second husband she had nine children, twins once, and two miscarriages, and by her third husband eleven children and one miscarriage. Her great fecundity outlasting the

normal limit and the regularity of childbearing are attested by the following table of the years when the last pregnancies occurred:—

Year	Age of Patient
1865.....	47
1867.....	49
1869.....	51
1871.....	53
1874.....	56
1878.....	60 miscarriage
1880.....	62

Apparently ovulation continues sometimes after menstruation has ceased, as attested by the following cases. Taylor ("Medical Jurisprudence," p. 736) reports the following: "A woman at forty-four had given birth to nine children. Then the menses were scanty at the regular periods for two years. They then ceased entirely for a year and a half and at the end of that time she was delivered of her tenth child. Therefore, conception must have taken place eight or nine months after the cessation of the menses."

R. G. Hann (*Journ. Obstet. and Gyn. of Brit. Empire*, 1902, Vol. II., p. 290) reports the case of a woman who in her forty-ninth year gave birth to her thirteenth child after a period of amenorrhea of three years following the birth of the twelfth child at forty-six. That ovulation may take place without menstruation the pathological finding of De Sinéty (*Progrès médical*, 1877, No. 23, p. 450) goes to show. He described the post-mortem appearances in a woman thirty-eight years of age who had never menstruated. The uterus consisted principally of cervix, as in the fetus, and the uterine cavity measured one and a half to two inches in length. The ovaries contained numerous corpora lutea.

I think we may assume that menstruation as well as ovulation occasionally lasts as late as sixty years. Kisch (*loc. cit.*, p. 27) cites a case of Brierre de Boismont as follows:—The woman menstruated first at twelve, was married, had several children, and continued to menstruate without interruption until sixty, after which she had an irregular show for four or five months. Raciborski (*idem*) observed in the Salpêtrière one woman who menstruated at fifty-seven, one at fifty-six, one at fifty-three, and two

at fifty-two. Tilt (*loc. cit.*, p. 26) gives the following list of his cases of over fifty years of age, including fibroids, cancer, and all diseases presumably:—

Age	No. of Cases	Age	No. of Cases
51.....	27	57.....	2
52.....	16	58.....	4
53.....	9	59.....	1
54.....	7	60.....	1
55.....	6	61.....	2
56.....	4		

In my own list of cases, from which fibroids were excluded, the menopause occurred at over fifty years as follows:—

Age	No. of Cases	Age	No. of Cases
51.....	5	54.....	2
52.....	2	55.....	2
53.....	1		

As before stated, it has been my observation that fibroid tumors cause a delay in the menopause. Often in these cases irregular hemorrhages take the place of menstruation and a most painstaking inquiry into the symptomatology is necessary to distinguish menstruation from hemorrhage.

LIST OF WOMEN BETWEEN THE AGES OF 41 AND 59 WHO WERE PASSING THROUGH OR HAD RECENTLY PASSED THE MENOPAUSE.

No.	Name.	Age.	Social condition.	No. of children and abortions.	Age when menses ceased.	Age when dodging began.	Length of dodging time.	Leading symptoms and diagnosis.
1.	A. B.	43	Mar.	6 ch. youngest	...	42½	6 mos.	Tachycardia, pruritus vulvæ, ovaries atrophied.
2.	J. B.	42	Mar.	1 ch. 17 yrs.	42	40	2 yrs.	Flowing, feeling of suffocation, uterine polyp, tubo-ovaritis.
3.	S. B.	43	Mar.	1 ch. 22 yrs.	43	42	1 yr.	Headaches, lacerated cervix and perineum, retroversion, uterus atrophic.
4.	R. K. B.	58	Mar.	No. ch. No. ab.	55	46	9 yrs.	Dyspepsia, tubo-ovarian abscess, under observation eleven years.
5.	E. J. C.	55	Mar.	1 ch.	...	52	3 yrs.	Neurasthenia, subinvolution, lacerated cervix, uterus atrophic 1 yr. 2 mos. after dodging.

THE MENOPAUSE.—(Continued.)

No.	Name.	Age.	Social condition.	No. of children and abortions.	Age when menses ceased.	Age when dodging began.	Length of dodging time.	Leading symptoms and diagnosis.
6.	N.M.C.	45	Mar.	1 ch. 13 yrs.	...	35	10 yrs.	Irritating leucorrhœa, vaginitis, uterus normal in size.
7.	J.E.C.	46	Mar.	6 ch. youngest 10 yrs.	45½	Eczema of knees, face, and arms, neurasthenia, relieved since menopause, retroversion, lacerated cervix and perineum.
8.	D. D.	42	Mar.	6 ch. youngest 7 yrs.	...	41	1 yr.	Frequency of micturition, lacerated cervix and perineum, prolapse.
9.	A.M.G.	55	Mar.	No. ch. No. ab.	44½	40	4½ yrs.	Flowing, retroversion, eczema of vulva.
10.	M.F.H.	49	Mar.	5 ch. youngest 8 yrs.	...	48	3 mos.	Retroflexion, subinvolution of vagina.
11.	M. H.	41	Mar.	3 ch. youngest 18 yrs.	...	40	5 mos.	Headaches, hot flashes, retroversion, lacerated cervix.
12.	E.G.H.	50	Mar.	2 ch. youngest 25 yrs.	48	46	2 yrs.	Indigestion, rheumatism, uterus atrophic, prolapse.
13.	A. K.	47	Mar.	3 ch. youngest 23 yrs.	46½	Hot flashes, lacerated cervix and perineum, through sphincter.
14.	L. L.	48	Sing.	No ch. No ab.	43	Pain in abdomen and back, frequent micturition, retroversion.
15.	G. M.	44	Mar.	1 ch. 23 yrs.	...	42	2 yrs.	Nervous invalid 23 years, tubo-ovariis for 23 years.
16.	M.C.M.	46	Mar.	No ch. No ab.	...	45½	7 mos.	Flowing, retroversion.
17.	D.L.M.	41	Sing.	No ch. No ab.	...	39	2 yrs.	Hysteria for many years, appendicitis, ovaries atrophic at operation.
18.	R.H.B.	56	Mar.	1 ch. 27 yrs.	50	Leucorrhœa, frequency of micturition, cystocele, hemorrhoids.
19.	A. S.	56	Mar.	No ch. No ab.	51	43	8 yrs.	Dyspareunia from erosion of fourchette, frequent micturition, atrophic uterus.
20.	L. S.	49	Mar.	7 ch. youngest 15 yrs.	...	48	2 yrs.	Hot flashes, dizziness, flowing, subinvolution, lacerated cervix.
21.	L. S.	51	Sing.	No ch. No ab.	50½	45	6 yrs.	Lifelong neurasthenia, retroversion.
22.	M. W.	41	Sing.	No ch. No ab.	41	39	2 yrs.	Neurasthenia, atrophic uterus.
23.	M.A.W.	48	Mar.	7 ch. youngest 17 yrs.	...	46½	1½ yrs.	Sense of prolapse, retroversion, lacerated cervix and perineum, ovaries

THE MENOPAUSE.—(Continued.)

No.	Name.	Age.	Social condition.	No. of children and abortions.	Age when menses ceased.	Age when dodging began.	Length of dodging time.	Leading symptoms and diagnosis.
24.	L. S.	45	Mar.	2 ch. youngest 10 yrs.	44	...	None	atrophic at operation, uterus not. Excitable, can't control herself, retroversion, atrophic uterus and vagina.
25.	K. M.	52	Mar.	4 ch. youngest 16 yrs.	48	44	4 yrs.	Flowing for 2 years of dodging time, hot flashes, stricture of urethra.
26.	M. L.	43	Mar.	6 ch. youngest 6 yrs.	43	Burning in vulva, retroflexion, lacerated cervix and perineum, caruncle.
27.	H. C.	51	Mar.	1 ch. 31 yrs.	51	46	5 yrs.	Asthma, heart disease, subinvolution, lacerated cervix, uterus still large 11 years later.
28.	N.F.L.	48	Mar.	3 ch. youngest 18 yrs.	...	47	1 yr.	Flowing, subinvolution, lacerated cervix.
29.	W. H.	50	Mar.	12 ch. youngest 7 yrs.	46	41	5 yrs.	Neurasthenia, retroflexed senile uterus, proctitis.
30.	E. C.	46	Mar.	No ch. No ab.	45	44½	6 mos.	Frequent and painful micturition, urethritis, debility.
31.	M.E.H.	57	Mar.	2 ch. youngest 37 yrs.	50	Hot flashes since menopause, depression, urethritis.
32.	M. I.	56	Mar.	8 ch. youngest 17 yrs.	49	...	None	Headaches, dyspnea with menopause, cancer of cervix, flowing for 6 weeks, ovaries and tubes atrophic at operation.
33.	J. S.	59	Sing.	No ch. No ab.	55	53½	1½ yrs.	Enlargement of abdomen, cancer of ovary (large cystoma).
34.	B. C.	45	Mar.	8 ch. youngest 6 yrs.	44½	43½	1 yr.	Pregnancy suspected, eczema of vulva, subinvolution, retroversion.
35.	O. L.	46	Mar.	No ch. No ab.	...	43	3 yrs.	Flowing, polypi in cervix.
36.	O.A.B.	46	Mar.	3 ch. youngest 24 yrs.	45½	Hot flashes, incontinence of urine, rheumatism, hemorrhoids, subinvolution.
37.	C. T.	46	Mar.	2 ch. youngest 12 yrs.	45½	Flowing for two months, retroflexion, lacerated cervix and perineum.
38.	M. R.	52	Mar.	2 ch. youngest 22 yrs.	...	51	8 mos.	Pain in thigh, retroflexion, polypi, proctitis, sciatica.
39.	J.G.B.	59	Mar.	3 ch.	50	Frequent micturition, retroversion, stenosis of canal.

THE MENOPAUSE.—(Continued.)

No.	Name.	Age.	Social condition.	No. of children and abortions.	Age when menses ceased.	Age when dodging began.	Length of dodging time.	Leading symptoms and diagnosis.
40.	G.P.P.	57	Mar.	4 ch. youngest 27 yrs.	50	Leucorrhœa, endometritis, cervix atrophic, uterine cavity 3½ inches.
41.	C.A.N.	52	Mar.	1 ch. 15 yrs.	...	51½	6 mos.	Indigestion, headaches, tubo-ovaritis, anemia.
42.	S. H.	56	Mar.	1 ch. 32 yrs.	48	47	1 yr.	Leucorrhœa 1 year, pain in groin 1 year, cancer of cervix, atrophic vagina.
43.	E. S.	57	Mar.	3 ch.	54	Vaginismus, headaches, cicatrix in perineum, lesion of central nervous system.
44.	C. D.	50	Mar.	4 ch. youngest 15 yrs.	49	Watery leucorrhœa for two months, cancer of cervix.
45.	A. J.	50	Mar.	5 ch. youngest 12 yrs.	43	...	None	Endometritis, uterus and vagina atrophic, hemorrhoids, leucorrhœa.
46.	E. H.	49	Mar.	44	Foul leucorrhœa for two months, cancer of cervix.
47.	M.A.S.	45	Sing.	No ch. No ab.	41	...	None	Cystocele and prolapse, cancer of ovary, breast, and liver later.
48.	M. N.	51	Mar.	8 ch. youngest 18 yrs.	43	Painful lump in abdomen for 6 months, colloid carcinoma of ovary, lacerated perineum, gradual cessation of menses.
49.	C. T.	55	Sing.	No ch. No ab.	52	52	3 mos.	Pain in vulva, urethral caruncle, senile atrophic uterus and vagina.
50.	H. O.	42	Mar.	No ch. No ab.	...	40	2 yrs.	Pain in bowels, tubo-ovaritis, lacerated cervix.
51.	M.A.R.	49	Mar.	2 ch. youngest 20 yrs.	43	Foul leucorrhœa for six weeks, cancer of cervix, prolapse 12 years ago.
52.	W.P.M.	52	Mar.	2 ch. youngest 26 yrs.	45	Ovarian cystoma with purulent contents, acute peritonitis.
53.	C.E.O.	49	Sing.	No ch. No ab.	...	48	3 mos.	Neurasthenia, retroversion, under observation 3 years.
54.	M. S.	44	Mar.	6 ch. youngest 5½ yrs.	43	Incontinence of urine, dizziness, dislocation of urethra downwards.
55.	E.J.S.	51	Mar.	4 ch. youngest 25 yrs.	50	49½	6 mos.	Headaches, flowing, retroversion, endometritis.
56.	N. H.	43	Mar.	No ch. No ab.	43	42	1 yr.	Hot flashes for first 6 months of dodging time, subinvolution.

THE MENOPAUSE.—(Continued.)

No.	Name.	Age.	Social condition.	No. of children and abortions.	Age when menses ceased.	Age when dodging began.	Length of dodging time.	Leading symptoms and diagnosis.
57.	M. E.	50	Mar.	2 ch. youngest 30 yrs.	45	Hot flashes, rheumatism, vaginitis, uterus atrophic.
58.	S. M.	57	Mar.	7 ch. youngest 17 yrs.	54	Sense of prolapse, subinvolution, vaginitis.
59.	J. P.	59	Mar.	5 ch. youngest 24 yrs.	50	Flowing at menopause, headaches before, pain in abdomen, lacerated cervix and perineum.
60.	J.A.A.	46	Mar.	4 ch. youngest 20 yrs.	...	45	1 yr.	Rheumatism, procidentia, lacerated cervix and perineum, ovaries normal at operation.
61.	C. B. Colored	48	Mar.	14 ch. youngest 17 yrs.	42	Flowing for six months, cancer of cervix, advanced.
62.	M. B.	58	Mar.	5 ch. youngest 28 yrs.	53	Flowing for one month, multilocular papillary cystoma of ovaries.
63.	M. B.	49	Mar.	6 ch. youngest 18 yrs.	48	48	4 mos.	Headaches, retroversion, lacerated cervix and perineum, pyosalpinx, ovaries normal at operation.
64.	M. C.	58	Mar.	7 ch. youngest 20 yrs.	40	Rheumatism, rectocele, cystocele, atrophic vagina.
65.	M. C.	45	Mar.	2 ch. youngest 10 yrs.	37	Occasional hot flashes, urethral caruncle.
66.	M. C.	48	Mar.	5 ch. youngest 8 yrs.	44	"Falling of womb" eight years, prolapse.
67.	J. D.	52	Mar.	6 ch. youngest 20 yrs.	42	Unable to control bowels, lacerated perineum through sphincter, polyp, urethral caruncle.
68.	S. J.	50	Mar.	2 ch.	50	48½	2½ yrs.	Tubo-ovaritis, uterus atrophied at operation, ovaries and tubes not, according to pathologist.
69.	M. J.	59	Mar.	1 ch. 31 yrs.	50	43	7 yrs.	Flowing during dodging time, abdominal tumor, lacerated cervix.
70.	B. L.	53	Mar.	10 ch.	49½	Painful micturition, urethritis, urethral caruncle.
71.	C. L.	49	Mar.	3 ch. youngest 22½ yrs.	45	42	3 yrs.	Scalding at vulva, eczema of vulva.
72.	A. L.	53	Sing.	No ch. No ab.	...	49	1 yr.	Painful defecation, hemorrhoids, partial atrophy of uterus.

THE MENOPAUSE.—(Continued.)

No.	Name.	Age.	Social condition.	No. of children and abortions.	Age when menses ceased.	Age when dodging began.	Length of dodging time.	Leading symptoms and diagnosis.
73.	F.J.M.	57	Mar.	No ch. 1 ab.	48	47	1 yr.	Hot flashes and headaches during dodging time, cystitis, proctitis, retroflexion.
74.	E.M.D.	42	Sing.	No ch. No ab.	...	42	3 mos.	Hysteria, hot flashes, retroversion, adherent prepuce, masturbation.
75.	M. M.	49	Mar.	1 ch. 14 yrs.	44	Flowing for one year, abdominal cancer, lacerated cervix and perineum.
76.	A. F.	50	Sing.	No ch. No ab.	47	...	None	Nervous headaches since menopause, hemorrhoids.
77.	A. F.	49	Mar.	No ch. No ab.	42	Tumor in abdomen for twelve years, dermoid ovarian cystoma.
78.	E. F.	56	Mar.	4 ch. youngest 22 yrs.	46	Yellow leucorrhœa for one and a half years. Tuberculosis of endometrium, ovaries and tubes atrophic at operation.
79.	S. G.	47	Sing.	No ch. No ab.	46	44	2 yrs.	Flowing two months, malignant adenoma of uterus, cervix and vagina atrophic.
80.	L. G.	48	Mar.	6 ch. youngest 14 yrs.	45	Flowing, polyp, subinvolution, lacerated cervix and perineum, cardiac disease.
81.	F. H.	46	Mar.	6 ch.	44½	...	None	Flowing for six months, uterine polyp.
82.	M. H.	53	Mar.	10 ch.	52	Pain in pelvis, dizziness, urethritis, cystitis, vaginitis.
83.	H. J.	45	Sing.	No ch. No ab.	45	Flowing, fungous endometritis.
84.	J. M.	49	Mar.	No ch. 1 ab.	...	47	2 yrs.	Flowing for two years, hyperplastic endometritis.
85.	M. M.	52	Mar.	1 ch. 25 yrs.	42	Painful and bloody micturition, stone in bladder, prolapse.
86.	M. M.	42	Mar.	2 ch. youngest 6 yrs.	40	Frequent micturition and bearing down, polyp, lacerated cervix and perineum.
87.	J.P.M.	52	Mar.	No ch. No ab.	50	Flowing for two years, adenocarcinoma of cervix.
88.	M. M.	55	Mar.	9 ch.	49½	Sense of prolapse, prolapse.
89.	D. O.	52	Mar.	12 ch. youngest 19 yrs.	44	No symptoms at menopause, retroversion, tumor of pelvis.

THE MENOPAUSE.—(Continued.)

No.	Name.	Age.	Social condition.	No. of children and abortions.	Age when menses ceased.	Age when dodinging began.	Length of dodinging time.	Leading symptoms and diagnosis.
90.	M.L.P.	55	Mar.	No ch. No ab.	50	48	2 yrs.	Indigestion, frequency of micturition, atrophic uterus.
91.	M. P.	58	Mar.	2 ch.	50	49	1 yr.	Incontinence of urine, tumor of vagina six months, malignant adenoma of vagina.
92.	A. R.	49	Mar.	6 ch.	44	Painful micturition, lacerated cervix and perineum, uterus atrophic at ether examination.
93.	H. D.	50	Mar.	7 ch. 6 ab.	48	Flowing for one and a half years, subinvolution, endometritis.
94.	J. G. S.	52	Mar.	1 ch. 20 yrs.	50	48	2 yrs.	Hot flashes for four or five years, lacerated perineum, intestinal catarrh.
95.	L. S.	45	Mar.	2 ch. youngest 10 yrs.	44	...	None	Hot flashes, urethritis, dislocation of urethra downward.
96.	L. S.	48	Mar.	7 ch. youngest 15 yrs.	...	47	1 yr.	Dizziness, pain in left side, subinvolution, lacerated cervix, endometritis.
97.	F.L.S.	49	Mar.	3 ch. youngest 16 yrs.	...	48	1 yr.	Frequent micturition, subinvolution, urethritis, eystitis.
98.	E. S.	47	Mar.	1 ch. 27 yrs.	...	45	2 yrs.	Flowing, subinvolution, polyp.
99.	J. W.	46	Sing.	No ch. No ab.	...	44½	1½ yrs.	Leucorrhœa, headaches, retroversion, vaginitis, old pelvic inflammation.
100.	L. R.	52	Mar.	3 ch. youngest 15 yrs.	50	Flowing for three weeks, lacerated cervix and perineum, polyp, fistula in ano.
101.	M.E.L.	52	Mar.	3 ch.	51	Prolapse, lacerated cervix and perineum.
102.	B. C.	56	Mar.	1 ch. 20 yrs.	51	Flowing for six months, cancer of body of uterus.
103.	M. C.	50	Mar.	9 ch. youngest 10 yrs.	...	49	8 mos.	Sense of prolapse, lacerated cervix and perineum, procidentia.
104.	M. D.	48	Sing.	No ch. No ab.	...	47	1 yr.	Flowing for one year, polyp.
105.	A. C.	49	Mar.	8 ch.	48	Sense of prolapse, lacerated cervix and perineum, prolapse.
106.	M. D.	54	Mar.	3 ch.	48	Can't control bowels, lacerated cervix and perineum through sphincter.
107.	J. M.	52	Mar.	10 ch. youngest 7 yrs.	50½	Prolapse, lacerated cervix and perineum.

THE MENOPAUSE.—(Continued.)

No.	Name.	Age	Social condition.	No. of children and abortions.	Age when menses ceased.	Age when dodging began.	Length of dodging time.	Leading symptoms and diagnosis.
108.	L. D.	46	Sing.	1 ch. 12 yrs.	44	Prolapse, lacerated cervix and perineum, uterus and ovaries atrophic.
109.	B. B.	54	Mar.	2 ch.	44	Leucorrhœa and sense of prolapse, cystocele and rectocele.
110.	M. D.	52	Mar.	No ch. 1 ab.	48	Flowing two and a half years, uterus large, spindle-celled sarcoma of ovary.
111.	C. N.	54	Mar.	7 ch.	47	...	None	Painful and bloody micturition two months, cancer of bladder.
112.	A. H.	48	Sing.	No ch. No ab.	45	Flowing for six months, cancer of body of uterus.
113.	M.E.T.	56	Mar.	2 ch. youngest 32 yrs.	50	No complaint except prolapse, lacerated perineum.
114.	M. M.	57	Sing.	No ch. No ab.	51	Acute obstruction of bowels, cancer of sigmoid.
115.	B. D.	54	Mar.	No ch. No ab.	44	Pain in abdomen, cystoma of left ovary, right ovary atrophic at operation.

THE DODGING TIME

Tilt and others have called the time from the beginning of irregularity of the menses to their cessation, the dodging time. In his 500 tabulated cases there was no dodging time in 137 women, menstruation stopping suddenly in these. The average length of the dodging time in 265 cases was 2.2 years. In my own list, data as to the length of the dodging time were obtained in 62 cases. Of these 8 had no dodging time and of the 54 remaining the average time was 2.2 years. However, of these the dodging time was surely completed in only 23 and in these the average was 2.8 years, the longest 10 years, and the shortest 3 months.

I think we should agree with Tilt that very little can be deduced as to the normal dodging time from these figures. Sudden cessation of the menses is of comparatively infrequent occurrence. In many of the women there was noted an alteration in either or both the quantity and the quality of the menstrual blood, also certain

phenomena such as hot flashes and nervous instability, previous to the beginning of irregularity of rhythm, so that the inference is justified that ovarian influence begins to fail before menstruation becomes irregular.

Two years and nine and a half months (2.8 years) represents the average duration of the dodging time as influenced by uterine or ovarian disease in my series of cases; hardly enough cases to warrant any weighty conclusions, however. We know nothing about the factors that govern a sudden or a prolonged menopause, and we have no means of knowing in any given case what the issue is likely to be.

We speak of the menopause being over, or passed, when the genital hemorrhages have ceased. Of course, this is not necessarily the case, for the changes in both the body (the uterine organs and the system at large) and in the psychical state of the individual that are peculiar to the menopause may be only begun when the menses cease. On the other hand, these general phenomena may precede the disappearance of the menses; therefore we might, perhaps, mark the beginning and the end of the climacteric by the appearance and the cessation of these phenomena, rather than by the stopping of menstruation.

PHENOMENA OF THE MENOPAUSE IN BODY AND MIND

Leaving for consideration in the succeeding section the influence of diseased uterine organs on the menopause, let us examine here the manifestations of the change of life in the other portions of the body.

Cardio-vascular System.—*Hot Flashes.*—Hot flashes, or flushes, are probably the most frequent and the most annoying of the symptoms of the menopause. In a well-developed hot flash the patient at first feels hot, some portion of the skin of the body, generally the face and hands, being suddenly filled with blood; a sort of exaggerated blush. Immediately afterward sweating occurs and finally the patient feels cold, the chilly sensation coming on either while the sweating is in progress or after it has ceased. The vigor with which these flashes seize the individual vary greatly in different patients and in the same patient at different times. Also the frequency of their recurrence varies from as many as ten

an hour in one case of artificial menopause, reported by Bland-Sutton ("Surgical Diseases of the Ovaries and Fallopian Tubes," p. 486) to an occasional irregular flash. No two cases are alike and there seems to be no definite relation between the sudden occurrence of the menopause and the severity or frequency of the flashes, except that in the case of the artificial menopause the flashes are generally more severe. Ordinarily the flashes are most severe in the beginning when the menses first become irregular and gradually, as the months go by, are less and less pronounced.

Tachycardia and High Arterial Tension.—Paroxysmal increase in the rapidity of the heart's action and a general high arterial tension have been observed in women at the menopause. These disturbances are, as in the case of the hot flashes, due to derangement of the vaso-motor nervous mechanism. They may be due to preëxisting heart disease, but occur in women who have no discoverable heart lesion. Stokes first called attention to them and they have been studied more recently by Kisch (*Berlin. klin. Woch.*, 1889), Fiessinger (*Journ. des Praticiens*, 1902, p. 802), Pawinski ("Tension arterielle dans la ménopause," *Acad. Med.*, 1904), and L. Williams (*Clin. Journ.*, March 3, 1909, Vol. XXXIII., p. 329). If we assume that a manometric reading of the pulse just before a normal menstrual period of 130 to 150 millimeters of mercury represents the highest average during sexual life (the lowest being about 110 millimeters just after a menstrual period) the manometer may show a blood pressure of 180 millimeters in the pulse of a woman who is passing through the menopause. The pulse feels bounding and full. The patient complains of palpitation, which is often especially annoying at night and is accompanied by smothering sensations. Sometimes in marked cases there is active dyspnea, the respiration becoming embarrassed at the least effort. The pulse rate may be as high as 150 or 160 a minute and sometimes it is also irregular, even in cases where organic heart disease can be absolutely excluded.

The Nervous System.—The phenomena of derangement of function of the vascular system that have been described already are undoubtedly caused by some unknown impairment of the nervous mechanism. Other indications of functional nervous disease are intercostal neuralgia, insomnia, ringing in the ears, loss of memory, suspicions, and change in character, especially by developing irri-

tability of temper. The small every-day annoyances assume exaggerated importance and become insupportable. Many women from being of a cheerful disposition become habitually sad and depressed. The thought is forced upon us that this state of mind is in part due to the gloomy views about the change of life that have been held by both laity and the profession in the past. To some women we can imagine that the knowledge that the child-bearing function is going, that she is becoming unsexed, is a dispiriting thought. If in addition sexual pleasures have been an important feature of her life the disappearance of these may be an added source of melancholy. Vinay (*loc. cit.*, p. 107) thinks that such a thought caused Mme. du Deffant to remark with regret, "Formerly, when I was a woman."

Neurasthenia is a common accompaniment of the menopause but, more often than not, does not originate at that time. Many nervous stigmata long existent, perhaps inherited but not noticed by either the patient or her physician, come to the fore at the change of life. Hysteria is developed sometimes at the menopause, but here in a majority of cases a careful sifting of the history will detect stigmata as having been present in the past.

Sexual Feeling at the Menopause.—This subject has been studied by Brierre de Boismont, Gueneau de Mussy, and other French writers. It would appear that there exists in many women an excess of sexual passion at the close of the menstrual life in not only the married but in widows and the unmarried. This is shown by platonic affections, by a morbid attraction for the opposite sex, young boys even being selected as the objects of lavish attentions, or by masturbation, nymphomania, or excessive lustfulness. Venereal desires become a positive obsession in some women and they may affect those who have not experienced them previously during their lives. Sexual feelings are apt to be manifest at the times when menstruation should occur and the seizures, which are of short duration, but perhaps often repeated, seem to replace the periods. They are accompanied often by hypochondria and melancholy. At the conclusion of the menopause sexual feeling generally disappears, though it may not. R. G. Hann (*Journ. Obstet. and Gyn. of British Empire*, 1902, Vol. II., p. 290) reports the unusual case of a woman, the mother of twelve children, who ceased to menstruate at forty-six years. Then all sexual feeling

was lost. Three years later she gave birth to her thirteenth child and sexual feeling returned with the first menstrual period.

Mental Diseases.—Many diseases of the nervous system are separated by such a delicate line from the diseases of the mind that their differentiation is often a matter of great difficulty. In the first place it may be best to state that there is no such thing as climacteric insanity in the opinion of such an authority on insanity as M. Craig, of the West Riding Asylum in England. Of the two hundred and twenty-two cases of insanity during the menopause occurring in the West Riding and Bethlehem asylums in ten years, (*Journ. of Mental Science*, 1894, Vol. XL., p. 236) between 63.3 and 68.6 per cent, respectively, were cases of melancholia. H. Berger, of Jena (*Monatss. für Psychiatrie u. Neurol.*, 1907, Bd. XXII., Ergänz. Heft 13), reports a similar conclusion from a series of fourteen cases which he has studied and a review of the literature, and this corresponds with the experience of most writers on mental disease that melancholia is most often observed at this time of life. The other diseases with their respective percentages observed by Craig were as follows:—

Mania, 15–18;	Weak-mindedness, 2–1;
Delusional insanity, 9–14;	General paralysis, 2–1.

He attributes an important influence to heredity in the causation of mental disease at this time, and points out that the menopause has a deleterious effect on preëxisting psychoses; therefore, from this point of view, we are justified in classing the menopause as a critical time of life. We must remember, however, that the patients who happen to be in the insane asylums during the climacteric years, are only a small proportion of all women of that age in the community, and that the causative agency of the menopause in producing mental disease is still most indefinite.

The Alimentary Canal.—Elsner found in the stomachs of menstruating women hyperchlorhydria that he attributed to hyperemia of the gastric mucous membrane coincident with the hyperemia of the uterine mucosa. At the menopause there is often found an atonic gastritis with hyperchlorhydria. Dyspepsia of one kind or another is frequently observed at the menopause, especially among American women where dyspepsia is such a common disease at all ages. Patients suffer with epigastric pain and heartburn two or

three hours after eating. There are acid eructations and sometimes vomiting and constipation. Gallard, according to Vinay, called attention to the penchant that many women have during the menopause for strong liquors and assigned part of the dyspepsia to an alcoholic habit. Chronic gastro-enteritis may be the cause of obstinate constipation which is common at the menopause. Puech found hematemesis as a vicarious menstruation in some of his women, but other authors do not mention it.

The Nutrition.—Obesity appears in certain young girls of a lymphatic type as they reach puberty. It is also often observed in women after prolonged lactation, and it is a very frequent concomitant of the menopause, either normal or artificial. The same increase in fat is seen in capons, oxen, and other castrated animals. Most of the fat is deposited in the panniculus adiposus of the anterior abdominal wall, over the breasts, the buttocks and the hips, and less in the limbs and face. The abdomen gets larger at the menopause both because of the excessive accumulation of adipose tissue in the anterior abdominal wall, and also because of the deposit of fat in the mesentery of the intestine and in the omentum, perhaps accompanying gastro-intestinal disturbances with chronic flatus. The increase in body size due to obesity at the menopause is seldom excessive.

Where loss of flesh accompanies the menopause, as it occasionally does, we look for some definite fault of nutrition. Anemia occurs at the climacteric especially in those women who have lost much blood as a result of uterine hemorrhages. There are pallor of the face and lips, shortness of breath on the slightest effort, indigestion, hemic murmurs over the precordia, and headaches and nervous irritability.

Rheumatism.—F. Neumann (*Med. Klin., Berlin*, 1908, Vol. IV., p. 407), physician to the baths of Baden-Baden where 3,158 women with joint disease (acute and chronic rheumatism of the joints, arthritis deformans, and gout) were treated in the seven years from 1901 to 1907, inclusive, notes the frequency of the association of chronic joint disease with the menopause. He has found that many women with chronic joint disease date the beginning of their ailment from the climacteric or the time just after it. He had seen forty-seven cases of this relation in the previous two years and a case where joint affections had been associated with the menopause artificially induced by castration. Whether the occurrence of

rheumatism at this time has to do with deficient elimination of waste products because of changes in the excretory glands of the body at the menopause, as assumed by many writers, is still *sub judice*. The urinary function seems to be impaired and deficient elimination with lithiasis occurs in some cases.

The Skin.—Pruritus and eczema are most common at the menopause and are frequently localized in the region of the vulva or anus. Urticaria and acne rosacea are not infrequently seen. Growth of hair, especially on the chin, the upper lip, and about the breasts, is sometimes observed at this time.

The diseases of the breasts have been considered in Chapter XXVII, page 531.

INFLUENCE OF UTERINE DISEASES ON THE MENOPAUSE

A certain relatively few uterine diseases originate at the menopause, such as injuries to an atrophic vagina from coitus, pruritus vulvæ, and prolapse. A large majority, however, have their origin long before the menses begin to be irregular, even though they may have previously excited little attention from either the patient or the physician.

Hemorrhages.—Let us consider first the pathological conditions which give rise to hemorrhages at the menopause.

(a) *Fibroids.*—The most frequent of these are fibroids of the uterus in situation either submucous or interstitial. The bleeding in such cases is apt to begin as menorrhagia occurring after the thirty-fifth year, gradually becoming greater in amount, and finally resulting in metrorrhagia as the patient enters the forties. Abdominal or pelvic pain may accompany the flow; it may be independent of it or it may be absent. Expulsive, labor-like pains are present sometimes when a submucous nodule is being driven out of the uterus. More often the uterus becomes atonic from the prolonged presence of the foreign body and the patient experiences no pain. The subject of fibroid tumors is described at length in Chapter XV., page 244. It is enough here to counsel a thorough local examination in the case of every woman who has excessive flowing at or about the menopause. We know that, although some fibroid tumors diminish in size and cause no symptoms after the

menopause has been established, the majority do not atrophy, and even if they do they are subject to a variety of degenerative changes that jeopardize the health or even the life of the patient. Not only that, but the change of life is delayed in the possessors of fibroid uteri and the loss of strength from prolonged and repeated hemorrhage, with its consequent anemia, constitutes a handicap from which many untreated women never recover. Others, hardier, the more rapid blood-makers, survive the drain on their vitality and are able to get back into good condition after a series of years of invalidism, and still others, the very tough sort who can stand anything, are not seriously incommoded.

(b) *Subinvolution*.—The next most frequent cause of hemorrhages at the climacteric is the condition known variously as *subinvolution* or *chronic metritis, with or without lacerated cervix*. In looking over my list of cases of women who were either passing through or had passed the menopause (see pages 604–611) I find the diagnosis of subinvolution or badly lacerated cervix noted in thirty-five of the ninety parous women in the list. Not all of these suffered with flowing, but it is plain that if the uterine muscle has been replaced by connective tissue or elastic tissue and has acquired an increased bulk because of these changes in its tissues brought about by chronic engorgement, the retrograde alterations in its structure which normally take place at the menopause are hindered, so that the organ can not shrink to the diminutive size found in old age under non-pathological conditions, except after a longer time and at the expense of disquieting local symptoms in the form of hemorrhages and leucorrhœa, and general symptoms as described in the last section.

(c) *Endometritis*.—Endometritis occurring under the varieties of fungous, polypoid, and glandular, is a cause of both flowing and leucorrhœa at the menopause in a considerable number of cases.

(d) *Polypi* were found in ten of the cases in my list and other observers have found these frequently during the menopause, some authors in the past alleging that they were due to the change of life. Endometritis so often accompanies subinvolution that in an analysis one can not separate the two. We must regard the disease as originating in some infection long before the menopause, but as becoming the cause of hemorrhage and leucorrhœa at that time because of the altered rhythm of the pelvic circulation. On account

of the decreased vitality of the uterine organs at the menopause the opportunities for the entrance of infection into the tissues are enhanced; therefore, it may well be the case that infections originate at this time in the uterine endometrium as they do in the vagina. My observation leads me to think that in most instances of endometritis at the menopause the disease is an exaggerated stage of a preëxisting endometritis.

(e) *Cancer of the Uterus.*—In looking up my cases of women who were passing through the menopause I found in addition to those in the list four who had flowing because of cancer,—two each of cancer of the cervix and of cancer of the body. There is no evidence to prove that the occurrence of cancer, except in the late stages of the disease, has any more effect on the menopause than subinvolution. As previously stated, cancer is a disease of the atrophic tissues. In my list of one hundred and fifteen cases there are seven cases of cancer of the cervix and three of cancer of the body of the uterus, all ten presenting no symptoms until the menopause had been well established for ten months in the shortest time, and eight years in the longest. Thus we have ten cases of cancer of the uterus first manifesting its presence after the menopause was over, as contrasted with four cases diagnosed in women of the same ages,—forty-one to fifty-nine,—during the menopause.

Before leaving the subject of hemorrhage at the menopause it may be proper to state that there are cases, although they are rare, in which no adequate explanation of flowing at the climacteric can be found either in the uterine organs or in the system at large. There is a probability, as suggested by Scanzoni long ago, that arteriosclerosis at this time of life, by rendering the blood-vessels of the uterus more rigid and friable so that they can not withstand increased blood pressure, predisposes to hemorrhage. Börner (*loc. cit.*, p. 42) reports the following case of unexplained climacteric flowing: "Mrs. R., aged sixty, had always menstruated regularly but profusely. She married at twenty-three and had three normal labors within seven years. She had always enjoyed good health except that she had a highly irritable nervous system. At forty-nine she suffered with a sudden and profuse flowing. Repeated local examinations failed to find any abnormality of the uterine organs and a general physical examination detected nothing

wrong with the circulatory system. Repeated hemorrhages at longer or shorter intervals produced such profound anemia that she was obliged to pass two entire winters in bed. Then, at fifty-one, the hemorrhages ceased and she became strong and well as before. Another examination of the uterine organs at this time failed to reveal any abnormality."

Displacements of the Uterus at the Menopause.—Displacements of the uterus at the menopause except prolapse are of minor importance. Retroversion is a condition of the uterus that may be regarded as normal after the climacteric atrophy has taken place. *Prolapse* : A uterus made heavy by subinvolution is more apt to sag down and to become prolapsed at the menopause than before because of the weakening of the uterine ligaments and the disappearance of the muscular wall of the vagina, coupled with a shortening and change in shape of the vagina at this time. The cervix becoming smaller and the upper vagina assuming a narrowed caliber and a conical shape, the cervix no longer enters the latter organ with its long axis at a right angle to the long axis of the vagina, but is a button at the upper end of the shortened, flabby-walled vagina.

Although only twelve of my one hundred and fifteen cases were affected with prolapse, the affection is common among the uterine diseases of the menopause. It occurs even in the virgin. Of this I remember having seen two cases. Börner (*loc. cit.*, p. 64) cites the following case: "Miss G. had passed the menopause about ten years before. She had been free from any sort of abdominal disturbances during her entire life. She was in good health, although incommoded recently by getting fat. Shortly before, she happened to be assisting in moving a chest, something she had done many times previously, when she felt suddenly a pain in the abdomen, and at once noticed a foreign body between her thighs. Soon after she consulted me and I found a total prolapse of the uterus and vagina while in every other respect the genitals were intact. The patient was a nullipara and had accordingly an uninjured, firm perineum; the vagina, already somewhat narrowed by senile shrinking, was absolutely free from those changes (hypertrophy, a dry leathery feel of some portions, etc.) which would have pointed to a proidentia of long standing; the uterus was already atrophied and was small, light and thin-walled, and the cervix was absolutely intact." Such a case must be explained by increased intra-abdominal

pressure coupled with the atrophic conditions of the uterine organs just described that favor prolapse.

Cystocele and **rectocele** are frequently found at the menopause because of the weakening of the vagina by atrophic changes in its walls; therefore the walls are more apt to become pouched during the climacteric than they are previously when the muscular and tendinous tissues of the perineum and vaginal walls are in a tonic condition.

Vaginitis and Injuries of the Vagina from Coitus.—A discussion of senile vaginitis will be found in Chapter XX., p. 365. Infection and inflammation of the atrophic vagina are not infrequently met during the menopause. The disease is more common, however, as a so-called post-climacteric phenomenon and will be considered under the diseases of old age. As previously stated, the non-elastic atrophic vagina may be excoriated or even torn as a result of coitus. Chadwick reported a case of this sort in which a woman forty-eight years old, who had not menstruated for about ten years, indulged in sexual intercourse after having refrained from it for four months, with a result that she had violent pain and profuse hemorrhage. Examination showed a recent tear an inch long in the upper third of the vagina, extending into the cellular tissues to a depth of half an inch. The vagina, on account of senile atrophy, was considerably shorter and narrower than in the childbearing period.

Eczema or **pruritus vulvæ** was noted eight times in my list of cases and I remember having found these affections rather frequently during the menopause in dispensary practice. They may occur at other times and they are more frequently met in the post-climacteric period,—in old age,—than during the menopause. Pruritus may be independent of any known pathological lesion of the skin of the vulva, and is thought often to be a local manifestation of a lesion of the general nervous system.

Vesical Symptoms.—Urinary symptoms were noted in twenty-three of my cases. The symptoms included frequent micturition, painful micturition, and incontinence of urine. A detailed analysis of the different diseases present is hardly worth while in such a small number of cases. The following were noted, however: urethritis, cystitis, dislocation of the urethra downward, and four cases of urethral caruncle. The menopause might act as a causative agent indirectly in producing urinary difficulties by the exaggera-

tion of preëxisting malpositions and traumatisms due to child-bearing, or through the atrophy of the labia pudendi and the labia urethrae offering more easy access of pathogenic bacteria to the canal of the urethra. In addition to the local causative agents the unstable equilibrium of the nervous system at the menopause is to be reckoned with when considering the function of urination. How much the derangement of function is caused by actual disease of the urinary organs, and how much by disorder of the general nervous system, we find most difficult to state in many actual cases in practice. My observation leads me to the view that the situation is the same with the urinary apparatus as with the uterine organs; that preëxisting disease, or impairment of function, causes a stormy change of life; that unsound organs which, while nourished by a well-equalized blood supply, cause only minor symptoms, under changed conditions cry out loudly. Therefore, let it be our aim to discover the abnormalities of the genital organs during the period of sexual maturity in the life of our patients and, by treating the diseases, help the patients to avoid many of the discomforts of the menopause.

OLD AGE

Bichat, writing in 1800, said: "The man who has reached the end of a long career dies in detail; his visible functions end one after the other." Woman apparently grows old faster than man and the exact reason can not be found. Women of tropical climes reach senility sooner than those of northern latitudes, just as the exuberance of vegetation in the torrid zones, after a season of forcing, comes to a climax and dies earlier than in the slower growth of the temperate regions. Hereditary predisposition of the individual to prolonged life, or to the longevity of certain functions of body or mind, must be considered in making a diagnosis and a prognosis in the case of any disease of advanced life. The menopause represents a phase of life which is introductory to old age. It is not, however, a part of old age, and, as has been said already in treating that period of life, is not to be credited with all the atrophic changes in the organs of the body which occur with advancing years. A good deal is said in the literature of the "post-climacteric phenomena." At the beginning of this chapter we

adopted the age of sixty years as an arbitrary point for the beginning of old age, and although some of the post-climacteric changes in the organs of the body must in single instances antedate this age, still this mark is as good as any other for our purpose.

This is not the place for a discussion of the alterations which take place, as a result of age, in the tissues and in the function of the heart and blood-vessels, the spleen, the thyroid and the suprarenal capsules, the nervous system, the digestive canal, the kidneys, the liver, the lungs, the skin, and the general nutrition. For an able exposition of these important considerations the reader is referred to Professor G. Rauzier's "Traité des Maladies des Vieillards," (Paris, 1909). Here it will be sufficient to call attention briefly to alterations in the structure and function of the genito-urinary system in old age. The senile changes in the breasts have been referred to in Chapter XXVII, page 531.

The Ovaries.—The ovaries are withered and have a cicatricial aspect, and finally shrivel to little knobs of connective tissue containing a few cysts in the outer portions where formerly was the cortical zone. Ovarian tumors not infrequently develop in old age and cases have been reported by many observers where cystomata developed after the age of sixty, notably those reported by Johnson¹ who operated on a woman sixty-four years old, Davis² at the age of sixty-five, Spencer Wells³ and J. Boeckel⁴ at seventy-three, Josephson⁵ at seventy-six, F. Terrier⁶ at seventy-seven, E. M. Owen⁷ at eighty, and John Homans⁸ at eighty-two years, four months. The last author (*Three hundred and eighty-four laparotomies*, 1887) in the course of two hundred and eighty-two ovariectomies, removed ovarian tumors from one woman aged seventy-two and three aged seventy-three years.

The Fallopian Tubes.—The Fallopian tubes are deprived of their lining epithelium, they shrink in all their dimensions, finally the lumen is obliterated, and they become mere cords of connective

¹ *Virginia Med. Monthly*, 1888, Vol. XV., p. 644.

² *Brit. Med. Journ.*, 1887, Vol. II., p. 1050.

³ "Tumours of the Ovary," 1888.

⁴ *Gaz. Méd. de Strasbourg*, 1896, p. 26.

⁵ *Centralblatt für Gyn.*, 1889, No. 47, p. 824.

⁶ *Progrès Méd.*, 1888, No. 24, p. 466.

⁷ *Brit. Med. Journ.*, 1888, Vol. IX., p. 38.

⁸ *N. Y. Med. Rec.*, May 5, 1888, p. 496.

tissue. Diseases of the tubes are extremely rare in old age. Chronically inflamed tubes necessarily can not undergo the retrograde changes as readily as healthy tubes. But, as a matter of clinical observation, diseased tubes generally cause symptoms during the childbearing period of life, exceptionally during the menopause, and almost never in old age.

The Uterus.—The uterus becomes lessened both in volume and in weight as a result of retrograde changes in its structure and only when chronic metritis during menstrual life has converted the muscular structure of the organ into connective tissue and elastic tissue is its volume greater than normal. Aran found that after seventy years the uterus diminished in length from $2\frac{5}{8}$ inches (68 millimeters) to $2\frac{1}{8}$ inches (57 millimeters) and in thickness from $1\frac{1}{16}$ inches (43 millimeters) to $1\frac{9}{16}$ inches (40 millimeters). According to his observation the weight of the organ diminished in the case of the virgin uterus from 45 grammes to 35 grammes, and in the case of the parous uterus from 70 grammes to 60 grammes. Ordinarily this amount of diminution both in dimensions and in weight is rather below the normal, and other observers, notably Arnal (Weinberg and Arnal, *Mém. Soc. Anatom.*, May, 1905), who found a senile uterus which weighed 11.5 grammes, have reported finding a smaller organ after atrophic changes are well advanced. The walls of the uterus are diminished in thickness and the cavity is reduced in all its dimensions. The cervix generally, unless hindered by lacerations and thickenings, withers more than the body of the uterus. The internal os of the senile uterus is commonly found closed, probably because of the disproportionate atrophy of the cervix, the os being stenosed either by a thin diaphragm or by the formation of a ring of sclerotic tissue formed in this situation. Guyon (Thesis, Paris, 1858) found the os closed in thirteen out of twenty cases he observed, and Arnal (*loc. cit.*) found obliteration in sixteen cases and a partial stricture in five out of forty-one cases. Occasionally the external os is found closed also. If the cervical canal is closed the uterus generally contains a variable quantity of mucus. I have known of two cases, neither of them due to cancer, in which the uterine cavity was converted into an abscess cavity. As a rule the atrophic uterine mucosa of the senile uterus is covered with a thick, yellowish-white mucus. The mucous membrane is thinned and contains in its structure, often, hemorrhagic areas or

small cysts, and its surface is wrinkled so that the appearance of hypertrophy is given to it.

Senile endometritis, which is sometimes present, has been described in Chapter XI., p. 183.

Cancer originates in the senile uterus,—more frequently cancer of the body, and less frequently cancer of the cervix,—the latter being a disease rather of the menopause. Any bloody vaginal discharge or a watery leucorrhœa in an old woman should arouse the suspicion of cancer in the mind of the practitioner, and should lead to a thorough local examination.

The Vagina.—The vagina, as was pointed out in the section of this chapter on the menopause, undergoes certain changes at the menopause which persist in old age, becoming more marked after the latter period of life is well advanced. The vagina is shortened, cone-shaped because of excessive atrophy in its upper portion, its walls are thinned and non-elastic. Later in life the diminution in caliber may be so great as to make coitus impossible. The atrophied, thinned mucosa may be the seat of inflammation. Senile vaginitis, which is described in Chapter XX., p. 365, is a very common affection and often results in adhesions. The symptoms consisting of a burning sensation in the vagina, dyspareunia, a feeling of weight in the pelvis accompanying a thin irritating leucorrhœa, are not characteristic. The diagnosis is made by a local examination.

The Vulva.—The vulva shows signs of marked atrophy in old age. The hair of the mons veneris and labia majora becomes gray and scanty. The fat under the mons and in the labia disappears gradually after the post-climacteric period of hypernutrition has been passed, and the labia become flabby and wrinkled so that they no longer come together firmly in the median line. Therefore the vulva gapes in varying degrees in different individuals, and the openings of the vagina and urethra are not so well protected from infection as in the younger woman. The mucous membrane of the vestibule is glassy, thin and smooth, and may show areas of ecchymosis.

Pruritus vulvæ (see Chapter X., p. 160) is a common affection, so are various dermatoses of which eczema is the most common. Kraurosis vulvæ may occur in the aged, and primary cancer has been found very rarely in the vulva at this time of life. [1]

INDEX

- ABDOMEN, auscultation of, 72**
cavity of, shape of, Fig. 86, 221
division of, into quadrants and indication of bony landmarks, Fig. 18, 65
gauze records of, 74, Fig. 20, 75
in late pregnancy, appearance of, 427
inspection of, 64
mensuration of, 74
 in case of ovarian tumors, 304
organs of, origin of tumors in, Fig. 129, 304
palpation of, 68
percussion of, 71
skin of, appearances of, 66
swelling of, in case records, 8
 in clinical history, 20
walls of, fat in, differentiated from ovarian tumor, 310
 fibromyoma of rectus muscle in, 310
 movements of, 66
with ascites, cross-section of, dorsal position, Fig. 132, 310
 lateral position, Fig. 133, 311
- Abortion, diagnosis of, 436**
etiology and frequency of, 437
inevitable, diagnosis of, 439
oxytoxic drugs a cause of, 437
partially or wholly completed, diagnosis of, 440
symptoms of, 438
syphilis, a cause of, 437
threatened, diagnosis of, 439
varieties of, definitions of, 436
- Abscess, anal, 514**
 submucous, 515
 appendiceal, differentiated from pelvic cellulitis, 196
 ischio-rectal, 515
 mammary, 542
 pelvic, 193
 mapped out by bimanual touch, 42
- Abscess, pelvi-rectal, 515**
 psoas, differentiated from pelvic cellulitis, 196
 sub-mammary, 542
 sub-urethral, differentiated from cystocele, 368
 from dislocation of urethra, 447
- Absence of any organ (see organ specified)**
- Acetonemia, odor of breath in, 61**
- Acetonuria, in extra-uterine pregnancy, 353**
- Acromegaly, attended by amenorrhea, 419**
- Actinomyces. See Salpingitis, actinomycotic**
- Acute diseases, a cause of sterility, 151**
- Address, in clinical history, 9**
- Adhesions, a result of pelvic peritonitis, 192**
 and incarceration of ovarian tumors, 315
- Age, in clinical history, 9**
- Alcoholism, a cause of sterility, 151**
- Alligator bladder forceps, Fig. 50, 105**
 rectal forceps, Fig. 62, 125
- Amenorrhea, 139**
 as a symptom of pregnancy, 419
 primary, 139
 secondary, 141
- Ammonia coefficient in vomiting of pregnancy, 435**
- Ampulla of Fallopian tube, Fig. 116, 285**
- Anal canal, anatomy of, 122**
 region, diagram of, Fig. 195, 515
- Anatomy of organ. See organ specified**
- Anemia, a cause of sterility, 151**
 in fibroid tumors, 258, 261
- Anomalies. See organ affected**
- Anteflexion. See Uterus, anteflexion of**
- Anuria, 156**

- Anus, abnormally small, 498
 abscess in, 514
 at third month of fetal life, Fig. 157, 392
 canal of, Fig. 150, 373, Fig. 191, 495
 east of, Fig. 192, 496
 cancer of, 526
 chancre of, 511, 512
 chaneroids of, 511, 512
 condylomata lata of, 512
 development of, Figs. 158-162, 395
 eversion of, for inspection of hemorrhoids, 502
 fissure of, 503
 gumma of, 512
 imperforate, 497, 561
 inspection of, 121
 lipoma of, 523
 mucous patches of, 511
 papilloma of, 522
 protrusion from, as a symptom, 158
 soft fibroma of, 523
 syphilis of, 510
 syphilitic ulcerations of, 512
 tuberculosis of, 513
 vaginalis, 393
- Anxiety, polyuria in, 485
- Appendicitis differentiated from salpingitis, 336
- Applicator, uterine, Fig. 37, 93
- Apprehension, a cause of polyuria, 485
- Arbor vitæ of cervical canal, 204, 209
- Areola, anatomy of, 421, 532
 primary, 421, 532
 secondary, 426, 535
- Arnal, views of, on diminution in size of uterus in old age, 624
- Arterial tension, high, in menopause, 613
- Arteriosclerosis, menorrhagia in, 136
- Ascites, abdomen of, seen in profile, Fig. 131, 307
 differentiation of, from fibroid, 263
 from ovarian cyst, 308
 encysted, 308
- Auscultation of abdomen, 72
- BACKACHE, 18
- Bacteriuria in children, 579
- Ball, Sir Charles, case of absence of rectum, 496
- Ballantyne and Thompson, cases of prolapse of uterus in infants, 562
- Ballotement, external, 429
 internal, 427
- Barker, Fordyce, cases of late child-bearing, 602
- Bartholinitis, 409
- Bartholin's glands, abscess of, 409, Fig. 176, 411
 abscess of ducts of, Fig. 175, 410
 anatomy of, 391
 cancer of, 414
 collection of discharges from, 61
 cyst and abscess of, differential diagnosis of, 412
 cyst of, differentiated from enterocele, 371
 differentiated from hernia, 413
 cyst of left, Fig. 174, 409
 cysts of, 408
 lurking places in, for infection, 180
- Baudelocque. See Pelvis, conjugate diameter of
 cases of regular menstruation during pregnancy, 469
- Baumgarten and Poffer on acetonuria in extra-uterine pregnancy, 353
- Bearing-down feeling, 19
- Bender, X., and Lardennois, G., observations that fibroids may be invaded by cancer metastases, 255
- Berger, H., cases of melancholia at menopause, 615
- Bichat, observations on old age, 622
- Bimanual touch. See Touch, bimanual; also Palpation, bimanual
- Bladder, absence of, 457
 adenoma of, 483
 anatomy of, 101
 anomalies of, 457
 base of, showing diverticula, Fig. 185, 458
 calculus of, 162
 in children, 582
 cancer of, 483
 capacity of, measurement of, 109
 catheterization of, 108
 clonic spasm of, 109

- Bladder, contracted, a cause of frequency of micturition, 154
 contraction of, 461
 development of, Fig. 71, 198, Figs. 158-162, 395
 diseases of, 457
 in children, 578
 displacement of, downward, 461
 lateral, 462
 upward, 461
 distended, 459. See also Bladder, overdistended
 differentiated from large ovarian tumor, 314
 differentiated from small ovarian tumor, 300
 diverticulum from, 458
 double, 458
 eversion of, through urethra, 462
 exstrophy of, 459
 fibroma of, 483
 fistule of, 474. See also Fistula
 foreign bodies in, 463
 functional disturbances of, 151, 484
 hernia of, 462
 hypertrophy of wall of, differentiated from cystocele, 368
 inflammation of, 465
 irritability of, 485
 landmarks in, 103
 loculate, 458
 myoma of, 483
 new growths of, 480
 normal, laid open from the front, Fig. 51, 106
 overdistended, incontinence in, 154
 shape of, Fig. 84*a*, 217
 papilloma of, 482, Fig. 190, 482
 primary tumor of, in children, 582
 removing urine from, by suction apparatus, Fig. 55, 113
 rupture of, 460
 in retroflexion and incarceration of pregnant uterus, 432
 sarcoma of, 484
 stammering of, 109, 465
 stone in, 462, Fig. 186, 463
 in children, 582
 tuberculosis of ureteral orifice in, Fig. 187, 469
- Bladder, vagina and rectum ballooned by air, in examination of, Fig. 54, 112
 varicose veins of, 474
 varix of, 474, Fig. 188, 474
 wall of, drumming of, 465
 hypertrophy of, differentiated from cystocele, 368
 thickening of, a cause of stricture of ureter, 489
- Bladder phantom, Fig. 58, 118
 Bladder symptoms, 151, 484
 in case records, 7
 in clinical history, 20
- Bland-Sutton, case of frequent hot flashes in menopause, 613
 case of multiple seedling fibroids, 244, 251
 on hydatid fremitus, 299
 on myomatous affection of Fallopian tubes, 338
 on ovariectomy performed on children, 576
- Blood pressure in menopause, 613
 vessels, uterine and ovarian, Fig. 8, 47
- Bloodgood, J. C., classification of diseases of the breast, 536
 on sarcoma of the breast, 549, 551
- Blum, case of three mammæ, 538
- Boils of vulva, 407
- Bokai, case of ligation of clitoris, 575
 statistics of rectal prolapse in children, 584
- Boldt, H. J., views on severe grades of exfoliative cystitis, 468
- Bondi, J., on varieties of cysts of the labia minora, 413
- Bonney, C. W., cases of rupture of pyosalpinx, 333
- Börner, case of premature menopause, 600
 case of unexplained flowing at menopause, 619
 case of prolapse in virgin at menopause, 620
 is ovulation abolished with cessation of menstruation? 599
- Bowels, in case records, 8
 in clinical history, 21

- Bozeman dressing forceps, 83
 Bozeman-Fritsch uterine irrigator, Fig. 35, 92
 Brain, disease of, cause of incontinence of urine, 155
 Breast, absence of, 538
 adenocarcinoma of, 546
 with papilloma in the cysts, 546
 age changes of, 534
 anatomy of, 533
 areola of, anatomy of, 421, 532
 primary, in early pregnancy, 421
 secondary, 426, 535
 cancer of, 545
 cancer cysts of, 548
 differentiated from galactocele, 548
 colloid adenocarcinoma of, 546
 colostrum in, 427
 comedo-adenocarcinoma of, 546
 cyst of, simple, 540
 differentiated from cancer cyst, 541
 cystic adenocarcinoma of, 546
 development of, incomplete, 538
 diseases of, 531
 classification of, 536
 dissection of lower half of, showing milk ducts, Fig. 198, 534
 division of, into quadrants, Fig. 200, 538
 enlarged glands in axilla, a sign of tumor or inflammation of, 553
 enlarged supraclavicular glands in late cancer of, 554
 fullness of, a symptom of pregnancy, 420
 galactocele of, 539
 hypertrophy of, diffuse bilateral, 540, Fig. 201, 541
 in puberty, 535
 infantile, 539
 lactation, 535
 senile parenchymatous, 540
 in early pregnancy, 421
 in late pregnancy, 426
 infantile, 534
 inflammations of, 542
 lactation hypertrophy of, 535
 late cancer of, ecluxia in, 554
 Breast, late cancer of, discharge from nipple in, 553
 enlarged supraclavicular glands in, 554
 metastases to other organs in, 553
 signs of, 553
 skin metastases in, 553
 ulceration of skin in, 553
 lymphatic glands of axilla, enlarged in inflammation of, 553
 lymphatics of, Fig. 199, 535
 medullary carcinoma of, 546
 milk ducts of, 532
 neuralgia of, 539, 553
 nipple of, anatomy of, 532
 discharge from, in late cancer, 553
 discharge of blood from, 545, 546
 Paget's disease of, 548
 retraction of, 553
 of puberty, 535
 pain in, 553
 phantom tumor of, 539
 rheumatism of pectoral muscle in, 553
 right, vertical section of, Fig. 197, 533
 sarcoma of, 549
 scirrhous cancer of, Fig. 202, 547
 scirrhous carcinoma of, 548
 senile, 536
 supernumerary mammae of, 538
 symptomatic lesions of, 539
 syphilis of, 544
 tumors of, age as affecting, 550
 diagnosis in general of, 549
 duration of, 551
 early diagnosis in, 549
 history as affecting diagnosis of, 550
 mobility of, 552
 rare forms of, 537
 situation of, 551
 varieties of: adenoma, cystic, 545
 adenofibroma, 544
 cancer, 545
 average duration of life in, 545
 fibro-epithelial, 544
 myxoma, intraacinar, 544
 papilloma, intra-cystic, 545
 veins of, enlarged in early pregnancy, 421

- Brewer bivalve speculum, Fig. 26, 87
- Broad ligaments. See Ligaments, broad
- Burrage uterine speculum, Fig. 36, 93
used in packing uterus, 96
- CABOT, A. T., case of horny-celled cystitis, 470
- Calibrator, meatus, Kelly, Fig. 44, 101
- Campbell, R. P., on the diagnostic significance of spirochæta pallida, 407
- Canal, anal, Fig. 191, 495
- Canavan, M. M., case of ulcerative vaginitis in bacillary dysentery, 364
- Cancer. See Organ affected
- Cancer and fibroids, to be excluded from statistics on the menopause, 590
- Cantharides, a cause of cystitis, 467
- Capacity of bladder, 109
of pelvic cavity, 98
- Carcinoma. See Cancer and organ affected
- Caruncle. See Urethra
- Carunculæ myrtiformes, Fig. 165, 397
- Case-record system, 6
- Case-records, form for, 6
- Casper, on appearances of bladder by indirect cystoscopy, 117
- Catheter, bladder, long, Fig. 43, 101
ureteral, Kelly, Fig. 48, 103
- Catheterization in children, 578
of bladder, 108
of ureters, 115
caution against, 479
- Cauliflower growth. See Cervix, cancer of
- Causation of disease in any organ. See organ affected
- Cellular tissue, pelvic, anatomy of, 192
- Cellulitis, pelvic, 192
diagnosis of, 194
differential diagnosis of, 195
differentiated from appendiceal abscess, 196
from pelvic hematocele, 196
from pelvic peritonitis, 195
from psoas abscess, 196
from pyosalpinx, 196
from subserous myoma, 196
- Cellulitis, etiology and pathology of, 192
symptoms of, 193
- Cervicitis. See Endocervicitis
- Cervix, adenocarcinoma of, diagnosis of, 275
differential diagnosis of, 276
adenocarcinoma of canal of, 268
early stage of, Fig. 111, 268
anatomy of, 204
appearance of, in early pregnancy, 422
atrophy of, at menopause, 594
canal of, collection of discharges from, 62
cancer of, a cause of stricture of ureter, 489
cauliflower growth, 271
diagnosis of, 271
differential diagnosis of, 272
differentiated from erosion, 186
from fibroid, 265
early stage of, Fig. 110, 267
infiltrating, 272
squamous-celled, 267
early stage of, Fig. 110, 267
ulcerating, 272
- chancre of, differentiated from erosion, 186
- chaneroids of, differentiated from cancer, 275
from erosion, 186
- condylomata of, differentiated from cancer, 273
- elongation of, hypertrophic, Fig. 88a, 225
case of Huguier, 225
differentiated from prolapse, 229
false, 209
- erosions of, 184
cause of sterility, 150
differentiated from cancer, 274
from cancerous ulceration, 186
from chancre, 186
from chancroid, 186
from tuberculous ulcer, 186
from ulceration, 186
- follicular, 185
- in children, 563
- papillary, 185

- Cervix, erosions of, purple in color in early pregnancy, 422
 simple, 184
 with lacerations, Fig. 69, 185
 fibroids of, 247
 follicles of, hypertrophied, differentiated from cancer, 273
 gumma of, differentiated from cancer, 275
 hypertrophic elongation of, true, 225, 229
 inflammatory thickening of, differentiated from cancer, 273
 lacerated, a cause of hemorrhage at menopause, 618
 lacerations of, 204
 a cause of sterility, 150, 151
 bilateral, Fig. 79, 205
 with eversion of lips, Fig. 82, 208
 crescentic, Fig. 81, 207
 differential diagnosis of, 210
 etiology of, 204
 mechanism of production of, 205
 old, 209
 recent, 208
 results of, 206
 stellate, Fig. 80, 206
 unilateral, Fig. 83, 209
 mucous polypi of, differentiated from cancer, 273
 myoma of, differentiated from cancer, 273
 of purplish color in early pregnancy, 422
 papillary tuberculosis of, differentiated from cancer, 273
 removal of tissue from, for examination, 62
 sarcoma of, 280
 syphilis of, differentiated from cancer, 275
 tuberculosis of, differentiated from cancer, 273
 ulcer of, from papule, differentiated from cancer, 275
 simple, differentiated from cancer, 274
 from erosion, 186
 tuberculous, differentiated from cancer, 274
- Cervix, tuberculous, differentiated from erosion, 186
 Chancre. See Vulva, Vagina, Cervix, Anus, and Urethra, chancre of
 Chancroids. See Vulva, Vagina, Cervix, and Anus, chancroids of
 Change of life. See Menopause
 Chiene, ovariectomy on three-months-old child, 293
 Child, new-born, longitudinal median section of, Fig. 204, 558
 Childbearing, in case records, 7
 late, 601
 Childhood, gynecological affections of, 555
 Children, examination of, 556
 number of, in clinical history, 11
 Chlorosis, amenorrhea a symptom of, 419
 Cholemia, menorrhagia in, 135
 Chorioepithelioma. See Uterus, Vagina, and Tube, Fallopian
 Chromocystoscopy, 119
 Chute, A. L., case of infected diverticulum of bladder, 458
 Claisse, A., theory as to etiology of fibroids, 250
 Cleanliness in vaginal examinations, 28
 Climacteric. See Menopause
 Clitoris, Fig. 156, 389
 anatomy of, 390
 at third month of fetal life, Fig. 157, 392
 malformations of, 393
 prepuce of, adherent, 557
 Cloaca, Fig. 159, 395
 Clothing, loosening of, as preparation for examination, 24
 Clover crutch leg-holders, 57
 Cocecygodynia, 159
 in clinical history, 19
 Cocecyx, pain in, 159
 Coitus, barred by vaginismus, 379
 excessive, a cause of abortion, 437
 of cystitis, 467
 of sterility, 151
 injuries of hymen due to, 401
 of vagina due to, 376
 painful, 146
 through dilated urethra, 444

- Coitus, unnatural, a cause of gonorrhoeal proctitis, 510
- Collection of tissues and discharges, 61
- Colostrum. See Breast
- Colpitis, 361
- Combined vagino-abdominal touch, 38
- Comby, J., on vulvar hemorrhages in little girls, 572
- Complaint, chief, in clinical history, 7, 12
- Conception, factors essential for, 149
late in life, 601
without sexual feeling, 149
- Condylomata, acuminata and lata. See Vulva and Anus
- Congenital anomalies and malformations. See organ affected, anomalies and malformations of
- Congestion, pelvic, a cause of leucorrhoea, 145
of menorrhagia, 135
of sterility, 151
- Conjugate diameter of pelvis, 96
- Constipation, a cause of fissure in ano, 503
of hemorrhoids, 500
of retroversion, 236
in clinical history, 21
- Controller, current, Fig. 57, 117
- Cord, spinal, diseases of, retention and incontinence of urine in, 485
- Corpus luteum. See Ovary
- Craig, M., views on mental disease at menopause, 615
- Cryptomenorrhoea, 139, 140
- Cullen, T. S., on adenomyoma of uterus, 245
- Cullingworth on hemorrhage in the new-born, 572
- Cultures, method of taking, 62
- Current controller, Fig. 57, 117
- Curette, uterine, Fig. 31, 90
forceps, Emmet, Fig. 30, 89
- Curetting, dangers of, 93
technique of, 90
- Currier, A., on the menopause among American Indians, 588, 598
- Cylinder, vertical, likened to cavity of abdomen, Fig. 7, 45
- Cyst. See Ovary, Vagina, and Parovarium, cyst of
tubo-ovarian, 334
- Cystitis, 465
a cause of dysuria, 153
catarrhal, 467
chronic, hypertrophy of bladder wall in, differentiated from cystocele, 368
classification of, 466
cystoscopy in, 473
diagnosis of, 471
etiology and pathology of, 466
examination of urine in, 471
exfoliative, 468
in children, 581
palpation of bladder in, 472
symptoms of, 471
tuberculous, 468
ulcerative, 468
vesicular, 470
with cornified patches, 470
with yellowish plaques, 471
- Cystocele, Fig. 148, 366, 367
at menopause, 621
diagram of, Fig. 148a, 368
differential diagnosis of, 367
- Cystoscope, bladder, Kelly, Fig. 49, 104
ureter, Nitze, Fig. 56, 116
- Cystoscopy, direct, 110
electric, 117
indirect, 117
instruments used in, 99
removing urine from bladder by suction in, Fig. 55, 113
- DALTON, J. C., case of absence of corpora lutea in degenerated ovaries, 593
- Davies, J., case of late child-bearing, 602
- Davis, L., analysis of forty-five cases of bladder tumor, 481
- Deeidea, uterine, in extra-uterine pregnancy, Fig. 143, 344, 345
- Defecation, difficulty in, as a symptom, 158
- Deformed pelvis, 95
- Delayed menopause, 601
- Demme-Gränicher, case of fibrosarcoma of vagina in a child, 570

- Depressor, Hunter, Fig. 29, 88
- Diabetes, urine of, a cause of pruritus, 160
- Diagnosis of disease in any organ.
See organ affected and disease affecting
- Diameters of pelvis, 96
- Diarrhea in rectal disease, 158
- Digital examination of rectum, 123
of vagina, 34
- Digital exploration of uterine cavity, 94
- Dilatation of uterus, 91
- Dilator, urethral, double-ended, Fig. 45, 102
uterine, Hanks, Fig. 33, 91
Wathen, Fig. 34, 92
- Discharge, rectal, 157
in hypertrophic proctitis, 509
vaginal. See Leucorrhœa
in case records, 7
in clinical history, 18
- Diseases, constitutional, causing amenorrhœa, 141
- Döderlein, lactic acid, bacterium of, 355
- "Dodging time" of menopause, 611
- Dressing forceps, uterine. See Forceps
- Drumming of bladder, 109, 465
- Ducts, milk. See Breast
of Müller, 197, Fig. 71, 198
- Dudley, E. C., tables of differential diagnoses, 195-196, 308-309
- Dysmenorrhœa, 128
associated with pelvic lesions, 129
differentiated from abortion, 441
due to poor health, 130
membranous, 131, 172
neurotic, 130
obstructive, 129
with fibroids, 129
with malformation of uterine organs, 129
with no pelvic lesion, 130
with pelvic inflammation, 129
with retroposition and ante flexion, 129
- Dyspareunia, 146
in clinical history, 11
- Dysuria, 151
- EARS, ringing in, in menopause, 613
- Echinococcus cyst, differentiated from large ovarian tumor, 314
from small ovarian tumor, 299
- Ectopic pregnancy and chorioepithelioma. See Pregnancy, extra-uterine, and Chorioepithelioma, ectopic
- Edebohls vaginal speculum, Fig. 32, 91
- Edgar, J. C., on frequency of abortion, 437
- Edwards, W. A., views on adherent prepuce in the child, 557
on malignant disease of the uterus and ovaries in children, 278, 576
on masturbation, 575
- Elevated pelvis position, 58
- Emmet, T. A., views on dilatation of urethra, 448
on laceration of the cervix, 204, 207, 209
on pelvic circulation, 48
on vesico-utero-vaginal fistula, 479
on vesico-vaginal fistula, 475
- Emmet curette forceps, 89
- Endocervicitis, 184
definition of, 165
- Endometritis, a cause of hemorrhage at menopause, 618
of sterility, 150, 151
acute septic, 174
acute simple, 173
anatomico-pathological classification of 171
atrophic, 171
chronic simple, 176
decidual, differentiated from membranous dysmenorrhœa, 131
definition of, 165
exfoliative, 172
fungous, 171
glandular, 171
gonorrhœal, 179
acute, 180
chronic, 182
hyperplastic, 170
hypertrophic, 170
in old women, 183
interstitial, 171
not preceded by an acute stage, 177

- Endometritis, polypoid, 172
 post-abortum, 176
 pseudodiphtheritic, 172
 senile, 183
 tuberculous, 173
- Endometrium, anatomy of, 166
 before puberty, 168
 decidual modification of, Fig. 146, 352
 during pregnancy, 169
 following menopause, 169
 normal, Fig. 65, 167
 pathology of, 169
- Endoscopy, direct, 110
- Enterocoele of vagina, 371
- Enteroptosis, 67
 body pose in, Fig. 19, 67
- Enuresis, 154
 in children, 578
- Epilepsy, incontinence of urine in, 485
- Epispadias, 393, 445, 459
- Epstein on vulvo-vaginitis in children, 566
- Erosion of cervix. See Cervix, erosion of
- Escherich, on bladder affections in children, 579, 581
- Etiology of disease in any organ. See organ affected
- Evacuator, bladder, Kelly, Fig. 46, 102
- Examination, positions for. See Positions
- Exanthemata, menorrhagia in, 135
- Excision of tissue for microscopic examination, 62
- Exploration of uterine cavity, digital, 94
- External genitals. See Genitals, external
- Extra-uterine pregnancy. See Pregnancy, extra-uterine
- Exudate, pelvic. See Inflammation, pelvic
- FABRICIUS, case of myoma of vagina, 381
- Face, aspect of, in pregnancy, 420
- Facies ovarina, 294, 295, 302
- Fallopian tube. See Tube, Fallopian
- Family history. See History, family
- Fecal accumulation, differential diagnosis of, from ovarian tumor, 309
- Feces, character of, as a symptom of rectal disease, 158
 incontinence of, in children, 585
- Fenwick, E. H., on villus-covered and bald bladder tumors, 481
- Ferguson cylindrical speculum, 86
- Fetus, mummified, 345
- Fibro-cystic tumors of uterus, 253
- Fibroids. See Uterus, fibroids of
- Fibroma. See Uterus, fibroids of; also Ovary, fibroma of
- Fibromyoma of rectus muscle, 310
- Figure, the, in late pregnancy, 426
- Fimbriated extremity of tube, Fig. 116, 285
- Finger, examining, points noted by, 36, 40
 introduction of, into vagina, 35
 used as speculum, 36
- Fischel, on erosions of cervix in children, 563
- Fissure in ano, 503, Fig. 194, 504
 diagnosis of, 504
 differential diagnosis of, 505
 in children, 585
 symptoms of, 503
 syphilitic, differentiated from fissure in ano, 505
- Fistula, between bladder and extra-uterine fetation sac, 480
 between bladder and ovarian cyst, 480
 between bladder and pelvic abscess, 480
 blind internal differentiated from fissure in ano, 505
 entero-vaginal, 387
 in ano, 516
 complete, 516, Fig. 196, 517
 diagnosis of, 518
 blind external, 517
 blind internal, 517, Fig. 196a, 517
 symptoms of, 518
 recto-vaginal, 386
 recto-vesical, 480
 uretero-intestinal, 493
 uretero-uterine, 492
 uretero-vaginal, 386, 492

- Fistula, uretero-vaginal, differentiated from vesico-vaginal fistula, 478
 uretero-vesical, 492
 urethro-vaginal, 386
 vesico-intestinal, 479
 vesico-uterine, 479
 differentiated from vesico-vaginal fistula, 479
 vesico-utero-vaginal, 479
 vesico-vaginal, 384, 474
 diagnosis of, 477
 frequency, etiology, and pathology of, 474
 symptoms of, 476
- Fistulae, genital, diagrammatic representation of, Fig. 189, 476
 scheme of, Fig. 155, 385
 ureteral, 492
 vesical, 474
- Flashes or flushes, hot, 612
- Floor, pelvic. See Pelvis, floor of
- Flowing. See Hemorrhage
- Forepeps, bladder, alligator, Fig. 50, 105
 Emmet curette, Fig. 30, 89
 rectal, long alligator, Fig. 62, 125
 tenaculum, double, 85
 uterine dressing, Fig. 23, 83
 vulsellum, Fig. 25, 85
- Foreign bodies in any organ. See organ affected
- Fourehette, Fig. 156, 389
- Fowler, case of incontinence of feces in a girl of thirteen, 585
- Fränkel, function of the corpus luteum, 13
- Friedlander, C., doubtful case of primary tuberculosis of vagina, 365
- GAIT, the, in late pregnancy, 426
- Galactocele, 539
- Garciau, cases of primary ureteral tumors, 493
- Garré, case of five mammae, 538
- Gärtner's duct, cyst of, Fig. 154, 381
 diagram of, Fig. 120, 290
- Gautier, V., cases of precocious menstruation and precocious maturity, 564
- Gee, on hematuria a sign of infantile scurvy, 583
- Gellhorn, G., on development of hymen, 396
- General appearance, in case records, 8
- General health, in case records, 8
- General paralysis, retention and incontinence of urine in, 485
- Genital fold, Fig. 157, 392
- Genital hemorrhage in the child, 571
- Genital organs, development of, Figs. 158-162, 395
 external, at beginning of third month, Fig. 157, 392
 atrophic changes in, at menopause, 595
 development of, 392
 inspection of, 33
- Genital ridge, Fig. 157, 392
- Gierke, cases of cystitis with yellowish plaques, 471
 on noma of the vulva, 570
- Girls, little, vulvar hemorrhages in, 572
 young, examination of, 25
- Glands, Bartholin's, abscess of, 409, Fig. 176, 411
 abscess of ducts of, Fig. 175, 410
 anatomy of, 391
 cancer of, 414
 collection of discharges from, 61
 cyst of left, Fig. 174, 409
 cysts of, 408
 differentiated from enterocele, 371
 from hernia, 413
 differential diagnosis of cyst and abscess of, 412
 lurking-places for infection, 180
 Lushka's coceygeal, 159
 lymphatic, of breast, 533
 enlarged in cancer, 553
 mammary. See Breast
 Skene's, anatomy of, 101
 collection of discharges from, 61
 lurking-places for infection, 180
 thyroid, function of, 593
- Gonococcus, characteristics of, 179
 in cervical canal in children, 577
 infection, 179
- Gonorrhoea, 179. See also organ affected
 history of, caution in procuring, 183
 latent, in women, 182

- Gonorrhœa, latent, lurking-places for gonococcus in, 452
- Goodsall and Miles, analysis of symptom of cancer of rectum, 527
enumeration of abscesses in anal region, 515
on fistulæ originating posterior to anus, 518
- Graafian follicles, degenerated after infectious diseases, 577
enlarged, 290
- Graves bivalve speculum, Fig. 27, 87
- Gross, S. D., statistics of sarcoma of breast, 551
- Growth, failure of, a cause of amenorrhœa, 139
- Gumma. See organ affected
- Gusserow, fatty degeneration of fibroids, 253
percentages of ages at which fibroids occur, 249
- Guyon, observations on closure of os uteri in old age, 624
- HAND, examining, showing protective sleeve, Fig. 2, 31
- Hanks uterine dilator, Fig. 33, 91
- Hann, R. G., case of late child-bearing, 603
case of recurrence of sexual feeling at forty-nine, 614
- Hare, F., case of inhalation of amyl nitrite stopping menstruation, 596
- Hart and Barbour, views on pelvic floor, 220
- Heart disease, a cause of hemorrhoids, 500
of pelvic congestion, 467
menorrhagia in, 135
- Heart sounds, fetal, auscultation of, 429
- Hegar, view that tubes, uterus, and vagina form a duct for the gland, the ovary, 593
- Hegar's sign, 425
bimanual palpation for, Fig. 179, 425
- Hematocele, pelvic, Fig. 142, 343, 347
differentiated from pelvic cellulitis, 196
- Hematocolpos, Fig. 171, 360
- Hematoma of ovary, 346
- Hematoma of vagina, 377
of vulva, 400
- Hematometra, 360, Fig. 172, 398
- Hematosalpinx, 334, 360, Fig. 139, 335
danger of rupturing, 398
diagram of, Fig. 173, 399
differentiated from small ovarian tumor, 298
- Hematuria, a sign of papilloma of bladder, 483
a symptom of ureteral tumors, 493
in children, 583
- Hemophilia, in children, 571
menorrhagia in, 135
- Hemorrhage, at menopause, 617
of unexplained causation, 619
following curetting, 94
from anus, in hemorrhoids, 502
genital, in the child, 571
in fibroid tumors, 260
uterine. See Menorrhagia and Metrorrhagia
- Hemorrhoids (or piles), 498
external, 500
inflamed, with erosion, Fig. 193, 499
not to be pushed into anus or squeezed, 501
frequency and etiology of, 498
internal, 501
hemorrhage as a symptom of, 157, 502
prolapsed, Fig. 193, 499
with edema of anal margin, Fig. 193, 499
mucoid discharge in, 502
thrombotic, Fig. 193, 499
types of, Fig. 193, 499
- Hernaphroditism, 399
false, female, 400
male, 400
true, 399
- Hernia, anterior, into vagina, 368
inguinal, in labium majus, 412
differentiated from rectocele, 371
intestinal, into vagina, differentiated from cystocele, 368
labial, 412
in the child, 558

- Hernia, vulvar, differentiated from rectocele, 371
- Heubner, on masturbation, 575
on vulvo-vaginitis in children, 567
- Hilton's white line, Fig. 191, 495
- Hind-gut, arrested development of, 496
development of, Fig. 158, 395
- Hirst, B. C., cases of operations on pregnant women by mistake, 418
cases of ovarian tumor in upper abdomen, 302
- History, family, 7, 12
method of getting, 5
previous, 7, 12
- Hitschmann and Adler's views on endometritis hypertrophica, 171
on the endometrium, 168
- Holt, L. Emmett, on masturbation, 575
on vulvo-vaginitis in children, 567
- Horizontal section of uterus, Fig. 67, 171
- Hot flashes in menopause, 612
"Hottentot apron," 394
- Hours, P., on metrorrhagia of puberty, 573
- Houston, valves of, 122
- Huguier, case of true hypertrophic elongation of cervix, 225
cases of abscess of duct of Bartholin's gland, 410
- Hunner, G., technique of finding tubercle bacilli in urine, 469
- Hunter vaginal depressor, 89
- Hurdon, E., cases of papilloma of Fallopian tube, 337
views on sarcoma of uterus, 278
- Hüsler, G., on primary tumors of bladder in children, 582
- Hydatid disease. See Echinococcus
"Hydatid fremitus," 299
- Hydatid of Morgagni, 327
- Hydatidiform mole, 441, Fig. 182, 442
diagnosis of, 443
pathology of, 441
symptoms of, 443
- Hydrocele of canal of Nuck, 213
- Hydrosalpinx, 333, Fig. 138, 334
differentiated from small ovarian tumor, 298
follicular, 334
- Hydrosalpinx, intermittent, 334
- Hydrup-Pederson, case of atresia of vagina in child following diphtheria, 569
- Hymen, Fig. 156, 389
anatomy of, 390
atresia of, a cause of amenorrhea, 140
development of, Fig. 162, 395
different forms of, Figs. 163-170, 397
imperforate, 396
in the child, 560
malformations of, 396
rigid, a cause of sterility, 150
with pin-head opening, 396
- Hyperemesis gravidarum, 434
- Hypernephroma differentiated from ovarian tumor, 313
- Hypophysis cerebri, tumors of, attended by amenorrhoea, 419
- Hypospadias, 393, 444
- Hysteria, anuria in, 156
polyuria in, 485
- ILLNESS, present, in clinical history, 22
- Imperforate anus, 497
rectum, 496
- Inbreeding, a cause of sterility, 151
- Incarceration of ovarian tumors, 315
- Incontinence of feces in children, 585
of urine, 154, 485
- Infancy, gynecological affections of, 555
- Infant at birth, uterine organs of, seen from above, Fig. 205, 562
- Infantile uterus, 140, 202, Fig. 117, 286
vulva, Fig. 203, 556
- Infectious diseases, menorrhagia in, 135
- Inflammation, pelvic, 187
a cause of cystitis, 467
causing fixation of uterus in pro-lapse, 223
differential diagnosis of (table), 195
dysmenorrhoea in, 129
exudate in, differentiated from cancer, 277
from fibroid, 263
routes of infection in, 187
- Injuries of. See Vulva, Vagina, Urethra, Bladder, injuries of
- Insemination without penetration, 149

- Introitus vaginae, Fig. 156, 389
- Instruments, care of, before and after use, 30
 for examination, list of, 28
 in diagnosis, 77
- Intercourse, sexual. See Coitus
- Intermenstrual pain, 132
- Intestines, gas or fecal matter in, differentiated from large ovarian tumor, 309
- Intra-abdominal pressure, variations in, 224
- Irrigator, uterine, Bozeman-Fritsch, Fig. 35, 92
- Irritable bladder, 485
- Ishuria, 155
- Isthmus of Fallopian tube, Fig. 116, 285
- Itching. See Pruritus
 at anus after going to bed, a symptom of piles or eczema, 157
 of vulva, 160
- JACOBI, M. P., on menstrual wave theory, 595
- Jacquemin's sign, 422
- Jaundice, menorrhagia in, 135
- Jet of urine from ureteral orifice, Fig. 52, 107
- Johnson, F. W., case of fibromyoma of rectus, 310
- Jung, on gonococcus in cervical canal in children, 577
- KAKELS, S. W., on vulvo-vaginitis in children, 567
- Kehrer, E., cases of pregnancy in rudimentary cornua, 433
- Kelly and Cullen, on myomata of uterus, 249, 258, 261
 on myoma of vagina, 381
- Kelly, H. A., case of fibroid that had developed while under observation, 251
 cases of imperforate hymen following typhoid fever, 560
 method of injecting kidney to produce renal colic, 312
 pus cells in urine of cystitis converted into mucus in presence of proteus infection, 472
- Kelly cystoscope, Fig. 49, 104
 double-ended urethral dilator, Fig. 45, 102
 evacuator, Fig. 46, 102
 meatus calibrator, Fig. 44, 101
 ureteral catheter, Fig. 48, 103
 ureteral searcher, Fig. 47, 102
 wash-bottle suction apparatus in use, Fig. 55, 113
- Kennedy, W. J., case of late child-bearing, 602
- Kerley, on causes of enuresis, 579
- Kidney, ache in, a sign of papilloma of bladder, 483
 echinococcus cyst of, differentiated from ovarian tumor, 313
 movable, differentiated from ovarian tumor, 313
 palpation of, 70, 71
 polycystic disease of, differentiated from ovarian tumor, 313
 simple cysts of, differentiated from ovarian tumor, 313
 tumors of, differentiated from ovarian tumor, 313
- Kisch, cases of prolonged menstruation, 603
 table of gynecological affections found during menopause, 589
- Knee-chest position, 56, Fig. 13, 56
 modified for cystoscopy, Fig. 53, 111
 side view of, Fig. 14, 57
- Kobelt's tubules, diagram of, Fig. 120, 290
- Kraurosis vulvæ, 404
- Krieger, E., statistics as to age of the menopause, 597
- LABIA MAJORA, anatomy of, 388
 malformations of, 394
- Labia minora, adherent, 394
 anatomy of, 390
 cysts of, 413
 malformations of, 394
- Labium majus, Fig. 156, 389
 hematoma of, 400
 hydrocele of, in the child, 559
 tumor of, differentiated from enterocele, 371
 from hernia, 413

- Labium minus, Fig. 156, 389
- Labor, premature, definition of, 436
- Laceration of cervix. See Cervix, laceration of
- Laceration of perineum. See Perineum, laceration of
- Lactation, a cause of amenorrhea, 141
prolonged amenorrhea a symptom in, 419
- Lactation atrophy of uterus, 203
- Lactation hypertrophy. (See Breast)
- Latent gonorrhoea, 182
- Latent seedling fibroids, 251
- Leg holders, 57
- Leopold, on erosion of cervix in children, 563
- Leucorrhoea, 143, 355
a cause of pruritus, 160
a symptom of endocervicitis, 185
of endometritis, 177
of pregnancy, 420
bloody discharge in, 144
"currant juice," in hydatidiform mole, 443
fetid discharge in, 144
in case records, 7
in children, 144
in clinical history, 18
in fibroid tumors, 261
in married women, 145
in old women, 146
in virgins, 145
normal vaginal discharge and, 355
watery discharge in, 144
white discharge in, 143
yellow discharge in, 143
- Leukemia, menorrhagia in, 135
- Levator ani muscle, Fig. 150, 373, Fig. 151, 374, Fig. 152, 375
- Ligament, infundibulo-pelvic, Fig. 116, 285
of ovary, Fig. 116, 285
- Ligaments, broad, attachments of, 44
diseases of, 211
varicocele of, 212
- round, attachments of, 45
diseases of, 212
hydrocele of, 213
tumors of, 212
- uterine, anatomy of, 44
- Ligaments, uterine, diseases of, 210
mechanics of, 222
utero-ovarian, 214
utero-sacral, 213
attachments of, 44
course of, in intraligamentous tumor, Fig. 135, 317
in retroperitoneal tumor, Fig. 134, 316
- Light for cystoscopy, varieties of, 111
- Linea alba, pigmentation of, 67, 427
- Linea nigra, 67, 427
- Lineæ albicantes, 67
- Lithopedion, 345
- Lithotomy position, 57
- Liver, cirrhosis of, a cause of pelvic congestion, 467
tumors of, differential diagnosis of, from ovarian tumors, 312
- Locomotor ataxia, incontinence of urine in, 155, 485
- Long female catheter, Fig. 43, 101
- Lubricant for vaginal examination, 35
- Lund, F. B., ovariectomy on three-months-old child, 294
- Luys urine separator, Fig. 59, 119
- McBURNLEY'S POINT, 337
- McCosh, A. J., case of early carcinoma of breast, 550
- McDonald, E., on rhythmical contractions of pregnant uterus, 424
- Macula gonorrhoeica, 411
- Mamma. See Breast
- Marchand, F., on chorioepithelioma, 280
on pathology of hydatidiform mole, 541
- Mastitis, acute, 542
carcinomatous, 543
chronic, 543
actinomycotic, 544
interstitial, 543
lobular, 543
syphilitic, 544
tuberculous, 543
- Mastodynia, 553, 539
- Masturbation, 574
a cause of leucorrhoea, 144
of sterility, 151
of vaginismus, 379

- Masturbation, and pruritus, 161
 breast changes in, similar to pregnancy, 421
- Maturity, precocious, 564
 case of, Fig. 207, 565
- Meatus calibrator, Kelly's, Fig. 44, 101
- Meatus urinarius, Fig. 156, 389
- Memory, loss of, in menopause, 613
- Menopause, 587
 age of occurrence of, 597
 atrophic changes in, 17
 blood pressure in, 613
 delayed, 601
 delusional insanity in, 615
 displacements of uterus at, 620
 dodging time of, 611
 duration of, 611
 dyspepsia in, 615
 eczema vulvæ at, 621
 gastritis, atonic, in, 615
 gastro-enteritis in, 616
 hemorrhages of, 617
 heredity as affecting, 598
 high arterial tension in, 613
 hot flashes in, 612
 hyperchlorhydria in, 615
 in clinical history, 16
 influence of race and locality on, 597
 injuries of vagina after, 621
 insomnia in, 613
 intercostal neuralgia in, 663
 irritability of temper in, 613
 loss of memory in, 613
 melancholia in, 615
 mental diseases at, 615
 nervous system in, 613
 neurasthenia in, 614
 nut in, 616
 obesity at, 616
 phenomena of body and mind in, 612
 premature, 598
 associated with obesity, 599
 pruritus vulvæ at, 161, 621
 psychoses in, 615
 pulse rate in, 613
 rheumatism in, 616
 sexual feeling in, 614
 skin diseases in, 617
 tables of 115 cases of, 604
 tachycardia in, 613
- Menopause, vesical symptoms at, 621
- Menorrhagia, 134
 constitutional causes of, 135
 differentiation of, from abortion, 441
- Menorrhagia and metrorrhagia, differentiated from abortion, 441
 in married women, 139
 in nulliparæ, 137
 in parous women, 138
 in pregnancy, 138
 in virgins, 137
 local causes of, 135
- Menstrual period, a predisposing cause of cystitis, 467
- Menstruation, date of beginning of
 last, 8
 delayed, and pelvic disease, 15
 description of, 13
 during pregnancy, 419
 in case record, 7
 molimen of, 128
 physiology of, 595
 precocious, 564
 prolonged, 603
 vital energy, wave of, governing, 595
 wave theory concerning, 595
- Mensuration of abdomen, 74
- Mental disease at menopause, 615
 overwork, a cause of amenorrhea, 142
- Metritis, 165
 chronic, a cause of hemorrhage at menopause, 618
- Metrorrhagia, 134
 after menopause a sign of cancer, 138
 coming on six weeks after labor may mean chorioepithelioma, 138
 differentiated from abortion, 441
 may mean extra-uterine pregnancy, 138
 may mean uterine polyp, 138
- Michaelis' rhomboid, 96
- Micturition, frequent, 153
 a symptom of pregnancy, 420
 painful, 151
- "Milk line." 532, Fig. 200, 538
- Miscarriage, definition of, 436
 diagnosis of, 440
- Miscarriages and abortions, in clinical history, 11
- Mittelschmerz, 132

- Mole, hydatidiform, in Fallopian tube, 345
 tubal, 344
- Molimina, menstrual, 128
- Mons veneris, Fig. 156, 389
 anatomy of, 388
- Morgagni, columns of, 123, Fig. 191, 495
 crypts of, 123, Fig. 191, 495
 hydatid of, 327
 valves of, 123, Fig. 191, 495
- "Morris' points," 337
- Morse, J. L., cases of precocious menstruation and precocious maturity, 564
 on bacteriuria, 579
 on hematuria in scurvy, 583
- Mucous patches. See Vulva and Anus
- Müller's ducts, 197, Fig. 71, 198
- Multiple sclerosis, retention of urine in, 485
- Muscular rheumatism, 19
 of pectoralis major, 553
- Myoma. See Uterus, fibroids of
- Myoma and cancer to be excluded from statistics on menopause, 590
- NABOTHIAN FOLLICLES, cysts of, 41, 185
- Nationality, in clinical history, 9
- Nausea and vomiting, symptoms of pregnancy, 419
- Neisser, gonococcus of, 179
- Nephritis, acute, anuria in, 156
- Neugebauer, on hermaphroditism, 399
- Neugebauer bivalve speculum, 86
- Neumann, F., cases of joint disease at menopause, 616
- Neuralgia, intercostal, in menopause, 613
 mammary, 539, 553
- Neurasthenia and dysmenorrhea, 130
- Neurasthenia associated with coccygodynia, 159
- New-born, the, genital hemorrhages in, 571
- Nipple, anatomy of, 532
 discharge from, in late cancer, 553
 discharge of blood from, 545, 546
 Paget's disease of, 548
 retraction of, 553
- Nitze cystoscope, Fig. 56, 116
- Noble, C. P., case of recto-vesical fistula, 480
 views on fibroids, 246, 253, 255, 256
- Nuck, canal of, hydrocele of, 213
 differentiated from cyst or abscess of labium, 412
 from hernia, 413
- Nymphæ, adherent, 394
 anatomy of, 390
 hypertrophy of, 394
- OBESITY, amenorrhea a symptom in, 141, 419
 associated with premature menopause, 599
 at menopause, 616
 rapidly occurring, a cause of sterility, 151
- Occupation, in clinical history, 9
- Odor as a diagnostic sign, 60
- Old age, 622
 conventional time for the beginning of, 588
- Olshausen, views on sterility in fibroid tumors, 258
- Omentum, cyst of, differentiated from ovarian tumor, 313
- Oöphoron, atrophied because of pressure, 290
 diagram of, Fig. 120, 290
- Os, parous, Fig. 66*a*, 169
 virginal, Fig. 66, 168
- Os tinæ, 41
- Ostheimer and Levi on enuresis, 579
- Ostium abdominale of tube, Fig. 116, 285
- Ovaritis, 288
 acute, diagnosis of, 288
 chronic, 290
 diagnosis of, 290
 differentiation of, from small ovarian tumor, 297
- Ovary, adhesions about, a cause of sterility, 150
 anatomy and age changes of, 284, 592
 and tube seen from behind, Fig. 116, 285
 anomalies of, 285
 atrophic changes of, in old age, 623

- Ovary, atrophy of, 285
 a cause of amenorrhea, 141
 of sterility, 150
 following steaming of uterine cavity, 286
 in exanthemata, 285, 599
 lactation, 285
 cancer of, primary, 322
 changes in, at menopause, 592
 corpus luteum of, cysts of, 321, formation of, 592
 function of, 13
 cyst and tumor of, regions of, Fig. 120, 290
 cyst of. See Ovary, tumors of, varieties of: cysts
 large, differentiated from ascites, 308
 from large fibroid, 309
 showing emaciation and "facies ovarina," Fig. 125, 294
 degeneration of, parenchymatous, 599
 small cystic, 290
 development of, Fig. 71, 198, 592
 diseases of, 284
 in the child, 576
 displacements of, 286
 fibroma of, differentiated from pedunculated fibroid, 263
 function of, 592
 impaired by infectious diseases, 577
 Graafian follicles of, degeneration of, after infectious diseases, 577
 hernia of, 288
 infantile, Fig. 117, 286
 inflammation of, 288
 normal, palpation of, 41
 position of, 48
 of mature woman, Fig. 118, 287
 prolapse of, 286
 sclerosis of, in tuberculosis, 599
 senile, Fig. 119, 289
 small cystic degeneration of, 290
 tumors of, 291
 a cause of sterility, 150
 aspiration of, 305
 association of, with pregnancy, 320
- Ovary, tumors of, classification of, 293
 complications of, 315
 cross section of body in, Fig. 127, 302
 degenerative processes in, 319
 diagnosis of, in general, 295
 in the child, 577
 differential diagnosis of pathological varieties of, 321
 etiology and symptoms of, 293
 Hegar's method of determining relation of, to uterus, Fig. 126, 301
 in old age, 623
 infantile, Fig. 206, 262
 infection of, 318
 intraligamentous development of, 316
 large, diagnosis of, 301
 differential diagnosis of, 305
 differentiated from cyst of pancreas, 311
 from cysts of omentum, 313
 from dilated stomach, 314
 from distended bladder, 314
 from echinococcus cysts, 314
 from fat in abdominal walls, 310
 from fecal accumulation, 309
 from fibroids, 309
 from pregnancy, 305
 from tumors of spleen, liver, and kidneys, 312
 inspection of, 302
 palpation of, 302
 percussion of, 303
 malignancy of, 293
 modes of development of, 292
 pedicle formation of, Figs. 121-124, 292
 pedicle of, pain caused by traction on, 296
 palpation of, 295
 torsion of, 317
 rupture of, 319
 small, diagnosis of, 297
 differential diagnosis of, 297
 differentiated from distended bladder, 300
 from echinococcus cyst, 299

- Ovary, tumors of, small, differentiated from encapsulated peritonitis, 298
 from extra-uterine pregnancy, 299
 from ovaritis, 297
 from parovarian cyst, 298
 from pregnancy, 300
 from subperitoneal fibroid, 297
 from tumors of the tube, 298
 suppuration of, 318
 symptoms of, 294
 tapping of, 305
 varieties of:
 adhesions and incarceration, 315
 carcinoma, primary, 322
 cysts, dermoid, 322
 differentiation of, from fibroid, 262
 follicular, 321
 multilocular, 321
 proliferating, 321
 simple, 321
 endothelioma, 323
 fibroma, 322
 differentiation of, from fibroid of uterus, 263
 perithelioma, 323
 sarcoma, 322
 teratomata, 322
 undescended, 286
 Ovulation, prolonged, 603
 Ovum, growth of, in early pregnancy, 423
 Oxyuris vermicularis, a cause of pruritus, 161
- PAGET'S DISEASE of the nipple, 548
- Pain following defecation, a symptom of fissure or fistula, 157
 in anus, after going to bed, a symptom of piles or eczema, 157
 in case records, 7
 in clinical history, 18
 in course of ureter, a symptom of stricture, 489
 in fibroid tumors, 261
 in groins, in clinical history, 19
 intermenstrual, 132
- Pain, menstrual. See Dysmenorrhea
- Palpation, bimanual, diagram of, Fig. 5, 38
 for Hegar's sign, Fig. 179, 425
 structures to be felt by, 49
 in diagnosis, 34
 pelvic structures felt by, 40
- Palpitation in fibroids, 259
 in menopause, 613
- Pancreas, cyst of, differentiated from large ovarian tumor, 311
- Paralysis, a cause of cystitis, 467
- Paravaginitis, 362
 phlegmonosa dissecans, 362
- Parkinson, J. P., on hematuria, a sign of infantile scurvy, 583
- Paroöphoron, diagram of, Fig. 120, 290
- Parovarium, cyst of, 211
 contents of, 211
 differentiated from small ovarian tumor, 298
 large cyst seen in profile, Fig. 128, 303
 diagram of, Fig. 116, 285, 290
- Pathology of disease in any organ. See organ affected
- Patient, preparation of, for examination, 23
- Pectoralis major muscle, rheumatism of, 553
- Pedicle, See Ovary, tumor of, pedicle torsion of, 317
- Pedicle of pubis, a cause of pruritus, 161
- Pelvic abscess, 193
- Pelvic cellulitis, 192. See also Cellulitis, pelvic
 definition of, 187
- Pelvic congestion, a cause of leucorrhœa, 145
- Pelvic inflammation, 187. See also Inflammation, pelvic
- Pelvic organs of an infant at birth, seen from above, Fig. 206, 562
- Pelvic peritonitis, 188. See also Peritonitis, pelvic
 definition of, 187
- Pelvimeter, Collyer's, Fig. 42, 98
- Pelvimetry, 95

- Pelvis, abdomen and contents of,
 mechanics of, 44
 cancer of, differentiated from fibroid,
 263
 cavity of, estimating of, 98
 circulation of, 46
 contents of, anatomy of, 43
 from above, Fig. 9, 48
 deformities of, 95, 96
 diameter of, conjugate, Baude-
 locque's, 96
 external conjugate, 96
 oblique conjugate, 97
 oblique diagonal, 98
 transverse, 98
 dimensions of, 95
 female normal, Fig. 9*a*, 50
 showing accessibility of contents
 to palpation, Fig. 10, 52
 with hand in position for vaginal
 examination, Fig. 4, 37
 floor of, diagram showing structures
 of, Fig. 150, 373.
 injuries of. See Perineum, inju-
 ries of
 lacerations of, 372
 mechanics of, 221
 of new-born child, longitudinal me-
 dian section of, Fig. 204, 558
 outlet of, transverse diameter of, 98
 Penrose, C. B., on erosion of cervix in
 infants, 563
 Percussion of abdomen, 71
 Perineum ("Perineal body"), 221
 development of, Figs. 160-161-162,
 395
 injuries of, a cause of garrulity of
 vagina, 378
 due to coitus, 376
 laceration of, 372
 a cause of sterility, 150
 complete, 374
 median, Fig. 151, 374
 partial, 374
 lateral, Fig. 152, 375
 through the sphincter ani, 374
 Peristalsis, waves of, seen on inspection
 of abdomen, 66
 Peritoneum, anatomy of, 188
 folds of, reflections of, Fig. 70, 189
 Peritonitis, body pose in, 67
 encapsulated, differentiated from
 small ovarian tumor, 298
 pelvic, 188
 acute, 190
 chronic, 191
 differential diagnosis of, 195
 etiology of, 189
 in Douglas' cul-de-sac, differen-
 tiated from cellulitis, 195
 tuberculous, 191
 Pessaries, a cause of ulceration of
 vagina, 377
 Pfannenstiel, classification of ovarian
 tumors, 291
 Phantom, bladder, Fig. 58, 118
 "Phantom tumor," 311
 Phthisis, menorrhagia in, 135
 Physician, preparation of, for examina-
 tion, 31
 Piles. See Hemorrhoids
 Pincus, L., views as to atresia of vagina
 following infectious diseases, 560
 "Pinhole os," 41, 81
 Pin-worms, a cause of pruritus, 161
 Placing patient on table, 33
 Poisonings, anuria in, 156
 chronic, amenorrhea a symptom in,
 419
 menorrhagia in, 135
 Polypus and polypi. See Endometritis,
 Uterus, fibroids of, Urethra, and
 Rectum
 Position, dorsal, 33
 for examination, Fig. 3, 32
 knee-chest, Fig. 13, 56
 modified for eystoscopy, Fig. 53,
 111
 side view, Fig. 14, 57
 lithotomy, Fig. 15, 58
 raised pelvis, Fig. 16, 59
 Sims, Fig. 11, 53
 diagram of, Fig. 12, 54
 standing, Fig. 17, 60
 Pott's disease, retention and incon-
 tinence of urine in, 485
 Pozzi, S., on development of hymen,
 396
 Precocious maturity, a case of, Fig.
 207, 565

- Pregnancy, a cause of amenorrhea, 141
 a cause of pelvic congestion, 467
 abdominal, 340
 secondary, 345
 abnormal, diagnosis of, 432
 advanced, a cause of retention of
 urine, 155
 associated with ovarian tumor, 320
 breasts in, 420, 421
 diagnosis of, 417
 diagnosis that it has occurred pre-
 viously, 433
 differential diagnosis of, 431
 differentiated from fibroid tumor,
 264
 from large ovarian tumor, 305
 from small ovarian tumor, 300
 during first three months, diagnosis
 of, 418
 during last six months, diagnosis of,
 426
 early, bimanual touch in, 423
 extra-uterine, 340
 differentiated from abortion, 441
 from normal pregnancy, 431
 from small ovarian tumor, 299
 early, 348
 ampullar, Fig. 140, 341
 mole and fetus removed from
 tube in, Fig. 141, 342
 diagnosis after rupture, 351
 late, 350
 ampullar, unruptured, Fig. 145,
 350
 diagnosis of, 353
 section of uterus, showing endome-
 trial modification, Fig. 146, 352
 symptoms and signs of, 346
 in bicornute uterus, 433
 interstitial, Fig. 144, 346
 diagnosis of, 433
 menstruation during, 419
 multiple, diagnosis of, 434
 nausea and vomiting, symptoms of,
 419
 normal, differentiated from small
 ovarian tumor, 300
 ovarian, 345
 pernicious vomiting of, 434
 salivation in, 420
- Pregnancy, symptoms and signs of,
 table of, 430
 tubal, 341
 diseases of ovum in, 345
 fate of fetus in, 344
 mole formed in, 344
 multiple, 348
 pathology of, 343
 repeated, 348
 rupture of, 344
 uterine decidua formed in, 344
 tubo-abdominal, 340
 tubo-ovarian, 340
 tubo-uterine, 340
- Premature labor, definition of, 436
 menopause, 598
- Prepuce, Fig. 156, 389
 a cause of enuresis, 558
 adherent, 394
 in the child, 557
- Present illness, in case records, 7
 in clinical history, 13, 22
 in interpretation of clinical history,
 22
- Previous history, 7, 12
- Probe, uterine, Fig. 22, 82
- Procidencia, Fig. 87, 223
- Procreation, factors essential for, 149
- Proctitis, 505
 acute catarrhal, 506
 atrophic, 507
 chronic catarrhal, 507
 differentiation of atrophic from
 hypertrophic, 509
 dysenteric, 513
 gonorrhœal, 510
 hypertrophic, 508
 in children, 585
 simple, 506
 specific, 510
- Proctodeum, development of, Fig. 160,
 395
- Proctoscope, long, Fig. 61, 124
 short, Fig. 60, 123
- Proctoscopy, 124
- Prolapse. See Uterus, prolapse of
- Pruritus vulvæ, 160, 404
- Pseudohermaphroditism, 400
- Pseudomasturbation, 574
- Puberty, description of, 14

- Puberty, metrorrhagia of, 573
 Puerperium, a favorable time for beginning of retroversion, 235
 Purpura, menorrhagia in, 135
 in the child, 572
 Pyosalpinx, 332, Fig. 137, 333
 differentiated from pelvic cellulitis, 196
 from small ovarian tumor, 298
 rupture of, 333
- RACHFORD, B. K., on pseudomasturbation, 574
 Raised pelvis position, 58
 Reconstruction of uterus, Fig. 64, 166
 Rectal speculum, Sims, Fig. 63, 126
 Rectal symptoms, 156
 Recti muscles, separation of, 66
 Rectocele, 369, Fig. 149, 369
 at menopause, 621
 diagram of, Fig. 149*a*, 370
 Rectum, adenoma of, 523
 anatomy of, 121
 anomalies of, 495
 cancer of, 525
 diagnosis of, 528
 differential diagnosis of, 528
 frequency of, 525
 hemorrhage as a symptom of, 157
 pathology and course of, 526
 symptoms of, 527
 chancere of, 512
 chaneroids of, 512
 development of, Figs. 158-162, 395
 digital examination of, 123
 discharge from, as a symptom, 157
 diseases of, 494
 in children, 584
 exudate about a fistula of, differentiated from cancer, 528
 fecal accumulation in, as a symptom, 157
 fibro-adenoma of, 523
 fibroma of, 524
 gumma of, 512
 differentiated from cancer, 529
 hemorrhage from, as a symptom, 157
 imperforate, 496, 561
 inflammation of, 505. See also Proctitis
 inspection of, 124
 lower part of, Fig. 195, 515
 lymphadenoma of, 523
 new growths of, 522
 pain in, as a symptom, 156
 polyp of, differentiated from cancer, 529
 fibrous, 524
 glandular, 524
 hemorrhage as a symptom of, 157
 mucous, 523
 myomatous, 524
 myxomatous, 525
 prolapse of, 521
 complete, 522
 hemorrhage as a symptom of, 157
 in children, 584
 incomplete, 522
 sarcoma of, 529
 stricture of, 518
 congenital, 519
 differentiated from cancer, 529
 due to pressure from without, 519
 inflammatory, 519
 spasmodic, 519
 syphilis of, 510
 syphilitic ulceration of, 512
 tuberculosis of, 513
 tuberculous ulceration of, differentiated from cancer, 528
 veins of, 123
 villous tumor of, 524
 differentiated from cancer, 529
 Rectus muscle, fibromyoma of, 310
 Reflections of folds of peritoneum, Fig. 70, 189
 Rheumatic diathesis and pruritus vulvæ, 161
 Rheumatism, at menopause, 616
 muscular, 19
 of pectoralis major, 553
 Richardson, M. H., on evils of too positive an opinion about breast tumors, 549
 on importance of making a complete physical examination in the case of breast tumors, 554
 Rivière, A., case of incontinence of feces in a girl of nine, 586
 Robb leg-holders, 57

- Rodman, W. L., analysis of 5,000 cases of cancer of the breast, 551
 on operability of cancer of the breast, 549
 on the three most important points in diagnosis of tumors of the breast, 550
- Rossi-Doria, delayed menstruation and pelvic disease, 15
- Round ligaments. See Ligaments, round
- Rupture of ovarian cyst by forcible manipulations, 319
- SACRO-ILIAC SUBLUXATION, 18
- Sactosalpinx, 332
 diagnosis of, 335
- Salpingitis, 327
 actinomycotic, 332
 acute, 327
 catarrhal, 327
 chronic, 329
 diagnosis of, 328
 differentiated from appendicitis, 336
 echinococic, 332
 follicular, a cause of sterility, 151
 gonorrhoeal, 330
 obliterating, a cause of sterility, 150
 purulent, 328
 symptoms of, 328
 syphilitic, 332
 tuberculous, 330, Fig. 136, 331
- Sampson, J. A., on pain caused by twisting pedicle of tumor, 296
- Sänger, M., on chorioepithelioma, 280
- Sapremia, 175
- Schulkowski, on genital hemorrhage in the new-born, 572
- Sclerosis, multiple, retention of urine in, 485
- Scurvy, hematuria in, 583
 menorrhagia in, 135
- Sea voyages, amenorrhoea following, 419
- Searcher, ureteral, Kelly, Fig. 47, 102
- Searching urethra and bladder, 108
- Separator, urine, Luys, Fig. 59, 119
- Sepsis. See Endometritis, acute septic Septicemia, 175
- Sexual feeling at menopause, 614
- Simon speculum, 86
- "Simpson symptom" of cancer of body of uterus, 276
- Sims position, 54
 rectal speculum, Fig. 63, 126
 vaginal speculum, 88
- Sinus, urogenital, persistence of, 393, 444
 urogenitalis, Fig. 71, 198, Fig. 157, 392, Fig. 160, 395
- Skene's glands, anatomy of, 101
 collection of discharges from, 61
 lurking-places for infection, 180
- Slanting shelf formed by psoas muscles and false pelvis, Fig. 86, 221
- Social condition, in clinical history, 10
- Souffle, uterine, 429
- Sound, uterine, 78, Fig. 21, 78
 caution in use of, 82
 facts to be learned by use of, 80
 how to pass bimanually, 79
 by sight, 80
 when to pass, 78
- Sound touch, 81
- Spasm of bladder, 109, 465
- Speculum, rectal, Sims, Fig. 63, 126
 uterine, Burrage, Fig. 36, 93
 vaginal, 85
 bivalve, 85
 Brewer, Fig. 26, 87
 Edebohls, 86, Fig. 32, 91
 Graves bivalve, Fig. 27, 87
 Sims, 87, Fig. 28, 88.
- Speese, John, on predisposition to cancer furnished by lactation mastitis, 544
- Sphincter ani, action of, preventing healing of fissure, 123
 external, Fig. 195, 515
 hypertrophy of, in hemorrhoids, 503
 internal, Fig. 195, 515
 method of stretching of, 126
- Spinal cord, disease of, a cause of incontinence of urine, 155
- Spirochæta pallida, in chancre of vulva, 407
 in mucous patches of vulva, 407
- Spleen, tumors of, differentiated from ovarian tumors, 312
 wandering, differentiated from ovarian tumor, 312

- Stammering of bladder, 109, 465
- Starfinger on sarcoma of vagina in children, 382
- Stark, M. M., cases of premature menopause, 600
- Stephenson, W., on menstrual wave theory, 595
- Sterility, 147
 age as affecting, 148
 conditions of uterine organs that interrupt pregnancy, 150
 constitutional diseases causing, 151
 due to anomalies and diseases of uterine organs, 150
 in the male, 148
- Stomach, dilated, differentiated from ovarian tumor, 314
- Stone in bladder, 462
 in children, 582
- Storer, M., cases of bilateral torsion of Fallopian tubes, 336
- Straining, a cause of hemorrhoids, 500
 at stool, with sense of only partial relief, a symptom of stricture of rectum, 158
- Strangury, 152
- Stricture of rectum. See Rectum, stricture of
- Subinvolution, 207
- Sunstroke, anuria in, 156
- Swelling of feet and legs in fistula in ano, 520
- Symptoms of disease in any organ. See organ affected
- Syphilis. See organ affected
 a cause of abortion, 437
 a cause of sterility, 151
 menorrhagia in, 135
- TABLE, examining, preparation of, 26
- Tachycardia, in fibroids, 259
 in menopause, 613
- Taylor, case of late conception, 603
- Tenaculum, uterine, Fig. 24, 83
- Tenaculum forceps, double, 85
- Thornton, case of ovariectomy on woman ninety-four years old, 294
- Thyroid. See Gland
- Tilt, E. J., cases of prolonged menstruation, 604
- Tilt, table of comparative dates of cessation of menstruation in different countries, 598
 table of uterine diseases found during menopause, 589
 views on length of dodging time, 611
- Tissue, preservation of, 63
 removal of, for microscopic examination, 62
- Torsion of uterus, 244
- Touch, bimanual, diagram of, Fig. 5, 38
 hindrances to, 39
 structures to be felt by, 49
 vagino-abdominal, 38
 rectal, 50
 recto-abdominal, 53
 in examination of children, 556
 sound, 81
 vaginal, 34
 vagino-abdominal, 38
- Townsend, C. W., on incontinence of urine relieved by removal of rectal polyp, 579
- Treatment advised, in case records, 8
- Trigone, hyperemia of, 471
- Trigonitis, 471
- Tube, Fallopian, a carrier of infection to ovarian tumors, 318
 absence of, 326
 accessory, 326
 anatomy of, 324
 anomalies of, 326
 atrophic changes in, in old age, 623
 atrophy of, at menopause, 594
 carcinoma of, 338
 chorioepithelioma of, 339
 cyst of Morgagni of, 327
 diseases of, 324
 in the child, 576
 displacement of, 326
 diverticula from, 326
 elongation of, 326
 embryoma of, 338
 fibroma of, 338
 fibromyxoma of, 338
 function of, 325
 hernia of, 326
 infantile, Fig. 206, 562
 inflammation of, 327
 myoma of, 338

- Tube, Fallopian, new growths of, 337
 papilloma of, 337
 polypus of, 337
 retention tumors of, 332
 rupture of, 336
 sarcoma of, 339
 tumors of, differentiated from
 small ovarian tumors, 298
- Tuberculosis. See organ affected
 amenorrhea a symptom in, 419
- Tubo-ovarian cyst, 334
- Tumor of any organ. See organ
 affected
 rising from pelvis, outlined by ab-
 dominal walls, 66
- Turpentine, a cause of cystitis, 467
- Tuttle, J. P., on frequency of cancer of
 rectum, 525
- Typhoid fever, anuria in, 156
- UNDERHILL, F. P., and Rand, R. F.,
 on the urine in pernicious vomiting
 of pregnancy, 436
- Uraehus, cyst of, differentiated from
 ovarian tumor, 311
- Uremia, anuria in, 156
 menorrhagia in, 135
- Ureter, absence of, 486
 anatomy of, 103
 anomalies of, 486
 blood clot in, a cause of stricture, 489
 calculus of, 490
 cancer of, a cause of stricture, 489
 catheterization of, 115
 compression of, by fibroid, 257
 development of, Fig. 71, 198
 diseases of, 486
 double, 486
 echinococcus cyst in, a cause of stric-
 ture, 489
 fistula of, 492
 gumma of, a cause of stricture, 489
 inflammation of, 488
 mucosa of, prolapse of, 491
 new growths of, 493
 occluded, cystic dilatation of, 487
 orifice of. See Bladder, anatomy of
 abnormal situation of, 486
 swollen, 488
 urine spurting from. Fig. 52, 107
- Ureter, stone in, 490
 a cause of stricture, 489
 stricture of, 489
 tumors of, 493
 valve formation in, 489
- Ureteritis, 488
- Urethra, anatomy of, 100
 angioma of, 453
 anomalies of, 444
 atresia of, 445
 bladder and, searching of, 108
 bladder and ureters, and, examina-
 tion of, 107
 cancer of, 455
 earuncle of, 453, Fig. 184, 454
 a cause of dysuria, 152
 of sterility, 150
 of vaginismus, 379
 differentiated from cancer, 415,
 455
 from prolapse of mucosa, 449
 development of, Fig. 71, 198,
 Figs. 160-162, 395
 dilated and short, 444
 dilatation of, 447
 limits to, 448
 diseases of, 444
 dislocation of, downward, 109, 446
 upward, 445
 external, partial defect of, 444
 fibroma of, 455
 granuloma of, 453
 inflammation of, 450
 mucosa of, prolapse of, 448
 mucous membrane of, prolapse of,
 Fig. 183, 449
 mucous polyp of, 453, 455
 myoma of, 455
 new growths of, 453
 polyp of, differentiated from pro-
 lapse of mucosa, 449
 sarcoma of, 456
 stricture of, 452
 a cause of frequency of micturi-
 tion, 154
 tuberculosis of, differentiated from
 cancer, 455
- Urethritis, 450
 a cause of dysuria, 152
 of frequency of micturition, 154

- Urethritis, acute, 450
 chronic, circumscribed, 451
 diffuse, 451
- Urethrocele, differentiated from dislocation of urethra, 447
- Urination, difficult, retarded or painful, 151
 too frequent, 153
- Urine, analysis of, in case records, 8
 incontinence of, 154, 485
 a symptom of abnormal opening of ureter, 487
 method of collecting, in children, 578
 retention of, 155
 in incarceration of retroflexed pregnant uterus, 155
 suppression of, 156
- Urogenital sinus, Fig. 71, 198, Fig. 157, 392, Fig. 160, 395
 persistence of, 393
- Uterine disease, a cause of hemorrhoids, 500
 influence of, on menopause, 617
 symptoms of, 127
- Uterine ligaments. See Ligaments, uterine
- Uterine organs, atrophic changes in, at menopause, 594
- Uterine segment, lower, true hypertrophic elongation of, 229
- Uterus, abnormalities of axis and form of, 234
 absence of, 198
 adenomyoma of, 245
 symptoms of, 262
 anomalies of, 197
 due to arrest of development, 201
 due to arrest of growth, 202
 antelexion of, 240. See also Retro-position with antelexion
 a cause of sterility, 150
 in the little girl, Fig. 90, 230
 pathological, Fig. 91, 231
 anteroposition of, 229
 anteversion of, 238
 ascent of, 218
 atrophic changes in, in old age, 624
 atrophy of, at menopause, 594
 congenital, 140, 203
 following steaming, 286
- Uterus, atrophy of, lactation, 203
 non-puerperal, 203
 puerperal, 203
- bicornis, 200
 diagram of, Fig. 74, 199
- bicornute, Fig. 78, 201
 pregnancy in, 433
- bipartitus, Fig. 72, 199, 200
- body of, cancer of, adeno-carcinoma, 269
 early stage of, Fig. 112, 269
 diagnosis of, 276
 differential diagnosis of, 277
 differentiated from fibroid, 265
 sarcoma of, 279, Fig. 113, 279
- cancer of, 266
 a cause of hemorrhage at menopause, 619
 diagnosis of, in general, 270
 in the child, 576
 leucorrhoea in, 271
 symptoms of, 270
- cavity of, digital exploration of, 94
 Kelly's method of exploration of, 94
 Figures illustrating, Figs. 38-41, 94-97
- cervix of. See Cervix
- chorioepithelioma of, diagnosis of, 283
 differentiated from fibroid, 265
 malignant, 280
 of posterior wall, Fig. 114, 281
- decidua in, in extra-uterine pregnancy, Fig. 143, 345
- didelphys, Fig. 73, 199, 200
- double, with double vagina, Fig. 147, 358
- fibro-cystic tumor of, 253
- fibroid in anterior wall of, differentiated from pregnancy, 431
- fibroids of, 244
 a cause of delayed menopause, 604
 of hemorrhage at menopause, 617
 anemia in, 261
 carcinoma complicating, 255
 cervical, 247
 classification of, 245
 complications of, 255
 course and development of, 251

- Uterus, fibroids of, dangerous to life, 260
- degenerations in, 252
- amyloid, 254
- colloid, 253
- fatty, 253
- hyaline, 253
- myxomatous, 253
- sarcomatous, 255
- in differential diagnosis, 264
- diagnosis and differential diagnosis of, 262
- differentiated from large ovarian cyst, 309
- from small ovarian tumors, 298
- diseases of tubes and ovaries complicating, 256
- edema in, 254
- effect of, on distant organs and system, 258
- on neighboring organs, 257
- etiology of, 250
- fibro-cystic, 253
- frequency of, 248
- gangrene in, 254
- globular, filling pelvis, Fig. 109, 256
- heart disease in relation to, 259
- hemorrhage in, 260
- in negro race, 249
- interstitial, 247
- diagnosis of, 263
- interstitial and submucous, Fig. 104, 248
- intraligamentous, 246, Fig. 105, 249
- diagnosis of, 263
- dysmenorrhea in, 129
- leucorrhœa in, 261
- metastases in, 255
- multiple, Fig. 102, 246
- of cervix, 247, Fig. 108, 254
- pain in, 261
- palpitation in, 259
- pathology of, 244
- pedunculated or polypus, differentiated from prolapse, 229
- in vagina, Fig. 107, 252
- pregnancy interfered with by, 258
- renal complications in, 257
- Uterus, fibroids of, rupture of uterus in, 260
- sarcoma in, 264
- seedling, 251
- situation of, 248
- sloughing, 248
- submucous, 247
- diagnosis of, 264
- intra-uterine, differentiated from incomplete inversion, 243
- large, Fig. 106, 250
- pedunculated, in vagina, differentiated from complete inversion, 242
- subperitoneal, a cause of stricture of ureter, 489
- differentiated from small ovarian tumor, 297
- subserous, 246
- diagnosis of, 262
- differentiated from pelvic cellulitis, 196
- side view of abdomen containing large, Fig. 103, 247
- suppuration in, 254
- symptoms of, 260
- thrombosis in, 255
- ureters compressed by, 257
- fundus of, height of, at various weeks of pregnancy, Fig. 130, 306
- gravid, changes in, during early pregnancy, 423
- hernia of, 233
- horizontal section of body showing shape of cavity of, Fig. 67, 171
- hyperinvolution of, a cause of sterility, 150
- infantile, 140, 202, Fig. 204, 558
- a cause of amenorrhœa, 140
- of sterility, 150
- inversion of, 240
- acute puerperal, Fig. 93, 239
- and conditions simulating, Figs. 94-101, 241
- diagnosis of, 240
- differential diagnosis of (table), 242
- differentiated from fibroid, 242, 243, 265
- from prolapse, 228
- lateroposition of, 229

- Uterus, ligaments of. See Ligaments
- lower segment of, softening of, in pregnancy, 425
- maldevelopment of, a cause of dysmenorrhea, 129
- amenorrhea a symptom of, 419
- malpositions of, 215
- at menopause, 620
- mechanism of, 219
- muscular wall of, sarcoma of, 280
- non-puerperal atrophy of, 203
- normal, mobility of, 49
- normal position of, 43, Fig. 6, 44, Fig. 84, 216, Fig. 150, 373
- polyp of, simulating prolapse, 229
- polyp of, a cause of hemorrhage at menopause, 618
- mucous, simulating cancer, 273
- pregnant, at sixth week, diagrammatic side view, during contraction, Fig. 178, 423
- during relaxation, Fig. 177, 422
- changes in shape of, during early pregnancy, 423
- contractions of, 424
- enlargement of, in late pregnancy, Fig. 181, 428
- palpation of, in late pregnancy, 428
- retroflexion and incarceration of, 432
- shape of, in early pregnancy, 423
- situation of, in early pregnancy, 423
- six weeks' section of, Fig. 178, 424
- prolapse of, 218, Fig. 87, 223
- a cause of sterility, 150
- acute, 218
- at menopause, 620
- causation of, 223
- diagnosis of, 226
- differential diagnosis of, 228
- in the child, 562
- mechanism of, 219
- partial, Fig. 89, 227
- pathology of, 218
- symptoms and course of, 226
- reconstruction of, showing shape of cavity, Fig. 64, 166
- retroflexion of, differentiated from pregnancy, 431
- Uterus, retroposition of, 230
- with antelexion, 231, Fig. 91, 231
- diagnosis of, 232
- differentiated from pregnancy, 231
- dysmenorrhea in, 129
- retroversio-flexion of, 234
- diagnosis of, 236
- etiology of, 235
- mechanism of, 222, 235
- retroversion of, 234, Fig. 92, 235
- a cause of menorrhagia, 137
- of sterility, 151
- caused by an overdistended bladder, Fig. 84, 218
- rudimentary, 198
- sarcoma of, 278, Fig. 113, 279
- in the child, 576
- septus, 200, Fig. 75, 198
- souffle of, 429
- subinvolution of, 207
- a cause of hemorrhage at menopause, 618
- differentiated from pregnancy, 431
- supravaginal elongation of, Fig. 88, 226
- torsion of, 243
- transverse longitudinal section of, Fig. 68, 172
- tubes, vagina, and, development of, Fig. 71, 198
- unicornis, Fig. 76, 199, 200
- with accessory cornu, Fig. 77, 199
- walls of, structure of, 167
- VAGINA, absence of, 356
- age changes in, 356
- anatomy of, 354
- anterior fornix of, 354
- anterior wall, tumor of, differentiated from cystocele, 368
- appearance of, in early pregnancy, 421
- atresia of, a cause of amenorrhea, 142
- of dysmenorrhea, 129
- of sterility, 150
- acquired, 359
- congenital, 357
- atrophic changes in, in old age, 625
- atrophy of, at menopause, 595

- Vagina, cancer of, 383
 chorioepithelioma of, metastatic, Fig. 115, 282
 primary, 384
 secondary, Fig. 115, 282
 column of, 355
 condylomata of, 384
 cross section of, Fig. 151, 374
 cysts of, 379
 in anterior wall, Fig. 154, 381
 in posterior wall, Fig. 153, 380
 development of, Figs. 158-161-162, 395
 discharge from, normal, 143, 355.
 See also Leucorrhea
 diseases of, 354
 displacements of, 366
 double, 357, Fig. 147, 358
 enterocele of, 371
 examination of, in children, 556
 fibroids of, 381
 fistulae of, 384
 scheme of, Fig. 155, 385
 foreign bodies in, 377
 garrulity of, 378
 gas in, 378
 hematoma of, 377
 hernia of, 368, 371
 differentiated from cystocele, 368
 inclusion cyst of posterior wall of, Fig. 153, 380
 infantile, examination of, with cystoscope, Fig. 205, 559
 inflammations of, 361
 injuries of, 371
 at menopause, 621
 due to coitus, 376
 due to falls on sharp bodies, 377
 due to unskillful instrumentation, 377
 etiology of, 371
 longitudinal section of, showing S-shaped curve, Fig. 85, 219
 malformations of, 356
 myoma of, 381
 new growths of, 379
 palpation of, 34
 posterior fornix of, 355
 prolapse of, Fig. 88, 224
- Vagina, sarcoma of, 381
 in adults, 382
 in children, 382, 570
 septate, 357
 stenosis of, acquired, 359
- Vaginal touch. See Touch, vaginal
- Vaginismus, 378
 a cause of dyspareunia, 146
 of sterility, 150
- Vaginitis, 361
 a cause of sterility, 150
 acute, 362
 chronic, 363
 condylomatous, 363
 diphtheritic, 362
 emphysematosa, as a cause of garrulity of vagina, 378
 emphysematous, 364
 erysipelatos, 362
 exfoliative, differentiated from membranous dysmenorrhea, 131
 gonorrhoeal, 363
 myeotic, 364
 pseudo-diphtheritic, 362
 senile, 365
 syphilitic, 365
 tuberculous, 365
 ulcerative, 364
 with bacillary dysentery, 364
- Valves, Houston's, 122
 semilunar, of rectum, 122, 123
- Vander Veer, operations on pregnant women by mistake, 417
- Varicocele and varix. See Ligament, broad, and Vulva
- Veit, J., on chorioepithelioma, 282
 on garrulity of the vagina due to a gas-forming bacillus, 378
 on vaginal atresia, a cause of hæmatoelpos, 359
- Vesical symptoms, 151
 at menopause, 621
- Vestibule, Fig. 156, 389
 anatomy of, 390
- Vinay, L., on goitre and the menopause, 593
 on sclerosis of the ovaries in tuberculosis, 599
- Vineberg, views on lactation atrophy of uterus, 203

- Volkman, on acute carcinoma of mastitis, 543
- Vomiting of pregnancy, 434
- Von Ott leg holders, 57
- Vulva, age changes in, 391
- anatomy of, 388
 - angioma of, 413
 - anomalies of, 391
 - at beginning of third month of fetal life, Fig. 157, 392
 - atrophic changes in, in old age, 625
 - benign tumors of, 413
 - cancer of, 414
 - chancre of, 406
 - differentiated from cancer, 415
 - chancroids of, 406
 - differentiated from cancer, 415
 - condylomata of, differentiated from cancer, 415
 - condylomata acuminata of, 407
 - condylomata lata of, 407
 - congestion of, a cause of pruritus, 161
 - development of, 392
 - diagram of, Fig. 156, 389
 - diseases of, 388
 - eczema of, a cause of pruritus, 161
 - edema of, 405
 - elephantiasis of, 404
 - fibroma of, 413
 - furunculosis of, differentiated from chancre, 407
 - gangrene of, 405
 - in the child, 569
 - gumma of, 408
 - hematoma of, 400
 - herpes of, differentiated from chancre, 407
 - in early pregnancy, appearance of, 421
 - infantile, Fig. 203, 556
 - inflammation of, 402
 - injuries of, 400
 - due to coitus, 401
 - due to direct violence, 401
 - inspection of, 33
 - itching of, 160, 404
 - lipoma of, 413
 - in a child, 573
 - malignant tumors of, 414
- Vulva, mucous patches of, 407
- myoma of, 413
 - myxoma of, 413
 - neuroma of, 413
 - noma of, 405
 - in the child, 569
 - sarcoma of, 416
 - thrush of, 403
 - a cause of pruritus, 161
 - tuberculosis of, 408
 - differentiated from cancer, 415
 - in the child, 568
 - tumors of, a cause of sterility, 150
 - uncleanliness of, a cause of pruritus, 161
 - varicose veins of, 405
 - varix of, 405
 - a cause of pruritus, 161
 - venereal lesions of, 406
- Vulvitis, a cause of pruritus, 161
- catarrhal, 402
 - diabetic, 403
 - diphtheritic, in the child, 569
 - gonorrhoeal, 402
 - simple, 402
- Vulvo-vaginitis in children, 566
- diagnosis of, 568
 - symptoms of, 568
- WARKER, VAN DE, on frequency of strictures of urethra, 452
- Wathen uterine dilator, Fig. 34, 92
- Webster, J. C., case of wandering spleen in iliac fossa, 312
- on renal complications in fibroid tumors, 257
- Wertheim, views on latent gonorrhoea, 182
- Whites. See Leucorrhoea
- Williams, J. W., cases of ovarian pregnancy, 245
- on etiology of extra-uterine pregnancy, 342
 - on pernicious vomiting of pregnancy, 434
- Winckel, case of spontaneous healing of vesico-vaginal fistula following subsequent pregnancy, 477
- Winter, cancer propaganda in East Prussia, 270

- Winter, observations on the heart in fibroid tumors, 259
on metastases in sarcoma of the uterus, 280
- Wischmann, C., case of precocious maturity, 564
- Worry, polyuria in, 485
- X-RAYS in diagnosis, 76
- YOUNG GIRLS, examination of, 25
- ZAPPERT, J., on genital hemorrhages in the new-born, 572
- Zweifel, views on frequency of gonorrhoea, 179

157
61
UC SOUTHERN REGIONAL LIBRARY FACILITY

A 000 510 136 5

WP141
B968g
1910
Burrage, Walter L
Gynecological diagnosis.

WP141
B968g
1910
Burrage, Walter L
Gynecological diagnosis.

MEDICAL SCIENCES LIBRARY
UNIVERSITY OF CALIFORNIA, IRVINE
IRVINE, CALIFORNIA 92664

