



3 1761 06704235 8

BNA















Digitized by the Internet Archive  
in 2007 with funding from  
Microsoft Corporation



ANATOMICAL TERMINOLOGY

---

BARKER



37.  
3.

# ANATOMICAL TERMINOLOGY

WITH SPECIAL REFERENCE TO THE [BNA]

BY

LEWELLYS F. BARKER, M.D.

PROFESSOR OF MEDICINE, JOHNS HOPKINS UNIVERSITY, BALTIMORE; (FORMERLY PROFESSOR OF  
ANATOMY, RUSH MEDICAL COLLEGE, UNIVERSITY OF CHICAGO).

With Vocabularies in Latin and English  
and Illustrations

85045  
10/12/07

PHILADELPHIA:  
P. BLAKISTON'S SON & CO.  
1012 WALNUT STREET.  
1907

---

COPYRIGHT, 1907, BY P. BLAKISTON'S SON & CO.

---

WM. F. FELL COMPANY  
ELECTROTYPERS AND PRINTERS  
1220-24 SANSON STREET  
PHILADELPHIA, PA.



# CONTENTS

	PAGE
INTRODUCTION,.....	I
WHAT THE BNA IS,.....	2
WHY THIS REVIEW OF ANATOMICAL TERMINOLOGY WAS UNDERTAKEN,.....	2
THE SCOPE OF THE WORK AND THE WORKERS,.....	4
THE WAY THE WORK WAS DONE,.....	5
THE PRINCIPLES ARRIVED AT AS THE WORK PROCEEDED,.....	6
THE ADOPTION OF THE BNA IN AMERICA AND GREAT BRITAIN,.....	8
THE FUTURE OF ANATOMICAL TERMINOLOGY,.....	II
ANATOMICAL NAMES,.....	14
Terms Indicating the Position and Direction of Parts of the Body,.....	14
General Terms,.....	14
Terms Relating to the Extremities,.....	14
GENERAL ANATOMICAL TERMS,.....	15
PARTS OF THE HUMAN BODY,.....	17
Head,.....	17
Skull,.....	17
Face,.....	17
Eye,.....	17
Nose,.....	17
Mouth,.....	17
Neck,.....	17
Trunk,.....	17
Thorax,.....	17
Back,.....	17
Belly,.....	18
Pelvis,.....	18
Upper Extremities,.....	18
Lower Extremities,.....	18
OSTEOLOGY,.....	19
Vertebral Column, or Spine,.....	19
Atlas,.....	19
Epistropheus (O. T. Axis),.....	20
Sacrum,.....	20
Coccyx,.....	20
Thorax,.....	20
Ribs,.....	20
Breast Bone,.....	20
Thoracic Cavity,.....	20
Bones of the Skull,.....	20
Basilar Bone,.....	20
Occipital Bone,.....	20
Sphenoid Bone,.....	21
Temporal Bone,.....	22
Parietal Bone,.....	23
Frontal Bone,.....	23
Ethmoid Bone,.....	23
Inferior Turbinated Bone,.....	24
Lacrimal Bone,.....	24
Nasal Bone,.....	24
Vomer, or Ploughshare, Bone,.....	24
Bones of the Face,.....	24
Maxilla (O. T. Superior Maxillary Bone),.....	24
Palate Bone,.....	24

	PAGE
<b>OSTEOLOGY (Continued)</b>	
Ligaments of the Girdle of Lower Extremity (O. T. Pelvic Girdle),.....	34
Sacro-Iliac Joint,.....	35
Symphysis of Pubic Bones,.....	35
Hip Joint,.....	35
Knee Joint,.....	35
Tibiofibular Joint (O. T. Superior Tibiofibular Articulation),.....	35
Tibiofibular Syndesmosis (O. T. Inferior Tibiofibular Articulation),.....	35
Joints of the Foot,.....	35
Ankle Joint,.....	35
Intertarsal Joints,.....	36
Talocalcaneonavicular Joint,.....	36
Talocalcanean Joint,.....	36
Chopart's Transverse Articulation of the Tarsus,.....	36
Talonavicular Joint,.....	36
Calcaneocuboid Joint,.....	36
Cuneonavicular Joint,.....	36
Interosseous Ligaments of Tarsus,.....	36
Dorsal Ligaments of Tarsus,.....	36
Plantar Ligaments of Tarsus,.....	36
Tarsometatarsal Joints,.....	36
Intermetatarsal Joints,.....	36
Metatarsophalangeal Joints,.....	36
Joints of the Toes,.....	37
<b>MYOLOGY OR MUSCULATURE,</b> .....	37
Muscles of the Back,.....	37
Muscles of the Head,.....	38
Muscles of the Hyoid Bone,.....	38
Muscles of the Neck,.....	38
Muscles of the Thorax,.....	39
Muscles of the Abdomen,.....	39
Coccygeal Muscles,.....	40
Muscles of the Upper Extremity,.....	40
Muscles of the Lower Extremity,.....	41
<b>BURSÆ AND MUCOUS SHEATHS,</b> .....	43
<b>SPLANCHNOLOGY,</b> .....	45
Digestive Apparatus,.....	45
Mouth Cavity,.....	45
Mucous Membrane of the Mouth,.....	45
Glands of the Mouth,.....	45
Teeth,.....	46
Tongue,.....	46
Fauces,.....	46
Muscles of the Palate and Fauces,.....	47
Pharynx,.....	47
Digestive Tube,.....	47
Oesophagus,.....	47
Stomach,.....	47
Small or Thin Intestine,.....	48
Large or Thick Intestine,.....	48
Rectum or Straight Gut,.....	49
Pancreas,.....	49
Liver,.....	49
<b>RESPIRATORY APPARATUS,</b> .....	50
Nasal Cavity,.....	50
External Nose,.....	51
Larynx,.....	51
Muscles of Larynx,.....	52
Cavity of Larynx,.....	52
Trachea and Bronchi,.....	52
Lung,.....	52
Thoracic Cavity,.....	53
Thyreoid Gland,.....	53
Carotid Skein (O. T. Intercarotid Gland),.....	53

CONTENTS

V

	PAGE
RESPIRATORY APPARATUS ( <i>Continued</i> )	
Thymus,.....	53
UROGENITAL APPARATUS,.....	53
Uropoietic Organs,.....	53
Kidney,.....	53
Renal Arteries,.....	54
Renal Veins,.....	54
Ureter,.....	54
Urinary Bladder,.....	54
Suprarenal Gland,.....	54
Male Genital Organs,.....	55
Testicle,.....	55
Seminal Vesicle,.....	55
Spermatic Cord and Coats of the Testicle and Cord,.....	55
Prostate,.....	55
Bulbo-urethral Gland (O. T. Cowper's Gland),.....	56
Parts of External Genitals,.....	56
Penis,.....	56
Male Urethra,.....	56
Scrotum,.....	56
Female Genital Organs,.....	56
Ovary,.....	56
Uterine Tube (O. T. Fallopian Tube),.....	56
Uterus,.....	57
Vagina,.....	57
Epo-ophoron (O. T. Parovarium or Organ of Rosenmueller),.....	57
External Genital Parts,.....	57
Paro-ophoron,.....	57
Large Vestibular Gland of Bartholin,.....	57
Clitoris,.....	57
Female Urethra,.....	58
Perineum,.....	58
Peritoneum,.....	58
ANGIOLOGY,.....	60
Heart,.....	60
Right Atrium (O. T. right auricle),.....	61
Right Ventricle,.....	61
Left Atrium (O. T. Left Auricle),.....	61
Left Ventricle,.....	61
Arteries,.....	61
Pulmonary Artery,.....	61
Aorta,.....	61
Innominate Artery,.....	62
Common Carotid Artery,.....	62
External Carotid Artery,.....	62
Superior Thyreoid Artery,.....	62
Ascending Pharyngeal Artery,.....	62
Lingual Artery,.....	62
External Maxillary Artery (O. T. Facial Artery),.....	62
Sternocleidomastoid Artery,.....	62
Occipital Artery,.....	62
Posterior Auricular Artery,.....	62
Superficial Temporal Artery,.....	62
Internal Maxillary Artery,.....	62
Internal Carotid Artery,.....	63
Ophthalmic Artery,.....	63
Cerebral Arteries,.....	63
Subclavian Artery,.....	63
Vertebral Artery,.....	63
Basilar Artery,.....	63
Internal Mammary Artery,.....	63
Thyreocervical Trunk (O. T. Thyreoid Axis),.....	63
Inferior Thyreoid Artery,.....	63
Ascending Cervical Artery,.....	64

ANGIOLOGY, Subclavian Artery ( <i>Continued</i> )	PAGE
Superficial Cervical Artery,.....	64
Transverse Artery of Scapula (O. T. Suprascapular),.....	64
Costocervical Trunk (O. T. Superior Intercostal),.....	64
Transverse Artery of Neck (O. T. Transversalis Coli),.....	64
Axillary Artery,.....	64
Highest Thoracic Artery (O. T. Superior Thoracic Artery),.....	64
Thoraco-Acromial Artery (O. T. Thoracic Axis),.....	64
Lateral Thoracic Artery (O. T. Long Thoracic),.....	64
Subscapular Artery,.....	64
Anterior Circumflex Artery of Humerus,.....	64
Posterior Circumflex Artery of Humerus,.....	64
Brachial Artery,.....	64
Deep Artery of Upper arm (O. T. Superior Profunda),.....	64
Superior Ulna Collateral Artery (O. T. Inferior Profunda),.....	64
Inferior Ulna Collateral Artery (O. T. Anastomotica Magna),.....	64
Radial Artery,.....	64
Ulnar Artery,.....	65
Thoracic Aorta,.....	65
Intercostal Arteries,.....	65
Abdominal Aorta,.....	65
Inferior Phrenic Artery,.....	65
Lumbar Arteries,.....	65
Middle Sacral Artery,.....	65
Coeliac Artery,.....	65
Superior Mesenteric Artery,.....	66
Inferior Mesenteric Artery,.....	66
Middle Suprarenal Artery (O. T. Middle Capsular Artery),.....	66
Renal Artery,.....	66
Internal Spermatic Artery,.....	66
Testicular Artery,.....	66
Ovarian Artery,.....	66
Common Iliac Artery,.....	66
Hypogastric Artery (O. T. Internal Iliac),.....	66
Iliolumbar Artery,.....	66
Lateral Sacral Artery,.....	66
Obturator Artery,.....	66
Superior Gluteal Artery,.....	66
Inferior Gluteal Artery,.....	66
Umbilical Artery,.....	66
Inferior Vesical Artery,.....	66
Deferential Artery,.....	66
Uterine Artery,.....	66
Middle Hemorrhoidal Artery,.....	66
Internal Pudendal Artery,.....	66
External Iliac Artery,.....	66
Inferior Epigastric Artery (O. T. Deep Epigastric),.....	66
Deep Circumflex Iliac Artery,.....	67
Femoral Artery,.....	67
Popliteal Artery,.....	67
Anterior Tibial Artery,.....	67
Posterior Tibial Artery,.....	67
Veins,.....	68
Pulmonary Veins,.....	68
Veins of the Heart,.....	68
Superior Vena Cava,.....	68
Right and Left Innominate Veins,.....	68
Internal Jugular Vein,.....	68
Sinuses of the Dura Mater,.....	68
Cerebral Veins,.....	69
Superior Ophthalmic Vein,.....	69
Common Facial Vein,.....	69
Anterior Facial Vein,.....	69
Posterior Facial Vein,.....	69



	PAGE
ANGIOLOGY, Veins ( <i>Continued</i> )	
External Jugular Vein, .....	69
Subclavian Vein, .....	70
Axillary Vein, .....	70
Azygos Vein (O. T. Vena Azygos Major), .....	70
Inferior Vena Cava, .....	70
Portal Vein, .....	70
Common Iliac Vein, .....	71
Hypogastric Vein (O. T. Internal Iliac Vein), .....	71
External Iliac Veins, .....	71
Lymphatic System, .....	71
Lymphatic Vessels, .....	71
Thoracic Duct, .....	72
Lymph Glands, .....	72
Lymphatic Plexuses, .....	72
NEUROLOGY, .....	73
Central Nervous System, .....	73
Spinal Cord, .....	73
Sections of the Spinal Cord, .....	73
Brain, .....	74
Medullary or After-Brain, .....	74
Medulla Oblongata, .....	74
Sections of Medulla Oblongata, .....	74
Fourth Ventricle, .....	75
Hind-Brain, .....	75
Pons ("Bridge") Varolii, .....	75
Sections of the Pons, .....	75
Cerebellum or Small Brain, .....	75
Sections of Cerebellum, .....	76
Isthmus of Rhombencephalon, .....	76
Sections of Isthmus, .....	76
Cerebrum (Large Brain), .....	76
Midbrain, .....	76
Inferior Surface, .....	76
Peduncle of Cerebrum (O. T. Crus Cerebri), .....	77
Sections of Cerebral Peduncle, .....	77
Quadrigeminal Bodies (O. T. Optic Lobes), .....	77
Sections of Quadrigeminal Bodies, .....	77
Forebrain, .....	77
Interbrain, .....	77
Hypothalamus (O. T. Subthalamic Region), .....	77
Sections of the Hypothalamus, .....	77
Thalamic Brain, .....	78
Thalamus (O. T. Optic Thalamus), .....	78
Metathalamus, .....	78
Epithalamus, .....	78
Sections of the Thalamic Brain, .....	78
End-Brain, .....	78
Hemisphere, .....	78
Brain Mantle, .....	78
Medial Surface of Hemisphere, .....	79
Fornix, .....	79
Transparent Septum, .....	80
Lateral Ventricle, .....	80
Olfactory Brain, .....	80
Sections of End-Brain, .....	80
Membranes of Brain, .....	81
Peripheral Nervous System, .....	81
Cerebral Nerves, .....	81
Olfactory Nerves, .....	81
Optic Nerve, .....	81
Oculomotor Nerve (O. T. Third Nerve), .....	81
Trochlear Nerve (O. T. Patheticus or Fourth Nerve), .....	81
Trigeminal Nerve (O. T. Fifth Nerve), .....	82

	PAGE
NEUROLOGY, Peripheral Nervous System, Cerebral Nerves ( <i>Continued</i> )	
Ophthalmic Nerve,.....	82
Maxillary Nerve (O. T. Superior Maxillary),.....	82
Mandibular Nerve (O. T. Inferior Maxillary),.....	82
Abducent Nerve (O. T. Sixth Nerve),.....	83
Facial Nerve,.....	83
Acoustic (O. T. Auditory Nerve),.....	83
Glossopharyngeal Nerve,.....	83
Vagus Nerve (O. T. Pneumogastric Nerve),.....	84
Accessory Nerve (O. T. Spinal Accessory),.....	84
Hypoglossal Nerve,.....	84
Spinal Nerves,.....	84
Cervical Nerves,.....	85
Brachial Plexus,.....	85
Median Nerve,.....	85
Ulnar Nerve,.....	85
Radial Nerve (O. T. Musculospiral),.....	86
Thoracic Nerves,.....	86
Lumbar, Sacral, and Coccygeal Nerves,.....	86
Lumbosacral Plexus,.....	86
Lumbar Plexus,.....	86
Iliohypogastric Nerve,.....	86
Ilio-inguinal Nerve,.....	86
Genitofemoral Nerve (O. T. Genitocrural Nerve),.....	86
Lateral Cutaneous Nerve of Thigh (O. T. External Cutaneous),.....	86
Obturator Nerve,.....	86
Femoral Nerve (O. T. Anterior Crural),.....	87
Sacral Plexus,.....	87
Sciatic Nerve (O. T. Great Sciatic),.....	87
Pudendal Plexus,.....	87
Coccygeal Nerve,.....	87
Sympathetic System of Nerves,.....	88
Cephalic and Cervical Portions of the Sympathetic System,.....	88
Thoracic Portion of the Sympathetic System,.....	88
Abdominal and Pelvic Portions of the Sympathetic System,.....	88
SENSE ORGANS AND COMMON INTEGUMENT,.....	89
Organ of Vision,.....	89
Eye,.....	89
Optic Nerve,.....	89
Eyeball,.....	89
Fibrous Tunic of Eye,.....	89
Sclera (O. T. Sclerotic Coat),.....	89
Cornea,.....	89
Vascular Coat of Eye,.....	89
Chorioid,.....	89
Ciliary Body,.....	90
Iris or Diaphragm of the Eye,.....	90
Layer of Pigment,.....	90
Retina,.....	90
Anterior Chamber of the Eye,.....	90
Posterior Chamber of the Eye,.....	90
Vitreous Body,.....	90
Crystalline Lens,.....	90
Ciliary Zonule (O. T. Zonule of Zinn),.....	91
Accessory Organs of the Eye,.....	91
Eye Muscles, Orbital Fasciae,.....	91
Eyebrow,.....	91
Eyelids,.....	91
Conjunctiva,.....	91
Lacrimal Apparatus,.....	91
Organ of Hearing,.....	92
Internal Ear,.....	92
Membranous Labyrinth,.....	92
Osseous Labyrinth,.....	92

CONTENTS

ix

	PAGE
SENSE ORGANS AND COMMON INTEGUMENT, Organ of Hearing ( <i>Continued</i> )	
Vestibule,.....	92
Cochlea,.....	92
Internal Acoustic Meatus,.....	93
Cavity of Tympanum,.....	93
Membrane of the Tympanum (O. T. Drumhead),.....	93
Auditory Ossicles,.....	93
Joints of the Auditory Ossicles,.....	94
Ligaments of the Auditory Ossicles,.....	94
Muscles of the Auditory Ossicles,.....	94
Tympanic Mucous Coat,.....	94
Auditory or Eustachian Tube,.....	94
External Acoustic Meatus,.....	94
External Ear,.....	94
Organ of Smell,.....	95
Organ of Taste,.....	95
Common Integument,.....	95
Skin,.....	95
Epidermis or Scarf Skin,.....	95
Corium or Leather Skin,.....	95
Subcutaneous Tissue,.....	95
Terminal Corpuscles of the Nerves,.....	95
Hair,.....	95
Nails,.....	96
Glands of the Skin.....	96
Coil Glands,.....	96
Sebaceous Glands,.....	96
Breast,.....	96
REGIONS OF THE HUMAN BODY,.....	97
of the Head,.....	98
of the Face,.....	98
of the Neck,.....	98
of the Breast,.....	99
of the Abdomen,.....	99
of the Back,.....	99
of the Upper Extremity,.....	99
of the Lower Extremity,.....	100
EXPLANATORY NOTES TO CERTAIN TERMS,.....	101
COLORED PLATES OF REGIONS,.....	105-107





# THE BASLE ANATOMICAL NOMENCLATURE [BNA].

---

## Introduction.

Now that the BNA is being followed in medical and scientific schools throughout the world, and has been adopted as the language used in several of the newer English and American anatomical text-books and atlases, it has occurred to the publishers of Morris's Anatomy that a concise statement concerning the origin and exact nature of this list of anatomical terms would be interesting and helpful to anatomists, physiologists, biologists, pathologists, and clinicians. They have asked me to prepare this statement, and I do so gladly, in the hope that it may bring the terminology to the attention of many who do not yet know of it, and make clear, perhaps, certain misunderstandings that have existed in the minds of some who have heard of it, but are not yet really familiar with it. To know its origin, nature, and aims is, I feel sure, in the majority of instances at least, to decide to use it. That the sooner a general decision to adopt it is reached the better it will be for anatomical instruction and research, and the easier it will be for teacher and taught, it is the aim of the following paragraphs to show. They have not been difficult to write, for, aside from the experience I have gained by personally using the BNA in anatomical laboratories during the past ten years, the material for the account lay ready at hand in the articles of Krause\* and His† and it has been necessary only to adapt it to the needs of readers in America and Great Britain. The article by Professor His has been followed especially closely, and parts of my account are no other than a free translation of his lucid paragraphs. The actual list of Latin names of the BNA is to be published at once by Messrs. P. Blakiston's Son & Co. and Messrs. J. & A. Churchill. It will be accompanied by a list of literal English equivalents which Dr. Benson A. Cohoe, Assistant Resident Physician in the Johns Hopkins Hospital, has been kind enough to help me to prepare. The English vocabulary is simply explanatory; in many instances it would be unwise to use the English synonyms given, and in many more instances anatomists would differ as to the most suitable English equivalent to be chosen. Each anatomist is of course at liberty to use whatever English equivalent he desires for the official Latin terms. Students are strongly advised, however, to use the original Latin terms as English words. The Latin terms are the only authorized ones.

\*Krause, W.: Die anatomische Nomenclatur. Internat. Monatsschr. f. Anat. u. Physiol., 1893, x, 313.

†His, W.: "Die anatomische Nomenclatur. Nomina anatomica, Verzeichniss der von der anatomischen Gesellschaft auf ihrer IX. Versammlung in Basel aufgenommenen Namen Eingeleitet und im Einverständniss mit dem Redactionsausschuss erläutert. Mit dreissig Abbildungen in Text und zwei Tafeln". Leipzig, Veit & Co., 1895. (Reprinted from the Arch. f. Anat. u. Physiol. anat. Abth. Leipzig, 1895, Supplement-Band.)

### What the "BNA" is.

The expression BNA is a shorthand title for a list of some 4500 anatomical terms (*nomina anatomica*) accepted at Basle in 1895 by the Anatomical Society as the most suitable designations for the various parts of the human anatomy which are visible to the naked eye. The terms are all in correct Latin and have been selected by a group of the most distinguished anatomists in the world, working six years at their task, as the shortest and simplest available names for the different structures; the majority of the terms were already in use in the various text-books, but some of them were selected from anatomical monographs not considered in the text-books, and a few of them are brand-new, introduced into the list, where an examination of the literature and of anatomical preparations showed that none of the terms hitherto coined was satisfactory.

One name only is given to each structure, and the mass of synonyms which encumbered the text-books can thus be swept away. If one of the larger text-books of gross anatomy be examined, as many as 10,000 terms will be found employed, the half of which are synonyms; and if the anatomical terms used in the various standard text-books be collected into one list, the total number amounts to more than 30,000. It is no small achievement to have reduced the necessary number of terms in gross anatomy, as it is known to-day, to less than 5000,—an achievement for which both students and teachers of the subject must be thankful.

Even more important is the exclusion from the list of all obscure or ambiguous terms, each name employed having a definite and easily ascertainable meaning. The construction of the list has led, too, to the establishment of certain general principles regarding the formation and use of anatomical terms, and these principles promise to be of great service in simplifying terminology and keeping it uniform as anatomical science continues to develop.

### Why this revision of anatomical terminology was undertaken.

Previous to undertaking this revision of the names used in gross anatomy, the burden of terms which had to be carried by text-book, teacher, and pupil had been growing progressively heavier. Anatomical structures had been christened in a most haphazard way. From the beginning of the science each investigator gave names as he would to the parts he studied, and as one investigator was often ignorant of the work done by others the same parts were frequently differently dubbed. The authors of anatomical text-books, especially those who read widely, gradually collected these terms, though each author selected and jerected names from the lists used by his predecessors as he thought fit.

It has thus come about that we have inherited from previous centuries an excess of anatomical terms, many single structures carrying double or even multiple designations. Examples come at once to mind: The pneumogastric nerve is also the vagus nerve as well as the tenth cerebral nerve; the trapezius muscle is known to some as the *musculus cucullaris*; the laryngeal prominence is also Adam's apple; the aqueduct of the cerebrum is also, in many books, the *iter e tertio ad quartum ventriculum*; *m. levator palati* is synonymous with *m. petrosalpingostaphylinus*. These double and multiple terms were passed on from lecture to lecture and from text-book to text-book, and as a result of this anarchy in the creation and use of terms the weight became terribly grievous. Teachers and pupils writhed under it. Anatomical research was, to some extent at least, retarded by it. When the *valvula coli* was known also variously as the *valvula ileocecalis*, the *valvula Bauhini*, the *valvula Tulpai*, and the *valvula Fallopii*, a certain historical sense may have been aroused and opportunity

given, as His suggests, for the discussion of fossil questions of priority, but the inconveniences of such ballast were sufficiently obvious.

As this naming went on by the authors of individual text-books or monographs, a great many terms were proposed which never became current; others were gradually employed in a sense other than that originally intended; some attained to general anatomical parlance. It was the success that a name met with which justified its adoption in the science, although often, as examination has shown, it was fashion which in her imperious way decided, sometimes suddenly replacing an entirely suitable anatomical term by another, no better. The names arising, as it were, by chance and at totally different periods in the various anatomical systems, it was scarcely possible that anatomical terminology as a whole could manifest any general plan or have much uniformity of character; it was necessarily chaotic and incoherent,—full of inequalities, contradictions, and obscurities.

The distinguished German anatomist, J. Henle, when writing his well-known treatise, felt keenly the faults of the inherited terminology and made a great effort at improvement. In his text-book of anatomy he gave only one name to each structure, banishing all synonyms to the footnotes; he waged war against personal names, and replaced them by objective terms, urging that historical injustice was frequently done by their retention. It is to Henle, also, that we owe the introduction and consistent use of those excellent terms of orientation,—the words sagittal, frontal, medial, lateral, etc. But even as great an anatomist as Henle could not simplify anatomical terminology satisfactorily without the sympathetic coöperation of other anatomists. Each great medical school had to a certain extent its own anatomical language, and the physician who tried to read articles in which the terms of schools other than that in which he had been brought up were used met with irritating difficulties. A student going from one university to another often found that the anatomical expressions acquired with great difficulty in the one had to be supplanted by another set of terms, equally hard to learn, in the other.

This harmful and humiliating state of affairs stirred up in anatomists in various countries a strong feeling for the necessity of remedy. Anatomical societies in America, in Germany, and in Great Britain interested themselves much in the problem. In America it was Professor Burt G. Wilder, of Ithaca, who felt most keenly the need of reform in terminology. He deserves great credit for his efforts to stimulate other American anatomists to a realization of this need, as well as for the time and labor he has given to attempt to improve and simplify anatomical terms.\* He writes me that the matter of terminology was definitely brought before the American Association for the Advancement of Science as long ago as 1880, and states that in connection with the revision of terminology in America the names of Messrs. Gage, Gerrish, Gould, Huntington, Leidy, and the Spitzkas, father and son, should be mentioned.

The movement for revision of terminology which originated in Germany in the enlarged Anatomical Society at its first meeting in Leipsic, in 1887, is the

\*Cf. Wilder, B. G.: "The Fundamental Principles of Anatomical Nomenclature" (Med. News, Phila., 1891, December 19); "Macroscopical Vocabulary of the Brain," presented to the Association of American Anatomists at Boston, Mass., December 20, 1890; "American Reports upon Anatomical Nomenclature," 1889-1890, with notes by B. G. Wilder, Cornell University, February 5, 1892; "Anatomical Terminology," by B. G. Wilder and S. H. Gage, in the first edition of Wood's Reference Handbook of the Medical Sciences; "Neural Terms, International and National," 1896; "Some Misapprehensions as to the Simplification of the Nomenclature of Anatomy," 1898. The Reports of the Committee of the Association of American Anatomists may also be consulted.



one which resulted finally in the production of the BNA. The Society in that year voted that its officers undertake at once a revision of anatomical terms, with the hope of remedying the obvious evils existing. No sooner did these officers begin their work, however, than unforeseen difficulties began to appear, and these did not lessen in number or significance as the work progressed. Anatomists may rejoice that the difficulties were not insuperable. How they were overcome and what the results achieved were, I shall try to explain in the paragraphs which succeed.

### The Scope of the Work and the Workers.

It soon became clear that a permanent commission on terminology could deal more effectively with the problem than the officers of the Society. Again, an editor-in-chief, who should devote himself almost entirely to the work for a number of years, must of necessity be appointed. These suggestions, emanating from Professor His, were adopted by the Society in 1889. The Commission on Nomenclature was at once appointed, with Professor von Kölliker as Chairman and Professors O. Hertwig, His, Kollmann, Merkel, Schwalbe, Toldt, Waldeyer, and v. Bardeleben as members,—a list of names as likely, surely, as any that could have been chosen to insure success from the start.

This Commission began its work most happily by securing the services of Professor W. Krause, of Berlin, as editor-in-chief. Krause's literary ability made the choice especially suitable. During the six years' work which followed his appointment he set an example, his collaborators tell us, of indefatigable diligence and inexhaustible patience. The necessary correspondence of such an editor was almost interminable; letters often passed to and fro for weeks in order to set a single term right or to get it into its proper place in the list.

The cost of the undertaking was a matter for early consideration. The work, while largely a labor of love, entailed unavoidably certain expenses. The original estimate of the Commission of 10,000 marks (\$2500) was exceeded only a little. It seems almost incredible that the work could have been accomplished with so small an outlay. A large proportion of the cost (some 8090 marks) was defrayed by the scientific academies of Munich, Berlin, Vienna, Leipsic, and Hungary; the rest of the amount (3800 marks) was contributed by the Anatomical Society itself.

The exact scope of the work had, of course, to be clearly before the minds of the members of the Commission from the outset. It was decided, therefore, to consider descriptive anatomy solely, and this only in as far as the structures are visible to the naked eye or through a simple hand lens. No attempts were to be made to settle the terminology in domains of lively contemporary investigation, nor were the terms of microscopic anatomy to be included. The list was to be constructed in one language—viz.: Latin; those who use the terminology were left, therefore, to translate, at will, the terms more or less freely, into their own tongues.

The question in how far the terminology should attempt to be international in character was a delicate one for the Commission to determine. The Anatomical Society, while organized in Germany and meeting usually only in cities in which the German language is spoken, has never been exclusively German in membership or character. Indeed, the list of members includes names from America, Austria, Belgium, Denmark, England, France, Hungary, Italy, Russia, Sweden, and Switzerland. The majority of members are German, it is true; in 1895 there were 145 German members to 129 members belonging to other countries. A society with such a membership might, perhaps, without criticism,

undertake the establishment of a terminology intended for international use. It was decided, however, not to make the undertaking too wide at the beginning, to try rather to form a list of terms which should, in the first place, be acceptable to German-speaking anatomists and, later on, to attempt to gain the coöperation of anatomists who speak other languages. Though the names of the Commission originally appointed are all those of German or Austrian anatomists, the lists of anatomical terms considered were, from the beginning, taken from French and English as well as from German books. In 1890 several anatomists from Great Britain and other European countries were invited to join the Commission, and, later, Professor Thane of London was included. It was partly owing, doubtless, to the relatively undeveloped state of anatomy at the time in American universities, partly to the fact that few, if any, of our anatomists then attended the meetings of the Anatomical Society, that no one from this country was invited to join the Commission. Were another revision to be made by the Society to-day, American anatomists would undoubtedly be requested to act. The terminology which the Commission prepared and which was accepted by the Society in Basle, in 1905, was, in origin and in execution, therefore, the affair of the Anatomical Society and is to be regarded as international only in as far as that Society and its affiliations may be so regarded.

#### The Way the Work was done.

It is interesting to learn the methods followed by the Commission in the accomplishment of its task. The plan adopted at the beginning was greatly modified as the work proceeded. Myology, as it promised to be much the easiest, was the first subject undertaken. The editor took as a basis the names used in the latest large text-book of gross anatomy.\* These terms were written down in a vertical column and the synonyms from a number of other much-used text-books placed in parallel columns. The lists were manifolded and a copy sent to each commissioner with the request that he mark the term of his choice, or if he found none suitable to propose a new one for the structure concerned. Each commissioner was to return his list with comments to Professor Krause.

When the first vote on myological terms was counted it was found that the names of 85 per cent. of the structures had received a majority vote,—more than 40 per cent. receiving practically unanimous approval. This surprising result was most encouraging. A second list was then made out indicating the accepted names, the terms still not decided upon, and the list of new terms proposed, and it, together with the comments made by the various commissioners, was again distributed. After the second vote any terms left undetermined were discussed and settled in personal sittings of the Commission. By June, 1891, the myological terminology was complete with a list of some 300 terms.

As a result of its early experience the Commission found that a second and third vote made by correspondence gave results but little better than the first vote. Further, it was soon learned that the new terms proposed and the comments made by the members, often as a result of hard work and special knowledge, were insufficiently considered unless each new term and comment were verbally discussed in personal meetings of the commissioners. On attempting such verbal discussion, however, in 1892, it was found that progress was made too slowly in the full Commission and it became necessary to parcel out the work to special committees. Thus the list of terms in Angiology was assigned to Professors Merkel, Thane, and Toldt; that in Regional Anatomy to Pro-

\* This happened to be C. Gegenbaur's "Lehrbuch der Anatomie des Menschen."



fessors Merkel, Rüdinger, and Toldt, while Professor Toldt was made a committee of one to consider the terminology of joints.

Another important step consisted in the appointment of a special editing committee consisting of Professors His, Krause, and Waldeyer. To this committee was delegated the task of giving a uniform character to the terminology as a whole, a matter of no little difficulty. Since the single systems had been voted upon at long intervals, the different terms accepted had received variable majorities. There was a considerable residue of terms still undetermined in the parts already considered and the whole list contained inequalities and even contradictions which had to be corrected. Indeed, this editing committee found itself deeply immersed in the hardest kind of work for no less than three years after it was appointed. The terminology of the nervous system and of the viscera proved to be the most difficult of all. In these chapters the completed list is deeply indebted especially to Professor His and to the support and advice he received from Professors von Kölliker, Toldt, and Waldeyer.

During the last three of the six years' work it was found that results were most quickly and satisfactorily reached by adopting the following program: First, the members of the Commission were asked to send in their special suggestions and comments for the unfinished lists even before the first vote was taken, so that they could be considered on the primary ballot. The editor-in-chief, after this vote had been made, rearranged the lists and turned them over to the editing committee, the members of which reconsidered each term separately and decided doubtful questions. This committee often found it necessary to refer to the bibliography and even to dissections to help it in its decisions. The lists thus edited were returned to the Commission for final comments. These, when received, were thoroughly studied by the editing committee, and in 1895 the definitive list was presented by the Commission to the Anatomical Society as a whole at its meeting in Basle. The Society voted its adoption.

### The Principles arrived at as the Work proceeded.

As the six years' work of the Commission proceeded certain principles of terminology crystallized out and simplified the further revision. It was found, however, that while these principles were of value as general rules, none of them could be employed absolutely without exception. The more important decisions arrived at were the following:

- (1) Each part shall have only one name.
- (2) Each term shall be in Latin and be philologically correct.
- (3) Each term shall be as short and simple as possible.
- (4) The terms shall be merely memory signs and need lay no claim to description or to speculative interpretation.
- (5) Related terms shall, as far as possible, be similar—*e. g.*, Femur, Arteria femoralis, Vena femoralis, Nervus femoralis.
- (6) Adjectives, in general, shall be arranged as opposites—*e. g.*, dexter and sinister, major and minor, anterior and posterior, superficialis and profundus.

The Commission was occasionally forced to deviate from these rules. Thus, the first one was violated with the mitral valve, which is named *valvula bicuspidalis* and *valvula mitralis*, neither term being omitted (a concession to clinicians). The third rule, while usually easily followed (few would care to retain the terms *crotaphitico-buccinatorius* or *petrosalpingostaphylinus*), could not always be obeyed; for instance, it did not seem wise to abolish that popular term, *sternocleidomastoideus*. The fifth rule was ignored in making the *arteria meningeo-media* go through a *foramen spinosum* (instead of through a

foramen meningeum medium), and other examples might be given. But only when compromise appeared to be unavoidable did the Commission consent to depart from the principles mentioned.

There was much difference of opinion regarding the retention of personal names. Some desired to continue their use; others wished to abolish them altogether. Much can be said on each side. The arguments pro and con have been marshalled by His. On the one hand (1) historical injustice is frequently done, the name borne by a part being not that of its real discoverer but of some later worker; (2) the personal names employed may vary in different countries, Lieberkühn's glands in Germany being Galeati's in Italy, Vater's corpuscles in the one country being those of Pacini in the other; (3) in the literature of the specialties personal names are often used in great excess, names of no importance figuring in the bibliography; and (4) no systematic plan seems to have been followed in adopting personal names; thus, even from among the immortals, the names of Eustachius and Malpighi have in more than one instance been chosen for anatomical structures, while the names of Vesalius and Harvey do not appear at all. On the other hand it is argued that (1) the personal names are usually good mnemotechnic material, a student easily retaining the names of Poupart's, Gimbernat's and Colles's ligaments and having the impulse to find out what each signifies; whereas, his interest is much less for a ligamentum inguinale, a ligamentum lacunare, or a ligamentum inguinale reflexum; (2) a certain feeling of piety should restrain us from sacrificing, to a principle arbitrarily established, terms which for centuries have been found good and useful; and (3) it is to the student's advantage in his first session in the medical school to become familiar with the names of Falloppia, Eustachius, Malpighi, etc., for through them his historical sense may be awakened; and it is, perhaps, matter of secondary importance whether or not the names are always rightly used, this being a function of the history of anatomy rather than of anatomical terminology. The Commission compromised by giving each part an objective name and putting widely used personal names in brackets. Though this makes the terms less simple, it has the advantage of leaving to time the final decision. The personal names are all put in the genitive case, following the precedent set by the Zoölogical Commission on terminology. Thus Poupart's ligament becomes Lig. inguinale [Poupart]. In time it will be known whether it is to be called ultimately the inguinal ligament or by Poupart's name.

Another matter which the Commission had to decide concerned the anatomical terms used in the medical specialties,—*e. g.*, in neurology, ophthalmology, otology, and laryngology. In recent years clinicians have been reworking the anatomy of their special domains quite independently of the anatomical laboratories. An examination of the literature of the specialties reveals an anatomical terminology and description which varies markedly from the language and presentation of the ordinary anatomical text-books. The Commission soon convinced itself that the creation of this special language was due to the insufficiency of the anatomies of the schools; it was its duty, therefore, to accept the terms introduced by the specialists or to supply better ones. While the average medical student cannot, in his course in anatomy, be expected to master completely the anatomical terms of all the medical specialties, still, as far as his training goes in that direction, he has the right to demand that it shall be correct and modern. For completeness' sake, therefore, the Commission has included a full list of the names of macroscopic structures in the special organs, being led to do so by the repeated assurance of distinguished specialists that they were ready to accept the nomenclature of the anatomists as soon as it covered their needs.



It is surprising to find how few really new terms were coined by the Commission. Indeed, the first plan was so conservative that it expected to make no new terms at all but only to choose the most suitable terms then in use in the text-books. Fortunately this plan was not adhered to. The only terms available in the text-books for some structures were antiquated and unworthy of retention; but, worse and oftener, among the terms used in the text-books are some that are employed by one author in one sense and by another in another, owing, in certain cases at least, to obscure or inexact views. The Commission was therefore sometimes compelled to search the bibliography, to study dissections, and even to make original investigations in connection with a given term. For the sake of clarity and accuracy a certain number of new terms had to be introduced, and in the explanatory notes which accompanied the publication of the BNA Professor His has indicated the exact meaning of these new terms. Now that the new anatomical text-books and atlases are being written in the language of the BNA the student and physician will have no difficulty in understanding the few terms which otherwise might have seemed unfamiliar to him. The fact, however, remains that the list consists chiefly of carefully selected old names; it gives quite a wrong impression, therefore, to speak of the BNA as the "new terminology" or "new nomenclature."\*

### **The adoption of the BNA in America and in Great Britain.**

Having reviewed the history of the origin and construction of the BNA let us now turn for a moment to the matter of its adoption in this and in other English-speaking countries. It was thought by some, at first, that there would be great difficulties in the way.

(1) Thus, though granting the desirability of an anatomical terminology which shall be the same in all civilized countries, some think that the time is not yet ripe for it; the needs of the anatomists of different countries as regards anatomical terms are, they argue, not yet fully identical. When it is remembered, however, that the terms of the BNA deal only with well-established gross anatomical structures and do not relate to microscopic parts or to parts concerning which views are still unsettled, it is not difficult to conceive of international coöperation in the use of them for the sake of uniformity. The work of all anatomists, physiologists, biologists, pathologists and clinicians would be made much easier thereby. The speed of progress in these days has compelled every scientific medical man to read articles on his subject appearing in several languages; unless he does so he falls hopelessly behind his colleagues. Even medical students, in the schools with the higher requirements, are now asked to read one or two modern languages other than their own before admission. How obviously the reading of medical articles in the international bibliography would be facilitated if all writers would make it a point to use the same anatomical terms in texts and at the sides of illustrative plates and figures! Certainly the vast majority of the terms of the BNA would be understandable of all and agreeable to all. Even if a small residue of names might be found objectionable and remain unused in each country, it would matter but little, though most of us, surely, would be willing temporarily, for the sake of uniformity, to use a few terms not wholly to our liking.

(2) There are, it is said, a few anatomists in America and in England who are prejudiced against the BNA because it was prepared by the German Anatomical Society and is largely the result of the work of German anatomists.

\*Through an oversight in proof-reading, I have myself fallen into this error in my "Laboratory Manual."



Aside from the facts referred to above—that the Anatomical Society had almost as many non-German as German members and that the Commission on Terminology contained English, Belgian and Italian anatomists as well as German, Austrian and Swiss—it would not, it seems to me, have mattered much, or hindered its acceptance by us, if the BNA had been wholly German in origin. If anatomists of worthily world-wide fame like His, Toldt, Waldeyer, Krause, and their colleagues are willing and able to give a large part of their time and energies for six years to such a task, to secure the money to defray the expense thereof, and then to present it freely to the rest of us,—if what they have done is really excellent,—are we to be sulky and reject it simply because it was “made in Germany”? I cannot believe that any one who reflects for a moment can be other than extremely grateful for the very valuable gift these men have made us; such a Chauvinistic attitude as I have described can surely not be assumed by more than a minute minority. On the contrary, it is characteristic of the people of this country that they seek out and adopt as their own the “best” wherever it is to be found, even if it chance to be “made in Thibet” or in Timbuctoo.

(3) The fact that the list of terms is written entirely in the Latin language has been the ground of objection on the part of a few. But this, I feel sure, is due to a misunderstanding of the intention of the Commission. Its members had no idea that, in actual use, the Latin form would always be employed; it is matter of indifference whether one says “biceps muscle” or “musculus biceps,” “femoral nerve” or “nervus femoralis,” “temporal bone” or “os temporale,” “yellow spot” or “macula lutea.” As a matter of fact, a student learning an anatomical term for the first time will usually find that the Latin term goes as trippingly on the tongue, often more so, than its English equivalent. There are marked individual preferences, however, in this regard and I have known some teachers and students who would fly from a Latinized form as though from Satan. Certainly in this country fewer teachers than in Germany use the Latin consistently, though, as the feeling for precision and uniformity grows, it is possible that the custom may increase, in which event all the Latin names would actually become English words, as has already happened with *conjunctiva*, *retina*, *plexus*, *fornix*, *thalamus*, *ganglion*, *ependyma*, *cranium*, *abdomen*, *pelvis*, *perineum*, and of the like many more. The Commission at first had the idea of placing translations for the various languages in parallel columns with the Latin names, but wisely, I think, refrained therefrom, thus leaving everyone free to supply the equivalent in his own tongue as he will. In the German dissecting-rooms, even, the Latin forms are not strictly adhered to; one hears “Rückenmark” rather than “Medulla spinalis,” “Kopfnicker” (not “Brustschlüsselzitzenfortsatzmuskel”) rather than “M. sternocleidomastoideus.” It is in books, and more particularly in atlases, that it is especially desirable that the BNA be used in its Latin form. Where there is, too, any likelihood of international use of book or atlas, or of translation from one tongue into another, it would be helpful if this rule were followed.

(4) It has been objected, further, that since English and American textbooks have been written without regard to the BNA, students and teachers will only add the burden of a lot of additional names to their already overcrowded memories,—that we shall have a “confusion worse confounded” than before. It has been asserted, too, that students passing from anatomical laboratories in which the BNA is employed into the clinics which are manned by professors who learned their anatomy years ago will taken with them a tongue unintelligible to their instructors and will find in use there a form of anatomical language unknown to themselves.

There is a minimum of truth in these objections, but the difficulties to be encountered are far less real than would at first sight appear. For, in the first place, experience has taught that the use of the BNA along with the older text-books is not an impracticable task. The older books contain a majority of the BNA terms and a great many others besides, so that the use of the BNA resolves itself, in these circumstances, largely into an emphasizing of the names of choice and the omission of the unnecessary synonyms; the addition of the few new terms required meets with no difficulty if the instructors be well versed in them. Since Professor Mall called my attention to the BNA in 1895 and recommended it to me I have used it more or less consistently and with satisfaction ever since in my anatomical and clinical teaching in Baltimore and in Chicago. Other American teachers who have done the same tell me that they have found its employment easy and rewarding, and students, often unsolicited, express marked approval of the BNA terms where they differ from those formerly in use. The BNA is now used regularly in several of the American anatomical laboratories and, in large part though not exclusively, in others.

That the student's text-books and atlases should be written in the BNA is, nevertheless, obviously desirable. In 1899, in writing a book on the nervous system, I found it satisfactory to employ it (with minor exceptions), exclusively, for the domains which it covered. Soon after, in the dissecting-room teaching in Chicago, I was impressed with the idea that the student's task could be greatly simplified if a guide to dissection were written in terms of the BNA, each term being brought in at the moment the pupil meets with the structure named in his practical work. To meet this need, I prepared and had published, with the help of Drs. D. D. Lewis and D. G. Revell, in 1904, "A Laboratory Manual of Human Anatomy." Meanwhile, three excellent anatomical atlases,—those of Spalteholz, Sobotta and Toldt,—had appeared in Germany, each with the BNA terms printed at the sides of the figures. In order to make the task of students and teachers still lighter, and again encouraged by Professor Mall, I undertook during the years 1900–1904 the translation into English of the text of Professor Spalteholz's work, and since then its beautiful illustrations and brief, precise, anatomical descriptions have been available to American and English readers. The kind way in which these books have been received by American anatomists and clinicians makes it evident that there exists in this country a warm sympathy with the movement to render anatomical terminology more simple, less cumbersome, and more precise.

In 1902, Dr. Hardesty used the BNA exclusively in his useful "Neurological Technique," and in the small text of Dr. Whitehead (1900) and the monograph of Dr. Sabin (1901), both on the brain, it had also been adopted. Indications, indeed, now point to its general acceptance by American and British writers. Besides Spalteholz's Atlas that of Sobotta and that of Toldt are now available in English translation. The new edition of that popular text-book, Morris's Anatomy, edited by Mr. Henry Morris, of London, and Professor McMurich, of Ann Arbor, just now being published, is couched in the BNA terms. It would take too long to cite all the books and important articles in which these names figure. A monograph recently published by Dr. Potter, of St. Louis, entitled "Topographical Anatomy of the Viscera of the Thorax and Abdomen," should not, however, be omitted, as it is most valuable as a companion to any one studying, for the first time, a series of cross-sections through the trunk of a human being; the BNA names are used throughout in its plates and descriptions. That biologists find the BNA satisfactory is indicated by its use in Professor J. B. Johnston's book, "The Anatomy of the Nervous System of



Vertebrates." And, now that the newest edition of Gould's Medical Dictionary is also to consider the BNA, there would seem to be no longer reason for delay in general recognition and employment.

The assumption that students who have been taught the BNA and their clinical teachers will be reciprocally embarrassed in one another's presence—that a sort of anatomical Babel will prevail—gives scarcely due credit to either student or clinician. For, on the one hand, the student is sure during this transition period to become acquainted quickly with the old synonyms of the few new anatomical terms foreign to the ordinary clinical vocabulary; he can scarcely escape, for instance, learning that clinicians almost invariably speak of the "atria" of the heart as its "auricles," or of the "omental bursa" as the "lesser peritoneum." And, on the other hand, we may be certain that the modern scientific clinician, worthy of a clinical chair in a medical school, will not be unfamiliar with those more recent studies in the anatomy of his field which are of sufficient permanent importance to have been reflected in the BNA. The internist who has not brought his anatomy of the lungs, the heart, the liver, the spleen, the kidneys and the peritoneum at least up to the level of precision indicated by the BNA list, handicaps himself in his work. So with the surgeon with regard to the bones, the articulations, the blood-vessels and nerves, the neck, the abdomen and the pelvis. There need be little fear, we may feel tolerably sure, of delinquency here. Should the nobler motives prove ineffective—they will not—the fierceness of competition among clinicians, the rivalry for prestige among the occupants of clinical chairs, would from now on, if it has not always so done in the past, compel the teachers of the practical branches to keep pace with progress in the fundamentals. We have seen above, as a matter of fact, how clinicians in the medical specialties have not only kept pace with the anatomists but, in part, have outstripped them in the race. Investigating the anatomy of their own special domains anew and independently, their inquiries have expanded knowledge and necessitated an enrichment of anatomical vocabulary. This process has begun in America. That it will go on and become an engine of great power in furthering the development of our knowledge of the human form in regions yet obscure, who can doubt?

### **The Future of Anatomical Terminology.**

No matter how many revisions of terminology are made, and entirely independently of those who make them, we can be sure that, in the long run, only those names will survive which are wisely selected, which are precise in expression, and which are organically connected with whatever great general plan our anatomical nomenclature ultimately assumes. Anatomical terms, to live, must satisfy the needs of, and be adopted by, a majority of anatomists and clinicians. It would be folly to attempt to force the use of the BNA or any other list of anatomical terms upon any man or group of men. A terminology must rely upon its intrinsic merits, not upon the influence of authority. The better it satisfies the needs of teaching and investigation, the greater its chances of general acceptance and permanence. Those of us who are convinced of the value of the BNA should set an example by using it and may recommend its use to others. More than this we ought not to do.

The fact should be emphasized that the BNA makes no attempt to limit the language of research, but only to supply a list of simple terms, free from ambiguity, for common use in the medical schools. Research must, of course, retain absolute freedom of expression. Investigators, to make themselves understood, are compelled to use temporarily many expressions consciously

wholly provisional in character. Only when time has brought a certain repose to scientific activity in a given region do more permanent terms crystallize out.

It should be easy in a country like America, for anatomists to agree with their colleagues in the rest of the world upon the adoption of a common set of terms for school use. It is fair to assume that the tendency to coöperation, so characteristic of the energies of this country, notably manifest in industrial combinations no less than in the team-work of athletes, will not be found lacking among anatomists.

Even when compromises have to be made, there is a certain special honor and satisfaction to be derived from the sacrifices involved when they contribute to the common weal. That some concessions must necessarily be made in using the BNA cannot be denied; almost every coöperative measure demands some self-denial among participants. This need not, however, be great. Where the list does not supply in full the requirements of the individual teacher, there is no reason why he should not extend it at will. On the other hand, where the list contains terms in excess of the needs of a given instructor or school, it is an easy matter to omit those which seem superfluous. It may seem a little hard for one who has spoken of the "M. complexus" all his life to get used to calling it the "M. semispinalis capitis," or for another who has been brought up with an "anterior crural" to abandon it for the "femoral" nerve. But when the good reasons for the change are known and appreciated, good-will will carry one far. It is only when a term is found to be incompatible with one's scientific convictions that reasonable difficulty arises. The BNA has, however, been constructed with such great care and has so sedulously avoided affixing labels to structures still in dispute that we need have little fear on that score. Even should there be a few terms, or even a few hundred, which we find hard at this time to digest, the general acceptance of the other 4000 will be a great gain, cutting the labors of students, as it will, in two.

That conditions will arise, perhaps soon, when another revision will be desirable and demanded there can be no doubt. Investigation is ever extending; our criteria of values are constantly changing; scientific needs in terminology vary, in spite of us, with the years; at intervals revision becomes unavoidable. But with foundations so well laid as in the BNA, a subsequent review should be facilitated. The development of the BNA has taught us the necessity of observing certain rules in the coining of new anatomical terms. If these rules be good ones, the work of extension will be easy. It would not be difficult, for instance, to merge the names of this list into a nomenclature which considers, more satisfactorily than the BNA does, the needs to which a fusion of Human Anatomy with Comparative Anatomy gives rise. And I, for one, hope that such a "merger" may be promoted in our time. I trust too that, at another revision, the terms in Professor Wilder's lists which differ from those of the BNA may be carefully considered, and that his terms, where they are better than those of the present BNA, may be adopted.

Of one thing I am convinced,—coöperation is, from now on, essential for the welfare of a satisfactory anatomical language. Simplicity, accuracy, and serial connection will be favored if anatomists agree to use terms, in common, for the structures studied in the schools. The teacher's work will be simplified and the pupil's task will be lightened; instruction will be unhampered, research will flourish and anatomical science will gain in dignity and in precision.



# Nomina anatomica<sup>1</sup>

## Termini, situm et directionem partium corporis indicantes

### Termini generales

Verticalis	Anterior	Longitudinalis
Horizontalis	Medius	Transversus
Medianus	Posterior	Cranialis
Sagittalis	Ventralis	<i>Rostralis</i>
Frontalis	Dorsalis	Caudalis
Transversalis	Internus	Superior
Medialis	Externus	Inferior
Intermedius	Dexter	Superficialis [sublimis]
Lateralis	Sinister	Profundus

? *Transversalis*

### Termini ad extremitates spectantes

Proximalis	Ulnaris
Distalis	Tibialis
Radialis	Fibularis

? *Volaris*

<sup>1</sup> In the lists the following explanations are necessary:

1. Oval brackets ( ) indicate variations (Varietates anatomicæ).
2. Angular brackets [ ] contain explanatory additions, among which are included double names and personal names.
3. Italics are used for ontogenetic expressions (e.g., *M. decidua*, *A. umbilicalis*, etc.)

## Anatomical names<sup>1</sup>

### Terms indicating the position and direction of parts of the body

#### General terms

Vertical	Anterior	Longitudinal
Horizontal	Middle	Transverse
Median	Posterior	Cranial
Sagittal	Ventral	<i>Rostral</i>
Frontal	Dorsal	Caudal
Transversal	Inner	Superior
Medial	Outer	Inferior
Intermediate	Right	Superficial
Lateral	Left	Deep

#### Terms relating to the extremities

Proximal	Ulnar
Distal	Tibial
Radial	Fibular

---

<sup>1</sup> The letters O. T. following a name indicate that it belongs to the older terminology.



## Termini generales

Accessorius	Corona	Glandula
Acinus	Corpus	Glomerulus
Aditus	Corpusculum	Glomus
Ala	Crista	Hilus
	Crus	Humor
Alveolus	Decussatio	Junctura
Ampulla	Dorsum	Impressio
Angulus	Ductulus	Incisura
Ansa	Ductus	Infundibulum
Antrum	Eminentia	Intestinum
Apertura	Endothelium	Isthmus
Apex	Epithelium	Labium
Appendix	Extremitas	Lacuna
Arcus	Facies	Lamina
Area	Fascia	Latus
Basis	Fasciculus	Ligamentum
Brachium	Fibra	Limbus
Canaliculus	Fibrocartilago	Limen
Canalis	Filum	Linea
Capsula	Fissura	Liquor
Caput	Flexura	Lobulus
Capitulum	Folium	Lobus
Cartilago	Folliculus	Macula
Caruncula	Foramen	Margo
Cauda	Formatio	Massa
Caverna	Fornix	Meatus
Cavum	Fossa	Medulla
Cellula	Fossula	Membrana
Circulus	Fovea	Membrum
Cisterna	Foveola	Mucus
Collum	Frenulum	Musculus
Columna	Fundus	Nervus
Commissura	Funiculus	Nodulus
	Geniculum	Nucleus
Cornu	Genu	Organon



## General Anatomical Terms

Accessory	Wreath, garland, or crown	Gland
Berry	Body	Little skein
Entrance	Little body or corpuscle	Skein
Wing (contraction of axilla)	Crest	Hilus
Little hollow	Leg or limb	Liquid or fluid
Flask	Decussation or crossing	Joint
Angle	Back	Impression
Handle or loop	Little duct	Incision or notch
Cave	Duct	Funnel
Opening	Eminence or protuberance	Intestine or inward
Tip	Endothelium	Isthmus
Appendage	Epithelium	Lip
Arch	Extremity	Gap, defect
Space	Face or surface	Plate or layer
Base	Bandage or band	Broad; flank
Arm	A little bundle or packet	Ligament
Small channel	Fibre or filament	Border or fringe
Canal	Fibrocartilage	Threshold, boundary
Capsule	Thread	Line
Head	Fissure or cleft	Fluid or liquid
Little head	Bending	A little lobe
Cartilage	Leaf	Lobe
Small piece of flesh	Little sac or bag	Spot
Tail	Hole, aperture, or opening	Margin
Cavern	Formation	Mass
Hole or cavity	Arch or vault	Way or passage
Little chamber or cell	Ditch or trench	Marrow
Circle	Little fossa	Membrane
Cistern	Pit	Limb or member
Neck	Little pit	Mucus
Column or pillar	Cord or rein	Muscle
Connection or commissure	Bottom	Nerve
Horn	Thin rope, cord, or string	Nodule
	Little knee or knot	Nucleus or kernel
	Knee	Organ

Orificium	Septum	Tunica
Os [oris]	Sinus	Tunica propria
Os [ossis]	Spatium	Umbo
Ostium	Spina	Uvula
Papilla	Stratum	
Parenchyma	Stria	Vagina
Paries	Stroma	Vallecula
Perichondrium	Substantia	Vallum
Periosteum	Succus	Valvula
Plexus	Sulcus	Vas
Plica	Taenia	Velum
Polus	Tegmen	
Processus	Tela	Vertex
Prominentia	Tela conjunctiva	Vesica
Punctum	Tela elastica	Vesicula
Radix	Torus	
Ramulus		Vestibulum
Ramus	Trabecula	
Raphe	Tractus	Villus
Recessus	Trigonum	Viscus [viscera]
Regio	Trochlea	
Rete	Truncus	Vortex
Rima	Tuber	Zona
Rudimentum	Tuberculum	
Septulum	Tubulus	

*pars*  
*Planum*

Orifice	Partition	Coat or covering
Mouth	Sinus	Proper coat
Bone	Space	Boss or prominence
Entrance	Spine or thorn	Little cluster or bunch
Papilla or nipple	Layer or covering	Sheath
Parenchyma	Furrow, stripe, or ridge	Crevice
Wall	Stroma, or bed	Wall or fortification
Perichondrium	Substance	Valve
Periosteum	Juice	Vessel
Plexus	Sulcus or furrow	Sail, covering or curtain
Fold	Ribbon; tape-worm	Crown of head
Pole	A cover	Bladder
Process	Web	Vesicle or little bladder
Prominence or projection	Connecting web	Vestibule or ante-chamber
Point or small puncture	Elastic web	Shaggy hair
Root	Round swelling or protuberance	Organ, internal organ
Little branch or twig	Little beam	Whirlpool
Branch	Tract	Girdle or zone
Raphe or seam	Trigone or triangle	
Recess	Pulley	
Region or territory	Trunk	
Net or network	Swelling or hump	
Slit or fissure	Tubercle	
Rudiment	Tubule or little tube	
Little septum		

## Partes corporis humani

Caput

Collum

Truncus

Extremitates

### Caput

#### Cranium

Vertex

Sinciput

Frons

Occiput

Tempora

Auris

Auricula

### Facies

#### Oculus

Palpebra superior

Palpebra inferior

Rima palpebrarum

Bulbus oculi

Supercilium

Sulcus infrapalpebralis

#### Os

Sulcus nasolabialis

Philtrum

Labium superius

Labium inferius

Rima oris

Cavum oris

Lingua

Fauces

Bucca [Mala]

Sulcus mentolabialis

Mentum

#### Nasus

Dorsum nasi

Apex nasi

Ala nasi

### Collum

Cervix

Larynx

Prominentia laryngea

Pharynx

Trachea

Oesophagus

### Truncus

#### Thorax

Cavum thoracis

Pectus

Mamma

Papilla mammae

#### Dorsum

Columna vertebralis

Canalis spinalis

## Parts of the human body

Head  
Neck

Trunk  
Extremities

### Head Skull

Crown of the head  
Sinciput; bregma  
Forehead  
Occiput

Temples  
Ear  
External ear, or pinna

### Face

#### Eye

Upper eyelid  
Lower eyelid  
Lid-slit  
Eyeball  
Eyebrow  
Infrapalpebral furrow

#### Nose

Back of the nose  
Tip of the nose  
Wing of the nose

#### Mouth

Nasolabial furrow  
Infranasal depression  
Upper lip  
Lower lip  
Mouth slit  
Mouth cavity  
Tongue  
Throat  
Cheek  
Mentolabial furrow  
Chin

### Neck

Neck (posterior part)  
Larynx  
Laryngeal prominence (O.  
T. Adam's apple)

Pharynx  
Trachea  
Oesophagus

### Trunk

#### Thorax

Thoracic cavity  
Breast  
Mammary gland  
Mammary nipple

#### Back

Vertebral column  
Spinal canal



**Abdomen**

Cavum abdominis	Latus
Scrobiculus cordis	Lumbus
Umbilicus	Inguen

**Pelvis**

Cavum pelvis	Anus
Mons pubis	Crena ani
Coxa	Perineum
Nates [Clunes]	

**Extremitas superior**

Axilla	Manus
Plica axillaris anterior	Carpus
Plica axillaris posterior	Metacarpus
Acromion	Dorsum manus
Brachium	Vola manus [Palma]
Facies anterior	Thenar
Facies posterior	Hypothenar
Facies lateralis	Digiti manus
Facies medialis	Pollex [Digitus I]
Sulcus bicipitalis lateralis	Index [ " II]
Sulcus bicipitalis medialis	Digitus medius [Digitus III]
Cubitus	Digitus annularis [ " IV]
Antibrachium	Digitus minimus [ " V]
Facies dorsalis	Facies dorsales
Facies volaris	Facies volares
Margo radialis	Margines radiales
Margo ulnaris	Margines ulnares

**Extremitas inferior**

Femur	Crus
Facies anterior	Facies anterior
Facies posterior	Facies posterior
Facies lateralis	Sura
Facies medialis	Malleolus lateralis
Sulcus gluteus	Malleolus medialis
Genu	Pes
Poples	Tarsus
Patella	Metatarsus

**Belly**

Abdominal cavity	Flank
“Heart fossa”; pit of stomach	Loin
Navel	Groin

**Pelvis**

Pelvic cavity	Anus
Pubic eminence	Anal cleft
Hip	Perineum
Buttock	

**Upper extremity**

Axilla; prominence of shoulder	Hand
Anterior axillary fold	Wrist
Posterior axillary fold	Metacarpus
Acromion; tip of shoulder	Back of the hand
Arm	Palm of the hand
Anterior surface	Thenar or radial palm
Posterior surface	Hypothenar or ulnar palm
Lateral surface	Fingers
Medial surface	Thumb
Lateral bicipital groove	Index finger
Medial bicipital groove	Middle finger
Elbow	Ring finger
Forearm	Little finger
Dorsal surface	Dorsal surfaces
Volar surface	Volar surfaces
Radial margin	Radial margins
Ulnar margin	Ulnar margins

**Lower extremities**

Thigh	Leg
Anterior surface	Anterior surface
Posterior surface	Posterior surface
Lateral surface	Calf
Medial surface	Lateral malleolus
Gluteal furrow	Medial malleolus
Knee	Foot
Posterior surface of knee	Root of foot
Knee-cap	Metatarsus

Dorsum pedis  
 Planta  
 Margo pedis lateralis  
 Margo pedis medialis  
 Calx  
 Digiti pedis  
 Hallux [Digitus I]

Digiti II–IV  
 Digitus minimus [Digitus V]  
 Facies dorsales  
 Facies plantares  
 Margines laterales  
 Margines mediales

## Osteologia

Os longum  
 Os breve  
 Os planum  
 Os pneumaticum  
 Epiphysis  
 Diaphysis

*Synchondrosis epiphyseos*  
 Apophysis  
 Facies articularis  
 Substantia compacta  
 Substantia corticalis  
 Substantia spongiosa

Cavum medullare  
 Medulla ossium  
 Medulla ossium flava  
 Medulla ossium rubra  
 Foramen nutricium  
 Canalis nutricius

### Columna vertebralis

Vertebrae cervicales  
 Vertebrae thoracales  
 Vertebrae lumbales  
 Vertebrae sacrales  
 Vertebrae coccygeae  
 Corpus vertebrae  
 Fovea costalis superior  
 Fovea costalis inferior  
 Canalis vertebralis  
 Foramen vertebrale  
 Arcus vertebrae  
 Radix arcus vertebrae  
 Incisura vertebralis superior  
 Incisura vertebralis inferior  
 Foramen intervertebrale  
 Sulcus n. spinalis  
 Processus spinosus  
 Vertebra prominens  
 Processus transversus  
 Fovea costalis transversalis

Tuberculum anterius [vertebrarum cervicalium]  
 Tuberculum caroticum [vertebrae cervicalis VI]  
 Foramen transversarium  
 Tuberculum posterius [vertebrarum cervicalium]  
 Processus articulares superiores  
 Facies articulares superiores  
 Processus articulares inferiores  
 Facies articulares inferiores  
 Processus costarius  
 Processus accessorius [vertebrarum lumbalium]  
 Processus mammillaris

### Atlas

Massa lateralis  
 Arcus anterior  
 Tuberculum anterius  
 Foveae articulares superiores  
 Facies articulares inferiores  
 Fovea dentis

Back of the foot	II-IV toes
Sole	Little toe
Lateral margin of the foot	Dorsal surfaces
Medial margin of the foot	Plantar surfaces
Heel	Lateral margins
Toes	Medial margins
Great toe	

## Osteology

Long bone	<i>Epiphyseal synchondrosis</i>	Medullary cavity
Short bone	Apophysis ("excrescence")	Bone marrow
Flat bone	Articular surface	Yellow bone marrow
Hollow bone	Compact substance	Red bone marrow
Epiphysis ("accretion")	Cortical substance	Nutrient foramen
Shaft	Spongy substance	Nutrient canal

### Vertebral column or spine

Cervical vertebrae	Anterior tubercle [of cervical vertebrae]
Thoracic vertebrae	Carotid tubercle [of sixth cervical vertebra]
Lumbar vertebrae	Foramen of transverse process
Sacral vertebrae	Posterior tubercle [of cervical vertebrae]
Coccygeal vertebrae	Superior articular processes
Body of vertebrae	Superior articular surfaces
Superior costal pit (O. T. demifacet for head of rib)	Inferior articular processes
Inferior costal pit (O. T. demifacet for head of rib)	Inferior articular surfaces
Vertebral canal	Costal process
Vertebral foramen	Accessory process of lumbar vertebrae
Vertebral arch	Mammillary process
Root of vertebral arch (O. T. pedicle)	
Superior vertebral notch	
Inferior vertebral notch	
Intervertebral foramen	
Groove for spinal nerve	
Spinous process	
Prominent vertebra (seventh cervical)	
Transverse process	
Costal pit of transverse process (O. T. facet for tubercle of rib)	

### Atlas

Lateral mass
Anterior arch
Anterior tubercle
Superior articular pits
Inferior articular surfaces
Pit of the tooth

Arcus posterior  
 Sulcus arteriae vertebralis  
 Tuberculum posterius

### Epistropheus

Dens  
 Facies articularis anterior  
 Facies articularis posterior

### Os sacrum

Facies dorsalis  
 Facies pelvina  
 Basis oss. sacri  
 Processus articularis superior  
 Promontorium

Pars lateralis  
 Facies auricularis  
 Tuberositas sacralis  
 Foramina intervertebralia  
 Foramina sacralia anteriora  
 Lineae transversae  
 Foramina sacralia posteriora  
 Crista sacralis media  
 Cristae sacrales laterales  
 Cristae sacrales articulares  
 Cornua sacralia  
 Canalis sacralis  
 Hiatus sacralis  
 Apex oss. sacri

### Os coccygis

Cornua coccygea

### Thorax

#### Costae

Costae verae  
 Costae spuriae  
 Os costale  
 Cartilago costalis  
 Capitulum costae  
 Facies articularis capituli costae  
 Crista capituli

Corpus costae  
 Tuberculum costae  
 Facies articularis tuberculi costae

Collum costae  
 Crista colli costae  
 Angulus costae  
 Tuberculum scaleni [Lisfranci]  
 Sulcus subclaviae  
 Tuberositas costae II  
 Sulcus costae

### 1 Sternum

$\alpha$  Manubrium sterni  
 $\delta$  Angulus sterni [Ludovici]  
 Synchondrosis sternalis

$\gamma$  Corpus sterni  
 Planum sternale  
 $\beta$  Processus xiphoideus

Incisura clavicularis  
 Incisura jugularis

Incisurae costales  
 (Ossa suprasternalia)

### Th o r a x

Cavum thoracis  
 Apertura thoracis superior  
 Apertura thoracis inferior  
 Arcus costarum  
 Spatia intercostalia  
 Angulus infrasternalis  
 Sulcus pulmonalis

### Ossa cranii

#### Os basilare

#### Os occipitale

Foramen occipitale magnum  
 Pars basilaris  
 Sulcus petrosus inferior  
 Pars lateralis



Posterior arch  
Groove for vertebral artery  
Posterior tubercle

**Epistropheus ("a turning") (O. T. axis)**

Tooth  
Anterior articular surface  
Posterior articular surface

**Sacrum**

Dorsal surface  
Pelvic surface  
Base of sacrum  
Superior articular process  
Promontory (O. T. sacrovertebral angle)  
Lateral part  
Auricular surface  
Sacral tuberosity  
Intervertebral foramina  
Anterior sacral foramina  
Transverse lines  
Posterior sacral foramina  
Middle sacral crest  
Lateral sacral crests  
Articular sacral crests  
Sacral horns  
Sacral canal  
Sacral hiatus  
Apex of sacrum

**Coccyx**

Coccygeal horns

**Thorax**

**Ribs**

True ribs  
False ribs  
Rib bone  
Rib cartilage  
Head of the rib  
Articular surface of the head of the rib  
Crest of the head

Body of the rib  
Tubercle of the rib  
Articular surface of the tubercle of the rib  
Neck of the rib  
Crest of neck of rib  
Angle of rib  
Scalene tubercle of Lisfranc  
Subclavian groove  
Tuberosity of the second rib  
Costal groove

**Breast Bone**

Handle of sternum  
Angle of sternum  
Sternal synchondrosis  
Body of sternum (O. T. gladiolus)  
Sternal plain, or anterior surface  
Xiphoid process (O. T. ensiform process)  
Clavicular notch  
Jugular notch (O. T. presternal notch)  
Notches for the ribs  
Suprasternal bones

**T h o r a x**

Thoracic cavity  
Upper thoracic opening  
Lower thoracic opening  
Arch of the ribs  
Intercostal spaces  
Infrasternal angle  
Pulmonary sulcus

**Bones of the skull**

**Basilar bone**

**Occipital bone**

Large occipital foramen  
Basilar part  
Inferior petrosal groove  
Lateral part

Squama occipitalis  
 Margo mastoideus  
 Margo lambdoideus  
 (Os interparietale)  
 Clivus  
 Tuberculum pharyngeum  
 Condylus occipitalis  
 Canalis condyloideus

Canalis hypoglossi

Tuberculum jugulare  
 Incisura jugularis  
 Processus jugularis  
 Fossa condyloidea  
 Processus intrajugularis  
 Planum occipitale  
 Planum nuchale  
 Protuberantia occipitalis externa  
 (Torus occipitalis)  
 Crista occipitalis externa  
 Linea nuchae suprema  
 Linea nuchae superior  
 Linea nuchae inferior  
 Eminentia cruciata  
 Protuberantia occipitalis interna  
 Sulcus sagittalis

Sulcus transversus  
 (Processus paramastoideus)

### Os sphenoidale

Corpus  
 Sella turcica  
 Fossa hypophyseos

Dorsum sellae  
 Tuberculum sellae  
 Processus clinoides medius  
 Processus clinoides posterior  
 Sulcus caroticus

Lingula sphenoidalis

Crista sphenoidalis

Rostrum sphenoidale  
 Sinus sphenoidalis  
 Septum sinuum sphenoidalium  
 Apertura sinus sphenoidalis  
 Conchae sphenoidales

Clivus

Ala parva  
 Sulcus chiasmatis

Foramen opticum  
 Processus clinoides anterior  
 Fissura orbitalis superior

Ala magna  
 Facies cerebri  
 Facies temporalis  
 Facies sphenomaxillaris  
 Facies orbitalis  
 Margo zygomaticus  
 Margo frontalis  
 Angulus parietalis  
 Margo squamosus  
 Crista infratemporalis

Foramen rotundum  
 Foramen ovale  
 Foramen spinosum  
 Spina angularis

Processus pterygoideus  
 Lamina lateralis processus pterygoidei  
 Lamina medialis processus pterygoidei  
 Fissura pterygoidea  
 Fossa scaphoidea  
 Processus vaginalis  
 Hamulus pterygoideus

Sulcus hamuli pterygoidei  
 Fossa pterygoidea  
 Canalis pterygoideus [Vidii]

Occipital squama ("scale")	Sphenoidal crest (O. T. ethmoidal crest)
Mastoid margin	Sphenoidal rostrum
Lambdoid margin	Sphenoidal sinus
Interparietal bone	Septum of sphenoidal sinuses
Clivus ("slope")	Opening of sphenoidal sinus
Pharyngeal tubercle	Sphenoidal conchae ("shell") (O. T. sphenoidal turbinated bones)
Occipital condyle	Clivus ("slope")
Condylod canal (O. T. posterior condylod foramen)	Small wing
Hypoglossal canal (O. T. anterior condylod foramen)	Sulcus of the chiasma (O. T. optic groove)
Jugular tubercle	Optic foramen
Jugular notch	Anterior clinoid process
Jugular process	Superior orbital fissure
Condylod fossa	Large wing
Intrajugular process	Cerebral surface
Occipital plain	Temporal surface
Nuchal plain	Sphenomaxillary surface
External occipital protuberance	Orbital surface
Occipital torus ("swelling")	Zygomatic margin
External occipital crest	Frontal margin
Supreme nuchal line	Parietal angle
Superior nuchal line	Squamosal margin
Inferior nuchal line	Infratemporal crest (O. T. pterygoid ridge)
Cruciate eminence	Round foramen
Internal occipital protuberance	Oval foramen
Sagittal sulcus (O. T. superior longitudinal sulcus)	Spinous foramen
Transverse sulcus	Angular spine (O. T. spinous process)
Paramastoid process	
<b>Sphenoid bone</b>	
Body	Pterygoid process
Turkish saddle	Lateral layer of pterygoid process
Hypophyseal fossa (O. T. pituitary fossa)	Medial layer of pterygoid process
Back of sella	Pterygoid fissure
Tubercle of sella or pommel	Scaphoid fossa
Middle clinoid process	Vaginal process
Posterior clinoid process	Pterygoid hamulus ("hook") (O. T. hamular process)
Carotid sulcus (O. T. cavernous groove)	Sulcus of pterygoid hamulus
Sphenoidal tongue	Pterygoid fossa
	Pterygoid canal (O. T. Vidian canal)

Canalis pharyngeus	Apertura externa aquaeductus vestibuli
Canalis basipharyngeus	Sulcus petrosus inferior
Sulcus tubae auditivae	Incisura jugularis
Sulcus pterygopalatinus	Processus intrajugularis
(Processus pterygospinosus [Civinini])	Fossa jugularis
	Canaliculus mastoideus
<b>Os temporale</b>	Sulcus canaliculi mastoidei
<b>Pars mastoidea</b>	Processus styloideus
Margo occipitalis	Vagina processus styloidei
Processus mastoideus	
Incisura mastoidea	Foramen stylomastoideum
Sulcus sigmoideus	Fossula petrosa
	Canaliculus tympanicus
Sulcus a. occipitalis	Sulcus tympanicus
Foramen mastoideum	Apertura inferior canaliculi tympanici
<b>Pars petrosa [Pyramis]</b>	
Facies anterior pyramidis	Apertura superior canaliculi tympanici
Facies posterior pyramidis	
Facies inferior pyramidis	
Apex pyramidis	Canaliculus cochleae
Angulus superior pyramidis	Apertura externa canaliculi cochleae
Angulus anterior pyramidis	
Angulus posterior pyramidis	Canalis caroticus
Sulcus petrosus superior	Canaliculi caroticotympanici
Tegmen tympani	Canalis musculotubarius
Eminentia arcuata	Semicanalis m. tensoris tympani
Canalis facialis [Falloppii]	Semicanalis tubae auditivae
Hiatus canalis facialis	Septum canalis musculotubarii
	Cavum tympani (v. Organon auditus)
Geniculum canalis facialis	
Sulcus n. petrosi superficialis majoris	Canaliculus chordae tympani
	Fissura petrotympanica [Glaseri]
Sulcus n. petrosi superficialis minoris	
	Fissura petrosquamosa
Impressio trigemini	<b>Pars tympanica</b>
	<i>Annulus tympanicus</i>
Porus acusticus internus	Meatus acusticus externus
Meatus acusticus internus	(Spina supra meatum)
Fossa subarcuata	Fissura tympanomastoidea
Aquaeductus vestibuli	

Pharyngeal canal (O. T. pterygo-palatine canal)	External opening of aqueduct of vestibule
Basipharyngeal canal	Inferior petrosal groove
Sulcus of auditory tube	Jugular notch
Pterygopalatine sulcus	Intrajugular process
Pterygospinous process	Jugular fossa
	Mastoid canaliculus
	Sulcus of mastoid canaliculus
	Styloid process
	Sheath of styloid process (O. T. vaginal process)
	Stylomastoid foramen
	Petrosal fossula
	Tympanic canaliculus
	Tympanic sulcus
	Inferior opening of tympanic canaliculus
	Superior opening of tympanic canaliculus (O. T. opening for smaller petrosal nerve)
	Canaliculus of the cochlea
	External opening of the canaliculus of the cochlea
	Carotid canal
	Caroticotympanic canaliculus
	Musculotubal canal
	Semicanal of the tensor muscle of tympanum (O. T. canal for tensor tympani muscle)
	Semicanal of auditory tube (O. T. canal for the Eustachian tube)
	Septum of the musculotubal canal
	Cavity of the tympanum (see <i>Organ of Hearing</i> )
	Canaliculus of cord of tympanum
	Petrotympanic fissure (O. T. Glaserian fissure)
	Petrosquamosal fissure
	Tympanic part
	<i>Tympanic ring</i>
	External acoustic meatus
	Spine above meatus
	Tympanomastoid fissure
<b>Temporal bone</b>	
Mastoid part	
Occipital margin	
Mastoid process	
Mastoid notch (O. T. digastric fossa)	
Sigmoid sulcus (O. T. fossa sigmoidea)	
Groove for the occipital artery	
Mastoid foramen	
Petrous part (pyramid)	
Anterior surface of pyramid	
Posterior surface of pyramid	
Inferior surface of pyramid	
Apex of pyramid	
Superior angle of pyramid	
Anterior angle of pyramid	
Posterior angle of pyramid	
Superior petrosal groove	
Roof of tympanum	
Arcuate eminence (O. T. eminence for superior semicircular canal)	
Facial canal (O. T. aqueduct of Fallopius)	
Hiatus of facial canal (O. T. hiatus Fallopii)	
Little knee of facial canal	
Groove for the greater superficial petrosal nerve	
Groove for the lesser superficial petrosal nerve	
Trigeminal impression (O. T. depression for Gasserian ganglion)	
Internal acoustic pore	
Internal acoustic meatus	
Subarcuate fossa	
Aqueduct of vestibule	



Spina tympanica major  
 Spina tympanica minor  
 Porus acusticus externus  
 Squama temporalis  
 Margo parietalis  
 Incisura parietalis  
 Margo sphenoidalis  
 Facies temporalis  
 Processus zygomaticus  
 Fossa mandibularis

Facies articularis  
 Tuberculum articulare  
 Facies cerebralis  
 Sulcus a. temporalis mediae

#### **Os parietale**

Facies cerebralis  
 Facies parietalis  
 Margo occipitalis  
 Margo squamosus  
 Margo frontalis  
 Margo sagittalis  
 Angulus frontalis  
 Angulus occipitalis  
 Angulus sphenoidalis  
 Angulus mastoideus  
 Foramen parietale  
 Tuber parietale

Linea temporalis inferior

Linea temporalis superior  
 Sulcus sagittalis  
 Sulcus transversus

#### **Os frontale**

Squama frontalis  
 Facies frontalis  
 Margo supraorbitalis  
 Pars orbitalis  
 Incisura ethmoidalis

Pars nasalis  
 Spina frontalis  
 Margo nasalis  
 Margo parietalis  
 Processus zygomaticus  
 Facies temporalis  
 Linea temporalis  
 Tuber frontale

Arcus superciliaris

Glabella  
 Foramen sive Incisura supraorbitalis  
 Incisura sive Foramen frontale  
 Facies orbitalis  
 (Spina trochlearis)  
 Fovea trochlearis  
 Foramen ethmoidale anterius  
 Foramen ethmoidale posterius  
 Fossa glandulae lacrimalis  
 Facies cerebralis

Crista frontalis  
 Sulcus sagittalis  
 Foramen caecum  
 Sinus frontalis  
 Septum sinuum frontalem

#### **Os ethmoidale**

Lamina cribrosa  
 Crista galli  
 Processus alaris  
 Lamina perpendicularis  
 Labyrinthus ethmoidalis

Cellulae ethmoidales  
 Infundibulum ethmoidale  
 Hiatus semilunaris  
 Bulla ethmoidalis  
 Lamina papyracea

Foramina ethmoidalia  
 (Concha nasalis suprema)

Larger tympanic spine  
 Smaller tympanic spine  
 External acoustic pore  
 Temporal squama ("scale")  
 Parietal margin  
 Parietal notch  
 Sphenoidal margin  
 Temporal surface  
 Zygomatic process  
 Mandibular fossa (O. T. glenoid cavity)  
 Articular surface  
 Articular tubercle  
 Cerebral surface  
 Groove for middle temporal artery

**Parietal bone**

Cerebral surface  
 Parietal surface  
 Occipital margin  
 Squamosal margin  
 Frontal margin  
 Sagittal margin  
 Frontal angle  
 Occipital angle  
 Sphenoidal angle  
 Mastoid angle  
 Parietal foramen  
 Parietal tuber (O. T. parietal eminence)  
 Inferior temporal line (O. T. temporal ridge)  
 Superior temporal line  
 Sagittal sulcus  
 Transverse sulcus (O. T. groove for lateral sinus)

**Frontal bone**

Frontal squama ("scale")  
 Frontal surface  
 Supraorbital margin  
 Orbital part  
 Ethmoidal notch

Nasal part  
 Frontal spine (O. T. nasal spine)  
 Nasal margin  
 Parietal margin  
 Zygomatic process  
 Temporal surface  
 Temporal line  
 Frontal tuber (O. T. frontal eminence)  
 Superciliary arch (O. T. superciliary ridge)  
 Glabella ("smooth")  
 Supraorbital foramen or notch  
 Frontal notch or foramen  
 Orbital surface  
 Trochlear spine  
 Trochlear pit  
 Anterior ethmoidal foramen  
 Posterior ethmoidal foramen  
 Fossa of lacrimal gland  
 Cerebral surface (O. T. internal surface)  
 Frontal crest  
 Sagittal sulcus  
 Blind foramen  
 Frontal sinus  
 Septum of frontal sinuses

**Ethmoid bone**

Cribriform plate  
 Cock's comb  
 Alar process  
 Perpendicular plate  
 Ethmoidal labyrinth (O. T. lateral mass of ethmoid)  
 Ethmoidal cells  
 Ethmoidal funnel  
 Semilunar hiatus  
 Ethmoidal bulla ("bubble")  
 Papyrus or paper plate (O. T. os planum)  
 Ethmoidal foramina  
 Supreme turbinated bone

Concha nasalis superior  
 Concha nasalis media  
 Processus uncinatus

### Concha nasalis inferior

Processus lacrimalis  
 Processus maxillaris  
 Processus ethmoidalis

### Os lacrimale

Crista lacrimalis posterior

Sulcus lacrimalis  
 Hamulus lacrimalis

Fossa sacci lacrimalis

### Os nasale

Foramina nasalia  
 Sulcus ethmoidalis

### Vomer

Ala vomeris

### Ossa faciei

#### Maxilla

Corpus maxillae  
 Facies anterior

Facies nasalis  
 Facies orbitalis  
 Facies infratemporalis

Sinus maxillaris

Margo infraorbitalis  
 Canalis infraorbitalis  
 Sulcus infraorbitalis  
 Foramen infraorbitale  
 Sutura infraorbitalis  
 Fossa canina

(Fossa praenasalis)  
 Incisura nasalis  
 Tuber maxillare  
 Foramina alveolaria  
 Canales alveolares

Planum orbitale  
 Margo lacrimalis  
 Sulcus lacrimalis  
 Canalis nasolacrimalis

Crista conchalis  
 Processus frontalis  
 Crista lacrimalis anterior  
 Incisura lacrimalis  
 Crista ethmoidalis  
 Processus zygomaticus

Processus palatinus  
 Crista nasalis  
 Spina nasalis anterior  
*Os incisivum*  
 Canalis incisivus  
 Sutura incisiva  
 Spinae palatinae  
 Sulci palatini  
 Processus alveolaris  
 Limbus alveolaris  
 Alveoli dentales  
 Septa interalveolaria  
 Juga alveolaria  
 Hiatus maxillaris  
 Foramen incisivum

### Os palatinum

Pars perpendicularis

Facies nasalis  
 Facies maxillaris  
 Incisura sphenopalatinus  
 Sulcus pterygopalatinus  
 Processus pyramidalis  
 Foramen palatinum majus

Superior turbinated bone  
 Middle turbinated bone  
 Uncinate process (O. T. unciform process)

**Inferior turbinated bone**

Lacrimal process  
 Maxillary process  
 Ethmoidal process

**Lacrimal bone**

Posterior lacrimal crest (O. T. lacrimal crest)  
 Lacrimal sulcus  
 Lacrimal hamulus ("hooklet") (O. T. hamular process)  
 Fossa of lacrimal sac

**Nasal bone**

Nasal foramina  
 Ethmoidal sulcus (O. T. groove for nasal nerve)

**Vomer, or ploughshare bone**

Wing of vomer

**Bones of the face**

**Maxilla, or upper jawbone (O. T. superior maxillary bone)**

Body of maxilla  
 Anterior surface (O. T. external or facial surface)  
 Nasal surface  
 Orbital surface  
 Infratemporal surface (O. T. zygomatic surface)  
 Maxillary sinus (O. T. antrum of Highmore)  
 Infraorbital margin  
 Infraorbital canal  
 Infraorbital groove  
 Infraorbital foramen  
 Infraorbital suture  
 Canine fossa

Prenasal fossa  
 Nasal notch  
 Maxillary tuber  
 Alveolar foramina  
 Alveolar canals (O. T. posterior dental canals)  
 Orbital plain  
 Lacrimal margin  
 Lacrimal sulcus  
 Nasolacrimal canal (O. T. lacrimal groove)  
 Turbinated crest  
 Frontal process (O. T. nasal process)  
 Anterior lacrimal crest  
 Lacrimal notch  
 Ethmoidal crest  
 Zygomatic process (O. T. malar process)

Palatine process  
 Nasal crest  
 Anterior nasal spine

*Incisive bone*

Incisive canal  
 Incisive suture  
 Palatine spines  
 Palatine grooves  
 Alveolar process  
 Alveolar margin  
 Tooth cavities  
 Interalveolar septa  
 Alveolar yokes  
 Maxillary hiatus  
 Incisive foramen

**Palate bone**

Perpendicular part (O. T. vertical plate)  
 Nasal surface  
 Maxillary surface  
 Sphenopalatine notch  
 Pterygopalatine sulcus  
 Pyramidal process  
 Larger palatine foramen

Foramina palatina minora	Linea mylohyoidea
Canales palatini	
Crista conchal	Sulcus mylohyoideus
	Juga alveolaria
Crista ethmoidalis	Ramus mandibulae
Processus orbitalis	Angulus mandibulae
Processus sphenoidalis	(Tuberositas masseterica)
<b>Pars horizontalis</b>	(Tuberositas pterygoidea)
	(Crista buccinatoria)
Facies nasalis	Incisura mandibulae
Facies palatina	
Spina nasalis posterior	Processus condyloideus
Crista nasalis	Capitulum [proc. condyl.] mandibulae
	Collum [proc. condyloidei] mandibulae
<b>Os zygomaticum</b>	Fovea pterygoidea proc. condyloidei
	Processus coronoideus
Facies malaris	Foramen mandibulare
Facies temporalis	
Facies orbitalis	Lingula mandibulae
Processus temporalis	Canalis mandibulae
Processus frontosphenoidalis	Fovea sublingualis
	(Fovea submaxillaris)
(Processus marginalis)	
Foramen zygomaticoorbitale	Pars alveolaris
	Limbus alveolaris
Foramen zygomaticofaciale	Alveoli dentales
	Septa interalveolaria
Foramen zygomaticotemporale	
	<b>Os hyoideum</b>
<b>Mandibula</b>	Corpus oss. hyoidei
Corpus mandibulae	Cornu minus
Basis mandibulae	Cornu majus
Protuberantia mentalis	
	<b>Cranium</b>
Tuberculum mentale	Calvaria
Spina mentalis	Pericranium
Foramen mentale	Lamina externa
Linea obliqua	Diploë
	Canales diploici [Brescheti]
Fossa digastrica	Lamina interna
	Facies [ossea]

8



Smaller palatine foramen	Mylohyoid line (O. T. internal oblique line)
Palatine canals	Mylohyoid groove
Turbinated crest (O. T. inferior turbinated crest)	Alveolar yokes
Ethmoidal crest (O. T. superior turbinated crest)	Ramus of lower jaw (O. T. perpendicular portion)
Orbital process	Angle of lower jaw
Sphenoidal process	Masseteric tuberosity
Horizontal part (O. T. horizontal plate)	Pterygoid tuberosity
Nasal surface	Buccinator crest
Palatine surface	Mandibular notch (O. T. sigmoid notch)
Posterior nasal spine	Condylod process
Nasal crest	Head of condylod process of lower jaw
<b>Zygoma, or yoke bone (O. T. malar bone)</b>	Neck of condylod process of lower jaw
Malar surface	Pterygoid pit of condylod process
Temporal surface	Coronoid process
Orbital surface	Mandibular foramen (O. T. inferior dental foramen)
Temporal process (O. T. zygomatic process)	Mandibular tongue
Frontosphenoidal process (O. T. frontal process)	Mandibular canal (O. T. inferior dental canal)
Marginal process	Sublingual pit (O. T. sublingual fossa)
Zygomatico-orbital foramen (O. T. temporo-malar canal)	Submaxillary pit (O. T. submaxillary fossa)
Zygomaticofacial foramen (O. T. malar foramen)	Alveolar part
Zygomaticotemporal foramen	Alveolar margin
	Tooth cavities
	Interalveolar septa
	<b>Hyoid bone</b>
<b>Mandible, or lower jaw bone (O. T. inferior maxillary bone)</b>	Body of hyoid bone
Body of lower jaw bone	Lesser horn
Base of lower jaw	Greater horn
Mental protuberance (O. T. mental process)	
Mental tubercle	<b>Skull</b>
Mental spine (O. T. genial tubercle)	Skull cap
Mental foramen	Periosteum of skull
Oblique line (O. T. external oblique line)	Outer plate
Digastric fossa	Cancellous bone
	Diploic canals or canals of Breschet
	Inner table
	Bony portion of face

Cranium cerebrale	Fibrocartilago basalis
Cranium viscerale	Palatum durum
Vertex	(Torus palatinus)
Frons	Orbita
Occiput	Aditus orbitae
Basis cranii interna	Margo supraorbitalis
Basis cranii externa	Margo infraorbitalis
Fossa cranii anterior	Paries superior
Fossa cranii media	Paries inferior
Fossa cranii posterior	Paries lateralis
Juga cerebralialia	Paries medialis
Impressiones digitatae	Fissura orbitalis superior
Sulci venosi	
Sulci arteriosi	
(Foveolae granulares [Pacchioni])	Fissura orbitalis inferior
(Ossa suturarum)	
Planum temporale	<b>Suturae cranii</b>
Fossa temporalis	Sutura coronalis
Arcus zygomaticus	Sutura sagittalis
Fossa infratemporalis	Sutura lambdoidea
Fossa pterygopalatina	Sutura occipitomastoidea
	Sutura sphenofrontalis
Canalis pterygopalatinus	Sutura sphenoorbitalis
	Sutura sphenoeethmoidalis
Foramen sphenopalatinum	Sutura sphenosquamosa
Apertura piriformis	Sutura sphenoparietalis
Cavum nasi	Sutura squamosa
Septum nasi osseum	(Sutura frontalis)
Meatus nasi communis	Sutura parietomastoidea
Meatus nasi superior	(Sutura squamosomastoidea)
Meatus nasi medius	Sutura nasofrontalis
Meatus nasi inferior	Sutura frontoeethmoidalis
Meatus nasopharyngeus	Sutura frontomaxillaris
Choanae	Sutura frontolacrimalis
	Sutura zygomaticofrontalis
Recessus sphenoeethmoidalis	Sutura zygomaticomaxillaris
Foramen jugulare	Sutura ethmoideomaxillaris
Fissura sphenopetrosa	Sutura sphenozygomatica
Fissura petrooccipitalis	(Sutura sphenomaxillaris)
Fissura sphenoccipitalis	Sutura zygomaticotemporalis
Foramen lacerum	Sutura internasalis
	Sutura nasomaxillaris

Cerebral cranium or calvaria	Basal fibrocartilage
Visceral cranium or face	Hard palate
Vertex or crown of head	Palatine torus or protuberance
Forehead	Orbital cavity
Back of head	Orbital opening
Internal base of skull	Supraorbital margin
External base of skull	Infraorbital margin
Anterior cranial fossa	Superior wall
Middle cranial fossa	Inferior wall
Posterior cranial fossa	Lateral wall
Cerebral projections ("yokes")	Medial wall
Digitate impressions	Superior orbital fissure (O. T. sphenoidal fissure or foramen lacerum anterius)
Grooves of the veins	Inferior orbital fissure (O. T. sphenomaxillary fissure)
Grooves of the arteries	
Granular foveolae (O. T. Pacchionian depressions)	
Sutural bones (O. T. Wormian bones)	
Temporal plain	
Temporal fossa	
Zygomatic arch	
Infratemporal fossa	
Pterygopalatine fossa (O. T. sphenomaxillary fossa)	
Pterygopalatine canal (O. T. posterior palatine canal)	
Sphenopalatine foramen	
Piriform opening (O. T. anterior nares)	
Nasal cavity	
Bony nasal septum	
Common meatus of nose	
Superior meatus of nose	
Middle meatus of nose	
Inferior meatus of nose	
Nasopharyngeal meatus	
Choanae ("funnels") (O. T. posterior nares)	
Spheno-ethmoidal recess	
Jugular foramen	
Sphenopetrosal fissure	
Petro-occipital fissure	
Spheno-occipital fissure	
Lacerated foramen (O. T. foramen lacerum medium)	
	<b>Sutures of the skull</b>
	Coronal suture
	Sagittal suture
	Lambdoidal suture
	Occipitomastoid suture
	Sphenofrontal suture
	Spheno-orbital suture
	Spheno-ethmoidal suture
	Sphenosquamosal suture
	Sphenoparietal suture
	Squamosal suture
	Frontal suture
	Parietomastoid suture
	Squamosomastoid suture
	Nasofrontal suture
	Fronto-ethmoidal suture
	Frontomaxillary suture
	Frontolacrimal suture
	Zygomaticofrontal suture
	Zygomaticomaxillary suture
	Ethmoideomaxillary suture
	Sphenozygomatic suture
	Sphenomaxillary suture
	Zygomaticotemporal suture
	Internasal suture
	Nasomaxillary suture

Sutura lacrimomaxillaris  
 Sutura lacrimoconchalis  
 Sutura intermaxillaris  
 Sutura palatomaxillaris  
 Sutura palatoethmoidalis  
 Sutura palatina mediana  
 Sutura palatina transversa

### Synchondroses cranii

Synchondrosis sphenoccipitalis  
 Synchondrosis sphenopetrosa  
 Synchondrosis petrooccipitalis  
*Synchondrosis intraoccipitalis posterior*  
*Synchondrosis intraoccipitalis anterior*  
*Synchondrosis intersphenoidalis*  
*Fonticulus frontalis [major]*  
*Fonticulus occipitalis [minor]*  
*Fonticulus mastoideus*  
*Fonticulus sphenoidalis*

### Ossa extremitatis superioris

Cingulum extremitatis superioris

### Scapula

Facies costalis  
 Lineae musculares  
 Fossa subscapularis  
 Facies dorsalis  
 Spina scapulae  
 Fossa supraspinata  
 Fossa infraspinata  
 Acromion  
 Facies articularis acromii  
 Margo vertebralis  
 Margo axillaris  
 Margo superior  
 Angulus inferior  
 Angulus lateralis  
 Angulus medialis  
 Cavitas glenoidalis  
 Collum scapulae  
 Tuberositas infraglenoidalis

Tuberositas supraglenoidalis

Incisura scapulae

Processus coracoideus

### Clavicula

Extremitas sternalis  
 Facies articularis sternalis  
 Tuberositas costalis

Extremitas acromialis  
 Facies articularis acromialis  
 Tuberositas coracoidea

Skeleton extremitatis superioris liberae

### Humerus

Caput humeri  
 Collum anatomicum  
 Collum chirurgicum  
 Tuberculum majus

Tuberculum minus

Sulcus intertubercularis

Crista tuberculi majoris

Crista tuberculi minoris

Corpus humeri  
 Facies anterior medialis

Facies anterior lateralis

Facies posterior  
 Margo medialis  
 Margo lateralis  
 Tuberositas deltoidea  
 Sulcus n. radialis

Lacrimomaxillary suture  
 Lacrimoconchal suture  
 Intermaxillary suture  
 Palatomaxillary suture  
 Palato-ethmoidal suture  
 Median palatine suture  
 Transverse palatine suture

### Synchondroses of the skull

Spheno-occipital synchondrosis  
 Sphenopetrosal synchondrosis  
 Petro-occipital synchondrosis  
*Posterior intraoccipital synchondrosis*  
*Anterior intraoccipital synchondrosis*  
*Intersphenoidal synchondrosis*  
*Larger frontal fontanelle*  
*Smaller occipital fontanelle*  
*Mastoid fontanelle*  
*Sphenoidal fontanelle*

### Bones of upper extremity

#### Shoulder girdle

##### Shoulder-blade

Costal surface  
 Muscular lines  
 Subscapular fossa  
 Dorsal surface  
 Spine of the scapula  
 Supraspinous fossa  
 Infraspinous fossa  
 Acromion, or acromial process  
 Articular surface of acromion  
 Vertebral margin  
 Axillary margin  
 Superior margin  
 Inferior angle  
 Lateral angle (O. T. anterior angle)  
 Medial angle (O. T. superior angle)  
 Glenoid cavity  
 Neck of the scapula  
 Infraglenoidal tuberosity

Supraglenoidal tuberosity (O. T. supraglenoid tubercle)  
 Scapular notch (O. T. suprascapular notch)  
 Coracoid ("crow's beak") process

### Collar bone or clavicle

Sternal extremity  
 Sternal articular surface  
 Costal tuberosity (O. T. impression for rhomboid ligament)  
 Acromial extremity  
 Acromial articular surface  
 Coracoid tuberosity (O. T. impression for conoid ligament)

### Skeleton of free upper extremity

#### Humerus, or upper arm bone

Head of humerus  
 Anatomical neck  
 Surgical neck  
 Larger tubercle (O. T. greater tuberosity)  
 Smaller tubercle (O. T. lesser tuberosity)  
 Intertubercular sulcus (O. T. bicipital groove)  
 Crest of larger tubercle (O. T. posterior bicipital ridge)  
 Crest of smaller tubercle (O. T. anterior bicipital ridge)  
 Body of humerus, or shaft  
 Medial anterior surface (O. T. internal surface)  
 Lateral anterior surface (O. T. external surface)  
 Posterior surface  
 Medial margin (O. T. internal border)  
 Lateral margin (O. T. external border)  
 Deltoid tuberosity  
 Groove for radial nerve (O. T. musculospiral groove)



Sulcus n. ulnaris  
Capitulum humeri

Trochlea humeri  
Epicondylus medialis

Epicondylus lateralis

Fossa olecrani  
Fossa coronoidea  
Fossa radialis  
(Processus supracondyloideus)

### Radius

Corpus radii  
Capitulum radii  
Fovea capituli radii  
Collum radii  
Circumferentia articularis  
Tuberositas radii

Crista interossea

Facies dorsalis  
Facies volaris  
Facies lateralis  
Margo dorsalis  
Margo volaris  
Processus styloideus  
Incisura ulnaris  
Facies articularis carpea

### Ulna

Corpus ulnae  
Olecranon  
Processus coronoideus  
Tuberositas ulnae  
Incisura semilunaris

Incisura radialis

Crista interossea

Facies dorsalis

Facies volaris  
Facies medialis  
Margo dorsalis  
Margo volaris  
Crista m. supinatoris  
Capitulum ulnae  
Circumferentia articularis  
Processus styloideus

### Carpus

Ossa carpi  
(Os centrale)  
Os naviculare manus

Tuberculum oss. navicularis  
Os lunatum  
Os triquetrum

Os pisiforme  
Os multangulum majus

Tuberculum oss. multang. majoris  
Os multangulum minus

Os capitatum  
Os hamatum  
Hamulus oss. hamati  
Eminentia carpi radialis  
Eminentia carpi ulnaris  
Sulcus carpi

### Metacarpus

Ossa metacarpalia I—V  
Basis  
Corpus  
Capitulum  
Os metacarpale III  
Processus styloideus

### Phalanges digitorum manus

Phalanx prima  
Phalanx secunda

Groove for ulnar nerve  
 Capitulum or little head of humerus  
 (O. T. capitellum or radial head)  
 Trochlea ("pulley") of humerus  
 Medial epicondyle (O. T. internal con-  
 dyle)  
 Lateral epicondyle (O. T. external  
 condyle)  
 Olecranon fossa  
 Coronoid fossa  
 Radial fossa  
 Supracondyloid process

**Radius ("spoke")**

Body of radius, or shaft  
 Head of radius  
 Pit of head of radius  
 Neck of radius  
 Articular circumference  
 Tuberosity of radius (O. T. bicipital  
 tuberosity)  
 Interosseous crest (O. T. internal or  
 interosseous border)  
 Dorsal surface (O. T. posterior surface)  
 Volar surface (O. T. anterior surface)  
 Lateral surface (O. T. external surface)  
 Dorsal margin (O. T. posterior border)  
 Volar margin (O. T. anterior border)  
 Styloid process  
 Ulnar notch (O. T. sigmoid cavity)  
 Carpal articular surface

**Ulna, or elbow bone**

Body of ulna, or shaft  
 Olecranon, or point of the elbow  
 Coronoid process  
 Tuberosity of the ulna  
 Semilunar notch (O. T. greater sig-  
 moid cavity)  
 Radial notch (O. T. lesser sigmoid  
 cavity)  
 Interosseous crest (O. T. external or  
 interosseous border)

Dorsal surface (O. T. posterior sur-  
 face)  
 Volar surface (O. T. anterior surface)  
 Medial surface (O. T. internal surface)  
 Dorsal margin (O. T. posterior border)  
 Volar margin (O. T. anterior border)  
 Ridge of supinator muscle  
 Head of ulna  
 Articular circumference  
 Styloid process

**Wrist**

**Bones of the wrist**  
 Central bone  
 Navicular bone of the hand (O. T.  
 scaphoid)  
 Tubercle of navicular bone  
 Lunate bone (O. T. semilunar)  
 Three-cornered bone (O. T. cuneiform  
 bone)  
 Pisiform bone  
 Large multangular bone (O. T. tra-  
 pezium)  
 Tubercle of large multangular bone  
 Small multangular bone (O. T. trape-  
 zoid)  
 Capitate bone (O. T. os magnum)  
 Hooked bone (O. T. unciform)  
 Hook of os hamatum  
 Radial eminence of wrist  
 Ulnar eminence of wrist  
 Carpal sulcus

**Metacarpus**

Metacarpal bones I—V  
 Base  
 Body, or shaft  
 Head  
 Third metacarpal bone  
 Styloid process

**Phalanges of the fingers**

First phalanx  
 Second phalanx

Phalanx tertia  
 Basis phalangis  
 Corpus phalangis  
 Trochlea phalangis  
 Tuberositas unguicularis  
 Ossa sesamoidea

### Ossa extremitatis inferioris

Cingulum extremitatis inferioris

#### Os coxae

Foramen obturatum  
 Acetabulum  
 32 Fossa acetabuli  
 Incisura acetabuli  
 Facies lunata  
 Sulci paragonoidales

#### Os ilium

33 Corpus oss. ilium  
 Ala oss. ilium  
 Linea arcuata  
 Crista iliaca  
 Labium externum  
 Linea intermedia  
 Labium internum  
 Spina iliaca anterior superior  
 Spina iliaca anterior inferior  
 Spina iliaca posterior superior  
 Spina iliaca posterior inferior  
 Linea glutaea anterior  
  
 Linea glutaea posterior  
  
 Linea glutaea inferior  
  
 Facies auricularis  
 Tuberositas iliaca  
 Fossa iliaca

#### Os ischii

34 Corpus oss. ischii  
 Ramus superior oss. ischii

Ramus inferior oss. ischii

Tuber ischiadicum

Spina ischiadica

Incisura ischiadica major

Incisura ischiadica minor

#### Os pubis

35 Corpus oss. pubis  
 Pecten oss. pubis  
 Eminentia iliopectinea  
 Tuberculum pubicum  
 Crista obturatoria  
 Sulcus obturatorius  
 Tuberculum obturatorium anterius  
 (Tuberculum obturatorium posterius)  
 Ramus inferior oss. pubis

Ramus superior oss. pubis

Facies symphyseos

#### Pelvis

36 Symphysis ossium pubis  
 Arcus pubis  
 Angulus pubis  
 Pelvis major  
 Pelvis minor  
 Linea terminalis  
 Pars sacralis  
 Pars iliaca  
 Pars pubica  
 Apertura pelvis [minoris] superior  
 Apertura pelvis [minoris] inferior

Axis pelvis

Conjugata

Third phalanx  
 Base of phalanx  
 Body of phalanx, or shaft  
 Pulley of phalanx  
 Ungual tuberosity  
 Sesamoid bones

**Bones of the lower extremity**

**Pelvic girdle**

**Hip bone (O. T. os innominatum)**

Obturator ("closed") foramen  
 Acetabulum ("cup")  
 Fossa of the acetabulum  
 Acetabular notch  
 Lunate surface  
 Paraglenoid grooves

**Ilium, or flank bone**

Body of ilium  
 Wing of ilium  
 Curved lines  
 Iliac crest  
     External lip  
     Intermediate line  
     Internal lip  
 Superior anterior iliac spine  
 Inferior anterior iliac spine  
 Superior posterior iliac spine  
 Inferior posterior iliac spine  
 Anterior gluteal line (O. T. middle curved line)  
 Posterior gluteal line (O. T. superior curved line)  
 Inferior gluteal line (O. T. inferior curved line)  
 Auricular surface  
 Iliac tuberosity  
 Iliac fossa

**Ischium, or bone of the hip**

Body of ischium  
 Superior ramus of ischium

Inferior ramus of ischium (O. T. ascending ramus)  
 Sciatic tuber (O. T. tuberosity of the ischium)  
 Sciatic spine (O. T. spine of the ischium)  
 Greater sciatic notch (O. T. great sacro-sciatic notch)  
 Lesser sciatic notch (O. T. lesser sacro-sciatic notch)

**Pubic bone**

Body of pubic bone  
 Pecten ("comb") of pubic bone  
 Iliopectineal eminence  
 Pubic tubercle (O. T. spine of os pubis)  
 Obturator crest  
 Obturator sulcus  
 Anterior obturator tubercle  
 Posterior obturator tubercle  
 Inferior ramus of pubic bone (O. T. descending ramus)  
 Superior ramus of pubic bone (O. T. ascending ramus)  
 Symphyseal surface (O. T. symphysis pubis)

**Pelvis ("basin")**

Symphysis of pubic bones  
 Pubic arch  
 Angle of pubis  
 Large pelvis (O. T. false pelvis)  
 Small pelvis (O. T. true pelvis)  
 Terminal line  
     Sacral part  
     Iliac part  
     Pubic part  
 Upper opening of lesser pelvis (O. T. pelvic inlet)  
 Lower opening of lesser pelvis (O. T. pelvic outlet)  
 Axis of pelvis  
 Conjugate diameter

Diameter transversa

Diameter obliqua

Inclinatio pelvis

Skeleton extremitatis inferioris liberae in-

**Femur**

Caput femoris

Fovea capitis femoris

Collum femoris

Corpus femoris

Trochanter major

Fossa trochanterica

Trochanter minor

(Trochanter tertius)

Linea intertrochanterica

Crista intertrochanterica

Linea aspera

Labium laterale

Labium mediale

Linea pectinea

Tuberositas glutea

Fossa intercondyloidea

Linea intercondyloidea

Planum popliteum

Condylus medialis

Condylus lateralis

Facies patellaris

Epicondylus lateralis

Epicondylus medialis

**Tibia**

Facies articularis superior

Corpus tibiae

Condylus medialis

Condylus lateralis

Fossa intercondyloidea anterior

Fossa intercondyloidea posterior

Eminentia intercondyloidea

Tuberculum intercondyloideum mediale

Tuberculum intercondyloideum laterale

Margo infraglenoidalis

Tuberositas tibiae

Facies medialis

Facies posterior

Facies lateralis

Margo medialis

Crista anterior

Crista interossea

Linea poplitea

Malleolus medialis

Incisura fibularis

Sulcus malleolaris

Facies articularis inferior

Facies articularis malleolaris

**Fibula**

Corpus fibulae

Crista interossea

Crista anterior

Crista lateralis

Crista medialis

Facies medialis

Facies lateralis

Facies posterior

Capitulum fibulae

Facies articularis capituli

Apex capituli fibulae

Malleolus lateralis

Facies articularis malleoli

**Patella**

Basis patellae

Apex patellae

Facies articularis



Transverse diameter	Intercondyloid eminence (O. T. spinous process)
Oblique diameter	Medial intercondyloid tubercle
Pelvic incline	
<b>Skeleton of free lower extremity</b>	Lateral intercondyloid tubercle
<b>Thigh bone</b>	Infraglenoidal margin
Head of femur	Tuberosity of the tibia (O. T. tubercle)
Pit of the head of femur	Medial surface
Neck of femur	Posterior surface
Body, or shaft, of femur	Lateral surface
Great trochanter	Medial margin
Trochanteric fossa (O. T. digital fossa)	Anterior crest
Lesser trochanter	Interosseous crest
Third trochanter	Popliteal line
Intertrochanteric line (O. T. spiral line)	Medial malleolus (O. T. internal malleolus)
Intertrochanteric crest (O. T. intertrochanteric line)	Fibular notch
Rough line	Malleolar sulcus
Lateral lip	Inferior articular surface
Medial lip	Malleolar articular surface
Pectineal line	
Gluteal tuberosity	<b>Calf bone</b>
Intercondyloid fossa	Body or shaft of fibula
Intercondyloid line	Interosseous crest
Popliteal plain (O. T. popliteal space)	Anterior crest
Medial condyle (O. T. inner condyle)	Lateral crest
Lateral condyle (O. T. outer condyle)	Medial crest
Patellar surface	Medial surface
Lateral epicondyle (O. T. outer tuberosity)	Lateral surface
Medial epicondyle (O. T. inner tuberosity)	Posterior surface
	Head of fibula
	Articular surface of head
	Apex of head of fibula
	Lateral malleolus (O. T. external malleolus)
	Articular surface of malleolus
	<b>Knee-cap</b>
	Base of patella
	Apex of patella
	Articular surface
<b>Shin bone</b>	
Superior articular surface	
Body or shaft of tibia	
Medial condyle (O. T. internal tuberosity)	
Lateral condyle (O. T. external tuberosity)	
Anterior intercondyloid fossa	
Posterior intercondyloid fossa	

	<b>Tarsus</b>	
Ossa tarsi		Facies articularis media
		Facies articularis posterior
		Sulcus m. peronei
		(Processus trochlearis)
		Facies articularis cuboidea
	<b>Talus</b>	
Caput tali		<b>Os naviculare pedis</b>
Corpus tali		Tuberositas oss. navicularis
Collum tali		<b>Os cuneiforme primum</b>
Trochlea tali		<b>Os cuneiforme secundum</b>
Facies superior		<b>Os cuneiforme tertium</b>
Facies malleolaris medialis		<b>Os cuboideum</b>
Facies malleolaris lateralis		Sulcus m. peronei
Sulcus tali		Tuberositas oss. cuboidei
Processus lateralis tali		
Facies articularis calcanea posterior		<b>Metatarsus</b>
Facies articularis calcanea media		Ossa metatarsalia I—V
Sulcus m. flexoris hallucis longi		Basis
		Corpus
		Capitulum
Facies articularis navicularis		Tuberositas oss. metatarsalis I
Facies articularis calcanea anterior		Tuberositas oss. metatarsalis V
Processus posterior tali		
(Os trigonum)		<b>Phalanges digitorum pedis</b>
<b>Calcaneus</b>		Phalanx prima
Corpus calcanei		Phalanx secunda
Tuber calcanei		Phalanx tertia
Processus medialis tuberis calcanei		Tuberositas unguicularis
Processus lateralis tuberis calcanei		Basis phalangis
Sustentaculum tali		Corpus phalangis
Sulcus m. flexoris hallucis longi		Trochlea phalangis
		Ossa sesamoidea
Sulcus calcanei		
Sinus tarsi		
Facies articularis anterior		

**Root of the foot****Tarsal bones****Ankle bone (O. T. astragalus)**

Head of ankle bone

Body of ankle bone

Neck of ankle bone

Trochlea ("pulley") of ankle bone

Superior surface

Medial malleolar surface

Lateral malleolar surface

Sulcus of ankle bone

Lateral process of ankle bone

Posterior calcanean articular surface

Middle calcanean articular surface

Groove for the long flexor muscle of  
the great toe

Navicular articular surface

Anterior calcanean articular surface

Posterior process of ankle bone

Triangular bone

**Heel bone (O. T. os calcis)**

Body of heel bone

Calcanean tuber

Medial process of calcanean tuber

Lateral process of calcanean tuber

Support of ankle bone

Groove for the long flexor muscle of  
great toe

Calcanean sulcus

Tarsal sinus

Anterior articular surface

Middle articular surface

Posterior articular surface

Groove for peroneal muscle

Trochlear process

Cuboid articular surface

**Scaphoid bone of foot**

Tuberosity of scaphoid bone

**First Cuneiform, or Wedge Bone****Second Cuneiform, or Wedge Bone****Third Cuneiform, or Wedge Bone****Cuboid bone**

Groove for peroneal muscle

Tuberosity of cuboid bone

**Metatarsus, or "after-root" of foot**

Metatarsal bones I—V

Base

Body

Head

Tuberosity of first metatarsal bone

Tuberosity of fifth metatarsal bone

**Phalanges of toes**

First phalanx

Second phalanx

Third phalanx

Ungual tuberosity

Base of phalanx

Body of phalanx

Trochlea ("pulley or block") of pha-  
lanx

Sesamoid bones

## Syndesmologia

Junctura ossium  
 Synarthrosis  
   Sutura  
     Sutura serrata  
     Sutura squamosa  
     Harmonia  
   Gomphosis  
   Synchondrosis  
   Symphysis  
 Diarthrosis  
   Articulatio  
   Articulatio simplex  
   Articulatio composita  
   Arthrodia  
   Articulatio sphaeroidea  
   Enarthrosis  
   Ginglymus  
   Articulatio cochlearis  
   Articulatio ellipsoidea  
   Articulatio trochoidea  
   Articulatio sellaris  
   Amphiarthrosis  
 Syndesmosis  
 Cartilago articularis  
 Cavum articulare  
 Discus articularis  
  
 Labrum glenoidale  
 Meniscus articularis  
 Capsula articularis  
   Stratum fibrosum  
   Stratum synoviale  
 Plica synovialis  
 Villi synoviales  
 Synovia

### Ligamenta columnae vertebralis et cranii

Fibrocartilaginee intervertebrales  
 Annulus fibrosus  
 Nucleus pulposus  
 Ligg. flava  
  
 Capsulae articulares  
 Ligg. intertransversaria  
 Ligg. interspinalia  
 Lig. supraspinale  
 Lig. nuchae  
 Lig. longitudinale anterius  
  
 Lig. longitudinale posterius  
  
 Symphysis sacrococcygea  
 Lig. sacrococcygeum posterius superficiale  
 Lig. sacrococcygeum posterius profundum  
 Lig. sacrococcygeum anterius  
 Lig. sacrococcygeum laterale  
 Lig. pterygospinosum  
 Lig. stylohyoideum

### Articulatio atlantooccipitalis

Capsulae articulares  
 Membrana atlantooccipitalis anterior  
 Membrana atlantooccipitalis posterior

### Articulatio atlantoepistrophica

Capsulae articulares

## Syndesmology, or Joint Articulation

- Joining of bones
- Immovable articulation
  - Suture or seam
    - Serrated suture
    - Scaly suture
    - Apposition suture
  - Socket articulation
  - Cartilaginous articulation
  - Bony coalescence or junction
- Movable articulation
  - Joint
    - Simple joint
    - Compound joint
    - Gliding joint
    - Spherical joint
    - Ball-and-socket joint
    - Hinge-joint
    - Spiral joint
    - Elliptical joint
    - Trochoid or pivot joint
    - Saddle joint
    - Mixed articulation
  - Ligamentous union
  - Articular cartilage
  - Joint cavity
  - Articular disk (O. T. interarticular fibrocartilage)
  - Glenoid lip
  - Articular crescent
  - Joint-capsule
    - Fibrous layer
    - Synovial layer
  - Synovial fold
  - Synovial tufts
  - Joint-oil
- Ligaments of the spine and skull**
  - Intervertebral fibrocartilages
  - Fibrous ring
  - Pulp-like nucleus
  - Yellow ligaments (O. T. ligg. subflava)
  - Joint-capsules
  - Intertransverse ligaments
  - Interspinous ligaments
  - Supraspinous ligament
  - Ligament of the nape
  - Anterior longitudinal ligament (O. T. anterior common ligament)
  - Posterior longitudinal ligament (O. T. posterior common ligament)
  - Symphysis of sacrum and coccyx
  - Superficial posterior sacrococcygeal ligament
  - Deep posterior sacrococcygeal ligament
  - Anterior sacrococcygeal ligament
  - Lateral sacrococcygeal ligament
  - Pterygospinous ligament
  - Stylohyoid ligament
- Joint between atlas and occipital bone**
  - Joint-capsules
  - Anterior atlanto-occipital membrane
  - Posterior atlanto-occipital membrane
- Joint between atlas and epistropheus or axis**
  - Joint-capsules



Ligg. alaria

Lig. apicis dentis

Lig. transversum atlantis

Lig. cruciatum atlantis

Membrana tectoria

### **Articulationes costovertebrales**

#### **Articulationes capitulorum**

Capsulae articulares

Lig. capituli costae radiatum

Lig. capituli costae interarticulare

#### **Articulationes costotransversariae**

Capsulae articulares

Lig. tuberculi costae

Lig. colli costae

Lig. costotransversarium anterius

Lig. costotransversarium posterius

Lig. lumbocostale

Foramen costotransversarium

#### **Articulationes sternocostales**

Capsulae articulares

Lig. sternocostale interarticulare

Ligg. sternocostalia radiata

Membrana sterni

Ligg. costoxiphoidea

Ligg. intercostalia

Ligg. intercostalia externa

Ligg. intercostalia interna

Articulationes interchondrales

### **Articulatio mandibularis**

Capsula articularis

Discus articularis

Lig. temporomandibulare

Lig. sphenomandibulare

Lig. stylomandibulare

### **Ligg. cinguli extremitatis superioris**

Lig. coracoacromiale

Lig. transversum scapulae superius

Lig. transversum scapulae inferius

### **Articulatio acromioclavicularis**

Capsula articularis

Lig. acromioclaviculare

(Discus articularis)

Lig. coracoclaviculare

Lig. trapezoideum

Lig. conoideum

### **Articulatio sternoclavicularis**

Capsula articularis

Discus articularis

Lig. sternoclaviculare

Lig. costoclaviculare

Lig. interclaviculare

### **Articulatio humeri**

Capsula articularis

Labrum glenoidale

Lig. coracohumerale

### **Articulatio cubiti**

Articulatio humeroulnaris

Articulatio humeroradialis

Alar ligaments (O. T. odontoid or check ligaments)

Ligament of apex of tooth (O. T. suspensory ligament)

Transverse ligament of atlas

Cruciform ligament of atlas

Tectorial ("roof") membrane (O. T. posterior occipito-axial ligament)

### Joints between ribs and vertebrae

#### Capitular joints, or articulations between the heads of the ribs and the vertebrae

Joint-capsules

Radiate ligament of head of rib (O. T. anterior costovertebral or stellate ligament)

Interarticular ligament of head of rib

#### Costotransverse joints

Joint-capsules

Ligament of tubercle of rib

Ligament of neck of rib

Anterior costotransverse ligament

Posterior costotransverse ligament

Lumbocostal ligament

Costotransverse foramen

#### Sternocostal joints

Joint-capsules

Interarticular sternocostal ligament (O. T. interarticular chondrosternal ligament)

Radiate sternocostal ligaments (O. T. anterior and posterior chondrosternal ligaments)

Membrane of sternum

Costoxiphoid ligaments (O. T. chondroxiphoid ligaments)

Intercostal ligaments

External intercostal ligaments

Internal intercostal ligaments

Interchondral joints

#### Jaw=joint

Joint-capsule (O. T. capsular ligament)

Joint-disk (O. T. interarticular fibrocartilage)

Temporomandibular ligament (O. T. external lateral ligament)

Sphenomandibular ligament (O. T. internal lateral ligament)

Stylomandibular ligament (O. T. stylo-maxillary ligament)

#### Ligaments of the girdle of upper extremity

Coraco-acromial ligament

Superior transverse ligament of scapula

Inferior transverse ligament of scapula

#### Acromioclavicular joint.

Joint-capsule

Acromioclavicular ligament

Intercalated disk of fibrocartilage

Coracoclavicular ligament

Trapezoid ligament

Conoid ligament

#### Sternoclavicular joint

Joint-capsule

Articular disk

Sternoclavicular ligament

Costoclavicular ligament (O. T. rhomboid ligament)

Interclavicular ligament

#### Shoulder=joint

Joint-capsule

Glenoid lip (O. T. glenoid ligament)

Coracohumeral ligament (O. T. accessory ligament)

#### Elbow=joint

Humero-ulnar articulation

Humero-radial articulation

Articulatio radioulnaris proximalis

Capsula articularis  
Lig. collaterale ulnare

Lig. collaterale radiale

Lig. annulare radii

Recessus sacciformis  
Membrana interossea antibrachii  
Chorda obliqua

### **Articulatio radioulnaris distalis**

Capsula articularis  
Discus articularis

Recessus sacciformis

### **Articulatio manus**

Articulatio radiocarpea

Articulatio intercarpea

Capsula articularis  
Lig. radiocarpeum dorsale

Lig. radiocarpeum volare

Lig. carpi radiatum  
Lig. collaterale carpi ulnare

Lig. collaterale carpi radiale

Ligg. intercarpea dorsalia  
Ligg. intercarpea volaria

Ligg. intercarpea interossea

### **Articulatio ossis pisiformis**

Capsula articularis

Lig. pisohamatum

Lig. pisometacarpeum

Canalis carpi

### **Articulationes carpometacarpeae**

Capsulae articulares  
Ligg. carpometacarpea dorsalia  
Ligg. carpometacarpea volaria

### **Articulatio carpometacarpea pollicis**

Capsula articularis

### **Articulationes intermetacarpeae**

Capsulae articulares  
Ligg. basium [oss. metacarp.] dorsalia

Lig. basium [oss. metacarp.] volaria

Lig. basium [oss. metacarp.] interossea

Spatia interossea metacarpi

### **Articulationes metacarpophalangeae**

Capsulae articulares  
Ligg. collateralia  
Ligg. accessoria volaria

Ligg. capitulorum [oss. metacarpalium]  
transversa

### **Articulationes digitorum manus**

Capsulae articulares  
Ligg. collateralia

### **Ligg. cinguli extremitatis inferioris**

Membrana obturatoria  
Canalis obturatorius  
Lig. iliolumbale

Proximal radio-ulnar articulation (O. T. superior radio-ulnar)

Joint-capsule

Ulnar collateral ligament (O. T. internal lateral ligament)

Radial collateral ligament (O. T. external lateral ligament)

Annular ligament of radius (O. T. orbicular)

Sacciform recess

Interosseous membrane of forearm

Oblique cord (O. T. oblique, or round ligament)

### **Distal radio-ulnar articulation (O. T. inferior radio-ulnar)**

Joint-capsule

Articular disk (O. T. triangular fibrocartilage)

Sacciform recess

### **Joint of the hand**

Radiocarpal articulation (O. T. wrist-joint)

Intercarpal articulation (O. T. carpal joints)

Joint-capsule

Dorsal radiocarpal ligament (O. T. posterior ligament)

Volar radiocarpal ligament (O. T. anterior ligament)

Radiate ligament of carpus

Ulnar collateral ligament of carpus (O. T. internal lateral ligament)

Radial collateral ligament of carpus (O. T. external lateral ligament)

Dorsal intercarpal ligaments

Volar intercarpal ligaments (O. T. palmar intercarpal)

Interosseous intercarpal ligaments

### **Joint of the pisiform bone**

Joint-capsule

Ligament between pisiform and hook-shaped bone

Ligament between pisiform and metacarpal bones

Carpal canal

### **Carpometacarpal joints**

Joint-capsules

Dorsal carpometacarpal ligaments

Volar carpometacarpal ligaments

### **Carpometacarpal joint of the thumb**

Joint-capsule

### **Intermetacarpal joints**

Joint-capsules

Dorsal ligaments of basal extremities of metacarpal bones

Volar ligament of basal extremities of metacarpal bones

Interosseous ligament of basal extremities of metacarpal bones

Interosseous space of metacarpus

### **Metacarpophalangeal joints**

Joint-capsules

Collateral ligaments

Volar accessory ligaments (O. T. palmar ligaments)

Transverse ligaments of the heads of the metacarpal bones

### **Joints of the fingers**

Joint-capsules

Collateral ligaments (O. T. lateral ligaments)

### **Ligaments of the girdle of lower extremity (O. T. pelvic girdle)**

Obturator membrane

Obturator canal

Iliolumbar ligament



Lig. sacrotuberosum

Processus falciformis

Lig. sacrospinosum

Foramen ischiadicum majus

Foramen ischiadicum minus

**Articulatio sacroiliaca**

Ligg. sacroiliaca anteriora

Ligg. sacroiliaca interossea

Lig. sacroiliacum posterius breve

Lig. sacroiliacum posterius longum

**Symphysis ossium pubis**

Lig. pubicum superius

Lig. arcuatum pubis

Lamina fibrocartilaginea interpubica

**Articulatio coxae**

Capsula articularis

Labrum glenoidale

Lig. transversum acetabuli

Lig. teres femoris

Zona orbicularis

Lig. iliofemorale

Lig. ischiocapsulare

Lig. pubocapsulare

**Articulatio genu**

Capsula articularis

Meniscus lateralis

Meniscus medialis

Lig. transversum genu

Ligg. cruciata genu

Lig. cruciatum anterius

Lig. cruciatum posterius

Plica synovialis patellaris

Plicae alares

Lig. collaterale fibulare

Lig. collaterale tibiale

Lig. popliteum obliquum

Lig. popliteum arcuatum

Retinaculum lig. arcuati

Lig. patellae

Retinaculum patellae mediale

Retinaculum patellae laterale

**Articulatio tibiofibularis**

Capsula articularis

Ligg. capituli fibulae

Membrana interossea cruris

**Syndesmosis tibiofibularis**

Lig. malleoli lateralis anterius

Lig. malleoli lateralis posterius

**Articulationes pedis****Articulatio talocruralis**

Capsula articularis

Lig. deltoideum

Lig. tibionaviculare

Lig. calcaneotibiale

Lig. talotibiale anterius

Lig. talotibiale posterius

Lig. talofibulare anterius



Sacro-tuberous ligament (O. T. posterior or great sacrosciatic ligament)  
 Falciform process (O. T. falciform ligament)  
 Sacrospinous ligament (O. T. anterior or small sacrosciatic ligament)  
 Greater sciatic foramen  
 Lesser sciatic foramen

### **Sacro=iliac joint**

Anterior sacro-iliac ligaments  
 Interosseous sacro-iliac ligaments  
 Short posterior sacro-iliac ligament  
 Long posterior sacro-iliac ligament

### **Symphysis of pubic bones**

Superior pubic ligament  
 Arcuate ligament of pubis  
 Interpubic fibrocartilaginous lamina

### **Hip=joint**

Joint-capsule  
 Glenoid lip (O. T. cotyloid ligament)  
 Transverse ligament of acetabulum  
 Round ligament of the femur  
 Orbicular zone (O. T. zonular band or ring ligament)  
 Iliofemoral ligament (O. T. Y-shaped ligament of Bigelow)  
 Ischiocapsular ligament (O. T. ischio-capsular band)  
 Pubocapsular ligament (O. T. pubo-capsular band, or pubofemoral ligament)

### **Knee=joint**

Joint-capsule  
 Lateral meniscus (O. T. external semilunar fibrocartilage)  
 Medial meniscus (O. T. internal semilunar fibrocartilage)  
 Transverse ligament of the knee  
 Crucial ligaments of the knee

Anterior crucial ligament  
 Posterior crucial ligament  
 Patellar synovial fold (O. T. ligamentum mucosum)  
 Alar folds (O. T. ligamentum alaria)  
 Fibular collateral ligament (O. T. long external lateral ligament)  
 Tibial collateral ligament (O. T. internal lateral ligament)  
 Oblique popliteal ligament (O. T. posterior ligament)  
 Arcuate popliteal ligament  
 Retaining band of arcuate ligament  
 Ligament of the patella  
 Medial retaining band of patella  
 Lateral retaining band of patella

### **Tibiofibular joint (O. T. superior tibiofibular articulation)**

Joint-capsule  
 Ligaments of the head of the fibula (O. T. anterior and posterior superior tibiofibular ligaments)  
 Interosseous membrane of leg (O. T. middle tibiofibular ligament)

### **Tibiofibular syndesmosis (O. T. inferior tibiofibular articulation)**

Anterior ligament of lateral malleolus  
 Posterior ligament of lateral malleolus

### **Joints of the foot**

#### **Ankle=joint**

Joint-capsule  
 Deltoid ligament (O. T. internal lateral ligament and anterior and posterior tibiotarsal ligaments)  
 Tibionavicular ligament  
 Calcaneotibial ligament  
 Anterior talotibial ligament  
 Posterior talotibial ligament  
 Anterior talofibular ligament (O. T. anterior fasciculus of external lateral ligament)

Lig. talofibulare posterius

Pars calcaneonavicularis

Lig. calcaneofibulare

Pars calcaneocuboidea

**Articulationes intertarseae****Articulatio talocalcaneonavicularis****Articulatio talocalcanea**

Capsula articularis

Lig. talocalcaneum laterale

Lig. talocalcaneum mediale

Lig. talocalcaneum anterius

Lig. talocalcaneum posterius

**Articulatio tarsi transversa  
[Choparti]****Articulatio talonavicularis**

Capsula articularis

**Articulatio calcaneocuboidea**

Capsula articularis

**Articulatio cuneonavicularis****Ligg. tarsi interossea**

Lig. talocalcaneum interosseum

Lig. cuneocuboideum interosseum

Ligg. intercuneiformia interossea

**Ligg. tarsi dorsalia**

Lig. talonaviculare [dorsale]

Lig. cuneocuboideum dorsale

Lig. cuboideonaviculare dorsale

Lig. bifurcatum

Lig. calcaneonaviculare dorsale

Ligg. navicularicuneiformia dorsalia

**Ligg. tarsi plantaria**

Lig. plantare longum

Ligg. tarsi profunda

Lig. calcaneocuboideum plantare

Lig. calcaneonaviculare plantare

Fibrocartilago navicularis

Ligg. navicularicuneiformia plantaria

Lig. cuboideonaviculare plantare

Ligg. intercuneiformia plantaria

Lig. cuneocuboideum plantare

**Articulationes tarsometatarseae**

Capsulae articulares

Ligg. tarsometatarsea dorsalia

Ligg. tarsometatarsea plantaria

Ligg. cuneometatarsea interossea

**Articulationes intermetatarseae**

Capsulae articulares

Ligg. basium [oss. metatars.] interossea

Ligg. basium [oss. metatars.] dorsalia

Ligg. basium [oss. metatars.] plantaria

Spatia interossea metatarsi

**Articulationes metatarsophalangeae**

Capsulae articulares

Ligg. collateralia

Posterior talofibular ligament (O. T. posterior fasciculus of external lateral ligament)

Calcaneofibular ligament (O. T. middle fasciculus of external lateral ligament)

### Intertarsal joints

#### Talocalcaneonavicular joint

##### Talocalcanean joint

Joint-capsule

Lateral talocalcanean ligament (O. T. external calcaneo-astragaloid ligament)

Medial talocalcanean ligament (O. T. internal calcaneo-astragaloid ligament)

Anterior talocalcanean ligament

Posterior talocalcanean ligament

#### Chopart's transverse articulation of the tarsus

##### Talonavicular joint

Joint-capsule

##### Calcaneocuboid joint

Joint-capsule

##### Cuneonavicular joint

#### Interosseous ligaments of tarsus

Interosseous talocalcanean ligament

Interosseous cuneocuboid ligament

Interosseous intercuneiform ligaments

#### Dorsal ligaments of tarsus

Dorsal talonavicular ligament (O. T. superior astragalonavicular ligament)

Dorsal cuneocuboid ligament

Dorsal cuboideonavicular ligament

Bifurcate ligament

Calcaneonavicular part (O. T. superior or external calcaneonavicular ligament)

Calcaneocuboidal part (O. T. internal calcaneocuboid ligament)

Dorsal calcaneonavicular ligament

Dorsal navicular cuneiform ligaments

#### Plantar ligaments of tarsus

Long plantar ligament (O. T. long calcaneocuboid ligament)

Deep ligaments of tarsus

Plantar calcaneocuboid ligament

Plantar calcaneonavicular ligament (O. T. inferior calcaneonavicular ligament)

Navicular fibrocartilage

Plantar navicular cuneiform ligaments

Plantar cuboideonavicular ligament

Plantar intercuneiform ligaments

Plantar cuneocuboid ligament

#### Tarsometatarsal joints

Joint-capsules

Dorsal tarsometatarsal ligaments

Plantar tarsometatarsal ligaments

Interosseous cuneometatarsal ligaments

#### Intermetatarsal joints

Joint-capsules

Interosseous ligaments of the bases of the metatarsal bones

Dorsal ligaments of the bases of the metatarsal bones

Plantar ligaments of the bases of the metatarsal bones

Interosseous spaces of metatarsus

#### Metatarsophalangeal joints

Joint-capsules

Collateral ligaments

Ligg. accessoria plantaria

Ligg. capitulorum [oss. metatars.]  
transversa

Articulationes digitorum pedis

Capsulae articulares

Ligg. collateralia

## Myologia

Musculus /

Caput /

Venter /

Musculus fusiformis /

Musculus unipennatus /

Musculus bipennatus /

Musculus sphincter /

Musculus orbicularis /

Musculus articularis /

Musculus skeleti } mit

Musculus cutaneus } mit

Tendo

Aponeurosis /

Perimysium /

Fascia /

Fascia superficialis mit

Inscriptio tendinea /

Arcus tendineus /

Ligamentum vaginale /

Vagina fibrosa tendinis /

Vagina mucosa tendinis

Trochlea muscularis /

Bursa mucosa /

### Musculi dorsi

M. trapezius /

(M. transversus nuchae) /

M. latissimus dorsi /

M. rhomboideus major /

M. rhomboideus minor /

M. levator scapulae

M. serratus posterior inferior /

M. serratus posterior superior

M. splenius cervicis /

M. splenius capitis /

M. sacrospinalis /

M. iliocostalis /

M. iliocostalis lumborum /

M. iliocostalis dorsi

M. iliocostalis cervicis

M. longissimus

M. longissimus dorsi

M. longissimus cervicis

M. longissimus capitis

M. spinalis

M. spinalis dorsi

M. spinalis cervicis

M. spinalis capitis

M. semispinalis

M. semispinalis dorsi

M. semispinalis cervicis

M. semispinalis capitis

Plantar accessory ligaments	<b>Joints of the toes</b>
Transverse ligaments of the heads of the metatarsal bones	Joint-capsules Collateral ligaments

## Myology, or Musculature

Muscle	Tendinous expansion
Head	Perimysium, or muscle sheath
Belly	Fascia ("band or swathe"), or fibrous covering
Fusiform muscle	Superficial fascia
Unipennate muscle	Tendinous inscription
Bipennate muscle	Tendinous arch
Sphincter muscle	Sheath ligament
Orbicular muscle	Fibrous sheath of tendon
Joint muscle	Mucous sheath of tendon
Skeletal muscle	Muscle pulley
Skin muscle	Mucous bursa or sac
Tendon	
<b>Muscles of the back</b>	Iliocostal muscle of neck (O. T. cer- vicalis ascendens)
Trapezius muscle	Longest muscle
Transverse muscle of nape	Longest muscle of back
Broadest muscle of back	Longest muscle of neck (O. T. trans- versalis cervicis)
Greater rhomboid muscle	Longest muscle of head (O. T. trachelomastoid)
Lesser rhomboid muscle	Spinal muscle
Levator muscle of scapula (O. T. levator anguli scapulae)	Spinal muscle of back
Inferior posterior serratus muscle	Spinal muscle of neck (O. T. spinalis colli)
Superior posterior serratus muscle	Spinal muscle of head
Splenius ("bandage") muscle of neck (O. T. splenius colli)	Semispinal muscle
Splenius muscle of head	Semispinal muscle of back
Sacrospinal muscle (O. T. erector spinae)	Semispinal muscle of neck (O. T. semispinalis colli)
Iliocostal muscle	Semispinal muscle of head (O. T. complexus)
Iliocostal muscle of loins (O. T. sacrolumbalis)	
Iliocostal muscle of back (O. T. musculus accessorius)	



- M. multifidus
- Mm. rotatores  
 M. rotatores longi  
 M. rotatores breves
- M. interspinales
- Mm. intertransversarii  
 Mm. intertransversarii laterales  
 Mm. intertransversarii mediales  
 Mm. intertransversarii anteriores  
 Mm. intertransversarii posteriores
- M. rectus capitis posterior major
- M. rectus capitis posterior minor
- M. rectus capitis lateralis  
 M. obliquus capitis superior  
 M. obliquus capitis inferior
- Fascia lumbodorsalis  
 Fascia nuchae
- Musculi capitis**
- M. epicraniius
- M. frontalis  
 M. occipitalis  
 M. procerus
- M. nasalis  
 Pars transversa  
 Pars alaris
- M. depressor septi  
 M. orbicularis oculi
- Pars palpebralis  
 Pars orbitalis  
 Pars lacrimalis [Horneri]
- M. auricularis anterior
- M. auricularis superior
- M. auricularis posterior
- M. orbicularis oris  
 M. triangularis
- (M. transversus menti)
- M. risorius  
 M. zygomaticus  
 M. quadratus labii superioris  
 Caput zygomaticum
- Caput infraorbitale
- Caput angulare
- M. quadratus labii inferioris
- M. caninus
- M. buccinator  
 Mm. incisivi labii superioris  
 Mm. incisivi labii inferioris  
 M. mentalis  
 M. masseter  
 M. temporalis  
 M. pterygoideus externus  
 M. pterygoideus internus  
 Galea aponeurotica
- Fascia buccopharyngea  
 Fascia parotideomasseterica  
 Fascia temporalis
- Musculi oss. hyoidei**
- M. digastricus  
 Venter anterior  
 Venter posterior  
 M. stylohyoideus  
 M. mylohyoideus  
 M. geniohyoideus
- Musculi colli**
- Platysma

- |   |   |
|---|---|
| Multifidus ("much divided") muscle<br>(O. T. multifidus spinae) | Posterior auricular muscle (O. T. retrahens auriculam)          |
| Rotator muscles   | Orbicular muscle of the mouth                                   |
| Long rotator muscles  | Triangular muscle (O. T. depressor anguli oris)                 |
| Short rotator muscles   | Transverse muscle of the chin                                   |
| Interspinal muscles   | Muscle of laughing  |
| Intertransverse muscles   | Zygomatic muscle  |
| Lateral intertransverse muscles                                 | Quadrate muscle of upper lip                                    |
| Medial intertransverse muscles                                  | Zygomatic head (O. T. zygomaticus minor)                        |
| Anterior intertransverse muscles                                | Infraorbital head (O. T. levator labii superioris)              |
| Posterior intertransverse muscles                               | Angular head (O. T. levator labii superioris alaeque nasi)      |
| Larger posterior straight muscle of the head                    | Quadrate muscle of lower lip (O. T. depressor labii inferioris) |
| Lesser posterior straight muscle of the head                    | Canine muscle (O. T. levator anguli oris)                       |
| Lateral straight muscle of the head                             | Cheek muscle  |
| Superior oblique muscle of the head                             | Incisive muscles of upper lip                                   |
| Inferior oblique muscle of the head                             | Incisive muscles of lower lip                                   |
| Lumbodorsal fascia  | Chin muscle   |
| Fascia of the nape  | Masseter muscle   |

**Muscles of the head**

- |   |   |
|---|---|
| Epicranius muscle (O. T. occipitofrontalis)                 | Temporal muscle                                   |
| Frontal muscle  | External pterygoid muscle                         |
| Occipital muscle  | Internal pterygoid muscle                         |
| Procerus ("prolonged") muscle (O. T. pyramidalis nasi)      | Aponeurotic helmet (O. T. epicranial aponeurosis) |
| Muscle of the nose  | Buccopharyngeal fascia                            |
| Transverse part   | Parotideomasseteric fascia                        |
| Alar part   | Temporal fascia                                   |
| Depressor muscle of the septum                              |   |
| Orbicular muscle of the eye (O. T. orbicularis palpebrarum) |   |
| Palpebral part  |   |
| Orbital part  |   |
| Lacrimal part (O. T. tensor tarsi or Horner's muscle)       |   |
| Anterior auricular muscle (O. T. attrahens auriculam)       |   |
| Superior auricular muscle (O. T. attolens auriculam)        |   |

**Muscles of the hyoid bone**

- Digastric muscle
  - Anterior belly
  - Posterior belly
- Stylohyoid muscle
- Mylohyoid muscle
- Geniohyoid muscle

**Muscles of the neck**

- Platysma, or flat muscle (O. T. platysma myoides)

- M. sternocleidomastoideus  
 M. sternohyoideus  
 M. omohyoideus  
     Venter superior  
     Venter inferior  
 M. sternothyreoideus  
 M. thyreochoideus  
 (M. levator glandulae thyreoideae)
- M. longus colli  
 M. longus capitis
- M. rectus capitis anterior
- M. scalenus anterior  
 M. scalenus medius  
 M. scalenus posterior  
 (M., scalenus minimus)  
 Fascia colli  
 Fascia praevertebralis
- Musculi Thoracis**
- (M. sternalis)  
 M. pectoralis major  
     Pars claviculæ  
     Pars sternocostalis  
     Pars abdominalis  
 M. pectoralis minor  
 M. subclavius  
 M. serratus anterior
- Mm. levatores costarum  
     Mm. levatores costarum longi  
     Mm. levatores costarum breves  
 Mm. intercostales externi  
 Mm. intercostales interni  
 Mm. subcostales  
 M. transversus thoracis
- Diaphragma  
     Pars lumbalis  
         Crus mediale  
         Crus intermedium
- Crus laterale  
         Pars costalis  
         Pars sternalis  
 Hjatus aorticus  
 Hiatus oesophageus  
 Centrum tendineum  
 Foramen venae cavae  
 Arcus lumbocostalis medialis [Halleri]
- Arcus lumbocostalis lateralis [Halleri]
- Fascia pectoralis  
 Fascia coracoclaviculæ [Scherer]
- Musculi abdominis**
- M. rectus abdominis  
 Falx [aponeurotica] inguinalis
- M. pyramidalis  
 M. obliquus externus abdominis  
 M. obliquus internus abdominis  
 M. cremaster  
 M. transversus abdominis  
 M. quadratus lumborum  
*Annulus umbilicalis*  
 Linea alba  
     Adminiculum lineae albae  
 Inscriptiones tendineae  
 Lig. suspensorium penis s. clitoridis
- Lig. fundiforme penis  
 Vagina m. recti abdominis  
 Linea semicircularis [Douglasi]  
 Lig. inguinale [Poupartii]  
 Lig. lacunare [Gimbernati]  
 Lig. inguinale reflexum [Collesi]
- Annulus inguinalis subcutaneus
- Crus superius  
         Crus inferius  
 Fibrae intercrurales

Sternocleidomastoid muscle  
 Sternohyoid muscle  
 Omohyoid muscle  
   Superior belly  
   Inferior belly  
 Sternothyroid muscle  
 Thyreohyoid muscle  
 Elevating muscle of the thyreoid gland  
 Long muscle of the neck  
 Long muscle of the head (O. T. rectus capitis anticus major)  
 Anterior straight muscle of the head (O. T. rectus capitis anticus minor)  
 Anterior scalene muscle  
 Middle scalene muscle  
 Posterior scalene muscle  
 Smallest scalene muscle  
 Cervical fascia  
 Prevertebral fascia

**Muscles of the chest**

Sternal muscle  
 Greater pectoral muscle  
   Clavicular part  
   Sternocostal part  
   Abdominal part  
 Smaller pectoral muscle  
 Subclavius muscle  
 Anterior serratus muscle (O. T. serratus magnus)  
 Elevators of the ribs  
   Long elevators of the ribs  
   Short elevators of the ribs  
 External intercostal muscles  
 Internal intercostal muscles  
 Subcostal muscles  
 Transverse muscle of thorax (O. T. triangularis sterni)  
 Diaphragm  
   Lumbar part  
     Medial crus  
     Intermediate crus

Lateral crus  
 Costal part  
 Sternal part  
 Aortic opening  
 Oesophageal opening  
 Central tendon  
 Opening of the vena cava  
 Medial lumbocostal arch (O. T. ligamentum arcuatum internum)  
 Lateral lumbocostal arch (O. T. ligamentum arcuatum externum)  
 Pectoral fascia  
 Coracoclavicular fascia

**Muscles of the abdomen**

Straight muscle of the abdomen  
 Inguinal aponeurotic falx (O. T. conjoined tendon)  
 Pyramidal muscle  
 External oblique muscle of abdomen  
 Internal oblique muscle of abdomen  
 Cremasteric muscle  
 Transverse muscle of abdomen  
 Quadratus muscle of the loins  
*Umbilical ring*  
 White line  
   Stay of the white line  
 Tendinous inscriptions  
 Suspensory ligament of the penis or clitoris  
 Sling-like ligament of penis  
 Sheath of the rectus muscle  
 Semicircular fold of Douglas  
 Inguinal ligament of Poupart  
 Lacunar ligament of Gimbernat  
 Reflex ligament of Colles (O. T. triangular fascia of the abdomen)  
 Subcutaneous inguinal ring (O. T. external abdominal ring)  
   Superior pillar  
   Inferior pillar  
 Intercrural fibres (O. T. intercolumnar fibres)



Trigonum lumbale [Petiti]  
 Linea semilunaris [Spigelii]  
 Fascia transversalis

Canalis inguinalis  
 Annulus inguinalis abdominalis

Lig. interfoveolare [Hesselbachi]

Plica epigastrica  
 Fovea inguinalis lateralis  
 Fovea inguinalis medialis  
 Fovea supravesicalis

### Musculi coccygei

M. coccygeus  
 M. sacrococcygeus anterior  
 M. sacrococcygeus posterior

### Musculi extremitatis superioris

M. deltoideus  
 M. supraspinatus  
 M. infraspinatus  
 M. teres minor  
 M. teres major  
 M. subscapularis  
 M. biceps brachii  
 Caput longum  
 Vagina mucosa intertubercularis  
 Caput breve  
 Lacertus fibrosus

M. coracobrachialis  
 M. brachialis

M. triceps brachii  
 Caput longum  
 Caput laterale  
 Caput mediale  
 M. anconaeus  
 (M. epitrochleoanconaeus)  
 M. pronator teres

Caput humerale  
 Caput ulnare  
 M. flexor carpi radialis  
 M. palmaris longus  
 M. flexor carpi ulnaris  
 Caput humerale  
 Caput ulnare  
 M. flexor digitorum sublimis  
 Caput humerale  
 Caput radiale  
 M. flexor digitorum profundus  
 M. flexor pollicis longus  
 M. pronator quadratus  
 M. brachioradialis

M. extensor carpi radialis longus  
 M. extensor carpi radialis brevis  
 M. extensor digitorum communis  
 Juncturae tendinum

M. extensor digiti quinti proprius

M. extensor carpi ulnaris  
 M. supinator

M. abductor pollicis longus

M. extensor pollicis brevis

M. extensor pollicis longus

M. extensor indicis proprius

M. palmaris brevis  
 M. abductor pollicis brevis

M. flexor pollicis brevis

M. opponens pollicis

M. adductor pollicis

M. abductor digiti quinti

M. flexor digiti quinti brevis

M. opponens digiti quinti

Mm. lumbricales





Mm. interossei dorsales		M. gemellus superior
Mm. interossei volares		M. gemellus inferior
Fascia axillaris		M. quadratus femoris
Fascia subscapularis		M. sartorius
Fascia supraspinata		M. quadriceps femoris
Fascia infraspinata		
Fascia brachii		M. rectus femoris
Septum intermusculare [humeri]		M. vastus lateralis
mediale		
		M. vastus intermedius
Septum intermusculare [humeri]		
laterale		M. vastus medialis
Sulcus bicipitalis medialis		M. articularis genu
Sulcus bicipitalis lateralis		
Fascia antibrachii		M. pectineus
Fascia dorsalis manus		M. adductor longus
Lig. carpi dorsale		M. gracilis
		M. adductor brevis
Aponeurosis palmaris		M. adductor magnus
Fasciculi transversi		M. adductor minimus
Lig. carpi transversum		M. obturator externus
		M: biceps femoris
Lig. carpi volare		Caput longum
Chiasma tendinum		Caput breve
Vinculum tendinum		M. semitendinosus
Vaginae mucosae		M. semimembranosus
Ligg. vaginalia digitorum manus		M. tibialis anterior
Ligg. annularia digitorum manus		
Ligg. cruciata digitorum manus		M. extensor digitorum longus
		M. peroneus tertius
		M. extensor hallucis longus
		M. peroneus longus
		M. peroneus brevis
		M. triceps surae
		M. gastrocnemius
		Caput laterale
		Caput mediale
		M. soleus
		Arcus tendineus m. solei
		Tendo calcaneus [Achillis]
<b>Musculi extremitatis inferioris</b>		
M. iliopsoas		
M. iliacus		
M. psoas major		
M. psoas minor		
M. gluteus maximus		
M. gluteus medius		
M. gluteus minimus		
M. tensor fasciae latae		
M. piriformis		
M. obturator internus		

- Dorsal interosseous muscles  
 Palmar interosseous muscles  
 Axillary fascia  
 Subscapular fascia  
 Supraspinous fascia  
 Infraspinous fascia  
 Brachial fascia  
 Medial intermuscular septum of arm  
 (O. T. internal intermuscular septum)  
 Lateral intermuscular septum of arm  
 (O. T. external intermuscular septum)  
 Medial bicipital furrow  
 Lateral bicipital furrow  
 Antibrachial fascia  
 Fascia of back of hand  
 Dorsal ligament of wrist (O. T. posterior annular ligament)  
 Palmar aponeurosis  
     Transverse fibres (O. T. transverse superficial ligament)  
 Transverse carpal ligament (O. T. anterior annular ligament)  
 Palmar carpal ligament  
 Crossing of the tendons  
 Bands of union of the tendons  
 Mucous sheaths  
 Ligaments of the sheaths of the fingers  
 Annular ligaments of the fingers  
 Cruciate ligaments of the fingers
- Muscles of the lower extremity**
- Iliopsoas muscle  
 Iliac muscle  
 Greater psoas muscle  
 Lesser psoas muscle  
 Greatest gluteal muscle  
 Middle gluteal muscle  
 Least gluteal muscle  
 Tensor muscle of broad fascia  
 Piriform muscle  
 Internal obturator muscle  
 Superior twin muscle  
 Inferior twin muscle  
 Quadratus muscle of thigh  
 Sartorius ("tailor") muscle  
 Quadriceps ("four-headed") muscle of thigh  
     Straight muscle of thigh  
     Lateral great muscle (O. T. vastus externus)  
     Intermediate great muscle (O. T. crureus)  
     Medial great muscle (O. T. vastus internus)  
 Articular muscle of knee (O. T. subcrureus)  
 Pectineus muscle  
 Long adductor muscle  
 Slender muscle  
 Short adductor muscle  
 Great adductor muscle  
 Smallest adductor muscle (O. T. upper portion of adductor magnus)  
 External obturator muscle  
 Biceps ("two-headed") muscle of thigh  
     Long head  
     Short head  
 Semitendinosus muscle  
 Semimembranosus muscle  
 Anterior tibial muscle (O. T. tibialis anticus)  
 Long extensor of digits  
 Third peroneal muscle  
 Long extensor of great toe  
 Long peroneal muscle  
 Short peroneal muscle  
 Triceps muscle of calf  
     Gastrocnemius muscle  
         Lateral head  
         Medial head  
     Soleus muscle  
 Tendinous arch of soleus muscle  
 Tendon of the heel (of Achilles) (O. T. tendo Achillis)

M. plantaris	Fossa iliopectinea
M. popliteus	Fascia pectinea
M. tibialis posterior	
	Canalis femoralis
M. flexor digitorum longus	Annulus femoralis
M. flexor hallucis longus	Septum femorale [Cloqueti]
M. extensor hallucis brevis	Fossa ovalis
M. extensor digitorum brevis	Margo falciformis
M. abductor hallucis	Cornu superius
M. flexor hallucis brevis	Cornu inferius
M. adductor hallucis	Fascia cribrosa
Caput obliquum	Fascia cruris
Caput transversum	Septum intermusculare anterius
M. abductor digiti quinti	[fibulare]
M. flexor digiti quinti brevis	
M. opponens digiti quinti	Septum intermusculare posterius
M. flexor digitorum brevis	[fibulare]
M. quadratus plantae	
Mm. lumbricales	Lig. transversum cruris
Mm. interossei dorsales	
Mm. interossei plantares	
Fascia lata	Lig. laciniatum
Tractus iliotibialis [Maissiati]	
Septum intermusculare [femoris]	Lig. cruciatum cruris
laterale	
Septum intermusculare [femoris]	Retinaculum mm. peroneorum sup.
mediale	
	Retinaculum mm. peroneorum inferius
Canalis adductorius [Hunteri]	Fascia dorsalis pedis
	Aponeurosis plantaris
Hiatus tendineus [adductorius]	Fasciculi transversi aponeurosis
Fascia iliaca	plantaris
Fascia iliopectinea	Vaginae mucosae
Lacuna musculorum	Ligg. annularia
Lacuna vasorum	Ligg. vaginalia
Trigonum femorale [Fossa Scarpae major]	Ligg. cruciata



- Plantaris muscle  
 Popliteus muscle  
 Posterior tibial muscle (O. T. tibialis  
   posticus)  
 Long flexor of the digits  
 Long flexor of the great toe  
 Short extensor of the great toe  
 Short extensor of the digits  
 Abductor of the great toe  
 Short flexor of the great toe  
 Adductor of the great toe  
   Oblique head  
   Transverse head  
 Abductor of the fifth toe  
 Short flexor muscle of fifth toe  
 Opposing muscle of fifth toe  
 Short flexor muscle of the toes  
 Quadrate muscle of the sole  
 Lumbrical muscles  
 Dorsal interosseous muscles  
 Plantar interosseous muscles  
 Broad fascia  
 Iliotibial band  
 Lateral intermuscular septum of thigh  
   (O. T. external intermuscular sep-  
   tum)  
 Medial intermuscular septum of thigh  
   (O. T. internal intermuscular sep-  
   tum)  
 Adductor canal of Hunter (O. T. Hun-  
   ter's canal)  
 Tendinous adductor gap  
 Iliac fascia  
 Iliopectineal fascia  
 Muscle gap  
 Vessel gap  
 Femoral triangle (greater fossa of  
   Scarpa) (O. T. Scarpa's triangle)
- Iliopectineal fossa  
 Pectineal fascia (O. T. pubic portion  
   of fascia lata)  
 Femoral canal (O. T. crural canal)  
 Femoral ring (O. T. crural ring)  
 Femoral septum of Cloquet  
 Oval fossa  
   Falciform margin  
     Superior horn  
     Inferior horn  
 Cribriform fascia  
 Fascia of the leg  
 Anterior (fibular) intermuscular sep-  
   tum (O. T. anterior peroneal sep-  
   tum)  
 Posterior (fibular) intermuscular sep-  
   tum (O. T. posterior peroneal sep-  
   tum)  
 Transverse ligament of the leg (O. T.  
   upper or broad part of anterior annu-  
   lar ligament)  
 Fringed ligament (O. T. internal annu-  
   lar ligament)  
 Cruciate ligament of the leg (O. T.  
   lower part of anterior annular liga-  
   ment of leg)  
 Upper retaining band of peroneal  
   muscles  
 Lower retaining band of peroneal  
   muscles  
 Dorsal fascia of the foot  
 Plantar aponeurosis  
   Transverse bundles of plantar apo-  
   neurosis  
 Mucous sheaths  
 Annular ligaments  
 Sheath ligaments  
 Cruciate ligaments



## Bursae et Vaginae mucosae

Bursa mucosa subcutanea  
 Bursa mucosa submuscularis  
 Bursa mucosa subfascialis

Bursa mucosa subtendinea  
 Vagina mucosa tendinis

B. musculi trochlearis  
 B. m. tensoris veli palatini  
 B. subcutanea praementalis  
 B. subcutanea prominentiae laryngeae

Vagina tendinis m. extensoris digiti  
 minimi

Vagina tendinis m. extensoris carpi  
 ulnaris

B. m. extensoris carpi radialis brevis

B. m. sternohyoidei  
 B. m. thyreohyoidei  
 B. subcutanea sacralis  
 B. coccygea  
 B. subcutanea acromialis  
 B. subacromialis  
 B. subdeltoidea

Bursae subcutaneae metacarpophalan-  
 geae dorsales

Bursae subcutaneae digitorum dorsales

B. m. coracobrachialis  
 B. m. infraspinati  
 B. m. subscapularis  
 B. m. teretis majoris  
 B. m. latissimi dorsi  
 B. subcutanea olecrani  
 B. intratendinea olecrani  
 B. subtendinea olecrani

B. m. flexoris carpi ulnaris

B. m. flexoris carpi radialis

Vagina tendinum mm. flexorum com-  
 munium

Vag. tendinis m. flexoris pollicis longi

B. subcutanea epicondyli [humeri]  
 lateralis  
 B. subcutanea epicondyli [humeri]  
 medialis  
 B. bicipitoradialis  
 B. cubitalis interossea

Bursae intermetacarpophalangeae

Vaginae tendinum digitales

B. trochanterica subcutanea

B. trochanterica m. glutaei maximi

Vagina tendinum mm. abductoris  
 longi et extensoris brevis pollicis

B. troch. m. glutaei medii anterior

B. troch. m. glutaei medii posterior

Vagina tendinum mm. extensorum  
 carpi radialis

B. troch. m. glutaei minimi

Vagina tendinis m. extensoris pollicis  
 longi

B. m. piriformis

B. m. obturatorii interni

Vagina tendinum mm. extensoris digi-  
 torum communis et extensoris indicis

Bursae glutaeofemorales

## Bursae and mucous sheaths

- |  |  |
|--|--|
| Subcutaneous mucous bursa  | Subtendinous mucous bursa  |
| Submuscular mucous bursa   | Mucous sheath of tendon  |
| Subfascial mucous bursa  |  |
|  |  |
| Bursa of the trochlear muscle  | of the extensor muscle of the index finger <sup>s</sup>          |
| Bursa of tensor muscle of soft palate  |  |
| Subcutaneous premental bursa   | Sheath of the tendon of the extensor muscle of the little finger |
| Subcutaneous bursa of the prominence of the larynx                                 | Sheath of the tendon of the ulnar extensor muscle of the wrist   |
| Bursa of the sternohyoid muscle  | Bursa of the short radial extensor muscle of the wrist           |
| Bursa of the thyreohyoid muscle  | Dorsal subcutaneous metacarpophalangeal bursa                    |
| Subcutaneous sacral bursa  | Dorsal subcutaneous bursae of the digits                         |
| Coccygeal bursa  | Bursa of the ulnar flexor muscle of the wrist                    |
| Subcutaneous acromial bursa  | Bursa of the radial flexor muscle of the wrist                   |
| Subacromial bursa  | Sheath of the tendons of the common flexor muscles               |
| Subdeltoid bursa   | Sheath of the tendon of the long flexor muscle of the thumb      |
| Bursa of the coracobrachial muscle   | Intermetacarpophalangeal bursae                                  |
| Bursa of the infraspinatus muscle  | Digital sheaths of the tendons                                   |
| Bursa of the subscapular muscle  | Subcutaneous trochanteric bursa                                  |
| Bursa of the greater round muscle  | Trochanteric bursa of the great gluteal muscle                   |
| Bursa of the broadest muscle of back   | Anterior trochanteric bursa of the middle gluteal muscle         |
| Subcutaneous bursa of the olecranon  | Posterior trochanteric bursa of the middle gluteal muscle        |
| Intratendinous bursa of the olecranon  | Trochanteric bursa of the smallest gluteal muscle                |
| Subtendinous bursa of the olecranon  | Bursa of the piriform muscle                                     |
| Subcutaneous bursa of the lateral epicondyle of humerus                            | Bursa of the internal obturator muscle                           |
| Subcutaneous bursa of the medial epicondyle of humerus                             | Glutaeofemoral bursae  |
| Bicipitoradial bursa   |  |
| Interosseous bursa of the elbow  |  |
| Sheath of the tendons of the long abductor and short extensor muscles of the thumb |  |
| Sheath of the tendons of the radial extensor muscles of the wrist                  |  |
| Sheath of the tendon of the long extensor muscle of the thumb                      |  |
| Sheath of the tendons of the common extensor muscle of the digits and              |  |

B. ischiadica m. glutaei maximi	Vag. tendinis m. tibialis anterioris
B. m. recti femoris	Vag. tendinis m. extensoris hallucis longi
B. iliopectinea	Vaginae tendinum m. extensoris digitorum pedis longi
B. iliaca subtendinea	
B. m. pectinei	Vaginae tendinum m. flexoris digitorum pedis longi
B. m. bicipitis femoris superior	
B. praepatellaris subcutanea	Vag. tendinis m. tibialis posterioris
B. praepatellaris subfascialis	
B. praepatellaris subtendinea	Vag. tendinis m. flexoris hallucis longi
B. suprapatellaris	
B. infrapatellaris subcutanea	Vag. tendinum mm. peronaeorum communis
B. infrapatellaris profunda	Bursa sinus tarsi
B. subcutanea tuberositatis tibiae	B. subtendinea m. tibialis anterioris
B. m. sartorii propria	B. subtendinea m. tibialis posterioris
B. anserina	B. subcutanea calcanea
B. m. bicipitis femoris inferior	B. tendinis calcanei [Achillis]
B. m. poplitei	
B. bicipitogastrocnemialis	Vag. tendinis m. peronaei longi plantaris
B. m. gastrocnemii lateralis	Bursae intermetatarsophalangeae
B. m. gastrocnemii medialis	Bursae mm. lumbricalium pedis
B. m. semimembranosi	
B. subcutanea malleoli lateralis	Vaginae tendinum digitales pedis
B. subcutanea malleoli medialis	

Sciatic bursa of the greatest gluteal muscle	Sheath of the tendon of the anterior tibial muscle
Bursa of the straight thigh muscle	Sheath of the tendon of the long extensor muscle of the great toe
Iliopectineal bursa	Sheaths of the tendons of the long extensor muscle of the digits of the foot
Subtendinous iliac bursa	Sheaths of the tendons of the long flexor muscle of the digits of the foot
Bursa of the pectineus muscle	Sheath of the tendon of the posterior tibial muscle
Superior bursa of the biceps muscle of the thigh	Sheath of the tendon of the long flexor muscle of the great toe
Subcutaneous prepatellar bursa	Common sheath of the tendons of the peroneal muscles
Subfascial prepatellar bursa	Bursa of the hollow of the ankle
Subtendinous prepatellar bursa	Subtendinous bursa of the anterior tibial muscle
Suprapatellar bursa	Subtendinous bursa of the posterior tibial muscle
Subcutaneous infrapatellar bursa	Subcutaneous calcanean bursa
Deep infrapatellar bursa	Bursa of the calcanean tendon of Achilles
Subcutaneous bursa of the tuberosity of the tibia	Sheath of the plantar tendon of the long peroneal muscle
Proper bursa of the sartorius muscle	Intermetatarsophalangeal bursae
Anserine bursa	Bursae of the lumbrical muscles of the foot
Inferior bursa of the biceps muscle of the thigh	Digital sheaths of the tendons of the foot
Bursa of the popliteus muscle	
Bicipitogastrocnemial bursa	
Lateral bursa of the gastrocnemius muscle	
Medial bursa of the gastrocnemius muscle	
Bursa of the semimembranosus muscle	
Subcutaneous bursa of the lateral malleolus	
Subcutaneous bursa of the medial malleolus	

## Splanchnologia

Tunica albuginea	Ligamentum serosum
Tunica fibrosa	Serum
Tunica adventitia	Epithelium
Tunica mucosa	Endothelium
Lamina propria mucosae	Organon parenchymatosum
Lamina muscularis mucosae	Parenchyma
Tela submucosa	Stroma
Plica mucosa	Glandula
Mucus	Lobus
Tunica muscularis	Lobulus
Tunica serosa	Glandula mucosa
Tela subserosa	Musculus viscerum
Plica serosa	

---

## Apparatus digestorius

<b>Cavum oris</b>	
Bucca	Frenulum labii inferioris
Corpus adiposum buccae	Gingiva
Vestibulum oris	Caruncula sublingualis
Cavum oris proprium	Plica sublingualis
Rima oris	Plicae palatinae transversae
Labia oris	Papilla incisiva
Labium superius	
Labium inferius	<b>Glandulae oris</b>
Commissura labiorum	Gl. labiales
Angulus oris	Gl. buccales
Palatum	Gl. molares
Palatum durum	Gl. palatinae
Palatum molle	Gl. linguales
Raphe palati	Gl. lingualis anterior [Blandini, Nuhni]
	Gl. sublingualis
<b>Tunica mucosa oris</b>	Ductus sublingualis major
Frenulum labii superioris	Ductus sublinguales minores



## Splanchnology

Albugineous coat	Serous ligament
Fibrous coat	Serum
Adventitious (external) coat	Epithelium
Mucous coat	Endothelium
Proper layer of the mucosa	Parenchymatous organ
Muscular layer of the mucosa	Parenchyma
Submucous web	Stroma
Mucous fold	Gland
Mucus	Lobe
Muscular coat	Little lobe
Serous coat	Mucous gland
Subserous web	Muscle of the viscera
Serous fold	

---

## Digestive apparatus

### Mouth cavity

Cheek  
 Fat body of cheek  
 Entrance to mouth  
 Mouth cavity proper  
 Mouth-slit  
 Lips of mouth  
    Upper lip  
    Lower lip  
 Junction of lips  
 Angle of mouth  
 Palate  
    Hard palate  
    Soft palate  
 Middle ridge of palate

### Mucous membrane of mouth

Check-cord of upper lip

Check-cord of lower lip  
 Gum  
 Sublingual caruncle  
 Sublingual fold  
 Transverse palatine folds  
 Incisor papilla

### Glands of mouth

Labial glands  
 Buccal glands  
 Molar glands  
 Palatine glands  
 Lingual glands  
 Anterior lingual gland (O. T. gland  
 of Nuhn)  
 Sublingual gland  
 Larger sublingual duct  
 Smaller sublingual ducts

Gl. submaxillaris  
 Ductus submaxillaris [Whartoni]

Gl. parotis  
 Processus retromandibularis  
 Gl. parotis accessoria

Ductus parotideus [Stenonis]  
 Saliva

### Dentes

Corona dentis  
 Tubercula [coronae] dentis  
 Collum dentis  
 Radix [Radices] dentis  
 Apex radices dentis  
 Facies masticatoria  
 Facies labialis [buccalis]  
 Facies lingualis  
 Facies contactus  
 Facies medialis } dentium incisivo-  
 Facies lateralis } rum et caninorum  
 Facies anterior } dentium praemola-  
 Facies posterior } rium et molarium  
 Cavum dentis  
 Pulpa dentis  
*Papilla dentis*  
 Canalis radices dentis  
 Foramen apicis dentis  
 Substantia eburnea  
 Substantia adamantina  
 Substantia ossea  
 Canaliculi dentales  
 Spatia interglobularia  
 Prismata adamantina  
 Cuticula dentis  
 Periosteum alveolare  
 Arcus dentalis superior  
 Arcus dentalis inferior  
 Dentes incisivi  
 Dentes canini  
 Dentes praemolares  
 Dentes molares

Dens serotinus  
 Dentes permanentes  
 Dentes decidui

### Lingua

Dorsum linguae  
 Radix linguae  
 Corpus linguae  
 Facies inferior [linguae]  
 Plica fimbriata  
 Margo lateralis [linguae]  
 Apex linguae  
 Tunica mucosa linguae  
 Frenulum linguae  
 Papillae linguales  
 Papillae filiformes  
 Papillae conicae  
 Papillae fungiformes  
 Papillae lenticulares  
 Papillae vallatae  
 Papillae foliatae  
 Sulcus medianus linguae  
 Sulcus terminalis  
 Foramen caecum linguae (Morgagnii)  
 (Ductus lingualis)  
*Ductus thyroglossus*  
 Tonsilla lingualis  
 Folliculi linguales  
 Septum linguae  
 Musculi linguae  
 M. genioglossus  
 M. hyoglossus  
 M. chondroglossus  
 M. styloglossus  
 M. longitudinalis superior  
 M. longitudinalis inferior  
 M. transversus linguae  
 M. verticalis linguae  
 Fauces  
 Isthmus faucium

Submaxillary gland  
 Submaxillary duct (O. T. Wharton's duct)  
 Parotid gland  
   Retromandibular process  
 Accessory parotid (O. T. *socia parotidis*)  
 Parotid duct (O. T. Steno's duct)  
 Mixed mouth secretions

### Teeth

Crown of tooth  
   Tubercles of crown of tooth  
 Neck of tooth  
 Root of tooth  
 Apex of root of tooth  
 Chewing-surface  
 Labial surface  
 Lingual surface  
 Contact surface  
   Medial surface } of incisor  
   Lateral surface } and canine teeth  
   Anterior surface } of premolars  
   Posterior surface } and molars  
 Tooth cavity  
 Tooth pulp  
*Papilla of tooth*  
 Root canal of tooth  
 Foramen of apex of tooth  
 Dentine  
 Enamel  
 Cement  
 Smaller dental canals  
 Granular layer  
 Enamel prisms  
 Cuticle of tooth  
 Alveolar periosteum  
 Superior dental arch  
 Inferior dental arch  
 Incisor teeth  
 Canine teeth  
 Premolar teeth (O. T. *bicuspidis*)  
 Molar teeth

Late tooth (O. T. wisdom tooth)  
 Permanent teeth  
 Deciduous teeth

### Tongue

Dorsum of tongue  
 Root of tongue  
 Body of tongue  
 Inferior surface  
   Fimbriated fold  
 Lateral margin  
 Tip of the tongue  
 Mucous membrane of tongue  
 Frenulum (check-rein) of tongue  
 Lingual papillae  
 Filiform papillae  
 Conical papillae  
 Fungiform papillae  
 Lenticular papillae  
 Vallate papillae (O. T. *circumvallate papillae*)  
 Foliate papillae  
 Median sulcus of tongue  
 Terminal sulcus  
 Blind foramen of tongue  
 Lingual duct  
*Thyreoglossal duct*  
 Lingual tonsil  
   Lingual folliculi  
 Septum of tongue  
 Muscles of tongue  
   Genioglossus muscle  
   Hyoglossus muscle  
   Chondroglossus muscle  
   Styloglossus muscle  
   Superior longitudinal muscle (O. T. superficial lingual)  
   Inferior longitudinal muscle (O. T. inferior lingual)  
   Transverse muscle of tongue  
   Vertical muscle of tongue

### Fauces, or throat

Isthmus of fauces

Velum palatinum  
 Uvula [palatina]  
 Arcus palatini  
 Arcus glossopalatinus

Arcus pharyngopalatinus

Plica salpingopalatina  
 Tonsilla palatina  
 Fossulae tonsillares  
 Sinus tonsillaris  
 Plica triangularis  
 Fossa supratonsillaris

#### Musculi palati et faucium

M. levator veli palatini

M. tensor veli palatini

M. uvulae

M. glossopalatinus

M. pharyngopalatinus

#### Pharynx

Cavum pharyngis  
 Fornix pharyngis  
 Pars nasalis  
 Pars oralis  
 Pars laryngea  
 Ostium pharyngeum tubae  
 Labium anterius  
 Labium posterius  
 Torus tubarius  
 Plica salpingopharyngea  
 Recessus pharyngeus [Rosenmuelleri]

(Bursa pharyngea)

Recessus piriformis

M. stylopharyngeus

Fascia pharyngobasilaris

Tunica mucosa

Gl. pharyngeae  
 Tonsilla pharyngea  
 Fossulae tonsillares  
 Tela submucosa

Tunica muscularis pharyngis  
 Raphe pharyngis  
 Raphe pterygomandibularis  
 M. constrictor pharyngis superior  
 M. pterygopharyngeus  
 M. buccopharyngeus  
 M. mylopharyngeus  
 M. glossopharyngeus  
 M. salpingopharyngeus  
 M. constrictor pharyngis medius  
 M. chondropharyngeus  
 M. ceratopharyngeus  
 M. constrictor pharyngis inferior  
 M. thyreopharyngeus  
 M. cricopharyngeus

#### Tubus digestorius

##### Oesophagus

Pars cervicalis  
 Pars thoracalis  
 Pars abdominalis  
 Tunica adventitia  
 Tunica muscularis  
 M. bronchooesophageus  
 M. pleurooesophageus  
 Tela submucosa  
 Tunica mucosa  
 Lam. muscularis mucosae  
 Gl. oesophageae

##### Ventriculus

[Gaster]

Paries anterior  
 Paries posterior  
 Curvatura ventriculi major  
 Curvatura ventriculi minor  
 Cardia  
 Fundus ventriculi

Palatine curtain  
 Uvula  
 Palatine arches  
   Glossopalatine arch (O. T. anterior  
   pillar of fauces)  
   Pharyngopalatine arch (O. T. pos-  
   terior pillar of fauces)  
 Tubopalatine fold  
 Palatine tonsil  
   Tonsillar crypts  
 Tonsillar sinus  
 Triangular fold  
 Supratonsillar fossa

### Muscles of palate and fauces

Levator muscle of palatine curtain (O.  
 T. levator palati)  
 Tensor muscle of palatine curtain (O.  
 T. tensor palati)  
 Muscle of uvula (O. T. azygos uvulae)  
 Glossopalatine muscle (O. T. palato-  
 glossus)  
 Pharyngopalatine muscle (O. T. pal-  
 atopharyngeus)

### Pharynx

Cavity of pharynx  
 Vault of pharynx  
 Nasal part (O. T. nasopharynx)  
 Oral part (O. T. oral pharynx)  
 Laryngeal part (O. T. laryngopharynx)  
 Pharyngeal opening of Eustachian tube  
   Anterior lip  
   Posterior lip  
   Tubal projection  
 Salpingopharyngeal fold  
 Pharyngeal recess of Rosenmueller (O.  
 T. recessus infundibuliformis)  
 Pharyngeal bursa  
 Piriform recess (O. T. sinus piriformis)  
 Stylopharyngeus muscle  
 Pharyngobasilar fascia  
 Mucous membrane

Pharyngeal glands  
 Pharyngeal tonsil  
 Tonsillar crypts  
 Submucous web (O. T. pharyngeal  
 aponeurosis)  
 Muscular coat of pharynx  
 Raphe of pharynx  
 Pterygomandibular raphe  
 Superior constrictor muscle of pharynx  
   Pterygopharyngeal muscle  
   Buccopharyngeal muscle  
   Mylopharyngeal muscle  
   Glossopharyngeal muscle  
 Salpingopharyngeal muscle  
 Middle constrictor muscle of pharynx  
   Chondropharyngeal muscle  
   Ceratopharyngeal muscle  
 Inferior constrictor muscle of pharynx  
   Thyreopharyngeal muscle  
   Cricopharyngeal muscle

### Digestive tube

#### Oesophagus

Cervical part  
 Thoracic part  
 Abdominal part  
 Adventitious coat  
 Muscular coat  
 Broncho-oesophageal muscle  
 Pleuro-oesophageal muscle  
 Submucous layer  
 Mucous membrane  
   Muscular layer of mucosa  
 Oesophageal glands

#### Stomach

Anterior wall  
 Posterior wall  
 Greater curvature of stomach  
 Lesser curvature of stomach  
 Cardia  
 Fundus of stomach



- Corpus ventriculi  
 Pylorus  
 Pars cardiaca  
 Pars pylorica  
 (Antrum cardiacum)  
 Antrum pyloricum  
 Tunica serosa  
 Tunica muscularis  
   Stratum longitudinale  
   Ligg. pylori  
   Stratum circulare  
   M. sphincter pylori  
   Fibrae obliquae  
 Valvula pylori  
 Tela submucosa  
 Tunica mucosa  
   Lam. muscularis mucosae  
 Areae gastricae  
 Plicae villosae  
 Foveolae gastricae  
 Glandulae gastricae [propriae]  
 Glandulae pyloricae  
 Noduli lymphatici gastrici  
 Succus gastricus
- Intestinum tenue**
- Tunica serosa  
 Tunica muscularis  
   Stratum longitudinale  
   Stratum circulare  
 Tela submucosa  
 Tunica mucosa  
   Lam. muscularis mucosae  
 Plicae circulares [Kerkringi]
- Villi intestinales  
 Gl. intestinales [Lieberkuehni]
- Noduli lymphatici solitarii  
 Noduli lymphatici aggregati [Peyeri]
- Chymus  
 Chylus
- Succus entericus  
 D u o d e n u m  
 Pars superior  
 Pars descendens  
 Pars inferior  
   Pars horizontalis [inferior]  
   Pars ascendens  
 Flexura duodeni superior  
 Flexura duodeni inferior  
 Flexura duodenojejunalis  
 M. suspensorius duodeni
- Plica longitudinalis duodeni  
 Papilla duodeni [Santorini]  
 Gl. duodenales [Brunneri]  
 Intestinum tenue mesen-  
   t e r i a l e  
 Intestinum jejunum  
 Intestinum ileum
- Intestinum crassum**
- Intestinum caecum  
 Valvula coli
- Labium superius  
   Labium inferius  
   Frenula valvulae coli  
 Processus vermiformis
- (Valvula processus vermiformis)
- Noduli aggregati processus vermifor-  
   m i s  
 C o l o n  
 Colon ascendens  
 Flexura coli dextra  
 Colon transversum  
 Flexura coli sinistra  
 Colon descendens  
 Colon sigmoideum  
 Plicae semilunares coli  
 Haustra coli  
 Tunica serosa  
 Appendices epiploicae

- Body of stomach  
 Pylorus  
 Cardiac part  
 Pyloric part  
 Cardiac antrum  
 Pyloric antrum  
 Serous coat  
 Muscular coat  
   Longitudinal layer  
   Pyloric ligaments  
   Circular layer  
   Sphincter muscle of pylorus  
   Oblique fibres  
 Pyloric valve  
 Submucous layer  
 Mucous membrane  
   Muscular layer of mucosa  
 Gastric areas  
 Folds of villi  
 Gastric pits  
 Gastric glands proper  
 Pyloric glands  
 Gastric lymph-nodules  
 Gastric juice
- Small or thin intestine**
- Serous coat  
 Muscular coat  
   Longitudinal layer  
   Circular layer  
 Submucous coat  
 Mucous coat  
   Muscular layer of mucosa  
 Circular folds (O. T. valvulae con-  
   nivalentes)  
 Intestinal villi  
 Intestinal glands (O. T. crypts of  
   Lieberkuehn)  
 Solitary lymph-nodules  
 Aggregated lymph-nodules of Peyer  
   (O. T. Peyer's patches)  
 Chyme  
 Chyle
- Intestinal juice  
 Duodenum  
   Superior part  
   Descending part  
   Inferior part  
     Horizontal part  
     Ascending part  
   Superior duodenal flexure  
   Inferior duodenal flexure  
   Duodenojejunal flexure  
   Suspensory muscle of duodenum (O.  
   T. muscle of Treitz)  
   Longitudinal fold of duodenum  
   Duodenal papilla  
   Duodenal glands of Brunner  
 Mesenterial small intestine  
  
 Empty intestine (O. T. jejunum)  
 Twisted intestine (O. T. ileum)
- Large or thick intestine**
- Blind intestine  
 Valve of the colon (O. T. ileocaecal  
   valve)  
   Superior lip  
   Inferior lip  
   Frenula of valve of colon  
 Vermiform process, or ap-  
   pendix  
 Valve of the vermiform process  
 Aggregated nodules of the vermiform  
   process  
 Colon, or great gut  
   Ascending colon  
   Right colic flexure  
   Transverse colon  
   Left colic flexure  
   Descending colon  
   Sigmoid colon  
   Semilunar folds of colon  
   Sacculations of colon  
   Serous coat  
   Epiploic (fatty) appendages

Tunica muscularis  
 Taeniae coli  
   Taenia mesocolica  
   Taenia omentalis  
   Taenia libera  
 Tela submucosa  
 Tunica mucosa  
   Lam. muscularis mucosae  
 Gl. intestinales [Lieberkuehni]  
 Noduli lymphatici solitarii

### Intestinum rectum

Flexura sacralis  
 Flexura perinealis  
 Ampulla recti  
 Tunica muscularis  
 M. sphincter ani internus  
 M. rectococcygeus  
 Tela submucosa  
 Tunica mucosa  
   Lam. m. mucosae  
   Gl. intestinales [Lieberkuehni]  
 Noduli lymphatici  
 Plicae transversales recti  
  
 Pars analis recti  
 Columnae rectales [Morgagnii]  
 Sinus rectales  
 Annulus haemorrhoidalis

### Pancreas

Caput pancreatis  
 Processus uncinatus [Pancreas Winslowi]  
 Incisura pancreatis  
 Corpus pancreatis  
   Facies anterior  
   Facies posterior  
   Facies inferior  
   Margo superior  
   Margo anterior  
   Margo posterior  
 Tuber omentale

Cauda pancreatis  
 Ductus pancreaticus [Wirsungi]  
 Ductus pancreaticus accessorius [Santorini]  
 (Pancreas accessorium)  
 Succus pancreaticus

### Hepar

Facies superior  
 Facies posterior  
 Facies inferior  
 Margo anterior  
 Incisura umbilicalis  
 Fossae sagittales dextrae  
   Fossa vesicae felleae  
   Fossa venae caevae  
 Fossa sagittalis sinistra  
   Fossa venae umbilicalis  
   Fossa ductus venosi  
 Tunica serosa  
 Lig. teres hepatis  
 Lig. venosum [Arantii]  
 Porta hepatis  
 Lobus hepatis dexter  
 Lobus quadratus  
 Lobus caudatus [Spigelii]  
   Processus papillaris  
   Processus caudatus  
 Lobus hepatis sinister  
 (Appendix fibrosus hepatis)  
 Impressio cardiaca  
 Tuber omentale  
 Impressio oesophagea  
 Impressio gastrica  
 Impressio duodenalis  
 Impressio colica  
 Impressio renalis  
 Impressio suprarenalis  
 Lobuli hepatis  
 Capsula fibrosa [Glissoni]  
 Rami arteriosi interlobulares  
 Venae interlobulares  
 Venae centrales

Muscular coat  
 Bands of the colon  
   Mesocolic band  
   Omental band  
   Free band  
 Submucous coat  
 Mucous coat  
   Muscular layer of mucosa  
 Intestinal glands of Lieberkuehn  
 Solitary lymph-nodules

**Rectum, or straight gut**

Sacral flexure  
 Perineal flexure  
 Ampulla of rectum  
 Muscular layer  
 Internal sphincter muscle of anus  
 Rectococcygeus muscle  
 Submucous coat  
 Mucous membrane  
   Muscular layer of mucosa  
   Intestinal glands of Lieberkuehn  
 Lymphatic nodules  
 Transverse folds of rectum (O. T.  
   valves of Houston)  
 Anal part of rectum  
 Rectal columns of Morgagni  
 Rectal sinuses  
 Hemorrhoidal ring

### Pancreas

Head of pancreas  
 Uncinate process

Notch of pancreas  
 Body of pancreas  
   Anterior surface  
   Posterior surface  
   Inferior surface  
   Superior margin  
   Anterior margin  
   Posterior margin  
 Omental tuber

Tail of pancreas  
 Pancreatic duct of Wirsung  
 Accessory pancreatic duct of Santorini

Accessory pancreas  
 Pancreatic juice

### Liver

Superior surface  
 Posterior surface  
 Inferior surface  
 Anterior margin  
 Umbilical notch  
 Right sagittal fossae  
   Fossa for gall-bladder  
   Fossa for vena cava  
 Left sagittal fossa  
   Fossa for umbilical vein  
   Fossa for venous duct  
 Serous coat  
 Round ligament of liver  
 Venous ligament of Arantius  
 Porta, or door of liver  
 Right lobe of liver  
 Quadrate lobe  
 Caudate lobe of Spigelius  
   Papillary process  
   Caudate process  
 Left lobe of liver  
 Fibrous appendix of liver  
 Cardiac impression  
 Omental tuber  
 Oesophageal impression  
 Gastric impression  
 Duodenal impression  
 Colic impression  
 Renal impression  
 Suprarenal impression  
 Lobules of liver  
 Fibrous capsule of Glisson  
 Interlobular arteries  
 Interlobular veins  
 Central veins

Ductus biliferi  
 Ductus interlobulares  
 Ductus hepaticus  
 Vasa aberrantia hepatis  
 Fel [Bilis]  
 Vesica fellea  
 Fundus vesicae felleae  
 Corpus vesicae felleae  
 Collum vesicae felleae  
 Ductus cysticus  
 Tunica serosa vesicae felleae  
 Tunica muscularis vesicae felleae  
 Tunica mucosa vesicae felleae  
 Plicae tun. mucosae v. felleae  
 Valvula spiralis [Heisteri]  
 Ductus choledochus  
 Gl. mucosae biliosae

**Lien**

Facies diaphragmatica  
 Facies renalis  
 Facies gastrica  
 Extremitas superior  
 Extremitas inferior  
 Margo posterior  
 Margo anterior  
 Hilus lienis  
 Tunica serosa  
 Tunica albuginea  
 Trabeculae lienis  
 Pulpa lienis  
 Rami lienales [arteriae lienalis]  
 Penicilli  
 Noduli lymphatici lienales [Malpighii]

(Lien accessorius)

---

**Apparatus respiratorius**
**Cavum nasi**

Nares  
 Choanae  
 Septum nasi  
 Septum cartilagineum  
 Septum membranaceum  
 Vestibulum nasi  
 Limen nasi  
 Sulcus olfactorius  
 (Concha nasalis suprema [Santorini])  
 Concha nasalis superior  
 Concha nasalis media  
 Concha nasalis inferior  
 Membrana mucosa nasi  
 Plexus cavernosi concharum  
 Agger nasi  
 Recessus spenoethmoidalis

**Meatus nasi**

Meatus nasi superior  
 Meatus nasi medius  
 Atrium meatus medii  
 Meatus nasi inferior  
 Meatus nasi communis  
 Meatus nasopharyngeus  
 Regio respiratoria  
 Regio olfactoria  
 Gl. olfactoriae  
 Sinus paranasales  
 Sinus maxillaris [Highmori]  
 Sinus sphenoidalis  
 Sinus frontalis  
 Cellulae ethmoidales  
 Bulla ethmoidalis  
 Infundibulum ethmoidale  
 Hiatus semilunaris  
 Gl. nasales



Bile-ducts (O. T. bile canaliculi)

Interlobular ducts

Hepatic duct

Aberrant vessels of liver

Bile

G a l l b l a d d e r

Fundus of gall bladder

Body of gall bladder

Neck of gall bladder

Cystic duct

Serous coat of gall bladder

Muscular coat of gall bladder

Mucous coat of gall bladder

Folds of mucous coat of gall bladder

Spiral valve of Heister

Common bile duct

Glands of biliary mucosa

## Spleen

Diaphragmatic surface

Renal surface

Gastric surface

Superior extremity

Inferior extremity

Posterior margin

Anterior margin

Hilus of the spleen

Serous coat

Albugineous coat

Trabeculae ("cords") of spleen

Spleen pulp

Splenic rami of splenic artery

Arterial tufts

Splenic lymph-nodules (O. T. Malpighian corpuscles)

Accessory spleen

---

## Respiratory system

### Nasal cavity

Anterior apertures

Posterior apertures

Nasal septum

Cartilaginous septum

Membranous septum

Vestibule of nose

Threshold of nose

Olfactory sulcus

Highest nasal concha (O. T. uppermost turbinated bone)

Superior nasal concha (O. T. superior turbinated bone)

Middle nasal concha (O. T. middle turbinated bone)

Inferior nasal concha (O. T. inferior turbinated bone)

Mucous membrane of nose

Cavernous layer of conchae

Agger ("elevation") of nose

Spheno-ethmoidal recess

Meatuses of the nose

Superior meatus

Middle meatus

"Entrance-hall" of middle meatus

Inferior meatus

Common meatus

Nasopharyngeal meatus

Respiratory region

Olfactory region

Olfactory glands

Sinuses near nose

Maxillary sinus (O. T. antrum of Highmore)

Sphenoidal sinus

Frontal sinus

Ethmoidal cells

Ethmoidal bulla ("bubble")

Ethmoidal infundibulum ("funnel")

Semilunar opening

Nasal glands

**Nasus externus**

Basis nasi  
 Radix nasi  
 Dorsum nasi  
 Margo nasi  
 Apex nasi  
 Ala nasi  
 Septum mobile nasi  
**Cartilagine s nasi**  
 Cartilago septi nasi  
   Processus sphenoidalis septi cartilaginei  
 Cartilago nasi lateralis  
 Cartilago alaris major  
   Crus mediale  
   Crus laterale  
 Cartilagine alares minores  
 Cartilagine sesamoideae nasi  
 Organon vomeronasale [Jacobsoni]  
 Cartilago vomeronasalis [Jacobsoni]  
 (Ductus incisivus)

**Larynx**

Prominentia laryngea  
  
**Cartilagine laryngis**  
 Cartilago thyreoidea  
   Lamina [dextra et sinistra]  
   Incisura thyreoidea superior  
   Incisura thyreoidea inferior  
   Tuberculum thyreoideum superius  
   Tuberculum thyreoideum inferius  
   (Linea obliqua)  
   Cornu superius  
   Cornu inferius  
   (Foramen thyreoideum)  
 Lig. hyothyreoideum laterale  
 Cartilago triticea  
 Lig. hyothyreoideum medium  
 Membrana hyothyreoidea  
  
 Cartilago cricoidea  
   Arcus [cartilaginis cricoideae]

Lamina [cartilaginis cricoideae]  
 Facies articularis arytaenoidea  
 Facies articularis thyreoidea  
 Articulatio cricothyreoidea  
 Capsula articularis cricothyreoidea  
 Ligg. ceratocricoidea lateralia  
 Lig. ceratocricoideum anterius  
 Ligg. ceratocricoidea posteriora  
 Lig. cricothyreoideum [medium]  
  
 Lig. cricotracheale  
 Cartilago arytaenoidea  
   Facies articularis  
   Basis [cartilaginis arytaenoideae]  
   Crista arcuata  
   Colliculus  
   Fovea oblonga  
   Fovea triangularis  
   Apex [cartilaginis arytaenoideae]  
   Processus vocalis  
   Processus muscularis  
 Cartilago corniculata [Santorini]  
  
 Synchondrosis arycorniculata  
 Articulatio cricoarytaenoidea  
 Lig. cricopharyngeum  
 Lig. corniculopharyngeum  
  
 Lig. ventriculare  
  
 Lig. vocale  
  
 (Cartilago sesamoidea)  
 Capsula articularis cricoarytaenoidea  
 Lig. cricoarytaenoideum posterius  
 Epiglottis  
   Petiolus epiglottidis  
   Tuberculum epiglotticum  
  
 Cartilago epiglottica  
 Lig. thyreoepiglotticum

**External nose**

Base of nose  
 Root of nose  
 Dorsum of nose  
 Margin of nose  
 Tip of nose  
 Wing of nose  
 Movable septum of nose  
 Nasal cartilages  
 Cartilage of nasal septum  
   Sphenoidal process of cartilaginous  
   septum  
 Lateral nasal cartilage  
 Greater alar cartilage  
   Medial crus  
   Lateral crus  
 Lesser alar cartilages  
 Sesamoid cartilages of nose  
 Vomer nasal organ of Jacobson  
 Vomer nasal cartilage of Jacobson  
 Incisor canaliculus

**Larynx**

Laryngeal prominence (O. T. Adam's  
 apple, or pomum Adami)  
 Laryngeal cartilages  
 Thyroid cartilage  
   Right and left plates  
   Superior thyroid notch  
   Inferior thyroid notch  
   Superior thyroid tubercle  
   Inferior thyroid tubercle  
   Oblique line  
   Superior horn  
   Inferior horn  
   Thyroid foramen  
 Lateral hyothyroid ligament  
 Triticeous ("wheat-like") cartilage  
 Middle hyothyroid ligament  
 Hyothyroid membrane (O. T. thyro-  
 hyoid membrane)  
 Cricoid cartilage  
   Arch of cricoid cartilage

Lamina of cricoid cartilage  
 Arytaenoid articular surface  
 Thyroid articular surface  
 Cricothyroid articulation  
 Capsule of cricothyroid joint  
 Lateral ceratocricoid ligaments  
 Anterior ceratocricoid ligaments  
 Posterior ceratocricoid ligaments  
 Middle cricothyroid ligament (O. T.  
 middle portion of cricothyroid mem-  
 brane)  
 Cricotracheal ligament  
 Arytaenoid cartilage  
   Articular surface  
   Base of arytaenoid cartilage  
   Arched ridge  
   Nodule or hillock  
   Oblong depression  
   Triangular depression  
   Tip or apex of arytaenoid cartilage  
   Vocal process  
   Muscular process  
 Corniculate cartilage (O. T. cartilage  
 of Santorini)  
 Arycorniculate synchondrosis  
 Cricoarytaenoid joint  
 Cricopharyngeal ligament  
 Corniculopharyngeal ligament (O. T.  
 Lig. jugale)  
 Ventricular ligament (O. T. superior  
 thyro-arytenoid ligament)  
 Vocal ligament (O. T. inferior thyro-  
 arytenoid ligament)  
   Sesamoid cartilage  
 Capsule of crico-arytaenoid joint  
 Posterior crico-arytaenoid ligament  
 Epiglottis  
   Stem of epiglottis  
   Epiglottic tubercle (O. T. cushion of  
   epiglottis)  
   Epiglottic cartilage  
 Thyreo-epiglottic ligament (O. T.  
 thyro-epiglottidean ligament)

Lig. hyoepiglotticum

Cartilago cuneiformis [Wrisbergi]

Tuberculum cuneiforme [Wrisbergi]

Tuberculum corniculatum [Santorini]

**Musculi laryngis**

M. aryepiglotticus

M. cricothyreoideus

Pars recta

Pars obliqua

M. cricoarytaenoideus posterior  
(M. ceratocricoideus)

M. cricoarytaenoideus lateralis

M. ventricularis

M. vocalis

M. thyreoepiglotticus

M. thyreoarytaenoideus [externus]

M. arytaenoideus obliquus

M. arytaenoideus transversus

**Cavum laryngis**

Vallecula epiglottica

Aditus laryngis

Vestibulum laryngis

Rima vestibuli

Labium vocale

Glottis

Rima glottidis

Pars intermembranacea

Pars intercartilaginea

Ventriculus laryngis [Morgagnii]

Appendix ventriculi laryngis

Tunica mucosa laryngis

Membrana elastica laryngis

Conus elasticus

Plica glossoepiglottica mediana

Plica glossoepiglottica lateralis

Plica aryepiglottica

Plica nervi laryngei

Plica ventricularis

Plica vocalis

Macula flava

Aditus glottidis inferior

Aditus glottidis superior

Incisura interarytaenoidea

Gl. laryngeae

Gl. laryngeae anteriores

Gl. laryngeae mediae

Gl. laryngeae posteriores

Noduli lymphatici laryngei

**Trachea et bronchi**

Cartilagineae tracheales

Ligg. annularia [trachealia]

Paries membranacea

Gl. tracheales

Bifurcatio tracheae

Bronchus [dexter et sinister]

Rami bronchiales

Ramus bronchialis eparterialis

Rami bronchiales hyparteriales

Tunica muscularis

Tela submucosa

Tunica mucosa

Gl. tracheales

Gl. bronchiales

**Pulmo**

Basis pulmonis

Apex pulmonis

Sulcus subclavius

Hyo-epiglottic ligament (O. T. hyo-epiglottidean ligament)  
 Cuneiform cartilage  
 Cuneiform tubercle  
 Corniculate tubercle of Santorini

**Muscles of larynx**

Aryepiglottic muscle (O. T. aryteno-epiglottidean muscle)  
 Cricothyroid muscle  
     Straight part (O.T. anterior or oblique part)  
     Oblique part (O. T. posterior or horizontal part)  
 Posterior crico-arytaenoid muscle  
 Ceratocricoid muscle  
 Lateral crico-arytaenoid muscle  
 Ventricular muscle  
 Vocal muscle (O. T. internal thyro-arytenoid muscle)  
 Thyreo-epiglottic muscle (O. T. thyro-epiglottidean muscle)  
 Thyreo-arytaenoid muscle (external)  
 Oblique arytaenoid muscle  
 Transverse arytaenoid muscle

**Cavity of larynx**

Epiglottic vallecula  
 Laryngeal aperture  
 Vestibule of larynx  
 Slit of vestibule (O. T. false glottis)  
 Vocal lip  
 Glottis (O. T. glottis vera)  
 Slit of glottis  
     Intermembranous part (O. T. glottis vocalis)  
     Intercartilaginous part (O. T. glottis respiratoria)  
 Ventricle of larynx (O. T. laryngeal sinus)  
     Appendage of ventricle of larynx (O. T. laryngeal pouch or sac)  
 Mucous coat of larynx

Elastic membrane of larynx  
     Elastic cone (O. T. cricothyroid membrane)  
 Median glosso-epiglottic fold (O. T. middle glosso-epiglottidean fold, or fraenum of the epiglottis)  
 Lateral glosso-epiglottic fold (O. T. lateral glosso-epiglottidean folds)  
 Ary-epiglottic fold  
 Fold of laryngeal nerve  
 Ventricular fold (O. T. false vocal cord)  
 Vocal fold (O. T. true vocal cord)  
 Yellow spot  
 Inferior entrance to glottis  
 Superior entrance to glottis  
 Interarytaenoid notch  
 Laryngeal glands  
     Anterior laryngeal glands  
     Middle laryngeal glands  
     Posterior laryngeal glands  
 Lymph-nodules of larynx

**Trachea and bronchi**

Tracheal cartilages  
 Annular ligaments  
 Membranous wall  
 Tracheal glands  
 Bifurcation of trachea  
 Right and left bronchus  
 Bronchial rami  
     Eparterial bronchial ramus  
     Hyparterial bronchial ramus  
 Muscular coat  
 Submucous layer  
 Mucous coat  
     Tracheal glands  
     Bronchial glands

**Lung**

Base of lung  
 Apex of lung  
 Subclavian sulcus



Facies costalis  
 Facies mediastinalis  
 Facies diaphragmatica  
 Margo anterior  
 Margo inferior  
 Hilus pulmonis  
 Radix pulmonis  
 Incisura cardiaca  
 Lingula pulmonis  
 Lobus superior  
 Lobus medius  
 Lobus inferior  
 Incisura interlobaris  
 Lobuli pulmonum  
 Rami bronchiales  
 Bronchioli  
 Bronchioli respiratorii  
 Ductuli alveolares  
 Alveoli pulmonum  
 Lymphoglandulae bronchiales  
 Noduli lymphatici bronchiales  
 Lymphoglandulae pulmonales

### **Cavum thoracis**

Fascia endothoracica  
 Cavum pleurae  
 Pleura  
 Cupula pleurae  
 Pleura pulmonalis  
 Pleura parietalis

Pleura mediastinalis  
 Laminae mediastinales  
 Pleura pericardiaca  
 Pleura costalis  
 Pleura diaphragmatica  
 Sinus pleurae  
 Sinus phrenicocostalis  
 Sinus costomediastinalis  
 Lig. pulmonale  
 Plicae adiposae  
 Villi pleurales  
 Septum mediastinale  
 Cavum mediastinale anterius  
 Cavum mediastinale posterius

### **Gl. thyreoidea.**

Isthmus gl. thyreoideae  
 (Lobus pyramidalis)  
 Lobus [dexter et sinister]  
 Lobuli gl. thyreoideae  
 Stroma gl. thyreoideae  
 (Gl. thyreoideae accessoriae)  
 (Gl. thyreoidea accessoria supra-  
 hyoidea)

### **Glomus caroticum**

#### **Thymus**

Lobus [dexter et sinister]  
 Tractus centralis  
 Lobuli thymi

---

## **Apparatus urogenitalis**

### **Organa uropoëtica**

#### **Ren**

Margo lateralis  
 Margo medialis  
 Hilus renalis  
 Sinus renalis  
 Facies anterior  
 Facies posterior  
 Extremitas superior

Extremitas inferior  
 (Impressio muscularis)  
 (Impressio hepatica)  
 (Impressio gastrica)  
 Capsula adiposa  
 Tunica fibrosa  
 Tunica muscularis  
 Tubuli renales  
 Tubuli renales contorti

Costal surface  
 Mediastinal surface  
 Diaphragmatic surface  
 Anterior margin  
 Inferior margin  
 Hilus of lung  
 Root of lung  
 Cardiac notch  
 Lingula, or little tongue, of lung  
 Upper lobe  
 Middle lobe  
 Inferior lobe  
 Interlobar incisure  
 Pulmonary lobules  
 Bronchial rami  
 Bronchioles  
 Respiratory bronchioles  
 Alveolar ductules  
 Pulmonary alveoli  
 Bronchial lymph glands  
 Bronchial lymph-nodules  
 Pulmonary lymph glands

### Thoracic cavity

Endothoracic fascia  
 Pleural cavity  
 Pleura  
   Dome or cupola of pleura  
   Pulmonary pleura  
   Parietal pleura

Mediastinal pleura  
   Mediastinal layers  
   Pericardiac pleura  
 Costal pleura  
 Diaphragmatic pleura  
 Sinuses of the pleura  
   Phrenicocostal sinus  
   Costomediastinal sinus  
 Pulmonary ligament  
 Adipose folds  
 Pleural villi  
 Mediastinal septum  
   Anterior mediastinal cavity  
   Posterior mediastinal cavity

### Thyroid gland

Isthmus of thyreoid  
 Pyramidal lobe  
 Right and left lobes  
 Lobules of gland  
 Stroma of gland  
 Accessory thyreoid glands  
   Suprahyoid accessory thyreoid gland

### Carotid skein (O. T. intercarotid gland)

#### Thymus

Right and left lobe  
 Central tract  
 Lobules of thymus

---

## Urogenital system

### Uropoietic organs

#### Kidney

Lateral margin  
 Medial margin  
   Renal hilus  
   Renal sinus  
 Anterior surface  
 Posterior surface  
 Superior extremity

Inferior extremity  
 Muscular impression  
 Hepatic impression  
 Gastric impression  
 Adipose capsule  
 Fibrous coat  
 Muscular coat  
 Renal tubules  
   Convoluted renal tubules

Tubuli renales recti  
 Substantia corticalis  
 Substantia medullaris  
 Lobi renales  
 Pyramides renales [Malpighii]  
 Basis pyramidis  
 Papillae renales  
 Area cribrosa  
 Foramina papillaria  
 Columnae renales [Bertini]  
 Lobuli corticales  
 Pars radiata [Processus Ferreini]

Pars convoluta  
 Corpuscula renis [Malpighii]

Glomeruli  
 Capsula glomeruli *Bunne*  
 Pelvis renalis  
 Calyces renales  
 Calyces renales majores  
 Calyces renales minores  
 Gl. pelvis renalis

#### Arteriae renis

Aa. interlobares renis  
 Arteriae arciformes  
 Arteriae interlobulares  
 Vas afferens  
 Vas efferens  
 Rami capsulares  
 Arteriolae rectae  
 Aa. nutriciae pelvis renalis

#### Venae renis

Vv. interlobares  
 Venae arciformes  
 Venae interlobulares  
 Venulae rectae  
 Venae stellatae

#### Ureter

Pars abdominalis

Pars pelvina  
 Tunica adventitia  
 Tunica muscularis  
 Stratum externum  
 Stratum medium  
 Stratum internum  
 Tunica mucosa  
 Gl. mucosae ureteris

#### Vesica urinaria

Vertex vesicae  
 Corpus vesicae  
 Fundus vesicae  
 Lig. umbilicale medium  
*Urachus*  
 Tunica serosa  
 Tunica muscularis  
 Stratum externum  
 Stratum medium  
 Stratum internum  
 M. pubovesicalis  
 M. rectovesicalis  
 Tela submucosa  
 Tunica mucosa  
 Gl. vesicales  
 Noduli lymphatici vesicales  
 Trigonum vesicae [Lieutaudi]  
 Uvula vesicae  
 Plica ureterica  
 Orificium ureteris  
 Orificium urethrae internum  
 Annulus urethralis

#### Glandula suprarenalis

Substantia corticalis  
 Substantia medullaris  
 Hilus gl. suprarenalis  
 Facies anterior  
 Facies posterior  
 Basis gl. suprarenalis  
 Apex suprarenalis [gl. dextrae]  
 Margo superior  
 Margo medialis

Straight renal tubules  
 Cortical substance  
 Medullary substance  
 Renal lobes (O. T. reniculi)  
 Renal pyramids  
 Base of pyramid  
 Renal papillae  
 Cribriform area  
 Papillary foramina  
 Renal columns  
 Cortical lobules  
   Radiate part (O. T. pyramid of  
   Ferrein)  
   Convolutated part (O. T. labyrinth)  
 Renal corpuscles (O. T. Malpighian  
   corpuscles)  
 Glomeruli  
   Capsule of glomerulus  
 R e n a l p e l v i s  
 Renal calyces  
   Greater renal calyces  
   Smaller renal calyces  
 Glands of renal pelvis

#### Renal arteries

Interlobar arteries of kidney  
   Arciform arteries or renal arches  
 Interlobular arteries  
   Afferent vessel  
   Efferent vessel  
 Capsular branches  
 Straight arterioles  
 Nutrient arteries of renal pelvis

#### Renal veins

Interlobar veins  
   Arciform veins  
 Interlobular veins  
 Straight venules  
 Stellate veins

#### Ureter

Abdominal part

Pelvic part  
 Adventitious coat  
 Muscular coat  
   External layer  
   Middle layer  
   Internal layer  
 Mucous coat  
 Mucous glands of ureter

#### Urinary bladder

Apex of bladder  
 Body of bladder  
 Fundus of bladder  
 Middle umbilical ligament  
*Urachus*  
 Serous coat  
 Muscular coat  
   External layer  
   Middle layer  
   Internal layer  
 Pubovesical muscle  
 Rectovesical muscle  
 Submucous layer  
 Mucous coat  
 Vesical glands  
 Vesical lymph-nodules  
 Lieutaud's trigone of the bladder  
   Vesical uvula  
   Ureteral fold  
   Orifice of ureter  
 Internal orifice of ureter  
 Urethral ring

#### Suprarenal gland

Cortical substance  
 Medullary substance  
 Hilus of suprarenal gland  
 Anterior surface  
 Posterior surface  
 Base of suprarenal gland  
 Apex of right suprarenal  
 Superior margin  
 Medial margin

Vena centralis  
(Gl. suprarenales accessoriae)

### Organa genitalia

#### Organa genitalia virilia

##### Testis

Extremitas superior  
Extremitas inferior  
Facies lateralis  
Facies medialis  
Margo anterior  
Margo posterior  
Tunica albuginea  
Mediastinum testis [Corpus Highmori]  
Septula testis  
Lobuli testis  
Parenchyma testis  
Tubuli seminiferi contorti  
Tubuli seminiferi recti  
    Tunica propria  
Rete testis [Halleri]  
Ductuli efferentes testis  
Sperma [Semen]  
Epididymis  
    Caput epididymidis  
    Corpus epididymidis  
    Cauda epididymidis  
    Lobuli epididymidis  
    Ductus epididymidis  
    Ductuli aberrantes  
    (Ductulus aberrans superior)  
Appendices testis  
    Appendix testis [Morgagnii]  
    (Appendix epididymis)  
Paradidymis  
  
Ductus deferens  
  
Ampulla ductus deferentis  
    Diverticula ampullae  
    Tunica adventitia

Tunica muscularis  
    Stratum externum  
    Stratum medium  
    Stratum internum  
Tunica mucosa  
Ductus ejaculatorius

##### Vesicula seminalis

Corpus vesiculae seminalis  
Tunica adventitia  
Tunica muscularis  
Tunica mucosa  
Ductus excretorius

##### Funiculus spermaticus et tunicae testis et funiculi spermatici

(Rudimentum processus vaginalis)  
Tunica vaginalis propria testis  
    Lamina parietalis  
    Lamina visceralis  
Lig. epididymidis superius  
Lig. epididymidis inferius  
Sinus epididymidis  
Tunica vaginalis communis [testis et funiculi spermatici]  
M. cremaster  
Fascia cremasterica [Cooperi]  
*Descensus testis*  
*Gubernaculum testis [Hunteri]*

##### Prostata

Basis prostatae  
Apex prostatae  
Facies anterior  
Facies posterior  
Lobus [dexter et sinister]  
Isthmus prostatae  
    (Lobus medius)  
Corpus glandulare  
Ductus prostatici  
Succus prostaticus  
M. prostaticus



Central vein  
 Accessory suprarenal glands

### Genital organs

#### Male genital organs

##### Testicle

Superior extremity  
 Inferior extremity  
 Lateral surface  
 Medial surface  
 Anterior margin  
 Posterior margin  
 Albugineous coat  
 Mediastinum of testicle  
 Septules of testicle  
 Lobules of testicle  
 Parenchyma  
 Convoluted seminiferous tubules  
 Straight seminiferous tubules  
   Proper coat  
 Network  
 Efferent ductules  
 Sperm or semen  
 Epididymis  
 Head of epididymis  
 Body of epididymis  
 Tail of epididymis  
 Lobules of epididymis  
 Ducts of epididymis  
 Aberrant ductules  
 Superior aberrant ductule  
 Appendages of the testicle  
   Morgagni's appendage of testicle (O. T. hydatid of Morgagni)  
   Appendage of epididymis  
 Paraididymis (O. T. organ of Giraldes)  
 Deferent duct (O. T. vas deferens)  
 Ampulla of deferent duct  
   Diverticula of ampulla  
 Adventitious coat

Muscular coat  
   External layer  
   Middle layer  
   Internal layer  
 Mucous coat  
 Ejaculatory duct

##### Seminal vesicles

Body of seminal vesicles  
 Adventitious coat  
 Muscular coat  
 Mucous coat  
 Excretory duct

##### Spermatic cord and coats of the testicle and cord

Rudiment of vaginal process  
 Proper sheath of testicle  
   Parietal layer  
   Visceral layer  
 Superior ligament of epididymis  
 Inferior ligament of epididymis  
 Sinus of epididymis  
 Common sheath of testicle and spermatic cord  
 Cremasteric muscle  
 Cremasteric fascia  
*Descent of the testicle*  
*Gubernaculum ("pilot") of testicle*

##### Prostate

Base of prostate  
 Apex of prostate  
 Anterior surface  
 Posterior surface  
 Right and left lobe  
 Isthmus of prostate  
   Middle lobe  
 Glandular body  
 Prostatic ducts  
 Prostatic fluid  
 Prostatic muscle

<b>Glandula bulbourethralis [Cowperi]</b>	Fossa navicularis urethrae [Morgagnii] (Valvula fossae navicularis)
Corpus gl. bulbourethralis	Orificium urethrae externum
Ductus excretorius	Lacunae urethrales [Morgagnii] Gl. urethrales [Littrei]

**Partes genitales externae****Penis**

Radix penis
Corpus penis
Crus penis
Dorsum penis
Facies urethralis
Glans penis
Corona glandis
Septum glandis
Collum glandis
Praeputium
Frenulum praeputii
Raphe penis
Corpus cavernosum penis
Corpus cavernosum urethrae
Bulbus urethrae
Hemisphaeria bulbi urethrae
Septum bulbi urethrae
Tunica albuginea corporum cavernosorum
Septum penis
Trabeculae corporum cavernosorum
Cavernae corporum cavernosorum
Arteriae helicinae
Venae cavernosae
Lig. suspensorium penis
Fascia penis
Gl. praeputiales
Smegma praeputii

**Urethra virilis**

Pars prostatica
Crista urethralis
Colliculus seminalis
Utriculus prostaticus
Pars membranacea
Pars cavernosa

**Scrotum**

Raphe scroti
Septum scroti
Tunica dartos

**Organa genitalia muliebria****Ovarium**

Hilus ovarii
Facies medialis
Facies lateralis
Margo liber
Margo mesovaricus
Extremitas tubaria
Extremitas uterina
Stroma ovarii
Folliculi oophori primarii
Folliculi oophori vesiculosi [Graafi]
Theca folliculi
Tunica externa
Tunica interna
Liquor folliculi
Stratum granulosum
Cumulus oophorus
Ovulum
Corpus luteum
Corpus albicans
Lig. ovarii proprium

**Tuba uterina [Falloppii]**

Ostium abdominale tubae uterinae
Infundibulum tubae uterinae
Fimbriae tubae
Fimbria ovarica
Ampulla tubae uterinae
Isthmus tubae uterinae

**Bulbo-urethral gland (O. T. Cow-  
per's gland)**

Body of gland  
Excretory duct

**Parts of external genitals**

**Penis**

Root of penis  
Body of penis  
Crus of penis  
Dorsum of penis  
Urethral surface  
Glans ("acorn") of penis  
    Corona of glans  
    Septum of glans  
    Neck of glans  
Prepuce  
Frenulum of prepuce  
Raphe of penis  
Cavernous body of penis  
Cavernous body of urethra  
Bulb of urethra  
    Hemispheres of bulb of urethra  
    Septum of bulb of urethra  
Albuginous coat of cavernous bodies  
  
Septum of penis  
Trabeculae of cavernous bodies  
Caverns of cavernous bodies  
Spiral arteries  
Cavernous veins  
Suspensory ligament of penis  
Fascia of penis  
Preputial glands  
Smegma of prepuce

**Male urethra**

Prostatic part  
Urethral crest  
Seminal hillock  
Prostatic utricle  
Membranous part  
Cavernous part

Navicular fossa of urethra  
Valve of navicular fossa  
External urethral orifice  
Urethral lacunae of Morgagni  
Urethral glands of Littre

**Scrotum**

Raphe of scrotum  
Septum of scrotum  
Dartos ("flayed") coat

**Female genital organs**

**Ovary**

Hilus of ovary  
Medial surface  
Lateral surface  
Free margin  
Mesovarian margin  
Tubal extremity  
Uterine extremity  
Stroma of ovary  
Primary ovarian follicles  
Vesicular ovarian follicles (O. T.  
    Graafian follicles)  
Theca of follicle  
    External coat  
    Internal coat  
Liquor of follicle  
Granular layer  
Ovarian mound (O. T. discus pro-  
    ligerus)  
Ovule  
Corpus luteum: "yellow body"  
Corpus albicans: "white body"  
Proper ligament of ovary

**Uterine tube (O. T. Fallopian tube)**

Abdominal mouth of uterine tube  
Infundibulum of uterine tube  
Fimbriae of tube  
    Ovarian fimbria  
Ampulla of uterine tube  
Isthmus of uterine tube

Pars uterina  
 Ostium uterinum tubae  
 Tunica serosa  
 Tunica adventitia  
 Tunica muscularis  
   Stratum longitudinale  
   Stratum circulare  
 Tela submucosa  
 Tunica mucosa  
 Plicae tubariae  
   Plicae ampullares  
   Plicae isthmicae

### Uterus

Corpus uteri  
 Fundus uteri  
 Margo lateralis  
 Facies vesicalis  
 Facies intestinalis  
 Cavum uteri  
 Orificium internum uteri

Cervix [uteri]  
 Portio supravaginalis [cervicis]  
 Portio vaginalis [cervicis]  
 Orificium externum uteri

  Labium anterius  
   Labium posterius  
 Canalis cervicis uteri  
 Plicae palmatae  
 Gl. cervicales [uteri]  
 Parametrium  
 Tunica serosa [Perimetrium]  
 Tunica muscularis  
 Tunica muscularis cervicis  
 Tunica mucosa  
   Gl. uterinae  
 M. rectouterinus  
 Lig. teres uteri  
 (Processus vaginalis peritonaei)

### Vagina

Fornix vaginae  
 Paries anterior  
 Paries posterior  
 Hymen [femininus]  
 Carunculæ hymenales  
 Tunica muscularis  
 Tunica mucosa  
 Noduli lymphatici vaginales  
 Rugae vaginales  
 Columnae rugarum  
   Columna rugarum posterior  
   Columna rugarum anterior  
 Carina urethralis [vaginae]

### Epoophoron

Ductus epoophori longitudinalis [Gartneri]  
 Ductuli transversi  
 Appendices vesiculosi [Morgagnii]

### Paroophoron

#### Partes genitales externae

Pudendum muliebre  
 Labium majus pudendi  
 Commissura labiorum anterior  
 Commissura labiorum posterior  
 Frenulum labiorum pudendi  
 Rima pudendi  
 Fossa navicularis [vestibuli vaginae]  
 Labium minus pudendi  
 Vestibulum vaginae  
 Bulbus vestibuli  
 Gl. sebaceae  
 Gl. vestibulares minores  
 Orificium vaginae

#### Gl. vestibularis major [Bartholini]

#### Clitoris

Crus clitoridis  
 Crus clitoridis

Uterine part  
 Uterine mouth of tube  
 Serous coat  
 Adventitious coat  
 Muscular coat  
   Longitudinal layer  
   Circular layer  
 Submucous tela  
 Mucous coat  
 Tubal folds  
   Ampullar folds  
   Isthmian folds

### Uterus

Body of uterus  
 Fundus of uterus  
 Lateral margin  
 Vesical surface  
 Intestinal surface  
 Cavity of uterus  
 Internal orifice of uterus (O. T. internal os)  
 Neck of uterus  
 Supravaginal portion of cervix  
 Vaginal portion of cervix  
 External orifice of uterus (O. T. external os)  
   Anterior lip  
   Posterior lip  
 Canal of neck of uterus  
 Palmate folds  
 Cervical glands of uterus  
 Parametrium  
 Serous coat  
 Muscular coat  
 Muscular coat of neck  
 Mucous coat  
   Uterine glands  
 Rectouterine muscle  
 Round ligament of uterus  
 Vaginal process of peritoneum (O. T. canal of Nuck)

### Vagina ("sheath")

Fornix of vagina  
 Anterior wall  
 Posterior wall  
 Hymen  
 Hymeneal caruncles  
 Muscular coat  
 Mucous coat  
 Vaginal lymph-nodules  
 Rugæ ("wrinkles") of vaginal wall  
 Columns of the rugæ  
   Posterior column  
   Anterior column  
 Urethral carina ("keel") of vagina

### Epo-ophoron (O. T. parovarium or organ of Rosenmueller)

Longitudinal duct of epo-ophoron (O. T. Gärtner's duct)  
 Transverse ductules  
 Vesicular appendages of Morgagni (O. T. hydatids of Morgagni)

### Paro-ophoron

#### External genital parts

Vulva ("wrapper")  
 Greater lip of vulva  
 Anterior labial commissure  
 Posterior labial commissure  
 Frenulum of pudendal labia  
 Pudendal slit  
 Navicular fossa of vestibule of vagina  
 Lesser lip of vulva  
 Vestibule of vagina  
 Vestibular bulb  
 Sebaceous glands  
 Lesser vestibular glands  
 Orifice of vagina

### Larger vestibular gland of Bartholin

#### Clitoris

Crus of clitoris  
 Body of clitoris



Glans clitoridis	Lig. anococcygeum
Frenulum clitoridis	Fascia pelvis
Praeputium clitoridis	Fascia endopelvina
Smegma clitoridis	Fascia diaphragmatis pelvis superior
Corpus cavernosum clitoridis	
Septum corporum cavernosorum	Arcus tendineus fasciae pelvis
Fascia clitoridis	Lig. puboprostaticum [pubovesicale]
Lig. suspensorium clitoridis	medium
	Lig. puboprostaticum [pubovesicale]
<b>Urethra muliebris</b>	laterale
Orificium urethrae externum	
Corpus spongiosum urethrae	Fascia diaphragmatis pelvis inferior
Tunica muscularis	<b>D i a p h r a g m a u r o g e n i t a l e</b>
Stratum circulare	
Stratum longitudinale	M. transversus perinei profundus
Tunica submucosa	M. sphincter urethrae membranaceae
Tunica mucosa	
Gl. urethrales	Fascia diaphragmatis urogenitalis superior
Crista urethralis	
(Ductus paraurethrales)	
<b>Termini ontogenetici</b>	
<i>Membranae deciduae</i>	Fascia diaphragmatis urogenitalis inferior
<i>Decidua vera</i>	
<i>Decidua capsularis</i>	Lig. transversum pelvis
<i>Decidua basalis</i>	
<i>Placenta</i>	
<i>Placenta uterina</i>	Fascia prostatae
<i>Placenta foetalis</i>	Fascia obturatoria
<i>Funiculus umbilicalis</i>	Fossa ischiorectalis
<i>Corpus Wolffii</i>	M. transversus perinei superficialis
<i>Ductus Wolffii</i>	M. ischiocavernosus
<i>Ductus Muelleri</i>	
<i>Sinus urogenitalis</i>	M. bulbocavernosus
<b>Perineum</b>	
Raphe perinei	Fascia superficialis perinei
Musculi perinei	
<b>D i a p h r a g m a p e l v i s</b>	
M. levator ani	
Arcus tendineus m. levatoris ani	<b>Peritoneum</b>
M. coccygeus [vide p. 40]	Tunica serosa
M. sphincter ani externus	Tela subserosa
	Peritoneum parietale
	Peritoneum viscerale

Glans of clitoris  
 Frenulum of clitoris  
 Prepuce of clitoris  
   Smegma of clitoris  
 Cavernous body of clitoris  
 Septum of cavernous bodies  
 Fascia of clitoris  
 Suspensory ligament of clitoris

### Female urethra

External orifice of urethra  
 Spongy body of urethra  
 Muscular coat  
   Circular layer  
   Longitudinal layer  
 Submucous coat  
 Mucous coat  
   Urethral glands  
 Urethral crest  
 Para-urethral ducts  
 Ontogenetic terms  
*Deciduous membranes*  
   *True decidua*  
   *Capsular decidua*  
   *Basal decidua*  
*Placenta ("cake")*  
   *Uterine placenta*  
   *Foetal placenta*  
*Umbilical cord*  
*Wolffian body*  
*Wolffian duct*  
*Muellerian duct*  
*Urogenital sinus*

### Perineum

Perineal raphe  
 Perineal muscles  
 Pelvic diaphragm  
 Levator muscle of anus  
   Tendinous arch of levator ani muscle (O. T. white line of the pelvis)  
 Coccygeus muscle  
 External sphincter muscle of anus

Anococcygeal ligament  
 Pelvic fascia  
 Endopelvic fascia  
 Superior fascia of the peivic diaphragm  
 Tendinous arch of pelvic fascia  
 Middle puboprostatic or pubovesical ligament (O. T. anterior true ligament of bladder)  
 Lateral puboprostatic or pubovesical ligament (O. T. lateral true ligament of bladder)  
 Inferior fascia of the pelvic diaphragm  
 Urogenital diaphragm (O. T. triangular ligament)  
 Deep transverse muscle of perineum  
 Sphincter muscle of the membranous urethra (O. T. compressor urethrae)  
 Superior fascia of urogenital diaphragm (O. T. deep layer of triangular ligament)  
 Inferior fascia of urogenital diaphragm (O. T. superficial layer of triangular ligament)  
 Transverse ligament of pelvis (O. T. median puboprostatic ligament of Krause)  
 Prostatic fascia  
 Obturator fascia  
 Ischiorectal fossa  
 Superficial transverse perineal muscle  
 Ischiocavernous muscle (O. T. erector penis [vel clitoridis] muscle)  
 Bulbocavernous muscle (O. T. ejaculator seminis or accelerator urinae; sphincter vaginae)  
 Superficial perineal fascia

### Peritoneum

Serous coat  
 Subserous tela  
 Parietal peritoneum  
 Visceral peritoneum

Cavum peritonaei	Lig. triangulare sinistrum
<i>Mesenterium commune</i>	Lig. hepatorenale
Mesenterium	(Lig. duodenorenale)
Radix mesenterii	Recessus duodenojejunalis
Lamina mesenterii propria	Plica duodenojejunalis
Mesocolon	(Plica duodenomesocolica)
Mesocolon transversum	Recessus intersigmoideus
Mesocolon ascendens	Recessus iliocaecalis superior
Mesocolon descendens	Recessus iliocaecalis inferior
Mesocolon sigmoideum	Plica iliocaecalis
Mesorectum	Fossa caecalis
Mesenteriolum processus vermiformis	Recessus retrocaecalis
<i>Mesogastrium</i>	Plica caecalis
Omentum minus	Recessus paracolicus
Lig. hepatogastricum	(Fossa iliacosubfascialis)
Lig. hepatoduodenale	(Recessus phrenicohepatici)
(Lig. hepatocolicum)	Plica umbilicalis media
Lig. gastrolienale	Plica umbilicalis lateralis
	Plica epigastrica
Lig. gastrocolicum	Plica pubovesicalis
Omentum majus	Plica vesicalis transversa
Bursa omentalis	<i>Mesorchium</i>
	<i>Processus vaginalis peritonaei</i>
Vestibulum bursae omentalis	Lig. latum uteri
Recessus superior omentalis	Mesometrium
Recessus inferior omentalis	Mesosalpinx
Recessus lienalis	Mesovarium
Plica gastropancreatica	Bursa ovarica
Foramen epiploicum [Winslowi]	Lig. suspensorium ovarii
	Plica rectouterina [Douglasi]
Lig. phrenicocolicum	Excavatio rectouterina [Cavum Douglasi]
	Excavatio vesicouterina
Lig. phrenicolienale	Excavatio rectovesicalis
Lig. falciforme hepatis	Spatium retroperitoneale
Lig. coronarium hepatis	
Lig. triangulare dextrum	

Peritoneal cavity	Left triangular ligament
<i>Common mesentery</i>	Hepatorenal ligament
Mesentery	Duodenorenal ligament
Root of the mesentery	Duodenojejunal recess
Proper layer of the mesentery	Duodenojejunal fold
Mesocolon	Duodenomesocolic fold
Transverse mesocolon	Intersigmoid recess
Ascending mesocolon	Superior ileocaecal recess
Descending mesocolon	Inferior ileocaecal recess
Sigmoid mesocolon	Ileocaecal fold
Mesorectum	Caecal fossa
Meso-appendix	Retrocaecal recess
<i>Mesogastrium</i>	Caecal fold
Lesser omentum	Paracolic recess
Hepatogastric ligament	Iliaco-subfascial fossa
Hepatoduodenal ligament	Phrenicohepatic recess
Hepatocolic ligament	Middle umbilical fold
Gastrosplenic ligament (O. T. gas- tro-splenic omentum)	Lateral umbilical fold
Gastrocolic ligament	Epigastric fold
Greater omentum	Pubovesical fold
Omental bursa (O. T. lesser perito- neal sac)	Transverse vesical fold
Vestibule of omental bursa	<i>Mesorchium</i>
Superior omental recess	<i>Sheath process of peritoneum</i>
Inferior omental recess	Broad ligament of uterus
Splenic recess	Mesometrium
Gastropancreatic fold	Mesosalpinx
Epiploic foramen (O. T. foramen of Winslow)	Mesovarium
Phrenicocolic ligament (O. T. cos- tocolic ligament)	Ovarian bursa
Phrenicosplenic ligament	Suspensory ligament of ovary
Falciform ligament of liver	Recto-uterine fold
Coronary ligament of liver	Recto-uterine excavation, or cul-de- sac of Douglas
Right triangular ligament	Vesico-uterine excavation
	Rectovesical excavation
	Retroperitoneal space

## Angiologia

Vas collaterale	Emissarium
Vas anastomoticum	Corpus cavernosum
Ramus communicans	Vas capillare
Plexus vasculosus	Vas lymphaticum
Rete vasculosum	Plexus lymphaticus
Rete mirabile	Lymphoglandula
Arteria	Nodus lymphaticus
Arteriola	Cisterna
Vena	Tunica externa [adventitia]
Vena cutanea	Tunica media
Vena comitans	Tunica intima
Venula	Vasa vasorum
Plexus venosus	Vagina vasorum
Rete venosum	Sanguis
Sinus [venosus]	Lympha

---

## Cor

Basis cordis	Epicardium
Facies sternocostalis	Myocardium
Facies diaphragmatica	Endocardium
Apex cordis	Ventriculus cordis
Incisura [apicis] cordis	Septum ventriculorum
Sulcus longitudinalis anterior	Septum musculare ventriculorum
Sulcus longitudinalis posterior	Septum membranaceum ventriculorum
Sulcus coronarius	Atrium cordis
Pericardium	Auricula cordis
Liquor pericardii	Septum atriorum
Ligg. sternopericardiaca	Pars membranacea septi atriorum
Sinus transversus pericardii	Ostium venosum
	Ostium arteriosum



## Angiology

Collateral vessel	Emissary (vessel)
Anastomotic vessel	Cavernous body
Communicating branch	Capillary vessel
Vascular plexus	Lymphatic vessel
Vascular rete	Lymphatic plexus
Rete mirabile ("wonderful network")	Lymph gland
Artery	Lymph nodule
Arteriole	Cistern
Vein	External coat
Cutaneous vein	Middle coat
Accompanying vein	Inner coat
Venule	Vessels of the vessels
Venous plexus	Sheath of the vessels
Venous rete	Blood
Venous sinus	Lymph

---

## Heart

Base of heart	Epicardium
Sternocostal surface	Myocardium
Diaphragmatic surface	Endocardium
Apex of heart	Ventricle of heart
Notch at apex of heart	Septum of ventricles
Anterior longitudinal sulcus (O. T. anterior interventricular groove)	Muscular septum of ventricles
Posterior longitudinal sulcus (O. T. posterior interventricular groove)	Membranous septum of ventricles
Coronary sulcus (O. T. auriculoventricular groove)	Forechamber (O. T. auricle)
Pericardium	Auricle (O. T. auricular appendix)
Pericardial fluid	Septum of atria
Sternopericardiac ligaments	Membranous part of septum of atria
Transverse sinus of pericardium	Venous orifice
	Arterial orifice

Trabeculae carneaе  
 Vortex cordis  
 Mm. papillares  
 Chordae tendineae  
 Trigona fibrosa  
 Annuli fibrosi

### Atrium dextrum

Mm. pectinati  
 Sulcus terminalis atrii dextri  
 Crista terminalis  
 Sinus venarum [cavarum]  
 Limbus fossae ovalis [Vieussenii]

Auricula dextra

Tuberculum intervenosum [Loweri]  
 Valvula venae cavae [inferioris, Eustachii]  
 Fossa ovalis  
 Valvula sinus coronarii [Thebesii]

Foramina venarum minimarum [Thebesii]

### Ventriculus dexter

Valvula tricuspidalis  
 Cuspis anterior

Cuspis posterior

Cuspis medialis  
 Crista supraventricularis  
 Conus arteriosus  
 Valvulae semilunares a. pulmonalis  
 Valvula semilunaris anterior  
 Valvula semilunaris dextra  
 Valvula semilunaris sinistra  
 Noduli valvularum semilunarium  
 Lunulae valvularum semilunarium

### Atrium sinistrum

Auricula sinistra

Valvula foraminis ovalis

### Ventriculus sinister

Valvula bicuspidalis [mitralis]  
 Cuspis anterior  
 Cuspis posterior  
 Valvulae semilunares aortae  
 Valvula semilunaris posterior  
 Valvula semilunaris dextra  
 Valvula semilunaris sinistra  
 Noduli valvularum semilunarium  
 [Arantii]  
 Lunulae valvularum semilunarium

---

## Arteriae

### A. pulmonalis

Ramus dexter  
 Ramus sinister  
*Ductus arteriosus* [Botalli]  
 Ligamentum arteriosum

### Aorta

Aorta ascendens

Bulbus aortae  
 Sinus aortae [Valsalvae]

Arcus aortae  
 Isthmus aortae  
 Aorta descendens  
 A. coronaria [cordis] dextra  
 Ramus descendens posterior  
 A. coronaria [cordis] sinistra

Fleshy cords (O. T. *columnae carnae*)  
 Vortex of heart  
 Papillary muscles  
 Tendinous cords  
 Fibrous trigones  
 Fibrous rings

**Right atrium**

Pectinate ("comb-like") muscles  
 Terminal sulcus of the right atrium  
 Terminal crest  
 Venous sinus  
 Edge of oval fossa (O. T. *annulus ovalis*)  
 Right auricle (O. T. *right auricular appendix*)  
 Intervenous tubercle of Lower  
 Valve of inferior vena cava (O. T. *Eustachian valve*)  
 Oval fossa  
 Valve of coronary sinus (O. T. *coronary valve, or valve of Thebesius*)  
 Foramina of the smallest veins (O. T. *foramina Thebesii*)

**Right ventricle**

Tricuspid valve (O. T. *right auriculo-ventricular valve*)  
 Anterior cusp (O. T. *infundibular cusp*)

Posterior cusp (O. T. *marginal cusp*)  
 Medial cusp (O. T. *septal cusp*)  
 Supraventricular crest  
 Arterial cone  
 Semilunar valves of pulmonary artery  
 Anterior semilunar valve  
 Right semilunar valve  
 Left semilunar valve  
 Nodules of the semilunar valves  
 Crescents of the semilunar valves

**Left atrium (O. T. left auricle)**

Left auricle (O. T. *left auricular appendix*)  
 Valve of the foramen

**Left ventricle**

Bicuspid or mitral valve (O. T. *left auriculoventricular valve*)  
 Anterior cusp  
 Posterior cusp  
 Semilunar valves of aorta  
 Posterior semilunar valve  
 Right semilunar valve  
 Left semilunar valve  
 Nodules of the semilunar valves (O. T. *corpora Arantii*)  
 Crescents, or "sails" of semilunar valves

---

Arteries

**Pulmonary artery**

Right ramus  
 Left ramus  
*Arterial duct*  
 Arterial ligament

**Aorta**

Ascending aorta

Bulb of aorta  
 Sinuses of aorta (O. T. *sinus Valsalvae*)  
 Arch of aorta  
 Isthmus of aorta  
 Descending aorta  
 Right coronary artery of heart  
 Posterior descending ramus  
 Left coronary artery of heart

Ramus circumflexus  
Ramus descendens anterior

**A. anonyma**

(A. thyreoidea ima)

**A. carotis communis**

**A. carotis externa**

**A. thyreoidea superior**

Ramus hyoideus  
Ramus sternocleidomastoideus  
A. laryngea superior  
Ramus cricothyroideus  
Ramus anterior  
Ramus posterior  
Rami glandulares

**A. pharyngea ascendens**

A. meningea posterior  
Rami pharyngei  
A. tympanica inferior

**A. lingualis**

Ramus hyoideus  
A. sublingualis  
Rami dorsales linguae  
A. profunda linguae

**A. maxillaris externa**

A. palatina ascendens  
Ramus tonsillaris  
A. submentalis  
Rami glandulares  
A. labialis inferior  
A. labialis superior  
A. angularis

**A. sternocleidomastoidea**

**A. occipitalis**

Ramus mastoideus  
Ramus auricularis

Rami musculares  
Ramus descendens  
(Ramus meningeus)  
Rami occipitales

**A. auricularis posterior**

A. stylomastoidea  
A. tympanica posterior  
Rami mastoidei  
Ramus stapedius  
Ramus auricularis  
Ramus occipitalis

**A. temporalis superficialis**

Rami parotidei  
A. transversa faciei  
Rami auriculares anteriores  
A. zygomaticoorbitalis  
A. temporalis media  
Ramus frontalis  
Ramus parietalis

**A. maxillaris interna**

A. auricularis profunda  
A. tympanica anterior  
A. alveolaris inferior  
  
R. mylohyoideus  
A. mentalis  
A. meningea media  
(Ramus meningeus accessorius)

Ramus petrosus superficialis  
A. tympanica superior

A. masseterica  
A. temporalis profunda posterior  
A. temporalis profunda anterior  
Rami pterygoidei  
A. buccinatoria  
A. alveolaris superior posterior

A. infraorbitalis

Aa. alveol. superiores anteriores

Circumflex ramus  
Anterior descending ramus

**Innominate artery**

Lowest thyreoid artery

**Common carotid artery**

**External carotid artery**

**Superior thyreoid artery**

Hyoid ramus  
Sternocleidomastoid ramus  
Superior laryngeal artery  
Cricothyreoid ramus  
Anterior ramus  
Posterior ramus  
Glandular rami

**Ascending pharyngeal artery**

Posterior meningeal artery  
Pharyngeal rami  
Inferior tympanic artery

**Lingual artery**

Hyoid ramus  
Sublingual artery  
Dorsal rami of tongue  
Deep artery of tongue (O. T. ranine artery)

**External maxillary artery (O. T. facial artery)**

Ascending palatine artery  
Tonsillar rami  
Submental artery  
Glandular rami  
Inferior labial artery  
Superior labial artery  
Angular artery

**Sternocleidomastoid artery**

**Occipital artery**

Mastoid ramus  
Auricular ramus

Muscular rami  
Descending ramus  
Meningeal ramus  
Occipital rami

**Posterior auricular artery**

Stylomastoid artery  
Posterior tympanic artery  
Mastoid rami  
Stapedial ramus  
Auricular ramus  
Occipital ramus

**Superficial temporal artery**

Parotid rami  
Transverse artery of face  
Anterior auricular rami  
Zygomatico-orbital artery  
Middle temporal artery  
Frontal ramus  
Parietal ramus

**Internal maxillary artery**

Deep auricular artery  
Anterior tympanic artery  
Inferior alveolar artery (O. T. inferior dental)  
Mylohyoid ramus  
Mental artery  
Middle meningeal artery  
Accessory meningeal ramus (O. T. small meningeal)  
Superficial petrosal ramus  
Superior tympanic artery  
Masseteric artery  
Posterior deep temporal artery  
Anterior deep temporal artery  
Pterygoid rami  
Buccinator artery (O. T. buccal)  
Posterior superior alveolar artery (O. T. posterior dental)  
Infraorbital artery  
Anterior superior alveolar arteries (O. T. anterior superior dental)



A. palatina descendens  
 A. canalis pterygoidei [Vidii]  
 A. palatina major  
 Aa. palatinae minores  
 A. sphenopalatina  
 Aa. nasales posteriores laterales et septi

### A. carotis interna

Ramus caroticotympanicus

### A. ophthalmica

A. centralis retinae  
 A. lacrimalis  
 Aa. palpebrales laterales  
 Rami musculares  
 Aa. ciliares posteriores breves  
 Aa. ciliares posteriores longae  
 Aa. ciliares anteriores  
 Aa. conjunctivales anteriores  
 Aa. conjunctivales posteriores  
 Aa. episclerales  
 A. supraorbitalis  
 A. ethmoidalis posterior  
 A. ethmoidalis anterior  
 A. meningea anterior  
 Aa. palpebrales mediales  
 Arcus tarseus superior  
 Arcus tarseus inferior  
 A. frontalis  
 A. dorsalis nasi

### Aa. cerebri

A. communicans posterior  
 A. chorioidea  
  
 A. cerebri anterior  
 A. communicans anterior  
 A. cerebri media

### A. subclavia

### A. vertebralis

Rami spinales  
 A. spinalis posterior  
 A. spinalis anterior  
 Ramus meningeus  
  
 A. cerebelli inferior posterior

### A. basilaris

A. cerebelli inferior anterior  
 A. auditiva interna

Rami ad pontem

A. cerebelli superior  
 A. cerebri posterior  
 Circulus arteriosus [Willisi]

### A. mammaria interna

Aa. mediastinales anteriores  
 Aa. thymicae  
 Rami bronchiales  
 A. pericardiacophrenica

Rami sternales

Rami perforantes

Rami mammarii

Rami musculares

Rami cutanei

(Ramus costalis lateralis)

Rami intercostales

A. musculophrenica

A. epigastrica superior

### Truncus thyrocervicalis

### A. thyreoidea inferior

A. laryngea inferior  
 Rami pharyngei  
 Rami oesophagei

Descending palatine artery  
 Artery of pterygoid canal  
 Greater palatine artery  
 Lesser palatine arteries  
 Sphenopalatine artery  
 Posterior lateral arteries of the nose  
 and of septum

**Internal carotid artery**

Caroticotympanic ramus (O. T. tym-  
 panic branch)

**Ophthalmic artery**

Central artery of retina  
 Lacrimal artery  
 Lateral palpebral arteries  
 Muscular rami  
 Short posterior ciliary arteries  
 Long posterior ciliary arteries  
 Anterior ciliary arteries  
 Anterior conjunctival arteries  
 Posterior conjunctival arteries  
 Episcleral arteries  
 Supraorbital artery  
 Posterior ethmoidal artery  
 Anterior ethmoidal artery  
 Anterior meningeal artery  
 Middle palpebral arteries  
 Superior tarsal arch  
 Inferior tarsal arch  
 Frontal artery  
 Dorsal artery of nose

**Cerebral arteries**

Posterior communicating artery  
 Chorioid artery (O. T. anterior cho-  
 roidal)  
 Anterior cerebral artery  
 Anterior communicating artery  
 Middle cerebral artery (O. T. arteria  
 fossae Sylvii)

**Subclavian artery**

**Vertebral artery**

Spinal rami  
 Posterior spinal artery  
 Anterior spinal artery  
 Meningeal ramus (O. T. posterior  
 meningeal branch)  
 Posterior inferior cerebellar artery

**Basilar artery**

Anterior inferior cerebellar artery  
 Internal auditory artery (O. T. audi-  
 tory artery)  
 Rami to pons (O. T. transverse arter-  
 ies)  
 Superior cerebellar arteries  
 Posterior cerebral artery  
 Arterial circle of Willis

**Internal mammary artery**

Anterior mediastinal arteries  
 Thymic arteries  
 Bronchial rami  
 Pericardiacophrenic artery (O. T.  
 arteria comes nervi phrenici)  
 Sternal rami  
 Perforating rami  
     Mammary rami  
     Muscular rami  
     Cutaneous rami  
 Lateral costal ramus  
 Intercostal rami (O. T. anterior inter-  
 costals)  
 Musculophrenic artery  
 Superior epigastric artery

**Thyreocervical trunk (O. T. thy-  
 roid axis)**

**Inferior thyroid artery**

Inferior laryngeal artery  
 Pharyngeal rami  
 Oesophageal rami

Rami tracheales  
Rami glandulares

**A. cervicalis ascendens**

Rami spinales  
Rami musculares  
Ramus profundus

**A. cervicalis superficialis**

**A. transversa scapulae**

Ramus acromialis

**Truncus costocervicalis**

A. intercostalis suprema

Rami dorsales  
Rami spinales  
A. cervicalis profunda

**A. transversa colli**

Ramus ascendens  
Ramus descendens

**A. axillaris**

Rami subscapulares

**A. thoracalis suprema**

**A. thoracoacromialis**

Ramus acromialis  
Rete acromiale  
Ramus deltoideus  
Rami pectorales

**A. thoracalis lateralis**

Rami mammarii externi

**A. subscapularis**

A. thoracodorsalis

A. circumflexa scapulae

**A. circumflexa humeri anterior**

**A. circumflexa humeri posterior**

**A. brachialis**

**A. profunda brachii**

Aa. nutritiae humeri  
R. deltoideus  
A. collateralis media  
A. collateralis radialis

**A. collateralis ulnaris superior**

**A. collateralis ulnaris inferior**

**A. radialis**

A. recurrens radialis  
Rami musculares  
Ramus carpeus volaris

Ramus volaris superficialis  
Ramus carpeus dorsalis

Rete carpi dorsale

Aa. metacarpeae dorsales

Aa. digitales dorsales  
A. princeps pollicis  
A. volaris indicis radialis

Arcus volaris profundus

Aa. metacarpeae volares  
Rami perforantes

Tracheal rami  
Glandular rami

**Ascending cervical artery**

Spinal rami  
Muscular rami  
Deep ramus

**Superficial cervical artery**

**Transverse artery of scapula (O. T. suprascapular)**

Acromial ramus

**Costocervical trunk (O. T. superior intercostal)**

**Highest intercostal artery (O. T. superior intercostal proper)**

Dorsal rami  
Spinal rami

Deep cervical artery

**Transverse artery of neck (O. T. transversalis colli)**

Ascending ramus  
Descending ramus

**Axillary artery**

Subscapular rami

**Highest thoracic artery (O. T. superior thoracic artery)**

**Thoraco-acromial artery (O. T. acromiothoracic or thoracic axis)**

Acromial ramus  
Acromial rete  
Deltoid ramus  
Pectoral rami

**Lateral thoracic artery (O. T. long thoracic)**

External mammary rami

**Subscapular artery**

Thoracodorsal artery

Circumflex artery of scapula (O. T. dorsalis scapulae)

**Anterior circumflex artery of humerus**

**Posterior circumflex artery of humerus**

**Brachial artery**

**Deep artery of upper arm (O. T. superior profunda)**

Nutrient arteries of the humerus

Deltoid ramus

Middle collateral artery

Radial collateral artery (O. T. articular branch of superior profunda)

**Superior ulnar collateral artery (O. T. inferior profunda)**

**Inferior ulnar collateral artery (O. T. anastomotica magna)**

**Radial artery**

Radial recurrent artery

Muscular rami

Volar carpal ramus (O. T. anterior radial carpal)

Superficial volar ramus

Dorsal carpal ramus (O. T. posterior radial carpal)

Dorsal carpal rete (O. T. posterior carpal rete)

Dorsal metacarpal arteries (O. T. dorsal interosseous arteries)

Dorsal digital arteries

Principal artery of thumb

Radial volar artery of index-finger (O. T. arteria radialis indicis)

Deep volar arch (O. T. deep palmar arch)

Volar metacarpal arteries

Perforating rami

**A. ulnaris**

- Aa. recurrentes ulnares
- Rete articulare cubiti
- A. interossea communis
- A. interossea dorsalis
  - A. interossea recurrens
- A. interossea volaris
- A. mediana
- Rami musculares
- Ramus carpeus dorsalis
- Ramus carpeus volaris
- Ramus volaris profundus
- Arcus volaris superficialis
- Aa. digitales volares communes
- Aa. digitales volares propriae

**Aorta thoracalis****Rami viscerales**

- Aa. bronchiales
- Aa. oesophageae
- Rami pericardiaci
  - Rami parietales**
- Rami mediastinales
- Aa. phrenicae superiores

**Aa. intercostales**

- Rami posteriores
  - Ramus spinalis
  - Rami musculares
  - Ramus cutaneus medialis
  - Ramus cutaneus lateralis
- Rami anteriores
  - Rami musculares
  - Rami cutanei laterales [pectorales et abdominales]

- Ramus posterior
- Ramus anterior
- Rami mammarii laterales
- Rami cutanei anteriores [pectorales et abdominales]
- Rami mammarii mediales

**Aorta abdominalis****Rami parietales****A. phrenica inferior**

- Rami suprarenales superiores

**Aa. lumbales**

- Ramus dorsalis
- Ramus spinalis

**A. sacralis media**

- A. lumbalis ima
- Glomus coccygeum

**Rami viscerales****A. coeliaca**

- A. gastrica sinistra
- Rami oesophagei
- A. hepatica
- A. gastrica dextra
- A. hepatica propria
  - Ramus dexter
  - A. cystica
  - Ramus sinister
- A. gastroduodenalis
  - A. pancreaticoduoden. superior
    - Rami pancreatici
    - Rami duodenales
  - A. gastroepiploica dextra
    - Rami epiploici
- A. lienalis
  - Rami pancreatici
  - A. gastroepiploica sinistra
- Aa. gastricae breves
- Rami lienales



**Ulnar artery**

- Recurrent ulnar arteries
- Articular rete of elbow
- Common interosseous artery
- Dorsal interosseous artery (O. T. posterior interosseous)
- Recurrent interosseous artery (O. T. posterior interosseous recurrent)
- Volar interosseous artery (O. T. anterior interosseous)
- Median artery
- Muscular rami
- Dorsal carpal ramus (O. T. posterior ulnar carpal)
- Volar carpal ramus (O. T. anterior ulnar carpal)
- Deep volar ramus
- Superficial volar arch (O. T. superficial palmar arch)
- Common volar digital arteries (O. T. palmar digital arteries)
- Volar digital arteries proper (O. T. collateral digital arteries)

**Thoracic aorta**

**Visceral rami**

- Bronchial arteries
- Oesophageal arteries
- Pericardial rami

**Parietal rami**

- Mediastinal rami
- Superior phrenic arteries

**Intercostal arteries**

- Posterior rami
- Spinal rami
- Muscular rami
- Medial cutaneous ramus
- Lateral cutaneous ramus
- Anterior rami
- Muscular rami
- Lateral cutaneous rami of breast and abdomen

- Posterior ramus
- Anterior ramus
- Lateral mammary rami
- Anterior cutaneous rami of breast and abdomen
- Medial mammary rami

**Abdominal aorta**

**Parietal rami**

**Inferior phrenic artery**

- Superior suprarenal rami

**Lumbar arteries**

- Dorsal ramus
- Spinal ramus

**Middle sacral artery**

- Lowest lumbar artery
- Coccygeal skein

**Visceral rami**

**Coeliac artery**

- Left gastric artery
- Oesophageal rami
- Hepatic artery
- Right gastric artery
- Proper hepatic artery
- Right ramus
- Cystic artery
- Left ramus
- Gastroduodenal artery
- Superior pancreaticoduodenal artery
- Pancreatic rami
- Duodenal rami
- Right gastro-epiploic artery
- Epiploic rami
- Splenic artery
- Pancreatic rami
- Left gastro-epiploic artery
- Short gastric arteries
- Splenic rami

- A. mesenterica superior**  
 Aa. intestinales  
 A. pancreaticoduodenalis inferior  
 Aa. jejunales  
 Aa. ileae  
 A. ileocolica  
 A. appendicularis  
 A. colica dextra  
 A. colica media
- A. mesenterica inferior**  
 A. colica sinistra  
 Aa. sigmoideae  
 A. haemorrhoidalis superior
- A. suprarenalis media**  
**A. renalis**  
 A. suprarenalis inferior
- A. spermatica interna**  
**A. testicularis**  
**A. ovarica**  
**A. iliaca communis**  
**A. hypogastrica**  
 Rami parietales  
**A. iliolumbalis**  
 Ramus lumbalis  
 Ramus spinalis  
 Ramus iliacus  
**A. sacralis lateralis**  
 Rami spinales  
**A. obturatoria**  
 Ramus pubicus  
 Ramus anterior  
 Ramus posterior  
 A. acetabuli
- A. glutaea superior**  
 amus superior  
 Ramus inferior  
**A. glutaea inferior**  
 A. comitans n. ischiadici  
 Rami viscerales  
**A. umbilicalis**  
 Aa. vesicales superiores  
 [Ligamentum umbilicale laterale]  
**A. vesicalis inferior**  
**A. deferentialis**  
**A. uterina**  
 A. vaginalis  
 Ramus ovarii  
 Ramus tubarius  
**A. haemorrhoidalis media**  
**A. pudenda interna**  
 A. haemorrhoidalis inferior  
 A. perinei  
 Aa. scrotales posteriores  
 Aa. labiales posteriores  
 A. penis  
 A. urethralis  
 A. bulbi urethrae  
 A. bulbi vestibuli [vaginae]  
 A. profunda penis  
 A. dorsalis penis  
 A. clitoridis  
 A. profunda clitoridis  
 A. dorsalis clitoridis  
**A. iliaca externa**  
**A. epigastrica inferior**  
 Ramus pubicus  
 Ramus obturatorius  
 A. spermatica externa

**Superior mesenteric artery**

- Intestinal arteries
  - Inferior pancreaticoduodenal artery
  - Jejunal arteries
  - Ileal arteries (O. T. rami intestini tenuis)
  - Ileocolic artery
    - Appendicular artery
  - Right colic artery
  - Middle colic artery

**Inferior mesenteric artery**

- Left colic artery
- Sigmoid arteries
- Superior hemorrhoidal artery

**Middle suprarenal artery (O. T. middle capsular artery)**

**Renal artery**

- Inferior suprarenal artery

**Internal spermatic artery**

**Testicular artery**

**Ovarian artery**

**Common iliac artery**

**Hypogastric artery (O. T. internal iliac)**

**P a r i e t a l r a m i**

**Iliolumbar artery**

- Lumbar ramus
- Spinal ramus
- Iliac ramus

**Lateral sacral artery**

- Spinal rami

**Obturator artery**

- Pubic ramus
  - Anterior ramus
  - Posterior ramus
- Artery of acetabulum

**Superior gluteal artery**

- Superior ramus
- Inferior ramus

**Inferior gluteal artery**

- Companion artery of sciatic nerve
- V i s c e r a l r a m i**

**Umbilical artery**

- Superior vesical arteries
- [Lateral umbilical ligament]

**Inferior vesical artery**

**Deferential artery**

**Uterine artery**

- Vaginal artery
- Ovarian ramus
- Tubal ramus

**Middle hemorrhoidal artery**

**Internal pudendal artery**

- Inferior hemorrhoidal artery
- Artery of perineum
- Posterior scrotal arteries
- Posterior labial arteries
- Artery of penis
- Urethral artery
- Artery of the bulb of urethra
- Artery of the vestibular bulb of vagina
- Deep artery of penis
- Dorsal artery of penis
- Artery of clitoris
- Deep artery of clitoris
- Dorsal artery of clitoris

**External iliac artery**

**Inferior epigastric artery (O. T. deep epigastric)**

- Pubic ramus
  - Obturator ramus
- External spermatic artery (O. T. cremasteric)

A. lig. teretis uteri

**A. circumflexa ilium profunda**

**A. femoralis**

A. epigastrica superficialis

A. circumflexa ilium superficialis

Aa. pudendae externae

Aa. scrotales anteriores

Aa. labiales anteriores

Rami inguinales

A. profunda femoris

A. circumflexa femoris medialis

Ramus superficialis

Ramus profundus

Ramus acetabuli

A. circumflexa femoris lateralis

Ramus ascendens

Ramus descendens

A. perforans prima

A. nutritia femoris superior

A. perforans secunda

A. perforans tertia

A. nutritia femoris inferior

Rami musculares

A. genu suprema

Rami musculares

Ramus saphenus

Rami articulares

**A. poplitea**

A. genu superior lateralis

A. genu superior medialis

A. genu media

Aa. surales

A. genu inferior lateralis

A. genu inferior medialis

Rete articulare genu

Rete patellae

**A. tibialis anterior**

(A. recurrens tibialis posterior)

A. recurrens tibialis anterior

A. malleolaris anterior lateralis

A. malleolaris anterior medialis

Rete malleolare mediale

Rete malleolare laterale

A. dorsalis pedis

A. tarsea lateralis

Aa. tarseae mediales

A. arcuata

Rete dorsale pedis

Aa. metatarsae dorsales

Aa. digitales dorsales

Ramus plantaris profundus

**A. tibialis posterior**

Ramus fibularis

A. peronea

A. nutritia fibulae

Ramus perforans

Ramus communicans

A. malleolaris posterior lateralis

Rami calcanei laterales

A. nutritia tibiae

A. malleolaris posterior medialis

Rami calcanei mediales

Rete calcaneum

A. plantaris medialis

Ramus profundus

Artery of round ligament of uterus

**Deep circumflex iliac artery**

**Femoral artery**

Superficial epigastric artery

Superficial circumflex iliac artery

External pudendal arteries (O. T. superficial and deep external pudic arteries)

Anterior scrotal arteries

Anterior labial arteries

Inguinal rami

Deep artery of thigh

Medial circumflex artery of thigh (O. T. internal circumflex)

Superficial ramus

Deep ramus

Ramus to acetabulum

Lateral circumflex artery of thigh (O. T. external circumflex)

Ascending ramus

Descending ramus

First perforating artery

Superior nutrient artery of femur

Second perforating artery

Third perforating artery

Inferior nutrient artery of femur

Muscular rami

Highest artery of knee

Muscular rami

Saphenous ramus

Articular rami

**Popliteal artery**

Lateral superior artery of knee (O. T. superior external articular artery)

Medial superior artery of knee (O. T. superior internal articular artery)

Middle artery of knee (O. T. azygos articular artery)

Sural arteries, or arteries of calf

Lateral inferior artery of knee (O. T. inferior external articular artery)

Medial inferior artery of knee (O. T. inferior internal articular artery)

Arterial network about knee-joint

Patellar network

**Anterior tibial artery**

Posterior recurrent tibial artery

Anterior recurrent tibial artery

Lateral anterior malleolar artery (O. T. external malleolar)

Medial anterior malleolar artery (O. T. internal malleolar)

Medial malleolar network

Lateral malleolar network

Dorsal artery of foot

Lateral tarsal artery

Medial tarsal arteries

Arcuate artery

Dorsal network of foot

Dorsal metatarsal arteries

Dorsal digital arteries

Deep plantar ramus

**Posterior tibial artery**

Fibular ramus

Peroneal artery

Nutrient artery of fibula

Perforating ramus (O. T. anterior peroneal)

Communicating ramus

Lateral posterior malleolar artery (O. T. posterior peroneal)

Lateral calcanean rami (O. T. external calcanean)

Nutrient artery of tibia

Medial posterior malleolar artery (O. T. internal malleolar)

Medial calcanean rami (O. T. internal calcanean)

Network of heel

Medial plantar artery (O. T. internal plantar)

Deep ramus



Ramus superficialis  
A. plantaris lateralis

Arcus plantaris

Aa. metatarsae plantares

Rami perforantes

Aa. digitales plantares

## Venae

### Venae pulmonales

Vv. pulmonales dextrae

Vv. pulmonales sinistrae

### Vv. cordis

Sinus coronarius

V. cordis magna

V. posterior ventriculi sinistri

V. obliqua atrii sinistri [Marshalli]

Lig. v. cauae sinistrae

V. cordis media

V. cordis parva

Vv. cordis anteriores

Vv. cordis minimae

### Vena cava superior

#### Vv. anonymae dextra et sinistra

Vv. thyroideae inferiores

V. thyroidea ima

Plexus thyroideus impar

V. laryngea inferior

Vv. thymicae

Vv. pericardiacae

Vv. phrenicae superiores

Vv. mediastinales anteriores

Vv. bronchiales anteriores

Vv. tracheales

Vv. oesophageae

V. vertebralis

V. cervicalis profunda

V. mammaria interna

Vv. subcutaneae abdominis

V. epigastrica superior

V. intercostalis suprema

### V. jugularis interna

Bulbus venae jugularis superior

V. canaliculi cochleae

Bulbus v. jugularis inferior

Plexus pharyngeus

Vv. pharyngeae

Vv. meningeae

Vv. canalis pterygoidei [Vidii]

V. lingualis

Vv. dorsales linguae

V. sublingualis

V. comitans n. hypoglossi

(Vv. thyroideae superiores)

V. sternocleidomastoidea

V. laryngea superior

### Sinus durae matris

Sinus transversus

Confluens sinuum

Vv. auditivae internae

Sinus occipitalis

Plexus basilaris

Sinus sagittalis superior

Sinus sagittalis inferior

Superficial ramus	Plantar metatarsal arteries (O. T. digital branches)
Lateral plantar artery (O. T. external plantar)	Perforating rami
Plantar arch	Plantar digital arteries (O. T. collateral digital branches)

## Veins

### Pulmonary veins

- Right pulmonary veins
- Left pulmonary veins

### Veins of heart

- Coronary sinus
- Large vein of heart (O. T. great cardiac vein)
- Posterior vein of left ventricle
- Oblique vein of left atrium (O. T. oblique vein of Marshall)
- Ligament of left vena cava (O. T. vestigial fold of Marshall)
- Middle vein of heart
- Small vein of heart
- Anterior veins of heart
- Smallest veins of heart (O. T. Vv. Thebesii)

### Superior vena cava

#### Right and left innominate veins

- Inferior thyroid veins
- Lowest thyroid vein
- Unpaired thyroid plexus
- Inferior laryngeal vein
- Thymic veins
- Pericardiac veins
- Superior phrenic veins
- Anterior mediastinal veins
- Anterior bronchial veins
- Tracheal veins
- Oesophageal veins
- Vertebral vein

- Deep cervical vein
- Internal mammary vein
- Subcutaneous veins of abdomen
- Superior epigastric vein
- Highest intercostal vein (O. T. left superior intercostal vein)

### Internal jugular vein

- Upper bulb of jugular vein
- Vein of canaliculus of cochlea
- Inferior bulb of jugular vein
- Pharyngeal plexus
- Pharyngeal veins
- Meningeal veins
- Veins of the pterygoid canal
- Lingual vein
- Dorsal veins of tongue
- Sublingual vein
- Companion vein to hypoglossal nerve
- Superior thyroid veins
- Sternocleidomastoid vein
- Superior laryngeal vein

### Sinuses of the dura mater

- Transverse sinus (O. T. lateral sinus)
- Confluence of the sinuses (O. T. torcular Herophili)
- Internal auditory veins
- Occipital sinus
- Basilar plexus (O. T. basilar sinus)
- Superior sagittal sinus (O. T. superior longitudinal sinus)
- Inferior sagittal sinus (O. T. inferior longitudinal sinus)

Sinus rectus  
 Sinus petrosus inferior  
 Sinus petrosus superior  
 Sinus cavernosus  
 Sinus intercavernosus anterior  
 Sinus intercavernosus posterior  
 Sinus circularis  
 Sinus sphenoparietalis

**Venae diploicae**

V. diploica frontalis  
 V. diploica temporalis anterior  
 V. diploica temporalis posterior  
 V. diploica occipitalis

Emissarium parietale  
 Emissarium mastoideum  
 Emissarium condyloideum  
 Emissarium occipitale  
 Rete canalis hypoglossi  
 Rete foraminis ovalis  
 Plexus venosus caroticus internus

**Venae cerebri**

Vv. cerebri superiores  
 V. cerebri media  
 Vv. cerebri inferiores  
 Vv. cerebelli superiores  
 Vv. cerebelli inferiores  
 Vv. cerebri internae

V. cerebri magna [Galen]

V. septi pellucidi  
 V. terminalis

V. basalis [Rosenthal]  
 V. chorioidea  
 V. ophthalmomeningea

**V. ophthalmica superior**

V. nasofrontalis  
 V. ethmoidalis anterior  
 V. ethmoidalis posterior

V. lacrimalis  
 Vv. musculares  
 Vv. vorticosae  
 Vv. ciliares posteriores  
 Vv. ciliares anteriores  
 V. centralis retinae  
 Vv. episclerales  
 Vv. palpebrales  
 Vv. conjunctivales anteriores  
 Vv. conjunctivales posteriores  
 V. ophthalmica inferior

**V. facialis communis**

**V. facialis anterior**

V. angularis  
 Vv. frontales  
 V. supraorbitalis  
 V. palpebrales superiores  
 V. nasales externae  
 V. palpebrales inferiores  
 V. labialis superior  
 V. labialis inferior  
 Vv. massetericae  
 Vv. parotideae anteriores  
 V. palatina  
 V. submental

**V. facialis posterior**

Vv. temporales superficiales  
 Vv. auriculares anteriores  
 Vv. parotideae posteriores  
 Vv. articulares mandibulae  
 Vv. tympanicae  
 V. stylomastoidea  
 V. transversa faciei  
 V. temporalis media  
 Plexus pterygoideus  
 Vv. meningea mediae  
 Vv. temporales profundae  
 V. thyreoidea superior

**V. jugularis externa**

V. occipitalis

Straight sinus  
 Inferior petrosal sinus  
 Superior petrosal sinus  
 Cavernous sinus  
 Anterior intercavernous sinus  
 Posterior intercavernous sinus  
 Circular sinus  
 Sphenoparietal sinus (O. T. sinus alae parvae)  
 Diploic veins  
     Frontal diploic vein  
     Anterior temporal diploic vein  
     Posterior temporal diploic vein  
     Occipital diploic vein  
 Parietal emissary  
 Mastoid emissary  
 Condylloid emissary  
 Occipital emissary  
 Network of hypoglossal canal  
 Network of oval foramen  
 Venous plexus of internal carotid

**Cerebral veins**

Superior cerebral veins  
 Middle cerebral vein  
 Inferior cerebral veins  
 Superior cerebellar veins  
 Inferior cerebellar veins  
 Internal cerebral veins (O. T. veins of Galen)  
 Large vein of cerebrum (O. T. vena magna Galeni)  
 Vein of septum pellucidum  
 Terminal vein (O. T. vein of the corpus striatum)  
 Basal vein (O. T. basilar vein)  
 Chorioid vein  
 Ophthalmomeningeal vein

**Superior ophthalmic vein**

Nasofrontal vein  
 Anterior ethmoidal vein  
 Posterior ethmoidal vein

Lacrimal vein  
 Muscular veins  
 Vortex veins  
 Posterior ciliary veins  
 Anterior ciliary veins  
 Central vein of retina  
 Episcleral veins  
 Palpebral veins  
 Anterior conjunctival veins  
 Posterior conjunctival veins  
 Inferior ophthalmic vein

**Common facial vein**

**Anterior facial vein**

Angular vein  
 Frontal veins  
 Supraorbital vein  
 Superior palpebral veins  
 External nasal veins  
 Inferior palpebral veins  
 Vein of upper lip  
 Vein of lower lip  
 Masseteric veins  
 Anterior parotid veins  
 Palatine vein  
 Submental vein

**Posterior facial vein**

Superficial temporal veins  
 Anterior auricular veins  
 Posterior parotid veins  
 Articular mandibular veins  
 Tympanic veins  
 Styломastoid vein  
 Transverse vein of face  
 Middle temporal vein  
 Pterygoid plexus  
 Middle meningeal veins  
 Deep temporal veins  
 Superior thyroid vein

**External jugular vein**

Occipital vein

V. auricularis posterior  
 V. jugularis anterior  
 Arcus venosus juguli  
 (V. mediana colli)  
 V. transversa scapulae

### V. subclavia

V. thoracoacromialis  
 Vv. transversae colli

### V. axillaris

V. thoracalis lateralis  
 Vv. costoaxillares  
 Vv. thoracoepigastricae  
 Plexus venosus mamillae  
 Vv. brachiales  
 Vv. radiales  
 Vv. ulnares  
 V. cephalica  
 V. cephalica accessoria  
 V. basilica  
 V. mediana cubiti  
 (V. mediana antibrachii)  
 (V. mediana basilica)  
 (V. mediana cephalica)  
 Rete venosum dorsale manus  
 Vv. intercapitulares  
 Arcus volaris venosus superficialis  
 Arcus volaris venosus profundus  
 Vv. digitales volares communes  
 Vv. metacarpeae dorsales  
 Vv. metacarpeae volares  
 Vv. digitales volares propriae  
 Arcus venosi digitales

### V. azygos

V. hemiazygos

V. hemiazygos accessoria  
 Vv. intercostales  
 Ramus dorsalis  
 Ramus spinalis  
 Vv. oesophageae  
 Vv. bronchiales posteriores  
 V. lumbalis ascendens  
 Vv. basivertebrales  
 Plexus venosi vertebrales externi  
 Plexus venosi vertebrales anteriores  
 Plexus venosi vertebrales posteriores  
 Plexus venosi vertebrales interni  
 Retia venosa vertebrarum  
 Sinus vertebrales longitudinales  
 Vv. intervertebrales  
 Vv. spinales externae anteriores  
 Vv. spinales externae posteriores  
 Vv. spinales internae

### V. cava inferior

#### Radices parietales

V. phrenica inferior  
 Vv. lumbales

#### Radices viscerales

Vv. hepaticae  
 Vv. renales  
 Vv. suprarenales  
 V. spermatica:  
 V. testicularis  
 V. ovarica  
 Plexus pampiniformis

### Vena portae

V. coronaria ventriculi  
 V. mesenterica superior  
 Vv. intestinales  
 V. gastroepiploica dextra  
 Vv. pancreatica  
 V. ileocolica  
 Vv. colicae dextrae  
 V. colica media  
 Vv. pancreaticoduodenales



Posterior auricular vein  
 Anterior jugular vein  
 Venous jugular arch  
 Median vein of neck  
 Transverse vein of scapula (O. T. suprascapular vein)

**Subclavian vein**

Thoraco-acromial vein (O. T. acromiothoracic, or thoracic axis)  
 Transverse veins of neck (O. T. transversalis colli)

**Axillary vein**

Lateral thoracic vein (O. T. long thoracic)  
 Costo-axillary veins  
 Thoraco-epigastric veins  
 Venous plexus of mammary gland  
 Brachial veins  
 Radial veins  
 Ulnar veins  
 Cephalic vein  
     Accessory cephalic vein  
 Basilic vein  
 Median vein of elbow  
     Median vein of forearm  
     Median basilic vein  
     Median cephalic vein  
 Dorsal venous network of hand  
 Intercapitular veins  
 Superficial venous volar arch  
 Deep venous volar arch  
 Common volar digital veins  
 Dorsal metacarpal veins  
 Volar metacarpal veins  
 Volar digital veins proper  
 Venous arches of digits

**Azygos vein (O. T. vena azygos major)**

Hemiazygos vein (O. T. v. azygos minor inferior)

Accessory hemiazygos vein (O. T. v. azygos minor superior)  
 Intercostal veins  
     Dorsal ramus  
     Spinal ramus  
 Oesophageal veins  
 Posterior bronchial veins  
 Ascending lumbar vein  
 Basivertebral veins  
 External vertebral venous plexuses  
     Anterior vertebral venous plexuses  
     Posterior vertebral venous plexuses  
 Internal vertebral venous plexuses  
     Venous networks of the vertebrae  
 Longitudinal vertebral sinuses  
 Intervertebral veins  
 Anterior external spinal veins  
 Posterior external spinal veins  
 Internal spinal veins

**Inferior vena cava**

**Parietal radicals**

Inferior phrenic vein  
 Lumbar veins

**Visceral radicals**

Hepatic veins  
 Renal veins  
 Suprarenal veins  
 Spermatic vein  
 Testicular vein  
 Ovarian vein  
 Pampiniform plexus

**Portal vein**

Coronary vein of stomach  
 Superior mesenteric vein  
     Intestinal veins  
         Right gastro-epiploic vein  
         Pancreatic veins  
         Ileocolic vein  
         Right colic veins  
         Middle colic vein  
         Pancreaticoduodenal veins

Vv. duodenales  
 V. mesenterica inferior  
 V. colica sinistra  
 Vv. sigmoideae  
 V. haemorrhoidalis superior  
 V. lienalis  
 Vv. gastricae breves  
 V. gastroepiploica sinistra  
 V. cystica

*Vena umbilicalis*

*Ductus venosus [Arantii]*

Vv. parumbilicales [Sappeyi]

### Vena iliaca communis

V. sacralis media

### V. hypogastrica

Vv. glutatae superiores  
 Vv. glutatae inferiores  
 Vv. obturatoriae  
 Vv. sacrales laterales  
 V. iliolumbalis  
 Plexus sacralis anterior  
 Plexus haemorrhoidalis  
 Plexus vesicalis  
 Plexus pudendalis  
 V. dorsalis penis  
 Vv. profundae penis  
 V. dorsalis clitoridis  
 Vv. profundae clitoridis  
 Vv. uterinae  
 Plexus uterovaginalis  
 V. haemorrhoidalis media  
 Vv. haemorrhoidales inferiores  
 Vv. scrotales posteriores

### V. iliaca externa

V. epigastrica inferior  
 V. circumflexa ilium profunda  
 V. femoralis  
 Vv. dorsales penis subcutaneae  
 Vv. scrotales anteriores  
 Vv. pudendae externae  
 V. epigastrica superficialis  
 V. saphena magna  
 V. saphena accessoria  
 V. circumflexa ilium superficialis  
 Vv. circumflexae femoris mediales  
 Vv. circumflexae femoris laterales  
 Vv. comitantes  
 Vv. profundae femoris  
 Vv. perforantes  
 V. saphena parva

V. femoropoplitea  
 Vv. peronaeae  
 Vv. popliteae  
 Vv. tibiales posteriores  
 Vv. tibiales anteriores  
 Rete venosum dorsale pedis  
 Arcus venosus dorsalis pedis  
 Vv. digitales communes pedis  
 Vv. metatarsae dorsales pedis  
 Vv. intercapitulares  
 Rete venosum plantare  
 Arcus venosus plantaris  
 Vv. metatarsae plantares  
 Vv. digitales pedis dorsales  
 Vv. digitales plantares

---

## Systema lymphaticum

### Vasa lymphatica

Vasa lymphatica superficialia

Vasa lymphatica profunda

Truncus jugularis

Duodenal veins  
 Inferior mesenteric vein  
   Left colic vein  
   Sigmoid veins  
   Superior hemorrhoidal vein  
 Splenic vein  
   Short gastric veins  
   Left gastro-epiploic vein  
   Cystic vein  
*Umbilical vein*  
*Venous duct of Arantius*  
 Paraumbilical veins

**Common iliac vein**

Middle sacral vein

**Hypogastric vein (O. T. internal iliac vein)**

Superior gluteal veins  
 Inferior gluteal veins  
 Obturator veins  
 Lateral sacral veins  
 Iliolumbar vein  
 Anterior sacral plexus  
 Hemorrhoidal plexus  
 Vesical plexus  
 Pundental plexus  
 Dorsal vein of penis  
 Deep veins of penis  
 Dorsal veins of clitoris  
 Deep veins of clitoris  
 Uterine veins  
 Uterovaginal plexus  
 Middle hemorrhoidal vein  
 Inferior hemorrhoidal veins  
 Posterior scrotal veins

**External iliac veins**

Inferior epigastric vein (O. T. deep epigastric)  
 Deep circumflex iliac vein  
 Femoral vein  
 Subcutaneous dorsal veins of penis  
 Anterior scrotal veins  
 External pundental veins  
 Superficial epigastric veins  
 Large saphenous vein (O. T. internal saphenous)  
 Accessory saphenous vein  
 Superficial circumflex iliac vein  
 Medial circumflex veins of thigh  
 Lateral circumflex veins of thigh  
 Accompanying veins  
 Deep veins of thigh  
 Perforating veins  
 Small saphenous vein (O. T. external saphenous vein)  
   Femoropopliteal vein  
 Peroneal veins  
 Popliteal veins  
 Posterior tibial veins  
 Anterior tibial veins  
 Dorsal venous network of foot  
 Dorsal venous arch of foot  
 Common digital veins of foot  
 Dorsal metatarsal veins of foot  
 Intercapitular veins  
 Plantar venous network  
 Plantar venous arch  
 Plantar metatarsal veins  
 Dorsal digital veins of foot  
 Plantar digital veins

---

**Lymphatic system**

**Lymphatic vessels**

Superficial lymphatic vessel

Deep lymphatic vessel  
 Jugular trunk

Truncus subclavius  
 Truncus bronchomediastinalis dexter  
 Ductus lymphaticus dexter

### Ductus thoracicus

Trunci lumbales  
 Truncus intestinalis  
 Cisterna chyli

### Lymphoglandulae

Vasa afferentia  
 Vasa efferentia  
 Substantia corticalis  
 Substantia medullaris  
 Hilus  
 Lymphoglandulae occipitales  
 " auriculares posteriores  
 " auriculares anteriores  
 " submaxillares  
 " faciales profundae  
 " parotideae  
 " cervicales superficiales  
 " cervicales profundae superiores  
 " cervicales profundae inferiores  
 " linguales  
 " axillares  
 " subscapulares  
 " pectorales  
 " epigastricae  
 " cubitales superficiales  
 " cubitales profundae  
 " tracheales

Lymphoglandulae bronchiales  
 " intercostales  
 " mediastinales posteriores  
 " mediastinales anteriores  
 " sternales  
 " iliaca  
 " lumbales  
 " coelicae  
 " gastricae superiores  
 " gastricae inferiores  
 " hepaticae  
 " pancreaticolienales  
 " mesentericae  
 " mesocolicae  
 " hypogastricae  
 " sacrales  
 " inguinales  
 " subinguinales superficiales  
 " subinguinales profundae  
 " popliteae  
 (Lymphoglandula tibialis anterior)

### Plexus lymphatici

Plexus jugularis  
 Plexus axillaris  
 Plexus mammarius  
 Plexus lumbalis  
 Plexus aorticus  
 Plexus sacralis medius  
 Plexus hypogastricus  
 Plexus coeliacus  
 Plexus iliacus externus  
 Plexus inguinalis

Subclavian trunk  
 Right bronchomediastinal trunk  
 Right lymphatic trunk

**Thoracic duct**

Lumbar trunks  
 Intestinal trunk  
 Chyle-cistern (O. T. receptaculum  
 . chyli)

**Lymph glands**

Afferent vessels  
 Efferent vessels  
 Cortical substance  
 Medullary substance  
 Hilus  
 Occipital lymph glands  
 Posterior auricular lymph glands  
 Anterior auricular lymph glands  
 Submaxillary lymph glands  
 Deep facial lymph glands  
 Parotid lymph glands  
 Superficial cervical lymph glands  
 Upper deep cervical lymph glands  
 Lower deep cervical lymph glands  
 Lingual lymph glands  
 Axillary lymph glands  
 Subscapular lymph glands  
 Pectoral lymph glands  
 Epigastric lymph glands  
 Superficial lymph glands of elbow  
 Deep lymph glands of elbow  
 Tracheal lymph glands

Bronchial lymph glands  
 Intercostal lymph glands  
 Posterior mediastinal lymph glands  
 Anterior mediastinal lymph glands  
 Sternal lymph glands  
 Iliac lymph glands  
 Lumbar lymph glands  
 Coeliac lymph glands  
 Superior gastric lymph glands  
 Inferior gastric lymph glands  
 Hepatic lymph glands  
 Pancreaticolienal lymph glands  
 Mesenteric lymph glands  
 Mesocolic lymph glands  
 Hypogastric lymph glands  
 Sacral lymph glands  
 Inguinal lymph glands  
 Superficial subinguinal lymph glands  
 Deep subinguinal lymph glands  
 Popliteal lymph glands  
 Anterior tibial lymph glands

**Lymphatic plexuses**

Jugular plexus  
 Axillary plexus  
 Mammary plexus  
 Lumbar plexus  
 Aortic plexus  
 Middle sacral plexus  
 Hypogastric plexus  
 Coeliac plexus  
 External iliac plexus  
 Inguinal plexus



## Neurologia

Nervus	Nuclei originis
Ganglion	Nuclei terminales
Substantia alba	Ramus communicans
Substantia grisea	Ramus anastomoticus
Substantia gelatinosa	Ramus muscularis
Taenia telarum	Nervus cutaneus
Ependyma ventriculorum	Nervus articularis
Sulcus limitans ventriculorum	Plexus nervorum spinalium
Nuclei nervorum cerebralium	

---

## Systema nervorum centrale

### Medulla spinalis

Pars cervicalis  
 Intumescencia cervicalis  
 Pars thoracalis  
 Pars lumbalis  
 Intumescencia lumbalis  
 Conus medullaris  
 Filum terminale  
 Ventriculus terminalis  
 Fissura mediana anterior  
 Sulcus medianus posterior  
 Sulcus lateralis anterior  
 Sulcus lateralis posterior  
 Sulcus intermedius posterior  
  
 (Sulcus intermedius anterior)  
 Funiculi medullae spinalis  
     Funiculus anterior  
     Funiculus lateralis  
     Funiculus posterior

### Sectiones medullae spinalis

Canalis centralis  
 Substantia grisea centralis  
 Commissura anterior alba  
 Commissura anterior grisea  
 Commissura posterior  
 Columnae griseae:  
     Columna anterior  
     Columna lateralis  
     Columna posterior  
  
     Cervix columnae posterioris  
     Apex columnae posterioris  
     Substantia gelatinosa [Rolandi]  
     Nucleus dorsalis [Stillingii, Clarkii]  
  
 Formatio reticularis  
 Funiculus anterior  
     Fasciculus cerebrospinalis anterior  
         [pyramidalis anterior]

## Neurology

Nerve	Nuclei of origin
Ganglion	End-nuclei
White matter	Communicating ramus
Gray matter	Anastomotic ramus
Gelatinous substance	Muscular ramus
Band of the telae ("web")	Cutaneous nerve
Ependyma ("cover") of ventricles	Articular nerve
Limiting sulcus of the ventricles	Plexus of spinal nerves
Nuclei of the cerebral nerves	

---

## Central nervous system

### Spinal cord

Cervical portion  
 Cervical enlargement  
 Thoracic portion (O. T. dorsal part)  
 Lumbar portion  
 Lumbar enlargement  
 Medullary cone  
 Terminal thread  
 (Swelling due to) terminal ventricle  
 Anterior median fissure  
 Posterior median sulcus  
 Anterior lateral sulcus  
 Posterior lateral sulcus  
 Posterior intermediate sulcus (O. T. paramedian furrow)  
 Anterior intermediate sulcus  
 Funiculi of spinal cord  
     Anterior funiculus  
     Lateral funiculus  
     Posterior funiculus

### Transverse sections of the spinal cord

Central canal  
 Central gray matter  
 Anterior white commissure  
 Anterior gray commissure  
 Posterior commissure  
 Gray columns  
 Anterior column (O. T. anterior horn)  
 Lateral column (O. T. lateral horn)  
 Posterior column (O. T. posterior horn)  
     Neck of posterior column  
     Apex of posterior column  
     Gelatinous substance of Rolando  
     Dorsal nucleus (O. T. Clark's column)  
 Reticular formation  
 Anterior funiculus  
     Anterior cerebrospinal or pyramidal fasciculus (O. T. direct pyramidal tract)

Fasciculus anterior proprius [Flechsigi]	Fasciculus anterolateralis superficialis [Gowersi]
Funiculus lateralis	Fasciculus lateralis proprius [Flechsigi]
Fasciculus cerebrospinalis lateralis [pyramidalis lateralis]	Funiculus posterior
Fasciculus cerebellospinalis	Fasciculus gracilis [Golli]
	Fasciculus cuneatus [Burdachi]

## Encephalon

### Rhombencephalon

#### Myelencephalon

#### Medulla oblongata

Fissura mediana posterior  
 Fissura mediana anterior  
 Foramen caecum  
 Pyramis [medullae oblongatae]  
 Decussatio pyramidum  
 Sulcus lateralis anterior  
 Sulcus lateralis posterior  
 Oliva  
 Corpus restiforme  
  
 Funiculus lateralis  
 Funiculus cuneatus  
  
 Tuberculum cinereum  
 Funiculus gracilis  
  
 Clava  
 Fibrae arcuatae externae

#### Sectiones medullae oblongatae

Raphe  
 Stratum nucleare  
 Nucleus n. hypoglossi  
 Nucleus ambiguus  
 Nucleus alae cinereae

Tractus solitarius  
  
 Nucleus tractus solitarii  
 Tractus spinalis n. trigemini  
  
 Nucleus tractus spinalis n. trigemini  
  
 Nucleus funiculi gracilis  
  
 Nucleus funiculi cuneati  
  
 Nuclei laterales  
 Nucleus olivaris inferior  
 Hilus nuclei olivaris  
 Nucleus olivaris accessorius medialis  
 Nucleus olivaris accessorius dorsalis  
 Nuclei arcuati  
 Fibrae arcuatae internae  
 Substantia reticularis grisea  
 Substantia reticularis alba  
 Fasciculus longitudinalis medialis

Stratum interolivare lemnisci  
 Decussatio lemniscorum

Corpus restiforme

Proper anterior fasciculus (O. T. anterior ground bundle)	Superficial anterolateral fasciculus (O. T. Gowers' tract)
Lateral funiculus	Proper lateral fasciculus (O. T. lateral ground bundle)
Lateral cerebrospinal or pyramidal fasciculus (O. T. crossed pyramidal tract)	Posterior funiculus
Cerebellospinal fasciculus (O. T. direct cerebellar tract of Flechsig)	Slender fasciculus (O. T. column or tract of Goll)
	Wedge-shaped fasciculus (O. T. column or tract of Burdach)

## Brain

### Lozenge-shaped brain

#### Medullary or after-brain

##### O b l o n g m e d u l l a

Posterior median fissure	Solitary tract (O. T. respiratory bundle)
Anterior median fissure	Nucleus of solitary tract
Blind foramen	Spinal tract of trigeminal nerve (O. T. ascending root of trigeminal nerve)
Pyramid of medulla oblongata	Nucleus of spinal tract of trigeminal nerve
Decussation of pyramids	Nucleus of slender funiculus (O. T. nucleus of Goll's column)
Anterior lateral sulcus	Nucleus of wedge-shaped funiculus (O. T. nucleus of Burdach's column)
Posterior lateral sulcus	Lateral nuclei
Olive (O. T. olivary eminence)	Inferior olivary nucleus
Restiform body (O. T. inferior cerebellar peduncle)	Hilus of olivary nucleus
Lateral funiculus	Medial accessory olivary nucleus
Cuneate funiculus (O. T. column of Burdach)	Dorsal accessory olivary nucleus
Gray or ashen tubercle	Arcuate nuclei
Slender funiculus (O. T. column of Goll)	Internal arcuate fibres
Club	Gray reticular substance
External arcuate fibres (O. T. superficial arcuate fibres)	White reticular substance
	Medial longitudinal fasciculus (O. T. posterior longitudinal bundle)
<b>Transverse sections of medulla oblongata</b>	Interolivary layer of lemniscus
Median raphe	Decussation of lemniscus or fillet (O. T. sensory decussation of medulla oblongata)
Nuclear layer	Restiform body (O. T. inferior cerebellar peduncle)
Nucleus of hypoglossal nerve	
Ambiguous nucleus	
Nucleus of ala cinerea	

Fasciculi corporis restiformis  
 Fibrae cerebelloolivares  
 Fasciculi pyramidales  
 Fibrae arcuatae externae

### Ventriculus quartus

Fossa rhomboidea  
 Pars inferior fossae rhomboideae  
 [Calamus scriptorius]  
 Pars intermedia fossae rhomboideae  
 Recessus lateralis fossae rhom-  
 boideae  
 Pars superior fossae rhomboideae  
 Sulcus limitans [fossae rhomboideae]  
 Fovea inferior  
 Fovea superior  
 Trigonum n. hypoglossi  
 Striae medullares  
 Eminentia medialis

Colliculus facialis  
 Ala cinerea  
 Area acustica

### Locus caeruleus

Tegmen ventriculi quarti  
 Velum medullare posterius  
 Taenia ventriculi quarti

### Obex

Lamina chorioidea epithelialis  
 (Apertura medialis ventriculi quarti  
 [Foramen Magendii])  
 (Apertura lateralis ventriculi quarti)  
 Fastigium

### Metencephalon

#### Pons [Varolii]

Sulcus basilaris  
 Fasciculus obliquus [pontis]  
 (Fila lateralia pontis)  
 Brachium pontis

### Sectiones pontis

#### Pars dorsalis pontis

Raphe  
 Nucleus n. abducentis

Nuclei motorii n. trigemini

Radix descendens [mesencephalica]  
 n. trigemini

Tractus spinalis n. trigemini

Nucleus tractus spinalis n. trigemini

Nucleus n. facialis

Radix n. facialis

Pars prima

Genu [internum]

Pars secunda

Nuclei n. acustici

Nuclei n. cochlearis

Nuclei n. vestibularis

Nucleus olivaris superior

Nucleus lemnisci lateralis

Fasciculus longitudinalis medialis

Formatio reticularis

Corpus trapezoideum

Lemniscus

Lemniscus medialis [sensitivus]

Lemniscus lateralis [acusticus]

Pars basilaris pontis

Fibrae pontis profundae

Fasciculi longitudinales [pyramidales]

Nuclei pontis

Fibrae pontis superficiales

### Cerebellum

Gyri cerebelli

Sulci cerebelli

Vallecula cerebelli

Incisura cerebelli anterior

Incisura cerebelli posterior



Fasciculi of restiform body  
 Cerebello-olivary fibres  
 Pyramidal fasciculi  
 External arcuate fibres

#### Fourth ventricle

Rhomboid fossa  
 Inferior part of rhomboid fossa  
 Writing pen  
 Intermediate part of rhomboid fossa  
 Lateral recess of rhomboid fossa

Superior part of rhomboid fossa  
 Limiting groove of rhomboid fossa  
 Inferior pit  
 Superior pit  
 Trigone of hypoglossal nerve  
 Medullary striae  
 Medial eminence (O. T. eminentia teres)  
 Facial hillock  
 Ash-like wing (O. T. trigonum vagi)  
 Acoustic area (O. T. trigonum acustici)  
 Blue place  
 Roof of fourth ventricle  
 Posterior medullary velum  
 Taenia of fourth ventricle: junction of epithelial part of roof with compact nerve substance  
 Bar  
 Epithelial chorioid layer  
 Median aperture of fourth ventricle (foramen of Magendie)  
 Lateral aperture of fourth ventricle  
 Fastigium: "summit of roof"

#### Hind-brain

Pons ("bridge") Varolii  
 Basilar groove  
 Oblique bundle of pons  
 Lateral fibres of pons  
 Brachium ("arm") of pons

#### Sections of the pons

Dorsal part of pons  
 Median raphe  
 Nucleus of the abducent nerve (O. T. nucleus of sixth nerve)  
 Motor nuclei of the trigeminal nerve  
 Descending or mesencephalic root of trigeminal nerve  
 Spinal tract of trigeminal nerve  
 Nucleus of spinal tract of trigeminal nerve  
 Nucleus of facial nerve  
 Root of facial nerve  
 First part  
 Internal knee  
 Second part  
 Nuclei of acoustic nerve (O. T. auditory nucleus)  
 Nuclei of cochlear nerve  
 Nuclei of vestibular nerve  
 Superior olivary nucleus  
 Nucleus of lateral lemniscus  
 Medial longitudinal fasciculus (O. T. posterior longitudinal bundle)  
 Reticular formation  
 Trapezoid body  
 Fillet or lemniscus  
 Medial (sensory) fillet  
 Lateral (acoustic) fillet  
 Basilar part of pons  
 Deep fibres of pons  
 Longitudinal pyramidal fasciculi  
 Nuclei of pons  
 Superficial fibres of pons  
 Cerebellum, or small brain  
 Convolutions of cerebellum  
 Sulci of cerebellum  
 Cerebellar vallicula  
 Anterior notch of cerebellum (O. T. semilunar notch)  
 Posterior notch of cerebellum (O. T. marsupial notch)

Sulcus horizontalis cerebelli

Fissura transversa cerebelli

~~Vermis~~

Lingula cerebelli

Vincula lingulae cerebelli

Lobulus centralis

Monticulus

Culmen

Declive

Folium vermis

Tuber vermis

Pyramis [vermis]

Uvula [vermis]

Nodulus

Hemisphaerium cerebelli

Facies superior

Ala lobuli centralis

Lobulus quadrangularis

Pars anterior

Pars posterior

Lobulus semilunaris superior

Facies inferior

Lobulus semilunaris inferior

Lobulus gracilis

Lobulus biventer

Tonsilla cerebelli

Flocculus

(Flocculi secundarii)

Pedunculus flocculi

Nidus avis

**Sectiones cerebelli**

Corpus medullare

Laminae medullares

Arbor vitae

Substantia corticalis

[Lamina basalis]

[Stratum cinereum]

[Stratum gangliosum]

[Stratum granulosum]

Nucleus dentatus

Hilus nuclei dentati

Nucleus fastigii

Nucleus globosus

Nucleus emboliformis

Capsula nuclei dentati

**Isthmus rhombencephali**

Brachium conjunctivum [cerebelli]

Lemniscus

Lemniscus lateralis

Lemniscus medialis

Trigonum lemnisci

Velum medullare anterius

Frenulum veli medullaris anterioris

**Sectiones isthmi**

[vide Pedunculus cerebri]

Ganglion interpedunculare

Nucleus n. trochlearis

**Cerebrum**

Facies convexa cerebri

Facies medialis cerebri

Basis cerebri

**Mesencephalon**

[Facies inferior]

Fossa interpeduncularis [Tarinii]

Horizontal sulcus of cerebellum (O. T. great horizontal fissure)	<b>Sections of cerebellum</b>
Transverse fissure of cerebellum	Medullary body
Vermis ("worm")	Medullary laminae
Lingua ("tongue") of cerebellum	Arbor vitae ("tree of life")
Vincula of the lingua	Cortical substance
Central lobule (O. T. lobus centralis)	Basal lamina
Monticulus ("little mountain")	Gray layer
Culmen ("summit")	Ganglion-cell layer
Declive ("slope or descent")	Granular layer
Folium of vermis ("leaflet of worm") (O. T. folium cacuminis)	Dentate nucleus
Tuber of vermis (O. T. tuber valvulus)	Hilus of dentate nucleus
Pyramid of vermis	Nucleus of fastigium ("roof")
Uvula of vermis	Spherical nucleus
Nodule	Emboliform nucleus (O. T. cork or plug)
Hemisphere of cerebellum	Capsule of dentate nucleus
Superior surface	<b>Isthmus of rhombencephalon</b>
Wing of central lobule	Brachium conjunctivum ("connecting arm") of cerebellum (O. T. superior cerebellar peduncle)
Quadrangular lobule (O. T. quadrate lobule)	Fillet or ribbon
Anterior part	Lateral fillet
Posterior part	Medial fillet (O. T. ribbon of Reil)
Superior semilunar lobule (O. T. posterior crescentic lobule)	Trigone of fillet
Inferior surface	Anterior medullary velum (O. T. valve of Vieussens)
Inferior semilunar lobule (O. T. postero-inferior lobule)	Frenulum ("check-rein") of anterior medullary velum)
Slender lobule	<b>Sections of isthmus</b>
Biventral lobule	[See <i>Cerebral peduncle</i> ]
Tonsil of cerebellum	Interpeduncular ganglion
Flocculus ("wool-tuft-like body")	Nucleus of trochlear nerve
Secondary flocculi	
Peduncle of flocculus	
Nidus avis ("bird's nest")	

---

## Cerebrum (large brain)

Convex surface of cerebrum  
 Medial surface of cerebrum  
 Base of cerebrum

**Midbrain**  
 Inferior surface  
 Interpeduncular fossa

Recessus anterior  
 Recessus posterior  
 Substantia perforata posterior

### Pedunculus cerebri

Aquaeductus cerebri [Sylvii]

Sulcus lateralis  
 Sulcus n. oculomotorii

#### Sectiones pedunculi cerebri

Tegmentum  
 Stratum griseum centrale  
 Formatio reticularis  
 Fasciculus longitudinalis medialis

Radix descendens n. trigemini  
 Nucleus radices descendentes n. tri-  
 gemini  
 Nucleus n. oculomotorii

Nuclei tegmenti  
 Nucleus ruber  
 Decussationes tegmentorum  
 Decussatio brachii conjunctivi

Lemniscus lateralis  
 Lemniscus medialis  
 Substantia nigra  
 Basis pedunculi

### Corpora quadrigemina

Lamina quadrigemina  
 Colliculus superior

Colliculus inferior

Brachium quadrigeminum superius  
 Brachium quadrigeminum inferius  
**Sectiones corporum quadrigeminorum**  
 Stratum zonale  
 Stratum griseum colliculi superioris

Nucleus colliculi inferioris  
 Stratum album profundum

### Prosencephalon

#### Diencephalon

Ventriculus tertius  
 Aditus ad aquaeductum cerebri

Commissura posterior [cerebri]  
 Foramen interventriculare [Monroi]  
 Sulcus hypothalamicus [Monroi]  
 Massa intermedia

Recessus opticus  
 Recessus infundibuli  
 Commissura anterior [cerebri]  
 Recessus triangularis

### Hypothalamus

Pars mamillaris hypothalami

Corpus mamillare  
 Pars optica hypothalami

Tuber cinereum  
 Infundibulum  
 Hypophysis  
 Lobus anterior  
 Lobus posterior

Tractus opticus  
 Radix medialis  
 Radix lateralis  
 Chiasma opticum  
 Lamina terminalis

#### Sectiones hypothalami

Nucleus hypothalamicus [Corpus  
 Luysi]  
 Pars grisea hypothalami  
 Commissura superior [Meynerti]  
 Commissura inferior [Guddeni]  
 Nuclei corporis mamillaris

Anterior recess  
 Posterior recess  
 Posterior perforated substance  
 Peduncle of cerebrum  
 (O. T. crus cerebri)  
 Aqueduct of cerebrum (O. T. iter e  
 tertio ad quartum ventriculum)  
 Lateral sulcus  
 Sulcus of oculomotor nerve

#### Sections of cerebral peduncle

Tegmentum ("cover")  
 Central gray layer  
 Reticular formation  
 Medial longitudinal fasciculus (O. T.  
 posterior longitudinal bundle)  
 Descending root of trigeminal nerve  
 Nucleus of descending root of trigemi-  
 nal nerve  
 Nucleus of oculomotor nerve (O. T. nu-  
 cleus of III. nerve)  
 Nuclei of tegmentum  
 Red nucleus  
 Decussations of tecta  
 Decussation of brachium conjunc-  
 tivum  
 Lateral fillet  
 Medial fillet  
 Black substance  
 Base of peduncle  
 Quadrigeminal bodies (O.  
 T. optic lobes)  
 Quadrigeminal layer  
 Superior hillock (O. T. anterior body  
 or nates)  
 Inferior hillock (O. T. posterior body  
 or testis)  
 Superior quadrigeminal brachium  
 Inferior quadrigeminal brachium

#### Sections of quadrigeminal bodies

Zonal layer  
 Gray layer of superior colliculus

Nucleus of inferior colliculus  
 Deep white layer

#### Forebrain

#### Interbrain

Third ventricle  
 Entrance to the aqueduct of the cere-  
 brum  
 Posterior commissure of the cerebrum  
 Interventricular foramen of Monroe  
 Hypothalamic sulcus of Monroe  
 Intermediate mass (O. T. middle, or  
 soft, or gray, commissure)  
 Optic recess  
 Recess of infundibulum  
 Anterior commissure of cerebrum  
 Triangular recess

#### Hypothalamus (O. T. subthalamic region)

Mammillary part of hy-  
 pothalamus  
 Mammillary body  
 Optic part of hypothala-  
 mus  
 Tuber cinereum ("ash-like tuber")  
 Infundibulum ("funnel")  
 Hypophysis (O. T. pituitary body)  
 Anterior lobe  
 Posterior lobe  
 Optic tract  
 Medial root  
 Lateral root  
 Optic chiasm  
 Terminal lamina

#### Sections of hypothalamus

Hypothalamic nucleus, or Luy's body  
 (O. T. subthalamic nucleus)  
 Gray part of hypothalamus  
 Superior commissure of Meynert  
 Inferior commissure of v. Gudden  
 Nuclei of mammillary body



Fasciculus thalamomamillaris [Vicq'  
d'Azyri]

Fasciculi pedunculomamillares

Pars tegmentalis

Pars basilaris

Ansa peduncularis

Ansa lenticularis

Pedunculus thalami inferior

### Thalamencephalon

#### Thalamus

Pulvinar

Tuberculum anterius thalami

Taenia thalami

Stria medullaris

Lamina chorioidea epithelialis

#### Metathalamus

Corpus geniculatum mediale

Corpus geniculatum laterale

#### Epithalamus

Corpus pineale

Recessus pinealis

Recessus suprapinealis

Habenula

Commissura habenularum

Trigonum habenulae

#### Sectiones thalamencephali

Stratum zonale

Nucleus anterior thalami

Nucleus medialis thalami

Nucleus lateralis thalami

Laminae medullares thalami

Nucleus corporis geniculati medialis

Nucleus corporis geniculati lateralis

Nucleus habenulae

Fasciculus retroflexus [Meynerti]

### Telencephalon

#### Hemisphaerium

#### Pallium

Fissura longitudinalis cerebri

Fissura transversa cerebri

Gyri cerebri

Gyri profundi

Gyri transitivi

Sulci cerebri

Impressio petrosa

Fossa cerebri lateralis [Sylvii]

Fissura cerebri lateralis [Sylvii]

Ramus posterior

Ramus anterior ascendens

Ramus anterior horizontalis

Lobus cerebri

Insula

Gyri insulae

Gyrus longus insulae

Gyri breves insulae

Sulcus circularis [Reili]

Operculum

Pars frontalis

Pars parietalis

Pars temporalis

Sulcus centralis [Rolandi]

Gyrus centralis anterior

Gyrus centralis posterior

Lobus frontalis

Polus frontalis

Sulcus praecentralis

Gyrus frontalis superior

Sulcus frontalis superior

Gyrus frontalis medius

Pars superior

Pars inferior

Sulcus frontalis inferior

Thalamomammillary fasciculus (O.  
T. bundle of Vicq d'Azyr)  
Pedunculomammillary fasciculi  
Tegmental part  
Basilar part  
Peduncular loop  
Lenticular loop  
Inferior peduncle of thalamus

### Thalamic brain

Thalamus ("bed") (O. T. optic thalamus)  
Pulvinar ("cushion")  
Anterior tubercle of thalamus  
Thalamic taenia  
Medullary stria (O. T. stria fornicis or stria pinealis)  
Epithelial chorioid layer

### Metathalamus

Medial geniculate body (O. T. internal geniculate body)  
Lateral geniculate body (O. T. external geniculate body)

### Epithalamus

Pineal body (O. T. conarium, or epiphysis cerebri)  
Pineal recess  
Suprapineal recess  
Habenula ("strap") (O. T. peduncle of the pineal body)  
Commissure of the habenula  
Trigone of the habenula

### Sections of the thalamic brain

Zonal layer  
Anterior nucleus of thalamus  
Medial nucleus of thalamus  
Lateral nucleus of thalamus  
Medullary layers of thalamus  
Nucleus of medial geniculate body  
Nucleus of lateral geniculate body  
Nucleus of habenula  
Retroflex fasciculus

### End-brain

### Hemisphere

### Brain mantle

Longitudinal fissure of cerebrum  
Transverse fissure of cerebrum  
Convolutions of cerebrum  
Deep convolutions  
Transitional convolutions (O. T. annectant gyri)  
Grooves of cerebrum  
Petrosal impression  
Lateral fossa of cerebrum  
Lateral fissure of cerebrum (O. T. fissure of Sylvius)  
Posterior ramus  
Ascending anterior ramus  
Horizontal anterior ramus  
Lobes of cerebrum  
Island (O. T. island of Reil, or central lobe)  
Convolutions of island  
Long convolution of island  
Short convolutions of island  
Circular sulcus of Reil (O. T. limiting sulcus of Reil)  
Operculum ("cover")  
Frontal part  
Parietal part  
Temporal part  
Central sulcus of Rolando (O. T. fissure of Rolando)  
Anterior central convolution  
Posterior central convolution  
Frontal lobe  
Frontal pole  
Precentral sulcus  
Superior frontal convolution  
Superior frontal sulcus  
Middle frontal convolution  
Superior part  
Inferior part  
Inferior frontal sulcus

Gyrus frontalis inferior	<b>Facies medialis hemisphaerii</b>
Pars opercularis	Sulcus corporis callosi
Pars triangularis	
Pars orbitalis	Sulcus cinguli
Gyrus rectus	
Sulcus olfactorius	Pars subfrontalis
Gyri orbitales	Pars marginalis
Sulci orbitales	Sulcus subparietalis
<b>L o b u s t e m p o r a l i s</b>	Fissura hippocampi
Polus temporalis	
Sulci temporales transversi	Gyrus fornicatus
Gyri temporales transversi	
Gyrus temporalis superior	Gyrus cinguli
Sulcus temporalis superior	
	Isthmus gyri fornicati
Gyrus temporalis medius	Gyrus hippocampi
Sulcus temporalis medius	Uncus [gyri hippocampi]
	Substantia reticularis alba [Arnoldi]
Gyrus temporalis inferior	Lobulus paracentralis
	Praecuneus
Sulcus temporalis inferior	Fissura parietooccipitalis
	Fissura calcarina
Fissura collateralis	Cuneus
Gyrus fusiformis	
Gyrus lingualis	<b>C o r p u s c a l l o s u m</b>
<b>L o b u s o c c i p i t a l i s</b>	
Polus occipitalis	Splenium corporis callosi
Sulcus occipitalis transversus	
Gyri occipitales superiores	Truncus corporis callosi
Sulci occipitales superiores	Genu corporis callosi
Gyri occipitales laterales	Rostrum corporis callosi
Sulci occipitales laterales	Lamina rostralis
<b>L o b u s p a r i e t a l i s</b>	Striae transversae
Lobulus parietalis superior	Stria longitudinalis medialis
Sulcus interparietalis	Stria longitudinalis lateralis
	Fasciola cinerea
Lobulus parietalis inferior	
Gyrus supramarginalis	<b>F o r n i x</b>
Gyrus angularis	Crus fornicis

## Inferior frontal convolution

Opercular part

Triangular part

Orbital part

## Straight convolution

Olfactory sulcus

Orbital convolutions

Orbital sulci

## T e m p o r a l l o b e

Temporal pole

Transverse temporal sulci

Transverse temporal convolutions

Superior temporal convolution (O. T. first temporal gyrus)

Superior temporal sulcus (O. T. parallel sulcus, or first temporal sulcus)

Middle temporal convolution (O. T. second temporal gyrus)

Middle temporal sulcus (O. T. second temporal sulcus)

Inferior temporal convolution (O. T. third temporal gyrus)

Inferior temporal sulcus (O. T. occipitotemporal sulcus)

Collateral fissure

Fusiform convolution (O. T. occipitotemporal convolution)

Lingual convolution

O c c i p i t a l l o b e

Occipital pole

Transverse occipital sulcus

Superior occipital convolutions

Superior occipital sulci

Lateral occipital convolutions

Lateral occipital sulci

P a r i e t a l l o b e

Superior parietal lobule

Interparietal sulcus (O. T. intraparietal sulcus of Turner)

Inferior parietal lobule

Supramarginal convolution

Angular convolution

**Medial surface of hemisphere**

Sulcus of corpus callosum (O. T. callosal sulcus)

Sulcus of cingulum (O. T. callosomarginal fissure)

Subfrontal part

Marginal part

Subparietal sulcus

Fissure of hippocampus (O. T. dentate fissure, or fissura dentata)

Fornicate convolution (O. T. limbic or falciform lobe)

Convolution of cingulum (O. T. callosal convolution, or gyrus fornicatus)

Isthmus of fornicate gyrus

Convolution of hippocampus (O. T. hippocampal convolution)

Hook of gyrus hippocampi

White reticular substance of Arnold

Paracentral lobule

Precuneus

Parieto-occipital fissure

Calcarine fissure

Cuneus ("wedge")

C o r p u s c a l l o s u m (great transverse commissure of cerebrum)

Splenum ("bandage") of corpus callosum

Trunk of corpus callosum (O. T. body)

Knee of corpus callosum

Beak of corpus callosum

Rostral lamina

Transverse striae

Medial longitudinal stria

Lateral longitudinal stria

Fasciola cinerea ("ash-like little bandage")

## F o r n i x

Crus of fornix (O. T. posterior pillar of fornix)

- Corpus fornicis  
 Taenia fornicis  
 Columna fornicis
- Pars libera columnae fornicis  
     Pars tecta columnae fornicis  
     Septum pellucidum  
 Lamina septi pellucidi  
 Cavum septi pellucidi
- Ventriculus lateralis
- Pars centralis  
 Cornu anterius  
 Cornu posterius  
 Cornu inferius  
 Corpus striatum  
 Nucleus caudatus  
     Caput nuclei caudati  
     Cauda nuclei caudati  
 Stria terminalis
- Lamina affixa  
 Taenia chorioidea  
 Lamina chorioidea epithelialis  
 Calcar avis
- (Bulbus cornu posterioris)  
 Eminentia collateralis  
     Trigonum collaterale
- Hippocampus
- Fimbria hippocampi  
 Taenia fimbriae  
 Digitationes hippocampi
- Fascia dentata hippocampi
- Commissura hippocampi
- Rhinencephalon
- Sulcus parolfactorius anterior  
 Pars anterior [rhinencephali]
- Lobus olfactorius  
     Bulbus olfactorius  
     Tractus olfactorius  
     Trigonum olfactorium  
     Stria medialis  
     Stria intermedia  
 Area parolfactoria [Brocae]  
 Sulcus parolfactorius posterior  
 Pars posterior [rhinencephali]
- Gyrus subcallosus [Pedunculus corporis callosi]  
     Substantia perforata anterior  
 Stria olfactoria lateralis  
 Limen insulae
- Sectiones telencephali
- Substantia corticalis  
 Centrum semiovale  
 Decursus fibrarum cerebralium
- Fibrae arcuatae cerebri  
     Cingulum  
     Fasciculus longitudinalis superior  
     Fasciculus longitudinalis inferior  
     Fasciculus uncinatus  
     Radiatio corporis callosi  
         Pars frontalis  
         Pars parietalis  
         Pars temporalis  
         Pars occipitalis
- Tapetum  
 Nucleus lentiformis
- Putamen  
     Globus pallidus  
 Claustrum  
 Capsula externa  
 Capsula interna  
     Genu capsulae internae



- Body of fornix  
 Taenia ("ribbon") of fornix  
 Column of fornix (O. T. anterior pillar of fornix)  
   Free part of column of fornix  
   Covered part of column of fornix  
     Transparent septum  
 Layer of septum pellucidum  
 Cavity of septum pellucidum (O. T. fifth ventricle)  
   Lateral ventricle  
 Central part  
 Anterior horn  
 Posterior horn  
 Inferior horn (O. T. descending horn)  
 Striate body  
 Caudate nucleus  
   Head of caudate nucleus  
   Tail of caudate nucleus  
 Terminal stria (O. T. taenia semicircularis)  
 Lamina affixa ("fastened layer")  
 Chorioid taenia  
 Epithelial chorioid layer  
 Calcar avis ("cock's spur") (O. T. hippocampus minor)  
 Bulb of posterior horn  
 Collateral eminence  
   Collateral trigone (O. T. trigonum ventriculi)  
 Hippocampus ("sea-horse") (O. T. hippocampus major, cornu Ammonis, or Ammon's horn)  
 Fimbria ("fringe") of hippocampus  
 Taenia of fimbria  
 Digitations of the hippocampus (O. T. pes hippocampi)  
 Dentate fascia of hippocampus (O. T. gyrus dentatus)  
 Commissure of the hippocampus (O. T. lyra, or lyre of David)  
 Olfactory brain  
 Anterior parolfactory sulcus  
 Anterior part of rhinencephalon  
 Olfactory lobe  
   Olfactory bulb  
   Olfactory tract  
   Olfactory trigone  
   Medial stria  
   Intermediate stria  
 Parolfactory area of Broca  
 Posterior parolfactory sulcus  
 Posterior part of rhinencephalon  
 Subcallosal convolution (peduncle of corpus callosum)  
   Anterior perforated substance  
 Lateral olfactory stria  
 Threshold of island  
   Sections of endbrain  
 Cortical substance  
 Semioval centre  
 Decursus ("running down") of cerebral fibres  
 Arcuate fibres of cerebrum  
   Cingulum ("girdle")  
   Superior longitudinal fasciculus  
   Inferior longitudinal fasciculus  
   Uncinate ("hooked") fasciculus  
   Radiation of corpus callosum  
     Frontal part (forceps minor)  
     Parietal part  
     Temporal part  
     Occipital part (O. T. forceps major)  
     Tapetum ("carpet," or "tapestry")  
 Lentiform nucleus (O. T. lenticular nucleus)  
   Putamen ("shell," or "paring")  
   Globus pallidus ("pale sphere")  
 Claustrum ("bulwark," or "barrier")  
 External capsule  
 Internal capsule  
   Knee of internal capsule

Pars frontalis capsulae internae	Arachnoidea spinalis
	Arachnoidea encephali
Pars occipitalis capsulae internae	Cavum subarachnoideale
	Cisternae subarachnoidales
Nucleus amygdalae	Cisterna cerebellomedullaris
Corona radiata	
Pars frontalis	Cisterna fossae lateralis cerebri
Pars parietalis	[Sylvii]
Pars temporalis	Cisterna chiasmatis
Pars occipitalis	Cisterna interpeduncularis
Radiatio corporis striati	
Radiatio occipitohalamica	Cisterna venae magnae cerebri
[Gratioletii]	Granulationes arachnoideales [Pac-
Commissura anterior [cerebri]	chioni]
Pars anterior	Pia mater spinalis
Pars posterior	
	Lig. denticulatum
	Septum cervicale intermedium
	Pia mater encephali
	Tela chorioidea ventriculi quarti
	Plexus chorioideus ventriculi quarti
	Tela chorioidea ventriculi tertii
	Plexus chorioideus ventriculi tertii
	Plexus chorioideus ventriculi lateralis
	Glomus chorioideum
	Acervulus

### Meninges

---

## Systema nervorum periphericum

### Nervi cerebrales

Nn. olfactorii

N. opticus

N. oculomotorius

Ramus superior

Ramus inferior

Radix brevis ganglii ciliaris

N. trochlearis

Decussatio nervorum trochlearium

Frontal part of internal capsule (O. T. anterior limb)	Arachnoid ("spider-web") of spine
Occipital part of internal capsule (O. T. posterior limb)	Arachnoid ("spider-web") of brain
Amygdaloid ("almond") nucleus	Subarachnoid space
Corona radiata ("radiate crown")	Subarachnoid cisterns
Frontal part	Cerebellomedullary cistern (O. T. cisterna magna)
Parietal part	Cistern of the lateral fossa of the cerebrum
Temporal part	Cistern of the chiasm
Occipital part	Interpeduncular cistern (O. T. cisterna basalis)
Radiation of corpus striatum	Cistern of the great vein of cerebrum
Occipitothalamic radiation (O. T. optic radiation)	Arachnoideal granulations (O. T. Pacchionian bodies)
Anterior commissure of cerebrum	Pia mater of spine (soft membrane of cord)
Anterior part	Denticulate ligament
Posterior part	Intermediate cervical septum

### Membranes

Dura mater of brain	Pia mater of brain (soft membrane of brain)
Falx ("sickle") of cerebrum	Chorioid tela of fourth ventricle (O. T. tela chorioidea inferior)
Tentorium of cerebellum (cerebellar tent)	Chorioid plexus of fourth ventricle
Falx of cerebellum (cerebellar sickle)	Chorioid tela of third ventricle (O. T. velum interpositum, or tela chorioidea superior)
Diaphragm of saddle	Chorioid plexus of third ventricle
Foramen of diaphragm of saddle	Chorioid plexus of lateral ventricle
Notch of tentorium	Chorioid skein
Hard membrane of spine	Brain sand
Thread of spinal dura mater	
Epidural cavity	
Subdural cavity	

---

## System of peripheral nerves

<b>Cerebral nerves</b>	Inferior ramus
<b>Olfactory nerves</b>	Short root of ciliary ganglion (O. T. motor root of lenticular ganglion)
<b>Optic nerve</b>	
<b>Oculomotor nerve (O. T. third nerve)</b>	<b>Trochlear nerve (O. T. patheticus or fourth nerve)</b>
Superior ramus	Decussation of trochlear nerves

**N. trigeminus**

Portio major  
Ganglion semilunare [Gasseri]

Portio minor

**N. ophthalmicus**

N. tentorii  
N. lacrimalis  
Ramus anastomoticus cum n. zygomatiko  
N. frontalis  
  N. supraorbitalis  
  Ramus frontalis  
  N. supratrochlearis  
N. nasociliaris  
  Radix longa ganglii ciliaris  
  Nn. ciliares longi  
  N. ethmoidalis posterior  
  N. ethmoidalis anterior  
  Rami nasales anteriores  
    Rami nasales interni  
    Rami nasales laterales  
    Rami nasales mediales  
    Ramus nasalis externus  
N. infratrochlearis  
  Ramus palpebralis superior  
  R. palpebralis inferior

**G. ciliare**

Nn. ciliares breves

**N. maxillaris**

N. meningeus [medius]  
N. zygomaticus  
  Ramus zygomaticotemporalis  
  Ramus zygomaticofacialis  
Nn. sphenopalatini

Nn. alveolares superiores  
  Rami alveolares superiores posteriores  
N. infraorbitalis  
  R. alveolaris superior medius

Rami alveolares superiores anteriores

Plexus dentalis superior

Rami dentales superiores

Rami gingivales superiores

Rami palpebrales inferiores

Rami nasales externi

Rami nasales interni

Rami labiales superiores

**Ganglion sphenopalatinum**

Rami orbitales

N. canalis pterygoidei [Vidii]

  N. petrosus superficialis major

  N. petrosus profundus

Rami nasales posteriores superiores laterales

Rami nasales posteriores superiores mediales

  N. nasopalatinus [Scarpae]

Rami nasales posteriores inferiores [laterales]

Nn. palatini

  N. palatinus anterior

  N. palatinus medius

  N. palatinus posterior

**N. mandibularis**

N. spinosus

N. masticatorius

  N. massetericus

  Nn. temporales profundi

    N. temporalis profundus posterior

- Trigeminal nerve (O. T. fifth nerve)**
- Larger (sensory) root
  - Semilunar ganglion (O. T. Gasserian ganglion)
  - Smaller (motor) root
- Ophthalmic nerve**
- Nerve to the tentorium
  - Lacrimal nerve
  - Ramus anastomosing with zygomatic nerve
  - Frontal nerve
    - Supraorbital nerve
    - Frontal ramus
    - Supratrochlear nerve
  - Nasociliary nerve (O. T. nasal nerve)
    - Long root of the ciliary ganglion
    - Long ciliary nerves
    - Posterior ethmoidal nerve
    - Anterior ethmoidal nerve
    - Anterior nasal rami
      - Internal nasal rami
        - Lateral nasal rami
        - Medial nasal rami
      - External nasal ramus
  - Infratrochlear nerve
    - Superior palpebral ramus
    - Inferior palpebral ramus
  - Ciliary ganglion (O. T. lenticular or ophthalmic ganglion)
  - Short ciliary nerves
- Maxillary nerve (O. T. superior maxillary)**
- Middle meningeal nerve (O. T. recurrent)
  - Zygomatic nerve (O. T. orbital or temporomalar)
    - Zygomaticotemporal ramus
    - Zygomaticofacial ramus
  - Sphenopalatine nerves
- Superior alveolar nerves
    - Posterior superior alveolar rami (O. T. posterior superior dental)
  - Infraorbital nerve
    - Middle superior alveolar ramus (O. T. middle superior dental)
    - Anterior superior alveolar rami (O. T. anterior superior dental)
      - Superior dental plexus
      - Superior dental rami
      - Superior gingival rami
      - Inferior palpebral rami
      - External nasal rami
      - Internal nasal rami
      - Superior labial rami
  - Sphenopalatine ganglion (O. T. Meckel's ganglion)
    - Orbital rami
    - Nerve of the pterygoid canal, or Vidian nerve
      - Larger superficial petrosal nerve
    - Deep petrosal nerve (O. T. great deep petrosal branch of carotid plexus)
    - Lateral superior posterior nasal rami
    - Medial superior posterior nasal rami
      - Nasopalatine nerve of Scarpa
    - Lateral inferior posterior nasal rami
  - Palatine nerves
    - Anterior palatine nerve
    - Middle palatine nerve (O. T. external palatine)
    - Posterior palatine nerve
  - Mandibular nerve (O. T. inferior maxillary)**
  - Spinosus nerve (O. T. recurrent nerve)
  - Masticator nerve
    - Masseteric nerve
    - Deep temporal nerves
      - Posterior deep temporal nerve



N. temporalis profundus anterior  
 N. buccinatorius  
 N. pterygoideus externus  
 N. pterygoideus internus  
 N. auriculotemporalis  
 N. meatus auditorii externi  
   R. membranae tympani\*  
 Rami parotidei  
 Rami anastomotici cum n. faciali  
 Nn. auriculares anteriores  
 Rami temporales superficiales  
 N. lingualis  
   Rami isthmi faucium  
   Rami anastomotici cum n. hypo-  
     glosso  
   N. sublingualis  
   Rami linguales  
 N. alveolaris inferior  
  
 Plexus dentalis inferior  
   Rami dentales inferiores  
   Rami gingivales inferiores  
 N. mylohyoideus  
 N. mentalis  
   Rami mentales  
   Rami labiales inferiores  
  
   G a n g l i o n o t i c u m  
  
 N. petrosus superficialis minor  
 N. tensoris veli palatini  
  
 N. tensoris tympani  
 Ramus anastomoticus cum n. spinoso  
  
 R. anastomoticus cum n. auriculo-  
   temporali  
 Ramus anastomoticus cum chorda  
   tympani  
 G a n g l i o n s u b m a x i l l a r e  
 Rami communicantes cum n. linguali  
 Rami submaxillares

**N. abducens****N. facialis**

Geniculum n. facialis  
 Ganglion geniculi  
 N. stapedius  
 Ramus anastomoticus cum plexu  
   tympanico  
 N. auricularis posterior  
   Ramus occipitalis  
 Ramus digastricus  
   Ramus stylohyoideus  
 Ramus anastomoticus cum n. glosso-  
   pharyngeo  
 Plexus parotideus  
 Rami temporales  
 Rami zygomatici  
 Rami buccales  
 Ramus marginalis mandibulae  
 Ramus colli  
 N. i n t e r m e d i u s

Chorda tympani

**N. acusticus**

Radix vestibularis  
 Radix cochlearis  
 Fila anastomotica  
 N. v e s t i b u l i  
   Ganglion vestibulare  
   N. utricularis  
   N. ampullaris superior  
   N. ampullaris lateralis  
   N. ampullaris inferior  
 N. c o c h l e a e  
   Ganglion spirale  
   N. saccularis  
  
   **N. glossopharyngeus**  
 Ganglion superius

- Anterior deep temporal nerve  
 Buccinator nerve  
 External pterygoid nerve  
 Internal pterygoid nerve  
 Auriculotemporal nerve  
 Nerve of external auditory meatus  
 Ramus to tympanic membrane  
 Parotid rami  
 Anastomotic rami to the facial nerve  
 Anterior auricular nerves  
 Superficial temporal rami  
 Lingual nerve  
 Rami to the isthmus of the fauces  
 Anastomotic rami to the hypoglossal nerve  
 Sublingual nerve  
 Lingual rami  
 Inferior alveolar nerve (O. T. inferior dental)  
 Inferior dental plexus  
 Inferior dental rami  
 Inferior gingival rami  
 Mylohyoid nerve  
 Mental nerve  
 Rami to chin  
 Rami to lower lip  
 Otic ganglion (O. T. ganglion of Arnold)  
 Lesser superficial petrosal nerve  
 Nerve of tensor muscle of palatine curtain  
 Nerve of tensor muscle of tympanum  
 Anastomotic ramus with spinosus nerve  
 Anastomotic ramus with auriculo-temporal nerve  
 Anastomotic ramus with chorda tympani  
 Submaxillary ganglion  
 Rami communicating with lingual nerve  
 Submaxillary rami
- Abducent nerve (O. T. sixth nerve)**  
**Facial nerve (O. T. seventh nerve)**  
 Knee of the facial nerve  
 Ganglion of the knee (official nerve)  
 Nerve to the stapedius muscle  
 Ramus anastomosing with tympanic plexus (O. T. tympanic branch)  
 Posterior auricular nerve  
 Occipital ramus  
 Digastric ramus  
 Stylohyoid ramus  
 Ramus anastomosing with glossopharyngeal nerve  
 Parotid plexus  
 Temporal rami  
 Zygomatic rami  
 Buccal rami  
 Ramus of margin of jaw  
 Ramus to neck  
 Intermediate nerve (O. T. pars intermedia of Wrisberg, or sensory part of facial nerve)  
 Cord of tympanum  
**Acoustic nerve (O. T. auditory nerve)**  
 Vestibular root  
 Cochlear root  
 Anastomotic fibres  
 Vestibular nerve  
 Vestibular ganglion  
 Utricular nerve  
 Superior ampullar nerve  
 Lateral ampullar nerve  
 Inferior ampullar nerve  
 Nerve of the cochlea  
 Spiral ganglion  
 Saccular nerve
- Glossopharyngeal nerve**  
 Upper ganglion (O. T. jugular ganglion)

- Ganglion petrosum
- N. tympanicus
- Intumescencia tympanica
- Plexus tympanicus [Jacobsoni]
- N. caroticotympanicus superior
- N. caroticotympanicus inferior
- Ramus tubae
- R. anastomoticus cum ramo auriculari  
  n. vagi
- Rami pharyngei
- Ramus stylopharyngeus
- Rami tonsillares
- Rami linguales
- N. vagus**
- Ganglion jugulare
- Ganglion nodosum
- Ramus meningeus
- Ramus auricularis
- R. anastomoticus cum n. glossopharyngeo
- Rami pharyngei
- Plexus pharyngeus
- N. laryngeus superior
- Ramus externus
- Ramus internus
- Ramus anastomoticus cum n. laryngeo inferiore
- Rami cardiaci superiores  
(N. depressor)
- N. recurrens
- Rami cardiaci inferiores
- Rami tracheales
- Rami oesophagei
- N. laryngeus inferior
- Ramus anterior
- Ramus posterior
- Rami bronchiales anteriores
- Rami bronchiales posteriores
- Plexus pulmonalis anterior
- Plexus pulmonalis posterior
- Rami oesophagei
- Plexus oesophageus anterior
- Plexus oesophageus posterior
- Rami gastrici
- Plexus gastricus anterior
- Plexus gastricus posterior
- Rami hepatici
- Rami coeliaci
- Rami lienales
- Rami renales
- N. accessorius**
- Ramus internus
- Ramus externus
- N. hypoglossus**
- Ramus descendens
- Ansa hypoglossi
- Ramus thyreo-hyoideus
- Rami linguales
- N. spinales**
- Fila radicularia
- Radix anterior
- Radix posterior
- Ganglion spinale
- Ramus anterior
- Ramus posterior
- Ramus communicans
- Ramus meningeus
- Cauda equina
- Ansae

- Petrous ganglion (O. T. ganglion of Andersch)
- Tympanic nerve (O. T. Jacobson's nerve)
- Tympanic swelling
- Tympanic plexus
- Superior caroticotympanic nerve
- Inferior caroticotympanic nerve
- Tubal ramus
- Ramus anastomosing with the auricular branch of the vagus
- Pharyngeal rami
- Stylopharyngeal ramus
- Tonsillar rami (O. T. tonsillitic branches)
- Lingual rami (O. T. terminal rami)
- Vagus nerve (O. T. pneumogastric nerve)**
- Jugular ganglion (O. T. ganglion of the root)
- Knotty ganglion (O. T. ganglion of the trunk)
- Meningeal ramus (O. T. recurrent branch)
- Auricular ramus (O. T. Arnold's nerve)
- Ramus anastomosing with glosso-pharyngeal nerve
- Pharyngeal rami
- Pharyngeal plexus
- Superior laryngeal nerve
- External ramus
- Internal ramus
- Ramus anastomosing with inferior laryngeal nerve
- Superior cardiac rami
- Depressor nerve
- Recurrent nerve (O. T. recurrent laryngeal)
- Inferior cardiac rami (O. T. cardiac branches of recurrent laryngeal)
- Tracheal rami
- Oesophageal rami
- Inferior laryngeal nerve
- Anterior ramus
- Posterior ramus
- Anterior bronchial rami
- Posterior bronchial rami
- Anterior pulmonary plexus
- Posterior pulmonary plexus
- Oesophageal rami
- Anterior oesophageal plexus (O. T. plexus gulae)
- Posterior oesophageal plexus (O. T. plexus gulae)
- Gastric rami
- Anterior gastric plexus
- Posterior gastric plexus
- Hepatic rami
- Coeliac rami
- Splenic rami
- Renal rami
- Accessory nerve (O. T. spinal accessory)**
- Internal ramus (O. T. accessory portion)
- External ramus (O. T. spinal portion)
- Hypoglossal nerve**
- Descending ramus
- Loop of the hypoglossus
- Thyreohyoid ramus
- Lingual rami
- Spinal nerves**
- Radicular fibres
- Anterior root
- Posterior root
- Spinal ganglion
- Anterior ramus
- Posterior ramus
- Communicating ramus
- Meningeal ramus
- Cauda equina ("horse's tail")
- Loops

- Nn. cervicales**
- Rami posteriores
- Ramus medialis  
    Ramus lateralis  
N. suboccipitalis
- N. occipitalis major
- (N. occipitalis tertius)
- Rami anteriores
- Plexus cervicalis**
- N. occipitalis minor  
N. auricularis magnus  
    Ramus posterior  
    Ramus anterior  
N. cutaneus colli
- Rami superiores  
    Rami inferiores  
Nn. supraclaviculares  
    Nn. supraclaviculares anteriores
- Nn. supraclaviculares medii
- Nn. supraclaviculares posteriores
- N. phrenicus  
    Ramus pericardiacus  
    Rami phrenicoabdominales
- Plexus brachialis**
- Pars supraclavicularis**
- Nn. thoracales posteriores  
    N. dorsalis scapulae
- N. thoracalis longus
- Nn. thoracales anteriores  
N. subclavius  
N. suprascapularis  
Nn. subscapulares  
N. thoracodorsalis
- N. axillaris  
    Rami musculares  
    N. cutaneus brachii lateralis  
**Pars infraclavicularis**  
    Fasciculus lateralis  
    Fasciculus medialis  
    Fasciculus posterior
- N. musculocutaneus  
    Rami musculares  
    N. cutaneus antibrachii lateralis
- N. cutaneus brachii medialis
- N. cutaneus antibrachii medialis
- Ramus volaris  
    Ramus ulnaris
- N. medianus**
- Rami musculares  
N. interosseus [antibrachii] volaris
- Ramus palmaris n. mediani
- Ramus anastomoticus cum n. ulnari  
Nn. digitales volares communes  
Nn. digitales volares proprii
- N. ulnaris**
- Ramus cutaneus palmaris  
Ramus dorsalis manus



**Cervical nerves**

Posterior rami (O. T. posterior primary divisions)

Medial ramus

Lateral ramus

Suboccipital nerve (O. T. posterior primary division of first cervical nerve)

Larger occipital nerve (O. T. great occipital, or medial branch of posterior primary division of second cervical nerve)

Third occipital nerve (O. T. third occipital, or medial branch of the posterior primary division of the third cervical nerve)

Anterior rami (O. T. anterior primary divisions)

**Cervical plexus**

Lesser occipital nerve

Great auricular nerve

Posterior ramus

Anterior ramus

Cutaneous nerve of the front of the neck (O. T. superficial cervical)

Upper rami

Lower rami

Supraclavicular nerves

Anterior supraclavicular nerves (O. T. suprasternal)

Middle supraclavicular nerves (O. T. supraclavicular)

Posterior supraclavicular nerves (O. T. supra-acromial)

Phrenic nerve

Pericardiac ramus

Phrenicoabdominal rami

**Brachial plexus**

Supraclavicular part

Posterior thoracic nerves

Dorsal nerve of scapula (O. T. nerve to the rhomboids)

Long thoracic nerve (O. T. external respiratory nerve of Bell, or posterior thoracic)

Anterior thoracic nerves

Subclavius nerve

Suprascapular nerve

Subscapular nerves

Thoracodorsal nerve (O. T. long subscapular nerve)

Axillary nerve (O. T. circumflex)

Muscular rami

Lateral cutaneous nerve of arm

**Infraclavicular part**

Lateral fasciculus (O. T. outer cord)

Medial fasciculus (O. T. inner cord)

Posterior fasciculus (O. T. posterior cord)

Musculocutaneous nerve

Muscular branches

Lateral cutaneous nerve of forearm (O. T. terminal cutaneous branch)

Medial nerve of upper arm (O. T. lesser internal cutaneous, or nerve of Wrisberg)

Medial nerve of forearm (O. T. internal cutaneous)

Volar ramus (O. T. anterior branch)

Ulnar ramus (O. T. posterior branch)

**Median nerve**

Muscular rami

Volar interosseous nerve of forearm (O. T. anterior interosseous)

Palmar ramus of median nerve (O. T. median palmar cutaneous)

Ramus anastomosing with ulnar nerve

Common volar digital nerves

Proper volar digital nerves (O. T. collateral palmar digital nerves)

**Ulnar nerve**

Palmar cutaneous ramus

Dorsal ramus of hand (O. T. dorsal cutaneous)

Nn. digitales dorsales  
 Ramus volaris manus  
 Ramus superficialis  
 Nn. digitales volares communes  
 Nn. digitales volares proprii  
 Ramus profundus  
 Rami musculares  
**N. radialis**  
 N. cutaneus brachii posterior  
 Rami musculares  
 N. cutaneus antibrachii dorsalis  
 Ramus profundus  
 N. interosseus [antibrachii] dorsalis  
 Ramus superficialis  
 Ramus anastomoticus ulnaris  
 Nn. digitales dorsales  
**Nn. thoracales**  
 Rami posteriores  
 Ramus cutaneus lateralis  
 Ramus cutaneus medialis  
 Rami anteriores [Nn. intercostales]  
 Rami musculares  
 Ramus cutaneus lateralis [pectoralis et abdominalis]  
 Ramus posterior  
 Ramus anterior  
 Rami mammarii laterales  
 Nn. intercostobrachiales  
 Ramus cutaneus anterior [pectoralis et abdominalis]  
 Rami mammarii mediales

**Nn. lumbales, sacrales, coccygeus**

Nn. lumbales  
 Rami posteriores  
 Ramus medialis  
 Ramus lateralis  
 Nn. clunium superiores  
 Rami anteriores  
 Nn. sacrales et coccygeus:  
 Rami posteriores  
 Ramus medialis  
 Ramus lateralis  
 Nn. clunium medii

**Plexus lumbosacralis****Plexus lumbalis**

Rami musculares  
**N. iliohypogastricus**  
 Rami musculares  
 Ramus cutaneus lateralis  
 Ramus cutaneus anterior

**N. ilioinguinalis**

Rami musculares  
 Nn. scrotales anteriores  
 Nn. labiales anteriores

**N. genitofemoralis**

N. lumboinguinalis  
 N. spermaticus externus

**N. cutaneus femoris lateralis****N. obturatorius**

Ramus anterior  
 Ramus cutaneus  
 Ramus posterior

Dorsal digital nerves  
 Volar ramus of hand  
 Superficial ramus  
 Common volar digital nerves  
 Proper volar digital nerves (O. T. collateral palmar digital)  
 Deep ramus  
 Muscular rami

### **Radial nerve (O. T. musculospiral)**

Posterior cutaneous nerve of upper arm (O. T. upper external cutaneous branch of musculospiral)  
 Muscular rami  
 Dorsal cutaneous nerve of forearm (O. T. lower external cutaneous branch of musculospiral)  
 Deep ramus  
 Dorsal interosseous nerve of forearm (O. T. posterior interosseous)  
 Superficial ramus (O. T. radial branch of musculospiral)  
 Ramus anastomosing with ulnar nerve  
 Dorsal digital nerves

### **Thoracic nerves**

Posterior rami  
 Lateral cutaneous ramus  
 Medial cutaneous ramus  
 Anterior rami [intercostal nerves]  
 Muscular rami  
 Lateral cutaneous ramus (of breast and abdomen)  
 Posterior ramus  
 Anterior ramus  
 Lateral mammary rami  
 Intercostobrachial nerves (O. T. intercosto-humeral nerves)  
 Anterior cutaneous ramus (of breast and abdomen)  
 Medial mammary rami

### **Lumbar, sacral, and coccygeal nerves**

Lumbar nerves  
 Posterior rami  
 Medial ramus  
 Lateral ramus  
 Superior clunial nerves  
 Anterior rami  
 Sacral and coccygeal nerves  
 Posterior rami  
 Medial ramus  
 Lateral ramus  
 Middle clunial nerves

### **Lumbosacral plexus**

#### **Lumbar plexus**

Muscular rami  
 Iliohypogastric nerve  
 Muscular rami  
 Lateral cutaneous ramus (O. T. iliac branch of hypogastric)  
 Anterior cutaneous ramus (O. T. hypogastric branch)

#### **Ilio-inguinal nerve**

Muscular rami  
 Anterior scrotal nerves  
 Anterior labial nerves

#### **Genitofemoral nerve (O. T. genitocrural nerve)**

Lumbo-inguinal nerve (O. T. crural branch of genitocrural)  
 External spermatic nerve (O. T. genital branch of genitocrural)

#### **Lateral cutaneous nerve of thigh (O. T. external cutaneous)**

#### **Obturator nerve**

Anterior ramus  
 Cutaneous ramus  
 Posterior ramus

**N. femoralis**

Rami cutanei anteriores  
 Rami musculares  
 N. saphenus

Ramus infrapatellaris

Rami cutanei cruris mediales

**Plexus sacralis**

Truncus lumbosacralis

N. glutaesus superior  
 N. glutaesus inferior  
 N. cutaneus femoris posterior  
 Nn. clunium inferiores  
 Rami perineales

**N. ischiadicus**

Rami musculares  
 N. peronaeus communis

Rami musculares  
 N. cutaneus surae lateralis  
 Ramus anastomoticus peronaeus

N. peronaeus superficialis

Rami musculares  
 N. cutaneus dorsalis medialis  
 N. cutaneus dorsalis intermedius  
 Nn. digitales dorsales pedis  
 N. peronaeus profundus

Rami musculares  
 Nn. digitales dorsales hallucis lateralis et digiti secundi medialis

**N. tibialis**

Rami musculares  
 N. interosseus curis  
 N. cutaneus surae medialis

[N. suralis]

Rami calcanei laterales  
 N. cutaneus dorsalis lateralis  
 Rami calcanei mediales  
 N. plantaris medialis

Nn. digitales plantares communes  
 Nn. digitales plantares proprii  
 N. plantaris lateralis

Ramus superficialis  
 Nn. digitales plantares communes  
 Nn. digitales plantares proprii  
 Ramus profundus

**Plexus pudendus**

Nn. haemorrhoidales medii  
 Nn. vesicales inferiores  
 Nn. vaginales  
 N. pudendus  
 Nn. haemorrhoidales inferiores  
 N. perinei  
 Nn. scrotales posteriores  
 Nn. labiales posteriores  
 N. dorsalis penis  
 N. dorsalis clitoridis

**N. coccygeus**

Plexus coccygeus  
 Nn. anococcygei

**Femoral nerve (O. T. anterior crural)**

- Anterior cutaneous rami
- Muscular rami
- Saphenous nerve (O. T. long saphenous)
- Infrapatellar ramus (O. T. patellar branch or long saphenous)
- Medial cutaneous rami of leg

**Sacral plexus**

- Lumbosacral trunk (O. T. lumbosacral cord)
- Superior gluteal nerve
- Inferior gluteal nerve
- Posterior cutaneous nerve of thigh
- Inferior nerves of buttock
- Perineal rami

**Sciatic nerve (O. T. great sciatic)**

- Muscular rami
- Common peroneal nerve (O. T. external popliteal)
- Muscular rami
- Lateral cutaneous nerve of calf
- Peroneal anastomotic ramus (O. T. nervus communicans fibularis)
- Superficial peroneal nerve (O. T. musculocutaneous)
- Muscular rami
- Medial dorsal cutaneous nerve
- Intermediate dorsal cutaneous nerve
- Dorsal digital nerves of foot
- Deep peroneal nerve (O. T. anterior tibial)
- Muscular rami
- Dorsal digital nerves to lateral surface of hallux and to medial surface of second digit

**Tibial nerve (O. T. internal popliteal nerve)**

- Muscular rami
- Interosseous nerve of the leg
- Medial cutaneous nerve of the calf (O. T. nervus communicans tibialis)
- Nerve of the calf (O. T. short saphenous nerve)
- Lateral calcanean rami
- Lateral dorsal cutaneous nerve
- Medial calcanean rami
- Medial plantar nerve (O. T. internal plantar)
- Common digital plantar nerves
- Proper digital plantar nerves
- Lateral plantar nerve (O. T. external plantar)
- Superficial ramus
- Common digital plantar nerves
- Proper digital plantar nerves
- Deep ramus

**Pudendal plexus**

- Middle hemorrhoidal nerves
- Inferior vesical nerves
- Vaginal nerves
- Pudendal nerve (O. T. pudic nerve)
- Inferior hemorrhoidal nerves
- Nerve of perineum
- Posterior scrotal nerves
- Posterior labial nerves
- Dorsal nerve of penis
- Dorsal nerve of clitoris

**Coccygeal nerve**

- Coccygeal plexus
- Anococcygeal nerves



## Systema nervorum sympathicum

- |   |  |
|---|--|
| Truncus sympathicus                               | Plexus thyreoideus inferior                      |
| Ganglia trunci sympathici                         | Plexus vertebralis                               |
| Plexus sympathici                                 |  |
| Ganglia plexuum sympathicorum                     | <b>Pars thoracalis s. sympathici</b>             |
| <b>Pars cephalica et cervicalis s. sympathici</b> | Ganglia thoracalia                               |
| Ganglion cervicale superius                       | N. splanchnicus major                            |
| N. jugularis                                      | Ganglion splanchnicum                            |
| N. caroticus internus                             | N. splanchnicus minor                            |
| Plexus caroticus internus                         | Ramus renalis                                    |
| Plexus cavernosus                                 | (N. splanchnicus imus)                           |
| Plexus arteriae cerebri anterioris                | Plexus aorticus thoracalis                       |
| Plexus arteriae cerebri mediae                    | Plexus cardiacus                                 |
| Plexus arteriae chorioideae                       | Plexus coronarius cordis anterior                |
| Plexus ophthalmicus                               | Ganglion cardiacum [Wrisbergi]                   |
| Radices sympathicae ganglii ciliaris              | Plexus coronarius posterior                      |
| Nn. carotici externi                              | Rami pulmonales                                  |
| Plexus caroticus externus                         | Plexus pulmonalis                                |
| Plexus thyreoideus superior                       | <b>Pars abdominalis et pelvina s. sympathici</b> |
| Plexus lingualis                                  | Ganglia lumbalia                                 |
| Plexus maxillaris externus                        | Ganglia sacralia                                 |
| Radix sympathica ganglii submaxillaris            | Plexus aorticus abdominalis                      |
| Plexus occipitalis                                | Plexus coeliacus                                 |
| Plexus auricularis posterior                      | Ganglia coeliaca                                 |
| Plexus temporalis superficialis                   | Ganglion mesentericum superius                   |
| Plexus maxillaris internus                        | Plexus phrenicus                                 |
| Plexus meningeus                                  | Ganglia phrenica                                 |
| Plexus caroticus communis                         | Plexus hepaticus                                 |
| Rami laryngopharyngei                             | Plexus lienalis                                  |
| Plexus pharyngeus ascendens                       | Plexus gastricus superior                        |
| N. cardiacus superior                             | Plexus gastricus inferior                        |
| Ganglion cervicale medium                         | Plexus suprarenalis                              |
| N. cardiacus medius                               | Plexus renalis                                   |
| Ganglion cervicale inferius                       | Plexus spermaticus                               |
| Ansa subclavia [Vieussenii]                       | Plexus arteriae ovaricae                         |
| N. cardiacus inferior                             | Plexus mesentericus superior                     |
| Plexus subclavius                                 | Plexus myentericus                               |
| Plexus mammarius internus                         |  |

## Sympathetic system of nerves

- |   |  |
|---|--|
| Sympathetic trunk   | Inferior thyroid plexus  |
| Ganglia of the sympathetic trunk                                | Vertebral plexus   |
| Sympathetic plexuses  | <b>Thoracic portion of the sympathetic system</b>              |
| Ganglia of the sympathetic plexuses                             | Thoracic ganglia   |
| <b>Cephalic and cervical portions of the sympathetic system</b> | Greater splanchnic nerve                                       |
| Superior cervical ganglion                                      | Splanchnic ganglion  |
| Jugular nerve   | Lesser splanchnic nerve  |
| Internal carotid nerve  | Renal ramus  |
| Internal carotid plexus   | Lowermost splanchnic nerve (O. T. smallest splanchnic)         |
| Cavernous plexus  | Thoracic aortic plexus   |
| Plexus of anterior cerebral artery                              | Cardiac plexus   |
| Plexus of middle cerebral artery                                | Anterior coronary plexus of heart                              |
| Plexus of chorioid artery                                       | Cardiac ganglion of Wrisberg                                   |
| Ophthalmic plexus   | Posterior coronary plexus                                      |
| Sympathetic roots of ciliary ganglion                           | Pulmonary rami   |
| External carotid nerves   | Pulmonary plexus   |
| External carotid plexus   | <b>Abdominal and pelvic portions of the sympathetic system</b> |
| Superior thyroid plexus   | Lumbar ganglia   |
| Lingual plexus  | Sacral ganglia   |
| External maxillary plexus                                       | Abdominal aortic plexus  |
| Sympathetic root of the submaxillary ganglion                   | Coeliac plexus   |
| Occipital plexus  | Coeliac ganglia  |
| Posterior auricular plexus                                      | Superior mesenteric ganglion                                   |
| Superficial temporal plexus                                     | Phrenic plexus   |
| Internal maxillary plexus                                       | Phrenic ganglia  |
| Meningeal plexus  | Hepatic plexus   |
| Common carotid plexus   | Splenic plexus   |
| Laryngopharyngeal rami  | Superior gastric plexus  |
| Ascending pharyngeal plexus                                     | Inferior gastric plexus  |
| Superior cardiac nerve  | Suprarenal plexus  |
| Middle cervical ganglion  | Renal plexus   |
| Middle cardiac nerve  | Spermatic plexus   |
| Inferior cervical ganglion                                      | Plexus of the ovarian artery                                   |
| Subclavian loop   | Superior mesenteric plexus                                     |
| Inferior cardiac nerve  | Myenteric plexus (O. T. plexus of Auerbach)                    |
| Subclavian plexus   |  |
| Internal mammary plexus   |  |

Plexus submucosus

Plexus mesentericus inferior

Nn. haemorrhoidales superiores

Plexus haemorrhoidalis superior

Plexus iliacus

Plexus hypogastricus

Plexus haemorrhoidalis medius

Plexus prostaticus

Plexus deferentialis

Plexus uterovaginalis

Plexus vesicalis

Nn. vesicales superiores

Nn. vesicales inferiores

Plexus cavernosus penis

N. cavernosus penis major

Nn. cavernosi penis minores

Plexus cavernosus clitoridis

N. cavernosus clitoridis major

Nn. cavernosi clitoridis minores

Plexus femoralis

Plexus popliteus

## Organa sensuum et Integumentum commune

### Organon visus

#### Oculus

##### N. opticus

Vaginae n. optici

Spatia intervaginalia

#### Bulbus oculi

Polus anterior

Polus posterior

Aequator

Meridiani

Axis oculi externa

Axis oculi interna

Axis optica

[Linea visus]

*Vesicula ophthalmica**Caliculus ophthalmicus*

#### Tunica fibrosa oculi

##### Sclera

Sulcus sclerae

Rima cornealis

Sinus venosus sclerae [Canalis

Schlemmi, Lauthi]

Lamina fusca

Lamina cribrosa sclerae

(Raphe sclerae)

(Funiculus sclerae)

##### Cornea

Annulus conjunctivae

Vertex corneae

Limbus corneae

Facies anterior

Facies posterior

Epithelium corneae

Lamina elastica anterior [Bowmani]

Substantia propria

Lamina elastica posterior [Demoursi,

Descemeti]

Endothelium camerae anterioris

#### Tunica vasculosa oculi

##### Chorioidea

Lamina suprachorioidea

Spatium perichorioideale

Lamina vasculosa

Lamina choriocapillaris

Lamina basalis

(Raphe chorioideae)

Plexus of submucosa (O. T. plexus of Meissner)	Vesical plexus
Inferior mesenteric plexus	Superior vesical nerves
Superior hemorrhoidal nerves	Inferior vesical nerves
Superior hemorrhoidal plexus	Cavernous plexus of penis
Iliac plexus	Larger cavernous nerve of penis
Hypogastric plexus	Lesser cavernous nerves of penis
Middle hemorrhoidal plexus	Cavernous plexus of clitoris
Prostatic plexus	Larger cavernous nerve of clitoris
Deferential plexus	Lesser cavernous nerves of clitoris
Uterovaginal plexus	Femoral plexus
	Popliteal plexus

## Sense organs and common integument

### Organ of vision

#### Eye

#### Optic nerve

Sheaths of the optic nerve  
Intervaginal spaces

#### Eyeball

Anterior pole  
Posterior pole  
Equator  
Meridian  
External axis of eye  
Internal axis of eye  
Optic axis  
Line of vision  
*Ophthalmic vesicle*  
*Ophthalmic cup*

#### Fibrous tunic of eye

##### Sclera (O. T. sclerotic coat)

Sulcus of the sclera  
Cleft for the cornea  
Venous sinus of the sclera, or canal of Schlemm  
Brown layer

Perforated layer of the sclera  
Ridge of the sclera  
Funiculus of the sclera

#### Cornea

Ring of conjunctiva  
Vertex of cornea  
Border of cornea  
Anterior surface  
Posterior surface  
Epithelium of cornea  
Anterior elastic layer (O. T. Bowman's membrane)  
Proper substance  
Posterior elastic layer (O. T. Descemet's membrane)  
Endothelium of anterior chamber

#### Vascular coat of eye

##### Chorioid

Suprachorioid layer  
Perichorioideal space  
Vascular layer  
Choriocapillary layer (O. T. tunica Ruyschiana)  
Basal layer  
Raphe of chorioid



**Corpus ciliare**

- Corona ciliaris
  - Processus ciliares
  - Plicae ciliares
- Orbiculus ciliaris
  - M. ciliaris
    - Fibrae meridionales [Bruecke]i
    - Fibrae circulares [Mueller]i
  - Plexus gangliosus ciliaris

**Iris**

- Margo pupillaris
- Margo ciliaris
- Facies anterior
- Facies posterior
- Annulus iridis major
- Annulus iridis minor
- Plicae iridis
- Pupilla
  - M. sphincter pupillae
  - Stroma iridis
  - M. dilatator pupillae
  - Lig. pectinatum iridis
- Spatia anguli iridis [Fontanae]
- Circulus arteriosus major
- Circulus arteriosus minor
- Membrana pupillaris*

**Stratum pigmenti**

- Stratum pigmenti retinae
- Stratum pigmenti corporis ciliaris
- Stratum pigmenti iridis

**Retina**

- Pars optica retinae
  - Ora serrata
- Pars ciliaris retinae
- Papilla n. optici
- Excavatio papillae n. optici
- Macula lutea
- Fovea centralis

**Vasa sanguinea retinae**

- Circulus vasculosus n. optici [Haller]i
- Arteriola [Venula] temporalis retinae superior
- Arteriola [Venula] temporalis retinae inferior
- Arteriola [Venula] nasalis retinae superior
- Arteriola [Venula] nasalis retinae inferior
- Arteriola [Venula] macularis superior
- Arteriola [Venula] macularis inferior
- Arteriola [Venula] retinae medialis

**Camera oculi anterior**

- Angulus iridis

**Camera oculi posterior****Corpus vitreum**

- A. hyaloidea*
- Canalis hyaloideus
- Fossa hyaloidea
- Membrana hyaloidea
  - Stroma vitreum
  - Humor vitreus

**Lens crystallina**

- Substantia lentis
  - Substantia corticalis
  - Nucleus lentis
- Fibrae lentis
- Epithelium lentis
- Capsula lentis
  - Polus anterior lentis
  - Polus posterior lentis
  - Facies anterior lentis
  - Facies posterior lentis
  - Axis lentis
  - Aequator lentis
  - Radii lentis



**Ciliary body**

Ciliary wreath

Ciliary processes

Ciliary folds

Ciliary disk

Ciliary muscle

Meridional fibres

Circular fibres

Ciliary ganglionic plexus

**Iris, or diaphragm of the eye**

Pupillary margin

Ciliary margin

Anterior surface

Posterior surface

Greater ring of iris

Lesser ring of iris

Folds of iris

Pupil

Sphincter muscle of pupil

Stroma of iris

Dilator muscle of pupil

Pectinate ("comb-like") ligament of iris (O. T. pillars of the iris)

Spaces of the angle of the iris (O. T. spaces of Fontana)

Greater arterial circle

Lesser arterial circle

*Pupillary membrane***Layer of pigment**

Pigment layer of the retina

Pigment layer of ciliary body

Pigment layer of iris

**Retina**

Optic part of retina

Serrated edge

Ciliary part of retina

Papilla of optic nerve

Excavation of papilla of optic nerve

Yellow spot

Central fovea

Blood vessels of the retina

Vascular circle of the optic nerve

Superior arteriole (venule) of temporal retina

Inferior arteriole (venule) of temporal retina

Superior arteriole (venule) of nasal retina

Inferior arteriole (venule) of nasal retina

Superior macular arteriole (venule)

Inferior macular arteriole (venule)

Medial arteriole (venule) of retina

**Anterior chamber of the eye**

Angle of the iris (O. T. iridocorneal angle)

**Posterior chamber of the eye****Vitreous body***Hyaloid artery*

Hyaloid canal (O. T. canal of Stilling)

Hyaloid fossa (O. T. fossa patellaris)

Hyaloid membrane

Vitreous stroma

Vitreous humor

**Crystalline lens**

Substance of the lens

Cortical substance

Nucleus of the lens

Fibres of the lens

Epithelium of the lens

Capsule of the lens

Anterior pole of lens

Posterior pole of lens

Anterior surface of lens

Posterior surface of lens

Axis of the lens

Equator of the lens

Radii of the lens

**Zonula ciliaris [Zinni]**

Fibrae zonulares  
Spatia zonularia

**Organa oculi accessoria****Musculi oculi, Fasciae orbitales**

M. orbitalis  
M. rectus superior  
M. rectus inferior  
M. rectus medialis  
  
M. rectus lateralis

Lacertus musculi recti lateralis  
Annulus tendineus communis [Zinni]

M. obliquus superior  
Trochlea  
M. obliquus inferior  
M. levator palpebrae superioris  
Periorbita  
Septum orbitale

Fasciae musculares  
Fascia bulbi [Tenoni]  
Spatium interfasciale [Tenoni]  
Corpus adiposum orbitae

**Supercilium****Palpebrae**

Palpebra superior  
Palpebra inferior  
Facies anterior palpebrarum  
Facies posterior palpebrarum  
Rima palpebrarum  
Commissura palpebrarum lateralis  
  
Commissura palpebrarum medialis  
  
Angulus oculi lateralis  
Angulus oculi medialis  
Limbi palpebrales anteriores  
Limbi palpebrales posteriores

Tarsus superior

Tarsus inferior

Lig. palpebrale mediale

Raphe palpebralis lateralis

Glandulae tarsales [Meibomi]

Sebum palpebrale  
M. tarsalis superior  
M. tarsalis inferior

**Conjunctiva**

Plica semilunaris conjunctivae  
Caruncula lacrimalis  
Tunica conjunctiva bulbi  
Tunica conjunctiva palpebrarum  
Fornix conjunctivae superior  
Fornix conjunctivae inferior  
Gl. mucosae [Krausei]  
Noduli lymphatici conjunctivales  
(Pinguecula)

**Apparatus lacrimalis**

Glandula lacrimalis superior  
Glandula lacrimalis inferior  
(Gl. lacrimales accessoriae)  
Ductuli excretorii [gl. lacrimalis]  
Rivus lacrimalis  
Lacus lacrimalis  
Puncta lacrimalia  
Ductus lacrimales  
Papillae lacrimales  
Ampulla ductus lacrimalis  
Saccus lacrimalis  
Fornix sacci lacrimalis  
Ductus nasolacrimalis  
Plica lacrimalis [Hasneri]  
Lacrimae

**Ciliary zonule (O. T. zonule of Zinn)**

Zonular fibres

Zonular spaces (O. T. canal of Petit)

**Accessory organs of eye****Eye muscles, orbital fasciae**

Orbital muscle

Superior straight muscle

Inferior straight muscle

Medial straight muscle (O. T. internal rectus)

Lateral straight muscle (O. T. external rectus)

Lacertus of lateral straight muscle

Common tendinous ring of Zinn

Superior oblique muscle

Pulley

Inferior oblique muscle

Levator muscle of superior lid

Periorbit

Orbital septum (O. T. palpebral ligaments)

Muscular fasciae

Fascia of ball (O. T. capsule of Tenon)

Interfascial space

Fat body of orbit

**Eyebrow****Eyelids**

Upper eyelid

Lower eyelid

Anterior surface of eyelids

Posterior surface of eyelids

Palpebral fissure

Lateral palpebral commissure (O. T. external canthus)

Medial palpebral commissure (O. T. internal canthus)

Lateral angle of the eye

Medial angle of the eye

Anterior palpebral margins

Posterior palpebral margins

Superior tarsus (O. T. superior tarsal plate)

Inferior tarsus (O. T. inferior tarsal plate)

Medial palpebral ligament (O. T. internal tarsal ligament)

Lateral palpebral raphe (O. T. external tarsal ligament)

Tarsal glands (O. T. Meibomian glands)

Palpebral sebum

Superior tarsal muscle

Inferior tarsal muscle (O. T. tensor tarsi)

**Conjunctiva or connecting membrane**

Semilunar fold of conjunctiva

Lacrimal caruncle

Conjunctival coat of eyeball

Conjunctival coat of eyelids

Superior fornix of conjunctiva

Inferior fornix of conjunctiva

Mucous glands of Krause

Conjunctival lymphatic nodules

Conjunctival fat

**Lacrimal apparatus**

Superior lacrimal gland

Inferior lacrimal gland

Accessory lacrimal glands

Excretory ductules of lacrimal gland

Lacrimal stream

Lacrimal lake

Lacrimal (punctate) openings

Lacrimal ducts

Lacrimal papillae

Ampulla of lacrimal duct

Lacrimal sac

Fornix, or summit of lacrimal sac

Nasolacrimal duct

Lacrimal fold of Hasner

Tears

**Organon auditus****Auris interna****Labyrinthus membranaceus**

Ductus endolymphaticus  
 Saccus endolymphaticus  
 Ductus utriculosaccularis  
 Utriculus  
 Ductus semicirculares  
   Ductus semicircularis superior  
   Ductus semicircularis posterior  
   Ductus semicircularis lateralis

Ampullae membranaceae  
   Sulcus ampullaris  
   Crista ampullaris  
   Ampulla membranacea superior  
   Ampulla membranacea posterior  
   Ampulla membranacea lateralis

Sacculus  
 Ductus reuniens [Henseni]  
 Maculae acusticae  
   Macula acustica utriculi  
   Macula acustica sacculi

Otoconia  
 Endolympha  
 Perilympha  
 Spatium perilymphaticum  
 Ductus perilymphatici  
 Ductus cochlearis

Caecum cupulare  
 Caecum vestibulare  
 Lamina basilaris  
 Membrana vestibularis [Reissneri]  
 Lig. spirale cochleae  
 Prominentia spiralis  
 Stria vascularis  
 Sulcus spiralis  
 Labium tympanicum  
   Foramina nervosa  
 Labium vestibulare

Ganglion spirale cochleae  
 Organon spirale [Cortii]  
 Vasa auris internae  
 A. auditiva interna  
   Rami vestibulares  
   Ramus cochleae  
   Glomeruli arteriosi cochleae  
 Vv. auditivae internae  
   V. spiralis modioli  
   Vas prominens  
 Vv. vestibulares  
   V. aquaeductus vestibuli  
   V. canaliculi cochleae

**Labyrinthus osseus****Vestibulum**

Recessus sphaericus  
 Recessus ellipticus  
 Crista vestibuli  
 Pyramis vestibuli  
 Recessus cochlearis  
 Maculae cribrosae  
   Macula cribrosa superior  
   Macula cribrosa media  
   Macula cribrosa inferior  
 Canales semicirculares ossei  
   Canalis semicircularis superior  
   Canalis semicircularis posterior  
   Canalis semicircularis lateralis

Ampullae osseae  
   Ampulla ossea superior  
   Ampulla ossea posterior  
   Ampulla ossea lateralis  
 Crura ampullaria  
 Crus commune  
 Crus simplex

**Cochlea**

Cupula  
 Basis cochleae



**Organ of hearing****Internal ear****Membranous labyrinth**

Endolymphatic duct  
 Endolymphatic sac  
 Utriculosaccular duct  
 Utricle  
 Semicircular ducts  
   Superior semicircular duct  
   Posterior semicircular duct  
   Lateral semicircular duct (O. T. external)  
 Membranous ampullae  
   Ampullary sulcus  
   Ampullary crest  
   Superior membranous ampulla  
   Posterior membranous ampulla  
   Lateral membranous ampulla  
 Sacculus  
 Uniting duct (O. T. canalis reuniens)  
 Acoustic spots  
   Acoustic spot of utricle  
   Acoustic spot of sacculus  
 Ear-stones  
 Endolymph  
 Perilymph  
 Perilymphatic space  
 Perilymphatic ducts  
 Cochlear duct (O. T. membranous cochlea, or scala media)  
 Cupular blind sac  
 Vestibular blind sac  
 Basilar layer  
 Vestibular membrane of Reissner  
 Spiral ligament of cochlea  
 Spiral prominence  
 Vascular stripe  
 Spiral sulcus  
 Tympanic lip  
   Openings for nerves  
 Vestibular lip

Spiral ganglion of cochlea  
 Spiral organ of Corti  
 Vessels of internal ear  
 Internal auditory artery  
   Vestibular rami  
   Cochlear ramus  
   Arterial glomeruli of cochlea  
 Internal auditory veins  
   Spiral vein of modiolus  
   Prominent vessel  
   Vestibular veins  
   Vein of aqueduct of vestibule  
   Vein of canaliculus of cochlea

**Osseous labyrinth****Vestibule**

Spherical recess (O. T. fovea hemisphaerica)  
 Elliptical recess (O. T. fovea hemieliptica)  
 Crest of vestibule  
 Pyramid of vestibule  
 Cochlear recess  
 Perforated spots  
   Superior perforated spot  
   Middle perforated spot  
   Inferior perforated spot  
 Osseous semicircular canals  
   Superior semicircular canal  
   Posterior semicircular canal  
   Lateral semicircular canal (O. T. external)  
 Osseous ampullae  
   Superior osseous ampulla  
   Posterior osseous ampulla  
   Lateral osseous ampulla  
 Ampullary limbs  
 Common limb  
 Simple limb

**Cochlea ("snail shell")**

Cupola  
 Base of cochlea



Canalis spiralis cochleae  
 Modiolus  
 Basis modioli  
 Lamina modioli  
 Lamina spiralis ossea  
 Hamulus laminae spiralis  
 Scala vestibuli  
 Scala tympani  
 Helicotrema  
 Lamina spiralis secundaria  
 Canalis spiralis modioli  
 Canales longitudinales modioli

### **Meatus acusticus internus**

Porus acusticus internus  
 Fundus meatus acustici interni  
 Crista transversa  
 Area n. facialis  
 Area cochleae  
 Tractus spiralis foraminosus  
 Area vestibularis superior  
 Area vestibularis inferior  
 Foramen singulare

### **Cavum tympani**

**P a r i e s t e g m e n t a l i s**  
 Recessus epitympanicus  
 Pars cupularis  
**P a r i e s j u g u l a r i s**  
 Prominentia styloidea  
**P a r i e s l a b y r i n t h i c a**

Fenestra vestibuli

Fossula fenestrae vestibuli  
 Promontorium  
 Sulcus promontorii  
 Subiculum promontorii

Sinus tympani  
 Fenestra cochleae

Fossula fenestrae cochleae

Crista fenestrae cochleae  
 Processus cochleariformis  
**P a r i e s m a s t o i d e a**

Antrum tympanicum

Prominentia canalis semicircularis  
 lateralis

Prominentia canalis facialis

Eminentia pyramidalis

Fossa incudis

Sinus posterior

Apertura tympanica canaliculi  
 chordae

Cellulae mastoideae

Cellulae tympanicae

**P a r i e s c a r o t i c a**

**P a r i e s m e m b r a n a c e a**

### **Membrana tympani**

Pars flaccida

Pars tensa

Limbus membranae tympani

Plica malleolaris anterior

Plica malleolaris posterior

Prominentia malleolaris

Stria malleolaris

Umbo membranae tympani

Stratum cutaneum

Annulus fibrocartilagineus

Stratum radiatum

Stratum circulare

Stratum mucosum

### **Ossicula auditus**

**S t a p e s**

Capitulum stapedis

Crus anterius

Crus posterius

Spiral canal of cochlea  
 Modiolus ("screw")  
 Base of modiolus  
 Shelf of modiolus  
 Osseous spiral shelf  
 Hooklet of spiral shelf  
 "Staircase" of vestibule  
 "Staircase" of tympanum  
 Helicotrema ("pore of the helix")  
 Secondary spiral shelf  
 Spiral canal of modiolus  
 Longitudinal canals of modiolus

### Internal acoustic meatus

Internal acoustic opening  
 Bottom of internal acoustic meatus  
 Transverse crest  
 Area of facial nerve  
 Area of cochlea  
 Foraminous spiral tract  
 Superior vestibular area  
 Inferior vestibular area  
 Isolated foramen

### Cavity of tympanum

Tegmental wall  
 Epitympanic recess  
 Cupular portion  
 Jugular wall (O. T. floor)  
 Styloid prominence  
 Labyrinthic wall (O. T. inner wall)  
 Fenestra ("window") of vestibule  
 (O. T. fenestra ovalis)  
 Little fossa of fenestra of vestibule  
 Promontory  
 Sulcus of promontory  
 Subiculum ("support") of promontory  
 Sinus of tympanum  
 Fenestra of cochlea (O. T. fenestra rotunda)  
 Little fossa of fenestra of cochlea

Crest of fenestra of cochlea  
 Cochleariform process  
 Mastoid wall (O. T. posterior wall)  
 Tympanic antrum (O. T. mastoidal antrum)  
 Prominence of lateral semicircular canal  
 Prominence of facial canal  
 Pyramidal eminence  
 Fossa of incus  
 Posterior sinus  
 Tympanic aperture of canaliculus of chorda

Mastoid cells  
 Tympanic cells  
 Carotid wall (O. T. anterior wall)  
 Membranous wall (O. T. outer wall)

### Membrane of the tympanum (O. T. drumhead)

Flaccid part  
 Tense part  
 Border of membrane of tympanum  
 Anterior malleolar fold  
 Posterior malleolar fold  
 Malleolar prominence  
 Malleolar stripe  
 Umbo ("prominent part") of tympanic membrane  
 Cutaneous layer  
 Fibrocartilaginous ring  
 Radiate layer  
 Circular layer  
 Mucous layer

### Auditory ossicles

Stirrup  
 Head of stirrup  
 Anterior limb  
 Posterior limb

Basis stapedis  
 Incus  
 Corpus incudis  
 Crus longum  
   Processus lenticularis  
 Crus breve  
 Malleus  
 Manubrium mallei  
 Capitulum mallei  
 Collum mallei  
 Processus lateralis

Processus anterior [Folii]

### **Articulationes ossiculorum auditus**

Articulatio incudomalleolaris  
 Articulatio incudostapedia  
 Syndesmosis tympanostapedia

### **Ligg. ossiculorum auditus**

Lig. mallei anterior  
 Lig. mallei superior  
 Lig. mallei laterale  
  
 Lig. incudis superior  
 Lig. incudis posterior  
 Membrana obturatoria (stapedis)  
 Lig. annulare baseos stapedis  
 [M. fixator baseos stapedis]

### **Musculi ossiculorum auditus**

M. tensor tympani  
 M. stapedius

### **Tunica mucosa tympanica**

(Gl. tympanicae)  
 Plica malleolaris posterior  
 Plica malleolaris anterior  
 Recessus membranae tympani anterior  
 Recessus tympani membranae superior  
 Recessus membranae tympani posterior  
 Plica incudis

Plica stapedis  
 Membrana tympani secundaria

### **Tuba auditiva [Eustachii]**

Ostium tympanicum tubae auditivae  
 Pars ossea tubae auditivae  
   Isthmus tubae auditivae  
   Cellulae pneumaticae tubariae  
 Pars cartilagineae tubae auditivae  
   Cartilago tubae auditivae  
     Lamina [cartilaginis] medialis  
     Lamina [cartilaginis] lateralis  
 Lamina membranacea  
 Tunica mucosa  
   Gl. mucosae  
   Noduli lymphatici tubarii  
 Ostium pharyngeum tubae auditivae

### **Meatus acusticus externus**

Porus acusticus externus  
 Incisura tympanica [Rivini]  
 Meatus acusticus externus cartilagineus  
 Cartilago meatus acustici  
   Incisurae cartilaginis meatus acustici externi [Santorini]  
 Lamina tragi

### **Auriculae**

Lobulus auriculae  
 Cartilago auriculae  
 Helix  
 Crus helices  
 Spina helices  
 Cauda helices  
 Anthelix  
 Fossa triangularis [auriculae]  
 Crura anthelices  
 Scapha  
 Concha auriculae  
 Cymba conchae  
 Cavum conchae  
 Antitragus

Base of stirrup (O. T. foot-piece)  
 A n v i l  
 Body of anvil  
 Long limb  
   Lenticular process  
 Short limb  
 H a m m e r  
 Handle of hammer  
 Head of hammer  
 Neck of hammer  
 Lateral process (O. T. processus  
   brevis)  
 Anterior process (O. T. processus  
   gracilis)

#### Joints of the auditory ossicles

Joint between anvil and hammer  
 Joint between anvil and stirrup  
 Junction of stirrup and tympanum

#### Ligaments of the auditory ossicles

Anterior ligament of hammer  
 Superior ligament of hammer  
 Lateral ligament of hammer (O. T.  
   external ligament)  
 Superior ligament of anvil  
 Posterior ligament of anvil  
 Obturator membrane of stirrup  
 Annular ligament of base of stirrup  
 Fixing muscle of the base of stirrup

#### Muscles of the auditory ossicles

Tensor muscle of the tympanum  
 Stapedius muscle

#### Tympanic mucous coat

Tympanic glands  
 Posterior maleolar fold  
 Anterior malleolar fold  
 Anterior recess of tympanic membrane  
 Superior recess of tympanic membrane  
 Posterior recess of tympanic membrane  
 Fold of anvil

Fold of stirrup  
 Secondary tympanic membrane

#### Auditory or Eustachian tube

Tympanic opening of auditory tube  
 Bony part of auditory tube  
   Isthmus of auditory tube  
   Tubal air cells  
 Cartilaginous part of auditory tube  
   Cartilage of auditory tube  
     Medial layer of cartilage  
     Lateral layer of cartilage  
 Membranous layer  
 Mucous membrane  
   Mucous glands  
   Tubal lymphatic nodules  
 Pharyngeal opening of auditory tube

#### External acoustic meatus

External acoustic opening  
 Tympanic incisure  
 Cartilaginous external acoustic meatus

Cartilage of acoustic meatus  
   Notches in cartilage of external  
     acoustic meatus  
   Layer of tragus

#### External ear, or auricle (O. T. pinna)

Lobule of auricle  
 Cartilage of auricle  
 Coil  
 Limb of coil  
 Spine of coil  
 Tail of coil  
 Anthelix  
 Triangular fossa of auricle  
 Limbs of anthelix  
 Scapha ("skiff")  
 Concha ("shell") of auricle  
 Cymba ("boat") of auricle  
 Cavity of concha  
 Antitragus

**Tragus**

- Incisura anterior [auris]  
 Incisura intertragica  
 (Tuberculum auriculae [Darwini])  
 (Apex auriculae [Darwini])  
 Sulcus auriculae posterior  
 (Tuberculum supratragicum)  
 Isthmus cartilagineus auris  
 Incisura terminalis auris  
 Fissura antitragohelicina  
 Sulcus anthelicis transversus  
 Sulcus cruris helices  
 Fossa anthelicis  
 Eminentia conchae  
 Eminentia scaphae  
 Eminentia fossae triangularis  
 Ligg. auricularia [Valsalvae]  
 Lig. auriculare anterius  
 Lig. auriculare superius  
 Lig. auriculare posterius  
 M. helices major  
 M. helices minor  
 M. tragicus  
 (M. pyramidalis auriculae [Jungi])  
 M. antitragicus  
 M. transversus auriculae  
 M. obliquus auriculae  
 (M. incisurae helices [Santorini])

**Organon olfactus****Organon gustus**

Calyculi gustatorii

**Integumentum commune****Cutis**

- Sulci cutis  
 Cristae cutis  
 Retinacula cutis  
 Toruli tactiles  
 Foveola coccygea  
 Lig. caudale

**Epidermis**

- Stratum corneum  
 Stratum germinativum [Malpighii]

**Corium**

- Tunica propria  
 Corpus papillare  
 Papillae

**Tela subcutanea**

- Panniculus adiposus

**Corpuscula nervorum terminalia**

- Corpuscula bulboidea [Krausii]  
 Corpuscula lamellosa [Vateri, Pacini]  
 Corpuscula tactus [Meissneri]  
 Corpuscula nervorum genitalia  
 Corpuscula nervorum articularia

**Pili**

- Lanugo  
 Capilli  
 Supercilia  
 Cilia  
 Barba  
 Tragi  
 Vibrissae  
 Hirci  
 Pubes  
 Folliculus pili  
 Fundus folliculi pili  
 Collum folliculi pili  
 Papilla pili  
 Scapus pili  
 Radix pili  
 Bulbus pili  
 Mm. arrectores pilorum  
 Flumina pilorum  
 Vortices pilorum  
 (Vortex coccygeus)



Tragus ("goat")  
 Anterior notch of ear  
 Intertragic notch  
 Darwinian tubercle of auricle  
 Tip of ear  
 Posterior sulcus of auricle  
 Supratragic tubercle  
 Cartilaginous isthmus of ear  
 Terminal notch of ear  
 Antitragohelicine fissure  
 Transverse groove of anthelix  
 Groove of crus of helix  
 Fossa of anthelix  
 Eminence of concha  
 Eminence of scapha  
 Eminence of triangular fossa  
 Auricular ligaments of Valsalva  
   Anterior auricular ligament  
   Superior auricular ligament  
   Posterior auricular ligament  
 Larger muscle of helix  
 Smaller muscle of helix  
 Muscle of tragus  
 Pyramidal muscle of ear  
 Muscle of antitragus  
 Transverse muscle of auricle  
 Oblique muscle of auricle  
 Muscle of notch of helix

### Organ of smell

### Organ of taste

Taste buds

## Common integument

### Skin

Grooves of skin  
 Ridges of skin  
 Retaining bands or folds of skin  
 Tactile elevations  
 Coccygeal depression  
 Caudal ligament

### Epidermis, or scarf skin

Horny layer  
 Germinative, or Malpighian layer

### Corium, or leather skin

Proper tunic  
 Papillary body  
 Papillae

### Subcutaneous tissue

Adipose panniculus ("garment") (O.  
 T. subcutaneous areolar tissue)

### Terminal corpuscles of the nerves

Bulb-like corpuscles of Krause  
 Lamellated corpuscles of Vater or  
 Pacini  
 Touch corpuscle of Meissner  
 Genital corpuscles of the nerves  
 Articular corpuscles of the nerves

### Hairs

Woolly hair  
 Hairs of the head  
 Hairs of the eyebrows  
 Eyelashes  
 Hairs of the beard  
 Hairs of the ear  
 Hairs of the nose  
 Axillary hairs  
 Pubic hairs  
 Hair follicle  
   Fundus of hair follicle  
   Neck of hair follicle  
 Papilla of hair  
 Shaft of hair  
 Root of hair  
 Bulb of hair  
 Arrector muscles of the hairs  
 Hair streams  
 Hair whirlpools  
 Coccygeal whirlpool

**Ungues**

Matrix unguis  
 Cristae matricis unguis  
 Sulcus matricis unguis  
 Vallum unguis  
 Corpus unguis  
 Radix unguis  
 Lunula  
 Margo occultus  
 Margo liber  
 Margo lateralis  
 Stratum corneum unguis  
 Stratum germinativum unguis

**Glandulae cutis****Gl. glomiformes**

Gl. sudoriferae  
 Corpus gl. sudoriferae  
 Ductus sudoriferus  
 Porus sudoriferus  
 Sudor  
 Gl. ciliares [Molli]

Gl. circumanales

Gl. ceruminosae

Cerumen

**Glandulae sebaceae**

Sebum cutaneum

**Mamma**

Papilla mammae

Corpus mammae

Lobi mammae

Lobuli mammae

Ductus lactiferi

Sinus lactiferi

Lac femininum

Colostrum

Areola mammae

Gl. sebaceae

Gl. areolares [Montgomerii]

**M a m m a v i r i l i s**

(Mammae accessoriae [muliebres et viriles])

**Nails**

Bed of the nail  
 Crest of unguis matrix  
 Sulcus of unguis matrix  
 Wall of nail  
 Body of nail  
 Root of nail  
 Lunule  
 Hidden margin  
 Free margin  
 Lateral margin  
 Horny layer of nail  
 Germinative layer of nail

**Glands of the skin****Coil glands**

Sweat glands  
 Body of sweat gland  
 Sweat duct  
 Sweat pore  
 Sweat  
 Glands of the eyelashes of Moll

Circumanal glands

Wax glands

Wax

**Sebaceous glands**

Cutaneous sebum

**Breast**

Nipple of the breast

Body of the breast

Lobes of the breast

Lobules of breast

Lactiferous duct

Lactiferous sinus

Female milk

Colostrum

Areola of breast

Sebaceous glands

Areolar glands of Montgomery

Male breast

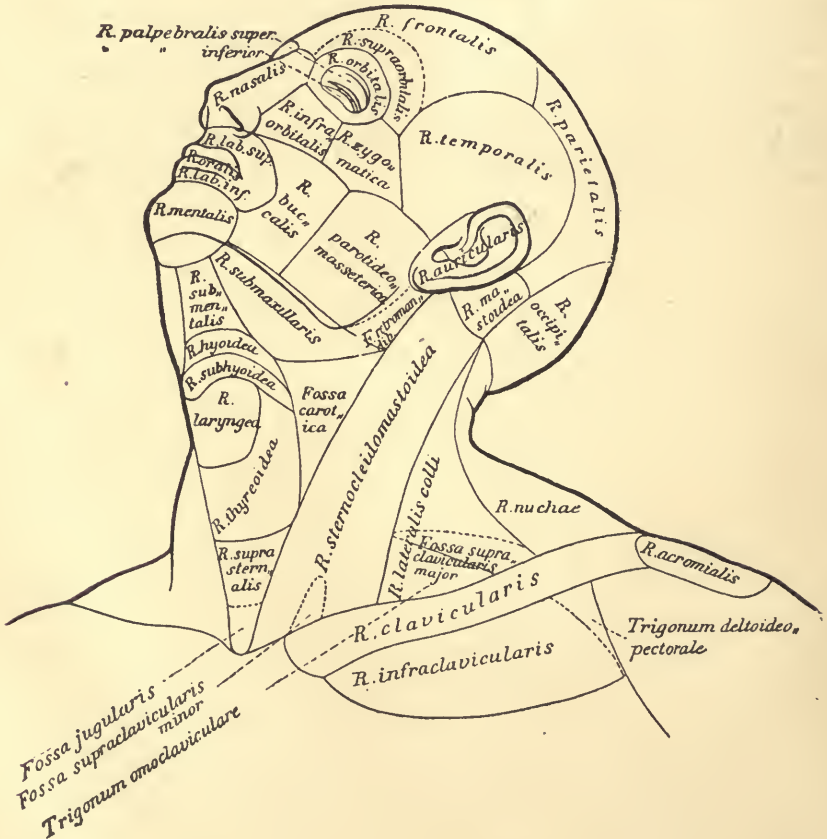
Accessory breasts, female and male

# Regiones corporis humani

auctoribus Merkel, Rüdinger, Toldt.

Linea mediana anterior  
 Linea mediana posterior  
 Linea sternalis  
 Linea parasternalis

Linea mamillaris  
 Linea axillaris  
 Linea scapularis



## Regions of the human body

After the authors Merkel, Rüdinger, Toldt.

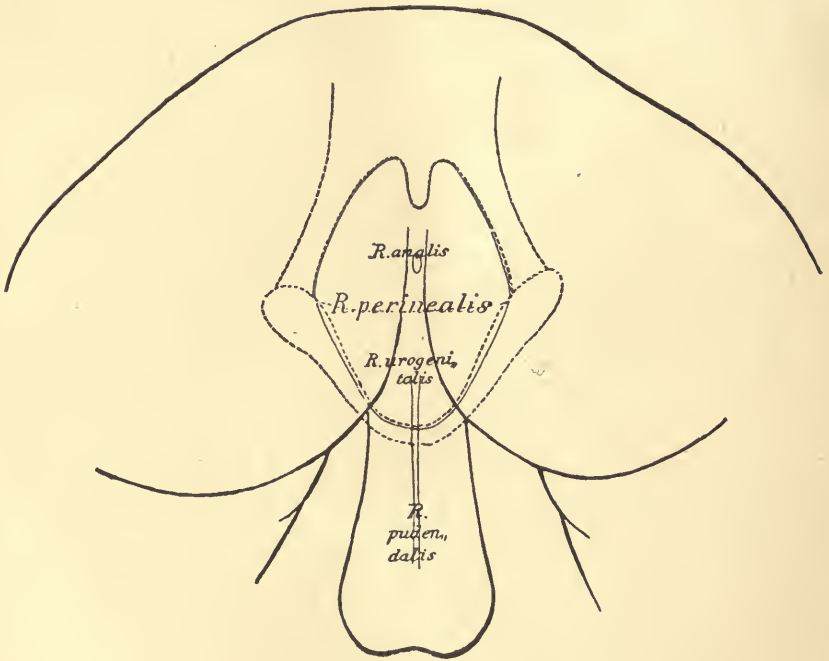
Anterior median line  
Posterior median line  
Sternal line  
Parasternal line

Mammillary line  
Axillary line  
Scapular line



Regiones capitis  
 Regio frontalis  
 Regio supraorbitalis  
 Regio parietalis  
 Regio occipitalis  
 Regio temporalis  
 Regio auricularis  
 Regio mastoidea  
 Regiones faciei  
 Regio nasalis

Regio parotideomasseterica  
 Fossa retromandibularis  
 Regiones colli  
 Regio colli anterior  
 Regio submentalialis  
 Regio hyoidea  
 Regio subhyoidea  
 Regio laryngea  
 Regio thyreoidea  
 Regio suprasternalis



Regio oralis  
 Regio labialis superior  
 Regio labialis inferior  
 Regio mentalis  
 Regio orbitalis  
 Regio palpebralis superior  
 Regio palpebralis inferior  
 Regio infraorbitalis  
 Regio buccalis  
 Regio zygomatica

Fossa jugularis  
 Regio submaxillaris  
 Fossa carotica  
 Regio sternocleidomastoidea  
 Fossa supraclavicularis minor  
 Regio colli lateralis  
 Fossa supraclavicularis major  
 Trigonum omoclaviculare  
 Regio colli posterior  
 Regio nuchae

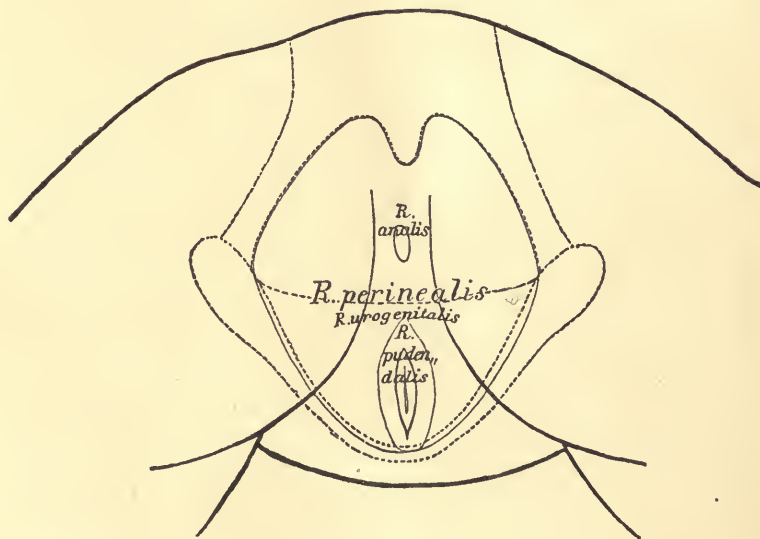
Regions of the head  
 Region of the forehead  
 Supraorbital region  
 Parietal region  
 Region of the occiput  
 Region of the temple  
 Region of the ear  
 Region of the mastoid  
 Regions of the face  
 Region of the nose

Parotidomasseteric region  
 Retromandibular fossa  
 Regions of the neck  
 Anterior region of neck  
 Region under the chin  
 Region of the hyoid  
 Region below hyoid  
 Region of the larynx  
 Region of the thyroid  
 Region above sternum

Region of the mouth  
 Region of the upper lip  
 Region of the lower lip  
 Region of the chin  
 Region of the eye  
 Region of upper eyelid  
 Region of lower eyelid  
 Infraorbital region  
 Region of the cheek  
 Region of the zygoma

Jugular fossa  
 Region below lower jaw  
 Carotid fossa  
 Region of the sternocleidomastoid  
 Lesser supraclavicular fossa  
 Region of the side of the neck  
 Larger supraclavicular fossa  
 Omoclavicular triangle  
 Region of the back of the neck  
 Region of the nape

Fovea nucae	Regio mediana dorsi
Regiones pectoris	Regio interscapularis
Regio pectoris anterior	Regio scapularis
Regio sternalis	Regio suprascapularis
Regio clavicularis	Regio infrascapularis
Regio infraclavicularis	Regio lumbalis
Trigonum deltoideopectorale	Regio coxae
Regio mammalis	Regio sacralis
Regio inframammalis	Regio glutaea
Regio pectoris lateralis	Regio perinealis
Regio axillaris	Regio analis
Fossa axillaris	Regio urogenitalis



Regio costalis lateralis	Regio pudendalis
Regiones abdominis	Regiones extremitatis superioris
Regio epigastrica	Regio acromialis
Regio hypochondriaca	Regio deltoidea
Regio mesogastrica	Regio brachii lateralis
Regio umbilicalis	Regio brachii medialis
Regio abdominalis lateralis	Regio brachii anterior
Regio hypogastrica	Regio brachii posterior
Regio pubica	Regio cubiti anterior
Regio inguinalis	Fossa cubitalis
Regiones dorsi	

Nuchal depression  
 Regions of the breast  
 Anterior region of breast  
   Region of the sternum  
   Region of the clavicle  
   Region below clavicle  
     Deltoideopectoral triangle  
   Region of the mammary gland  
   Region below mammary gland  
 Lateral region of the breast  
   Region of the axilla  
     Axillary pit

Median region of the back  
 Interscapular region  
 Region of the scapula  
 Region above scapula  
 Region below scapula  
 Lumbar region  
 Region of the hip  
 Region of the sacrum  
 Region of the buttocks  
 Region of the perineum  
   Anal region  
   Urogenital region

Lateral region of ribs  
 Regions of abdomen  
 Epigastric region  
 Hypochondriac region  
 Mesogastric region  
   Region of umbilicus  
   Lateral region of abdomen  
 Hypogastric region  
   Region of the pubes  
   Region of the groin  
 Regions of the back

Pundental region  
 Regions of upper extremity  
 Region of the acromion  
 Region of the deltoid  
 Lateral region of upper arm  
 Medial region of upper arm  
 Anterior region of upper arm  
 Posterior region of upper arm  
 Anterior region of elbow  
   Fossa of elbow

Regio cubiti posterior	Regio femoris medialis
Regio olecrani	Regio genu anterior
Regio cubiti lateralis	Regio patellaris
Regio cubiti medialis	Regio genu posterior
Regio antibrachii volaris	Fossa poplitea
Regio antibrachii dorsalis	Regio cruris anterior
Regio antibrachii radialis	Regio cruris posterior
Regio antibrachii ulnaris	Regio suralis
Regio dorsalis manus	Regio cruris lateralis
Regio volaris manus	Regio cruris medialis
Regiones digitales [manus]	Regio malleolaris lateralis
Regiones dorsales digitorum	Regio malleolaris medialis
Regiones unguiculares	Regio retromalleolaris lateralis
Regiones volares digitorum	Regio retromalleolaris medialis
Regiones extremitatis in-	Regio calcanea
ferioris	Regio dorsalis pedis
Regio femoris anterior	Regio plantaris pedis
Fossa subinguinalis	Regiones digitales pedis
Regio femoris lateralis	Regiones dorsales digitorum pedis
Regio trochanterica	Regiones unguiculares
Regio femoris posterior	Regiones plantares digitorum pedis



- Posterior region of elbow  
     Region of olecranon  
 Lateral region of elbow  
 Medial region of elbow  
 Volar region of forearm  
 Dorsal region of forearm  
 Radial region of forearm  
 Ulnar region of forearm  
 Dorsal region of the hand  
 Volar region of the hand  
 Regions of the digits of the hand  
     Dorsal regions of digits  
     Regions of the nails  
     Volar regions of digits  
 Regions of lower extrem-  
     i t y  
 Anterior region of the thigh  
     Fossa below the groin  
 Lateral region of thigh  
     Region of the trochanter  
 Posterior region of thigh  
     Medial region of thigh  
 Anterior region of the knee  
     Region of the patella  
 Posterior region of knee  
     Popliteal fossa  
 Anterior region of the leg  
 Posterior region of leg  
     Region of the calf  
 Lateral region of leg  
 Medial region of leg  
 Region of lateral malleolus  
 Region of medial malleolus  
     Lateral retromalleolar region  
     Medial retromalleolar region  
 Region of the heel  
 Region of the dorsum of foot  
 Region of the sole of the foot  
 Regions of the digits of the foot  
 Dorsal regions of the digits of the foot  
 Regions of the nails  
 Plantar regions of the digits of the foot

## Explanatory Notes to Certain of the Terms.

While there can be no doubt as to the exact meaning of the majority of the names in the list, there are some names included which hitherto have been used with different meanings in different text-books, and here and there a new term, not to be found in any of the text-books, is included.

To indicate the exact meaning of these, Professor His, with the approval of the editing committee, wrote a series of brief explanatory notes. Thus, for example, the designations regarding the position and direction of parts of the body are explained, *transversalis* meaning across the axis of the body, *transversus* across the axis of the organ concerned. The word *intermedius* is used for the position midway between *medialis* and *lateralis* in order to avoid the juxtaposition of words sounding so much alike as *medius* and *medialis*; between *anterior* and *posterior* or between *externus* and *internus* the adjective *medius* is retained. The notes contain a long discussion on the nomenclature of "glands" and "lymphglands." In connection with general terms it is noted that *discus* means "disc," while *meniscus* means "crescent." In the osteological notes the terms *glabella*, *infundibulum ethmoidale*, and *sulci paraglenoidales* are, among others, clearly defined. Comments on the *Pars lacrimalis m. orbicularis* or Horner's muscle, the *M. quadratus labii superioris* (the old "Mm. levator labii superioris proprius, levator labii superioris alæque nasi and zygomaticus minor" combined), the *Raphe pterygomandibularis*, the *Fasciculi transversi* of the palmar aponeurosis, the *Scalenus minimus*, the *Ligamentum fundiforme penis*, the *Falx inguinalis* (the old "conjoined" tendon or Henle's ligament), and the *Ligamentum interfoveolare* (Hesselbach's ligament) are made in connection with myology.

Some rather important notes accompany the splanchnological terms. Certain new terms have been adopted in the tonsillar region, partly on embryological grounds. The *Recessus pharyngeus* of Rosenmueller is exactly defined, as is also the *Bursa pharyngeus* (p. 128). In connection with the *Pars analis recti* attention is called to the excellent description given by the French anatomists, Sappey and Testut. A number of the names for parts of the nose and larynx have been drawn from the special literature. The less familiar of these in the nose—*Limen nasi*, *atrium meatus medii*, *agger nasi*, *Sulcus olfactorius*, *Recessus sphenoehtmoidalis*, *meatus nasopharyngeus*, *Meatus nasi communis*, *Processus sphenoidalis septi cartilaginei*—are explained. In the larynx marked precision has been arrived at and a great advance in nomenclature has been made. The old terms *Glottis vera* and *Glottis spuria* have been done away

with; the terms adopted throughout are exceedingly satisfactory. The names for the genitourinary organs are nearly all easily understood; the terms *Annulus urethralis vesicæ*, *Crista urethralis*, *Corpus glandulare prostatae*, *Isthmus prostatae*, *Colliculus seminalis* (the old *Caput gallinaginis*) are especially dealt with.

As might have been expected, there are numerous notes upon the pelvic floor and the pelvic fascia. After the notes were written the Commission changed *Trigonum urogenitale* to *Diaphragma urogenitale*. The floor of the pelvic cavity is formed by the *M. levator ani* and the *M. coccygeus*, and to this muscular funnel the name *Diaphragma pelvis*, suggested by H. Meyer, is given; the fascia above it is called the *Pars diaphragmatica fasciæ pelvis*, that below it the *Fascia inferior diaphragmatis pelvis*. The two parts of the Fascia pelvis are designated *Pars diaphragmatica* and *Pars endopelvina*, instead of, as of yore, *Pars parietalis* and *Pars visceralis*, the reason being that the latter terms are used only for serous membranes. The distinction between the *Arcus tendineus musculi levatoris ani* (the tendinous arch helping to give origin to the *M. levator ani* interwoven with the obturator fascia, whose two extremities reach to the upper margin of the pelvis) and the *Arcus tendineus fasciæ pelvis* is sharply drawn; the latter crosses the former and the two are easily separable from one another.

The *Diaphragma urogenitale*, the triangular mass of tissue stretching across between the pubic rami leaving a space at its upper end (beneath the *Lig. arcuatum*) open for the passage of the *Vena dorsalis penis* (s. *clitoridis*), is described as having a framework made up of two powerful fascial layers, the *Fascia diaphragmatis urogenitalis superior* (the old "deep layer of the triangular ligament"), and the *Fascia diaphragmatis urogenitalis inferior* (the old "superficial layer of the triangular ligament"). These two fasciæ are fused at their upper and lower margins, enclosing a flat slit-like space. The union of the upper margins gives rise to the *Lig. transversum pelvis*. The compartment between the two layers (middle perineal compartment) is traversed by the membranous urethra with its *M. sphincter urethrae membranaceæ*. In the compartment lie the *M. transversus profundus*, Cowper's glands, and numerous venous plexuses. The term "*Fascia perinei propria*" has been dropped; it was used in so many different ways that students were confused by it.

The revision of the names for the peritoneum seems satisfactory. By *Membrana mesenterii propria* is meant the layer of connective tissue remaining after removal of the two peritoneal layers; it carries the blood and lymph-vessels, lymph glands, and fat. The division of the *Bursa omentalis* (lesser peritoneal cavity) into a *Vestibulum*, *Recessus superior*, *Recessus inferior*, and *Recessus lienalis*, is important. The *Plica gastropancreatica* is explained.

The old name of suspensory ligament of the liver has been changed to *Lig. falciforme hepatis* for obvious reasons.

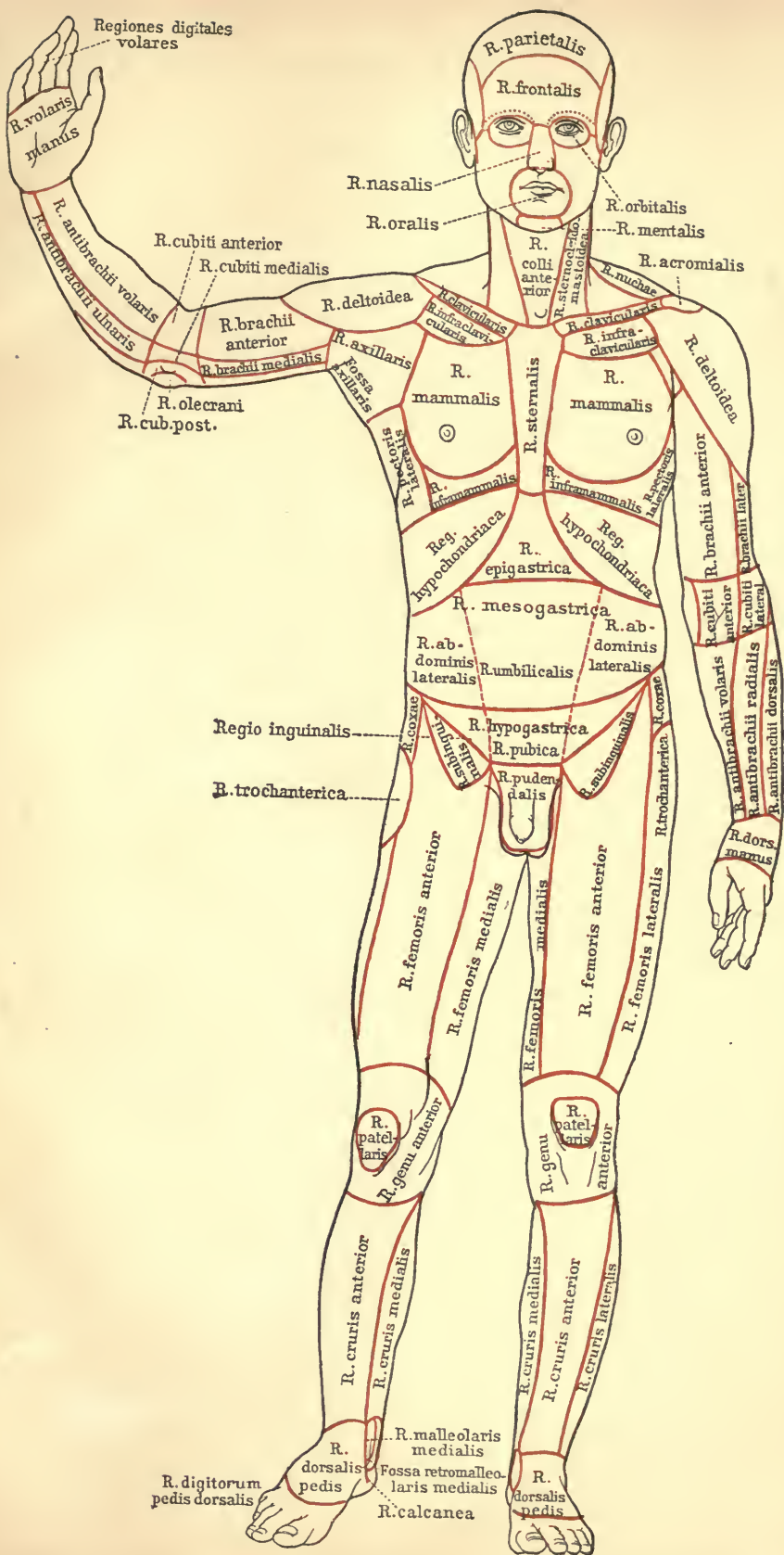
On the following terms of gynaecological anatomy comments are made: *Lig. suspensorium ovarii*, *Bursa ovarica*, and *Parametrium*.

The angiological notes are meagre, it being assumed that the names are in general wholly intelligible; a few names of parts of the heart are commented on and the question of the veins about the navel is thoroughly ventilated.

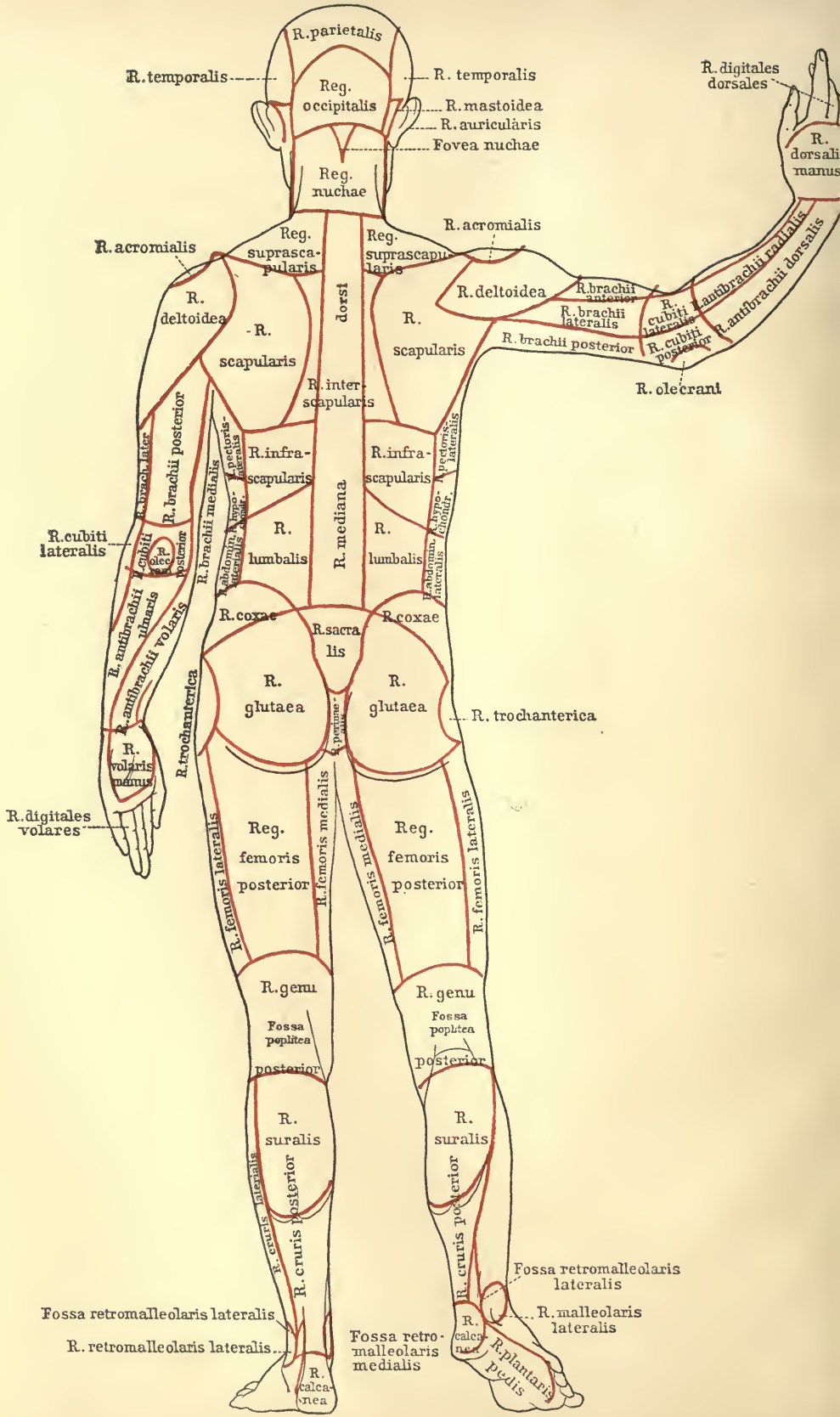
The neurological notes are in accord with the well-known nomenclature based on the embryological studies of His, and those familiar with his work will find but little new in them.

These notes are not more fully incorporated into this volume for two reasons: (1) They are easily accessible to those who desire to refer to them in the *Arch. f. Anat. u. Entwicklungs geschichte* (1895), and (2) they would have inconveniently enlarged the size and increased the price of the present publication.









R. parietalis  
 R. temporalis  
 Reg. occipitalis  
 R. mastoidea  
 R. auricularis  
 Fovea nuchae

R. digitales dorsales  
 R. dorsalis manus

R. acromialis  
 Reg. suprascapularis  
 Reg. suprascapularis  
 R. deltoidea  
 R. scapularis  
 R. inter-scapularis  
 R. infra-scapularis

R. acromialis  
 R. deltoidea  
 R. brachii anterior  
 R. brachii lateralis  
 R. brachii posterior  
 R. olecrani  
 R. antibrachii radialis  
 R. antibrachii dorsalis

R. cubiti lateralis  
 R. cubiti posterior  
 R. olecrani posterior  
 R. brachii posterior  
 R. brachii medialis  
 R. infra-scapularis  
 R. mediana  
 R. lumbalis

R. pectoralis lateralis  
 R. abdominis lateralis  
 R. abdominis medialis

R. antibrachii ulnaris  
 R. antibrachii volares  
 R. trochanterica  
 R. glutea  
 R. trochanterica  
 R. glutea  
 R. trochanterica

R. digitales volares

Reg. femoris posterior  
 R. femoris posterior  
 R. femoris medialis  
 R. femoris medialis  
 R. femoris lateralis  
 R. femoris lateralis

R. genu  
 Fossa poplitea posterior  
 R. genu  
 Fossa poplitea posterior

R. suralis  
 R. cruris posterior  
 R. suralis  
 R. cruris posterior

Fossa retromalleolaris lateralis  
 R. retromalleolaris lateralis

Fossa retromalleolaris lateralis  
 R. malleolaris lateralis  
 Fossa retromalleolaris medialis  
 R. calcanea  
 R. plantaris pedis





**A**  
**LIST OF BOOKS**

**ON**

**Anatomy, Physiology,  
Histology, Biology,  
Embryology, Zoology**



**Published by**  
**P. Blakiston's Son & Co.**  
**Philadelphia.**



**Illustrated Circulars sent to  
any Address upon Application**

Arranged upon an Embryological Basis

Just Ready

# Stohr's Histology

Sixth American, from the Twelfth German Edition.

Revised and Arranged by **FREDERIC T. LEWIS**

*Assistant Professor of Embryology at the Harvard Medical School.*

With 450 Illustrations, 45 in Colors. Octavo; ix + 434 pages. Cloth, \$3.00 net.

THE need of a text-book of histology arranged upon an embryological basis has long been felt, and the opportunity to accomplish this arrangement was promptly embraced when Professor Stohr's generous permission was given to adapt a new edition of his book to American needs. As a leading Professor of Histology says, "the book is now in its arrangement and treatment something adequate as a statement of the present knowledge of the subject. The illustrations *illustrate*; the text *instructs*."

The Basle Anatomical Nomenclature (BNA) is used throughout.

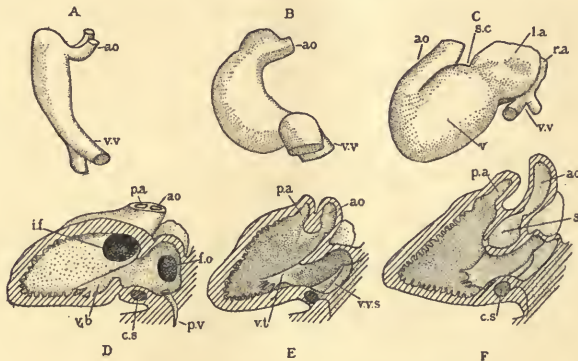


FIG. 159 (Reduced).—EMBRYONIC HEARTS.

A and B, from Rabbits 9 days after coitus, C, from a human embryo of 3 (?) weeks; D and E, from a 12 mm. pig (D sectioned on the left of the median septum, and E on the right of it); F, from a 13.6 mm. human embryo, sectioned like E.

**Synopsis of Contents.**—MICROSCOPIC ANATOMY. *Cytology:* The Cell; Form and Size of Cells; Vital Phenomena; Formation and Reproduction of Cells; Cytomorphosis. GENERAL HISTOLOGY: Histogenesis; Epithelia; Mesenchymal, Muscle, Nerve, and Vascular Tissues; Blood Forming and Blood Destroying Organs; Entodermal Tract; Urinary and Male and Female Genital Organs; Skin; Supra-renal Glands; Brain and Sense Organs. THE PREPARATION AND EXAMINATION OF MICROSCOPICAL SPECIMENS: Fresh Tissues; Isolation; Sectioning; Fixation; Decalcification; Imbedding; Staining and Mounting; General Stains; Special Stains; the Microscope; Drawings; Reconstruction.



# An Americanized Fourth Edition Rewritten and Revised

NEARLY READY

## Morris' Human Anatomy

A Complete, Systematic Treatise by American and English Authors

EDITED BY

**HENRY MORRIS**  
F.R.C.S.

and **J. PLAYFAIR McMURRICH**  
A.M., Ph.D.

*Consulting Surgeon to, and formerly Lecturer on Surgery and Anatomy at Middlesex Hospital, London. and Examiner in Anatomy, University of Durham, etc.*

*Professor of Anatomy, University of Michigan; Member Association of American Anatomists; Member of Advisory Board, Wistar Institute of Anatomy, etc.*

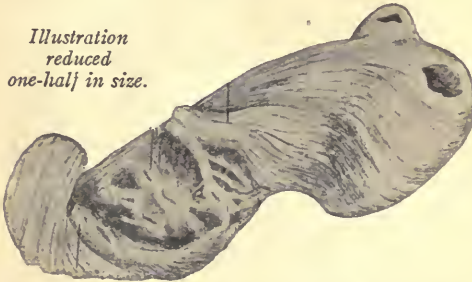
For the first time in the history of this famous work, American anatomists have been asked to contribute original articles and to rewrite and revise sections, the object in this being the desire to incorporate the very important results of recent investigations in the anatomical laboratories of the United States. The book has become international in scope, and with its widening

of view, of even greater usefulness to all English-speaking students.

Among the American contributors will be noted J. Playfair McMurrich, R. J. Terry, Irving Hardesty, G. Carl Huber, Abram T. Kerr, Charles R. Bardeen and Florence R. Sabin. Henry Morris, R. Marcus Gunn and W. H. A. Jacobson head the English contributors.

The text has been completely revised, and an additional feature of merit will be found in its **conformity with the new Anatomical Nomenclature (BNA)\***

*Illustration reduced one-half in size.*



THE VENTRICLES UNROLLED. (After MacCallum.)

*(Note:—It is not possible in this space to give a thoroughly representative illustration. That shown is one of a series depicting—according to Professor MacCallum, of Johns Hopkins University—the fact that the heart may be considered as three flat bands.)*

Very especial attention, in this new edition, has been paid to the illustrations, with the result that the teaching value of the book has been very materially increased.

Containing about 1024 Illustrations, of which many are in Colors. One Handsome Octavo Volume. Cloth, \$6.00. Sheep or Half Morocco. \$7.00, net. Or in Five Parts, as follows, each part sold separately.

PART I. Morphogenesis. Osteology. Articulation. Index.

PART II. Muscles. Organs of Circulation. Index.

PART III. Nervous System. Organs of Special Sense. Index.

PART IV. Organs of Digestion; of Voice and Respiration. Urinary and Reproductive Organs. Ductless Glands. Skin and Mammary Glands. Index.

PART V. Surgical and Topographical Anatomy. Index.

# Entomology

With Special Reference to Its Biological and Economic Aspects

By Justus Watson Folsom, Sc.D. (*Harv.*)

*Instructor in Entomology at the University of Illinois.*

Five Plates, 1 Colored, and 300 other Illustrations. 8vo; 485 pages. Cloth, \$3.00 net.

“‘Entomology,’ by Dr. Justus W. Folsom, is an advance over all other American works of its kind. It should be in the hands of every entomologist or entomological student, and in every public library. A most careful work, containing much information that only an expert has heretofore known where to find.”—MR. F. M. WEBSTER, *in charge of the Cereal and Forage Crops Insect Investigations, Department of Agriculture at Washington.*

A comprehensive and concise account of insects, written to meet the growing demand for a biological treatment of entomology. The aim has been to introduce much material that, hitherto, has not appeared in the text-books; and though adapted for students and teachers of entomology and zoology (being the only book that fills the actual teaching requirements) it will also be valuable to the professional and amateur entomologists and to the general reader, especially on account of its consideration of economic subjects. The book contains, in small compass, authenticated facts that have had to be sought in many foreign languages. The new illustrations, which are many, have been prepared by the author; the others have been copied, by permission from various authoritative sources.

**Synopsis of Contents:** Classification.—Anatomy and Physiology.—Development.—Adaptations of Aquatic Insects.—Color and Coloration.—Adaptive Coloration.—Origin of Adaptations and of Species.—Insects in Relation to Plants; to other Animals.—Interrelations of Insects.—Insect Behavior.—Distribution.—Insects in Relation to Man.—Literature.—Index.

“This is an eminently satisfactory work on insects, both from the standpoint of the school and of the general reader. It is the first adequate treatment of this subject as adapted to the science of entomology, and at the same time to agriculture, horticulture and forestry. It teaches every fact about insects that it is desirable to know from the point of view of popular science, and literally all that need be known from the economic. This is an admirable realization of the dream of the schoolmaster and of the general reader for a book at once comprehensive, concise and attractive.”—*Journal of Education, Boston.*

“Of high, practical importance” (*Outlook*). “it is a complete and concise account of insect life, planned to meet the growing interest in biology” (*School*). “The book is a noteworthy one” (*Psyche*), “and is a very valuable addition to the general work on the subject. It covers much ground not touched by the other books on insects” (*Entomological News*). “It is a book to lean upon and draw upon” (*School Bulletin*). “Will be most useful to the general student” (*Science*).

# Embryology

## The Development of the Human Body

By J. Playfair McMurrich, A. M., Ph. D.  
*Professor of Anatomy in the University of Michigan.*

Second Edition, Revised, Enlarged.  
With 272 Illustrations.  
12mo; 539 pages. Cloth, \$3.00 net.

A CONCISE statement of the development of the human body and a foundation for the proper understanding of the facts of anatomy. The comparative anatomy and development of the lower animals, too, is constantly referred to, a different style type being used for these references.

The assimilation of the enormous mass of facts which constitute what is usually known as descriptive anatomy has always been a difficult task for the student. Part of the difficulty has been due to a lack of information regarding the causes which have determined the structure and relations of the parts of the body, for without some knowledge of the "why" things are so, the facts of anatomy stand as so many isolated items, while with such knowledge they become bound together to a continuous whole and their study assumes the dignity of a science. The great key to the significance of the structure and relations of organs is their development, recognizing by that term the historical as well as the individual development.

**Synopsis of Contents:** PART I.—*General Development: The Spermatozoon and Spermatogenesis; the Ovum and Its Maturation and Fertilization; the Segmentation of the Ovum and the Formation of the Germ Layers; The Development of the External Form of the Human Embryo; The Medullary Groove, Notochord, and Mesodermic Somites; The Yolk-stalk, Belly-stalk, and the Fetal Membranes.* PART II.—*Organogeny: The Development of the Integumentary System; Connective Tissues and Skeleton; Muscular System; Circulatory and Lymphatic Systems; Digestive Tract and Glands; Pericardium and Pleuro-peritoneum, the Diaphragm and the Spleen; Organs of Respiration; Urinogenital System and the Suprarenal Bodies; Nervous System; Organs of Special Sense; Post-Natal Development; Index.*

"Right up to date."—*Lancet, London.*

## A Laboratory Text-Book of Embryology

By Charles S. Minot, S. D., LL. D.  
*Professor of Histology and Human Embryology, Harvard University Medical School.*

With 218 Illustrations, mainly original.  
Quarto; 380 pages. Cloth, \$4.50 net.

This work is intended primarily for the use of students taking a practical laboratory course in Embryology. The author's experience has led him to believe that the study of carefully selected sections of embryos, accompanied by directions and explanations of the significant structures in each section, offers many advantages. This conviction has determined the arrangement of the book. Attention is given chiefly to such points as serve to explain adult anatomical relations, to illustrate general biological principles, and to afford insight into pathological processes.

**Synopsis of Contents:** General Conceptions.—The Early Development of Mammals.—The Human Embryo.—Study of Pig Embryos.—Study of Young Chick Embryos.—Study of the Blastodermic Vesicle and the Segmentation of the Ovum.—Study of the Uterus and the Foetal Appendages in Man.—Methods.—Index.

"This new laboratory text-book of Embryology is worthy of particular attention. It is a practical guide of a novel and original type, which is to be recommended as a valuable aid in laboratory teaching of a difficult nature. It is a valuable addition to the list of available text-books of Embryology. In fact, the book stands by itself and is an original departure in a very desirable direction, introducing the student to the subject by a practical method which promises excellent results. After a year's experience with it, we feel much confidence in its success."—*Bulletin of the Johns Hopkins Hospital.*



# First Course In Zoology

A NEW TEXT-BOOK FOR SECONDARY SCHOOLS,  
NORMAL SCHOOLS, AND COLLEGES

By **T. W. Galloway, Ph. D.**

*Professor of Biology, James Millikin University, Decatur, Illinois.*

With 240 Illustrations. Octavo; 460 pages. Cloth, \$2.50 net.

**T**HE AUTHOR has endeavored in this book to present a balanced course in Zoology which will be suitable to beginning classes in the last years of the High School or the first year of College. It provides specifically for class-room work, reference work in the library, laboratory work, and field work. It includes a brief treatment of the fundamental principles of the science in the first part of the book; the second part, which contains a discussion of the great branches of the animal kingdom, is treated as a concrete illustration of these general principles.

Among many other distinctive excellences are seven features which give the work especial merit: (1) It follows no fads; (2) Because of the wealth of practical exercises suggested, it provides more work than any one class can cover in the time allotted; (3) Much collateral work in the library, field and laboratory is outlined; (4) The practical work is placed upon the broader problems of physiology, of the relations of animals to the environment, and of the adaptations of organic form to needs, rather than upon dissection and minute anatomy; (5) The practical (i. e. the laboratory, field and library) work is interspersed through the text in such a way as to illustrate and enforce the more abstract definitions; (6) Especial emphasis is put upon the illustrations; (7) There are numerous analytical reviews and summaries.

**Synopsis of Contents:**—Introduction.—Protoplasm: Its Morphology and Physiology.—The Animal Cell: Its Morphology and Physiology.—From the Simple Cell to the Complex Animal.—Cellular Differentiation.—Tissues.—General Animal Functions and Their Appropriate Organs.—Promorphology.—Individual Differentiation and Adaptation.—A General Preview of the Animal Kingdom.—Protozoa.—Porifera.—Coelenterata.—Unsegmented “Worms.”—Echinodermata.—Annulata: Segmented “Worms.”—Mollusca.—Arthropoda.—Chordata: Proto-vertebrata.—Chordata: Vertebrata.—Pisces.—Amphibia.—Reptilia.—Aves.—Mammalia.—General Summary.—A Review Outline.—Appendix.—Suggestions to Teachers.—Index.

“Galloway’s ‘First Course in Zoology’ is one of the authoritative text-books. The teacher may refer to it with confidence, and cannot fail to do so with profit.”—*School Bulletin.*

# The Nervous System of Vertebrates

By J. B. Johnston, Ph. D.

*Professor of Zoology in West Virginia University.*

With 180 Illustrations, the majority from original drawings.

Octavo; xx+370 pages. Cloth, \$3.00 net.

THE attempt has been made in this book to give an account of the nervous system as a whole, to trace its phylogenetic history and to show the factors which have determined the course of evolution. The functional point of view, which is the chief characteristic of the present book, brings the treatment of the nervous system into close relation with the work of recent years on the behavior of animals. The study of behavior aims to give an account of the actions of animals in relation to the environment. The study of the nervous system aims to describe the mechanism by which actions are directed and adapted to the conditions of life. A text-book of comparative neurology at the present time must meet the needs of workers of all grades, students, investigators and instructors. Its descriptions should be intelligible to students who have had one year of work in zoology or medicine, including the anatomy and embryology of some vertebrate. On the other hand, there should be included all facts which are important for the functional and phylogenetic mode of treatment. Every effort has been made to bring out clearly the functional significance and relationships of the structures described, and to interest and train the student in the interpretation of structure in terms of function, adaptation and evolution. The (BNA) terms, which are now the most generally familiar, have been employed so far as possible. Much material has been collected which is published here for the first time.

## Two prominent instructors say:

"It is an exceedingly useful piece of work,—well done." "Professor Johnston's text-book makes a valuable addition to our researches and represents the newer developments of neurological science in a way which, so far as I know, no other book has even attempted."

**Synopsis of Contents:**—Study of the Nervous System.—General Morphology of the Nervous System.—Development of the Nervous System.—Nerve Elements and their Functions.—The Functional Divisions of the Nervous System.—Somatic Afferent Division; General Cutaneous Subdivision; Special Cutaneous Subdivision; Visual Apparatus.—Visceral Afferent Division.—Olfactory Apparatus.—Somatic Motor Division.—Visceral Efferent Division.—Sympathetic System.—Centers of Correlation.—Cerebellum.—Centers of Correlation; Mesencephalon and Diencephalon.—Evolution of the Cerebral Hemisphere.—Neopalium. Bibliography and Laboratory Work Suggestions at end of each Chapter.



# Surgical Anatomy

A Treatise on Human Anatomy in its Application  
to the Practice of Medicine and Surgery

By John B. Deaver, M.D.

*Surgeon-in-Chief to the German Hospital, Philadelphia, etc., etc.*

“The reader is not only taken by easy and natural stages from the more superficial to the deeper regions, but the various important regional landmarks are also indicated by schematic tracing. . . In summing up the general excellences of this remarkable work, we can accord our unqualified praise for the accurate, exhaustive, and systematic manner in which the author has carried out his plan, and we can commend it as a model of its kind, which must be possessed to be appreciated.”—*Medical Record, New York.*

Three Royal Octavo Volumes, of 2157 pages, containing 499 Full-page Plates engraved from original drawings made by special artists from dissections prepared for the purpose in the dissection-rooms of the University of Pennsylvania. *Sold by Subscription, in Complete Sets Only.* Leather or Half-Morocco, Marbled Edges, \$30.00; Half-Russia, Gilt, Marbled Edges, \$33.00 *net.*

**Synopsis of Contents:** (*Number of Illustrations in Parentheses.*)  
**Vol. I.**—Upper Extremity (95); Back of Neck, Shoulder, and Trunk (24); Cranium, Scalp, Face (32). 632 pages; 151 Plates. **Vol. II.**—Neck (47); Mouth (3); Pharynx (6); Larynx (10); Nose (9); Orbit (8); Eye (14); Ear (12); Brain (32); Joints of Head and Neck (4); Male Perineum (17); Female Perineum (8). 709 pages; 170 Plates. **Vol. III.**—Abdomen (74); Pelvis (16); Chest (32); Lower Extremity (56). 816 pages; 178 Plates.

“In order to show its thoroughness, it is only necessary to mention that no less than twelve full-page plates are reproduced in order to accurately portray the surgical anatomy of the hand, and it is doubtful whether any better description exists in any work in the English language.”—*Journal of the American Medical Association.*

“The illustrations are lavishly supplied and are both helpful and informing. . . . No better text-book of surgical anatomy is in existence, and we can confidently predict that Dr. Deaver has satisfied the needs of the profession for at least a generation.”—*The British Medical Journal, London.*

# THE LOOSE LEAF SYSTEM OF LABORATORY NOTES

FOR GUIDANCE IN THE DISSECTION AND  
ELEMENTARY STUDY OF ANIMAL TYPES

Prepared by

THEO. H. SCHEFFER, A. M.

Assistant Professor of Zoology, Kansas State Agricultural College.

Octavo ; vi + 112 pages. Strong Adjustable Cloth Covers, Cloth, \$1.00 net.

## Excerpts From the Preface:

INSTRUCTORS in biology very generally direct the laboratory work by means of written or printed guides placed in the hands of the student. These are sometimes hastily prepared for the occasion, or, if more elaborated, the sheets furnished the student at various times are not uniform in size and will not fit in with any system of notes which he may be keeping.

The LOOSE LEAF guides are the results of several years' experience in directing zoological work in high school and college laboratories. The sheets outlining the work on each type of animal are separate, so that they may be incorporated with the student's drawings and notes on that particular type. The recorded information on the subject is thus collected together, not only simplifying at the time the work of studying the specimen, taking notes, and indexing the drawings, but making future reference to the records an easy matter. Then, too, the laboratory guides being thus bound in with the student's notes, do not become scattered or lost.

The twenty-one types of animal life herein treated give the student a brief general survey of the field from Protozoan to Vertebrate. Similar treatment is accorded each type. It will be noted that the zoological position of each animal is given (*Parker and Haswell's classification*), that its habitat receives attention, and that there are hints on collecting the material for class study. Details of structure that are very obscure are either omitted, or, if essential, attention is called to them without demonstration.

**Synopsis of Contents:** PROTOZOA. *Amæba; Paramæcium; Vorticella.* PORIFERA. *Marine Sponge.* COELENTERATA. *Fresh-Water Hydra; Hydroid; Hydroid Medusa.* PLATYHELMINTHES. *Flat-Worm.* ECHINODERMATA. *Starfish.* ANNULATA. *Earthworm.* ARTHROPODA. *Water-flea; Lobster or Crayfish; Centiped; Grasshopper; Spider.* MOLLUSCA. *Fresh-water Mussel; Snail; Squid.* CHORDATA. *Catfish; Frog or Toad; English Sparrow.*

"The book will prove useful in high school and elementary college courses."—*The Nation*.

"It is a most capital idea" (*School Bulletin*), "and is a most excellent system of keeping notes."—*Country Life in America*.

---

☞ Scheffer's "Loose Leaf System" is not bound in the usual manner. Each leaf is separate and the whole tied into strong adjustable cloth covers, so that leaves may be removed or notes and drawings may be inserted at any place.

# Blakiston's Manikins

**A Series of Twelve Manikins of the Head, Nose, Throat, Eye, Ear, Lungs, Heart, Stomach, Kidney, Liver, Foot, and Hand, with Descriptions of each.** ❧ ❧ ❧ ❧

One Volume. Octavo. Cloth, \$1.50 net.

The manikin of the HEAD shows 88 different structures; that of the ORAL CAVITY, with the PHARYNX, LARYNX, and TEETH, shows 61; the EYE, 44; the FOOT, 68; the HAND, 55; the LIVER, 47; the KIDNEY, 20; the STOMACH, 23; the NOSE, 32; the EAR, 24; the LUNGS, 18; and the HEART, 33,—A TOTAL OF 513 STRUCTURES.

The work is issued in book form, octavo in size, and embraces twelve manikins, some containing as many as ten flaps, lithographed in colors on heavy serviceable cardboard, the whole arranged to fold flat and compact when the volume is closed. Each manikin is cut to the exact shape of the organ illustrated, and the various flaps are intended to fold one upon the other in the order shown in nature, the deeper details becoming visible only when all the outer layers have been in their proper turn exposed. Every flap is printed on two sides, each side representing a different anatomical feature.

---

## A Manual and Atlas of Dissection

**By Simon Menno Yutzy, M.D.**

*Instructor in Osteology and Demonstrator of Anatomy in the University of Michigan.*

**With an Introduction by J. Playfair McMurrich, A.M., Ph.D.**

*Professor of Anatomy, University of Michigan; author of "A Manual of Human Embryology."*

This work is a topographical index, providing the reader with a list of the structures to be found during dissection; together with concise directions for procedure.

With 314 Illustrations, many in Colors. Large Octavo; 256 pages. Cloth, \$2.50 net.

"The author's experience as a teacher has effected an arrangement likely to be very useful to the student."—*New York Medical Journal.*



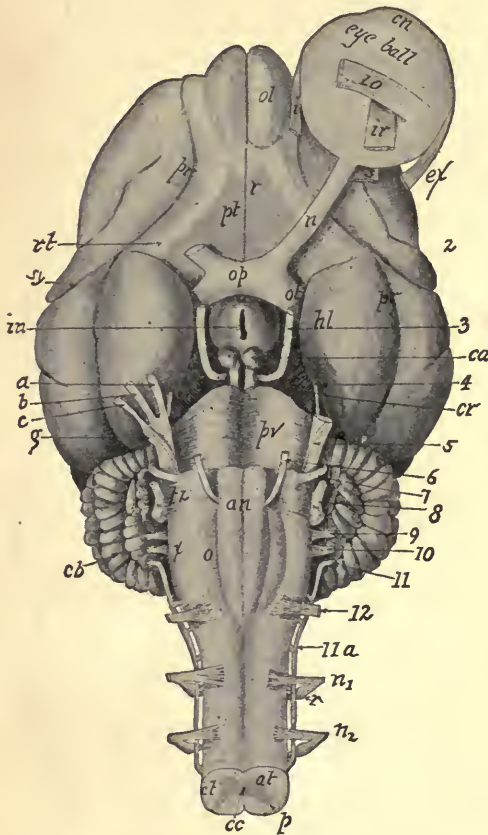
# Mammalian Anatomy

With Special Reference to the Cat

By Alvin Davison, Ph. D.

Professor of Biology in Lafayette College.

With over 100 Illustrations made by W. H. REESE, A. M., from the author's dissections. 12mo; 250 pages. Cloth, \$1.50 net.



VENTRAL ASPECT OF THE BRAIN.

THIS work is intended to acquaint the student with the general structure of the cat, and at the same time introduce him to some of the most important morphologic features of the Mammalian. All eminent zoologists agree on the desirability of beginning zoological work by studying one of the higher animals. Again, since the majority of college students have not time for the acquisition of a fruitful knowledge of both vertebrates and invertebrates, the study of the former is a matter of vital importance, as it enables the student to become familiar with the anatomy and physiology of his own body. It also has the advantage of throwing light on the significant problem of organic evolution, such as is not to be derived from the study of invertebrate forms. Professor Davison's work has a distinct place in biological study.

**Synopsis of Contents:**—The Biological Sciences—Classification of the Animal Kingdom—Preparation and Preservation of Material—General Structure of a Vertebrate—The Skeleton—The Joints—The Muscles—Organs of Digestion—The Vascular System—Respiratory System—Excretory and Reproductive Systems—Nervous System—Index.

“It is designed to fill the gap between the more detailed works and those which are merely laboratory guides, and to afford the student who cannot pursue a lengthy course of zoological study, a general idea of the structure of a mammal and of the principles of mammalian anatomy. The book furnishes an excellent idea of the structure of the cat, free from a superfluity of detail. Throughout the book are frequent remarks of a comparative nature, and at the close of each chapter is a list of questions or suggestions, for the most part of a general nature, which will serve as excellent topics for comment by the teacher or for collateral investigation under his direction by the student. An introductory chapter is devoted to an account of useful methods by which the dissection may be facilitated, and the text is illustrated by numerous figures and diagrams.”—*Science*.

A Text-Book of  
**Anatomy for Nurses**

Just Ready

**By Elizabeth R. Bundy, M.D.**

*Member of the Medical Staff of the Woman's Hospital of Philadelphia, etc., etc.;  
late Adjunct Professor of Anatomy, and Demonstrator of Anatomy in  
the Woman's Medical College of Pennsylvania; formerly  
Superintendent of Connecticut Training School  
for Nurses, New Haven.*

THE pupil-nurse in a training school has little time at command for the study of text-books, and conciseness, clearness and accuracy are essential requisites of any work written for her use. In this "Anatomy for Nurses" these requisites are observed, and nurses—pupil or graduate—will find in it a satisfactory aid to the acquirement of that knowledge of the human body which is necessary to the full understanding of their important duties.

Dr. Bundy, by reason of her positions, training and experience, is particularly well qualified to write such a book. It does not unnecessarily burden the mind of the student by endeavoring to reach into the domains of the physician, nor does it concern itself with useless abstract or theoretical matters. On the contrary, it fills a void for a work that is simple, terse, didactic,—one that, confining itself strictly to its own chosen field, is yet complete in all details of moment therein.

With a Glossary and 191 Illustrations, 34 of which are Colored.  
12mo; viii + 252 pages. Cloth, \$1.75 net, postage prepaid.



# Miscellaneous Books

---

---

Holden.

## Holden's Anatomy

A Manual of the Dissections of the Human Body

By **John Langton, F.R.C.S.**

*Surgeon to, and Lecturer on Anatomy at, St. Bartholomew's Hospital.*

**Seventh Edition, Carefully Revised by A. Hewson, M.D.**

*Demonstrator of Anatomy, Jefferson Medical College, Philadelphia, etc.*

320 Illustrations. Two small compact volumes. 12mo.

Vol. I. Scalp, Face, Orbit, Neck, Throat, Thorax, Upper Extremity.  
435 pages. 153 Illustrations. Oil Cloth, \$1.50 net.

Vol. II. Abdomen, Perineum, Lower Extremity, Brain, Eye, Ear, Mammary  
Gland, Scrotum, Testes. 445 pages. 167 Illustrations.  
Oil Cloth, \$1.50 net.

"The last edition of this standard work comes in two volumes instead of one as formerly. A few alterations have been made in the text, but the general character of the book is still maintained throughout, which is saying all of good that can be said of an anatomical classic."—*Medical Record, New York.*

---

## Human Osteology

Comprising a Description of the Bones, with Colored  
Delineations of the Attachments of the Muscles.

The General and Microscopical Structure  
of Bone and Its Development

Eighth Edition. Carefully Revised.

Edited by **Charles Stewart, F.R.S.**

and **R. W. Reid, M.D., F.R.C.S.**

With Colored Lithographic Plates and Numerous Illustrations. Cloth, \$5.25 net.

---

## Landmarks—Medical and Surgical

Fourth Edition. 8vo. Cloth, \$ .75 net

## **Miscellaneous Books (Continued)**

---

Gordinier.

### **The Gross and Minute Anatomy of the Central Nervous System**

**With a Chapter on the Embryology of the Central Nervous System**

**By H. C. Gordinier, A.M., M.D.**

*Professor of Physiology and of the Anatomy of the Nervous System in the Albany Medical College; Member American Neurological Association.*

With 48 Full-page Plates and 213 other Illustrations, a number of which are printed in Colors and many of which are original. Large 8vo. Cloth, \$6.00; Sheep or Half-Morocco, \$7.00, net.

"It represents much painstaking research and bears also the stamp of original investigation. It is unusually well written, and the illustrations, many of which are original, are well chosen. It is destined to take its place among the standard books of its class."—*N. Y. Medical Journal.*

---

Broomell.

### **Anatomy and Histology of the Mouth and Teeth**

**By Dr. I. N. Broomell**

*Professor of Dental Anatomy, Dental Histology, and Prosthetic Technics in the Pennsylvania College of Dental Surgery.*

Second Edition, Revised and Enlarged by 72 pages. 337 Handsome Illustrations, the majority of which are original. Large Octavo. Cloth, \$4.50; Leather or Half-Morocco, \$5.50, net.

"A most excellent manual and one of the most up-to-date textbooks upon the subject of the anatomy of the mouth which has appeared in recent years."—*The American Journal of Medical Sciences.*

---

Box and Eccles.

### **Clinical Applied Anatomy**

**or, the Anatomy of Medicine and Surgery**

**By Charles R. Box, M.D., F.R.C.S.**

*Lecturer on Applied Anatomy, St. Thomas's Hospital,*

**and W. McAdam Eccles, F.R.C.S.**

*Demonstrator of Operative Surgery, St. Bartholomew's Hospital.*

With 45 Plates, 12 Colored; 6 figures. 8vo; 471 pages. Cloth, \$4.00 net.

"This excellent work is one of the most practical and applicable to the needs of the medical practitioner or senior student which has yet appeared on the subject of applied anatomy. The plan pursued by the authors in this book has been to treat the subject entirely from a clinical point of view rather than that of the anatomist, with the result of making the work delightfully readable. Any author who can accomplish this with an anatomical subject, and without detracting from the technical value of his work, deserves and is bound to receive great credit."—*Medical Record, New York.*

## Miscellaneous Books (Continued)

Tomes.

### **Dental Anatomy**

**A Manual of Dental Anatomy, Human and Comparative**  
**By C. S. Tomes, D.D.S.**

263 Illustrations. Sixth Edition, Revised. 12mo. Cloth, \$4.00 net.

"This standard work on Dental Anatomy has been brought thoroughly up to date and is a distinct advance on any of the previous editions. At first written with a view of providing the dental student with the requisite knowledge for his qualifying examination it has since become a text-book for the student of biology in general. This fact, combined with the rapidly increasing literature on the subject, has, as the author points out, greatly enhanced the difficulty of bringing the book up to date. It is, however, needless to say that the work of editing has been carried out in an admirable way."—*Lancet, London.*

Ballou.

### **Equine Anatomy and Physiology**

**By Wm. R. Ballou, M.D.**

*Late Professor of Equine Anatomy, New York College of Veterinary Surgeons.*

With 29 Graphic Illustrations. 12mo. *Blakiston's ? Quiz-Compend ? Series.*  
Cloth, \$1.00 ; Interleaved for the Addition of Notes, \$1.25, net.

"One of Blakiston's series of Quiz-Compends. These Compends are based on popular text-books and the lectures of prominent professors, and are kept constantly revised, so that they represent the present state of the subjects upon which they treat. The one now before us supplies for students of veterinary anatomy and physiology a work which will answer their needs not only as a text-book, but also for work in the dissecting room."—*Science.*

Potter.

### **Compend of Anatomy** **Including Visceral Anatomy**

**By Samuel O. L. Potter, M.A., M.D., M.R.C.P.**  
(London)

*Formerly Professor of the Principles and Practice of Medicine, Cooper Medical College, San Francisco ; Major and Brigade Surgeon, U. S. Vol.*

Seventh Edition, Revised and greatly enlarged. With numerous Tables, 16 Plates and 138 other Illustrations. *Blakiston's ? Quiz-Compend ? Series.*  
Cloth, \$1.00 ; Interleaved for Taking Notes, \$1.25, net.

"Through the opportunity afforded a revision by the frequent editions of this manual, the author has given a concise and accurate work of anatomy. It makes an excellent text-book, permitting the teacher to enlarge upon the information given as the exigencies of the class-room demand."—*Bulletin of the American Academy of Medicine.*



# A Text-Book of Human Physiology

By **A. P. Brubaker, M.D.**

*Professor of Physiology and Hygiene at Jefferson Medical College; Professor of Physiology, Pennsylvania College of Dental Surgery, Philadelphia.*

Second Edition. Revised and Enlarged. With Colored Plates and 356 other Illustrations. Octavo; 715 pages.

Cloth, \$3.00; Leather or Half-Morocco, \$4.00, *net*.

"An admirable exposition of the facts of physiology brought down to the latest date. . . . The author's style is lucid, concise, and pleasing. The work is one which may be warmly commended in every respect."—*New York Medical Journal*.

---

# Landois' Human Physiology

Including Histology and Microscopical Anatomy,  
with Special Reference to the Require-  
ments of Practical Medicine

By **Dr. L. Landois**

*Professor of Physiology and Director of the Physiological Institute in the University of Greifswald.*

Tenth Edition. Revised and Enlarged.

Edited and Translated by **A. P. Brubaker, M.D.**

*Professor of Physiology at Jefferson Medical College, Philadelphia, etc.,*

and **Augustus A. Eshner, M.D.**

*Professor of Clinical Medicine, Philadelphia Polyclinic, etc.*

With 394 Illustrations. Octavo; 1027 pages.

Cloth, \$7.00; Leather or Half-Morocco, \$8.00, *net*.

"There is no other work of its kind in the English language which deals with the normal physiological processes so as to show where the physiological merges into the pathological, and how the facts of pathology are to be explained by, and how they are in reality of the same essence as, those of physiology. . . . The book will be useful to practitioners of medicine and to clinicians, while students reading for the higher examinations will find it a trustworthy guide to the fundamental facts of physiology and histology, and an encyclopædia of reference as well as an exposition of the latest discoveries and theories of physiology."—*The Lancet, London*.

"The author, editor, translator and publisher have unitedly produced a most valuable and attractive book which can in every way be depended upon as authoritative."—*American Medicine*.







85045

Barker, Lewellys F  
Anatomical terminology.

MA  
B

UNIVERSITY OF TORONTO  
LIBRARY

Do not

remove

the card

from this

Pocket.

Acme Library Card Pocket  
Under Pat. "Ref. Index File."  
Made by LIBRARY BUREAU, Boston

