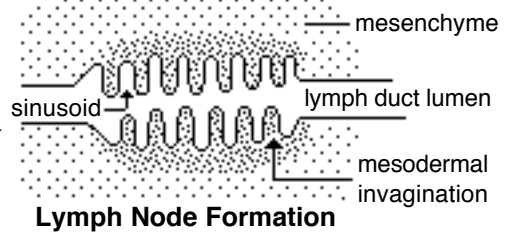


Lymphatics:

Lymph vessel formation is similar to blood angiogenesis. Lymphatics begin as lymph sacs in three regions: jugular (near brachiocephalic veins); cranial abdominal (future cisterna chyli); and iliac region. Lymphatic vessels (ducts) form as outgrowths of the sacs.

Lymph nodes are produced by localized mesodermal invaginations that partition the vessel lumen into sinusoids. The mesoderm develops a reticular framework within which lymphocytes accumulate. The spleen and hemal nodes (in ruminants) develop similar to the way lymph nodes develop.



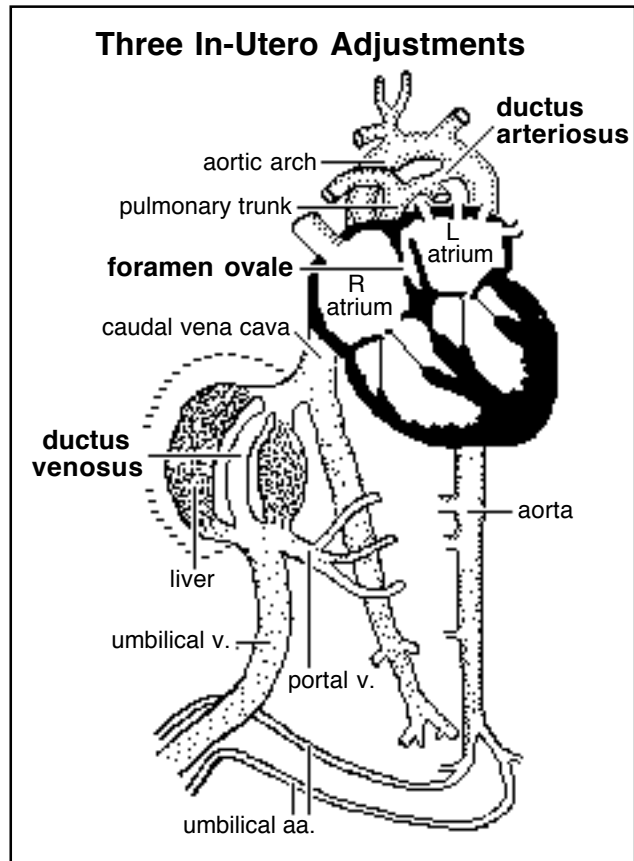
Prior to birth, fetal circulation is designed for an *in utero* aqueous environment where the placenta oxygenates fetal blood.

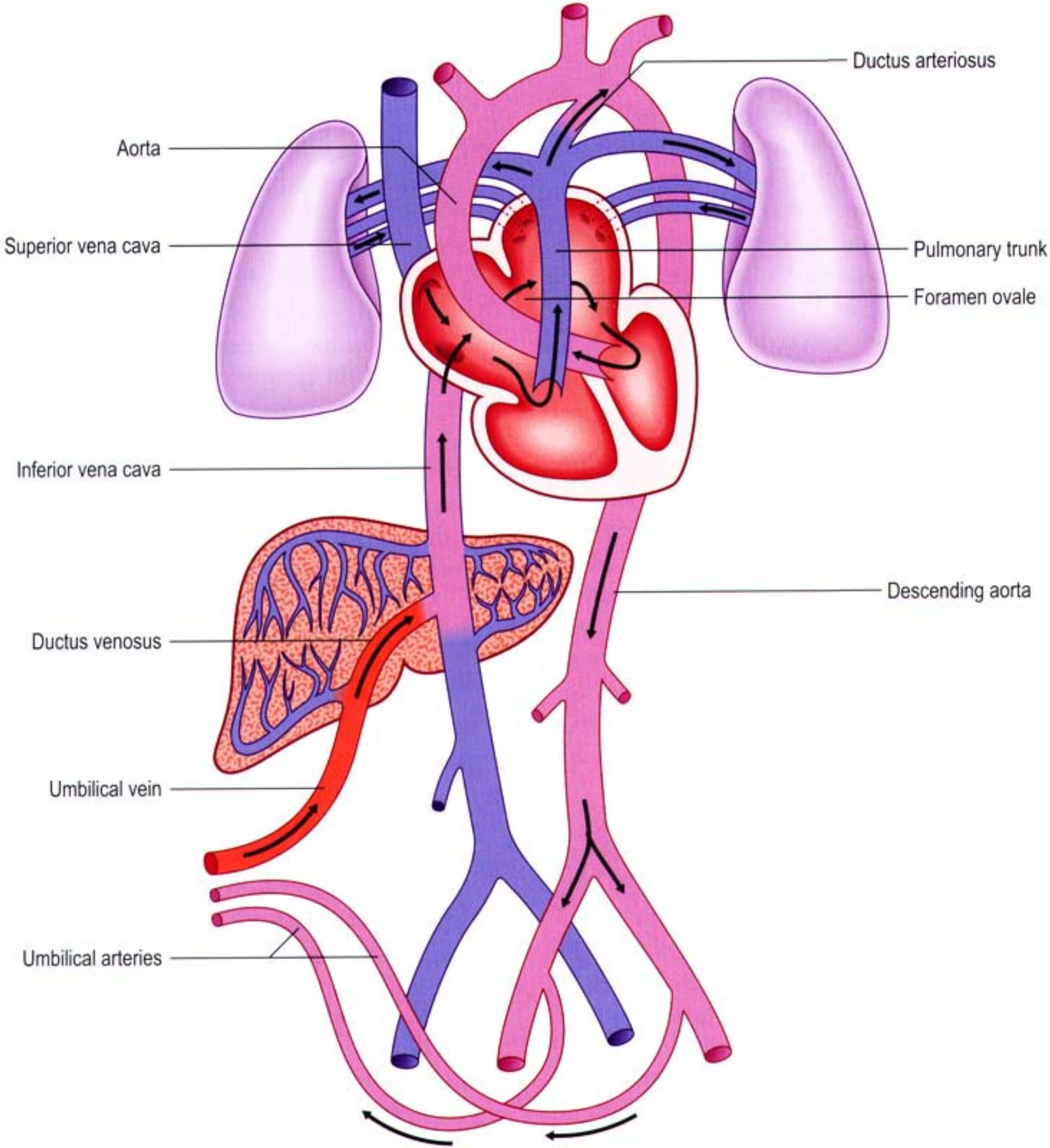
Suddenly, at birth...

Stretching and constriction of umbilical arteries shifts fetal blood flow from the placenta to the fetus. Reduced venous return through the (left) umbilical vein and ductus venosus allows the latter to gradually close (over a period of days).

Bradykinin released by expanding lungs and increased oxygen concentration in blood triggers constriction of the ductus arteriosus which, over two months, is gradually converted to a fibrous structure, the ligamentum arteriosum.

The increased blood flow to the lungs and then to the left atrium equalizes pressure in the two atria, resulting in closure of the foramen ovale that eventually grows permanent.





The cardiogenic area, the place where the embryonic heart originates, is located . . .

- A]** in splanchnic mesoderm anterior to the embryo (head)
- B]** in splanchnic mesoderm ventral to the pharynx
- C]** in splanchnic mesoderm within the thorax
- D]** in somatic mesoderm within the thorax

Cardiovascular System

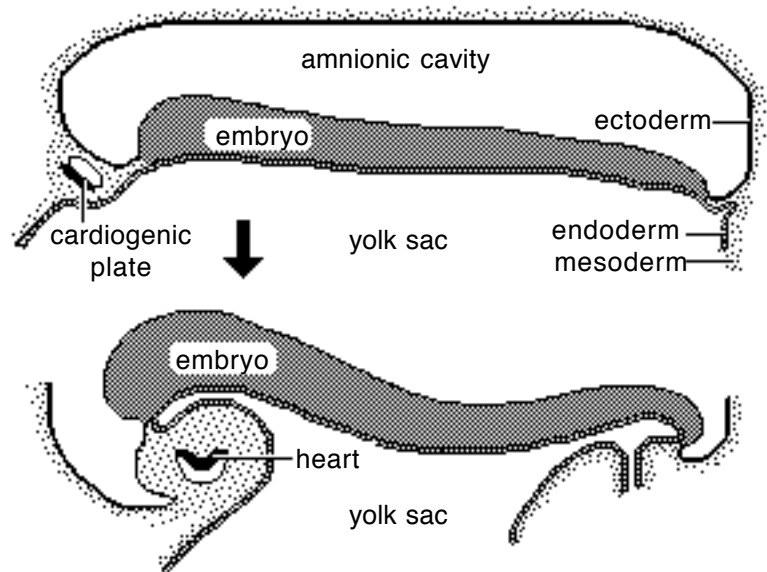
Note: The cardiovascular system develops early (week 3), enabling the embryo to grow beyond the short distances over which diffusion is efficient for transferring O₂, CO₂, and cellular nutrients & wastes.

Heart:

From a simple tube, the heart undergoes differential growth into a four chambered structure while it is pumping blood throughout the embryo and into extra-embryonic membranes. Major vessels form and the heart initiates a peristaltic pumping action during the third week in the dog.

Formation of a Tubular Heart:

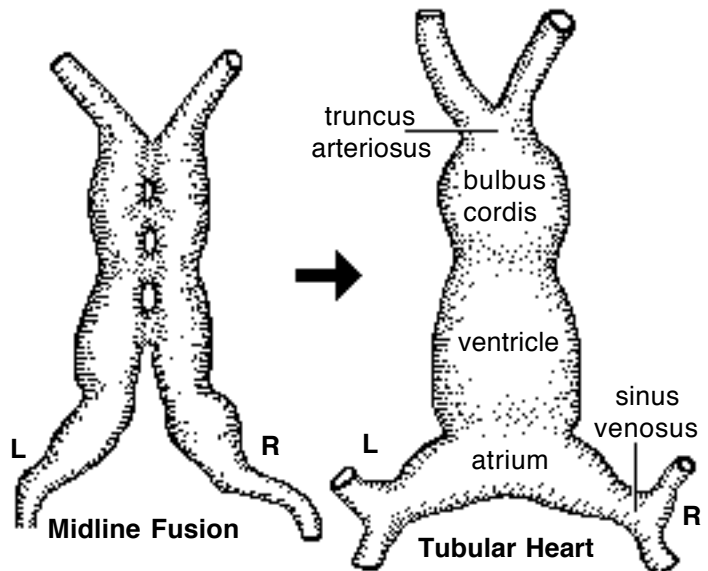
The first evidence of heart development is horse-shoe shaped vessel formation within the *cardiogenic plate*, which is splanchnic mesoderm situated anterior and lateral to the embryo. As the head process grows upward and outward, the cardiogenic plate shifts ventral to the pharynx and bilateral endocardial tubes meet at the midline & fuse into a single endocardial tube. Splanchnic mesoderm surrounding the tube forms cardiac muscle cells.



Primitive Heart Regions:

Differential growth of the endocardial tube establishes five primitive heart regions:

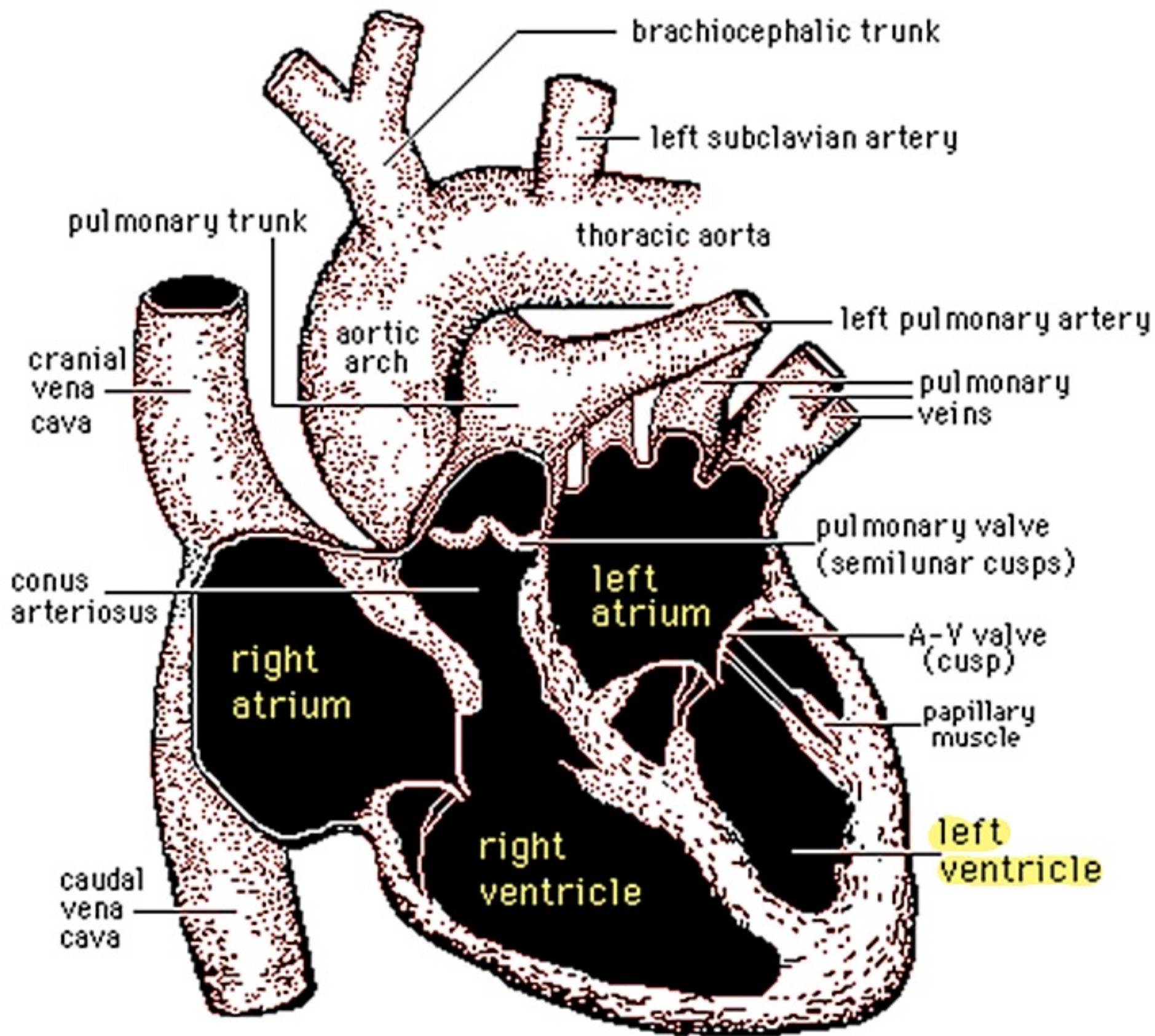
- 1] *Truncus arteriosus* — the output region of the heart. It will develop into the ascending aorta and pulmonary trunk.
- 2] *Bulbus cordis* — a bulb-shaped region destined to become right ventricle.
- 3] *Ventricle* — an enlargement destined to become the left ventricle.
- 4] *Atrium* — a region that will expand to become both right and left auricles.
- 5] *Sinus venosus* — a paired region into which veins drain. The left sinus venosus becomes the coronary sinus; the right is incorporated into the wall of the right atrium.

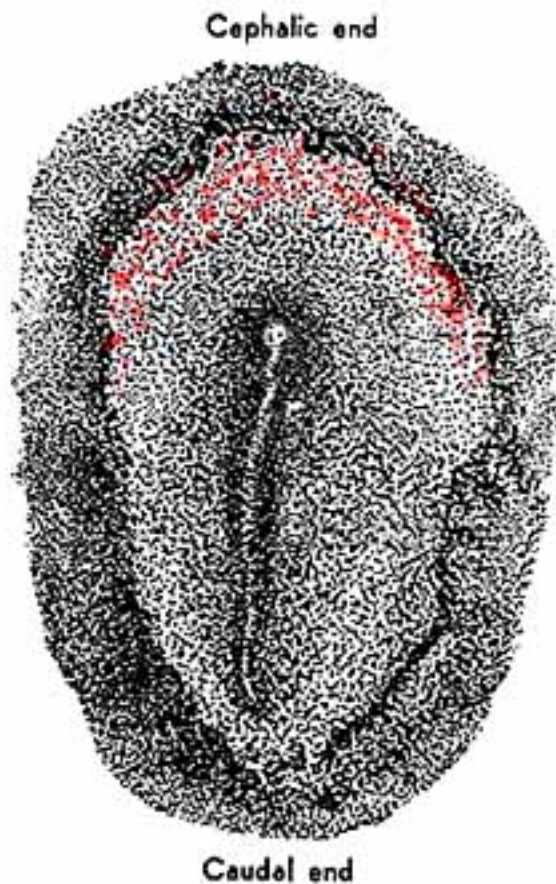
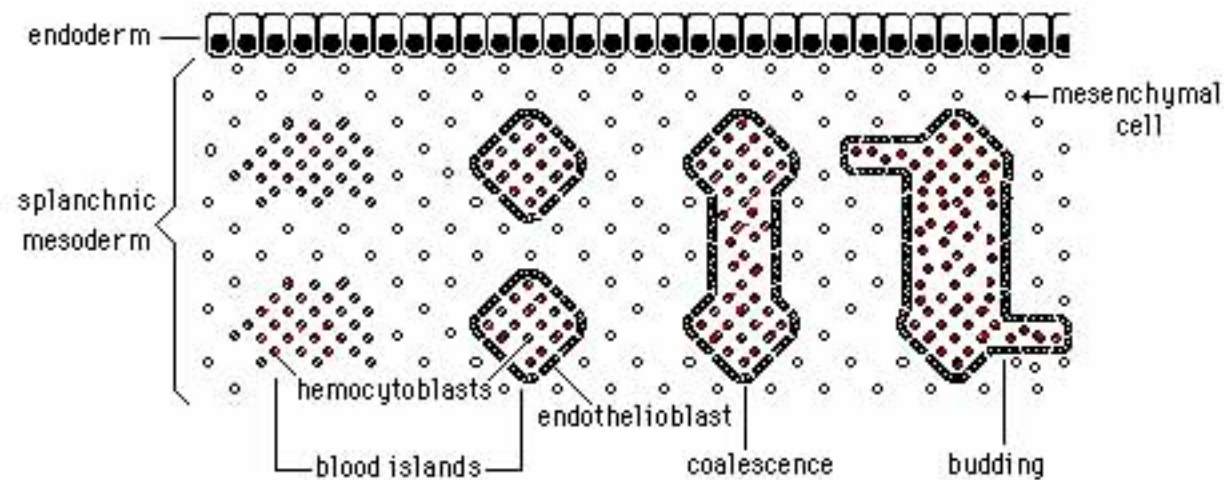


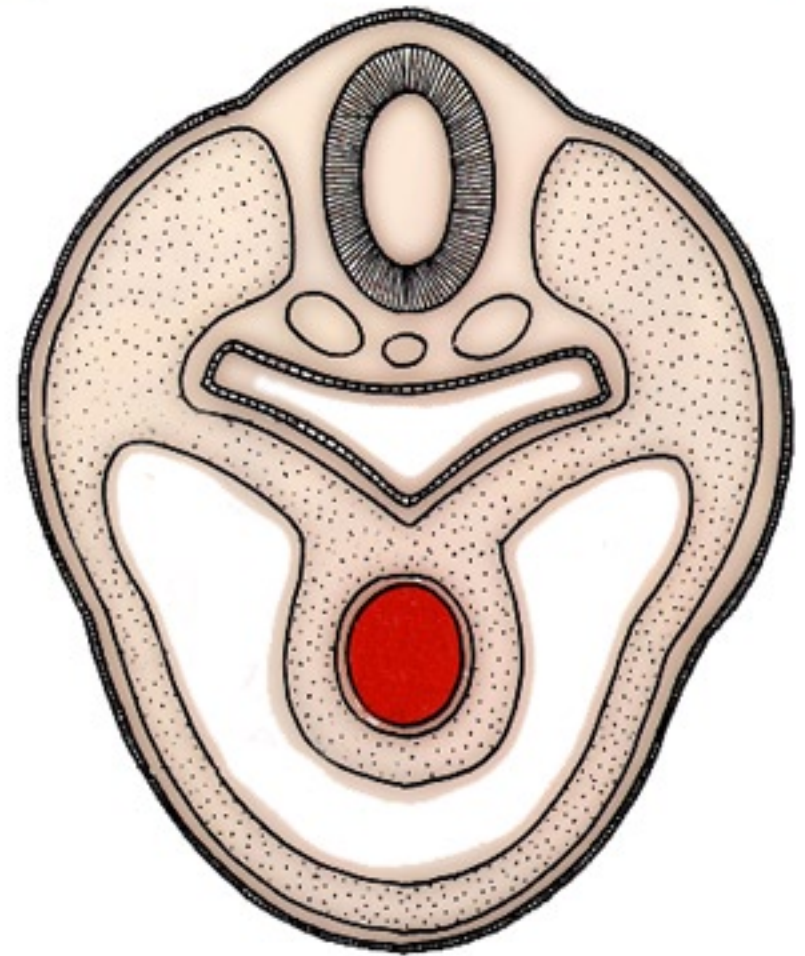
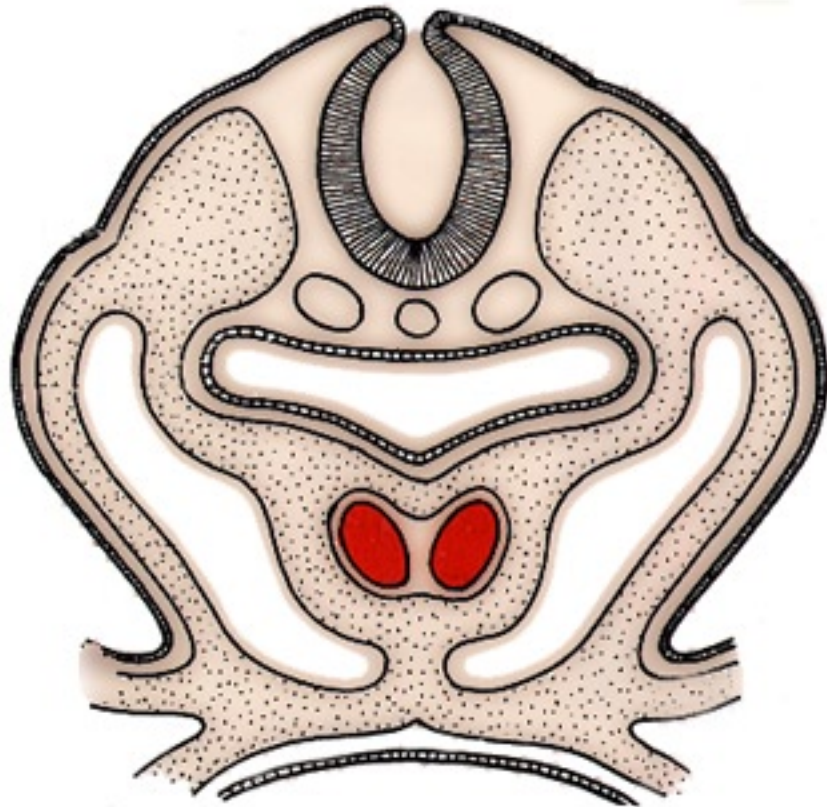
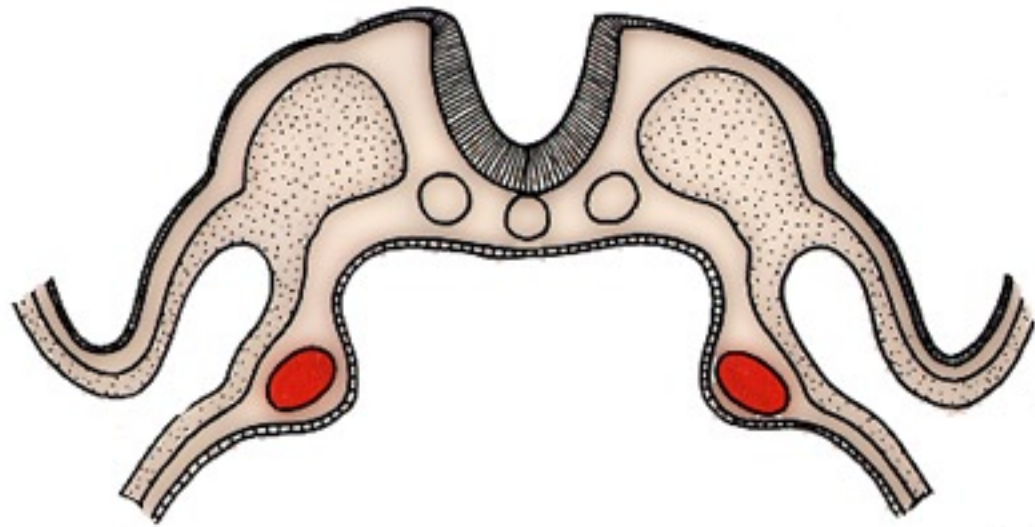
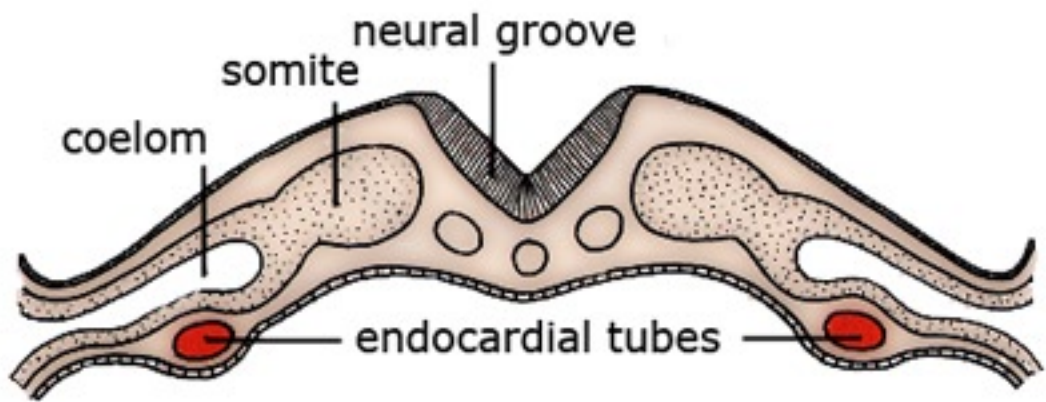
Forming a Four-Chambered Heart:

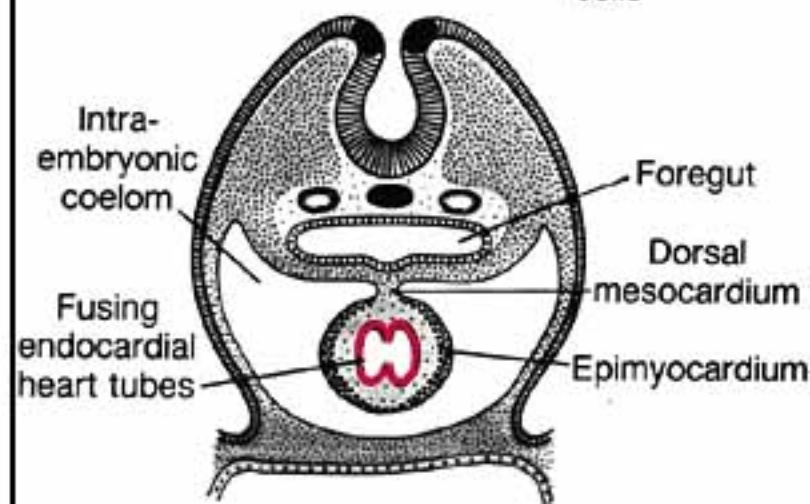
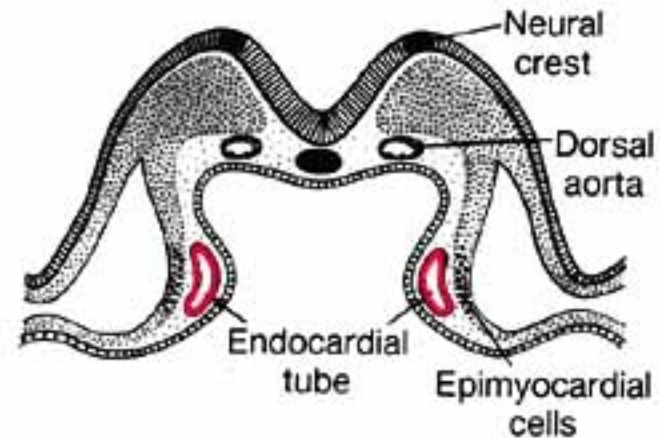
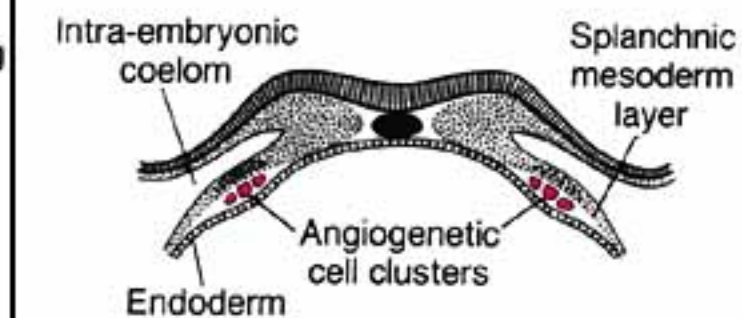
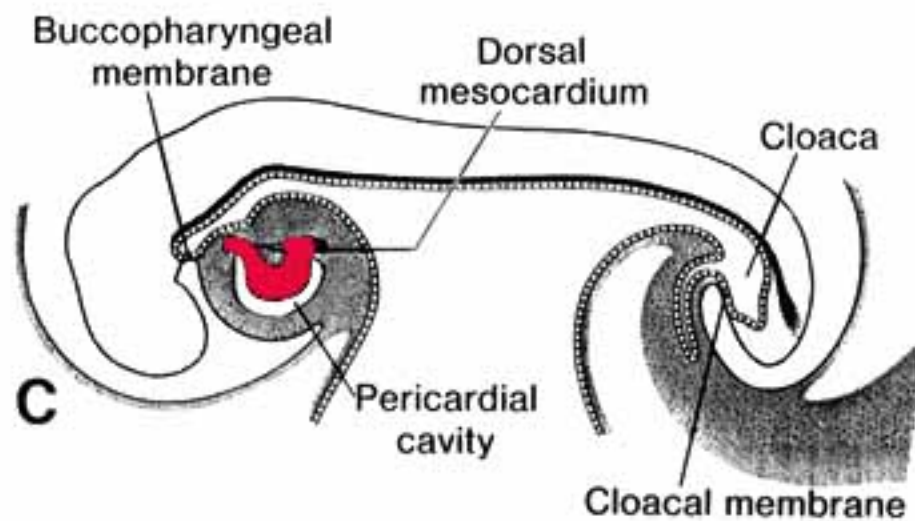
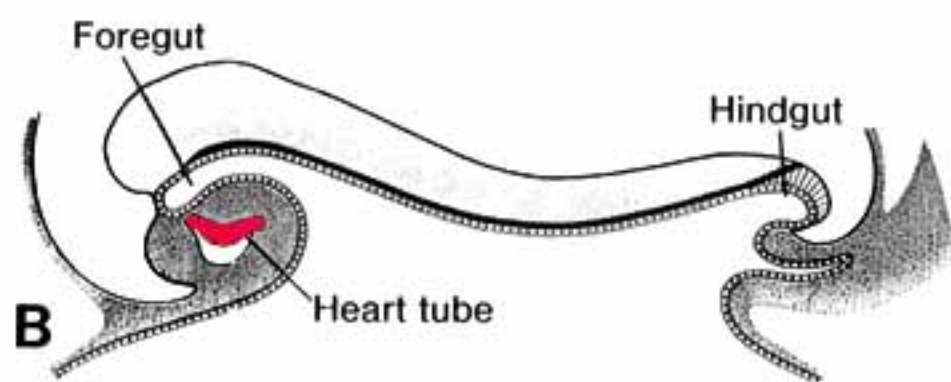
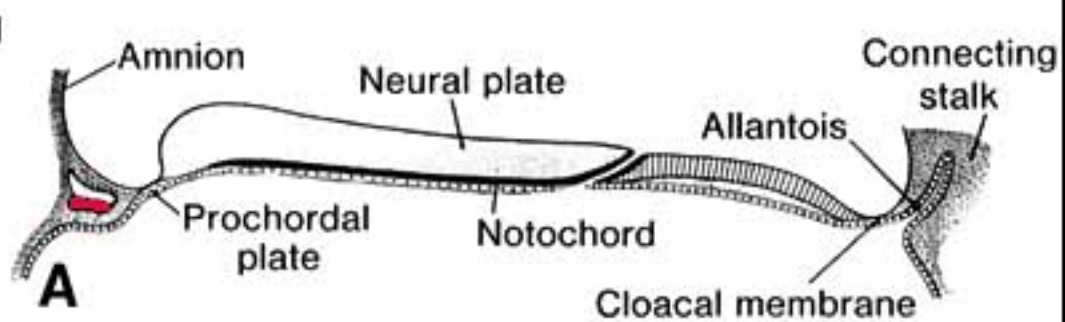
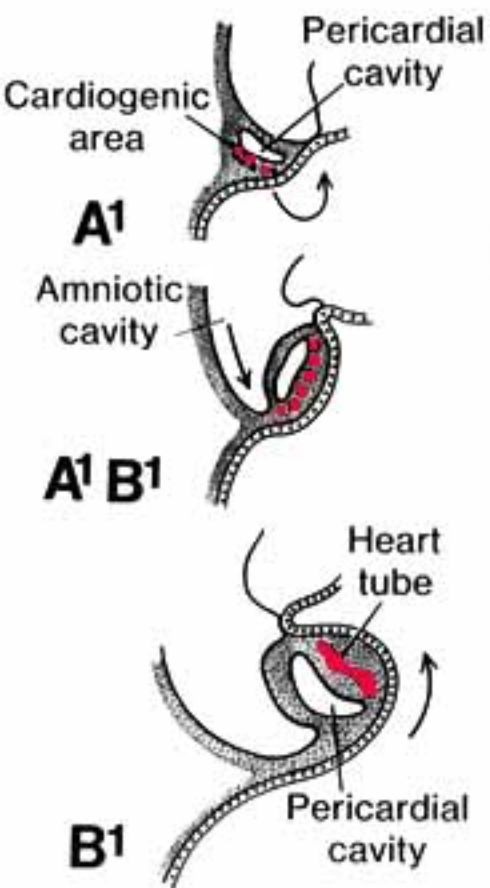
The following six snapshots of the development process are considered:

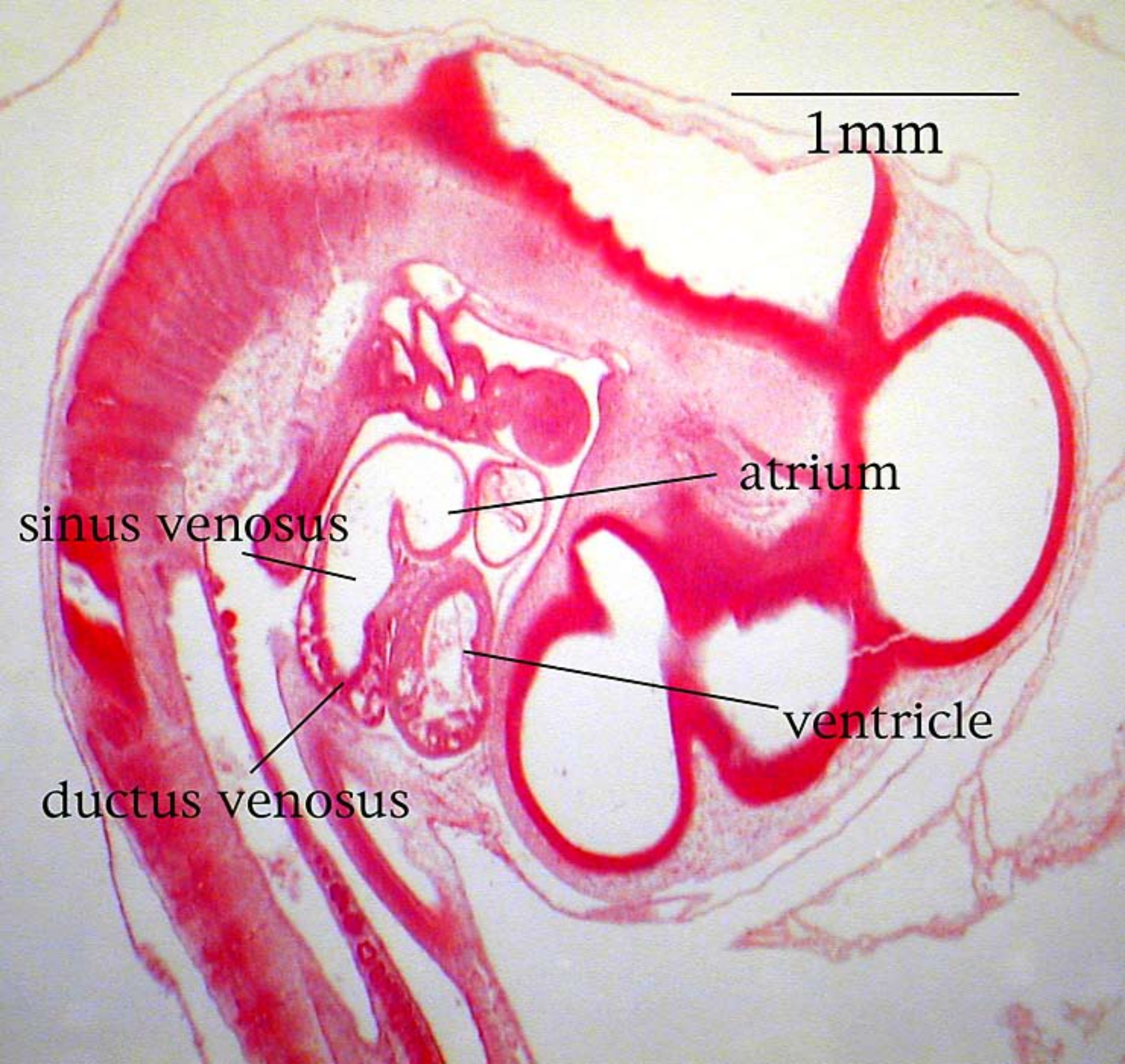
A] The *endocardial tube lengthens and loops on itself*—this puts the bulbus cordis (right ventricle) beside the ventricle (left ventricle) and the atrium dorsal to the ventricle.











1mm

atrium

sinus venosus

ventricle

ductus venosus

Cardiovascular System

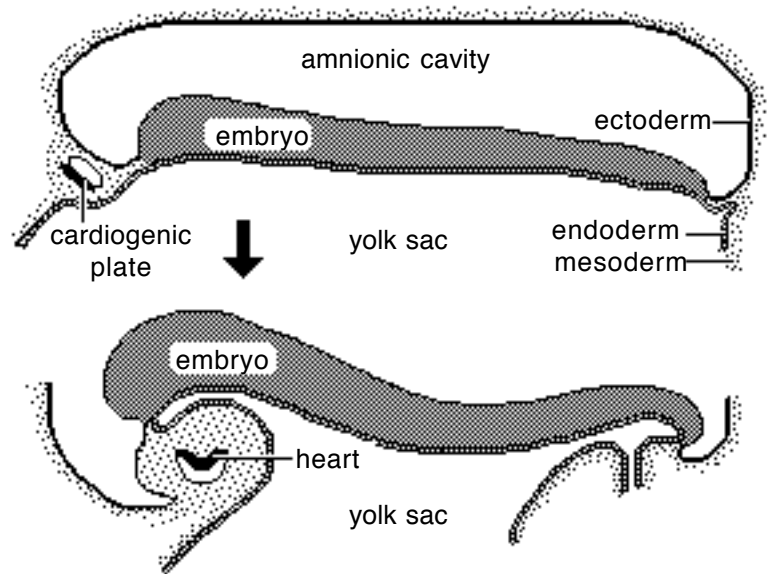
Note: The cardiovascular system develops early (week 3), enabling the embryo to grow beyond the short distances over which diffusion is efficient for transferring O₂, CO₂, and cellular nutrients & wastes.

Heart:

From a simple tube, the heart undergoes differential growth into a four chambered structure while it is pumping blood throughout the embryo and into extra-embryonic membranes. Major vessels form and the heart initiates a peristaltic pumping action during the third week in the dog.

Formation of a Tubular Heart:

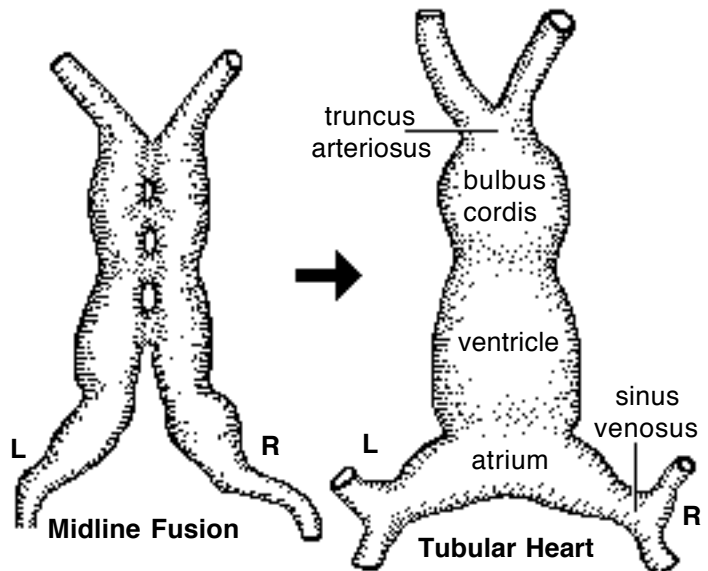
The first evidence of heart development is horse-shoe shaped vessel formation within the *cardiogenic plate*, which is splanchnic mesoderm situated anterior and lateral to the embryo. As the head process grows upward and outward, the cardiogenic plate shifts ventral to the pharynx and bilateral endocardial tubes meet at the midline & fuse into a single endocardial tube. Splanchnic mesoderm surrounding the tube forms cardiac muscle cells.



Primitive Heart Regions:

Differential growth of the endocardial tube establishes five primitive heart regions:

- 1] *Truncus arteriosus* — the output region of the heart. It will develop into the ascending aorta and pulmonary trunk.
- 2] *Bulbus cordis* — a bulb-shaped region destined to become right ventricle.
- 3] *Ventricle* — an enlargement destined to become the left ventricle.
- 4] *Atrium* — a region that will expand to become both right and left auricles.
- 5] *Sinus venosus* — a paired region into which veins drain. The left sinus venosus becomes the coronary sinus; the right is incorporated into the wall of the right atrium.

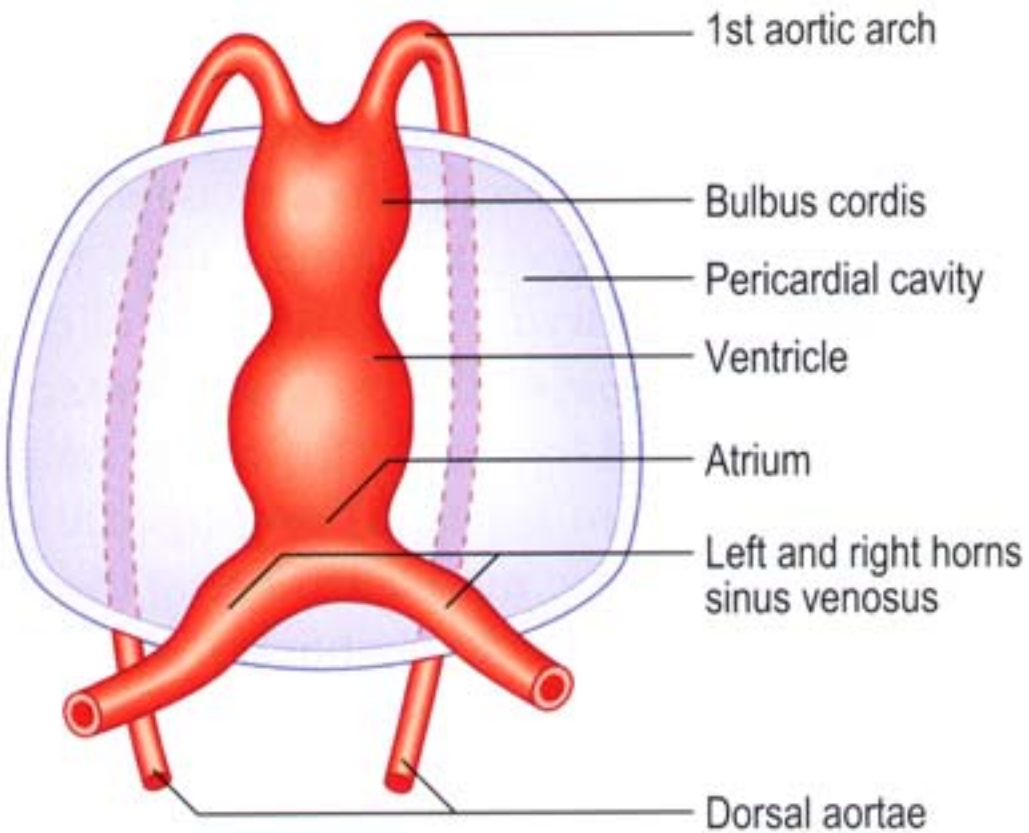


Forming a Four-Chambered Heart:

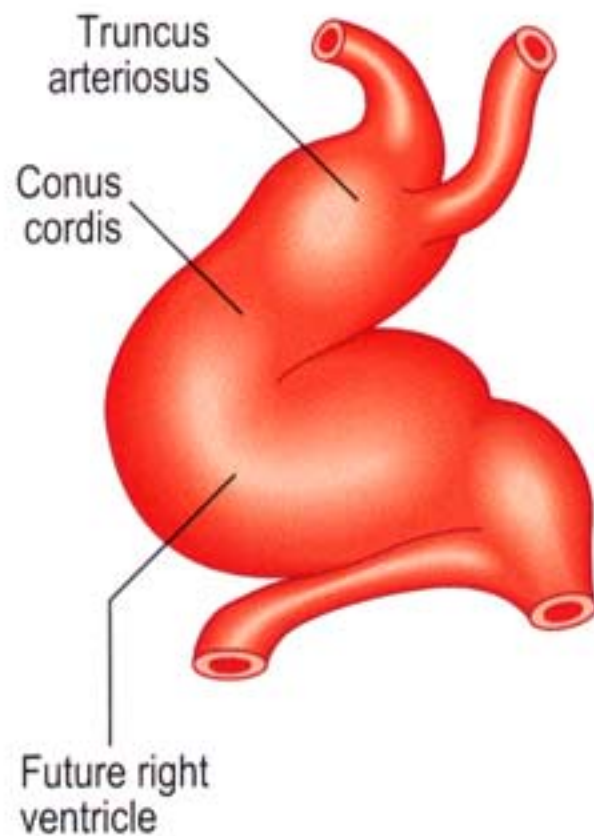
The following six snapshots of the development process are considered:

A] The *endocardial tube lengthens and loops* on itself—this puts the bulbus cordis (right ventricle) beside the ventricle (left ventricle) and the atrium dorsal to the ventricle.

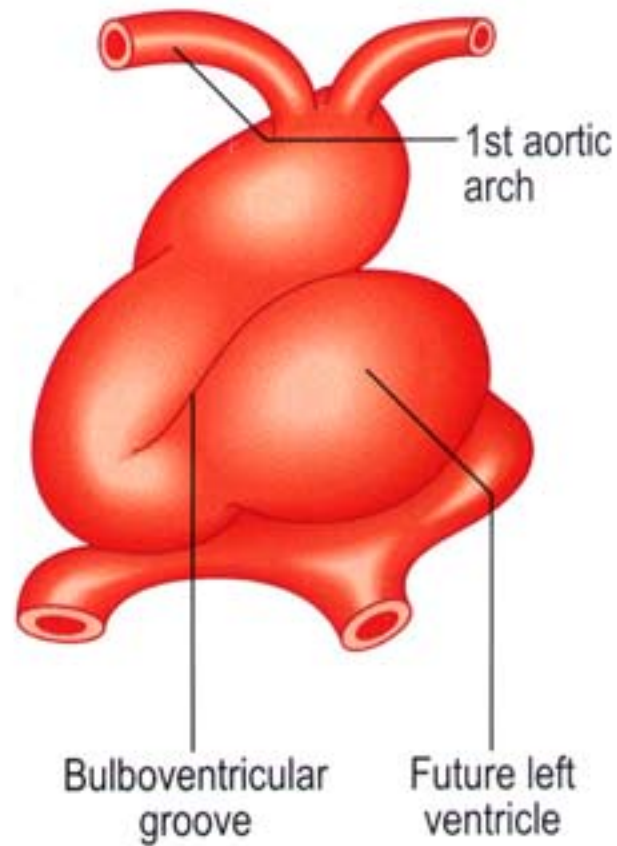
21 days



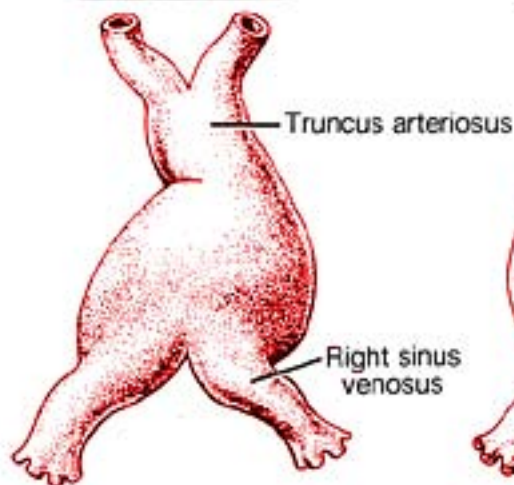
22 days



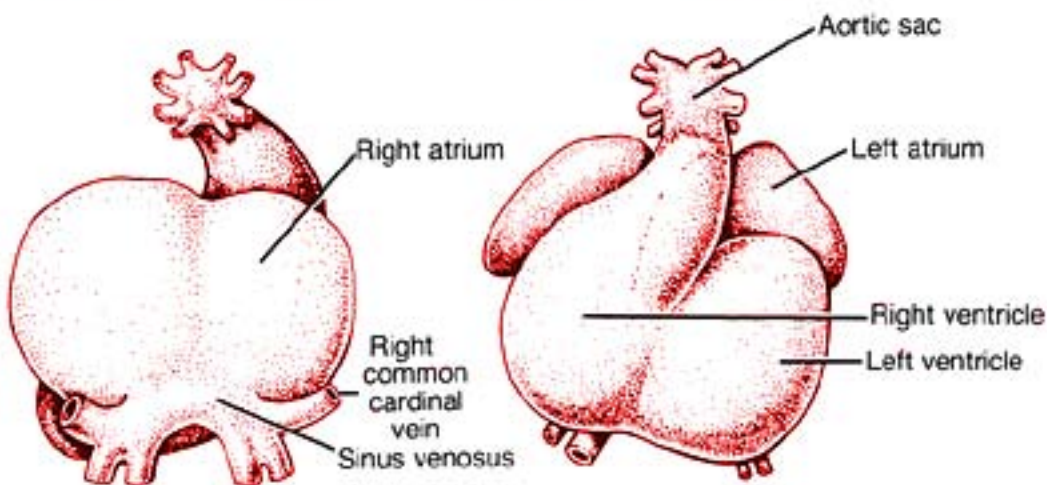
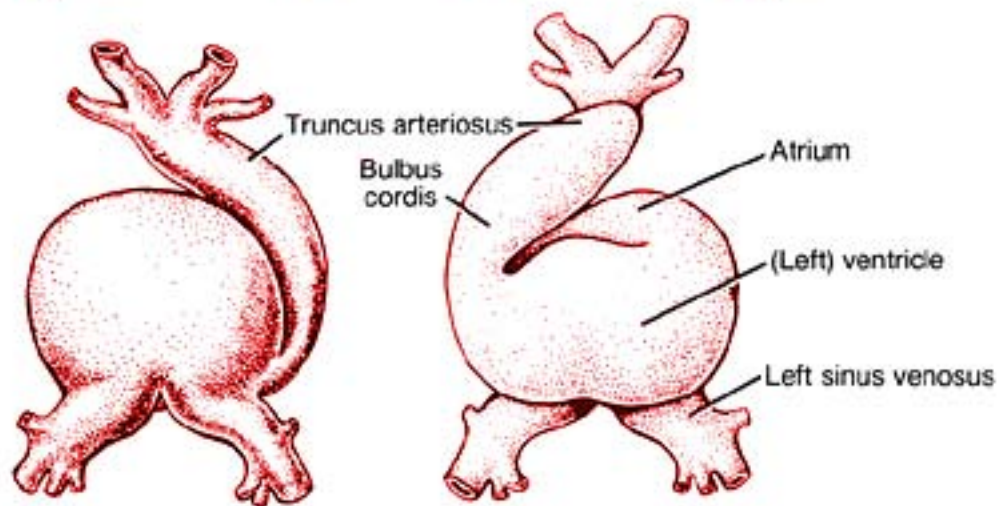
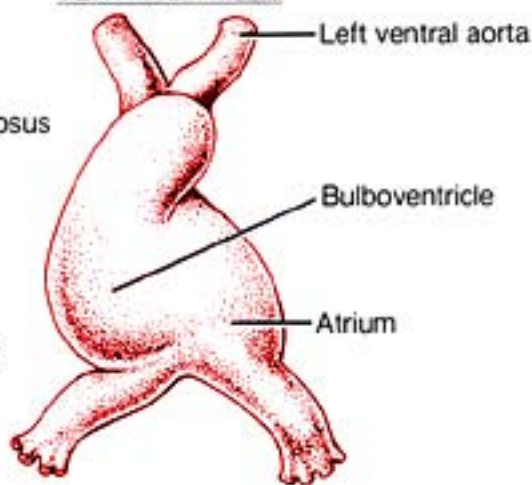
24 days


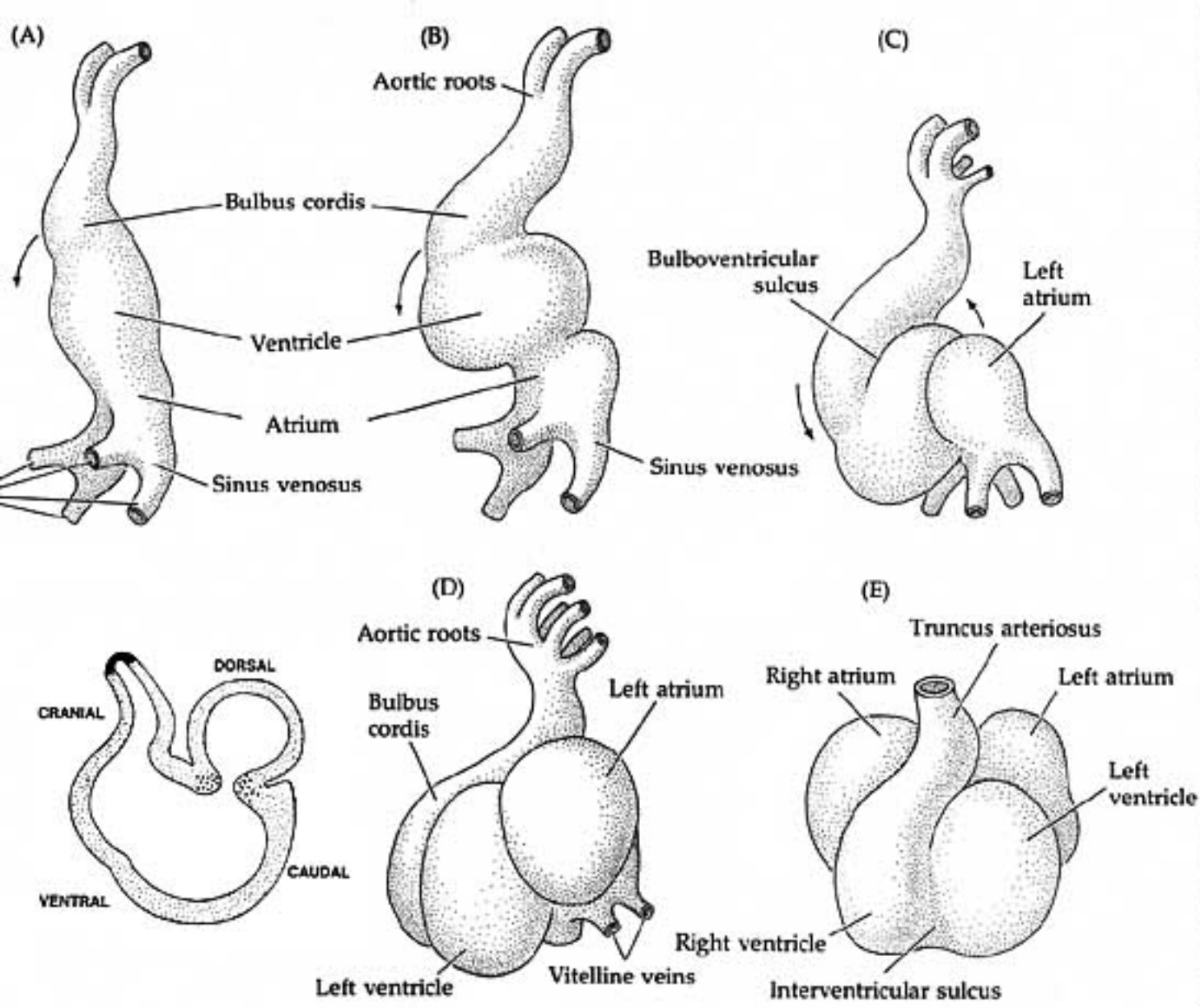


DORSAL VIEWS



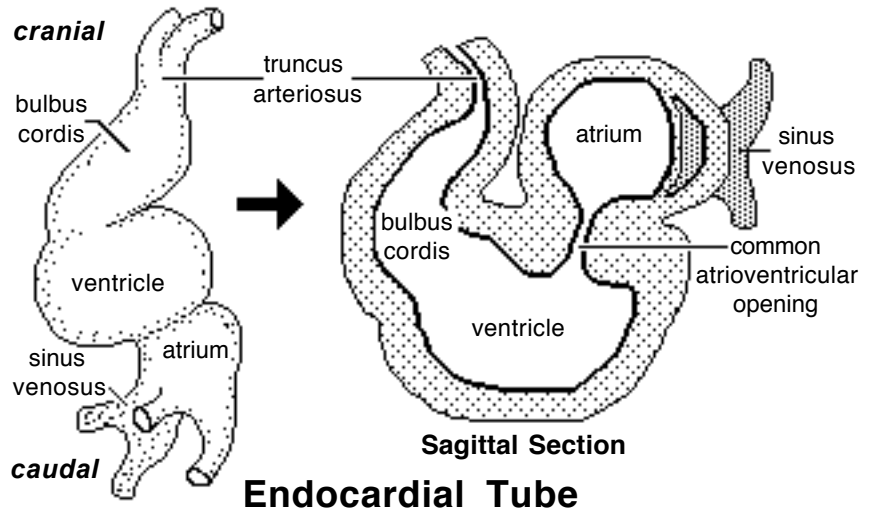
VENTRAL VIEWS





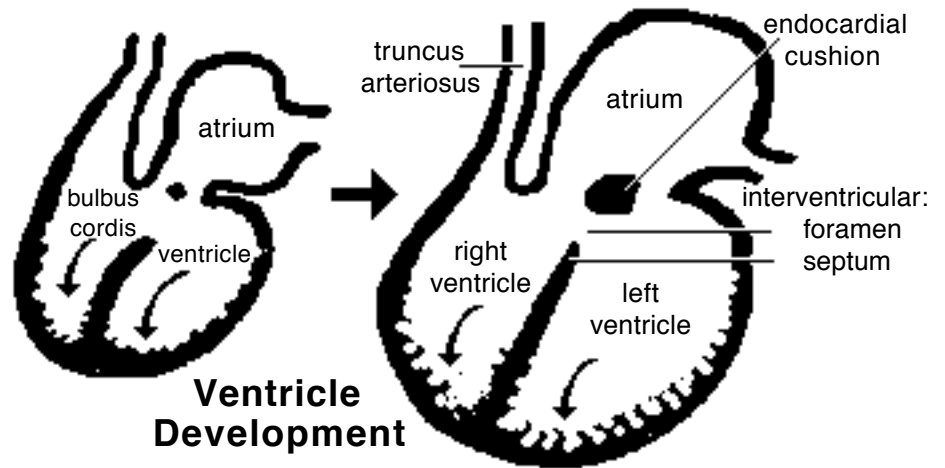
B) *Venous return is shifted to the right side.* The right sinus venosus becomes enlarged and incorporated into the future right atrium. The smaller, left sinus venosus merges into the future right atrium as the coronary sinus.

The atrium expands and overlies the ventricle chamber. A common atrioventricular opening connects the two chambers. At the level of the atrioventricular opening, a constriction, the future coronary groove, separates atrium and the ventricle.



C) The common *atrio-ventricular opening is partitioned* into right and left A-V openings by growth of endocardial “cushions”. Subsequently, ventral growth of the cushions contributes to a septum that closes the interventricular foramen (the original opening between the bulbus cordis & ventricle).

(Incomplete closure of the interventricular septum (ventricular septal defect) results in blood flow from the left to the right ventricle and an associated murmur. Large defects produce clinical signs of cardiac insufficiency.)



D) The *right and left ventricles* are formed by ventral growth and excavation of the bulbus cordis and ventricle, respectively. An interventricular septum, atrioventricular valves, chordae tendineae, papillary muscles, and irregularities of the internal ventricular wall are all sculptured by selective excavation of ventricular wall tissue.

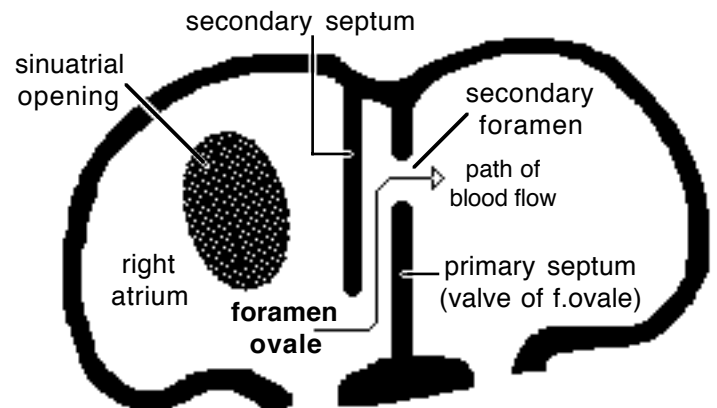
E) *Right and left atria* are established by formation of an interatrial septum. Septum formation is complicated by the need, until birth, for a patent (open) septum that allows blood to flow from the right atrium to the left. The septal opening is called the foramen ovale.

Two septae and three foramina are involved in dividing the atria:

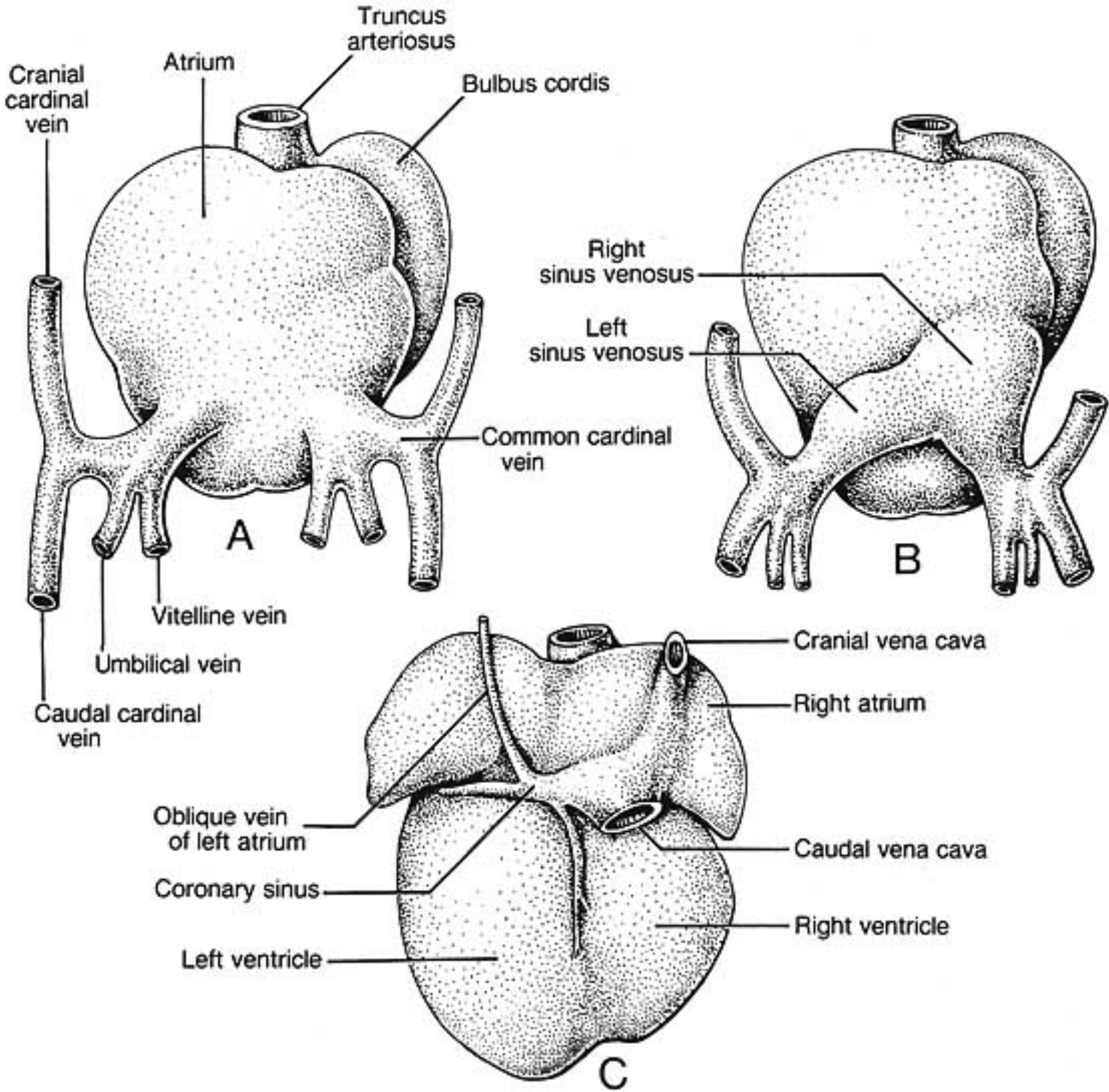
Interatrial Septum 1 grows from the dorsal atrial wall toward the endocardial cushions. The pre-existing *Foramen 1* is obliterated when Septum 1 meets the endocardial cushion.

Foramen 2 develops by fenestration of the dorsocranial region of Septum 1 (before *Foramen 1* is obliterated).

Interatrial Septum 2 grows from the cranial wall of the right atrium toward the caudal wall. The septum remains incomplete and its free edge forms the boundary of an opening called the Foramen Ovale.

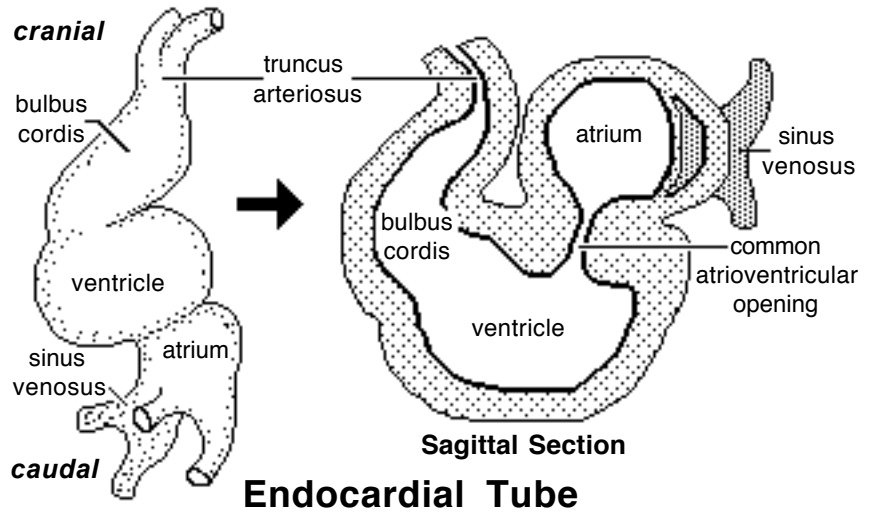


Blood Flow Through Foramen Ovale



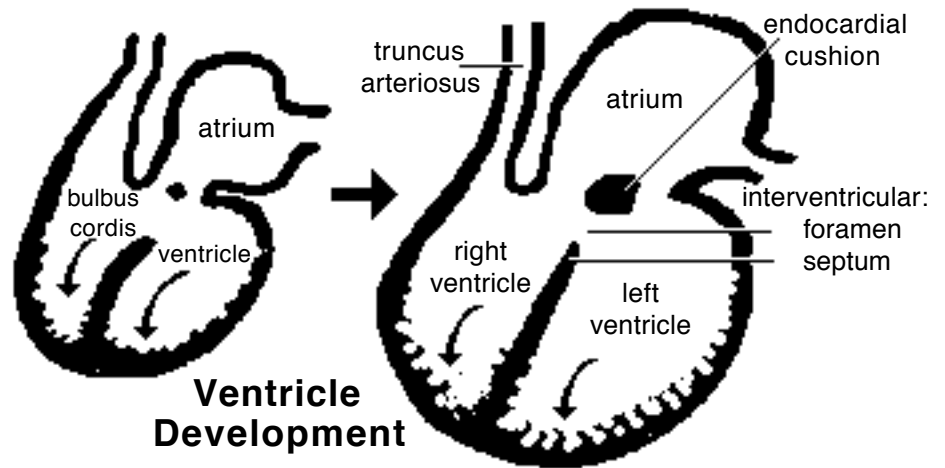
B) *Venous return is shifted to the right side.* The right sinus venosus becomes enlarged and incorporated into the future right atrium. The smaller, left sinus venosus merges into the future right atrium as the coronary sinus.

The atrium expands and overlies the ventricle chamber. A common atrioventricular opening connects the two chambers. At the level of the atrioventricular opening, a constriction, the future coronary groove, separates atrium and the ventricle.



C) The common *atrio-ventricular opening is partitioned* into right and left A-V openings by growth of endocardial “cushions”. Subsequently, ventral growth of the cushions contributes to a septum that closes the interventricular foramen (the original opening between the bulbus cordis & ventricle).

(Incomplete closure of the interventricular septum (ventricular septal defect) results in blood flow from the left to the right ventricle and an associated murmur. Large defects produce clinical signs of cardiac insufficiency.)



D) The *right and left ventricles* are formed by ventral growth and excavation of the bulbus cordis and ventricle, respectively. An interventricular septum, atrioventricular valves, chordae tendineae, papillary muscles, and irregularities of the internal ventricular wall are all sculptured by selective excavation of ventricular wall tissue.

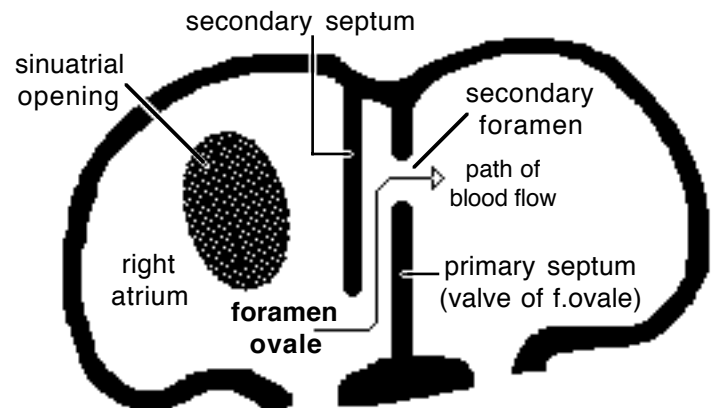
E) *Right and left atria* are established by formation of an interatrial septum. Septum formation is complicated by the need, until birth, for a patent (open) septum that allows blood to flow from the right atrium to the left. The septal opening is called the foramen ovale.

Two septae and three foramina are involved in dividing the atria:

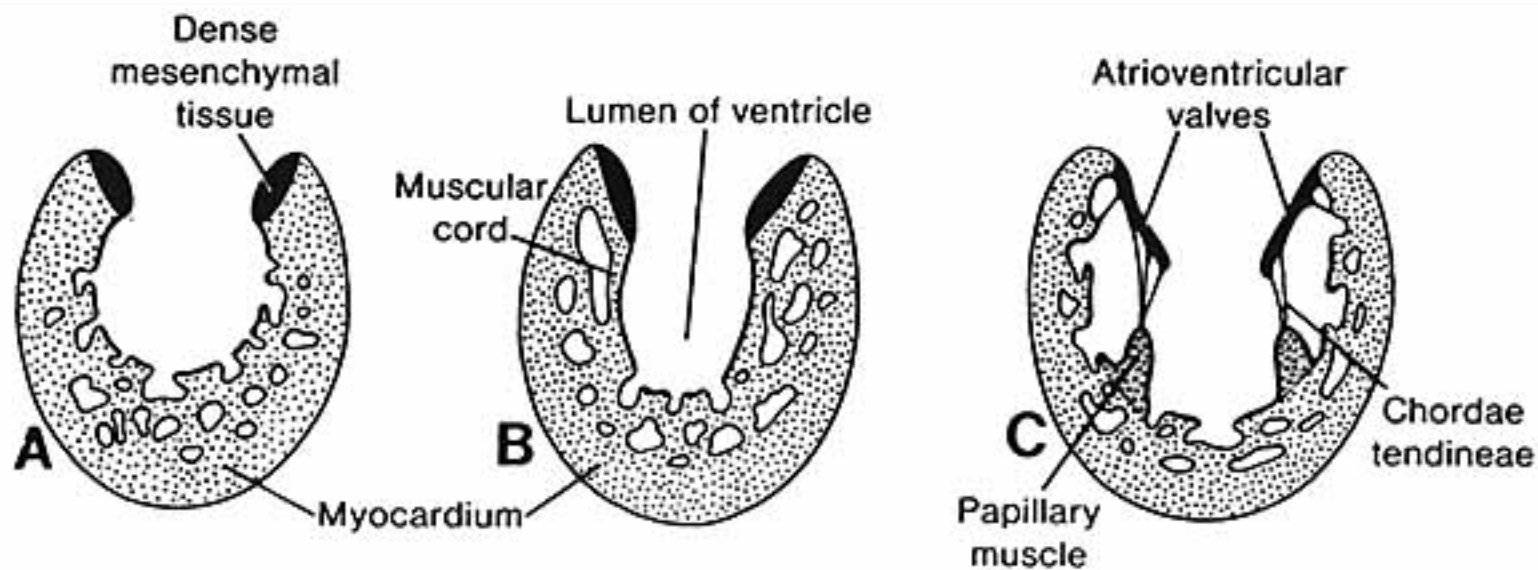
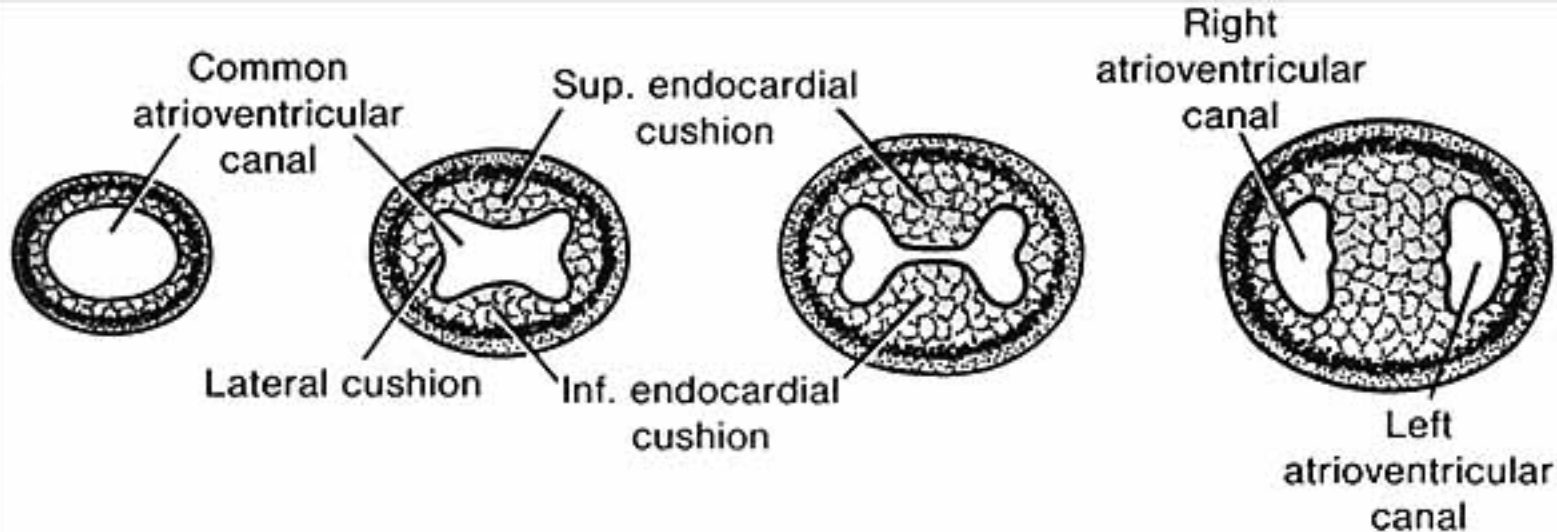
Interatrial Septum 1 grows from the dorsal atrial wall toward the endocardial cushions. The pre-existing *Foramen 1* is obliterated when Septum 1 meets the endocardial cushion.

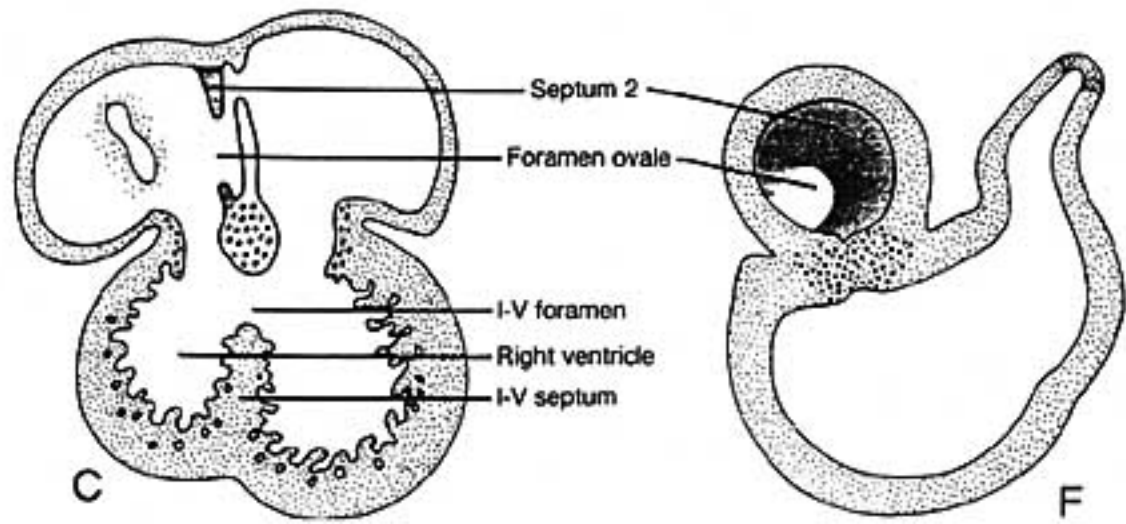
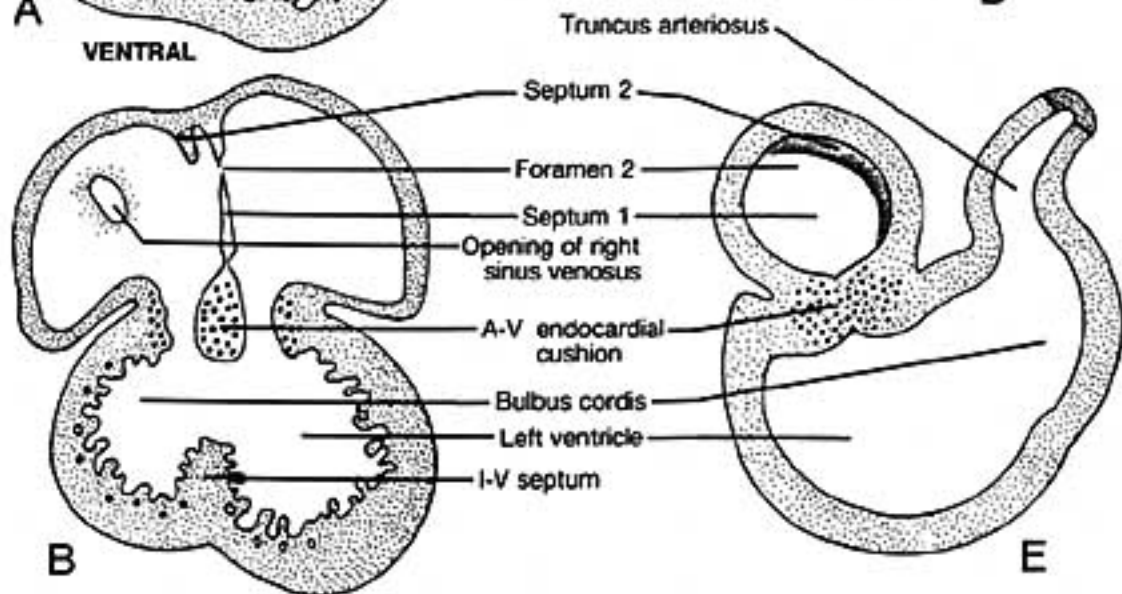
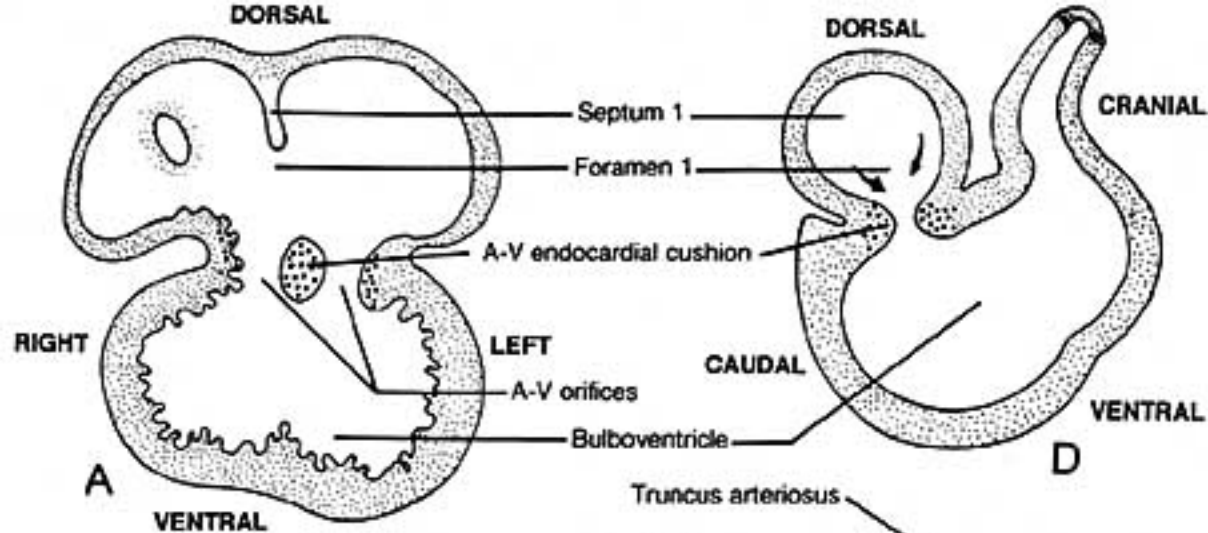
Foramen 2 develops by fenestration of the dorsocranial region of Septum 1 (before *Foramen 1* is obliterated).

Interatrial Septum 2 grows from the cranial wall of the right atrium toward the caudal wall. The septum remains incomplete and its free edge forms the boundary of an opening called the Foramen Ovale.



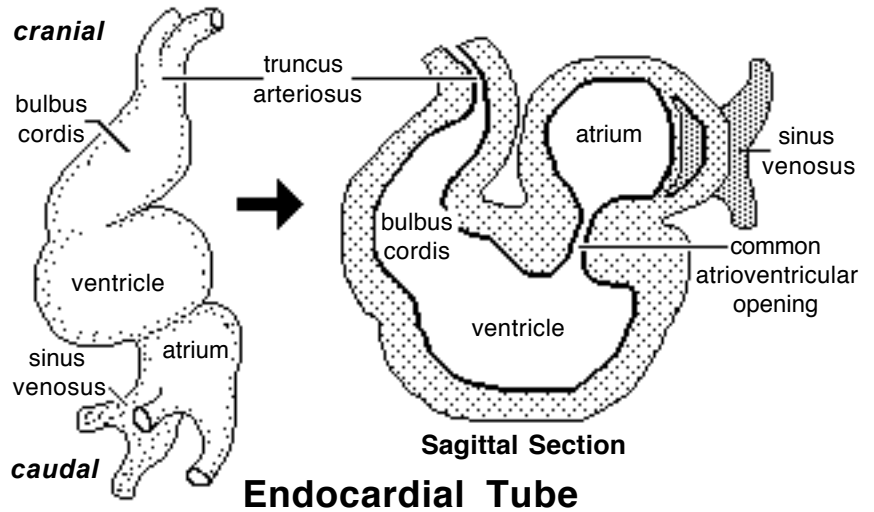
Blood Flow Through Foramen Ovale





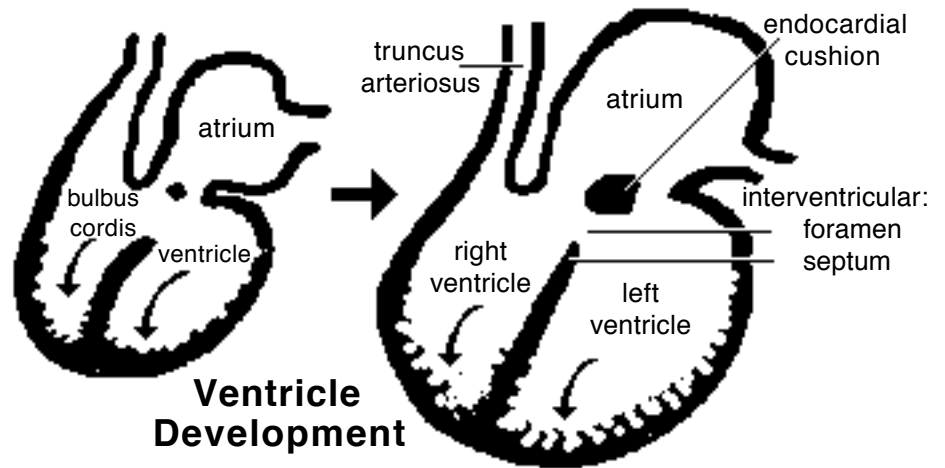
B) *Venous return is shifted to the right side.* The right sinus venosus becomes enlarged and incorporated into the future right atrium. The smaller, left sinus venosus merges into the future right atrium as the coronary sinus.

The atrium expands and overlies the ventricle chamber. A common atrioventricular opening connects the two chambers. At the level of the atrioventricular opening, a constriction, the future coronary groove, separates atrium and the ventricle.



C) The common *atrio-ventricular opening is partitioned* into right and left A-V openings by growth of endocardial “cushions”. Subsequently, ventral growth of the cushions contributes to a septum that closes the interventricular foramen (the original opening between the bulbus cordis & ventricle).

(Incomplete closure of the interventricular septum (ventricular septal defect) results in blood flow from the left to the right ventricle and an associated murmur. Large defects produce clinical signs of cardiac insufficiency.)



D) The *right and left ventricles* are formed by ventral growth and excavation of the bulbus cordis and ventricle, respectively. An interventricular septum, atrioventricular valves, chordae tendineae, papillary muscles, and irregularities of the internal ventricular wall are all sculptured by selective excavation of ventricular wall tissue.

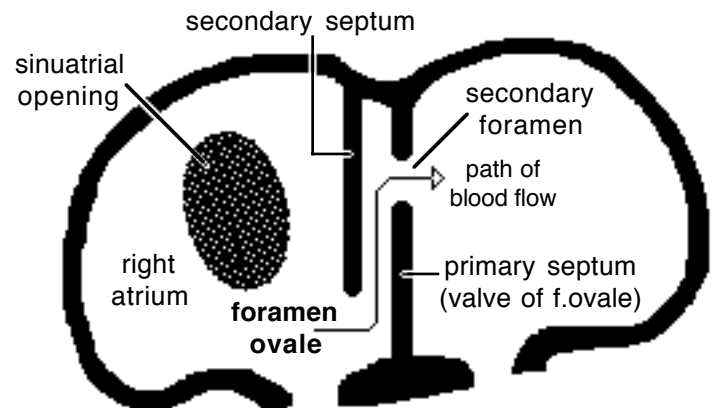
E) *Right and left atria* are established by formation of an interatrial septum. Septum formation is complicated by the need, until birth, for a patent (open) septum that allows blood to flow from the right atrium to the left. The septal opening is called the foramen ovale.

Two septae and three foramina are involved in dividing the atria:

Interatrial Septum 1 grows from the dorsal atrial wall toward the endocardial cushions. The pre-existing *Foramen 1* is obliterated when Septum 1 meets the endocardial cushion.

Foramen 2 develops by fenestration of the dorsocranial region of Septum 1 (before *Foramen 1* is obliterated).

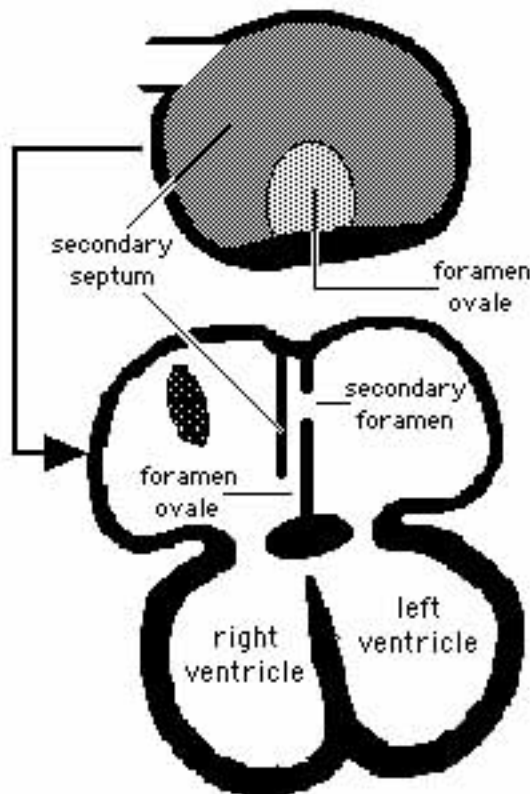
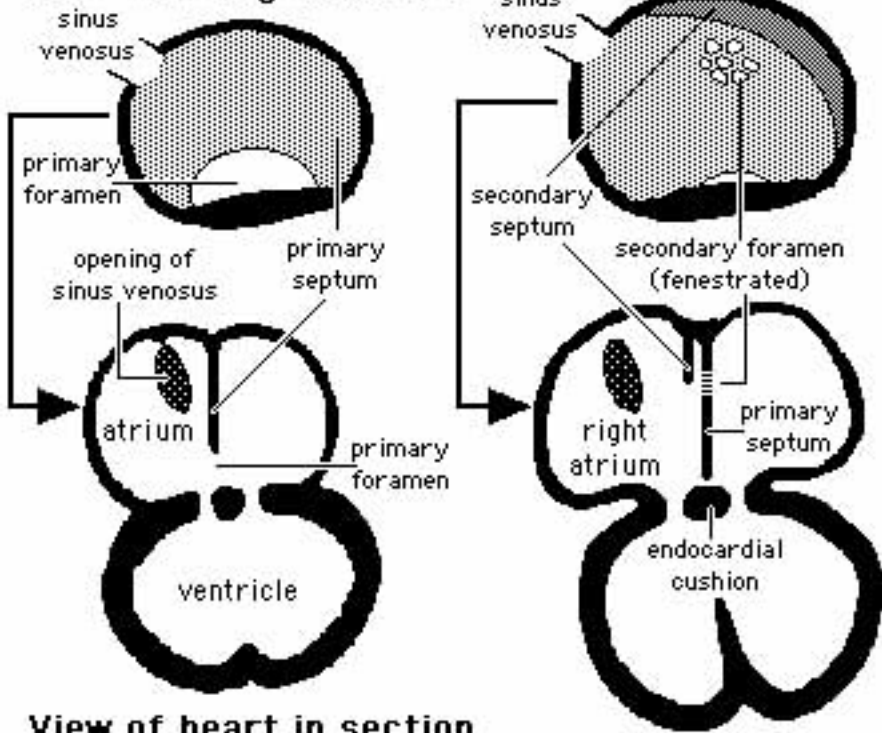
Interatrial Septum 2 grows from the cranial wall of the right atrium toward the caudal wall. The septum remains incomplete and its free edge forms the boundary of an opening called the Foramen Ovale.



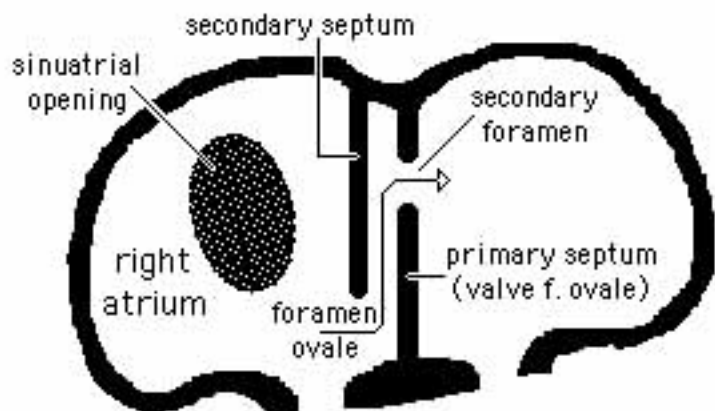
Blood Flow Through Foramen Ovale

Septum Formation in the Atrium

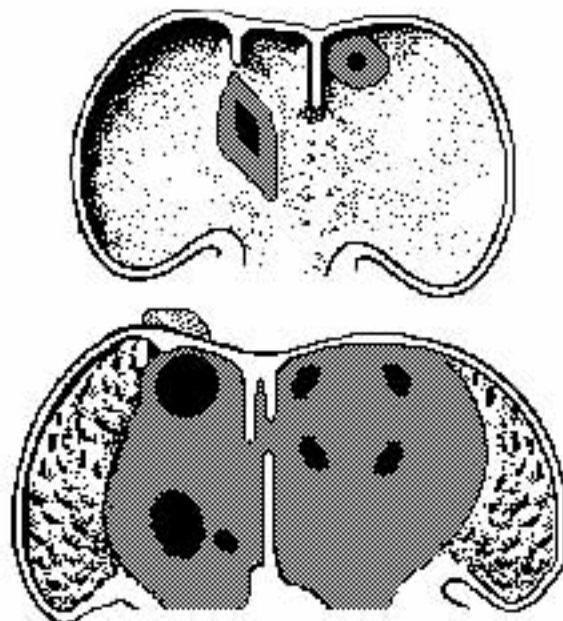
View from right atrium

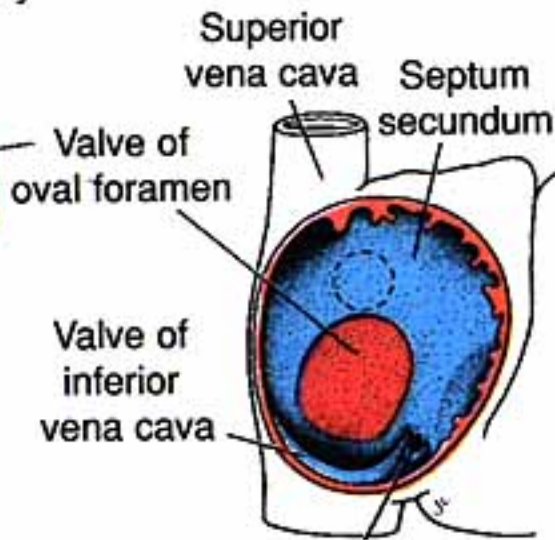
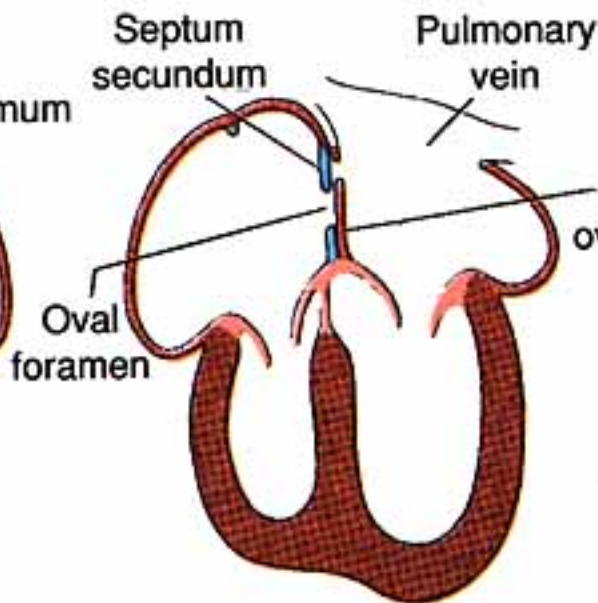
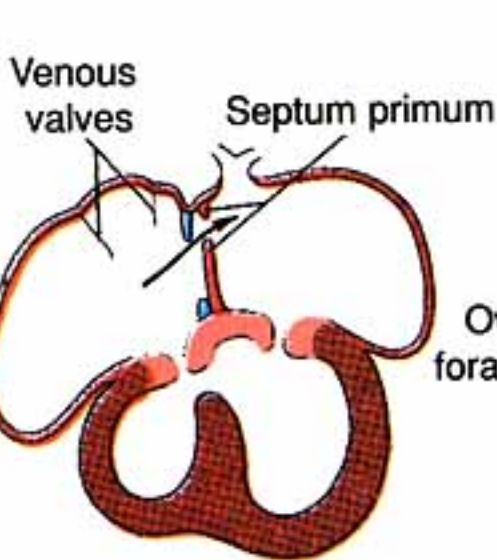
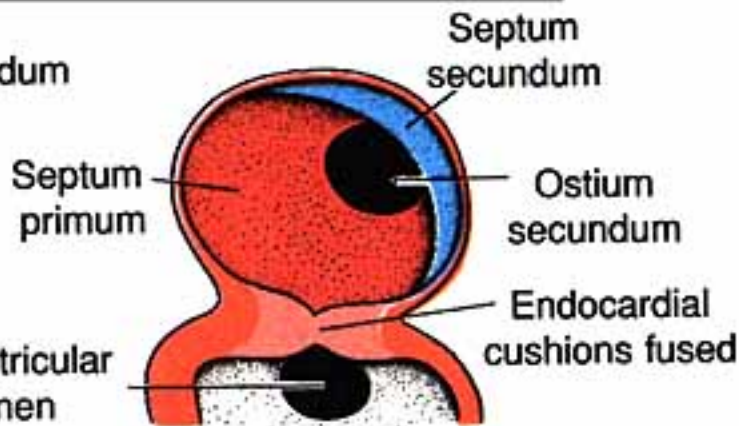
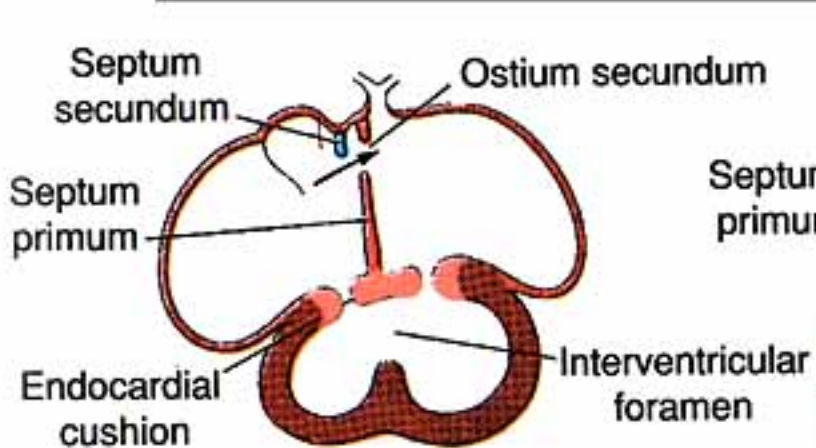
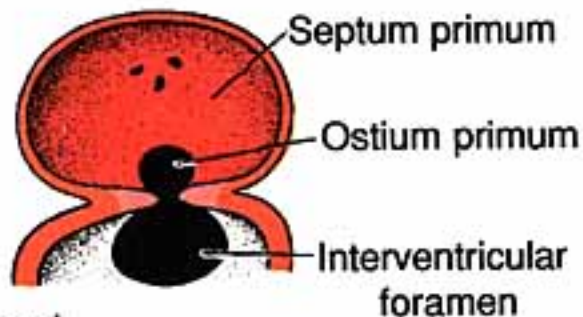
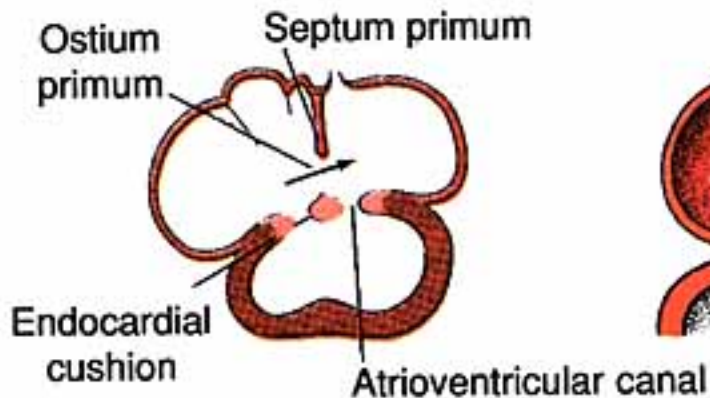


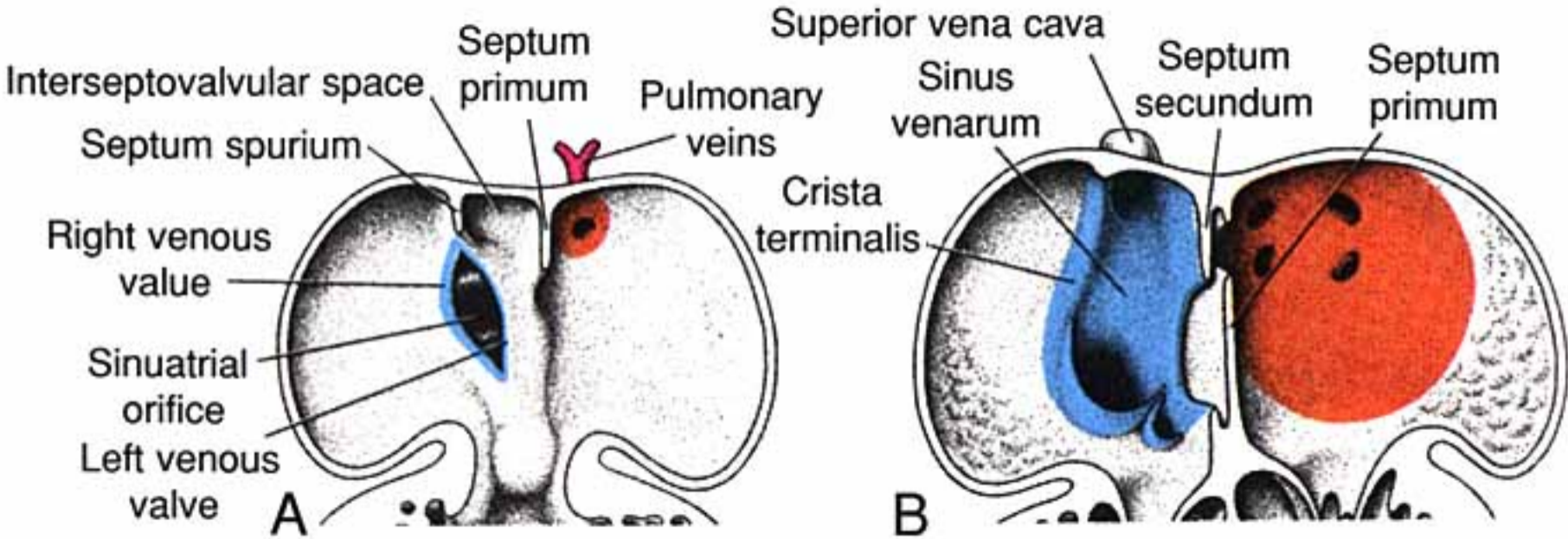
View of heart in section



Blood Flow: from foramen ovale to secondary foramen







NOTE: As long as blood pressure in the right atrium exceeds that of the left atrium, blood enters the Foramen Ovale, flows between the two septae and exits through Foramen-2. When, at birth, pressure is equal in the two atria, Septum-1 is forced against the Foramen Ovale, acting as a valve to close the foramen and preclude direct blood flow between the atria.

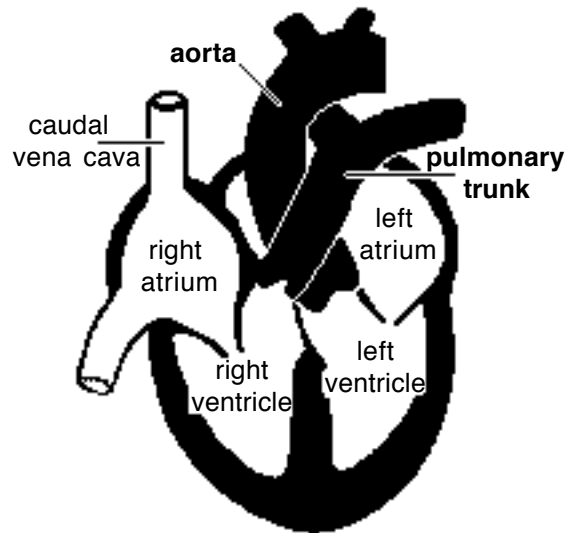
An atrial septal defect is not a serious developmental anomaly as long as pressure is approximately equal in the two atria, which is normally the case.

F] *Aorta* and *pulmonary trunk* are formed by partition of the truncus arteriosus (and adjacent bulbus cordis). In a spiral pattern, ridges appear along the lumen wall, grow inward and merge creating a spiral septum. As a result, the aorta and pulmonary trunk spiral around one another.

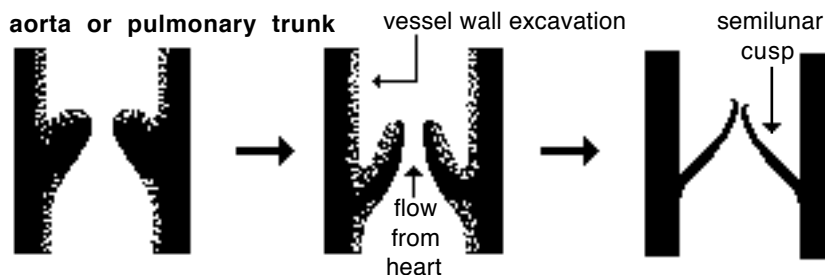
Failure of the septum to spiral leaves the aorta connected to the right ventricle and the pulmonary trunk to the left ventricle—a fatal flaw.

Growths from the spiral septum and endocardial cushions both contribute to closure of the interventricular septum.

Aortic and pulmonary semilunar *valves* are formed like atrioventricular valves, by selective erosion of cardiac/vessel wall. Improper valve sculpturing will produce valvular insufficiency in the case of excessive erosion or vessel stenosis (narrow lumen) in cases of not enough erosion



Spiral Arrangement of the Aorta & Pulmonary Trunk



Development of semilunar valves by excavation

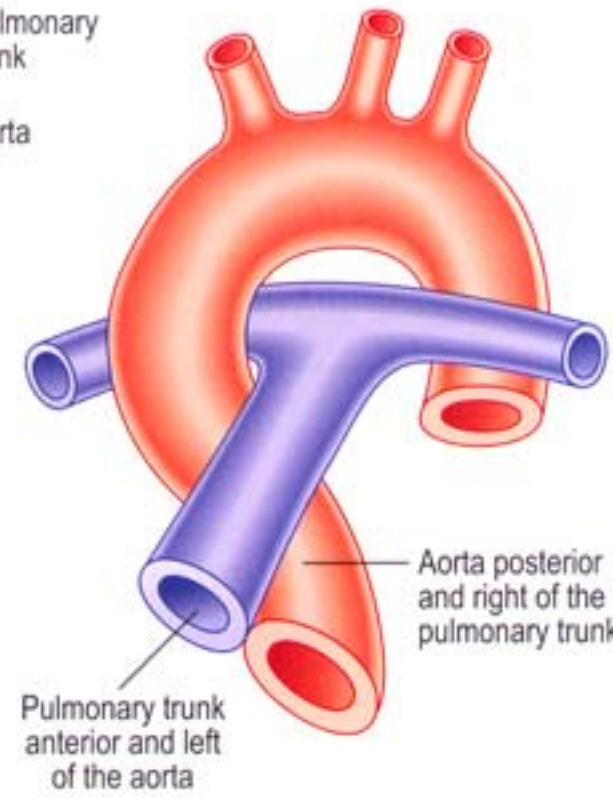
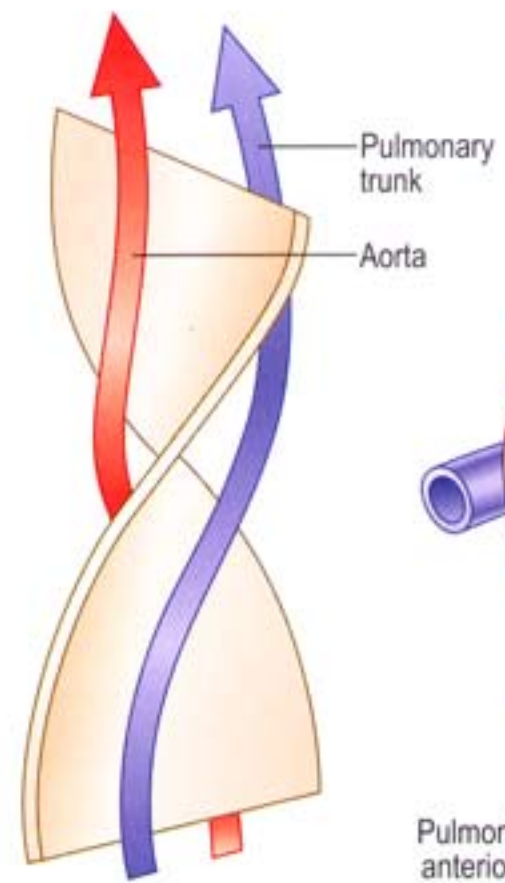
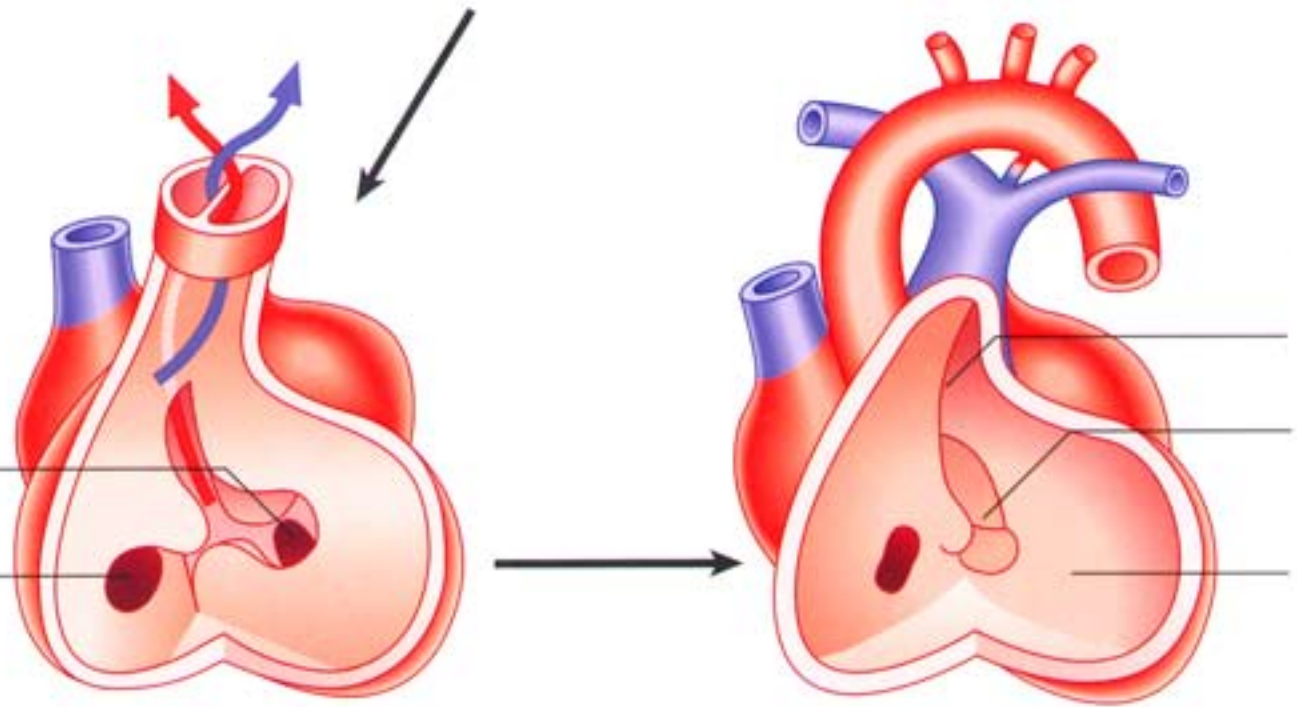
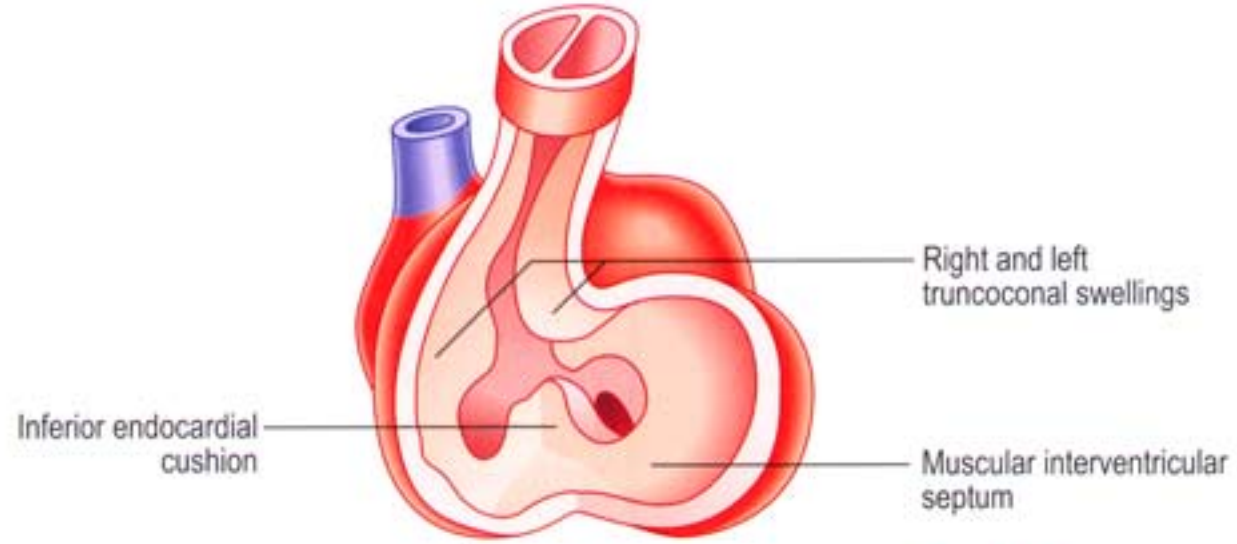
Note: Neural crest cells migrate to the region of the truncus arteriosus and direct its partitioning by the spiral septum. Ablation of the neural crest results in anomalies of the great vessels.

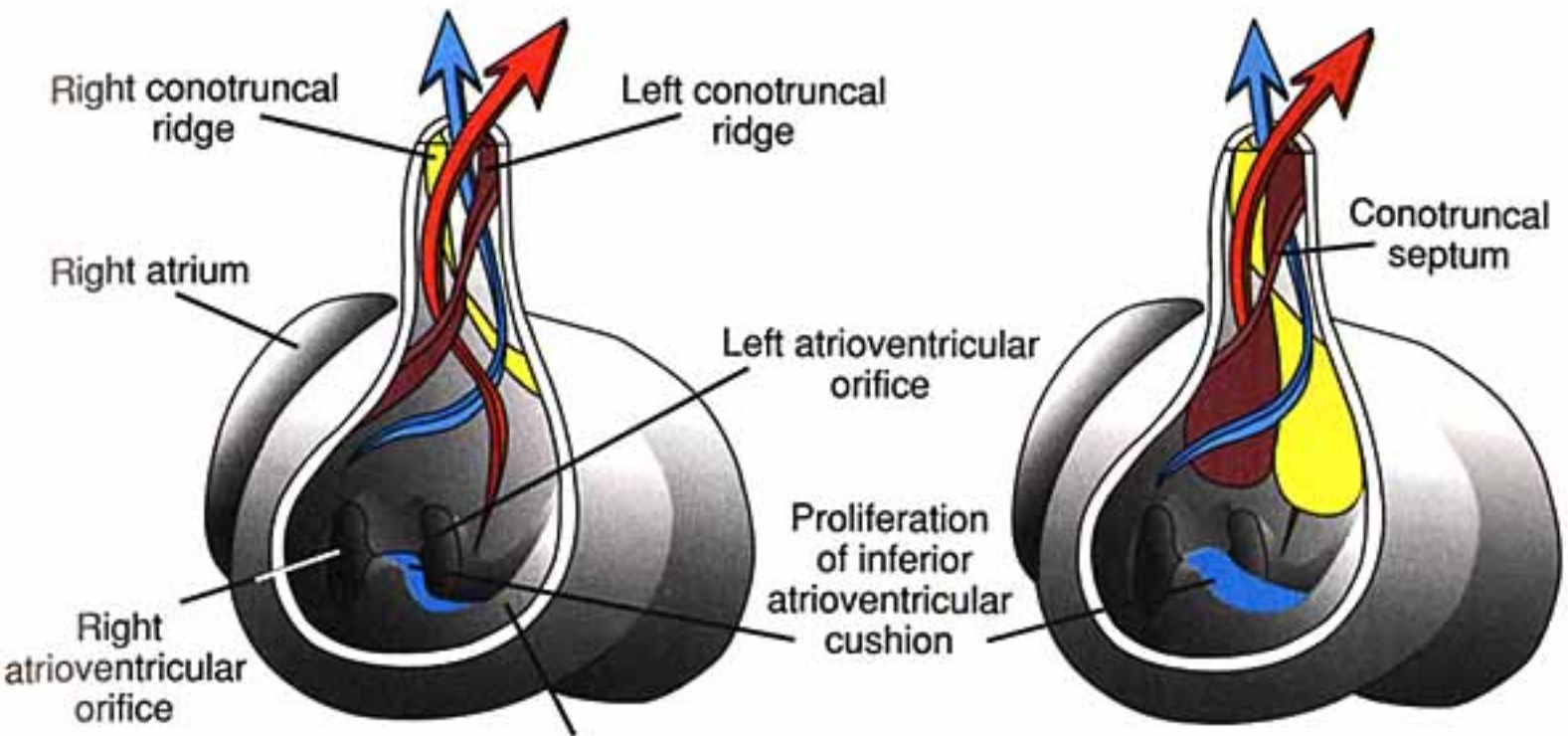
Tetralogy of Fallot:

This is a cardiac anomaly that occurs in number of species, including humans. It involves a combination of four defects all related to a defective spiral septum formation in the truncus arteriosus & bulbus cordis:

- ventricular septal defect;
- stenosis of the pulmonary trunk;
- enlarged aorta that overrides the right ventricle (dextroposition of the aorta); and
- hypertrophy of the right ventricle, secondary to communication with the high pressure left ventricle.

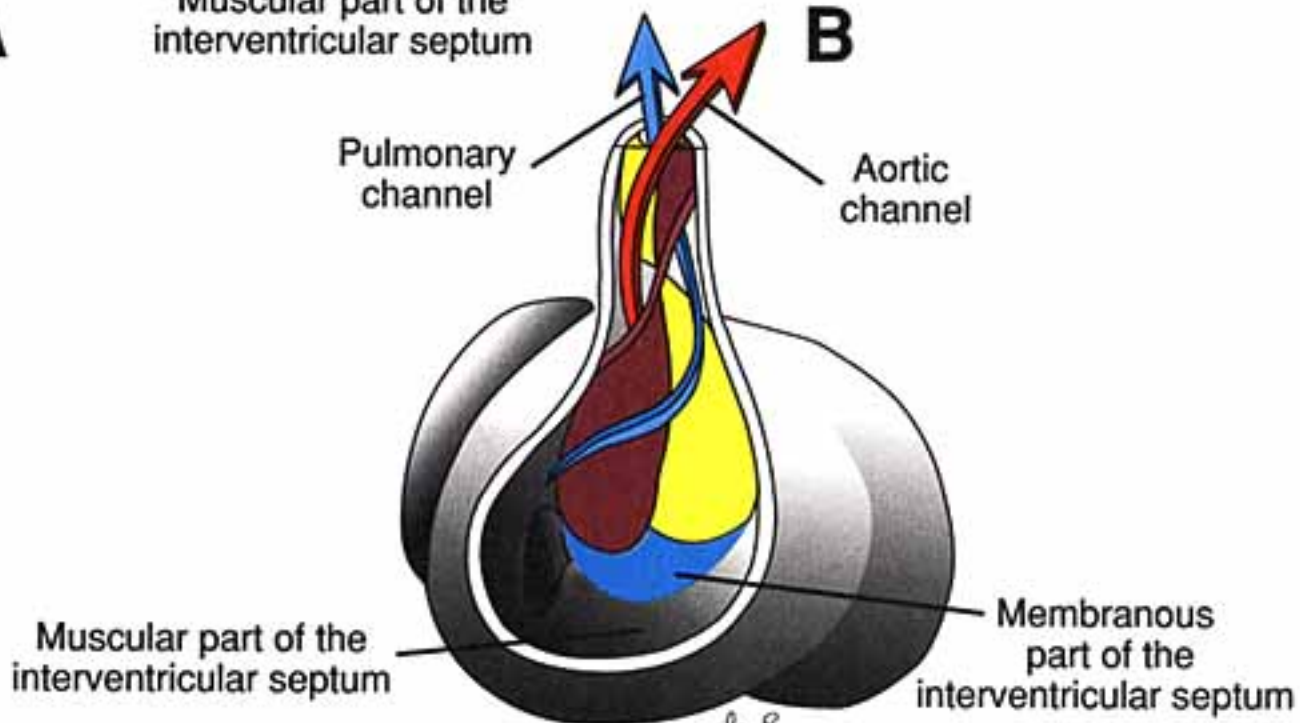
Note: Vasculogenesis begins with blood islands formation in splanchnic mesoderm of the yolk sac and allantois. Angiogenesis (vessel formation) occurs when island vesicles coalesce, sprout buds, and fuse to form vascular channels. Subsequently, hematopoiesis (blood cell formation) occurs in the liver and spleen and later in the bone marrow. The transition from fetal to adult circulation involves new vessel formation, vessel merger, and degeneration of early vessels.



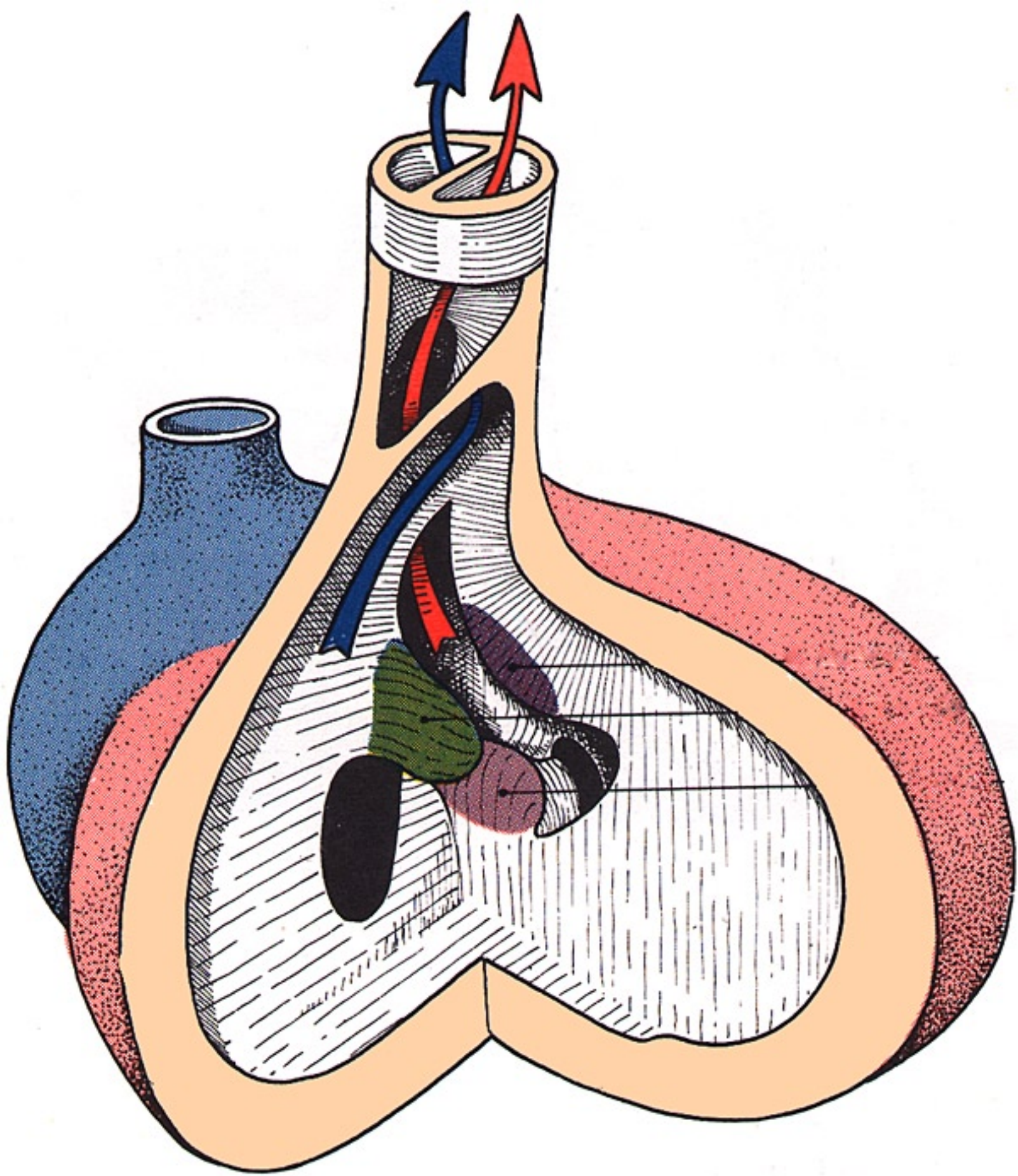


A

B

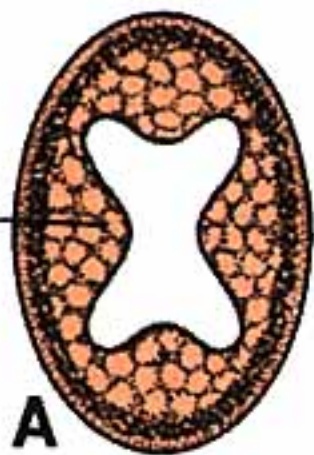


C



Minor truncus swelling

Right truncus swelling

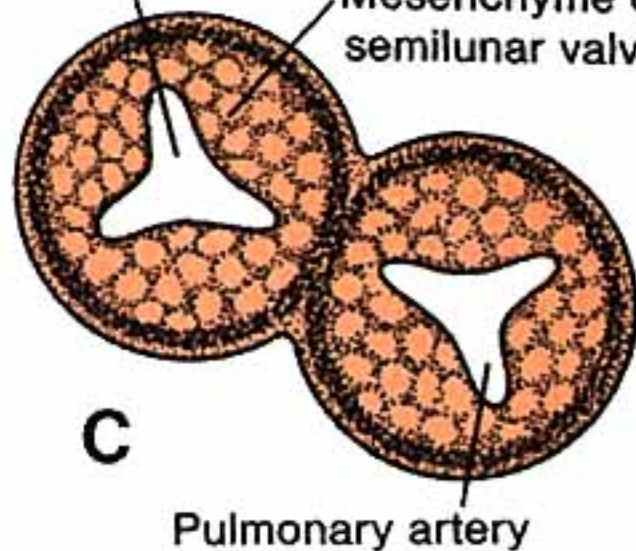


B

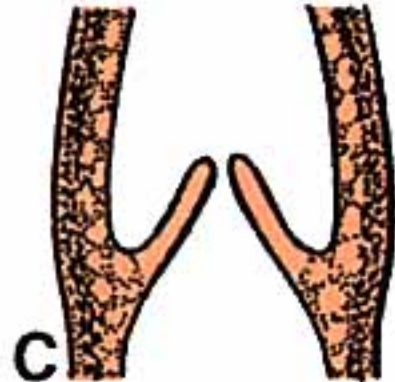
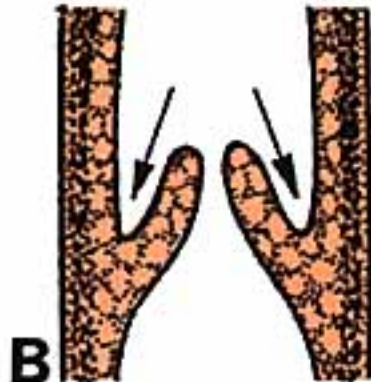
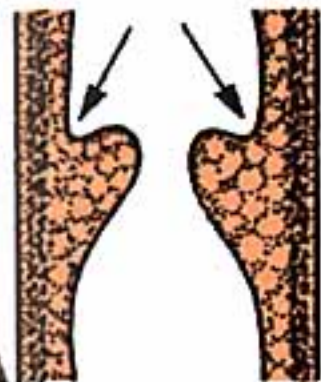


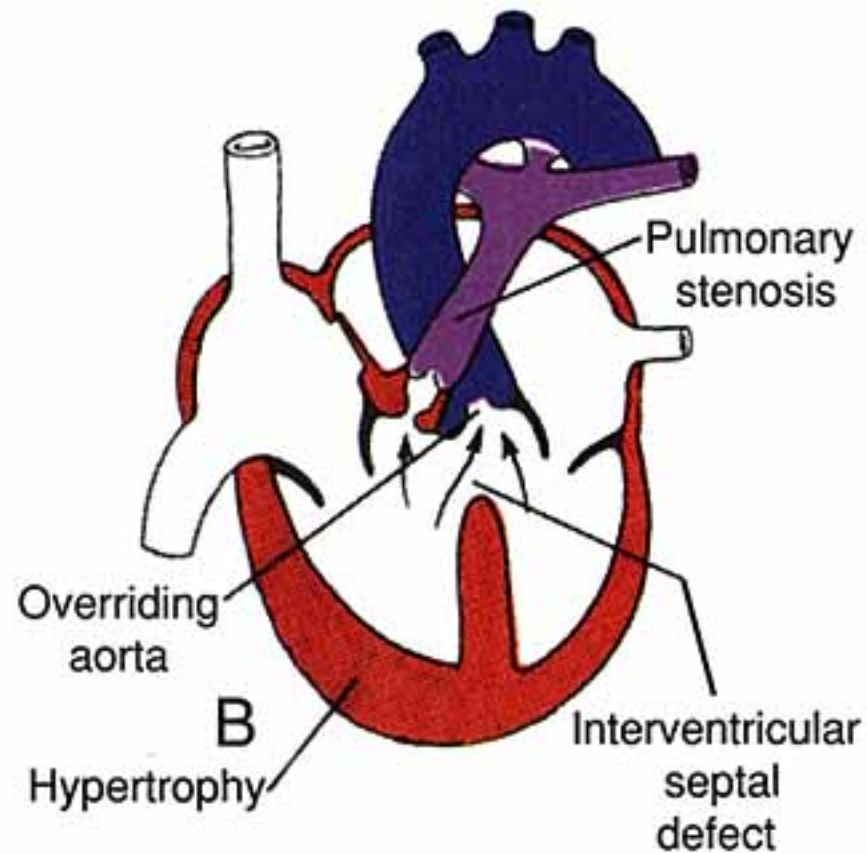
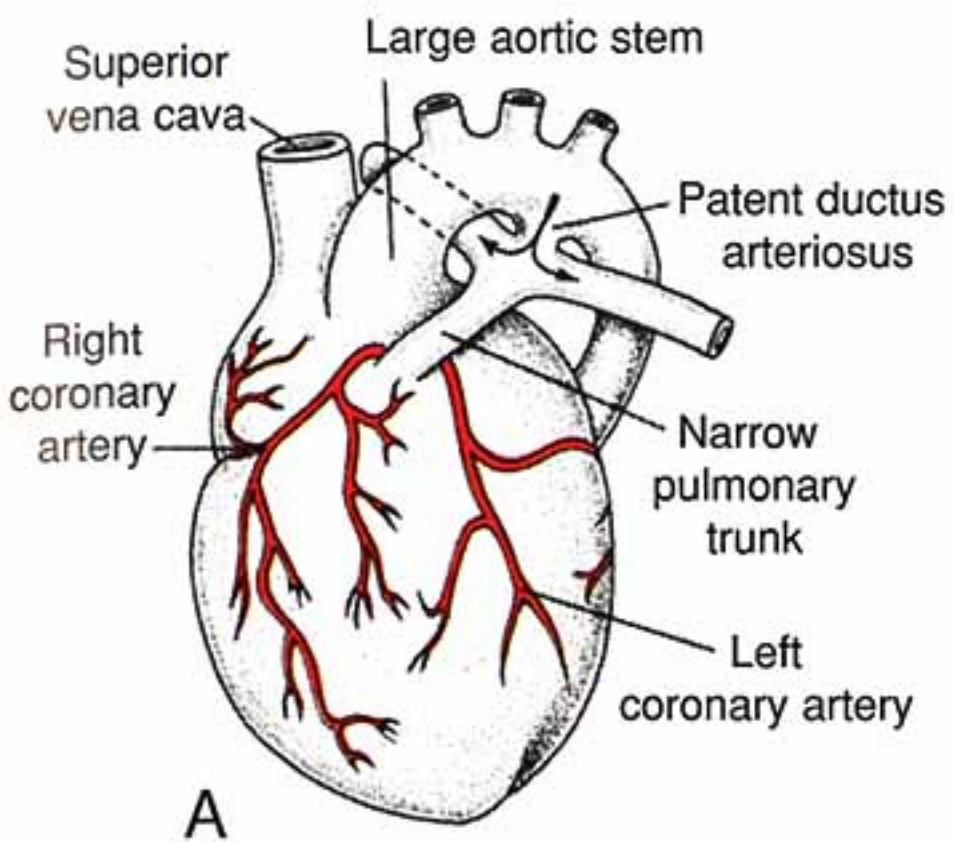
Aorta

Mesenchyme of semilunar valve

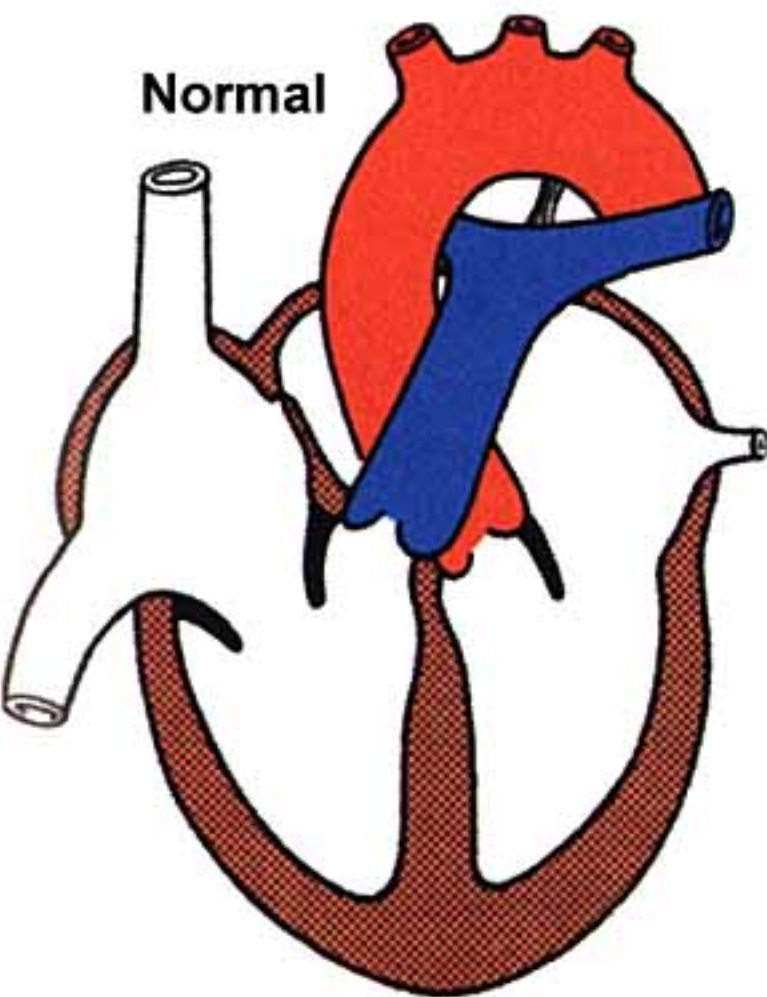


Pulmonary artery

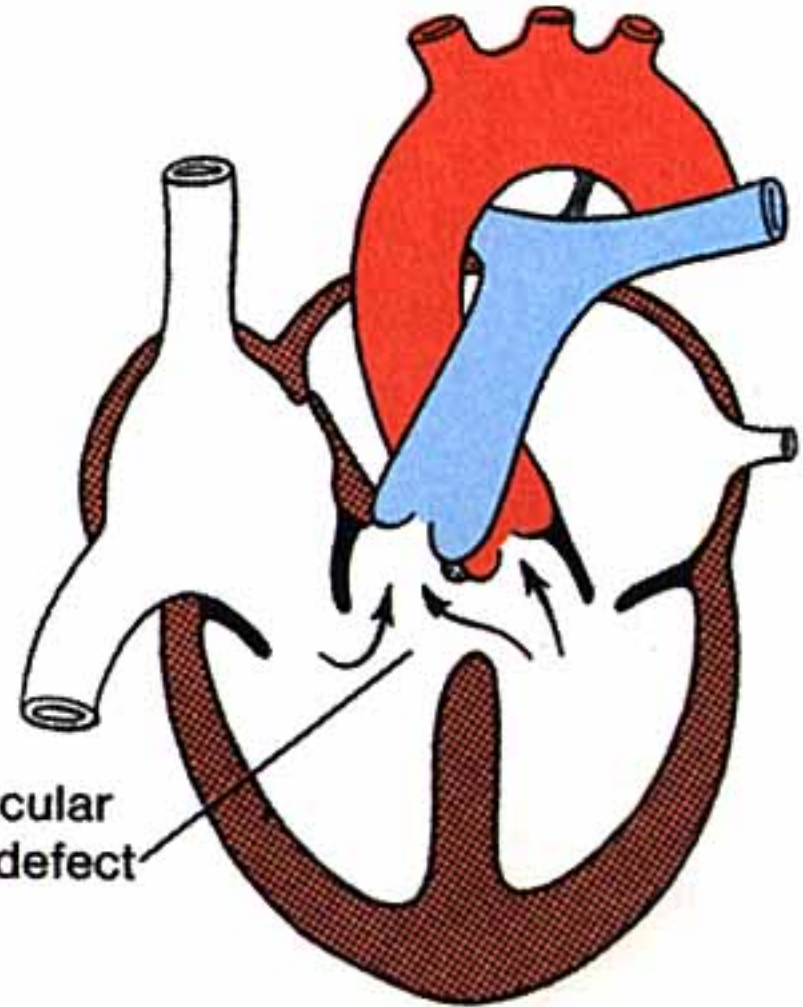


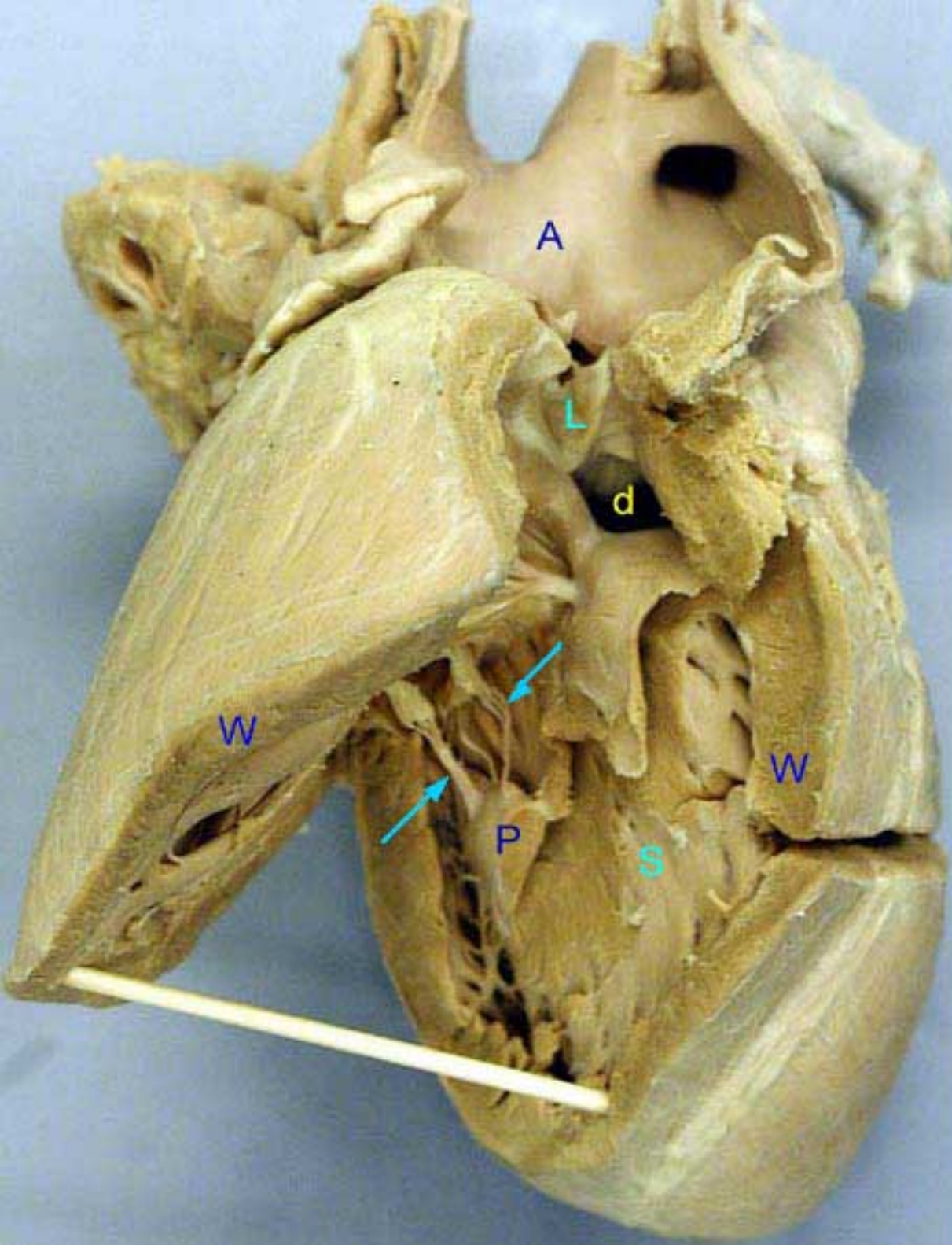

Normal

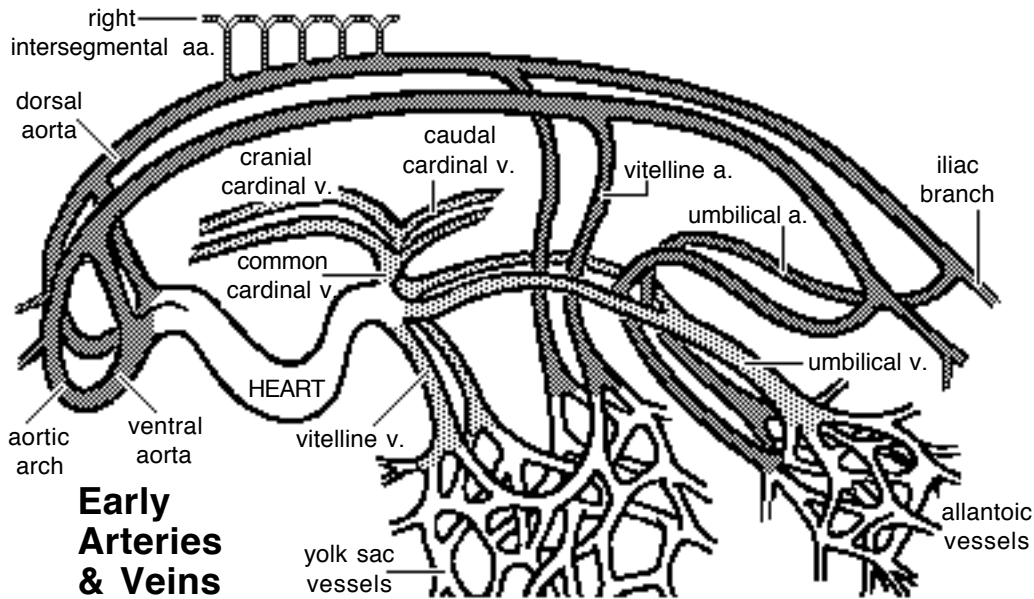


Ventricular septal defect





Interventricular septal defect (d) in a calf heart. The right ventricular wall (w) is cut open to expose the septum (s) between the ventricles. The defect is high in the septum as most septal defects are. The semilunar valve (L) leads into the aorta (A) rather than the pulmonary trunk due to transposition of the great vessels. P = papillary muscle to which the chordae tendinae (arrows) of the right AV valve are attached.



Arteries:

Dorsal and Ventral Aortae:

The embryo develops paired ventral and dorsal aortae. The two ventral aortae receive blood from the truncus arteriosus. Bilaterally, ventral and dorsal aortae are connected by a series of up to six *aortic arches*. Each aortic arch is situated within a pharyngeal (branchial) arch.

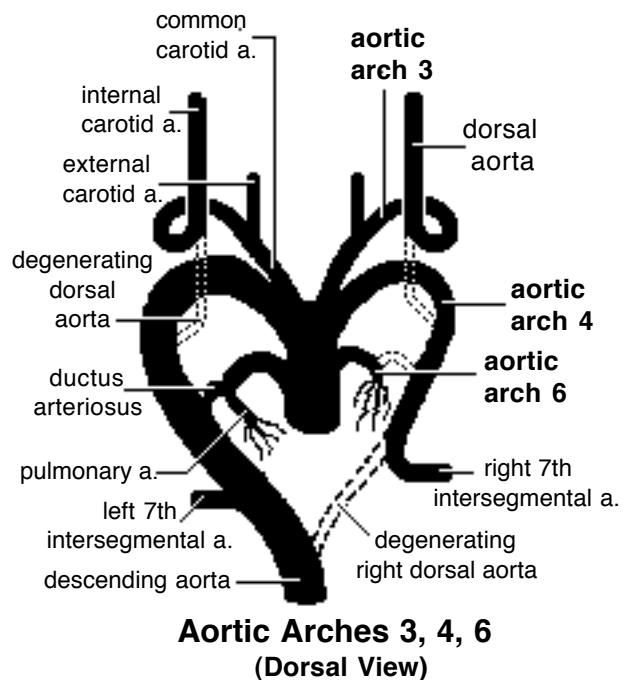
Paired ventral aortae fuse to form the *brachiocephalic trunk*. Caudal to the aortic arches, the paired dorsal aortae merge to form a single *descending aorta*, as found in the adult. The aorta gives off dorsal, lateral, and ventral branches, some of which persist as adult vessels. Aortic arches become carotid, subclavian, arch of the aorta, and pulmonary arteries.

Disposition of Aortic Arches:

Only the third, fourth, and sixth aortic arches become adult vessels. The first two arches degenerate and the fifth arch is rudimentary or absent.

Each *third* aortic arch becomes an internal carotid artery. Proximally the third arch forms a common carotid artery. The dorsal aorta degenerates between the third and fourth aortic arches. Consequently, the third arch supplies the head and the fourth arch supplies more caudal regions. The *external carotid artery* buds from the third arch.

The *left fourth* aortic arch becomes the adult arch of the aorta. The *right fourth* aortic arch becomes the proximal part of the right subclavian artery as the distal connection between the arch and the dorsal aorta normally degenerates. (Persistence of a connection between the fourth aortic arch and the descending aorta results in compression of the esophagus, accompanied difficult swallowing and an enlarged esophagus cranial to the compression.)



The proximal part of each *sixth* aortic arch becomes a pulmonary artery. The distal part of the arch degenerates on the right side but persists as ductus arteriosus on the left side.

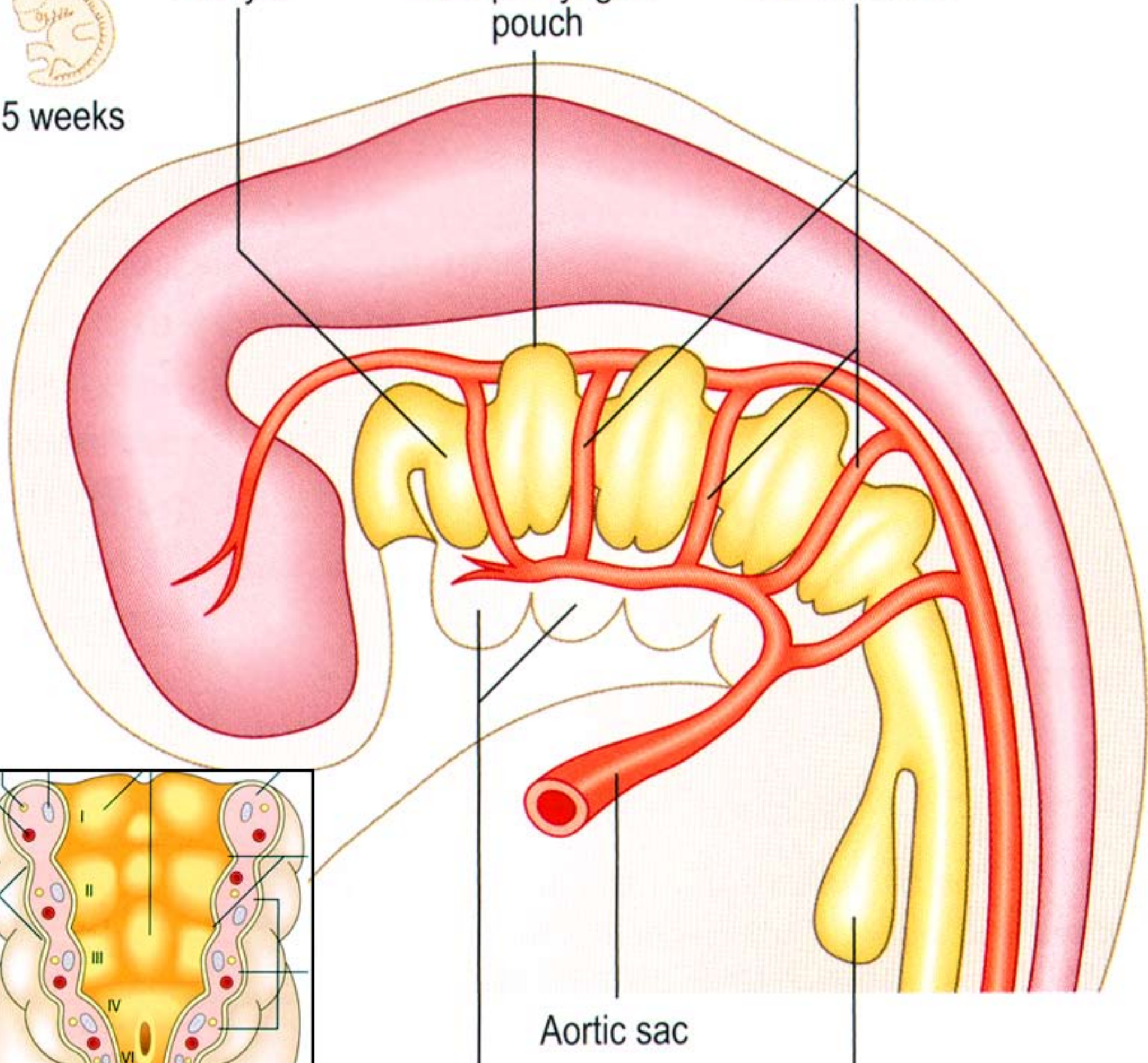


5 weeks

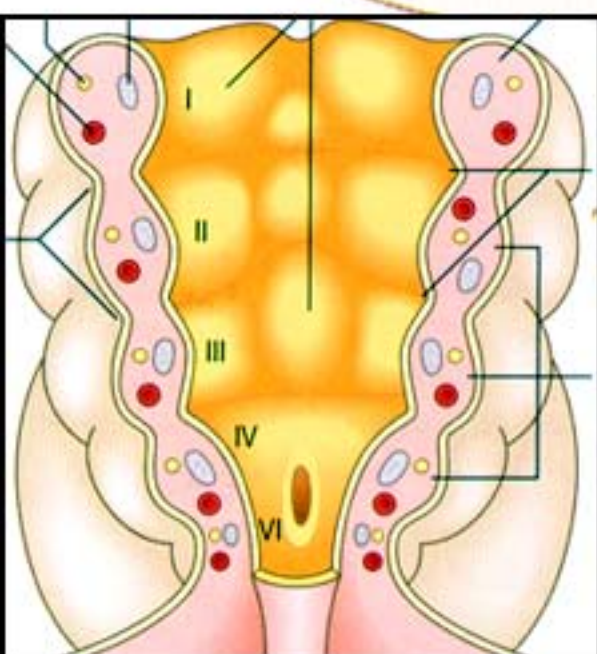
Pharynx

First pharyngeal pouch

Aortic arches

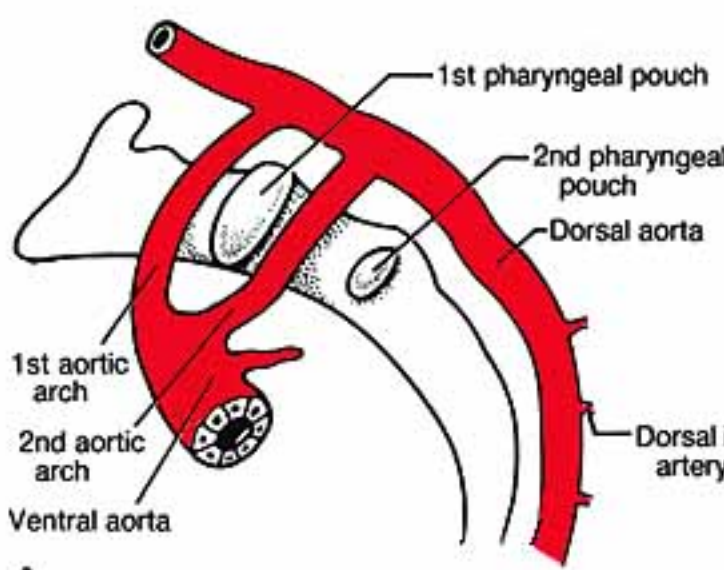


Aortic sac

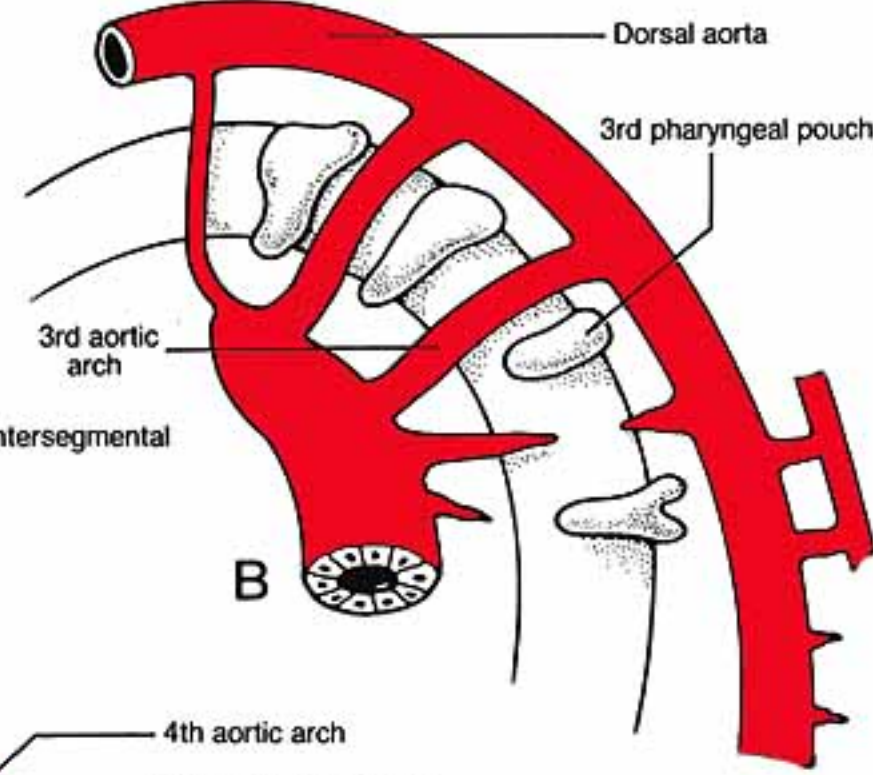


Pharyngeal arches

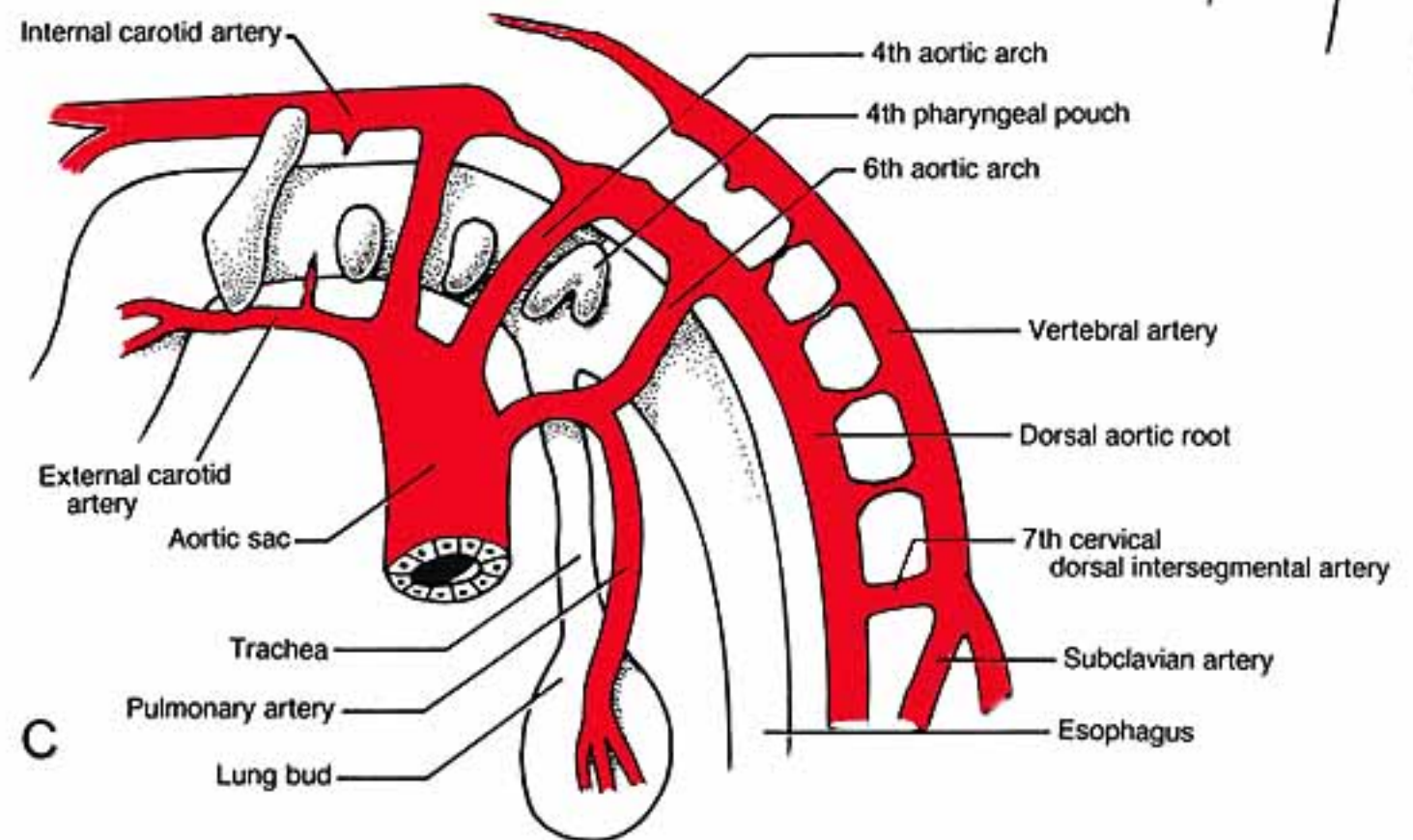
Lung bud



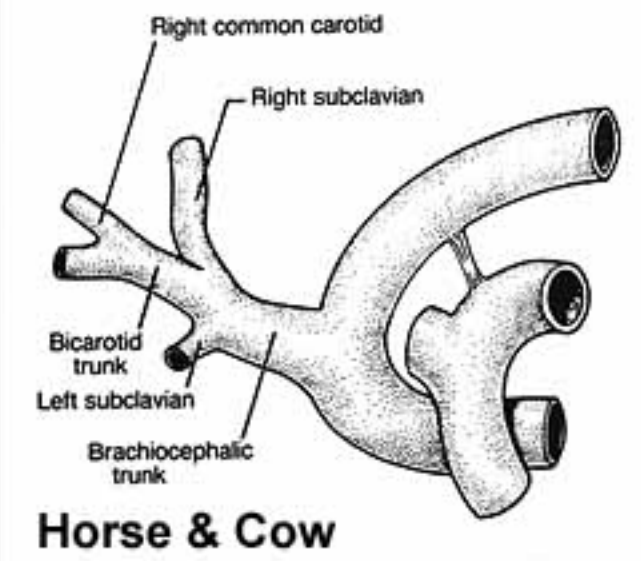
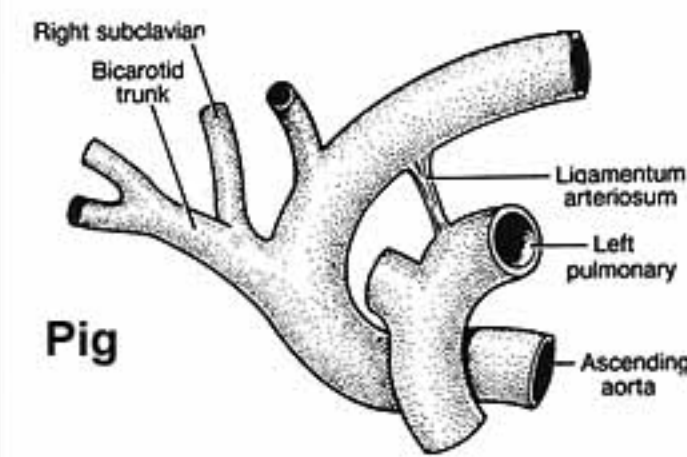
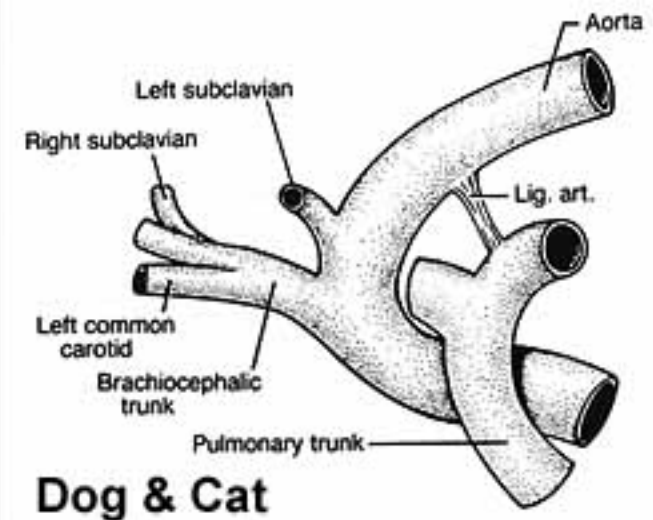
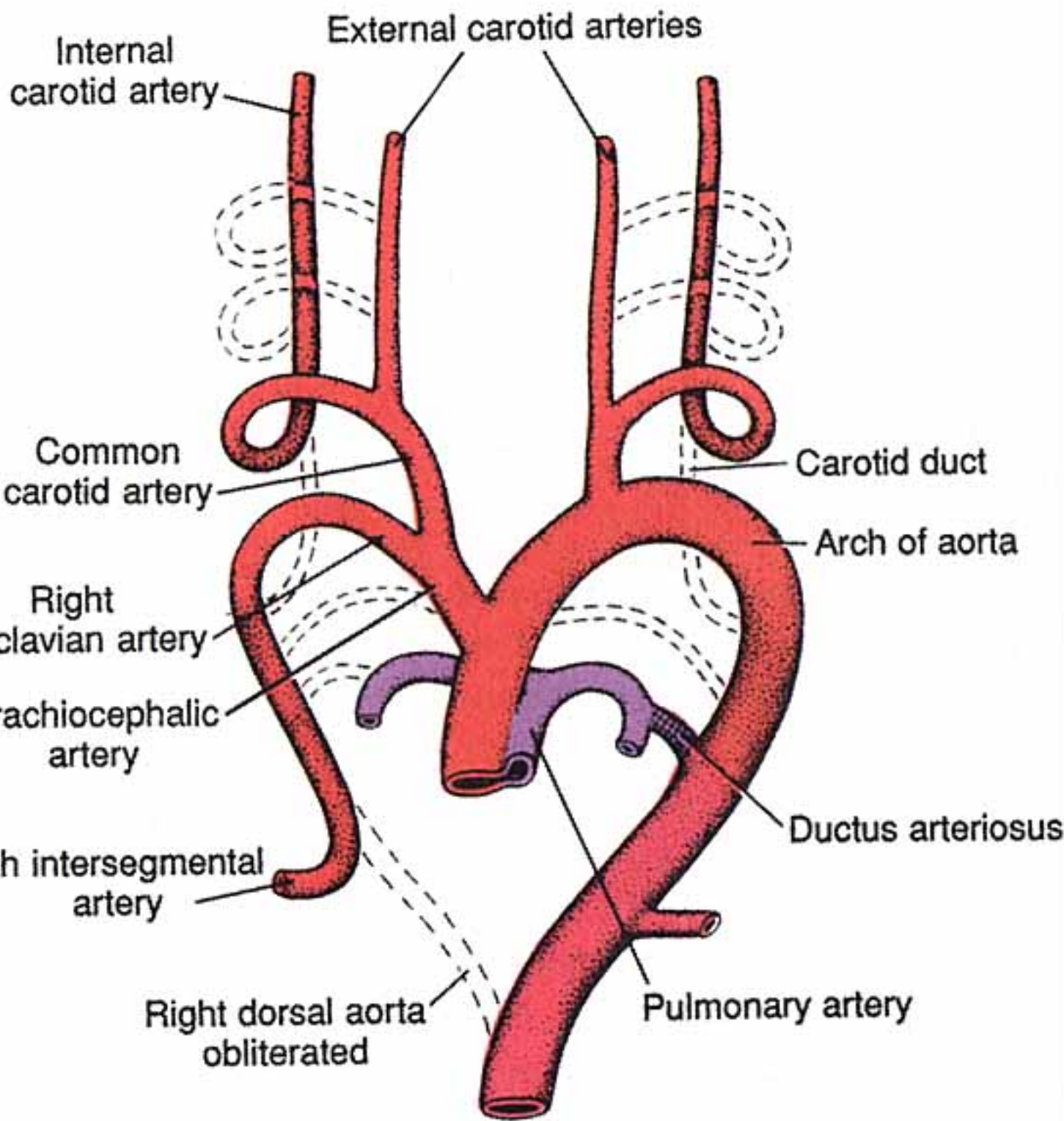
A



B

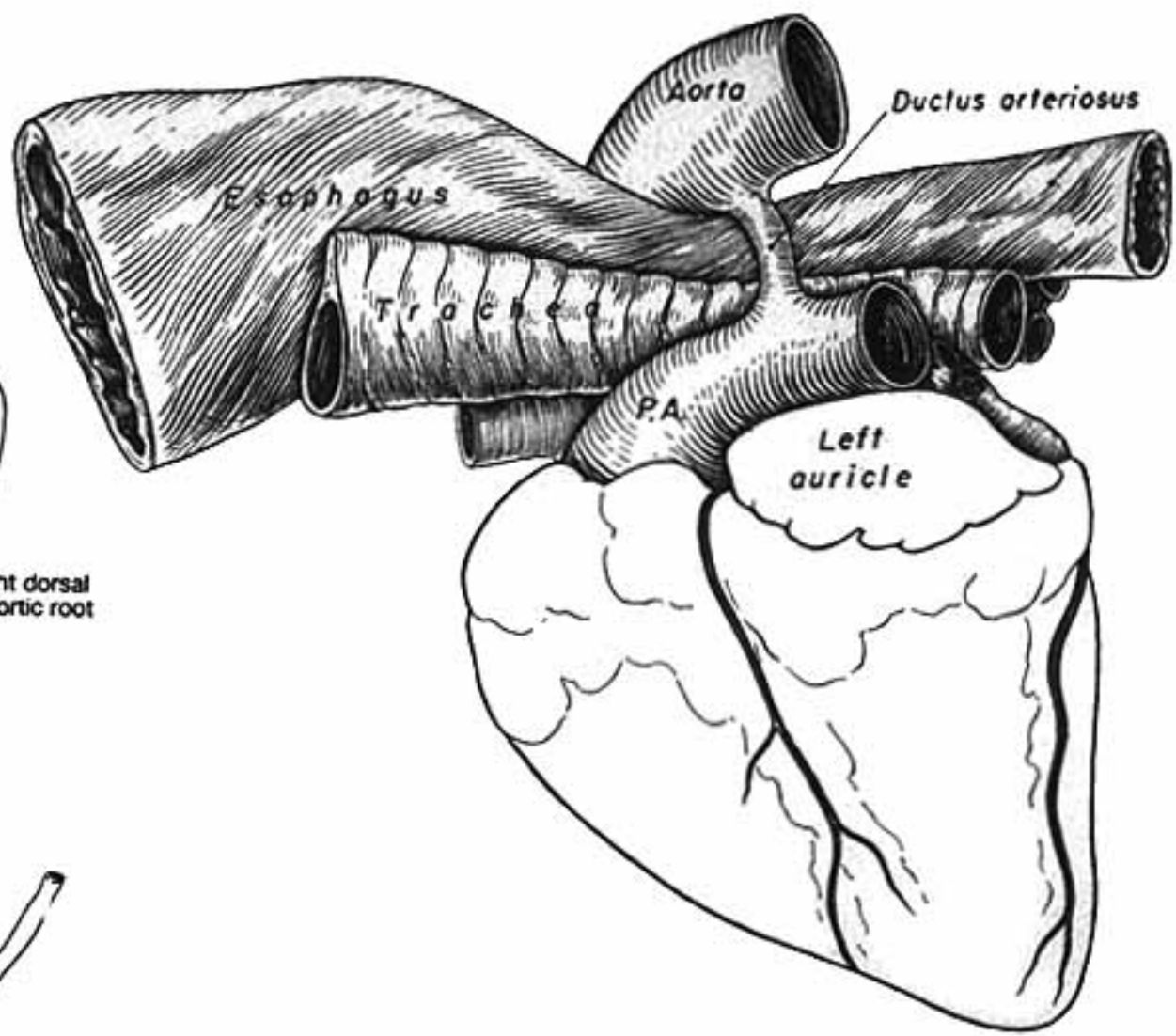
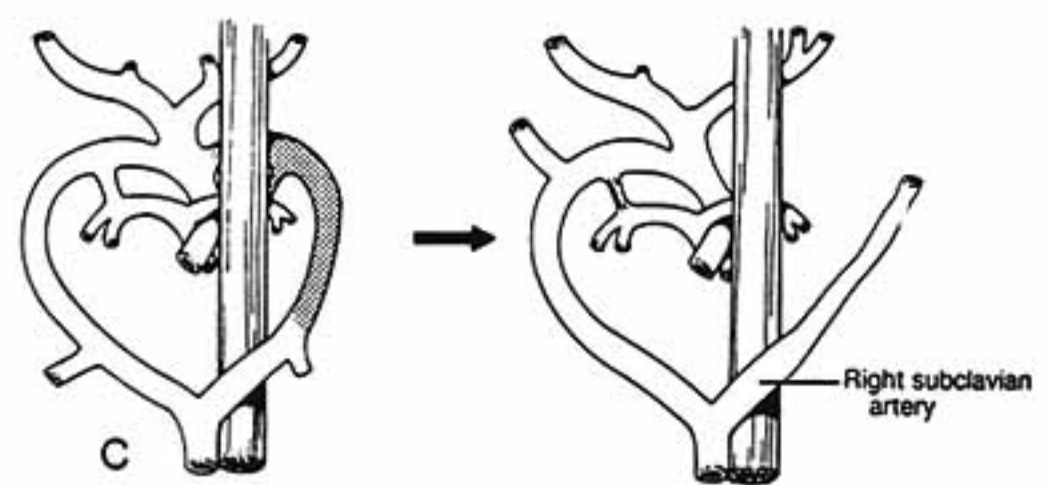
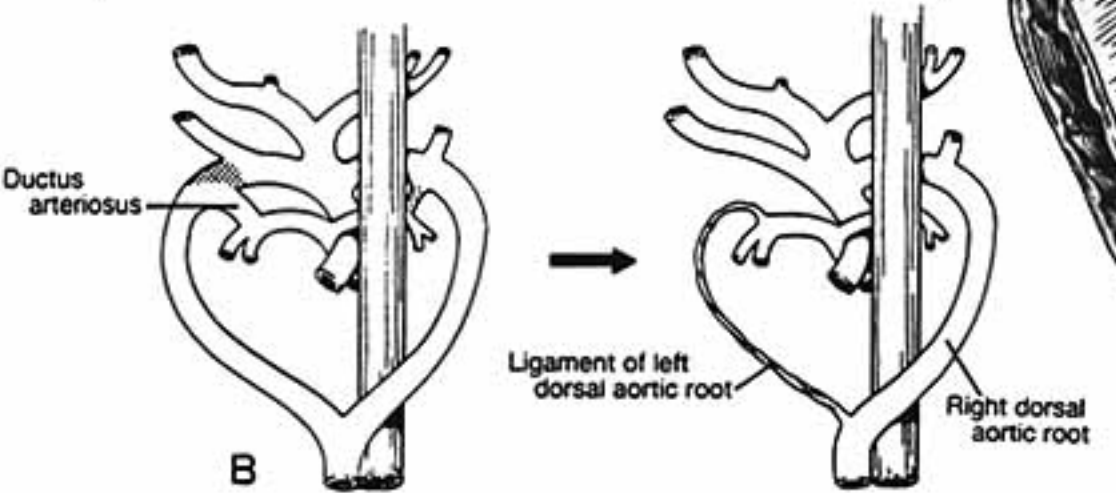
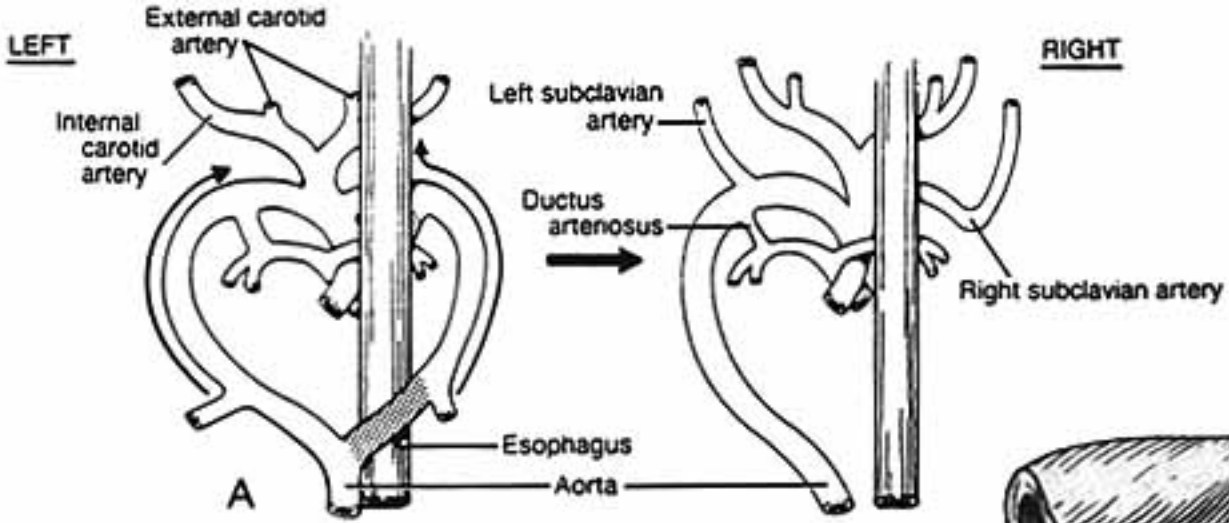


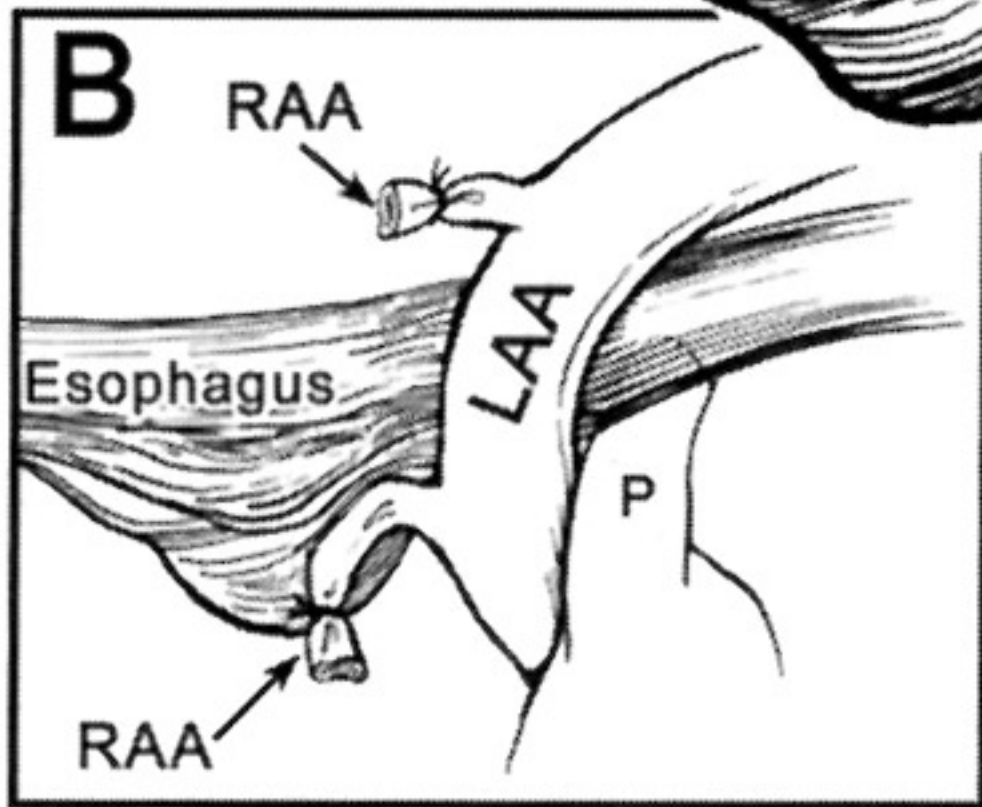
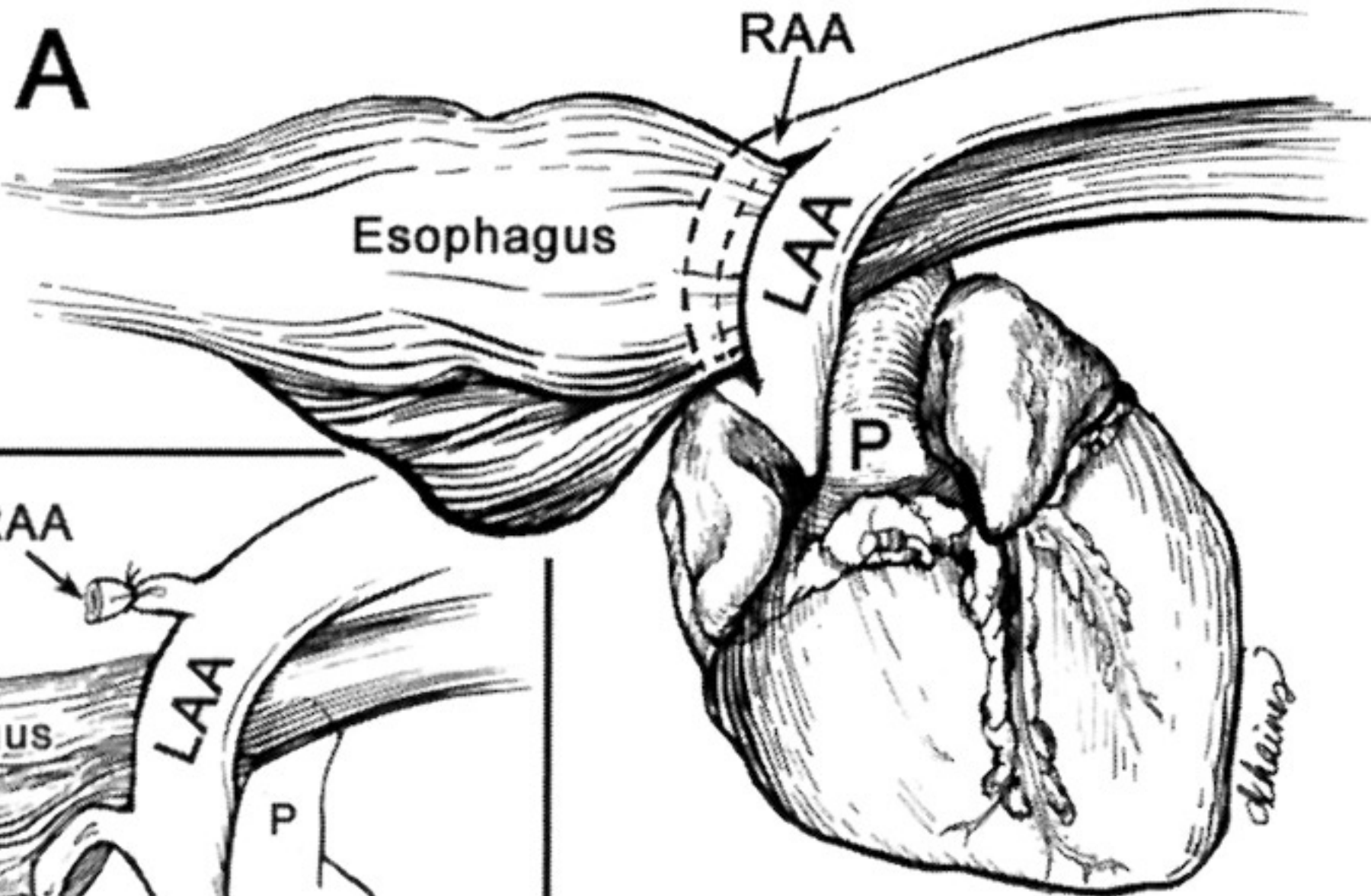
C



LEFT

RIGHT





Canine Double Aortic Arch

Note: The *ductus arteriosus* shunts blood from the pulmonary trunk to the aorta. The shunt allows the right ventricle to be exercised in the face of limited capacity of the lungs to accept & return blood. At birth, ductus arteriosus constriction abruptly shifts pulmonary trunk output into the lungs. Eventually, a ligamentum arteriosum replaces the constricted ductus arteriosus. (A persistent ductus arteriosus results in a continuous murmur during both systole and diastole.)

Subclavian & Vertebral arteries:

Each dorsal aorta gives off intersegmental arteries that pass dorsally between somites. Bilaterally, the seventh cervical intersegmental artery becomes the distal portion of the subclavian artery.

Intersegmental arteries cranial to the seventh cervical form the vertebral artery (by anastomosing with one another and losing connections to the aorta via degeneration). Intersegmental arteries caudal to the seventh cervical become intercostal and lumbar arteries.

As the heart shifts caudally from the neck to the thoracic cavity, positions of aortic arch arteries are changed relative to the heart. In particular the subclavian arteries becomes transposed from a position caudal to the heart to a cranial position.

Branches of Dorsal Aortae:

Right and left vitelline arteries arise from right and left dorsal aortae, respectively, to supply the yolk sac. The right vitelline artery becomes the *cranial mesenteric artery*. The left vitelline artery normally degenerates. (Incomplete degeneration of the left vitelline artery can result in a fibrous band that may cause colic by entrapping a segment of intestine.)

Each dorsal aorta terminates in an umbilical artery that supplies blood to the allantois. In the adult, umbilical arteries persist proximal to the urinary bladder and degenerate distal to the bladder. External and internal iliac arteries develop as outgrowths of the umbilical artery.

Veins:

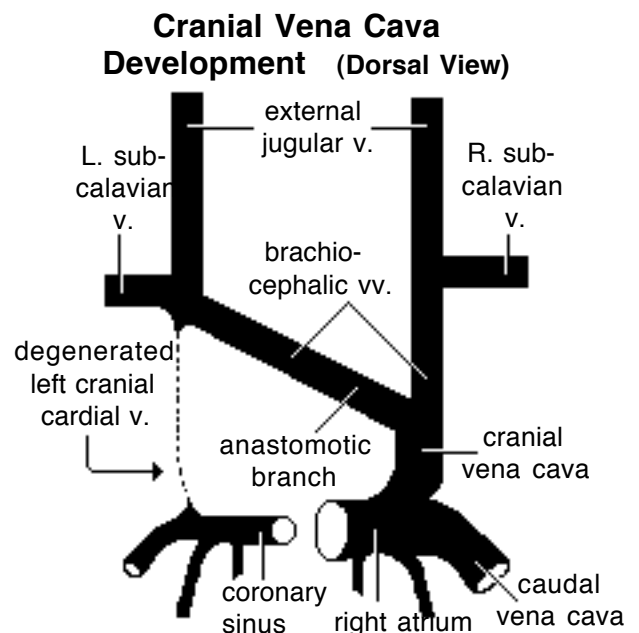
The sinus venosus receives vitelline veins which drain the yolk sac, umbilical veins which drain the allantois, and cardinal veins which drain the embryo. The transition from embryonic to adult venous patterns involves the formation of new veins, anastomoses between veins, and the selective degeneration of embryonic segments.

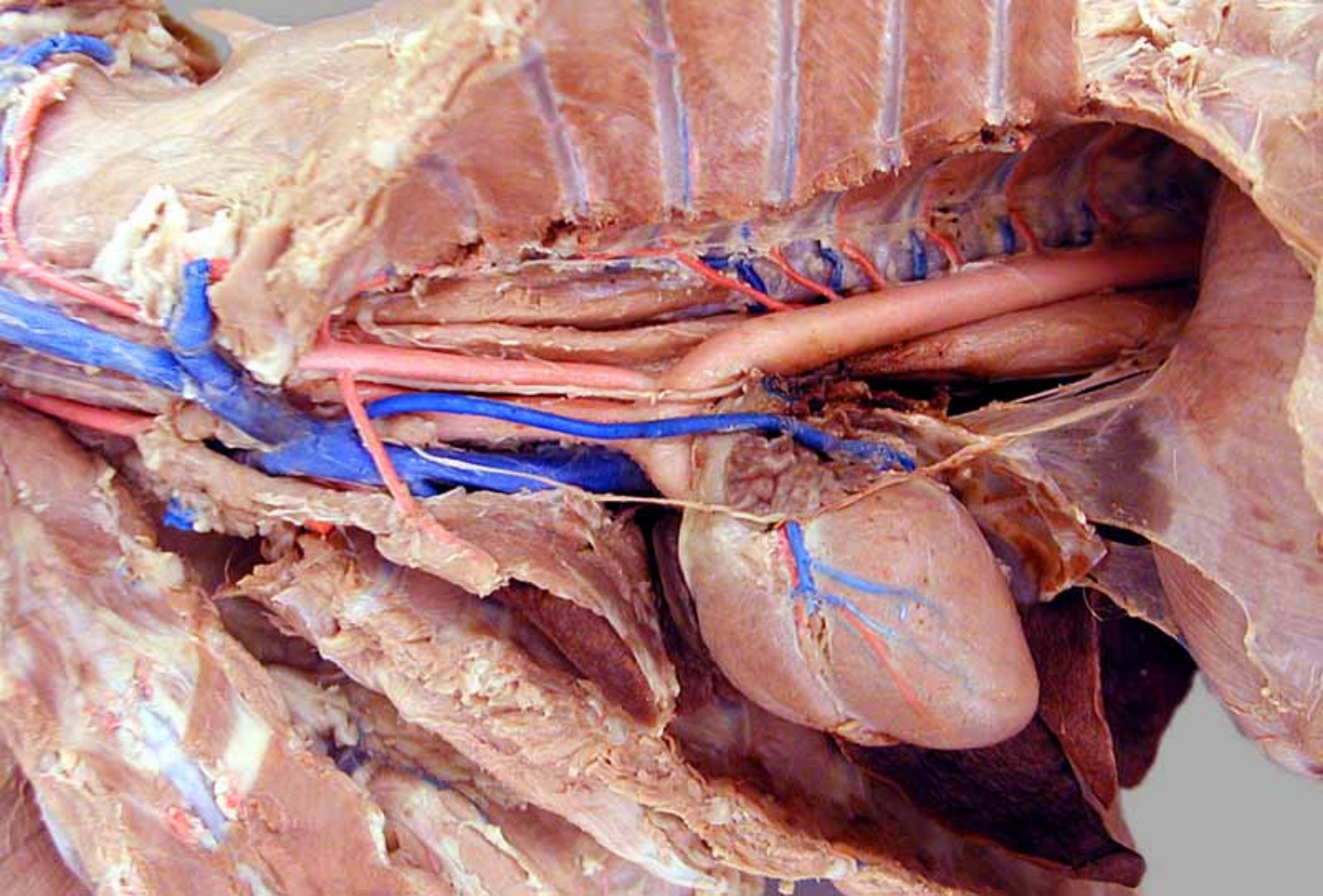
Note: Recall that venous return is shifted to the right side and the right sinus venosus is incorporated into the wall of the right atrium. The left sinus venosus is reduced and becomes coronary sinus.

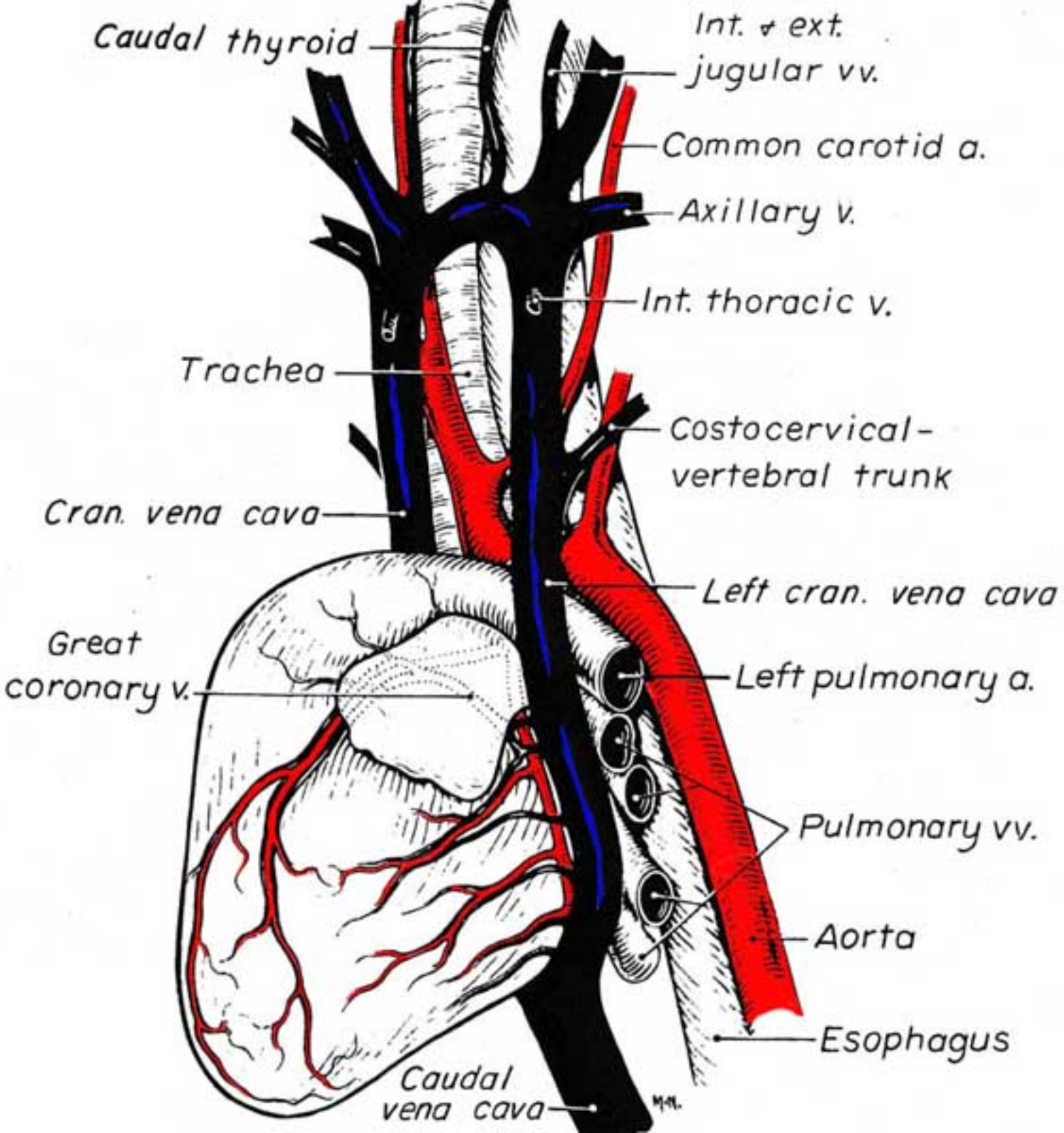
Cranial Vena Cava Formation:

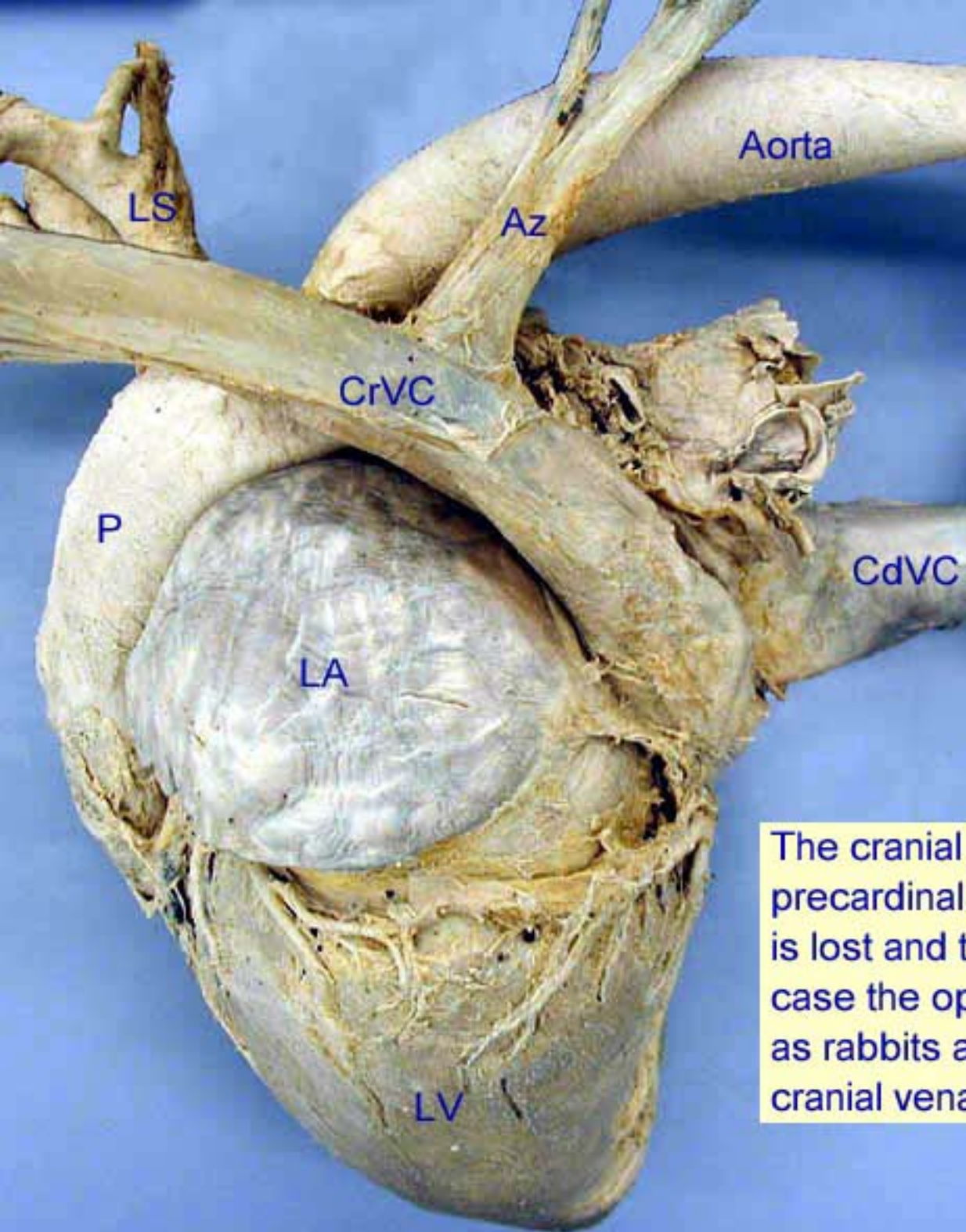
Each cranial cardinal vein becomes the adult *internal jugular vein*. The much larger *external jugular* and *subclavian* veins arise by budding from the cranial cardinal vein.

An anastomotic vein develops and runs from left to right cranial cardinal veins, shifting venous return to the right side and becoming left *brachiocephalic vein*. The caudal segment of right cranial cardinal vein along with the right common cardinal vein becomes the *cranial vena cava*. (Failure of the anastomotic vein to develop results in a double cranial vena cava, the typical condition in rats and mice.)









Left cranial vena cava of a 25 year old Arabian mare.

This horse was clinically normal and no other abnormalities were found during complete dissection in an anatomy class*. The cranial vena cava drained into the coronary sinus as does a left azygous in pig and ox.

Az = Azygous vein

CdVC = Caudal vena cava

CrVC = Cranial vena cava

LA = Left atrium

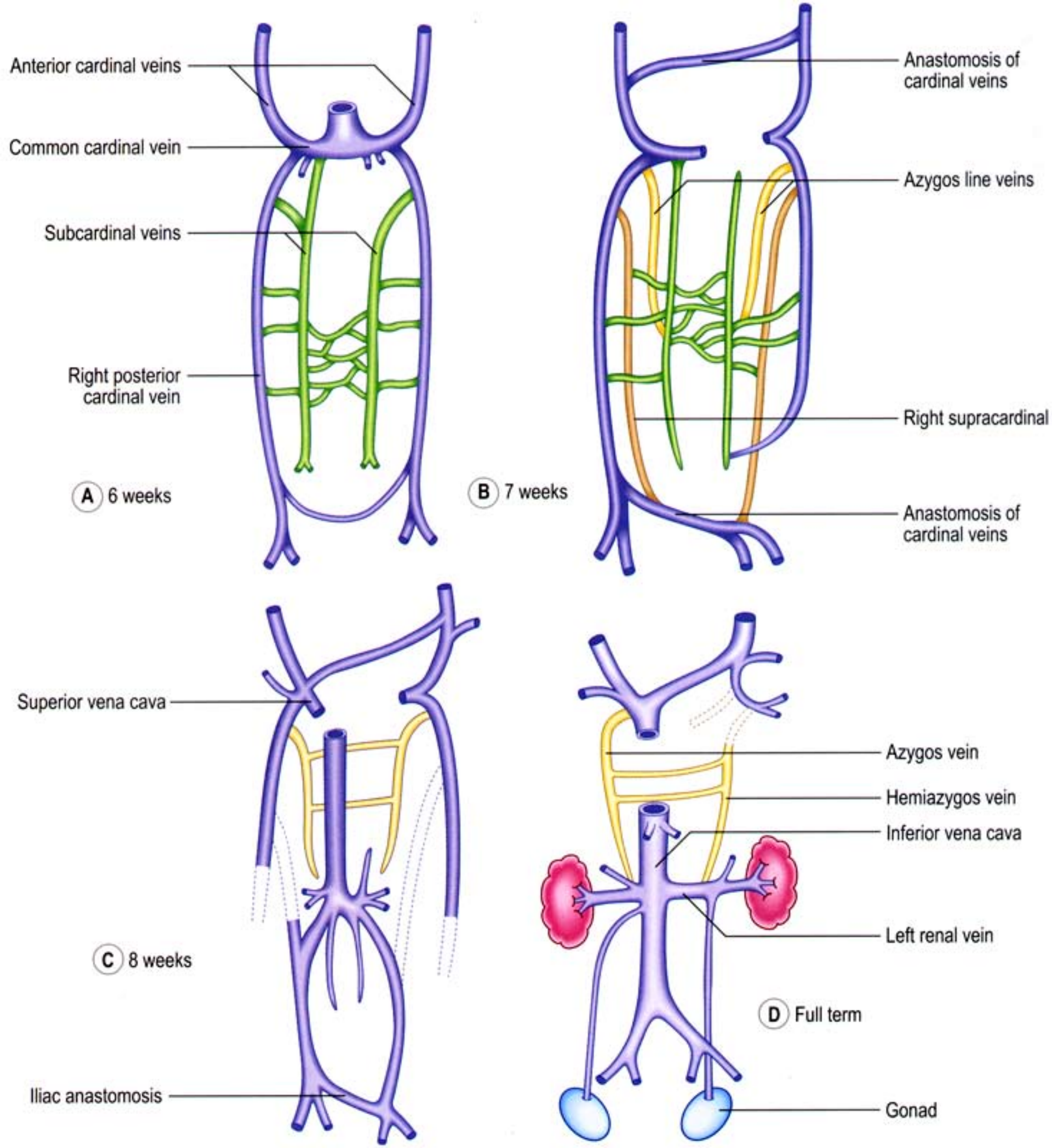
LS = Left subclavian a.

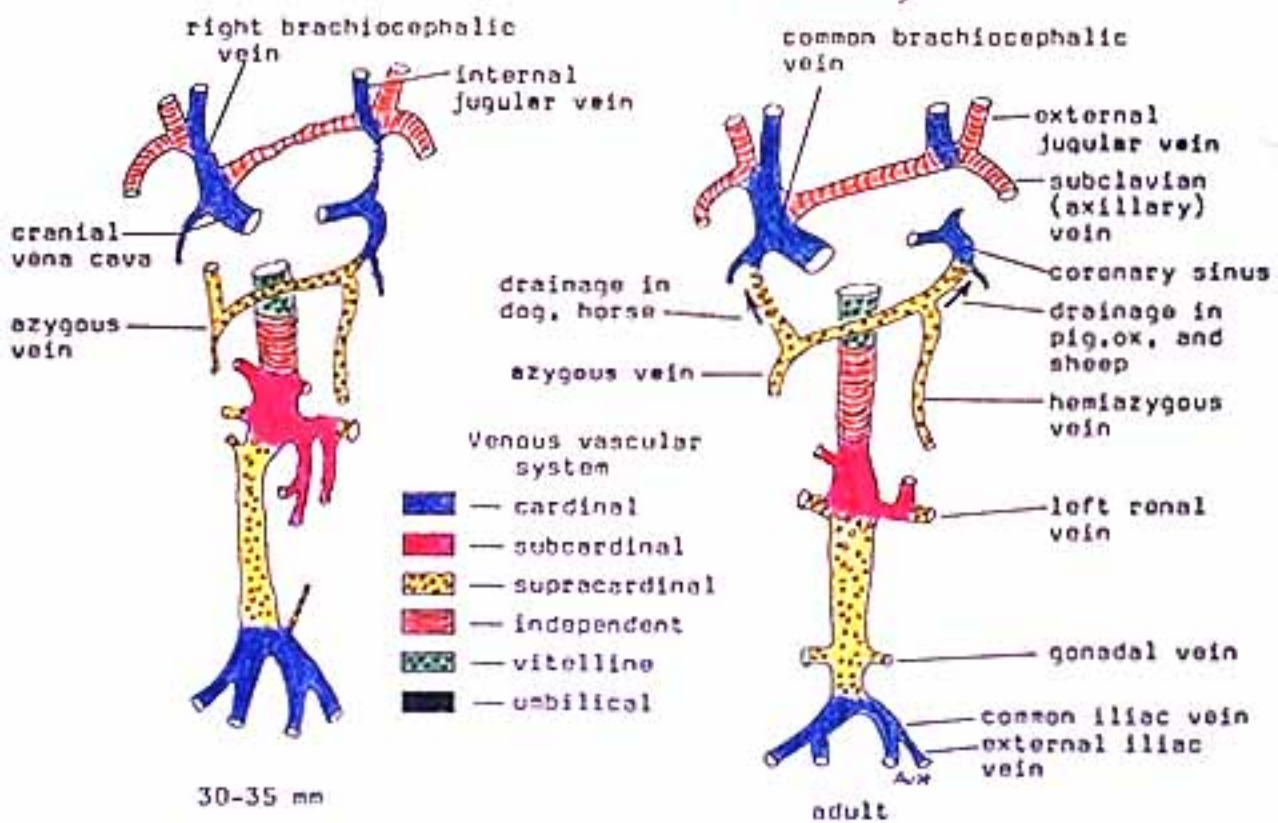
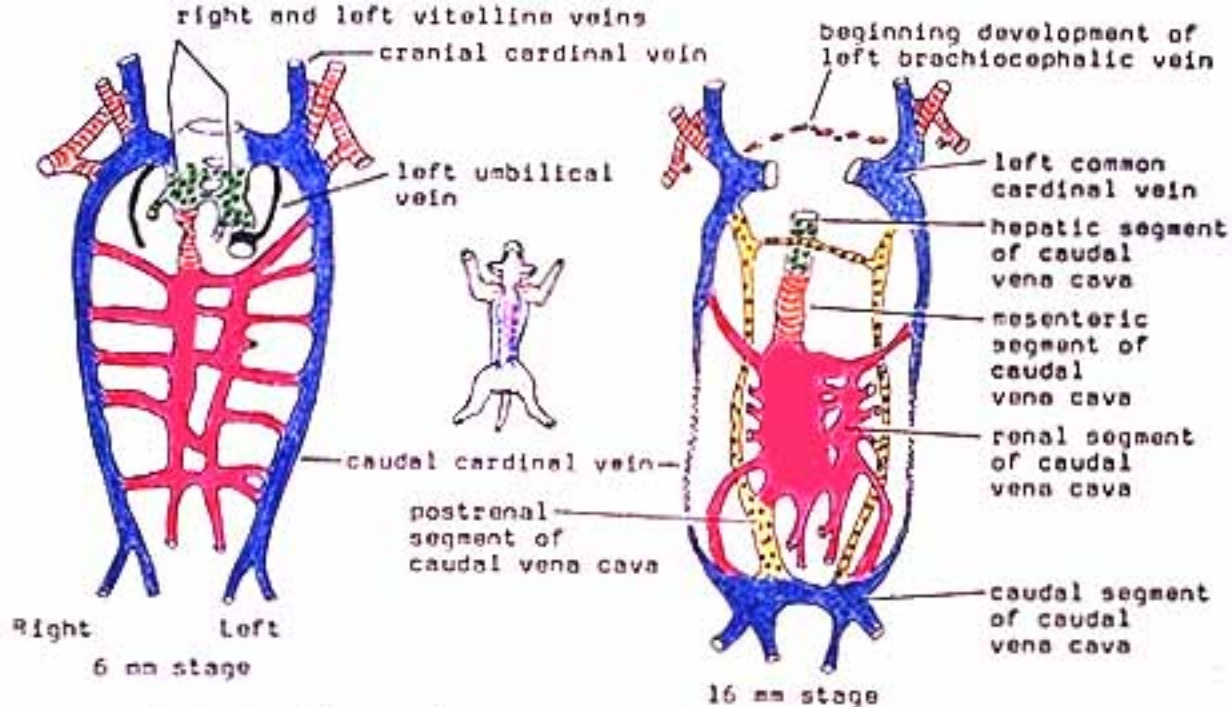
LV = Left ventricle

P = Pulmonary trunk a.

The cranial vena cava forms from the paired precardinal veins of the embryo. Normally the left is lost and the right persists as the CrVC but in this case the opposite occurred. Some animals such as rabbits and elephants are born with paired cranial vena cavae that persist throughout life.

* Cox, et al., Anat. Histol. Embryol. 20, 37-43 (1991).





Caudal Vena Cava and Azygos Vein:

Each caudal cardinal vein gives rise to supra-cardinal and sub-cardinal veins with extensive anastomoses among all of the veins. These venous networks, located in intermediate mesoderm, supply embryonic kidneys and gonads.

Selective segments of particularly the right subcardinal venous network, including an anastomosis with the proximal end of the right vitelline vein form the *caudal vena cava*.

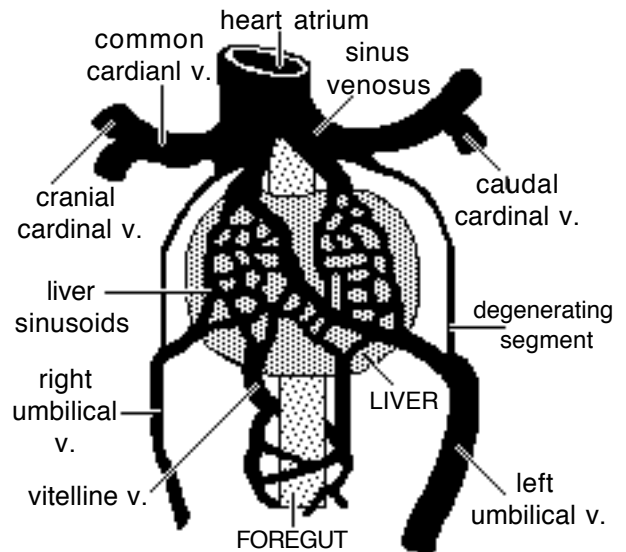
The *azygos vein* develops from the supracardinal vein as well as the caudal and common cardinal veins of the right side (dog, cat, horse) or the left side (pig) or both sides (ruminants). The azygos vein will drain into the cranial vena cava (or right atrium) on the right side and into the coronary sinus on the left side.

Portal Vein and Ductus Venosus:

Proximally, vitelline veins form liver sinusoids as the developing liver surrounds the veins. Vitelline veins give rise to the portal vein, formed by anastomoses that develop between right and left vitelline veins and enlargement/atrophy of selective anastomoses.

Umbilical veins, also engulfed by the developing liver, contribute to the formation of liver sinusoids. Within the embryo, the right umbilical vein atrophies and the left conveys placental blood to the liver. Within the liver, a shunt, the ductus venosus, develops between the left umbilical vein and the right hepatic vein which drains into the caudal vena cava.

Postnatally, the left umbilical vein becomes the round ligament of the liver located in the free edge of the falciform ligament.



**Vitelline & Umbilical Veins
(Ventral View)**

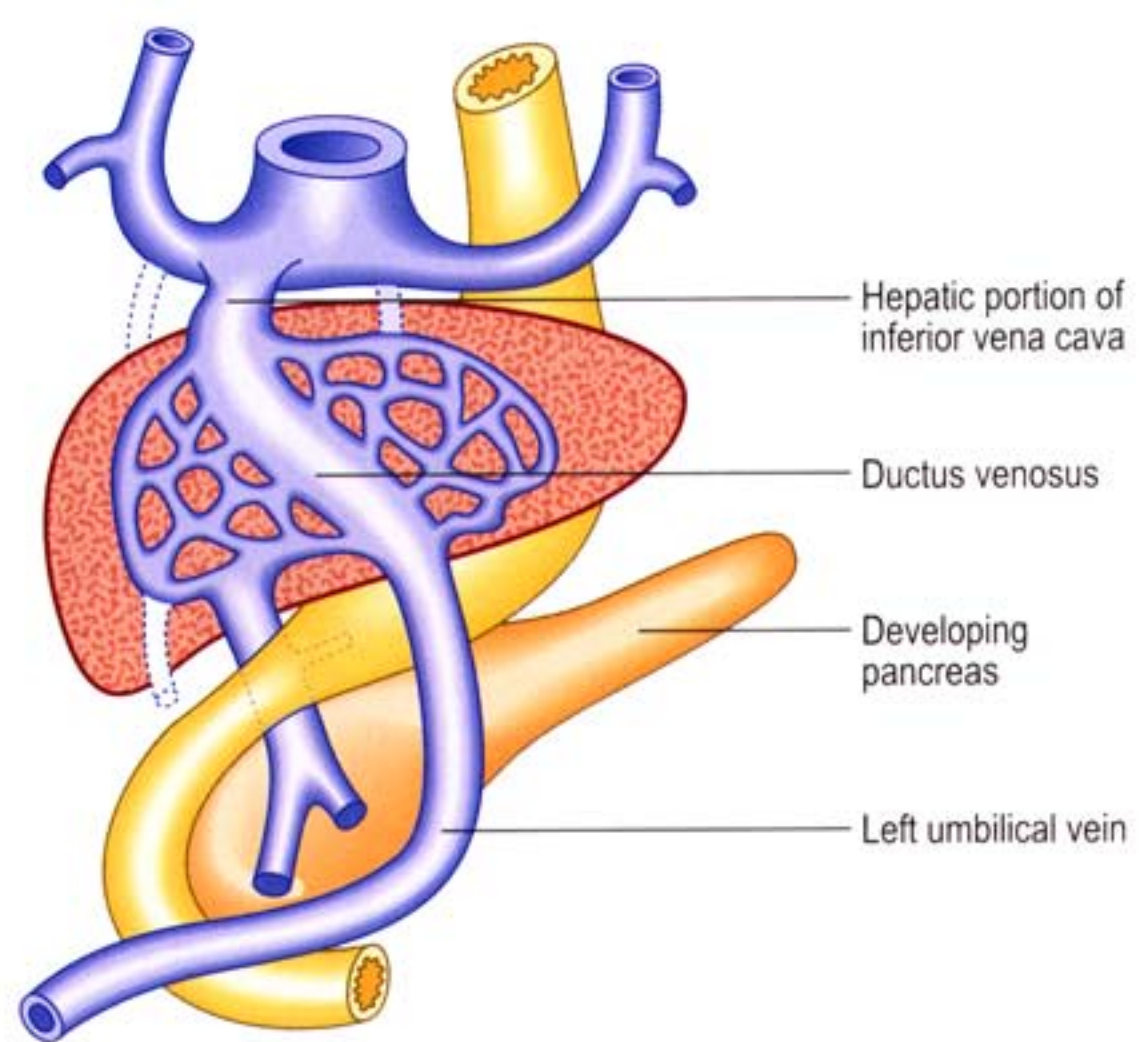
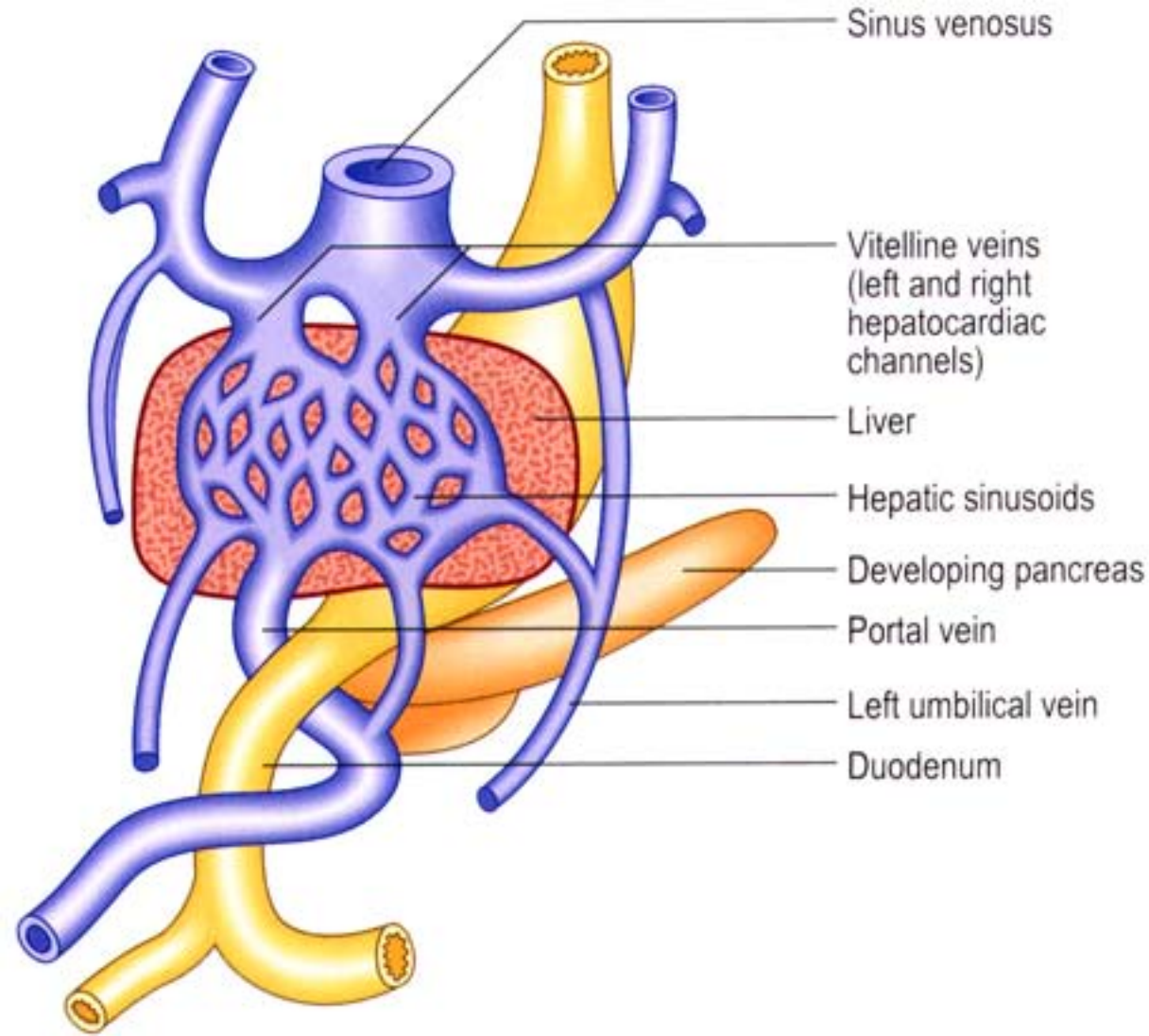
Pulmonary Veins:

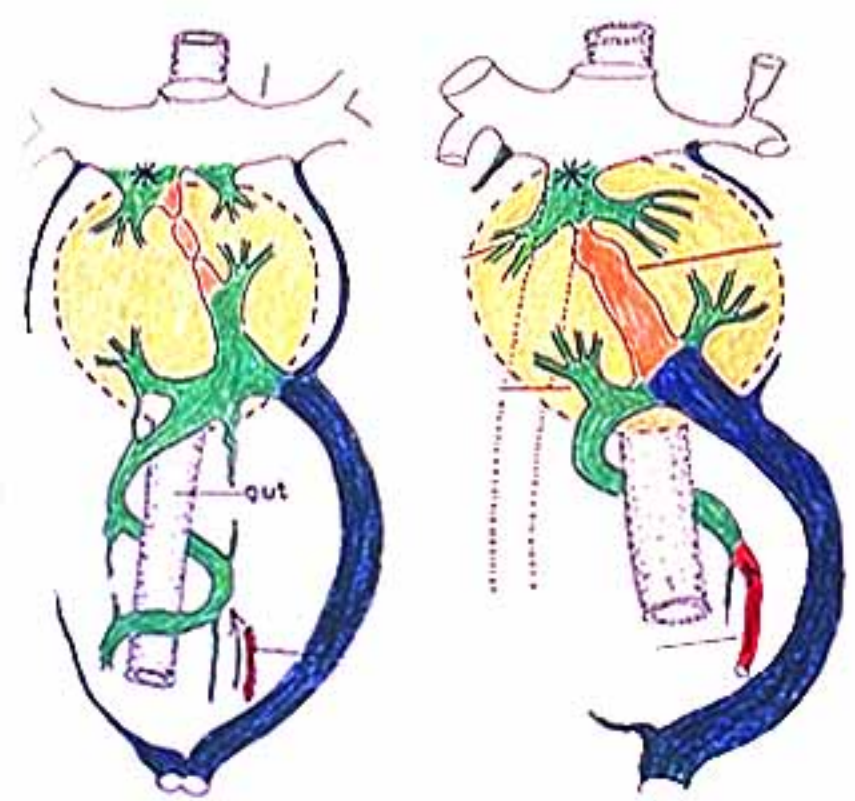
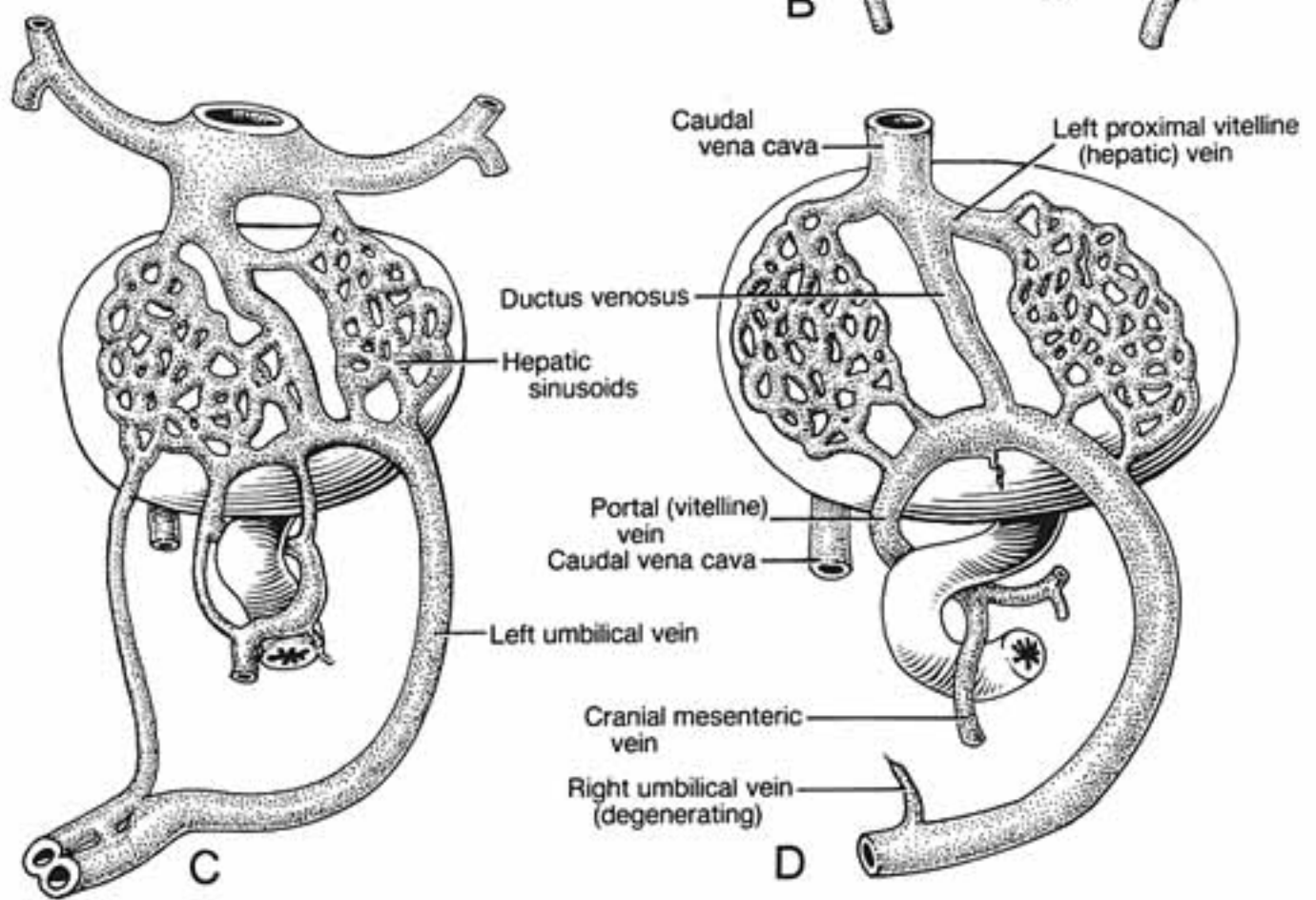
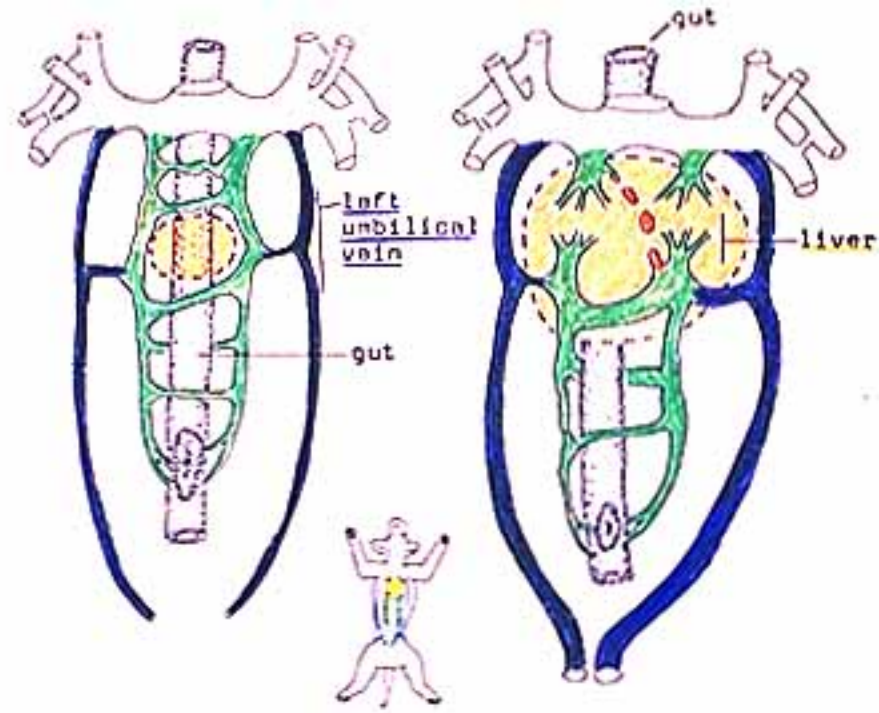
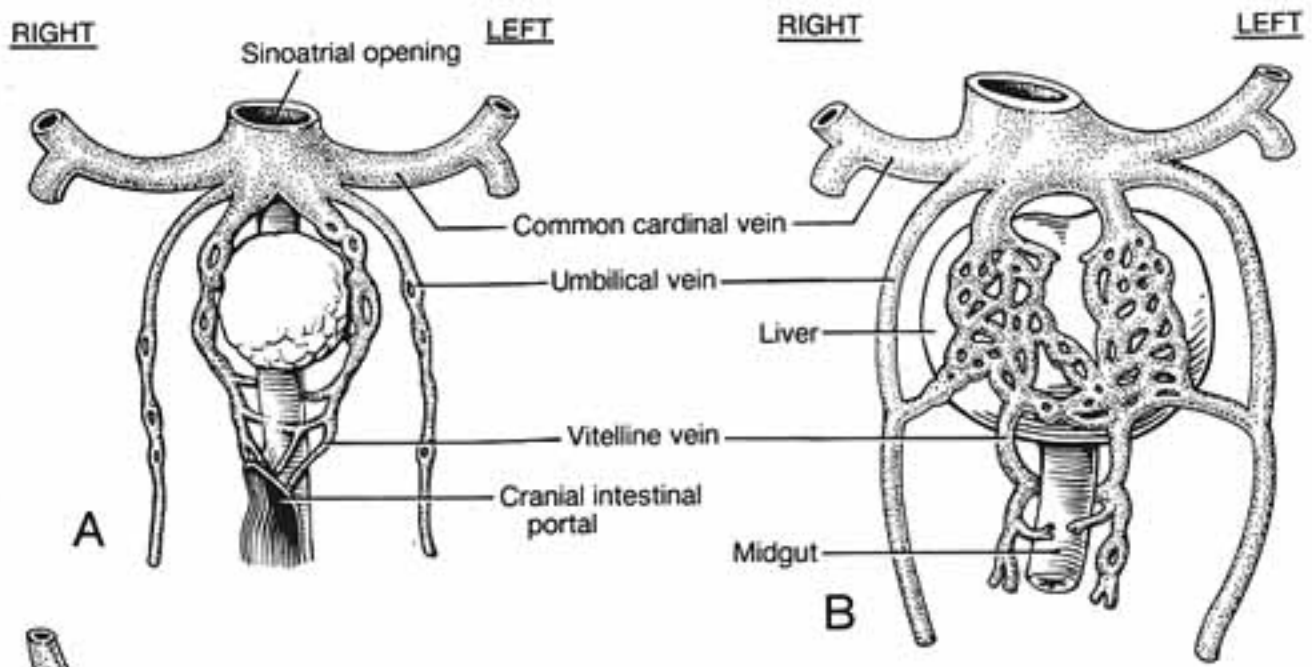
These develop as outgrowth of the left atrium. The initial growth divides into left and right branches, each of which subdivides into branches that drains lobes of the lung. Pulmonary branches become incorporated into the wall of the expanding left atrium. The number of veins entering the adult atrium is variable due to vein fusion.

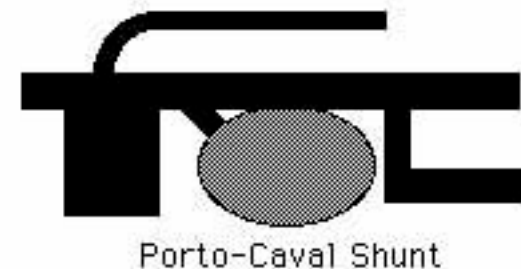
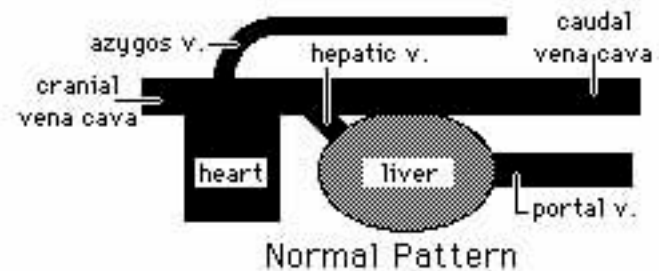
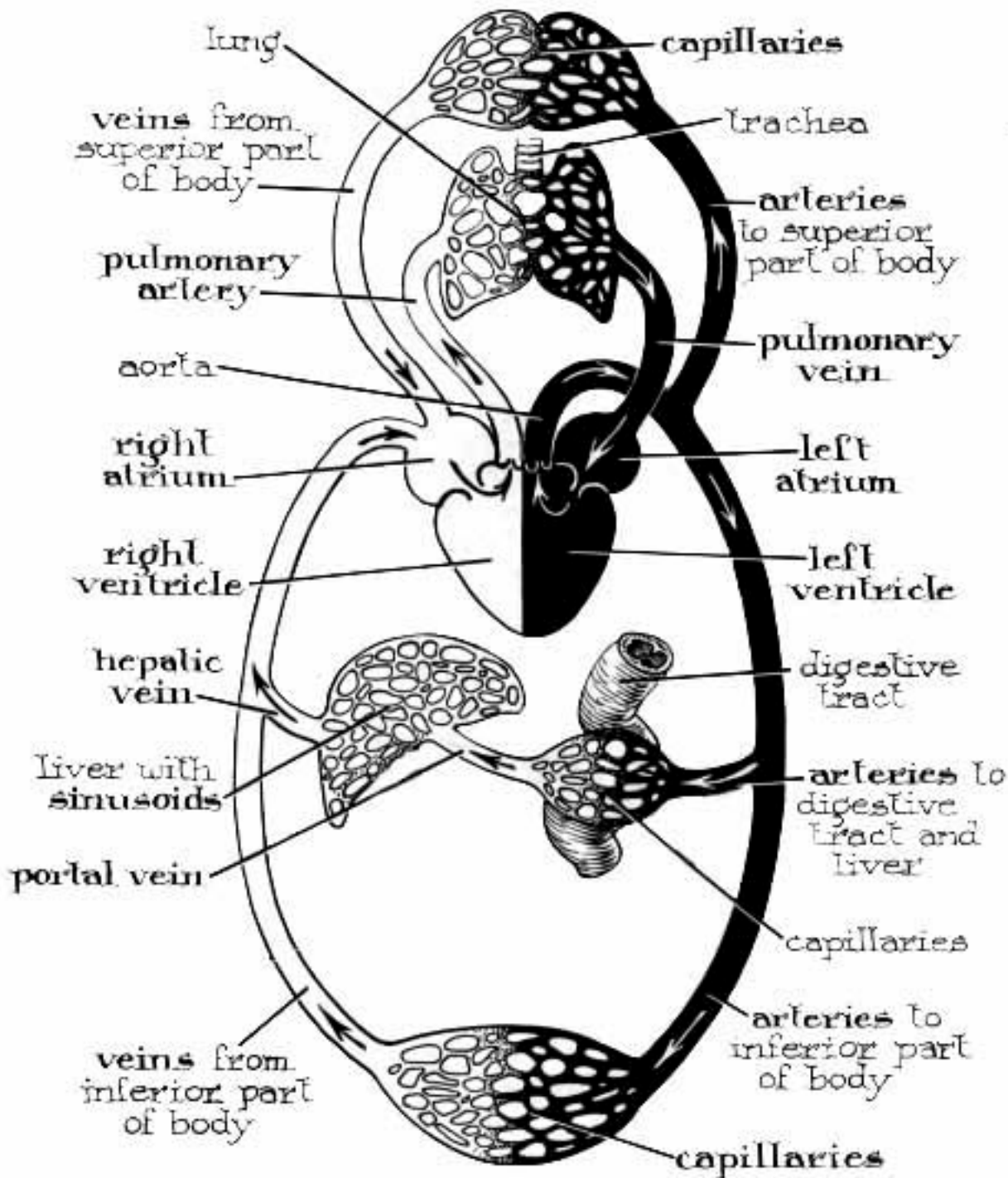
Because a fetus is not eating and because the placenta is able to detoxify blood and because it is mechanically desirable for venous return to by-pass fetal liver sinusoids, the **ductus venosus**, a shunt that diverts blood to systemic veins, develops in the embryo.

Postnatally, however, a continuing **portosystemic shunt** allows toxic digestive products to bypass the liver. These toxic agents typically affect the brain resulting in neurologic disorders at some time during life.

A portosystemic shunt can be the result of a persistent ductus venosus or a developmental error that results in anastomosis between the portal vein and the caudal vena cava or the azygos vein. Since adult veins are established by patching together parts of embryonic veins, it is not surprising that mis-connections arise from time to time.



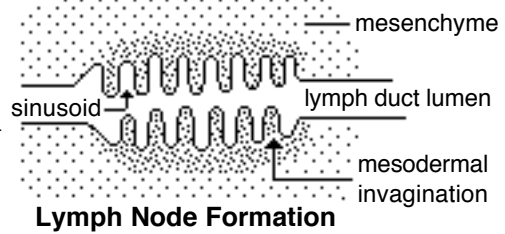




Lymphatics:

Lymph vessel formation is similar to blood angiogenesis. Lymphatics begin as lymph sacs in three regions: jugular (near brachiocephalic veins); cranial abdominal (future cisterna chyli); and iliac region. Lymphatic vessels (ducts) form as outgrowths of the sacs.

Lymph nodes are produced by localized mesodermal invaginations that partition the vessel lumen into sinusoids. The mesoderm develops a reticular framework within which lymphocytes accumulate. The spleen and hemal nodes (in ruminants) develop similar to the way lymph nodes develop.



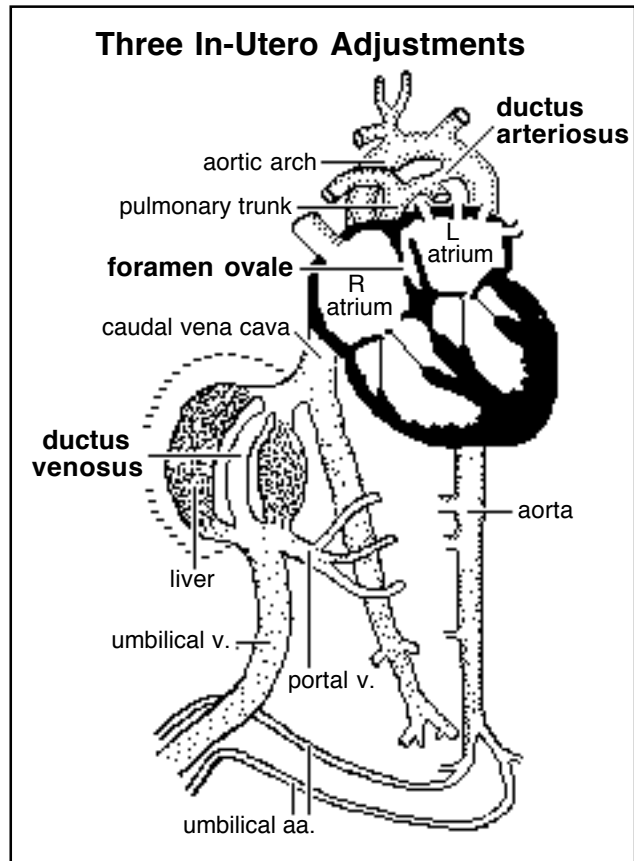
Prior to birth, fetal circulation is designed for an *in utero* aqueous environment where the placenta oxygenates fetal blood.

Suddenly, at birth...

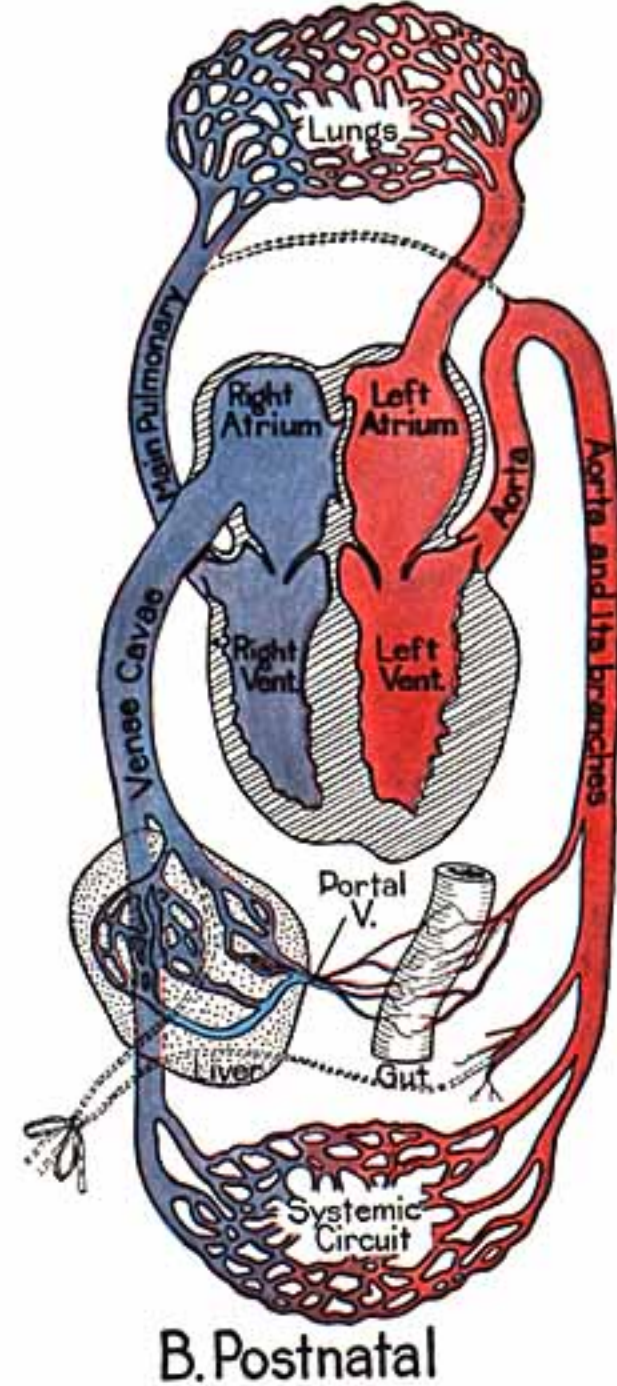
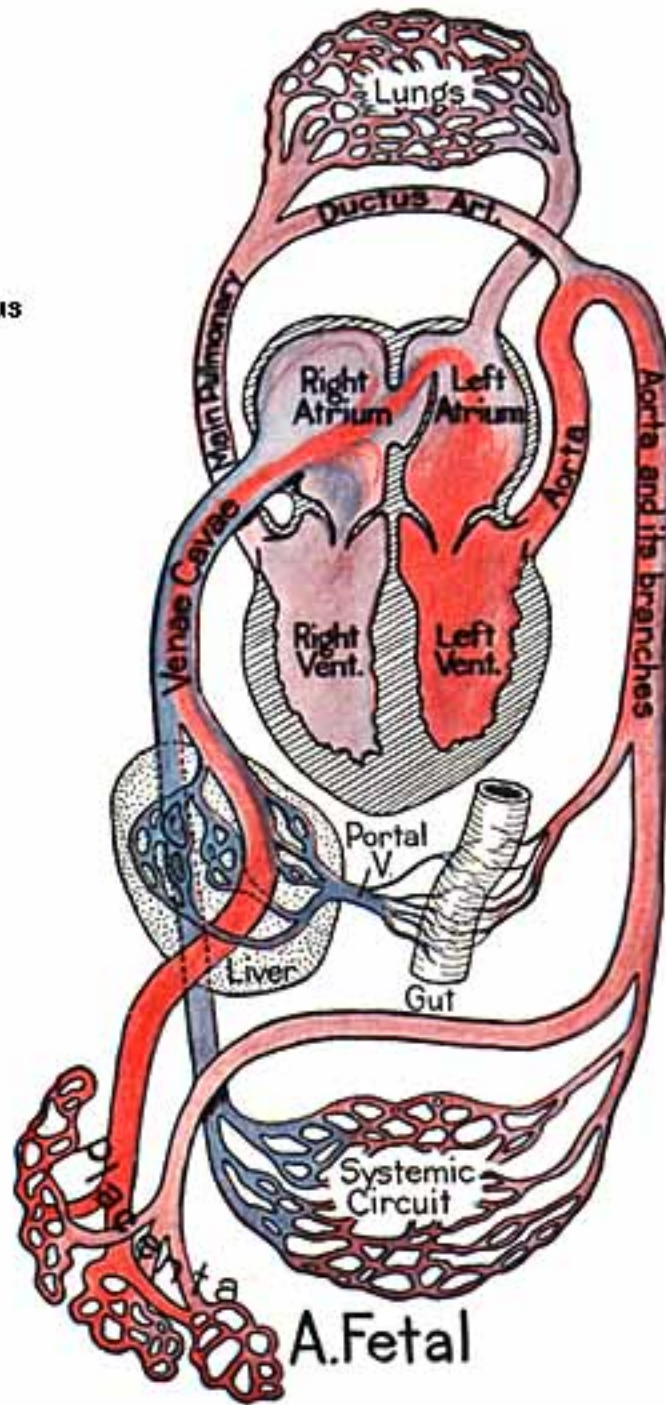
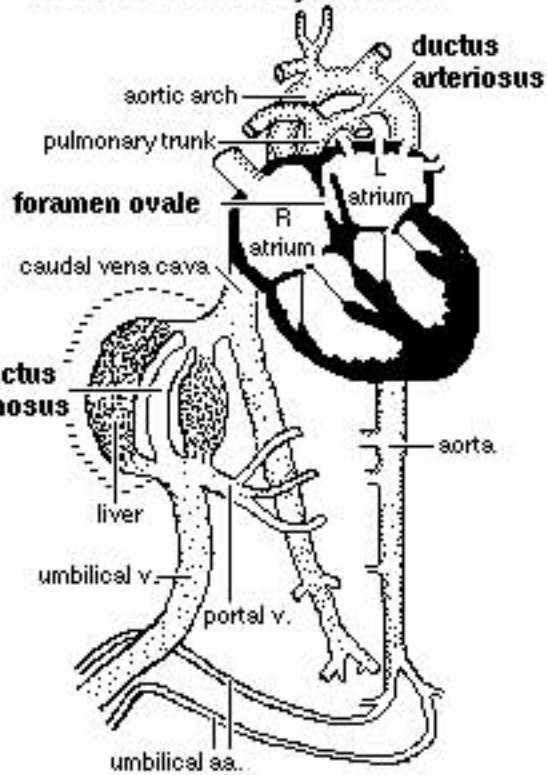
Stretching and constriction of umbilical arteries shifts fetal blood flow from the placenta to the fetus. Reduced venous return through the (left) umbilical vein and ductus venosus allows the latter to gradually close (over a period of days).


Bradykinin released by expanding lungs and increased oxygen concentration in blood triggers constriction of the ductus arteriosus which, over two months, is gradually converted to a fibrous structure, the ligamentum arteriosum.

The increased blood flow to the lungs and then to the left atrium equalizes pressure in the two atria, resulting in closure of the foramen ovale that eventually grows permanent.



Three In-Utero Adjustments





EMBRYONIC

NORMAL

ANOMALOUS

