

2013

Veterinary
Developmental Anatomy

(Veterinary Embryology)

CVM 6903

by

Thomas F. Fletcher, DVM, PhD

and

Alvin F. Weber, DVM, PhD

CONTENTS

Early Embryogenesis	3
Musculo-Skeletal Development	16
Serous Body Cavities	23
Cardiovascular System	25
Digestive System	32
Respiratory System	38
Urinary System	41
Genital System	44
Pharynx, Face, Nasal Cavity & Mouth.....	49
Nervous System & Special Senses	56
Appendix I. Gametogenesis	69
Appendix II. Mitosis and Meiosis	71
Appendix III. List of Anomalies	75

Early Embryogenesis

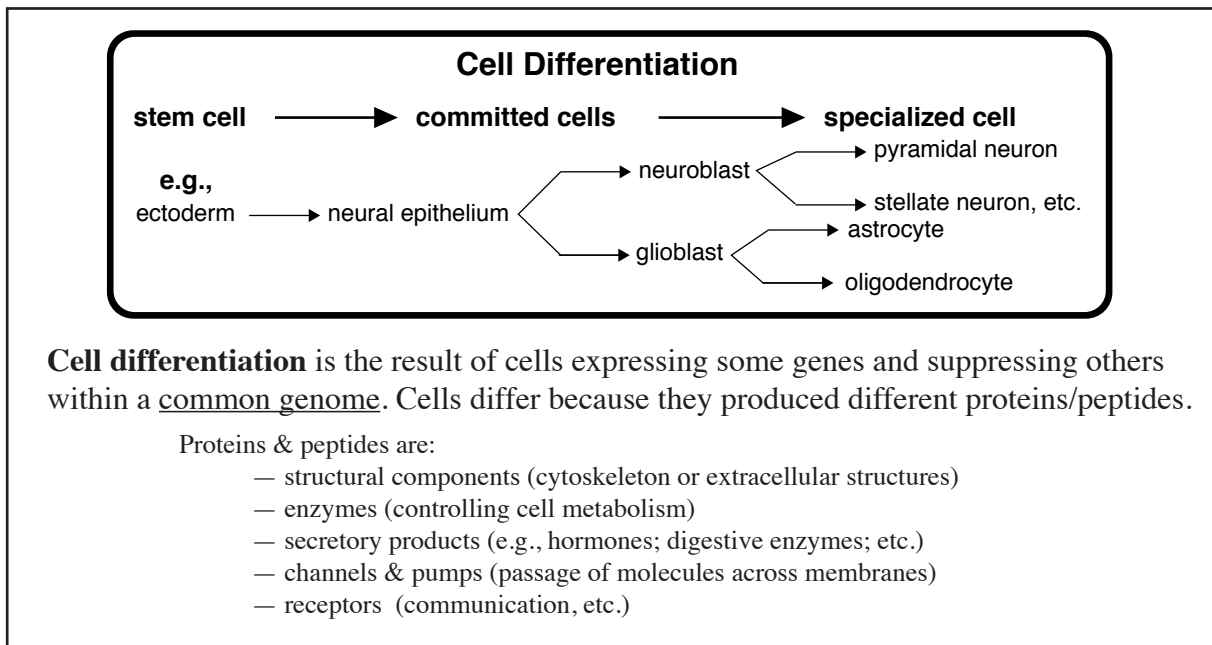
Embryogenesis:

- formation of body structures & organs (organogenesis)
- requires cell division (proliferation) and cell differentiation (specialization)
- produces the great variety of cell types and extracellular products found in the body.

Cell specialization:

— selective gene expression (and resultant protein production) is the ultimate explanation for the cell differentiation process during embryogenesis.

— genetic expression by a particular cell depends on the cell's previous genetic history (commitment lineage) and its current cellular environment (intercellular communications).



Periods:

Embryonic Period — defined as the time from fertilization to the earliest (primordial) stages of organ development (about 30 days in dog, cat, sheep, pig; almost 60 days in horse, cattle, human).

Fetal Period — the time between the embryonic period and parturition (the end of gestation), during which organs grow and begin to function.

Fertilization:

- union of a haploid oocyte and a haploid spermatozoon, producing a diploid zygote (a pluripotent cell capable of developing into a new individual)
- fertilization begins with gamete fusion (zygote formation)
- fertilization ends with the initiation of zygote cell division (the start of cleavage)

Fertilization related details:

- fusion of a spermatozoon with an oocyte takes place in the uterine tube, near the ovary
- the spermatozoon must bind to a specific glycoprotein on the zona pellucida surrounding the oocyte [this species recognition process prevents union with foreign sperm];

- then the spermatozoon releases degradative enzymes (acrosomal reaction) [the enzymes denature the zona pellucida, allowing the sperm cell to penetrate the barrier]
- spermatozoon and oocyte plasma membranes fuse (secondary oocyte completes meiosis)
- the oocyte immediately cancels its membrane potential (via Ca^{++} influx) and then denatures its zona pellucida (via enzymes are released by exocytosis from oocyte cytoplasmic granules) [this prevents fusion by additional sperm]
- male & female haploid pronuclei make contact, lose their nuclear membranes, and begin mitosis (mitosis begins 12 hours after sperm fusion; DNA synthesis takes place before mitosis)

Oocyte (enveloped by a zona pellucida (glycoprotein membrane) and corona radiata (granulosa cells) at ovulation)

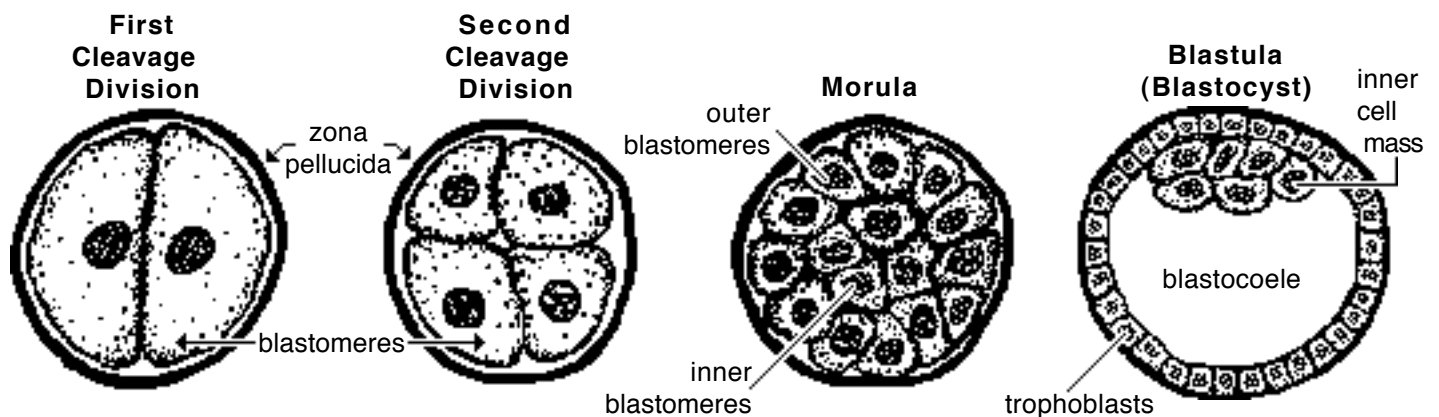
- selective follicles mature at each cycle (in response to circulating FSH hormone from the pituitary)
- oogonia (germ cells) give rise to primary oocytes by mitosis within the embryo
- primary oocytes initiate Meiosis I (reduction division) within the embryo and only resume Meiosis I following ovulation (being suspended in Meiosis I by inhibitory secretion of follicle granulosa cells)
- secondary oocytes complete meiosis (Meiosis II) following fertilization (if unfertilized they degenerate), producing a fertilized oocyte (ovum).

Spermatozoa (several hundred million per ejaculate)

- propelled from vagina to uterine tube by contraction of female genital tract
- spermatogonia (germ cells) give rise to primary spermatocytes by mitosis repetitively following puberty
- primary spermatocytes undergo Meiosis I (reduction division) producing secondary spermatocytes
- secondary spermatocytes complete meiosis (Meiosis II), producing spermatids that undergo transformation into spermatozoa (spermiogenesis)
- subsequently, spermatozoa undergo capacitation (removal of surface proteins that would impede contact with an oocyte)

Cleavage:

- refers to the initial series of mitotic divisions by which the large zygote is fractionated into numerous “normal size” cells.
- each daughter cell of the cleavage process is termed a *blastomere*.
- cleavage begins with a *zygote*, progresses through compaction to a *morula* stage and terminates at the start of the *blastocyst* (blastula) stage
- the first eight blastomeres are undifferentiated and have identical potential in mammals; thereafter, blastomeres differentiate into inner & outer cells with different missions



Note: The first cleavage division occurs 1 to 5 days following ovulation (depending on species), thereafter cells divide about once every 12 hours; As many as eight generations of mitoses may occur without intervening cell growth (cytoplasmic increase). Thus, e.g., one 150 micron diameter zygote can become a collection of 256 cells, each about 7 microns in diameter.

Morula [L.= small mulberry]

- a solid ball of blastomeres within a zona pellucida (typically consisting of 16 to 64 blastomeres)
- blastomeres become compacted; cells on the inside differentiate from those along the surface of the morula:
- *outer blastomeres* become flattened and form tight junctions (reducing fluid permeability); they develop the capacity to secrete fluid (internally); they are destined to become **trophoblasts** which form the chorion & amnion (fetal membranes) of the conceptus;
- *inner blastomeres* form gap junctions to maximize intercellular communication; they are destined to become **inner cell mass** which forms the embryo itself (plus two fetal membranes).

- Note:**
- As few as three inner blastomeres are sufficient to produce an entire embryo (and adult).
 - When a morula leaves the uterine tube and enters the uterus (uterine horn) it is at about the 16-cell stage, around 4 to 7 days after fertilization (depending on species).
 - The 32-cell stage morula (5-7 days post ovulation) is ideal for embryo transfer in cattle.

Blastocyst (or Blastula)

- develops during the second week, after the zona pellucida ruptures
- consists of a large number of blastomeres arranged to form a hollow, fluid-filled, spherical or cylindrical structure
- contains an **inner cell mass** (embryoblast), evident as a collection of cells localized inside one polar end of the blastula
- surface cells of the blastocyst are designated **trophoblasts** (future chorion of the conceptus)
- the cavity of the blastocyst is called a **blastocoele**
- eventually the blastocyst attaches to or implants within the uterine wall (pending species).

Cleavage in fish, reptiles, and birds:

Large quantities of yolk impede cell division during cleavage. Thus a *blastodisc* (rather than a spherical or elliptical *blastocyst*) is formed at the animal pole of the egg.

A *telolecithal ovum* (egg with large amounts of asymmetrically distributed yolk) has an *animal pole* where the nucleus is located and an opposite *vegetal pole* where yolk is concentrated. Cleavage is partial (meroblastic): cells divide more rapidly at the animal pole than at the vegetal pole, resulting in many, small blastomeres at the animal pole and a few, large macromeres at the vegetal pole.

In contrast, mammalian ovum has meager amounts of yolk (oligolecithal ovum) which is uniformly distributed (isolecithal). Cleavage is holoblastic (total) and each blastomere division produces two equal-size daughter cells. Thus animal and vegetal poles are not evident in mammalian ova.

TWINS

Monozygotic: identical (same genetic composition) twins can result from either:

- 1] separation of early blastomeres (up to the 8-cell stage)—each of the separate blastomere(s) develops into an independent conceptus; or
- 2] separation of inner blastomeres within a single morula—each of the separate blastomere(s) develops into an independent embryo and both embryos share a common placenta (this is less common than the first possibility).

Note: Separations later in embryonic development result in conjoined twins (diplopagus; Siamese twins), or double heads, etc. types of anomalies.

Dizygotic: fraternal twins result when two zygotes develop “independently” during the same pregnancy (independence can be compromised by fusion of fetal membranes and blood supplies). It is possible for fraternal blastomeres to merge and produce a single conceptus with two different genotypes (a chimera).

GERM LAYERS

Ectoderm, **mesoderm** and **endoderm** are designated *primary germ layers* because origins of all organs can be traced back to these three layers.

Ectoderm forms epidermis of the skin, epithelium of the oral and nasal cavities, and the nervous system and sense organs.

Mesoderm forms muscle and connective tissue, including bone, and components of the circulatory, urinary and genital systems.

Endoderm forms mucosal epithelium and glands of respiratory and digestive systems.

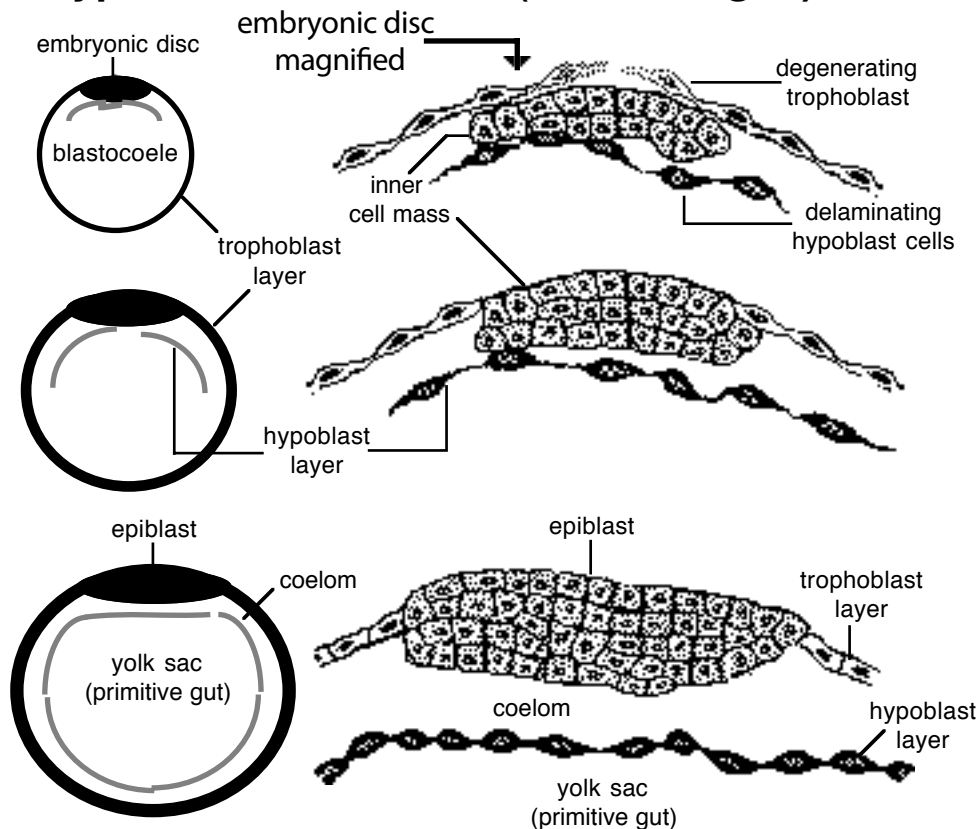
Gastrulation:

The morphogenic process that gives rise to three germ layers: **ectoderm**, **mesoderm**, and **endoderm**. (In some species, evidence of primitive gut formation can be seen [*gastrula* Gr.= little stomach] .)

Gastrulation includes the following sequence, beginning with a blastocyst:

- A thickened embryonic disc becomes evident at the blastocyst surface, due to cell proliferation of the inner cell mass cells. Trophoblast cells overlaying the inner cell mass degenerate in domestic mammals (in the mouse and human, trophoblast cells overlaying the inner cell mass separate and, instead of degenerating, become amnionic wall.)
- From the inner cell mass, cells proliferate, break loose (delaminate), and migrate to form a new cell layer inside the trophoblast layer. The new layer of cells, called the *hypoblast*, will form a yolk sac. The remaining inner cell mass may be called the *epiblast*.
- On the epiblast surface, a **primitive streak** forms as differential cell growth generates a pair of ridges separated by a depression. [NOTE: The primitive streak defines the longitudinal axis of the embryo and indicates the start of germ layer formation.]

Hypoblast Formation (three stages)



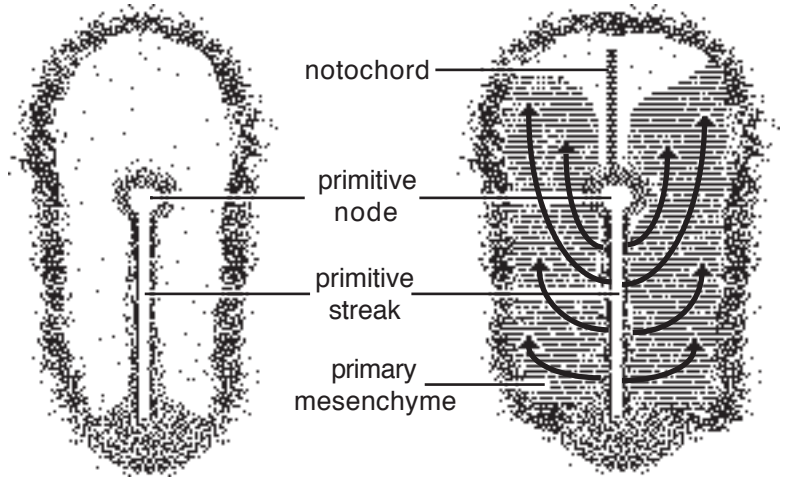
- Deep to the primitive streak, a space (**coelom/celom**) becomes evident between the hypoblast layer and epiblast. Subsequently, the coelom is filled by mesoderm that undergoes cavitation and gives rise to body cavities.

- Epiblast cells proliferate along primitive streak margins and migrate through the streak into the coelom. The migrating cells form endoderm & mesoderm layers.

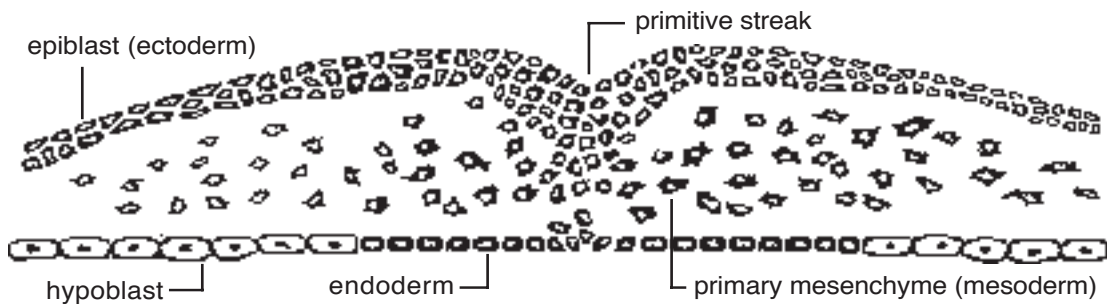
- Initial migrating cells join the hypoblast layer, forming embryonic **endoderm** (hypoblast cells constitutes yolk sac endoderm).

- The majority of migrating cells enter the coelom as primary mesenchyme and become **mesoderm**. The primary mesenchyme migrates laterally and cranially (but not along the midline region directly cranial to the primitive streak where notochord will form). Note: Mesoderm divides into: paraxial, intermediate, and lateral mesodermal regions.

Dorsal View of Embryonic Disc

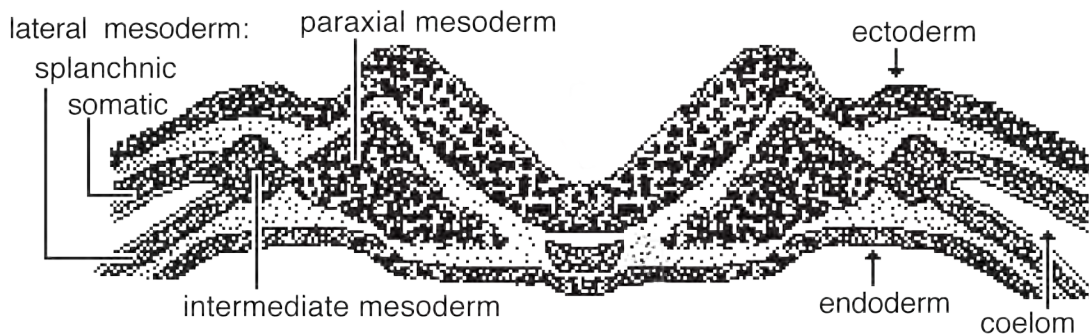


NOTE: Arrows indicate the spread of primary mesenchyme through the primitive streak and between the epiblast and hypoblast



- Within the lateral mesoderm, cavitation re-establishes a coelom (horseshoe-shaped). The mesoderm splits into two layers bordering the coelom—*somatic mesoderm* is attached to the ectoderm and *splanchnic mesoderm* is joined to endoderm.

- The remaining epiblast becomes **ectoderm** which forms skin epidermis & nervous system.



NOTE:

Mesoderm can exist in two morphologic forms: mesenchyme and epithelioid:

Mesenchyme features aggregates of stellate cells within an abundant extracellular matrix composed of fluid and macromolecules (polymers).

Epithelioid refers to organized cells having distinct apical and basal surfaces; the latter commonly rests on a basal lamina produced by epithelioid secretion.

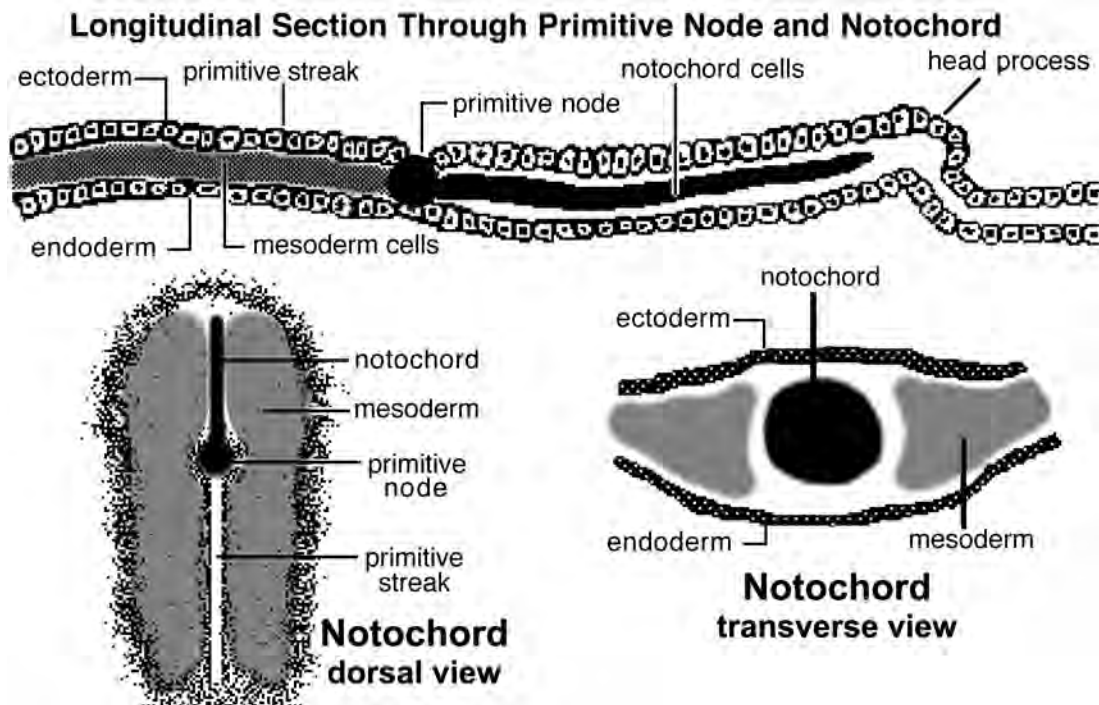
Mesoderm can transform from a mesenchyme to epithelioid and vice versa: The mesoderm that streams through the primitive streak is *primary mesenchyme*. Somatic, splanchnic, and somite mesoderm can be temporarily epithelioid. The temporary epithelioid transforms to a *secondary mesenchyme* which ultimately forms muscle and connective tissue (including cartilage, bone, ligaments, tendons, dermis, fascia, and adipose tissue).

Thus, the term “mesenchyme” refers to the morphologic appearance of embryonic tissue. Although most mesenchyme is mesoderm, the other germ layers can also form mesenchyme, e.g., ectomesenchyme from neural crest ectoderm.

Formation of the Notochord:

- The **notochord** is a rod-shaped aggregate of cells located between ectoderm and endoderm anterior to the primitive streak of the embryo. It occupies the midline coelomic space that was not invaded by migrating primary mesenchyme.
- The notochord is important because it induces:
 - formation of the head process,
 - development of the nervous system, and
 - formation of somites
- The notochord marks the future location of the vertebral column and the base of the cranium.
- The ultimate fate of the notochord is to become nucleus pulposus of intervertebral discs.

Note: The notochord develops from the *primitive node* located at the cranial end of the primitive streak. From the node, mesoderm-forming cells proliferate and migrate forward into the future head region where they become the rod-shaped notochord.



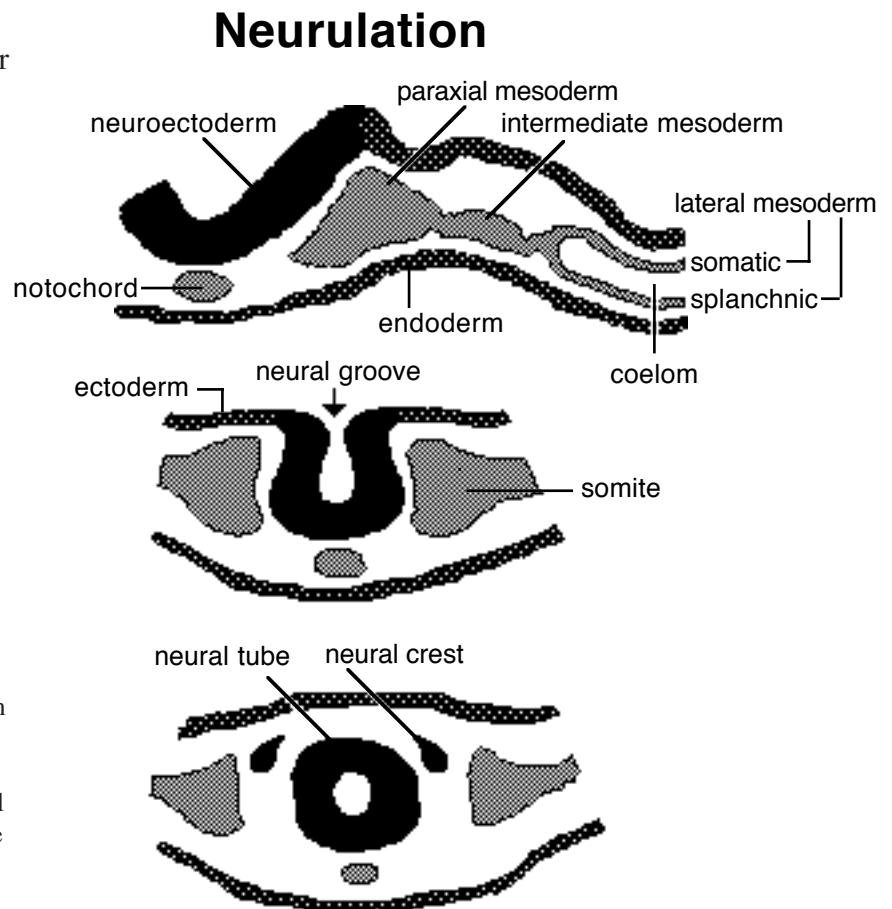
Note: Each organ system has a critical period during development when it is most sensitive to external agents (teratogens) that produce birth defects.

Early Formation of the Nervous System (Neurulation):

Neurulation refers to notochord-induced transformation of ectoderm into nervous tissue. The process begins during the third week in the region of the future brain and then progresses caudally into the region of the future spinal cord.

The neurulation process involves the following steps:

- ectodermal cells overlaying the notochord become tall columnar (neuroectoderm); they form a thickened area designated the *neural plate*. The other ectodermal epithelium is flattened.
- a *neural groove* is formed as edges of the neural plate become raised on each side of a midline depression. (Apical ends of individual neuroectodermal cells constrict.)
- a *neural tube* is then formed as the neural groove undergoes midline merger of its dorsal edges. The tube separates from non-neural ectoderm which unites dorsal to it. (Tube formation begins in the cranial cervical region of the central nervous system and progresses cranially and caudally until *anterior* and *posterior neuropores*, the last openings, finally close.)
- bilaterally, where the neural groove is joined to non-neural ectoderm, cells detach as the neural groove closes; the cells proliferate and assume a position dorsolateral to the neural tube—forming *neural crest*.



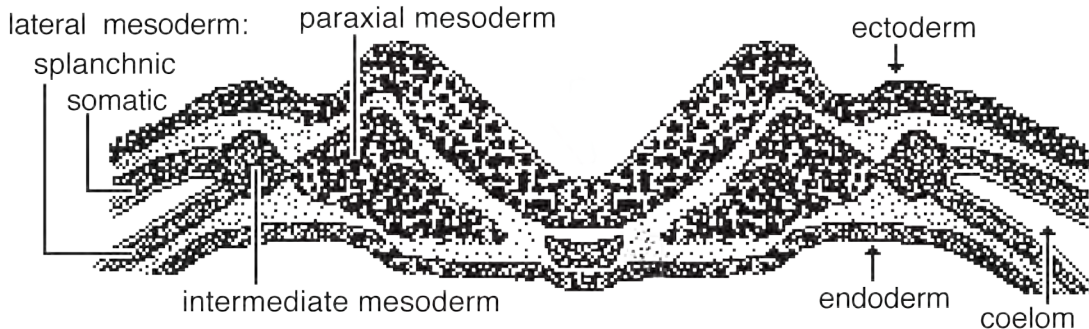
NOTE:

Neural tube becomes the central nervous system, i.e., the brain and spinal cord.

Neural crest cells are remarkable for the range of structures they form. Some cells migrate dorsally and become pigment cells in skin. Other cells migrate ventrally and become neurons and glial cells of the peripheral nervous system, or adrenal medulla cells. In the head, neural crest forms mesenchyme (ectomesenchyme) which becomes meninges, bone, fascia, and teeth.

Somites:

- Mesoderm blocks located just lateral to the notochord, which induced somite development.
- A pair of somites develops for every vertebra, plus a half dozen somite pairs in the head.
- Number of somites in an embryo is indicative of age, individual somites develop chronologically, in craniocaudal order.



Somites develop as follows:

- mesoderm, designated *paraxial mesoderm*, accumulates on each side of the notochord
- progressing from rostral to caudal over time, transverse fissures divide the paraxial mesoderm into blocks
- each block becomes a **somite** (epithelioid cells within a somite block re-orient 90°, from transverse to the notochord to longitudinal)
- head (occipital) somites develop from proliferation of local mesenchyme lateral to the cranial end of the notochord
- rostral to the notochord, mesenchyme forms less-developed somites, called *somitomeres*; these migrate into pharyngeal arches and form muscles of the jaw, face, pharynx, & larynx.

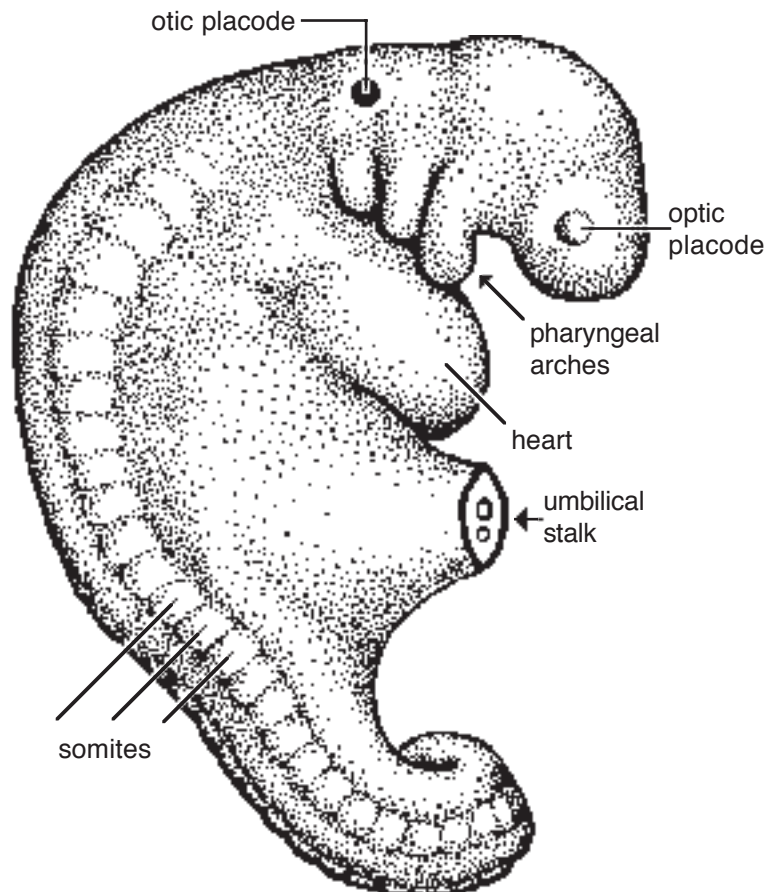
NOTE:

Each somite differentiates into three regions:

Sclerotome (ventromedial region) gives rise to vertebrae, ribs, and endochondral bones at the base of the skull.

Dermatome (lateral region) gives rise to the dermis of skin

Myotome (intermediate region) gives rise to skeletal muscles of the body



Development of a Cylindrical Body:

The early embryo is flat, but the vertebrate body plan features a cylindrical theme—various cylindrical structures (derivatives of the gut, neural tube, notochord, etc.) enclosed within a cylindrical body. Transition from a flat embryo to a cylindrical one involves the following developments:

Head Process Formation:

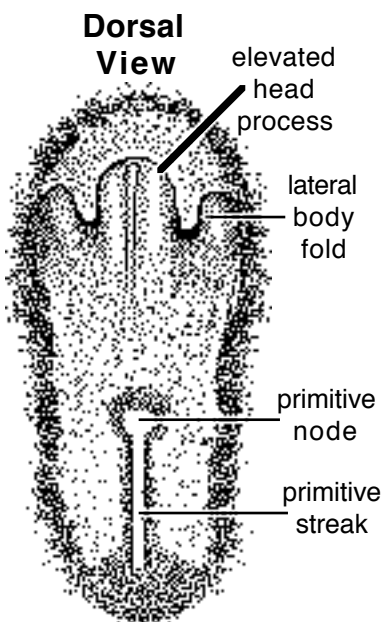
- The cranial end of the embryo grows dorsally and forward so that it projects above the region originally in front of the embryo.
- The cylindrical head process elongates by additional growth from its base (located in front of the primitive node). Consequently, the most anterior part of the embryo is the oldest. The elongation incorporates the most anterior half-dozen somites into the future head.
- Within the head process, endoderm is reflected ventrally upon itself, forming a blind-ended *foregut* (future pharynx).

Tail Fold Formation:

- At the caudal end of the embryo, a cylindrical tail fold is formed in a manner similar to that of the head process.
- Folded endoderm encloses a blind *hindgut*.

Lateral Body Folds:

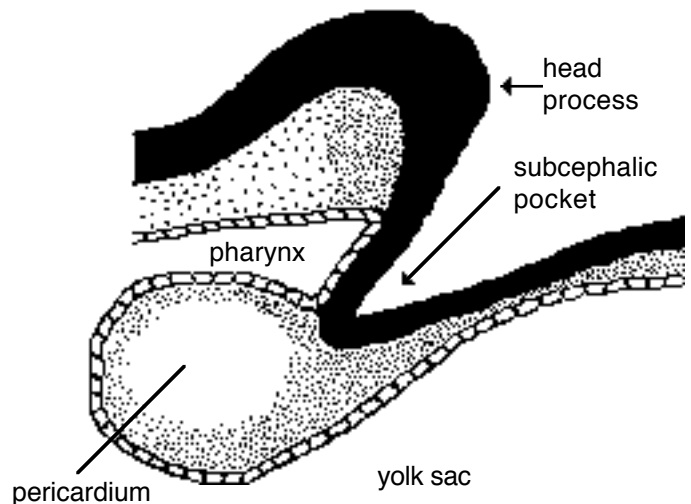
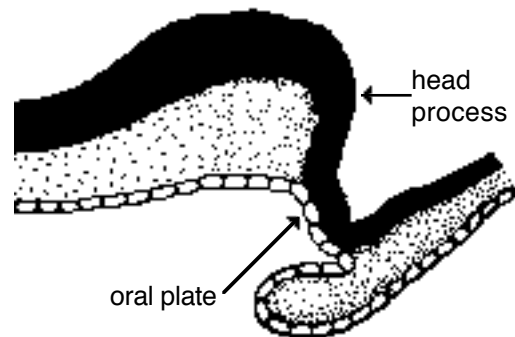
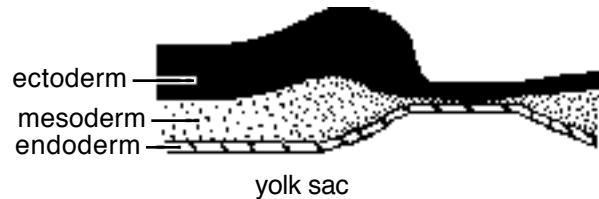
As the head process elongates upward & forward, a subcephalic pocket (space) is formed ventral to the head process, between the head process and extra-embryonic tissue. The bilateral margins of this pocket are lateral body folds—



which constitute the continuity between the elevated embryo and the relatively flat extra-embryonic tissue.

- Similar folds exist caudally in association with the tail process.
- As the embryo grows and is elevated dorsally, lateral body folds adduct and join together ventrally, establishing a tubular embryo separated from flattened extra-embryonic tissue.
- Progressing caudally from the head process and cranially from the tail fold, ventral fusion of lateral body folds stops at the *umbilicus*—leaving a ventral opening in the body wall that allows vessels and the yolk sac and allantois to enter the embryo (and communicate with the gut).

Three Stages of Head Process Formation (longitudinal views)

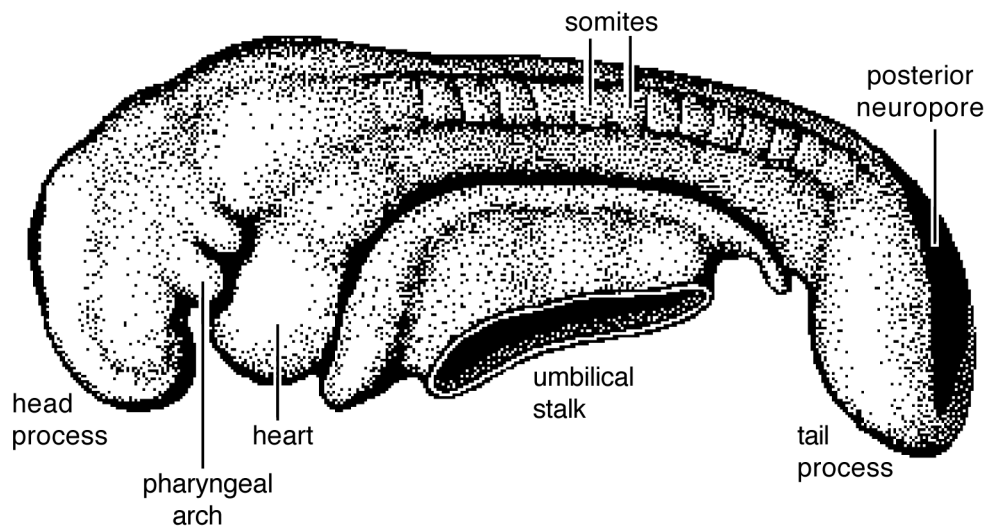
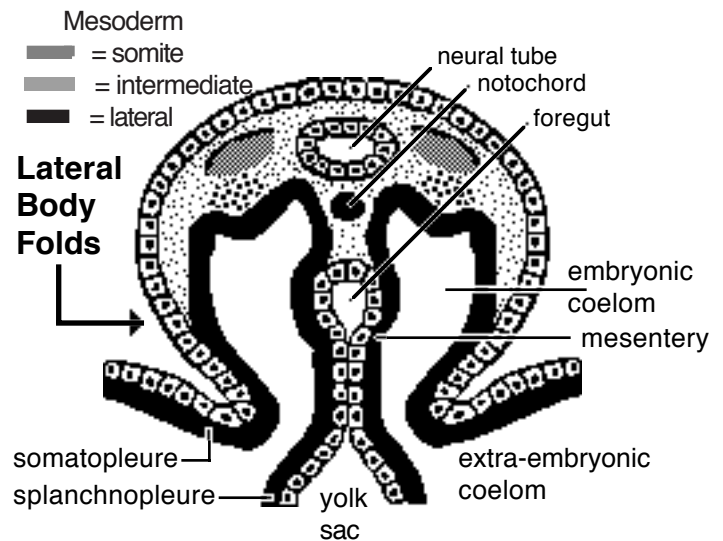


- Ventral fusion of lateral body folds distinguishes the embryo from extra-embryonic tissue (fetal membranes):

- embryonic coelom (future body cavities of the trunk) is distinguished from extra-embryonic coelom within fetal membranes.

- somatopleure (somatic mesoderm + ectoderm) that forms body wall is distinguished from that forming fetal membranes (chorion and amnion).

- splanchnopleure (splanchnic mesoderm + endoderm) merges bilaterally to form gut and mesentery, differentiated from extra-embryonic yolk sac (and allantois).

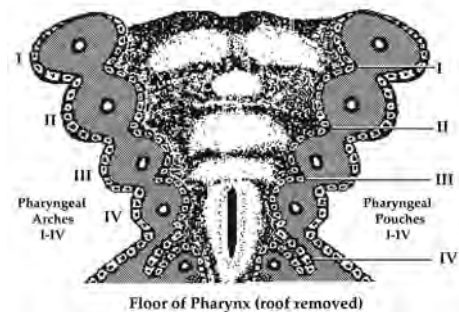


Pharyngeal Arches:

In the head region, dorso-ventral arches demarcated by grooves (clefts) appear. The arches are called *pharyngeal arches* and they are bounded internally by *pharyngeal pouches*.

Each arch contains a vessel (aortic arch). Within each arch, ectomesenchyme (derived from neural crest) gives rise to bone and fascia. Myotomes of somitomers migrate to pharyngeal arches to provide skeletal musculature. Each arch is innervated by one cranial nerve.

Only the first three *pharyngeal arches* are externally evident in mammals. The first arch develops into upper and lower jaws and muscles of mastication. The second gives rise to hyoid bones and muscles of the face. The remaining pharyngeal arches form hyoid bones, larynx and associated muscles. Each arch is innervated by a particular cranial nerve.



The pharynx (foregut) develops five bilateral diverticula that internally demarcate the pharyngeal arches. These *pharyngeal pouches* develop into auditory tube, parathyroid glands, thymus, etc.

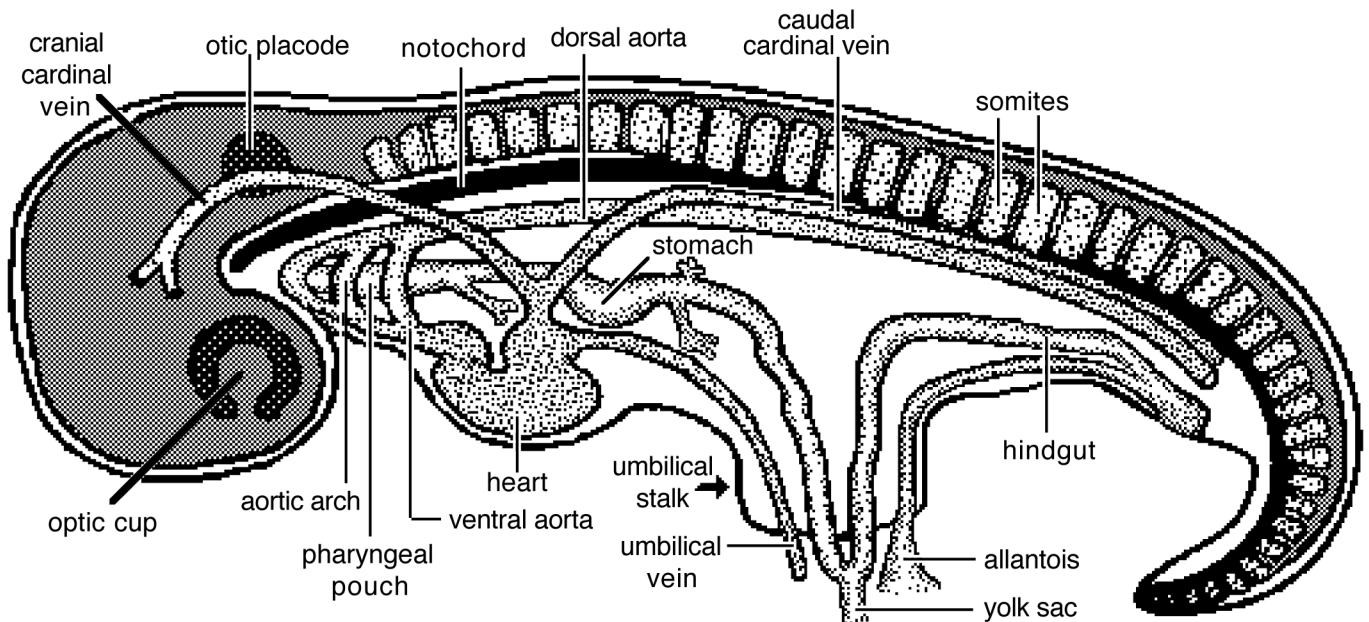
NOTE: In fish, five or six branchial [Gr. = gill] arches are well developed. Cells degenerate where branchial clefts and pharyngeal pouches meet so that the pharynx communicates with the outside (this occurs only temporarily between the first two arches in mammals). The first arch forms the jaw apparatus and the rest form gill arches separated by gill slits.

Flexures:

The tube-shaped embryo undergoes three flexures that make it C-shaped. The first occurs in the future midbrain region, the second in the future neck region, and the third occurs in the tail region.

Cardiovascular system:

- The cardiovascular system develops early (in the third week after the start of the nervous system), as the embryo enlarges and diffusion alone becomes inadequate for tissue preservation.
- Angiogenesis (formation of blood vessels) begins in splanchnic mesoderm of the yolk sac, in the form of blood islands composed of mesenchyme and hemocytoblasts. The latter forms blood cells and the mesenchyme forms vesicles lined by endothelium. The vesicles coalesce to form vascular channels and then blood vessels (the latter are formed by budding, fusion, & enlargement).
- Vessels are formed first in extra-embryonic tissue: vitelline (yolk sac) and umbilical (allantoic) vessels appear first.
- Ventral to the pharynx, bilateral vessels merge to form a tubular heart; dorsal and ventral aortae are connected by aortic arches. Also, cranial and caudal cardinal veins return embryonic blood to the heart and umbilical veins return placental blood to the heart. None of these vessels will persist as such in the adult.

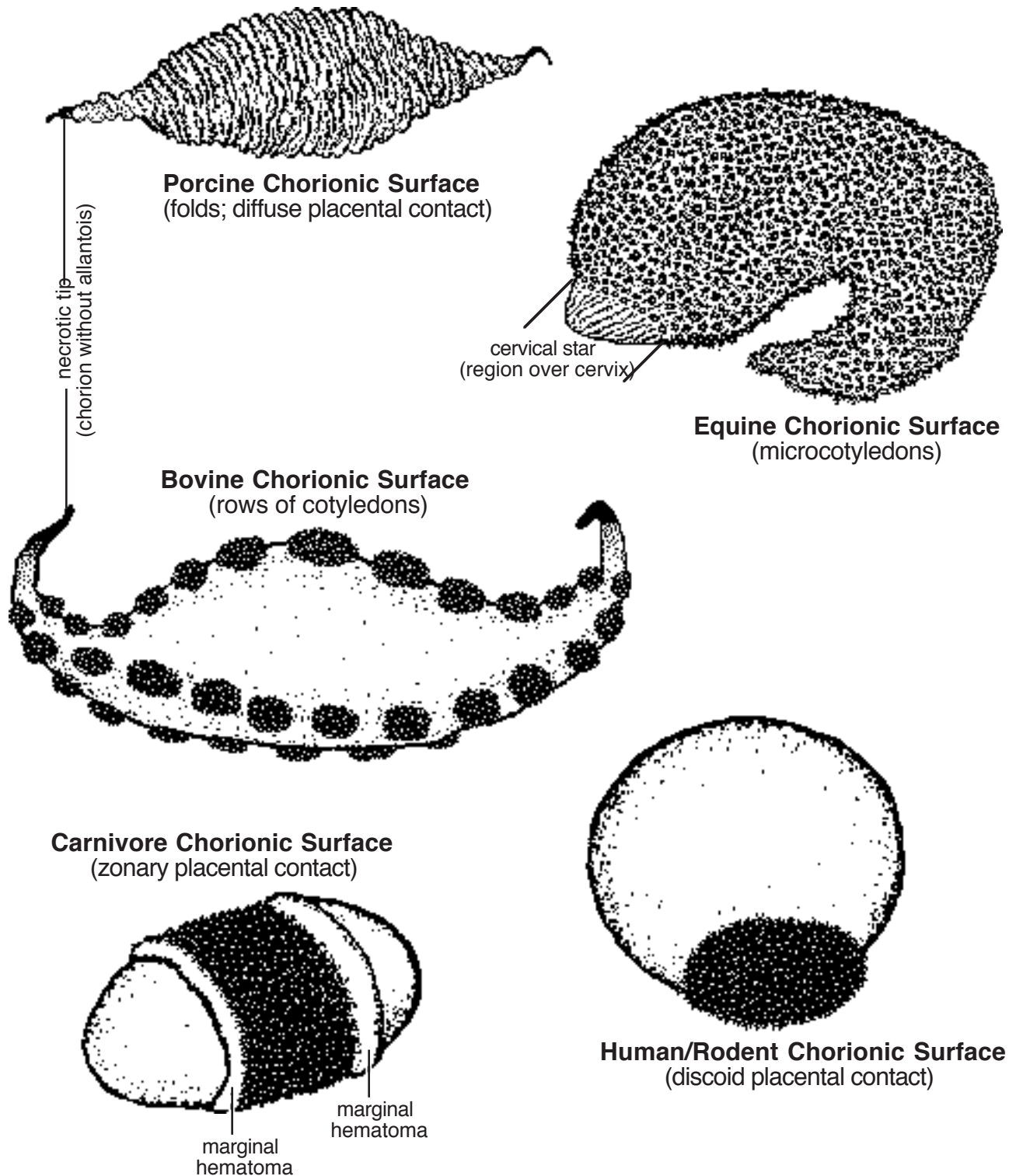


Placentation

Placenta = region(s) of apposition between uterine lining and fetal membranes where metabolites are exchanged for sustaining pregnancy.

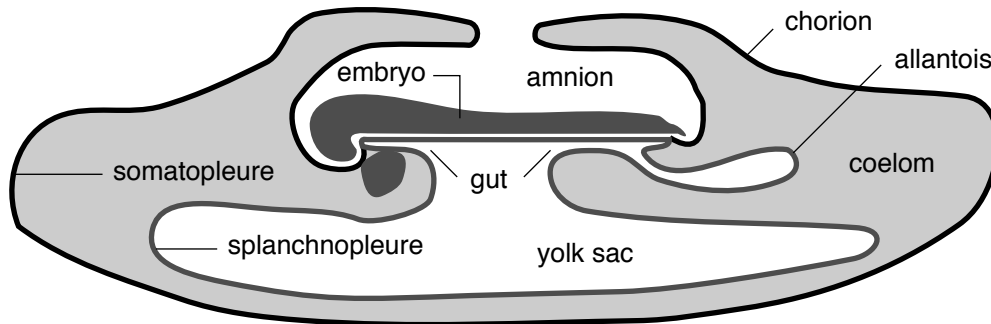
- Chorion forms the surface fetal membrane. Apposition areas (placental types) may be: *diffuse* (pig), *zonary* (carnivore), *discoid* (primates & rodents), or involve placentomes.
- A *placentome* is a discrete area of interdigitation between a maternal caruncle and a fetal cotyledon. Equine placentas are microcotyledonary (microplacentomes are distributed diffusely). Ruminant placentas consist of rows of relatively large placentomes.
- Placentas (placentae) may also be classified according to the tissue layers separating fetal and maternal blood. Uterine epithelium, uterine connective tissue and uterine endothelium may be eroded, giving rise to four placental types: epitheliochorial (swine, equine, cattle); synepitheliochorial, formerly called syndesmochorial, (sheep, goats); endothelial chorial (carnivore); and hemochorial (primates & rodents).

Fetal Components of Placentae



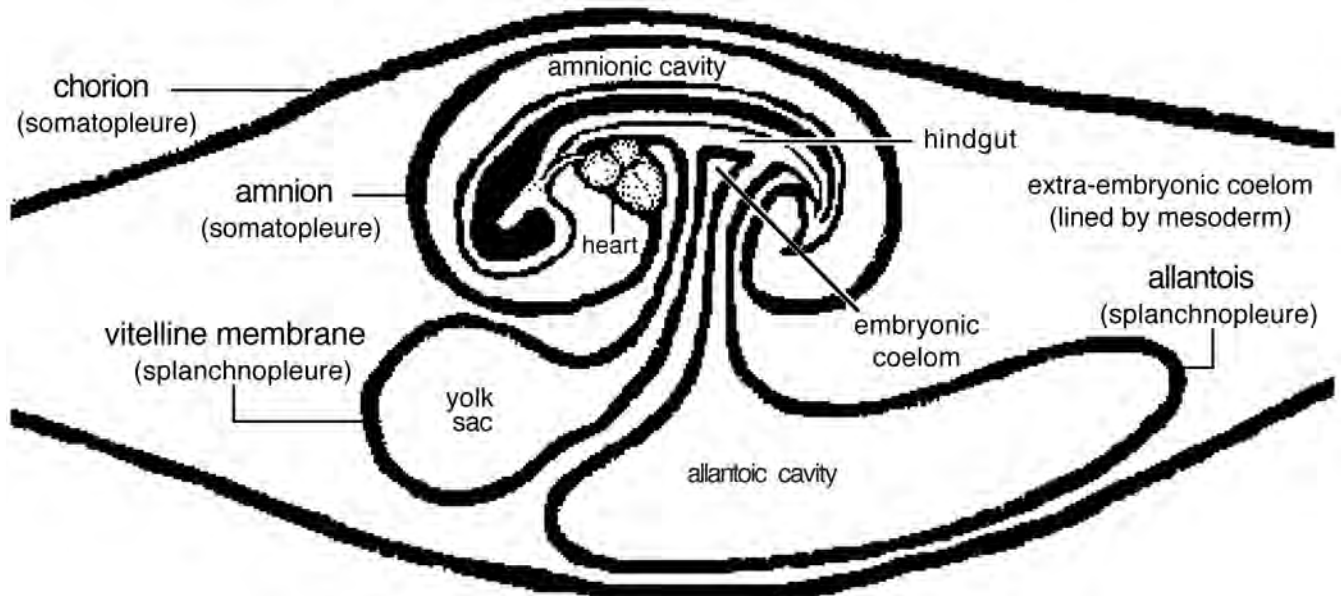
Fetal membranes:

Four fetal membranes develop in a conceptus. Two arise from the trophoblast layer of the blastocyst (and are continuous with the somatopleure of the embryo). Two arise from the inner cell mass of the blastocyst (and are continuous with splanchnopleure of the embryo); these two splanchnopleure membranes are vascular. The four fetal membranes are:



1. **Chorion** — forms the outer boundary of the entire conceptus (from trophoblast)
2. **Amnion** — encloses the embryo within a fluid-filled amniotic cavity; formed by folds of chorion in domestic mammals (in humans, amnion forms by cavitation deep to a persistent trophoblast).
3. **Allantois** — develops as an outgrowth of hindgut splanchnopleure (originates from inner cell mass). Allantois grows to fill the entire extra-embryonic coelom, with fluid-filled allantoic cavity in domestic mammals. The outer surface of allantois binds to the inner surface of chorion (and the outer surface of amnion). The allantois is highly vascular and provides the functional vessels of the placenta, via umbilical vessels.
4. **Yolk sac** — continuous with midgut splanchnopleure (develops early with hypoblast formation from inner cell mass). Supplied by vitelline vessels, it forms an early temporary placenta in the horse and dog. Yolk sac is most important in egg laying vertebrates.

Note: The term *conceptus* refers to the embryo or fetus plus its fetal membranes.



Implantation

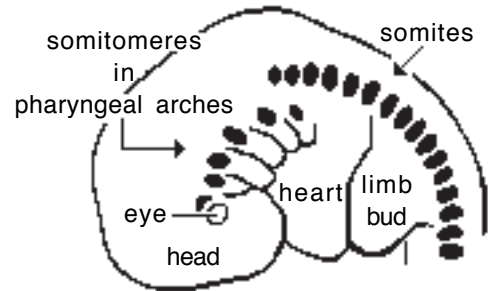
The blastocyst is initially free in the uterine lumen (nourished by uterine glands). Implantation of the blastocyst is a gradual process, beginning with apposition, leading to adhesion (or invasion in the case of the human & Guinea Pig).

Approximate implantation times are: one week (human); two weeks (dog, cat, sheep), 3-5 weeks (cattle), 3-8 weeks horse; or delayed up to 4 mons (deer, bears).

Musculo-Skeletal System (Trunk, Limbs, and Head)

General Statements:

- Mesoderm gives rise to skeletal muscle, skin dermis, endochondral bones and joints.
- Notochord induces paraxial mesoderm to form somites (somitomeres develop rostral to the notochord in the head).
- Each somite differentiates into three regions:
 - **sclerotome** (medial): forms most of the axial skeleton (vertebrae, ribs, and base of the skull).
 - **dermatome** (lateral): migrates to form dermis of the skin
 - **myotome** (middle): migrates to form skeletal muscles. Individual adult muscles are produced by merger of adjacent myotomes.



Somites & Somitomeres

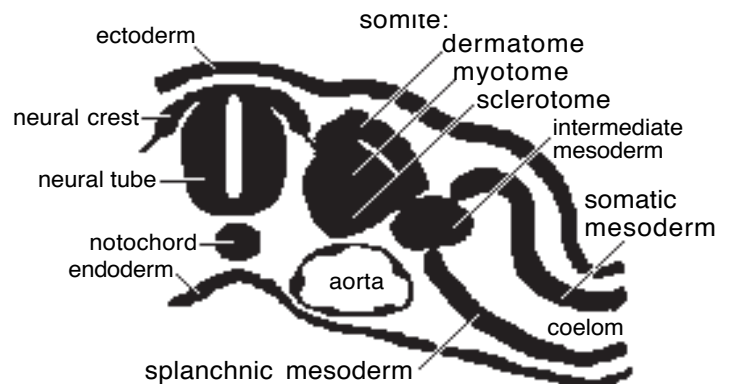
Note: Early in development, nerves make connections with adjacent myotomes and dermatomes, establishing a segmental innervation pattern. As myotome/dermatome cells migrate to assume adult positions, the segmental nerve supply must follow along to maintain its connection to the innervation target. (Recurrent laryngeal & phrenic nerves travel long distances because their targets migrated far away.)

Skin.

Consists of dermis and epidermis:

Epidermis, including hair follicles & glands, is derived from ectoderm. Neural crest cells migrate into epidermis and become *melanocytes*. (Other neural crest cells become tactile disc receptors.)

Dermis arises from dermatomes of somites. Adjacent dermatomes overlap; thus, each skin region is innervated by 2 or 3 spinal nerves.



Mesoderm Regions

Muscle.

All *skeletal muscle* is derived from paraxial mesoderm which forms *somites* and, rostrally in the head, *somitomeres*. (The one exception is iris musculature, derived from optic cup ectoderm.)

Cardiac and *smooth muscles* originate from splanchnic mesoderm.

Myotome cells differentiate into myoblasts which fuse to form multinucleate myocytes (muscle fibers). The myocytes synthesize myosin & actin (the myofilaments align producing a striated muscle appearance). Developing muscles and tendons must be under tension (stretched by growing bone) in order to grow to proper lengths.

Muscle development requires innervation. Muscles release trophic molecules that determine muscle cell type (I, IIa, IIb). Also, muscles release trophic molecules that affect nerve growth.

Note: Each anatomical muscle is genetically allocated a specific number of myoblasts that is determined by the time of birth. Thereafter, muscle cell growth is due solely to cellular hypertrophy. Regeneration (hyperplasia) of adult muscle cells does not occur.

Bone.

- Most bones are formed *endochondrally* (ossification of cartilage precursor)
- Bones of the calvaria (top of the skull) & face are formed *intramembranously* (osteoblasts arise directly from ectomesenchyme cells rather than from chondroblasts)

Embryologically, the skeleton originates from different sources:

- *paraxial mesoderm* forms sclerotomes that give rise endochondrally to axial skeleton
- *somatic mesoderm* forms endochondral appendicular bones per particular regions
- *ectomesenchyme* from neural crest forms intramembranous bones of the calvaria and face.

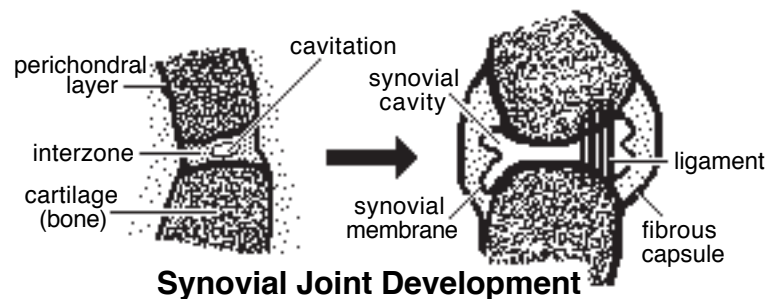
Endochondral bone formation:

- local mesenchyme undergoes condensation and cells differentiate into chondroblasts
- chondroblasts secrete matrix to produce a cartilage model of the future bone; the model is surrounded by perichondral fibrous tissue
- the diaphysis of the cartilage model undergoes ossification first (primary ossification); epiphyseal ossification occurs later (secondary ossification)
- physis ossification is postponed until bones stop growing in length.
- overall bone shape is genetically determined; surface irregularities of bone are acquired due to localized tension (stress) produced by ligaments and tendons.

Ligaments, Tendons & Fibrous Tissue originate from local mesenchyme or ectomesenchyme.

Joints.

- condensation of mesenchyme produces an *interzone* region within perichondral tissue connecting adjacent cartilage models of bones
- the interzone becomes fibrous connective tissue or fibrocartilage or a synovial cavity (according to the nature of the future joint)



Synovial joint formation:

- mesenchyme at the center of the interzone undergoes cavitation
- tissue bordering the cavity become *synovial membrane*, uneven expansion of the cavity creates synovial folds
- interzone mesenchyme also forms intra-articular ligaments where these are present
- perichondral tissue surrounding the interzone becomes *joint capsule* and localized thickenings of the joint capsule forms *ligaments*

Note:

Nerve driven muscle activity is essential for proper synovial joint development after the joint cavity is formed.

Joints must move during *in utero* and postnatal development to prevent ankylosis (fixed/frozen joint).

Also, muscles must be stretched by growing bones *in utero*; otherwise, joints would be restricted by contracted muscles at birth.

Regional Specifics

Trunk Region:

Skeletal Muscles.

- adjacent myotomes merge, forming broad muscles that are segmentally innervated (each myotome brings its own innervation when it overlaps with adjacent myotomes).
- myotome accumulations segregate into a dorsal mass (epimere) innervated by dorsal branches of spinal nerves and a ventral mass (hypomere) innervated by ventral branches of spinal nerves.
- epimere and hypomere masses subdivide, the epimere becomes *epaxial muscles* and the hypomere becomes *hypaxial muscles*.

Axial Skeleton.

- sclerotomes give rise to vertebrae and ribs.
- the sternum develops differently, from chondrification/ossification of local somatic mesenchyme of the ventral thorax.

Formation of Vertebrae and Ribs:

- somite sclerotomes migrate & become a continuous mass surrounding the notochord and neural tube. Thus the original somite segmentation is lost!
- the continuous mass differentiates into diffuse & dense regions per original sclerotome
- to produce a cartilage model of one vertebra, the diffuse region from one somite combines with the dense region of an adjacent somite
- intervertebral disc regions develop between newly formed vertebrae, sclerotome mesenchyme forms *annulus fibrosus* and notochord forms *nucleus pulposus* (elsewhere notochord degenerates)
- ribs develop as extensions of thoracic vertebrae processes

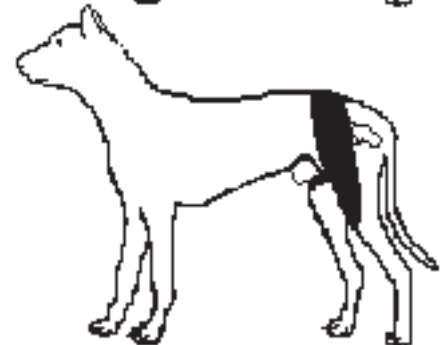
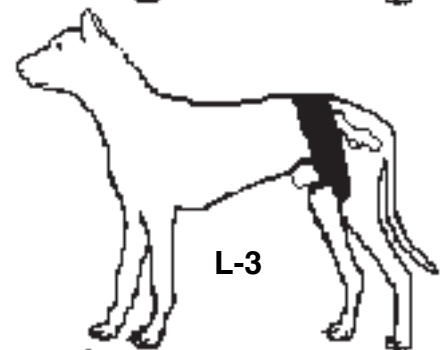
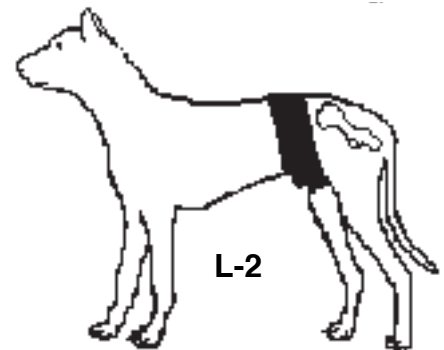
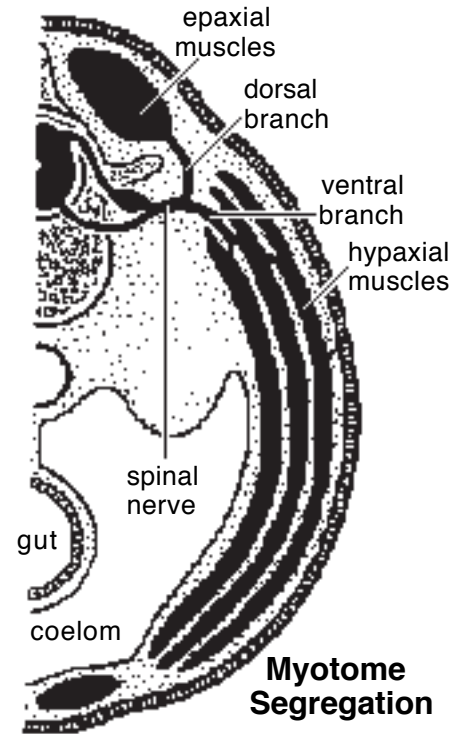
Note: As a result of the above re-segmentation, vertebrae are shifted relative to other segmental structures (see next page). Consequently, muscles span adjacent vertebrae; spinal nerves traverse intervertebral foramina (located dorsal to intervertebral discs); and embryonic intersegmental arteries become spinal arteries that run along side vertebral bodies.

The notochord, neural tube, and neural crest all play a role directing somite differentiation and vertebral segmentation (formation).

Vertebral anomalies include:

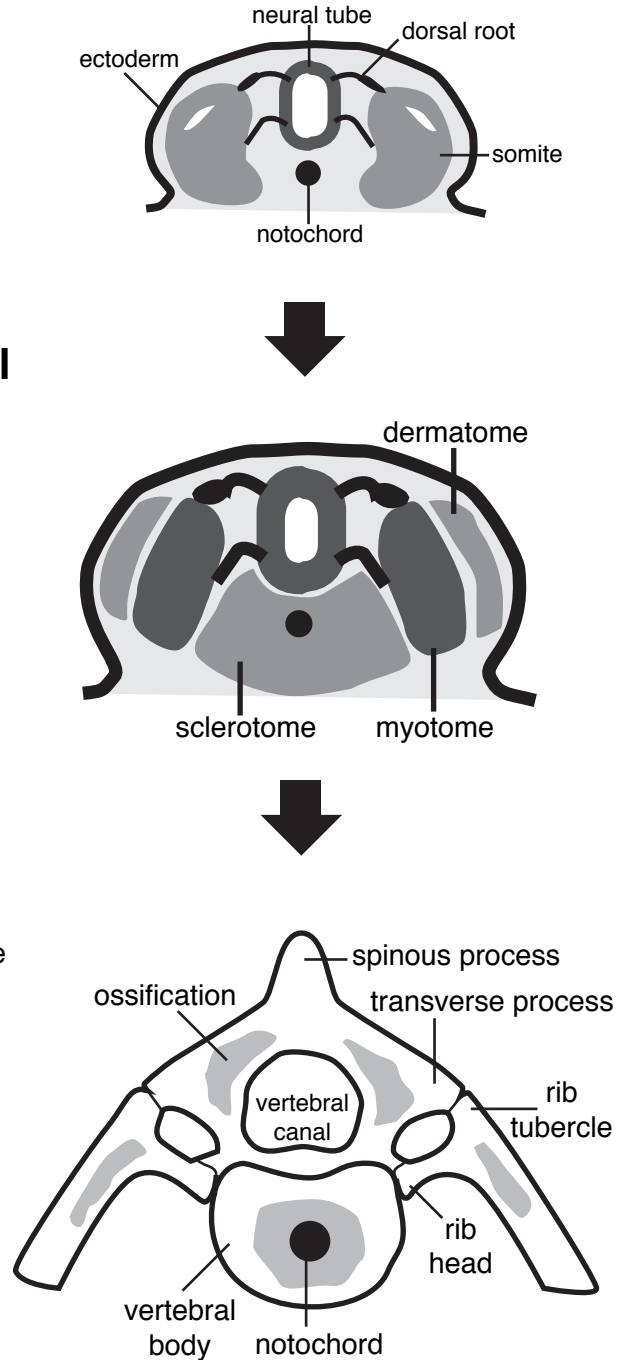
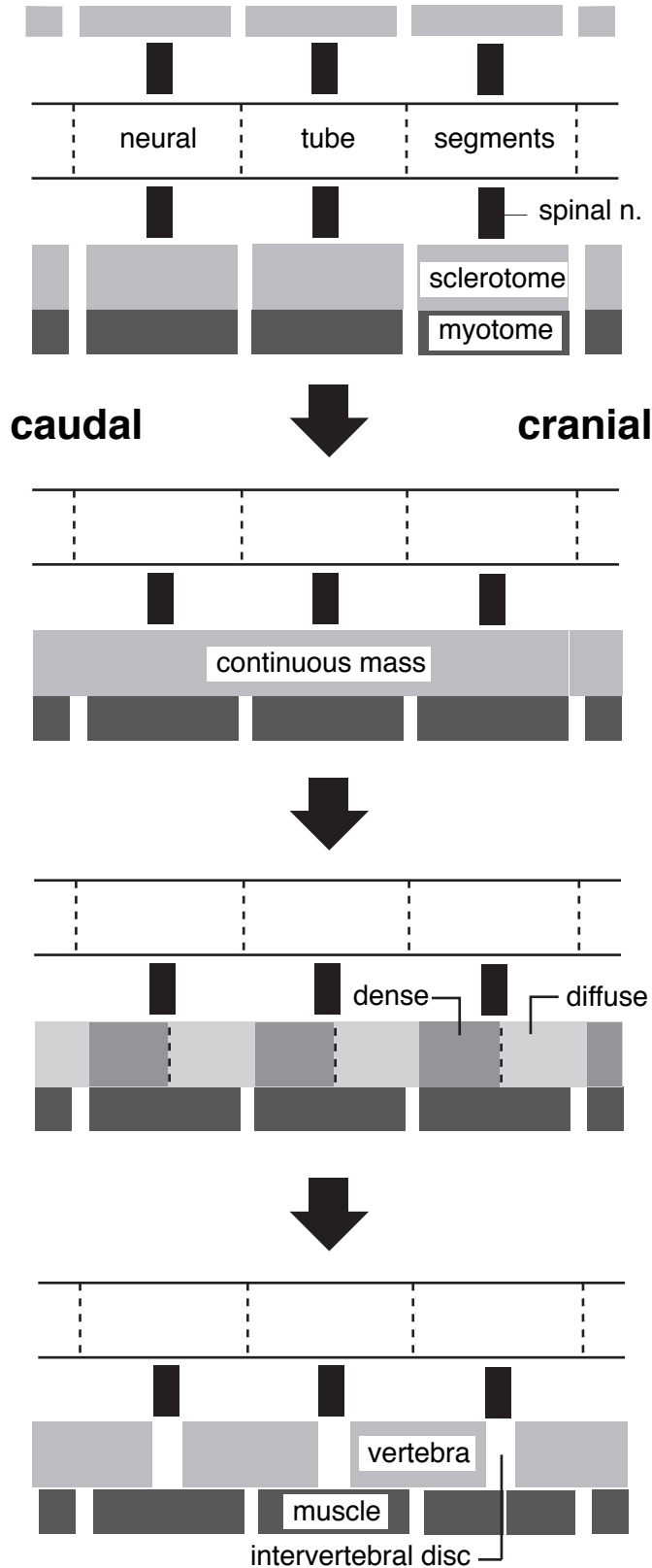
- stenosis of the vertebral canal;
- mal-articulation;
- hemivertebra; and
- spinal bifida (absent vertebral arch).

Note: The dens originates as the body of vertebra C₁ (atlas), but it fuses with vertebra C₂ (axis).



Canine Dermatomes

Sclerotomes to Vertebrae



Limbs:

Skeletal Muscles.

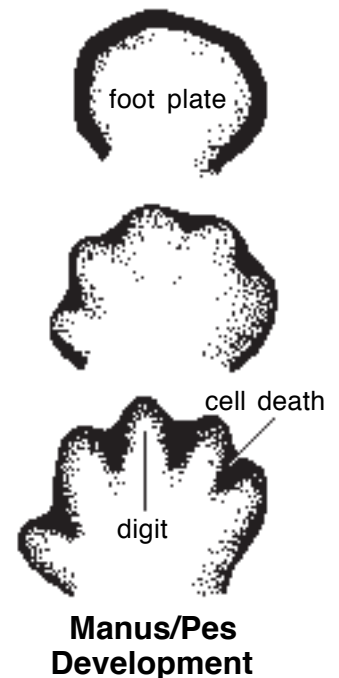
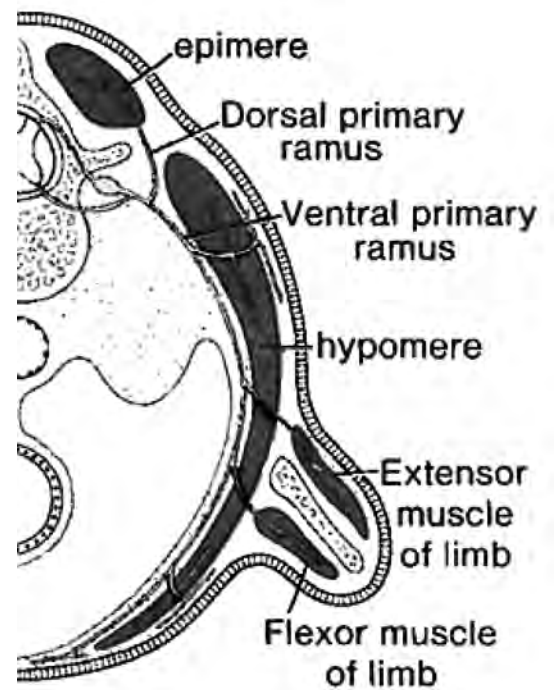
- hypomere myotomes along with their innervation migrate into the developing limb bud.
- myotomes segregate initially into an extensor mass and a flexor mass
- subsequently the two masses subdivide into the individual *extensor muscles* and *flexor muscles*.

Appendicular Skeleton and Skin.

- bone, cartilage, and connective tissue of the limb arise from the local somatic mesoderm of the limb bud.
- local mesenchyme condenses and forms cartilage models of limb bones
- dermis comes from dermatome migrations into the limb bud
- vessels and nerves grow into the limb.

Limb Morphogenesis:

- limbs grow outward from body wall somatopleure as limb buds
- a limb bud begins as a limb field (an area of somatopleure committed to forming a limb)
- a **limb bud** is produced by localized proliferation & condensation of mesenchyme, surface covered by ectoderm
- regions of the limb develop in proximal to distal order as the limb bud elongates (the shoulder/hip appears first, the manus/pes is the last to be added)
- the distal end of the limb bud (footplate) is flattened like a paddle & ectoderm along its outer margin forms a thickened apical ridge
- the **apical ridge** is induced to form by underlying mesoderm and, in turn, it induces the mesoderm to continue growing into a limb)
- mechanically, limb growth consists of:
 - elongation of a dorsoventrally flattened limb bud
 - ventroflexion of the distal half of the limb (ventral now faces medially)
 - pronation of the distal half (previous medial surface now becomes caudal)
- separate digits are produced by interdigital necrotic zones (species with fewer digits undergo further degeneration and/or fusion of digits);



Clinical considerations:

- Achondroplasia (dwarfism; Dachshund) — inherited, systemic, premature ossification of physes of extremities.
- Arthrogryposis [Gr. gryposis = crooked] can result from malformed joints, denervation, abnormal muscle tension, or impaired mobility *in utero*.
- Polydactyly (extra digits); syndactyly (fused digits); brachydactyly (stumpy digits) [Gr. dactylos = digit]
- Amelia (no limb); meromelia (absence of part of limb); micromelia (small limb) [Gr. melos = limb]

Note: phocomelia (seal limb) = absence of proximal segment(s) of limb was a consequence of pregnant women taking thalidomide in the late 1950s.

Head Region:

- The head consists of a *cranium* (which contains the brain within a cranial cavity) and a *face*.
- The cranium is formed during growth of the head process; the face develops from outgrowths of the frontonasal process and first pharyngeal arch.
- Since the face and cranium have different embryonic origins, they can be independently influenced genetically (e.g., in the case of brachycephalic breeds) or by teratogens.

Skeletal Muscles.

Muscles of the head arise from myotomes derived from somitomeres (seven) or somites (four occipital somites):

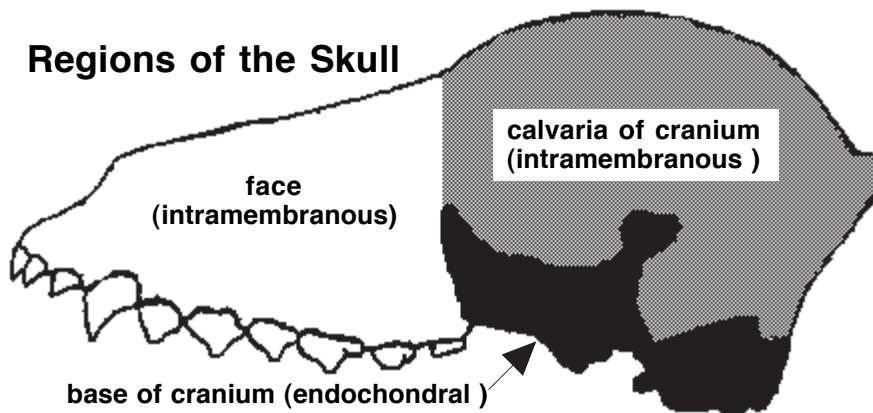
- *Somitomere* myotomes migrate to the orbit (two giving rise eye muscles) or they migrate to pharyngeal arches (becoming muscles of mastication, facial expression muscles).
- *Somite* myotomes become tongue and neck muscles and they migrate to pharyngeal arches (IV-VI), becoming pharyngeal, laryngeal & esophageal muscles.
- Cranial nerves establish early connections with adjacent somitomeres & somites and accompany them to definitive muscle sites. Each pharyngeal arch is innervated by specific cranial nerves (I=trigeminal; II=facial; III=glossopharyngeal; IV-VI=vagus).

Skull.

Bones of the base of the cranium develop endochondrally; but the relatively flat bones that comprise the calvaria (roof of the cranium) and the face develop intramembranously.

- Endochondral bones are formed from the sclerotomes of somitomeres and the first four somites (occipital somites).
- Intramembranous bones arise from ectomesenchyme (derived from neural crest). Intramembranous bones articulate by means of fibrous joints called sutures. Widened suture areas, at the corners of growing bones, are called *fontanel*s. Sutures and fontanel allow bony plates to overlap one another during parturition.
- The mandible has a complex origin involving both endochondral and intramembranous development.
- Auditory ossicles arise endochondrally from pharyngeal arches I (malleus & incus) and II (stapes).

Note: Ectomesenchyme (mesenchyme derived from neural crest) gives rise to cartilage, bone, and connective tissue of the face and dorsal head (calvaria).



Pharyngeal Arch Summary:

- Ectomesenchyme fills pharyngeal arches and forms connective tissue, cartilage and bone.
- Somitomere/somite myotomes migrate into pharyngeal arches and give rise to the skeletal muscles that arise from that arch
- Each arch is innervated by a particular cranial nerve.

First arch. (innervated by cranial nerve V)

- jaw bones (mandible & maxilla); also, ossicles of the middle ear (malleus & incus)
- muscles of mastication, plus rostral digastricus, mylohyoid, & tensor tympani mm.

Second arch: (innervated by cranial nerve VII)

- hyoid bones & stapes (ossicle of the middle ear)
- muscles of facial expression, including caudal digastricus & stapedius mm.

Third arch: (innervated by cranial nerve IX)

- hyoid bones
- one pharyngeal muscle (stylopharyngeus mm.)

Arches IV through VI: (innervated by cranial nerve X)

- laryngeal cartilages
- pharyngeal mm & cricothyroid m — innervated by cranial branch of X
- intrinsic laryngeal mm — innervated by recurrent laryngeal n. of X

Formation of Body (Serous) Cavities

Serous Body Cavities:

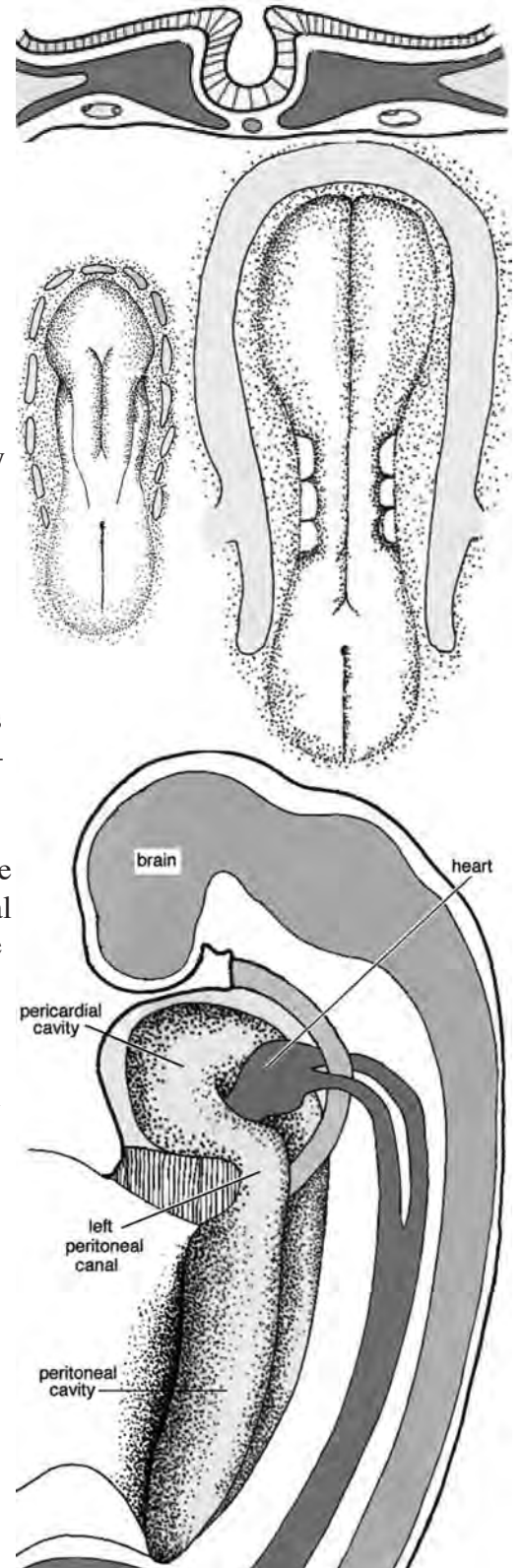
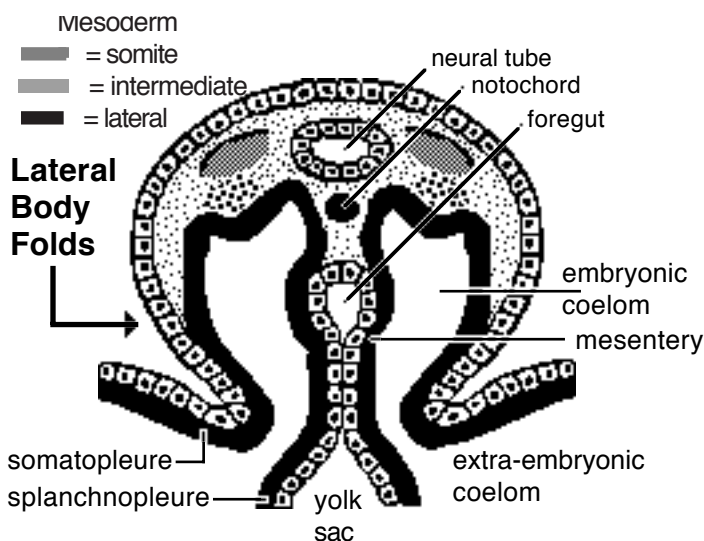
- Serous cavities are located within the trunk and lined by serous membrane (mesothelium).
- Adult, serous cavities are:
 - *pericardial cavity*,
 - two *pleural cavities*, and
 - *peritoneal cavity*, including the *vaginal cavities* (bilateral extensions of the peritoneal cavity).

Serous cavity formation may be summarized as follows:

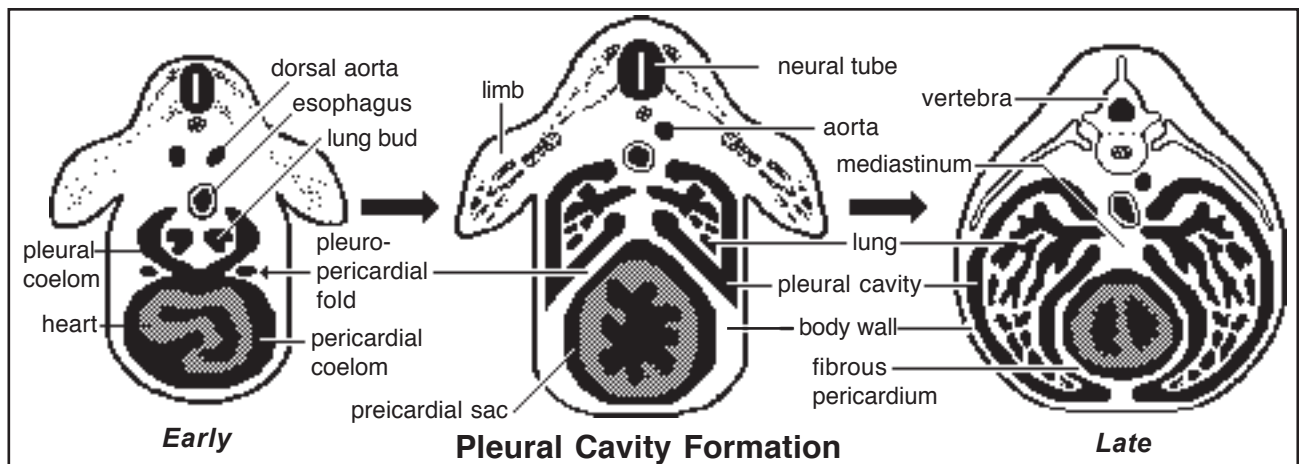
- all of the serous cavities develop from a common embryonic coelom; thus, the cavities are continuous until partitions develop to separate them;
- the individual serous cavities of the adult are formed by inward growth of tissue folds from the body wall (**partitions**) and by outgrowth of coelomic cavity into the body wall (**excavation**).

Coelom (Celom) Development:

- primary mesenchyme forms mesoderm and cavitation within lateral mesoderm expands to establish a horseshoe shaped **coelom** bounded by somatopleure and splanchnopleure
- as head and tail processes develop and lateral body folds merge medially (except at the umbilicus), embryonic and extra-embryonic coelomic compartments become differentiated; the former becomes the serous body cavities, the latter is chorionic
- head process formation produces a foregut and brings the heart and pericardial coelom into the embryo, positioned ventral to the foregut. Right and left sides of the embryonic coelom are separated by gut and by dorsal and ventral mesenteries, but the latter fails to develop at the level of the midgut
- thus, the embryonic coelom features an anterior-ventral pericardial compartment, a caudal peritoneal compartment, and bilateral pleural compartments connecting these



— mesoderm lining the coelom forms mesothelium



Separation of Pericardial and Pleural Cavities:

- pericardial and pleural cavities are separated by fibrous pericardium in the adult.
- in the embryo, the pericardial coelomic cavity communicate with two dorsally positioned pleural cavities (canals)
- the cavities become partitioned initially by *pleuropericardial folds* and subsequently by somatic mesoderm.
- details of the separation include:
 - bilateral pleuropericardial folds (which accompany common cardinal veins) converge medially to unite with the mediastinum, partitioning the pericardial cavity from the pleural canals
 - subsequently, growing pleural cavities dissect ventrolaterally into the body wall, incorporating somatic mesoderm into fibrous pericardium.

NOTE: Mediastinum is formed initially by dorsal and ventral mesenteries of the esophagus.

Separation of Peritoneal and Pleural Cavities:

- adult peritoneal and pleural cavities are separated by the diaphragm
- the diaphragm is formed by a *septum transversum*, paired *pleuroperitoneal folds*, and somatic mesoderm

NOTE: diaphragm muscle is derived from somites in the cervical region ($C_{5,6,7}$), where it initially develops

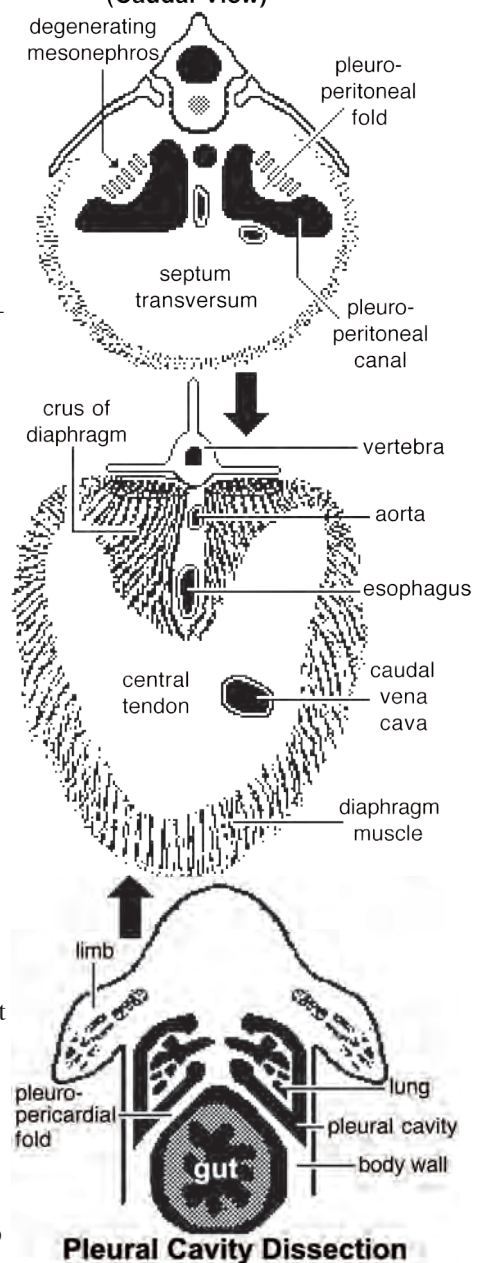
Details of diaphragm formation include:

- the septum transversum originates as mesoderm anterior the heart and becomes incorporated into the ventral body wall and mesentery caudal to the heart when the heart moves ventral to the foregut
- the septum transversum grows dorsally and forms a transverse partition ventral to the level of the gut
- dorsal to the gut, bilateral pleuroperitoneal folds grow medially and meet the septum transversum, completing the central tendon
- subsequently, pleural cavities grow into body wall somatic mesoderm; myotomes migrate to this region which will contain diaphragm musculature

Growth of Pleural Cavities:

Initially pleural cavities are small canals into which lung buds project. As lungs grow, pleural cavities enlarge and carve into the body wall (into somatic mesoderm). Consequently, somatic mesoderm forms partitions (fibrous pericardium & diaphragm) that bound the pleural cavities.

Diaphragm Formation (Caudal View)



Cardiovascular System

Note: The cardiovascular system develops early (week-3), enabling the embryo to grow beyond the short distances over which diffusion is efficient for transferring O₂, CO₂, and cellular nutrients & wastes.

Heart:

Beginning as a simple tube, the heart undergoes differential growth into a four chambered structure, while it is pumping blood throughout the embryo and into extra-embryonic membranes.

Angiogenesis begins with *blood island* formation in splanchnic mesoderm of the yolk sac and allantois. Vessel formation occurs when island vesicles coalesce, sprout buds, and fuse to form vascular channels. Hematopoiesis (blood cell formation) occurs in the liver and spleen and later in the bone marrow. The transition from fetal to adult circulation involves new vessel formation, vessel merger, and degeneration of early vessels.

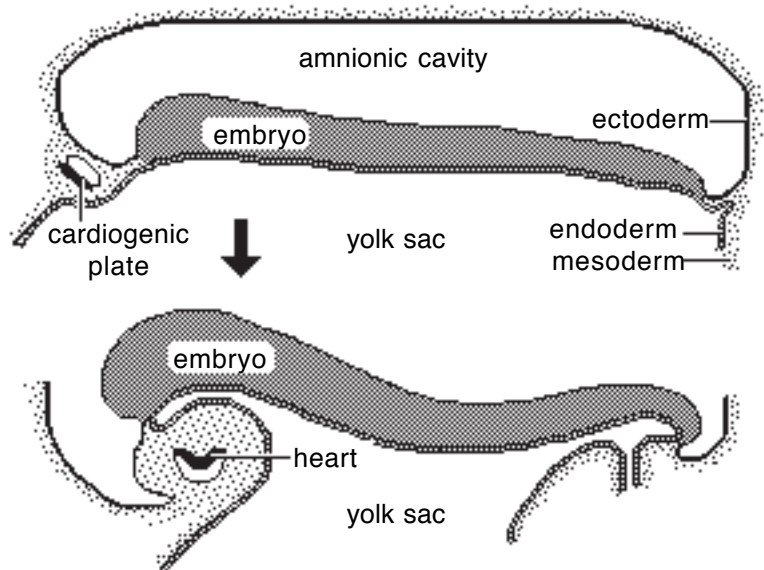
Formation of a Tubular Heart:

The first evidence of heart development is bilateral vessel formation within the *cardiogenic plate* (splanchnic mesoderm situated anterior to the embryo).

The cardiogenic plate moves ventral to the pharynx as the head process grows upward and outward.

Bilateral endocardial tubes meet at the midline & fuse into a single *endocardial tube*, the future heart.

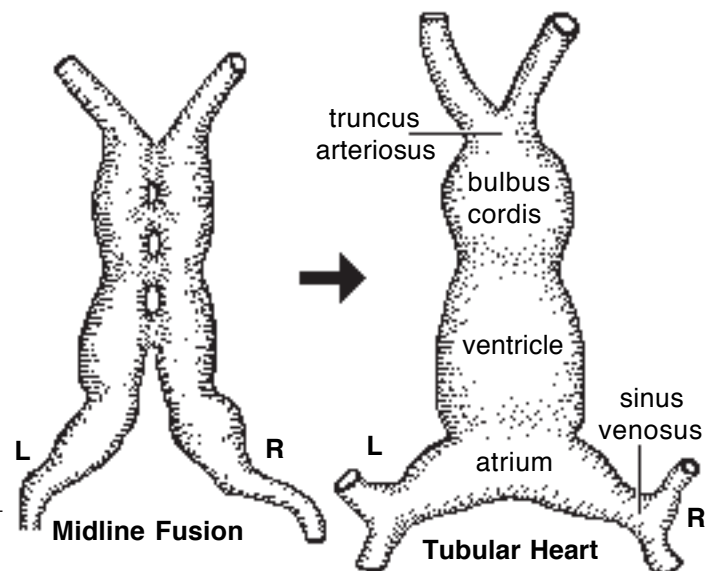
Splanchnic mesoderm surrounding the tube forms cardiac muscle cells capable of pumping blood.



Primitive Heart Regions:

Differential growth of the endocardial tube establishes five primitive heart regions:

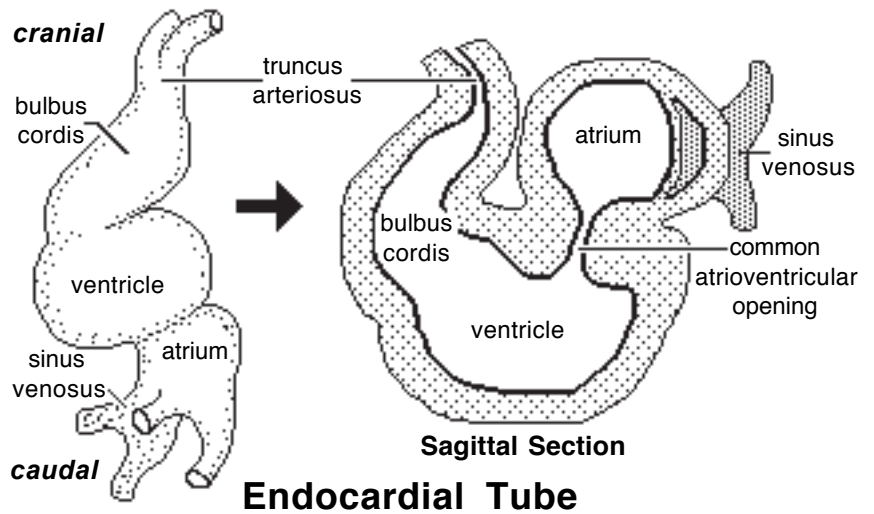
- 1] *Truncus arteriosus* — the output region of the heart. It will develop into the ascending aorta and pulmonary trunk.
- 2] *Bulbus cordis* — a bulb-shaped region destined to become right ventricle.
- 3] *Ventricle* — an enlargement destined to become the left ventricle.
- 4] *Atrium* — a region that will expand to become both right and left auricles.
- 5] *Sinus venosus* — a paired region into which veins drain. The left sinus venosus becomes the coronary sinus; the right is incorporated into the wall of the right atrium.



Forming a Four-Chambered Heart:

The following are six snapshots of the development process:

A) *Endocardial tube lengthens and loops on itself*—this puts the bulbus cordis (right ventricle) beside the ventricle (left ventricle) and the atrium dorsal to the ventricle.



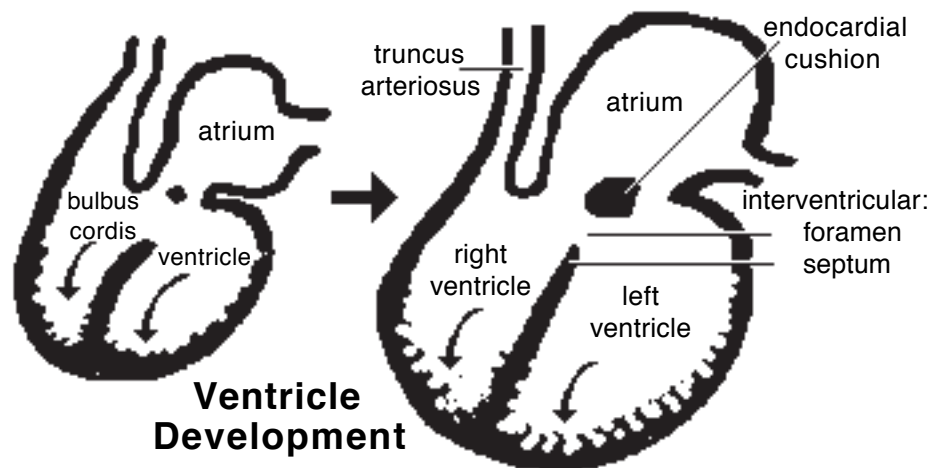
B) *Venous return is shifted to the right side:*

- The larger *right sinus venosus* becomes the right atrium. (The embryonic atrium becomes auricles.)
- The smaller *left sinus venosus* joins the future right atrium as the *coronary sinus*.

The embryonic atrium expands and overlies the ventricle chamber. A common atrioventricular opening connects the two chambers. A constriction, the future coronary groove, separates atrium and the ventricle.

C) *Atrio-ventricular opening is partitioned:*

- Growth of endocardial “cushions” partitions the common A-V opening into right and left openings.
- Ventral growth of the cushions contributes to a septum that closes the interventricular foramen (the original opening between the bulbus cordis & ventricle).



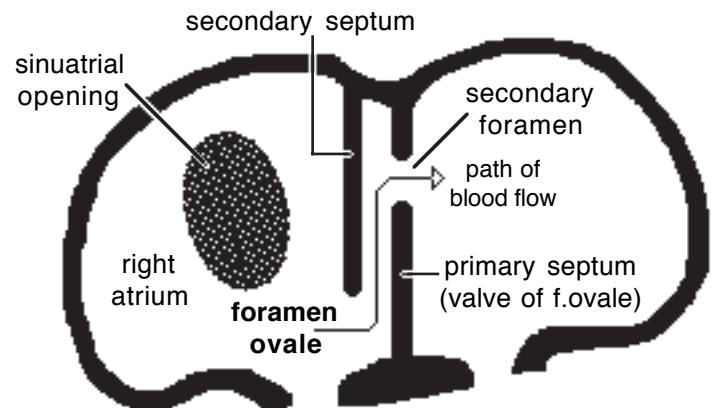
Incomplete closure of the interventricular septum (ventricular septal defect) results in blood flow from the left to the right ventricle and an associated murmur. Large defects produce clinical signs of cardiac insufficiency.

D) *Right & left ventricles formed:*

- Ventral growth and interior excavation of the bulbus cordis and ventricle form right & left ventricles, respectively.
- The interventricular septum, atrioventricular valves, chordae tendineae, papillary muscles, and irregularities of the internal ventricular wall are all sculptured by selective excavation of ventricular wall tissue.

E) *Right and left atria divided by a septum:*

- Septum formation is complicated by the need, until birth, for a patent (open) septum that allows blood to flow from the right atrium to the left. The septal opening is called the *foramen ovale*.



Blood Flow Through Foramen Ovale

- Formation of the interatrial septum and **foramen ovale**:

Interatrial Septum 1 grows from the dorsal atrial wall toward the endocardial cushions.

The pre-existing *Foramen 1* is obliterated when Septum 1 meets the endocardial cushion.

Foramen 2 develops by fenestration of the dorsocranial region of Septum 1 (before *Foramen 1* is obliterated).

Interatrial Septum 2 grows from the cranial wall of the right atrium toward the caudal wall. The septum remains incomplete and its free edge forms the boundary of an opening called the Foramen Ovale.

NOTE: As long as blood pressure in the right atrium exceeds that of the left, blood enters the Foramen Ovale, flows between the two septae and exits into the left atrium. When, at birth, pressure is equal in the two atria, the left septum is forced against the Foramen Ovale, acting as a valve to preclude blood flow.

An atrial septal defect is not a serious developmental anomaly as long as pressure is approximately equal in the two atria, which is normally the case.

F] *Aorta and pulmonary trunk formed:*

- The truncus arteriosus (and adjacent bulbus cordis) is partitioned in a spiral pattern in order to form the aorta & pulmonary trunk.

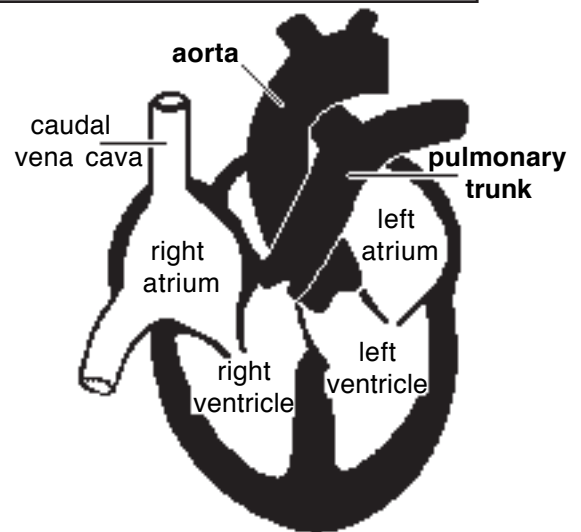
- Ridges appear along the lumen wall, grow inward and merge to create the spiral septum. As a result, the aorta and pulmonary trunk spiral around one another.

- Failure of the septum to spiral leaves the aorta connected to the right ventricle and the pulmonary trunk to the left ventricle—a fatal flaw.

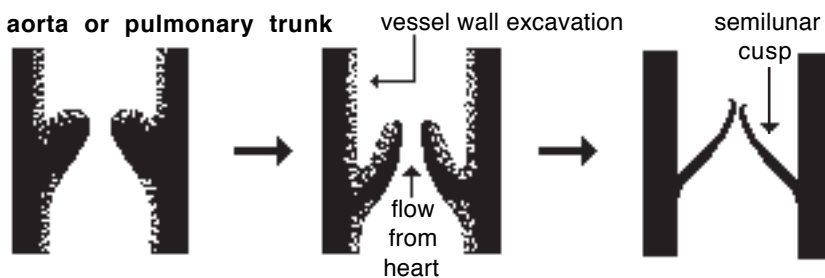
- Growths from the spiral septum and endocardial cushions both contribute to proper closure of the interventricular septum.

- Aortic and pulmonary semilunar *valves* are formed like atrioventricular valves, by selective erosion of cardiac/vessel wall.

- Improper valve sculpturing will produce valvular insufficiency in the case of excessive erosion or vessel stenosis (narrow lumen) in cases of not enough erosion.



Spiral Arrangement of the Aorta & Pulmonary Trunk



Development of semilunar valves by excavation

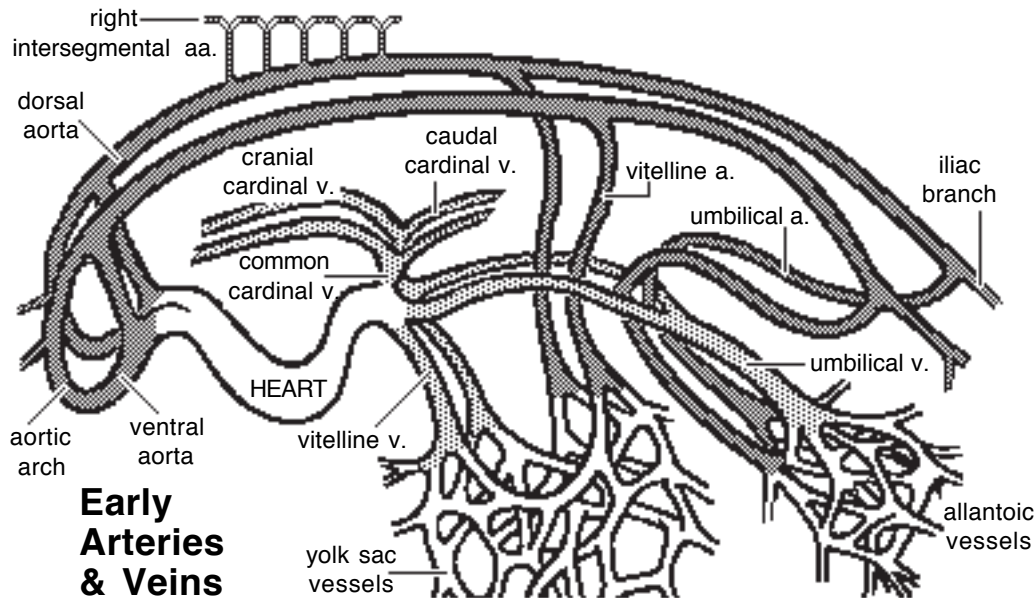
Note:

Neural crest cells migrate to the region of the truncus arteriosus and direct its partitioning by the spiral septum. Ablation of the neural crest results in anomalies of the great vessels.

Tetralogy of Fallot:

This is a cardiac anomaly that occurs in number of species, including humans. It involves a combination of four defects all related to a defective spiral septum formation in the truncus arteriosus & bulbus cordis:

- ventricular septal defect;
- stenosis of the pulmonary trunk;
- enlarged aorta that overrides the right ventricle (dextroposition of the aorta); and
- hypertrophy of the right ventricle, secondary to communication with the high pressure left ventricle.



Early Arteries & Veins

Arteries:

Paired ventral and dorsal aortae develop in the embryo. Bilaterally, ventral & dorsal aortae are connected by up to six **aortic arches**. Each aortic arch is situated within a pharyngeal arch.

Caudal to the aortic arches, the paired dorsal aortae merge to form a single **descending aorta**, as found in the adult. The aorta gives off dorsal, lateral, and ventral branches, some of which persist as adult vessels.

Paired ventral aortae receive blood from the truncus arteriosus and fuse to form the adult **brachiocephalic trunk**.

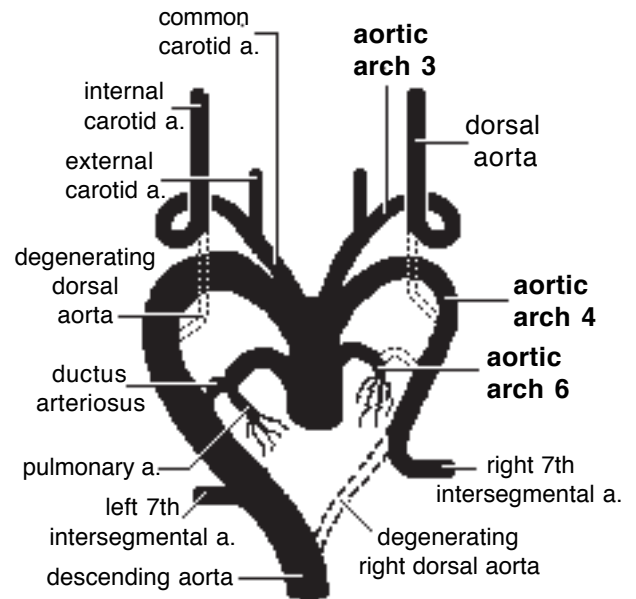
Disposition of Aortic Arches:

The third, fourth, and sixth aortic arches become adult vessels. The first two arches degenerate and the fifth arch is rudimentary or absent.

Each **third** aortic arch becomes an **internal carotid artery** and proximally the third arch forms a **common carotid artery**. The dorsal aorta degenerates between the third and fourth aortic arches. Consequently, the third arch supplies the head and the fourth arch supplies more caudal regions. The **external carotid artery** buds from the third arch.

The **left fourth** aortic arch becomes the adult **arch of the aorta**. The **right fourth** aortic arch becomes the proximal part of the right **subclavian artery** as the distal connection between the arch and the dorsal aorta normally degenerates. (Persistence of a connection between the fourth aortic arch and the descending aorta results in compression of the esophagus, accompanied difficult swallowing and an enlarged esophagus cranial to the compression.)

The proximal part of each **sixth** aortic arch becomes a **pulmonary artery**. The distal part of the arch degenerates on the right side but persists as **ductus arteriosus** on the left side.



Aortic Arches 3, 4, 6 (Dorsal View)

Note: The **ductus arteriosus** shunts blood from the pulmonary trunk to the aorta, allowing the right ventricle to be exercised in the face of limited blood return from the lungs. At birth, abrupt constriction of the ductus arteriosus shifts pulmonary trunk output into the lungs. Eventually, a ligamentum arteriosum replaces the constricted ductus arteriosus. (A persistent ductus arteriosus results in a continuous murmur during both systole and diastole.)

Subclavian & Vertebral arteries:

Each dorsal aorta gives off intersegmental arteries that pass dorsally between somites. Bilaterally, the seventh cervical intersegmental artery becomes the distal portion of the *subclavian artery*.

Intersegmental arteries cranial to the seventh cervical form the *vertebral artery* (by anastomosing with one another and losing connections to the aorta via degeneration). Intersegmental arteries caudal to the seventh cervical become intercostal and lumbar arteries.

When the heart shifts caudally from the neck to the thoracic cavity, positions of aortic arch arteries are changed. In particular the subclavian arteries become transposed from a position caudal to the heart to a cranial position.

Branches of Dorsal Aortae:

Right and left *vitelline arteries* arise from right and left dorsal aortae to supply the yolk sac. The right vitelline artery becomes the adult *cranial mesenteric artery*. The left vitelline artery normally degenerates. (Incomplete degeneration of the left vitelline artery can result in a fibrous band that may cause colic by entrapping a segment of intestine.)

Each dorsal aorta terminates in an *umbilical artery* that supplies blood to the allantois. In the adult, umbilical arteries persist to the urinary bladder and degenerate distal to the bladder. External and internal iliac arteries develop as outgrowths of the umbilical artery.

Veins:

Bilaterally, the embryonic sinus venosus receives:

- *vitelline veins*, which drain the yolk sac
- *umbilical veins* which drain the allantois, and
- *cardinal veins* which drain the embryo.

The transition from embryonic to adult venous patterns involves the formation of new veins, anastomoses between veins, and the selective degeneration of embryonic segments.

Note: Recall that venous return is shifted to the right side and the right sinus venosus is incorporated into the right atrium. The left sinus venosus is reduced and becomes coronary sinus.

Cranial Vena Cava Formation:

Each cranial cardinal vein becomes the adult *internal jugular vein*. The much larger *external jugular* and *subclavian* veins arise by budding from the cranial cardinal vein.

An anastomotic vein develops and runs from left to right cranial cardinal veins, shifting venous return to the right side and becoming left *brachiocephalic vein*. (Failure of the anastomotic vein to develop results in a double cranial vena cava, the typical condition in rats and mice.)

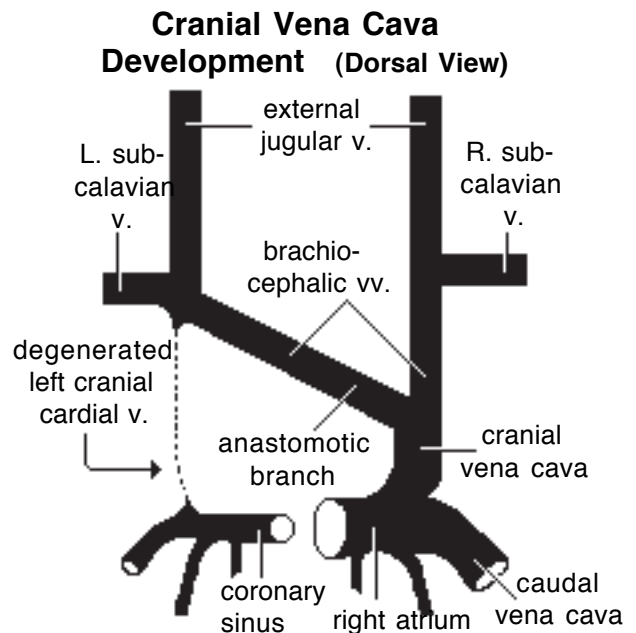
The caudal segment of right cranial cardinal vein along with the right common cardinal vein becomes the *cranial vena cava*.

Caudal Vena Cava and Azygos Vein:

Each caudal cardinal vein gives rise to supra-cardinal and sub-cardinal veins with extensive anastomoses among all of the veins. These venous networks, located in intermediate mesoderm, supply embryonic kidneys and gonads.

Selective segments of particularly the right subcardinal venous network, including an anastomosis with the proximal end of the right vitelline vein form the *caudal vena cava*.

The *azygos vein* develops from the supracardinal vein as well as the caudal and common cardinal veins of the right side (dog, cat, horse) or the left side (pig) or both sides (ruminants). The azygos vein will drain into the cranial vena cava (or right atrium) on the right side and into the coronary sinus on the left side.

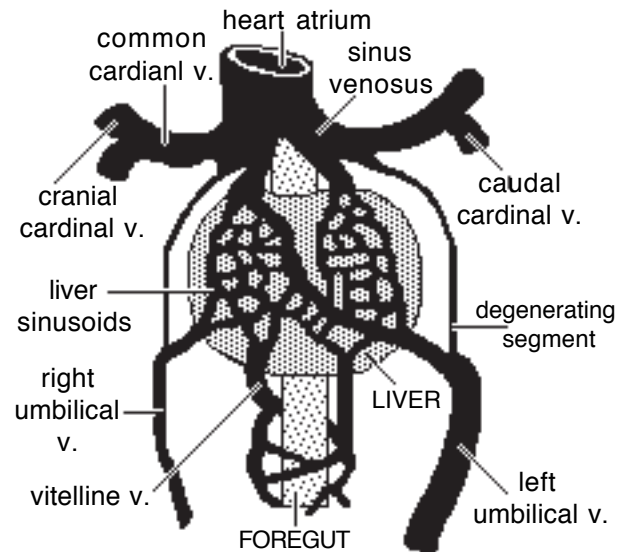


Portal Vein and Ductus Venosus:

Proximally, *vitelline veins* form liver sinusoids as the developing liver surrounds the veins. Vitelline veins gives rise to the *portal vein*, formed by anastomoses that develop between right and left vitelline veins and enlargement/atrophy of selective anastomoses.

Umbilical veins, also engulfed by the developing liver, contribute to the formation of liver sinusoids. Within the embryo, the right umbilical vein atrophies and the left conveys placental blood to the liver. Within the liver, a shunt, the *ductus venosus*, develops between the left umbilical vein and the right hepatic vein which drains into the caudal vena cava.

Postnatally, the left umbilical vein becomes the round ligament of the liver located in the free edge of the falciform ligament.



**Vitelline & Umbilical Veins
(Ventral View)**

Because a fetus is not eating & because the placenta is able to detoxify blood & because it is mechanically desirable for venous return to bypass fetal liver sinusoids, the **ductus venosus** develops in the embryo as a shunt that diverts blood away from sinusoids and toward systemic veins.

Postnatally, however, a persistent **portosystemic shunt** allows toxic digestive products to bypass the liver. These toxic agents typically affect the brain resulting in neurologic disorders at some time during life.

A portosystemic shunt can be the result of a *persistent ductus venosus* or a developmental error that results in *anastomosis between the portal vein and the caudal vena cava or the azygos vein*. Since adult veins are established by patching together parts of embryonic veins, it is not surprising that mis-connections arise from time to time.

Pulmonary Veins:

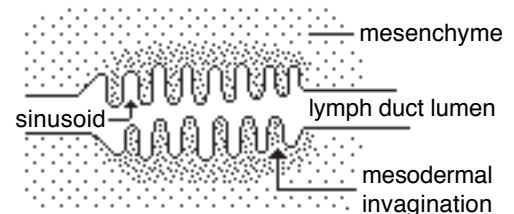
These develop as outgrowth of the left atrium. The initial growth divides into left and right branches, each of which subdivides into branches that drains lobes of the lung. Pulmonary branches become incorporated into the wall of the expanding left atrium. The number of veins entering the adult atrium is variable due to vein fusion.

Lymphatics:

Lymph vessel formation is similar to blood angiogenesis. Lymphatics begin as lymph sacs in three regions: jugular (near brachiocephalic veins); cranial abdominal (future cisterna chyli); and iliac region. Lymphatic vessels (ducts) form as outgrowths of the sacs.

Lymph nodes are produced by localized mesodermal invaginations that partition the vessel lumen into sinusoids. The mesoderm develops a reticular framework within which lymphocytes accumulate.

The spleen and hemal nodes (in ruminants) develop similar to the way lymph nodes develop.



Lymph Node Formation

Prior to birth, fetal circulation is designed for the *in utero* aqueous environment, where the placenta oxygenates fetal blood.

Suddenly, at birth...

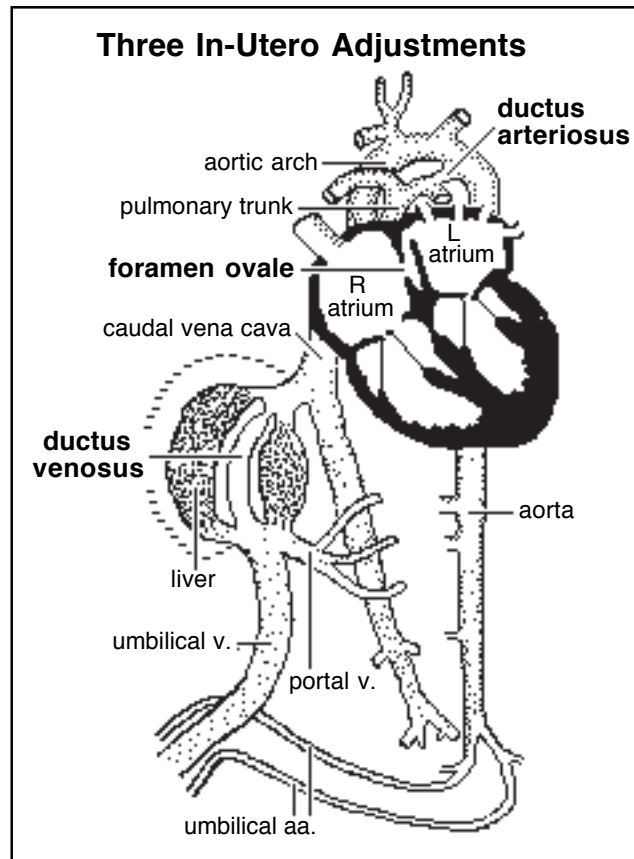
The environment is changed:

Stretching and constriction of umbilical arteries shifts fetal blood flow from the placenta to the fetus.

Reduced venous return through the (left) umbilical vein and *ductus venosus* allows the latter to gradually close (over a period of days).

Bradykinin being released by expanding lungs, a loss of prostaglandins generated by the placenta, and increased oxygen concentration in blood, all combine to trigger rapid constriction of the *ductus arteriosus* which, over two months, is gradually converted to a fibrous structure, the *ligamentum arteriosum*.

The increased blood flow to the lungs and then to the left atrium equalizes pressure in the two atria, resulting in closure of the *foramen ovale* that eventually grows permanent.



Digestive System

NOTE: The digestive system consists of the: mouth (oral cavity); pharynx; esophagus; stomach; small intestine; colon and cecum; rectum; anal canal; and the liver, pancreas, and salivary glands.

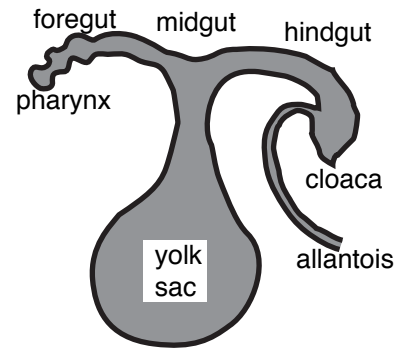
- Development of head and tail processes, and the merger ventrally of lateral body folds, transforms splanchnopleure into: *foregut*, *hindgut*, & *midgut* (the latter is continuous with the yolk sac).
- *Endoderm* becomes epithelium lining of the digestive tract; *splanchnic mesoderm* forms connective tissue and smooth muscle components (except that *ectoderm* forms epithelium lining the proctodeum (caudal end of anal canal) and stomadeum (mouth & some salivary glands — parotid, zygomatic, labial & buccal)).

Foregut becomes pharynx, esophagus, stomach, cranial duodenum, and liver and pancreas.

Midgut becomes the remaining small intestines, cecum, ascending colon, and part of the transverse colon.

Hindgut becomes transverse and descending colon and a cloaca which forms the rectum and most of the anal canal.

In the adult abdomen, derivatives of the *foregut*, *midgut*, and *hindgut* are those structures supplied by the *celiac*, *cranial mesenteric*, and *caudal mesenteric arteries*, respectively.



Pharynx...

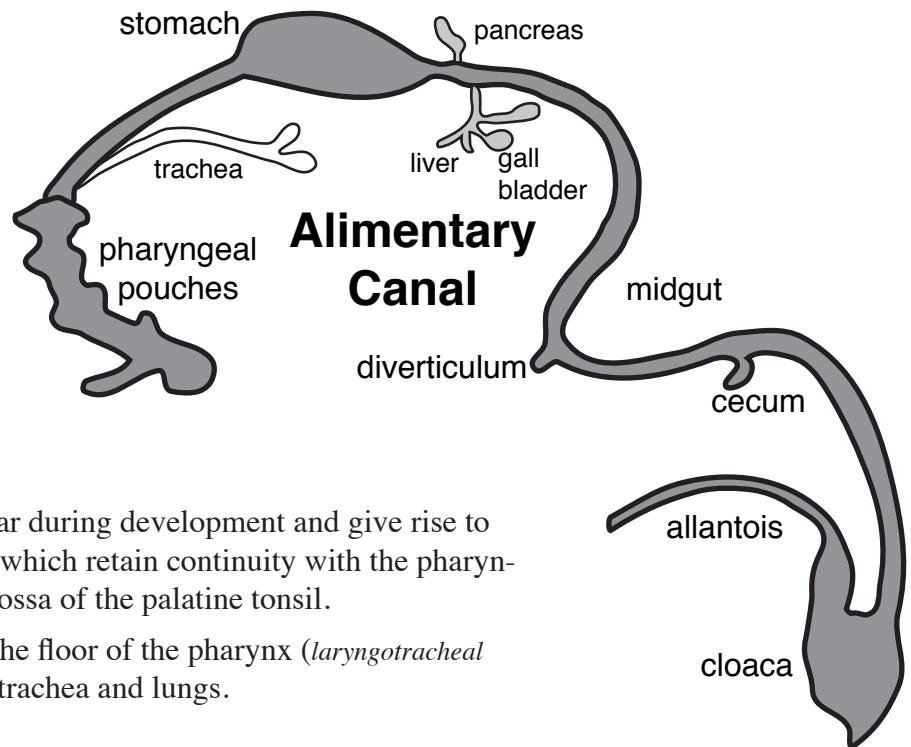
- The adult pharynx is a common respiratory-digestive chamber.

- Initially, the pharynx is closed cranially by an *oropharyngeal membrane* that must degenerate to allow:

- the pharynx to communicate with oral and nasal cavity outgrowths;
- migration of tongue muscle from the pharynx into the oral cavity.

- *Pharyngeal pouches* appear during development and give rise to several adult structures, two of which retain continuity with the pharyngeal cavity: auditory tube and fossa of the palatine tonsil.

- A midline evagination of the floor of the pharynx (*laryngotracheal groove*) gives rise to the larynx, trachea and lungs.



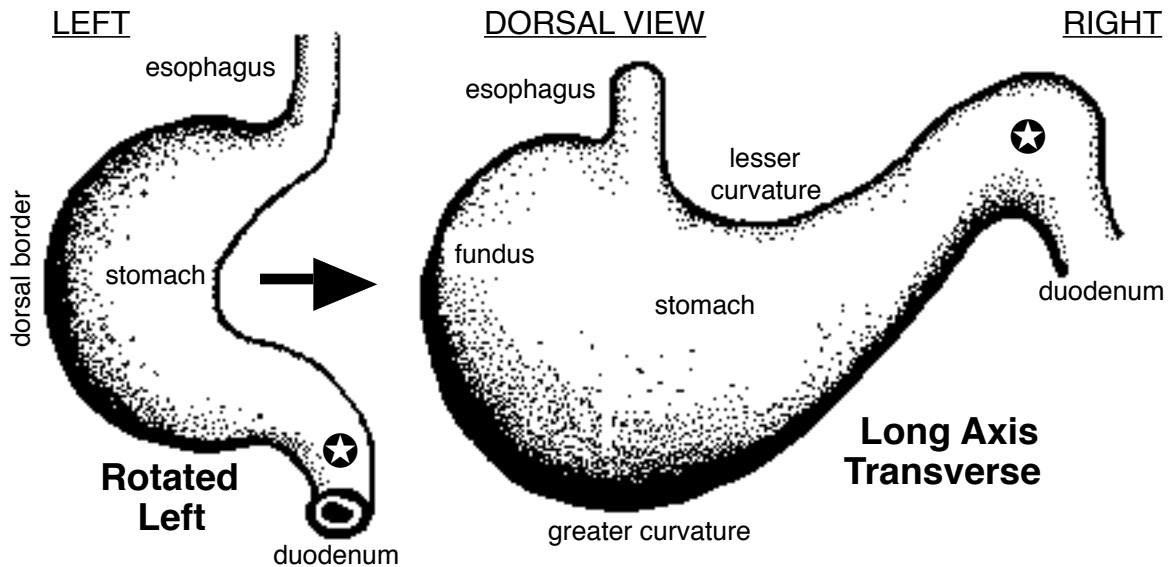
Esophagus...

- The esophagus develops from *foregut*, caudal to the pharynx. Its principal morphogenic development is elongation.

- Skeletal muscle associated with both the esophagus & pharynx is derived from somites that migrate to the pharyngeal arches IV & VI (innervation is from *vagus nerve*).

NOTE: Esophagus may be coated by skeletal muscle: throughout its length (dog, ruminants), to the level of the diaphragm (pig), to the mid-thorax (cat, horse, human), or not at all (avian).

SIMPLE STOMACH DEVELOPMENT



Stomach (simple stomach)...

Most domestic mammals have a simple stomach; in contrast, ruminants have a complex stomach with multiple compartments.

The simple stomach develops from a tubular segment of *foregut* that undergoes the following morphogenic changes:

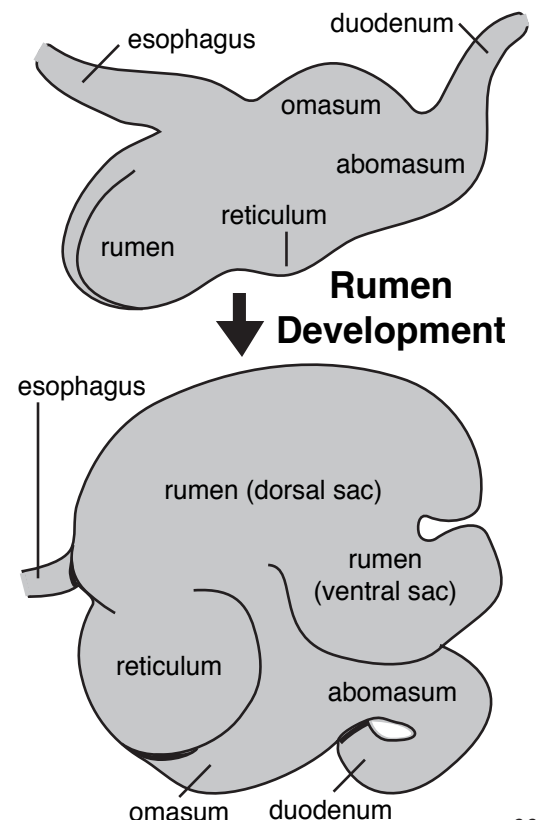
- the tube becomes convex dorsally (future **greater curvature**) and concave ventrally (future **lesser curvature**), because growth is more rapid dorsally than it is ventrally
- the tube rotates 90° to the left (dorsal faces left & ventral faces right);
- the long axis becomes transverse as liver growth pushes the cranial end of the stomach to the left side (the greater curvature faces caudally and drops ventrally when the stomach is filled);
- increased growth along the left cranial margin of the future greater curvature produces a **fundus** region;
- endoderm forms the epithelium lining the stomach and differentiates into different cells types that vary regionally among species.

Ruminant stomach...

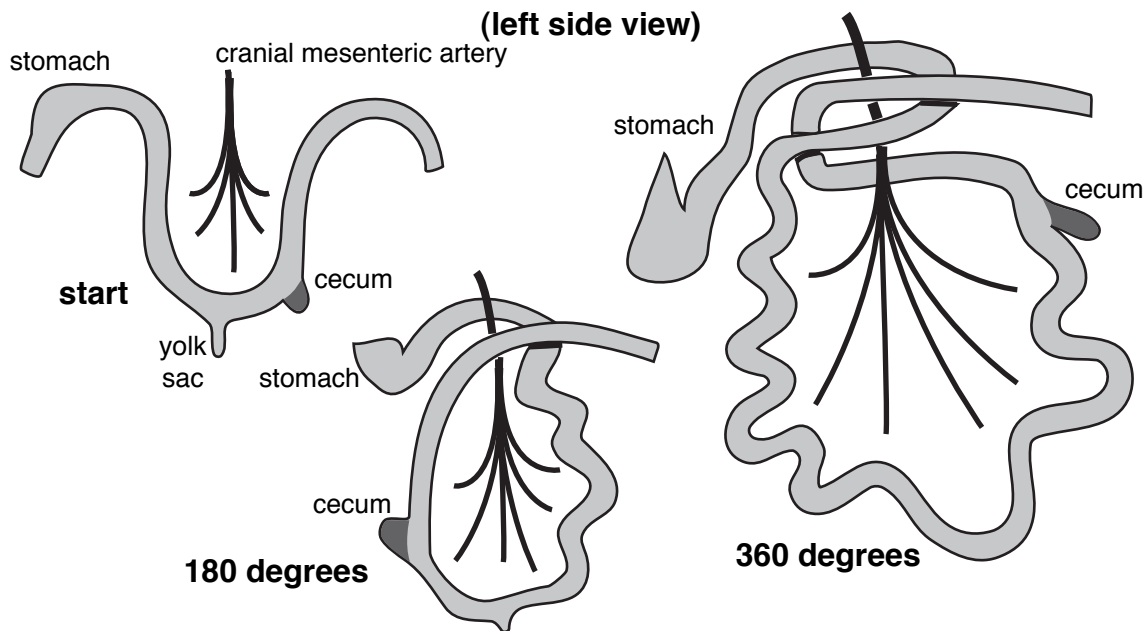
The adult ruminant stomach consists of three compartments lined by stratified squamous epithelium (**rumen**, **reticulum**, and **omasum**) and one glandular compartment (**abomasum**).

- The early development of the ruminant stomach is the same as the simple stomach; subsequently:
- the **rumen** develops as an expansion of the fundus
- the **reticulum** arises as a caudoventral pocket of the developing rumen
- the **omasum** develops as a bulge along the lesser curvature.
- the **abomasum** develops from rest of the stomach

Later in development the rumen “flips” caudally so it lays on top of the abomasum and the reticulum is cranial.



Rotation of Gut Around Cranial Mesenteric A.



Intestinal tract...

NOTE. The intestinal tract consists of: duodenum (descending & ascending), jejunum, ileum, colon (ascending, transverse, & descending), cecum (diverticulum at the beginning of the colon), rectum, and anal canal.

Along with general tubular elongation, the following morphogenic events occur:

- where the *yolk sac* is attached, the *midgut* to form an elongate loop that herniates through the *umbilicus* (out of the embryo and into the coelom of the umbilical stalk); as the embryo grows, the loop returns into the embryonic coelom (abdominal cavity).
- the elongating loop rotates 360° around the right vitelline a. (adult ***cranial mesenteric artery***), the rotation is clockwise as viewed dorsally (freedom to rotate is the result of the reduced yolk sac attachment and elongation of the cranial limb of the midgut loop).
- the caudal limb of the loop develops a diverticulum, the future cecum.

Additional intestinal events in ungulates...

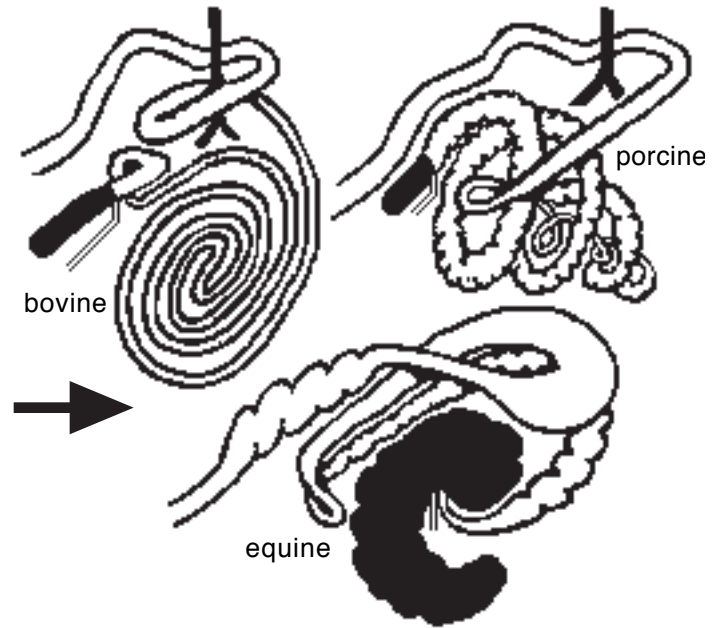
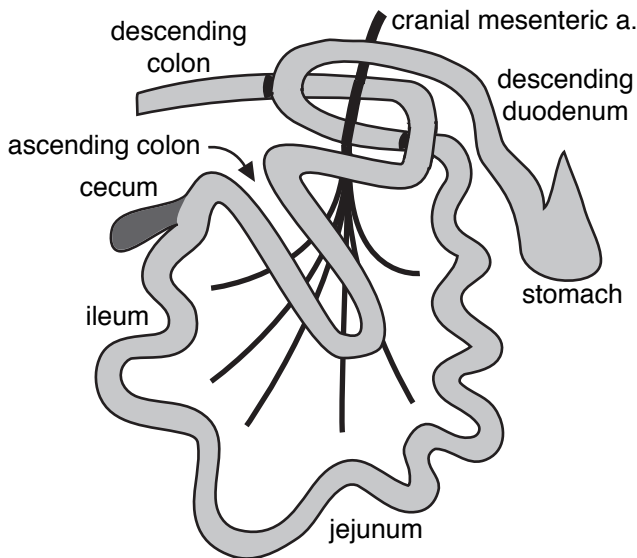
- a loop of colon forms just distal to the cecum (loop of adult ascending colon)
- in pig and ruminant—the loop coils (forming a spiral or coiled colon);
- in horse—the loop enlarges and bends on itself; also, the cecum enlarges so that the proximal colon is incorporated within the cecum.

Anomalies...

- The intestinal tract and esophagus normally undergo temporary atresia (occluded lumen) during development as a result of epithelial proliferation. Re-canalization occurs by formation of vacuoles that coalesce to form the ultimate lumen. Persistent **atresia** (failure to re-canalize) or **stenosis** (narrow lumen) is a congenital anomaly that can occur at localized sites anywhere along the esophagus or intestines.

- Failure of the *yolk sac* to be absorbed by the *midgut* (**jejunum**) can result in: a diverticulum of the jejunum, a fistulous (hollow) cord to the umbilicus, or a fibrous connection between the jejunum and umbilicus. Each of these can become a source of colic

Ascending Colon Loop (right side view)



Cloaca...

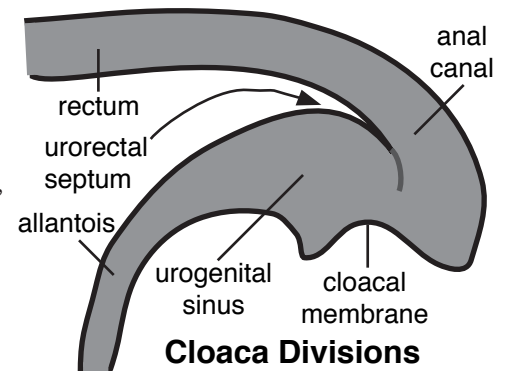
The *hindgut* terminates in a *cloaca*, i.e., a chamber that communicates with digestive, urinary and genital systems:

- the caudal wall of the cloaca (*cloacal membrane*) is endoderm apposed to surface ectoderm
- the allantois evaginates from the hindgut at the cranial end of the cloaca
- the cloaca persists in adult birds, reptiles, & amphibians

Rectum:

The rectum is formed when a mesenchyme partition (*urorectal septum*) divides the cloaca into dorsal and ventral chambers:

- The dorsal chamber, which is continuous with the hindgut, becomes the **rectum** and most of the **anal canal**, including a temporary anal membrane.
- The ventral chamber, the *urogenital sinus*, is continuous with the allantois. The urinary bladder and urethra develop from the proximal allantois and urogenital sinus.



Anal canal:

The cranial part of the anal canal (most of the canal) is formed along with the rectum; this part of the anal canal is lined by a mucosal epithelium derived from endoderm.

The caudal part of the anal canal (caudal to the adult ***anocutaneous line***) is lined by stratified squamous epithelium. It forms as follows:

- external tissue surrounding the anal membrane grows caudally creating a *ectoderm* lined depression called the *proctodeum*
- the proctodeum becomes incorporated into the anal canal when the anal membrane degenerates (atresia ani or intact anal membrane is a congenital anomaly);
- in carnivores, lateral diverticula of proctodeum ectoderm become anal sacs.

Liver...

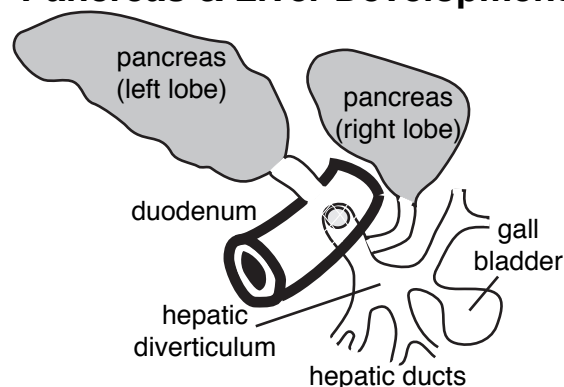
- the liver originates from endoderm as an *hepatic diverticulum* that arises from the region of foregut that will become adult *descending duodenum*
- the diverticulum gives rise to multiple branches that, in the adult, become: *hepatic ducts*, *cystic duct* and the *pancreatic duct*
- **lobes** of the **liver** are formed during continued growth & branching of hepatic duct primordia
- a *gall bladder* develops at the end of the cystic duct
- the *bile duct* is derived from the initial part of the hepatic diverticulum
- the hepatic diverticulum originates ventrally but differential growth of the duodenal wall results in the bile duct entering the duodenum dorsally, with the pancreatic duct on the *major duodenal papilla*.

Pancreas...

- The pancreas originates from two separate endoderm diverticula, each of which elongates, branches, and then forms acini in typical glandular fashion
 - one diverticulum arises ventrally as a bud of the hepatic diverticulum, it forms the *pancreatic duct* and *right lobe of the pancreas*
 - the other diverticulum arises dorsally from the duodenum (*minor duodenal papilla*) and forms the *accessory pancreatic duct* and the *left lobe of the pancreas*
- As the right and left lobes cross one another during development, they fuse to form the *body* of the *pancreas*; also, the duct systems anastomose to form a common drainage system
- The endocrine (islet) cells of the pancreas also develop from the endoderm of the diverticula.

NOTE: One of the two pancreatic ducts will be smaller than the other and may even disappear. Which one is destined to become smaller or absent depends on the species. In the dog, the accessory pancreatic duct is the larger one, but only about 20% of cats have an accessory pancreatic duct and the associated minor duodenal papilla.

Pancreas & Liver Development



Avian...

The avian digestive tract features:

- a crop, which develops as a diverticulum of the esophagus;
- a two-compartment stomach:
 - 1] proventriculus (glandular stomach) and
 - 2] ventriculus or gizzard (stratified squamous epithelium and heavy muscles for grinding);
- a pair of ceca;
- a cloaca which opens externally by means of a vent.

Mesenteries...

- The embryonic *coelom* separates splanchnic mesoderm from somatic mesoderm. The mesoderm lining the coelom transforms into serous membrane, making the coelom a serous cavity.

- Mesenteries are formed by *splanchnic mesoderm* at the same time that the embryonic gut is created as the embryo assumes a tubular shape.

- Caudal to the pharynx, dorsal and ventral “mesenteries” of the esophagus persist as *mediastinum* in the thorax.

- In the abdomen, a dorsal mesentery persists, but a ventral mesentery is absent in the midgut region.

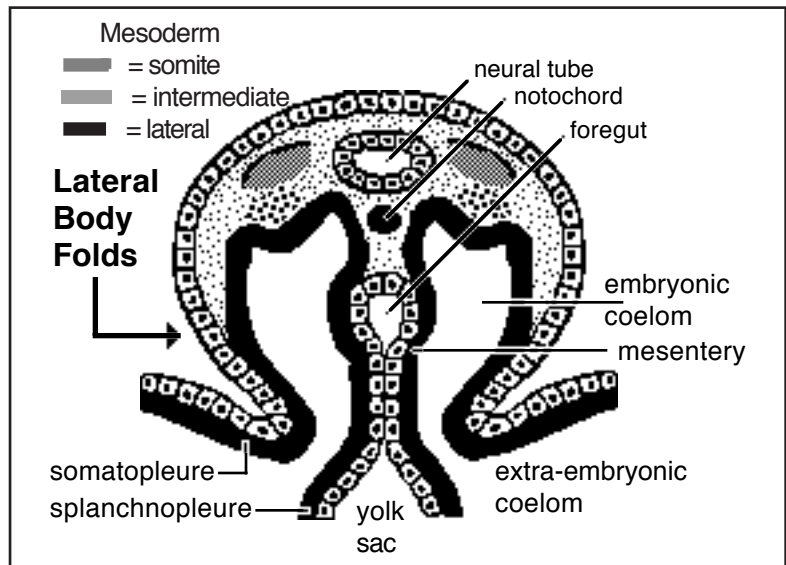
Abdomen:

The *dorsal mesentery* becomes: greater omentum, mesoduodenum, mesentery (mesojejunum and mesoileum), mesocolon, and mesorectum.

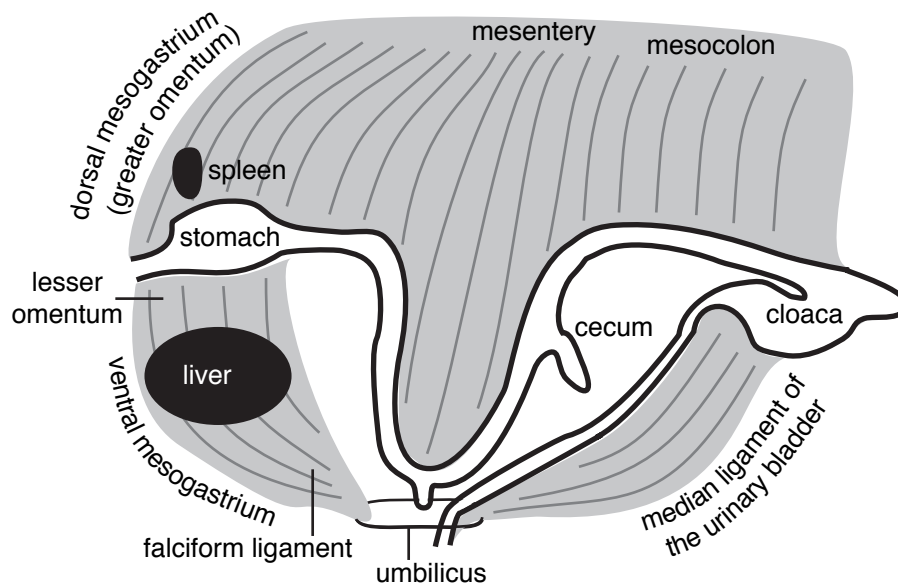
The original dorsal mesogastrium elongates greatly as it forms *greater omentum*. The left lobe of the pancreas develops within the dorsal portion of the greater omentum. The spleen develops within the greater omentum from blood vessels that accumulate in the vicinity of the greater curvature of the stomach.

As the *midgut* elongates and rotates around the cranial mesenteric artery, portions of the mesojejunum and mesoileum come into contact near the dorsal body wall and fuse, forming the *root of the mesentery*. Parts of the mesoduodenum and mesocolon also fuse to the root the mesentery.

The *ventral mesentery*, in which the liver develops, becomes the *lesser omentum* and coronary and falciform ligaments of the liver. Caudally, ventral mesentery becomes *median ligament of the urinary bladder*.



Mesenteries (lateral view)

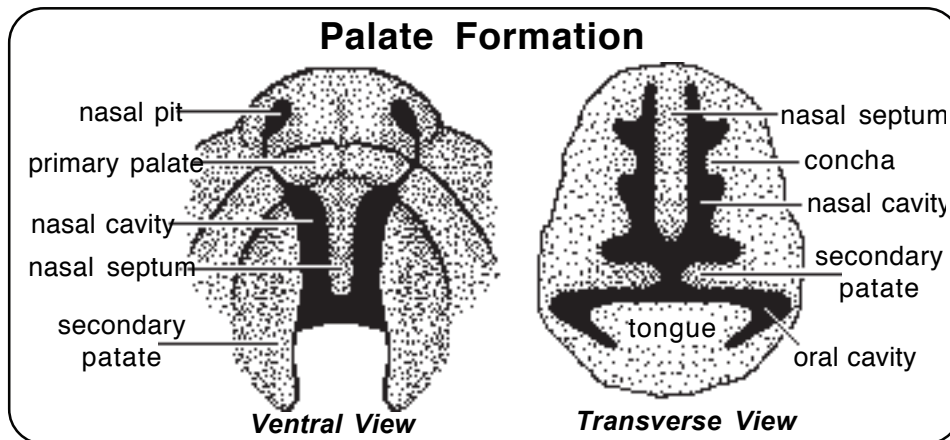


Respiratory System

The respiratory system consists of: nasal cavity, pharynx, larynx, trachea and lungs. Epithelium lining the nasal cavity is derived from *ectoderm*; that lining of the rest of the respiratory system comes from *endoderm*.

Summary of Nasal Cavity Development: (details given later in Face Development lecture)

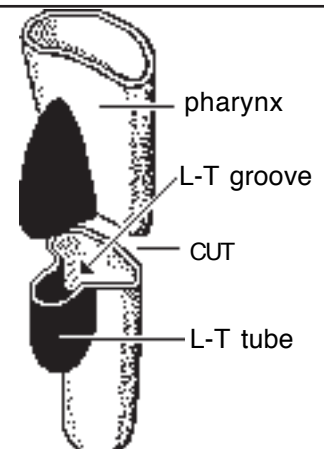
- initially, bilateral *nasal placodes* appear (ectodermal thickenings at the tip of the frontonasal prominence)
- placodes become *nasal pits* by outward growth of the surrounding *medial* and *lateral nasal processes*; continued outgrowth transforms the pits into a *nasal cavity*
- right & left medial nasal processes fuse to form a *primary palate* (incisive bone & upper lip) and a *nasal septum*; lateral nasal processes become nose cartilage and nasal & lacrimal bones
- formation of the *secondary palate* divides the common naso-oral space into three separated cavities (right & left sides of the nasal cavities and the oral cavity); also, the secondary palate divides the pharynx into three compartments (nasopharynx, oropharynx, & laryngopharynx)



- *conchae* (scrolls of thin bone covered by mucosa) arise as cartilaginous ridges from bones of the nasal cavity wall
- *paranasal sinuses* (diverticula of the nasal cavity) develop postnatally.

Larynx, Trachea and Lungs:

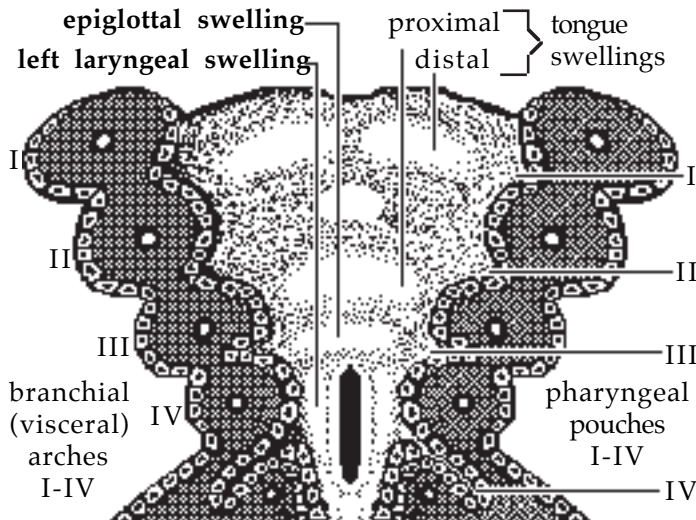
- originate as an evagination of endoderm along the floor of the pharynx, named *laryngotracheal groove*.
- a *tracheoesophageal septum* grows from lateral walls of the laryngotracheal groove and fuses along the midline
- the septum creates a *laryngotracheal tube* (future *trachea* & *lung buds*) as a separate entity from the esophagus
- the *larynx* develops rostrally, where the lumen of the groove retains communication with the pharynx.



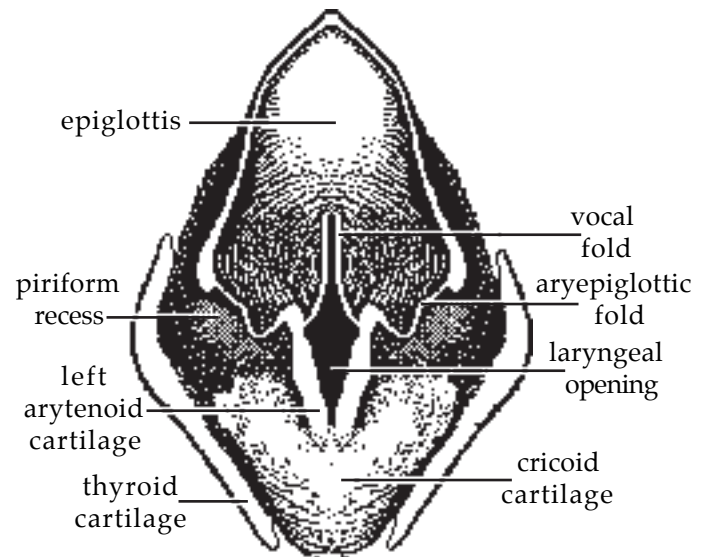
Laryngo-Tracheal Groove (ventral view)

Larynx:

- pharyngeal arch *splanchnic mesoderm* forms bilateral *laryngeal swellings* and a rostral *epiglottal swelling*
- the swellings border the *laryngeal opening* (between the laryngotracheal groove and pharynx)
- growth of the laryngeal swellings that give rise to *cartilages of the larynx*
- a diverticulum of the lateral laryngeal wall produces a *lateral ventricle & vocal fold*, bilaterally (except in cats & cattle which lack these)
- laryngeal muscles are formed from somite myotomes that migrate into pharyngeal arches:
 - IV (cricothyroideus m. innervated by the vagus n. cranial branch) and
 - VI (other muscles innervated by the vagal recurrent laryngeal n.)



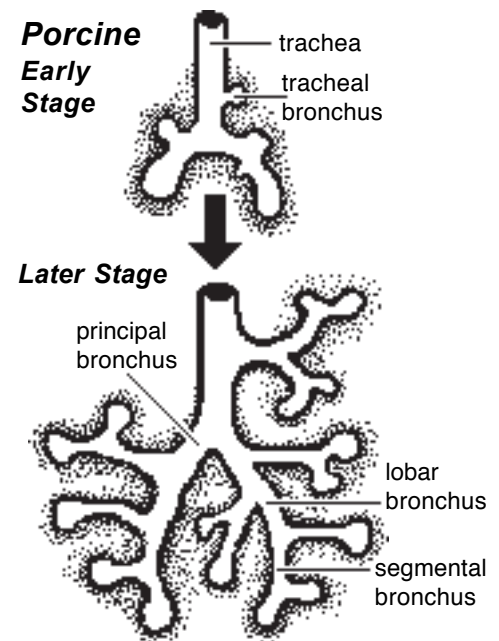
Dorsal View of Floor of Pharynx (roof removed)



Dorsal View of Larynx

Trachea and bronchi:

- the *laryngotracheal tube* grows caudally; elongation shifts bronchi caudally into thoracic splanchnic mesoderm
- splanchnic mesoderm contributes cartilage and connective tissue to the trachea and lungs
- endoderm contributes respiratory epithelium to the trachea and lungs
- the blind, caudal end of the tube develops bi-lobed bronchial buds which grows to form the future *principal bronchi*
- outgrowths of each principal bronchus form future *lobar bronchi*, each of which gives rise to outgrowths that become future *segmental bronchi*, each of which gives rise to more than a dozen additional bronchial branches. The smallest branches are *bronchioles*. They give rise to lung terminal sacs and *alveoli*.
- bronchial branchings continue to occur throughout the fetal period and into the postnatal period.



Bronchial Development (Dorsal View)

NOTE: Generally in domestic mammals, the right principal bronchus divides into four lobar bronchi (to cranial, middle, caudal & accessory lobes), while the left gives rise to two lobar bronchi (to cranial & caudal lobes).

There are right side exceptions: the horse lacks a middle lobe; (humans lack an accessory lobe;) in ruminants and swine the right cranial lobe is supplied by a tracheal bronchus.

Lungs:

- The endoderm-lined bronchial tree grows into splanchnic mesoderm which forms the cartilage, fascia, smooth muscle, and vessels of the lung.

- Continued branching of the bronchial tree results in lung tissue, coated by visceral pleura, occupying more and more of the pleural cavity.

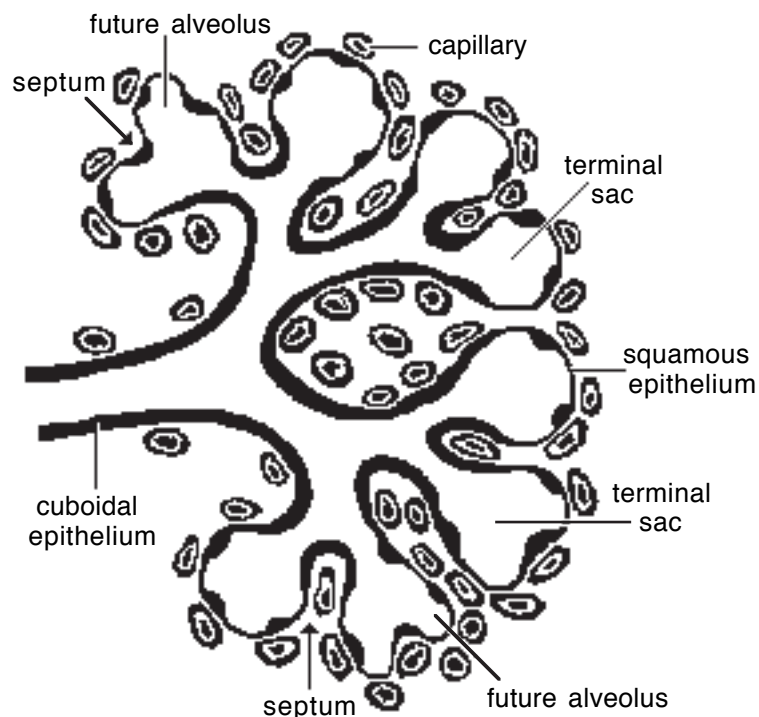
- Initially, as they grow into splanchnic mesoderm, the bronchiole-lung branches are solid cores of cells (growth is like exocrine gland growth into mesoderm). Eventually, terminal branches become hollow, dilated, and sac-like with endoderm becomes a thin epithelium (*terminal sacs*).

- *Alveoli* are created by the formation of septae that partition the terminal sacs.

- Some endodermal alveolar cells become cuboidal rather than flat and produce a phospholipid surfactant that reduces surface tension and thus facilitates alveolar expansion (as opposed to alveolar collapse). Fetal lungs contain fluid that facilitates the breathing movements that take place *in utero* to prepare for postnatal respiration. At birth, lung fluid drains or is absorbed as air is breathed.

NOTE: Species differ in degree of lung maturity at birth. Also, within a single lung, distal regions are less mature than proximal ones. Formation of new alveoli occurs post-natally to a considerable extent in all mammals. Subsequently, lung growth is due to hypertrophy (increased size) of alveoli and air passageways.

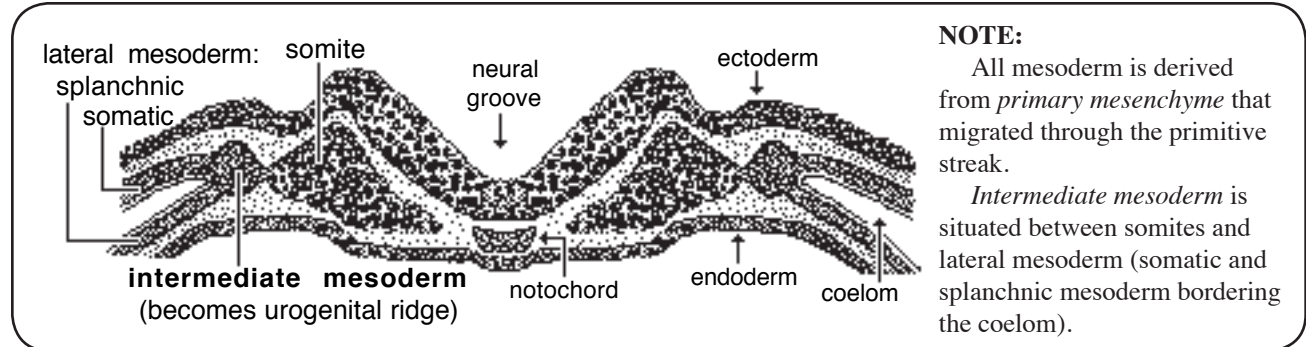
Alveolar Formation



Urinary System

NOTE: Urine production requires an increased capillary surface area (glomeruli), epithelial tubules to collect plasma filtrate and extract desirable constituents, and a duct system to convey urine away from the body.

Intermediate mesoderm:



Intermediate mesoderm (including adjacent coelom mesothelium) forms a *urogenital ridge*, consisting of a laterally-positioned *nephrogenic cord* (that becomes kidneys & ureter) and a medially-positioned *gonadal ridge* (for ovary/testis & female/male genital tract formation).

Urinary & genital systems have a common embryonic origin; also, they share common ducts.

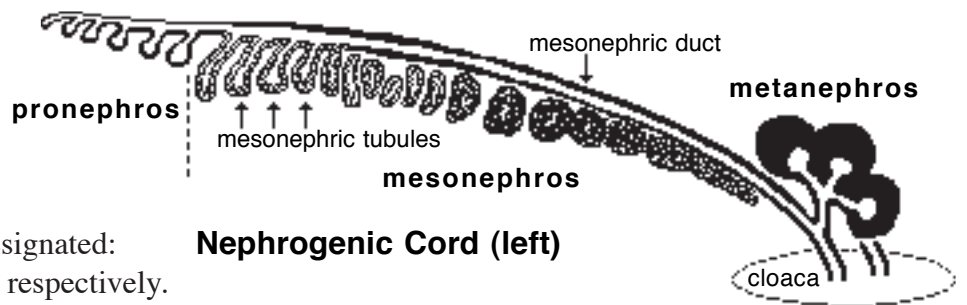
Kidneys:

- three kidneys develop chronologically, in cranial-caudal sequence, from each bilateral *nephrogenic cord*

- the three kidneys are designated: *pro*—, *meso*—, and *meta*—, respectively.

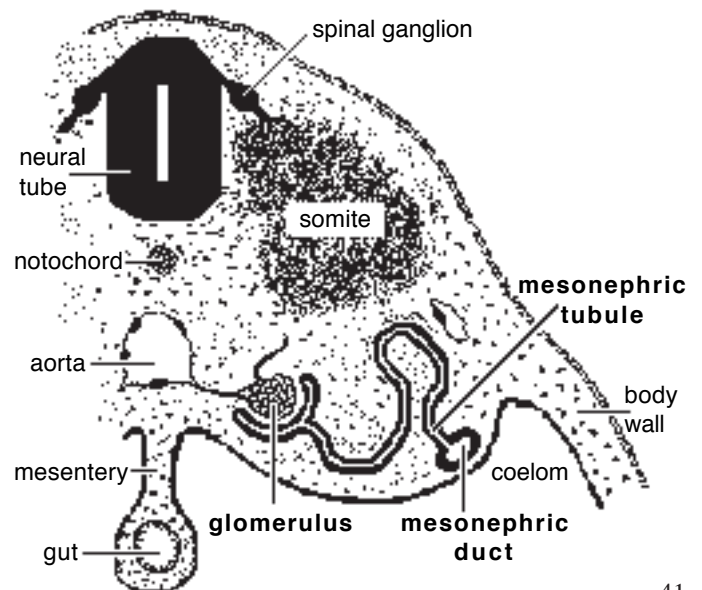
- the *pronephros* and *mesonephros* have a similar development:
 - nephrogenic cord mesoderm undergoes segmentation,
 - segments become tubules that drain into a duct
 - eventually the tubules disintegrate.

1] **Pronephros**—consists of (7-8) primitive tubules and a *pronephric duct* that grows caudally and terminates in the cloaca. The tubules soon degenerate, but the pronephric duct persists as the *mesonephric duct*.



NOTE

- The *pronephros* is not functional, except in sheep.
- The *mesonephros* is functional in only some mammals (related to placental layers). However, the *mesonephros* becomes the functional kidney of adult fish & amphibians.
- The *metanephros* becomes the functional kidney of adult reptiles, birds, & mammals.
- Although kidneys may be functional *in-utero*, they are not essential because the placenta is able to remove toxic agents from fetal blood.



2] Mesonephros:

- consists of (70-80) tubules induced to form by the *mesonephric duct* (former pronephric duct)
- one end of each *tubule* surrounds a glomerulus (vascular proliferation produced by a branch of the dorsal aorta)
- the other end of the tubule communicates with the mesonephric duct
- eventually, the mesonephros degenerates, but the *mesonephric duct* becomes *epididymis* & *ductus deferens* and some tubules that become incorporated within the testis.

3] Metanephros:

- becomes adult kidney & ureter of mammals, birds, and reptiles
- originates in the pelvic region and moves cranially into the abdomen during embryonic differential growth
- lobulated initially but becomes smooth in most species.

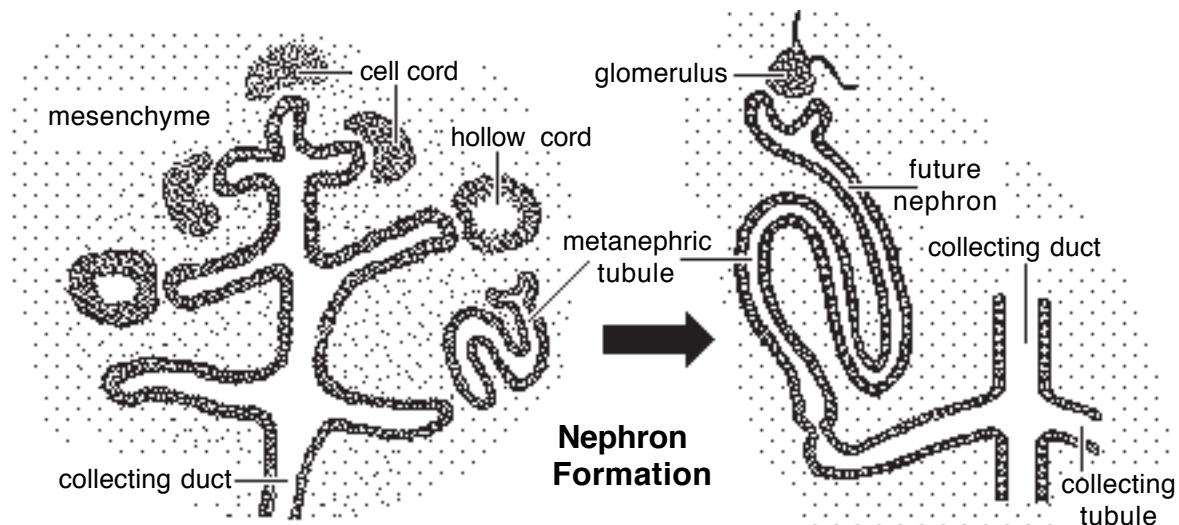
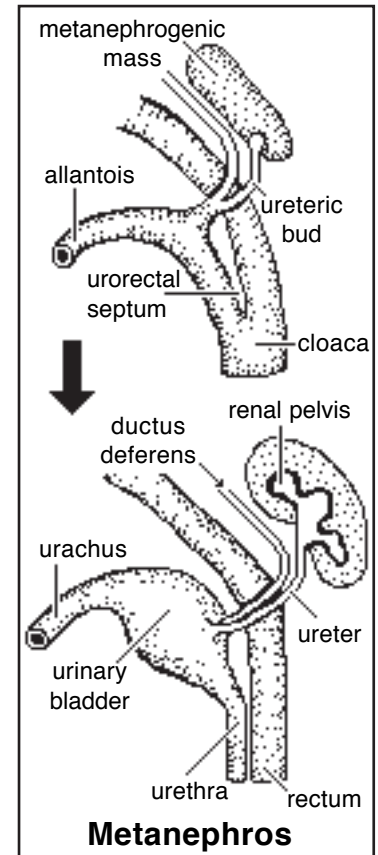
The *metanephros* originates from two sources:

- 1] a *ureteric bud*, which grows out of the mesonephric duct near the cloaca; the bud develops into the *ureter*, *renal pelvis*, and numerous *collecting ducts*;
- 2] *metanephrogenic mass*, which is the caudal region of the nephrogenic cord; the mass forms *nephrons*.

Note: The *neural tube* induces the *ureteric bud* to grow into the *metanephrogenic mass*. The bud induces development of metanephrogenic mesoderm; in turn, the mass induces the cranial end of the ureteric bud to differentiate into renal pelvis and collecting tubules—the tubules induce the metanephrogenic mass cells to form nephrons.

Nephron formation...

- adjacent to collecting tubules, mesodermal cells of the metanephrogenic mass proliferate and form cell cords
- the cords canalize and elongate, becoming S-shaped metanephric tubules that eventually become nephrons
- one end of each metanephric tubule expands to surround a capillary glomerulus (forming a glomerular capsule)
- the other end of the tubule must establish communication with a collecting tubule
- between the two ends, each metanephric tubule differentiates into regions characteristic of a *nephron* (proximal segment, thin loop, distal segment).



NOTE: Nephrons develop from deep to superficial in the kidney. Many of the early nephrons subsequently degenerate as a normal occurrence. Nephrons continue to form and mature postnatally (except in the bovine); thereafter, nephrons cannot be replaced if they are damaged.

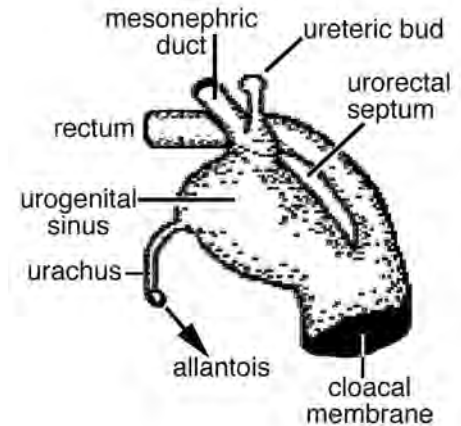
Urinary Bladder and Urethra

A *urorectal septum* divides the *cloaca* into:

- dorsally, a **rectum**, **anal canal** & **anal membrane**, and
- ventrally, a **urogenital sinus** and **urogenital membrane**

The membranes subsequently degenerate, resulting in an **anus** and a **urogenital orifice**, respectively.

Cranially, the *urogenital sinus* connects with the *urachus*, the intra-embryonic stalk of the allantois.



Urinary bladder...

- develops from the cranial end of the *urogenital sinus* and the adjacent region of *urachus*
- growth expansion results in separate openings of the *mesonephric duct* and *ureter* into the dorsal wall of the urogenital sinus
- differential growth of the dorsal wall results in mesonephric duct and ureter openings being switched cranio-caudally, creating a **trigone region** (that anchors ureters to the bladder & urethra)

Urethra...

- develops from the urogenital sinus, caudal to the urinary bladder
- urethra development is gender specific:
 - females: the mid region of the urogenital sinus becomes **urethra**. (The caudal region of the urogenital sinus become vestibule and the vagina grows out of the vestibule wall.)
 - males: the **pelvic urethra** develops from the mid region of the urogenital sinus and the **penile urethra** develops from elongation of the caudal end of the urogenital sinus.

NOTE: In the fetus, urine is discharged into the allantoic cavity through the urachus and into the amniotic cavity through the urogenital orifice.

Abnormalities of urinary development include:

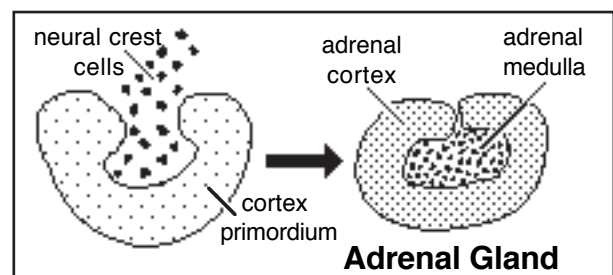
- Hydronephrosis (cystic/polycystic kidneys) may result from ureteric atresia or from failure of nephrons to communicate with collecting tubules.
- Patent urachus (urachal fistula) results from a failure of the allantoic stalk to close at birth; & vesicourachal diverticulum (urachus persists as a bladder pouch, predisposing to chronic cystitis).
- Ectopic ureter, where the ureter opens into the urethra or vagina instead of the bladder; a source of incontinence because urine is delivered beyond urinary sphincters.

Adrenal Cortex

NOTE: The adrenal gland consists of an **adrenal medulla** and an **adrenal cortex** that are embryologically, histologically, and functionally different, even though they are combined anatomically.

The **adrenal medulla** is derived from *neural crest* (ectoderm).

The **adrenal cortex** arises from cells of *mesonephric tubules* that dissociate and migrate to the location of the adrenal gland after the mesonephros degenerates.



Genital System

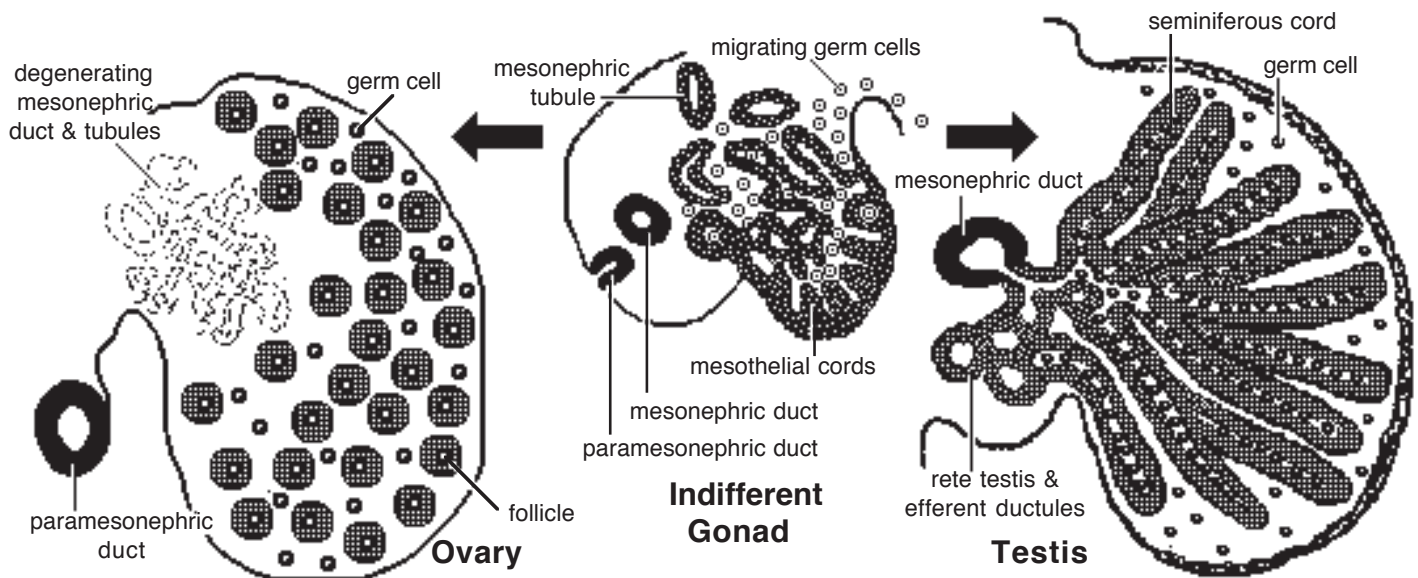
Gender **genotype** is inherited, but gender **phenotype** is a consequence of hormones released during embryonic development, by the gonad determined by genotype.

Genital development involves transition through an *indifferent stage* in which gonads, genital ducts and external features are the same in both sexes. Thus, many genital anomalies involve some combination of intersex development and appearance.

Gonads

Indifferent stage:

- the gonad originates from the *gonadal ridge*, a thickening of intermediate mesoderm plus coelomic mesothelium that develops medial to the mesonephric kidney.
- the gonad is composed of germ cells and supporting cells:
 - *supporting cells* form cellular cords (*gonadal cords*) that radiate into the gonadal ridge, the cells arise from invading mesothelium and disintegrating mesonephric tubules
 - *germ cells* arise from yolk sac endoderm, they migrate along the gut wall and mesentery to reach the gonadal ridge. Their arrival induces further gonadal development.
- germ cells proliferate and must migrate inside gonadal cords so they are surrounded by supporting cells (germ cells that fail to enter gonadal cords suffer degeneration).



Testis:

- gonadal cords hypertrophy and are called *seminiferous cords*
- germ cells within seminiferous cords differentiate into *spermatogonia* and become dormant.
- at puberty, seminiferous cords become canalized, forming *seminiferous tubules*, and spermatogonia initiate *spermatogenesis* (deep cords that lack germ cells become tubules of the *rete testis*, located centrally in the testis).
- supporting cells differentiate into *sustentacular (Sertoli) cells* and *interstitial cells*:
 - *sustentacular cells*, located in walls of seminiferous tubules, secrete inhibitory factors that suppress both spermatogenesis and female duct development (paramesonephric duct)
 - *interstitial cells*, located outside seminiferous tubules, become two populations: one produces androgen hormones immediately, the other population delays androgen production until sexual maturity (androgens stimulate male genitalia development)
- mesothelium covering the testis becomes visceral peritoneum; mesenchyme deep to the mesothelium becomes the tunica albuginea of the testis.

Ovary:

- *gonadal cords* undergo reorganization such that individual germ cells become surrounded by a sphere of flat supporting cells, thus **primordial follicles** are formed
- germ cells (oogonia) differentiate into primary oocytes that commence meiosis, but remain stuck in prophase of Meiosis I (meiosis is not continued until ovulation occurs, as an adult)
- follicle and germ cell proliferation is completed *in utero*, the lifetime allotment of primary oocytes is already present in the neonatal ovary.

NOTE: Because they fail to become incorporated within follicles, 90% of the germ cells complete meiosis and then degenerate (to reduce degeneration, meiosis onset is delayed in the embryos of species having longer gestations).

Genital Ducts | Accessory Glands | Ligaments

Indifferent stage:

- both sexes have male (*mesonephric*) and female (*paramesonephric*) genital ducts and a *urogenital sinus*
 - the *mesonephric* (Wolffian) *duct* persists after the mesonephros disintegrates
 - a *paramesonephric* (Mullerian) *duct* develops along the ventrolateral coelomic surface of the mesonephros (it begins as a groove, then becomes a core of cells, and subsequently it canalizes and elongates)
 - testicular hormones determine which duct system develops:

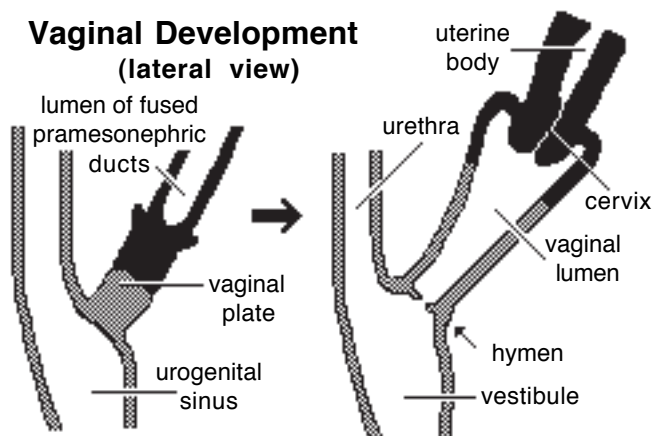
male duct development requires testosterone, produced by interstitial cells;

female duct development is suppressed by an inhibitory hormone released by sustentacular cells.

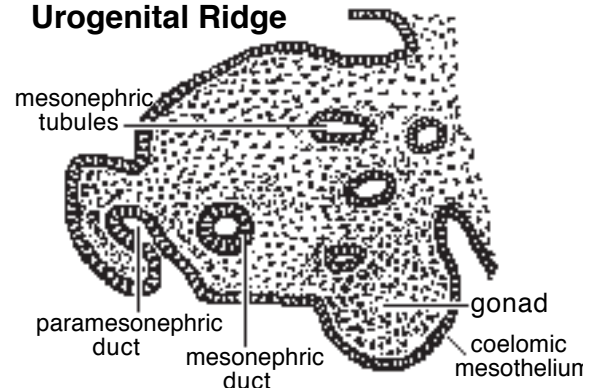
Females:

- in the absence of testosterone, mesonephric ducts fail to develop (remnants may be found in the wall of the vestibule).
- the cranial region of each paramesonephric duct remains open and forms the future *uterine tube*
- caudal to the level of the inguinal fold (gubernaculum), each paramesonephric duct becomes a *uterine horn*.

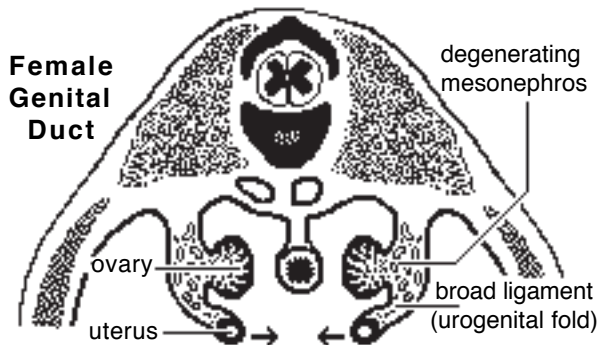
Vaginal Development (lateral view)



Transverse Section through Urogenital Ridge



Female Genital Duct



- further caudally, bilateral paramesonephric ducts shift medially and fuse into a single tube that ends blindly in contact with the urogenital sinus. The fused ducts become: *uterine body*, *uterine cervix*, and the cranial third of the *vagina*.

NOTE: The degree of paramesonephric duct fusion is species dependent. Among domestic mammals, fusion is greatest in the horse and least in carnivores. In primates (women) fusion normally produces a uterine body without horns. In contrast, rodents and the rabbit have a double uterus (two cervixes enter a single vagina). Monotremes and many marsupials have a double vagina (no fusion at all).

The *vagina* has a dual origin:

- the cranial one-third comes from fused *paramesonephric* ducts.
- the caudal two-thirds comes from an outgrowth of the future *vestibule*, as follows:
 - at the site where the fused paramesonephric ducts contact the urogenital sinus, a solid tubercle, the *vaginal plate*, grows outward from the future vestibule
 - degeneration of the center of the solid tubercle creates the vaginal lumen.
 - a hymen may persist where the vagina joins urogenital sinus.

Males:

- paramesonephric ducts regress due to an inhibitory hormone produced by sustentacular cells of the testis (duct remnants are often evident in the adult male horse as a uterus masculinus).

- several *mesonephric tubules* become *efferent ductules* (they already communicate with the mesonephric duct but must establish communication with the rete testis tubules)

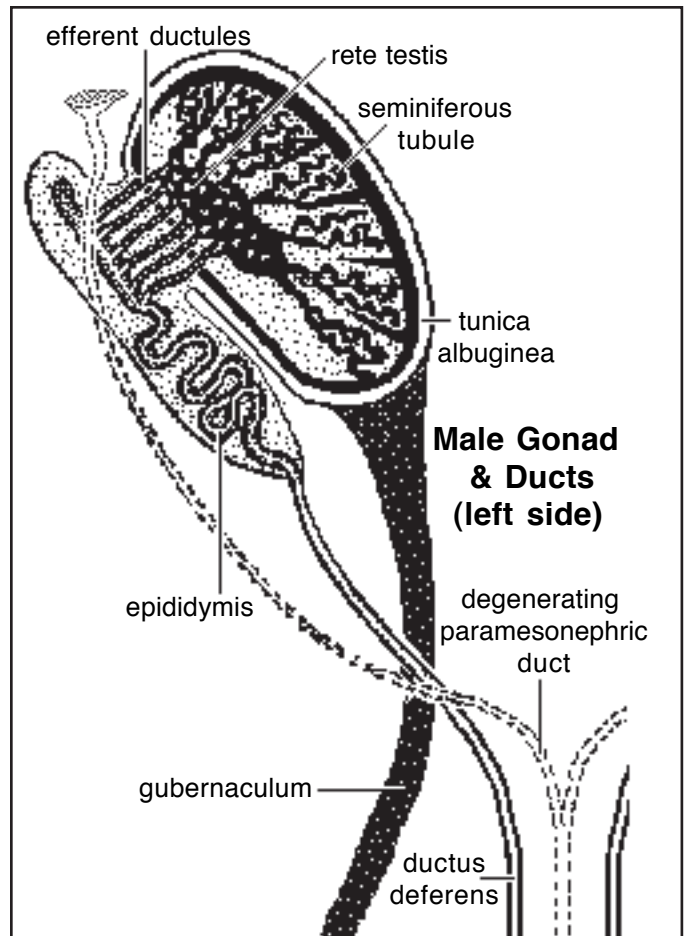
- the cranial region of the *mesonephric duct* undergoes extensive elongation and coiling to become the *epididymis*; the remainder of the duct enlarges and becomes *ductus deferens*

- the mesonephric duct (ductus deferens) empties into the region of urogenital sinus that becomes *pelvic urethra*.

Glands. *Prostate* and *bulbourethral glands* develop in typical gland fashion by outgrowths of *urogenital sinus endoderm*. (Vestibular glands are female homologues of male bulbourethral glands.) Vesicular glands (seminal vesicles) arises as an epithelial outgrowth from the caudal region of the mesonephric duct (mesoderm). Gland smooth muscle comes from surrounding mesenchyme.

Descent of the testis:

- a *gubernaculum* is produced by condensation of mesenchyme within the inguinal fold, which runs along the body wall linking the gonad to the inguinal region
- the gubernaculum accumulates fluid and become a gel mass as large in diameter as a testis (under the influence of gonadotropins and testicular androgens)
- the swollen gubernaculum preclude closure of the body wall, and is responsible for formation of the inguinal canal and vaginal process (coelom evagination)
- subsequent outgrowth of the scrotal wall and dehydration of the gubernaculum passively pulls the testis to the inguinal canal
- a sudden increase in intra-abdominal pressure can pop it through the canal into the scrotum.



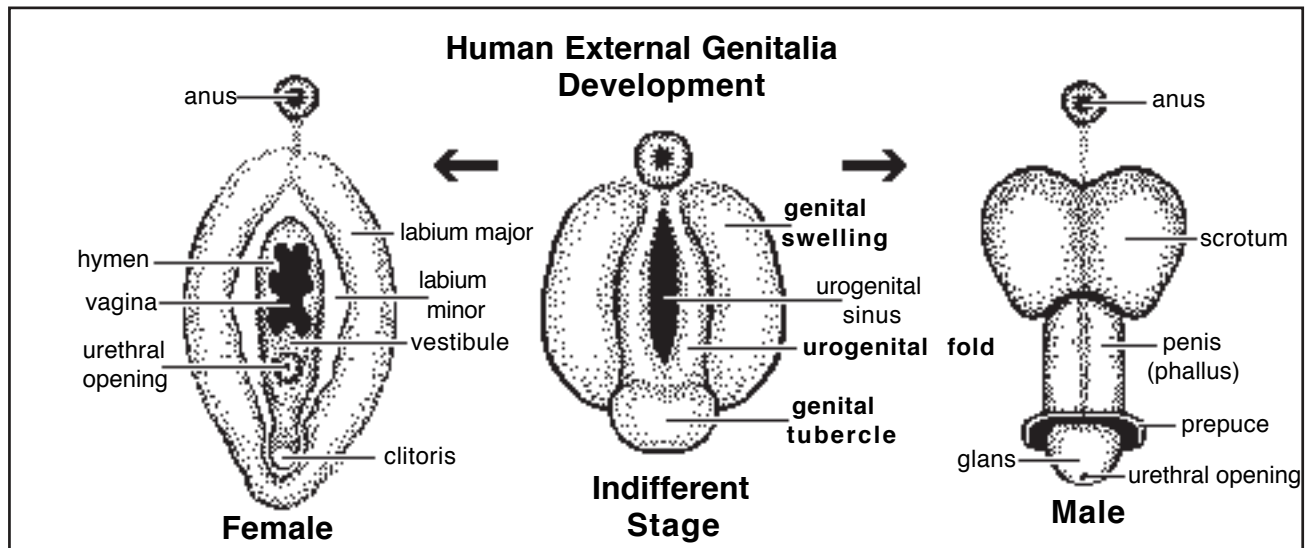
NOTE: In both genders, there is some caudal shift of the gonad from its original position, due to elongation of the body and a variable degree of retention by inguinal fold derivatives that pull on the gonad.

In females, the ovary remains intra-abdominal and the extent of caudal shift is species dependent (e.g., slight in the bitch vs. descent into the pelvis in the cow).

In males, each testis descends to the inguinal region (scrotum).

Genital Ligaments:

- when the *mesonephros* degenerates, it leaves behind a *genital fold* that persists to suspend the gonad and genital duct system
- the caudal extension of the genital fold that runs along the body wall and into the inguinal region is called the *inguinal fold* and it gives rise to the *gubernaculum* of the fetus
- the genital and inguinal folds become male & female genital ligaments:
 - females: the *genital fold* becomes the **broad ligament** (*suspensory ligament of the ovary*, *mesovarium*, *mesosalpinx*, and *mesometrium*); the *inguinal fold* becomes the **proper ligament of the ovary** and **round ligament of the uterus**
 - males: the *genital fold* becomes *mesorchium* and *mesoductus deferens*; the *inguinal fold* becomes the *gubernaculum* and the adult **proper ligament of the testis** and **ligament of the tail of the epididymis**.



External Genitalia

Indifferent stage:

- external genitalia are derived from three different perineal swellings:
 - bilateral *urogenital folds* border the *urogenital orifice* and elongate ventrally (Urogenital folds are the caudal end of the urogenital sinus.)
 - a *genital tubercle*, develops at the ventral commissure of the urogenital folds
 - bilateral *genital (labioscrotal) swellings* are located lateral to the urogenital swellings (in domestic mammals these persist only in males, unlike primates, where the swellings develop in both sexes, forming major labia in females and scrotum in males).

Males:

- growth at the base of the *genital tubercle* generates an elongate **phallus** with the original genital tubercle becoming **glans** at the tip of the phallus
- the *urogenital orifice* and *urogenital folds* elongate ventrally along with the attached phallus; the folds form a urogenital groove and the **penile urethra** is created when the groove closes by medial merger of urogenital folds in proximal to distal sequence.
- the opening at the distal end of the penile urethra, within the original *genital tubercle*, is created by ectoderm invasion and canalization which establishes communication between the ectoderm exterior and the endoderm interior of the penile urethra
- genital tubercle mesenchyme gives rise to penile erectile tissue, tunica albuginea, smooth muscle, and bone (carnivores).

- **prepuce** is formed when a ring of surface ectoderm invades into the mesenchyme of the free end of the phallus, dividing tissue into a penis encircled by preputial skin. (Except in the cat, the phallus of domestic mammals elongates deep to the skin of the ventral body wall.)

- **genital swellings** enlarge and merge at the midline to form a single **scrotum** (with two compartments). The scrotum initially overlies the gubernaculum and vaginal process in the inguinal region, and then it generally shifts cranially (except that it remains caudal in the cat and pig).

Females:

- **urogenital orifice** becomes the **vulval cleft**, which opens into the **vestibule** (*urogenital sinus*)
- the **genital tubercle** becomes the **clitoris**
- **urogenital folds** elongate, overgrow the genital tubercle, and become **labia** of the vulva
- **genital swellings** disappear in female domestic mammals (but become major labia in primates).

Mammary Glands

In both genders, a mammary ridge (line) of thickened ectoderm forms bilaterally from the axillary region to the inguinal region.

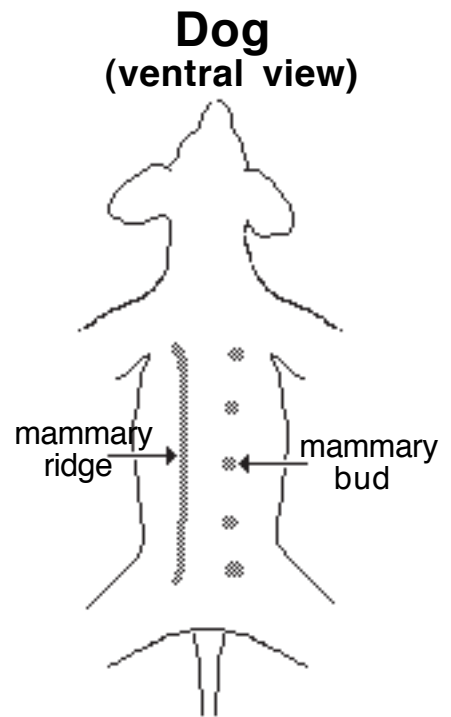
Mammary buds develop periodically along the ridge; elsewhere, mammary ridge ectoderm regresses. Buds determine the number and locations of mammary glands, since each bud develops into a *mammary gland* (2, sheep, goat, mare; 4 cow; 8, queen; 10, bitch; 14; sow).

At each mammary bud, ectoderm induces proliferation of underlying mesoderm and mesoderm induces epithelial cell proliferation (teat formation).

Epithelial cell solid cords invade underlying mesoderm and eventually canalize to form epithelial lined lactiferous ducts. The number of cell cord invasions and subsequent lactiferous duct systems per teat is species dependent (approximately: 1, sheep, goat, cow ; 2 mare sow; 6, queen; 12, bitch).

In some cases, multiple lactiferous ducts open into a pit (inverted nipple) that becomes a nipple following proliferation of underlying mesoderm.

It is common for extra buds develop and degenerate, failure to degenerate results in supernumerary teats.

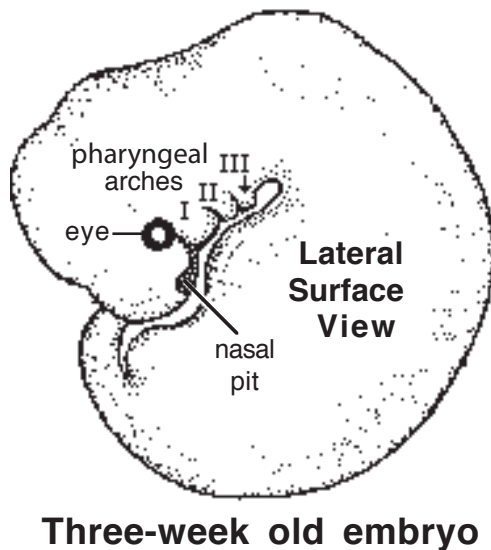
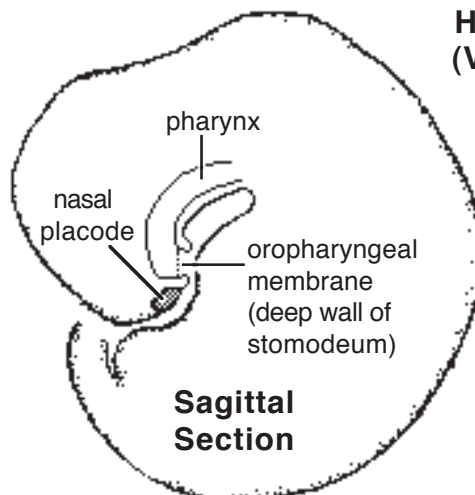


Pharynx, Face, Nasal Cavity & Mouth

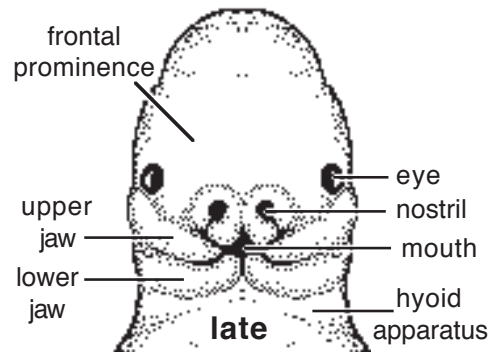
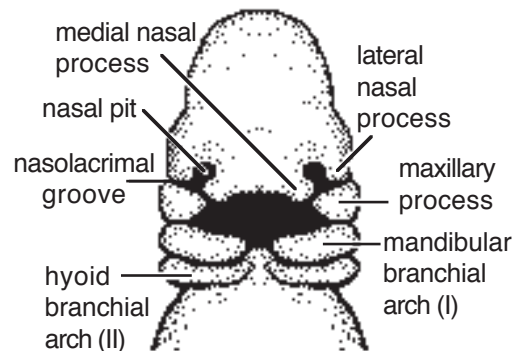
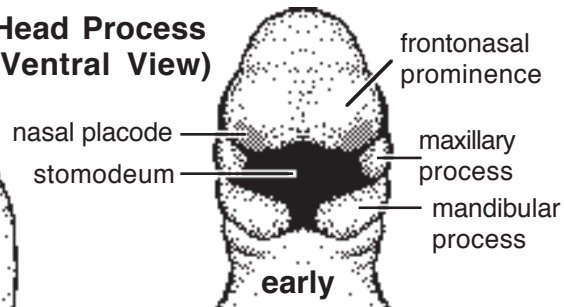
Note: The **head** consists of a **face** and **cranium**. The cranium (formed by the head process) houses the brain, eyes, and pharynx. The face (formed later by outgrowth) contains the mouth and nasal cavity. Because the face develops separately, and it can undergo wide variation in shape & size, as seen in dogs.

Pharynx:

- the embryonic pharynx is the anterior end of the *foregut*, it arises during head process and lateral body fold formation when the embryo becomes cylindrical.
- the pharynx is bounded externally by *pharyngeal arches*; the arches are demarcated externally by pharyngeal clefts and internally by expansions called *pharyngeal pouches*
- initially the pharynx is closed anteriorly by an *oropharyngeal membrane* (composed of pharyngeal endoderm and surface ectoderm); following growth of the *stomodeum* (mouth) the oropharyngeal membrane must degenerate to permit communication
- six pair of pharyngeal arches develop (only three are evident, 5 atrophies and 4 & 6 combine)
- each arch contains an aortic arch vessel, ectomesenchyme from neural crest, myotomes from somites/somitomeres, innervation from one cranial nerve
- pharyngeal arches contribute to the formation of: jaws, larynx, hyoid bones, and head muscles.



Head Process (Ventral View)



More Pharyngeal Arch Products

- Mesenchyme within pharyngeal arches (and the frontonasal prominence) is *ectomesenchyme*, derived from neural crest. Ectomesenchyme forms fascia and *intramembranous bone* of the *face* and *calvaria*. (In contrast, bones along the floor of the skull develop endochondrally from occipital somite sclerotomes.)

- Skeletal muscle of the head is derived from *somite* or *somitomere* myotomes that migrate into pharyngeal arches (or the frontonasal prominence). In general, each pharyngeal arch is innervated by one cranial nerve and that nerve supplies all muscles derived from the arch:

Arch I -- mastication muscles (V nerve);

Arch II -- facial muscles (VII nerve);

Arch III -- a pharyngeal muscle (IX nerve); and

Arches IV & VI -- muscles of pharynx, larynx, & esophagus (X nerve).

- In fish, pharyngeal arches are called branchial (gill) arches. Tissue separating external clefts and internal pharyngeal pouches degenerates, creating gill slits.

Note: *Somitomeres* originate from paraxial mesoderm located rostral to the notochord and are less developed somites. There are seven pair of somitomeres. They give rise to extraocular, masticatory, facial, and some pharyngeal muscles.

Pharyngeal Pouch Derivatives

1st pouch — — tympanic (middle ear) cavity and auditory tube

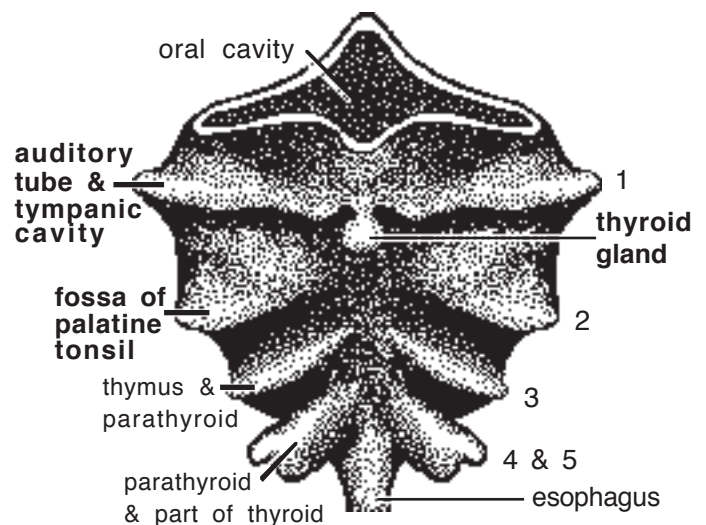
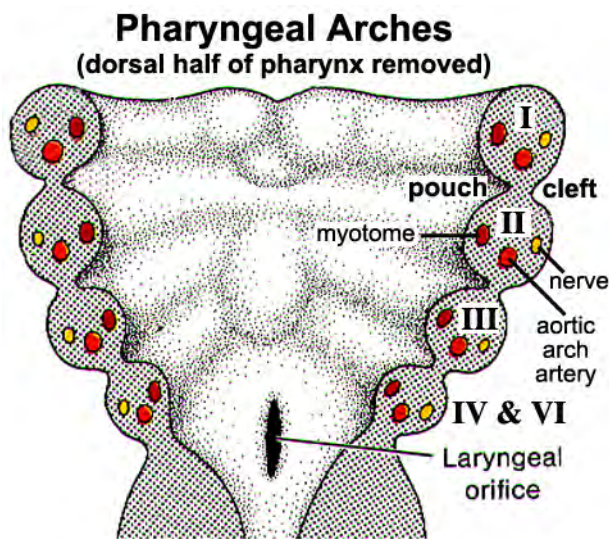
2nd pouch — — fossa for the palatine tonsil and the fold covering it

3rd pouch — — external parathyroid gland and thymus

4th pouch — — internal parathyroid gland

5th pouch — — parafollicular cells of thyroid gland (avian ultimobranchial body)

NOTE: The thyroid gland originates as a single endoderm outgrowth from the floor of the pharynx. Depending on species, the thyroid may remain single (pig) or split into bilateral lobes connected by an isthmus (horse) or become separate paired lobes (dog). The thyroid connection to the pharynx normally degenerates, but rarely a remnant persists as a cyst that can enlarge and interfere with breathing by compressing the pharynx.

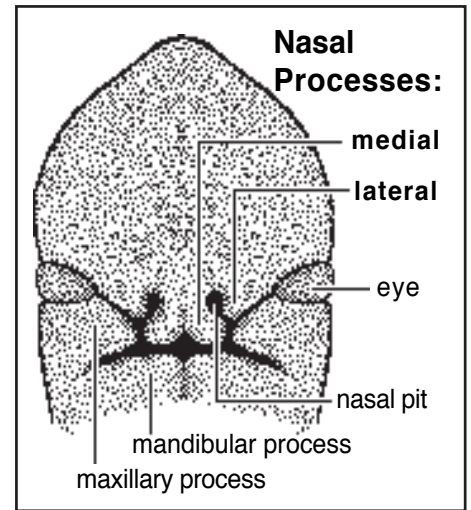


Face:

- the face develops from outward growth of the cranium
- the **lower jaw** and most of the **upper jaw** are formed by growth of the *first pharyngeal arch*
- the **upper incisor** region and the **nose** and **forehead** are formed from the *frontonasal prominence* (ectomesenchyme from neural crest, located rostral to the neural tube)

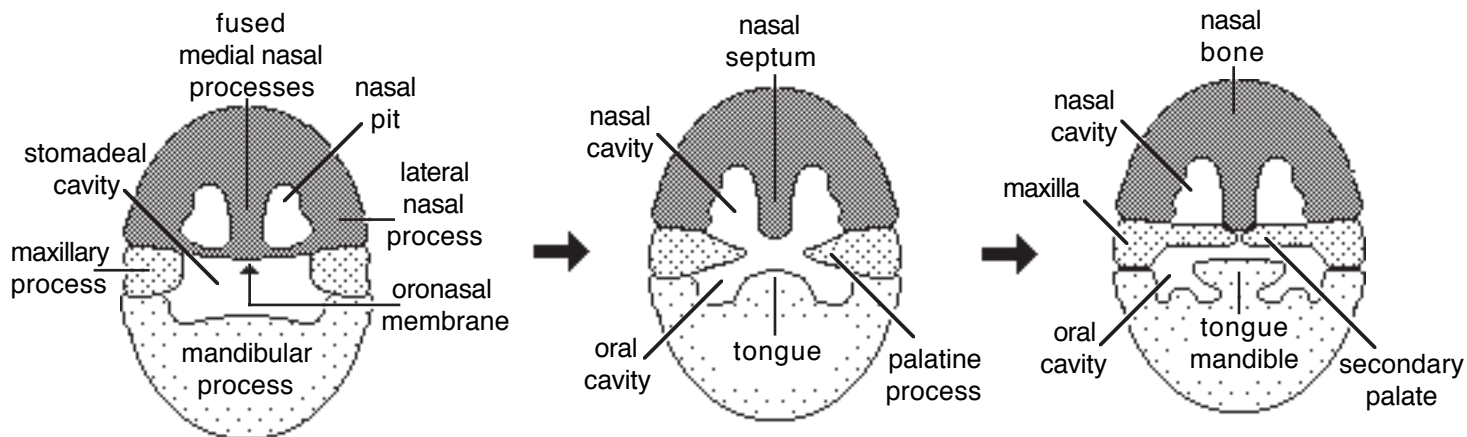
Development proceeds as follows:

- the **first pharyngeal arch** divides into two processes:
 - a ventral *mandibular process* forms the **mandible** and soft tissue of the **lower jaw**; right & left sides fuse to form the **mandibular symphysis**
 - a dorsal *maxillary process* forms most of the **upper jaw**, caudal to incisor teeth
- dorsal to the first pharyngeal arch, the **frontonasal prominence** expands and divides into:
 - a *frontal prominence*, which forms frontal bone of the **forehead**, and
 - *medial & lateral nasal processes*, which form the **nose**, **nasal cavity** & **primary palate**



Nasal cavity:

- Initially, bilateral *nasal placodes* (ectoderm thickenings) appears at the rostral end of the *frontonasal prominence*
- Subsequently, growth of surrounding *medial and lateral nasal processes* establishes bilateral *nasal pits*
- Continued growth of nasal processes produces a primitive **nasal cavity** and subsequent oronasal erosion during growth establishes communication between the nasal & oral cavity.
- Fusion of right and left *medial nasal processes* forms a *primary palate* rostrally and the *nasal septum* caudally:
 - the primary palate becomes **incisive bone**, **upper incisor teeth** and the rostral **upper lip**
 - the **nasal septum** separates right & left halves of the nasal cavity
 - the bilateral rostral openings of the nasal cavity becomes **external nares** (nostrils) and ectomesenchyme surrounding them forms cartilage of the **nose**
- Each *lateral nasal process* give rise to alar cartilage of the **nose**, **nasal bone**, and **lacrimal bone**
- A **nasolacrimal duct** is formed by ectoderm along the seam where the *lateral nasal process* meets the maxillary process of the *first pharyngeal arch*.



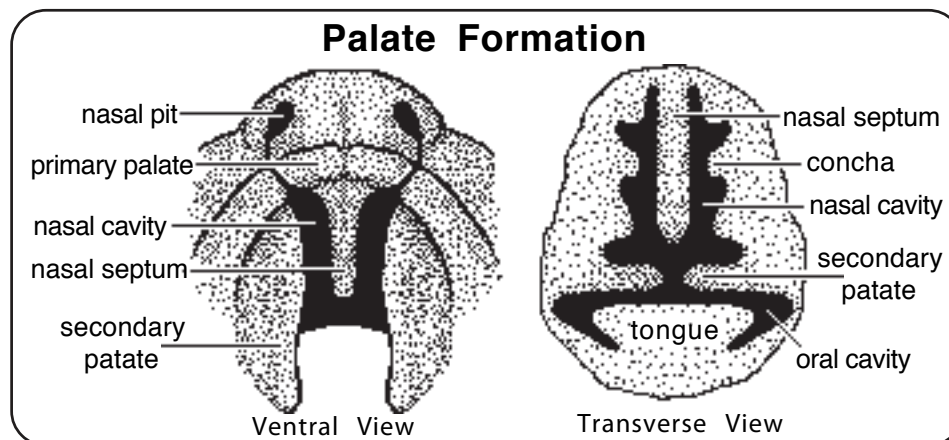
Palates:

- Nasal and oral cavities communicate with one another following erosion of an oronasal membrane that initially separated them.
- In mammals, nasal and oral cavities are again separated by formation of primary and secondary palates that shift the nasal-oral communication caudally into the pharynx.

Two palates are formed:

- the *primary palate*, which becomes *incisive bone*, is formed by *medial nasal processes*
- the *secondary palate* (hard palate) is formed bilaterally by maxillary processes extensions:
 - the extensions (*palatine processes*) meet at the midline, merging dorsally with the nasal septum and rostrally with primary palate
 - caudal extension of the secondary palate (*hard palate*) into the pharynx, creates the *soft palate* which separates the dorsal *nasopharynx* from the ventral *oropharynx*.

- Cleft palate results from failure of the palate to close along the midline, leaving a gap or cleft. The secondary palate is affected more commonly than the primary palate. The condition may be inherited or be the result of exposure to a teratogen (an agent that causes birth defects). Cleft palate is often fatal in animals due to inability to suckle or because of aspiration of milk into the lungs (aspiration pneumonia).
- Failures of medial nasal process fusion (primary cleft palate), produces hare lip (cheiloschisis) and related defects. (Hare lip alone is normal in hares, sheep, etc.).



Conchae:

- Conchae (turbinates) are thin bone scrolls covered by mucosa within the nasal cavity.
- Conchae originate bilaterally as cartilaginous ridges of bones that form the nasal cavity wall.

Paranasal sinuses:

- Sinuses arise as epithelial lined diverticula of the lining of the nasal cavity; the extent of sinus development varies with species
- Most of the sinus development occurs postnatally, newborn animals have cute, rounded heads that become angular with age as sinuses develop.

Vomeronasal organ:

- This is a specialized olfactory sense organ located rostrally in the floor of each nasal cavity.
- The organ is produced by an outgrowth of nasal epithelium that forms a caudally-closed tube.

Mouth:

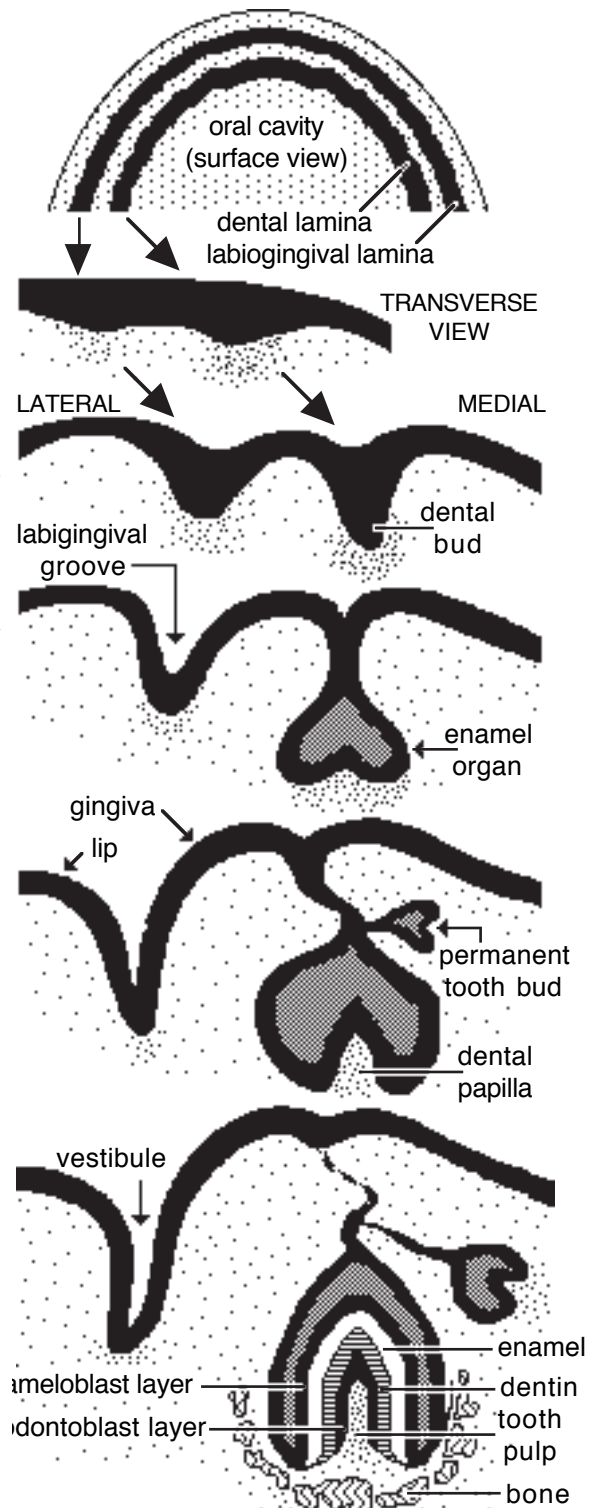
- The mouth (oral cavity) develops as a consequence of upper and lower jaw formation
- The first evidence of an oral cavity is called a *stomadeum*; containing a *stomadeal cavity*.
- The deep boundary of the stomadeum (*oropharyngeal membrane*) is composed of a layer of stomadeal ectoderm apposed to a layer of pharyngeal endoderm; the oropharyngeal membrane becomes fenestrated and disintegrates (the palatoglossal fold marks its location in adults)
- The stomadeal cavity and nasal pits are separated initially by an oronasal membrane that subsequently degenerates so the cavities communicate freely; eventually, palates develops, shifting oral-nasal communication caudally into the pharynx.

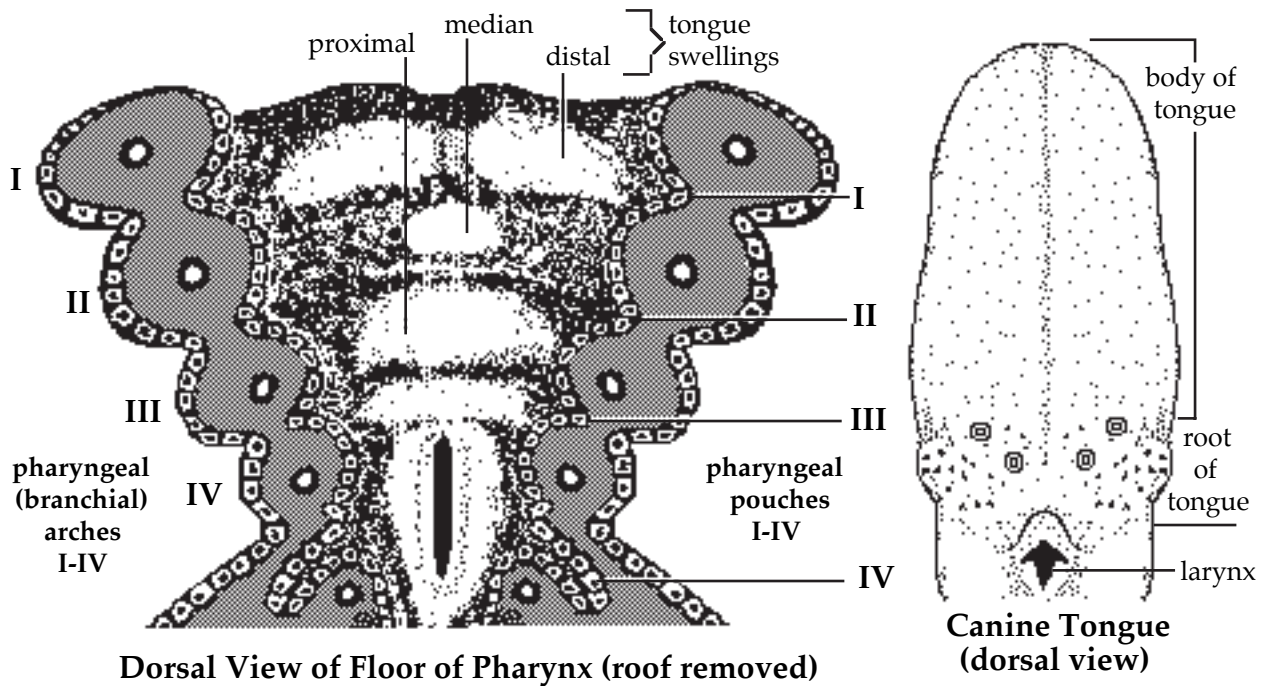
Lips and gingivae:

- An arc of thickened ectoderm, the *labiokingival lamina*, forms in ectoderm lining the stomadeal cavity on upper and lower jaws.
- The lamina invaginates into underlying ectomesenchyme, forming a *labiokingival groove*
- The groove forms the future oral *vestibule*; tissue external to the groove forms *lips* and medial tissue forms *gingivae*.
- Caudal fusion of upper & lower lips forms cheeks.

Teeth:

- The *dental lamina* is an arc of thickened ectoderm, situated inside of the labiokingival lamina
- Periodic thickenings of the lamina produce *dental buds*, which give rise to individual teeth
- If a bud is destined to form a deciduous tooth, then an additional bud for its permanent replacement develops superficial and medial to the deciduous bud
- Each *dental bud* develops into a tooth in the following way:
 - the bud assumes a cup-shaped configuration, becoming an *enamel organ*
 - condensation of ectomesenchyme within the concavity of the cup forms a *dental papilla*
 - the concave epithelial layer of the enamel organ induces ectomesenchyme of the dental papilla to form an epithelial layer of *odontoblasts* that deposit the dentin of the tooth
 - the odontoblasts induce the concave epithelium of the enamel organ to differentiate into *ameloblasts*
 - ectomesenchyme surrounding the enamel organ condenses into a *dental sac* that gives rise to three layers:
 - 1] Outer cells of the dental sac differentiate into osteoblasts that deposit alveolar (tooth socket) bone (osteoclasts re-absorb bone in prior to eruption).
 - 2] Middle layer of the dental sac forms a periodontal ligament (which anchors the tooth within the alveolus).
 - 3] Inner cells of the dental sac become cementoblasts, producing cementum (modified bone) which adheres to the surface of the tooth, particularly the dentin surface of the root of the tooth.





Tongue:

- The tongue develops from four swellings situated on the floor of the pharynx:

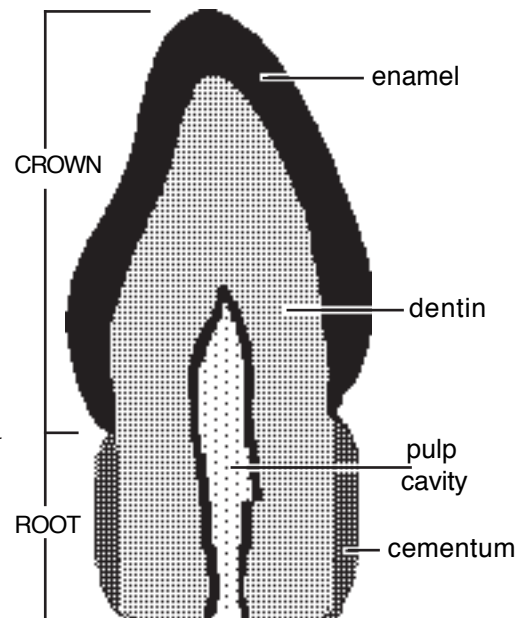
- the **body & apex** of the **tongue** arise from paired **distal (lateral) swellings** in the floor of the pharynx, the swellings fuse along the midline and grow forward into the oral cavity (thereby acquiring an ectodermal covering)

- the **body & apex** of the **tongue** arises predominantly from the **first pharyngeal arch** (general sensation is from the trigeminal nerve, V). The **second pharyngeal arch** also contributes (taste sensation is from the facial nerve, VII).

- the **root** of the **tongue** is formed by the **proximal swelling** and covered by endoderm. It arises from the third pharyngeal arch (sensation is supplied by the glossopharyngeal nerve, IX).

- the **median swelling** contributes significantly to the tongue only in ungulates (especially cattle where it forms a prominent bulge);

- The muscles of the tongue originate from occipital somites (innervated by the hypoglossal nerve, XII).



Salivary glands:

- Salivary glands are derived from **ectoderm** (parotid, zygomatic, and labial and buccal accessory salivary glands) or from **endoderm** (mandibular and mono- and poly-stomatic sublingual salivary glands).

- The process of salivary **gland formation** is typical of exocrine gland development in general:

- surface epithelial cells undergo localized proliferation, forming a cellular cord that invades underlying ectomesenchyme

- the initial site of penetration ultimately becomes the **duct opening** at the surface

- the invading cord of cells begins to branch, ultimately becoming the **main duct** and **branched ducts** of the gland;

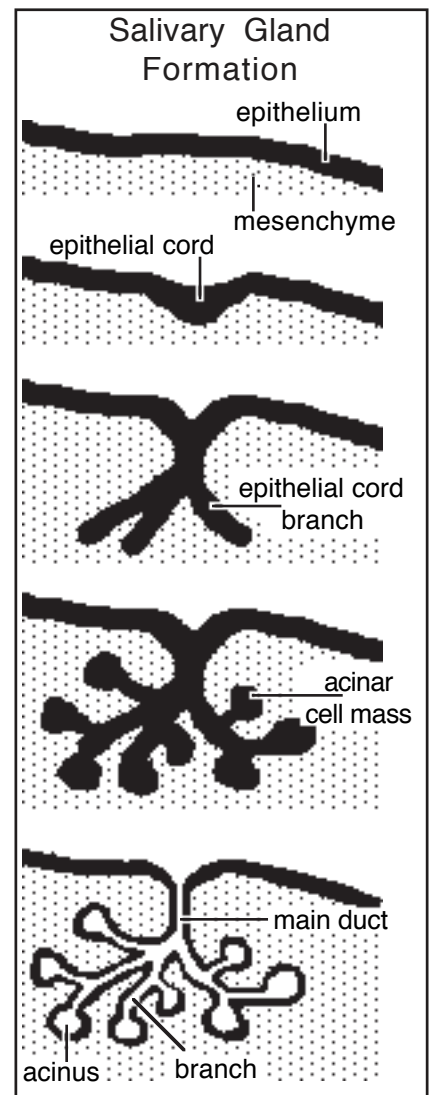
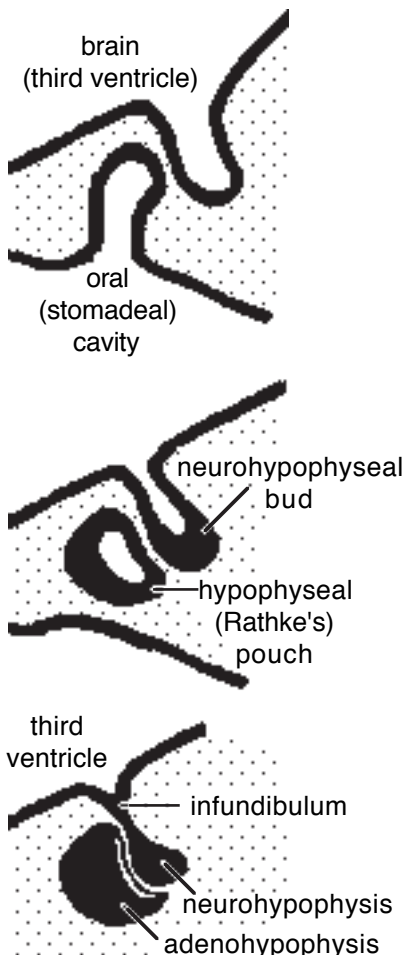
- masses of epithelial cells accumulate at the ends of each branch, forming **secretory acini** of the gland;

— the epithelial cords and masses canalize (become hollow) and the gland becomes functional; growth of the jaw causes elongation of the main duct.

NOTE: A polystomatic gland is one that has many duct openings to the surface. Such glands arise as a series of independent epithelial cords. Although they are independent glands embryologically, they appear to form a single mass and in gross anatomy they are collectively identified as a single gland.

Adenohypophysis:

- The adenohypophysis develops from an ectodermal thickening (*placode*) in the roof of the *stomadeal cavity*.
- The placode evaginates to form an hypophyseal pouch (Rathke's pouch).
- The pouch separates from the stomadeal ectoderm and wraps around the neurohypophysis, an outgrowth of the hypothalamus.
- Depending on species, the cavity of the pouch may persist as a cleft (separating a *pars tuberalis* from a more voluminous *pars distalis* of the adenohypophysis).



NOTE:

The *hypophysis* (pituitary gland) consists of a *neurohypophysis* and an *adenohypophysis*. Both components are controlled by the hypothalamus of the brain.

Hypothalamic neurons must release hormones into the blood stream to control the adenohypophysis.

The neurohypophysis is connected to the hypothalamus by means of an infundibulum. Axons of hypothalamic neurons run through the infundibulum and terminate in the neurohypophysis.

Development of the Nervous System and Special Senses

Neurulation

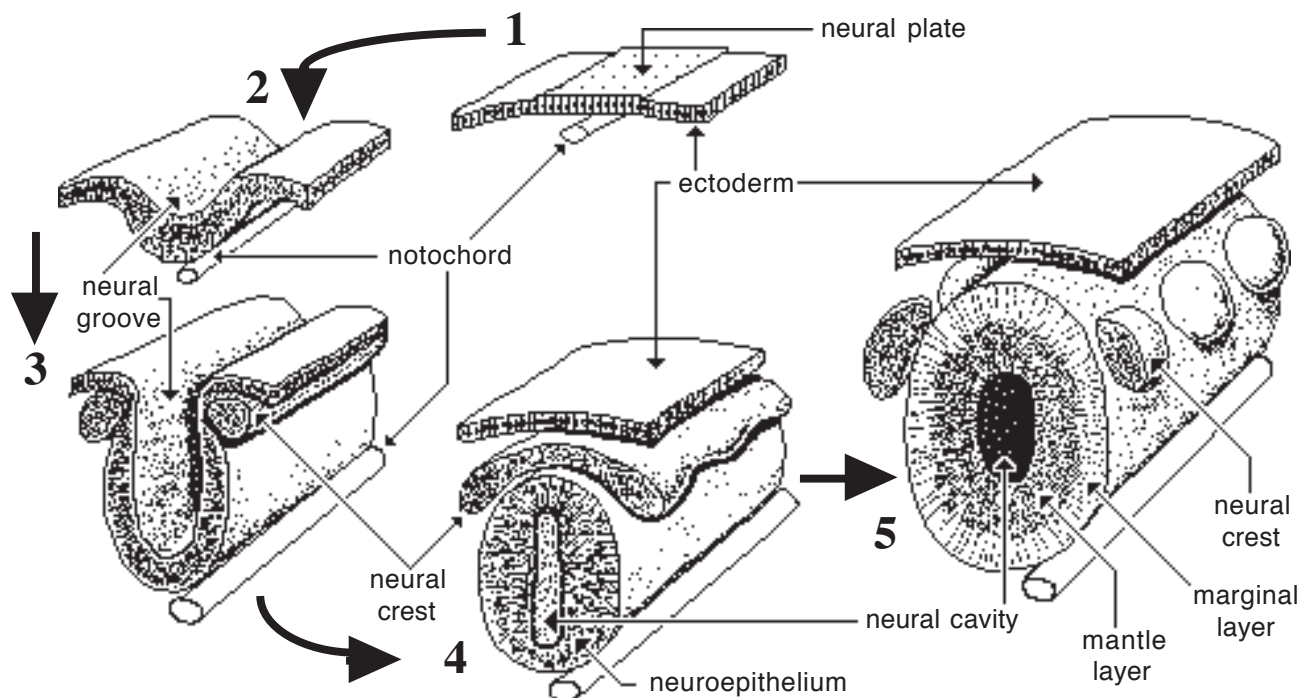
The notochord induces overlying ectoderm to become neuroectoderm and form a neural tube. The following stages of neural tube formation are evident:

- **neural plate**—ectodermal cells overlying the notochord become tall columnar, producing a thickened neural plate (in contrast to surrounding ectoderm that produces epidermis of skin).
- **neural groove**—the neural plate is transformed into a neural groove.
- **neural tube**—the dorsal margins of the neural groove merge medially, forming a neural tube composed of columnar neuroepithelial cells surrounding a **neural cavity**.

In the process of separating from overlying ectoderm, some neural plate cells become detached from the tube and collect bilateral to it, forming **neural crest**.

Note:

- **Neural tube** becomes central nervous system (CNS), which consists of the brain and spinal cord. The cavity of the tube (neural cavity) becomes the ventricles of the brain and central canal of the spinal cord.
- **Neural crest** cells become those neurons of peripheral nervous system (PNS) that have their cell bodies located in ganglia. They also become neurolemmocytes (Schwann cells) of the PNS. Additionally, neural crest cells become adrenal medulla cells, melanocytes of skin and a variety of structures in the face.



Central Nervous System

Formation of neurons and glial cells from neuroepithelium:

Neuroepithelium gives rise to neurons, glial cells (astrocytes and oligodendrocytes), and ependymal cells (additionally, the CNS contains blood vessels and microglial cells derived from mesoderm).

Neuroepithelial cells have processes which contact the inner and outer surfaces of the neural tube; they undergo mitotic division in the following manner:

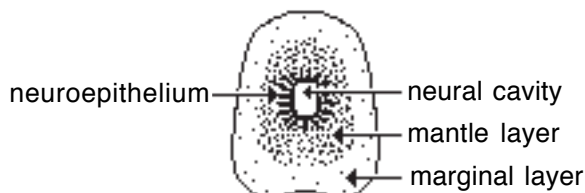
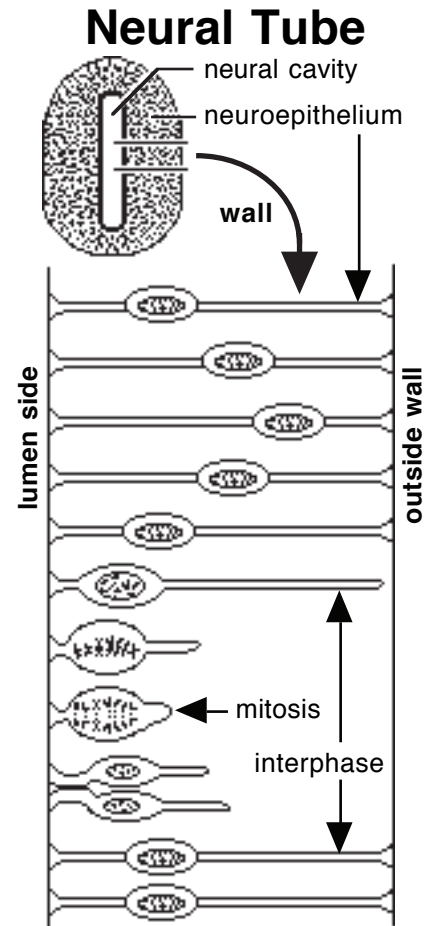
- the nucleus (and perikaryon) moves away from the neural cavity for interphase (DNA synthesis);
- the nucleus moves toward the neural cavity and the cell becomes spherical and loses its connection to the outer surface of the neural tube for mitosis; this inward-outward nuclear movement is repeated at each cell division.

Some cell divisions are differential, producing neuroblasts which give rise to neurons or glioblasts (spongioblasts) which give rise to glial cells (oligodendroglia and astrocytes). Neuroblasts and glioblasts lose contact with surfaces of the neural tube and migrate toward the center of the neural tubewall.

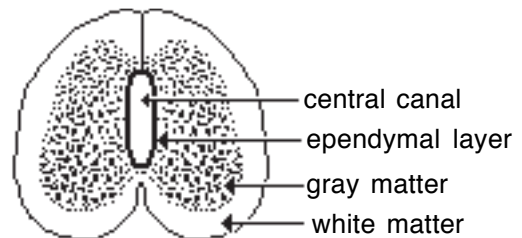
Note: Microglia are derived from mesoderm associated with invading blood vessels.

Layers and plates of the neural tube:

Accumulated neuroblasts and glioblasts form the mantle layer, a zone of high cell density in the wall of the neural tube. Cells that remain lining the neural cavity are designated ependymal cells; they form an ependymal layer. Surrounding the mantle layer, a cell-sparse zone where axons of neurons and some glial cells are present is designated the marginal layer. The mantle layer becomes gray matter and the marginal layer becomes white matter of the CNS.



Neural Tube

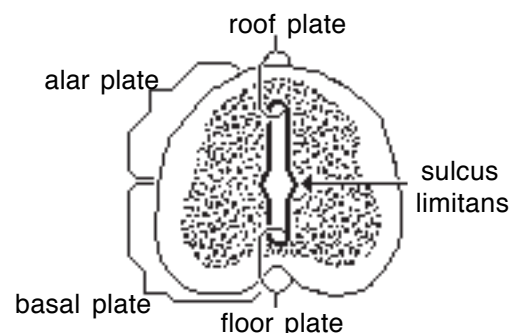


Embryonic Spinal Cord

The lateral wall of the neural tube is divided into two regions (plates). A bilateral indentation evident in the neural cavity (the *sulcus limitans*) serves as a landmark to divide each lateral wall into an *alar plate* (dorsal) and a *basal plate* (ventral). Midline regions dorsal and ventral to the neural cavity constitute, respectively, the *roof plate* and the *floor plate*.

The basal plate contains efferent neurons that send axons into the PNS.

The alar plate contains neurons that receive input from the PNS.



Embryonic Cord Regions

Generally, neurons are incapable of cell division, so all neurons must be formed during nervous system development. However, in hippocampus and olfactory bulb, some stem cells or neuroblasts persist and can give rise to a small number of new neurons postnatally.

Note: • A typical neuron has a cell body (perikaryon) and numerous processes emanating from the cell body. One process, the axon, is generally long and often encased in a *myelin sheath* formed by glial cells. Unstained myelin has a white “color”.
• *White matter* refers to CNS regions that have a high density of myelinated axons. *Gray matter* has sparse myelinated axons and generally a high density of neuron cell bodies.

Sculpting Neuronal Circuits

Sculpting – removing excess material to achieve a desired effect

To ensure that all targets get sufficient innervation, initial neural development produces an excessive number of neurons along with a profuse, random growth of neuronal processes.

Neurons that fail to contact an appropriate target will degenerate and disappear, because they do not receive sufficient neurotrophic molecules. For the same reason, processes of surviving neurons will undergo degeneration if they fail to contact an appropriate target (selective pruning). Neurotrophic molecules are released by target cells to nurture neurons (and by neurons to modify target cells).

Selective degeneration of neurons and neuronal processes is the result of functional competition. More appropriate targets are associated with more excitation conduction and more neurotransmitter release. Thus developmental remodeling is a consequence of electrochemical activity related to experiences/behavior. **Throughout life, experiences drive nervous system remodeling through selective growth and pruning of neuronal synapses.**

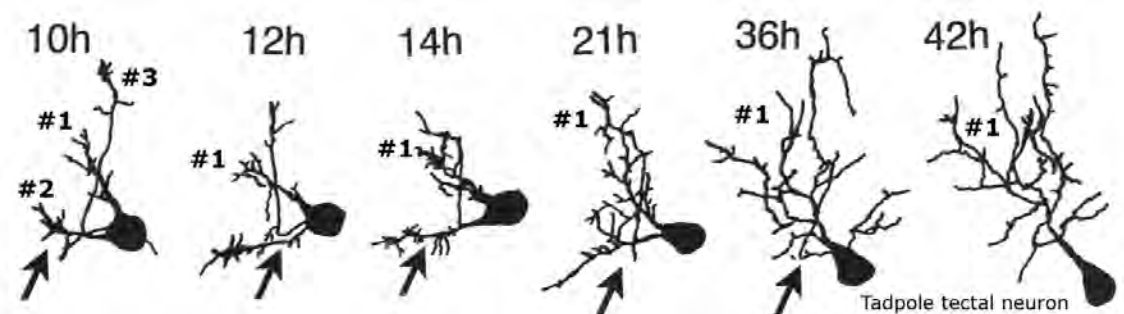
Neuromuscular Innervation

Initially, individual neurons innervate an excessive number of muscle fibers and individual muscle fibers are innervated by a number motor neurons. Ultimately, motor neurons will innervate only about 10% of their initial muscle fibers and individual muscle fibers will retain only a single neuromuscular synapse.

The survivors (winners) released more neurotransmitter per terminal branch. (Neurons having fewer branches are able to release more neurotransmitter per terminal branch, giving them a competitive advantage over neurons with many more processes.)

Neonatal Cortex

In human prefrontal cortex, synaptic density peaks during the first year of age (80K/neuron). The adult has half that synaptic density (and synaptic spine density). (Note: different studies show different timelines for degeneration of neurons and dendrites.)



Formation of the Central Nervous System

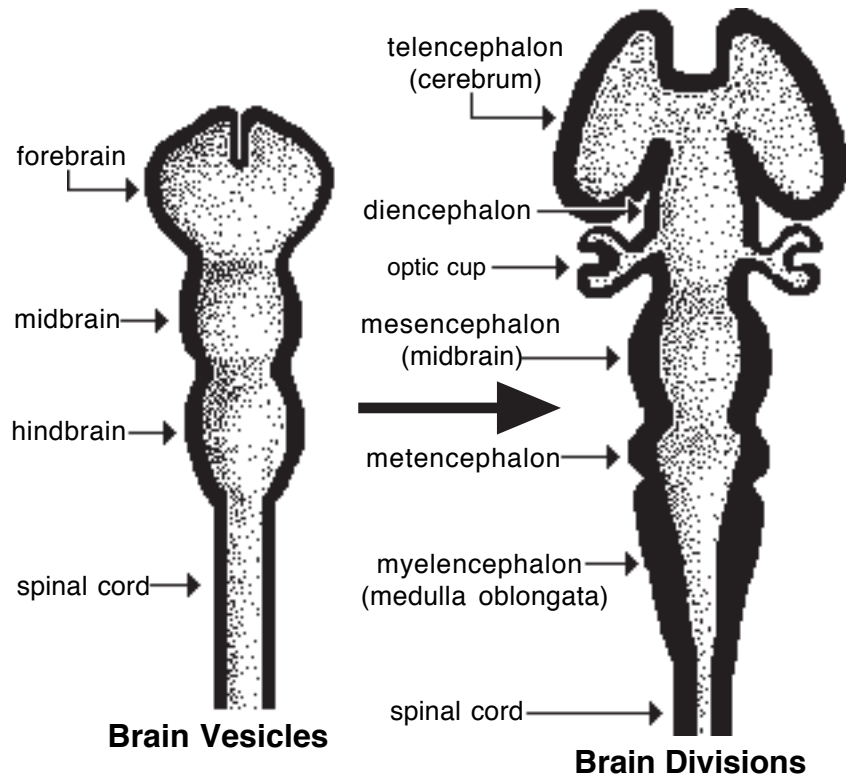
The cranial end of the neural tube forms three vesicles (enlargements) that further divide into the five primary divisions of the *brain*. Caudal to the brain the neural tube develops into *spinal cord*.

Flexures: During development, the brain undergoes three flexures which generally disappear (straighten out) in domestic animals.

The *midbrain flexure* occurs at the level of the midbrain.

The *cervical flexure* appears at the junction between the brain and spinal cord (it persists slightly in domestic animals).

The *pontine flexure* is concave dorsally (the other flexures are concave ventrally).



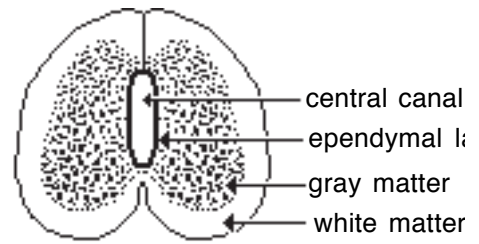
Adult CNS Structures Derived From Embryonic Brain Divisions

Embryonic Brain Division	Derived Brain Structures	Definitive Brain Cavities	Associated Cranial Nerves
FOREBRAIN Telencephalon	Cerebrum	Lateral ventricles	Olfactory (I)
Diencephalon	Thalamus; hypothalamus; etc.	Third Ventricle	Optic (II)
MIDBRAIN Mesencephalon	Midbrain	Mesencephalic aqueduct	III & IV
HINDBRAIN Metencephalon	Pons and Cerebellum	Fourth ventricle	V
Myelencephalon	Medulla Oblongata		VI–XII

Note: The portion of brain remaining after the cerebrum and cerebellum are removed is referred to as the *brain stem*.

Spinal cord development

- the neural cavity becomes *central canal* lined by ependymal cells;
- growth of alar and basal plates, but not roof and floor plates, results in symmetrical right and left halves separated by a ventral median fissure and a dorsal median fissure (or septum);
- the mantle layer develops into gray matter, i.e., dorsal and ventral *gray columns* separated by intermediate gray matter (in profile, the columns are usually called *horns*); cell migration from the basal plate produces a lateral gray column (horn) at thoracic and cranial lumbar levels of the spinal cord (sympathetic preganglionic neurons);
- the marginal layer becomes white matter (which is subdivided bilaterally into a *dorsal funiculus* (bundle), a *lateral funiculus*, and a *ventral funiculus*).

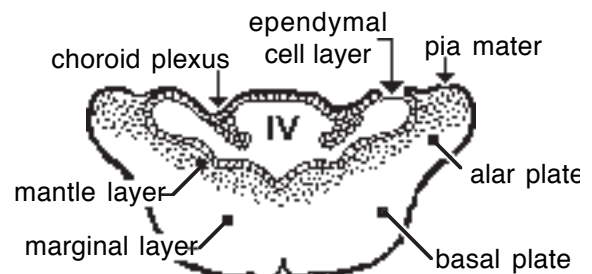


Embryonic Spinal Cord

Enlargements of spinal cord segments that innervate limbs (cervical and lumbosacral enlargements) are the result of greater numbers of neurons in those segments, due to less neuronal degeneration compared to segments that do not innervate limbs.

Hindbrain: Medulla oblongata and pons

- alar plates move laterally and the cavity of the neural tube expands dorsally forming a fourth ventricle; the roof of the fourth ventricle (roof plate) is stretched and reduced to a layer of ependymal cells covered by pia mater; a choroid plexus develops bilaterally in the roof of the ventricle and secretes cerebrospinal fluid;
- the basal plate (containing efferent neurons of cranial nerves) is positioned medial to the alar plate and ventral to the fourth ventricle;
- white and gray matter (marginal & mantle layers) become intermixed (unlike spinal cord); cerebellar development adds extra structures.



Medulla Oblongata

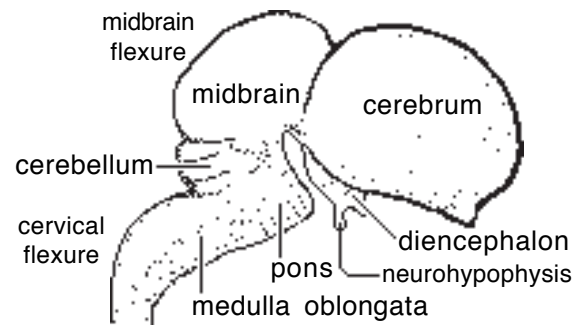
Hindbrain: Cerebellum

NOTE: • Adult cerebellum features surface gray matter, called **cerebellar cortex**, and three pair of **cerebellar nuclei** located deep within the cerebellar white matter. The cerebellum connects to the brain stem by means of three pair of *cerebellar peduncles*, each composed of white matter fibers.

- Cerebellar cortex is composed of three layers: a superficial *molecular layer* which is relatively acellular; a middle *piriform* (Purkinje) *cell layer* consisting of a row of large cell bodies; and a deep *granular* (granule cell) *layer* composed of numerous very small neurons.
- The cerebellum functions to adjust muscle tone and coordinate posture and movement so they are smooth and fluid vs. jerky and disunited.

- bilateral *rhombic lips* are the first evidence of cerebellar development; the lips are expansions of the alar plate into the roof plate; the rhombic lips merge medially, forming a midline isthmus (the lips form the two cerebellar hemispheres and the isthmus forms the vermis of the cerebellum);

- cellular migrations:
 - superficial and deep layers of neurons are evident within the mantle layer of the future cerebellum; the deep cells migrate (pass the superficial cells) toward the cerebellar surface and become Purkinje cells of the cerebellar cortex; meanwhile, neurons of the superficial layer migrate deeply and become cerebellar nuclei;
 - neuroblasts located laterally in the rhombic lip migrate along the outer surface of the cerebellum, forming an *external germinal layer* (which continues to undergo mitosis); subsequently, neurons migrate deep to the Purkinje cells and form the granule cell layer of the cerebellar cortex;
 - some alar plate neurons migrate to the ventral surface of the pons, forming pontine nuclei which send axons to the cerebellum.



Brain Divisions & Flexures

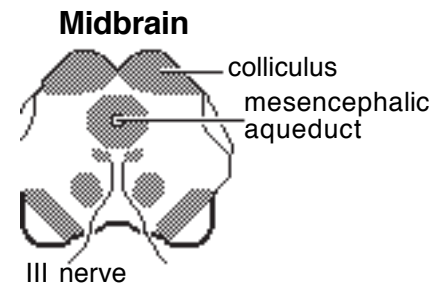
Migration of neuron populations past one another allows connections to be established between neurons of the respective populations. Neurons that fail to connect are destined to degenerate. Connections are made by axons that subsequently elongate as neurons migrate during growth.

Midbrain

- the neural cavity of the midbrain becomes *mesencephalic aqueduct* (which is not a ventricle because it is completely surrounded by brain tissue and thus it lacks a choroid plexus).

- alar plates form two pairs of dorsal bulges which become rostral and caudal colliculi (associated with visual and auditory reflexes, respectively);

- the basal plate gives rise to oculomotor (III) and trochlear (IV) nerves which innervate muscles that move the eyes.



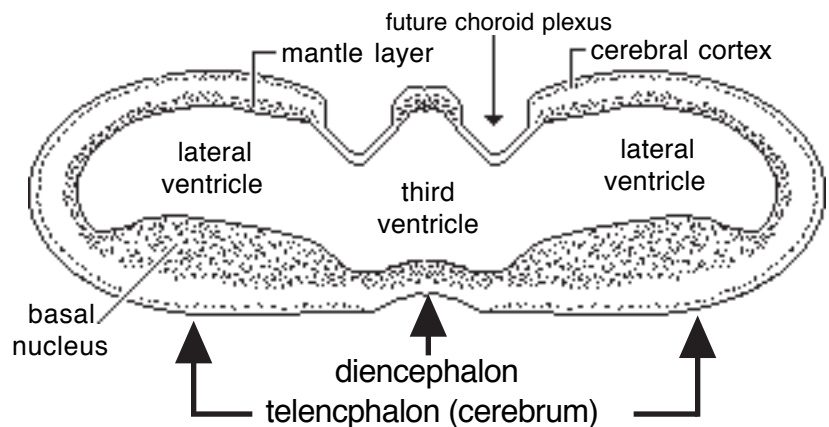
Note: The midbrain is the rostral extent of the basal plate (efferent neurons).

Forebrain (derived entirely from alar plate)

Diencephalon:

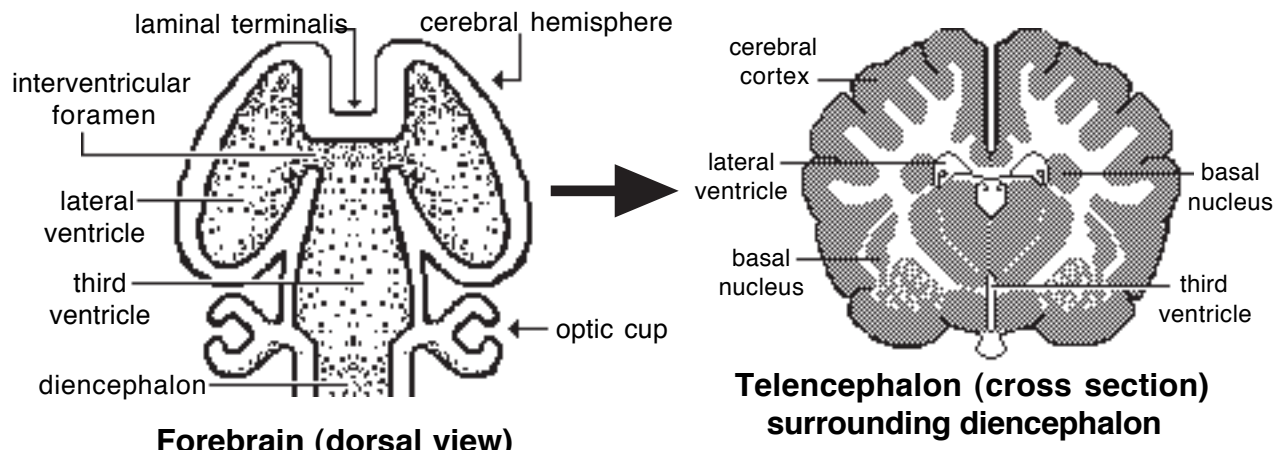
- the neural cavity expands dorsoventrally and becomes the narrow *third ventricle*, the roof plate is stretched and choroid plexuses develop bilaterally in the roof of the third ventricle and secrete cerebrospinal fluid;

- the floor of the third ventricle gives rise to the neurohypophysis (neural lobe of the pituitary gland);



Developing Forebrain (transverse section)

- the mantle layer of the diencephalon gives rise to thalamus, hypothalamus, etc.; the thalamus enlarges to the point where right and left sides meet at the midline and obliterate the center of the third ventricle.
- the optic nerve develops from an outgrowth of the wall of the diencephalon.



Telencephalon (cerebrum):

- bilateral hollow outgrowths become right and left *cerebral hemispheres*; the cavity of each outgrowth forms a *lateral ventricle* that communicates with the third ventricle via an interventricular foramen (in the wall of each lateral ventricle, a choroid plexus develops that is continuous with a choroid plexus of the third ventricle via an interventricular foramen);
- at the midline, the rostral end of the telencephalon forms the rostral wall of the third ventricle (the wall is designated lamina terminalis);
- the mantle layer surrounding the lateral ventricle in each hemisphere gives rise to basal nuclei and *cerebral cortex*;
- cellular migrations that form cerebral cortex:
 - from the mantle layer, cells migrate radially to the surface of the cerebral hemisphere, guided by glial cells that extend from the ventricular surface to the outer surface of the cerebral wall (thus each locus of mantle gives rise to a specific area of cerebral cortex);
 - migration occurs in waves; the first wave (which becomes the deepest layer of cortex) migrates to the surface of the cortex; the second wave (which forms the next deepest layer of cortex) migrates to the cortical surface, passing through first wave neurons which are displaced to a deeper position; the third wave . . . etc. (the cerebral cortex has six layers).

Cell connections are established within the cerebral cortex as waves of newly arriving neurons migrate through populations of neurons that arrived earlier.

NOTE: Carnivores are born with a nervous system that does not mature until about six weeks postnatally (mature behavior is correspondingly delayed). In herbivores, the nervous system is close to being mature at birth.

Peripheral Nervous System

NOTE:

- The peripheral nervous system (PNS) consists of cranial and spinal nerves. Nerve fibers within peripheral nerves may be classified as afferent (sensory) or efferent (motor) and as somatic (innervating skin and skeletal muscle) or visceral (innervating vessels and viscera). The visceral efferent (autonomic) pathway involves two neurons: 1] a preganglionic neuron that originates in the CNS and 2] a postganglionic neuron located entirely in the PNS. The glial cell of the PNS is the neurolemmocyte (Schwann cell).
- All afferent neurons are unipolar and have their cell bodies in sensory ganglia, either spinal ganglia on dorsal roots or ganglia associated with cranial nerves. Somatic efferent and preganglionic visceral efferent neurons have their cell bodies located in the CNS, but their axons extend into the PNS. Postganglionic visceral efferent neurons have their cell bodies in autonomic ganglia.

— *neurolemmocytes* (Schwann cells) arise from **neural crest** and migrate throughout the PNS, ensheathing and myelinating axons and forming satellite cells in ganglia;

— *afferent neurons* originate from neural crest as bipolar cells that subsequently become unipolar; in the case of cranial nerves, afferent neurons also originate from placodes (placode = localized thickening of ectoderm in the head);

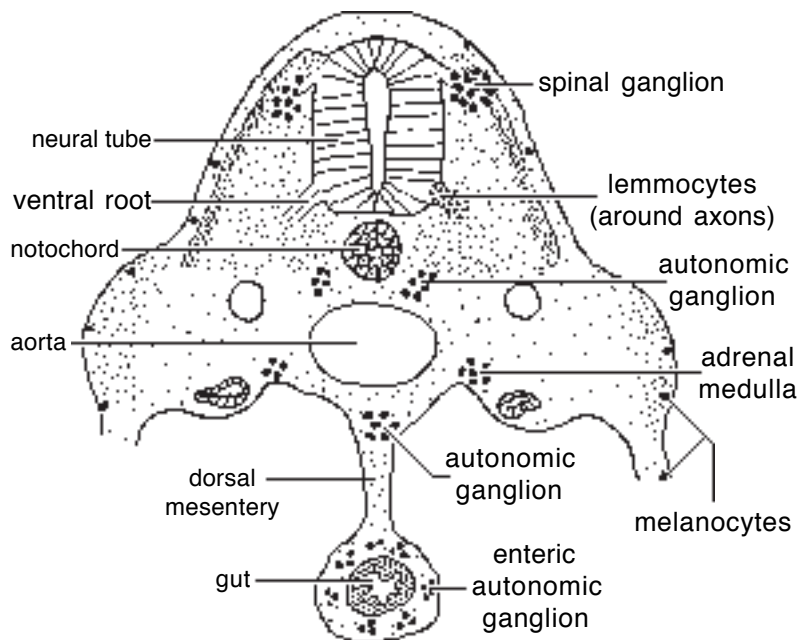
— *postganglionic visceral efferent neurons* arise from neural crest, the cells migrate to form autonomic ganglia at positions within the head, or beside vertebrae (along sympathetic trunk), or near the aorta, or in the gut wall (the latter are parasympathetic and come from sacral and hindbrain regions);

— *somatic efferent neurons* and *preganglionic visceral efferent neurons*

arise from the basal plate of the neural tube; their cell bodies remain in the CNS and their axons join peripheral nerves;

Peripheral nerves establish contact early with the nearest somite, somitomere, placode, or pharyngeal arch and innervate derivatives of these embryonic structures.

Innervation continuity is retained even when the derivatives are considerably displaced or when other structures have obstructed the pathway. The early establishment of an innervation connection explains why some nerves travel extended distances and make detours to reach distant inaccessible targets. The foremost example is the recurrent laryngeal nerve which courses from the brainstem to the larynx via the thorax, because the heart migrates from the neck to the thorax pulling the nerve with it.



Developing Peripheral Nervous System

Note: Cranial nerves innervate specific pharyngeal arches and their derivatives:
trigeminal (V) - innervates first pharyngeal arch (muscles of mastication)
facial (VII) - innervates second pharyngeal arch (muscles of facial expression)
glossopharyngeal (IX) - innervates third pharyngeal arch (pharyngeal muscles)
vagus (X) - 4 & 6 pharyngeal arches (muscles of pharynx, larynx, & esophagus)

Formation of Meninges

Meninges surround the CNS and the roots of spinal and cranial nerves.

Three meningeal layers (dura mater, arachnoid, and pia mater) are formed as follows:

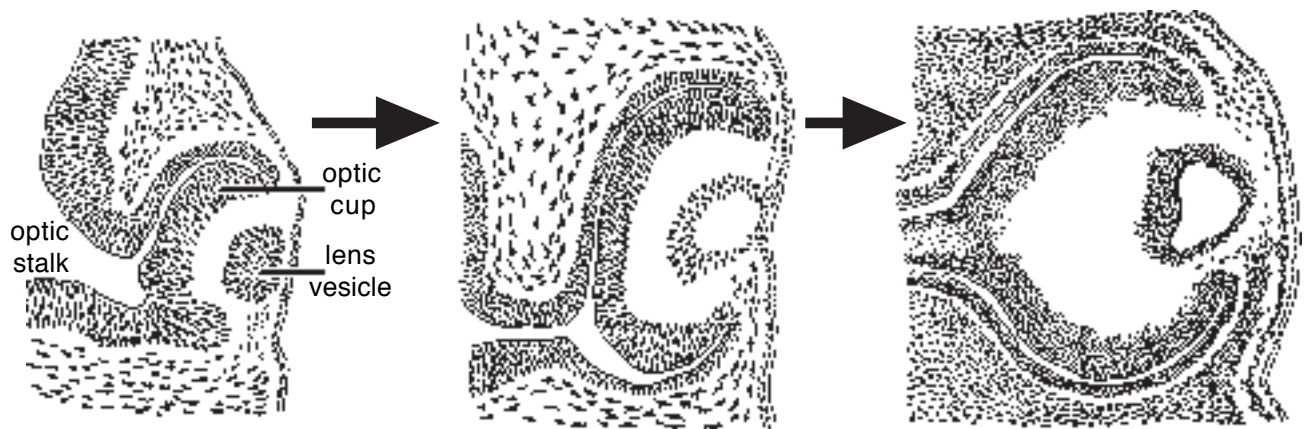
- mesenchyme surrounding the neural tube aggregates into two layers;
- the outer layer forms dura mater;
- cavities develop and coalesce within the inner layer, dividing it into arachnoid and pia mater; the cavity becomes the subarachnoid space which contains cerebrospinal fluid.

Special Senses

Formation of the Eye

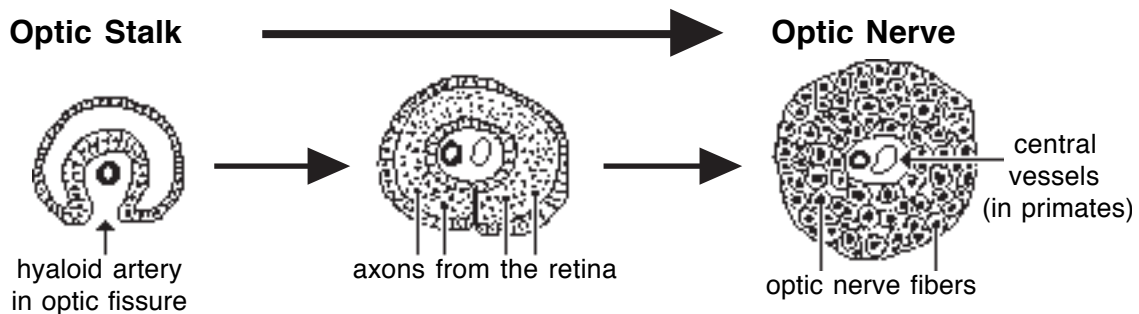
Both eyes are derived from a single field of the neural plate. The single field separates into bilateral fields associated with the diencephalon. The following events produce each eye:

- a lateral diverticulum from the diencephalon forms an *optic vesicle* attached to the diencephalon by an *optic stalk*;
- a *lens placode* develops in the surface ectoderm where it is contacted by the optic vesicle; the lens placode induces the optic vesicle to invaginate and form an **optic cup** while the placode invaginates to form a *lens vesicle* that invades the concavity of the optic cup;
- an *optic fissure* is formed by invagination of the ventral surface of the optic cup and optic stalk, and a *hyaloid artery* invades the fissure to reach the lens vesicle;



NOTE: The optic cup forms the *retina* and contributes to formation of the ciliary body and iris. The outer wall of the cup forms the outer pigmented layer of the retina, and the inner wall forms neural layers of the retina.

- The optic stalk becomes the *optic nerve* as it fills with axons traveling from the retina to the brain.
- The lens vesicle develops into the *lens*, consisting of layers of lens fibers enclosed within an elastic capsule.
- The vitreous compartment develops from the concavity of the optic cup, and the *vitreous body* is formed from ectomesenchyme that enters the compartment through the optic fissure.



— ectomesenchyme (from neural crest) surrounding the optic cup condenses to form inner and outer layers, the future *choroid* and *sclera*, respectively;

— the *ciliary body* is formed by thickening of choroid ectomesenchyme plus two layers of epithelium derived from the underlying optic cup; the ectomesenchyme forms ciliary muscle and the collagenous zonular fibers that connect the ciliary body to the lens;

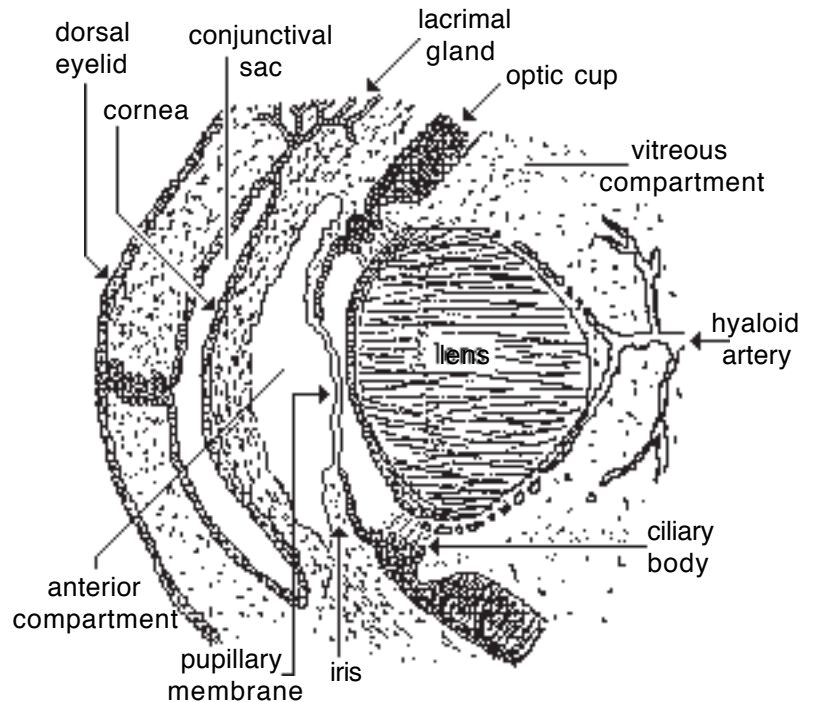
— the *iris* is formed by choroid ectomesenchyme plus the superficial edge of the optic cup; the outer layer of the cup forms dilator and constrictor muscles and the inner layer forms pigmented epithelium; the ectomesenchyme of the iris forms a *pupillary membrane* that conveys an anterior blood supply to the developing lens; when the membrane degenerates following development of the lens, a pupil is formed;

— the *cornea* develops from two sources: the layer of ectomesenchyme that forms sclera is induced by the lens to become inner epithelium and stroma of the cornea, while surface ectoderm forms the outer epithelium of the cornea; the *anterior chamber* of the eye develops as a cleft in the ectomesenchyme situated between the cornea and the lens;

— the *eyelids* are formed by upper and lower folds of ectoderm, each fold includes a mesenchyme core; the folds adhere to one another but they ultimately separate either prenatally (ungulates) or approximately two weeks postnatally (carnivores); ectoderm lining the inner surfaces of the folds becomes *conjunctiva*, and *lacrimal glands* develop by budding of conjunctival ectoderm;

— skeletal muscles that move the eye (*extraocular eye mm.*) are derived from rostral somitomeres (innervated by cranial nerves III, IV, and VI).

Anterior Eyeball and Eyelids

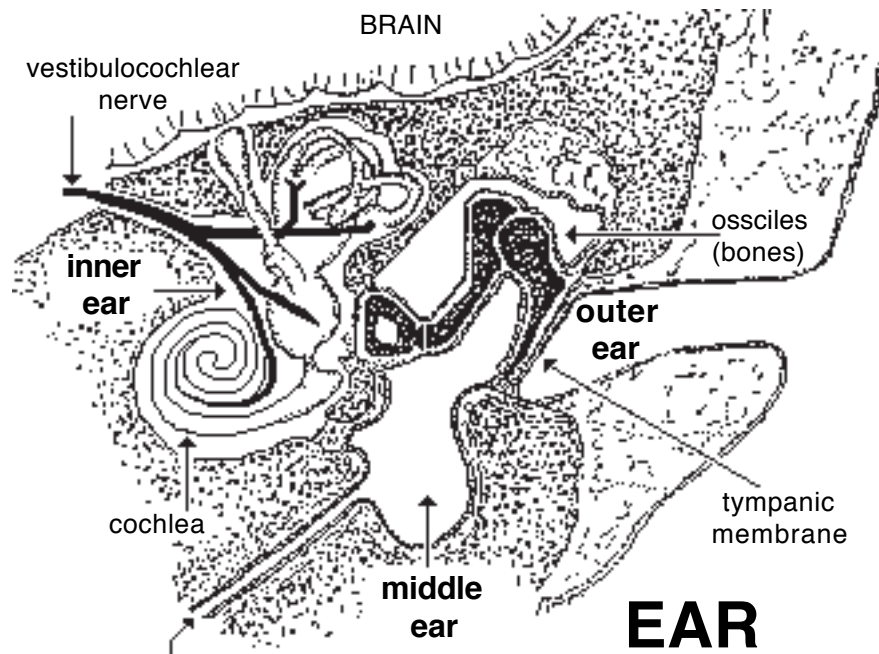


Clinical considerations:

- The ungulate retina is mature at birth, but the carnivore retina does not fully mature until about 5 weeks postnatally.
- Retinal detachment occurs between the neural and outer pigmented layers of the retina (inner and outer walls of the optic cup) which do not fuse but are held apposed by pressure of the vitreous body.
- Coloboma is a defect due to failure of the optic fissure to close.
- Microphthalmia (small eye) results from failure of the vitreous body to exert sufficient pressure for growth, often because a coloboma allowed vitreous material to escape.
- Persistent pupillary membrane results when the pupillary membrane fails to degenerate and produce a pupil.

Formation of the Ear

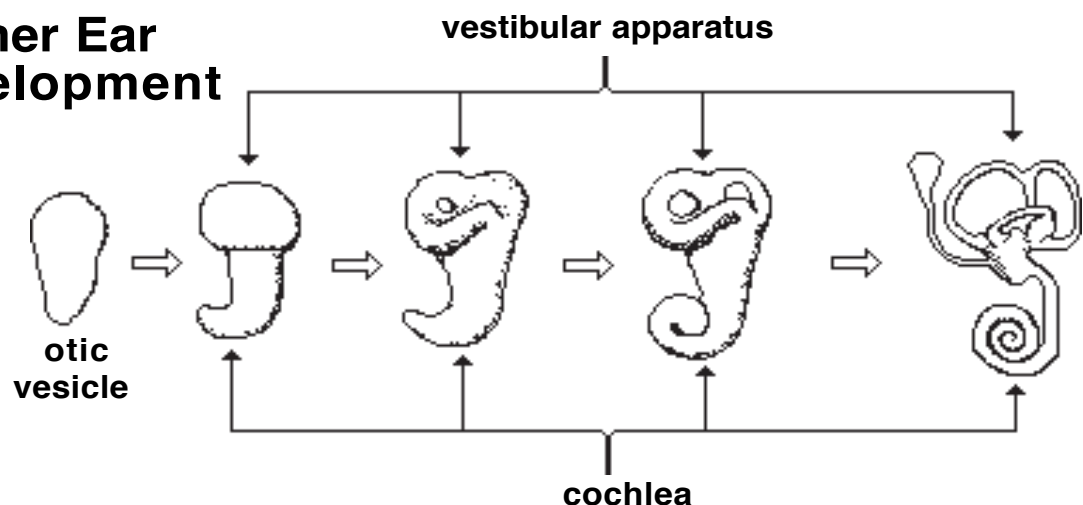
The ear has three components: external ear, middle ear, and inner ear. The *inner ear* contains sense organs for hearing (cochlea) and detecting head acceleration (vestibular apparatus), the latter is important in balance. Innervation is from the cochlear and vestibular divisions of the VIII cranial nerve. The *middle ear* contains bones (ossicles) that convey vibrations from the tympanic membrane (ear drum) to the inner ear. The *outer ear* channels sound waves to the tympanic membrane.



Inner ear:

- an *otic placode* develops in surface ectoderm adjacent to the hindbrain; the placode invaginates to form a cup which then closes and separates from the ectoderm, forming an *otic vesicle* (otocyst); an *otic capsule*, composed of cartilage, surrounds the otocyst;
- some cells of the placode and vesicle become neuroblasts and form afferent neurons of the vestibulocochlear nerve (VIII);
- the otic vesicle undergoes differential growth to form the cochlear duct and semicircular ducts of the membranous labyrinth; some cells of the labyrinth become specialized receptor cells found in maculae and ampullae;
- the cartilagenous otic capsule undergoes similar differential growth to form the osseous labyrinth within the future petrous part of the temporal bone.

Inner Ear Development

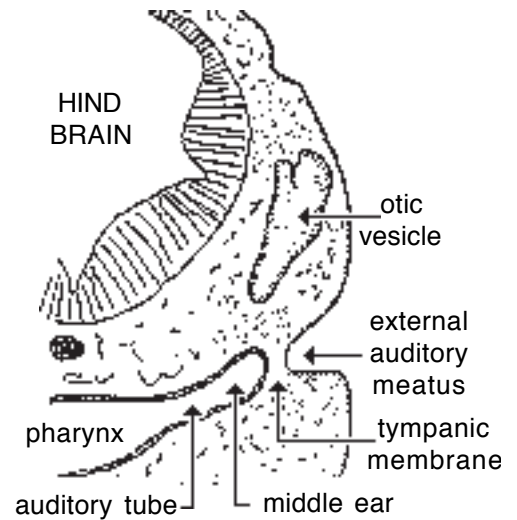


Middle ear:

- the dorsal part of the *first pharyngeal pouch* forms the lining of the auditory tube and tympanic cavity (in the horse a dilation of the auditory tube develops into the guttural pouch);
- the malleus and incus develop as endochondral bones from ectomesenchyme in the first pharyngeal arch and the stapes develops similarly from the second arch (in fish, these three bones have different names; they are larger and function as jaw bones).

Outer ear:

- the tympanic membrane is formed by apposition of endoderm and ectoderm where the first pharyngeal pouch is apposed to the groove between the first and second pharyngeal (pharyngeal) arches;
- the external ear canal (meatus) is formed by the groove between the first and second pharyngeal arches; the arches expand laterally to form the wall of the canal and the auricle (pinna) of the external ear.



Auditory Tube Formation

Taste buds

Taste buds are groups of specialized (chemoreceptive) epithelial cells localized principally on papillae of the tongue. Afferent innervation is necessary to induce taste bud formation and maintain taste buds. Cranial nerves VII (rostral two-thirds of tongue) and IX (caudal third of tongue) innervate the taste buds of the tongue.

Olfaction

Olfaction (smell) involves olfactory mucosa located caudally in the nasal cavity and the vomeronasal organ located rostrally on the floor of the nasal cavity. Olfactory neurons are chemoreceptive; their axons form olfactory nerves (I).

- an olfactory (nasal) placode appears bilaterally as an ectodermal thickening at the rostral end of the future upper jaw; the placode invaginates to form a nasal pit that develops into a nasal cavity as the surrounding tissue grows outward; in the caudal part of the cavity, some epithelial cells differentiate into olfactory neurons;

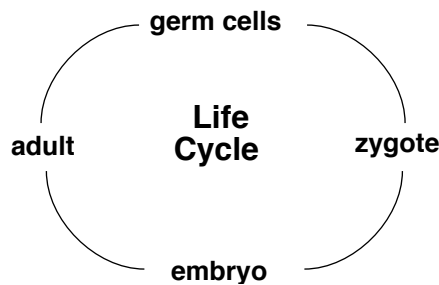
- the vomeronasal organ develops as an outgrowth of nasal epithelium that forms a blind tube; some epithelial cells of the tube differentiate into chemoreceptive neurons.

Appendix I

Gametogenesis

Germ cells provide the continuity of life between generations of a species, by passing on chromosomal DNA which contains developmental information for the species. Diploid (2N) germ cells are capable of producing haploid (1N) gametes. Fusion of haploid gametes produces a diploid zygote (the beginning of a new individual of the species).

Note: N = the number of pairs of chromosomes, i.e., the number of chromosomes each parent contributes to the new individual.



Gametogenesis . . .

refers to the formation of haploid (1N) gametes (sperm or oocytes) by diploid (2N) germ cells (primary spermatocytes or primary oocytes) through a process called meiosis.

Spermatogenesis (duration varies: 34 days in mouse; 36 days in stallion; 74 days in human)

- spermatocytogenesis
 - spermatogonia (2N) proliferate, producing themselves & primary spermatocytes (2N)
 - primary spermatocyte (2N) produces two secondary spermatocytes (1N) via Meiosis I
 - two secondary spermatocytes (1N) divide into four spermatids (1N) via Meiosis II
- spermiogenesis
 - transformation of a spermatid into a sperm (spermatozoon) cell (duration 18 days)

Oogenesis (duration: from before birth to some time between puberty and loss of fertility)

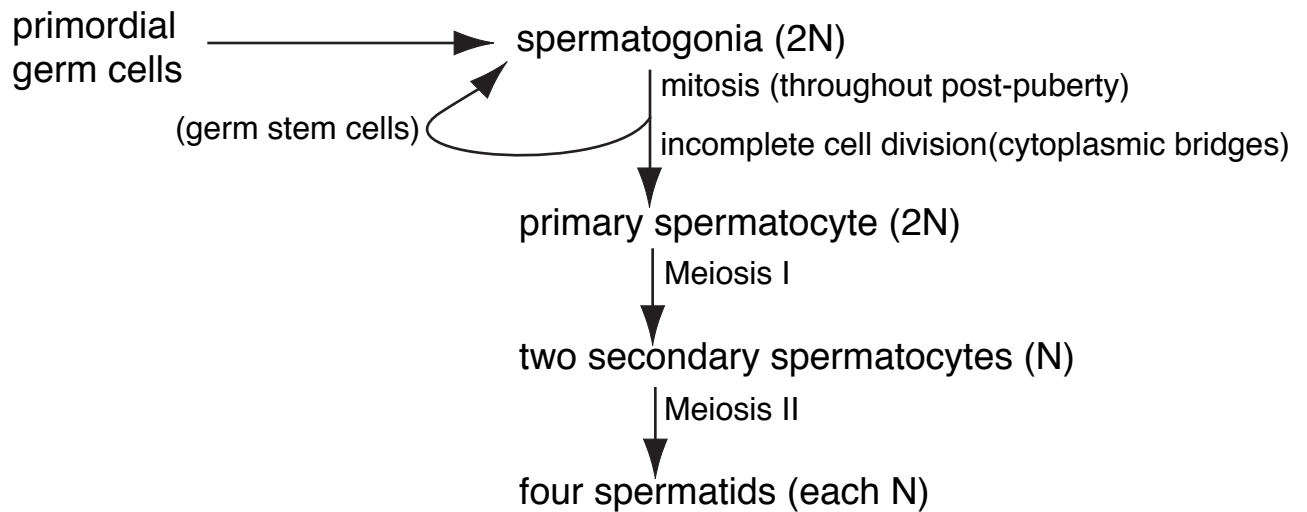
- oogonia (2N) proliferate themselves and primary oocytes (2N) in the embryo & fetus
- primary oocyte (2N) remains in prophase of Meiosis I until it is ovulated;
 - then, it divides into a secondary oocyte (1N) and a polar body (1N)
- following fusion with sperm, the secondary oocyte (1N) completes Meiosis II;
 - the result is a fertilized ovum or zygote (now 2N)

NOTE: Following Meiosis I, all of the oocyte cytoplasm becomes associated with just one of the daughter cells, called a secondary oocyte. The other daughter cell (nucleus) is called a polar body. Following Meiosis II, all of the oocyte cytoplasm becomes associated with just one of the daughter cells, called an ovum. The other daughter cell (nucleus) is called a polar body. Since the first polar body also undergoes Meiosis II, a total of three polar bodies are produced by meiosis.

Gametogenesis

Spermatogenesis (formation of spermatozoa)

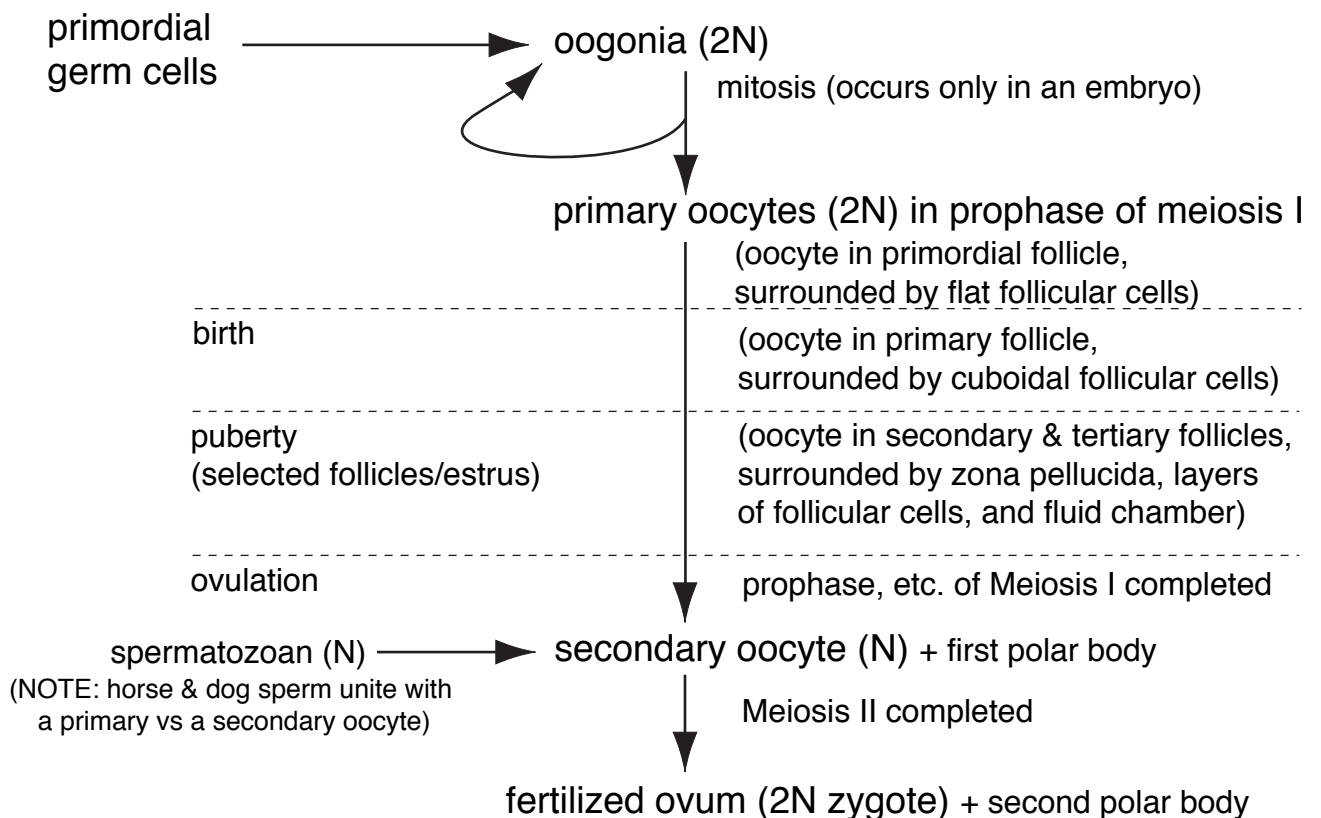
A] Spermatocytogenesis (formation of spermatids in seminiferous tubules)



B] Spermiogenesis (transformation of spermatids to spermatozoa)

- elongate nucleus, loss of cytoplasm & cytoplasmic bridges, formation of acrosome & tail
- transformation occurs while linked to a Sertoli cell
- spermatozoa are released into lumen of seminiferous tubule

Oogenesis (formation of an ovum)

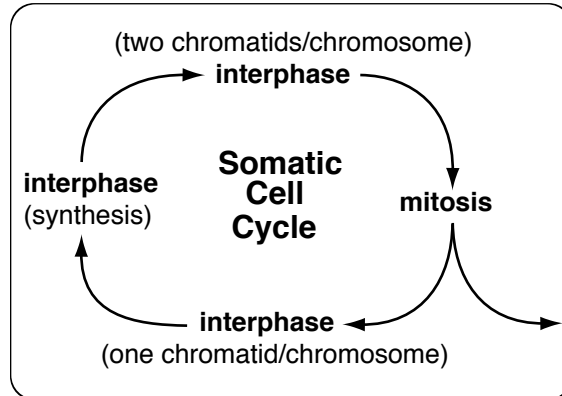


Note: Fertilization begins with union of male and female gametes and ends with the start of zygote cell division (cleavage).

Appendix II

Mitosis and Meiosis

Somatic Cell Cycle and Cell Division (Mitosis):



Interphase:

period prior to DNA synthesis [G_1 = days or G_0 = very long time];
 period of DNA synthesis [S = 10 hrs.];
 period of preparation for mitosis [G_2 = 1 hr].

Synthesis = each double-stranded helix of DNA (one chromatid/chromosome) becomes two double-stranded helices of DNA (two chromatids/chromosome).

Mitosis = cell division where each of two daughter cells receives chromosomal material identical to the parent cell (i.e., one of two chromatids per chromosome).

Stages of mitosis:

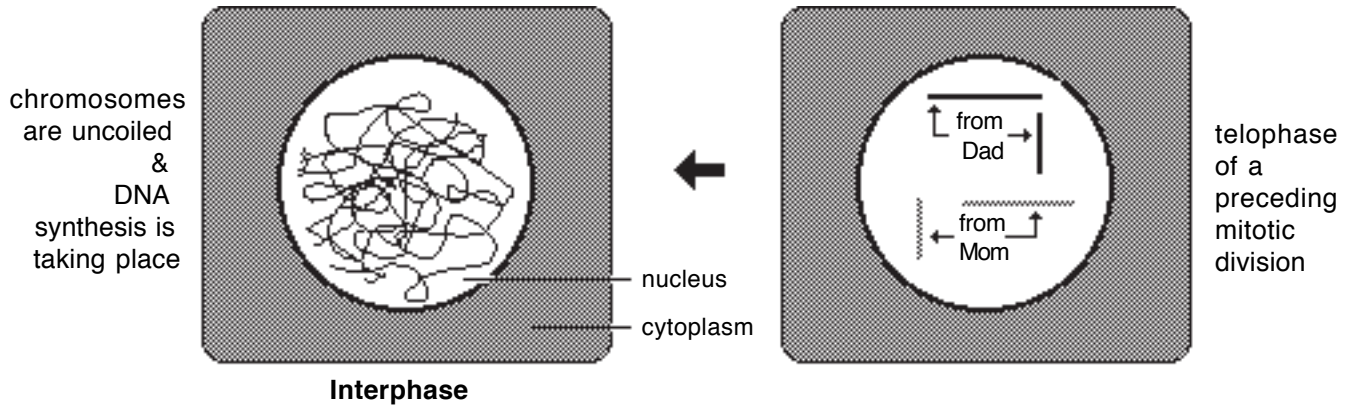
Prophase — chromosomes become visible and the nuclear membrane disappears under the light microscope (90 min.) ;

Metaphase — individual, double-chromatid chromosomes align randomly at the equatorial region between centrioles (30 min.) ;

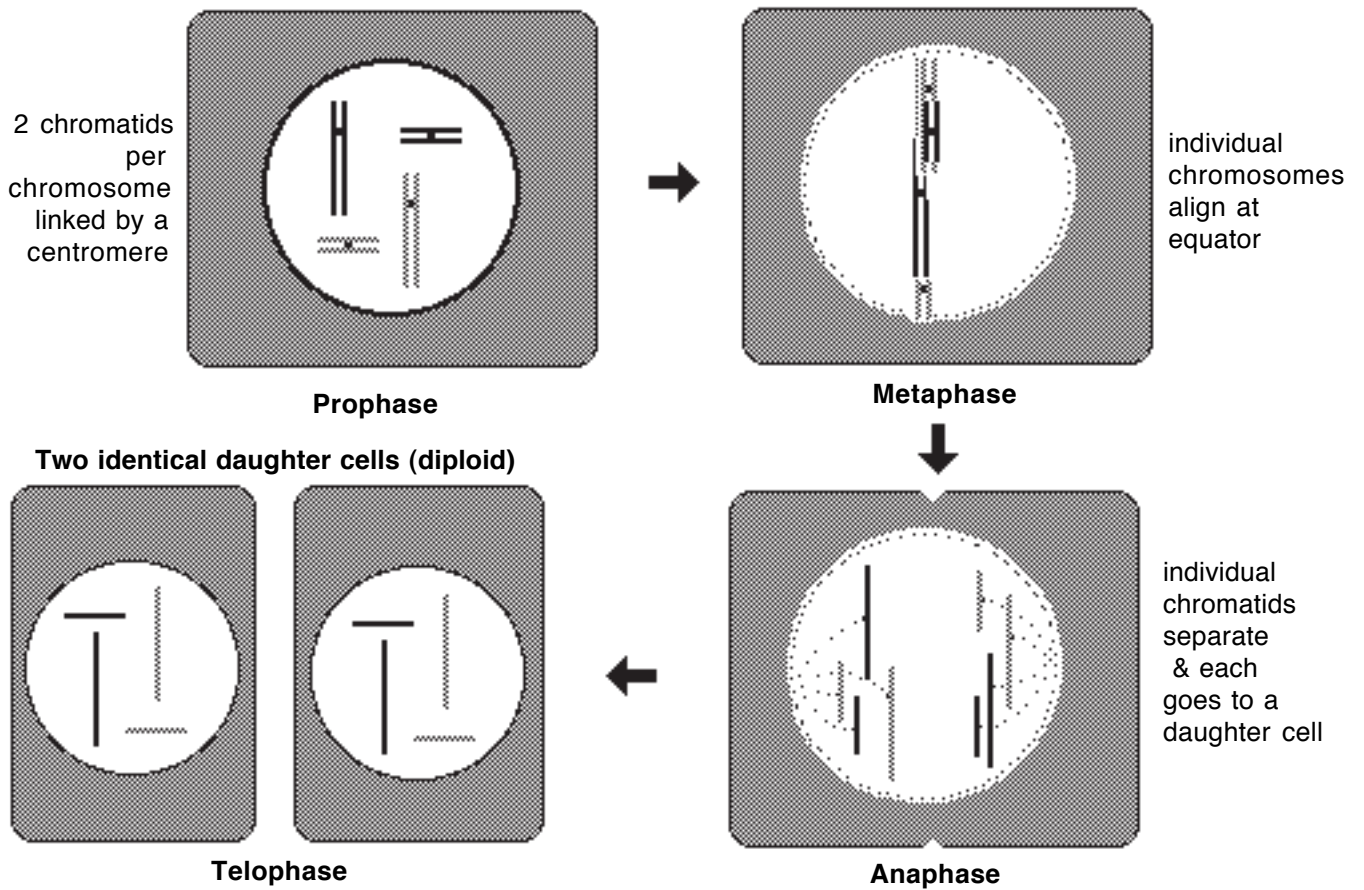
Anaphase — the two chromatids per chromosome separate as the centromere divides and each chromatid becomes a chromosome in a new nucleus (5 min.) ;

Telophase — chromosomes become invisible and the nuclear membrane reappears

Diploid Somatic Cell



Mitosis

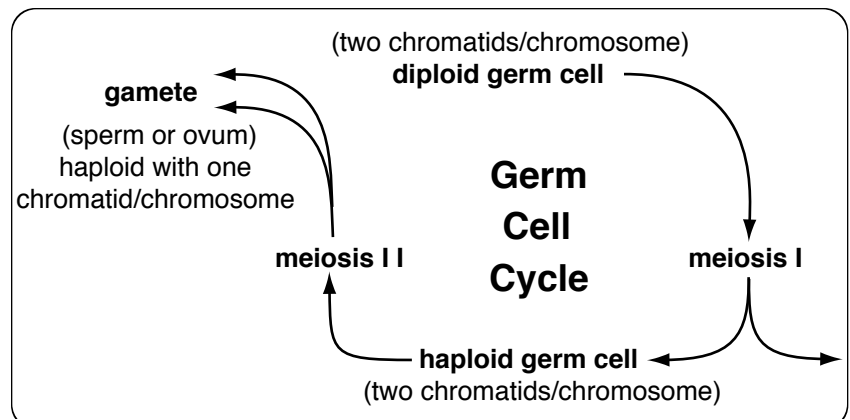


Germ cell division:

A diploid germ cell initially undergoes **Meiosis I**, a reduction division: $[2N \rightarrow 2(1N)]$.

Then each of two haploid daughter cells undergoes **Meiosis II**, a mitotic-like division.

Four gametes (four spermatids or one ovum plus three polar bodies) are produced.



Meiosis: (following interphase in which DNA synthesis occurs)

Meiosis I (reduction division: one diploid \rightarrow two haploid cells)

Prophase

- chromosomes become visible (as paired chromatids joined at centromeres)
 - homologous chromosomes are paired (linked by a synaptonemal complex)
- Note: chromatids of linked homologous chromosomes may exchange comparable DNA, i.e., exchange genes (genetic cross-over)

Metaphase

- homologous chromosome pairs align at equatorial region between centrioles

Anaphase

- homologous chromosome pairs separate (one chromosome of a pair moves toward one centriole and the other toward the other centriole).

Note: haploid daughter cells inherit different assortments of maternal/paternal chromosomes.

The number of possible assortments = 2^N , where N = number of chromosomes/gamete, e.g., for human 2^{23} = over 8 million. Including cross-overs = incalculable variety.

Telophase

- chromosomes become less visible; nuclear membrane reappears; cytoplasm division occurs.

Meiosis II (mitosis-like division of each haploid cell)

Prophase

- chromosomes visible (very brief period)

Metaphase

- individual chromosomes align at equatorial region between centrioles.

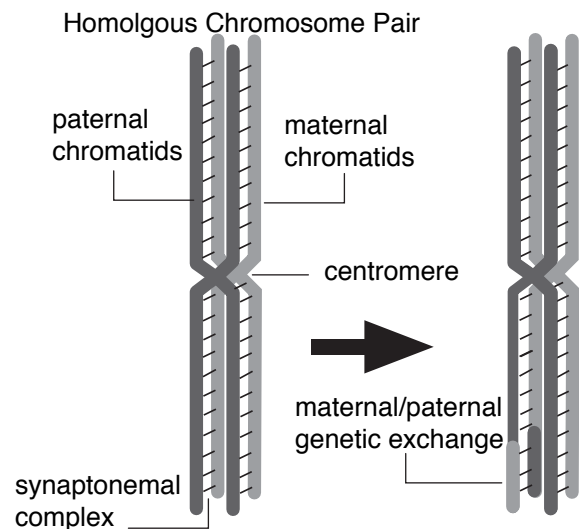
Anaphase

- the two chromatids per chromosome separate at the centromere region
- each chromatid moves toward its respective centriole and becomes a chromosome in a new nucleus

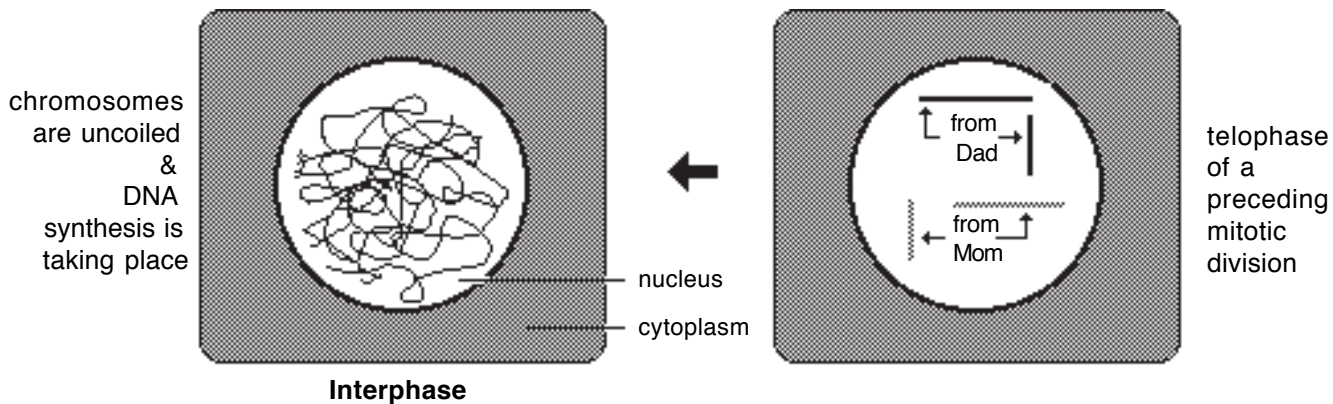
Telophase

- chromosomes become less visible; nuclear membrane reappears; cytoplasm division occurs (cytokinesis).

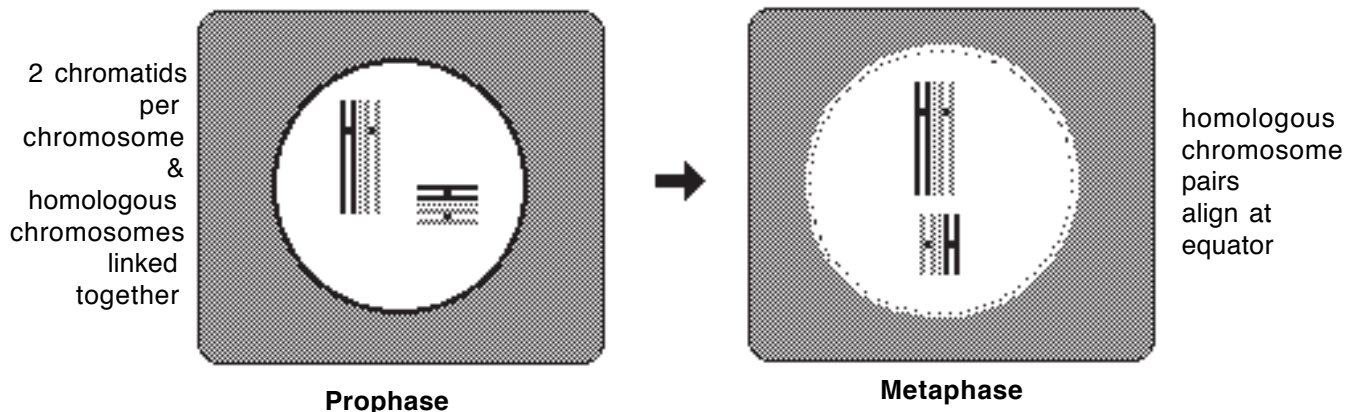
Crossover during Meiosis I



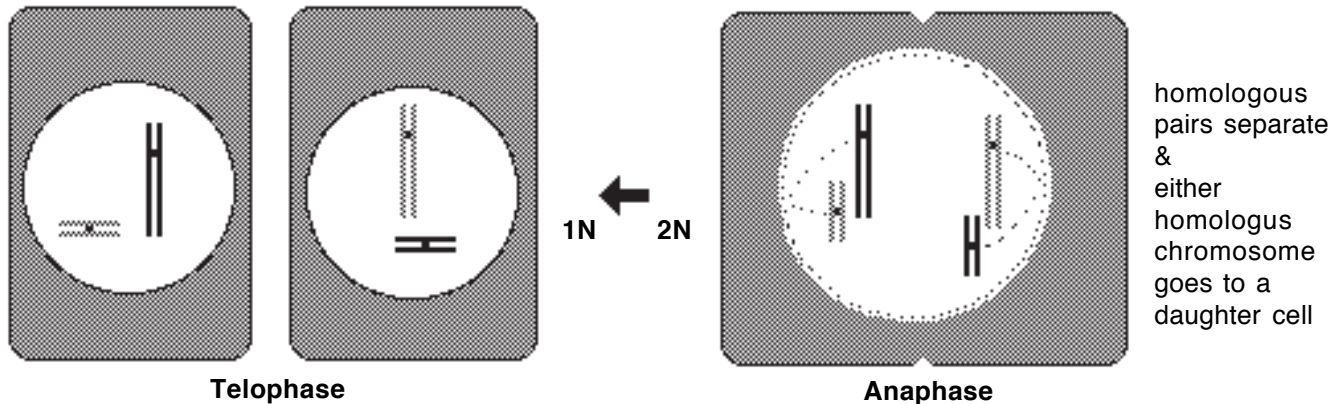
Primary spermatocyte or oocyte (diploid germ cell)



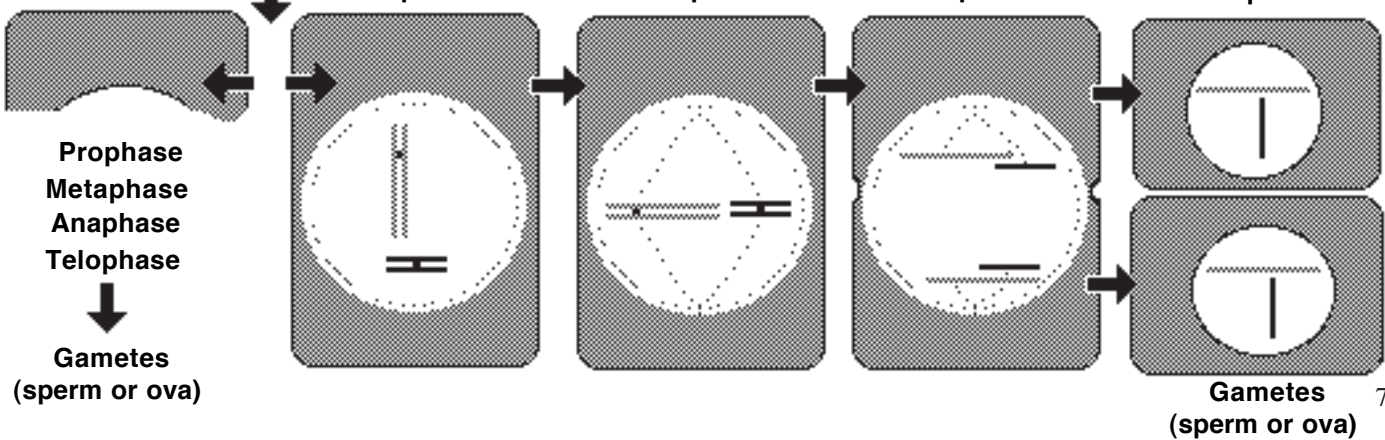
Meiosis I



Secondary spermatocytes or oocytes (haploid)



Meiosis II



Appendix III

Congenital Anomalies of Clinical Significance

(See also Noden and De Lahunta, Embryology of Domestic Animals)

This is a small representation of the many anomalies which can occur. It is presented here to stimulate an awareness in practitioners-to-be to that congenital malformations are etiological factors to be considered in making differential diagnoses

A. Placentation:

1. Hydrops of the amnion or allantois.

Accumulation of excessive fluid in either amniotic or allantoic cavities results in fetal death. If not relieved, in late pregnancy they can cause uterine or prepubic tendon rupture. Progressive bilateral abdominal distention, anorexia, and recumbency are signs of their occurrence.

2. Strangulation by umbilical cord.

In species with long umbilical cords, e.g., swine, neck or limb strangulation in varying degree may occur.

B. Face, mouth, nasal cavity, and pharynx.

1. Cheiloschisis (cleft lip), palatoschisis (cleft palate).

Cleft lip is caused by failure of fusion of medial nasal and maxillary processes; cleft palate is caused by failure of medial palatine processes to fuse.

2. **Branchial cyst** (no opening), branchial **sinus** (opening to exterior), branchial **fistula** (openings to interior and exterior).

These result from failure of involution of the branchial apparatus caudal to branchial arch II. Cysts and sinuses are minor problems, and can be surgically relieved.

3. Heterotopic polyodontia (dentigerous cyst, “ear teeth”).

Primordia of enamel organs escape to the exterior and develop tooth structures anchored on the parietal bone or base of the ear. These cause festering problems and must be relieved surgically.

4. Thyroglossal duct cyst.

Failure of involution of thyroglossal duct is the cause. A surgically removable fluid-filled cyst seen at birth interferes with breathing.

C. Digestive tract.

1. Meckel's diverticulum.

Persistence, inflammation, and rupture of this structure, which is an appendix-like remnant of the **yolk stalk**, results in colic, with peritonitis.

2. Atresia of the jejunum, ileum, colon, rectum.

A lack of epithelial canalization and gut wall development results in feed impaction and death if surgical intervention cannot be made. Some evidence suggests that one cause is manual manipulation of fetal membranes rectally in pregnancy diagnosis.

3. Imperforate anus.

This results from lack of involution of the **cloacal membrane**, and leads to fatal feed impaction. Where anal musculature is developed, surgical removal of the cloacal membrane offers temporary if not permanent relief.

D. Lower respiratory tract.

1. Tracheoesophageal fistula.

This results from a partial persistence of the **laryngotracheal groove**. Its presence in the newborn causes refluxing of feed through the upper respiratory tract, and inhalation pneumonia. Surgical treatment is difficult.

2. Barker foal syndrome: hyalin disease.

This is believed to result from a lack of production of **pulmonary surfactant**, which may be temporary. Gasping of the newborn is a sign of its presence.

E Heart and arterial system.

1. Ectopia cordis.

Here the heart remains in the cervical region where it was formed embryologically. Though some animals survive to adulthood, they become unthrifty.

2. Interatrial septal defect (ASD); interventricular septal defect (VSD).

An unthrifty animal usually results.

3. Tetralogy of Fallot.

Three primary abnormalities are: ventricular septal defect; shift of left ventricular outflow to the right; and pulmonary stenosis.

A resulting fourth abnormality is a hypertrophy of the right ventricle.

4. Persistent truncus arteriosus.

This is due to a partial or complete lack of formation and fusion of truncus spiral ridges. Depending upon the severity of malformation, cyanosis and fatigue, poor growth, and death may occur.

5. Persistent ductus arteriosus.

Failure of closure at birth results in the so-called **blue baby** condition, wherein poorly oxygenated blood is delivered to the whole body except the head, neck, and right fore appendage regions.

6. Right aortic arch.

The **left** aortic arch normally forms the ascending aorta; an anomalous **right** arch, together with the normal left ductus arteriosus (ligamentum arteriosum), forms a strangulating vascular ring around the esophagus and trachea. Inability to swallow solid feed in young animals is a first symptom.

7. Ectopic right subclavian artery.

Origin of the right subclavian artery from the ascending aorta instead of the brachiocephalic trunk also results in a strangulation of the esophagus and trachea.

8. Persistent vitelloumbilical band.

Especially in equidae where there is a well developed yolk sac, the left vitelline artery and yolk stalk may persist, forming a band between the ileum and umbilicus. Intestinal strangulation may result. Development of colic is a first symptom.

F. Venous and lymphatic systems.

1. Portosystemic shunts.

Venous return from the gut should first pass through the liver since it contains toxic substances normally metabolized in the liver. One anomaly which prevents this return is an anomalous **persisting ductus venosus**. The other is a **central** or **peripheral portal-venous** shunt to the caudal vena cava or azygous vein. Both result in young animals showing abnormal nervous behavior as a first symptom.

2. Congenital hereditary lymphoedema.

Absence of lymph vascular connections to the venous system result in edema of the involved body regions.

G. Body cavities.

1. Pleuroperitoneal hernia.

Failure of closure of one or both pleuroperitoneal folds results in intestinal herniation into the pleural cavity. Labored breathing is a symptom.

2. Peritoneopericardial diaphragmatic hernia.

During fetal development the liver dissects away from the transverse septum, occasionally leaving a central weakness in the fibrous part of the diaphragm. Intestinal herniation through this area into the pericardial sac will result in abnormal cardiac sounds and dyspnoea.

H. Urinary and genital systems.

*Three facts render the urogenital system vulnerable to anomalies, as follows: 1), they arise in part by **faulty division** of the cloaca; into rectum and urogenital sinus; 2), in both sexes, especially the male, part of the urinary tract is **co-opted** during fetal development for use in the formation of the internal genital system; and 3), there is a marked **translocation** of urinary and reproductive duct terminals during fetal development.*

1. Ectopic ureter.

Entry of the ureters into the vagina or urethra results in dribbling of urine and bladder infection. Hydronephrosis may also result due to blockage of terminal ureteral orifices.

2. Urorectal fistula: rectovesicular, rectovestibular, rectourethral.

Due to faulty separation of the cloaca into rectum and urogenital sinus a fistulous tract may remain. This leads to abnormal elimination of urine and feces, and urinary tract infection.

3. Patent urachus.

The urachus is the urinary canal of the fetus. It becomes the median ligament of the bladder. Moistness or dribbling of urine at the umbilicus following birth results if it remains patent.

4. Double cervix.

This results from lack of fusion of the paramesonephric ducts beyond the body of the uterus. It may present parturition difficulties.

5 Paramesonephric duct atresia (White heifer disease).

This consists of the absence of the paramesonephric duct derived parts of the female tract (oviducts, uterus, cervix, and vagina). Ovaries are normal. The cause is known; it is not limited to white cattle.

6. Hypospadias.

Failure of urethral folds to fuse results in an opening of the urethra on the ventral surface of the penis

I. Nervous system.

Aganglionosis.

This results from lack of migration of neural crest cells to form intestinal ganglia. This condition, seen especially in Overo spotted horses, results in a flaccid, atonic large intestine. It is fatal for newborn animals due to intestinal impaction.

J. Musculoskeletal system.

1. Premature physal closure (achondroplasia, chondrodysplasia).

This may be a generalized anomaly of the appendages, or involve one of the long bones. In the latter instance, normal appendage use can be restored through orthopedic surgery. The cause is unknown.

2. Spina bifida.

This results from a failure of the vertebral arch to form dorsally over the vertebral canal. It usually occurs in the lumbar and sacral regions, and may interfere with locomotion.

3. Flexural and angular limb deformities (arthrogryposis).

These occur most frequently in equidae. Preliminary investigations indicate that autosomal trisomy of one of the smaller chromosomes is associated with their appearance.

Veterinary Developmental Anatomy

Early Embryogenesis

Key Objectives:

- *comprehend: embryogenesis, cell differentiation, embryonic period, fetal period*
- *describe the cells and events that comprise fertilization*
- *define: cleavage, morula, blastocyst, gastrulation, germ layers, mesenchyme, primitive streak*
- *describe how endoderm, mesoderm, and ectoderm are formed during gastrulation*
- *describe the formation and role of the notochord and of somites*
- *describe (sketch) the initial formation of the nervous system*
- *comprehend the transition from a flat embryo to a cylindrical body*
- *describe (sketch) the four fetal membranes in relation to the placenta and fetus, including significant species differences*
- *note the presence of pharyngeal arches, flexures, and cardiovascular components*

Musculo-Skeletal Development

Key Objectives:

- *comprehend the mesodermal origin of dermis, muscle, bone, joints, and ligaments*
- *define: somite, sclerotome, myotome, dermatome, paraxial mesoderm, ectomesenchyme*
- *describe, for the trunk, formation of the axial skeleton and epaxial/hypaxial skeletal muscles*
- *describe how limbs and separate digits are formed, including the origin of muscles & bone*
- *describe head development in terms of endochondral/intramembranous skull formation, somitomere/somite muscle formation, and cranial nerve innervation of pharyngeal arches*

Cardiovascular Development

Key Objectives:

- *comprehend how the endocardial tube is formed and what five tubular regions become in the adult heart*
- *comprehend heart development from six viewpoints: elongate & loop; shift venous return; partition atrioventricular opening; excavate ventricles; foramen ovale formation; and aorta/pulmonary trunk partition.*
- *comprehend how aortic arches contribute to major adult vessels located cranial to the adult heart*
- *comprehend how embryonic veins give rise to: cranial and caudal venae cavae, the portal vein, and pathologic portosystemic shunts*
- *describe the three cardiovascular adaptations necessary for in utero fetal development and their fate in the neonate*

Digestive System Development

Key Objectives:

- comprehend how splanchnopleure forms foregut, hindgut, and midgut connected to the yolk sac
- recognize the development of the oropharyngeal membrane, pharyngeal pouches and esophagus
- describe the stages of simple stomach development and understand how ruminant compartments arise
- describe intestinal tract development in relation to the cranial mesenteric a., yolk sac, and cecum
- explain(sketch) how the cloaca is subdivided the rectum and anal canal; what is the protodeum
- comprehend the origin of the pancreas, liver lobes, gall bladder, bile duct and duodenal papillae
- understand how mesenteries are formed in conjunction with regional gut formation

Respiratory System Development

Key Objectives:

- recognize that nasal process outgrow and give rise to primary & secondary palates, the nasal septum, conchae, and paranasal sinuses
- describe the origin of the larynx, trachea & lungs from the floor of the pharynx (laryngotracheal tube)
- understand that differential growth of pharyngeal swellings give rises to laryngeal cartilages, the vocal fold and laryngeal muscles and innervation
- describe (sketch) how the trachea and various bronchi develop
- comprehend how alveoli arise from terminal sacs and how lung development relates to birth

Urinary System Development

Key Objectives:

- understand how intermediate mesoderm is formed and what it becomes
- define: nephrogenic cord, pronephros, mesonephros, metanephros, nephron
- comprehend the dual source of metanephros development and report what the ureteric bud and metanephrogenic mass contribute to the adult kidney
- describe (sketch) the process of nephron formation
- comprehend how the urinary bladder, trigone region, and urethra arise from the urogenital sinus & urachus

Genital System Development

Key Objectives:

- understand the terms: genotype, phenotype, indifferent stage, supporting cell, germ cell, gonad
- describe the indifferent gonad in terms of supporting cell and germ cell origin and arrangement; describe subsequent gonad development in the case of a testis and an ovary
- describe genital ducts during the indifferent stage and what leads to male vs female development
- describe female development (uterine tube & uterus, vagina, broad ligament)
- describe male development (efferent ductules, epididymis, ductus deferens, accessory glands)
- explain descent of the testis events, including the fate of the gubernaculum and inguinal fold
- describe external genitalia components of the indifferent stage and what each becomes in the male and female
- recognize the development stages of mammary gland formation including species variations

Pharynx, Face, Nasal & Oral Development

Key Objectives:

- *define: face, cranium, pharynx, pharyngeal arch, pharyngeal pouch, oropharyngeal membrane, stomadeum*
- *comprehend that pharyngeal arches and pouches give rise various adult structures*
- *describe how the face is formed by outgrowth of mandibular and maxillary process of the first pharyngeal arch and nasal processes of the frontonasal prominence*
- *describe development of the nasal cavity and septum, including contributions of the primary and secondary palates and defects resulting from impaired development*
- *describe development of the oral cavity, including the processes by which lips, gingivae, tongue and salivary glands are formed*
- *describe (sketch) deciduous/permanent tooth development, including the origins of odontoblasts from dental papillae and ameloblasts from enamel organs*
- *explain the dual origin of the hypophysis (pituitary gland)*