

MORPHOLOGICAL ASPECTS OF THE THORACIC LIMB SKELETON IN BACTRIAN CAMEL

Cristian BELU, Anca ȘEICARU, Alexandru MANOLESCU, Sorina Andreea MIHAI,
Petronela Mihaela ROȘU, Iulian DUMITRESCU, Mădălina Laura ȘIRBU

University of Agronomic Sciences and Veterinary Medicine of Bucharest,
Faculty of Veterinary medicine, 105, Spl. Independentei, District 5, Bucharest, Romania

Corresponding author email: cristbelu@yahoo.com

Abstract

The paper describes in detail the particular aspects of the thoracic limb bones in two adult Bactrian camels. The working methods used were bone preparation and analysis of their macroscopic morphological features compared to large local domestic ungulates. The scapula of the camel has an intermediate aspect between those of equines and cattle. The humerus shows a reduction of the humeral neck and a less developed epicondylar crest. No delimitation between the articular surface of the proximal extremity of the radius and the semilunar surface of the ulna on the medial side was observed, which gives a maximum of consolidation of the zeugopodium, increasing the resistance to movement. The trapezius is absent from the second carpal bone row. The main metacarpal consisted of the fusion of metacarpals III and IV. The most important difference from the phalanges of equines and cattle is the lack of the sulcus that crosses in dorso-palmar direction the proximal joint surface.

Key words: camel, forelimb, humerus, zeugopodium, autopodium.

INTRODUCTION

Camelids, as compared to other domestic and farm ungulate, have been scientifically studied to a lesser extent. We used as study material the bones from two Bactrian camels, which belong to the Mammalia class, Cetartiodactyla order, Camelidae family, genus *Camelus*, *Camelus bactrianus* species (Bactrian camel or Asian/Mongolian camel). Recently, scientific research groups have begun to increasingly recognize and raise awareness of the importance of this species, as it is listed as critically endangered on the IUCN Red (International Union for Conservation of Nature). Like equines and cattle in our country, the Bactrian camel is socio-economically integrated into the lives of pastoral people in specific areas, represented by Central and East Asia's rocky deserts (Barat & Khomeiri, 2015; Gebreyohanes & Assen, 2017). It can better survive and easily move in drought conditions, representing a better means of transportation in the desert than other domestic animals. The camel shows different form of the distal extremity of the limbs as compared to cattle and horses, probably due to the anatomophysiological particulars. These aspects

should be known in order to offer the emergency medical care (Bani et al., 2008; Nourinezhad et al., 2014; Ocal, et al., 2004). Specialty literature is rather scarce as concerns studies regarding the osteology of Bactrian camelids. We have considered interesting and relevant the comparison between the thoracic limb bones in *Camelus bactrianus* and similar information existent in the literature for cattle and equines (Predoi et al., 2021).

MATERIALS AND METHODS

This study was carried out in the laboratory of the Anatomy discipline from the Faculty of Veterinary Medicine in Bucharest with the approval of competent authorities in the domain. The study material was represented by the bones obtained from an adult specimen (approximately 20 years old) from the Băneasa Zoo, Bucharest and a camel skeleton existing in the collection of the Comparative Anatomy laboratory of the Faculty of Veterinary Medicine Bucharest.

After skinning the corpse and removing the organs and muscle mass, the bone pieces were processed thermally in water with detergent for 4-6 hours. After completing this process, the

bones were cleaned under tap water and the remnants of soft tissues were manually removed. The bones thus obtained were placed in a 5% hydrogen peroxide (H₂O₂) was followed by washing in water and drying in a well-ventilated space. Following the analysis of the macroscopic morphological features, the pieces of interest were photographed.

RESULTS AND DISCUSSIONS

Forelimb zonoskeleton

In Bactrian camel, **the scapula** (Figure 1) is quite elongated in proximodistal direction. We found a ratio of 2:1 of the two proximo-distal and cranio-caudal axes, measured from the dorsal margin to the glenoid angle, respectively between the cervical and thoracic angles.

The lateral surface is crossed by an approximately rectilinear scapular spine, which increases progressively in height, starting from the dorsal edge, and reaching the maximum at the half of the bone.



Figure 1. Right scapula - lateral view:

- 1 – suprascapular fossa; 2 – infraspinous fossa;
- 3 – scapular spine; 4 – acromion; 5 – supraglenoid tuberosity; 6 – suprascapular cartilage; 7 – neck of the scapula; 8 – cervical angle; 9 – thoracic angle

The tuberosity of the scapular spine is elongated (reaching distally close to the origin of the acromion). Starting with its origin, the scapular spine is inclined over the infraspinatus fossa and, at the neck of the scapula, becomes perpendicular to the lateral surface of the bone. The ratio between the suprascapular and the

infraspinatus fossae is 1:2, identical to that of the horse. In the area of the suprascapular fossa, near the detachment edge of the scapular spine, there is one of the two first-order nutrient foramina of this bone.

The medial surface has a superficial subscapular fossa. Its surface is crossed by several vertical lines for muscle insertion.

The dorsal margin of the scapula is strongly convex (contrary to cattle where it is approximately rectilinear). The suprascapular cartilage was largely ossified in the studied specimens. The cervical margin is extremely thin, almost sharp along its entire length. On its lateral side, in the rectilinear area, there is a narrow, rough band for muscle attachment.

The thoracic margin is very thick. On this edge, at the cranial limit of the neck, the second first-order vascular foramen was identified.

The cervical angle is very fine, while the thoracic angle is thick, tuberos, in the form of an elongated tubercle, oblique in the proximodistal direction. The joint angle is supported by a long, thick neck. The glenoid cavity showed a cranio-caudal axis twice as long as the transverse one.

Compared to cattle, in which the acromion is widened, in camel it is cylindrical, thick, separated by a deep notch from the neck of the scapula.

The surface intended for insertion of the serrated muscles is extremely small, the lower limit reaching up to the middle of the cranial margin.

No glenoid notch similar to that of equines or cattle was observed, except, a wide notch present on lateral side of the thick and rough lip of the glenoid cavity.

Analyzing the general appearance of the scapula, we appreciate that it is intermediate, between that of equines and cattle.

Stylopodium

The **humerus** (Figure 2), although exhibiting a massive, thick body, due to the reduced ratio between its total length and width at the half of the bone, renders it a relatively slender appearance. As in equines, the humerus has three tubers: greater, lesser and intermediate, approximately equal. In camel, the tendinous groove located laterally to intermediate tubercle is much wider and shallower than the medial one. The insertion surface for the infraspinatus

muscle is circular (similar to cattle). The elongated, voluminous deltoid tuberosity is slightly drawn caudally.

As concerns the humerus, the essential differential element is the reduction of the neck that supports the head, which leads to an increase of the angle between the axis that passes through the center of the articular head and the axis of the shaft. Dissimilar to cattle and horses, the brachial groove is not well defined; the epicondyle crest was absent.

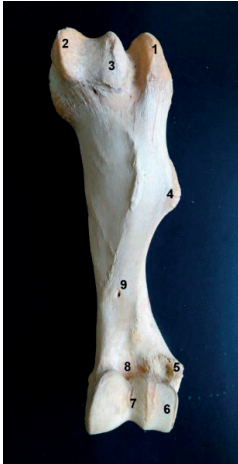

Figure 2. Left humerus - cranial view:

- 1 – greater cranial tubercle; 2 – lesser cranial tubercle;
- 3 – intermediate tubercle; 4 – deltoid crest; 5 – lateral epicondyle; 6 – humeral condyle; 7 – humeral trochlea;
- 8 – coronoid fossa; 9 – main vascular foramen

Zeugopodium

The bones of the zeugopodium are completely fused excepting the proximal and distal arches (interosseous spaces), which form a single piece, called in the literature radioulnar bone (Gupta et al., 2015), on which the boundaries of the two bones can be observed only by careful examination. Unlike cattle and horses, the Bactrian camel shows no diarthrodial joint surfaces. The oblique medial distal groove, characteristic for cattle and horses, could not be identified (Figure 3).

The proximal end of the **radius** was slightly widened transversely, forming two glenoid cavities, of approximately same dimensions, but with different appearance. The elevation that separates them is the highest eminence of this surface. The lateral surface is divided into two areas in continuity. Laterally, a cranio-

caudally elongated cavity is observed. Its cranial half continues in the medial direction with a smaller articular area, which extends above the mentioned eminence with the medial cavity. The lateral articular surface, formed by the two subdivisions, deepens in the central part, the place where the lateral lip of the humeral trochlea enters.

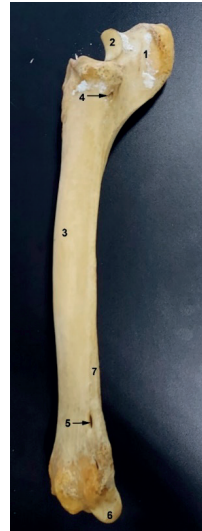

Figure 3. Radius and ulna of the left limb - lateral view:

- 1 – olecranon; 2 – semilunar notch; 3 – body of the radius; 4 – proximal radio-ulnar arch; 5 – distal radioulnar arch; 6 – ulnar styloid process; 7 – body of the ulna

The medial articular surface continues caudally with the articular surface of the semilunar notch. In the middle of the dorsal surface of the entire joint surface is a rough area, the synovial fovea, relatively large. On the anterior margin of the articular surface protrudes a strong coracoid process, from which start two grooves, one medial and one lateral, the first being more inclined than the second. The connection between the olecranon and the proximal end of the radius is very strong. There are no diarthrodial joint surfaces present in domestic ungulates. We consider these elements a particularity that gives maximum strength to the zeugopodium, increasing the resistance in movement. Immediately below the anterior edge of the proximal surface, on the corresponding side of the proximal extremity of the shaft, there is a rough area, well defined, relatively large, corresponding to the biceps

tuberosity. The lateral tuberosity of the radius, delimited by a notch at an angle of 90° from the lateral articular surface of the proximal extremity, is very prominent and rough, being much more elevated than the bicapital one.

The distal end of the radius, slightly more voluminous than the proximal one, has a widened articular surface, with a concave-convex appearance in the cranio-caudal direction. More precisely, in the anterior part, we identified three true cavities, continued caudally with three condyles, their direction being perpendicular to the axis of the bone, as in equines. By careful examination of this extremity, we observed that the lateral condyle belongs ontogenetically to the ulna. There is a rough area, placed at the border between the medial and median articular formations of the distal extremity, which represents a synovial fossa. On the anterior part of the distal extremity, there are two wide grooves, separated by a protrusion, for the common digital extensor and carpo-radial extensor muscles. The presence of three digital fossae was noticed, a wider medial one, a rough central one and a lateral one, slightly oblique. The body of the radius has the longitudinal axis slightly twisted: in the upper third, it is slightly curved, the convexity being directed medially, while in the middle and distal third, it is rectilinear. The medial margin of the radius shaft begins with a shallow, rounded part and then, after the first quarter, continues with a prominent ridge that runs caudo-distally in the second quarter, vertically from the middle of the bone to the distal quarter, where it fades, the edge remaining rounded and rough. The caudal surface of the radius forms a synostosis with the cranial surface of the ulna. Below the proximal extremity of the radius there is a canal about 5 cm long that replaces the proximal radio-ulnar arch. The distal radio-ulnar arch shows two narrow spaces, with a maximum length of 11-13 mm each, that separate the distal end of the ulna from that of the radius.

The **ulna** has a short olecranon as compared to the total length of the bone. The tuberosity of the olecranon is reduced and, when viewed caudally, is rounded in the proximal part and sharp in the distal part. It is slightly beveled on the rostral side, with a transverse notch similar to cattle, but much wider. The apex of the

olecranon, slightly prominent, is rostrally directed and continued distally with articular surfaces. The medial surface is in continuity with the articular surface of the proximal extremity of the radius. The lateral one is interrupted by the synovial fossa of the humero-radial joint.

Basipodium

There are seven carpal bones, located in two rows, proximal and distal, as in equines, the trapezium being absent from the distal row (Figure 4).

The **accessory bone** (*Os carpi accessorium* syn. *Os pisiforme*) presents, as in equines, two articular surfaces, one for articulation with the ulnar condyle and another for articulation with the pyramidal. The articular surfaces of the accessory bone are concave and separated only by a short ridge. The caudal part of the bone progressively narrows to form a rounded tuber, slightly directed proximal, making the dorsal edge of the pisiform to be concave and shorter than the distal one, which is thick and convex. The groove of the metacarpal tendon of the carpoulnar extensor muscle was not identified.

The **ulnar bone** (*Os carpi ulnare* syn. *Os triquetrum*) does not resemble that of equines or cattle. It is an approximately parallelepiped bone, concave convex in the dorso-palmar direction. Dorsally, it articulates with the ulnar condyle and, partially, with the distal articular surface of the radius. The lateral dorsal and palmar surfaces are rough. Only the medial surface exhibits two articular surfaces, one proximal and one distal, located towards the dorsal margin, intended for articulation with the two congruent surfaces of the intermediate bone (lunate).

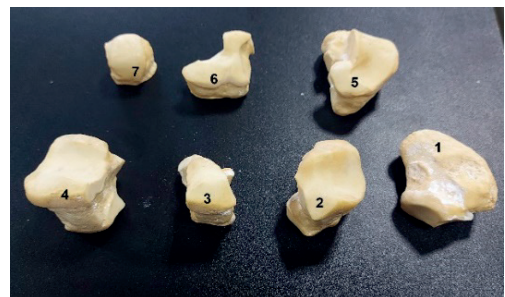


Figure 4. Carpal bones of the left limb - dorsoproximal view: 1 – accessory bone; 2 – ulnar bone; 3 – intermediate bone; 4 – radial bone; 5 – 4th carpal bone; 6 – 3rd carpal bone; 7 – second carpal bone

The **intermediate bone** (*Os carpi intermedium* syn. *Os lunatum*) is taller than wide, being smaller than the ulnar and radial bones. The distal articular surface of the intermediate bone consists of two elongated articular areas, separated by an elevation in the median plane of the bone. The dorsal, non-articular surface is high and slightly narrowed in the middle, as in cattle. The palmar surface, non-articular, shows a more developed tubercle, directed towards the median plane. This tuber has a joint surface for the scaphoid bone.

The **radial bone** (*Os carpi radiale* syn. *Os scaphoideum*) is the largest bone in the proximal row, with a parallelepiped appearance. It has the distal articular surface formed by two cavities, one superficial, anterior, and one deep, almost circular (intended for the convexity of the trapezoid). They are separated by an evident transverse eminence, perpendicular to the one described in the lunatum. Between the dorsal and medial surfaces, in the upper angle, a tubercle widened in transverse direction was observed.

The **fourth carpal bone** (*Os carpale quatum IV* syn. *Os hamatum*) differs from that of bovines and horses, being flattened proximodistally. Thus, the proximal and distal joint surfaces are very large. The proximal one is intended for articulation with the ulnar bone, as well as with the lunate bone. The articular surface of the fourth carpal bone with the ulnar bone is concave convex in dorso-palmar direction. The articular surface intended for the lunatum is subdivided into a dorsal area, oriented proximally and a palmar area that becomes almost vertical. On the palmar side is a tuber with a sharp distally directed prominence. The relatively regular dorsal non-articular surface (rectangular) is widened transversely and continues through a rounded angle with the lateral one. Due to the narrowing of the bone in palmar direction, we noticed a third surface of the outline, medio-palmar, with two articular surfaces, one dorsal and one palmar, separated by a wide and rough notch.

The **third carpal bone** (*Os carpale tertium III* syn. *Os capitatum*) is flattened and reduced, showing dorsally a triangular outline due to the presence of the palmar tubercle. It articulates with both the lunate and radial bones. The dorsal surface of the 3rd carpal is non articular, and the lateral one is congruent with the medio-

palmar surface of the carpal bone. The medial surface has two central joints, each having a semicircular shape. These two surfaces are intended for the second carpal bone.

The **second carpal bone** (*Os carpale secundum II* syn. *Os trapezoideum*) is almost cubic shaped. The proximal articular surface is a true articular head, strongly convex in all directions.

Metapodium

The **main metacarpus** (Mc.) is formed by fusion of Mc. III and IV. The proximal end of the main metacarpus has a slightly widened articular surface represented by three areas: an approximately triangular, planiform, lateral one, intended for the carpal bone, separated by a prominence from the areas for the 3rd and 2nd carpal bones; between the last two areas there is a second, much smaller eminence. In the central part, caudal to the main prominence, is a deep synovial fossa.



Figure 5. Metacarpal bone:

- 1 – proximomedial tuberosity of the metacarpal bone;
- 2 – metacarpal III; 3 – metacarpal IV; 4 – dorsal longitudinal groove; 5 – distal articular surfaces

On the medio-proximal side, an elongated tuberosity occupies the proximal extremity of Mc. III and the medial extremity of Mc. IV. The shaft is thick in the proximal and middle third and flattened in the distal third (Figure 5). The caudal surface of the shaft describes a wide convexity from bottom to top and is slightly

concave in transverse direction. The concavity is formed by two high and rough ridges, which limit this surface laterally and medially. On the dorsal surface of the shaft lies a longitudinal groove. The distal extremities of the two metacarpals that participate in the formation of the intermetacarpal groove are slightly divergent. An interesting feature, as compared to cattle, is the conformation of the joint surfaces of each participating bone. Thus, the condylar surfaces, separated by the eminences characteristic to ruminants, are placed caudally.

Acropodium

Phalanges of camels have a quite different appearance than those of bovines and horses. The most important difference from equines and cattle **phalanges** is the lack of the groove that crosses the proximal articular dorso-palmar surface, this being replaced by a shallow glenoid cavity that has contact only with the anterior, convex part of the distal articular surface of the metapodium bones (Figure 6).

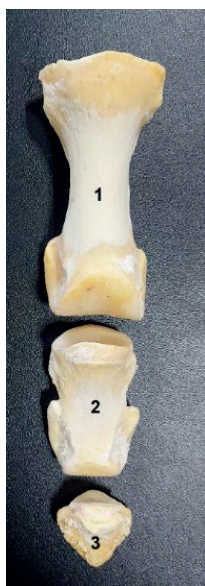

Figure 6. Phalanges of the anterior right limb:
1 – proximal; 2 – middle; 3 – distal

The proximal phalanx has a very long body, being quite symmetrical in respect to its longitudinal axis as compared to cattle. Its extremities are voluminous. The second phalanx is more flattened dorso-palmar than in cattle, and longer than in horse, and highly symmetrical in respect to its longitudinal axis.

The distal phalanx is very short, with a pyramidal appearance. At the base of the distal phalanx, three angles slightly spaced from the joint surface, were noticed. One dorsal, corresponding to the pyramidal eminence and two lateral.

CONCLUSIONS

Compared to equines and cattle, the general appearance of camel scapula is closer to that of equines. The presence of the acromion makes a clear difference. The humerus as a whole can be easily confused with that of the horse. We consider that the reduction of the humeral neck and the reduced crest of the epicondyle in camels are specific elements of differentiation. The bones of the forearm, the radius and the ulna, are fused along the entire length of their shaft. The suture line is not visible. The radius has two glenoid cavities at the proximal extremity. The appearance of the distal extremity, relates much to the radius of horse. There are seven carpal bones, resembling those of equines. Exceptions are the ulnar bone (more like the lunatum bone) and the 4th carpal bone (with an intermediate shape between equines and the bovines).

Although we did not have the opportunity to perform functional studies, we can anticipate that in camel, the structure of the mid-carpal joint contributes to the mobility of the joint complex, much more than in bovines and equines. The extension of the convex surfaces on the palmar edge of the third and second carpal bones, supports this statement.

As a general conclusion, we appreciate that the morphology of the skeleton of the thoracic limb in the Bactrian camel presents common elements with both equines and cattle, but also specific elements that allow the differentiation of bones.

REFERENCES

- Barat, A.Y.Z., & Khomeiri, M. (2015). Introduction to camel origin, history, raising, characteristics, and wool, hair and skin: a review. *RJAEM*, 4(11), 496-508.
- Bani Ismail, Z., Alzghoul, M.B., Daradka, M., Al-Shiyab, A.H., & Tashman, O.G. (2008). Morphometric measurements of digital bones in juvenile male camels (*Camelus dromedarius*). *J. Camel. Pract. Res.*, 15, 117-120.
- Gebreyohanes, M. G., and Assen, A. M. (2017). Adaptation mechanisms of camels (*Camelus*

- dromedarius*) for desert environment: a review. *J. Vet. Sci. Technol.* 8, 6–10.
- Gupta, s. K., Deshmukh, S. K., Karmore, S. K. (2015). Gross morphometrical study on the forearm bones of camel (*Camelus dromedarius*). *Veterinary Practitioner*, 16(2), 286-287.
- Nourinezhad, J., Mazaheri, Y. & Ahi, M.R. (2014). Metrical analysis of dromedary digital bones. *Anat. Sci. Int.*, 14-24.
- Ocal, M.K., Sevil, F. & Parin, U. (2004). A quantitative study on the digital bones of cattle. *Ann. Anat.* 186,165.
- Predoi, G., Belu, C., Seicaru, A. (2021). *Anatomy of domestic animals: Osteology, Arthrology and Myology* (pp. 31-50). Bucharest, RO: Ex Terra Aurum Publishing House.