

Surface anatomy and
structure of anterior abdominal
wall.by
talib jawad , 12\ 10 \ 2021

[Anterior Abdominal Wall: Structure & Layers, Dr Adel Bondok Making Anatomy Easy - YouTube](#)

[Anatomy of anterior abdominal wall - dissection - Bing video](#)

Learning outcome

At the end of the lecture we must understand the following :

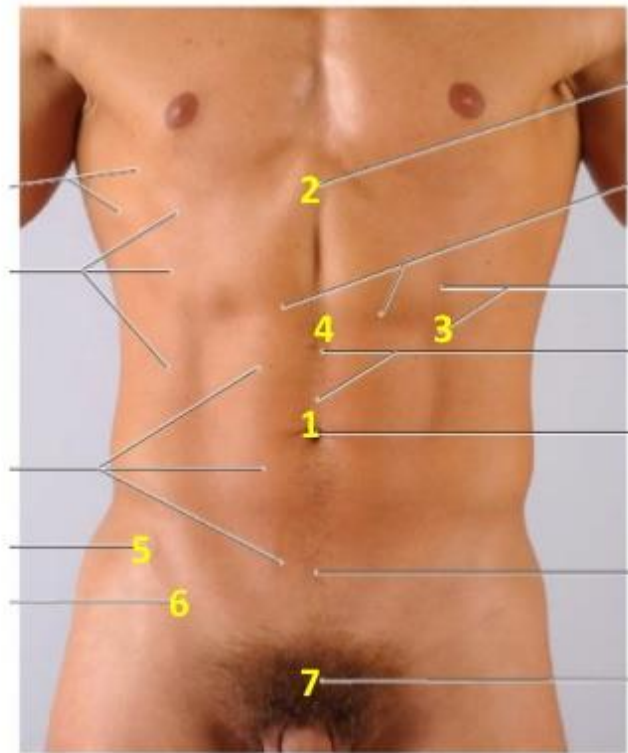
Abdominal landmarks and surface anatomy

Structure of the wall and blood, lymphatic, and nerve supply.

Clinical applied anatomy of anterior abdominal wall

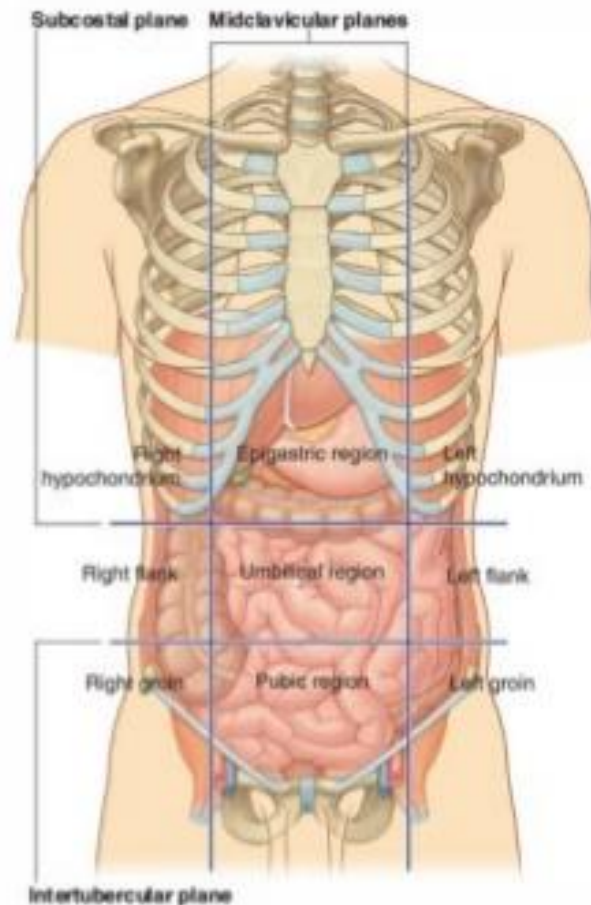
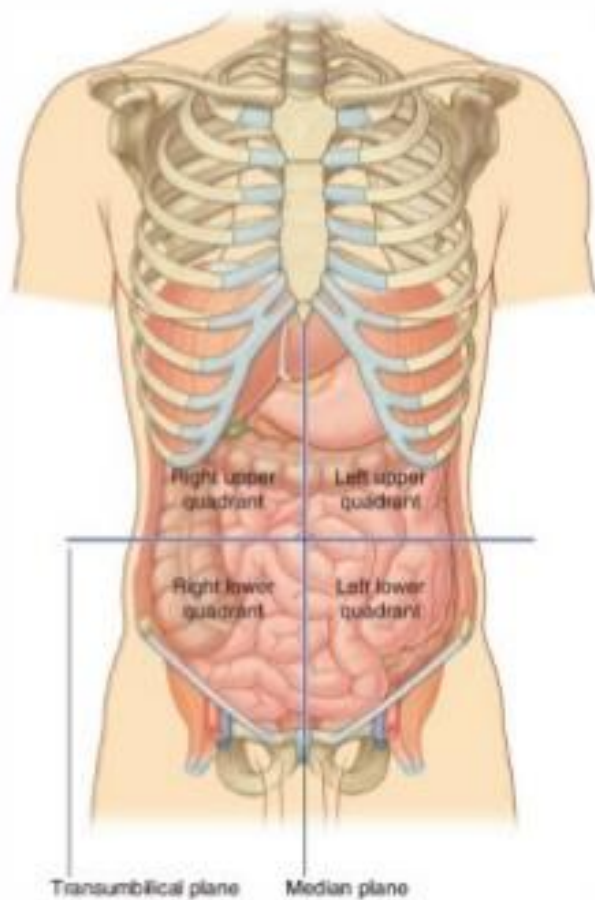
Surface anatomy of abdomen

1. Umbilicus
2. Xiphoid process
3. Lina emilunaris
4. Lina alba
5. Anterior superior iliac spine (ASIS)
6. Inguinal ligament
7. Pubic symphysis



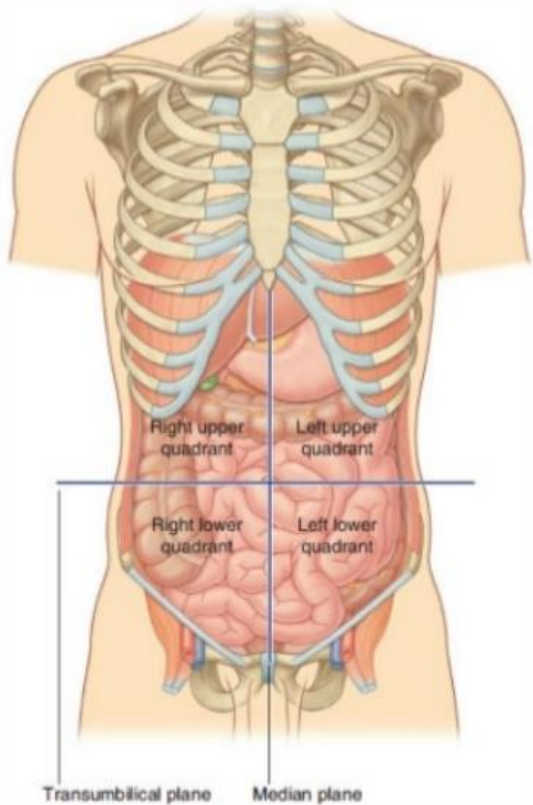
Quadrants of the abdomen

- Abdomen is divided either as four quadrants pattern or six quadrants pattern

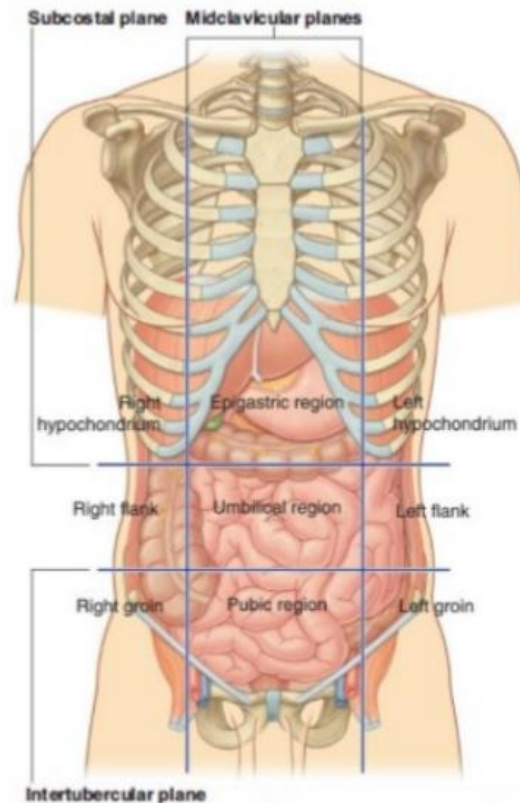


Abdominal quadrants

➤ Midline and transabdominal plane divided the abdomen into 4 quadrants



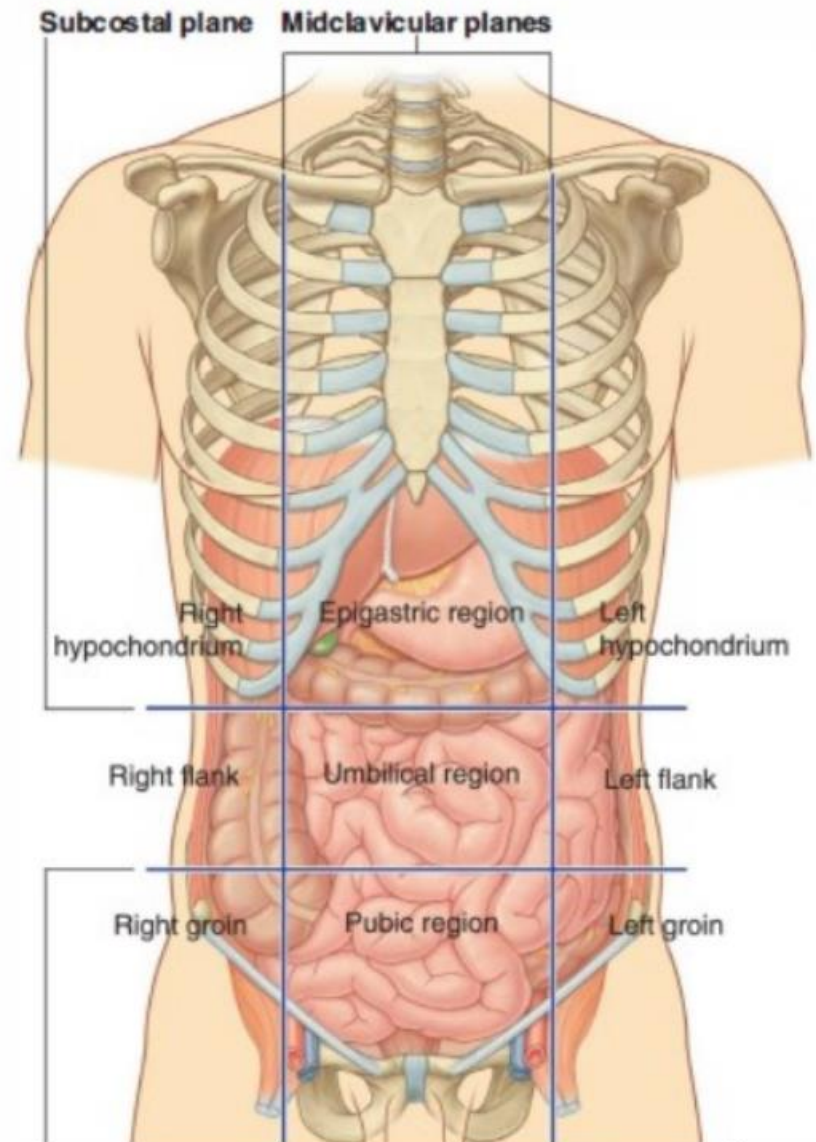
• Subcostal, intertubercular and 2 midclavicular planes divide the abdomen into 9 quadrants



➤ Transpyloric plane may be used instead of subcostal plane !!

Nine-quadrants of abdomen

1. right & left hypochondrium (2)
2. epigastric (1)
3. right & left flank (2)
4. umbilicus (1)
5. right and left groin (2)
6. pubic (1)



Basic anatomy

Abdomen : area between diaphragm above and pelvic inlet below.

Between: xiphoid process (level of 9th costal cartilage) above to pubic symphysis (level of coccyx) below.

content reach up to T8 in midline, and to 5th rib in midclavicular line.

Costal margin:

Midclavicular line : L1, (9th costal cartilage)

Mid axillary: L3 , (11th rb)

Costo-diaphragmatic recess

- ***Posteriorly : upper border of L1(crosses 12th rib).***
- ***Mid-axillary: at 10th rib, at L3 , 4 cm superior to iliac crest.***
- ***Penetrating wounds of chest includes abdominal content.***
- ***Only deep inspiration liver and enlarged spleen can be palpate inferior to costal margin, but hidden in quiet respiration.***

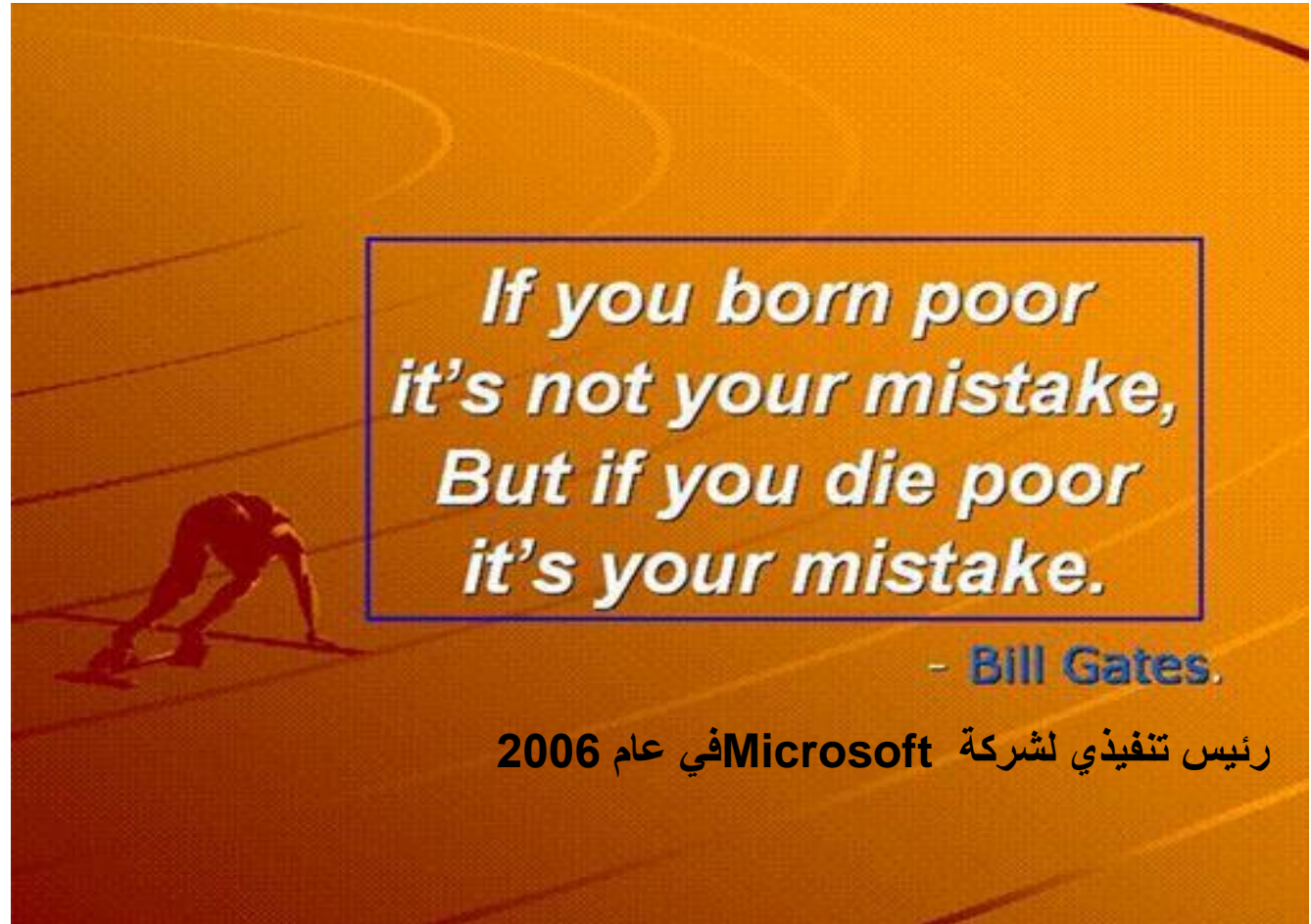
He is best known as the co-founder of Microsoft Corporation.

Education: [Harvard University](#) (dropped out)

Parents: [Bill Gates Sr.](#) (father); [Mary Maxwell](#) ...

Years active: 1975–present

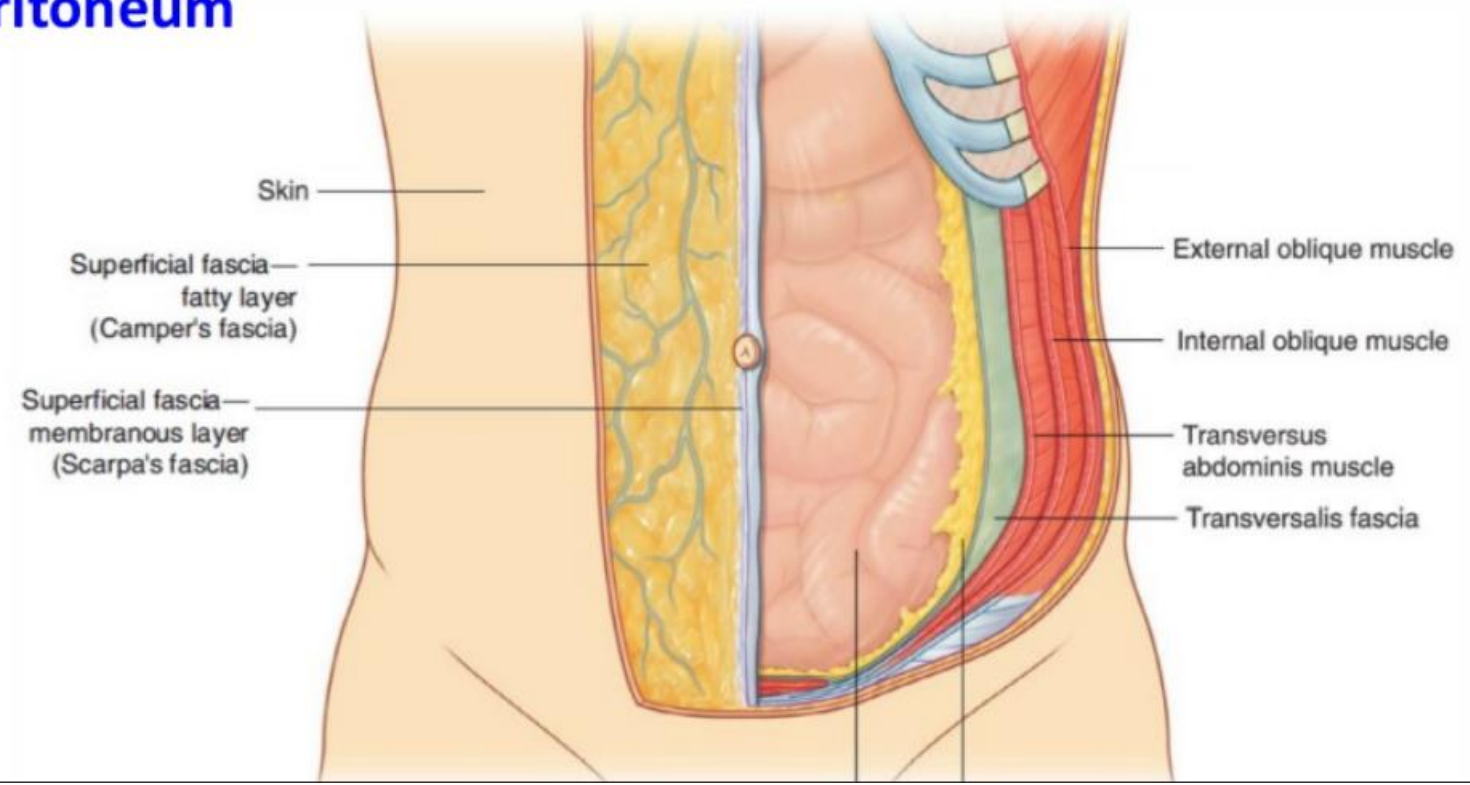
Occupation: Software developer; investor; entr...



رئيس تنفيذي لشركة Microsoft في عام 2006

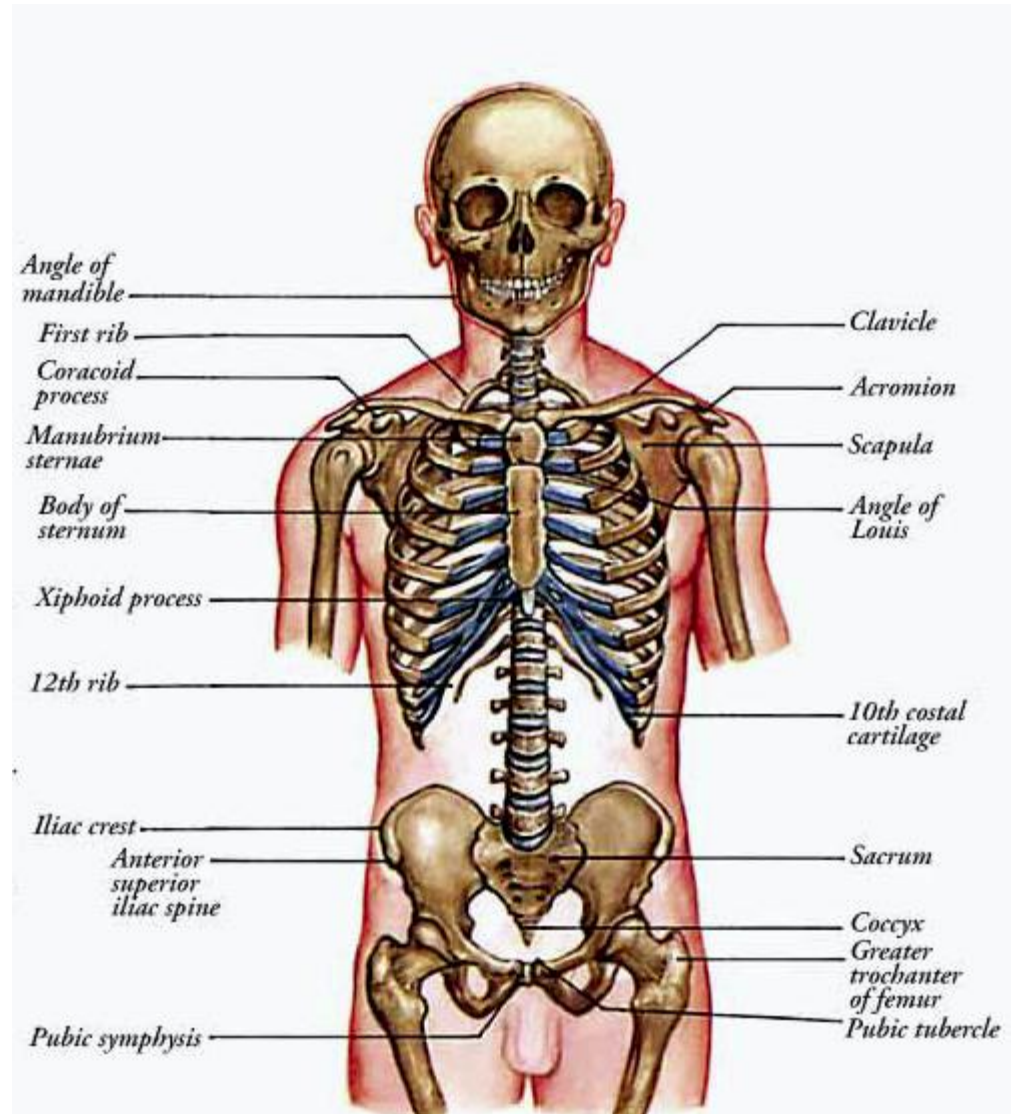
Abdominal wall

1. Skin
2. Superficial fascia (subcutaneous)
3. Muscles & associated deep fascia
4. Extraperitoneal fascia
5. Parietal peritoneum



Bones

- Lower ribs and costal cartilages
- Lumbar vertebrae
- Sacrum
- Hip bone

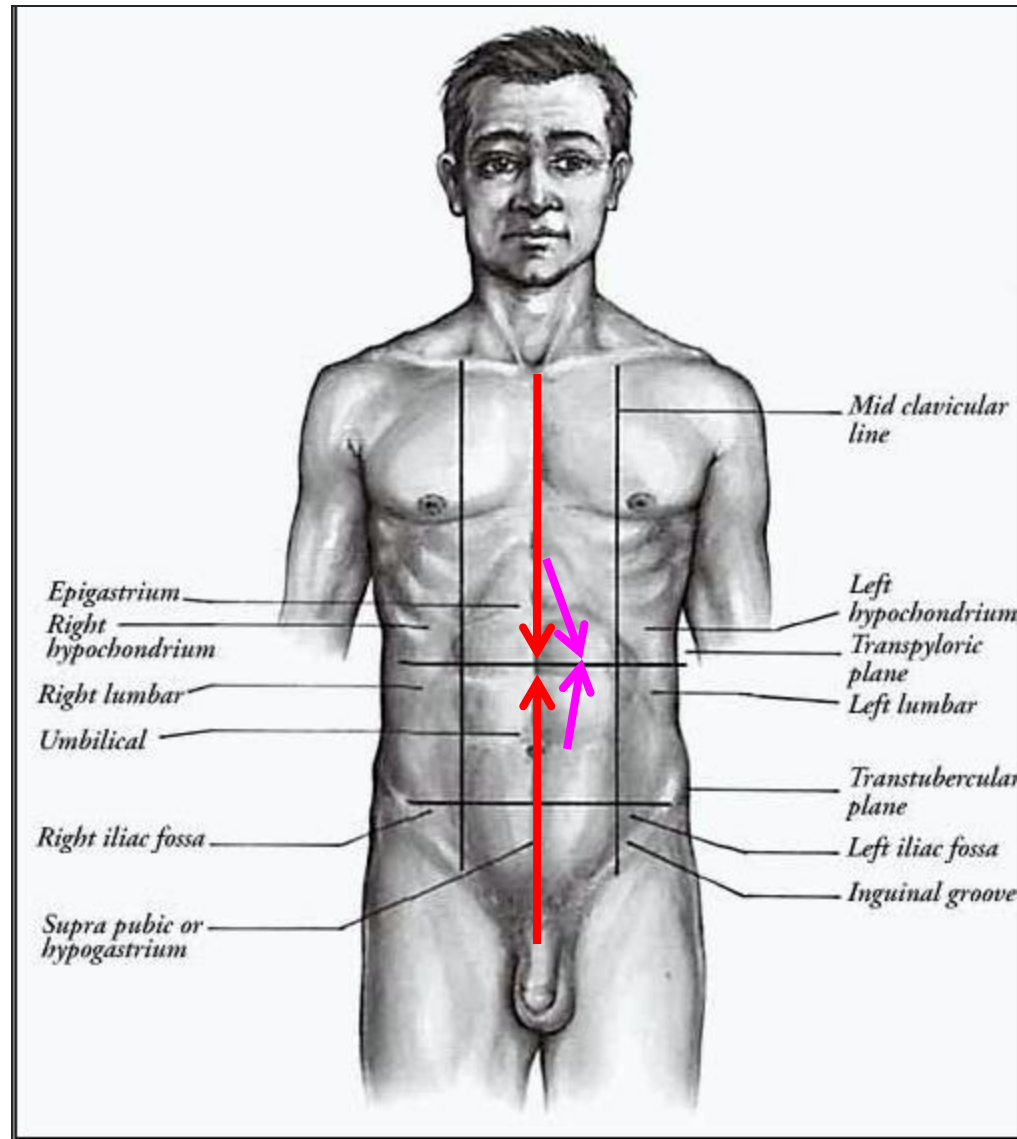


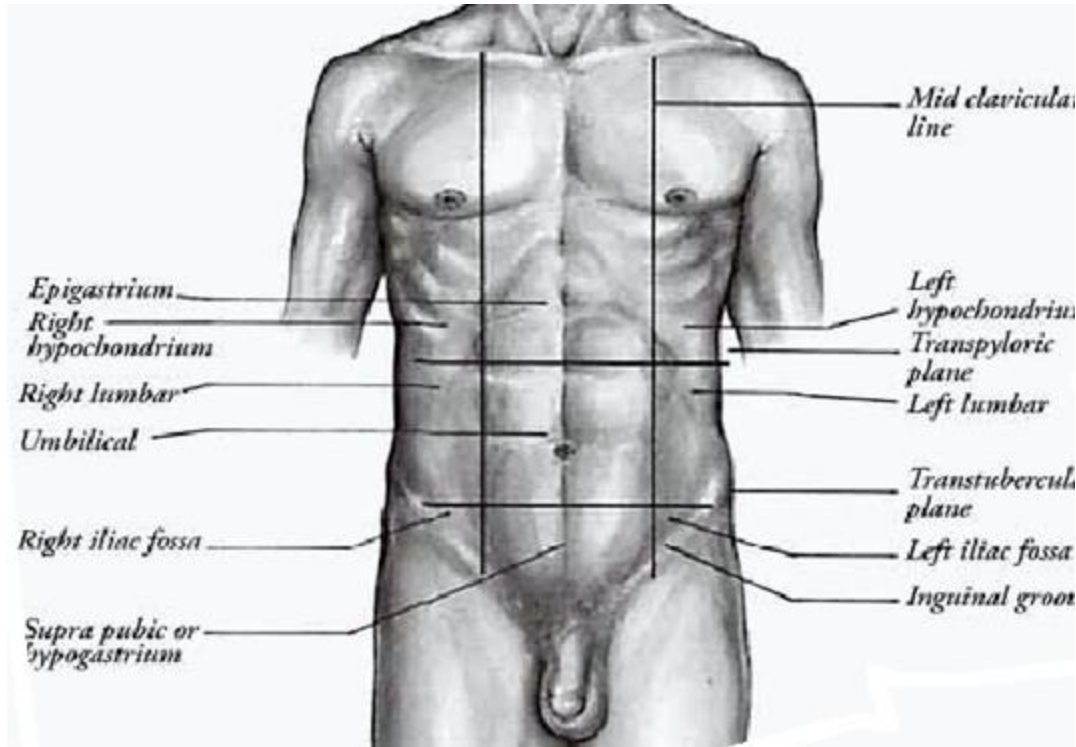
- **Surface marking of anterior abdominal wall**
- **Umbilicus**
 - L3-4
 - aorta bifurcates about 2 cm distal to it.
- **Linea Alba**
- The median groove: can be seen by flexing the trunk.
- It is wide and obvious above the umbilicus but is almost linear and invisible below this level.

- **Linea Semilunaris**
- lateral margin of the rectus sheath,
- Inferiorly, it rises from the pubic tubercle, then passes upwards and outwards to reach the costal margin at the level of the tip of the **ninth costal cartilage**
- **On the right side, this marks the usual position of the fundus of the gallbladder.**

surface anatomy

Midclavicular line
Transpyloric plane: L1
Trans tubercular plane: L5
2 Midclavicular line:
mid point of clavicle and mid
pint of inguinal
ligaments





❑ The two vertical lines:

Mid clavicular lines on either side.

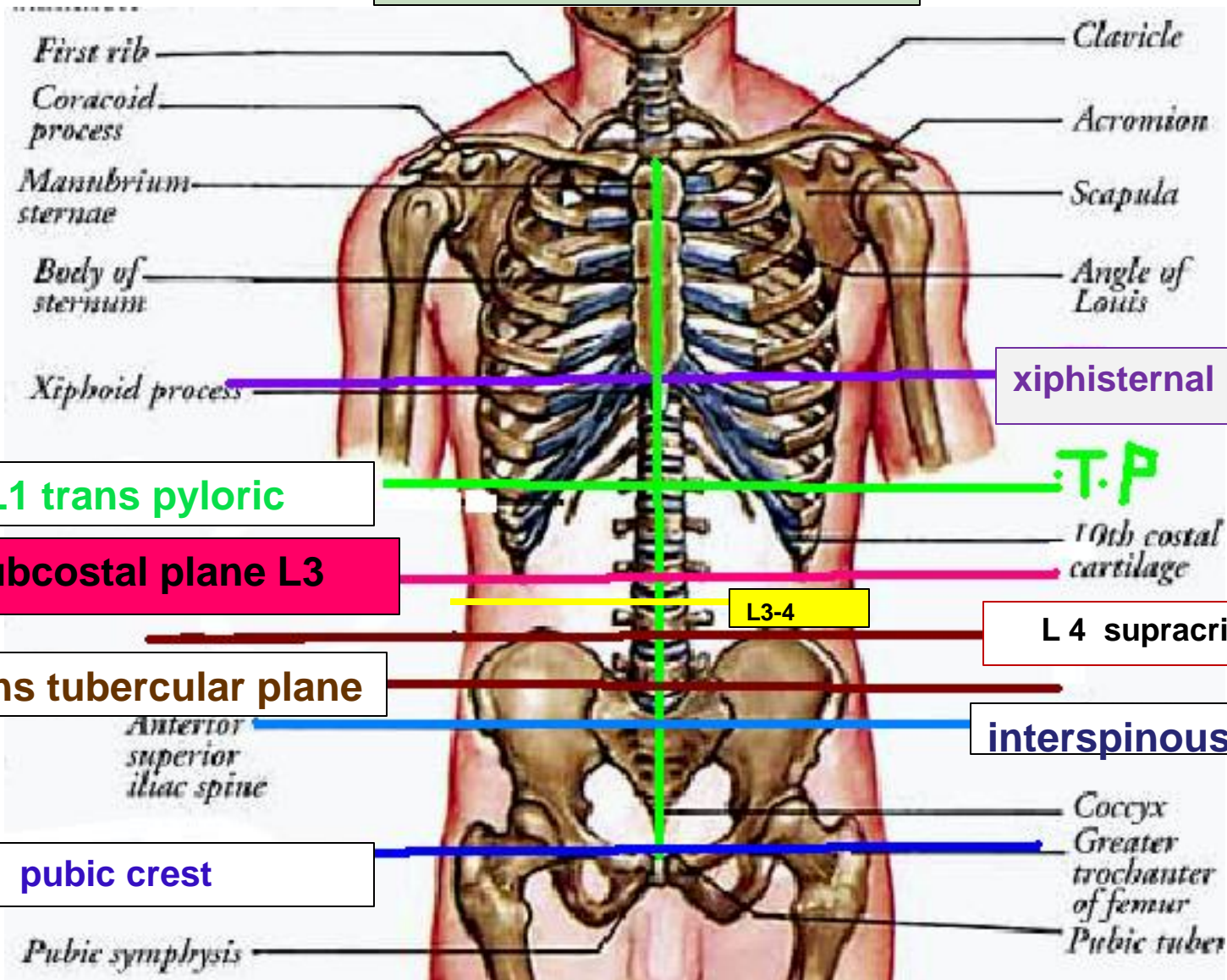
❑ Two horizontal lines: transpyloric and the transtuberous planes.

• The nine regions thus formed are:

- Epigastrium
- Hypochondrium
- Umbilical region

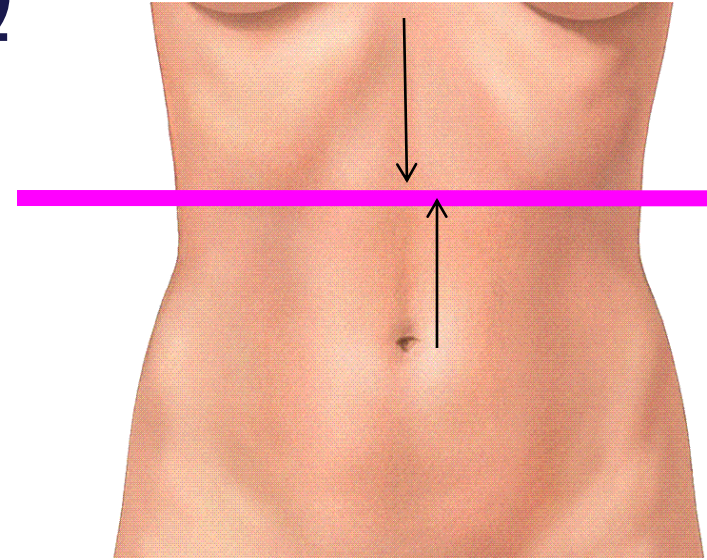
- the right and left lumbar region
- the hypogastrum (or suprapubic region)
- the right and left iliac fossa.

Horizontal plains

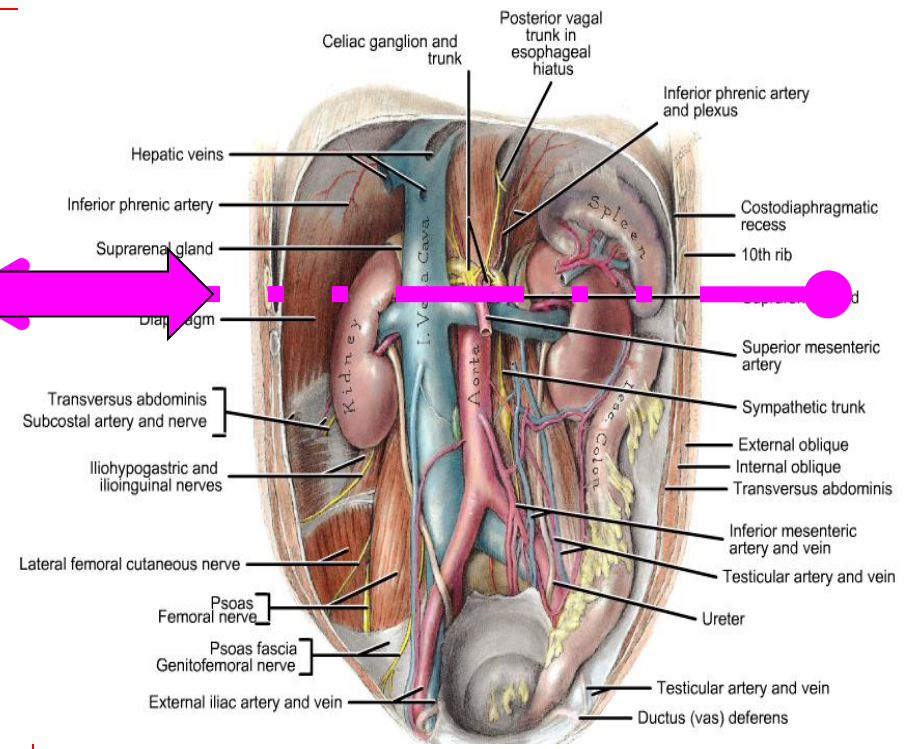


❖ Transpyloric plane:(of Addison)

- Midpoint: suprasternal notch-symphysis pubis
- Midway: umbilicus -inferior end of sternum, or at midpoint: umbilicus and xiphoid
- Hand's breadth of the subject below the xiphisternal joint.
- At tip of 9th rib



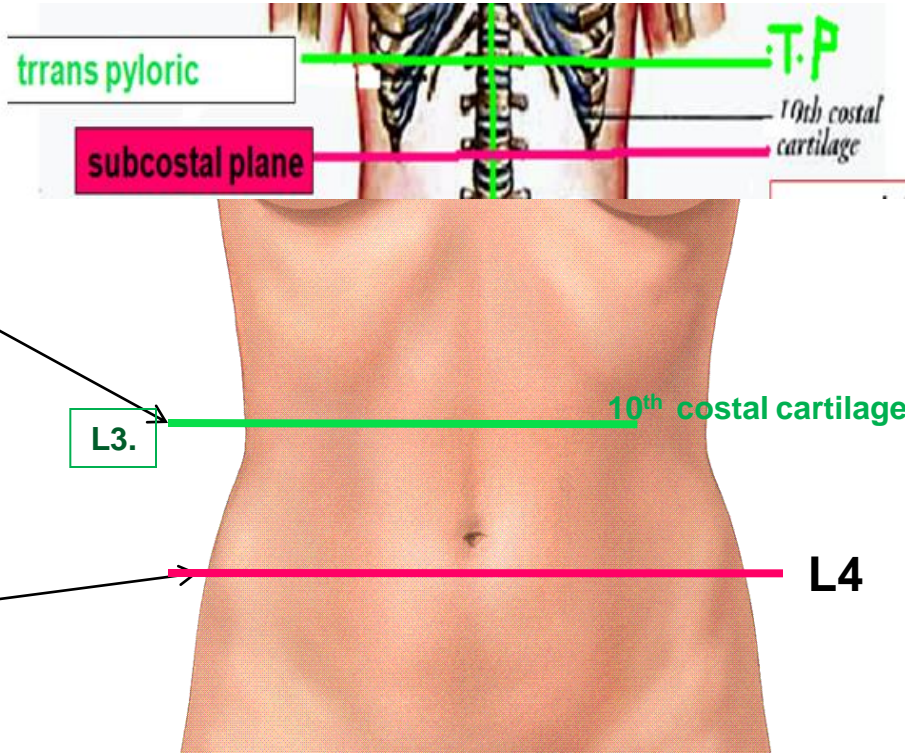
- **Structures at trans pyloric plane are:**
 - **the hila of both kidneys**
 - **the origin of the superior mesenteric artery from the aorta**
 - **the termination of the spinal cord**



- **the neck and adjacent body and head of the pancreas**
- **the confluence of the superior mesenteric and splenic veins, forming the hepatic portal vein.**
- **Pylorus, duodeno-jejunal junction, Greater and lesser curvature of stomach**

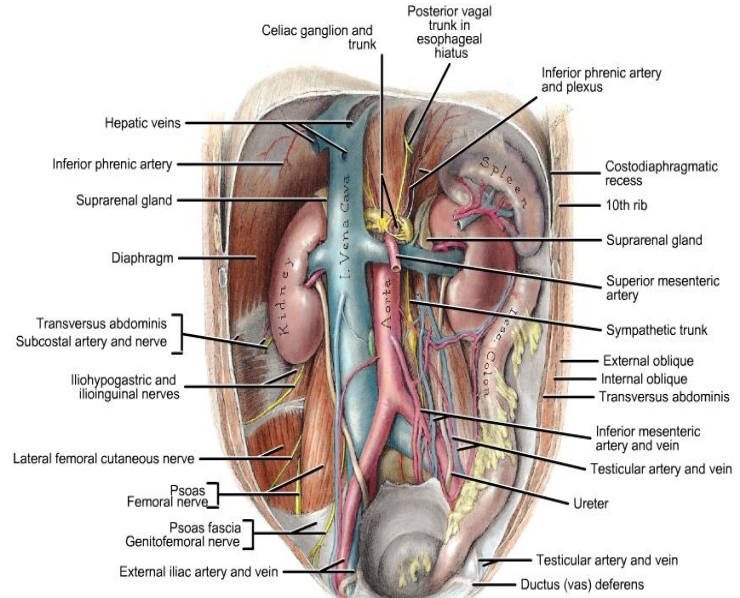
The subcostal plane

- lower margins of the thoracic cage,
- 10th costal cartilage on each side.
- L3.
- origin of the inferior mesenteric artery
- horizontal (third) part of the duodenum.



The supracristal plane

- crest on each side.
- L4
- bifurcation of the abdominal aorta,
- landmark in performing lumbar puncture (L4-L5 or L5-S1).
safely below the termination of the spinal cord.



Trans tubercular plane:

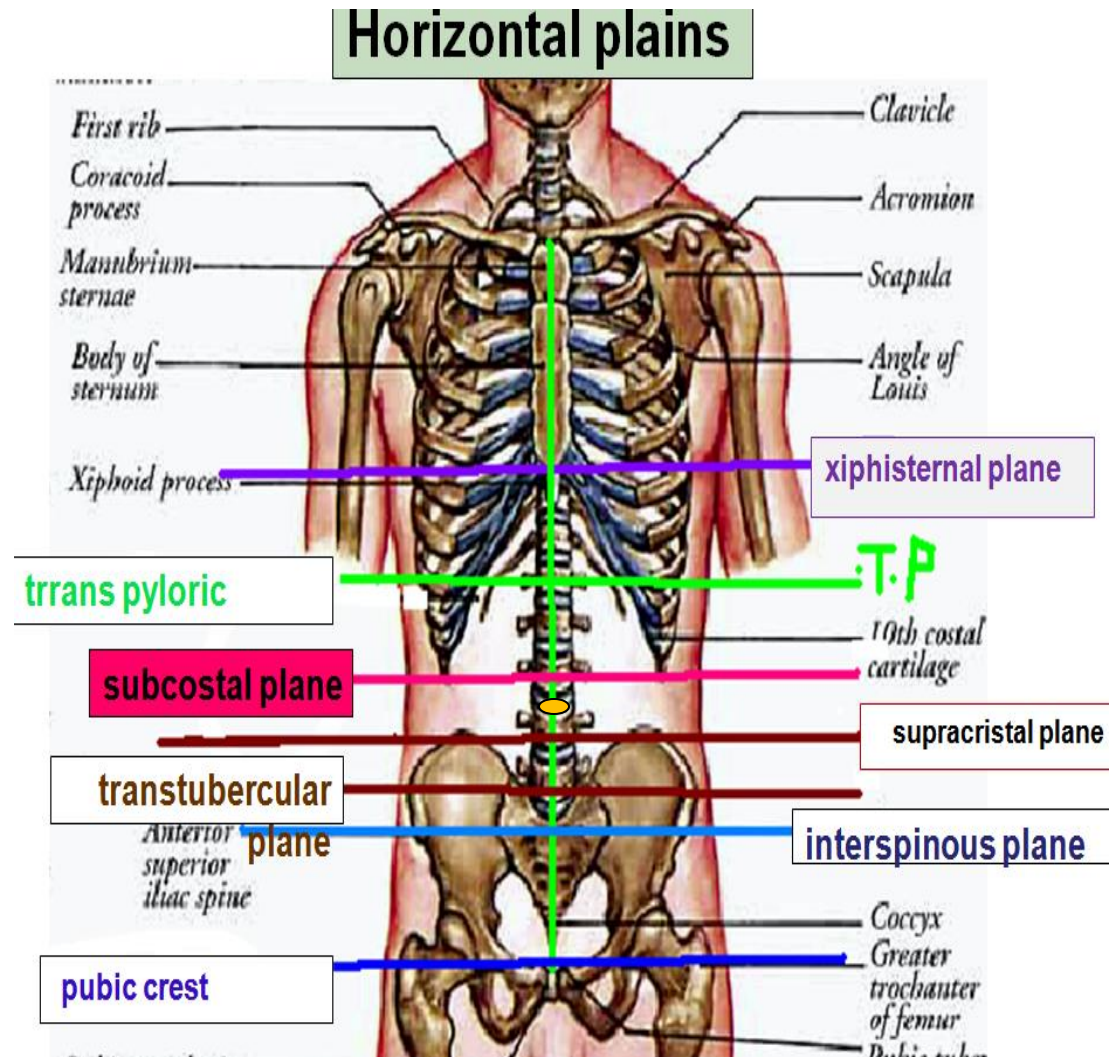
- at tubercles of the iliac crests.
- L5 upper border or is just above, the confluence of the common iliac veins and marks the origin of the inferior vena cava.

Interspinous plane

- anterior superior spines.
- lumbosacral disc, or sacral promontory, or just below, depending on the degree of lumbar lordosis, sacral inclination and curvature.

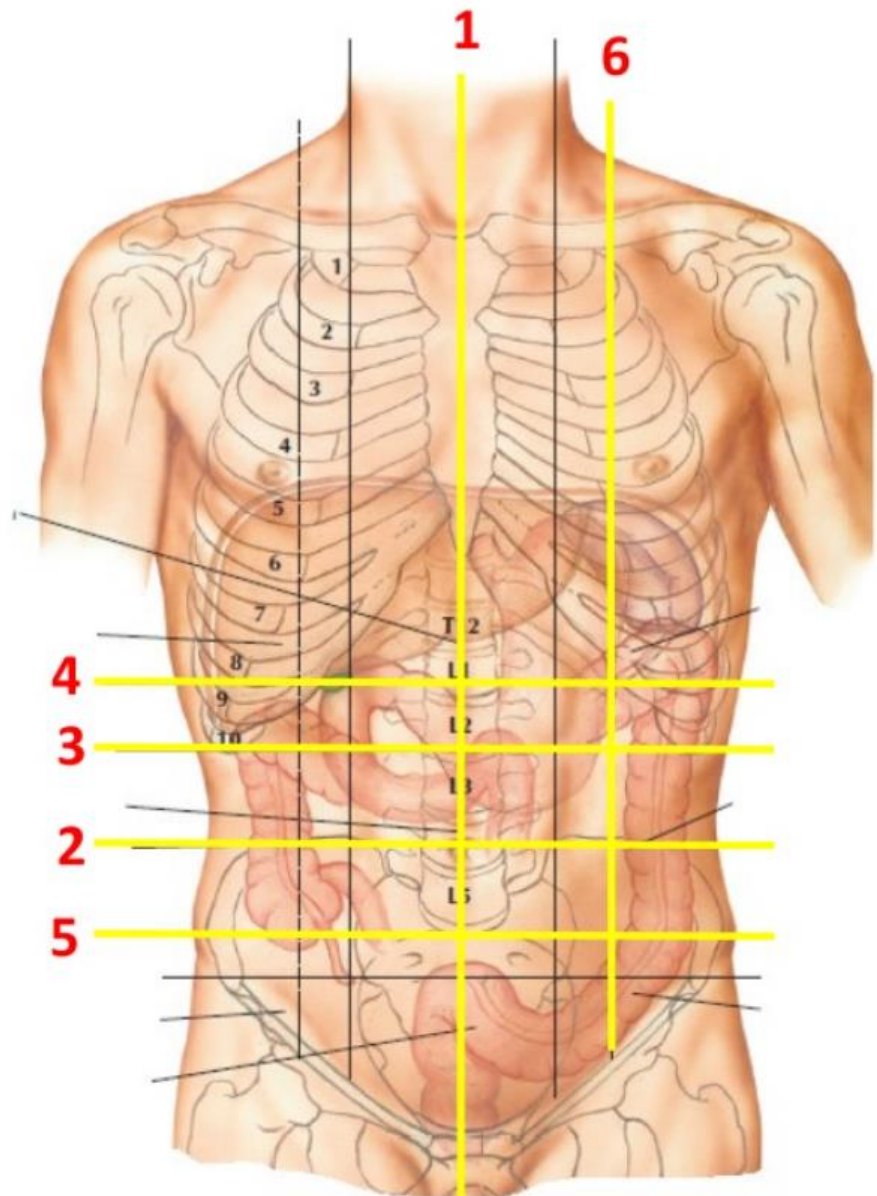
Plane of the pubic crest

- Inferior end of the sacrum or part of the coccyx, again, depending on the degree of lumbar lordosis, sacral inclination and curvature.



Planes used to estimate abdominal structures

- 1) **midline plane**
- 2) **transumbilical plane** : pass between the Intervertebral disk (IVD) between **L3-L4 vertebrae**
- 3) **Subcostal plane** : at the costal cartilage of X rib .. And pass through the body of **L3 vertebrae**
- 4) **transpyloric plane** : at midline between the jugular notch & pupic symphysis .. Cross the costal margin at rib IX ...
- 5) **intertubercular plane** : pass through the tubercles of iliac crest, it pass also through **L4 vertebra** ..
- 6) **midclavicular plane** : pass through mid clavicle above and between in the mid-point between anterior superior iliac spine and pupic symphysis



**R
e
s
t**

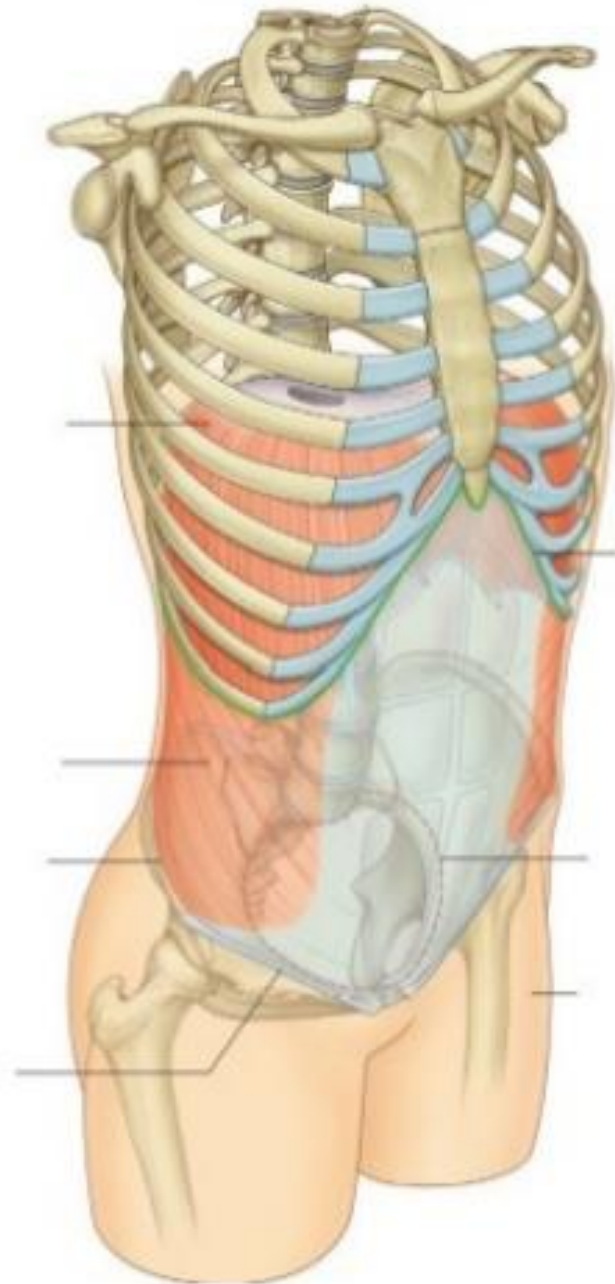
Without comment



For 3 m minutes

Abdomen

- Abdomen is a cylindrical chamber extending from the inferior margin of the thorax to the superior margin of pelvis and lower limb.
- The abdomen is margined superiorly by the **inferior thoracic aperture** and inferiorly by the **pelvic inlet**.
- **Abdominal wall** enclose the chamber
- This chamber have only **ONE** large cavity = **peritoneal cavity**



Walls of abdomen

- **above : diaphragm**
- **below : pelvic diaphragm and cavity**
- **anteriorly : lower border of thoracic cage, pleura, separated from them by diaphragm, muscle and fascia.**
- **Posteriorly : lumber vertebrae, muscles ((quadrates lumborum, psoas, origin of transversus abdominis)), 12th ribs, and upper part of boney pelvis**

Structure of the abdominal wall

Skin, peritoneum, muscles, fascia, their vessels and nerves, and lower margin of thoracic cage

Skin:- attaché to underlying fascia except at umbilicus (scar tissue)

Line of cleavage (lines of collagen fibers in the dermis) around the trunk.

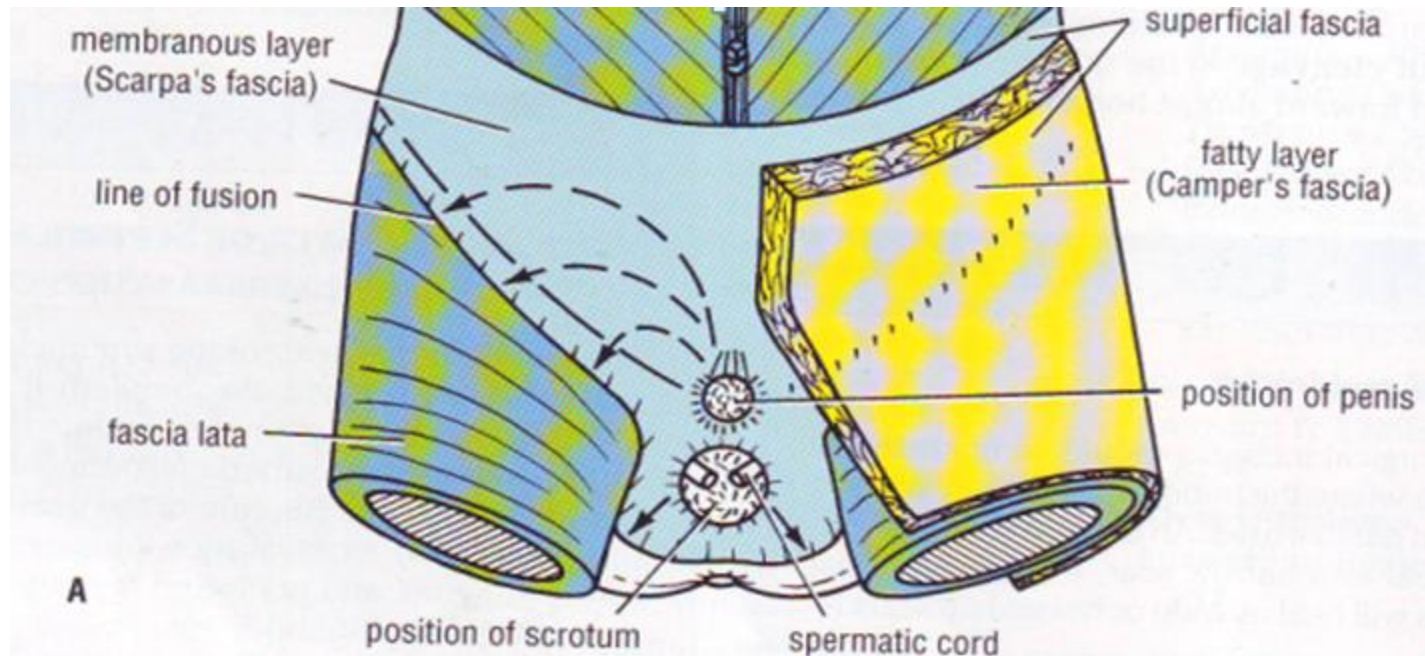
Skin incision must be made parallel to line of cleavage , give rapid and healing with less scar.

Superficial Fascia

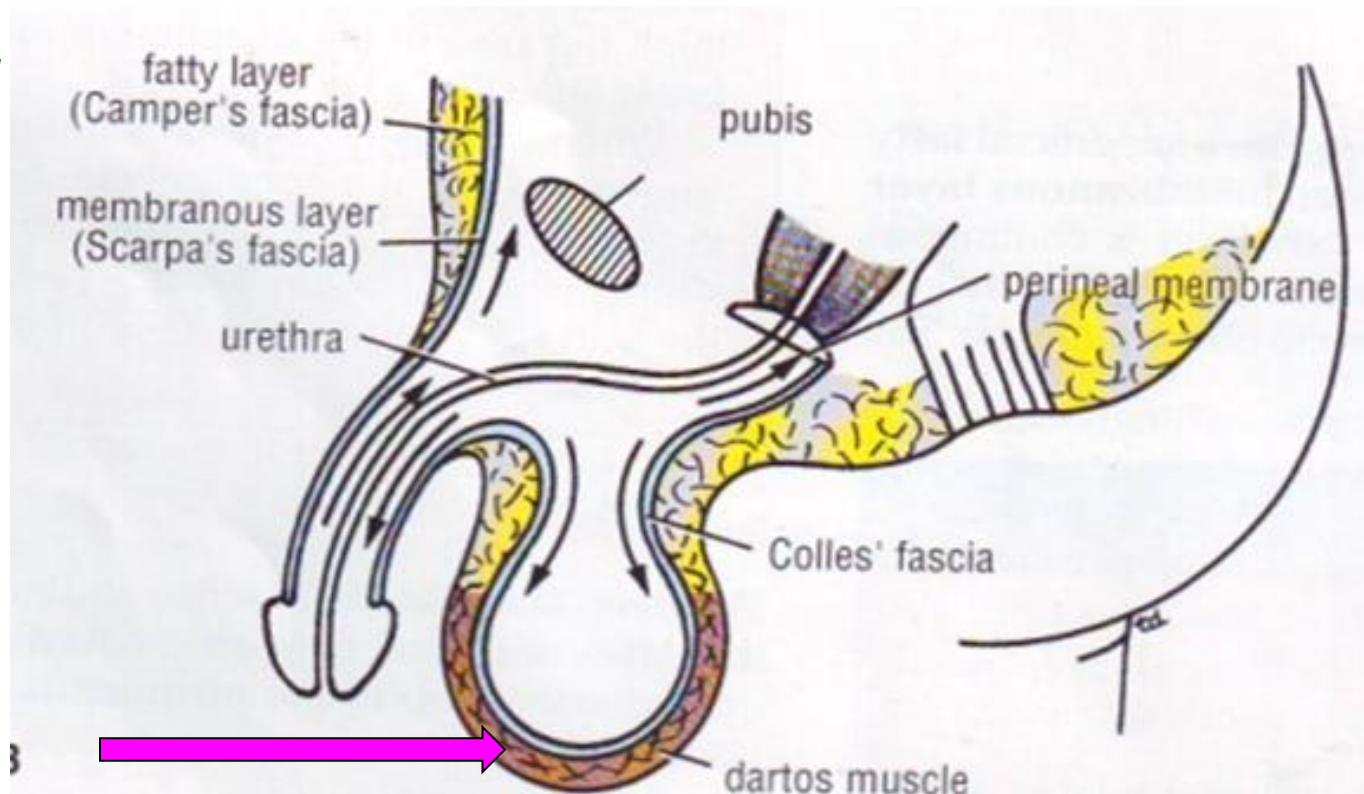
- **single layer that contains a variable amount of fat.**
- **differentiates into a superficial and a deep layer, between which are superficial vessels, nerves and the superficial inguinal lymph nodes.**

The extra peritoneal connective tissue is a stratum of areolar connective tissue lying between the peritoneum and the general fascial lining of the abdominal and pelvic cavities.

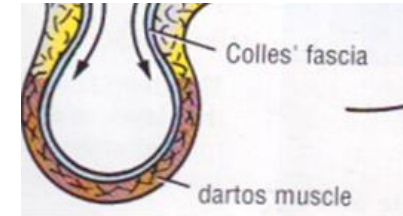- *superficial layer (of Campers) is thick, areolar in texture and contains a variable amount of fat in its meshes. Inferiorly it passes over the inguinal ligament to merge with the superficial fascia of the thighs.*



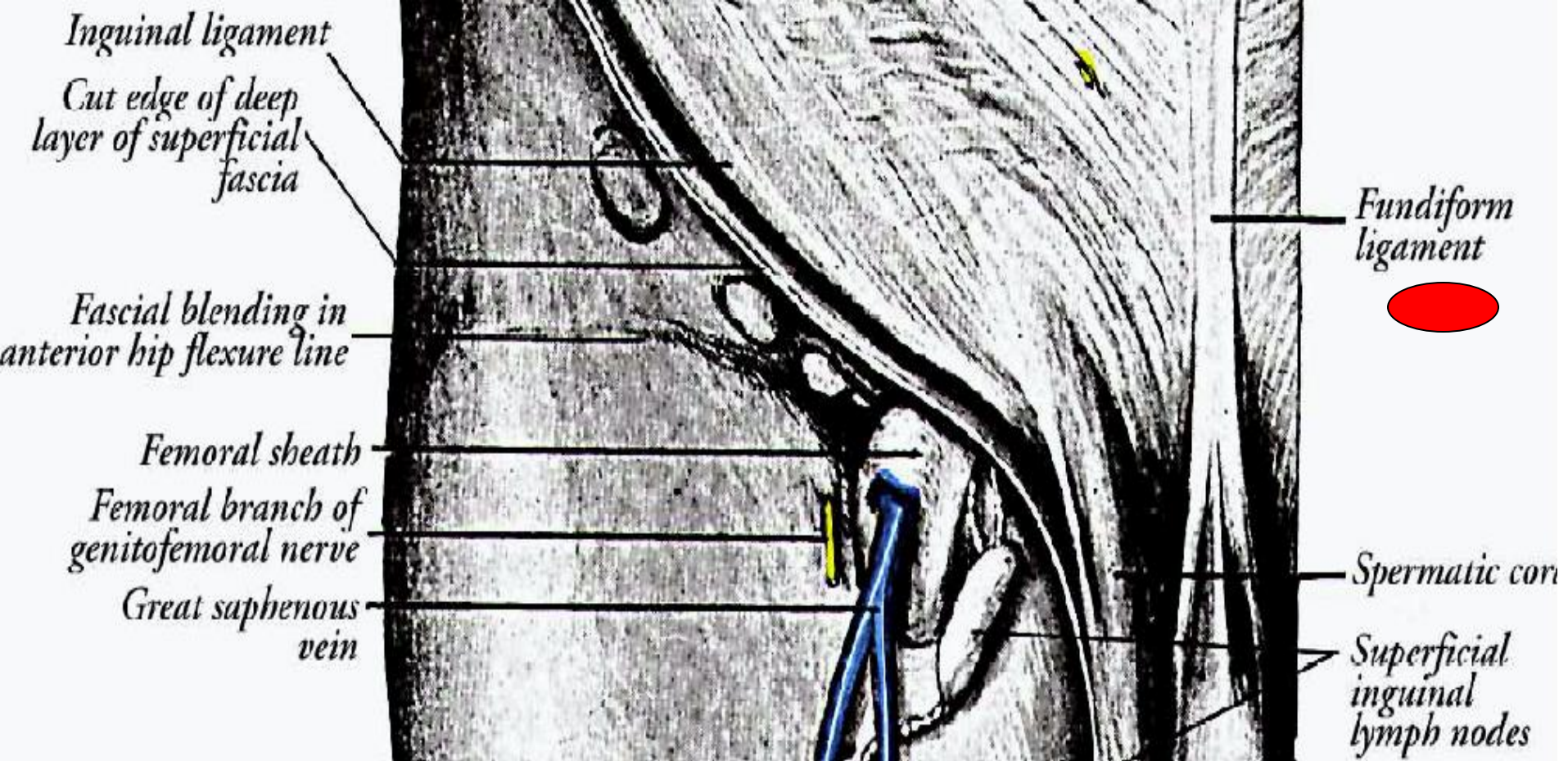- In the male this layer continues over the penis and outer surface of the spermatic cord, into the scrotum, where it changes its character, becoming thin, devoid of adipose tissue and pale reddish in color.***



- In the scrotum it also contains smooth muscle fibres, which form the **dartos muscle**.



- In the female it continues from the abdomen into the labia majora and perineum.
- *The deep layer:*
more membranous than the superficial, and contains elastic fibres. It is loosely connected by areolar tissue to the aponeurosis of external oblique and continues **one finger breadth below inguinal ligament** where fused with deep fascia of the thigh.



- ***In the male it is prolonged on the dorsum of the penis, contributing to its fundiform ligament***

- **Below not attaché to pubic crest but turn around and form tubular sheath to penis and around scrotum (Colles fascia) to attach to perineal body forming potential sac and space in continuous with the superficial perineal pouch.**

- *Rupture of urethra lead to extravasations of urine around penis and scrotum deep to Colles fascia but not to the thigh because this fascia attach firmly to the fascia lata of thigh.*

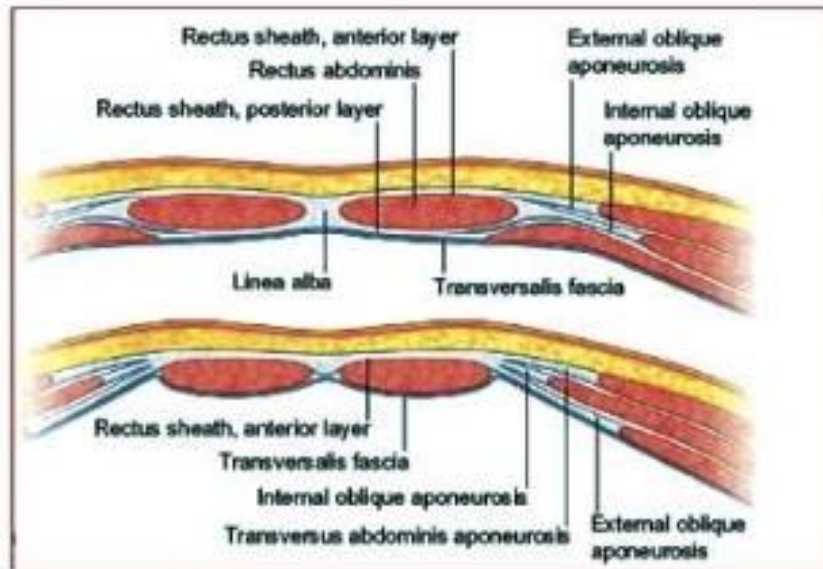
- **Deep fascia of the anterior abdominal wall:-** thin layer of connective tissue covering the muscle , occur deep to the membranous layer of the superficial fascia.
- **Transversalis fascia :** is a thin stratum of connective tissue lying between the internal surface of transversus and the extra peritoneal fat. **Continues in abdomen as renal, psoas, diaphragmatic, and pelvic fascias according to the site.**

Muscles of the anterior abdominal wall

- Three broad thin sheath:- **external, internal, transversus**, and wide vertical muscle the **rectus abdominis** which enclosed by the (rectus sheath) extension of the aponeurosis of the three sheath anteriorly. The lower border of the sheath contain the **pyramidalis muscle (often absent)**, in front of RA arises from anterior surface of pubic bone and ascend upward inserted to linea alba.
- **The cremasteric muscle : division**

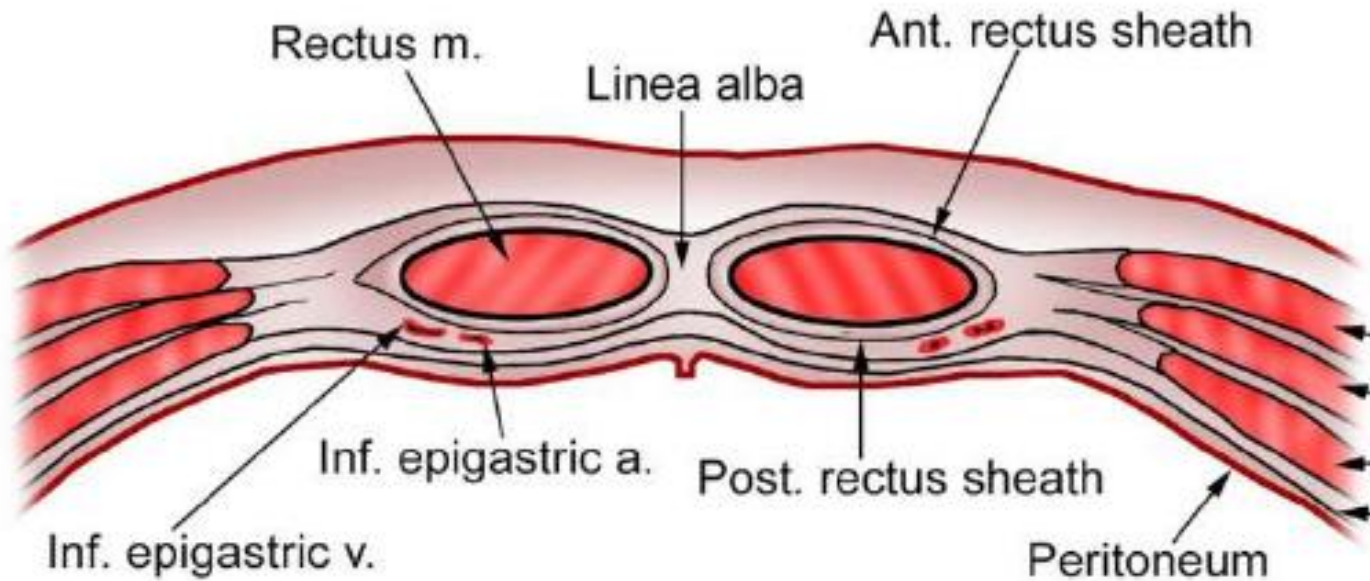
Rectus sheath

Rectus sheath covers RM anteriorly and posteriorly
 Posterior sheath ends inferiorly between Umb and pubis
 Ant. & Post. layers of sheath by division of Int Obl muscle above semicircular line
 Ext Obl aponeurosis joins anterior rectus sheath
 TA aponeurosis joins posterior sheath above the SC line
 Below the SC line, muscle is covered with transversalis fascia

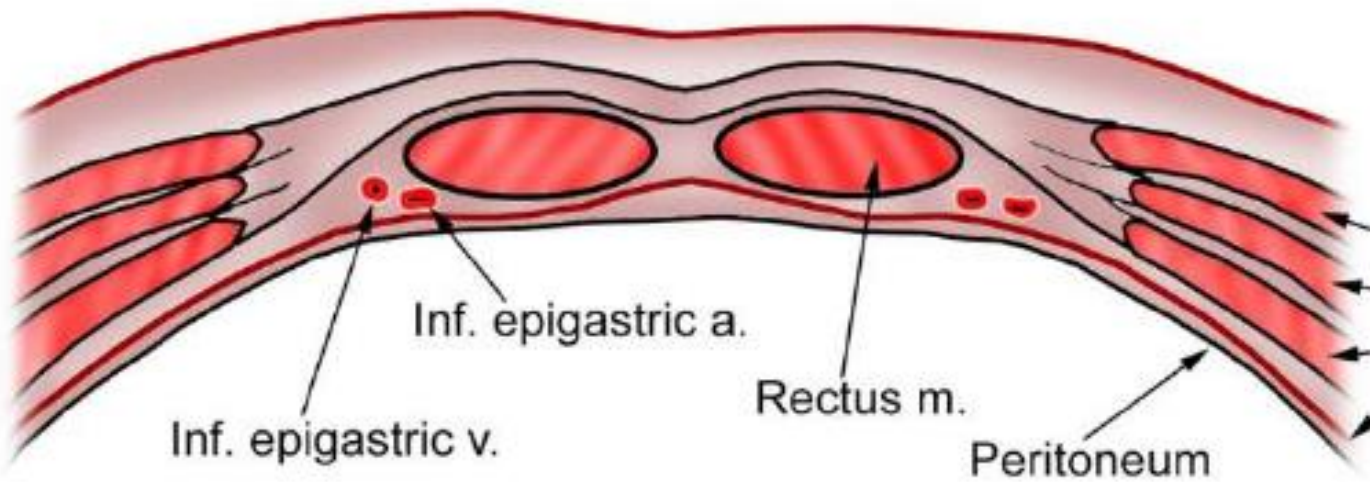


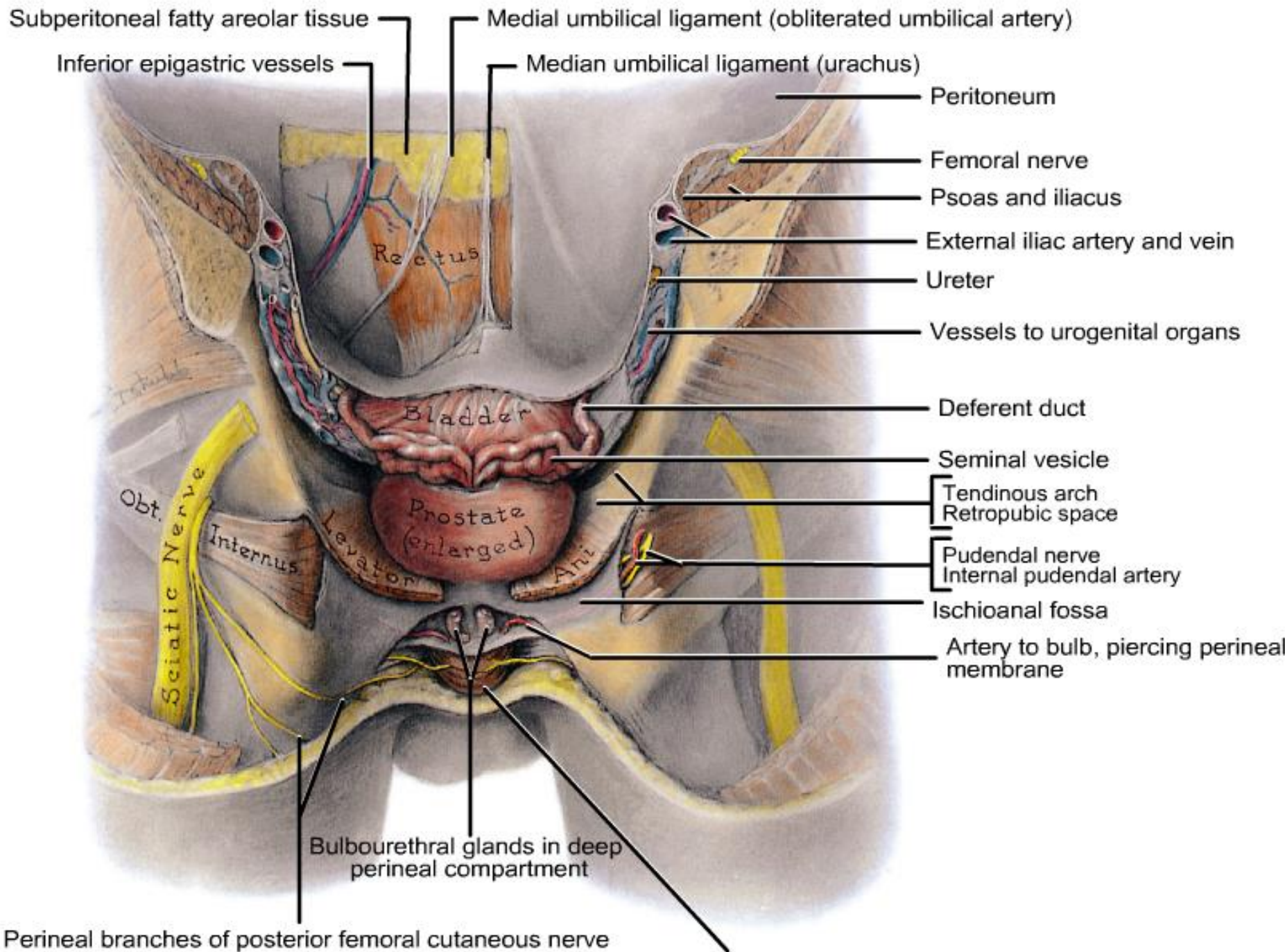
<https://www.kenhub.com/en/library/anatomy/rectus-sheath>

Above Arcuate Line

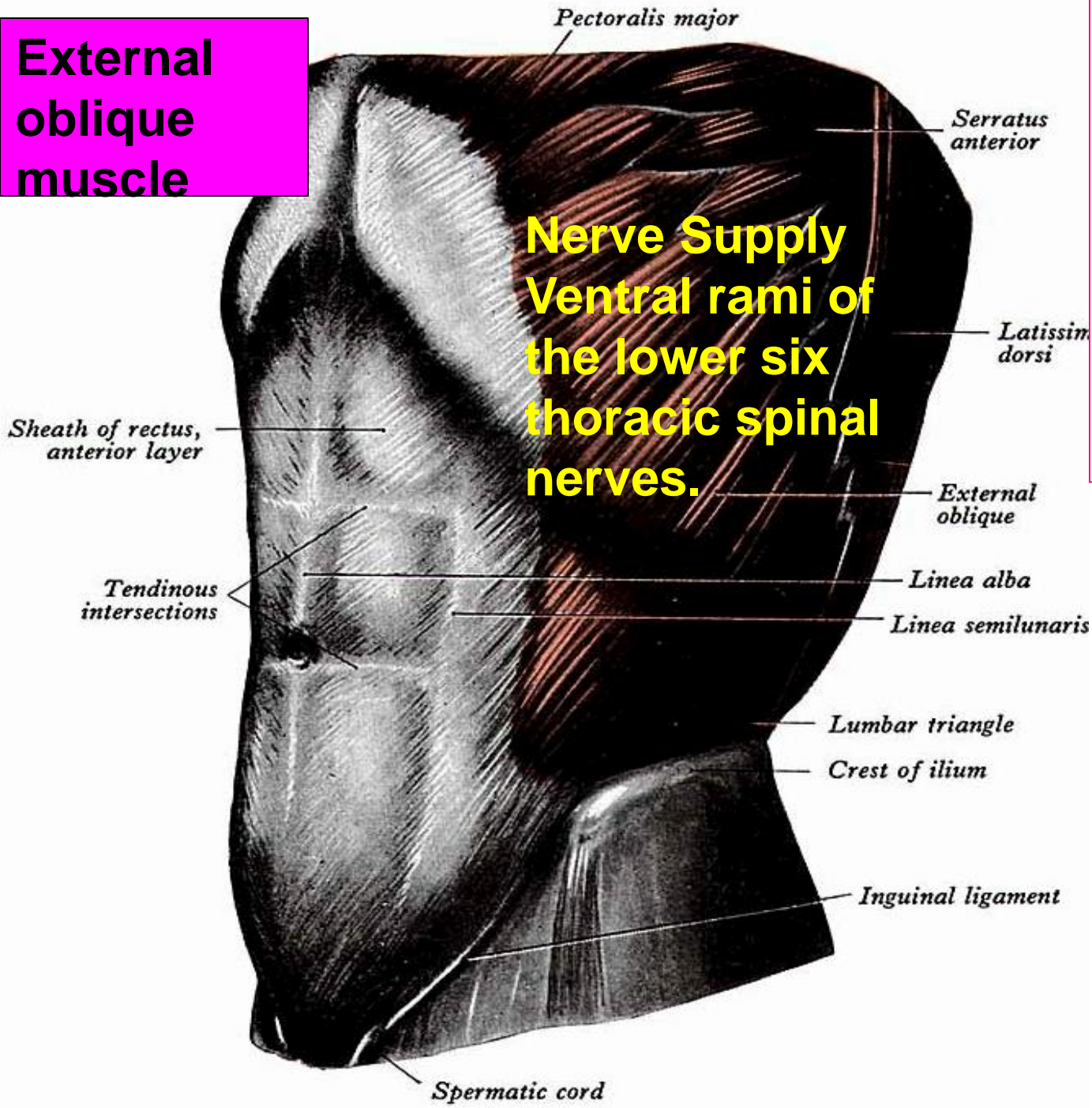


Below Arcuate Line





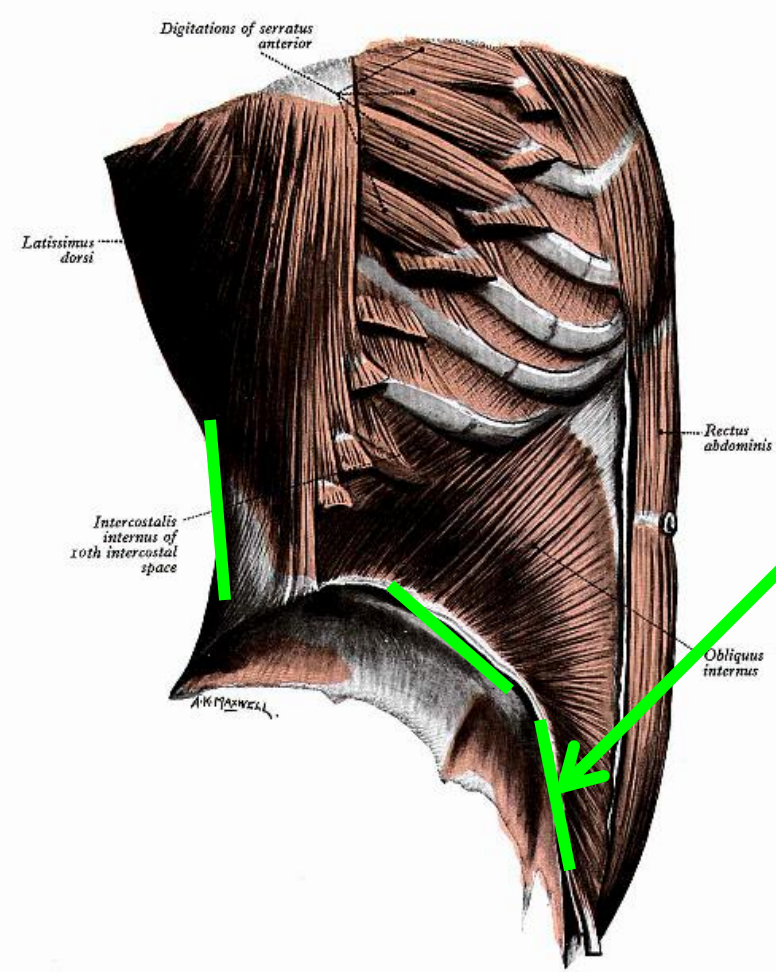
External oblique muscle



It arises by eight fleshy slips from the external surfaces of the lower eight ribs

middle and upper fibers inserted to xiphoid, linea alba and anterior superior iliac spine.

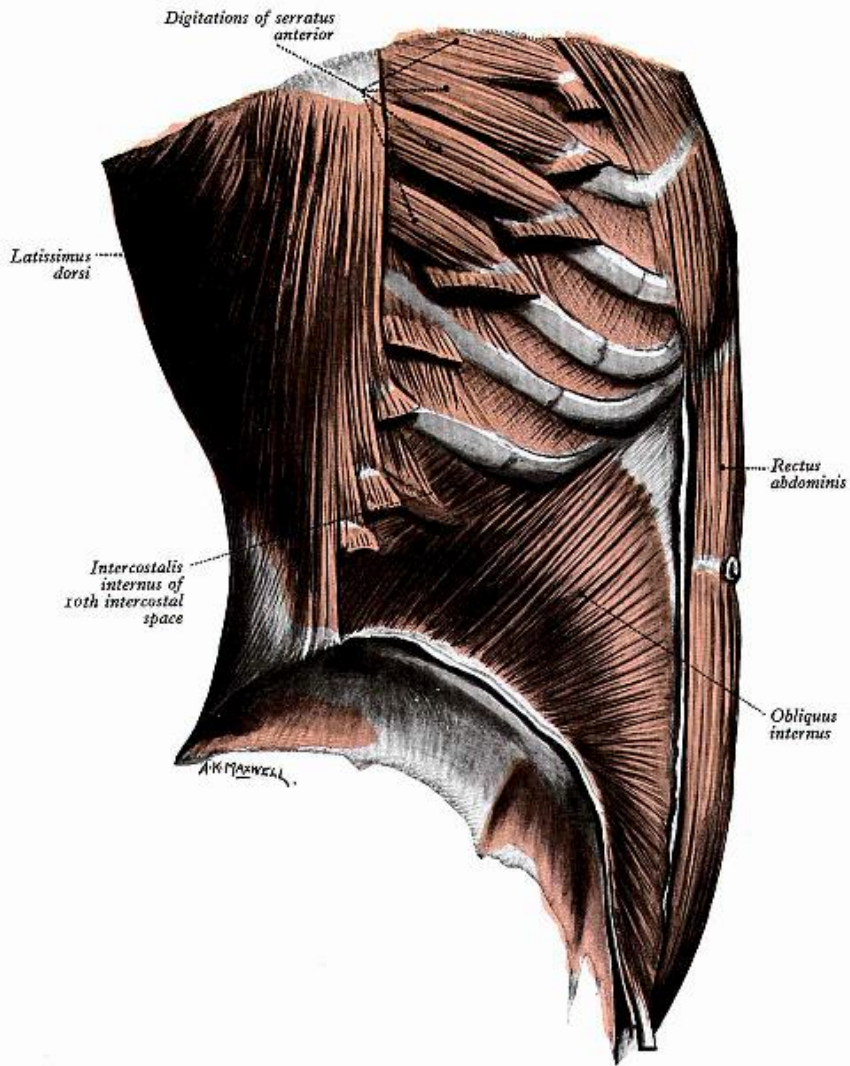
+ From Lower two RIBS :to the anterior half the iliac crest



Internal oblique

arise from lateral two-thirds of the inguinal ligament, anterior two-thirds of the iliac crest and thoracolumbar fascia

The uppermost part is inserted to the lower borders of cartilages of the 7th , 8th and 9th ribs.



intermediate fibres •
diverge and end in an
aponeurosis which
gradually broadens from
below upwards. In its
upper two-thirds this
aponeurosis splits at the
lateral border of rectus
abdominis into two
Laminae which pass
around it and reunite in
the linea alba, which they
help to form.

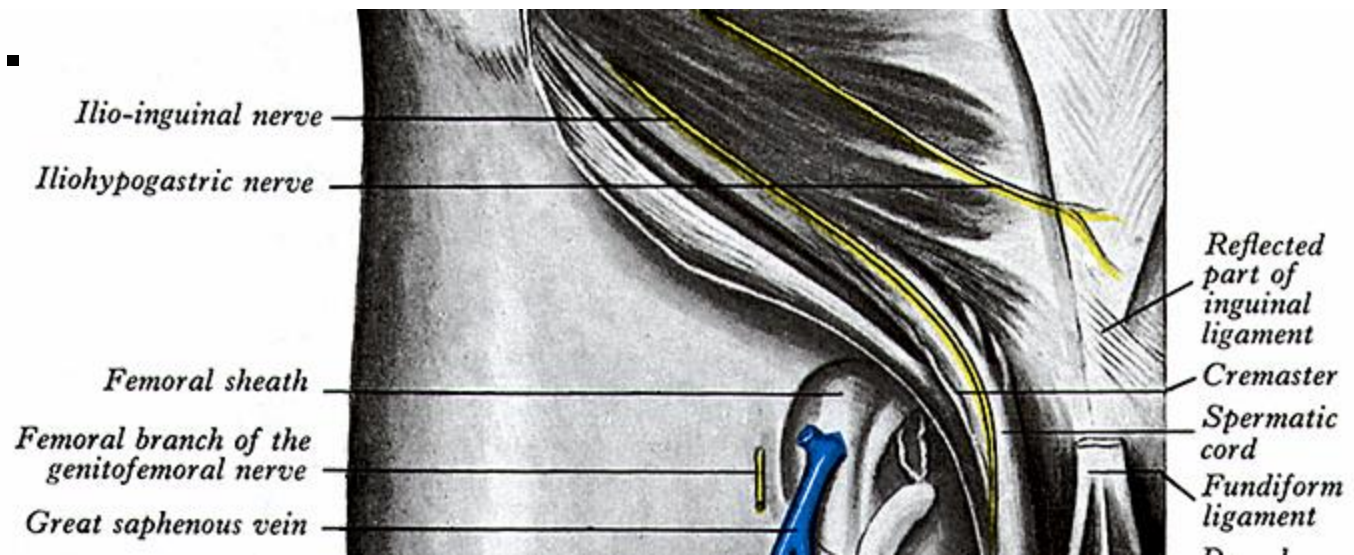
Cremasteric muscle.

Muscle fasciculi lying along the spermatic cord and united by areolar tissue to form the sac-like cremasteric fascia around the cord and testis within the external spermatic fascia. in continuity with either the internal oblique or transversus abd.

Nerve Supply

Genital branch of the **genitofemoral** nerve, derived from the first and second lumbar spinal nerves.

*Cremasteric reflex:
Stroking the skin of the medial side of the thigh evokes a reflex contraction of the muscle . Have A role in testicular thermoregulation.*



Transversus Abdominis

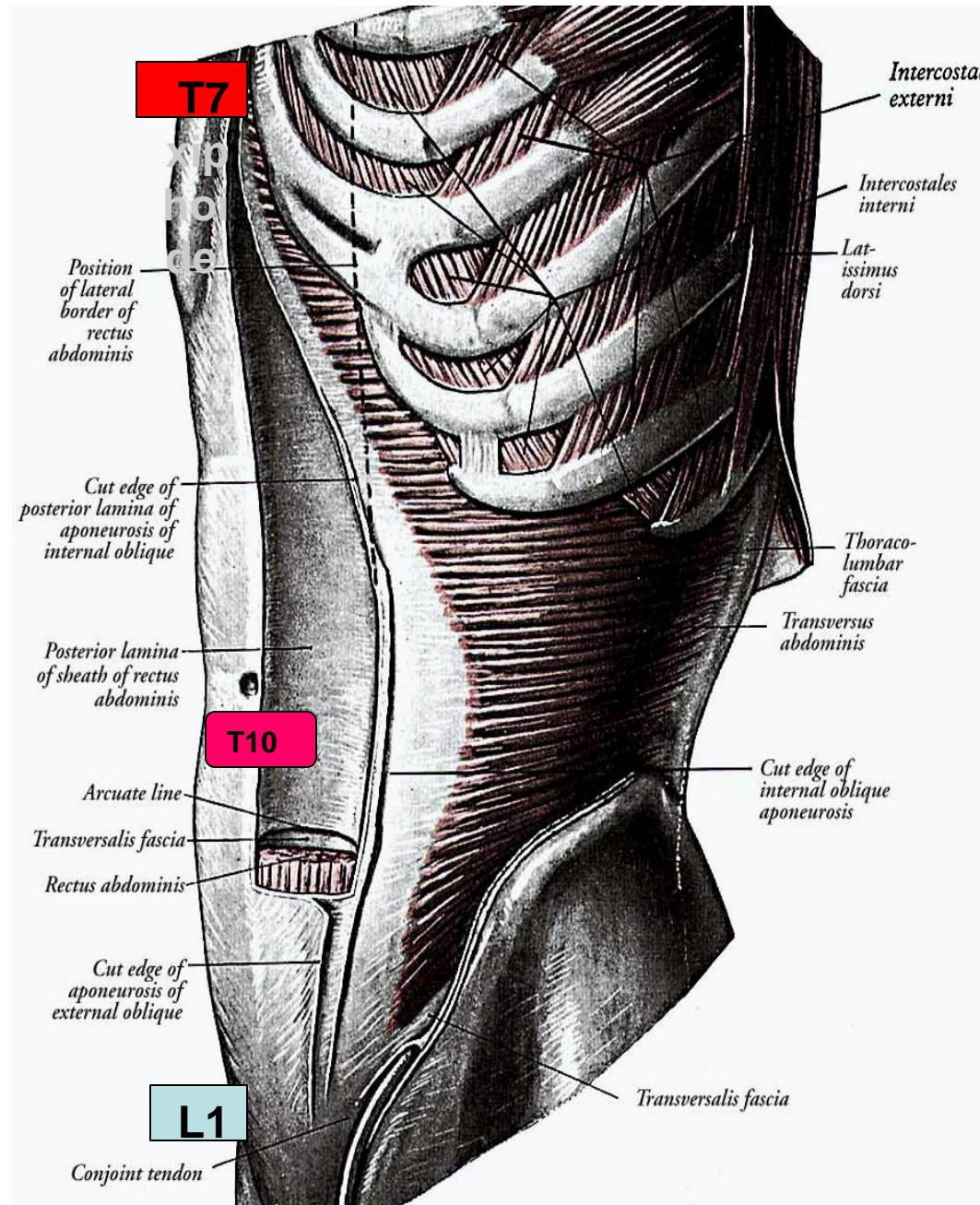
Origin From -

- the lateral third of the inguinal ligament;
- Inner lip of ventral segment of the iliac crest,
- thoracolumbar fascia
- Internal aspects of the lower six costal cartilages.-

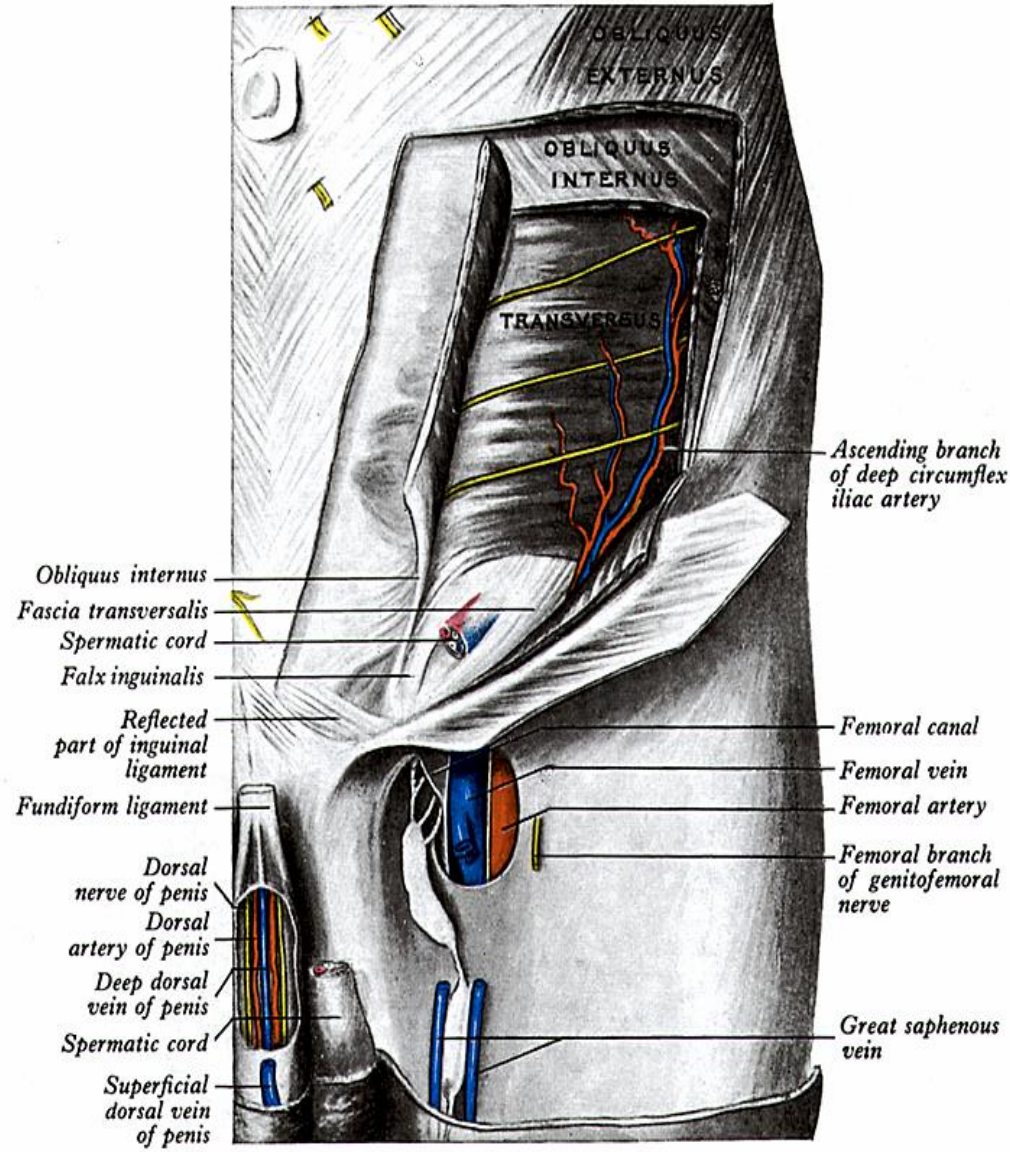
INSERTION; To :
the crest and pecten of the pubis, to form the ***falx inguinalis*** blend with the linea alba medially.

Nerve Supply

Ventral rami of the lower 6th thoracic and L1.



- Falx Inguinalis**
(conjoint tendon) lower part of the aponeurosis of internal oblique & transversus, inserts into the crest and pectin of the pubis.



https://www2.slideshare.net/harshal55/assessment-questions-147898000?next_slideshow=1

Arteries supply the Anterolateral abdominal

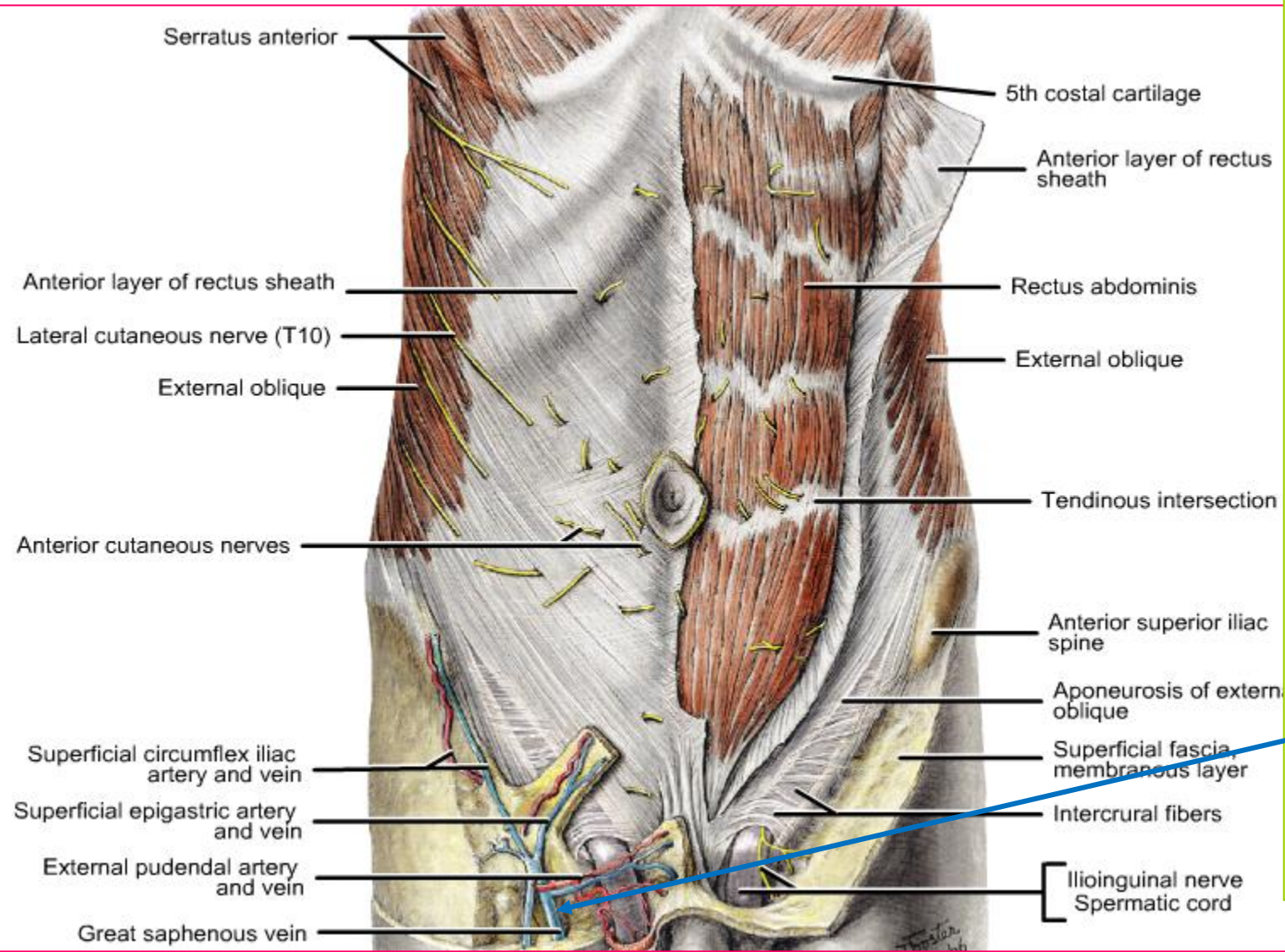
- lower two or three posterior intercostals arteries
- sub costal artery
- musculophrenic artery
- superior epigastric artery
- inferior epigastric artery, **Including its pubic branch and the cremasteric artery**
- superficial epigastric artery ;

- **superficial circumflex iliac artery;**
- **deep circumflex iliac artery, particularly its ascending branch**



- **continuation of four lumbar arteries**
- **rami from lumbar branch of iliolumbar artery (br posterior division of internal iliac ar.). Additional contributions come from anastomoses between many of the above arteries.**

anterior cutaneous nerves (T8 to T12) pierce the rectus abdominis muscle and anterior layer of its sheath; T10 supplies the region of the umbilicus;



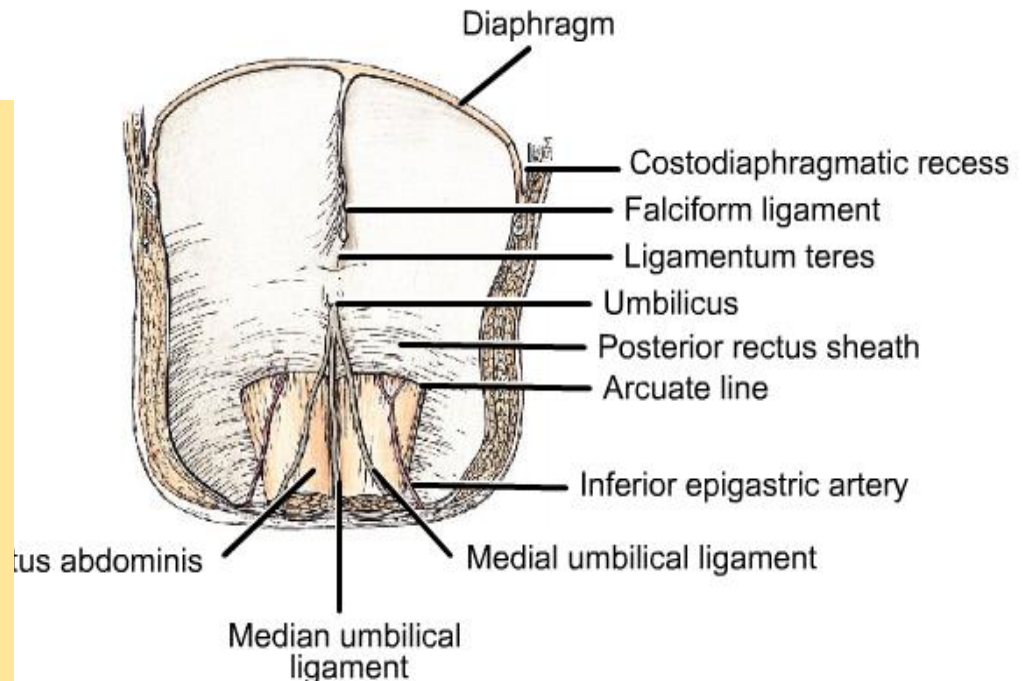
three superficial inguinal branches of the femoral artery (superficial circumflex iliac artery, superficial epigastric artery, and external pudendal artery) and the great (long) saphenous vein;

Posterior aspect of anterior abdominal wall:-

Note the attachment of the falciform ligament and ligamentum teres to the abdominal wall; the ligamentum teres (the obliterated umbilical vein); the median umbilical ligament (the remnant of the urachus); the medial umbilical ligament (the obliterated umbilical artery); and the inferior epigastric artery (lateral umbilical ligament).

ARCUATE LINE

The **arcuate line of the abdomen**, **linea semicircularis** or **Douglas' line** is a horizontal line that demarcates the lower limit of the posterior layer of the rectus sheath. It is also where the inferior epigastric vessels perforate the rectus abdominis.



Clinical notes

- **Muscle rigidity and referred pain:-
confusable:-**
 - **peritoneum inflammation**
 - **voluntary contraction du to cold
examiner hand.**

**Solved by :- flex the hip joint in supine
position, examiner warm his hand**

❑ *Abdomino thoracic rhythm:-*

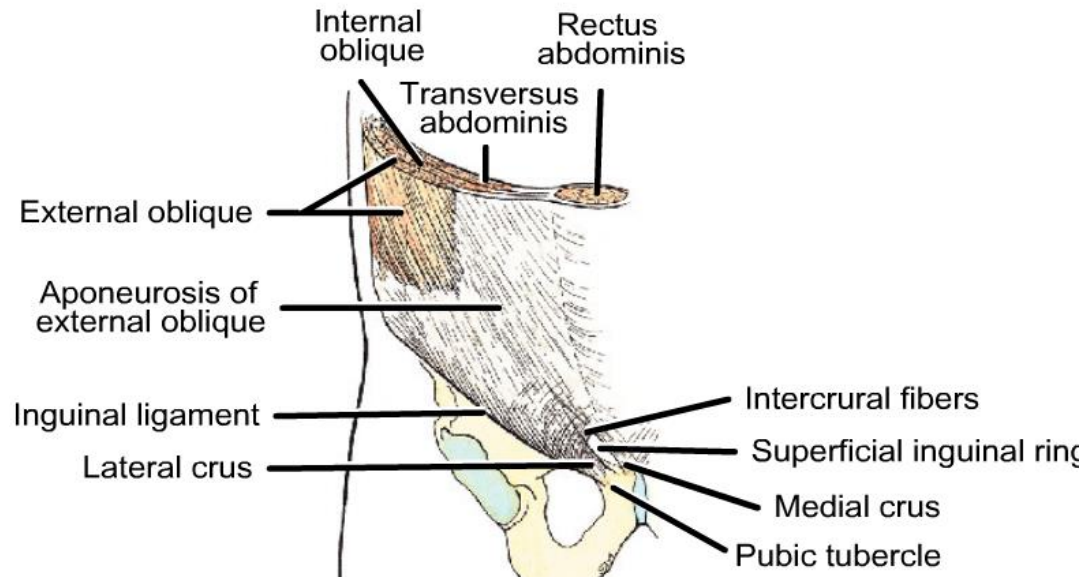
- ❑ extension of the chest without abdomen indicates for peritonitis.**
- ❑ extension of the abdomen without chest indicating for abdominal respiration and pleurisy.**
- ❑ visceroptosis: protrusion of the lower anterior abdominal wall due to weakness of the muscle due to multiple pregnancy.**
- Caput medosa: engorgement of veins around umbilicus due to obstruction of portal vein**



Inguinal Ligament

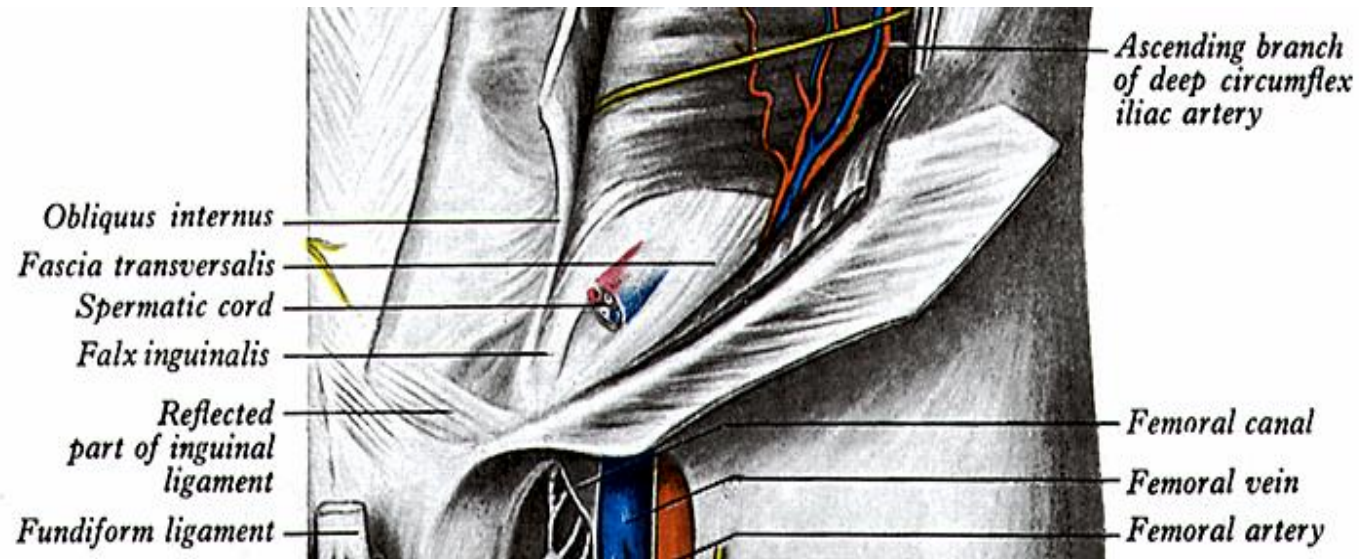
a- thick, inrolled lower border of the aponeurosis of external oblique, and stretches from the anterior superior iliac spine to the pubic tubercle;

b- forms the 'floor' of the inguinal canal. (It has also been called the **crural arch, or Poupart's ligament.**)



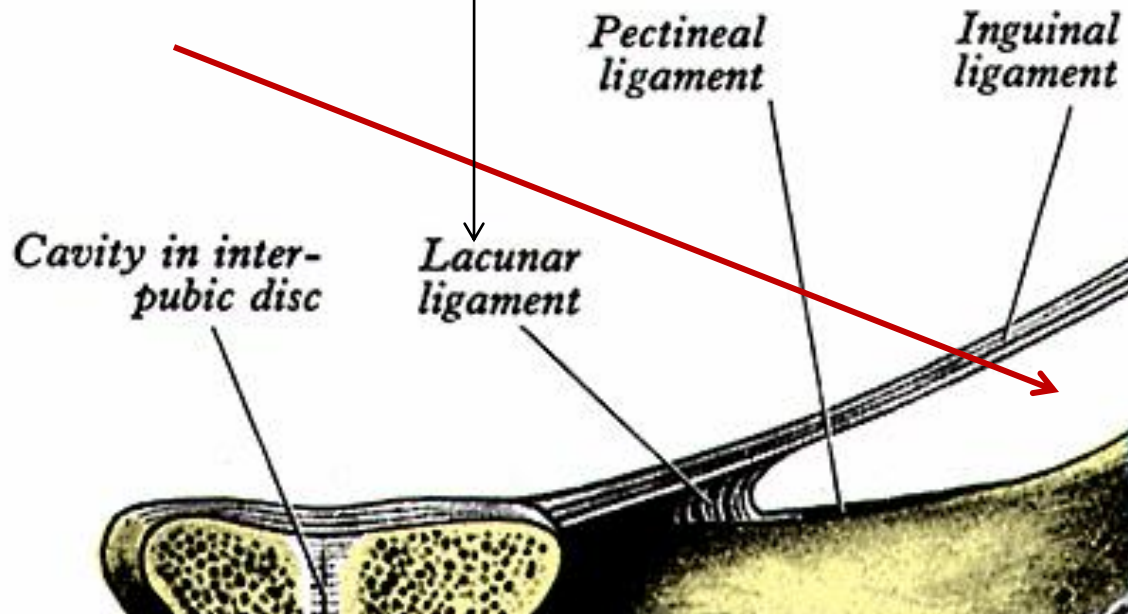
- c- In adults it is 12– 14 cm in length and inclined at 35–40° to the horizontal.
- d- Its lateral half is rounded and more oblique;
- e- Some fibres pass upwards and medially to join the rectus sheath and the linea alba; these constitute the *reflected part of the*

- *inguinal*
- *ligament*



- At the medial end of inguinal ligament , some of it's fibers extend posteriorly and laterally to the pectin pubis is known as the *lacunars ligament complex*.

it” posterior fibers extend laterally and is concave and forms pectineal ligament which form the medial boundary of the *femoral ring*;

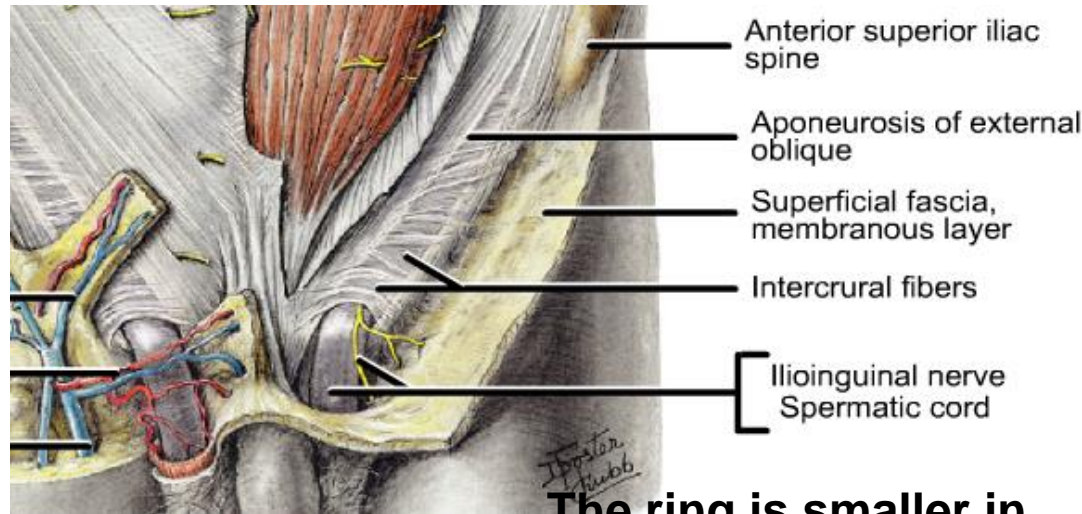
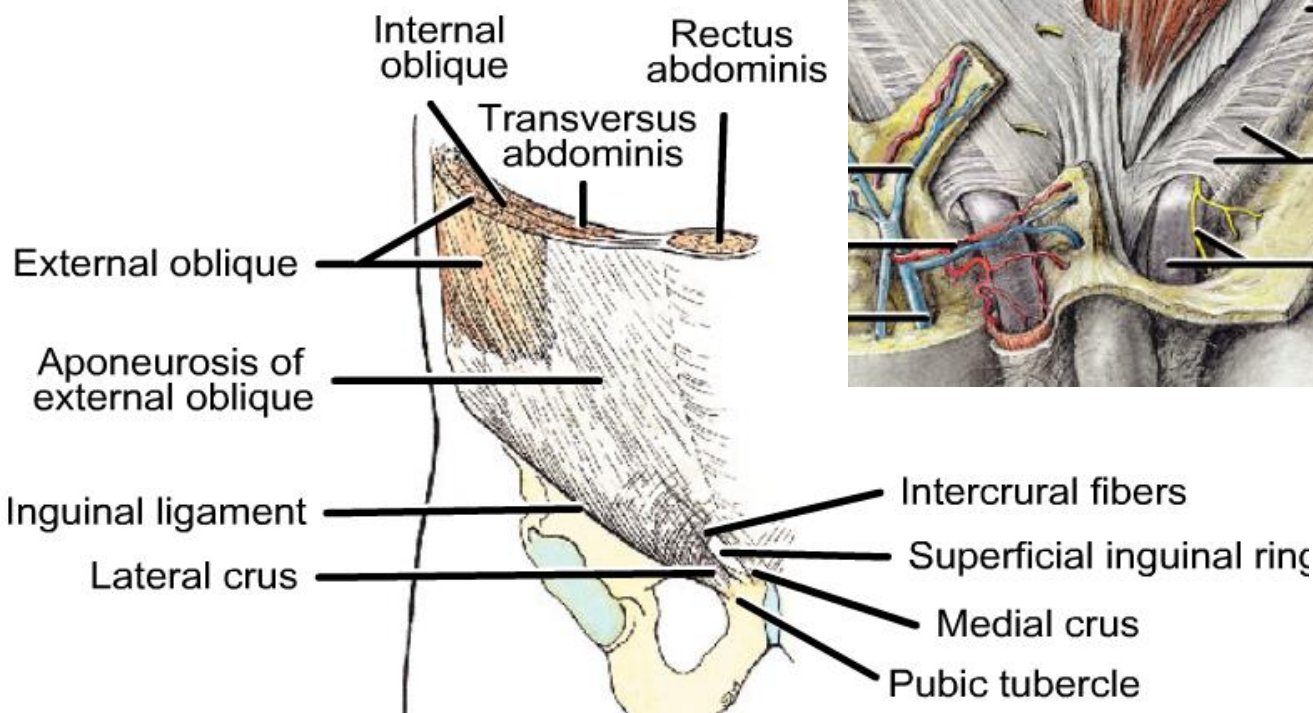


Inguinal canal

- *1.5 inch(4 cm)*
- *Oblique passage in lower abdominal wall for structures passes to and from the testis and round ligament in the ligament of the uterus.*
- *Deep inguinal ring: hole in fascia transversalis*
- *No canal in child (2 rings apposite each other)*

Protrusion of the intestine into the inguinal canal is known as an oblique or indirect inguinal hernia

- Superficial Inguinal Ring:
- - is a hiatus in the aponeurosis, just above and lateral to the tubercle of the pubis. It transmits the spermatic cord in the male, the round ligament of the uterus in the female and the *ilio-inguinal nerve in both*.
- - somewhat triangular



The ring is smaller in the female.

Give attachment to external spermatic fascia, Have two crura

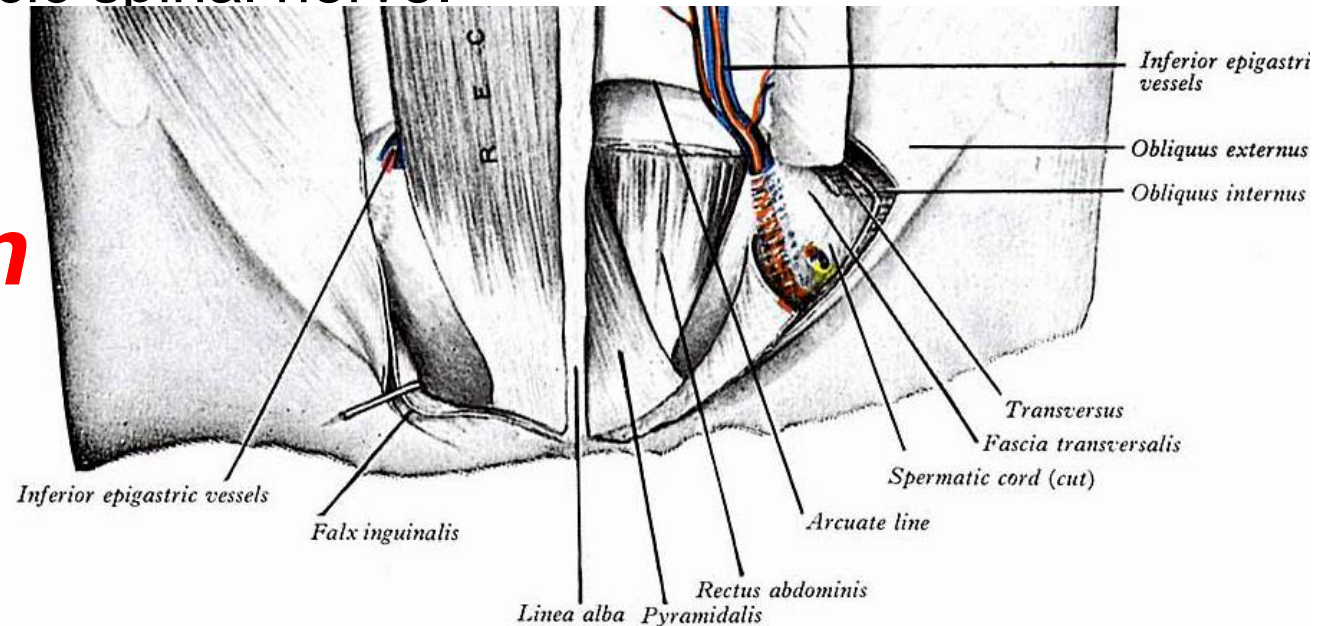
- **Deep inguinal ring :**
- **Oval (0.5) inches (1.3 cm) above inguinal ligament**
- **Give attachment to internal spermatic fascia**
- **midway between the anterior superior iliac spine and the symphysis pubis and about 1.25 cm above the inguinal ligament.**
- **It is related above to the arched lower margin of transversus abdominis, and medially to the inferior epigastric vessels and the interfoveolar ligament, when present.**

- **Walls of the inguinal canal:**

- anterior:- external oblique aponeurosis, + laterally origin of internal oblique
- Posteriorly:- fascia transversalis , medial third conjoined tendon (int.& Tr)
- Inferiorly: inguinal ligament, lacunars ligament,
- Superiorly : arch of lower fibers of inter oblique + transverse m.

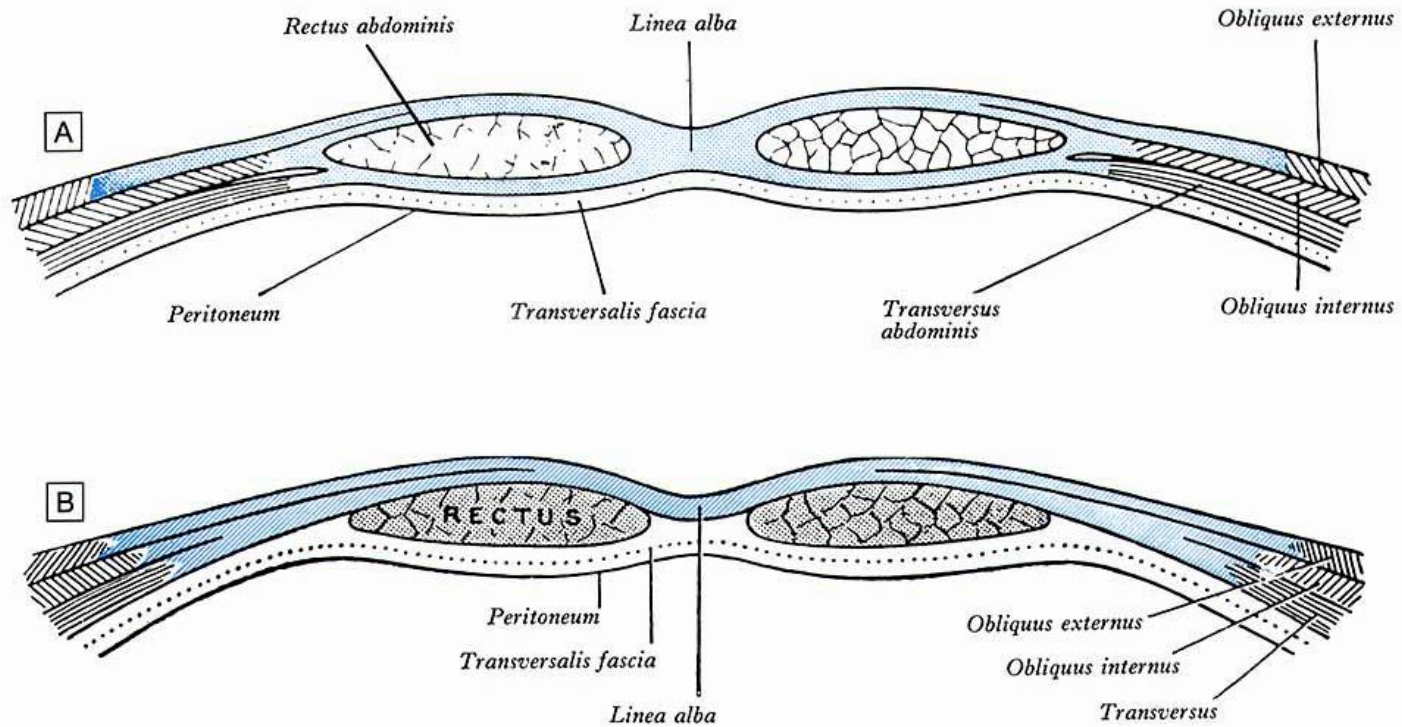
- ***Pyramidalis:***
- ***triangular muscle that lies in front of the lower part of rectus abdominis within the rectus sheath.***
- ***It is attached to the front of the pubis and to the ligamentous fibres in front of the symphysis.***
- Nerve Supply:
- The subcostal nerve, which is the ventral ramus of the twelfth thoracic spinal nerve.

***assist in
respiration***



Actions of the Anterolateral Abdominal Muscles

- ***Flex and rotate the trunk***
- ***Rectus abdominis: flex and stabilize trunk***
- ***Pyramidalis : assist in respiration,***
- ***accommodate viscera, in coughing and sneezing by pull ribs down ward.***
- ***Protect abdominal viscera***
- ***Help in micturition, defecation, vomiting, and parturition,***

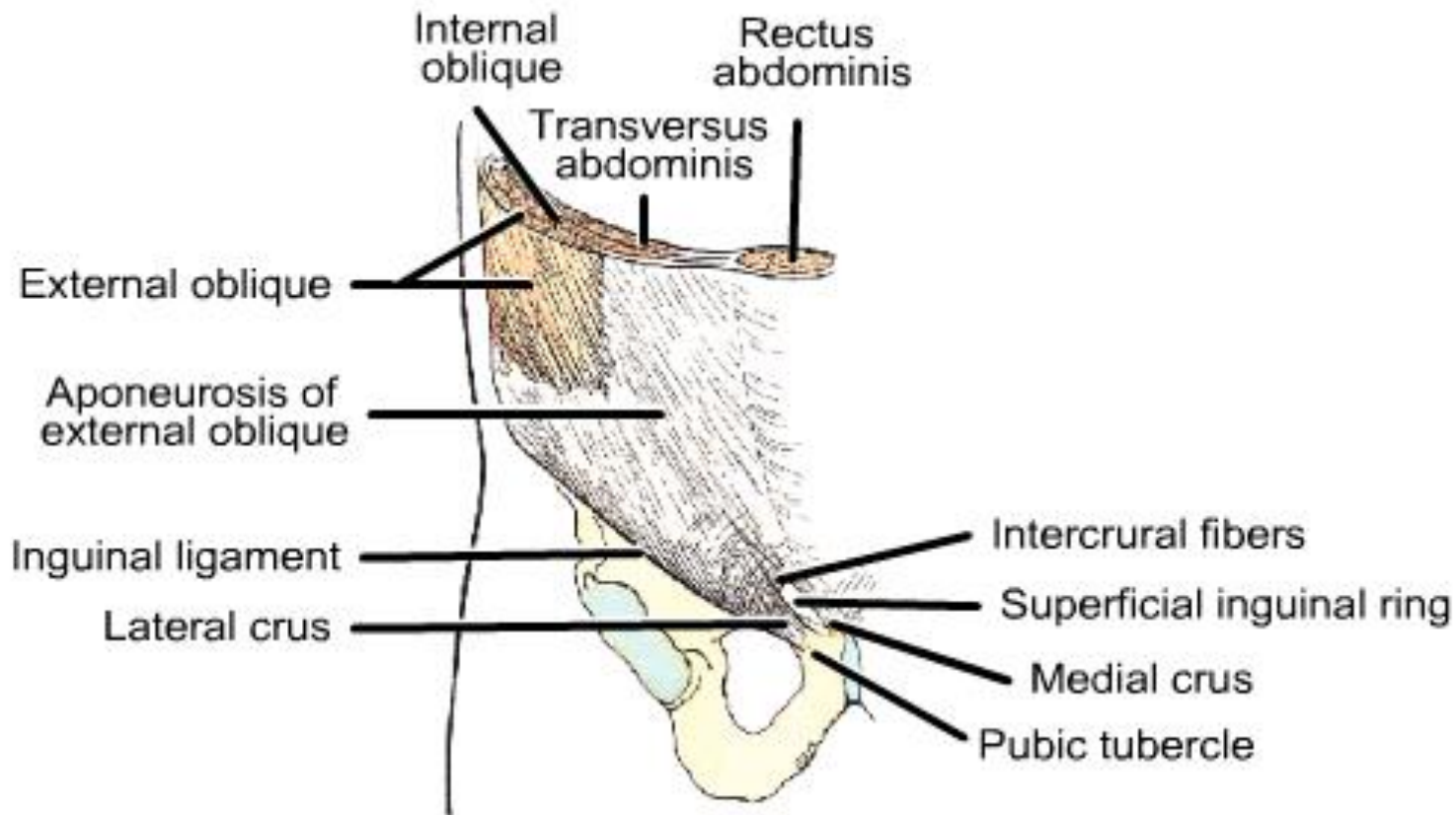


At the lateral margin of the rectus, the aponeurosis of the internal oblique divides into two lamellae:

one of which passes in front of the rectus, blending with the aponeurosis of the external oblique as well as the aponeurosis of the anterior half of the internal oblique.

the other, behind it, blending with the aponeurosis of the transversus as well as the posterior half of the internal oblique, and these, joining again at the medial border of the rectus, are inserted into the linea alba

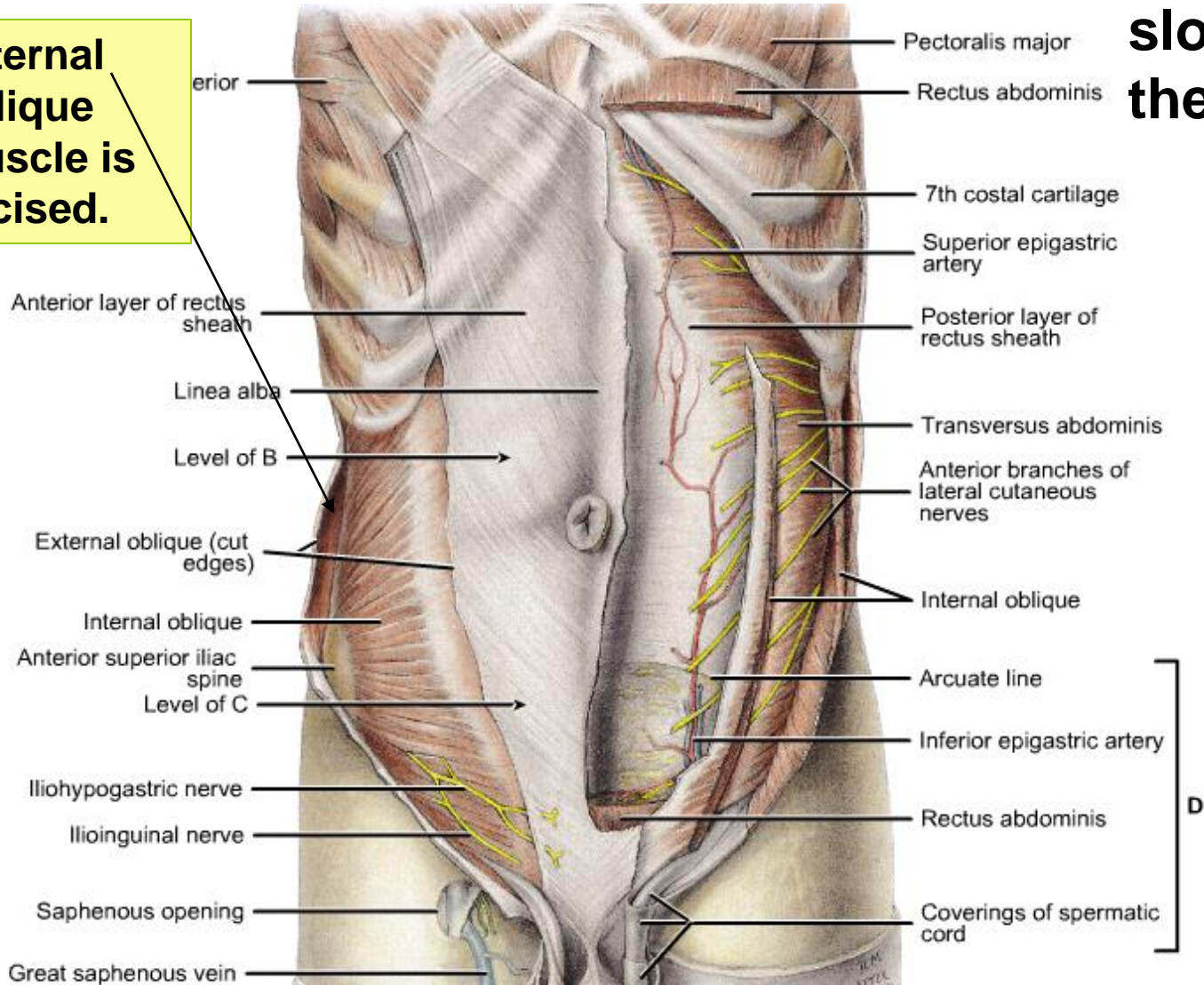
superficial inguinal ring. The superficial inguinal ring is an oblique, triangular opening, 2 to 3 cm long; its central point is superior to the pubic tubercle.



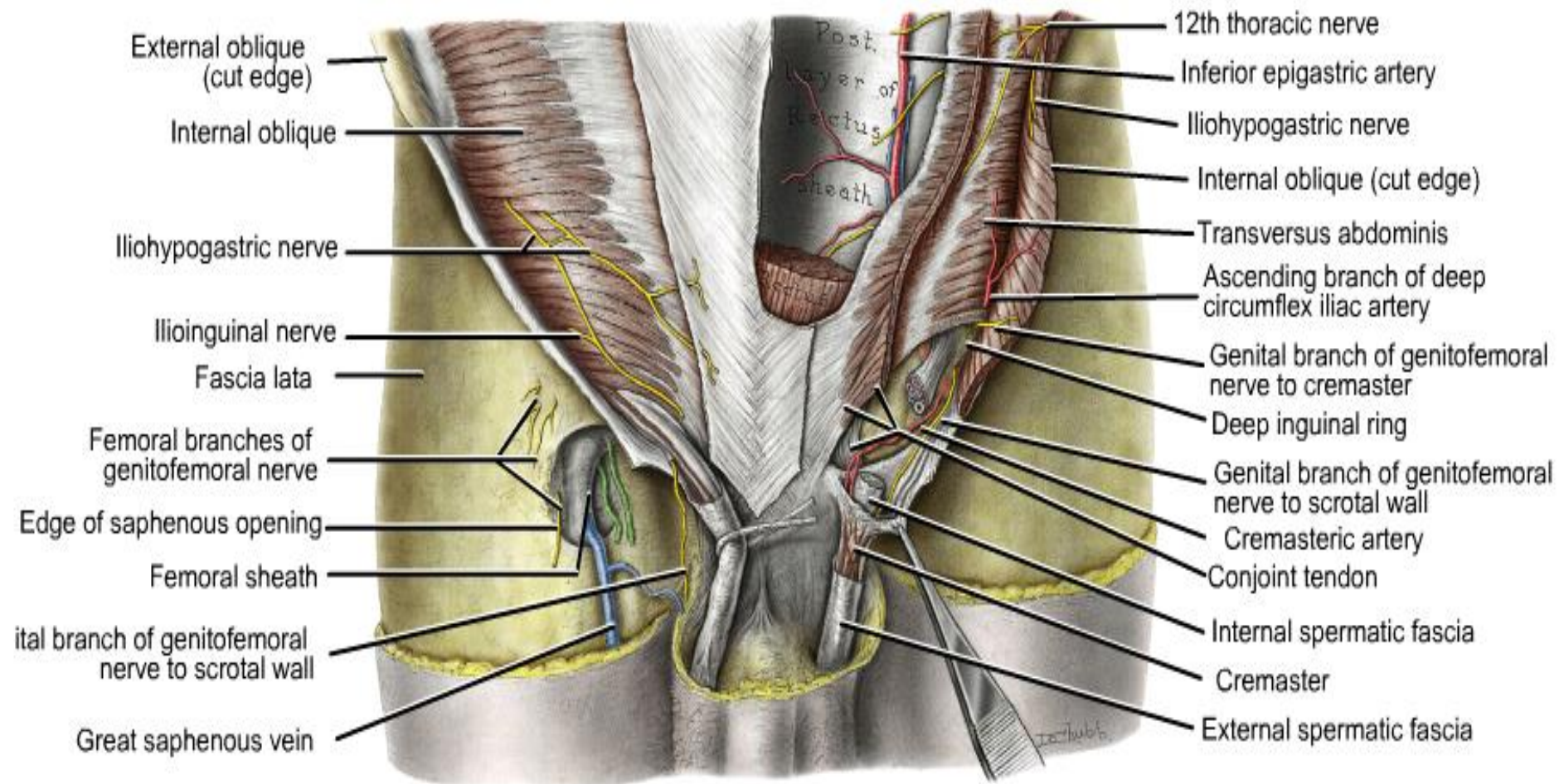
superior and inferior epigastric arteries indirectly unites the arteries of the upper limb to those of the lower limb (subclavian to external iliac).

The anastomosis can become functionally patent because of slow occlusion of the aorta

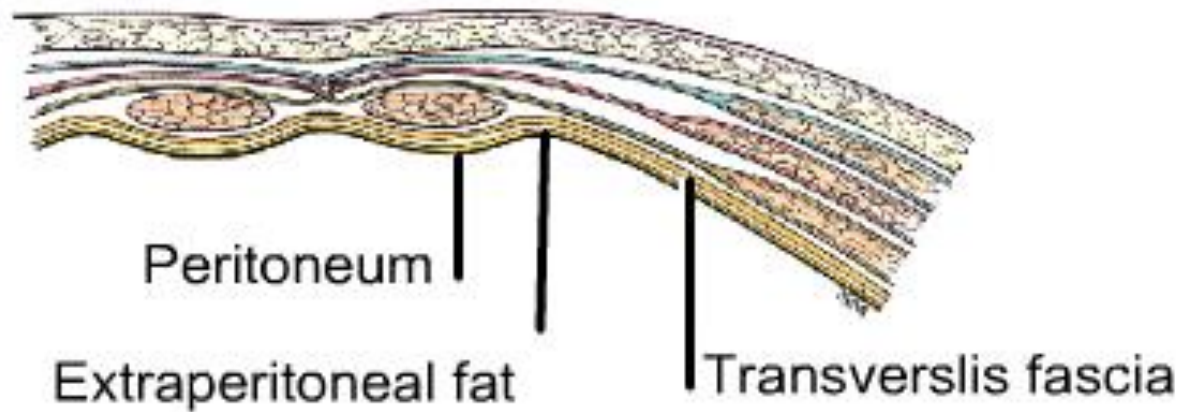
external oblique muscle is excised.



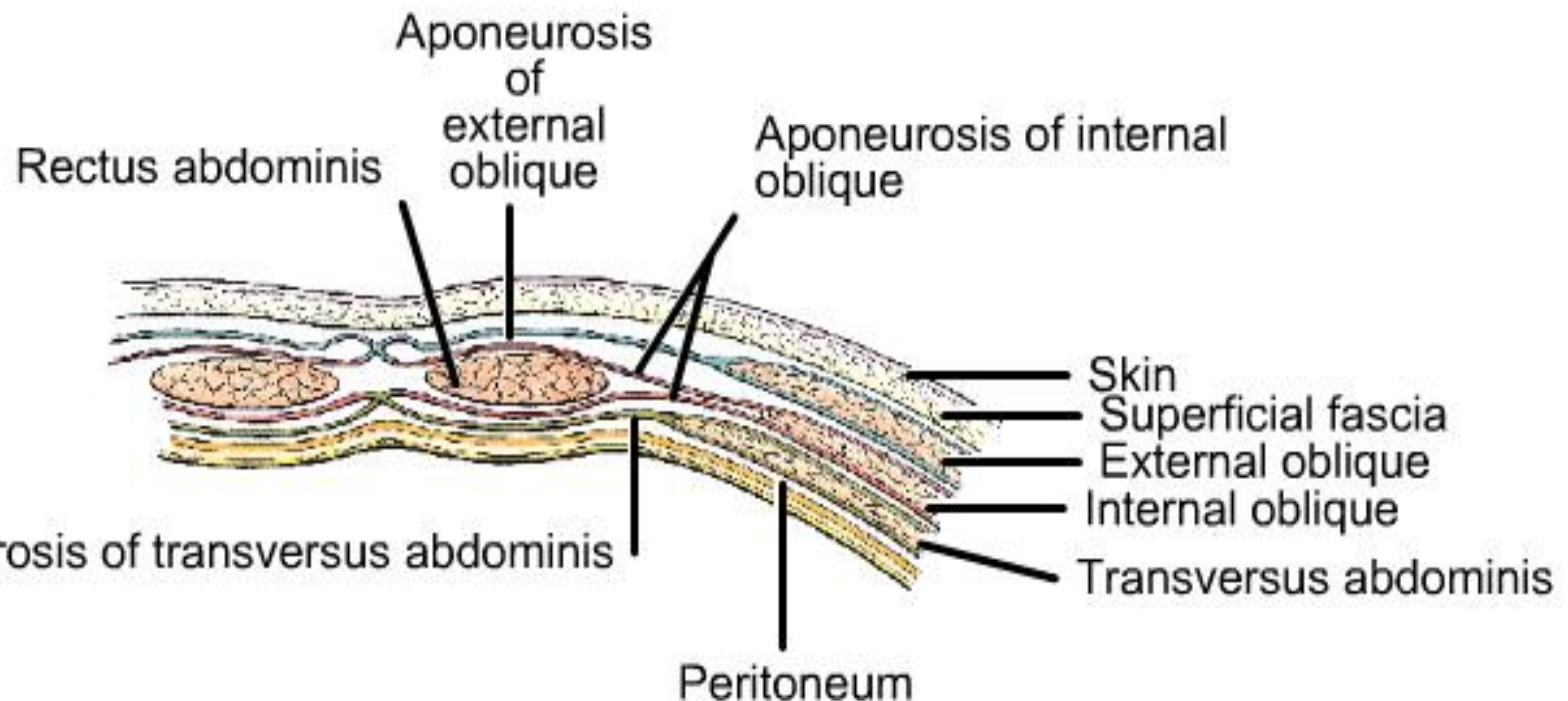
Coverings of the cord: (a) internal spermatic fascia, derived from fascia transversalis; (b) cremaster muscle and fascia, from internal oblique and transversus abdominis; (c) external spermatic fascia, from external oblique aponeurosis.



Approximately midway between the umbilicus and the symphysis pubis, all of the aponeuroses pass anterior to the rectus abdominis muscle; the posterior rectus sheath gradually ends at the arcuate line where the transversalis fascia comes into contact with the posterior aspect of the rectus abdominis muscle.

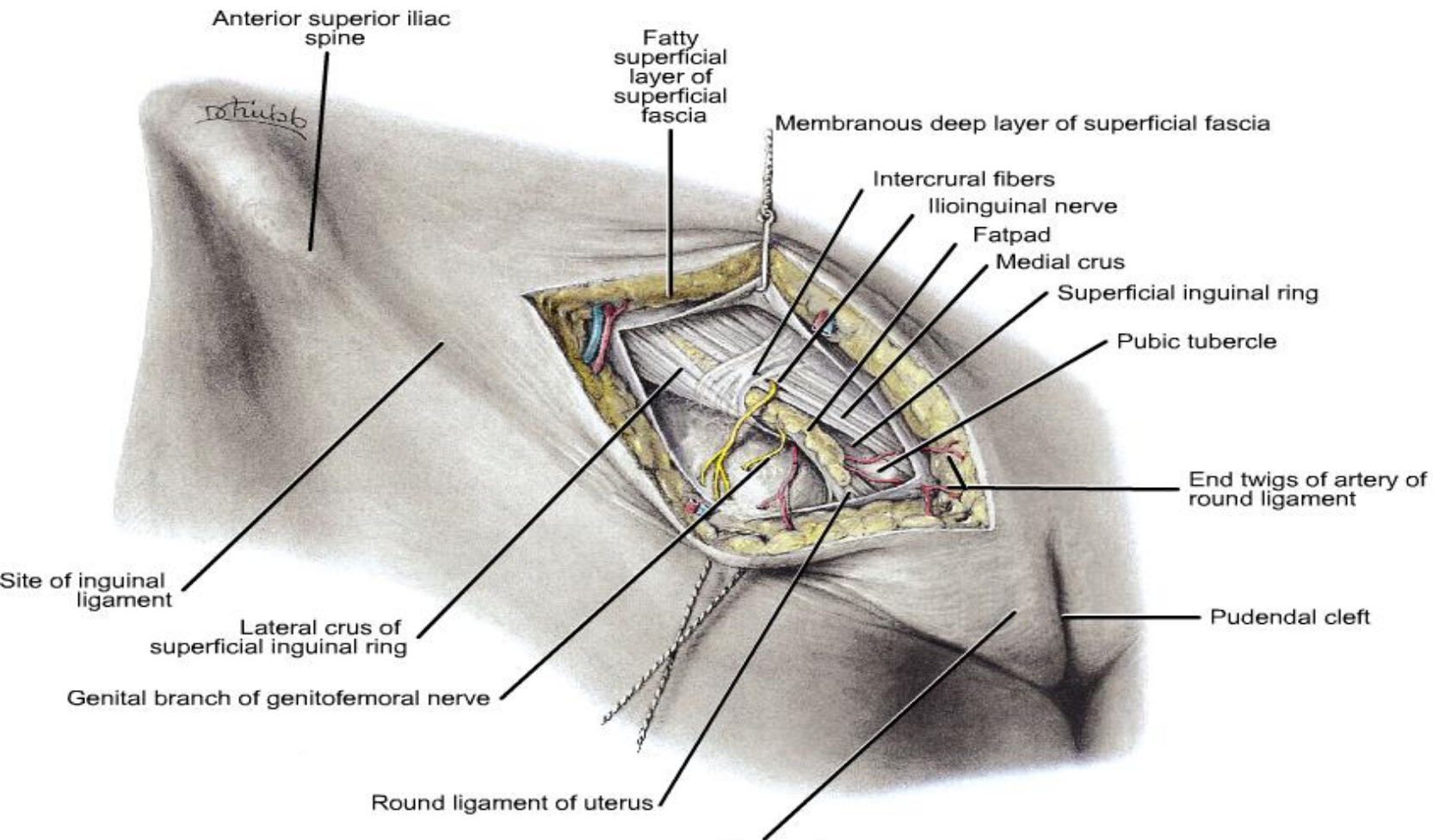


Superior to the umbilicus, both anterior and posterior rectus sheaths are trilaminar. Anteriorly, there are the two layers of the aponeurosis of the external oblique muscle and the superficial layer of the aponeurosis of the internal oblique muscle. Posteriorly, there is the deep layer of the aponeurosis of the internal oblique muscle and two layers of the aponeurosis of the transversus abdominis muscle.

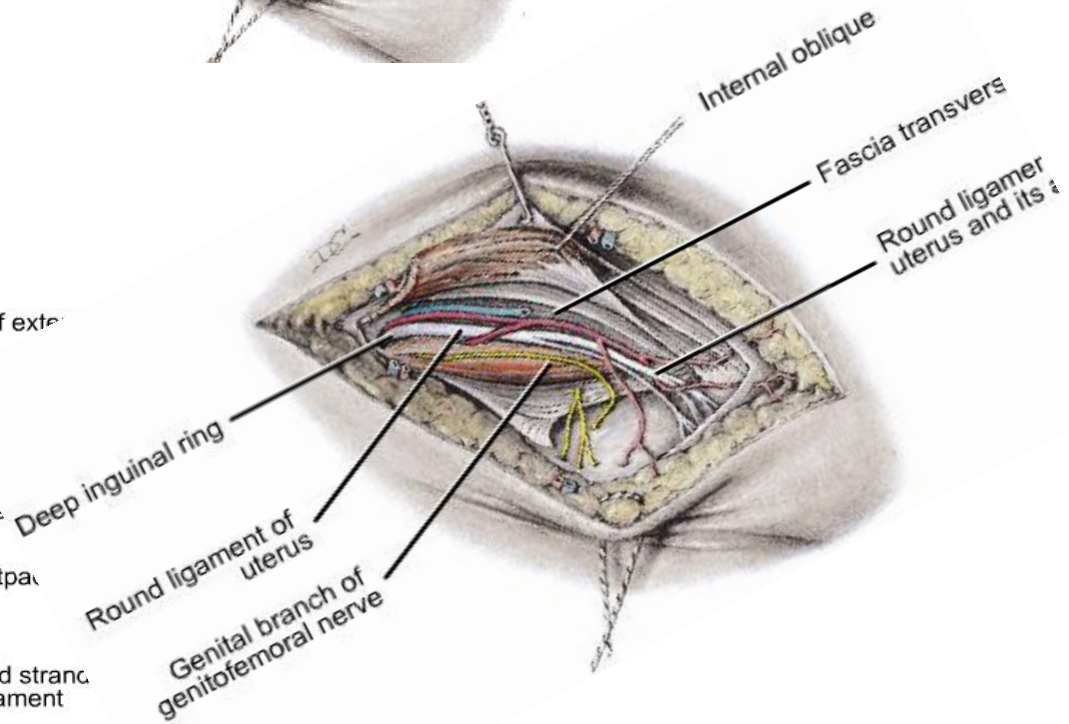
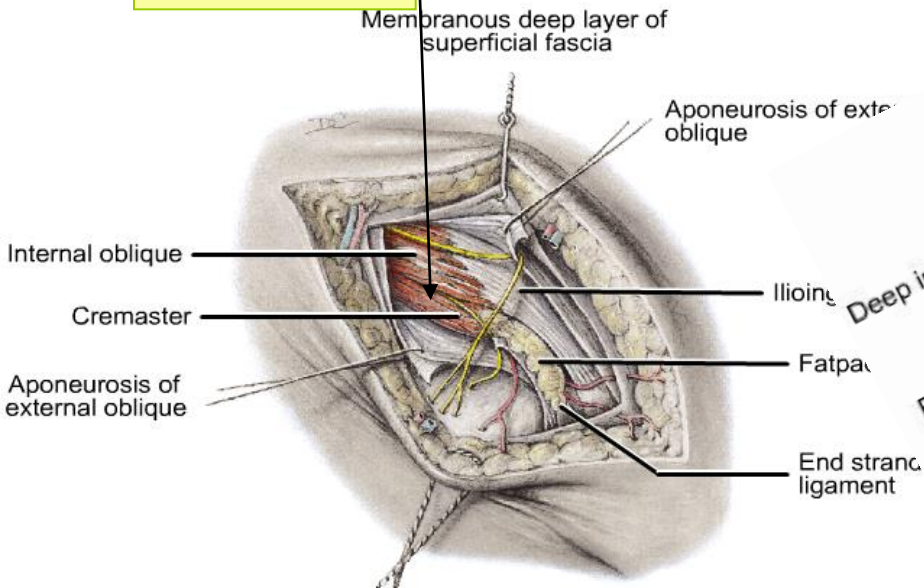
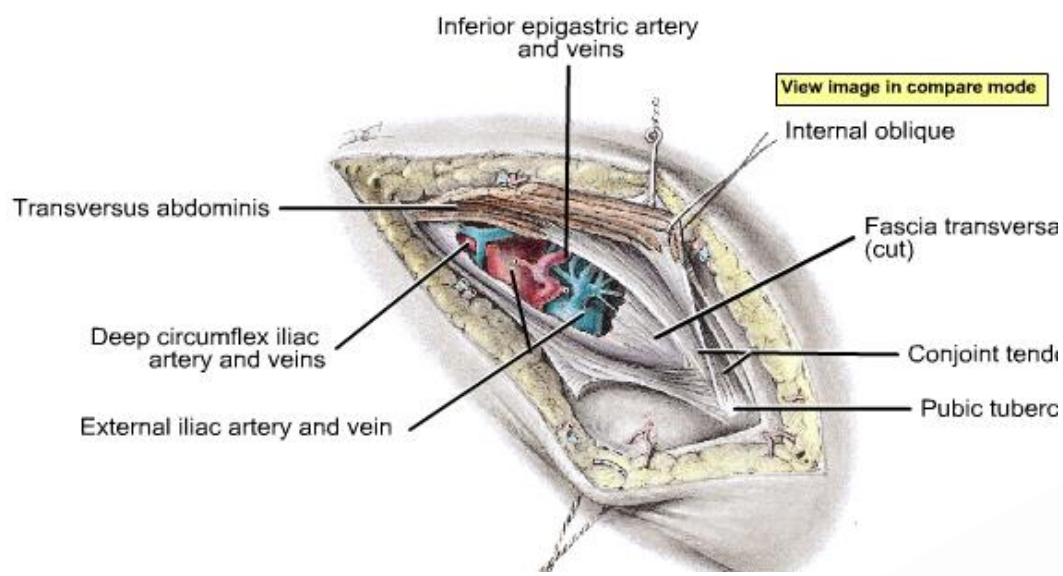




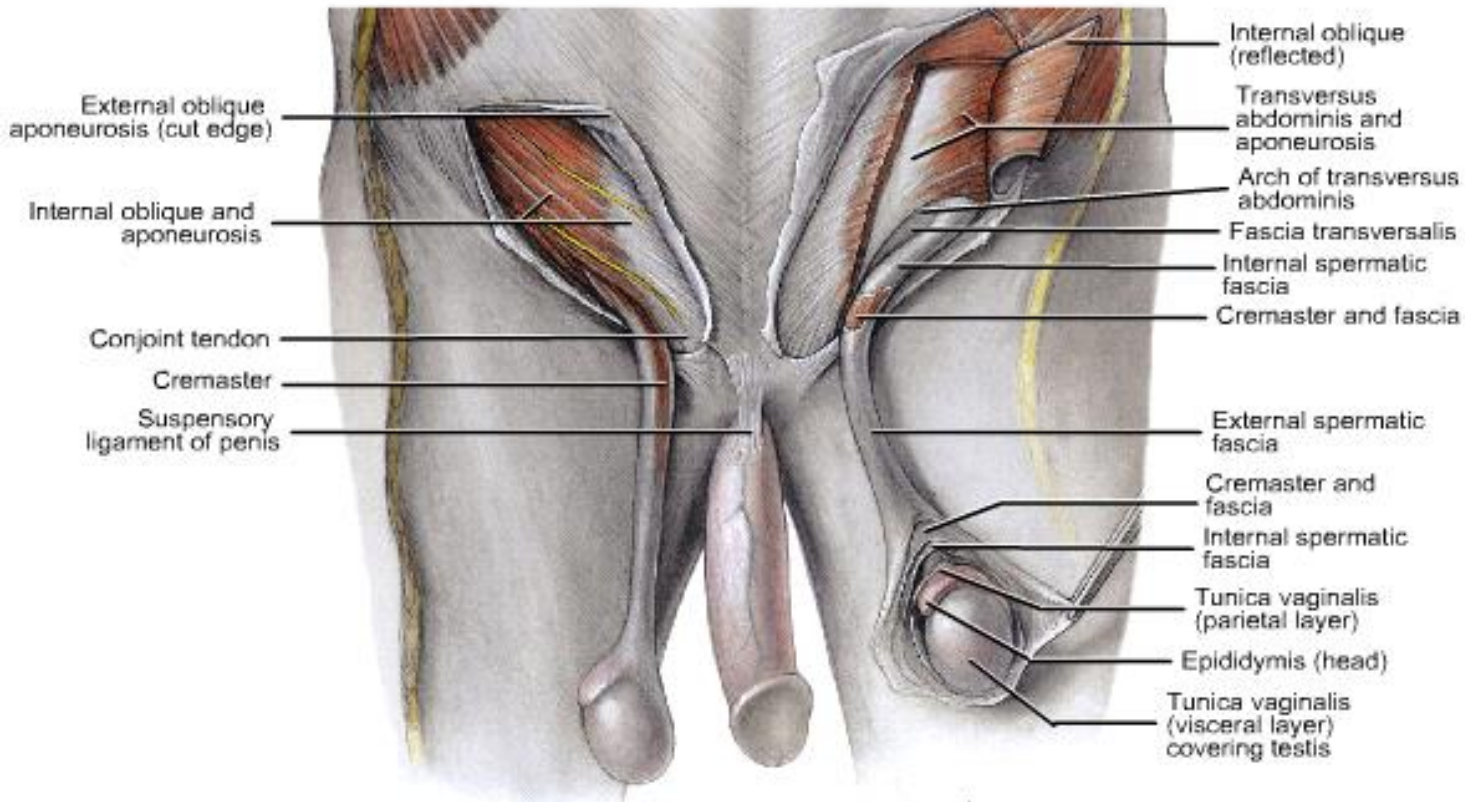
Passing through the **superficial inguinal ring are**: (a) the round ligament of the uterus, (b) a closely applied fatpad, (c) the genital branch of the genitofemoral nerve, and (d) the artery of the round ligament of the uterus;
The ilioinguinal nerve perforates the medial crus of the superficial inguinal ring.



**In females
cremaster
muscle
does not
extend
beyond
the
superficial
inguinal
ring**

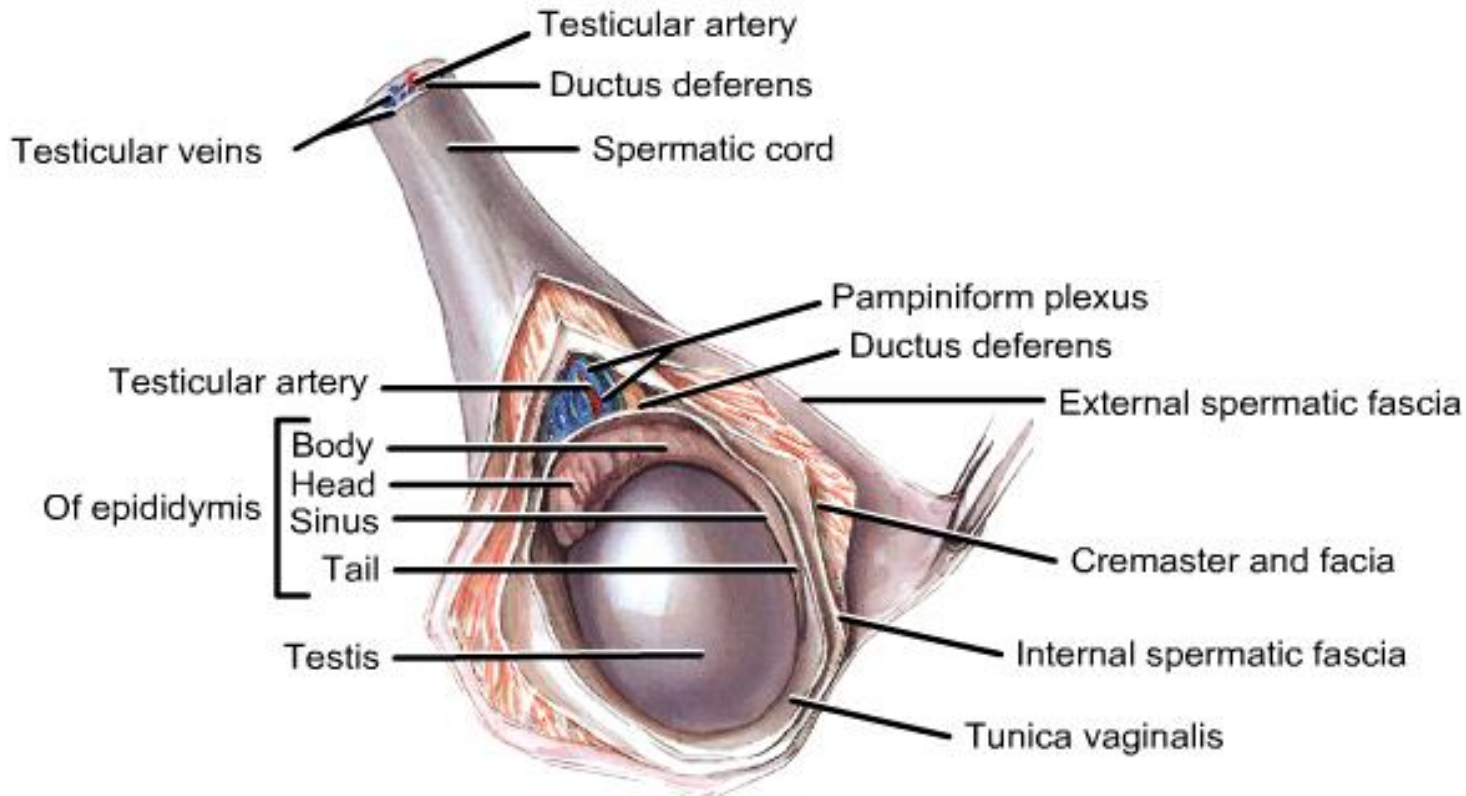


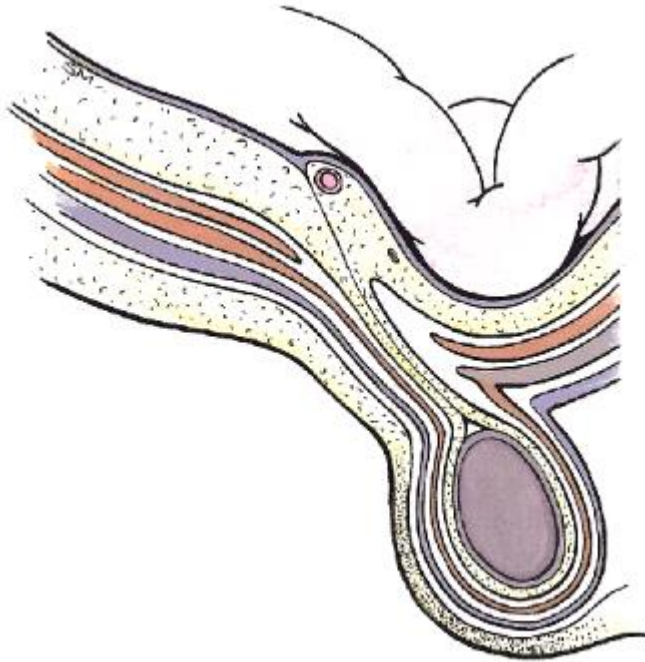
the arch of the transversus abdominis muscle and aponeurosis, laterally, arch superior to the spermatic cord and, medially, terminate posterior to it;



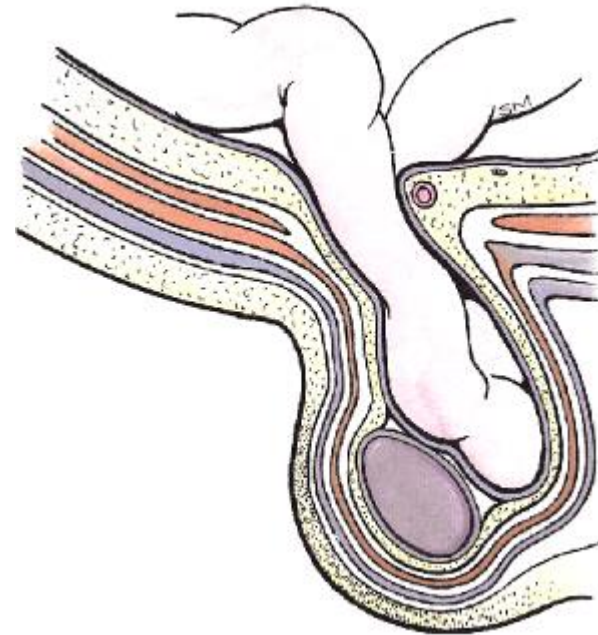
The genital branch crosses the lower part of the external iliac artery, enters the inguinal canal by its deep ring and supplies the cremasteric and the scrotal skin. In females it accompanies the round ligament and ends in the skin of the mons pubis and labium majus.

Layers covering the testis have been cut open sequentially: the external spermatic fascia, the cremaster muscle and fascia, the internal spermatic fascia, and the parietal layer of the tunica vaginalis of the testis.





Direct inguinal hernias bulge directly through the abdominal wall, medial to the inferior epigastric artery (C).



**indirect inguinal hernia.
Schematic horizontal section.**

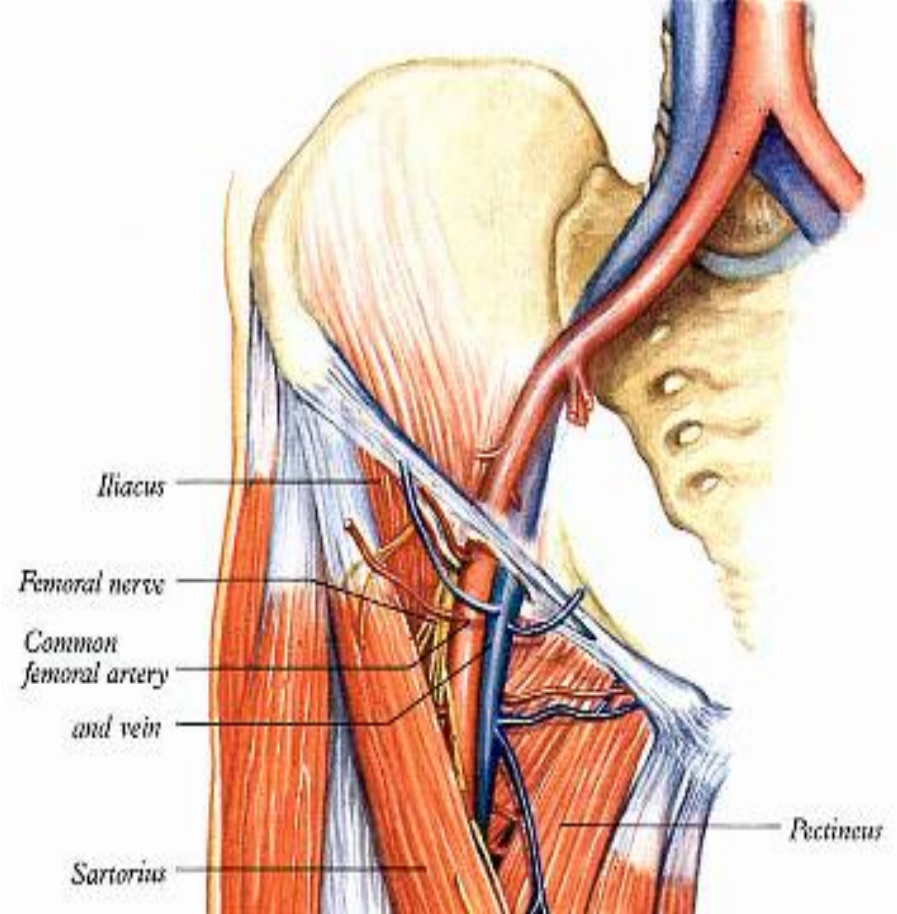
- ***Rectus Abdominis***

- it extends from the pubis to the horizontal line from the xiphoid to the fifth costal cartilage.
- ***tendinous intersections*** may be visible at the level of the umbilicus, the level of the xiphoid and midway between these two points.



- **Mid inguinal, or Femoral point**

- it marks the position of the femoral pulse,
- continuation of the external iliac artery into the femoral artery,
- deep inguinal ring, immediately superior to it,
- and it lies just inferior to the origin of the inferior epigastric and the deep circumflex iliac arteries as these arise from the external iliac artery.



Branches of femoral artery to the anterior abdominal wall

- **Superficial Epigastric Artery:** supplies the superficial inguinal lymph nodes and superficial fascia and skin
- **Superficial Circumflex Iliac Artery:** it supplies the skin, superficial fascia and superficial inguinal lymph nodes
- **Superficial External Pudendal Artery:** across the spermatic cord (or round ligament) to supply the lower abdominal, penile, scrotal or labial skin.
- **Deep External Pudendal Artery:** anterior or posterior to the adductor longus, supply the skin of the perineum and scrotum or labium majus

Inferior Epigastric Artery

It raises the parietal peritoneum of the anterior abdominal wall as the lateral umbilical fold .

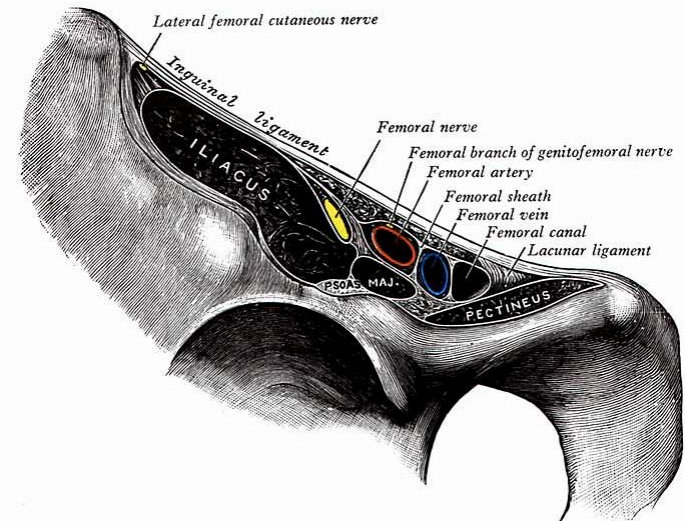
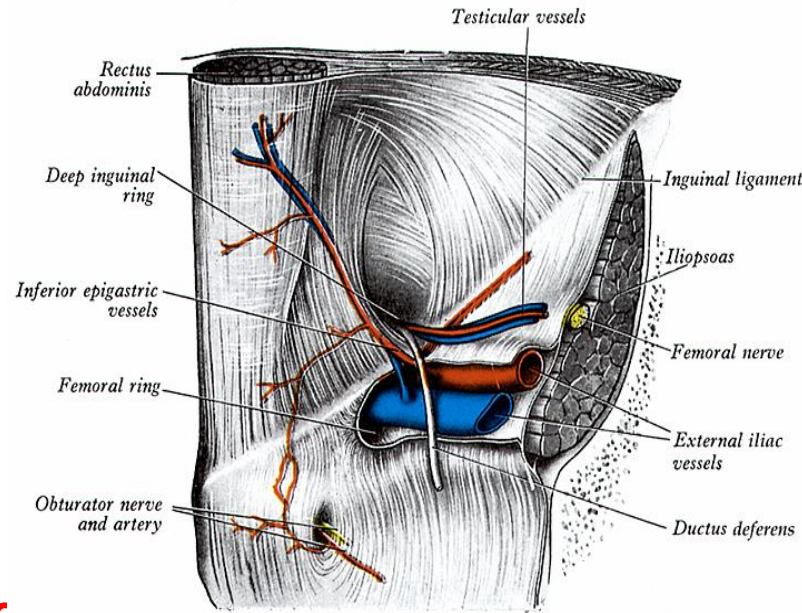
The ductus deferens, or round ligament, winds laterally round it. It supplies the following branches:

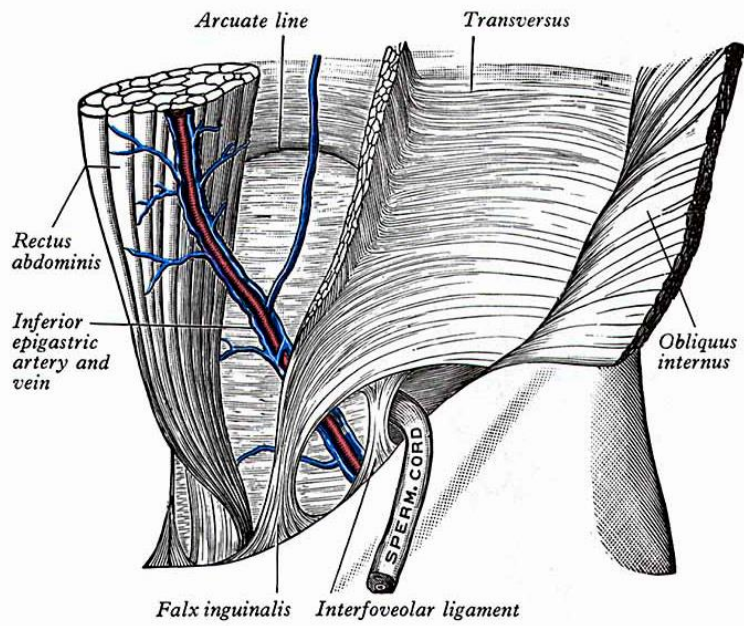
❑• **The cremasteric artery** accompanies the spermatic cord,

❑• **A pubic branch**, anastomoses with the pubic branch of the obturator.

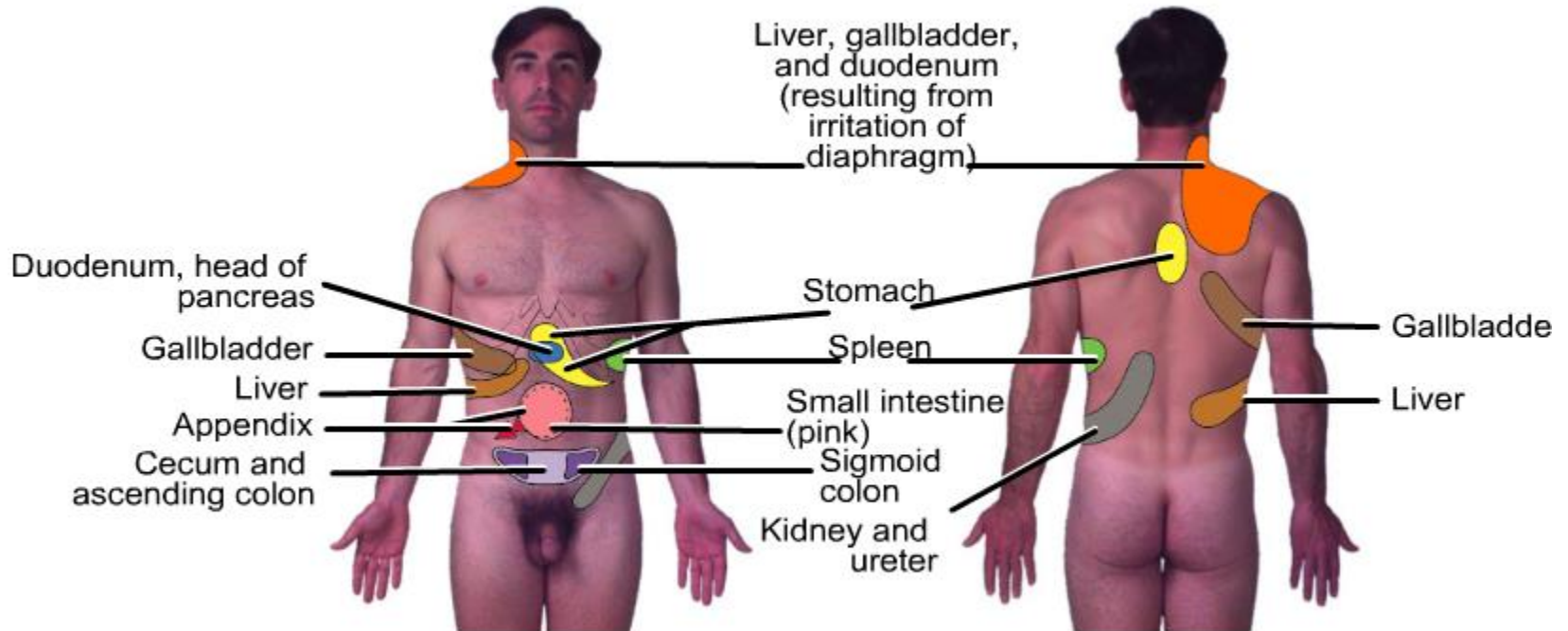
❑• **Muscular branches** supply the abdominal muscles and peritoneum

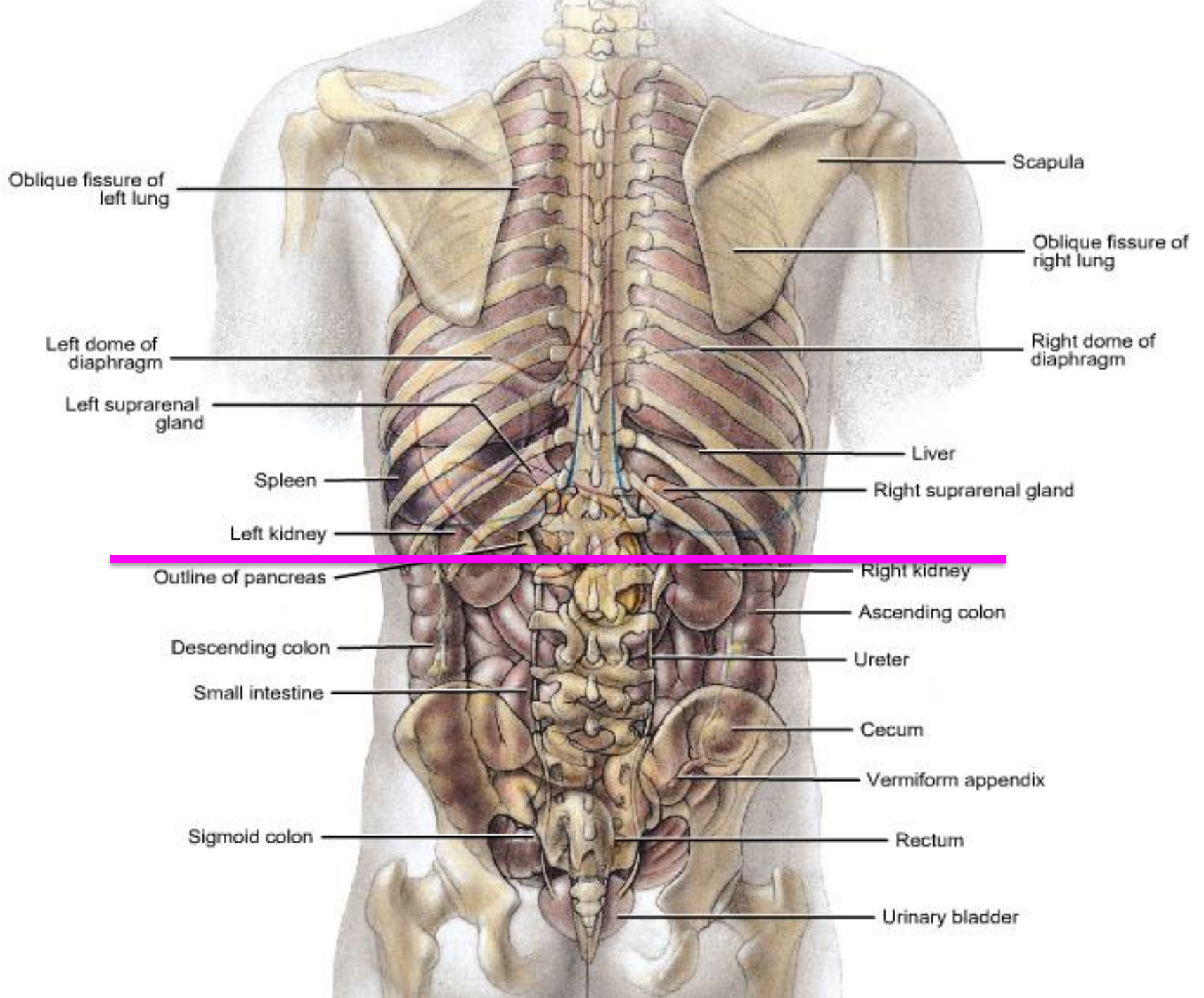
❑ **Cutaneous branches** perforate the aponeurosis of the external oblique, supply the skin and anastomose with branches of the **superficial epigastric artery**.

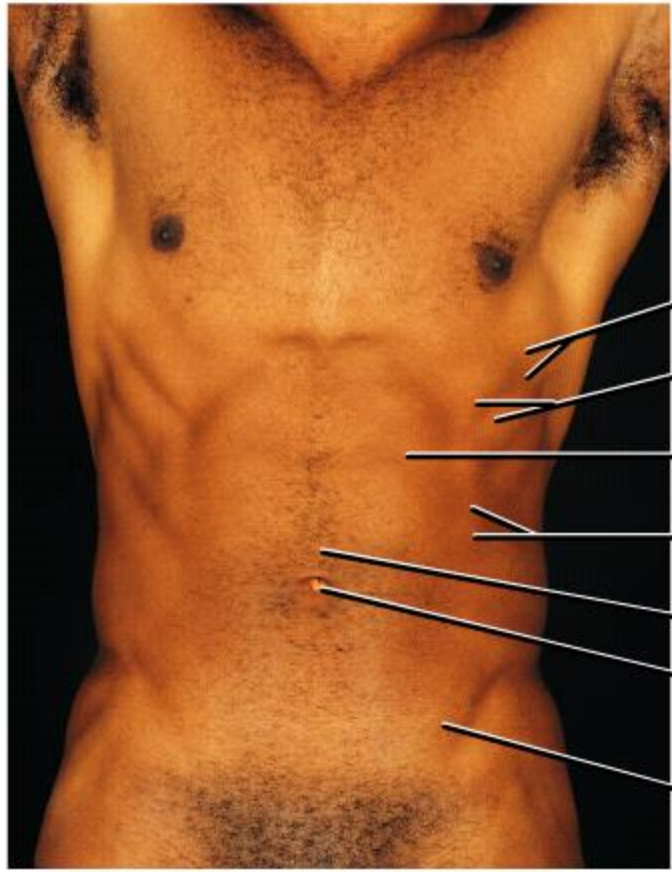




Referred pain







Serratus anterior

External oblique

Rectus abdominis

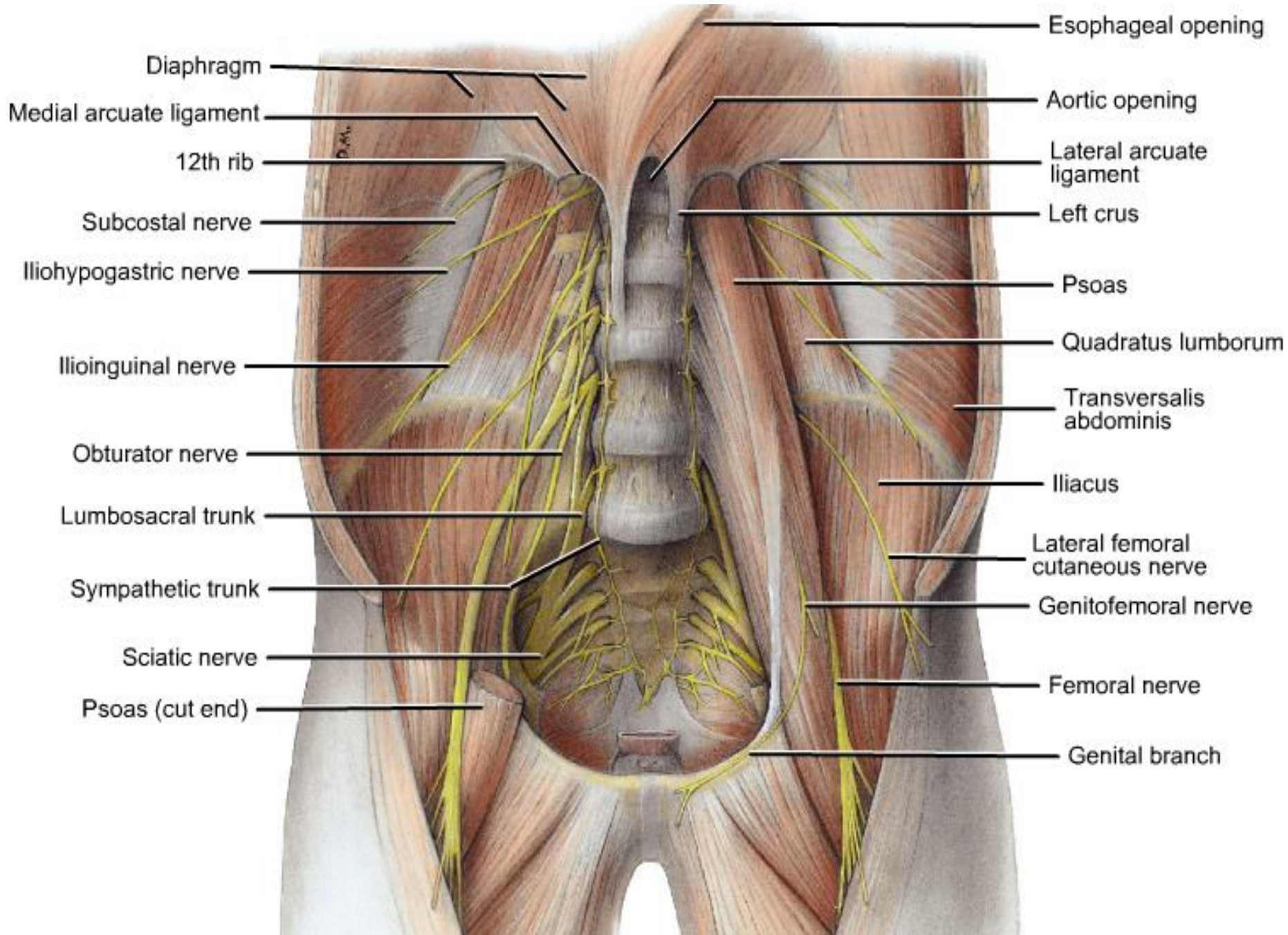
Linea semilunaris

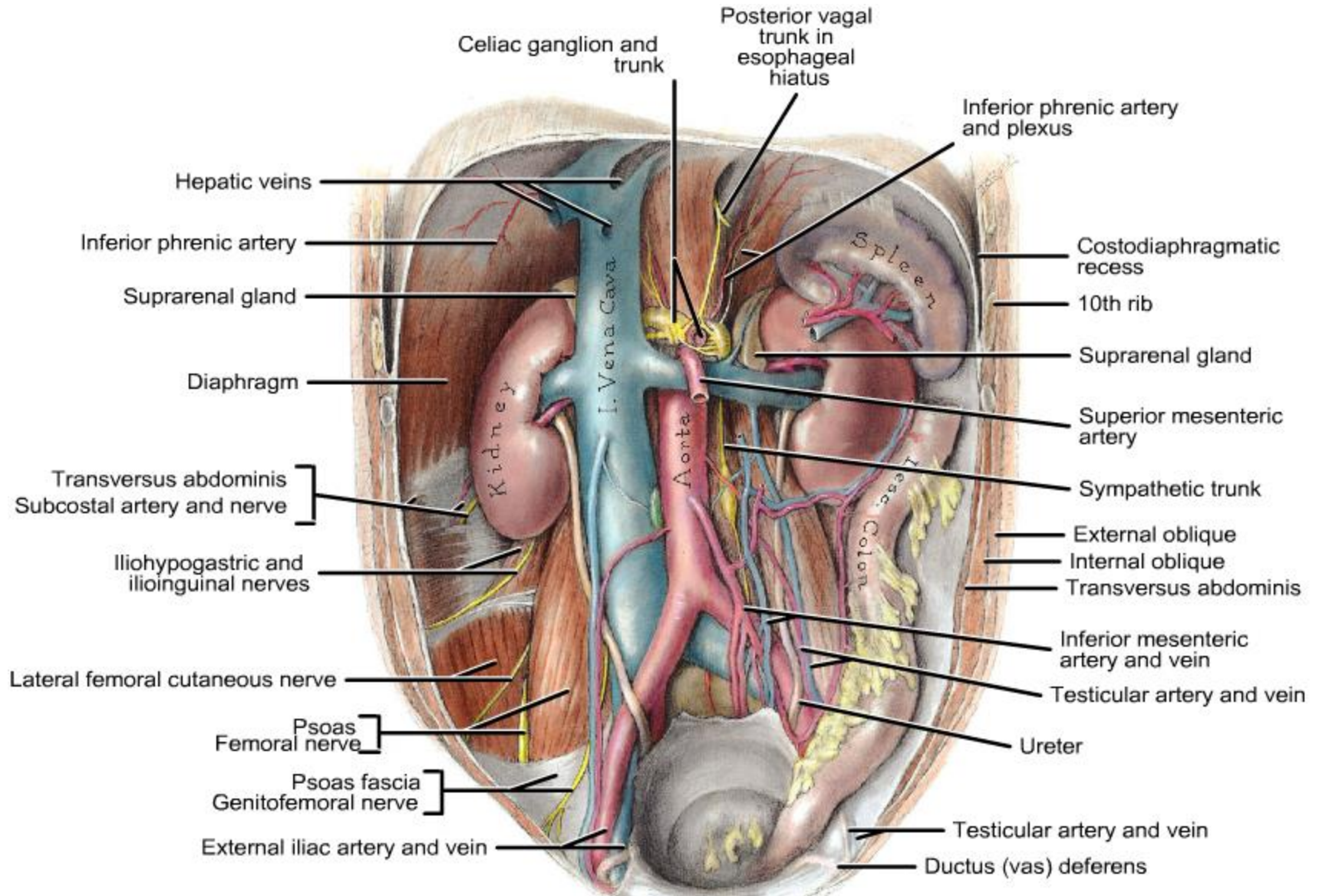
Location of linea alba

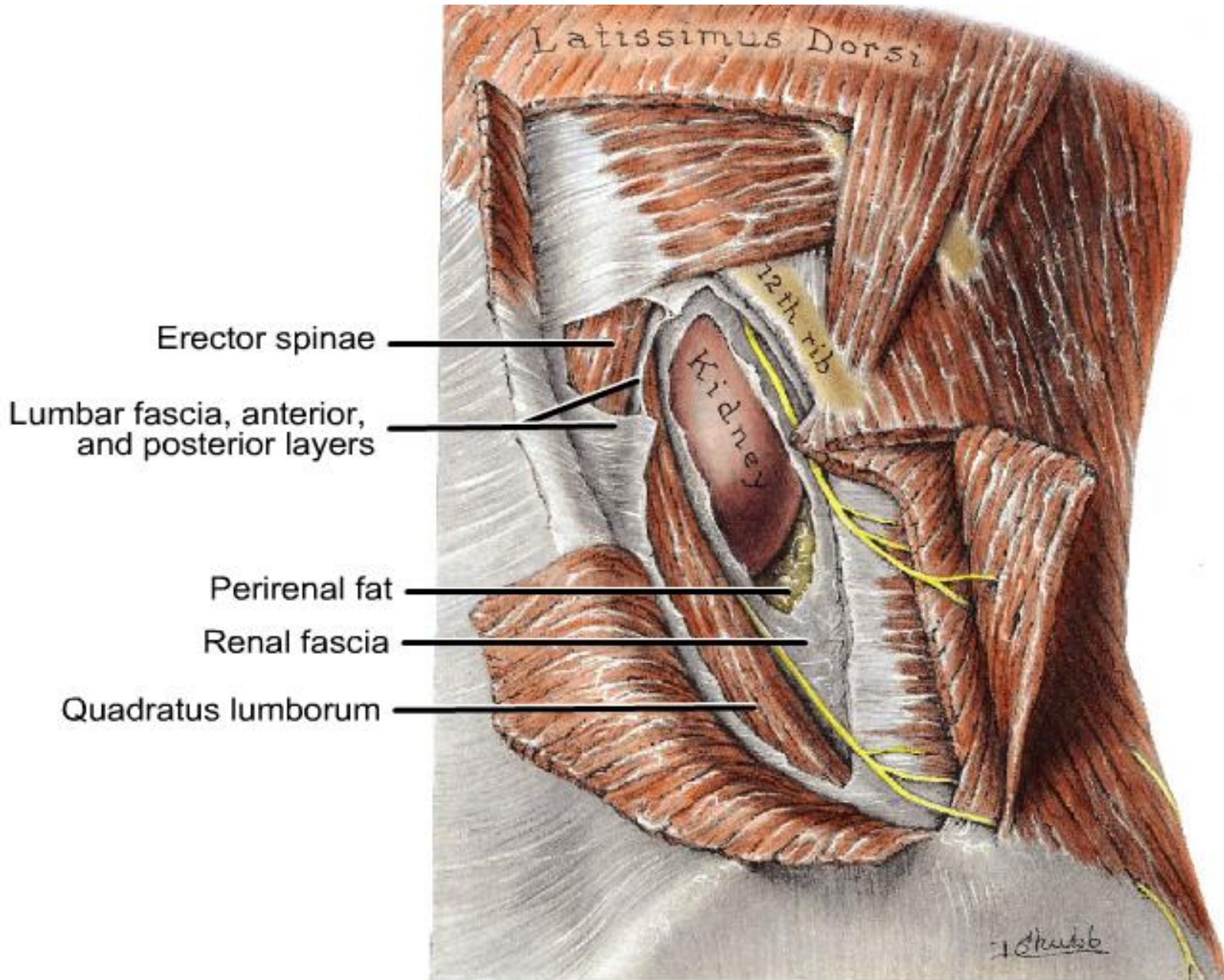
Umbilicus

Location of inguinal ligament

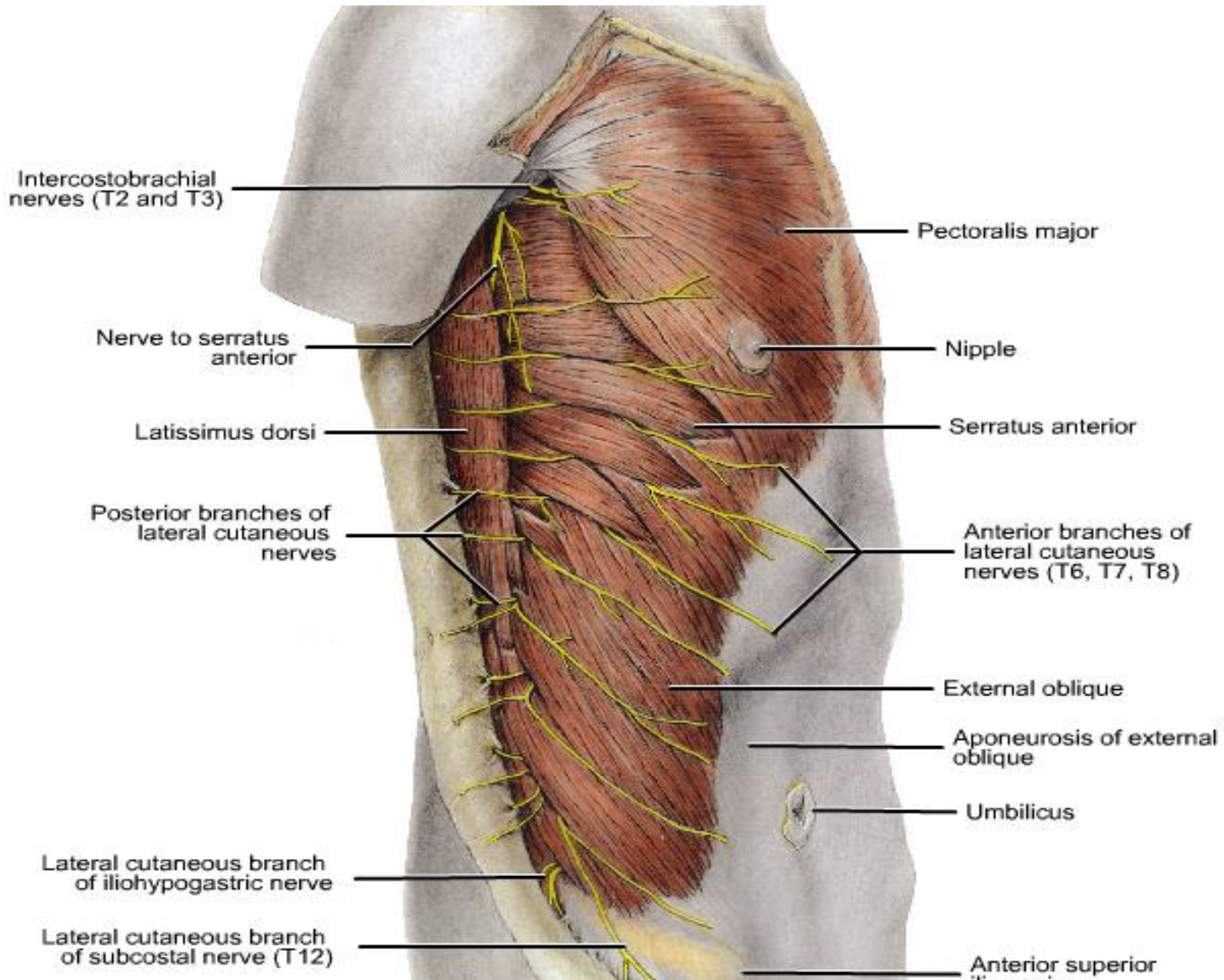




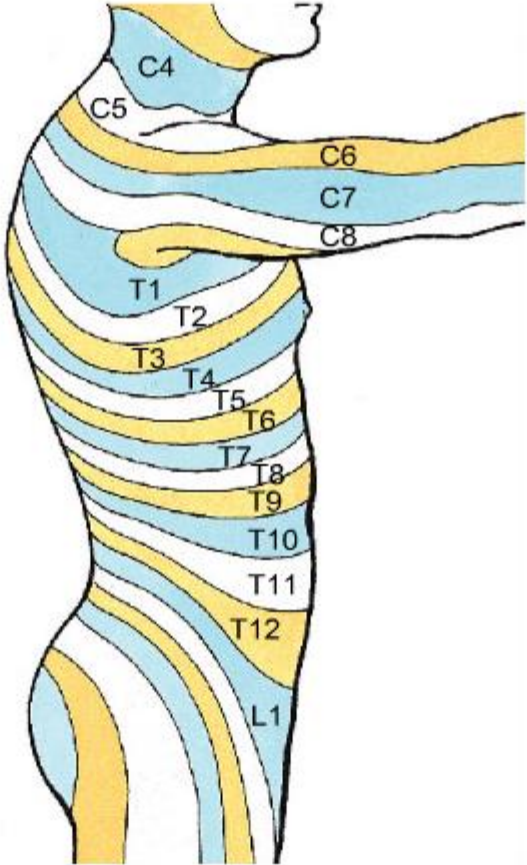


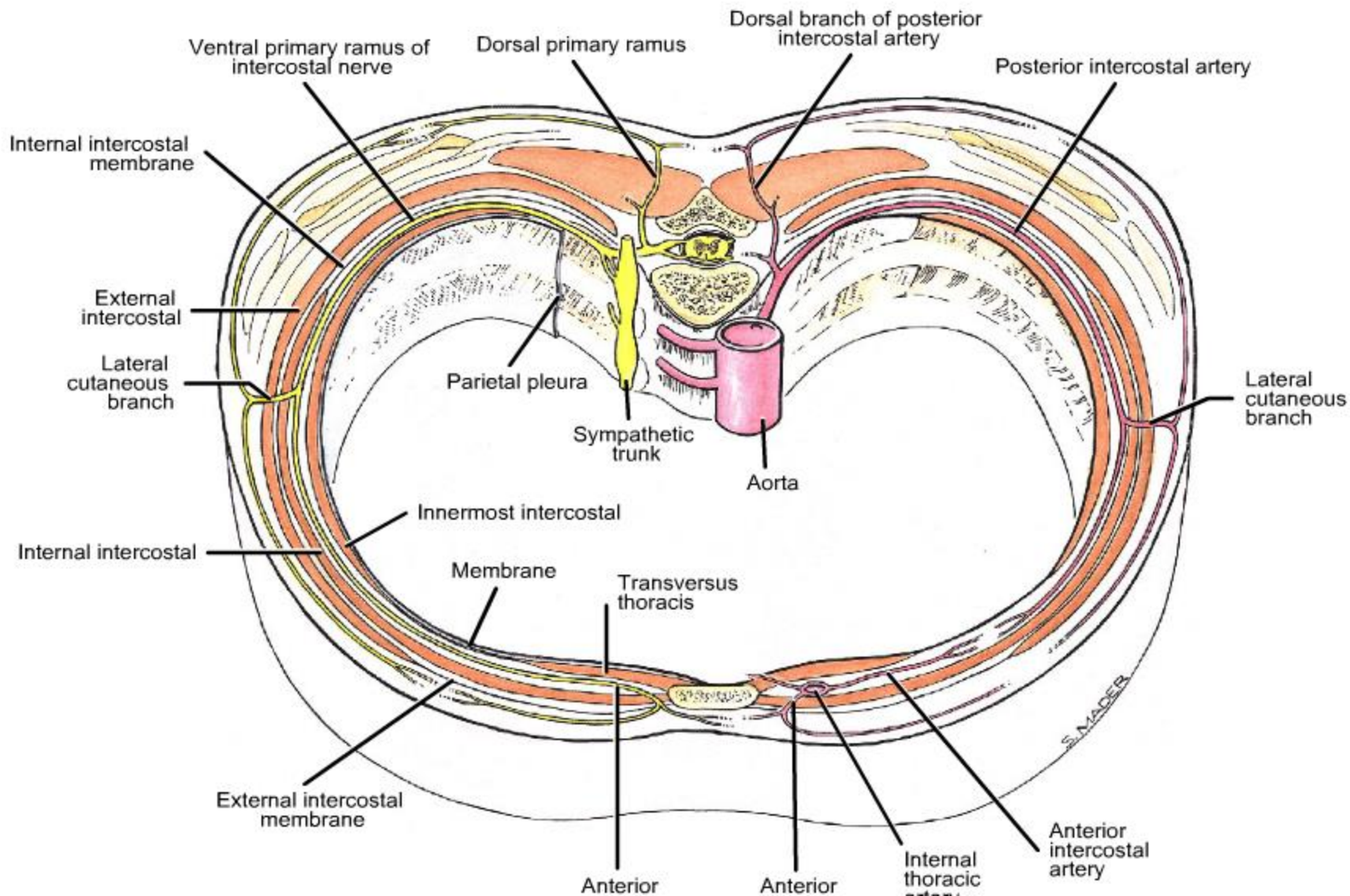


Lateral cutaneous intercostals n.

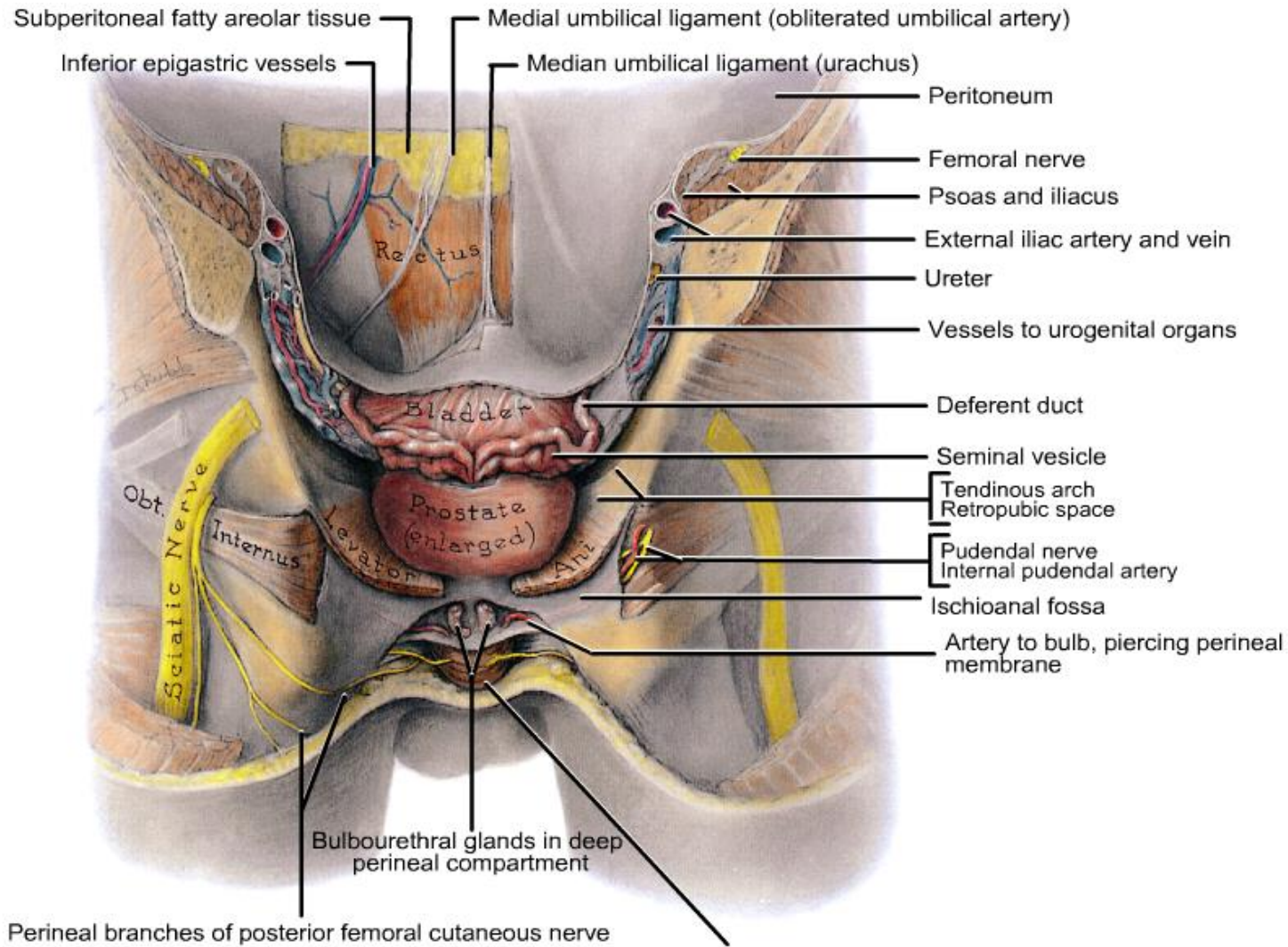


Dermatome



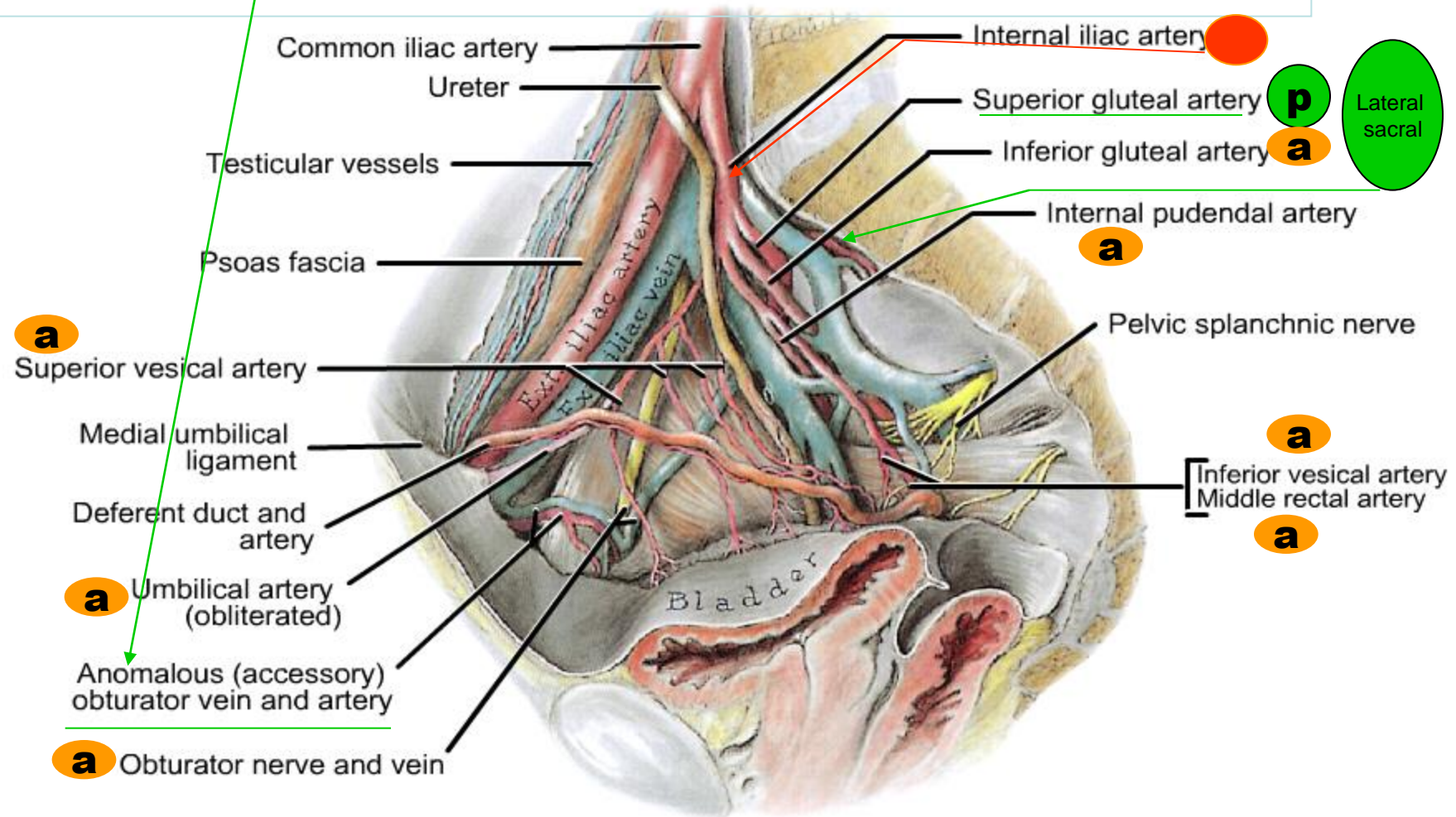


The levator ani muscle and its fascial coverings separate the retropubic space from the ischioanal fossa; note the free anterior borders of the

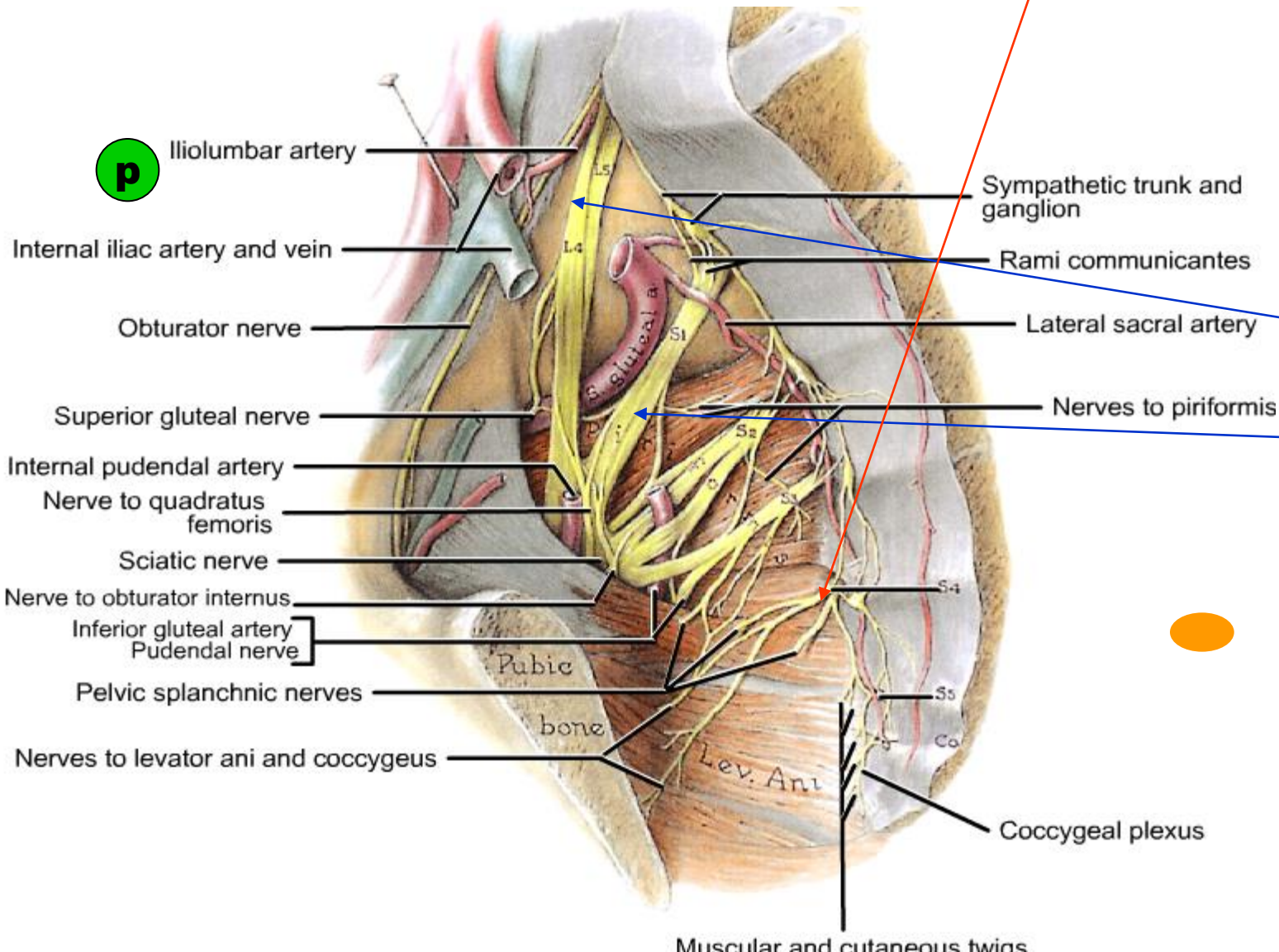


The ureter crosses the external iliac artery at its origin (common iliac bifurcation), and the deferent duct crosses the external iliac artery at its termination (deep inguinal ring);

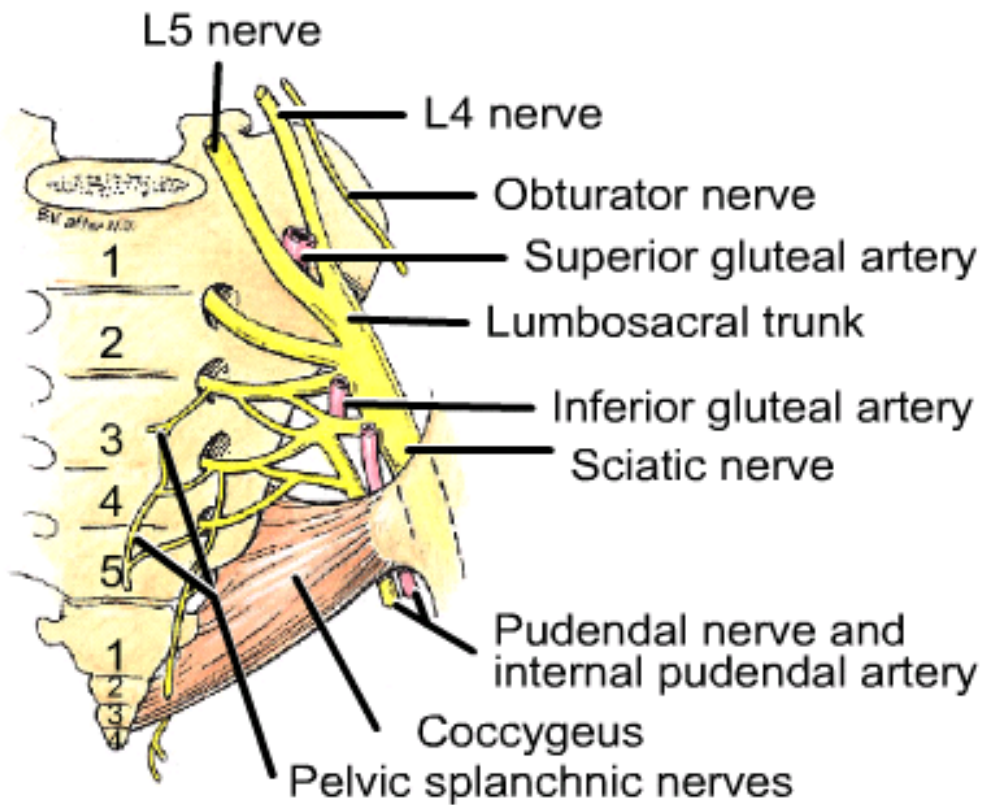
anomalous obturator artery branches from the inferior epigastric artery; there are normal and anomalous obturator veins.



The roots of S1 and S2 supply the piriformis muscle; S3 and S4 supply the coccygeus and levator ani muscles, and S2, S3, and S4 each contributes a branch to the formation of the pelvic splanchnic nerves;



The branch from L4 joins L5 to form the lumbosacral trunk



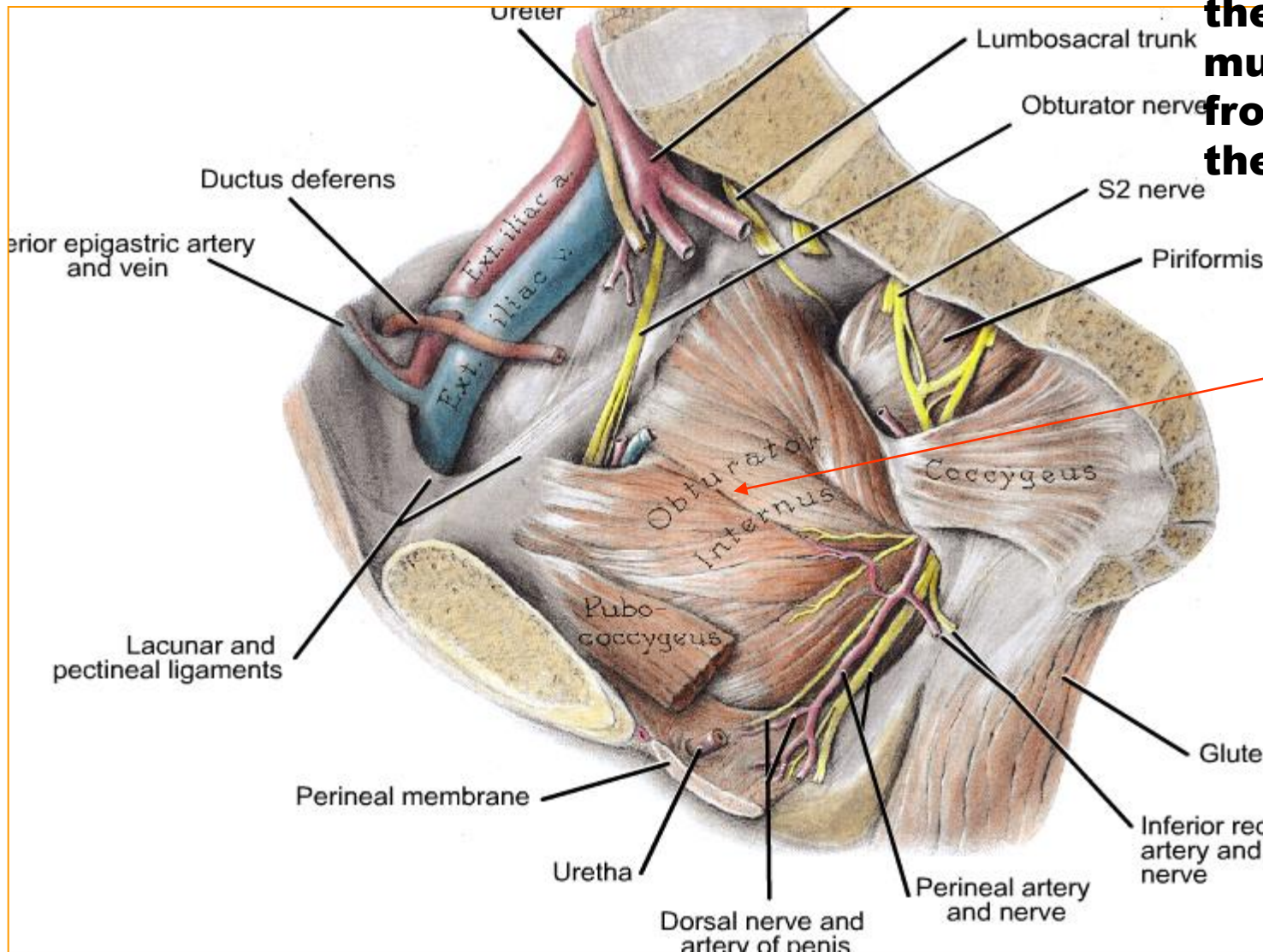
the sacral plexus is pierced by the superior and inferior gluteal arteries, which turn posteriorly; the internal pudendal artery continues anteroinferiorly toward the ischial spine.

piriformis muscle pads the posterior wall and leaves through the greater sciatic foramen.

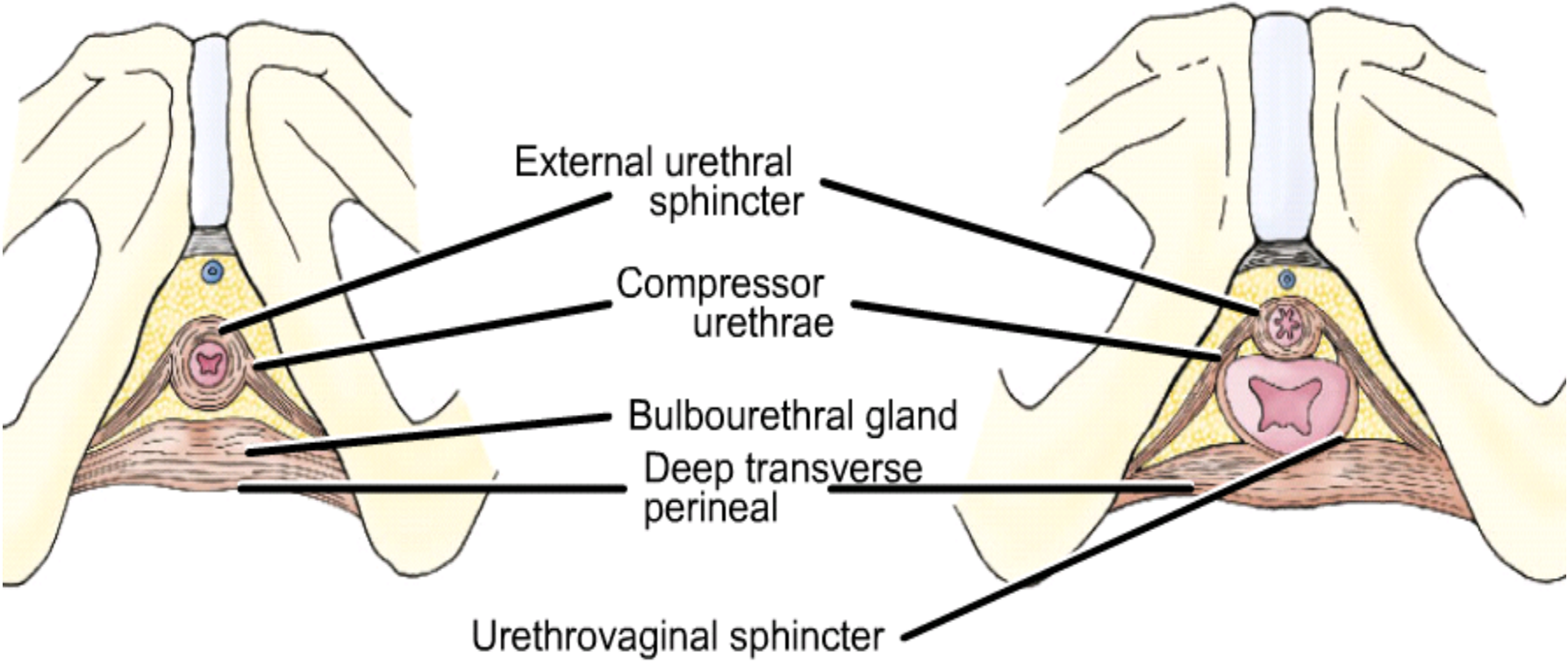
The coccygeus muscle conceals the sacrospinous ligament.

pubococcygeus muscle, chief, strongest part of the levator ani muscle, springs from the body of the pubis;

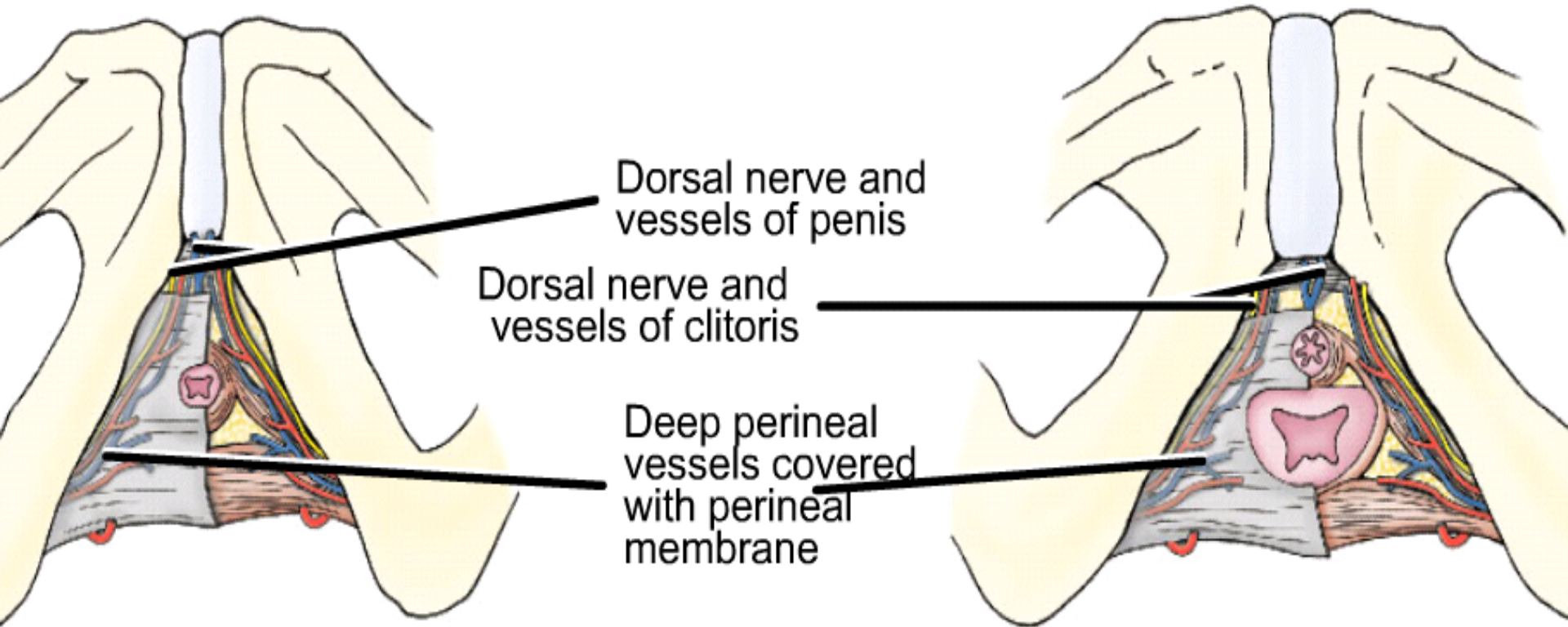
obturator internus muscle pads the lateral wall of the pelvis and leaves the pelvis minor through the lesser sciatic foramen,



The perineal membrane is strong, spanning between the ischiopubic rami, and separating the superficial and deep perineal compartments.



perineal vessels are covered by the perineal membrane.



dorsal artery, which ends in the glans penis. The deep dorsal vein, originally double, ends in the prostatic venous plexus

