

Primary sclerosing cholangitis

Primary sclerosing cholangitis (PSC) is a chronic cholestatic disease of the liver involving intra- and extrahepatic bile ducts. These are **diffuse inflammation** and **fibrosis** of the bile ducts distal to the interlobular ducts (septal, segmental, extrahepatic), which lead to the obliteration of the bile ducts and subsequently to the liver cirrhosis, liver failure, portal hypertension or cholangiocarcinoma. The etiology of PSC is unknown. Affected people are mostly men under 40 years of age; approximately half of PSC patients suffer from concurrent non-specific intestinal inflammation - mostly ulcerative colitis.

Clinical picture

Fatigue, weight loss, increased body temperature, painless icterus, pruritus. In more advanced stages, the clinical picture is conditioned by complications of liver cirrhosis.

⚠ When the general condition of the patient worsens and with any significant stenosis of the bile ducts, it is always necessary to rule out cholangiocarcinoma by differential diagnosis (biopsy and subsequent histopathological examination, cytology, oncomarkers CEA and CA 19-9).

Diagnostics

- Laboratory image of cholestasis: elevation GGT, ALP, bilirubin,
- ERCP, PTC, MRCP (in contrast cholangiogram typically "rosary image"; ERCP/PTC under the ATB screen),
- histopathological examination of biopsied material.

⚠ Patients suffering from both PSC and ulcerative colitis must undergo regular colonoscopy due to the increased risk of colorectal cancer.

Therapy

- Ursodeoxycholic acid (UDCA), immunosuppressants,
- balloon dilatation during ERCP or PTD,
- **liver transplant.**

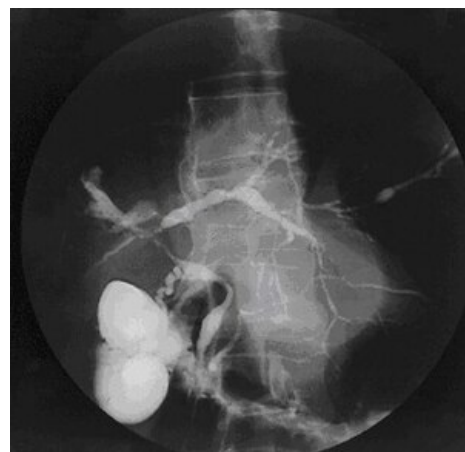
Links

related articles

- Sclerosing cholangitis
- Primary biliary cholangitis
- Acute cholangitis

References

- WORTHINGTON, Joy – CHAPMAN, Roger. Primary sclerosing cholangitis. *Orphanet J Rare Dis* [online]. 2006, vol. 1, p. 41, Available from <<https://ojrd.biomedcentral.com/articles/10.1186/1750-1172-1-41>>. ISSN 1750-1172.
- ZAVORAL, Miroslav – VENEROVÁ, Johana. *Gastroenterology a hepatology*. 1. edition. Triton, 2007. ISBN 978-80-7254-902-3.
- ČEŠKA, Richard. *Interna*. 1. edition. Triton, 2010. 855 pp. ISBN 978-80-7387-423-0.



Cholangiogram of primary sclerosing cholangitis.

Risk factors	male sex, familial occurrence
Clinical picture	fatigue, pruritus, liver failure
Diagnostics	laboratory, MRCP, ERCP + histology
Therapy	immunosuppressants
Complication	liver cirrhosis, cholangiocarcinoma
Classification and references	
ICD-10	K83.01