

Differential diagnosis of a scrotal mass

ADAM BROMBY AND JOANNE CRESSWELL

The authors discuss the various presentations of scrotal swellings, explaining how a careful clinical assessment and use of ultrasound can aid diagnosis and management of this common problem.

Scrotal swellings are a common problem among men of all ages. The cause of swelling may be malignant or benign (Figure 1). A careful assessment of the patient is essential in diagnosis and management (Box 1). Examination of the patient can also often elucidate the cause of the scrotal mass (Box 2). Initial investigation of a swelling may include an ultrasound scan, which has a high sensitivity and specificity, particularly for testicular tumours (Figure 2).¹

PAINFUL MASSES

Torsion of the testis

Torsion of the testis is a twist of the spermatic cord causing avascularity of the testis and is a urological emergency. It has an annual incidence of 3.8 per 100 000 in boys less than 18 years of age.² There is a bimodal distribution of age, occurring in neonates or around puberty and young adulthood.³

Sudden-onset scrotal pain is the most common presenting symptom; a tender testis riding high in the scrotum is suggestive on examination. Although torsion does not typically present as a scrotal swelling, delay

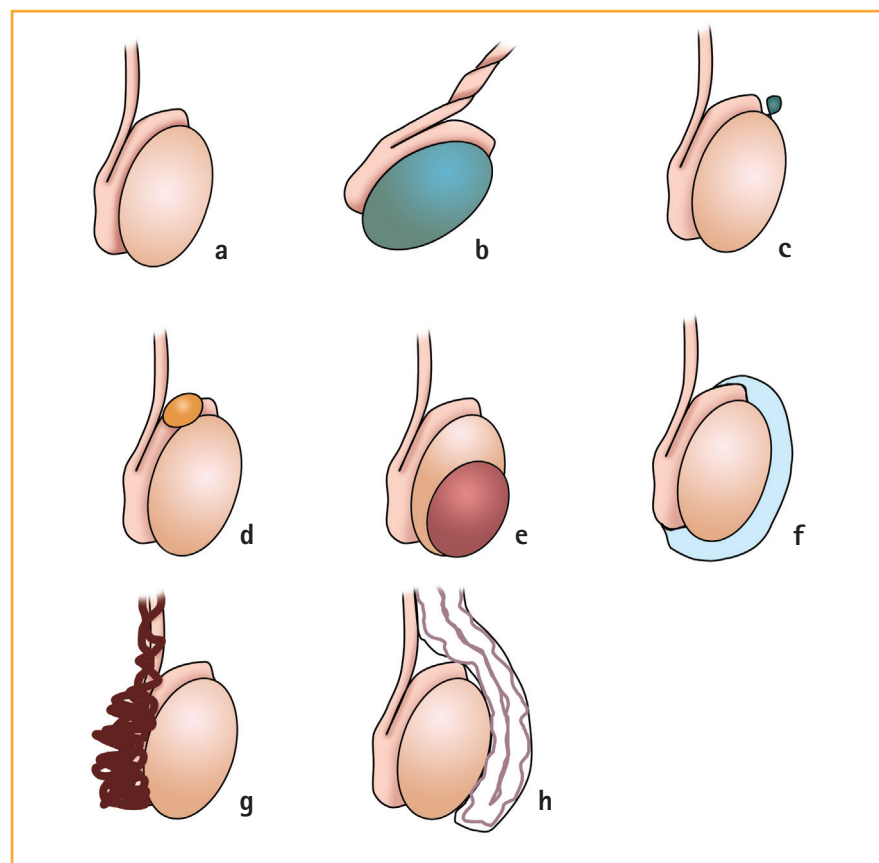


Figure 1. Schematic representation of scrotal masses: (a) normal; (b) testicular torsion; (c) torsion of a testicular appendage; (d) epididymal cyst; (e) testicular tumour; (f) hydrocoele; (g) varicocele; (h) inguinoscrotal hernia

in presentation may result in infarction of the testis and secondary swelling.

The emergency management of a suspected torsed testis is scrotal exploration to allow detorsion of the testis to restore vascularity, combined with bilateral orchidopexy. Ultrasound scanning should not delay exploration as it has only 84 per cent sensitivity.⁴ Optimum results are obtained

Adam Bromby, MRCS(Ed), MA, MB BChir, Core Surgical Trainee, Department of Urology; Joanne Cresswell, FRCS(Urol), PhD, MB BS, BMedSci, Consultant Urologist, James Cook University Hospital, Middlesbrough

BOX 1. Key points in the history of a man with scrotal swelling

- Age
- Duration of swelling
- Onset of swelling (sudden or gradual)
- Presence of pain
- Associated lower urinary tract or infective symptoms
- Recent trauma
- Previous scrotal surgery including orchidopexy
- Previous testicular tumour
- Family history

within six hours of onset of symptoms; certainly after 24 hours, chances of salvage of the testis are minimal.⁵ If the testis is non-viable, orchidectomy is necessary with fixation of the contralateral testis.

Epididymo-orchitis and scrotal abscesses

Epididymo-orchitis may affect all age groups. Children and men over 35 years of age may have epididymo-orchitis secondary to urinary pathogens; in adolescents and young adults sexually transmitted infections should also be considered. Swelling and tenderness are most commonly localised to the epididymis.

Complications may include abscess formation, which may be palpable as a tender, fluctuant, warm, erythematous swelling. There may be accompanying infective symptoms of dysuria, frequency, pyrexia or urethral discharge.

Treatment is usually an extended course of antibiotics (such as ciprofloxacin for 14 days). Ultrasound may be a useful adjunct in confirming the diagnosis, excluding abscess formation and examining the renal tract for underlying abnormality or predisposing factors for developing urinary tract infections. Associated urinary infection in men should be investigated as for complex urinary tract infections.

BOX 2. Key points in the examination of a man with scrotal swelling

- Site
- Size
- Tenderness
- Irregular/smooth
- Solid/soft/fluctuant
- Can upper border be palpated?
- Transilluminescence
- Scrotal appearance
- Auscultation
- Inguinal lymphadenopathy (for superficial pathology)

Torsion of testicular appendage (hydatid cyst of Morgagni)

Torsion of the testicular appendage is a common cause for painful swelling in the paediatric patient. It is caused by a twist of the testicular appendage with consequent infarction. Peak incidence is between 10 and 13 years of age. Clinical presentation may be similar to testicular torsion and may be diagnosed only on scrotal exploration. Although a 'blue dot' sign is specific, it is

present in only 10 per cent.⁶ The tortored appendage may be excised with diathermy at exploration. The natural history of a tortored appendage if not excised is 48–72 hours of pain and swelling.

Trauma (scrotal haematoma)

Trauma to the testis may result in swelling of the testis. This is most commonly caused by haematoma formation. With significant trauma there may also be testicular rupture. An ultrasound scan may allow assessment of the underlying testis to visualise any rupture of the tunica albuginea. With testicular rupture or expanding haematoma, scrotal exploration may be advised to repair rupture and evacuate haematoma. If the testis is non-viable, orchidectomy may be necessary. Antibiotic prophylaxis with haematoma may be considered to prevent secondary infection and abscess formation.

PAINLESS MASSES

Testicular tumour

Although testicular tumours are rare, accounting for fewer than 1 per cent of all cancers, they are the most common solid

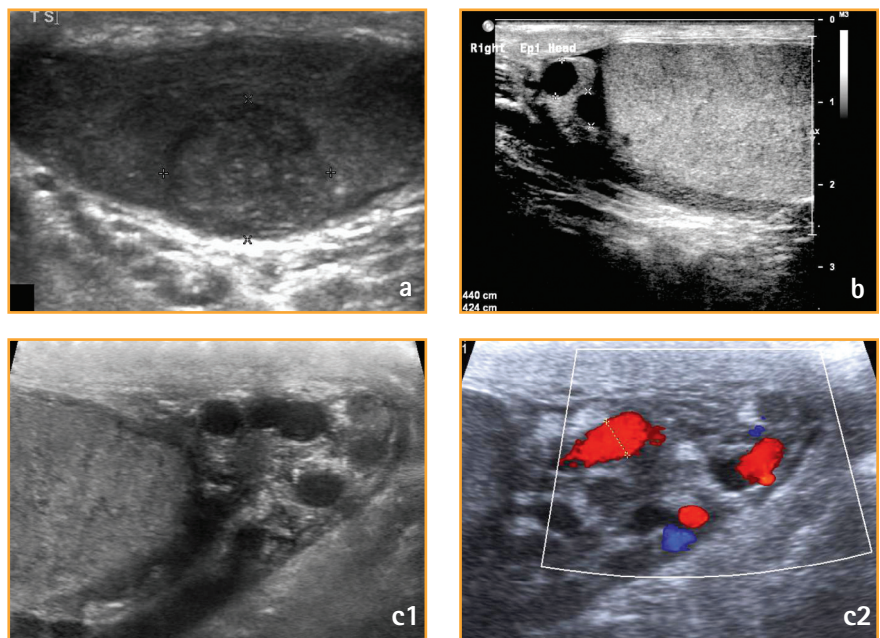


Figure 2. Ultrasound is a useful tool to aid clinical assessment of the patient with a scrotal mass. (a) A pT1 classical seminoma in a 30-year-old man with a previous history of undescended testes; (b) 46-year-old man with 2.4mm right epididymal head cysts; (c) 66-year-old man with left varicocele

tumours to affect young men aged 15–44 years, with 1871 cases in England in 2010.⁷ The incidence is rising among Caucasian populations.⁸ Testicular tumours are treatable, with 97 per cent overall five-year survival.⁹

Risk factors for testicular tumours include age, Caucasian ethnicity, cryptorchidism (increased relative risk persists even after orchidopexy), family history and a history of testicular tumour in the contralateral testis.

Ninety-five per cent are germ cell in origin (of which 45 per cent are seminomas, 50 per cent non-seminomatous germ cell tumours [NSGCT]), 4 per cent lymphomas, and 1 per cent other rare histological types.¹⁰

Presentation may be with a painless unilateral lump within the testis. Twenty per cent present with pain, with symptoms mimicking epididymo-orchitis or more acute pain suggestive of haemorrhage. Gynaecomastia may be the presenting symptom in 7 per cent as a result of paraneoplastic syndrome.

Tumour markers may be useful in initial investigation of a suspicious scrotal swelling. Alpha-fetoprotein (AFP) may be produced by NSGCTs. Beta-human chorionic gonadotrophin (β -hCG) may be produced by teratomas and seminomas. Lactate dehydrogenase (LDH) may be elevated in patients with advanced testicular tumours. Elevated tumour markers are a prognostic indicator, as is the degree to which they are elevated. AFP, β -hCG and LDH may also be used in monitoring patients following treatment.

Ultrasound is both a specific and sensitive modality for investigation of testicular tumours.¹ Staging with computed tomography (CT) scan of the chest, abdomen and pelvis is used for assessment of retroperitoneal, thoracic and mediastinal node disease and also for hepatic metastases. Brain CT or magnetic resonance imaging and bone scans should be performed if there is clinical suspicion of metastases to these organs.

Treatment of testicular tumours may involve inguinal orchidectomy with excision of the testis and cord at the level of the internal ring, with or without the insertion of a testicular prosthesis. Adjuvant chemotherapy or radiotherapy may also be beneficial dependent upon staging and grading of the tumour.¹¹

Poor prognostic factors for non-seminomatous tumours include mediastinal primary disease, non-pulmonary visceral metastases, or significantly raised AFP, β -hCG or LDH (greater than 10 000ng/ml, 50 000IU/l [10 000ng/ml], 10 x upper limit of normal, respectively). For seminomas the presence of non-pulmonary visceral metastasis is a poor prognostic factor.¹² Mixed germ cell tumours should be treated as for NSGCT.

Abnormal semen analysis may be found in men with testicular tumours, and fertility is often affected by chemotherapy or radiotherapy. Prior to commencing treatment, patients should be offered fertility testing and cryopreservation of sperm.¹¹

Hydrocoele

A hydrocoele is a collection of fluid between the visceral and parietal layers of the tunica vaginalis around the testis. In the paediatric population hydrocoeles are most commonly a result of a patent processus vaginalis (PPV), and treatment is therefore PPV ligation. In adults hydrocoeles usually form as a result of imbalance between secretion and absorption of fluid by the tunica. Care must be taken to exclude a reactive hydrocoele secondary to an underlying testicular tumour. Treatment may be by Lord's or Jaboulay procedures. Surgical treatment may not always be necessary, particularly if the hydrocoele is small in size or the patient asymptomatic.

Epididymal cyst

Epididymal cysts are common benign cysts outside the testis, found within the epididymis. Clinically epididymal cysts present as painless smooth round lumps

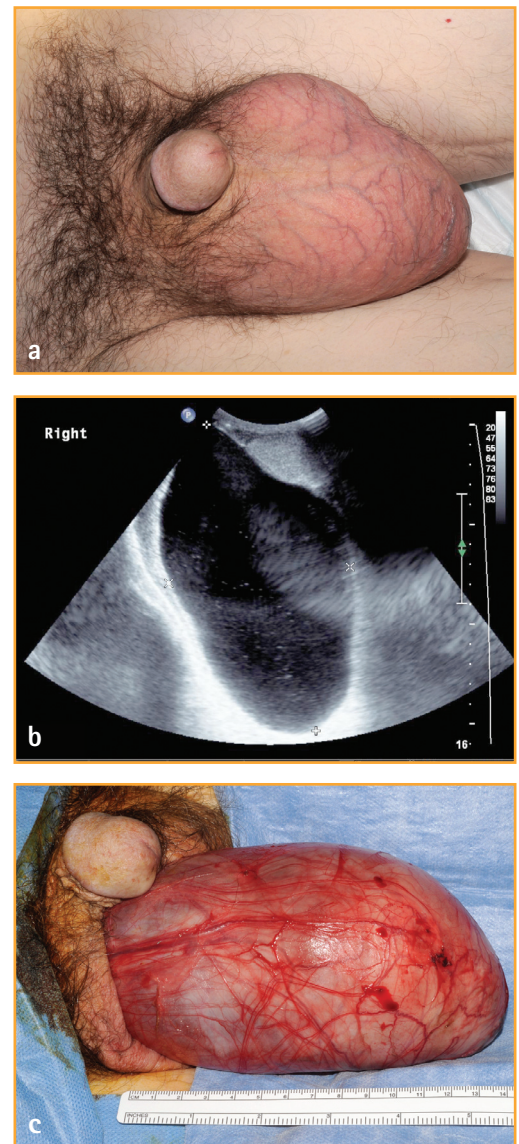


Figure 3. (a) 75-year-old man with 15cm right epididymal cyst; (b) seen at ultrasound; (c) seen during surgical excision. Usually epididymal cysts are small and palpable separate to the testis, most commonly at the epididymal head

within the epididymis, most commonly found within the head of the epididymis, but also in the body and tail. Epididymal cysts may be multiple; most require no formal treatment, with the patient being reassured of their benign nature. Occasionally epididymal cysts may be the cause of scrotal pain or be large in size (Figure 3). Surgical treatment with excision of the cyst is possible; however, there is a

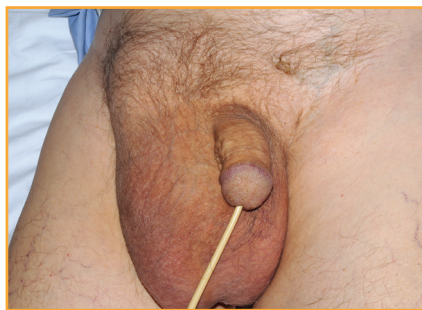

Figure 4. An 87-year-old man with a right inguino-scrotal hernia, shown as a palpable mass with the upper border not palpable within the scrotum but extending to the inguinal region. Bowel sounds could be auscultated

significant risk of subfertility following the procedure, and the patient therefore should receive careful prior counselling.

Varicocele

Abnormal dilatation of veins within the pampiniform plexus may result in a varicocele. Varicoceles may be asymptomatic, cause scrotal pain, or be associated with subfertility. Clinically varicoceles are palpable as a tortuous mass of veins, which may be more prominent when the patient is standing or during a Valsalva manoeuvre.

Ninety-seven per cent of varicoceles are present on the left; this is because of the anatomy of the left testicular vein draining into the left renal vein perpendicularly. When a varicocele is present on the right, it is often in conjunction with a left-sided varicocele.

Doppler ultrasound can be used in the diagnosis of varicocele. It also allows assessment of the kidney for tumours, which can rarely present with a varicocele caused by venous obstruction. Embolisation is the most commonly used treatment of the varicocele. Surgical varicocelectomy is an alternative.

Inguino-scrotal hernia

Occasionally large inguinal hernias may extend down into the scrotum. These are usually indirect inguinal hernias. Examination may reveal a soft swelling that extends above

the scrotum (Figure 4), bowel loops may be palpated, and bowel sounds may be auscultated within the swelling. Although usually asymptomatic, pain, tenderness or change in bowel habit may be suggestive of incarceration. Surgical repair may be indicated.

SCROTAL DISORDERS AFFECTING THE SKIN

Scrotal oedema

Acute idiopathic scrotal oedema may present as a unilateral or, more commonly, bilateral swelling of the scrotum, often with associated erythema and warmth. The swelling is usually non-tender and may extend to the penis or perineum. Boys under the age of 10 years are the most commonly affected. The condition is self-limiting and no specific treatment is necessary.

The scrotum may also be oedematous in association with other causes of lower limb oedema such as congestive cardiac failure or nephrotic syndrome.

Sebaceous cyst

Sebaceous cysts may present as mobile, firm, smooth swellings within the skin of the scrotum. They may be multiple and usually painless unless infected. Surgical excision may be considered if the patient is symptomatic.

Carcinoma of the scrotum

Carcinomas of the scrotum are rare and may present as an ulcerating lesion on the skin of the scrotum. Lesions are usually squamous cell carcinomas, although melanoma, basal cell carcinoma, or Kaposi sarcoma may also be found. Squamous cell carcinomas of the scrotum may be associated with exposure to industrial oils and tar, or with chronic inflammatory skin conditions. Surgical excision may offer the possibility of cure.

SUMMARY

Scrotal masses are common and often cause the patient considerable anxiety. However, with careful clinical assessment, a diagnosis can usually be made, with

ultrasound utilised to aid assessment and guide management.

Declaration of interests: none declared.

REFERENCES

1. Lau MWM, Taylor PM, Payne SR. The indications for scrotal ultrasound. *Br J Radiol* 1999;72:833–7.
2. Zhao LC, Lautz TB, Meeks JJ, et al. Paediatric testicular torsion epidemiology using a national database: incidence, risk of orchiectomy and possible measures toward improving the quality of care. *J Urol* 2011; 186:2009–13.
3. Somani BK, Watson G, Townell N. Easily missed? Testicular torsion. *BMJ* 2010;341: c3213.
4. Yu KJ, Wang TM, Chen HW, et al. The dilemma in the diagnosis of acute scrotum: clinical clues for differentiating between testicular torsion and epididymo-orchitis. *Chang Gung Med J* 2012;35:38–45.
5. Visser AJ, Heyns CF. Testicular function after torsion of the spermatic cord. *BJU Int* 2003; 92:200–3.
6. Makela E, Lahdes-Vasama T, Rajakorpi H, et al. A 19-year review of paediatric patients with acute scrotum. *Scand J Surg* 2007;96:62–6.
7. Office for National Statistics. *Cancer statistics registrations, England, series MB1, no. 41, 2010, 2012.*
8. Huyghe E, Matsuda T, Thonneau P. Increasing incidence of testicular cancer worldwide: a review. *J Urol* 2003;170:5–11.
9. Office for National Statistics. *Cancer survival in England – patients diagnosed 2005–2009 and followed up to 2010, 2011.*
10. Cancer Research UK. *Testicular cancer incidence statistics.* www.cancerresearchuk.org/cancer-info/cancerstats/types/testis/incidence/
11. Albers P, Albrecht W, Algaba F, et al. *European Association of Urology guidelines on testicular cancer.* Uroweb 2012. www.uroweb.org/gls/pdf/10_Testicular_Cancer.pdf
12. International Germ Cell Cancer Collaborative Group. International Germ Cell Consensus Classification: a prognostic factor-based staging system for metastatic germ cell cancers. *J Clin Oncol* 1997;15:594–603.