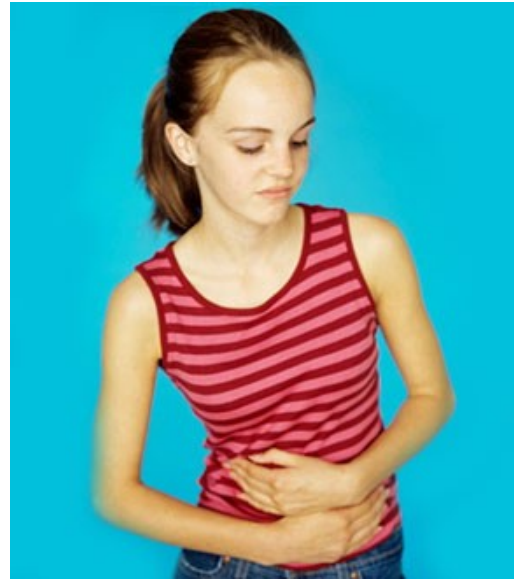

Abdominal pain in children



*University of Warmia and Mazury in Olsztyn
Faculty of Medical Sciences
Department of Clinical Pediatrics*

Abdominal pain in childhood-

general informations

- One of the most frequent complaint that brings children to a doctor
- Steps in reaching the diagnosis: a history, physical examination, laboratory testing, imaging studies, response to therapy
- Age- a key factor in evaluating the cause
- Poor sense of onset or location of pain, individual reaction to pain
- Can be caused by a wide range of surgical and non-surgical conditions

Abdominal pain in childhood-

general informations

- Repeated examination may be useful to look for the persistence or evolution of abdominal signs.
- Some children will have a cause found, however a significant number of children will be diagnosed with “nonspecific abdominal pain”.
- Neonates often present due to parental concern over “perceived abdominal pain” and broad differentials for presentation should be considered.
- Functional abdominal pain is very common but is a diagnosis of exclusion

Abdominal pain in childhood- pathophysiology

- Visceral (splanchnic)- sensitization of nerve endings -tension, stretching; ischaemia, inflammation
 - *stomach, intestines - dull, poorly localised,
 - *hepatobiliary, pancreatic, gastroduodenal disease- felt in epigastrium,
 - *small and large bowel- periumbilically,
 - *rectosigmoid colon, urinary tract, pelvic organs- suprapubic area
- Parietal (somatic)- stimulation of parietal peritoneum-sharp, intense, constant, localized, coughing and movement aggravate it
- Referred- felt in remote areas supplied by the same dermatome

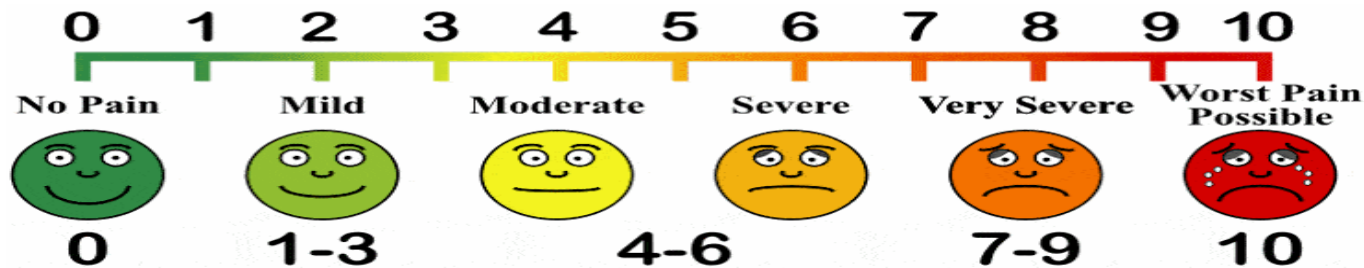
Abdominal pain in childhood- types of pain

Acute (organic),

Chronic (functional) - at least 2 weeks- 10-15% of children

✓ **persistent**

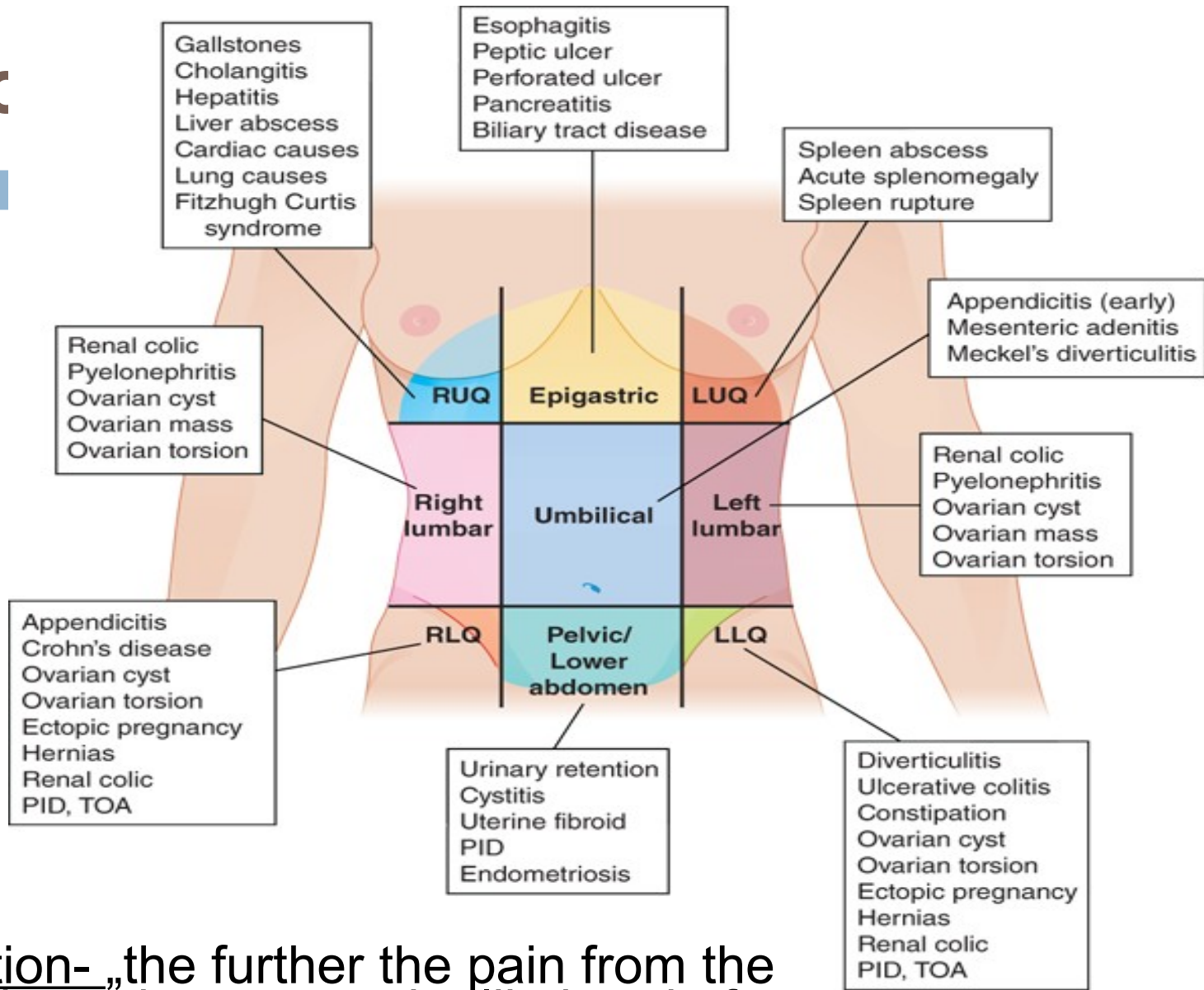
✓ **recurrent** - 3 or more episodes occurring in 3 months



- Intensity (1-10 scale, smile to „frown to tears” face),
- Character (hurt like needle? butterflies in stomach?, help to lie down? to poop?),
- Duration of pain, time of day or night

Cc

in



der, D.M. Cline:
dition

- Location- „the further the pain from the umbilicus, the greater the likelihood of organic disease”,

Abdominal pain in childhood- differential diagnosis by age

- **Birth to 1 yr:** infantile colic, gastroenteritis, constipation, urinary tract infection, intussusception, volvulus, Hirschsprung's disease,
- **2-5 yrs :** gastroenteritis, appendicitis, constipation, urinary tract infection, intussusception, volvulus, trauma, pharyngitis, sickle cell crisis, Henoch-Schonlein purpura, mesenteric lymphadenitis,
- **6-11 yrs :** gastroenteritis, appendicitis, constipation, functional pain, urinary tract infection, trauma, pharyngitis, pneumonia, sickle cell crisis, Henoch-Schonlein purpura, mesenteric lymphadenitis,
- **12-18 yrs :** appendicitis, gastroenteritis, constipation, dysmenorrhea, pelvic inflammatory disease, threatened abortion, ectopic pregnancy, ovarian/testicular torsion

Age- a key factor in evaluating the cause

Neonates	Infants and Preschool	School age child	Adolescents
Hirschprung's enterocolitis	Appendicitis	Appendicitis	Appendicitis
Incarcerated hernia_	Gastroenteritis	DKA	DKA
Intussusception_	Intussusception	Gastroenteritis	Ectopic pregnancy
Meckel's diverticulum_	Pneumonia	Henoch Schonlein Purpura	Cholecystitis/Cholelithiasis
UTI_	UTI	Mesenteric adenitis	Gastroenteritis
Volvulus	Volvulus	Migraine	Inflammatory Bowel disease
	Constipation	Ovarian Pathology	Ovarian cyst-torsion or rupture
		Pneumonia	Pancreatitis
		Constipation	Pelvic Inflammatory Disease
		Testicular torsion	Renal calculi
		UTI	Testicular torsion
		Viral Illness	UTI
			Viral illness

Highlighted in red=time critical illness

History





Assessment

History:

□ Onset of pain - sudden onset of pain, consider


} testicular or ovarian torsion

} intussusception  a medical condition in which a part of the **intestine folds into** the section next to it, similar to the way the parts of a **collapsible telescope** retract, this can often result in an obstruction.

} perforated viscus  An organ with an abnormal opening often is referred to as a perforated **viscus**. Viscus technically means a hollow organ found inside the body. Examples of these hollow organs mostly are found in the chest and **abdomen** such as the stomach, **appendix**, intestines, spleen, gallbladder, and urinary bladder.

Assessment

History:

- ❑ **Character of pain-** Episodic severe pain
- ❑ **intussusception** 
- ❑ **mesenteric adenitis**

Mesenteric adenitis means inflamed lymph glands in the abdomen, common cause of abdominal pain in children aged under 16 years, the name comes from mesentery- the part of the abdomen where the glands are located, adenitis which means inflamed lymph glands. It is sometimes called mesenteric lymphadenitis.

 - } gastroenteritis
 - } constipation
- ❑ **Testicular torsion** in patients with pain referred to the scrotum.

Assessment

History:

□ Associated Symptoms

- Bilious vomiting implies volvulus or bowel obstruction and warrants surgical review.
- Pallor and lethargy during episodes of abdominal pain occurs in intussusception.
- Rash and purpura on extensor surface of lower limbs/buttocks: consider Henoch Schonlein Purpura
- Cough and fever with RUQ or LUQ pain- pneumonia
- Dysuria, and frequency - UTI.
- Polyuria, polydipsia, loss of weight - diabetic ketoacidosis
- Menstrual and sexual history in post-pubertal girls as ectopic pregnancy can be fatal.

Assessment History:

□ Associated Symptoms

- Diarrhea often is associated with gastroenteritis or food poisoning, but it also can occur with other conditions.
- Bloody diarrhea is much more suggestive of inflammatory bowel disease or infectious enterocolitis.
- The classic “currant-jelly stool” often is seen in patients with intussusception.
- Failure to pass flatus or feces suggests intestinal obstruction
- Polyuria and polydipsia suggest diabetes mellitus
- Cough, shortness of breath, and chest pain point to a thoracic source.

Assessment

History:

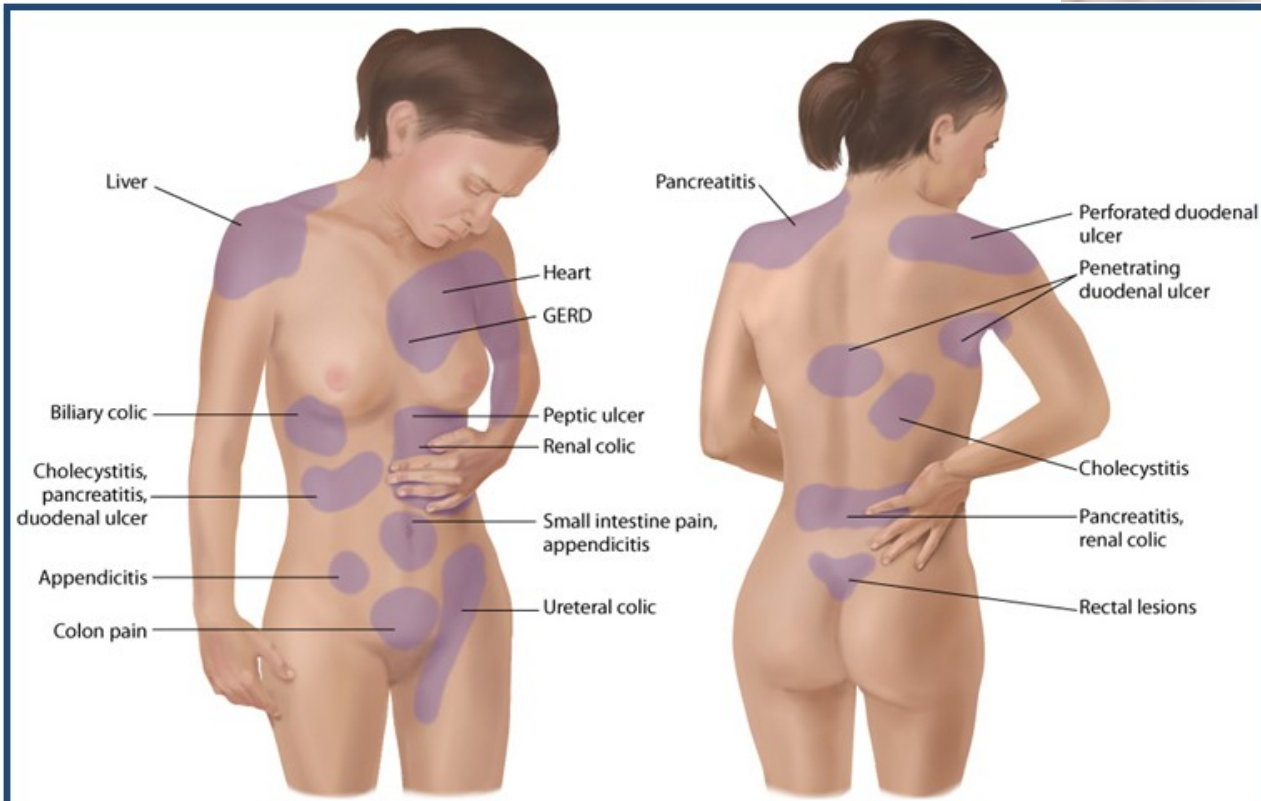
- stool pattern, consistency, completeness of evacuation, weight loss, growth, pubertal delay, fever, joint complaints, rash, chronic cough
- a past history of: ulcer disease, gallstone colic gastroesophageal reflux, diarrhea, constipation, jaundice, melena, mucus or blood in stool, hematuria, hematemesis
- medications
- family history- peptic disease, irritable colon, inflammatory bowel disease, pancreatitis, biliary disease, travels
- interference with school, family and peer relations, sexual issues

Assessment

History:

- **Past medical history:** associated with rarer causes of abdominal pain
 - } Hirschprung's disease and Cystic Fibrosis - complicated by enterocolitis with sudden painful abdominal distension and bloody diarrhoea. These patients can rapidly deteriorate with dehydration, electrolyte disturbances and systemic toxicity and are at risk of colonic perforation.
 - } Primary bacterial peritonitis can occur in children with liver disease, nephrotic syndrome, splenectomy, ascites and those with VP shunts.
 - } Pancreatitis can be caused by drugs including chemotherapy and immunosuppressant agents.
 - } Inflammatory bowel disease- toxic megacolon

Examination:



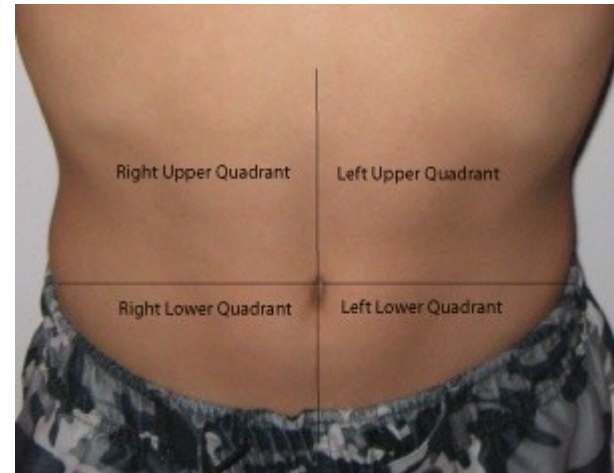
Examination:

- Assess hydration status
- Children with peritonism:
 - will often not want to move in the bed
 - be unable to walk or hop comfortably
 - abdominal tenderness with percussion
 - internal rotation of the right hip can irritate an inflamed appendix.

Examination:

□ Examine abdomen

- focal vs generalised tenderness
- rebound tenderness
- guarding or rigidity
- abdominal masses
- distension
- palpable faeces

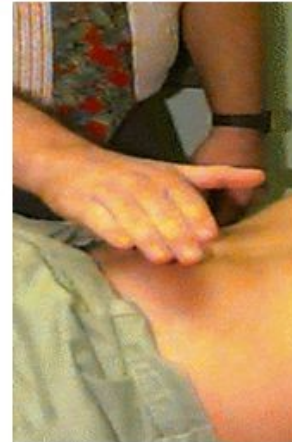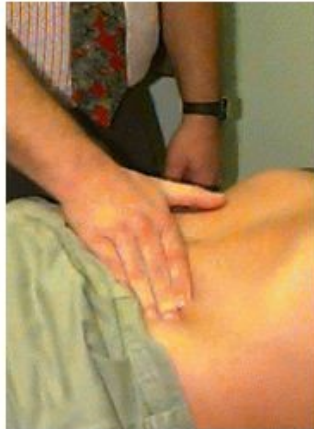


□ Respiratory examination

- Inguinoscrotal examination – including testes, look for hernia

Rectal or vaginal examination is rarely indicated in a child and should only be performed by one person

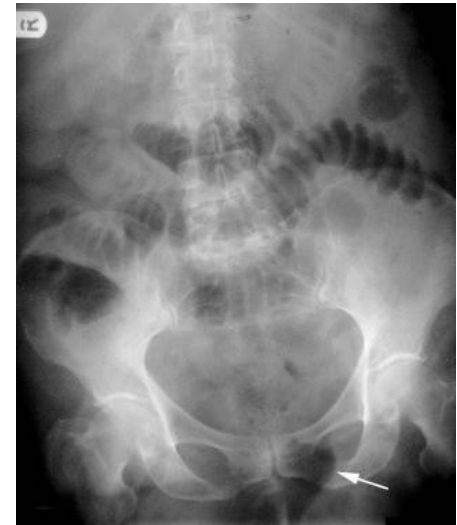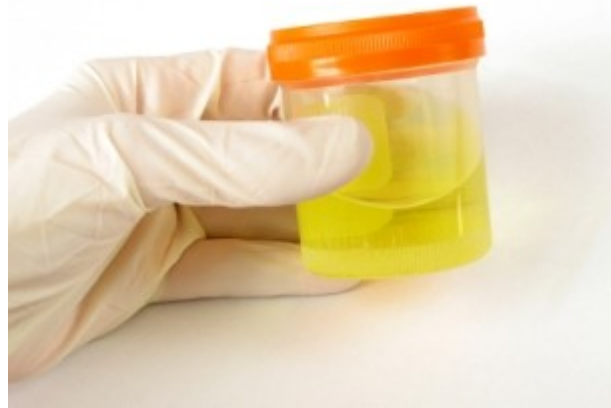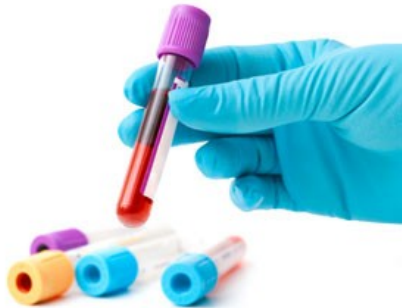Rebound tenderness



- This is a test for peritoneal irritation. Palpate deeply and then quickly release pressure. If it hurts more when you release, the patient has rebound tenderness.

Investigations :


These will depend on differential diagnosis but may include the following



*But
many children need no investigations*

Investigations :

- urine
- blood sugar for DKA
- electrolytes +/- liver function tests
- Lipase (pancreatitis)
- urine pregnancy test/ quantitative beta hCG
- Coeliac serology and total IgA - consider for chronic abdominal pain
- Imaging
 - } AXR if obstruction suspected. Not helpful in diagnosing constipation.
 - } CXR if pneumonia suspected
 - } Ultrasound
 - May be requested after discussion with senior staff
 - Is *not* clinically indicated for testicular torsion.



Algorithm for evaluating acute abdominal pain in children.


Management

- Treatment should be directed at the underlying cause
- In many patients, the key to diagnosis is repeated physical examination by the same physician over an extended time
- Indications for surgical consultations
- The use of analgesics



Treatment

Abdominal pain



Abdominal pain is one of the most common reason for which parents take the child to a doctor.

 + recurrent 

Acute abdominal pain



- **Common-** appendicitis, gastroenteritis, dietary indiscretion, food poisoning
- **Less common-** incarcerated hernia, intussusception, Meckel's diverticulum, mesenteric lymphadenitis, peritonitis, pneumonia, Henoch-Schonlein purpura, viral gastroenteritis, abdominal trauma, rupture of spleen, intestinal obstruction, cholecystitis, cholelithiasis, splenic infarction, pancreatitis, urinary calculi, ectopic pregnancy, ovarian/testicular torsion, diabetic ketoacidosis, porphyria, acute adrenal insufficiency, sickle cell anaemia, hemolytic uremic syndrome

APPENDICITIS

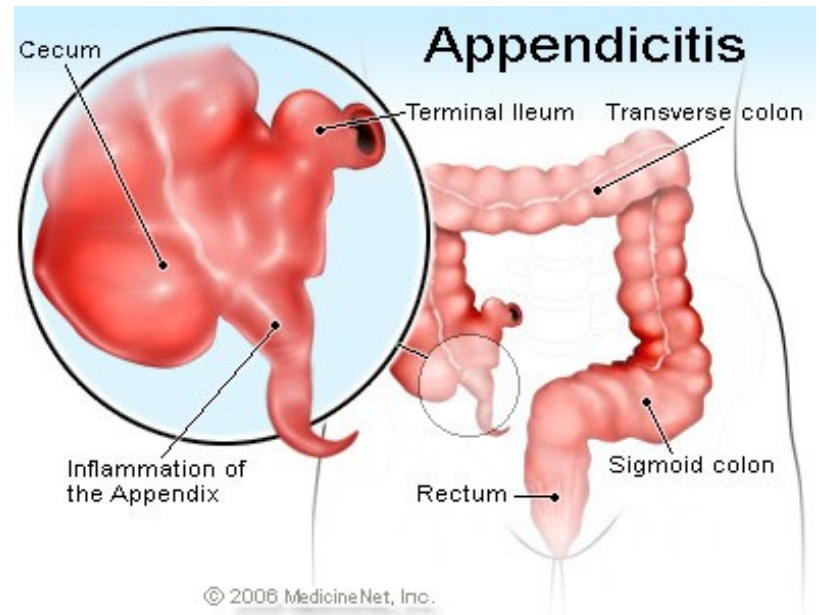
- Peak incidence 10-12 years
- Begins as dull, steady pain in periumbilical area...
Progresses over 4-6 hours & localizes to right lower quadrant
- Low grade fever
- Nausea
- Anorexia
- Sudden pain relief may indicate rupture of appendix (Leads to peritonitis)



Diagnosis


- Clinical signs and symptoms
- ↑ WBC
- Abdominal Sonogram
- Exploratory Lap

- Rebound Pain or Tenderness (RLQ) at McBurney's Point

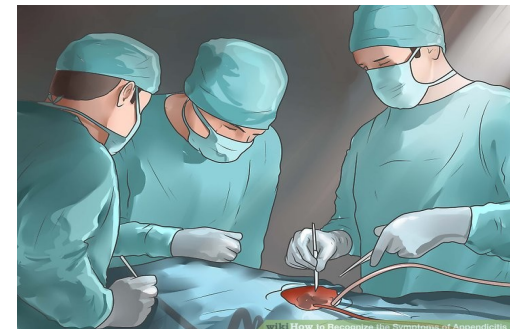


© 2006 MedicineNet, Inc.


Acute abdominal pain in childhood- indications for **surgical consultations**



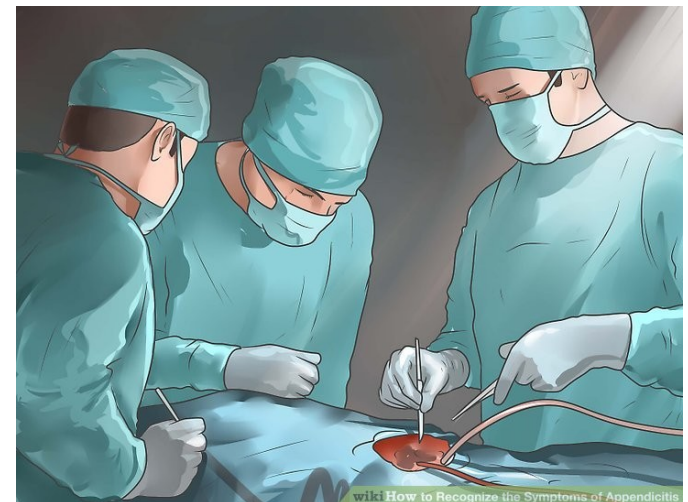
- ❑ Severe or increasing abdominal pain with progressive signs of deterioration
- ❑ Bile-stained or feculent vomitus
- ❑ Involuntary abdominal guarding/rigidity
- ❑ Rebound abdominal tenderness
- ❑ Marked abdominal distension with diffuse tympany, no peristalsis
- ❑ Signs of acute fluid or blood loss into the abdomen
- ❑ Significant abdominal trauma
- ❑ Suspected surgical cause for the pain
- ❑ Abdominal pain without obvious etiology

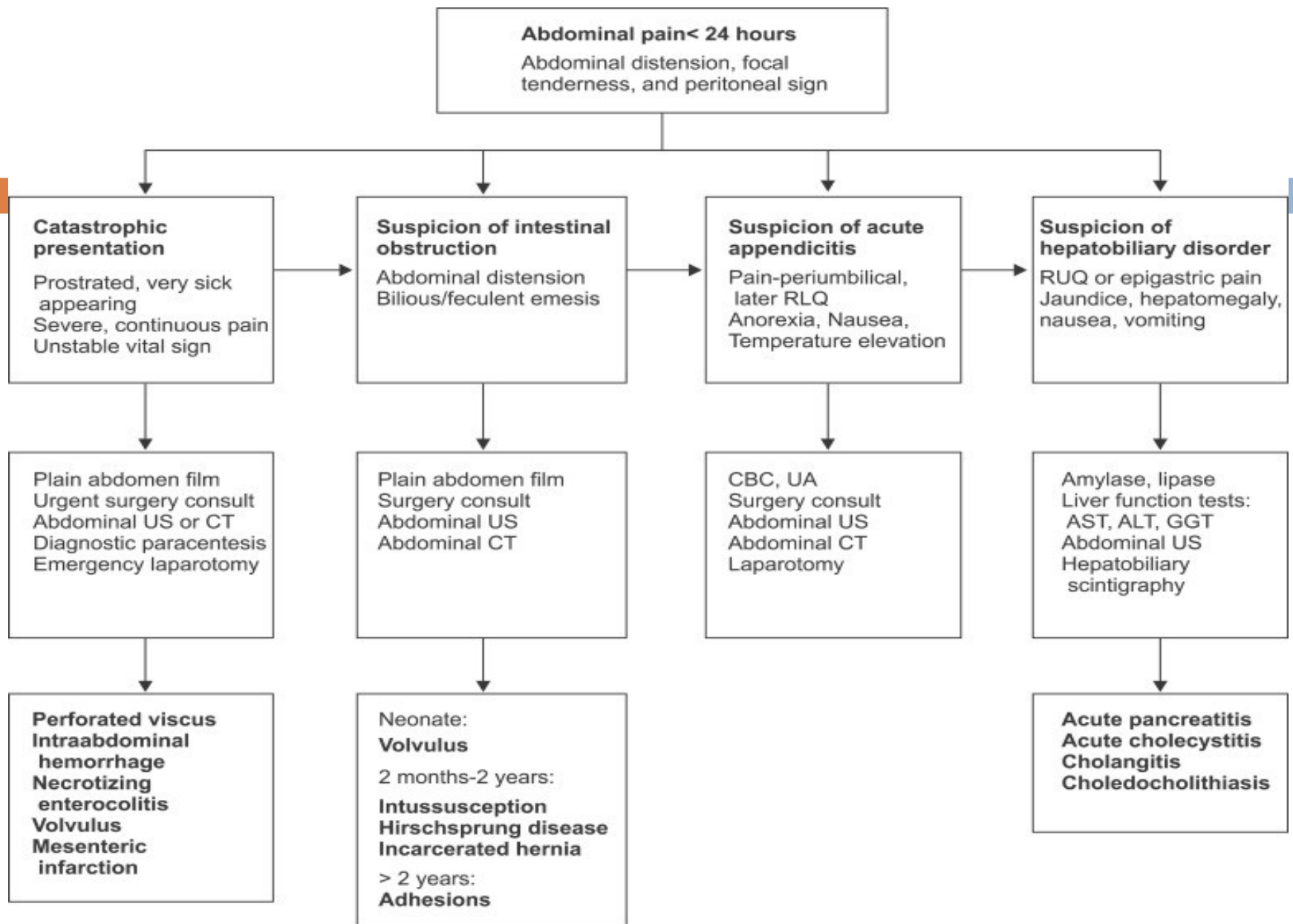


Acute abdominal pain in childhood- surgical emergency



- Appendicitis
- Intussusception
- Meconium peritonitis
- Intestinal obstruction from atresia
- Stenosis
- Esophageal webs
- Volvulus of a gut





Algorithmic approach to the children with acute abdominal pain requiring urgent management

Chronic and recurrent abdominal pain-

TERMINOLOGY

- ▶ Chronic and recurrent abdominal pain are common symptoms in children and adolescents
- ▶ Chronic abdominal pain can be organic or nonorganic, depending on whether a specific etiology is identified
- ▶ Nonorganic abdominal pain or functional abdominal pain refers to pain without evidence of anatomic, inflammatory, metabolic, or neoplastic abnormalities
- ▶ Overlap between chronic and recurrent abdominal pain exists, and the terms are sometimes used synonymously.

Chronic abdominal pain in children

- Chronic abdominal pain (long-standing intermittent or constant abdominal pain) is common in children and adolescents
- In most children, chronic abdominal pain is functional, that is, without objective evidence of an underlying organic disorder
- Yet, an important part of the physician's job is to determine which children have **an organic disorder**
- Children with chronic abdominal pain are more likely than children without chronic abdominal pain to have headache, joint pain, anorexia, vomiting, nausea, excessive gas, and altered bowel symptoms

Chronic abdominal pain in children

- The physician must decide whether to order **diagnostic tests** and, if so, which tests.

The presence of alarm symptoms or signs suggests a higher pretest probability or prevalence of organic disease and may justify the performance of diagnostic tests.

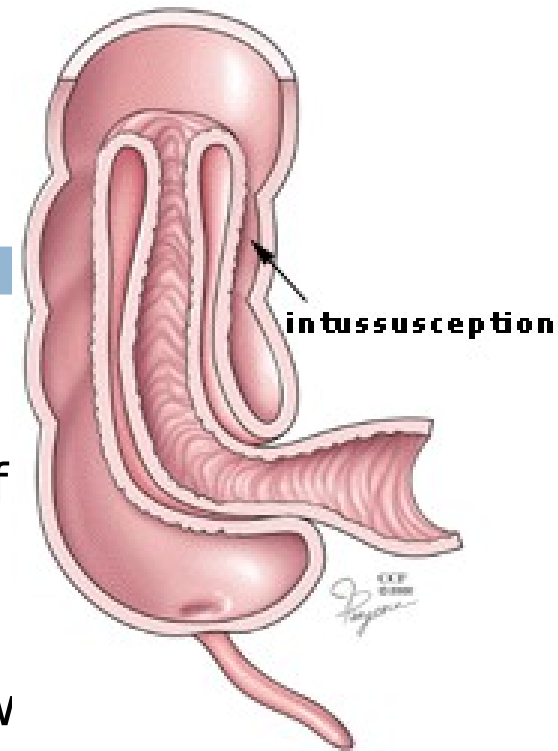
Red flag symptoms

- Localisation of pain away from the central abdominal region
- Pain associated with changes in bowel habit, particularly diarrhoea, constipation or nocturnal bowel movement
- Pain associated with night-waking
- Constitutional symptoms such as recurrent fever, and loss of appetite and energy
- RAP in very young children aged < 4 years
- History of weight loss or poor growth
- Recurrent unexplained fever
- Recurrent bloody stools
- Unexplained pallor

Some causes of abdominal pain- more information



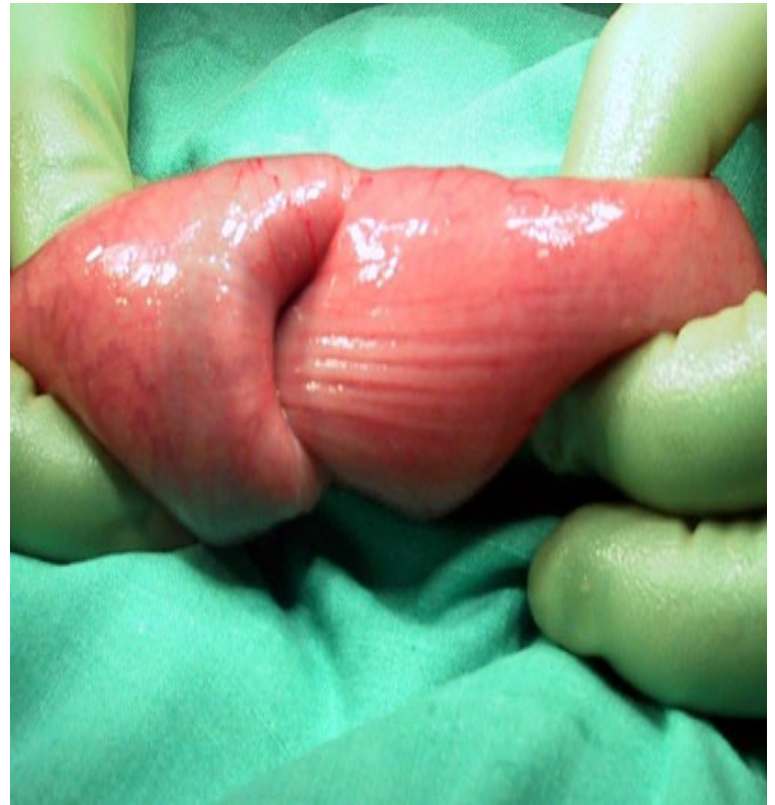Intussusception- a surgical abdomen



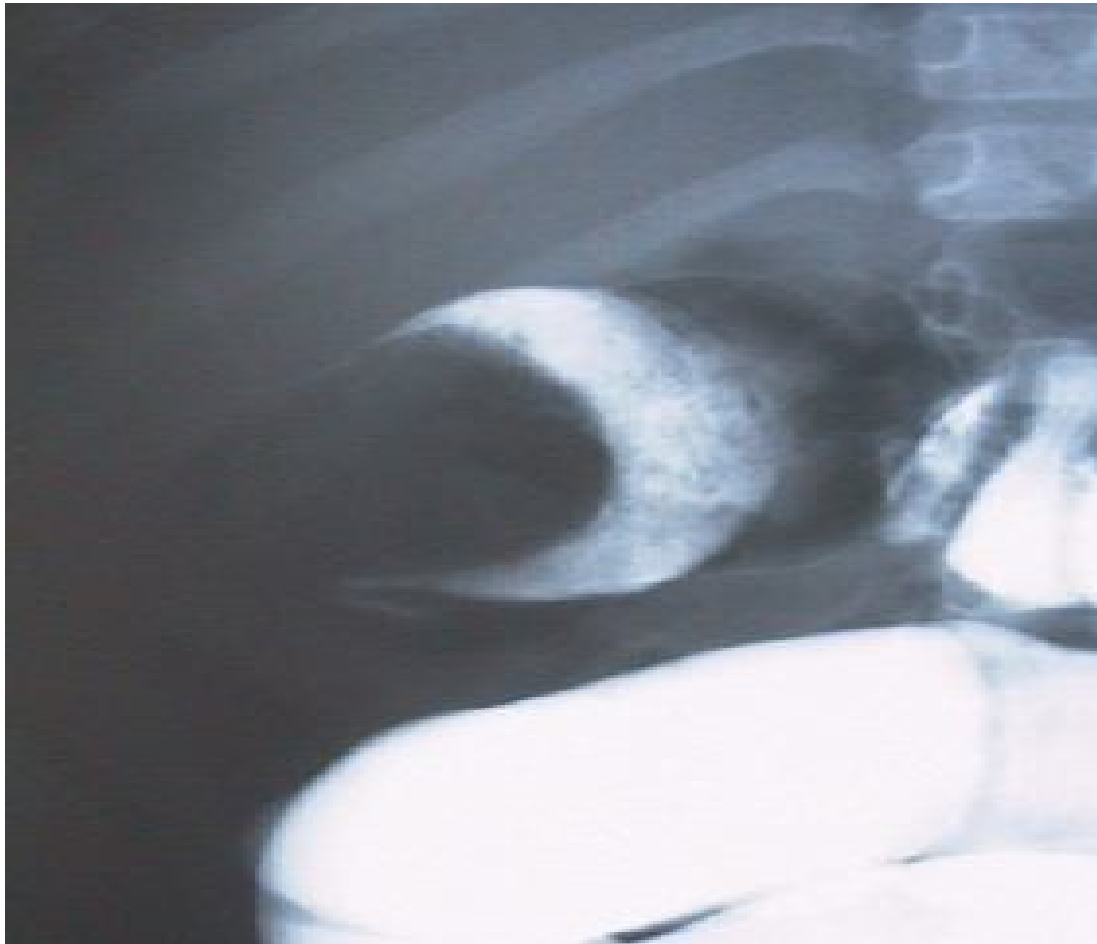- invagination of one part of intestine into itself
- age < 1 year, neonates seldom
- etiology: 90% idiopathic = unknown
(2-7%)- viral infection w
patches enlarged, Meckel's diverticulum, polyps, enteric
duplications, Henoch-Schonlein purpura, tumors
(lymphoma),
- patomechanism: mesentery entrapped→ venous
compression→ cessation of arterial circulation→
ischemia→ necrosis
- localisation: 75% ileocolic, 15% ileo-ileocolic, 10%
ileoileal, colocolic

Intussusception- a surgical abdomen

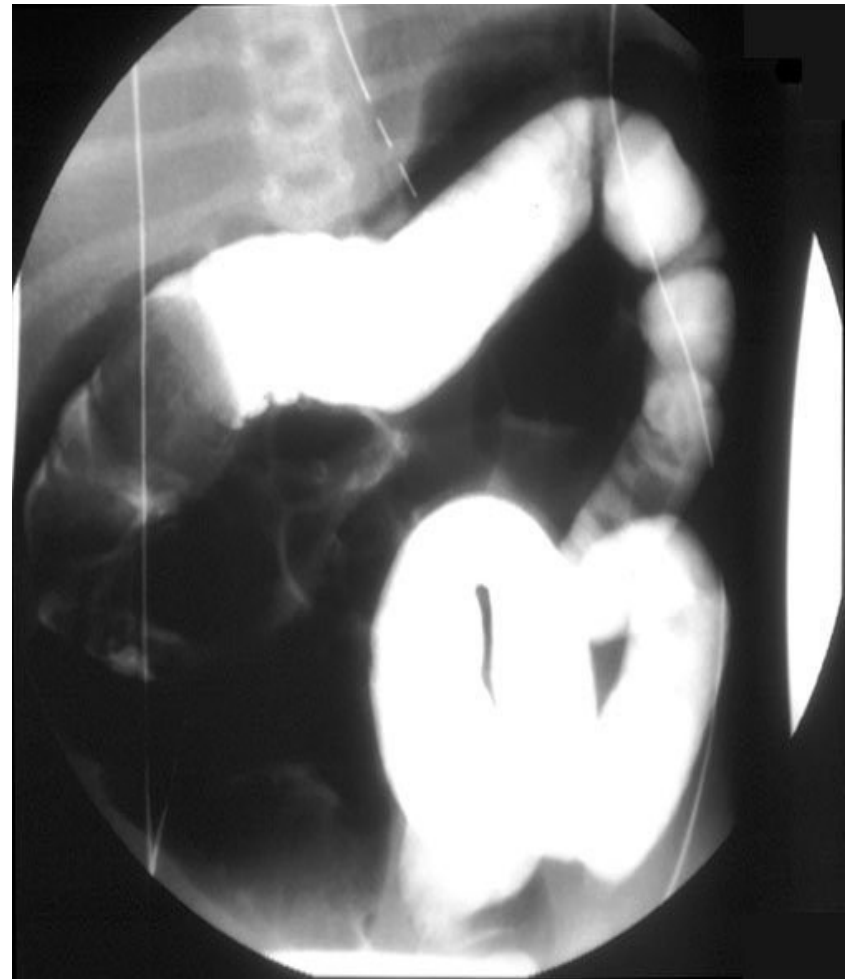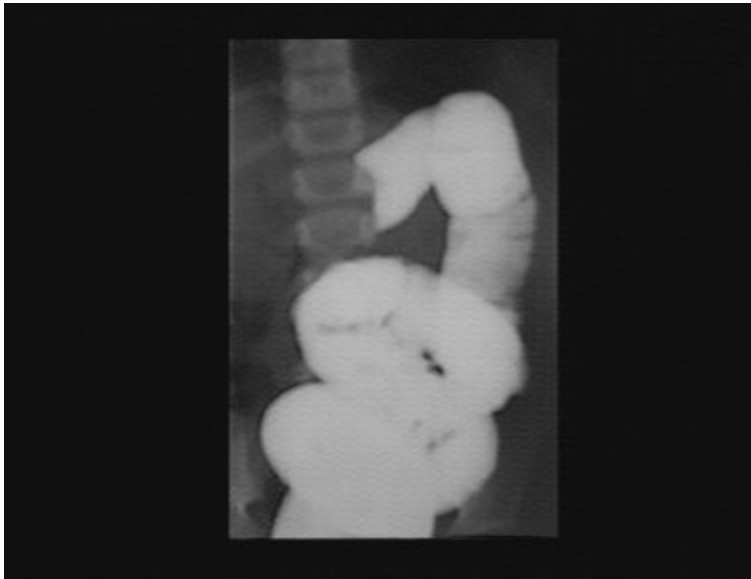
- symptoms: colicky abdominal pain with intervals of wellness, bloody stools- „red jelly”, projectile vomiting
- asymptomatic- altered states of consciousness
- physical examination: „sausage shaped” mass, intinsic peristaltic movements ahead, silence behind the intussusception
- diagnosis: usg, barium enema (ileocecal junction)+ treatment (hydrostatic reduction)-5% recurrent
- surgical reduction-3% recurrence rate



Intussusception- radiology



Intussusception- barium enema



Pyloric Stenosis

- More common in boys than girls
- First born most commonly affected
- Family history in 10% patients
- Unexplained hypertrophy of the circular muscles of the pylorus develops
- Short history of vomiting in a baby of 2-8 weeks of age
- Vomit may contain altered blood, non bile stained
- Upper abdo may be distended, visible gastric

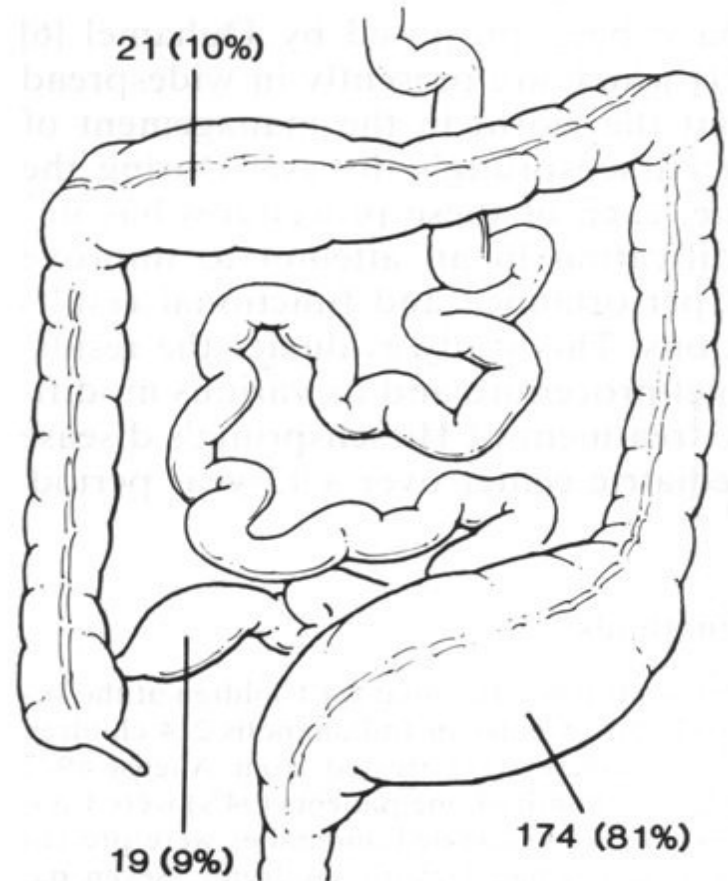
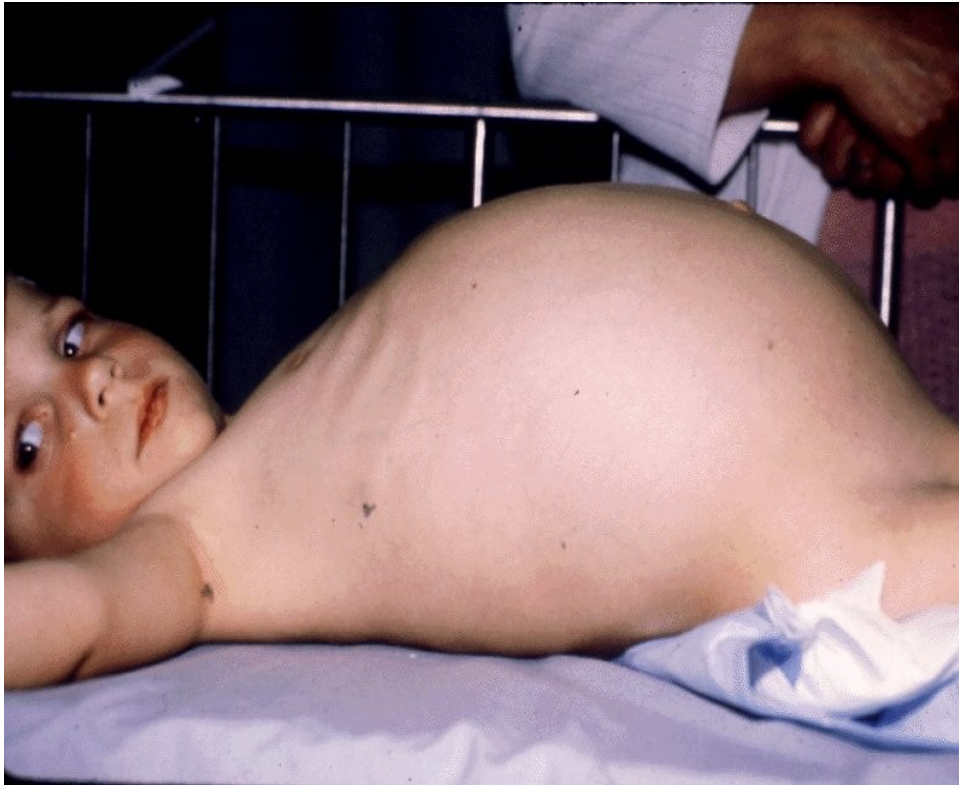Hirschprung's disease

- Etiology- congenital abnormality- inheritance pattern autosomal dominant with reduced penetrance (risk closer to 50%), mutations inactivating RET gene cause a susceptibility to HD, defective stem cells?
- Epidemiology: 1/5000 newborn
- Result- the absence of ganglion cells (parasympathetic ganglion cells) from the myenteric and submucosal plexuses of part of the large bowel due to changes in the proliferation, survival and migration of neural crest cells, narrow, contracted segment (75%-rectosigmoid, 10% entire colon), secondary dilatation of proximal colon

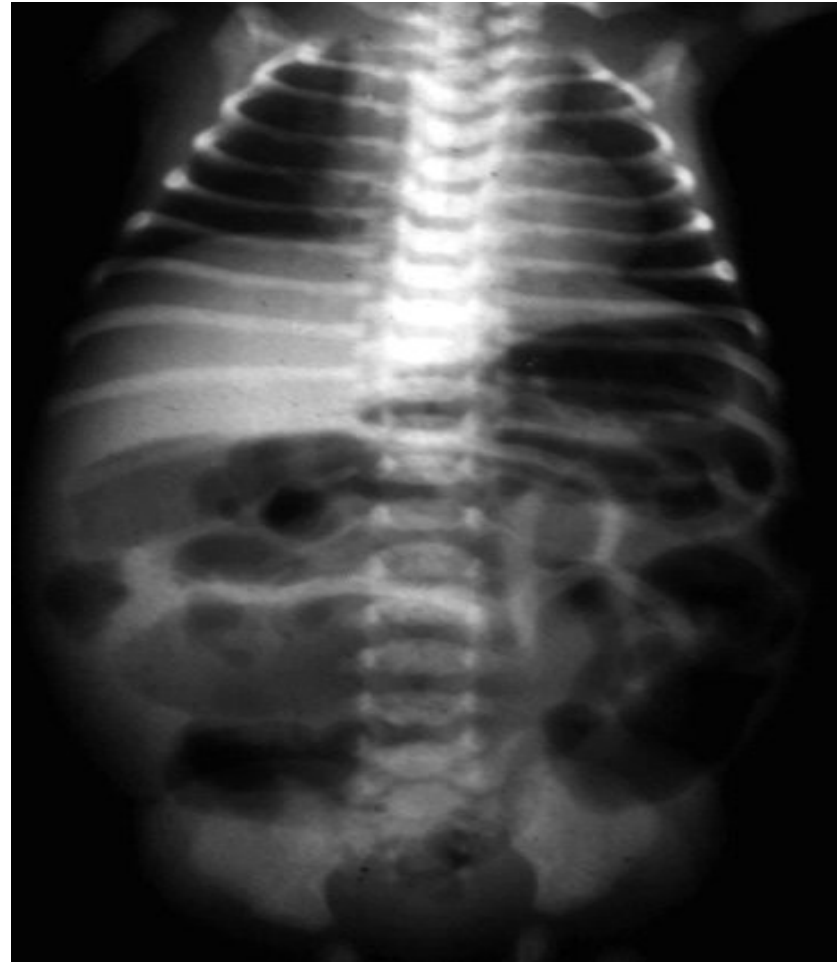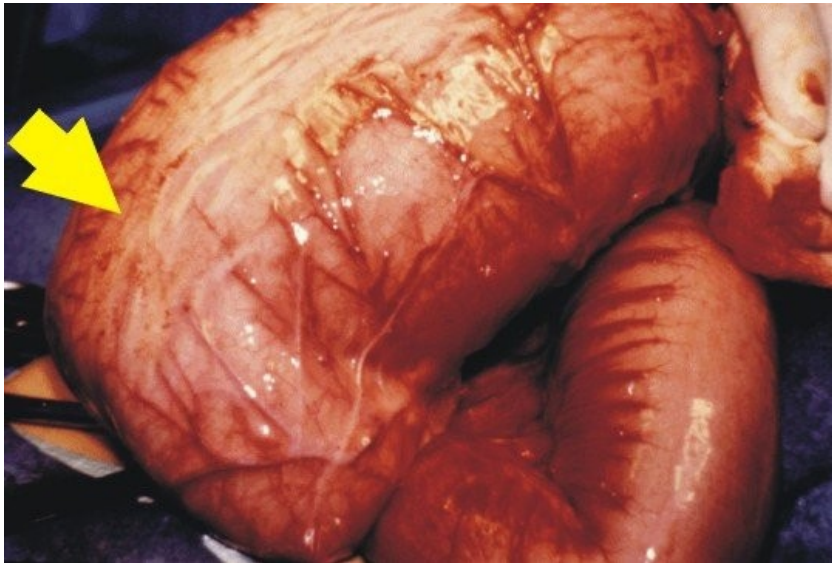Hirschprung's disease

- Symptoms: first 24 hours of life- intestinal obstruction □ meconium ileus, abdominal distention, bile-stained vomiting, constipation, fever, enterocolitis, dehydration, death if not treated
- Rectal examination- narrow segment
- Treatment: surgery in 2 stages: colostomy with the creation of stoma, closure of stoma with removal of narrow part of bowel, perform a „pull-through” procedure to connect functional bowel to anus

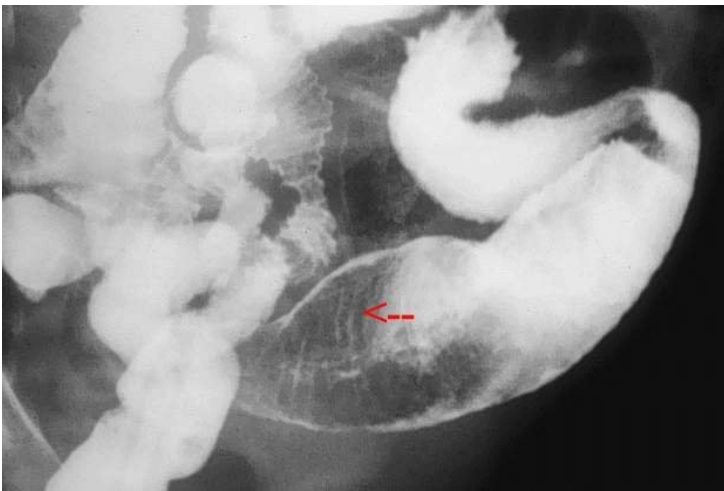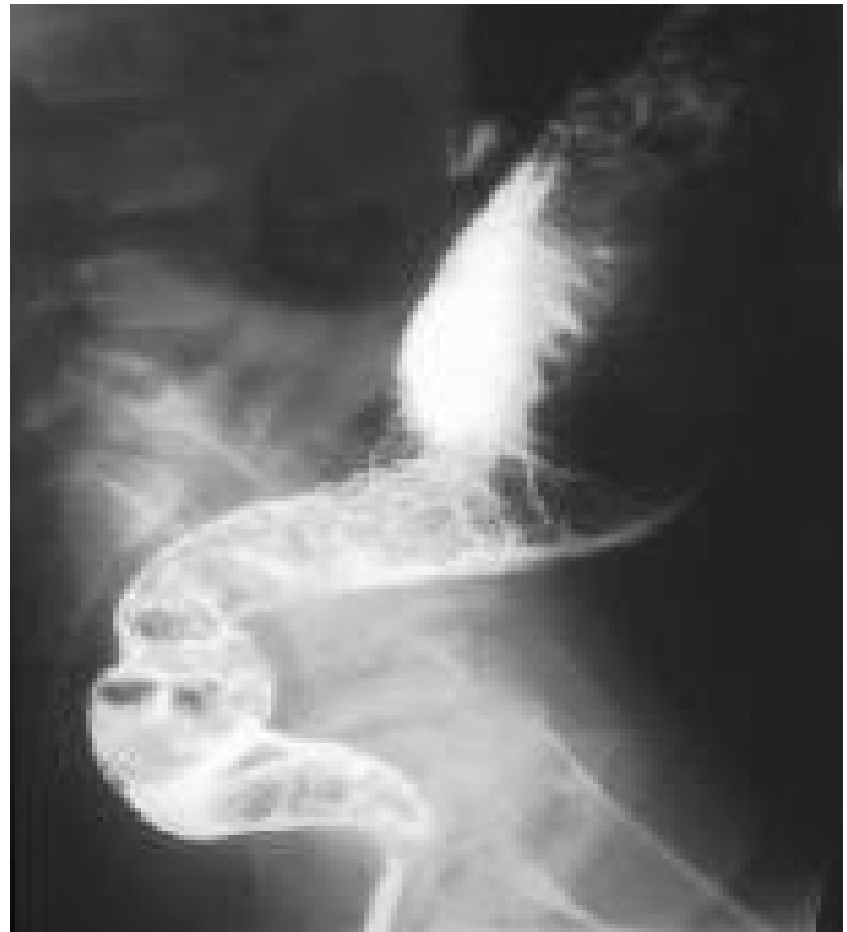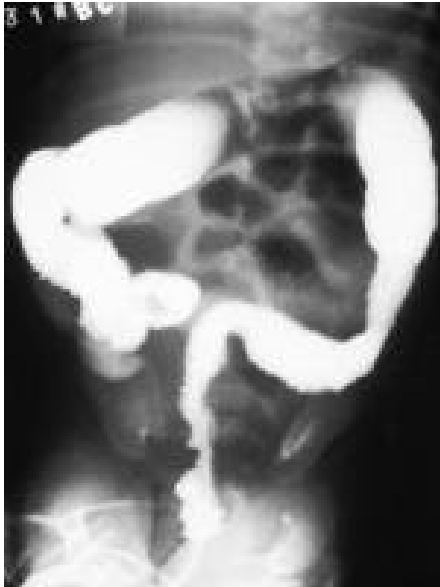Hirschsprung disease- abdomen distention (left), the localisation (right)



Hirschprung disease- megacolon

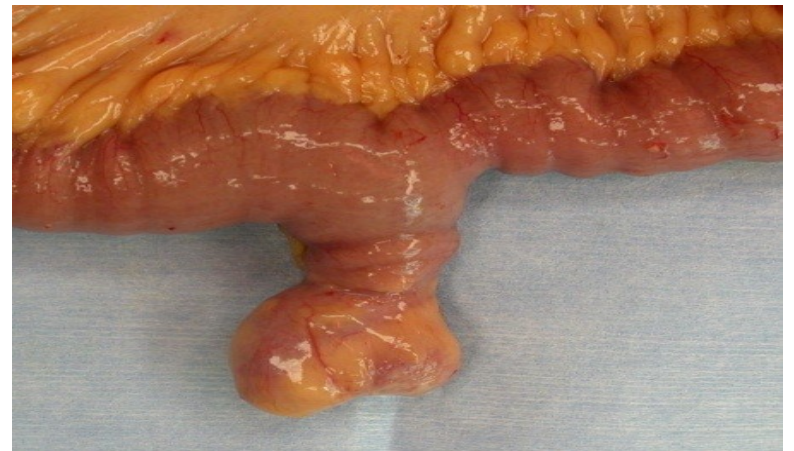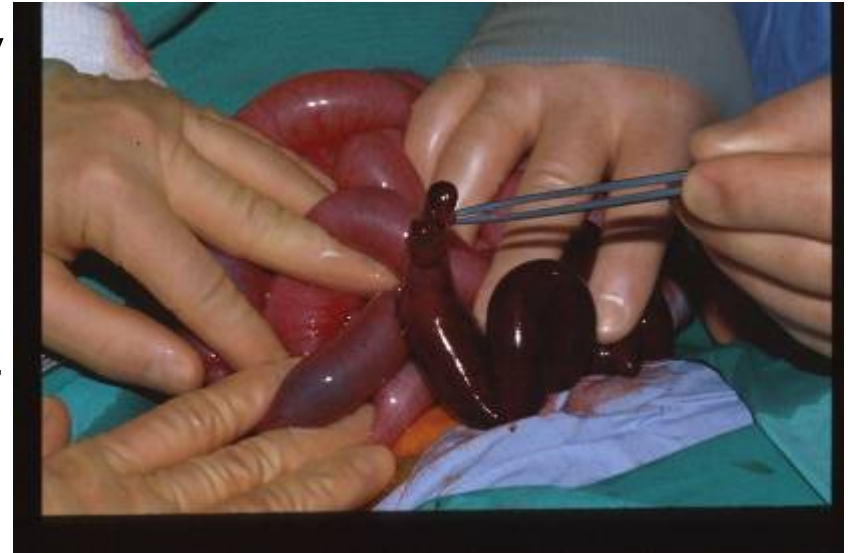


Hirschsprung disease- dilatation of colon, narrow rectum



Meckel's diverticulum

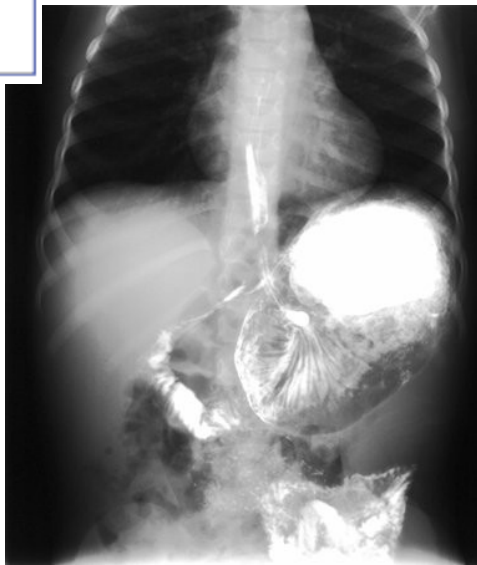
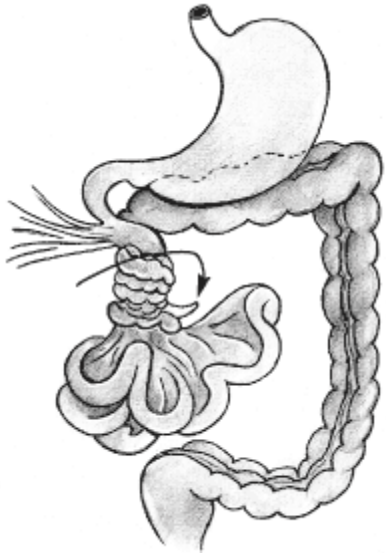
- Most common congenital anomaly involving the small bowel and terminal ileum (2% of population), 2:1- male: female
- Remnant of omphalomesenteric duct (Vitelline duct), 2 feet from ileocecal valve, 2 inches in length, 2 types of ectopic tissue: gastric and pancreatic
- Symptoms: asymptomatic, (2% symptomatic)- most < 2 yrs of life, hemorrhage, intussusception, volvulus, diverticulitis
- 2 main complications: bleeding, obstruction
- Diagnosis: scintigraphy with 99-Tc-pertechnetate, sensitivity and specificity is 85-95%.



Abdominal pain in childhood- mesenteric lymphadenitis

- Poorly defined symptoms
- MA is self limited inflammatory process that affects the mesenteric lymph nodes in RLQ
- Thought that inflammation of mesenteric lymph nodes leads to peritoneal reaction
- Site of tenderness may shift when child moves position
- 'active observation' useful
- Leucocytosis is common
- Diagnosis is one of exclusion
- Ultrasound
- A persisting localized tenderness lasting more than 3-6hrs may warrant surgical exploration

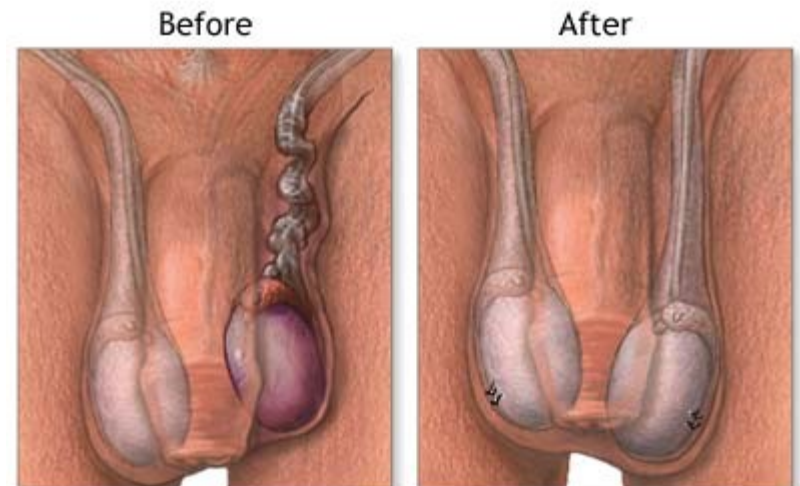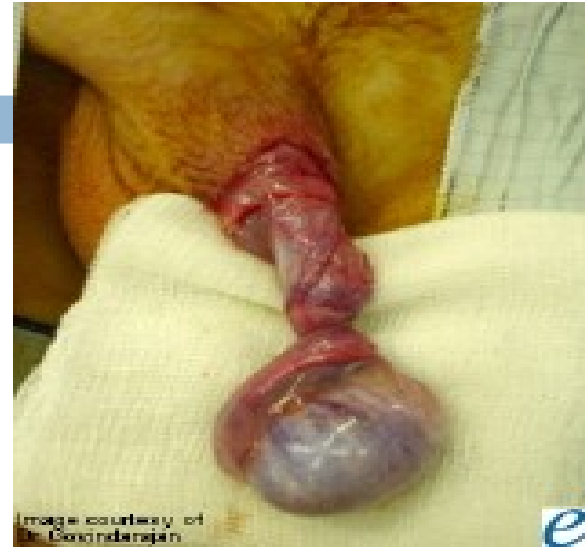Volvulus



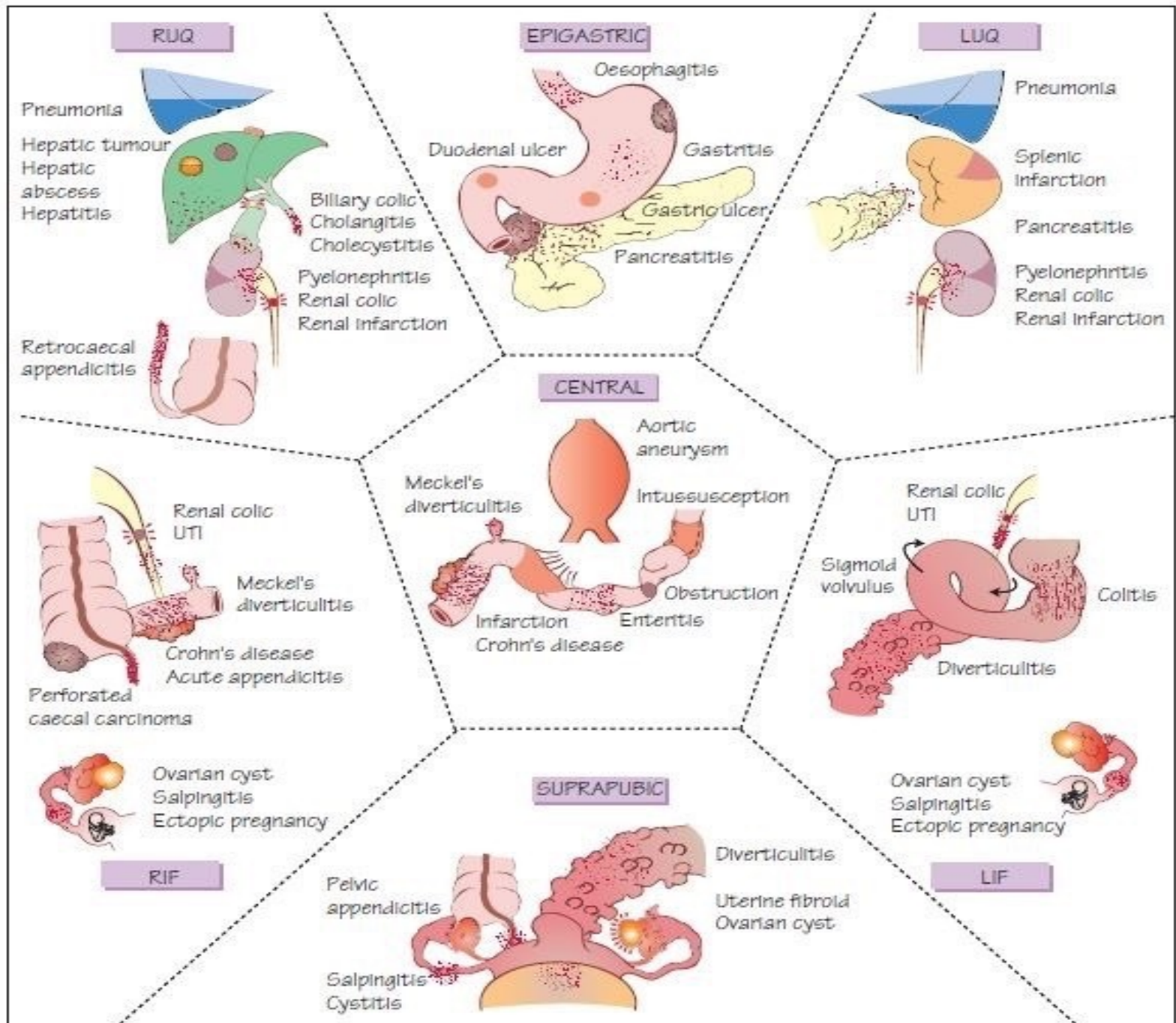
- ❑ Malrotation of bowel may predispose infant to volvulus
- ❑ Bowel become twisted
- ❑ Up to 90% in children younger than 1yr
(up to 60% in 1st month of life)
- ❑ Male: female presentations 2:1
- ❑ Babies who present in first week of life tend to have more severe obstruction
- ❑ Bilious vomiting, apnoeic episodes, bloody stool, abdo pain, shock

Testicular Torsion

- Teenage boys
- May occur from strenuous exercise or injury, or no apparent cause
- Sudden and severe pain.
- Swelling and tenderness on the side of scrotum that is affected (more often on the right side).
- The testicle becomes sore and extremely tender.
- Associated nausea and vomiting
- The scrotum may also become red and inflamed
- Surgery needed within 6 hours



Clinical features	Organic	Non organic
Site of pain	Flanks, suprapubic, RUQ, RLQ	Central, epigastric
Family History- particularly of abdo pain, headache and depression	Less likely, but take note of IBS	Likely
Psychological factors - particularly anxiety	Less likely	Likely, especially anxiety
Headache	Less likely	More likely
Alarm symptoms	Vomiting generally equally likely but beware persistent or significant vomiting. Chronic severe diarrhoea more likely. Unexplained fever.	Alarm symptoms less likely
Abnormal signs	Present	Absent
Abnormal growth/ and or weight loss	Present	Absent
Abnormal investigations	Expected	Not found





- a diagnostic dilemma!
- many cases of abdominal pain are benign, some require rapid diagnosis and treatment to minimize morbidity
- numerous disorders can cause abdominal pain
- the most common medical cause is gastroenteritis, and the most common surgical cause is appendicitis
- in most instances, abdominal pain can be diagnosed through the history and physical examination.
- age is a key factor in evaluating the cause
- in the acute surgical abdomen, pain generally precedes vomiting, while the reverse is true in medical conditions



- diarrhea often is associated with gastroenteritis or food poisoning
- appendicitis should be suspected in any child with pain in the right lower quadrant
- signs that suggest an acute surgical abdomen include involuntary guarding or rigidity, marked abdominal distention, marked abdominal tenderness, and rebound abdominal tenderness.
- selected imaging studies also might be helpful
- surgical consultation is necessary if a surgical cause is suspected or the cause is not obvious after a thorough evaluation.